

AD_____

Award Number: W81XWH-11-2-0142

TITLE: Alginate Oligomers to Treat Infectious Microbial Biofilms

PRINCIPAL INVESTIGATOR: Dr. Chandan Sen

CONTRACTING ORGANIZATION: Ohio State University
Columbus, OH 43210

REPORT DATE: June 2012

TYPE OF REPORT: Annual

PREPARED FOR: U.S. Army Medical Research and Materiel Command
Fort Detrick, Maryland 21702-5012

DISTRIBUTION STATEMENT: Approved for Public Release;
Distribution Unlimited

The views, opinions and/or findings contained in this report are those of the author(s) and should not be construed as an official Department of the Army position, policy or decision unless so designated by other documentation.

REPORT DOCUMENTATION PAGE				Form Approved OMB No. 0704-0188	
Public reporting burden for this collection of information is estimated to average 1 hour per response, including the time for reviewing instructions, searching existing data sources, gathering and maintaining the data needed, and completing and reviewing this collection of information. Send comments regarding this burden estimate or any other aspect of this collection of information, including suggestions for reducing this burden to Department of Defense, Washington Headquarters Services, Directorate for Information Operations and Reports (0704-0188), 1215 Jefferson Davis Highway, Suite 1204, Arlington, VA 22202-4302. Respondents should be aware that notwithstanding any other provision of law, no person shall be subject to any penalty for failing to comply with a collection of information if it does not display a currently valid OMB control number. PLEASE DO NOT RETURN YOUR FORM TO THE ABOVE ADDRESS.					
1. REPORT DATE June 2012		2. REPORT TYPE Annual		3. DATES COVERED 10 May 2011 – 9 May 2012	
4. TITLE AND SUBTITLE Alginate Oligomers to Treat Infectious Microbial Biofilms				5a. CONTRACT NUMBER	
				5b. GRANT NUMBER W81XWH-11-2-0142	
				5c. PROGRAM ELEMENT NUMBER	
6. AUTHOR(S) Dr. Chandan Sen E-Mail: chandan.sen@osumc.edu				5d. PROJECT NUMBER	
				5e. TASK NUMBER	
				5f. WORK UNIT NUMBER	
7. PERFORMING ORGANIZATION NAME(S) AND ADDRESS(ES) Ohio State University Columbus, OH 43210				8. PERFORMING ORGANIZATION REPORT NUMBER	
9. SPONSORING / MONITORING AGENCY NAME(S) AND ADDRESS(ES) U.S. Army Medical Research and Materiel Command Fort Detrick, Maryland 21702-5012				10. SPONSOR/MONITOR'S ACRONYM(S)	
				11. SPONSOR/MONITOR'S REPORT NUMBER(S)	
12. DISTRIBUTION / AVAILABILITY STATEMENT Approved for Public Release; Distribution Unlimited					
13. SUPPLEMENTARY NOTES					
14. ABSTRACT War burn wounds become colonized with pathogenic microorganisms including Acinetobacter (ACETB) & Pseudomonas (PSEUD) leading to formation of biofilms. The following two hypotheses have been proposed to test the efficacy of AlgiPharma's alginate oligomer (Oligo G) in disrupting biofilms for treatment of microbial infections as well as an adjuvant effect for other therapies such as antibiotic treatment. Hypothesis-1 Biofilm is formed on pre-clinical full-thickness porcine burn wounds and impairs healing. Hypothesis-2. OligoG inhibits biofilm formation and potentiates antibiotic activity against gram negative infected wounds. As per timeline, the studies (4 sub aims) proposed to test Hypothesis-1 have concluded in year1. We have successfully Developed and characterized the first reproducible pre-clinical large animal (porcine) model of biofillm infection in burn injuries. We show that biofilm infections increase inflammation and impair healing of burn wounds. This model is likely to facilitate the early development and testing of novel (and existing) treatment interventions with proposed anti-bacterial or anti-biofilm therapies in skin injuries. Development of such model is critical in the translation of this program to clinical practice. The next step will be to take the findings of the proposed study to clinical testing of OligoG.					
15. SUBJECT TERMS Biofilm, Burn wounds, debridement, therapeutics, wound healing					
16. SECURITY CLASSIFICATION OF:			17. LIMITATION OF ABSTRACT	18. NUMBER OF PAGES	19a. NAME OF RESPONSIBLE PERSON
a. REPORT	b. ABSTRACT	c. THIS PAGE			USAMRMC
U	U	U	UU	11	19b. TELEPHONE NUMBER (include area code)

Table of Contents

	<u>Page</u>
Introduction.....	1
Body.....	1
Key Research Accomplishments.....	6
Reportable Outcomes.....	6
Conclusion.....	7
References.....	7
Appendices.....	N/A

INTRODUCTION

Biofilms pose significant threat to military wounds^{1,2}. According to the Center for Disease Control 60% of all chronic infections in the United States are related to biofilms, which are difficult to eradicate. New treatments with topical agents that inhibit biofilm formation or promote their detachment and reduce wound infections would have a significant impact not only for military medicine, but also for civilian hospitals, wound care centers, and trauma units worldwide. Lack of pre-clinical models poses a serious impediment to biofilm research. The present proposal seeks to develop a novel porcine **pre-clinical model of multispecies biofilm** on burn wounds and study its role in impaired healing. The study focusses on the **efficacy of the alginate oligomer OligoG** on eradicating biofilms from experimental burn wounds. As such, this proposal presents a novel solution to the problem of biofilms by exploiting the potential of OligoG to modulate bacterial colonization and infection of wounds.

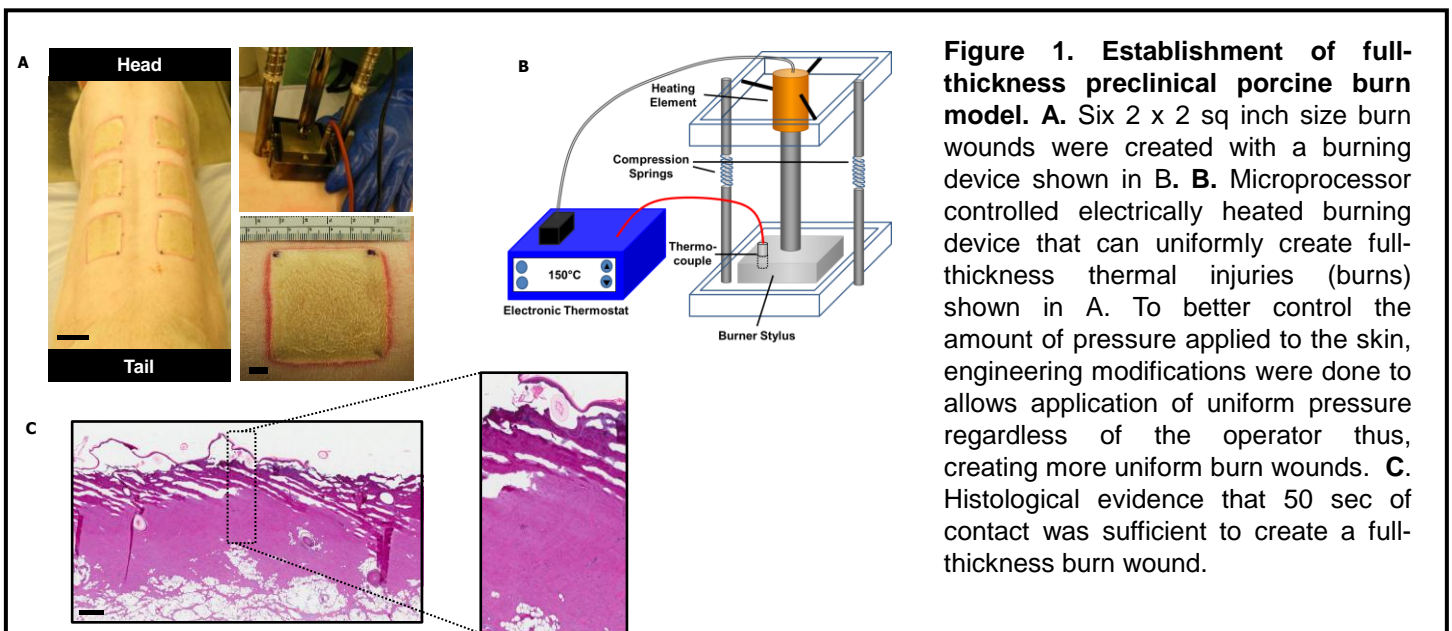
BODY: STATEMENT OF WORK update

The proposal seeks to address the following hypotheses utilizing a novel pre-clinical approach to study the efficacy of OligoG. As per suggested time-line in **Statement of Work**, we present data and finding of work proposed in Hypothesis 1.

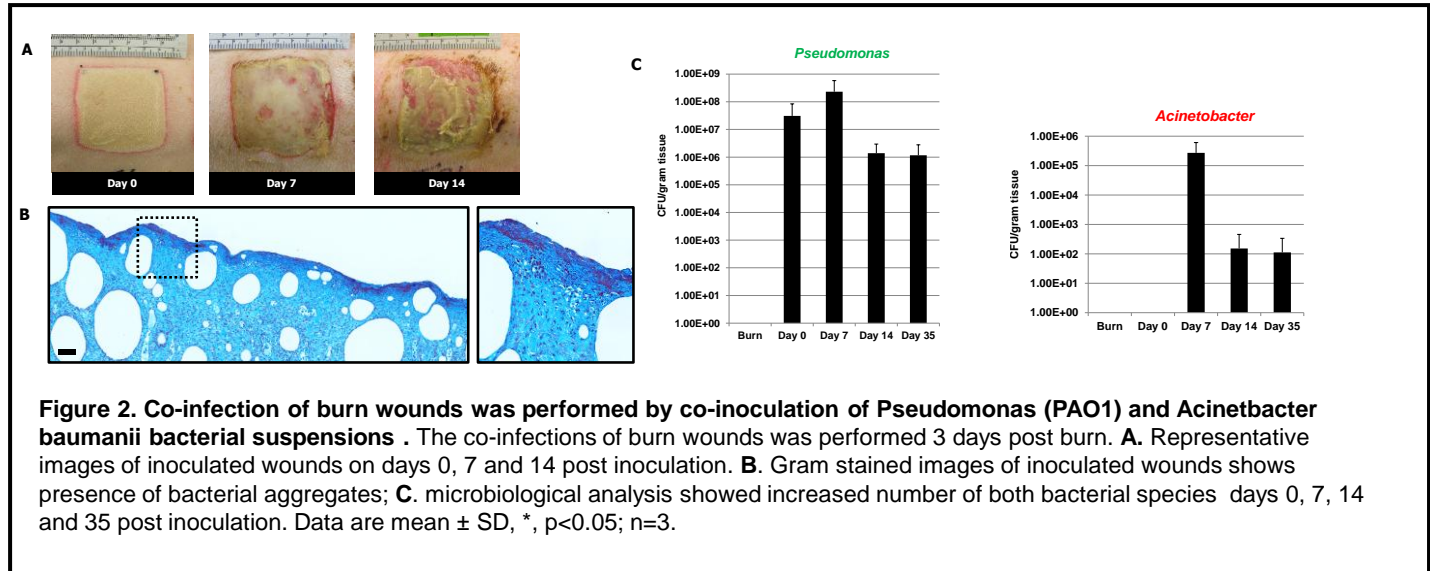
Hypothesis 1. Biofilm is formed on pre-clinical full-thickness porcine burn wounds and impairs healing.

Hypothesis 1.1 *Acinetobacter spp (ACETB) / Pseudomonas spp (PSEUD) forms biofilm on full thickness experimental burns on preclinical porcine model.*

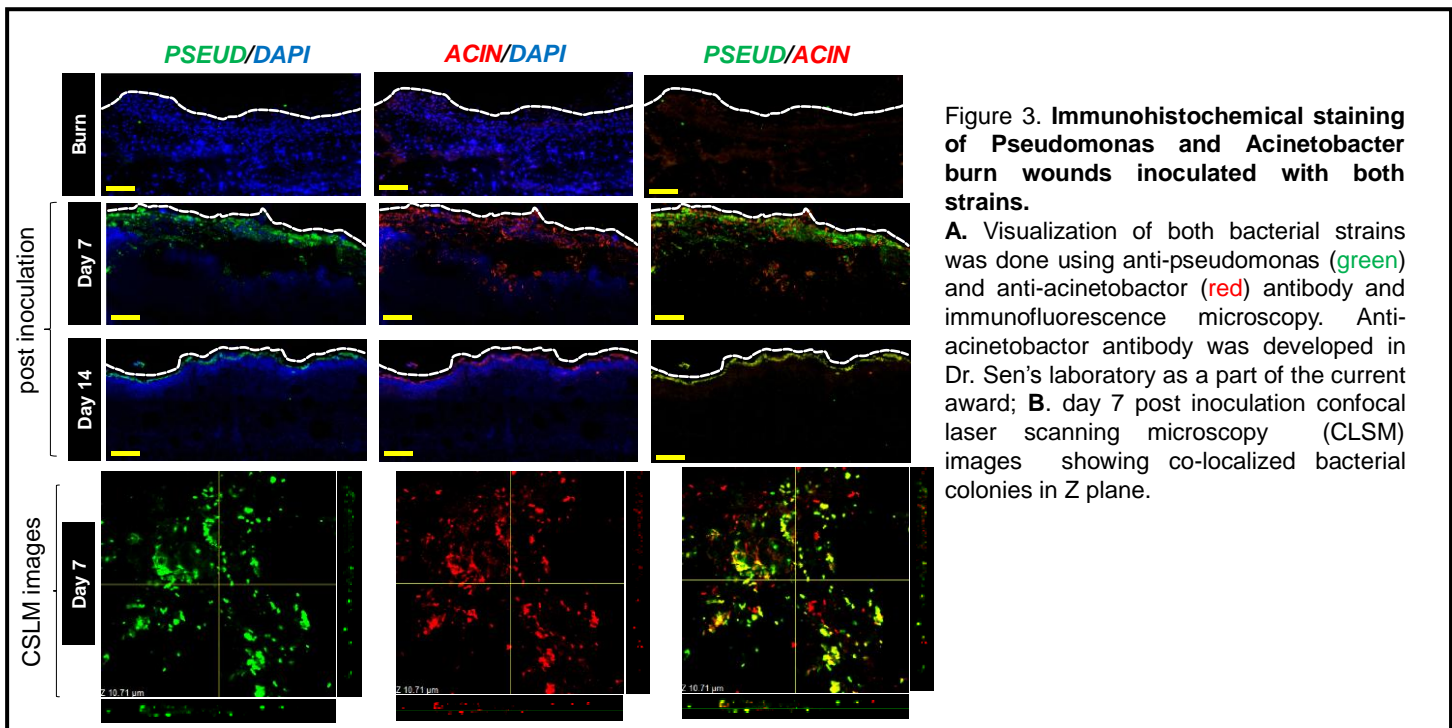
There is no prior report of any large animal pre-clinical model for biofilms. Development of such pre-clinical large animal model would enable screening of therapeutics as well as help understand mechanisms underlying impaired healing. The porcine model has been favored over other animals for studying burn injuries due to: anatomical, biochemical and physiological considerations³⁻⁵. **The first objective of the proposal was to establish a standardized multispecies biofilm infection model of porcine burn injury.** To perform a standardized approach for porcine burn injury, we constructed a large microprocessor controlled electrically heated burning device that can uniformly create full-thickness thermal injuries (burns) that are 2 x 2 sq inch in size (Figure 1). While performing routine histology, we noticed that applying the burn device on the back of porcine manually by individual researchers was causing variations in the degrees of burn. To better control the amount of pressure applied, we made some engineering modifications to the current device that now allows application of uniform pressure regardless of the operator thus, creating reproducible burn wounds. (Figure-1).



Next we established a standardized approach of inoculating the bacteria into the burn wounds. Topical application versus intra-dermal injection and low bacterial load (5×10^3) versus high bacterial load (5×10^7) were tested. Sampling of these wounds was done at various time points after inoculation. Visual inspection of the wounds revealed yellowish green discoloration with discharge that increased with time (**Figure 2**). Histological analysis using gram staining and microbiological analysis confirmed the presence of bacteria in wound bed. Infected animals maintained localized infections in the wound-site, no evidence of systemic infection was observed (**data not shown**).



Co-infection. Military casualties are known to be at high risk of acquiring MDR infections and increasing numbers of cases of MDR septicemia, urinary tract infections, and ventilator-associated pneumonia have been



reporte⁶⁻⁸. The most frequently identified MDR bacteria include *Acinetobacter baumannii*, *Pseudomonas aeruginosa*, *Staphylococcus aureus*, and *Klebsiella pneumoniae*. *Acinetobacter baumannii* is among the most significant bacterial species that is associated with battle casualties and represents a major threat in battlefield related wounds today^{6,7,9,10}. **Multidrug resistant *Acinetobacter* sp (ACETB)/ *Pseudomonas* (PSEUD) are among the most significant bacterial species that are associated with battle wound casualties^{8,11,12} and with a wide spectrum of infectious diseases ranging from nosocomial to community-acquired infections to**

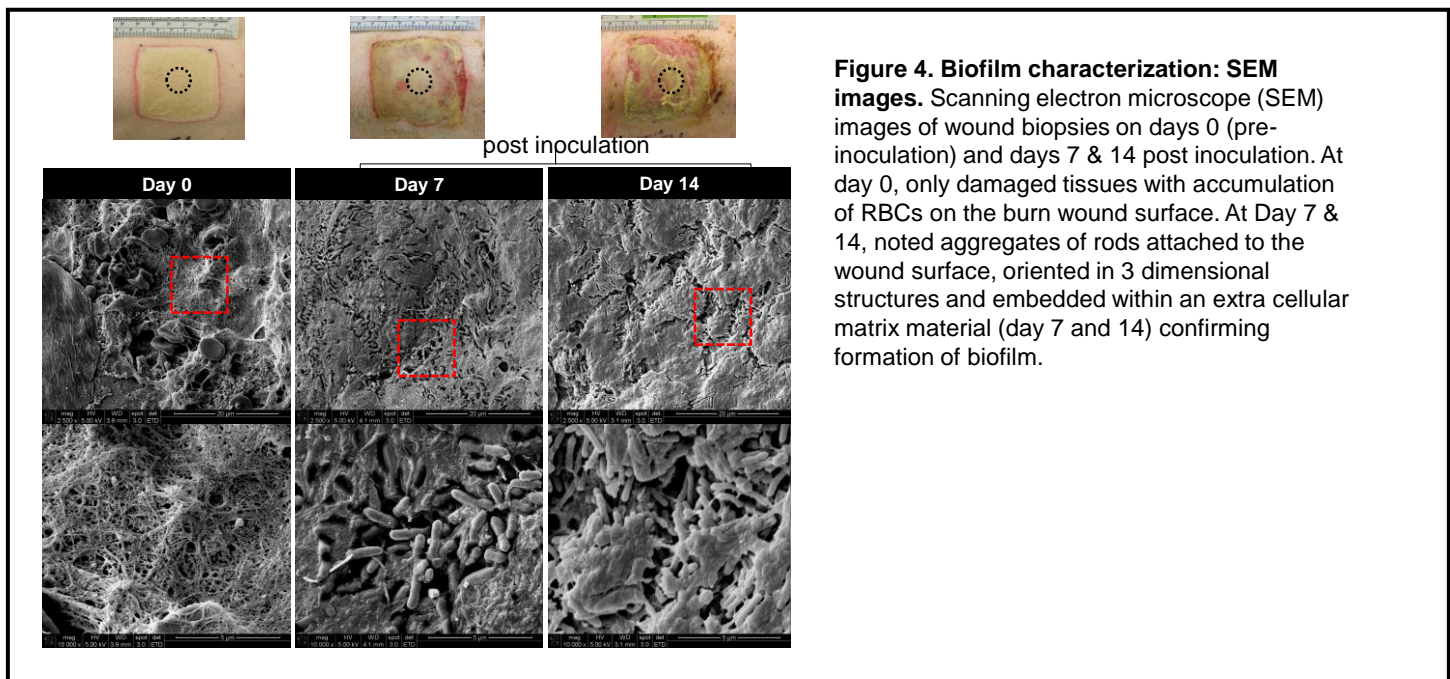
those acquired following war or natural disaster. Thus, we chose to perform a **multispecies infection** using *Acinetobacter baumannii* and *Pseudomonas aeruginosa* co-infection. Following infection, visualization of bacterial species in burn wounds is essential to determine localization of biofilm in wounds. Our collaborator had already developed an anti-pseudomonas antibody. Anti-acinetobacter antibody was not available. We **developed an antibody specific against *Acinetobacter***. Immunohistochemical (IHC) optimizations using anti-Pseudomonas and anti-*Acinetobacter* antibody was performed. Visualization of acinetobacter and pseudomonas were done by imaging with a confocal laser scanning microscope (CLSM). The CLSM images confirm presence of both *Acinetobacter* & *Pseudomonas* in inoculated burn wounds on 7, 14, and 35 days after inoculation (**Figure 3**). More interestingly, at higher magnification of confocal laser scanning microscopy (CLSM) we can see some areas of co-localization of both bacterial strains (**Figure 3**).

Next, the characterization of biofilm formation by co-infection was performed. The standard criteria for formation of biofilm includes¹³:

- i) adherence to a surface;
- ii) aggregates of bacteria in EPS
- iii) persistent & localized infection
- iv) anti-microbial drug resistance.

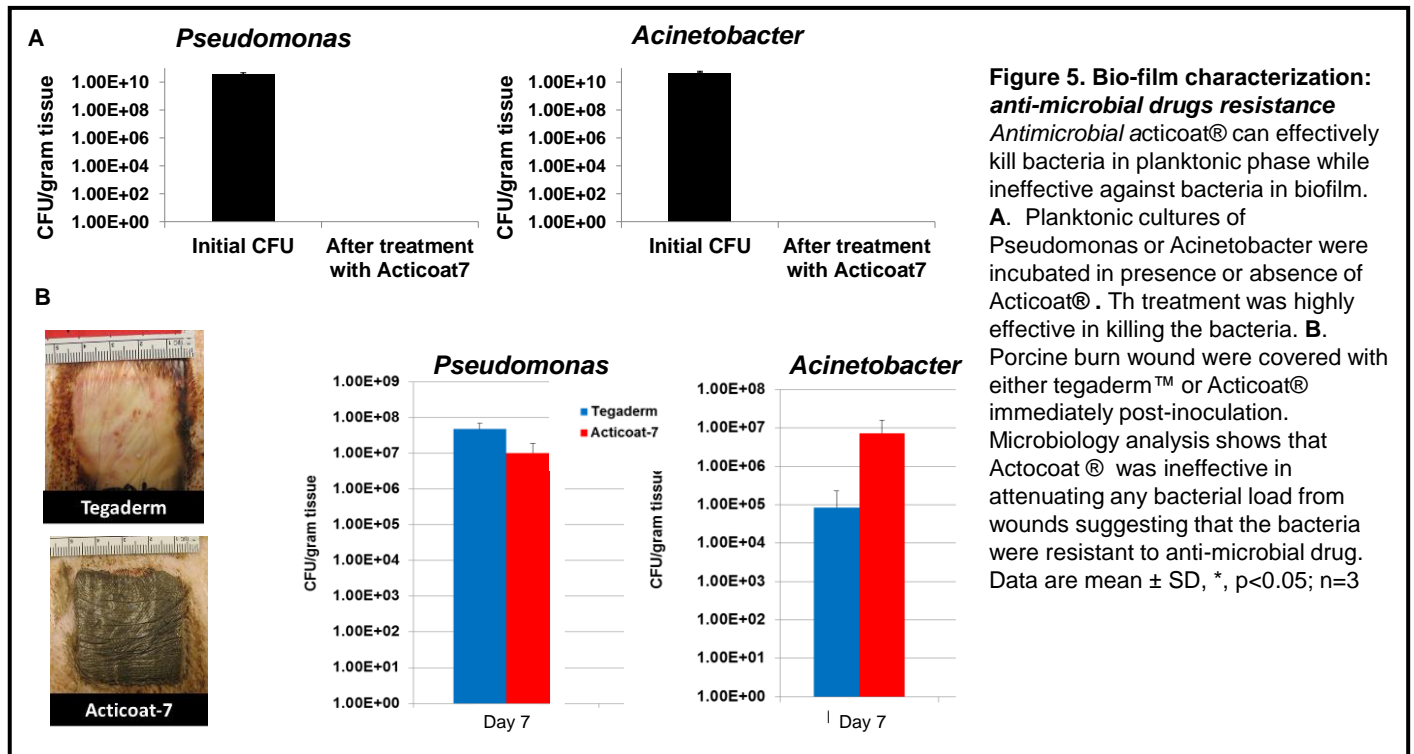
The following data demonstrate that the co-infection resulted in a biofilm:

- i) *adherence to a surface*: A flush technique was used. This technique removes the free (planktonic) bacteria from the burn wounds before taking the biopsies so that further analysis of the tissue biopsies will only determine the bacteria that are adherent to the wound surface. Washing was performed with double opened end sterile plastic tubes; 3 times with sterile saline and 1 time with a detergent (4% Tween in ddH₂O). Microbiology analysis shows that the bacterial counts did not significantly changed before or after flush.
- ii) *aggregates of bacteria in EPS*: Imaging of burn wound biopsies with scanning electron microscope (SEM) show aggregates of *P. aeruginosa* attached to the surface of the burn wounds and embedded in an EPS confirming formation of biofilm (**Figure 4**).



- iii) *Persistent & localized infection*: we observed that bacterial biofilms were present in the burn wounds till day 35 post inoculation. Blood cultures from the pigs did not show bacterial growth with no systemic signs of infection were observed in the animals suggesting the infection to be localized.

- iv) anti-microbial drugs resistance: Silver is the most prevalent topical antimicrobial used to prevent and treat bacterial infection and prevent wound sepsis¹⁴⁻¹⁷. To address this in a PI and co-I biweekly meeting, the use of silver dressing (Acticoat) as an antimicrobial agent for porcine burn wound in our study was suggested by Dr. Gordillo, a plastic surgeon co-I. Acticoat is routinely used as a part of standard of care of burn wounds in patients. The studies show that Acticoat can effectively kill



bacteria while in planktonic phase, however, was ineffective against bacteria in biofilm (**Figure 5**).

Hypothesis 1.2. Immunosuppression, as also noted in battlefield situation, facilitates biofilm development and persistence in burn wound

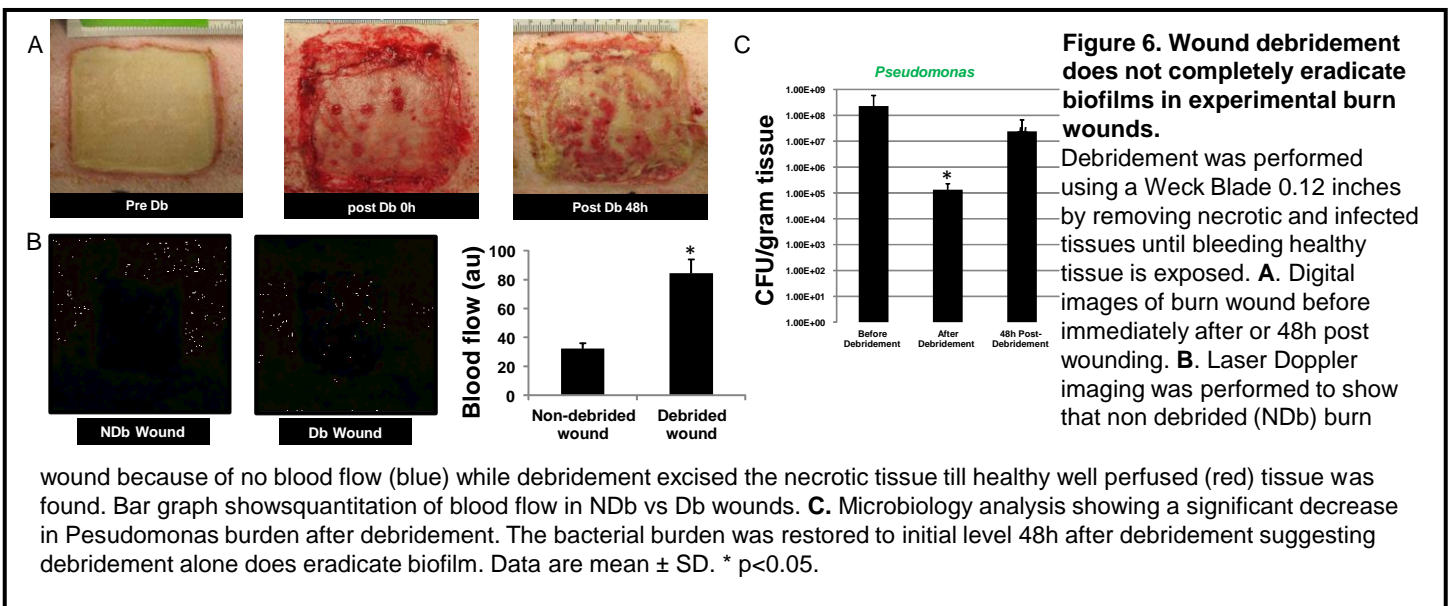
Immunosuppression were performed using long acting steroid (Depo-medrol 240 mg, IM). The studies indicated that there was no significant difference in the bacterial numbers in pigs treated with Depo-medrol (24h before establishing burn wounds) vs. pigs not treated with Depo-medrol. We reproduced immune-suppression in pigs but with increasing the dose of Depo-medrol to double, 24h before establishing burn wounds and 14 days later. Again, there was no significant difference in the bacterial numbers in pigs treated with Depo-medrol vs. pigs not treated with Depo-medrol. Thus, the hypothesis tested negative however, the data from these studies did not affect the overall scope of the as the project as the overarching hypothesis was that **Biofilm is formed on pre-clinical full-thickness porcine burn wounds** and impairs healing which we successfully have established by completing the studies proposed in hypothesis 1.1.

Hypothesis 1.3. Wound debridement does not completely eradicate biofilms in experimental burn wounds.

Debridement of wounds represents a key tool used to disrupt biofilms and facilitate healing. The question is whether such disruption is sufficient to eradicate the biofilm or is it a temporary relief which if not adequately addressed would re-establish the biofilm over time. Non-vital wound tissue is a “reservoir” for bacterial growth which facilitates the rapid re-establishment of wound microflora and wound biofilm. Therefore complete elimination of bacteria from the wounds does not occur. “Persister” bacteria within wounds remain in the deep tissues and re-colonize the wound within 48 hours¹¹.

Debridement was performed using a weck blade 0.12 inches by removing necrotic and infected tissues until bleeding healthy tissue was exposed. Debridement was performed as per standard of care in a clinical setting. Dr. Gordillo (plastic surgeon in the team) was involved for the procedure along with Dr. Bergdall (the veterinarian in the team). The experiments to test the hypothesis stated above will continue in the coming quarter. In control wounds (spontaneously colonized from skin flora), debridement was effective in preventing infection keeping the total bacterial burden below 10^3 , which is considered just colonization of the wounds.

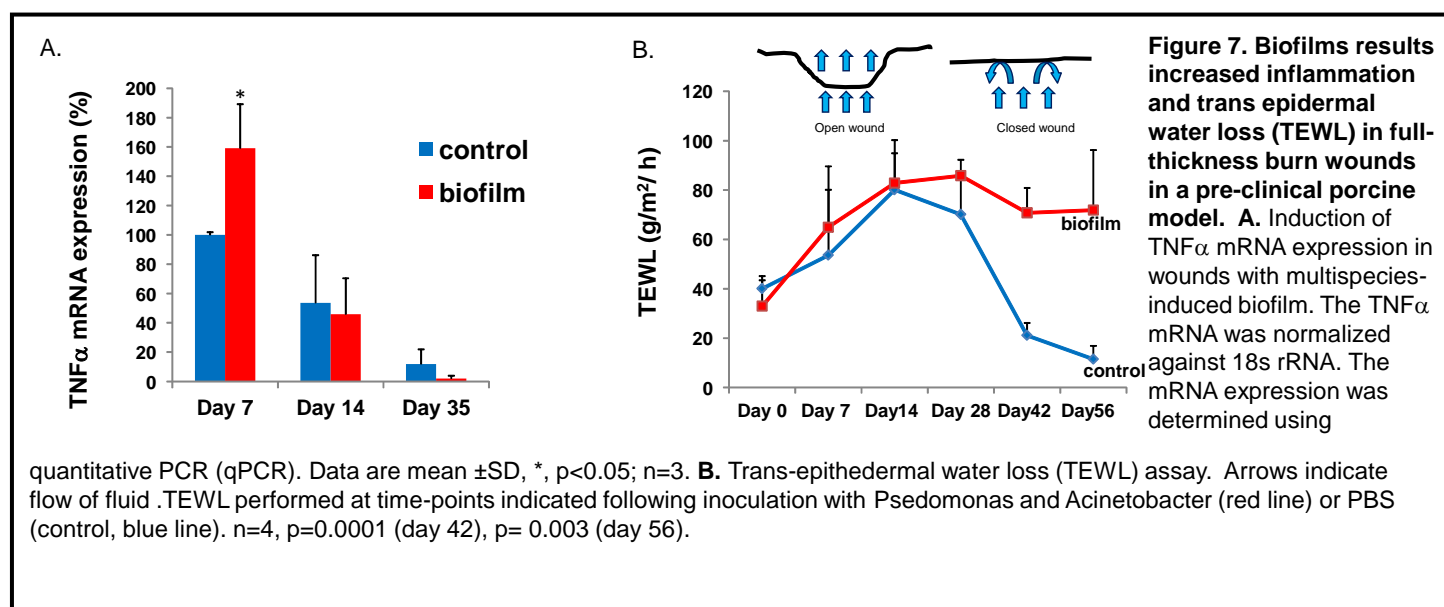
In wounds inoculated with *Pseudomonas* & *Acinetobacter* bacteria, debridement will be done 48h after 7th day post bacterial inoculation. We chose this time point as the 7th day was the first time point we utilized to identify biofilm structures in wound beds in our model, thus, we chose to perform debridement at that time point and look for re-colonization of the wounds 48h after debridement. In clinical reports it is suggested that resistant bacterial populations inside the biofilm can reattach to the wound beds within 48 h after debridement. We show that bacterial loads were significantly lower immediately after debridement, however, 48h after debridement the bacterial counts reached almost to the levels similar to that of the pre-debrided levels (**Figure 6**).



Hypothesis 1.4. Biofilms impair the healing of full-thickness burn wounds in a pre-clinical porcine model.

Wound repair is a highly coordinated and complex dynamic series of events including clotting, inflammation, granulation tissue formation, epithelialization, neovascularization, collagen synthesis, tissue remodeling and wound contraction¹⁸⁻²⁰. Once a wound becomes infected it delays the resolution of inflammation and closure is delayed^{1,21-23}. From a pathophysiological standpoint, infection places a massive oxygen demand on the wound tissue. Leukocyte respiratory burst consumes copious amounts of oxygen to fight infection²⁴. This results in an increase in the severity of wound hypoxia stifling oxidative metabolism. Also, persistent infection dysregulates the inflammatory system impairing resolution^{25,26}. In turn, chronic inflammation limits wound closure. Furthermore, components of infectious agents, such as lipopolysaccharide (LPS), are known to stall cell proliferation and migration which are necessary for wound closure^{27,28}. We show increased TNF α expression in wounds inoculated with *pseudomonas* and *acinetobacter* (**Figure 7**) suggesting an increased inflammatory response. Trans-epidermal water loss (TEWL) assay was performed to quantitatively study barrier function of the epidermis. A marked impairment in the restoration of TEWL was noted in biofilm-affected wounds compared to wounds that received sterile saline (control).

These data suggest that pseudomonas and acinetobacter multispecies biofilm significantly impairs burn injury healing (**Figure 7**).



As per timeline proposed in SOW, experiments in hypothesis 2 will be performed in year 2. OligoG has been formulated and manufactured and is ready for wound treatment studies. The formulation was received by PI's laboratory on June 6th, 2012.

KEY RESEARCH ACCOMPLISHMENTS

- Developed a custom device for producing standardized uniform burn injuries on porcine skin.
- Establishment and characterization of the first pre-clinical large animal multi-species biofilm burn injury model to facilitate testing of therapeutics.
- Development of antibody specific against *Acinetobacter*. This reagent will enable detection *Acinetobacter* in infected wounds including military wounds.
- Demonstration of ineffectiveness of debridement or anti-microbial silver containing dressing in eradication of biofilm from infected wounds.
- Novel observation that biofilm infection results in impaired restoration of barrier function of epidermis (shown using TEWL assay) providing evidence that biofilm infection impairs wound healing.
- Preparation of OligoG therapeutic formulation

REPORTABLE OUTCOMES

- **Manuscripts, abstracts, presentations**

The current work in past year resulted in two presentations (one poster and one oral) at International wound healing conferences:

1. The 5th Annual Translational to Clinical (T2C) Regenerative Medicine Wound Care Conference, March 23-24, 2012, Columbus, OH. Poster presentation

2. Symposium on Advanced Wound Care and Wound Healing Society (SAWC Spring/WHS), April 19-22, 2012, Atlanta, GA. Oral presentation

- **Development of cell lines, tissue or serum repositories**

Development of antibody specific against *Acinetobacter*.

- **Informatics such as databases and animal models, etc**

Establishment and characterization of a pre-clinical large animal multi-species biofilm burn injury model to facilitate the study of specific interventions.

- **Funding applied for based on work supported by this award**

None.

- **Employment or research opportunities applied for and/or received based on experience/training supported by this award**

The studies were integral component for post-doctoral training of Dr. Haytham Elgharably, MD, who is joining cardiac surgery clinical Fellowship at Cleveland Clinic, Cleveland from July 01, 2012.

CONCLUSION: Development and characterization of the first reproducible pre-clinical large animal model will facilitate the early development and testing of novel (and existing) treatment interventions with proposed anti-bacterial or anti-biofilm therapies in skin injuries. Development of such model is critical in the translation of this program to clinical practice. The test agents we will employ in these systems represent a novel target and treat biofilms and multi-drug resistance in military injuries. **Future Directions:** The next step will be to take the findings of the proposed study to clinical testing of OligoG.

REFERENCES:

1. Wolcott RD, Dowd SE. A rapid molecular method for characterising bacterial bioburden in chronic wounds. *J Wound Care*. 2008;17:513-516
2. Robson MC. Wound infection. A failure of wound healing caused by an imbalance of bacteria. *Surg Clin North Am*. 1997;77:637-650
3. Dahiya P. Burns as a model of sirs. *Front Biosci*. 2009;14:4962-4967
4. Roy S, Biswas S, Khanna S, Gordillo G, Bergdall V, Green J, Marsh CB, Gould LJ, Sen CK. Characterization of a preclinical model of chronic ischemic wound. *Physiol Genomics*. 2009;37:211-224
5. Sullivan TP, Eaglstein WH, Davis SC, Mertz P. The pig as a model for human wound healing. *Wound Repair Regen*. 2001;9:66-76
6. Hujer KM, Hujer AM, Hulten EA, Bajaksouzian S, Adams JM, Donskey CJ, Ecker DJ, Massire C, Eshoo MW, Sampath R, Thomson JM, Rather PN, Craft DW, Fishbain JT, Ewell AJ, Jacobs MR, Paterson DL, Bonomo RA. Analysis of antibiotic resistance genes in multidrug-resistant *acinetobacter* sp. Isolates from military and civilian patients treated at the walter reed army medical center. *Antimicrob Agents Chemother*. 2006;50:4114-4123
7. Davis KA, Moran KA, McAllister CK, Gray PJ. Multidrug-resistant *acinetobacter* extremity infections in soldiers. *Emerg Infect Dis*. 2005;11:1218-1224
8. Calhoun JH, Murray CK, Manring MM. Multidrug-resistant organisms in military wounds from iraq and afghanistan. *Clin Orthop Relat Res*. 2008;466:1356-1362
9. Zapor MJ, Moran KA. Infectious diseases during wartime. *Curr Opin Infect Dis*. 2005;18:395-399
10. Stuart TL, Mulvey M, Simor AE, Tien HC, Battad A, Taylor G, Vayalumkal JV, Weir C, Ofner M, Gravel D, Paton S. *Acinetobacter baumannii* in casualties returning from afghanistan. *Can J Infect Control*. 2007;22:152-154
11. Davis SC, Ricotti C, Cazzaniga A, Welsh E, Eaglstein WH, Mertz PM. Microscopic and physiologic evidence for biofilm-associated wound colonization in vivo. *Wound Repair Regen*. 2008;16:23-29

12. Kennedy P, Brammah S, Wills E. Burns, biofilm and a new appraisal of burn wound sepsis. *Burns*. 2010;36:49-56
13. Parsek MR, Singh PK. Bacterial biofilms: An emerging link to disease pathogenesis. *Annu Rev Microbiol*. 2003;57:677-701
14. Beam JW. Topical silver for infected wounds. *J Athl Train*. 2009;44:531-533
15. Storm-Versloot MN, Vos CG, Ubbink DT, Vermeulen H. Topical silver for preventing wound infection. *Cochrane Database Syst Rev*. 2010;3:CD006478
16. Wasiak J, Cleland H, Campbell F. Dressings for superficial and partial thickness burns. *Cochrane Database Syst Rev*. 2008:CD002106
17. Dai T, Huang YY, Sharma SK, Hashmi JT, Kurup DB, Hamblin MR. Topical antimicrobials for burn wound infections. *Recent Pat Antiinfect Drug Discov*. 2010;5:124-151
18. Singer AJ, Clark RA. Cutaneous wound healing. *N Engl J Med*. 1999;341:738-746
19. Clark RA. Biology of dermal wound repair. *Dermatol Clin*. 1993;11:647-666
20. Eichler MJ, Carlson MA. Modeling dermal granulation tissue with the linear fibroblast-populated collagen matrix: A comparison with the round matrix model. *J Dermatol Sci*. 2006;41:97-108
21. Madsen SM, Westh H, Danielsen L, Rosdahl VT. Bacterial colonization and healing of venous leg ulcers. *APMIS*. 1996;104:895-899
22. Gjodsbol K, Christensen JJ, Karlsmark T, Jorgensen B, Klein BM, Krogfelt KA. Multiple bacterial species reside in chronic wounds: A longitudinal study. *Int Wound J*. 2006;3:225-231
23. Frank DN, Wysocki A, Specht-Glick DD, Rooney A, Feldman RA, St Amand AL, Pace NR, Trent JD. Microbial diversity in chronic open wounds. *Wound Repair Regen*. 2009;17:163-172
24. Sen CK. Wound healing essentials: Let there be oxygen. *Wound Repair Regen*. 2009;17:1-18
25. Usher LR, Lawson RA, Geary I, Taylor CJ, Bingle CD, Taylor GW, Whyte MK. Induction of neutrophil apoptosis by the *pseudomonas aeruginosa* exotoxin pyocyanin: A potential mechanism of persistent infection. *J Immunol*. 2002;168:1861-1868
26. Leor J, Rozen L, Zuloff-Shani A, Feinberg MS, Amsalem Y, Barbash IM, Kachel E, Holbova R, Mardor Y, Daniels D, Ocherashvili A, Orenstein A, Danon D. Ex vivo activated human macrophages improve healing, remodeling, and function of the infarcted heart. *Circulation*. 2006;114:194-100
27. Golec M. Cathelicidin II-37: Lps-neutralizing, pleiotropic peptide. *Ann Agric Environ Med*. 2007;14:1-4
28. Jonuleit H, Knop J, Enk AH. Cytokines and their effects on maturation, differentiation and migration of dendritic cells. *Arch Dermatol Res*. 1996;289:1-8