

Balantidiasis

*Ronald C. Neafie, Ellen M. Andersen, and
Mary K. Klassen-Fischer*

Introduction

Definition

Balantidiasis is infection by *Balantidium coli*, the largest protozoan parasite and the only ciliate parasite known to infect humans. Malmsten first described the organism in 1857 in 2 patients with severe diarrhea; one of these infections was fatal.¹

Synonyms

Balantidiasis is also known as balantidiosis, balantidial dysentery, and ciliary dysentery.

Epidemiology

Balantidium coli is endemic worldwide. It is most prevalent in temperate and tropical regions, but has been reported in Norway, Sweden, Finland, and northern Russia.² This ciliate parasite inhabits a variety of hosts, especially primates.³ Humans are most commonly infected by contact with infected pigs.⁴ In some pig-raising areas of New Guinea, human infection rates are as high as 28%.^{5,6} An outbreak of balantidiasis on the Pacific island of Truk in 1971 led to 110 human infections.⁷ Human-to-human transmission can occur when personal hygiene is poor, es-

pecially among institutionalized populations.⁸ Nonhuman primates are another source of infection. *Balantidium coli* has been reported in numerous primate species, including orangutans, chimpanzees, gorillas, and Old and New World monkeys.^{3,9,10} Other hosts for *B. coli* include rats, fowl, turtles, and cockroaches. Humans have been reported to be asymptomatic carriers of *B. coli*.⁴

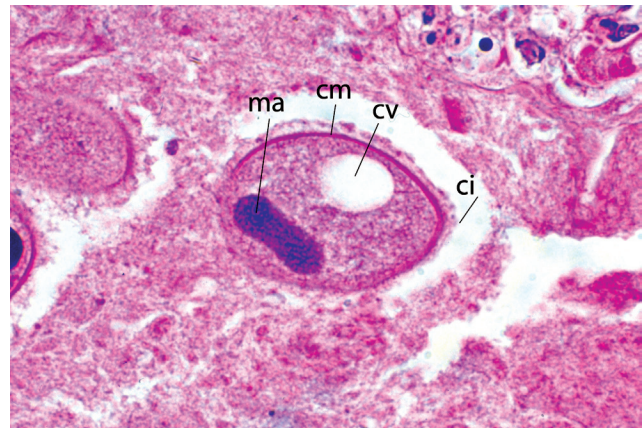


Figure 15.1
Balantidium coli trophozoite in colon. Note cilia (ci), cell membrane (cm), large macronucleus (ma), and large contractile vacuole (cv). x570

Report Documentation Page

Form Approved
OMB No. 0704-0188

Public reporting burden for the collection of information is estimated to average 1 hour per response, including the time for reviewing instructions, searching existing data sources, gathering and maintaining the data needed, and completing and reviewing the collection of information. Send comments regarding this burden estimate or any other aspect of this collection of information, including suggestions for reducing this burden, to Washington Headquarters Services, Directorate for Information Operations and Reports, 1215 Jefferson Davis Highway, Suite 1204, Arlington VA 22202-4302. Respondents should be aware that notwithstanding any other provision of law, no person shall be subject to a penalty for failing to comply with a collection of information if it does not display a currently valid OMB control number.

1. REPORT DATE JUN 2011	2. REPORT TYPE	3. DATES COVERED 00-00-2011 to 00-00-2011			
4. TITLE AND SUBTITLE Balantidiasis		5a. CONTRACT NUMBER			
		5b. GRANT NUMBER			
		5c. PROGRAM ELEMENT NUMBER			
6. AUTHOR(S)		5d. PROJECT NUMBER			
		5e. TASK NUMBER			
		5f. WORK UNIT NUMBER			
7. PERFORMING ORGANIZATION NAME(S) AND ADDRESS(ES) Armed Forces Institute of Pathology, Washington, DC, 20306		8. PERFORMING ORGANIZATION REPORT NUMBER			
9. SPONSORING/MONITORING AGENCY NAME(S) AND ADDRESS(ES)		10. SPONSOR/MONITOR'S ACRONYM(S)			
		11. SPONSOR/MONITOR'S REPORT NUMBER(S)			
12. DISTRIBUTION/AVAILABILITY STATEMENT Approved for public release; distribution unlimited					
13. SUPPLEMENTARY NOTES See also ADA545141. Chapter 15 from e-book, Topics on the Pathology of Protozoan and Invasive Arthropod Diseases.					
14. ABSTRACT					
15. SUBJECT TERMS					
16. SECURITY CLASSIFICATION OF:			17. LIMITATION OF ABSTRACT Same as Report (SAR)	18. NUMBER OF PAGES 6	19a. NAME OF RESPONSIBLE PERSON
a. REPORT unclassified	b. ABSTRACT unclassified	c. THIS PAGE unclassified			

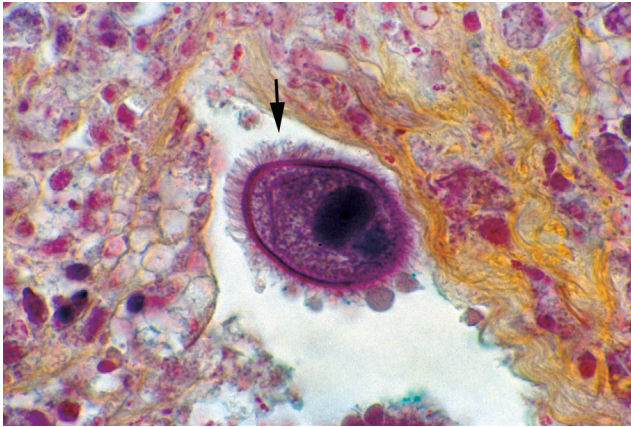

Figure 15.2
Balantidium coli trophozoite in colon. Note prominent cilia (arrow), cell membrane, and large macronucleus. Movat x570

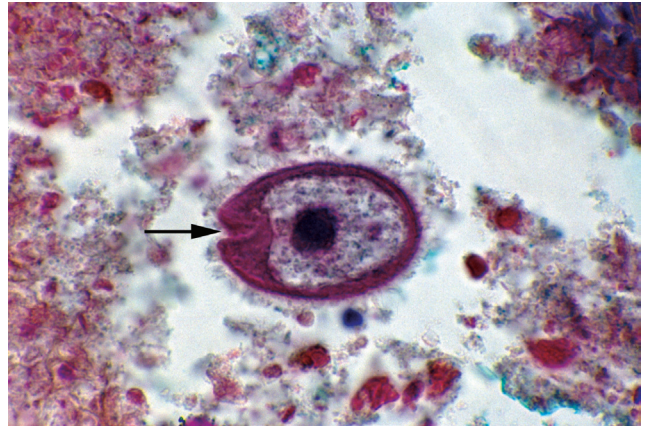


Figure 15.3
Balantidium coli in colonic ulcer. Note cilia-lined peristome (arrow) at anterior end. Movat x610

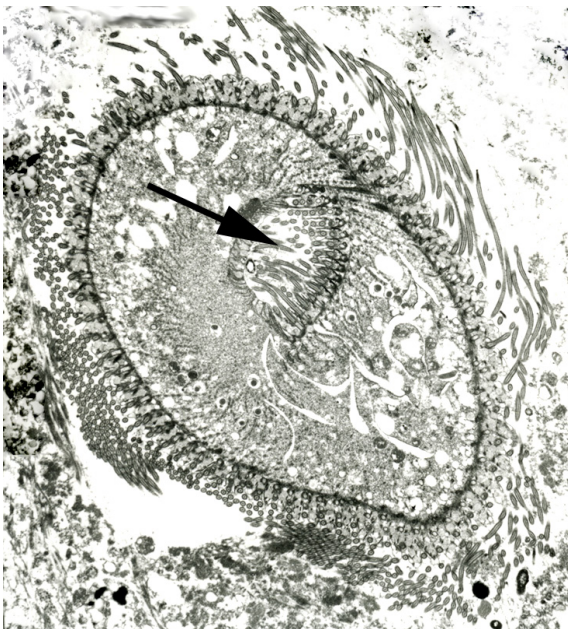


Figure 15.4
Electron micrograph of *Balantidium coli* trophozoite in colon depicting ciliated cell membrane and cilia-lined peristome (arrow) surrounding cytostome. x1350

Infectious Agent **Morphologic Description**

The trophozoite of *B. coli* is 50 μm to 200 μm by 40 μm to 70 μm ; in tissue sections most are 40 μm to 80 μm by 25 μm to 45 μm . They are ovoid, with a cell membrane covered with uniform cilia (Figs 15.1 and 15.2). Near the anterior end is the funnel-shaped peristome, a ciliated area surrounding the cytostome (mouth) (Figs 15.3 and 15.4). Residual products are eliminated through the cytopyge, a small triangular opening at the posterior end. The granular cytoplasm contains food and usually 1 or 2 contractile vacuoles (Fig 15.1). The most obvious structure within the cytoplasm is the large, often kidney-shaped macronucleus (Fig 15.5). The tiny micronucleus lies within the concave depression of the macronucleus (Fig 15.6). The micronucleus is not observed in hematoxylin and eosin stained sections, but may be identified using special stains such as Brown-Hopps, Movat, and Masson. Unusual forms, possibly undergoing division, conjugation, or apoptosis, may rarely be seen (Figs 15.7 and 15.8). Precysts are round, ciliated, and have a peristome (Fig 15.9). Cysts, which are not observed in histologic sections of colon, are spherical and vary from 45 μm to 75 μm in diameter. They have a large macronu-

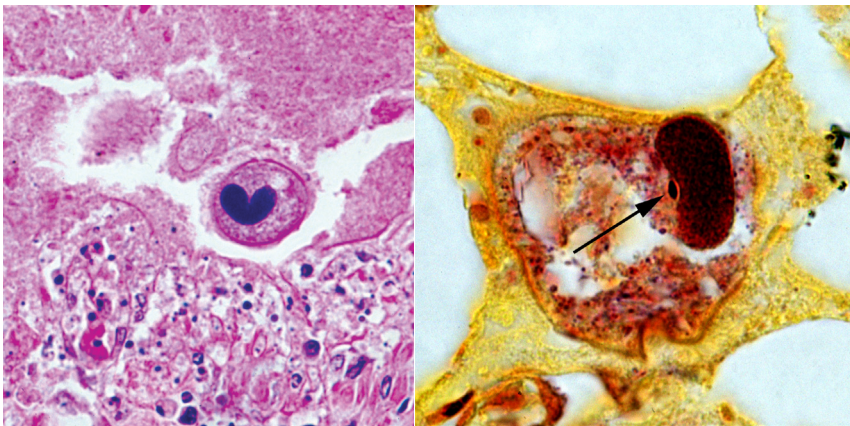


Figure 15.5 (left) and 15.6 (right)
Left, *Balantidium coli* trophozoite in colon demonstrating kidney-shaped macronucleus. x380 and right, the tiny micronucleus (arrow) adjacent to the macronucleus. BH x835

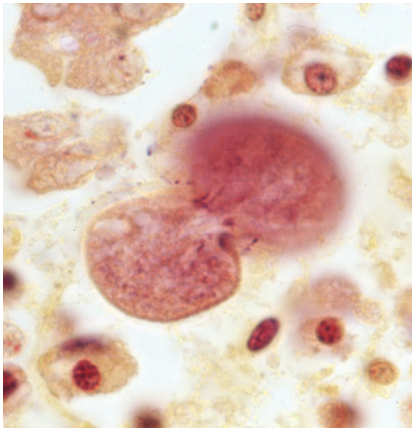


Figure 15.7 (Left)
Unusual appearance of *Balantidium coli* trophozoite in colonic mucosa. H x1000

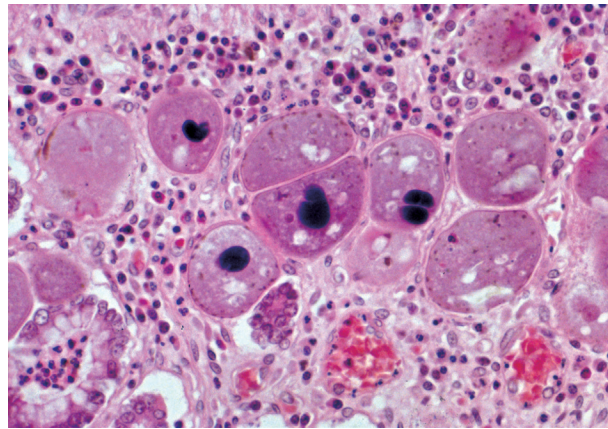


Figure 15.8 (Right)
Multiple *Balantidium coli* trophozoites in wall of colon. x240

cleus (Fig 15.10) and a tiny micronucleus which is rarely observed (Fig 15.6). Cysts may also contain cytoplasmic inclusions, cellular debris, mucus, and food vacuoles (Fig 15.11). The ultrastructural and molecular characterization of *B. coli* have been reported but the molecular nature needs more study to be a useful tool for identification.¹¹

Life Cycle and Transmission

Trophozoites of *B. coli* usually inhabit the colon of the host. They divide asexually by transverse binary fission of the micronucleus, the macronucleus, and finally the cytoplasm. Rarely, they reproduce sexually by conjugation. Trophozoites encyst during transport through the intestine or externally in soft stool (Fig 15.12). In this process, a trophozoite becomes round, partially retracts its cilia, and secretes a cyst wall. Cysts can remain viable for several days in stool. The parasite excysts after it is ingested by another suitable host. Humans are infected by ingesting cysts, the infective stage of *B. coli*, in contaminated water or food. Pigs and rats are the most important reservoir hosts for *B. coli*.

Clinical Features and Pathogenesis

Balantidium coli may inhabit the bowel lumen without invading tissue or provoking clinical symptoms. Parasites that invade tissue do so by mechanical action of the cilia and by lytic action, particularly in patients weakened by underlying factors such as malnutrition or immunosuppression.¹²

Balantidiasis can mimic intestinal amebiasis. The acute form of the disease is marked by rapid onset of diarrhea or dysentery, with 20 bowel movements or more per day.¹³ Other frequent complaints are abdominal colic, tenesmus, nausea, and vomiting. Chronic balantidiasis produces intermittent diarrheal episodes alternating with normal bowel movements or constipation. Patients may occasionally have headache, insomnia, anorexia, weight loss, or muscular weakness. *Balantidium coli* may cause appendicitis and lung involvement, and has been attributed to urinary tract disease.¹⁴⁻¹⁷ Extra-abdominal balantidiasis occasionally develops in patients with cancer or post-organ transplantation.¹⁸⁻²⁰ Peripheral eosinophilia is not a feature of balantidiasis.

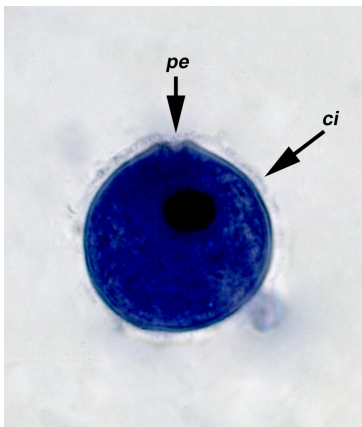


Figure 15.9
Balantidium coli trophozoite in colon demonstrating kidney-shaped macronucleus. Iron-hematoxylin x380

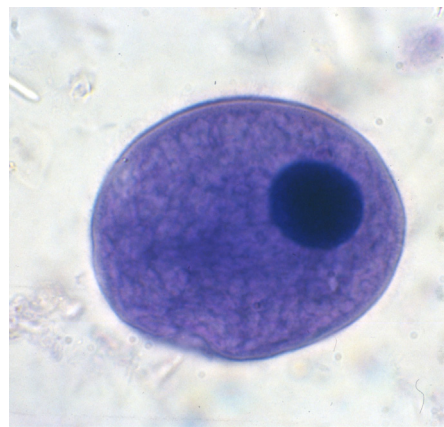


Figure 15.10
Balantidium coli cyst in stained stool specimen illustrating cyst wall and single large macronucleus. Iron-hematoxylin x860

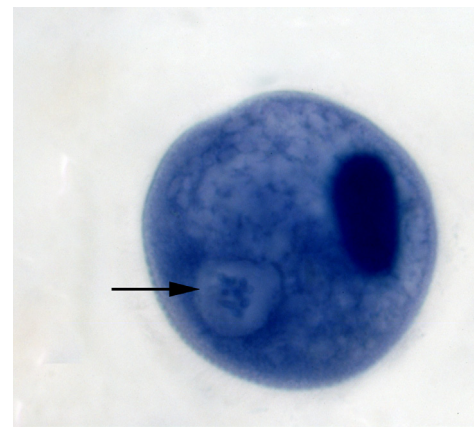


Figure 15.11
Balantidium coli cyst in stained stool specimen showing single large macronucleus and food vacuole (arrow) containing bacteria. Iron-hematoxylin x900

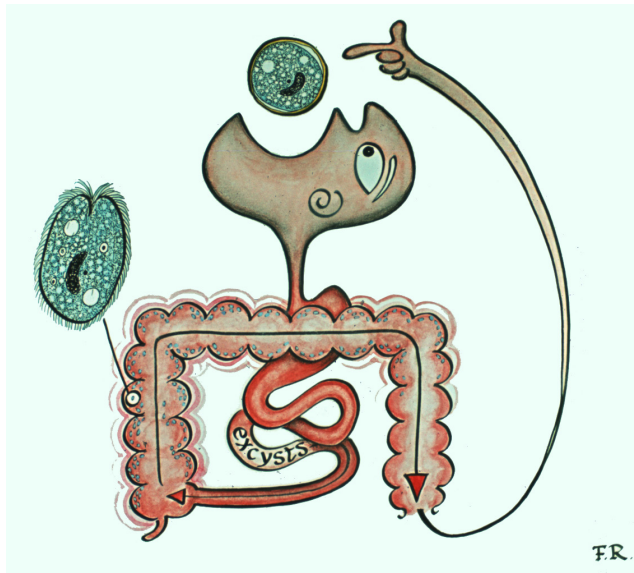


Figure 15.12

Life cycle of *Balantidium coli*. Humans usually acquire balantidiasis from infected pigs, although human-to-human transmission takes place. Ingested cysts excyst in the intestine to become trophozoites. Drawing by Frank O. Raasch.

Pathologic Features

Parasites usually invade the colon and appendix. Invasion of the ileum however, has been reported. Early lesions appear as flask-shaped ulcers a few millimeters in diameter, similar to those seen in intestinal amebiasis. Ulcer borders are frayed, swollen, and undermined (Fig 15.13). The surface is covered with a thick, friable, adherent mucous layer. Ulcers may be superficial or may perforate the intestinal wall (Fig 15.14), releasing parasites into the peritoneal cavity and causing peritonitis, and sometimes death.²¹ Extraintestinal infections involving the liver, vagina, ureter, bladder, and lung have been reported but are extremely rare.^{22,23}

Microscopically, coagulation necrosis containing trophozoites of *B. coli* forms the base of the ulcer (Fig 15.15). Trophozoites stain well with hematoxylin and eosin and are readily seen within the ulcer (Figs 15.16 to 15.19). The macronucleus stains black and, although it may vary considerably in shape, a kidney-shaped configuration is diagnostic (Fig 15.5). Trophozoites are usually more numerous at the periphery of the ulcer than in the necrotic center. There is edema of adjacent tissues, with infiltrates of chronic inflammatory cells, primarily lymphocytes and plasma cells (Fig 15.20). Neutrophils are insignificant unless there is secondary bacterial infection (Fig 15.21). Eosinophils have been reported, but are not a common finding.^{2,24}

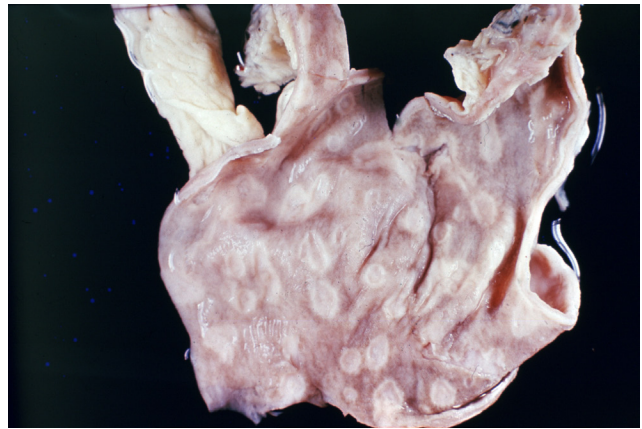


Figure 15.13

Numerous ulcers in colon of patient with balantidiasis. x1

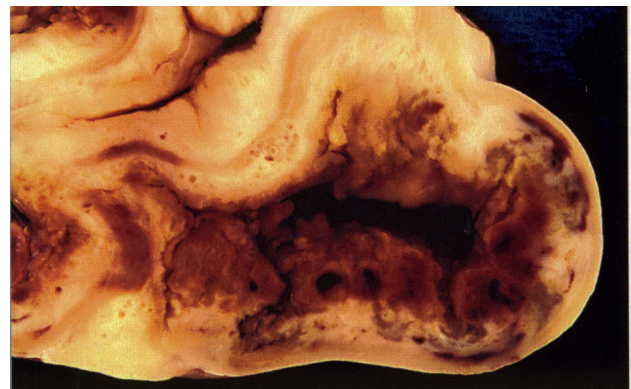


Figure 15.14

Necrotic lesion of large intestine caused by *Balantidium coli*. x60

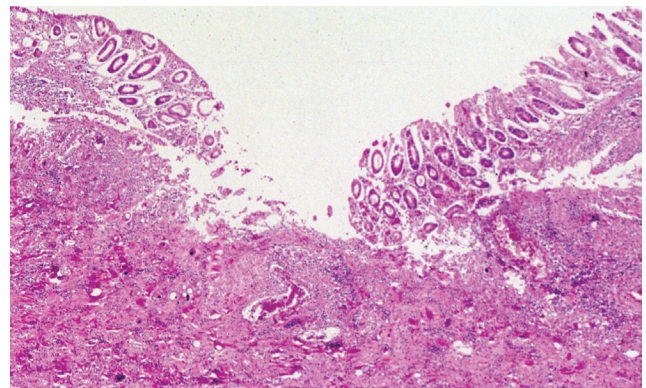


Figure 15.15

Flask-shaped ulcer in colon of patient with balantidiasis. x25

Diagnosis

Diagnosis is established by identifying *B. coli* trophozoites or cysts in feces or scrapings from intestinal lesions. Only trophozoites are seen in biopsy specimens of infected tissues (Fig 15.1). Trophozoites usually appear in diarrheic stools; cysts appear in more solid stools. Trophozoites are actively motile in wet mounts of fresh feces. The macro-

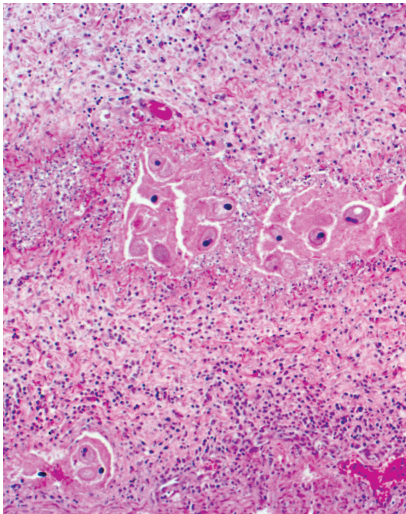


Figure 15.16
Several *Balantidium coli* trophozoites in necrotic area of colon. x60

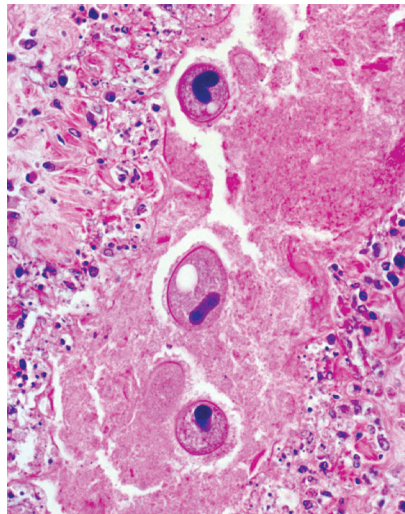


Figure 15.17
Higher magnification of *Balantidium coli* trophozoites shown in Figure 15.16. x235

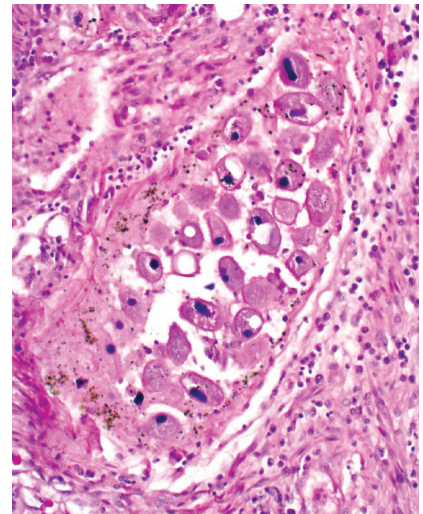


Figure 15.18
Cluster of *Balantidium coli* trophozoites in wall of colon. Note readily identifiable macronuclei. x120

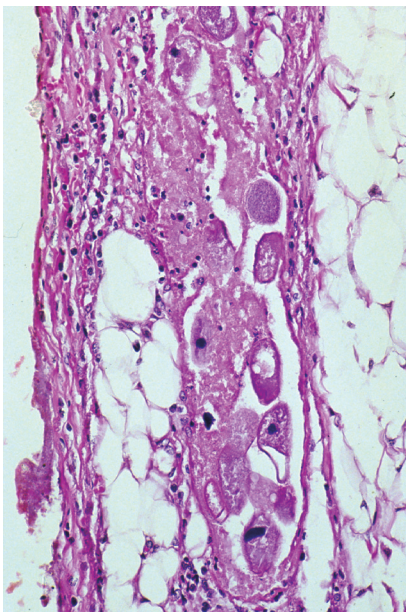


Figure 15.19
Trophozoites of *Balantidium coli* in inflamed, necrotic serosa of patient with peritonitis. x160

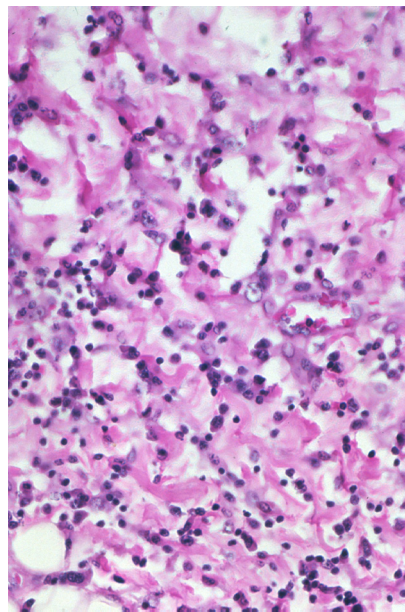


Figure 15.20
Inflammatory infiltrate adjacent to ulcer in wall of colon of patient with balantidiasis. Infiltrate is composed of plasma cells and lymphocytes. x245

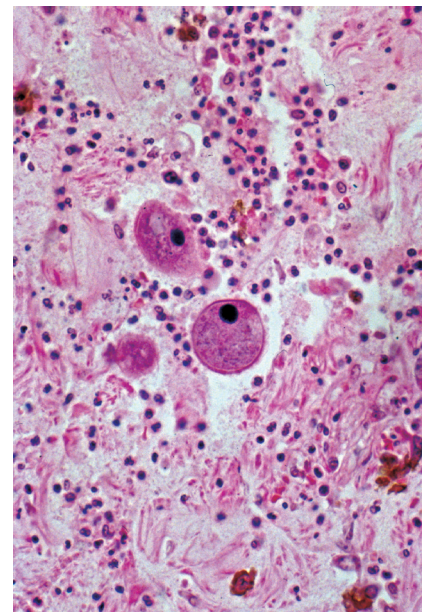


Figure 15.21
Trophozoites of *Balantidium coli* in colonic exudate composed primarily of neutrophils. Neutrophils suggest secondary bacterial infection. x235

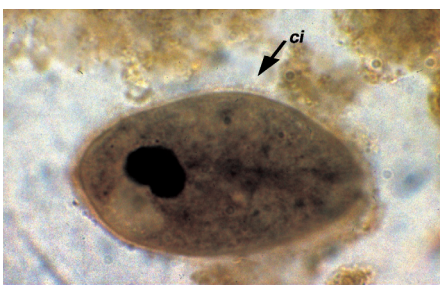

Figure 15.22
Trophozoite of *Balantidium coli* in feces. Note oval configuration, kidney-shaped macronucleus, vacuole in cytoplasm, and cilia (ci). Iron-hematoxylin. x590

nucleus stains well with iron-hematoxylin on smears from fresh stool (Fig 15.22). Diagnosis can also be made by identifying trophozoites in surgical, cytological,²⁵ and autopsy specimens (Figs 15.16 and 15.17). Special care must be taken in differentiating *B. coli* from ciliocytophthoria in nasopharyngeal specimens.²⁶

Treatment and Prevention

The drugs of choice for balantidiasis are tetracycline (for adults: 500 mg 4 times/day for 10 days), or iodoquinol (650 mg 3 times/day for 20 days), metronidazole (500 mg 2 times/day for 5 days); other drugs such as ampicillin, carbasona, diodoquin, nitrimidazine, and paromomycin have been used with varying results.^{22,27,28} Effective sanitation and use of water from protected sources are the most useful measures of protection. Limiting exposure to pigs is helpful but often impractical.²⁹⁻³²

References

- Kean BH, Mott KE, Russell AJ, eds. *Tropical Medicine and Parasitology Classic Investigations*. Vol 1. Ithaca, NY: Cornell University Press; 1978:173-177.
- Arean VM, Koppisch E. Balantidiasis: a review and report of cases. *Am J Pathol*. 1956;32:1089-1115.
- Nakauchi K. The prevalence of *Balantidium coli* infection in fifty-six mammalian species. *J Vet Med Sci*. 1999;61:63-65.
- Esteban JG, Aguirre C, Angles R, Ash LR, Mas-Coma S. Balantidiasis in Aymara children from the northern Bolivian Altiplano. *Am J Trop Med Hyg*. 1998;59:922-927.
- Ewers WH. Parasites of man in Papua-New Guinea. *Southeast Asian J Trop Med Public Health*. 1972;3:79-86.
- Radford AJ. Balantidiasis in Papua New Guinea. *Med J Aust*. 1973;1:238-241.
- Walzer PD, Judson FN, Murphy KB, Healy GR, English DK, Schultz MG. Balantidiasis outbreak in Truk. *Am J Trop Med Hyg*. 1973;22:33-41.
- Giacometti A, Cirioni O, Balducci M, et al. Epidemiologic features of intestinal parasitic infections in Italian mental institutions. *Eur J Epidemiol*. 1997;13:825-830.
- Labes EM, Hegglin D, Grimm F, et al. Intestinal parasites of endangered orangutans (*Pongo pygmaeus*) in Central and East Kalimantan, Borneo, Indonesia. *Parasitology*. 2010;137:123-135.
- Toft JD 2d. The pathoparasitology of the alimentary tract and pancreas of nonhuman primates: a review. *Vet Pathol Suppl*. 1982;7:44-92.
- Nilles-Bije ML, Rivera WL. Ultrastructural and molecular characterization of *Balantidium coli* isolated in the Philippines. *Parasitol Res*. 2010;106:387-394.
- Vasilakopoulou A, Dimarongona K, Samakovli A, Papadimitris K, Avlami A. *Balantidium coli* pneumonia in an immunocompromised patient. *Scand J Infect Dis*. 2003;35:144-146.
- Castro J, Vazquez-Iglesias JL, Arnal-Monreal F. Dysentery caused by *Balantidium coli*—report of two cases. *Endoscopy*. 1983;15:272-274.
- Dodd LG. *Balantidium coli* infestation as a cause of acute appendicitis. *J Infect Dis*. 1991;163:1392.
- Sharma S, Harding G. Necrotizing lung infection caused by the protozoan *Balantidium coli*. *Can J Infect Dis*. 2003;14:163-166.
- Koopowitz A, Smith P, van Rensburg N, Rudman A. *Balantidium coli*-induced pulmonary haemorrhage with iron deficiency. *S Afr Med J*. 2010;100:534-536.
- Maino A, Garigali G, Grande R, Messa P, Fogazzi GB. Urinary balantidiasis: diagnosis at a glance by urine sediment examination. *J Nephrol*. 2010;23:732-737.
- Anargyrou K, Petrikos GL, Suller MT, et al. Pulmonary *Balantidium coli* infection in a leukemic patient. *Am J Hematol*. 2003;73:180-183.
- Yazar S, Altuntas F, Sahin I, Atambay M. Dysentery caused by *Balantidium coli* in a patient with non-Hodgkin's lymphoma from Turkey. *World J Gastroenterol*. 2004;10:458-459.
- Barsoum RS. Parasitic infections in organ transplantation. *Exp Clin Transplant*. 2004;2:258-267.
- Ferry T, Bouhour D, De Monbrison F, et al. Severe peritonitis due to *Balantidium coli* acquired in France. *Eur J Clin Microbiol Infect Dis*. 2004;23:393-395.
- Garcia-Laverde A, de Bonilla L. Clinical trials with metronidazole in human balantidiasis. *Am J Trop Med Hyg*. 1975;24:781-783.
- Ladas SD, Savva S, Frydas A, Kaloviduris A, Hatzioannou J, Raptis S. Invasive balantidiasis presented as chronic colitis and lung involvement. *Dig Dis Sci*. 1989;34:1621-1623.
- Arean VM, Echevarria R. Balantidiasis. In: Marcial-Rojas RA, Moreno E, eds. *Pathology of Protozoal and Helminthic Diseases with Clinical Correlation*. Huntington, NY: Krieger Publishing Co; 1975:234-253.
- Lahiri VL, Elhence BR, Agarwal BM. *Balantidium* peritonitis diagnosed on cytological material. *Acta Cytol*. 1977;21:123-124.
- Hadziyannis E, Yen-Lieberman B, Hall G, Procop GW. Ciliocytophthoria in clinical virology. *Arch Pathol Lab Med*. 2000;124:1220-1223.
- Garcia LS. Flagellates and ciliates. *Clin Lab Med*. 1999;19:621-638.
- Wolfe MS. Miscellaneous intestinal protozoa. In: Strickland GT, ed. *Hunter's Tropical Medicine and Emerging Infectious Diseases*. 8th ed. Philadelphia, Pa: WB Saunders; 2000:603-606.
- Schuster FL, Ramirez-Avila L. Current world status of *Balantidium coli*. *Clin Microbiol Rev*. 2008;21:626-638.
- Ogbolu DO, Alli OA, Ogunleye VF, Olusoga-Ogbolu FF, Olaosun I. The presence of intestinal parasites in selected vegetables from open markets in south western Nigeria. *Afr J Med Med Sci*. 2009;38:319-324.
- Karanis P, Kourenti C, Smith H. Waterborne transmission of protozoan parasites: a worldwide review of outbreaks and lessons learnt. *J Water Health*. 2007;5:1-38.
- Schuster FL, Visvesvara GS. Amebae and ciliated protozoa as causal agents of waterborne zoonotic disease. *Vet Parasitol*. 2004;126:91-120.

Acknowledgement

15.12

Drawing by Frank O. Raasch