



DTIC FILE COPY

2

AD-A222 000

Institute Report No. 443

DTIC  
ELECTE  
MAY 11 1990  
S D D eg

A Carcinogenicity Bioassay of  
Isobutyl 2-Cyanoacrylate (IBC) in  
Fischer-344 Rats -- Final Report


Larry D. Brown, DVM, LTC, VC  
Paul W. Mellick, DVM, COL, VC  
Catherine D. Smith, DVM, MAJ, VC  
and  
Don W. Korte, Jr., PhD, LTC, MSC

**DISTRIBUTION STATEMENT A**  
Approved for public release;  
Distribution Unlimited

MAMMALIAN TOXICOLOGY BRANCH  
DIVISION OF TOXICOLOGY

January, 1990

Toxicology Series: 187



LETTERMAN ARMY INSTITUTE OF RESEARCH PRESIDIO OF SAN FRANCISCO CALIFORNIA 94129

A Carcinogenicity Bioassay of Isobutyl 2-Cyanoacrylate (IBC) in Fischer-344 Rats -- Final Report (Toxicology Series 187)--  
Brown *et al.*

This document has been approved for public release and sale; its distribution is unlimited.

Destroy this report when it is no longer needed. Do not return to the originator.

Citation of trade names in this report does not constitute an official endorsement or approval of the use of such items.

This research was conducted in compliance with the "Guide for the Care and Use of Laboratory Animals," NIH Publication No. 85-23, as prepared by the Institute of Laboratory Animal Resources, National Research Council.

This material has been reviewed by Letterman Army Institute of Research and there is no objection to its presentation and/or publication. The opinions or assertions contained herein are the private views of the author(s) and are not to be construed as official or as reflecting the views of the Department of the Army or the Department of Defense. (AR 360-5)

Donald G. Corby                      23 Jan 90  
Donald G. Corby                      (date)  
COL, MC  
Commanding

**BEST  
AVAILABLE COPY**

## REPORT DOCUMENTATION PAGE

Form Approved  
OMB No. 0704-0188

1a. REPORT SECURITY CLASSIFICATION UNCLASSIFIED		1b. RESTRICTIVE MARKINGS	
2a. SECURITY CLASSIFICATION AUTHORITY		3. DISTRIBUTION / AVAILABILITY OF REPORT  APPROVED FOR PUBLIC RELEASE; DISTRIBUTION IS UNLIMITED.	
2b. DECLASSIFICATION / DOWNGRADING SCHEDULE		4. PERFORMING ORGANIZATION REPORT NUMBER(S)  Institute Report No.: 443	
4. PERFORMING ORGANIZATION REPORT NUMBER(S)		5. MONITORING ORGANIZATION REPORT NUMBER(S)	
6a. NAME OF PERFORMING ORGANIZATION Mammalian Toxicology Division of Toxicology	6b. OFFICE SYMBOL (if applicable) SGRD-ULE-T	7a. NAME OF MONITORING ORGANIZATION US Army Institute of Dental Research	
6c. ADDRESS (City, State, and ZIP Code) Letterman Army Institute of Research Presidio of San Francisco, CA 94129-6800		7b. ADDRESS (City, State, and ZIP Code) Washington, DC 20307-5400	
8a. NAME OF FUNDING / SPONSORING ORGANIZATION US Army Medical Research & Development Command	8b. OFFICE SYMBOL (if applicable)	9. PROCUREMENT INSTRUMENT IDENTIFICATION NUMBER	
8c. ADDRESS (City, State, and ZIP Code) Fort Detrick Frederick, Maryland 21701-5012		10. SOURCE OF FUNDING NUMBERS	
		PROGRAM ELEMENT NO. 62775A	PROJECT NO. A825
		TASK NO. AA	WORK UNIT ACCESSION NO. DA301858
11. TITLE (Include Security Classification) (U) A Carcinogenicity Study of Isobutyl 2-Cyanoacrylate (IBC) in Fischer-344 Rats -- Final Report			
12. PERSONAL AUTHOR(S) LD Brown, PW Mellick, CD Smith, and DW Korte, Jr.			
13a. TYPE OF REPORT Institute	13b. TIME COVERED FROM 30JAN85 to 14FEB86	14. DATE OF REPORT (Year, Month, Day) January 1990	15. PAGE COUNT 1150
16. SUPPLEMENTARY NOTATION  Toxicology Series No. 187			
17. COSATI CODES			18. SUBJECT TERMS (Continue on reverse if necessary and identify by block number) Chronic Toxicity; Isobutyl 2-Cyanoacrylate, IBC, Bucrylate®, Mammalian Toxicology, Tissue Adhesive; Carcinogenicity Bioassay, Rats
FIELD	GROUP	SUB-GROUP	
19. ABSTRACT (Continue on reverse if necessary and identify by block number) This report covers the results from the second year of a two-year carcinogenicity bioassay of the tissue adhesive, isobutyl 2-cyanoacrylate (IBC). Four hundred seven 6-week-old Fischer-344 rats were randomized into three groups (control, 10 µl IBC, and 100 µl IBC), each group containing both male and female animals. The IBC was administered by surgical implantation of the liquid monomer directly onto the ventral capsule of the liver. The monomer was allowed to polymerize before two-layer closure of the abdominal incision. Control animals received 100 µl of isotonic saline, also by surgical implantation. All animals were examined daily, and weighed and palpated monthly. A dose-related increase in the incidence of clinically observed intra-abdominal masses was evident among IBC-treated animals of both sexes. In addition to the masses and the more permanent sequelae of the surgical procedure (xyphoid protuberance, corneal opacity), the animals			
20. DISTRIBUTION / AVAILABILITY OF ABSTRACT <input checked="" type="checkbox"/> UNCLASSIFIED/UNLIMITED <input type="checkbox"/> SAME AS RPT. <input type="checkbox"/> DTIC USERS		21. ABSTRACT SECURITY CLASSIFICATION UNCLASSIFIED	
22a. NAME OF RESPONSIBLE INDIVIDUAL DONALD G. CORBY, COL, MC		22b. TELEPHONE (Include Area Code) (415) 561-3600	22c. OFFICE SYMBOL SGRD-ULZ

19 (cont.) - presented with a variety of transitory clinical signs sporadically throughout the first and second year. These signs were observed in all dose groups, and could not be attributed to compound administration. The weight gain of the two IBC treatment groups was comparable to that recorded for the control group.

Three hundred five animals remained on study at the start of the second year. During the second year, 118 animals died or were sacrificed prematurely. Twenty-one were unscheduled deaths and 97 were unscheduled sacrifices. At the end of the second year, the 187 remaining animals were sacrificed. All animals (118 unscheduled and 187 scheduled) were evaluated by necropsy during the second year. One hundred eighty-four of the animals that received the IBC had fibrotic adhesions between the liver and the omentum, peritoneal membrane, diaphragm, stomach, skin, and/or intestine. These lesions were characterized histologically as foreign body granulomatous reactions. Thirty-one rats treated with IBC developed sarcomas during the second year. The first sarcoma was detected on day 399 after intra-abdominal administration of the test material. Twenty-one of 31 animals with sarcoma died or were sacrificed in a moribund condition, while 10 animals with sarcoma survived until terminal sacrifice. Twenty-seven of 31 animals with sarcoma had grossly detectable masses at necropsy. Four sarcomas were detected only by microscopic examination. The liver was the most frequently affected organ (27 of 31 animals had lesions in the liver). Four IBC-treated rats (2 low-dose males and 2 high-dose females) had hepatocellular carcinomas of the liver, while controls had none. F-344 leukemia or large granular lymphocyte leukemia (LGLL) occurred in 62 animals distributed among all groups, including controls. Solid-state carcinogenesis mechanisms are the most probable cause for the sarcomas, but humans, unlike rodents, fail to elicit a solid-state carcinogenesis effect. The incidence of hepatocellular carcinomas was twice that reported for rats of the same strain and age, which provides reason for concern. However, the incidence of this tumor was not statistically significant and there was no dose-response pattern by sex. All other gross or histopathological findings were considered incidental to IBC treatment, or were sequelae of the surgical procedure.

Results of this study indicate that the presence of IBC in the abdominal cavity had no effect on survival, weight gain, or the clinical condition of F-344 rats during the second year following its implantation. IBC did produce sarcomas in the abdomen of 16% of the animals. The sarcomas were attributed to a solid-state effect which is not present in man. A nonstatistically significant increase in hepatocellular carcinomas was observed in 4 IBC-treated rats but there was no clear evidence that this could be attributed to the IBC implants.

*Keywords: Previous Page*

## ABSTRACT

This report covers the results from the second year of a two-year carcinogenicity bioassay of the tissue adhesive, isobutyl 2-cyanoacrylate (IBC). Four hundred seven 6-week-old Fischer-344 rats were randomized into three groups (control, 10  $\mu$ l IBC, and 100  $\mu$ l IBC), each group containing both male and female animals. The IBC was administered by surgical implantation of the liquid monomer directly onto the ventral capsule of the liver. The monomer was allowed to polymerize before two-layer closure of the abdominal incision. Control animals received 100  $\mu$ l of isotonic saline, also by surgical implantation. All animals were examined daily, and weighed and palpated monthly. A dose-related increase in the incidence of clinically observed intra-abdominal masses was evident among IBC-treated animals of both sexes. In addition to the masses and the more permanent sequelae of the surgical procedure (xyphoid protuberance, corneal opacity), the animals presented with a variety of transitory clinical signs sporadically throughout the first and second year. These signs were observed in all dose groups, and could not be attributed to compound administration. The weight gain of the two IBC treatment groups was comparable to that recorded for the control group.

Three hundred five animals remained on study at the start of the second year. During the second year, 118 animals died or were sacrificed prematurely. Twenty-one were unscheduled deaths and 97 were unscheduled sacrifices. At the end of the second year, the 187 remaining animals were sacrificed. All animals (118 unscheduled and 187 scheduled) were evaluated by necropsy during the second year. One hundred eighty-four of the animals that received the IBC had fibrotic adhesions between the liver and the omentum, peritoneal membrane, diaphragm, stomach, skin, and/or intestine. These lesions were characterized histologically as foreign body granulomatous reactions. Thirty-one rats treated with IBC developed sarcomas during the second year. The first sarcoma was detected on day 399 after intra-abdominal administration of the test material. Twenty-one of 31 animals with sarcoma died or were sacrificed in a moribund condition, while 10 animals with sarcoma survived until terminal sacrifice. Twenty-seven of 31 animals with sarcoma had grossly detectable masses at necropsy. Four sarcomas were detected only by microscopic examination. The liver was the most frequently affected organ (27 of 31 animals had lesions in the liver). Four IBC-treated rats (2 low-dose males and 2 high-dose females) had hepatocellular carcinomas of the liver, while controls had none. F-344 leukemia or large granular lymphocyte leukemia (LGLL) occurred in 62 animals distributed among all groups, including controls.

Solid-state carcinogenesis mechanisms are the most probable cause for the sarcomas, but humans, unlike rodents, fail to elicit a solid-state carcinogenesis effect. The incidence of hepatocellular carcinomas was twice that reported for rats of the same strain and age, which provides reason for concern. However, the incidence of this tumor was not statistically significant and there was no dose-response pattern by sex. All other gross or histopathological findings were considered incidental to IBC treatment, or were sequelae of the surgical procedure.

Results of this study indicate that the presence of IBC in the abdominal cavity had no effect on survival, weight gain, or the clinical condition of F-344 rats during the second year following its implantation. IBC did produce sarcomas in the abdomen of 16% of the animals. The sarcomas were attributed to a solid-state effect which is not present in man. A nonstatistically significant increase in hepatocellular carcinomas was observed in 4 IBC-treated rats but there was no clear evidence that this could be attributed to the IBC implants.

Key Words: Chronic Toxicity, Isobutyl 2-Cyanoacrylate, IBC, Bucrylate®, Mammalian Toxicology, Tissue Adhesive, Carcinogenicity Bioassay, Rat

## PREFACE

TYPE REPORT: Chronic Carcinogenicity Bioassay GLP Final Report

TESTING FACILITY:

US Army Medical Research and Development Command  
Letterman Army Institute of Research  
Presidio of San Francisco, CA 94129-6800

SPONSOR: US Army Medical Research and Development Command  
US Army Institute of Dental Research  
Washington, D.C. 20307-5400  
Project Officer: Eric S. Koppelman, COL, DC

PROJECT/WORK UNIT/APC: Tissue Adhesive Project,  
35162775A825, WU 015, APC TL11

GLP STUDY NUMBER: 83009

STUDY DIRECTOR: LTC Don W. Korte, Jr., PhD, MSC  
Diplomate, American Board of Toxicology

PRINCIPAL INVESTIGATOR: LTC Larry D. Brown, DVM, MPVM, VC  
Diplomate, American College of  
Veterinary Preventive Medicine;  
Dipl., American Board of Toxicology

PATHOLOGISTS: COL Paul W. Mellick, DVM, PhD, VC  
Diplomate, American College of Veterinary  
Pathology (ACVP)  
MAJ Catherine D. Smith, DVM, VC  
Diplomate, ACVP

TOXSYS™/DATA MANAGER: Yvonne C. LeTellier, BS

REPORT AND DATA MANAGEMENT:

A copy of the final report, study protocol, retired SOPs, raw data, analytical, stability, and purity data of the test compound, tissues, microslides, and an aliquot of the test compound will be retained in the LAIR Archives.

TEST SUBSTANCE: Isobutyl 2-Cyanoacrylate (IBC), Bucrylate®

INCLUSIVE STUDY DATES (YEAR 2): 30 January 1985 -  
14 February 1986

OBJECTIVE: The objective of this study was to evaluate the carcinogenic/tumorigenic potential of isobutyl 2-cyanoacrylate in male and female Fischer-344 rats subjected to lifetime (2-year) exposure to the implanted test material.

### ACKNOWLEDGMENTS

Richard A. Spieler, RLAT (AALAS), SGT Thomas W. Johnson, and Nancy J. Smith assisted in the study. SSG James D. Justus and staff provided animal and facility management. Dianna B. Johnson provided office management and secretarial assistance for this study and preparation of the report. LTC William G. Rodkey, DVM, Diplomate, American College of Veterinary Surgeons, COL William B. Carpenter, DDS, and LTC Eric S. Koppelman, DDS, performed the requisite surgery in support of this project. Histology technicians were Lucille Cote and Marge Henderson. CPT Dan Brogdon, DVM, Ocular Hazards Division, was the veterinary ophthalmology consultant to this study. CPT Gary M. Zaucha, DVM, collated the final report. CPT Robert E. Harris, DVM, provided assistance with collating the final report.



**SIGNATURES OF PRINCIPAL SCIENTISTS AND MANAGERS  
INVOLVED IN THE STUDY**

We, the undersigned, declare that the GLP Study 83009 was performed under our supervision, according to the procedures described herein, and that this report is an accurate record of the results obtained.

*Don W. Korte* 5 Jan 90  
 DON W. KORTE, JR. PhD / DATE  
 LTC, MSC  
 Study Director

*Conrad Wheeler* 5 Jan 90  
 CONRAD R. WHEELER, PhD / DATE  
 DAC  
 Analytical Chemist

*Larry D. Brown*  
 LARRY D. BROWN, DVM / DATE  
 LTC, VC  
 Principal Investigator

*Yvonne LeTellier* 5 Jan 90  
 YVONNE LETELLIER, BS / DATE  
 DAC  
 TOXSYS/Data Manager

*Paul W. Mellick*  
 PAUL W. MELLICK, DVM / DATE  
 COL, VC  
 Senior Pathologist

*C. Dahlem Smith*  
 C. DAHLEM SMITH, DVM / DATE  
 MAJ, VC  
 Assistant Study Pathologist



Location	
NYS	✓
...	
...	
...	
By	
Date	
...	
...	
...	

A-1



DEPARTMENT OF THE ARMY  
LETTERMAN ARMY INSTITUTE OF RESEARCH  
PRESIDIO OF SAN FRANCISCO, CALIFORNIA 94129-6800

REPLY TO  
ATTENTION OF:

SGRD-ULZ-QA

19 January 1990

MEMORANDUM FOR RECORD

SUBJECT: GLP Compliance for GLP Study 83009

1. This is to certify that in relation to LAIR GLP Study 83009 the following inspections were made:

23 August 1983	- Protocol Review
17 January 1984	- Weighing
23 January 1984	- Weighing/Dosing
17 February 1984	- Observation/Weighing
26 March 1984	- Observation
17 May 1984	- Observation
05 July 1984	- Observation/Weighing
02 August 1984	- Weighing
29 January 1986	- Observation/Necropsy

2. The institute report entitled "A Carcinogenicity Bioassay of Isobutyl 2-Cyanoacrylate (IBC) in Fischer-344 Rats--Final Report," Toxicology Series 187, was audited on 2 January 1990.

*Carolyn M. Lewis*  
CAROLYN M. LEWIS  
Diplomate, American Board of  
Toxicology  
Quality Assurance Auditor

# TABLE OF CONTENTS

Volume 1

	Page
Abstract .....	i
Preface .....	iii
Acknowledgments .....	iv
Signatures of Principal Scientists .....	v
Report of Quality Assurance Unit .....	vi
Table of Contents .....	vii
INTRODUCTION .....	1
Objective of Study .....	1
MATERIALS .....	1
Test Substance .....	1
Animal Data .....	2
Husbandry .....	2
METHODS .....	3
Group Assignment/Acclimation .....	3
Dosage Levels .....	3
Preparation of Compound .....	3
Chemical Analysis of IBC .....	3
Test Procedures .....	4
Clinical Observations .....	4
Pathological Examinations .....	5
Statistical Analyses .....	6
Duration of Study .....	6
Changes/Deviations from Protocol .....	6
Storage of Raw Data and Final Report .....	6
RESULTS .....	7
Mortality .....	7
Clinical Observations .....	16
Gross Pathology .....	23
Microscopic Pathology .....	24
DISCUSSION .....	31

**TABLE OF CONTENTS (cont.)**

	Page
CONCLUSION .....	34
REFERENCES .....	35
APPENDICES .....	38
Appendix A. Chemical Data .....	39
Appendix B. Animal Data .....	46
Appendix C. Surgical Report .....	48
Appendix D. Historical Listing of Study Events .....	54
Appendix E. Glossary of Terms for Clinical Observations .....	57
Appendix F. Individual Animal Histories .....	64
Appendix G. Gross Necropsy Observations, Incidence Summary .....	369
Appendix H. Microscopic Observations, Incidence Summary .....	379
Appendix I. Glossary of Terms for Pathology Findings .....	402
Appendix J. Pathology Individual Animal Data .....	466
OFFICIAL DISTRIBUTION LIST .....	1150

**A Carcinogenicity Bioassay of Isobutyl 2-Cyanoacrylate (IBC) in Fischer-344 Rats -- Final Report--Brown et al.**

**INTRODUCTION**

Isobutyl 2-cyanoacrylate (IBC) is being evaluated by the U.S. Army Medical Department as a tissue adhesive for use in sutureless wound closure, oral and maxillofacial surgery, and in other surgical procedures. The use of this modality could provide a time-saving and sometimes life-saving dimension to the management of combat wounds. The U.S. Army Institute of Dental Research (USAIDR) has been assigned the mission of evaluating the therapeutic potential of IBC. As part of their mandate, USAIDR has tasked the Toxicology Branch, Letterman Army Institute of Research (LAIR), to evaluate IBC in a chronic carcinogenicity bioassay.

Results from the first year of the study indicate that IBC has no effect on survival, weight gain, or the clinical condition of rats during the first year following its implantation. The only gross or histopathological finding observed in the first year that was attributed to the IBC treatment was the presence of adhesions and a granulomatous reaction of the liver and those adjacent organs that came in contact with the IBC. No tumors were observed during the first year that could be attributed to IBC treatment (1). This report will review salient features of the first year and address findings that occurred during the second year of this study.

Objective of Study

The objective of this study was to evaluate the carcinogenic/tumorigenic potential of isobutyl 2-cyanoacrylate in male and female Fischer-344 rats subjected to lifetime (2-year) exposure of the implanted test material.

**MATERIALS**

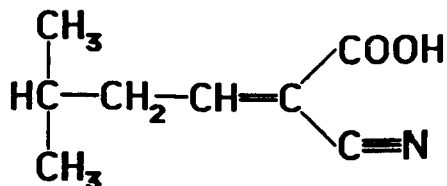
Test Substance

Chemical Name: Isobutyl 2-cyanoacrylate (IBC),  
Bucrylate®

Chemical Abstract Service Registry No.: 1069-55-2

Molecular Formula:  $C_8H_{11}NO_2$

Molecular Structure:



Additional information on the test substance is presented in Appendix A.

Animal Data

Two hundred nine male and 210 female 4-week-old Fischer-344 (CDF) rats were received for this study on 11 Jan 84 from Charles River Breeding Laboratories, Inc., Wilmington, MA. They were identified individually with ear tags numbered 84D00001 to 84D00209 (inclusive) for the males and 84D00226 to 84D00435 (inclusive) for the females. Four males and 4 females were selected randomly for quality control necropsy evaluation at receipt. The animal weights on the day following receipt (12 Jan 84) ranged from 30-57 g. During quarantine, three underweight females and one maloccluded male were submitted to necropsy on 20 Jan 84. Additional animal data are presented in Appendix B.

Husbandry

Animals used in this study were housed at LAIR in the Toxicology Suite, a restricted access facility. Rats were caged individually in stainless steel wire-mesh cages in racks equipped with automatically flushing dumptanks. No bedding was used in any of the cages. The diet, fed *ad libitum*, consisted of Purina Certified Rodent Chow® Diet 5002 (Ralston Purina Company, St. Louis, MO). Tap water was provided by automatic water valves on a central line. Water was analyzed quarterly for impurities, bacteria, physical and chemical properties, organic residues, pesticides, and heavy metals. The animal room temperature and relative humidity were continuously recorded. The room was maintained at temperatures ranging from 20.0°C to 25.5°C, with a relative humidity range of 35% to 60%, except for short periods (spikes) during which cleaning of the room altered the relative humidity, and on six occasions when increases up to 70-86% occurred for 4-14 hours due to steam outages or servicing of the ventilation system fans. The photoperiod of 12 hours of fluorescent light per day was electronically controlled. Air changes, cage size, and husbandry conformed to National Research Council Institute of Laboratory Animal Resources standards (2). The LAIR animal facility is

accredited by the American Association for Accredited Laboratory Animal Care.

## **METHODS**

This study was performed in accordance with the protocol, applicable amendments, and cited operating procedures including: LAIR Standard Operating Procedure OP-STX-81, "Chronic Bucrylate Bioassay Procedures within Toxicology GLP Suite and Administrative Areas" (3); OP-STX-73, "Chronic Carcinogen Bioassay" (4); and FDA Nonclinical Laboratory Studies, Good Laboratory Practice Regulations (5).

### Group Assignment/Acclimation

Study rats were randomized on 19 January 1984 into two experimental dose groups of 68 males and 68 females each, and a saline control group of 68 males and 67 females. Allocation was accomplished by using the Beckman TOXSYS™ Animal Allocation Program (Beckman Instruments, Inc., Somerset, NJ). The animals were acclimated for 12 days before the day of dosing. During this period they were observed daily for signs of illness.

### Dosage Levels

The following test doses were administered: high-dose group, 100  $\mu$ l IBC/animal; low-dose group, 10  $\mu$ l IBC/animal; and vehicle control group, 100  $\mu$ l saline/animal.

### Preparation of Compound

Bucrylate® IBC tissue adhesive (lot 929-252, Ethicon, Inc., Somerville, NJ) was received from the sponsor on 10 January 1984 as 750 0.5 ml scored ampules in individual overwrap sterile bags. The IBC required no preparation prior to implantation. It was stored at LAIR at room temperature under darkness. Dosing of control animals was performed with commercial sterile isotonic (0.9%) saline (Lot No. 56-329-FD-05, expiration date 1 Sep 86, Abbott Labs, Chicago, IL).

### Chemical Analysis of IBC

Ethicon, Inc., provided data on infrared, chromatographic, and chemical analysis of the IBC (Appendix A). Lot 929-252 contained 99.9% (w/w) total monomer. Before dosing, the LAIR Analytical Chemistry Group verified the identity of the IBC by IR spectroscopy, confirmed the purity

by gas chromatography, and demonstrated the stability of the IBC during the dosing period (Appendix A).

#### Test Procedures

The fixed volume of neat IBC or saline each animal received was based upon its assigned dosage group, and was administered directly onto the ventral (inferior surface) capsule of the liver. High-dose animals received 100  $\mu$ l of IBC, low-dose animals received 10  $\mu$ l of IBC, and control animals received 100  $\mu$ l of saline. Rats were 6 weeks of age at dosing. Since the surgical survival rate for implantation of this compound was unknown, all animals, regardless of size, were subjected to the surgical procedure and dosed to ensure that sufficient numbers would be available for inclusion in the chronic phase of the study. Body weights at dosing ranged from 29 g to 123 g, with the mean male and female weights at 94.0 g and 73.8 g, respectively.

The test compound was implanted under sterile conditions in the LAIR Operating Room Suite on 23 and 24 Jan 84. The surgical laparotomy implantation procedure was performed under xylazine/ketamine anesthesia. Following anesthesia, surgical preparation, and midline incision, the animal's liver was exposed by "tenting" the abdominal wall with either ophthalmic retractors or tissue forceps. The IBC was applied to the ventral capsule of the liver, usually the caudate lobe, by using either a sterile tip 100  $\mu$ l or 10  $\mu$ l fixed volume Eppendorf micropipette. The IBC was then allowed to polymerize for 2-3 minutes before closure. All pipettes used in the study were shown to be accurate within  $\pm$  2%. A two-layer closure of bioresorbable 4-0 Vicryl® (Ethicon, Inc.) and skin staples or skin clips was used. After the animals recovered to sternal recumbency, they were returned to the Toxicology Suite. A complete surgical report is provided in Appendix C.

#### Clinical Observations

On the day of dosing and during the following 2-week period, animals were checked intermittently throughout the day. During the first postoperative week, 25 animals were removed from the study due to underweight condition and/or complications. Three hundred eighty-two animals recovered satisfactorily and remained on study as of 1 Feb 84. After the animals were stabilized, observations for mortality and signs of toxicity or illness were reduced in frequency to twice daily. An observation was performed according to the following procedure: (a) each morning all animals were observed closely for signs of toxicity or illness without



disturbing them in the cage; (b) once a week the animals (20% of them per work day) were removed from their cages and observed; (c) animals were observed after being returned to their cages. A second "walk-through, live/dead check" observation was performed every afternoon with only significant observations recorded. Monthly, a more detailed clinical examination was performed, body weights were obtained, and the abdomens of all animals were gently palpated. These data were recorded electronically on a Beckman TOXSYS™ Data Collection Terminal. Daily observations/clinical signs were recorded on written records and significant changes entered into the TOXSYS workstation. TOXSYS software on the LAIR Data General Computers, Models MV8000 and C330, was used to analyze clinical signs and body weight data.

#### Pathological Examinations

Animals that were moribund at the time of clinical examination were euthanized by pentobarbital overdose, exsanguinated by axillary incision, and necropsied. During the second year, 21 animals died unexpectedly (unscheduled), and 97 unscheduled sacrifices were required. Additionally, 187 animals were submitted for sacrifice at the end of the second year, 27 Jan - 14 Feb 1986. Gross necropsy examinations were performed, and tissues were collected from each animal in accordance with LAIR OP-STX-32, "General Pathology Procedures", OP-PSG-7, "Necropsy Procedure--Gross Examination of Small Laboratory Animals", and OP-PSG-12, "Histopathology--Trimming of Rodent Tissues."

The pathologic evaluation consisted of gross and microscopic examination of major organs/tissues and all gross lesions from sacrificed animals and animals found dead. The following organs/tissues were examined microscopically: eyes and lens, skin, subcutaneous tissue, mammary gland, brain (4 levels: anterior cerebral, midcerebral, midbrain, cerebellum), middle ears, auditory canal, sebaceous gland, trachea, lungs, nasal region, sternum, heart, aorta, salivary glands (parotid, submaxillary, sublingual), Harderian lacrimal and intraorbital lacrimal glands, exorbital lacrimal glands, liver (2-4 sections of various lobes), pancreas, esophagus, stomach, duodenum, jejunum, ileum, cecum, colon, rectum, kidneys, urinary bladder, accessory sex glands (male only--prostate, seminal vesicle, coagulating gland, epididymis), testes/ovaries, uterus (horns and body), skeletal muscle (2 sections, longitudinal and cross), sciatic nerve, tongue, pituitary, thyroid/parathyroid, adrenals, thymus, spleen (2 cross sections), mesenteric lymph nodes, femur (bone marrow), and vertebrae with spinal cord (3

sections: cervical, thoracic, and lumbar). These tissues were preserved in 10% buffered formalin, trimmed, embedded in paraffin, sectioned, and stained with hematoxylin and eosin prior to microscopic examination. Necropsy data were recorded and entered into a Xybion™ (Xybion Medical Systems, Cedar Knoll, NJ) computerized data acquisition program designed for a DEC VAX™ 750 computer. Microscopic findings were entered into the computer directly as microslides were read. Since the Xybion animal-numbering system was incompatible with the TOXSYS numbering system used during the "in-life" phases of the study, the animals had to be renumbered by the Pathology Section as they were necropsied in order to enter them into the Xybion Pathology Data System. A cross reference of animal identification numbers is presented in Appendix J.

#### Statistical Analyses

Statistical analyses were performed on the study results. TOXSYS System programs were used to determine the group mean animal body weights (EDS002) and the frequencies of clinical signs (EDS057-61). The Xybion Pathology Data System was used to generate the pathology raw data listings, summary pathology reports, lesion frequency data, and terminal body weights (group mean, standard deviation, Bartlett's Test, ANOVA, and Dunnett's Test). The incidence of microscopic lesions for each test group were compared to the control group using the Kolmogorov-Smirnov two-tailed test. The 5% ( $p \leq 0.05$ ) level of significance was used for all tests.

#### Duration of Study

The "in-life" period for the second year of the study ran from 30 Jan 85 until 14 Feb 86, when the terminal sacrifice was completed. Appendix D is a complete historical listing of study events.

#### Changes/Deviations from Protocol

Performance of this study was in accordance with the protocol and applicable amendments.

#### Storage of Raw Data and Final Report

A copy of the final report, study protocol and amendments, raw data, relevant SOPs, analytical data for the test compound, and an aliquot of the test compound will be retained in the LAIR Archives.

**RESULTS****Mortality**

One hundred eighteen animals died or were sacrificed prematurely during the second year of the study (controls, 13 males, 22 females; low dose, 16 males, 19 females; high dose, 27 males, 21 females). Of these, 21 unscheduled deaths were recorded and 97 animals were euthanized because they were moribund, had infections, had lost weight, or were in poor condition (Tables 1a - 1d).

**TABLE 1a**

**Listing of Unscheduled Deaths/Euthanized\* Animals  
1 Feb - 30 Apr 85**

Toxicology Animal No.	Date	Clinical Outcome	Sex	Dose Group
84D00-				
376	13 Feb 85	Died in cage	F	High IBC
157	26 Feb 85	Died in cage	M	High IBC
296	15 Mar 85	Sacrificed, large** intra-abdominal mass	F	High IBC
170	23 Apr 85	Sacrificed, alopecia and skin scabbing/scaling (infection control)	M	Control
428	23 Apr 85	Sacrificed, perivaginal fistula & discharge	F	Control

\* Animals were sacrificed to conserve tissues in face of imminent death, for infection control purposes, or for humane reasons.

\*\*Large =  $\geq 20$  mm in diameter

TABLE 1b

**Listing of Unscheduled Deaths/Euthanized\* Animals  
1 May - 31 Jul 85**

Toxicology Animal No. 84D00-	Date	Clinical Outcome	Sex	Dose Group
422	7 May 85	Sacrificed, severe dehydration	F	Low IBC
156	9 May 85	Died in cage	M	High IBC
423	10 May 85	Sacrificed, large** intra-abdominal mass	F	High IBC
181	10 May 85	Sacrificed, large intra-abdominal mass	M	High IBC
109	19 May 85	Sacrificed, large intra-abdominal mass	M	High IBC
384	31 May 85	Sacrificed, skin lesions neck (infection control)	F	Control
129	5 Jun 85	Large intra-abdominal mass	M	High IBC
275	14 Jun 85	Large intra-abdominal mass	F	High IBC
326	1 Jul 85	Died in cage	F	Low IBC
431	8 Jul 85	Large intra-abdominal mass	F	High IBC
430	9 Jul 85	Died in cage	F	High IBC
415	17 Jul 85	Pallor with palpable splenic mass	F	Low IBC
193	21 Jul 85	Died in cage	M	High IBC
091	30 Jul 85	Died in cage	M	High IBC

\* Animals were sacrificed to conserve tissues in face of imminent death, for infection control purposes, or for humane reasons.

\*\*Large =  $\geq 20$  mm in diameter

**TABLE 1c**  
**Listing of Unscheduled Deaths/Euthanized\* Animals**  
**1 Aug - 31 Oct 85**

Toxicology Animal No. 84D00-	Date	Clinical Outcome	Sex	Dose Group
099	1 Aug 85	Large** intra-abdominal mass	M	High IBC
149	1 Aug 85	Emaciated and dehydrated	M	Low IBC
301	1 Aug 85	Malocclusion	F	Control
191	1 Aug 85	Infected subcutaneous mass	M	High IBC
286	2 Aug 85	Pallor with palpable abdominal mass	F	High IBC
388	2 Aug 85	Pallor with palpable abdominal mass, died in cage	F	Control
147	16 Aug 85	Large subcutaneous perihumeral mass	M	Low IBC
407	16 Aug 85	Large subcutaneous mass on thoracic wall	F	Low IBC
279	20 Aug 85	Marked weight loss and perianal staining	F	Low IBC
081	28 Aug 85	Large subcutaneous mass	M	High IBC
426	28 Aug 85	Pallor with weight loss	F	Low IBC
074	30 Aug 85	Large intra-abdominal mass with excessive weight loss	M	High IBC

\* Animals were sacrificed to conserve tissues in face of imminent death, for infection control purposes, or for humane reasons.

\*\*Large =  $\geq 20$  mm in diameter

TABLE 1c (cont.)

Listing of Unscheduled Deaths/Euthanized\* Animals  
1 Aug - 31 Oct 85

Toxicology Animal No. 84D00-	Date	Clinical Outcome	Sex	Dose Group
102	30 Aug 85	Large** intra-abdominal mass and pallor	M	Low IBC
108	30 Aug 85	Skin mass over maxilla	M	High IBC
151	30 Aug 85	Pallor with large intra-abdominal mass	M	High IBC
327	30 Aug 85	Large intra-abdominal mass	F	High IBC
338	30 Aug 85	Large intra-abdominal mass	F	High IBC
180	9 Sep 85	Large intra-abdominal mass with weight loss	M	Low IBC
288	9 Sep 85	Emaciated	F	Control
363	13 Sep 85	Oral discharge	F	Low IBC
389	13 Sep 85	Cardiac murmur with weight loss	F	Control
032	19 Sep 85	Large subcutaneous mass	M	Control
404	23 Sep 85	Died in cage	F	Control
260	25 Sep 85	Enteritis with weight loss	F	Low IBC
059	26 Sep 85	Large subcutaneous mass	M	Low IBC
095	26 Sep 85	Large intra-abdominal mass	M	High IBC

\* Animals were sacrificed to conserve tissues in face of imminent death, for infection control purposes, or for humane reasons.

\*\*Large =  $\geq 20$  mm in diameter

TABLE 1c (cont.)

**Listing of Unscheduled Deaths/Euthanized\* Animals  
1 Aug - 31 Oct 85**

Toxicology Animal No. 84D00-	Date	Clinical Outcome	Sex	Dose Group
104	26 Sep 85	Large** intra-abdominal mass	M	High IBC
124	26 Sep 85	Large splenic mass	M	Control
266	3 Oct 85	Large subcutaneous mass on neck	F	Control
069	3 Oct 85	Large intra-abdominal mass with weight loss	M	High IBC
368	8 Oct 85	Severe pallor from hemorrhagic enteritis	F	Control
199	16 Oct 85	Deteriorated condition and large palpable intra-abdominal mass	M	High IBC
278	17 Oct 85	Large subcutaneous mass over humerus	F	Control
166	17 Oct 85	Large subcutaneous mass	M	Control
084	24 Oct 85	Pallor, weak, depressed	M	Low IBC
080	24 Oct 85	Died in cage	M	High IBC
203	24 Oct 85	Pallor, large intra-abdominal mass	M	Low IBC
424	25 Oct 85	Weight loss, dehydrated, depressed	F	High IBC

\* Animals were sacrificed to conserve tissues in face of imminent death, for infection control purposes, or for humane reasons.

\*\*Large =  $\geq 20$  mm in diameter

TABLE 1d

**Listing of Unscheduled Deaths/Euthanized\* Animals  
1 Nov 85 - 14 Feb 86**

Toxicology Animal No. 84D00-	Date	Clinical Outcome	Sex	Dose Group
139	5 Nov 85	Large** intra-abdominal mass with weight loss	M	High IBC
416	5 Nov 85	Large intra-abdominal mass with deterioration	F	High IBC
164	8 Nov 85	Weight loss	M	Control
320	15 Nov 85	Large intra-abdominal mass, anorexic	F	High IBC
390	15 Nov 85	Anorexic, pallor	F	Control
146	18 Nov 85	Died in cage	M	Low IBC
343	19 Nov 85	Large intra-abdominal mass	F	High IBC
367	19 Nov 85	Large mass lower abdomen	F	High IBC
414	19 Nov 85	Large subcutaneous mass	F	Control
273	18 Nov 85	Weight loss, palpable intra-abdominal mass	F	High IBC
322	23 Nov 85	Died in cage after monthly palpation, large splenic mass	F	Low IBC
365	23 Nov 85	Splenic mass, died in cage	F	Control
182	26 Nov 85	Large intra-abdominal mass, pallor	M	Low IBC

\* Animals were sacrificed to conserve tissues in face of imminent death, for infection control purposes, or for humane reasons.

\*\*Large =  $\geq 20$  mm in diameter



TABLE 1d (cont.)

**Listing of Unscheduled Deaths/Euthanized\* Animals  
1 Nov 85 - 14 Feb 86**

Toxicology Animal No. 84D00-	Date	Clinical Outcome	Sex	Dose Group
290	26 Nov 85	Pallor	F	Control
036	3 Dec 85	Anorexic, weight loss	M	Control
334	3 Dec 85	Pallor and emaciated	M	Control
392	3 Dec 85	Emaciated and pallor	F	Low IBC
041	11 Dec 85	Emaciated	M	Low IBC
062	11 Dec 85	Large** intra-abdominal mass, rapid weight loss	M	High IBC
030	18 Dec 85	Anorexic, emaciated	M	Control
033	19 Dec 85	Died in cage	M	Low IBC
070	23 Dec 85	Rapid weight loss	M	Low IBC
051	23 Dec 85	Weight loss	M	Low IBC
359	23 Dec 85	Died in cage	F	Control
200	24 Dec 85	Weight loss, circumoral staining	M	Control
399	29 Dec 85	Anorexic, emaciated, skin pallor	F	Low IBC
078	3 Jan 86	Emaciated, pallor, large intra-abdominal mass	M	High IBC

\* Animals were sacrificed to conserve tissues in face of imminent death, for infection control purposes, or for humane reasons.

\*\*Large =  $\geq 20$  mm in diameter

TABLE 1d (cont.)

**Listing of Unscheduled Deaths/Euthanized\* Animals  
1 Nov 85 - 14 Feb 86**

Toxicology Animal No. 84D00-	Date	Clinical Outcome	Sex	Dose Group
114	3 Jan 86	Pallor, emaciated, large** intra-abdominal mass	M	High IBC
185	3 Jan 86	Large intra-abdominal mass, pallor	M	High IBC
328	3 Jan 86	Pallor and emaciated	F	Low IBC
060	9 Jan 86	Large intra-abdominal mass	M	Low IBC
289	11 Jan 86	Died in cage	F	Low IBC
257	13 Jan 86	Large subcutaneous tumor	F	Low IBC
324	13 Jan 86	Acute weight loss	F	Control
345	13 Jan 86	Emaciated	F	Low IBC
089	14 Jan 86	Died in cage	M	High IBC
100	14 Jan 86	Convulsed and died in cage	M	High IBC
120	14 Jan 86	Moribund	M	Control
117	14 Jan 86	Moribund	M	Control
053	16 Jan 86	Two large intra-abdominal masses	M	Low IBC
039	16 Jan 86	Weight loss	M	Control
198	16 Jan 86	Large intra-abdominal mass	M	Control

\* Animals were sacrificed to conserve tissues in face of imminent death, for infection control purposes, or for humane reasons.

\*\*Large =  $\geq 20$  mm in diameter

TABLE 1d (cont.)

Listing of Unscheduled Deaths/Euthanized\* Animals  
1 Nov 85 - 14 Feb 86

Toxicology Animal No. 84D00-	Date	Clinical Outcome	Sex	Dose Group
413	16 Jan 86	Subcutaneous swelling between anus and vulva, intra-abdominal mass	F	High IBC
280	17 Jan 86	Pallor, enlarged spleen	F	Control
356	17 Jan 86	Malocclusion, weight loss, intra-abdominal mass	F	High IBC
397	17 Jan 86	Pallor, enlarged spleen	F	Control
425	17 Jan 86	Deteriorated condition, hypothermic, with weight loss	F	Low IBC
418	17 Jan 86	Splenic and liver masses, hypothermic	F	Low IBC
346	21 Jan 86	Moribund	F	Low IBC
412	21 Jan 86	Died in cage	F	High IBC
172	22 Jan 86	Died in cage	M	High IBC
393	23 Jan 86	Deteriorated condition	F	High IBC
432	23 Jan 86	Died in cage	F	High IBC
115	24 Jan 86	Moribund	M	High IBC
096	27 Jan 86	Emaciated, hypothermic, severe respiratory problem	M	Low IBC

\* Animals were sacrificed to conserve tissues in face of imminent death, for infection control purposes, or for humane reasons.

\*\*Large =  $\geq 20$  mm in diameter

TABLE 1d (cont.)

**Listing of Unscheduled Deaths/Euthanized\* Animals  
1 Nov 85 - 14 Feb 86**

Toxicology Animal No. 84D00-	Date	Clinical Outcome	Sex	Dose Group
361	29 Jan 86	Emaciated, intra-abdominal mass	F	Low IBC
179	29 Jan 86	Deteriorated condition	M	Control
302	3 Feb 86	Two intra-abdominal masses, emaciated, pallor	F	High IBC
330	7 Feb 86	Emaciated, pallor, perianal stain	F	Control
331	7 Feb 86	Splenic mass, pallor	F	Control
403	10 Feb 86	Emaciated, sudden onset conjunctivitis	F	Control

\* Animals were sacrificed to conserve tissues in face of imminent death, for infection control purposes, or for humane reasons.

#### Clinical Observations

A glossary of terms for clinical observations is presented in Appendix E. Individual clinical observation and body weight data are presented in Appendix F. The majority of animals gained or maintained body weight throughout the first 8 months of the second year of the study (observation periods 14-23). During the final 4 months (observation periods 24-27), slight decreases in group mean body weights were observed for treatment and control group males. Decreases were observed for the females only at terminal sacrifice (fasted body weight). Mean body weights of IBC-dosed and saline-treated control animals were comparable throughout the second year for both sexes. Tables 2 (male) and 3 (female) present mean monthly body weights by group.

Clinical signs closely duplicating those seen during the first year of the study (1) were observed throughout the second year. With the exception of clinically observed

masses, signs were generally routine, of minor consequence, and were distributed relatively equally among the treatment and control groups. Clinical sign categories observed during the second year included ocular abnormalities (179 of 305 animals affected), masses (145 of 305), skin/fur abnormalities (129 of 305), general signs (69 of 305), respiratory abnormalities (23 of 305), genitourinary abnormalities (14 of 305), behavioral aberrations (12 of 305), postoperative complications (5 of 305), and miscellaneous observations (21 ear tag reactions, 2 malocclusions, 1 cardiac irregularity).

With the exceptions of the masses, ocular abnormalities, and the few iatrogenic postoperative complications (xyphoid protuberance and abdominal/peritoneal fistula), clinical signs developed rapidly, and were relatively mild and of short duration. An incidence summary of clinical signs is presented in Table 4.

TABLE 2

**Group Mean Body Weights: Males -  
Year Two of Two-Year IBC Carcinogenicity Bioassay\***

Date	Observation Period	High Dose IBC	Low Dose IBC	Saline Controls
14 Feb 85	14	396.5 (50)	400.9 (55)	404.2 (57)
14 Mar 85	15	404.2 (49)	407.8 (55)	410.3 (57)
11 Apr 85	16	407.5 (49)	409.5 (55)	414.8 (57)
9 May 85	17	410.7 (49)	415.7 (55)	420.9 (56)
6 Jun 85	18	417.8 (45)	419.6 (55)	422.7 (56)
2 Jul 85	19	416.2 (45)	419.4 (55)	422.3 (56)
1 Aug 85	20	420.6 (43)	421.8 (55)	425.8 (56)
29 Aug 85	21	415.7 (40)	422.4 (53)	427.3 (56)
26 Sep 85	22	417.8 (37)	423.5 (51)	426.1 (55)
24 Oct 85	23	417.8 (33)	425.5 (50)	431.5 (53)
21 Nov 85	24	407.5 (31)	415.6 (47)	420.3 (52)
19 Dec 85	25	406.3 (30)	412.8 (45)	416.7 (50)
16 Jan 86	26	401.4 (25)	403.8 (41)	404.4 (47)
27 Jan -	27	376.2 (23)	377.5 (39)	376.8 (44)
5 Feb 86**				

\* Data are presented as group mean value in grams, with n, the number of animals in each group, in parentheses.

\*\* Final sacrifice period, fasted body weights

TABLE 3

**Group Mean Body Weights: Females -  
Year Two of Two-Year IBC Carcinogenicity Bioassay\***

Date	Observation Period	High Dose IBC	Low Dose IBC	Saline Controls
15 Feb 85	14	232.7 (40)	227.8 (52)	225.3 (51)
15 Mar 85	15	241.0 (40)	233.2 (52)	231.9 (51)
12 Apr 85	16	248.7 (39)	240.3 (52)	236.4 (51)
10 May 85	17	255.4 (39)	245.2 (51)	244.8 (50)
7 Jun 85	18	261.2 (38)	252.1 (51)	246.8 (49)
3 Jul 85	19	263.8 (37)	256.8 (50)	253.1 (49)
2 Aug 85	20	270.1 (34)	264.1 (49)	261.1 (48)
30 Aug 85	21	274.6 (33)	265.8 (46)	263.6 (47)
27 Sep 85	22	281.2 (31)	273.1 (44)	273.2 (44)
25 Oct 85	23	281.2 (31)	276.5 (44)	273.8 (41)
22 Nov 85	24	281.4 (26)	278.9 (44)	274.1 (39)
20 Dec 85	25	281.6 (25)	278.2 (42)	276.5 (36)
17 Jan 86	26	279.1 (25)	278.0 (37)	274.1 (34)
7-14 Feb 86**27		261.2 (19)	264.6 (33)	256.7 (29)

\* Data are presented as group mean value in grams, with n, the number of animals in each group, in parentheses.

\*\* Final sacrifice period, fasted body weights

The clinically observed masses included intra-abdominal masses, subcutaneous masses, inguinal masses, cutaneous masses of the ear or scrotum, a maxillary mass, a subscapular mass, a swollen maxilla, and splenomegaly. Of these, only the intra-abdominal group could be correlated to IBC-treatment. The intra-abdominal masses were primarily associated with the ventral aspect of the liver. An increased incidence of intra-abdominal masses was observed for the males relative to the females, and a dose response was apparent for both sexes.

The ocular signs (conjunctivitis, corneal opacity, opaque lens, prolapsed lens, hyphema, ocular discharge/ chromodacryorrhea, microphthalmia, exophthalmus/enlarged globe, iris tear, and dilated pupil) observed in many of the animals (179 of 305) were sequelae to drying (keratoconjunctivitis sicca) of the eyes during surgery (Appendix C). Corneal ulcers formed within 7-14 days. These lesions healed, leaving persistent corneal scars.

**TABLE 4**  
**Incidence Summary of Clinical Signs**

Clinical Category and Sign	Males		Females	
	Saline Control	100 $\mu$ l IBC	Saline Control	100 $\mu$ l IBC
Total Number at Start of 2nd Year	57	50	51	40
Scheduled Terminal Sacrifice	44	23	29	19
Unscheduled Sacrifice/Death	13	27	22	21
Ocular Abnormalities	20	18	46	36
conjunctivitis	8	3	39	26
corneal opacity	9	16	28	23
opaque lens	6	3	2	3
prolapsed lens	4	1	1	1
hyphema	2	1	-	-
ocular discharge/chromodacryorrhea	1	1	-	2
microphthalmia	1	-	-	-
exophthalmus/enlarged globe	-	1	-	2
iris tear	-	1	-	-
dilated pupil	1	-	-	-
Masses	10	48	10	24
intra-abdominal mass	7	45	5	23
subcutaneous mass	3	3	4	3
inguinal mass	-	-	2	2
swollen/mass maxilla	1	1	-	-
cutaneous mass ear/scrotum	1	1	-	-
subscapular mass	-	-	-	1
splenomegaly	-	-	-	-

TABLE 4 (cont.)  
Incidence Summary of Clinical Signs

Clinical Category and Sign	Males		Females	
	Saline Control	100 $\mu$ l IBC	Saline Control	100 $\mu$ l IBC
Skin/Fur Abnormalities	27	22	20	16
anterior body stain	22	16	8	6
posterior body stain	4	3	10	13
rough coat	1	2	3	2
scab/lesion head/neck/back/abdomen	1	2	2	-
papilloma nose/mouth/base of tail	3	1	-	-
pustules/dermal lesions on tail	-	1	-	-
necrosis tail	-	2	-	-
abscess	2	-	-	-
alopecia	-	-	1	-
pododermatitis	1	-	-	-
sebaceous cyst	-	-	-	-
ears erythematous	-	-	-	-
scaling back	1	-	-	-
swollen lip	1	-	-	-
General Signs	11	10	17	6
pallor	3	5	9	1
emaciated/severe weight loss	6	4	7	3
anorexia	3	-	1	1
dehydration	-	-	2	1
moribund	2	-	-	-
prostrate	-	-	-	1
anemic	-	1	1	-
decreased body temperature	-	1	-	-



**TABLE 4 (cont.)**  
**Incidence Summary of Clinical Signs**

Clinical Category and Sign	Males		Females	
	Saline Control	100 $\mu$ l IBC	Saline Control	100 $\mu$ l IBC
Respiratory Abnormalities				
tachypnea	-	1	9	5
wheezing	-	1	8	5
incr. resp depth	-	-	2	1
decr. resp rate	-	-	-	-
gasping	-	-	-	-
apnea	-	-	-	-
bloody discharge eyes/nose/mouth	-	-	-	-
Genitourinary Abnormalities				
perivaginal fistula/	2	-	5	4
purulence/bleeding	-	-	5	4
preputial fistula/discharge	2	-	-	-
bloody urine/calculi	-	-	-	-
Behavioral Aberrations				
irritable	5	3	2	1
inactive	4	-	2	-
hypotonia	1	2	-	1
aggressive	-	1	-	1
tremors	-	-	-	-
depressed	1	-	-	1
decreased preening	-	1	-	-

**TABLE 4 (cont.)**  
**Incidence Summary of Clinical Signs**

Clinical Category and Sign	Males		Females	
	Saline Control	100 $\mu$ l IBC	Saline Control	100 $\mu$ l IBC
Postoperative Complications	-	3	1	-
xyphoid protuberance	-	3	1	-
fistula, lower abdomen/peritoneal	-	-	1	1
Miscellaneous Observations				
ear tag reaction/infection	6	8	1	-
malocclusion	-	-	1	1
cardiac irregularity	-	-	1	-

Some animals also had conjunctivitis and chromodacryorrhea which persisted for long periods. *Streptococcus faecalis*, a common normal flora bacterium, was cultured from the affected eyes. The consulting ophthalmologist reported that this low-grade ocular infection was limited to the globe and its accessory structures. Therefore, no treatment was rendered. Other postsurgical complications included xyphoid cartilage protuberance/nodule (due to accidental incision of the xyphoid cartilage in some animals while attempting to expose the liver sufficiently) and peritoneal fistula. Significant postoperative complications occurred in less than 5% of all animals.

### Gross Pathology

Incidence summary reports for gross necropsy observations during year two are presented in Appendix G.

Twenty-one animals, 10 males and 11 females, were found dead, and 97 animals (46 males and 51 females) were euthanized prematurely during the second year of the study. Compound-related lesions (liver adhesions) were observed in 70 of 83 IBC-treated animals in the unscheduled group. One hundred eighty-seven animals (106 males and 81 females) survived to the end of the study and were euthanized. Compound-related lesions (liver adhesions) were observed in 111 of 114 IBC-treated animals.

Dense, tough, fibrous adhesions were observed on the capsular surface of the liver in 48/50 Group 1 (100  $\mu$ l IBC) males, 34/40 Group 1 (100  $\mu$ l IBC) females, 52/55 Group 2 (10  $\mu$ l IBC) males, and 47/52 Group 2 (10  $\mu$ l IBC) females. The microscopic characteristics of this test compound-related inflammatory reaction are described in detail below in the paragraphs dealing with histologic findings. Only 1/57 Group 3 (saline control) males and 3/51 Group 3 females had grossly evident adhesions on the liver. The adhesions in control animals were very fine, delicate strands in marked contrast to the extensive, tough, fibrous areas observed in IBC-treated animals.

Liver masses were observed grossly in 9/50 Group 1 (100  $\mu$ l IBC) males, 13/40 Group 1 (100  $\mu$ l IBC) females, 3/55 Group 2 (10  $\mu$ l IBC) males, and 0/53 Group 2 (10  $\mu$ l IBC) females. Grossly, these irregularly-shaped masses were usually white to light yellow/gray in color, and very firm. In several masses there was gross evidence of hemorrhage and/or necrosis. Gross observation revealed no liver masses in any Group 3 (saline control) male or female rats. In some of the IBC-treated animals, masses were noted in organs other than

the liver, including the diaphragm, stomach, intestines, other abdominal organs, and in the thoracic cavity. Gross appearance of these extrahepatic masses was similar to that of the liver masses. Histologic examination revealed that masses in the liver and other sites were sarcomas arising in the compound-related chronic inflammatory reaction. The incidence of these tumors, a detailed histologic description, and anatomic distribution is provided in the paragraphs below dealing with histologic findings.

#### Microscopic Pathology

In the text of this report, the description of histologic lesions is limited to those lesions that can be attributed to administration of the test compound, and lesions or disease entities that may affect results or interpretation of results. A complete listing of all microscopic findings (neoplastic and non-neoplastic) in this study is provided in Appendix H. Appendix I is a glossary of pathologic terms used in this study. It includes a definition, a brief morphologic description, and criteria for severity grades of all microscopic lesions observed in this study.

#### Non-Neoplastic Lesions:

An incidence summary for all non-neoplastic lesions in this study is presented in Appendix H. Non-neoplastic lesions of statistically significant ( $p \leq 0.05$ ) incidence include compound-related inflammatory reactions in the liver and different locations of the gastrointestinal tract in both males and females receiving the high dose of IBC, hepatocytic vacuolization in high-dose females, the presence of red blood cells and/or hemosiderin within lymph nodes of high-dose males and females, and reactive hyperplasia of lymph nodes in males and females in both high and low dose groups.

Compound-related inflammatory reactions were present in nearly all animals in both high and low dose IBC groups. Table 5 presents the incidence and distribution of these lesions in abdominal viscera. In most animals, the lesions were located at the site where the test material was placed, i.e., on the capsule of the liver and the adjacent diaphragm. Fewer lesions were present on surfaces of the stomach, different portions of the intestinal tract, spleen, and pancreas. The microscopic characteristics of compound-related inflammatory reactions were similar in all sites. In histologic sections, the test material was a clear, slightly yellow, homogeneous crystalline material. Surrounding the test material there was a granulomatous foreign-body reaction

characterized by infiltration of macrophages, lymphocytes, and large multinucleated foreign-body giant cells within abundant fibrous connective tissue. Usually this lesion was limited to the serosal surface of abdominal viscera. In some cases, there was necrosis of underlying tissues and penetration of the serosal surface by the inflammatory response accompanied by regenerative hyperplasia of cells of the organ involved. In four rats, the presence of the compound caused necrosis of the intestinal wall. Regenerating cells of the intestinal mucosa migrated through the submucosa and muscular tunics of the intestine and were entrapped in the adjacent fibrous, granulomatous inflammatory

**TABLE 5**  
**Distribution of Compound-Related**  
**Inflammatory Reactions: Scheduled and Unscheduled**  
**Animals Combined, Year 2**

Group (Number in Group)	CTLS* (57)	MALE		FEMALE		
		1† (50)	2§ (55)	CTLS* (51)	1† (40)	2§ (52)
Liver	0	48	52	0	40	45
Diaphragm	0	41	19	0	38	25
Jejunum	0	14	0	0	13	0
Stomach	0	6	0	0	12	0
Duodenum	0	7	0	0	6	0
Ileum	0	7	0	0	4	0
Pancreas	0	3	0	0	1	0
Cecum	0	4	0	0	1	0
Colon	0	3	0	0	2	0
Spleen	0	1	0	0	1	0
Abdominal Cavity	0	1	3	0	0	0

\* CTLS = Saline controls

† Group 1 = 100  $\mu$ l IBC

§ Group 2 = 10  $\mu$ l IBC

tissues. In these cases, the entrapped cells had essentially normal histologic characteristics, except for their location and their association with mild degenerative and atrophic changes. There were no indications of cellular atypia, nuclear pleomorphism, or abnormal mitotic activity. These lesions were present in the jejunum in two females and one male in the high dose group, and in the duododenum in one high-dose female. No intestinal lesions of this type were observed in control animals.

The incidence of hepatocytic vacuolization was statistically significant only in female rats in the high dose group. Seventeen of 40 animals in this group exhibited the lesion, as compared to 8 of 51 control females. In other treatment groups, the lesion was present, but the incidence was not statistically significant. Hepatocytic vacuolization consisted of small-to-large cytoplasmic vacuoles within hepatocytes. In sections appropriately prepared and stained, fat could be demonstrated. The vacuolated hepatocytes were not uniformly distributed in the liver.

The incidence of reactive hyperplasia in lymph nodes was significantly greater in male and female rats in both high and low dose groups compared to control animals. Reactive hyperplasia consisted of non-neoplastic, noninflammatory increases in cellularity in lymph nodes. There were increased numbers of cells in perifollicular areas of the cortex. Medullary cords and sinuses contained large numbers of plasma cells. Eosinophilic, protein-rich edema fluid may have been present.

The presence of red blood cells and/or hemosiderin pigment in lymph nodes occurred with increased frequency in both males and females in the high dose group. Table 6 shows the incidence of these changes in lymph nodes.

#### Neoplastic Lesions:

An incidence summary for all neoplasms, both malignant and benign, is presented in Appendix H. Sarcomas that arose in the compound-related inflammatory reaction were the only neoplasms that exhibited a statistically significant incidence. Thirty-one rats treated with IBC developed these tumors. Table 7 displays the distribution of these lesions by treatment group, sex, and whether in scheduled or unscheduled animals. The first animal necropsied with a compound-related sarcoma died on 26 February 1985, day 399 after intra-abdominal administration of the test material.

TABLE 6

**Incidence of Reactive Hyperplasia,  
Red Blood Cells and/or Hemosiderin  
in Lymph Nodes, Year 2**

Group (Number in Group)	MALE			FEMALE		
	CTLS* (57)	1† (50)	2§ (55)	CTLS* (51)	1† (40)	2§ (52)
Reactive Hyperplasia	8	25**	29**	7	25**	24**
RBC's and/or Hemosiderin	12	24**	18	15	28**	17

\* CTLS = Saline controls

† Group 1 = 100  $\mu$ l IBC

§ Group 2 = 10  $\mu$ l IBC

\*\*Entries flagged with (\*\*) are significantly different from control at the 0.05 significance level using Kolmogorov-Smirnov Two-Tailed Test.

Of the 31 animals with compound-related sarcomas, 21 died or were sacrificed in a moribund condition prior to scheduled termination of the study. Ten sarcoma-affected animals survived until terminal sacrifice. Only 27 of the 31 animals with sarcomas had grossly detectable masses at necropsy. Four sarcomas were detected only by microscopic examination.

These sarcomas involved many organs in some animals, through either multicentric sites of origin, or local invasion, or metastasis. The histologic characteristics of these tumors were extremely variable. The entire spectrum of histologic differentiation of mesenchymal tissue was represented in this group of tumors. Some tumors were well-differentiated fibrosarcomas, osteosarcomas, or myxosarcomas, while others were very anaplastic and poorly differentiated. In some lesions, multiple types of histologic differentiation occurred in the same tumor. Of the 31 compound-related sarcomas in this study, 13 were predominantly fibrosarcomas, 12 were anaplastic sarcomas, 5 were osteosarcomas, and one was a myxosarcoma. One anaplastic sarcoma had an abundance of chondrocytes and cartilaginous matrix. Two other tumors

TABLE 7

**Sarcomas Arising in Compound-Related  
Inflammatory Reaction**  
Time of Sacrifice: **Unscheduled or Terminal, Year 2**

Group	MALE			FEMALE			Total
	CTLS*	1†	2§	CTLS*	1†	2§	
Unscheduled	0	9	3	0	9	0	21
Terminal**	0	6	1	0	3	0	10
Total	0	15	4	0	12	0	31

\* CTLS = Saline controls

† Group 1 = 100 µl IBC

§ Group 2 = 10 µl IBC

\*\*Terminal or final sacrifice (scheduled animals)

had large areas that resembled rhabdomyosarcoma, but no cross striations could be demonstrated in sections stained with phosphotungstic acid-hematoxylin stains. The liver was the most frequently affected organ, but it was not involved in every case. Twenty-seven of the 31 animals with these tumors had lesions in the liver. In one rat, only the duodenum was involved, one animal only had a tumor in the ileum, and in another, the sarcoma was limited to the stomach and spleen. Table 8 lists the anatomic distribution of these compound-related sarcomas. Because of the multiple sites of involvement, the primary site for these lesions is coded as the abdominal cavity, and involvement of each individual organ is coded as a metastatic lesion. Using this method of computer entry, it was possible to tabulate the occurrence of these sarcomas and document the organs involved without duplicating incidence. The diagnosis: "Presence of Metastatic Sarcoma" is used only when it is certain that the sarcoma developed within the reaction to the test material.



TABLE 8  
 Anatomic Distribution of Sarcomas Arising in  
 Compound-Related Inflammatory Reaction\*\*, Year 2

Tissue	MALE			FEMALE			Total
	CTLS*	1†	2§	CTLS*	1†	2§	
Liver	0	12	3	0	12	0	27
Diaphragm	0	8	2	0	10	0	19
Mediastinal	0	4	0	0	2	0	6
Jejunum	0	2	2	0	2	0	6
Spleen	0	2	2	0	1	0	5
Pancreas	0	3	1	0	1	0	5
Stomach	0	1	1	0	2	0	4
Duodenum	0	3	0	0	1	0	4
Ileum	0	3	0	0	1	0	4
Lung	0	1	0	0	1	0	2
Lymph Nodes	0	0	0	0	2	0	2
Kidney	0	0	0	0	1	0	1
Cecum	0	1	0	0	0	0	1
Colon	0	1	0	0	0	0	1

\* CTLS = Saline controls

† Group 1 = 100  $\mu$ l IBC

§ Group 2 = 10  $\mu$ l IBC

\*\*Includes both primary and metastatic sites

Six rats in this study had fibrosarcomas that did not arise in the compound-related inflammatory reaction. Four of these were female (1 control, 1 high dose, and 2 low dose) animals in which sarcomas occurred in the subcutaneous tissue of the inguinal region. In three of these animals, the tumors invaded the adjacent pelvic cavity and involved the

rectum. One male control rat had a fibrosarcoma that was limited to the cortex of one kidney. One male in the high dose group had a fibrosarcoma surrounding the metal identification tag in the pinna of the external ear. Three females (2 control and 1 high dose) had endometrial stromal sarcomas. These lesions did not resemble the sarcomas that arose in compound-related inflammatory reaction.

Four IBC-treated rats (2 low dose males and 2 high dose females) had hepatocellular carcinomas in the liver. The morphologic characteristics of hepatocellular carcinomas are well documented in the literature. For this study, the criteria of Maronpot et al. (6) were followed. Important features of these tumors included irregular shape, cellular atypia, local invasiveness, haphazardly arranged cells, broad sheets of cells, trabecular patterns, and glandlike formations of tumor cells. Hemorrhage, necrosis, vascular invasion, and metastases were observed in several of these lesions.

Large granular lymphocyte leukemia occurred in 62 animals in this study. The group distribution of this malignant tumor of lymphoid cells is shown in Table 9. The histologic characteristics of this common neoplasm in Fischer-344 rats are described in the Glossary of Pathologic Terms, Appendix I.

TABLE 9

**Large Granular Lymphocyte Leukemia**  
Time of Sacrifice: **Unscheduled or Terminal, Year 2**

Group	MALE			FEMALE			Total
	CTLS*	1†	2§	CTLS*	1†	2§	
Unscheduled	3	9	9	9	3	9	42
Terminal**	2	1	7	5	3	2	20
Total	5	10	16	14	6	11	62

\* CTLS = Saline controls

† Group 1 = 100  $\mu$ l IBC

§ Group 2 = 10  $\mu$ l IBC

\*\*Terminal sacrifice or scheduled animals

There was no statistical significance for the incidence of this lesion; however, 42 animals died or were sacrificed in a moribund condition because of the presence of this disease.

Many animals in this study developed a variety of malignant and benign tumors. Tumors of the testes, endocrine glands, and mammary glands were the most common. There was no statistically significant increase in incidence for any of these miscellaneous tumors in IBC-treated animals compared to controls.

The individual animal pathology reports are provided in Volume 2, Appendix J.

## DISCUSSION

This report records the findings from the second year of a two-year carcinogenicity bioassay of IBC. This includes complete clinical histories and gross and microscopic pathological data on all unscheduled and scheduled (final sacrifice) animals surviving the first year of the study.

Clinical findings during the second year indicated that male and female animals treated with IBC gained weight at the same rate as the control animals. These findings also indicated that, as a whole, the animals in this study remained relatively healthy throughout the second year. Clinical signs observed during this period were a continuation of those seen during the first year (1), and generally were of little clinical significance. Ocular conditions, which were secondary to desiccation of the eyes during surgery, were limited to the globe and accessory structures, and had no significant impact on the animals' health. Other postsurgical complications, e.g., xyphoid protuberance, were also insignificant to the outcome of the study.

One hundred eighteen unscheduled animals died or were euthanized at various times during the second year. These animals exhibited more aging and compound-related complications than did animals in the first year. IBC-treated animals in the unscheduled group had compound-related gross fibrous adhesions between the liver and the diaphragm, abdominal wall, and/or visceral organs. A similar lesion was observed in IBC-treated animals euthanized at the final sacrifice (scheduled animals). Microscopically, these lesions were characterized as a foreign-body granulomatous reaction involving the liver capsule and parenchyma.

Analysis of the results of this study indicates that the intra-abdominal administration of IBC is related to the development of sarcomas in Fischer-344 rats. Thirty-one (16%) of the IBC-treated animals and none of the controls developed these tumors. The major concern is the mechanism by which the test material exerts its carcinogenic effect. The results of this study do not indicate definitively whether chemical carcinogenesis or solid-state carcinogenic mechanisms were involved in the induction of these tumors.

Solid-state carcinogenesis is a phenomenon which has been recognized for nearly fifty years (7). There is a large body of literature documenting the occurrence of this phenomenon, and comprehensive reviews of this topic have been published (8,9,10). Solid-state carcinogenesis involves the development of sarcomas in the subcutis or abdominal cavity of laboratory rodents that have had solid, smooth-surfaced material implanted in these sites. A wide variety of materials, including numerous plastics, cellophane, teflon, metals, and glass have been shown to induce sarcomas by this mechanism. The chemical nature of the implanted material is irrelevant to the production of tumors. The characteristics essential for tumor production are the size and form of the implant. A smooth surface is essential. Solid-state carcinogenesis occurs only when the implanted material is a film, sheet, or other large form having a smooth surface. If the same material is pulverized and administered as a powder, no tumors result. The tumors develop in the fibrous, granulomatous, foreign-body reaction that envelopes the implanted material. The tumors that result are invariably sarcomas that have diverse histologic variation.

The sarcomas that were present in rats implanted with IBC in this study probably developed as a result of solid-state carcinogenesis. The characteristics of the implanted material, the anatomic sites involved, and the histologic differentiation of the sarcomas fulfill the criteria for this mechanism. However, since a group of animals implanted with pulverized IBC was not included in the experimental design, chemical carcinogenic mechanisms, though an unlikely cause of the sarcomas, cannot be completely ruled out on the basis of these results.

Six animals in this study had sarcomas that were clearly unrelated to the test material. Four were invasive fibrosarcomas observed in the subcutis of the inguinal region in female rats. The inguinal fibrosarcomas probably resulted from malignant transformation of the connective tissue stroma of mammary glands. The incidence of these tumors does not differ significantly from that in published reports. The fibrosarcoma that was present in the external ear adjacent to

the metal identification tag in one animal is interesting in that it may represent an additional case of solid-state carcinogenesis in response to a foreign body. The presence of one sarcoma in the kidney of a control rat is interpreted as a spontaneous lesion unrelated to the experiment, and of little consequence.

Four IBC-treated rats in this study (2 low-dose males and 2 high-dose females) developed hepatocellular carcinoma. No control animals exhibited this lesion. Although the incidence of this malignant liver tumor was not statistically significant, these results may have biological significance and provide reason for concern. The incidence of hepatocellular carcinoma for IBC-treated male rats in this study was 1.9%, while the incidence for treated females was 2.1%. In published reports documenting tumor incidence, hepatocellular carcinomas occur at a rate of 0.2% in female and 0.8% in male control Fischer-344 rats (11-16). However, the increased incidence of hepatocellular carcinoma did not follow a dose-response trend characteristic of hepatocellular tumors induced by chemical carcinogens.

Sixty-two rats in this study developed large granular lymphocyte leukemia, a common neoplasm of lymphoid tissue in Fischer-344 rats. This disease has been well-studied and characterized in the literature (17,18,19). The incidence and characteristics of this disease in rats used in this study did not differ significantly from published information. Forty-two rats died with this disease prior to scheduled terminal sacrifice. The premature deaths of these animals probably had little or no impact on the results or conclusions drawn from this study.

Most of the rats treated with IBC had gross adhesions and fibrous, granulomatous foreign-body reactions on the liver and adjacent organs that came in contact with the test material. These lesions persisted for the normal life-span of the rat. As noted in the interim report covering the first year of this study, the physical presence of the compound and attendant response may have affected the function and patency of the intestinal tract. The increased incidence of hepatocytic vacuolization in livers of treated animals indicates possible alterations in metabolism of these cells. Although such altered metabolism could be due to chemical toxicity, it is just as likely the result of local circulatory disturbances caused by the presence of the compound and associated foreign body reaction. The increased incidence of reactive hyperplasia, red blood cells, and hemosiderin pigment in lymph nodes of treated rats is not surprising. Such changes normally occur in nodes draining areas of chronic inflammation.

The results of this study do not elucidate fully the carcinogenic potential of isobutyl 2-cyanoacrylate. Although the data suggest the sarcomas were induced by solid-state mechanisms, they are not definitive because of a lack of a dose group that received ground polymerized IBC. The incidence of hepatocellular carcinomas in treated animals, at a rate more than twice that reported for rats of the same strain and age in other studies (although a statistically nonsignificant incidence), gives cause for concern. Because of the potential usefulness of IBC as a tissue adhesive in surgical and dental procedures, additional studies designed to evaluate fully the carcinogenic potential and mechanisms of this material should be conducted.

### CONCLUSION

During the second year of this two-year carcinogenicity bioassay of IBC, there were no treatment-related changes in survival, weight gain, or clinical condition of the rats. Compound-related lesions observed in animals during the second year included adhesions and/or local granulomatous reactions of the liver or other abdominal organs, and liver or other soft tissue tumors or neoplasia. An increased incidence of sarcomas was attributed to the chronic implantation of IBC in the Fischer-344 rat. There was no clear evidence that the hepatocellular carcinomas observed were attributable to the IBC.

## REFERENCES

1. Brown LD, Smith CD, Lollini LO, Korte DW. A carcinogenicity bioassay of isobutyl 2-cyanoacrylate (IBC) in Fischer-344 rats--one-year interim sacrifice report. Toxicology Series 144. Institute Report No. 262. Presidio of San Francisco, CA: Letterman Army Institute of Research, March 1988.
2. National Institutes of Health. National Research Council. Guide for the care and use of laboratory animals. (5th revised ed.) Bethesda, MD: U.S. Department of Health, Education and Welfare, 1985; NIH Publication No. 85-23.
3. Chronic bucrylate<sup>®</sup> bioassay procedures within toxicology GLP suite and administrative areas. LAIR Standard Operating Procedure OP-STX-81. Letterman Army Institute of Research, Presidio of San Francisco, CA: 21 March 1984.
4. Chronic carcinogen bioassay. LAIR Standard Operating Procedure OP-STX-73. Letterman Army Institute of Research, Presidio of San Francisco, CA: 9 November 1983.
5. Food and Drug Administration. Nonclinical laboratory studies, good laboratory practice regulations, final rule. In: 21 CFR 58. Washington, DC: Food and Drug Administration, 22 Dec 1978; 43 FR 59986-60025.
6. Maronpot RR, Montgomery CA, Boorman GA, McConnell EE. National toxicology program nomenclature for hepatoproliferative lesions of rats. Tox Pathol 1986; 14:263-273.
7. Turner FC. Sarcomas at sites of subcutaneously implanted bakelite discs in rats. JNCI 1941; 2:81-83.
8. Bischoff F, Bryson G. Carcinogenesis through solid surfaces. Progr Exp Tumor Res 1964; 5:85-113.
9. Lawrence WH. Tumor induction. Chapter 17. In: von Recum AF, ed. Handbook of biomaterials evaluation: scientific, technical, and clinical testing of implant materials. 1st ed. New York: Macmillan Publishing Co, 1986:188-197 (66 references).

REFERENCES (cont.)

10. Woodward SC, Salthouse TN. The tissue response to implants and its evaluation by light microscopy. Chapter 30. In: von Recum AF, ed. Handbook of biomaterials evaluation: scientific, technical, and clinical testing of implant materials. 1st ed. New York: Macmillan Publishing Co, 1986:364-378 (32 references).
11. Haseman JK, Huff J, Boorman GA. Use of historical control data in carcinogenicity studies in rodents. *Tox Pathol* 1984; 12:126-135.
12. Haseman JK, Huff J, Rao GN, Boorman GA, McConnell EE. Neoplasms observed in untreated and corn oil control groups of F344/N Rats and (C57BL/6N x C3H/HeN)F1 (B6C3F1) Mice. *JNCI* 1985; 75:975-984.
13. Salleveld HA, Haseman JK, McConnell EE. Natural history of body weight gain, survival, and neoplasia in the F-344 rat. *JNCI* 1984; 72:929-940.
14. National Institutes of Health. National Toxicology Program. Toxicology and carcinogenesis studies of dimethyl morpholinophosphoramidate (CAS No. 597-25-1) in F344/N rats and B6C3F1 mice (gavage studies). Research Triangle Park, NC: US Department of Health and Human Services, January 1986; Technical Report Series NTP No. 298 (NIH No. 86-2554).
15. National Institutes of Health. National Toxicology Program. Toxicology and carcinogenesis studies of HC red no. 3 (CAS No. 2871-01-4) in F344/N rats and B6C3F1 mice (gavage studies). Research Triangle Park, NC: US Department of Health and Human Services, January 1986; Technical Report Series NTP No. 281 (NIH No. 86-2537).
16. National Institutes of Health. National Toxicology Program. Toxicology and carcinogenesis studies of CI basic red 9 monohydrochloride (pararosaniline) (CAS No. 569-61-9) in F344/N rats and B6C3F1 mice (feed studies). Research Triangle Park, NC: US Department of Health and Human Services, January 1986; Technical Report Series NTP No. 285 (NIH No. 86-2541).
17. Ward JM, Reynolds CW. Large granular lymphocyte leukemia, a heterogeneous lymphocytic leukemia in F344 rats. *Am J Pathol* 1983; 111:1-10.



**REFERENCES (cont.)**

18. Stromberg PC. Large granular lymphocyte leukemia in F-344 rats. Am J Pathol 1985; 119:517-519.
19. Losco PE, Ward JM. The early stage of large granular lymphocyte leukemia in the F-344 rat. Vet Pathol 1984; 21:286-291.

	Page
Appendix A. Chemical Data .....	39
Appendix B. Animal Data .....	46
Appendix C. Surgical Report .....	48
Appendix D. Historical Listing of Study Events .....	54
Appendix E. Glossary of Terms for Clinical Observations .....	57
Appendix F. Individual Animal Histories .....	64
Appendix G. Gross Necropsy Observations, Incidence Summary .....	369
Appendix H. Microscopic Observations, Incidence Summary .....	379
Appendix I. Glossary of Terms for Pathology Findings .....	402
Appendix J. Pathology Individual Animal Data .....	466

**Appendix A: CHEMICAL DATA**

Chemical Name: Isobutyl 2-cyanoacrylate

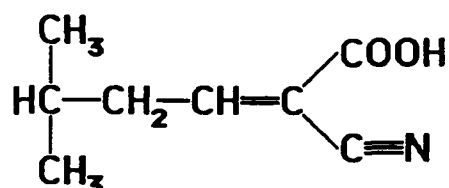
Other Listed Names: Bucrylate<sup>®</sup>, 2-cyano-2-propenoic acid 2-methyl-propyl ester, 2-cyanoacrylic acid isobutyl ester, bucrilate, IBC, IBCA\*

Chemical Abstracts Service Registry No.: 1069-55-2\*

Therapeutic Category: Surgical aid (tissue adhesive)\*

LAIR Code: TP60

Chemical Structure:



Molecular Formula: C<sub>8</sub>H<sub>11</sub>NO<sub>2</sub>

Molecular Weight: 153.18

Physical State: Clear colorless liquid

Boiling Point: 170°C\*

Stability: Stable in sealed ampules. Polymerizes within minutes on contact with air. Polymerizes in less than 1 second on contact with ionic solutions, e.g., saline or blood.\*

Name of Contaminants and Percentages: See chemical data sheet attached

Source: Ethicon, Inc.  
Somerville, NJ 08876

Lot No.: 929-252

Analytical Data/Purity:

Infrared spectrophotometry was performed on 11, 23, and 25 Jan 84, and the results were identical to the standard spectrum from Ethicon, Inc. Major absorption peaks were observed at 2965, 1740, 1470, 1385, 1290, 1190, 980, 930, and 715 cm<sup>-1</sup>.

**Appendix A (cont.): CHEMICAL DATA**

Analytical Data/Stability:

Samples of isobutyl 2-cyanoacrylate (IBC) were evaluated by gas chromatography on 11, 23, and 25 Jan 84.† Thus, IBC was analyzed prior to dosing, on the first day of dosing, and the day following dosing. The chromatogram for each analysis showed only one peak, with a retention time of 3.3 min. These data support the sponsor's claim that the IBC will not deteriorate inside the sealed ampules.

---

\* Windholz M. Merck index. 10th edition, 1983. Monograph number 1433, Bucrylate®. Page 201-202. Merck & Co, Inc, Rahway, NJ.

† O'Connor RJ. Memorandum for record, 26 Jan 1984, Subject: Analysis report, GLP Study No. 83009, Analytical Chemistry Group. Letterman Army Institute of Research, Presidio of San Francisco, CA.

Appendix A (cont.): CHEMICAL DATA

# ETHICON

INC.

SOMERVILLE . NEW JERSEY

January 6, 1984

To: Dr. W. D. Sheffield

cc: Mrs. S. L. Couchman  
Dr. A. W. Fetter  
Mr. J. P. O'Donnell  
Dr. D. W. Regula

Subject: BUCRYLATE TISSUE ADHESIVE  
TUMORGENICITY STUDY  
-----

The following material is being transmitted to you for initiation of the tumorigenicity study:

Lot #929-252 (750 ampules)  
0.5 ml  
IBC-2

One hundred twenty-five ampules have been included for stability assurance testing and another one hundred twenty-five ampules for long-term retention as required by GLP regulations.

Attached are the finished goods test results and a reference infrared spectrum for this lot. The primary sterility run number is R315001 and the overwrap sterility run number is R343MB2.

Please let me know if I can answer any questions.

*Eva Furrier*  
Eva Furrier

mem

Attachment

## Appendix A (cont.): CHEMICAL DATA

Finished Goods Test Results

Lot #929-252

<u>Test</u>	<u>Result</u>
Identification, Infra-Red	Conforms to standard
Total Monomer, % (W/W)	99.9.
SO <sub>2</sub> , ppm (W/V)	562
Hydroquinone, % (W/W)	0.081
Isobutyl Cyanoacetate, ppm (W/W)	None detected
Color	0.046 at 400 nanometer 0.0002 from 400-800 nanometers
NIR Absorptivity, mg/absorbance unit	2.188
H <sub>2</sub> O, ppm (W/V)	<100
Heavy Metals as Lead, ppm (W/W)	<10
Isobutanol, ppm (W/V)	725
Viscosity, cps at 30°C	2.3

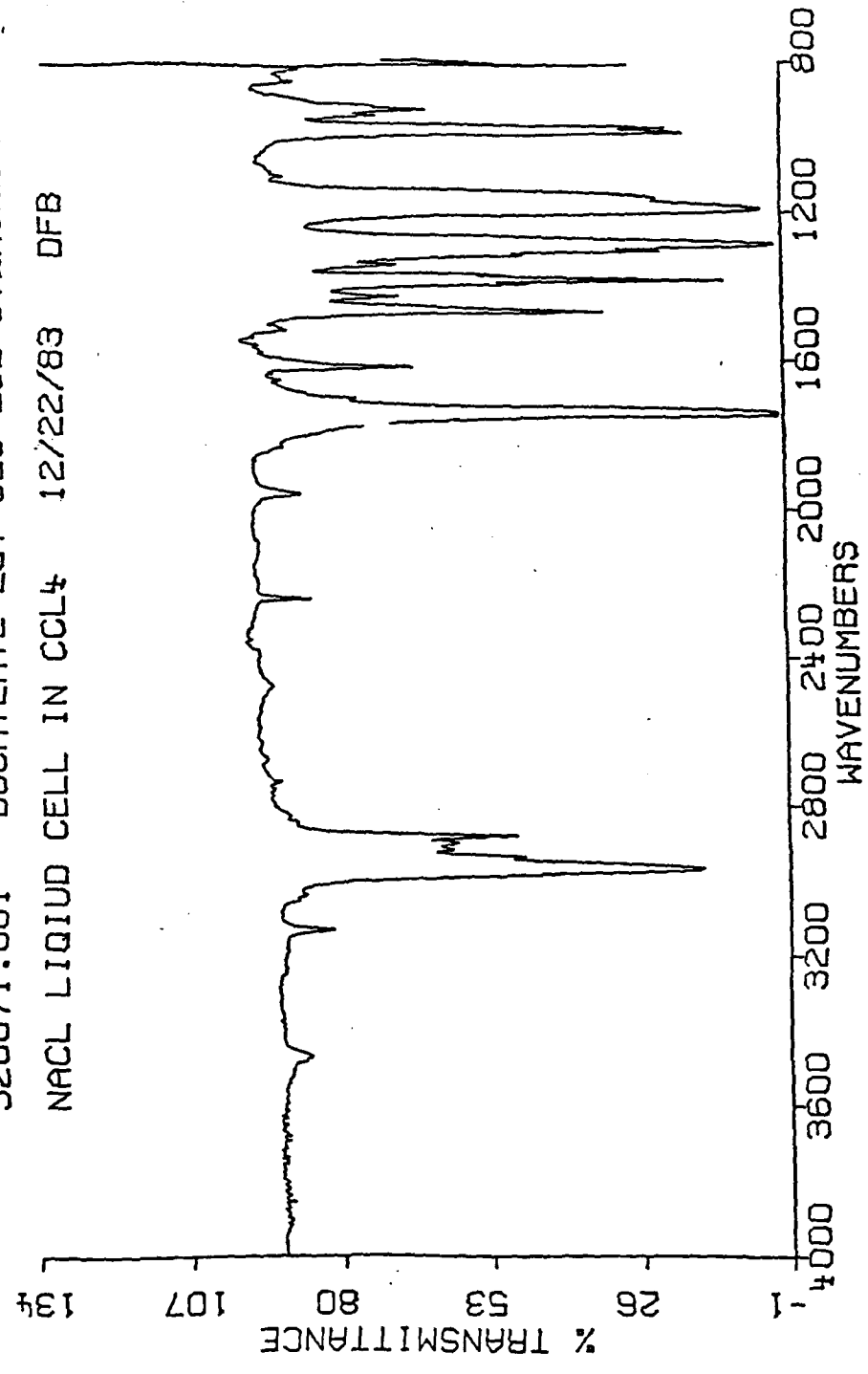
Reference #929-252  
Analytical Service Request #20071

S220071  
12/22/83  
258

Appendix A (cont.): CHEMICAL DATA

S20071.001 BUCRYLATE LOT 929-252 STERILE FINISHED PRODUCT

NACL LIQUID CELL IN CCL4 12/22/83 DFB



Appendix A (cont.): CHEMICAL DATA



DEPARTMENT OF THE ARMY  
LETTERMAN ARMY INSTITUTE OF RESEARCH  
PRESIDIO OF SAN FRANCISCO, CALIFORNIA 94129

REPLY TO  
ATTENTION OF:

SGRD-ULV-AC

26 January 1984

MEMORANDUM FOR RECORD

SUBJECT: Analysis Report, GLP Study No. 83009, Analytical Chemistry Group

Date: 26 Jan 84  
Sample: IBC-2 (Isobutyl-2-cyanoacrylate)  
Lot: 929-252

I. Identity

The Infrared Spectrums 131, 132, 133 (11 Jan 84), 135, 136, 137 (23 Jan 84), and 138, 139, 140 (25 Jan 84) are consistent with the Infrared Spectrum provided by ETHICON (SR 20071 - 12/22/83-DFB).

Instrument: Perkin-Elmer Model 457  
Red Tag 2912  
FSN 6650-C19-5014

Methods: Analytical method AD-100B, identification of isobutyl-2-cyanoacrylates, analytical chemistry, ETHICON, Inc. (9/16/70), was used as the basis for analysis. The Infrared Spectrums were done in two different ways. The first followed the above method with the following exceptions: KBr (potassium bromide) was used for the window material and the reference cell was a variable path length cell that was matched to the sample cell. The second method was a "Neat" film of the sample between KBr windows. The film method provided additional information including a peak near  $800\text{ cm}^{-1}$  which was masked by the solvent in the first method.

II. Purity

The gas chromatographic profiles of IBC-2 showed one major component representation 100% of the total peak area when it was run on 11 Jan 84, 23 Jan 84, and 25 Jan 84.

Methods: Analytical method AD-100B, identification of isobutyl-2-cyanoacrylates, analytical chemistry, ETHICON, Inc. (9/16/70), was used as the basis for the analysis.



Appendix A (cont.): CHEMICAL DATA

SGRD-ULV-AC

26 January 1984

SUBJECT: Analysis Report, GLP Study No. 83009, Analytical Chemistry Group

Instrument: Varian 4600

Column: 3% SP-2100 on 100/120

Injector: 200°C

Detector: 250°C

Carrier Gas: Nitrogen (20 cc/min)

Run Length: 15 minutes

Detector: FID

Sensitivity: 10-11

III. Conclusion

The above data indicates that the IBC-2, Lot 929-252, has not deteriorated in the sealed vials provided by ETHICON and is consistent with the data provided.



RICHARD J. O'CONNOR  
Research Chemist  
Analytical Chemistry Group

**Appendix B: ANIMAL DATA**

Species: *Rattus norvegicus*

Strain: Fischer-344 (CDF)

Source: Charles River Breeding Laboratories, Inc.  
Wilmington, MA 01887  
Reared at Kingston (K62) plant

Sex: Male and female

Date of birth: 13 December 1983

Method of randomization: Weight biased, stratified animal  
allocation (TOXSYS Animal  
Allocation Program, SOP OP-ISG-24)

Animals in each group: 68 male and 68 female animals, except  
female control group totaled 67  
animals

Condition of animals at start of study: Normal

Body weight range at dosing: 29 g - 123 g  
(male mean = 94.0 g; female mean = 73.8 g)

**Toxicology In-Life**

**Identification Procedures (TOXSYS):**

Ear-tagging procedure (SOP-OP-ARG 1), tag numbers  
84D00001 to 84D00209 (inclusive) for males and  
84D00226 to 84D00435 (inclusive) for females.

**Pathology Identification Procedures:**

Animals were assigned a three-digit number for data  
entry into the Xybion Data Acquisition Computer. A  
cross reference list for the TOXSYS assigned numbers  
was generated by the LAIR Comparative Pathology  
Branch (Appendix J).

Pretest conditioning: Quarantine/acclimation 11-22 January  
1984

**Justification:** The Fischer-344 laboratory rat (versus the  
Sprague-Dawley or Charles River CD rat) has proven to  
be a sensitive and reliable model for chronic  
carcinogenesis bioassays due to its low incidence of  
spontaneous mammary gland and liver cancer. This  
strain is recommended by the NCI Carcinogenesis  
Bioassay Program.

## Appendix B (cont.): ANIMAL DATA

## Group Codes:

<u>Group</u>	<u>Toxicology Code</u>	<u>Pathology Code</u>
High-Dose IBC (100 $\mu$ l)	A* (Red)†	1 §(High)
Low-Dose IBC (10 $\mu$ l)	B* (Yellow)†	2 §(Low)
Saline Control (100 $\mu$ l)	C* (White)†	3 §(CTL)

\* Alphabetic code used on 2 x 3 inch cage card and on animal's chest during surgical phase.

† Plastic cage card protector contained a bar-coded animal number (84D00---) and a 0.5 inch square piece of color coded tape.

§ Numerical code used to group pathology data within Xybion computer software.

**Appendix C: SURGICAL REPORT**

SGRD-ULV-P

30 March 1984

MEMORANDUM FOR RECORD

SUBJECT: Surgical Report, GLP Study 83009

1. On 23 & 24 January 1984, surgery was performed in the Operating Room, LAIR, on 407 six-week-old acclimated Fischer-344 rats assigned to the Toxicology Services Group's (TSG) chronic two-year Bucrylate® Carcinogenesis Bioassay. Surgeons involved were: COL Carpenter and LTC Koppelman, USAIDR, and LTC Rodkey, LAIR. Surgery was performed under LAIR GLP Protocol 83009.

2. Surgery was necessary to enable the test substance (Bucrylate) to be applied directly to the surface of the liver of study animals. Surgery on 179 males occurred on 23 Jan, and surgery on the remaining 25 males and 203 females occurred on 24 Jan 84.

3. Animals were transported, one rack of 60 rats at a time, to the Operating Room Services Group (ORSG) Surgical Suite from the Toxicology Services Group Animal Suite. Racks were covered with sterile sheets to provide for infection control and a dark, quiet, unstressed environment. Surgery started at 0730 hours on 23 Jan with animal number 84D00001 and progressed through animal numbers sequentially to 84D00434. Animals were randomly assigned to the three dose groups. Animals were presented to the surgeons in a random fashion without regard to group assignment. Animals were fasted (from food only) 1-4 hours prior to surgery.

4. Each animal was examined for health, checked to verify identification (ear tag, cage card bar code, and group assignment tape), and weighed on an Arbor scale (TOXSYS terminal recorded). The scale was recalibrated each morning prior to use. Male animals weighed approximately 100 g and females 75 g each. Anesthesia consisted of an intramuscular hindlimb injection of a mixture of xylazine HCl (10 mg/kg) and ketamine HCl (50 mg/kg). Anesthetic was prepared by LTC Rodkey by mixing 5 ml ketamine (100 mg/cc), 2.5 ml Rompun® (20 mg/cc) and 42.5 ml of sterile saline. Dose calculations, lot, and expiration of anesthetics and diluent are provided in Incl #1.

**Appendix C (cont.): SURGICAL REPORT**

5. Proper identification and controls on group assignment for dosing were stressed. Color coded tape, containing the animal's number, was placed on the tail of the animal while a "back-up system" letter signifying dose group was placed on the chest of the animal with surgical marker pen (black CMS fine tip marking pen, lot #138-800). Animals were prepared for surgery by clipping the abdomen and caudal ventral half of the thorax with a number 40 Oster™ blade and Oster electric clipper. Animal anesthesia, weighing, and clipping were performed by TSG technicians under MAJ Morgan's supervision.

6. Rats were placed on a rat restraining board in the supine position and the clipped area was scrubbed with povidone-iodine surgical soap and disinfected with povidone-iodine solution and alcohol. The rats were moved to the surgery table and draped so that only the surgically prepared area was exposed. LAIR surgical operating procedures applicable to instrument sterilization, aseptic technique, and sterile field were in effect. Surgical packs were exchanged, cleaned, and autoclaved after every 6 animals. Surgeons changed gloves after every six animals, and dosing personnel changed gloves frequently.

7. A midline laparotomy incision was made extending 2-3 cm caudal from the xyphoid cartilage. The liver was exposed by the surgeon using either ophthalmic surgical retractors or by "tenting" the abdominal wall with forceps. Bucrylate (Lot 929-252; Ethicon, Inc.) or sterile saline was applied to the inferior surface of the exposed liver (usually caudate lobe) in amounts specified in the protocol. Dose Group 1, the high dose IBC group, received 100 microliters ( $\mu$ l) of isobutyl 2-cyanoacrylate (IBC); Dose Group 2 (low dose IBC) received 10  $\mu$ l of IBC, and Group 3 (saline control) received 100  $\mu$ l of sterile isotonic saline (Lot 56-329-FD-05, Exp. 1 Sep 1986; Abbott). Dosing was performed by TSG personnel using fixed volume Eppendorf micropipettes (calibrated 17 and 18 Jan 84) with sterile disposable tips. One ampule of Bucrylate was used per animal for dose groups 1 and 2--any remaining test compound was discarded.

8. One animal (84D00126) was misdosed and immediately removed from the study. After application of the IBC, the abdominal walls were retracted or "tented" for approximately two minutes to allow for drying of the test substance. Dosing was monitored by the principal investigator, MAJ Brown (TOXSYS ID 10186).

**Appendix C (cont.): SURGICAL REPORT**

9. The laparotomy incision was closed using two layers. The first consisted of 4-0 Vicryl® (Ethicon, Inc.) in a simple continuous pattern for the abdominal fascia, muscle, and peritoneum. The skin was closed using either 35 mm Proximate® (Ethicon, Inc.) skin staples or 35 mm Michelle skin clips.

10. Animals were recovered in clean, rat rack cages in the autoclave room adjoining the Surgical Suite. Room temperature in the recovery area was warm (29.1-31.9°C). After approximately 2 hours in the recovery area, the animals were transferred back to the TSG Animal Suite, and given water and food.

11. Animals were monitored postoperatively by LTC Rodkey and TSG staff. Skin staples were removed on 31 Jan and 1 Feb 84 (7-10 days) by TSG veterinarians. Twelve of the 407 rats died or were removed from the study during the first week after surgery due to underweight condition, surgical complications, and/or obstructed intestine due to Bucrylate adhesions. Postoperatively, rat #84D00013 acquired an infection along the line of incision. After one week of treatment with hydrogen peroxide, the incision healed. Approximately 50 animals were noted to have corneal opacities one week postoperatively. Keratoconjunctivitis sicca (dry eye) and subsequent ulcerative keratitis are fairly common sequelae to rat surgery. The etiology is thought to be related to drying of the cornea as the globe protrudes, and under anesthesia, the eyelids fail to cover the cornea and the blink reflex is absent. Ophthalmic ointment is probably indicated in all rodent procedures using general level anesthesia.


12. Overall, the surgery went very smoothly and animals tolerated the procedure well. On 1 Feb 84, 382 animals had recovered--the initial goal was to have at least 360 survivors for the study.

13. Personnel assisting in the surgery are listed in Incl #2. Study records are on file listing, by animal, the amounts of anesthesia administered, surgeon, and dosing personnel. Ms. Janice M. Adams, Manager, Regulatory Affairs, Ethicon, Inc., audited the surgery on 23 & 24 Jan 84. CPT Carroll, LAIR, QAO also visited the Surgical Suite during this period.

**Appendix C (cont.): SURGICAL REPORT**

14. In preparation for surgery, a meeting was held between ORSG and TSG personnel on 13 Jan 84. The Ethicon videotape on the surgical procedure was reviewed and technicians practiced the dosing procedure using Eppendorf micropipettes and one ampule of Bucrylate. Pilot surgery was performed on 20 Jan 84. Eighteen rats were operatively laparotomized and dosed according to simulated group assignments.

Incl  
as



WILLIAM G. RODKEY, DVM  
LTC, VC  
Chief, Operating Room Services Group  
Diplomate, Am Coll Vet Surgeons

CF:  
COL Carpenter  
LTC Koppelman  
MAJ Korte  
Raw data Binder, 83009

**Appendix C (cont.): SURGICAL REPORT**

Enclosure One to Surgical Memorandum For Record, 30 March 1984

**ANESTHESIA GLP STUDY 83009**

---

Rat Wt	Xylazine*	Ketamine†	Vol Mixture§
80 g	0.4 mg	4 mg	0.4 ml
100 g	0.5 mg	5 mg	0.5 ml
120 g	0.6 mg	6 mg	0.6 ml
140 g	0.7 mg	7 mg	0.7 ml

---

\* Rompun® , 10 mg/cc, Haver-Lockart, Shawnee, KS.

† Vetalar® , 100 mg/cc, Parke-Davis, Morris Plains, NJ.

§ Anesthetic mixture contained 10 mg ketamine and 1 mg xylazine (Rompun®)/ml

**Mixture§ Components**

---

Xylazine (Rompun®) 10 mg/kg, 20 mg/cc, (Lot 260013, Jan 85 Exp.)

Ketamine (Vetalar®) 50 mg/kg, 100 mg/cc, (Lot 03793p, Jul 88 Exp.)

Saline Diluent∞, (Lot 7C856X9, Nov 84 Exp.)

---

§ Anesthetic Mixture Formula: 5 ml ketamine soln + 2.5 ml xylazine soln + 42.5 ml saline = 50 ml anesthetic mixture

∞ Viaflex®, 0.9% NaCl Injection USP, Travenol Laboratories, Inc., Deerfield, IL.



**Appendix C (cont.): SURGICAL REPORT**

Enclosure Two to Surgical Memorandum For Record, 30 March  
1984

LAIR PERSONNEL WORKING ON SURGICAL PHASE OF GLP STUDY 83009

<u>Personnel</u>	<u>Group</u>	<u>Duty</u>
MAJ Korte, Don W. Jr	Toxicology	Study Director
MAJ Brown, Larry D.	Toxicology	Principal Investigator
MAJ Morgan, Earl W.	Toxicology	TOXSYS, Presurgery Prep, Recovery
SFC Farmer, Charles N.	Toxicology	Scheduling
SP5 Kellner, Thomas P.	Toxicology	Dosing
SP5 Mullen, Lawrence	Toxicology	Dosing
SP5 Rodriquez, Justo	Toxicology	Prep
PFC Sano, Steven K.	Toxicology	Prep, Late Night Recovery
Ms. Lewis, Carolyn M.	Toxicology	Dosing
Ms. Coppes, Valerie G.	Toxicology	Initial Recovery, Prep
Mr. Dacey, John	Toxicology	Dosing
Mr. Spieler, Richard A.	Toxicology	Primary Animal Caretaker
Ms. Hernandez, Susan	Toxicology	TOXSYS, Prep
Mr. Sands, Edward M.	Toxicology	Prep
LTC Rodkey, William G.	Operating Rm	Surgery
SSG Del la Cerda, Maria V.	Operating Rm	Surgery
SSG Davis, Garry	Operating Rm	Surgery
SP5 Weber, David	Operating Rm	Surgery
SP5 Aiken, Byron	Operating Rm	Surgery
SP5 Cornier-Garcia Juan	Operating Rm	Surgery
SP5 Stevens, Daniel	Operating Rm	Surgery
SP4 Peterson, Kimothy	Operating Rm	Surgery
PFC Rothhammer, Gregory A.	Animal Res Group	Prep

**Appendix D: HISTORICAL LISTING OF STUDY EVENTS**

<u>Date</u>	<u>Event</u>
11 Jan 84	209 male and 210 female Charles River (CDF) Fischer-344 rats were received. Animals were checked for physical condition, sexed, individually caged, and fed.
12 Jan 84	Rats were ear-tagged and weighed. Eight rats (4 male and 4 female) were submitted for necropsy quality control.
11 - 22 Jan 84	Animals were observed daily during quarantine/acclimation period.
19 Jan 84	Animals were weighed and randomized into dose groups.
20 Jan 84	Three underweight animals and one maloccluded animal were sacrificed.
23 Jan 84 - 29 Jan 85	All animals were observed twice daily throughout the study for clinical signs and mortality.
23 Jan 84	One hundred seventy-nine animals were weighed, provided with ketamine/xylazine anesthesia, surgically laparotomized, and implanted with IBC or saline according to dose group.
24 Jan 84	Two hundred twenty-eight animals were weighed, provided with ketamine/xylazine anesthesia, surgically laparotomized, and implanted with IBC or saline according to dose group.
24 Jan - 1 Feb 84	All animals were observed frequently during the 7-day postoperative recovery period.
24, 25, 26, 27, or 28 Jan 84	Twenty-five animals either died or were sacrificed during the postoperative period because of complications or underweight conditions.

**Appendix D (cont.): HISTORICAL LISTING OF STUDY  
EVENTS**

<u>Date</u>	<u>Event</u>
1 Feb 84	Three hundred eighty-two (93.9%) of 407 rats that went to surgery remained on study.
3 Feb 84 - 27 Jan 85	Seventeen unscheduled animals were necropsied during first year of study - 14 sacrificed due to poor condition and 3 died in cage.
3,31 Mar, 8 Apr, 9,18,19,27 Jun, 14,16 Jul,15 Sep, 13 Dec 84	Steam outages occurred, or animal suite ventilation fans were down. Spikes in room temperature and small drops in relative humidity occurred during these periods.
12,19,23 or 24 Jan 84, 28 or 29 Jan 85	All animals were weighed.
16 or 17 Feb, 15 or 16 Mar, 12 or 13 Apr, 10 or 11 May, 7 or 8 Jun, 5 or 6 Jul, 2 or 3 Aug, 30 or 31 Aug, 27 or 28 Sep, 25 or 26 Oct, 22 or 23 Nov, 20 or 21 Dec 84, and 17 or 18 Jan 85	All animals were examined, palpated by veterinarian or toxicologist, and weighed at 28-day intervals (monthly).
28 - 29 Jan 85	Interim sacrifice. Sixty animals were weighed, sacrificed, and necropsied.
30 Jan 85	Three hundred five rats remain "on study" for second year of study.
30 Jan 85 - 10 Feb 86	One hundred eighteen unscheduled animals were necropsied during second year of study - 97 sacrificed due to poor condition and 21 died in cage.

**Appendix D (cont.): HISTORICAL LISTING OF STUDY  
EVENTS**

<u>Date</u>	<u>Event</u>
27 Apr, 21 Aug, 26 Oct, 2 Nov, 14 Dec 85, 7 Jan 86	Steam outages occurred, or animal suite ventilation fans were down. Spikes in relative humidity and small drops in room temperature occurred during these periods.
14 or 15 Feb, 14 or 15 Mar, 11 or 12 Apr, 9 or 10 May, 6 or 7 Jun, 2 or 3 Jul, 1 or 2 Aug, 29 or 30 Aug, 26 or 27 Sep, 24 or 25 Oct, 21 or 22 Nov, 19 or 20 Dec 85, 16 or 17 Jan 86	All animals were examined, palpated by veterinarian or toxicologist, and weighed at 28-day intervals (monthly).
27 Jan - 14 Feb 86	Final sacrifice. One hundred and eighty-seven animals were weighed, sacrificed and necropsied.
14 Feb 86	Study "in-life" completed.

**Appendix E: GLOSSARY OF TERMS FOR CLINICAL  
OBSERVATIONS**

Long-term (TOXSYS® Term) - Definition

1. General

- a. Normal (NORMAL) - animal appears to be healthy, exhibits no recognizable clinical signs.
- b. Hunched Posture (HUNCH POS) - an increase in the curvature of the thoracic spine as viewed from the side.
- c. Prostration (PROSTRATE) - animal stretched out in a horizontal position but conscious.
- d. Loss of Consciousness (LOSS CONS) - prostrate and unresponsive to sensory stimuli (touch, sound, pain, light, etc.).
- e. Moribund (MORIBUND) - animal is near death.
- f. Death (DEATH) - permanent cessation of all vital body functions.
- g. Emaciated (EMACIATED) - the animal appears to have lost weight, but the skin appears hydrated (i.e., the skin does not remain in place when squeezed together).
- h. Dehydrated (DEHYDRATE) - the animal appears to have lost weight and skin remains in place when squeezed.
- i. Pallor (PALLOR) - a lack of color to the skin or eyes.

2. Behavioral

- a. Inactive (INACTIVE) - a decrease in the locomotor activity of the animal.
- b. Hyperactive (HYPERACT) - an increase in the locomotor activity of the animal.
- c. Irritable (IRRITABLE) - an increase in annoyance or anger to slight stimulation.

**Appendix E (cont.): GLOSSARY OF TERMS FOR CLINICAL OBSERVATIONS**

- d. Aggressive (AGGRESS) - animal is bold, wants to fight, characterized by a desire to bite for no apparent reason.
- e. Vocalization (VOCAL) - production of sound from the larynx.
- f. Increased or Decreased Preening (IN PREEN or DE PREEN) - an increase or decrease in the grooming behavior of the animal.
- g. Circling (CIRCLING) - repeated walking or running in a circle.
- h. Jumping (JUMPING) - springing or leaping around the cage.
- i. Chewing (CHEWING) - animal goes through the motion of biting and/or grinding with no external stimulus.
- j. Ataxia (ATAXIA) - loss of coordination characterized by staggering or loss of gait.
- k. Hypotonia (HYPOTONIA) - decrease in muscle tone.
- l. Hypertonia (HYPERTONIA) - increase in muscle tone.
- m. Catalepsy (TRANCE) - animal tends to remain in any position in which it is placed.
- n. Somnolence (DROWSY) - animal appears drowsy, but can be aroused by prodding and resumes normal activities.
- o. Tremors (TREMORS) - a trembling or quivering of the limbs or entire body.
- p. Fasciculation (TWITCH) - twitching of the muscles seen on the back, shoulders, hind limbs, and paws.
- q. Writhing (WRITH) - twisting or wrenching the body abnormally.
- r. Paralysis (PARALYSIS) - loss or impaired motor function in the limbs or entire body.

**Appendix E (cont.): GLOSSARY OF TERMS FOR CLINICAL OBSERVATIONS**

- s. Disoriented (DISORIENT) - animal appears dazed and confused.

3. Convulsions

- a. Tonic Convulsion (TONIC) - persistent contraction of muscles with rigid extension of limbs.
- b. Clonic Convulsion (CLONIC) - convulsion alternating contraction and relaxation of muscles.
- c. Tonic-clonic Convulsion (MIXED) - both types may appear consecutively.
- d. Opisthotonus (OPISTOT) - tetanic spasm in which the back is arched and the head pulled towards the dorsal position.

4. Reflexes

- a. Depressed Myotactic Reflex (PULL) - decreased ability of animal to retract its hind limb when the limb is pulled down.
- b. Depressed Pinch Reflex (PINCH) - decreased response (jerking away of limb) to pinching of toes.
- c. Depressed Grasping Reflex (GRASP) - decreased ability to take hold of finger firmly when hung from it.
- d. Depressed Righting Reflex (RIGHTING) - decreased ability to assume normal position when the animal has been placed on its side or back.
- e. Depressed Corneal Reflex (CORNEAL) - decreased response (closing of the eyelids) to touching of the cornea.
- f. Depressed Pupillary Reflex (PUPILLARY) - decreased constriction of the pupil in the presence of light.
- g. Increased Startle Reflex (STARTLE) - increased response to external stimuli (e.g., touch, noise).

**Appendix E (cont.): GLOSSARY OF TERMS FOR CLINICAL OBSERVATIONS**

- h. Depressed Pinnal Reflex (PINNAL) - decreased response (twitching of external ear) elicited by stroking of inside surface of ear.

5. Respiratory

- a. Increased or Decreased Respiratory Rate (IN RATE or DE RATE) - an increase or decrease in the repetitions of inhaling and exhaling air.
- b. Increased or Decreased Respiratory Depth (IN DEPTH or DE DEPTH) - an increase or decrease in the volume of air inhaled or exhaled with each repetition.
- c. Irregular Respiration (IRREGULAR) - any irregular rate and/or depth of respiration. Since this can be any pattern, a description should be given.
- d. Apnea (APNEA) - transient cessation of breathing.
- e. Gasping (GASPING) - deep, labored inspiration, often accompanied by a wheezing sound.
- f. Panting (PANTING) - rapid, shallow breathing.
- g. Wheezing (WHEEZE) - raspy sound made with breathing.
- h. Sneezing (SNEEZE) - animal makes sneezing-like sounds.
- i. Nasal Discharge (NASAL DIS) - a discharge from the nose is produced. A description of the color is required.

6. Ocular

- a. Lacrimation (TEARING) - an increase in the production of tears.
- b. Chromodacryorrhea (RED TEARS) - production of red-colored tears.
- c. Miosis (MIOSIS) - decreased pupil size.
- d. Mydriasis (MYDRIASIS) - increased pupil size.



**Appendix E (cont.): GLOSSARY OF TERMS FOR CLINICAL OBSERVATIONS**

- e. Squinting (SQUINTING) - closing of the eyelids, usually in response to light.
- f. Exophthalmus (BULGING) - increased protrusion of the eyeball.
- g. Corneal Opacity (OPACITY) - an opaque spot or area on the cornea.
- h. Conjunctivitis (CONJUNC) - inflammation of the conjunctiva, characterized by red, swollen eyelids.
- i. Ptosis (PTOSIS) - drooping of the upper eyelid from paralysis.

**7. Gastrointestinal**

- a. Increased Salivation (IN SALIVA) - an increase in the production of saliva.
- b. Dried Mucous Membranes (DRY MOUTH) - drying of the mucous membranes in the mouth, usually from decreased salivation.
- c. Retching (RETCHING) - a strong, unproductive gag response.
- d. Vomiting (VOMITING) - the expulsion of the contents of the stomach through the mouth.
- e. Diarrhea (DIARRHEA) - increased frequency and liquidation of fecal discharges.
- f. Scant Feces (SCANT) - decrease in the frequency of fecal discharges.
- g. Tarry Feces (TARRY) - blackish, watery feces often due to blood in the feces.

**8. Skin/fur**

- a. Hyperemia (HYPEREMIA) - an increase in reddish color of skin over entire body, usually from vasodilation (i.e., flushed).

**Appendix E (cont.): GLOSSARY OF TERMS FOR CLINICAL OBSERVATIONS**

- b. Cyanosis (CYANOSIS) - a bluish discoloration of the skin, often related to respiratory problems.
  - c. Jaundice (JAUNDICE) - a yellow discoloration of the skin, often due to liver dysfunction.
  - d. Scaling (SCALING) - scaling of the skin.
  - e. Erythema (ERYTHEMA) - an increase in the redness of the skin in small areas (i.e., not the entire body). Location should be specified.
  - f. Bleeding (BLEEDING) - loss of blood. Location should be specified.
  - g. Scab (SCAB) - a crust of hardened blood and serum over a wound on the skin. Location should be specified.
  - h. Edema (EDEMA) - the presence of large amounts of fluid in the intercellular tissue spaces. Location should be specified.
  - i. Ulceration (ULCERATN) - the formation of a break in the skin or mucous membrane with loss of surface tissue, disintegration and necrosis of epithelial tissue, and often pus. Location should be specified.
  - j. Necrosis (NECROSIS) - localized death of living tissue. Location should be specified.
  - k. Alopecia (HAIR LOSS) - absence or loss of hair from the skin where it normally is present. Location should be specified.
  - l. Rough Coat (RGH COAT) - a rough appearance to the coat due to any number of reasons, such as piloerection, dullness, lack of grooming.
9. Miscellaneous
- a. Urine, Feces - meant to be used with color descriptors to describe any abnormal coloration.

**Appendix E (cont.): GLOSSARY OF TERMS FOR CLINICAL  
OBSERVATIONS**

- b. Stain, Material - meant to be used with color and location descriptors to describe any abnormal stains or material found on the coat.
- c. Color Descriptors - clear, light, dark, yellow, orange, red, blue, green, and brown.
- d. Location Descriptors - head, mouth, eye, ear, nose, neck, front leg, hind leg, thorax, abdomen, back, side, flank, perianal, tail, left, right, and both.

PAGE 1  
DATE: 6/09/87  
TIME: 14:40:13  
EDS017 V4M11

**Appendix F: INDIVIDUAL ANIMAL HISTORIES**

CARCINOGENICITY BIOASSAY OF ISOBUTYL 2-CYANO-  
ACRYLATE (IBC) IN MALE AND FEMALE RATS.

STUDY: 0083009  
COMPOUND: ISOBUTYL 2-CYANOACRYLATE  
START DATE: 1/28/85

**ANIMAL HISTORY**

Animal ID: 84D00030 Species: D Sex: MALE Group: CONTROLS

DATE	TIME	OPERATOR	WEIGHT (GRAMS)	CLINICAL OBSERVATIONS
2/14/85	7:52:18	0000337	405.0	NORMAL
3/14/85	8:05:02	0078478	410.0	NORMAL
4/11/85	7:59:50	0000337	409.0	NORMAL
5/09/85	6:53:14	0000337	416.0	NORMAL
6/06/85	7:54:16	0010186	419.0	NORMAL
7/02/85	6:46:16	0000337	411.0	NORMAL
8/01/85	8:20:02	0001576	411.0	NORMAL
8/29/85	6:50:10	0000337	416.0	NORMAL
9/26/85	7:21:24	0000337	414.0	NORMAL
10/24/85	7:15:52	0034567	415.0	NORMAL
11/21/85	13:17:58	0002920	414.0	NORMAL
12/18/85	8:30:56	0000337		STAIN BROWN HEAD MODERATE, EMACIATED MARKED, ANOREXIA MARKED
12/18/85	8:34:14	0000337		* No observations recorded.

## Appendix F (cont.): INDIVIDUAL ANIMAL HISTORIES

PAGE 2  
 DATE: 6/09/87  
 TIME: 14:40:13  
 EDS017 V4M11

STUDY: 0083009 CARCINOGENICITY BIOASSAY OF ISOBUTYL 2-CYANO-  
 COMPOUND: ISOBUTYL 2-CYANOACRYLATE ACRYLATE (IBC) IN MALE AND FEMALE RATS.

START DATE: 1/28/85

## ANIMAL HISTORY

Animal ID: 84D00032 Species: D Sex: MALE Group: CONTROLS

DATE	TIME	OPERATOR	WEIGHT (GRAMS)	CLINICAL OBSERVATIONS
2/14/85	8:36:22	0000337	446.0	NORMAL
3/14/85	8:06:22	0078478	454.0	NORMAL
3/25/85	8:17:42	0000337		CONJUNCTIVITIS BOTH EYE SLIGHT, STAIN BROWN NOSE MODERATE, STAIN YELLOW PERIANAL MODERATE, STAIN BROWN MOUTH SLIGHT, ANOREXIC
3/27/85	9:43:30	0000337		NORMAL
4/11/85	8:01:20	0000337	444.0	NORMAL
5/09/85	7:28:12	0000337	457.0	PAPILLOMA NOSE SMALL
6/06/85	7:55:26	0010186	461.0	PAPILLOMA NOSE SMALL
7/02/85	6:54:38	0000337	452.0	PAPILLOMA NOSE SMALL
8/01/85	8:20:46	0001576	459.0	PAPILLOMA NOSE SMALL
8/29/85	7:12:30	0084799	476.0	SUBCUTANEOUS MASS LEFT SIDE ABDOMEN SIZE LARGE (20 X 20MM) SUBCUTANEOUS MASS LEFT SIDE OF ABDOMEN SIZE LARGE (35 X 40 MM), PAPILLOMA NOSE SMALL
9/19/85	6:04:28	0084799		SUBCUTANEOUS MASS LEFT SIDE LARGE

**Appendix F (cont.): INDIVIDUAL ANIMAL HISTORIES**

STUDY: 0083009 CARCINOGENICITY BIOASSAY OF ISOBUTYL 2-CYANO-  
 COMPOUND: ISOBUTYL 2-CYANOACRYLATE ACRYLATE (IBC) IN MALE AND FEMALE RATS.  
 START DATE: 1/28/85

PAGE 30  
 DATE: 6/09/87  
 TIME: 14:40:13  
 EDS017 VAM11.1

ANIMAL HISTORY

Animal ID: 84D00033 Species: D Sex: MALE Group: 10 UL/ANM

DATE	TIME	OPERATOR	WEIGHT (GRAMS)	CLINICAL OBSERVATIONS
2/14/85	8:36:50	0000337	435.0	INTERABDOMINAL MASS VENTRAL TO LIVER
2/28/85	7:47:12	0000337	445.0	INTERABDOMINAL MASS VENTRAL TO LIVER
3/14/85	8:06:52	0078478	446.0	INTRAABDOMINAL MASS VENTRAL TO LIVER, SIZE MEDIUM
4/03/85	9:13:14	0000337	449.0	INTRAABDOMINAL MASS, SIZE MEDIUM
4/11/85	8:02:30	0000337	447.0	INTRAABDOMINAL MASS VENTRAL TO LIVER, SIZE MEDIUM
4/25/85	8:22:50	0000337	455.0	INTRAABDOMINAL MASS VENTRAL TO LIVER, SIZE MEDIUM
5/09/85	7:30:18	0000337	455.0	INTRAABDOMINAL MASS VENTRAL TO LIVER, SIZE MEDIUM
5/22/85	7:18:14	0000337		INTRAABDOMINAL MASS VENTRAL TO LIVER SIZE LARGE
6/04/85	7:15:38	0000337		INTRAABDOMINAL MASS VENTRAL TO LIVER SIZE LARGE, CORNEAL OPACITY LEFT EYE MARKED
6/06/85	7:56:50	0010186	454.0	CORNEAL OPACITY LEFT EYE MARKED, INTRAABDOMINAL MASS VENTRAL TO LIVER MODERATE
6/19/85	6:49:54	0000337		INTRAABDOMINAL MASS VENTRAL TO LIVER SIZE LARGE, PROLAPSED LENS LEFT EYE MARKED
7/02/85	6:58:16	0084799	448.0	INTRAABDOMINAL MASS VENTRAL TO LIVER SIZE MEDIUM OPAQUE LENS LEFT EYE MARKED PROLAPSED LENS LEFT EYE MARKED
8/01/85	8:25:56	0084799	450.0	OPAQUE LENS LEFT EYE MARKED, PROLAPSED LENS LEFT EYE MARKED, INTRAABDOMINAL MASS VENTRAL TO LIVER SIZE MEDIUM
8/29/85	7:15:32	0000337	455.0	OPAQUE LENS LEFT EYE MARKED, PROLAPSED LENS LEFT EYE MARKED, INTRAABDOMINAL MASS VENTRAL TO LIVER SIZE MEDIUM
9/26/85	7:22:18	0000337	444.0	HYPHEMIA LEFT EYE MODERATE, OPAQUE LENS LEFT EYE MARKED, INTRAABDOMINAL MASS VENTRAL TO LIVER SIZE MEDIUM
10/24/85	7:30:50	0084799	449.0	OPAQUE LENS LEFT EYE MARKED, INTRAABDOMINAL MASS VENTRAL TO LIVER SIZE MEDIUM
11/21/85	13:19:48	0084799	437.0	OPAQUE LENS LEFT EYE MARKED, INTRAABDOMINAL MASS VENTRAL TO LIVER SIZE MEDIUM
12/19/85	7:50:26	0084799	426.0	INTRAABDOMINAL MASS VENTRAL TO LIVER SIZE LARGE, SPLENIC MASS SIZE LARGE, PROLAPSED LENS LEFT EYE MARKED
12/19/85	15:22:44	0000337		* No observations recorded.

**Appendix F (cont.): INDIVIDUAL ANIMAL HISTORIES**

PAGE 4  
 DATE: 6/09/87  
 TIME: 14:40:13  
 EDS017 V4M11

STUDY: 0083009 ISOBUTYL 2-CYANOACRYLATE  
 COMPOUND: ISOBUTYL 2-CYANOACRYLATE  
 START DATE: 1/28/85

CARCINOGENICITY BIOASSAY OF ISOBUTYL 2-CYANO-  
 ACRYLATE (IBC) IN MALE AND FEMALE RATS.

ANIMAL HISTORY

Animal ID: 84D00034 Species: D Sex: MALE Group: 10 UL/ANM

DATE	TIME	OPERATOR	WEIGHT (GRAMS)	CLINICAL OBSERVATIONS
2/14/85	8:40:36	0000337	393.0	NORMAL
3/14/85	8:11:08	0078478	399.0	NORMAL
4/11/85	8:06:58	0000337	403.0	NORMAL
5/09/85	7:31:32	0000337	404.0	NORMAL
6/06/85	8:00:48	0010186	419.0	NORMAL
7/02/85	7:02:20	0000337	413.0	NORMAL
8/01/85	8:27:54	0001576	418.0	NORMAL
8/29/85	7:18:16	0000337	419.0	NORMAL
9/26/85	7:26:10	0000337	415.0	NORMAL
10/21/85	8:52:32	0072808		SCAB HEAD SLIGHT
10/24/85	7:32:38	0034567	420.0	SCAB HEAD SLIGHT
11/21/85	13:23:54	0002920	408.0	SCAB HEAD SLIGHT
12/19/85	7:54:06	0000337	411.0	SCAB HEAD SLIGHT
1/16/86	7:48:26	0000337	406.0	SCAB HEAD SLIGHT
1/27/86	8:03:24	0000337	380.0	SCAB HEAD SLIGHT, EUTHANIZED

STUDY: 0083009  
 COMPOUND: ISOBUTYL 2-CYANOACRYLATE  
 START DATE: 1/28/85

CARCINOGENICITY BIOASSAY OF ISOBUTYL 2-CYANO-  
 ACRYLATE (IBC) IN MALE AND FEMALE RATS.

**Appendix F (cont.): INDIVIDUAL ANIMAL HISTORIES**

PAGE 5  
 DATE: 6/09/87  
 TIME: 14:40:13  
 EDS017 V4M11

ANIMAL HISTORY

Animal ID: 84D00035 Species: D Sex: MALE Group: CONTROLS

DATE	TIME	OPERATOR	WEIGHT (GRAMS)	CLINICAL OBSERVATIONS
2/14/85	8:41:00	0000337	408.0	NORMAL
3/04/85	7:49:02	0000337		STAIN BROWN NOSE SLIGHT
3/12/85	7:51:30	0000337		NORMAL
3/14/85	8:11:48	0078478	417.0	NORMAL
4/11/85	8:08:10	0000337	427.0	NORMAL
5/09/85	7:32:00	0000337	429.0	NORMAL
6/06/85	8:01:28	0010186	435.0	NORMAL
7/02/85	7:03:00	0000337	437.0	NORMAL
8/01/85	8:28:14	0001576	440.0	NORMAL
8/29/85	7:20:44	0000337	435.0	NORMAL
9/26/85	7:26:32	0000337	433.0	NORMAL
10/24/85	7:33:32	0034567	439.0	NORMAL
11/21/85	13:26:32	0002920	412.0	NORMAL
12/19/85	7:54:38	0000337	419.0	PODODERMATITIS LEFT REAR HOCK SLIGHT
1/16/86	9:00:02	0000337	406.0	PODODERMATITIS LEFT REAR HOCK SLIGHT
1/27/86	8:05:38	0000337	368.0	PODODERMATITIS LEFT HOCK SLIGHT, EUTHANIZED



## Appendix F (cont.): INDIVIDUAL ANIMAL HISTORIES

PAGE 6  
DATE: 6/09/87  
TIME: 14:40:13  
EDS017 V4M11

STUDY: 0083009  
COMPOUND: ISOBUTYL 2-CYANOACRYLATE  
START DATE: 1/28/85

CARCINOGENICITY BIOASSAY OF ISOBUTYL 2-CYANO-  
ACRYLATE (IBC) IN MALE AND FEMALE RATS.

## ANIMAL HISTORY

Animal ID: 84D00036 Species: D Sex: MALE Group: CONTROLS

DATE	TIME	OPERATOR	WEIGHT (GRAMS)	CLINICAL OBSERVATIONS
2/14/85	8:41:22	0000337	428.0	NORMAL
3/14/85	8:12:40	0078478	423.0	NORMAL
4/11/85	8:08:58	0000337	435.0	PAPILLOMA BASE OF TAIL
5/09/85	7:32:32	0000337	442.0	PAPILLOMA BASE OF TAIL SMALL
6/06/85	8:01:58	0010186	453.0	PAPILLOMA BASE OF TAIL SMALL
7/02/85	7:03:32	0000337	448.0	PAPILLOMA BASE OF TAIL SMALL
8/01/85	8:28:40	0001576	412.0	PAPILLOMA BASE OF TAIL SMALL
8/29/85	7:21:22	0000337	454.0	PAPILLOMA BASE OF TAIL SIZE SMALL
9/26/85	7:26:58	0000337	434.0	TAIL PAPILLOMA SMALL
10/24/85	7:33:52	0084799	444.0	PAPILLOMA TAIL SMALL
11/06/85	7:50:10	0000337		NORMAL
11/21/85	13:27:18	0002920	419.0	NORMAL
12/02/85	10:36:42	0072808		INACTIVE SLIGHT, STAIN RED BACK SLIGHT, DEPRESSED MODERATE
12/03/85	12:50:58	0000337		INACTIVE MARKED, ANOREXIA MARKED



## Appendix F (cont.): INDIVIDUAL ANIMAL HISTORIES

PAGE 8  
DATE: 6/09/87  
TIME: 14:40:13  
EDS017 V4M11

STUDY: 0083009 ISOBUTYL 2-CYANOACRYLATE  
COMPOUND: ISOBUTYL 2-CYANOACRYLATE  
START DATE: 1/28/85

CARCINOGENICITY BIOASSAY OF ISOBUTYL 2-CYANO-  
ACRYLATE (IBC) IN MALE AND FEMALE RATS.

## ANIMAL HISTORY

Animal ID: 84D00039 Species: D Sex: MALE Group: CONTROLS

DATE	TIME	OPERATOR	WEIGHT (GRAMS)	CLINICAL OBSERVATIONS
2/14/85	8:42:06	0000337	405.0	NORMAL
3/14/85	8:15:48	0078478	414.0	NORMAL
4/11/85	8:11:40	0000337	417.0	NORMAL
5/09/85	7:34:08	0000337	425.0	NORMAL
6/06/85	8:03:00	0010186	435.0	NORMAL
7/02/85	7:04:40	0000337	439.0	NORMAL
8/01/85	8:30:18	0001576	441.0	NORMAL
8/29/85	7:22:38	0000337	441.0	NORMAL
9/26/85	7:28:40	0000337	450.0	NORMAL
10/24/85	7:35:24	0034567	460.0	NORMAL
11/21/85	13:31:32	0002920	438.0	NORMAL
12/19/85	7:56:16	0000337	404.0	NORMAL
1/03/86	9:43:30	0000337		STAIN BROWN HEAD SLIGHT, PALLOR SLIGHT, EMACIATED MODERATE
1/16/86	9:01:22	0000337	316.0	EMACIATED MARKED, CONJUNCTIVITIS BOTH EYE MARKED, STAIN YELLOW PERIARIAL

PAGE 90  
 DATE: 6/09/87  
 TIME: 14:40:13  
 EDS017 VAM11

**Appendix F (cont.): INDIVIDUAL ANIMAL HISTORIES**

STUDY: 0083009  
 COMPOUND: ISOBUTYL 2-CYANOACRYLATE  
 START DATE: 1/28/85

CARCINOGENICITY BIOASSAY OF ISOBUTYL 2-CYANO-  
 ACRYLATE (IBC) IN MALE AND FEMALE RATS.

ANIMAL HISTORY

Animal ID: 84D00040 Species: D Sex: MALE Group: CONTROLS

DATE	TIME	OPERATOR	WEIGHT (GRAMS)	CLINICAL OBSERVATIONS
2/14/85	8:42:22	0000337	419.0	NORMAL
3/14/85	8:16:16	0078478	431.0	NORMAL
4/11/85	8:12:26	0000337	427.0	NORMAL
5/09/85	7:34:30	0000337	431.0	NORMAL
6/06/85	8:03:22	0010186	437.0	NORMAL
7/02/85	7:05:14	0000337	433.0	NORMAL
8/01/85	8:30:38	0001576	429.0	NORMAL
8/29/85	7:23:02	0000337	433.0	NORMAL
9/26/85	7:28:58	0000337	428.0	NORMAL
10/24/85	7:36:12	0034567	425.0	NORMAL
11/21/85	13:32:14	0002920	421.0	NORMAL
12/19/85	7:56:58	0000337	402.0	NORMAL
1/16/86	9:05:10	0000337	383.0	NORMAL
1/27/86	8:10:58	0000337	355.0	NORMAL / EUTHANIZED

## Appendix F (cont.): INDIVIDUAL ANIMAL HISTORIES

PAGE 10  
 DATE: 6/09/87  
 TIME: 14:40:13  
 EDS017 VHM1

STUDY: 0083009 ISOBUTYL 2-CYANOACRYLATE CARCINOGENICITY BIOASSAY OF ISOBUTYL 2-CYANO-  
 COMPOUND: ISOBUTYL 2-CYANOACRYLATE ACRYLATE (IBC) IN MALE AND FEMALE RATS.  
 START DATE: 1/28/85

## ANIMAL HISTORY

Animal ID: 84D00041 Species: D Sex: MALE Group: 10 UL/ANM

DATE	TIME	OPERATOR	WEIGHT (GRAMS)	CLINICAL OBSERVATIONS
2/14/85	8:42:50	0000337	392.0	NORMAL
3/14/85	8:16:44	0078478	404.0	NORMAL
4/11/85	8:13:26	0000337	406.0	NORMAL
5/09/85	7:34:58	0000337	412.0	NORMAL
6/06/85	8:03:46	0010186	421.0	NORMAL
7/02/85	7:06:02	0000337	415.0	NORMAL
8/01/85	8:31:00	0001576	423.0	NORMAL
8/29/85	7:23:22	0000337	422.0	NORMAL
9/26/85	7:29:22	0000337	427.0	NORMAL
10/24/85	7:36:30	0034567	433.0	NORMAL
11/21/85	13:32:46	0002920	397.0	NORMAL
12/04/85	8:02:04	0000337		STAIN BROWN NOSE SLIGHT
12/11/85	10:45:28	0000337		STAIN BROWN MODERATE, STAIN BROWN MOUTH MODERATE, EMACIATED MARKED

PAGE 11  
 DATE: 6/09/87  
 TIME: 14:40:13  
 EDS017 VAN11

**Appendix F (cont.): INDIVIDUAL ANIMAL HISTORIES**

STUDY: 0083009  
 COMPOUND: ISOBUTYL 2-CYANOACRYLATE  
 START DATE: 1/28/85

CARCINOGENICITY BIOASSAY OF ISOBUTYL 2-CYANO-  
 ACRYLATE (IBC) IN MALE AND FEMALE RATS.

ANIMAL HISTORY

Animal ID: 84D00042 Species: D Sex: MALE Group: CONTROLS

DATE	TIME	OPERATOR	WEIGHT (GRAMS)	CLINICAL OBSERVATIONS
2/14/85	8:43:10	0000337	355.0	NORMAL
3/14/85	8:17:06	0078478	377.0	NORMAL
4/11/85	8:14:18	0000337	382.0	NORMAL
5/09/85	7:35:20	0000337	382.0	NORMAL
6/06/85	8:04:10	0010186	377.0	NORMAL
7/02/85	7:06:32	0000337	379.0	NORMAL
8/01/85	8:31:26	0001576	389.0	NORMAL
8/29/85	7:23:48	0000337	392.0	NORMAL
9/26/85	7:29:46	0000337	386.0	NORMAL
10/24/85	7:36:52	0034567	395.0	NORMAL
11/21/85	13:33:14	0002920	391.0	NORMAL
12/19/85	7:57:12	0000337	394.0	NORMAL
1/16/86	9:05:34	0000337	379.0	NORMAL
1/27/86	8:12:18	0000337	360.0	NORMAL / EUTHANIZED

**Appendix F (cont.): INDIVIDUAL ANIMAL HISTORIES**

PAGE 14  
 DATE: 6/09/87  
 TIME: 14:40:13  
 EDS017 VAM11

STUDY: 0083009  
 COMPOUND: ISOBUTYL 2-CYANOACRYLATE  
 START DATE: 1/28/85

CARCINOGENICITY BIOASSAY OF ISOBUTYL 2-CYANO-  
 ACRYLATE (IBC) IN MALE AND FEMALE RATS.

ANIMAL HISTORY

Animal ID: 84D00046 Species: D Sex: MALE Group: 10 UL/ANM

DATE	TIME	OPERATOR	WEIGHT (GRAMS)	CLINICAL OBSERVATIONS
2/14/85	8:43:40	0000337	390.0	NORMAL
3/14/85	8:17:34	0078478	392.0	NORMAL
4/11/85	8:15:08	0000337	396.0	NORMAL
5/09/85	7:35:54	0000337	397.0	NORMAL
6/06/85	8:04:34	0010186	408.0	NORMAL
7/02/85	7:07:18	0000337	409.0	NORMAL
8/01/85	8:31:48	0001576	408.0	NORMAL
8/29/85	7:24:30	0000337	404.0	NORMAL
9/26/85	7:30:08	0000337	403.0	NORMAL
10/24/85	7:37:10	0034567	411.0	NORMAL
11/21/85	13:33:34	0002920	402.0	NORMAL
12/19/85	7:57:30	0000337	404.0	NORMAL
1/16/86	9:07:34	0000337	386.0	NORMAL
1/27/86	8:13:32	0000337	366.0	NORMAL / EUTHANIZED

**Appendix F (cont.): INDIVIDUAL ANIMAL HISTORIES**

STUDY: 0083009  
COMPOUND: ISOBUTYL 2-CYANOACRYLATE  
START DATE: 1/28/85

CARCINOGENICITY BIOASSAY OF ISOBUTYL 2-CYANO-  
ACRYLATE (IBC) IN MALE AND FEMALE RATS.

ANIMAL HISTORY

Animal ID: 84D00047 Species: D Sex: MALE Group: CONTROLS

DATE	TIME	OPERATOR	WEIGHT (GRAMS)	CLINICAL OBSERVATIONS
2/14/85	8:44:16	0000337	417.0	NORMAL
3/12/85	7:53:26	0000337		STAIN BROWN NOSE SLIGHT
3/14/85	8:18:50	0078478	430.0	NORMAL
4/11/85	8:15:54	0000337	433.0	NORMAL
5/09/85	7:36:22	0000337	444.0	NORMAL
6/06/85	8:05:02	0010186	447.0	NORMAL
7/02/85	7:07:46	0000337	436.0	NORMAL
8/01/85	8:32:18	0001576	454.0	NORMAL
8/29/85	7:24:54	0000337	455.0	NORMAL
9/26/85	7:30:34	0000337	463.0	NORMAL
10/24/85	7:37:38	0034567	457.0	NORMAL
11/21/85	13:34:02	0002920	447.0	NORMAL
12/19/85	7:57:50	0000337	449.0	NORMAL
1/16/86	9:07:52	0000337	439.0	NORMAL
1/27/86	8:14:50	0000337	405.0	NORMAL / EUTHANIZED



**Appendix F (cont.): INDIVIDUAL ANIMAL HISTORIES**

PAGE 14  
 DATE: 6/09/87  
 TIME: 14:40:14  
 EDS01/V4311

STUDY: 0083009  
 COMPOUND: ISOBUTYL 2-CYANOACRYLATE  
 START DATE: 1/28/85

CARCINOGENICITY BIOASSAY OF ISOBUTYL 2-CYANO-  
 ACRYLATE (IBC) IN MALE AND FEMALE RATS.

ANIMAL HISTORY

Animal ID: 84D00049 Species: D Sex: MALE Group: 10 UL/ANM

DATE	TIME	OPERATOR	WEIGHT (GRAMS)	CLINICAL OBSERVATIONS
2/14/85	8:44:34	0000337	374.0	NORMAL
3/14/85	8:19:44	0078478	430.0	NORMAL
4/11/85	8:16:50	0000337	434.0	NORMAL
5/09/85	7:36:44	0000337	440.0	NORMAL
5/22/85	7:24:32	0000337		INTRAABDOMINAL MASS VENTRAL TO LIVER SIZE MEDIUM
6/06/85	8:06:04	0010186	446.0	INTRAABDOMINAL MASS VENTRAL TO LIVER SIZE MEDIUM
6/06/85	8:11:48	0010186	446.0	PODDERMATITIS LEFT REAR HOCK SLIGHT
6/10/85	7:50:42	0000337		PODDERMATITIS RIGHT REAR HOCK SLIGHT, INTRAABDOMINAL MASS VENTRAL TO LIVER SIZE MEDIUM
7/02/85	7:08:28	0000337	467.0	INTRAABDOMINAL MASS VENTRAL TO LIVER SIZE MEDIUM
8/01/85	8:32:42	0001576	450.0	CONJUNCTIVITIS RIGHT EYE SLIGHT, INTRAABDOMINAL MASS VENTRAL TO LIVER SIZE MEDIUM
8/13/85	8:28:12	0000337		INTRAABDOMINAL MASS VENTRAL TO LIVER SIZE MEDIUM
8/29/85	7:25:32	0000337	448.0	INTRAABDOMINAL MASS VENTRAL TO LIVER SIZE MEDIUM
9/26/85	7:30:54	0000337	449.0	INTRAABDOMINAL MASS VENTRAL TO LIVER SIZE MEDIUM
10/24/85	7:38:12	0034567	470.0	INTRAABDOMINAL MASS VENTRAL TO LIVER SIZE MEDIUM
11/21/85	13:34:30	0002920	461.0	INTRAABDOMINAL MASS VENTRAL TO LIVER SIZE MEDIUM
12/19/85	7:58:10	0000337	454.0	INTRAABDOMINAL MASS VENTRAL TO LIVER SIZE MEDIUM
1/16/86	9:08:12	0000337	452.0	INTRAABDOMINAL MASS VENTRAL TO LIVER SIZE MEDIUM, SUBCUTANEOUS MASS LEFT THORAX SIZE MEDIUM
1/27/86	8:16:14	0000337	422.0	INTRAABDOMINAL MASS VENTRAL TO LIVER SIZE MEDIUM, SUBCUTANEOUS MASS LEFT THORAX SIZE MEDIUM, EUTHANIZED

PAGE 15  
 DATE: 6/09/87  
 TIME: 14:40:13  
 EDS017 VAM11

**Appendix F (cont.): INDIVIDUAL ANIMAL HISTORIES**

STUDY: 0083009 CARCINOGENICITY BIOASSAY OF ISOBUTYL 2-CYANO-  
 COMPOUND: ISOBUTYL 2-CYANOACRYLATE ACRYLATE (IBC) IN MALE AND FEMALE RATS.

START DATE: 1/28/85

ANIMAL HISTORY

Animal ID: 84D00050 Species: D Sex: MALE Group: 100 UL/ANM

DATE	TIME	OPERATOR	WEIGHT (GRAMS)	CLINICAL OBSERVATIONS
2/14/85	8:46:06	0000337	368.0	INTERABDOMINAL MASS VENTRAL TO LIVER
2/14/85	8:48:06	0000337	388.0	INTERABDOMINAL MASS VENTRAL TO LIVER
2/28/85	7:51:42	0000337	416.0	INTERABDOMINAL MASS VENTRAL TO LIVER
3/14/85	8:20:38	0078478	421.0	INTRAABDOMINAL MASS VENTRAL TO LIVER, SIZE MEDIUM
4/03/85	9:16:00	0000337	422.0	INTRAABDOMINAL MASS VENTRAL TO LIVER, SIZE MEDIUM
4/11/85	8:17:42	0000337	426.0	INTRAABDOMINAL MASS VENTRAL TO LIVER, SIZE MEDIUM
4/25/85	8:27:38	0000337	430.0	INTRAABDOMINAL MASS VENTRAL TO LIVER, SIZE MEDIUM
5/09/85	7:37:30	0000337	431.0	INTRAABDOMINAL MASS VENTRAL TO LIVER, SIZE MEDIUM
6/06/85	8:10:18	0010186	435.0	INTRAABDOMINAL MASS VENTRAL TO LIVER, SIZE MEDIUM
7/02/85	7:09:50	0000337	426.0	INTRAABDOMINAL MASS VENTRAL TO LIVER, SIZE MEDIUM
8/01/85	8:34:02	0001576	428.0	INTRAABDOMINAL MASS VENTRAL TO LIVER, SIZE MEDIUM
8/29/85	7:27:02	0000337	439.0	INTRAABDOMINAL MASS VENTRAL TO LIVER, SIZE MEDIUM
9/26/85	7:34:00	0000337	441.0	INTRAABDOMINAL MASS VENTRAL TO LIVER, SIZE MEDIUM
10/24/85	7:40:36	0034567	446.0	INTRAABDOMINAL MASS VENTRAL TO LIVER, SIZE MEDIUM
11/21/85	13:38:52	0002920	442.0	INTRAABDOMINAL MASS VENTRAL TO LIVER, SIZE LARGE
12/04/85	8:06:16	0000337	440.0	INTRAABDOMINAL MASS VENTRAL TO LIVER, SIZE LARGE
12/19/85	7:59:30	0000337	430.0	INTRAABDOMINAL MASS VENTRAL TO LIVER, SIZE LARGE
1/16/86	9:10:28	0000337	430.0	INTRAABDOMINAL MASS VENTRAL TO LIVER, SIZE LARGE
1/27/86	8:20:02	0000337	397.0	INTRAABDOMINAL MASS VENTRAL TO LIVER, SIZE LARGE, EUTHANIZED

## Appendix F (cont.): INDIVIDUAL ANIMAL HISTORIES

PAGE 16  
DATE: 6/09/87  
TIME: 14:40:13  
EDS017 V4M11

STUDY: 0083009  
COMPOUND: ISOBUTYL 2-CYANOACRYLATE  
START DATE: 1/28/85

CARCINOGENICITY BIOASSAY OF ISOBUTYL 2-CYANO-  
ACRYLATE (IBC) IN MALE AND FEMALE RATS.

## ANIMAL HISTORY

Animal ID: 84D00051 Species: D Sex: MALE Group: 10 UL/ANN

DATE	TIME	OPERATOR	WEIGHT (GRAMS)	CLINICAL OBSERVATIONS
2/14/85	8:49:14	0000337	388.0	NORMAL
3/14/85	8:22:14	0078478	421.0	NORMAL
4/02/85	8:09:06	0000337		STAIN BROWN NOSE SLIGHT
4/11/85	8:19:18	0000337	419.0	NORMAL
5/09/85	7:38:44	0000337	424.0	NORMAL
6/06/85	8:14:50	0010186	417.0	NORMAL
7/02/85	7:10:44	0000337	413.0	NORMAL
8/01/85	8:36:50	0001576	417.0	NORMAL
8/29/85	7:28:08	0000337	418.0	NORMAL
9/26/85	7:38:22	0000337	423.0	NORMAL
10/24/85	7:41:42	0034567	413.0	NORMAL
11/21/85	13:40:06	0002920	398.0	NORMAL
12/19/85	8:00:20	0000337	353.0	PALLOR MODERATE, SPLENOMEGALY MEDIUM
12/23/85	10:33:48	0000337		PALLOR MODERATE, SPLENOMEGALY MODERATE



## Appendix F (cont.): INDIVIDUAL ANIMAL HISTORIES

PAGE 18  
DATE: 6/09/87  
TIME: 14:40:13  
EDS017 V4M11

STUDY: 0083009  
COMPOUND: ISOBUTYL 2-CYANOACRYLATE  
START DATE: 1/28/85

CARCINOGENICITY BIOASSAY OF ISOBUTYL 2-CYANO-  
ACRYLATE (IBC) IN MALE AND FEMALE RATS.

ANIMAL HISTORY

Animal ID: 84D00053 Species: D Sex: MALE Group: 10 UL/ANM

DATE	TIME	OPERATOR	WEIGHT (GRAMS)	CLINICAL OBSERVATIONS
2/14/85	8:50:22	0000337	450.0	NORMAL
3/14/85	8:23:26	0078478	462.0	NORMAL
4/11/85	8:21:46	0000337	469.0	NORMAL
5/09/85	7:39:56	0000337	468.0	NORMAL
6/06/85	8:16:24	0010186	472.0	NORMAL
7/02/85	7:12:20	0000337	467.0	INTRAABDOMINAL MASS VENTRAL TO LIVER SIZE MEDIUM
8/01/85	8:37:58	0001576	463.0	INTRAABDOMINAL MASS VENTRAL TO LIVER SIZE MEDIUM
8/29/85	7:29:22	0000337	467.0	INTRAABDOMINAL MASS VENTRAL TO LIVER SIZE MEDIUM
9/26/85	7:40:24	0000337	458.0	INTRAABDOMINAL MASS VENTRAL TO LIVER SIZE MEDIUM
10/24/85	7:43:16	0034567	459.0	INTRAABDOMINAL MASS VENTRAL TO LIVER SIZE MEDIUM
11/06/85	7:58:38	0000337		INTRAABDOMINAL MASS VENTRAL TO LIVER SIZE LARGE
11/21/85	13:42:22	0002920	448.0	INTRAABDOMINAL MASS VENTRAL TO LIVER SIZE LARGE
12/19/85	8:03:14	0000337	451.0	INTRAABDOMINAL MASS VENTRAL TO LIVER SIZE LARGE
1/16/86	9:11:40	0000337	395.0	INTRAABDOMINAL MASS VENTRAL TO LIVER SIZE LARGE, SPLENIC MASS SIZE LARGE

PAGE 190  
DATE: 6/09/87  
TIME: 14:40:13  
EDS017 V4M11

**Appendix F (cont.): INDIVIDUAL ANIMAL HISTORIES**

CARCINOGENICITY BIOASSAY OF ISOBUTYL 2-CYANO-  
ACRYLATE (IBC) IN MALE AND FEMALE RATS.

ANIMAL HISTORY

STUDY: 0083009  
COMPOUND: ISOBUTYL 2-CYANOACRYLATE  
START DATE: 1/28/85

Animal ID: 84D00054 Species: D Sex: MALE Group: CONTROLS

DATE	TIME	OPERATOR	WEIGHT (GRAMS)	CLINICAL OBSERVATIONS
2/14/85	8:50:48	0000337	412.0	NORMAL
3/14/85	8:23:56	0078478	425.0	NORMAL
4/11/85	8:22:56	0000337	435.0	NORMAL
5/09/85	7:40:26	0000337	438.0	NORMAL
6/06/85	8:17:02	0010186	439.0	NORMAL
7/02/85	7:14:38	0000337	440.0	NORMAL
8/01/85	8:38:44	0001576	444.0	NORMAL
8/29/85	7:30:34	0000337	454.0	NORMAL
9/26/85	7:41:42	0000337	432.0	NORMAL
10/24/85	7:44:10	0034567	435.0	NORMAL
11/21/85	13:43:30	0002920	410.0	NORMAL
12/19/85	8:03:54	0000337	405.0	NORMAL
1/16/86	9:16:08	0000337	389.0	NORMAL
1/27/86	8:24:28	0000337	358.0	NORMAL / EUTHANIZED

## Appendix F (cont.): INDIVIDUAL ANIMAL HISTORIES

PAGE 20  
DATE: 6/09/87  
TIME: 14:40:13  
EDS017 V4M11

STUDY: 0083009 CARCINOGENICITY BIOASSAY OF ISOBUTYL 2-CYANO-  
COMPOUND: ISOBUTYL 2-CYANOACRYLATE ACRYLATE (BC) IN MALE AND FEMALE RATS.

START DATE: 1/28/85

## ANIMAL HISTORY

Animal ID: 84D00055 Species: D Sex: MALE Group: 100 UL/ANM

DATE	TIME	OPERATOR	WEIGHT (GRAMS)	CLINICAL OBSERVATIONS
2/14/85	8:51:12	0000337	387.0	CORNEAL OPACITY LEFT EYE MODERATE, CORNEAL OPACITY RIGHT EYE SLIGHT
3/14/85	8:24:32	0078478	409.0	CORNEAL OPACITY LEFT EYE MODERATE, CORNEAL OPACITY RIGHT EYE SLIGHT
4/11/85	8:23:34	0000337	417.0	CORNEAL OPACITY LEFT EYE MODERATE, CORNEAL OPACITY RIGHT EYE SLIGHT
5/09/85	7:41:10	0000337	423.0	CORNEAL OPACITY LEFT EYE MODERATE, CORNEAL OPACITY RIGHT EYE SLIGHT, INTRAABDOMINAL MASS VENTRAL TO LIVER SIZE SMALL
5/22/85	7:33:36	0000337		CORNEAL OPACITY LEFT EYE MODERATE, CORNEAL OPACITY RIGHT EYE SLIGHT, INTRAABDOMINAL MASS VENTRAL TO LIVER SIZE MEDIUM
6/06/85	8:17:30	0010186	429.0	CORNEAL OPACITY LEFT EYE MODERATE, CORNEAL OPACITY RIGHT EYE SLIGHT, INTRAABDOMINAL MASS VENTRAL TO LIVER SIZE MEDIUM
6/19/85	7:04:00	0000337		CORNEAL OPACITY LEFT EYE MODERATE, CORNEAL OPACITY RIGHT EYE SLIGHT, INTRAABDOMINAL MASS VENTRAL TO LIVER SIZE MEDIUM
7/02/85	7:15:10	0000337	425.0	CORNEAL OPACITY LEFT EYE MODERATE, CORNEAL OPACITY RIGHT EYE SLIGHT, INTRAABDOMINAL MASS VENTRAL TO LIVER SIZE MEDIUM
8/01/85	8:39:04	0001576	432.0	CORNEAL OPACITY LEFT EYE MODERATE, CORNEAL OPACITY RIGHT EYE SLIGHT, INTRAABDOMINAL MASS VENTRAL TO LIVER SIZE MEDIUM
8/29/85	7:31:20	0000337	430.0	CORNEAL OPACITY LEFT EYE MODERATE, CORNEAL OPACITY RIGHT EYE SLIGHT, INTRAABDOMINAL MASS VENTRAL TO LIVER SIZE MEDIUM
9/26/85	7:42:08	0000337	421.0	CORNEAL OPACITY LEFT EYE MODERATE, CORNEAL OPACITY RIGHT EYE SLIGHT, INTRAABDOMINAL MASS VENTRAL TO LIVER SIZE MEDIUM
10/16/85	7:32:48	0084799		CORNEAL OPACITY LEFT EYE MODERATE, CORNEAL OPACITY RIGHT EYE SLIGHT, INTRAABDOMINAL MASS VENTRAL TO LIVER SIZE LARGE
10/24/85	7:44:52	0034567	423.0	CORNEAL OPACITY LEFT EYE MARKED, INTRAABDOMINAL MASS VENTRAL TO LIVER SIZE MEDIUM
11/21/85	13:44:12	0084799	411.0	CORNEAL OPACITY LEFT EYE MARKED, INTRAABDOMINAL MASS VENTRAL TO LIVER SIZE MEDIUM,
12/19/85	8:04:22	0084799	410.0	CORNEAL OPACITY LEFT EYE MARKED, INTRAABDOMINAL MASS VENTRAL TO LIVER SIZE MEDIUM, IRIS TEAR DORSAL ASPECT LEFT EYE
1/16/86	9:17:08	0000337	400.0	CORNEAL OPACITY LEFT EYE MARKED WITH OPAQUE LENS, ENLARGED GLOBE LEFT EYE MARKED WITH OPAQUE LENS
1/27/86	8:26:28	0000337	377.0	CORNEAL OPACITY LEFT EYE WITH MARKED OPACITY, EUTHANIZED, ENLARGED GLOBE LEFT EYE WITH MARKED OPACITY, EUTHANIZED

PAGE 21 @  
 DATE: 6/09/87  
 TIME: 14:40:13  
 EDS017 V4M11

**Appendix F (cont.): INDIVIDUAL ANIMAL HISTORIES**

STUDY: 0083009  
 COMPOUND: ISOBUTYL 2-CYANOACRYLATE  
 START DATE: 1/28/85

CARCINOGENICITY BIOASSAY OF ISOBUTYL 2-CYANO-  
 ACRYLATE (IBC) IN MALE AND FEMALE RATS.

ANIMAL HISTORY

Animal ID: 84D00056 Species: D Sex: MALE Group: CONTROLS

DATE	TIME	OPERATOR	WEIGHT (GRAMS)	CLINICAL OBSERVATIONS
2/14/85	8:52:06	0000337	394.0	CORNEAL OPACITY LEFT EYE SLIGHT
3/04/85	7:55:42	0000337		CORNEAL OPACITY LEFT EYE SLIGHT, STAIN BROWN NOSE SLIGHT
3/12/85	7:57:28	0000337		CORNEAL OPACITY LEFT EYE SLIGHT
3/14/85	8:25:12	0078478	407.0	CORNEAL OPACITY LEFT EYE SLIGHT
4/11/85	8:24:32	0000337	406.0	CORNEAL OPACITY LEFT EYE SLIGHT
5/09/85	7:45:32	0000337	415.0	CORNEAL OPACITY LEFT EYE SLIGHT
5/22/85	7:35:58	0000337		CORNEAL OPACITY LEFT EYE SLIGHT, SCAB RIGHT EAR SLIGHT
6/06/85	8:19:34	0010186	418.0	CORNEAL OPACITY LEFT EYE SLIGHT, SCAB RIGHT EAR SLIGHT
7/02/85	7:16:10	0000337	415.0	CORNEAL OPACITY LEFT EYE SLIGHT, SCAB RIGHT EAR SLIGHT
8/01/85	8:39:56	0001576	416.0	CORNEAL OPACITY LEFT EYE SLIGHT
8/29/85	7:32:38	0000337	416.0	CORNEAL OPACITY LEFT EYE SLIGHT
9/26/85	7:45:42	0000337	417.0	CORNEAL OPACITY LEFT EYE SLIGHT
10/24/85	7:47:34	0034567	421.0	CORNEAL OPACITY LEFT EYE SLIGHT, SCAB RIGHT EAR MODERATE
11/21/85	13:47:56	0002920	409.0	CORNEAL OPACITY LEFT EYE SLIGHT, SCAB RIGHT EAR MODERATE
12/04/85	8:11:42	0000337		CORNEAL OPACITY LEFT EYE SLIGHT
12/19/85	8:07:00	0000337	409.0	CORNEAL OPACITY LEFT EYE SLIGHT
1/16/86	9:19:40	0000337	401.0	CORNEAL OPACITY LEFT EYE SLIGHT, SCAB LEFT EAR MODERATE
1/27/86	6:29:32	0000337	377.0	CORNEAL OPACITY LEFT EYE SLIGHT, SCAB LEFT EAR MODERATE, EUTHANIZED



## Appendix F (cont.): INDIVIDUAL ANIMAL HISTORIES

PAGE 22  
DATE: 6/09/87  
TIME: 14:40:13  
EDS017 V4M11

STUDY: 0083009 ISOBUTYL 2-CYANOACRYLATE  
COMPOUND: ISOBUTYL 2-CYANOACRYLATE  
START DATE: 1/28/85

CARCINOGENICITY BIOASSAY OF ISOBUTYL 2-CYANO-  
ACRYLATE (IBC) IN MALE AND FEMALE RATS.

## ANIMAL HISTORY

Animal ID: 84D00058 Species: D Sex: MALE Group: CONTROLS

DATE	TIME	OPERATOR	WEIGHT (GRAMS)	CLINICAL OBSERVATIONS
2/14/85	8:52:50	0000337	410.0	CORNEAL OPACITY LEFT EYE SLIGHT, PROLAPSED LENS RIGHT EYE MARKED, OPAQUE LENS RIGHT EYE MARKED
3/12/85	7:58:16	0000337		CORNEAL OPACITY LEFT SLIGHT, PROLAPSED LENS RIGHT EYE MARKED, OPACITY RIGHT EYE MARKED, STAIN BROWN NOSE SLIGHT
3/14/85	8:25:44	0078478	413.0	CORNEAL OPACITY LEFT EYE SLIGHT, PROLAPSED LENS RIGHT EYE MARKED, OPAQUE LENS RIGHT EYE MARKED
4/11/85	8:25:22	0000337	408.0	CORNEAL OPACITY LEFT EYE SLIGHT, PROLAPSED LENS RIGHT EYE MARKED, OPAQUE LENS RIGHT EYE MARKED
5/09/85	7:46:02	0084799	411.0	PROLAPSED LENS RIGHT EYE MARKED, OPAQUE LENS RIGHT EYE MARKED, HEMORRHAGE ANTERIOR CHAMBER RIGHT EYE MARKED, DILATED PUPIL LEFT EYE MARKED
6/06/85	8:20:18	0010186	415.0	PROLAPSED LENS RIGHT EYE MARKED, OPAQUE LENS RIGHT EYE MARKED, PROLAPSED LENS LEFT EYE MARKED, DILATED PUPIL LEFT EYE MARKED
7/02/85	7:16:54	0000337	405.0	PROLAPSED LENS BOTH EYE MARKED, OPAQUE LENS BOTH EYES MARKED
8/01/85	8:40:18	0001576	403.0	PROLAPSED LENS BOTH EYE MARKED, OPAQUE LENS BOTH EYE MARKED, HYPHEMA ANTERIOR CHAMBER LEFT EYE SLIGHT
8/29/85	7:33:04	0000337	411.0	PROLAPSED LENS BOTH EYES MARKED, OPAQUE LENS BOTH EYES MARKED
9/26/85	7:46:10	0000337	418.0	OPAQUE LENS BOTH EYES MARKED
10/24/85	7:48:34	0034567	425.0	OPAQUE LENS BOTH EYES MARKED
11/21/85	13:53:02	0002920	416.0	OPAQUE LENS BOTH EYES MARKED
12/19/85	8:07:18	0084799	429.0	PROLAPSED LENS BOTH EYES MARKED, OPAQUE LENS BOTH EYES MARKED
1/16/86	9:20:26	0000337	427.0	BILATERAL OPAQUE LENS
1/27/86	8:31:52	0000337	404.0	BILATERAL OPAQUE LENSES, EUTHANIZED

PAGE 23 of  
 DATE: 6/09/87  
 TIME: 14:40:13  
 EDS017 V4M11

**Appendix F (cont.): INDIVIDUAL ANIMAL HISTORIES**

CARCINOGENICITY BIOASSAY OF ISOBUTYL 2-CYANO-  
 ACRYLATE (IBC) IN MALE AND FEMALE RATS.

STUDY: 0083009  
 COMPOUND: ISOBUTYL 2-CYANOACRYLATE  
 START DATE: 1/28/85

ANIMAL HISTORY

Animal ID: 84D00059 Species: D Sex: MALE Group: 10 UL/ANM

DATE	TIME	OPERATOR	WEIGHT (GRAMS)	CLINICAL OBSERVATIONS
2/14/85	8:55:48	0000337	407.0	NORMAL
3/14/85	8:28:52	0078478	424.0	NORMAL
4/11/85	8:27:12	0000337	422.0	NORMAL
5/09/85	7:50:42	0000337	432.0	NORMAL
6/06/85	8:25:02	0010186	439.0	NORMAL
7/02/85	7:18:52	0000337	442.0	NORMAL
8/01/85	8:42:42	0001576	454.0	NORMAL
8/29/85	7:35:06	0000337	446.0	SUBCUTANEOUS MASS LOWER RIGHT FOREARM SIZE SMALL
9/24/85	8:38:58	0000337	459.0	SUBCUTANEOUS MASS RIGHT SIDE HUMERUS SIZE LARGE
9/26/85	7:47:14	0000337	459.0	SUBCUTANEOUS MASS RIGHT SIDE HUMERUS

## Appendix F (cont.): INDIVIDUAL ANIMAL HISTORIES

PAGE 24  
DATE: 6/09/87  
TIME: 14:40:13  
EDS017 V4M11

STUDY: 0083009 ISOBUTYL 2-CYANOACRYLATE CARCINOGENICITY BIOASSAY OF ISOBUTYL 2-CYANO-  
COMPOUND: ISOBUTYL 2-CYANOACRYLATE ACRYLATE (IBC) IN MALE AND FEMALE RATS.  
START DATE: 1/28/85

## ANIMAL HISTORY

Animal ID: 84D00060 Species: D Sex: MALE Group: 10 UL/ANN

DATE	TIME	OPERATOR	WEIGHT (GRAMS)	CLINICAL OBSERVATIONS
2/14/85	8:56:16	0000337	387.0	NORMAL
3/14/85	8:29:40	0078478	396.0	NORMAL
4/11/85	8:28:18	0000337	411.0	NORMAL
5/09/85	7:52:16	0000337	416.0	NORMAL
6/06/85	8:25:44	0010186	424.0	NORMAL
7/02/85	7:19:28	0000337	419.0	INTRABDOMINAL MASS VENTRAL TO LIVER SIZE MEDIUM
8/01/85	8:43:30	0001576	422.0	INTRABDOMINAL MASS VENTRAL TO LIVER SIZE MEDIUM
8/29/85	7:37:54	0000337	408.0	INTRABDOMINAL MASS VENTRAL TO LIVER SIZE MEDIUM
9/26/85	7:49:02	0000337	418.0	INTRABDOMINAL MASS VENTRAL TO LIVER SIZE MEDIUM
10/16/85	7:38:26	0000337	426.0	INTRABDOMINAL MASS VENTRAL TO LIVER SIZE MEDIUM
10/24/85	7:49:18	0034567	418.0	INTRABDOMINAL MASS VENTRAL TO LIVER SIZE MEDIUM
11/21/85	13:54:08	0002920	418.0	INTRABDOMINAL MASS VENTRAL TO LIVER SIZE MEDIUM
12/04/85	8:12:54	0000337	407.0	INTRABDOMINAL MASS VENTRAL TO LIVER SIZE MEDIUM
12/19/85	8:08:50	0000337	407.0	INTRABDOMINAL MASS VENTRAL TO LIVER SIZE MEDIUM
1/06/86	8:29:40	0000337		INTRABDOMINAL MASS SPLENIC SIZE LARGE, EMACIATED MODERATE, STAIN BROWN NOSE SLIGHT
1/09/86	9:58:44	0000337		INTRABDOMINAL MASS SPLENIC SIZE LARGE, EMACIATED MARKED, STAIN YELLOW PERIANAL MARKED

PAGE 25  
 DATE: 6/09/87  
 TIME: 14:40:13  
 EDS017 V4MIJ

**Appendix F (cont.): INDIVIDUAL ANIMAL HISTORIES**

CARCINOGENICITY BIOASSAY OF ISOBUTYL 2-CYANO-  
 ACRYLATE (IBC) IN MALE AND FEMALE RATS.

STUDY: 0083009  
 COMPOUND: ISOBUTYL 2-CYANOACRYLATE  
 START DATE: 1/28/85

ANIMAL HISTORY

Animal ID: 84D00061 Species: D Sex: MALE Group: 100 UL/ANM

DATE	TIME	OPERATOR	WEIGHT (GRAMS)	CLINICAL OBSERVATIONS
2/14/85	8:56:42	0000337	403.0	NORMAL
3/04/85	7:58:06	0000337		STAIN BROWN NOSE SLIGHT
3/12/85	8:01:40	0000337		NORMAL
3/14/85	8:30:10	0078478	412.0	NORMAL
4/11/85	8:29:00	0000337	410.0	NORMAL
5/09/85	7:52:48	0000337	414.0	NORMAL
6/06/85	8:26:18	0010186	412.0	NORMAL
6/19/85	7:29:04	0000337		SCAB RIGHT EAR SLIGHT
7/02/85	7:22:00	0000337	413.0	SCAB RIGHT EAR SLIGHT
8/01/85	8:44:20	0001576	417.0	SCAB RIGHT EAR SLIGHT
8/29/85	7:39:12	0000337	402.0	SCAB RIGHT EAR SLIGHT
9/10/85	9:12:48	0000337		NORMAL
9/26/85	7:50:18	0000337	400.0	NORMAL
10/24/85	7:50:20	0034567	417.0	NORMAL
11/21/85	13:56:12	0002926	407.0	INTRAABDOMINAL MASS VENTRAL TO LIVER SIZE SMALL
12/19/85	8:10:46	0000337	404.0	INTRAABDOMINAL MASS VENTRAL TO LIVER SIZE MEDIUM
1/16/86	9:21:44	0000337	400.0	INTRAABDOMINAL MASS VENTRAL TO LIVER SIZE MEDIUM
1/27/86	8:34:38	0000337	376.0	INTRAABDOMINAL MASS VENTRAL TO LIVER SIZE MEDIUM, EUTHANIZED

## Appendix F (cont.): INDIVIDUAL ANIMAL HISTORIES

PAGE 26  
DATE: 6/09/87  
TIME: 14:40:13  
EDS017 V4M11

STUDY: 0083009  
COMPOUND: ISOBUTYL 2-CYANOACRYLATE  
START DATE: 1/28/85

CARCINOGENICITY BIOASSAY OF ISOBUTYL 2-CYANO-  
ACRYLATE (IBC) IN MALE AND FEMALE RATS.

## ANIMAL HISTORY

Animal ID: 84D00062 Species: D Sex: MALE Group: 100 UL/ANM

DATE	TIME	OPERATOR	WEIGHT (GRAMS)	CLINICAL OBSERVATIONS
2/14/85	8:57:04	0000337	376.0	NORMAL
3/12/85	8:02:42	0000337		SCAB RIGHT EAR SLIGHT
3/14/85	8:30:34	0078478	386.0	SCAB RIGHT EAR SLIGHT
4/11/85	8:30:00	0000337	397.0	NORMAL
5/09/85	7:53:12	0000337	402.0	INTRAABDOMINAL MASS VENTRAL TO LIVER SIZE MEDIUM
6/06/85	8:26:58	0010186	405.0	INTRAABDOMINAL MASS VENTRAL TO LIVER SIZE MEDIUM
7/02/85	7:22:58	0000337	408.0	INTRAABDOMINAL MASS VENTRAL TO LIVER SIZE MEDIUM
8/01/85	8:44:38	0001576	410.0	INTRAABDOMINAL MASS VENTRAL TO LIVER SIZE MEDIUM
8/29/85	7:40:12	0000337	406.0	INTRAABDOMINAL MASS VENTRAL TO LIVER SIZE MEDIUM
9/26/85	7:50:44	0000337	407.0	INTRAABDOMINAL MASS VENTRAL TO LIVER SIZE MEDIUM
10/24/85	7:50:56	0034567	412.0	SCAB RIGHT EAR SLIGHT, INTRAABDOMINAL MASS VENTRAL TO LIVER SIZE MEDIUM
11/06/85	8:09:06	0000337		SCAB RIGHT EAR MODERATE, INTRAABDOMINAL MASS VENTRAL TO LIVER SIZE MEDIUM
11/21/85	13:57:58	0002920	408.0	SCAB RIGHT EAR MODERATE, INTRAABDOMINAL MASS VENTRAL TO LIVER SIZE LARGE
12/04/85	8:16:40	0000337		INTRAABDOMINAL MASS VENTRAL TO LIVER SIZE LARGE
12/11/85	10:37:08	0000337		INTRAABDOMINAL MASS VENTRAL TO LIVER SIZE LARGE, EMACIATED MODERATE, PALLOR MODERATE

PAGE 27 0  
 DATE: 6/09/87  
 TIME: 14:40:13  
 EDS017 VAM11

**Appendix F (cont.): INDIVIDUAL ANIMAL HISTORIES**

STUDY: 0083009  
 COMPOUND: ISOBUTYL 2-CYANOACRYLATE  
 START DATE: 1/28/85

CARCINOGENICITY BIOASSAY OF ISOBUTYL 2-CYANO-  
 ACRYLATE (IBC) IN MALE AND FEMALE RATS.

ANIMAL HISTORY

Animal ID: 84D00063 Species: D Sex: MALE Group: 10 UL/ANM

DATE	TIME	OPERATOR	WEIGHT (GRAMS)	CLINICAL OBSERVATIONS
2/14/85	8:57:28	0000337	432.0	NORMAL
3/14/85	8:35:38	0078478	435.0	NORMAL
4/11/85	8:30:38	0000337	443.0	NORMAL
5/09/85	7:55:34	0000337	444.0	NORMAL
5/22/85	7:39:54	0000337		INTRAABDOMINAL MASS VENTRAL TO LIVER SIZE MEDIUM
6/06/85	8:28:04	0010186	448.0	INTRAABDOMINAL MASS VENTRAL TO LIVER SIZE MEDIUM
7/02/85	7:24:02	0000337	447.0	INTRAABDOMINAL MASS VENTRAL TO LIVER SIZE MEDIUM
8/01/85	8:45:22	0001576	443.0	INTRAABDOMINAL MASS VENTRAL TO LIVER SIZE MEDIUM
8/29/85	7:41:12	0000337	441.0	INTRAABDOMINAL MASS VENTRAL TO LIVER SIZE MEDIUM
9/26/85	7:51:34	0000337	448.0	INTRAABDOMINAL MASS VENTRAL TO LIVER SIZE MEDIUM
10/16/85	7:45:28	0000337		INTRAABDOMINAL MASS VENTRAL TO LIVER SIZE LARGE
10/24/85	7:52:08	0034567	456.0	INTRAABDOMINAL MASS VENTRAL TO LIVER SIZE LARGE
11/21/85	14:00:34	0002920	452.0	INTRAABDOMINAL MASS VENTRAL TO LIVER SIZE LARGE
12/04/85	8:19:54	0000337		INTRAABDOMINAL MASS VENTRAL TO LIVER SIZE LARGE, STAIN BROWN NOSE SLIGHT
12/19/85	8:11:38	0000337	447.0	INTRAABDOMINAL MASS VENTRAL TO LIVER SIZE LARGE
1/16/86	9:22:40	0000337	453.0	INTRAABDOMINAL MASS VENTRAL TO LIVER SIZE MEDIUM
1/27/86	8:37:18	0000337	428.0	INTRAABDOMINAL MASS VENTRAL TO LIVER SIZE MEDIUM, EUTHANIZED

PAGE 28  
 DATE: 6/09/87  
 TIME: 14:40:13  
 EDS017 V4M11

**Appendix F (cont.): INDIVIDUAL ANIMAL HISTORIES**

STUDY: 0083009  
 COMPOUND: ISOBUTYL 2-CYANOACRYLATE  
 START DATE: 1/28/85  
 CARCINOGENICITY BIOASSAY OF ISOBUTYL 2-CYANO-  
 ACRYLATE (IBC) IN MALE AND FEMALE RATS.

ANIMAL HISTORY

Animal ID: 84D00064 Species: D Sex: MALE Group: CONTROLS

DATE	TIME	OPERATOR	WEIGHT (GRAMS)	CLINICAL OBSERVATIONS
2/14/85	8:57:46	0000337	392.0	NORMAL
3/14/85	8:36:08	0078478	392.0	NORMAL
4/11/85	8:31:34	0000337	397.0	NORMAL
5/09/85	7:56:16	0000337	396.0	CORNEAL OPACITY LEFT EYE SLIGHT
6/06/85	8:29:42	0010186	401.0	CORNEAL OPACITY LEFT EYE SLIGHT
7/02/85	7:25:54	0000337	395.0	CORNEAL OPACITY LEFT EYE SLIGHT
8/01/85	8:46:02	0001576	397.0	CORNEAL OPACITY LEFT EYE SLIGHT
8/29/85	7:42:06	0000337	387.0	CORNEAL OPACITY LEFT EYE SLIGHT
9/26/85	7:52:26	0000337	399.0	CORNEAL OPACITY LEFT EYE SLIGHT
10/24/85	7:53:38	0034567	407.0	CORNEAL OPACITY LEFT EYE SLIGHT
11/21/85	14:01:36	0002920	403.0	CORNEAL OPACITY LEFT EYE SLIGHT
12/04/85	8:21:52	0000337	401.0	CORNEAL OPACITY LEFT EYE SLIGHT, SCAB RIGHT EAR SLIGHT
12/19/85	8:12:24	0000337	401.0	CORNEAL OPACITY LEFT EYE SLIGHT, SCAB RIGHT EAR SLIGHT
1/16/86	9:23:46	0000337	394.0	CORNEAL OPACITY LEFT EYE SLIGHT
1/27/86	8:39:46	0000337	366.0	CORNEAL OPACITY LEFT EYE SLIGHT, EUTHANIZED

PAGE 290  
 DATE: 6/09/87  
 TIME: 14:40:13  
 EDS017 V4M11

**Appendix F (cont.): INDIVIDUAL ANIMAL HISTORIES**

CARCINOGENICITY BIOASSAY OF ISOBUTYL 2-CYANO-  
 ACRYLATE (IBC) IN MALE AND FEMALE RATS.

STUDY: 0083009  
 COMPOUND: ISOBUTYL 2-CYANOACRYLATE  
 START DATE: 1/28/85

ANIMAL HISTORY

Animal ID: 84D00066 Species: D Sex: MALE Group: CONTROLS

DATE	TIME	OPERATOR	WEIGHT (GRAMS)	CLINICAL OBSERVATIONS
2/14/85	8:58:10	0000337	418.0	NORMAL
3/04/85	8:00:14	0000337		STAIN BROWN NOSE SLIGHT
3/12/85	8:04:26	0000337		NORMAL
3/14/85	8:36:40	0078478	428.0	NORMAL
4/11/85	8:32:14	0000337	434.0	NORMAL
5/09/85	7:56:56	0000337	437.0	NORMAL
6/06/85	8:30:14	0010186	435.0	NORMAL
7/02/85	7:26:26	0000337	425.0	NORMAL
8/01/85	8:46:22	0001576	430.0	NORMAL
8/29/85	7:42:38	0000337	429.0	NORMAL
9/26/85	7:52:50	0000337	431.0	NORMAL
10/24/85	7:54:04	0034567	434.0	NORMAL
11/21/85	14:02:40	0002920	421.0	NORMAL
12/19/85	8:12:58	0000337	424.0	OPAQUE LENS LEFT EYE SLIGHT
1/16/86	9:24:10	0000337	419.0	OPAQUE LENS LEFT EYE SLIGHT
1/27/86	8:41:06	0000337	395.0	OPAQUE LENS LEFT EYE SLIGHT, EUTHANIZED



PAGE 30  
 DATE: 6/09/87  
 TIME: 14:40:13  
 EDS017 V4M11

**Appendix F (cont.): INDIVIDUAL ANIMAL HISTORIES**

STUDY: 0083009 CARCINOGENICITY BIOASSAY OF ISOBUTYL 2-CYANO-  
 COMPOUND: ISOBUTYL 2-CYANOACRYLATE ACRYLATE (IBC) IN MALE AND FEMALE RATS.  
 START DATE: 1/28/85

ANIMAL HISTORY

Animal ID: 84D00067 Species: D Sex: MAL3 Group: 100 UL/ANM

DATE	TIME	OPERATOR	WEIGHT (GRAMS)	CLINICAL OBSERVATIONS
2/05/85	8:49:28	0000337		CONJUNCTIVITIS LEFT EYE MODERATE
2/13/85	9:46:22	0000337		CONJUNCTIVITIS LEFT EYE MODERATE, SCAB RIGHT EAR SLIGHT
2/14/85	8:58:32	0000337	420.0	CONJUNCTIVITIS LEFT EYE MODERATE, SCAB RIGHT EAR SLIGHT
3/14/85	8:37:06	0078478	419.0	SCAB RIGHT EAR SLIGHT
4/11/85	8:33:04	0000337	422.0	SCAB RIGHT EAR MODERATE, CORNEAL OPACITY RIGHT EYE SLIGHT
4/24/85	8:14:46	0000337		SCAB RIGHT EAR MODERATE, CORNEAL OPACITY RIGHT EYE SLIGHT, CONJUNCTIVITIS LEFT EYE MODERATE
5/02/85	6:47:12	0000337		SCAB RIGHT EAR MODERATE, CORNEAL OPACITY RIGHT EYE SLIGHT, CONJUNCTIVITIS LEFT EYE MARKED
5/07/85	7:24:28	0000337		SCAB RIGHT EAR MODERATE, CORNEAL OPACITY RIGHT EYE SLIGHT, CONJUNCTIVITIS LEFT EYE MODERATE
5/09/85	7:57:22	0000337	423.0	SCAB RIGHT EAR SLIGHT, CORNEAL OPACITY RIGHT EYE SLIGHT, CONJUNCTIVITIS LEFT EYE MARKED
5/14/85	7:49:20	0000337		SCAB RIGHT EAR SLIGHT, CORNEAL OPACITY RIGHT EYE SLIGHT, CONJUNCTIVITIS LEFT EYE MODERATE
6/04/85	7:33:34	0000337		CORNEAL OPACITY RIGHT EYE SLIGHT, CONJUNCTIVITIS LEFT EYE MODERATE
6/06/85	8:30:44	0010186	429.0	CORNEAL OPACITY RIGHT EYE SLIGHT, CORNEAL OPACITY LEFT EYE SLIGHT, CONJUNCTIVITIS LEFT EYE MODERATE
6/19/85	7:34:08	0000337		CORNEAL OPACITY RIGHT EYE SLIGHT, CORNEAL OPACITY LEFT EYE SLIGHT, CONJUNCTIVITIS LEFT EYE MARKED,
7/02/85	7:26:58	0000337	427.0	INTRABDOMINAL MASS VENTRAL TO LIVER SIZE MEDIUM CORNEAL OPACITY LEFT EYE SLIGHT, CONJUNCTIVITIS LEFT EYE SLIGHT,
8/01/85	8:46:38	0001576	430.0	INTRABDOMINAL MASS VENTRAL TO LIVER SIZE MEDIUM CORNEAL OPACITY RIGHT EYE SLIGHT, CORNEAL OPACITY LEFT EYE SLIGHT,
8/29/85	7:43:04	0000337	427.0	INTRABDOMINAL MASS VENTRAL TO LIVER SIZE MEDIUM CORNEAL OPACITY BOTH EYE SLIGHT,
9/26/85	7:53:16	0000337	427.0	INTRABDOMINAL MASS VENTRAL TO LIVER SIZE MEDIUM CORNEAL OPACITY BOTH EYE SLIGHT,
10/16/85	7:49:52	0000337		INTRABDOMINAL MASS VENTRAL TO LIVER SIZE MEDIUM CORNEAL OPACITY BOTH EYE SLIGHT, CONJUNCTIVITIS LEFT EYE MARKED,
10/24/85	7:54:26	0034567	414.0	INTRABDOMINAL MASS VENTRAL TO LIVER SIZE MEDIUM CORNEAL OPACITY BOTH EYE SLIGHT, CONJUNCTIVITIS LEFT EYE MARKED,
11/21/85	14:03:04	0002920	404.0	INTRABDOMINAL MASS VENTRAL TO LIVER SIZE LARGE CORNEAL OPACITY BOTH EYE SLIGHT,
12/19/85	8:14:00	0000337	401.0	INTRABDOMINAL MASS VENTRAL TO LIVER SIZE SLIGHT,
1/16/86	9:24:46	0084799	391.0	INTRABDOMINAL MASS VENTRAL TO LIVER SIZE SLIGHT,
1/27/86	8:42:52	0084799	369.0	INTRABDOMINAL MASS VENTRAL TO LIVER SIZE SLIGHT, EUTHANIZED

PAGE 31  
 DATE: 6/09/87  
 TIME: 14:40:13  
 EDS017 V4M11

### Appendix F (cont.): INDIVIDUAL ANIMAL HISTORIES

STUDY: 0083009  
 COMPOUND: ISOBUTYL 2-CYANOACRYLATE  
 START DATE: 1/28/85  
 CARCINOGENICITY BIOASSAY OF ISOBUTYL 2-CYANO-  
 ACRYLATE (IBC) IN MALE AND FEMALE RATS.

#### ANIMAL HISTORY

Animal ID: 84D00068 Species: D Sex: MALE Group: 100 UL/ANN

DATE	TIME	OPERATOR	WEIGHT (GRAMS)	CLINICAL OBSERVATIONS
2/14/85	8:59:30	0000337	432.0	CORNEAL OPACITY RIGHT EYE SLIGHT
3/14/85	8:40:00	0078478	434.0	CORNEAL OPACITY RIGHT EYE SLIGHT
4/11/85	8:36:10	0000337	430.0	CORNEAL OPACITY RIGHT EYE SLIGHT
5/09/85	7:59:18	0000337	439.0	CORNEAL OPACITY RIGHT EYE SLIGHT
6/06/85	8:33:08	0010186	448.0	CORNEAL OPACITY RIGHT EYE SLIGHT
7/02/85	7:29:06	0000337	447.0	CORNEAL OPACITY RIGHT EYE SLIGHT
8/01/85	8:47:54	0001576	449.0	CORNEAL OPACITY RIGHT EYE SLIGHT
8/29/85	7:45:44	0000337	420.0	CORNEAL OPACITY RIGHT EYE SLIGHT
9/26/85	7:54:28	0000337	432.0	CORNEAL OPACITY RIGHT EYE SLIGHT, INTRAABDOMINAL MASS DORSAL TO LIVER SIZE SMALL
10/16/85	7:52:26	0084799		CORNEAL OPACITY RIGHT EYE SLIGHT, INTRAABDOMINAL MASS VENTRAL TO LIVER SIZE MEDIUM
10/16/85	7:56:44	0000337		CORNEAL OPACITY RIGHT SLIGHT, INTRAABDOMINAL MASS VENTRAL TO LIVER SIZE LARGE
10/24/85	7:55:54	0034567	427.0	CORNEAL OPACITY RIGHT SLIGHT, INTRAABDOMINAL MASS VENTRAL TO LIVER SIZE LARGE
11/21/85	14:05:12	0002920	423.0	INTRAABDOMINAL MASS VENTRAL TO LIVER SIZE LARGE, CORNEAL OPACITY RIGHT EYE SLIGHT, MULTIPLE SKIN LESIONS (PUSTULES) TAIL SLIGHT
12/19/85	8:14:58	0000337	417.0	CORNEAL OPACITY RIGHT EYE SLIGHT, INTRAABDOMINAL MASS VENTRAL TO LIVER SIZE LARGE, MULTIPLE SKIN LESIONS (PUSTULES) TAIL MARKED
1/16/86	9:26:20	0000337	407.0	CORNEAL OPACITY RIGHT EYE SLIGHT, INTRAABDOMINAL MASS VENTRAL TO LIVER SIZE LARGE, MULTIPLE LESIONS (PUSTULES) TAIL
1/27/86	8:45:50	0084799	377.0	CORNEAL OPACITY RIGHT EYE SLIGHT, INTRAABDOMINAL MASS VENTRAL TO LIVER SIZE LARGE, MULTIPLE LESIONS ON TAIL, EUTHANIZED

**Appendix F (cont.): INDIVIDUAL ANIMAL HISTORIES**

STUDY: 0083009  
 COMPOUND: ISOBUTYL 2-CYANOACRYLATE  
 START DATE: 1/28/85

CARCINOGENICITY BIOASSAY OF ISOBUTYL 2-CYANO-  
 ACRYLATE (IBC) IN MALE AND FEMALE RATS.

PAGE 32  
 DATE: 5/09/87  
 TIME: 11:40:13  
 EDS017 VIM11

ANIMAL HISTORY

Animal ID: 84D00069 Species: D Sex: MALE Group: 100 UL/ANM

DATE	TIME	WEIGHT OPERATOR (GRAMS)	CLINICAL OBSERVATIONS
2/14/85	8:59:58	0000337 456.0	CORNEAL OPACITY BOTH EYE SLIGHT
2/16/85	8:06:56	0078478 452.0	CORNEAL OPACITY BOTH EYE SLIGHT
3/12/85	8:06:46	0000337	CORNEAL OPACITY BOTH EYE SLIGHT, SCAB RIGHT EAR MODERATE
3/14/85	8:40:30	0078478 452.0	CORNEAL OPACITY BOTH EYE SLIGHT, SCAB RIGHT EAR MODERATE
4/02/85	8:17:32	0000337	CORNEAL OPACITY BOTH EYE SLIGHT
4/11/85	8:37:02	0000337 454.0	CORNEAL OPACITY BOTH EYE SLIGHT
5/09/85	7:59:44	0000337 497.0	CORNEAL OPACITY BOTH EYE SLIGHT
6/06/85	8:33:44	0010186 463.0	CORNEAL OPACITY BOTH EYE SLIGHT, INTRAABDOMINAL MASS VENTRAL TO LIVER SIZE MEDIUM
7/02/85	7:29:54	0000337 466.0	CORNEAL OPACITY BOTH EYE SLIGHT, INTRAABDOMINAL MASS VENTRAL TO LIVER SIZE MEDIUM
8/01/85	8:48:22	0001576 481.0	INTRAABDOMINAL MASS VENTRAL TO LIVER SIZE MEDIUM, CORNEAL OPACITY BOTH EYE SLIGHT
8/29/85	7:46:18	0000337 470.0	CORNEAL OPACITY BOTH EYE SLIGHT, INTRAABDOMINAL MASS VENTRAL TO LIVER SIZE LARGE
9/26/85	7:56:20	0000337 442.0	CORNEAL OPACITY BOTH EYE SLIGHT, INTRAABDOMINAL MASS VENTRAL TO LIVER SIZE LARGE
10/03/85	8:12:28	0002920 410.0	EUTHANIZED

PAGE 33  
 DATE: 6/09/87  
 TIME: 14:40:13  
 EDS017 V4M11

**Appendix F (cont.): INDIVIDUAL ANIMAL HISTORIES**

STUDY: 0083009  
 COMPOUND: ISOBUTYL 2-CYANOACRYLATE  
 START DATE: 1/28/85  
 CARCINOGENICITY BIOASSAY OF ISOBUTYL 2-CYANO-  
 ACRYLATE (IBC) IN MALE AND FEMALE RATS.

ANIMAL HISTORY

Animal ID: 84D00070 Species: D Sex: MALE Group: 10 UL/ANM

DATE	TIME	OPERATOR	WEIGHT (GRAMS)	CLINICAL OBSERVATIONS
2/14/85	9:00:20	0000337	387.0	NORMAL
3/14/85	8:42:52	0078478	385.0	NORMAL
4/11/85	8:38:02	0000337	386.0	NORMAL
5/09/85	8:00:34	0000337	390.0	NORMAL
6/06/85	8:37:52	0010186	394.0	PROLAPSED LENS RIGHT EYE MODERATE
7/02/85	7:31:38	0000337	401.0	PROLAPSED LENS RIGHT EYE MODERATE, OPAQUE LENS RIGHT EYE MODERATE
8/01/85	8:49:12	0001576	411.0	PROLAPSED LENS RIGHT EYE MARKED, OPAQUE LENS RIGHT EYE MARKED
8/29/85	7:47:24	0000337	397.0	PROLAPSED LENS RIGHT EYE MARKED, OPAQUE LENS RIGHT EYE MARKED
9/26/85	7:57:32	0000337	409.0	OPAQUE LENS RIGHT EYE MARKED, PROLAPSED LENS RIGHT EYE MARKED, INTRAABDOMINAL MASS VENTRAL TO LIVER SIZE SMALL
10/24/85	7:57:04	0034567	416.0	OPAQUE LENS RIGHT MARKED, PROLAPSED LENS RIGHT MARKED, INTRAABDOMINAL MASS VENTRAL TO LIVER SIZE SMALL
11/06/85	8:15:56	0084799		OPAQUE LENS RIGHT EYE MARKED, PROLAPSED LENS RIGHT EYE MARKED, INTRAABDOMINAL MASS VENTRAL TO LIVER SIZE MEDIUM
11/21/85	14:11:00	0002920	374.0	PALLOR MARKED, INTRAABDOMINAL MASS VENTRAL TO LIVER SIZE MEDIUM, PROLAPSED LENS RIGHT EYE MARKED, OPAQUE LENS RIGHT EYE MARKED
12/19/85	8:18:56	0000337	362.0	PALLOR MARKED, INTRAABDOMINAL MASS SPLENIC SIZE LARGE, PROLAPSED LENS RIGHT EYE MARKED, OPAQUE LENS RIGHT EYE MARKED
12/23/85	10:42:24	0084799		PALLOR MARKED, INTRAABDOMINAL MASS SPLENIC SIZE LARGE, PROLAPSED LENS RIGHT EYE MARKED, OPAQUE LENS RIGHT EYE MARKED, BLOODY DISCHARGE EYES NOSE MOUTH

## Appendix F (cont.): INDIVIDUAL ANIMAL HISTORIES

PAGE 34  
DATE: 6/09/87  
TIME: 14:40:13  
EDS017 V4M11

STUDY: 0083009 CARCINOGENICITY BIOASSAY OF ISOBUTYL 2-CYANO-  
COMPOUND: ISOBUTYL 2-CYANOACRYLATE ACRYLATE (IBC) IN MALE AND FEMALE RATS.  
START DATE: 1/28/85

## ANIMAL HISTORY

Animal ID: 84D00071 Species: D Sex: MALE Group: 10 UL/ANM

DATE	TIME	OPERATOR	WEIGHT (GRAMS)	CLINICAL OBSERVATIONS
2/14/85	9:00:36	0000337	425.0	PROLAPSED LENS RIGHT EYE SLIGHT, OPAQUE LENS RIGHT EYE MARKED
3/14/85	8:43:28	0084799	422.0	PROLAPSED LENS RIGHT EYE MODERATE, OPAQUE LENS RIGHT EYE MARKED
4/11/85	8:38:38	0000337	425.0	PROLAPSED LENS RIGHT EYE, OPAQUE LENS RIGHT EYE MARKED
4/24/85	8:18:32	0000337		PROLAPSED LENS RIGHT EYE MARKED, OPAQUE LENS RIGHT EYE MARKED, STAIN BROWN NOSE SLIGHT
5/02/85	6:48:24	0000337		PROLAPSED LENS RIGHT EYE MARKED, OPAQUE LENS RIGHT EYE MARKED
5/09/85	8:00:46	0000337	437.0	PROLAPSED LENS RIGHT EYE MARKED, OPAQUE LENS RIGHT EYE MARKED
6/06/85	8:39:44	0010186	444.0	PROLAPSED LENS RIGHT EYE MARKED, OPAQUE LENS RIGHT EYE MARKED
7/02/85	7:33:18	0000337	446.0	OPAQUE LENS RIGHT EYE MARKED, PROLAPSED LENS RIGHT EYE MARKED
8/01/85	8:49:56	0001576	460.0	OPAQUE LENS RIGHT EYE MARKED, PROLAPSED LENS RIGHT EYE MARKED
8/29/85	7:48:30	0000337	450.0	PROLAPSED LENS RIGHT EYE MARKED, OPAQUE LENS RIGHT EYE MARKED, MICROOPHTHALMIA RIGHT EYE, INTRAABDOMINAL MASS VENTRAL TO LIVER SIZE MEDIUM
9/26/85	7:59:42	0000337	453.0	OPAQUE LENS RIGHT EYE MARKED, PROLAPSED LENS RIGHT EYE MARKED, INTRAABDOMINAL MASS VENTRAL TO LIVER SIZE MEDIUM
10/24/85	8:03:10	0034567	454.0	OPAQUE LENS RIGHT EYE MARKED, PROLAPSED LENS RIGHT EYE MARKED, INTRAABDOMINAL MASS VENTRAL TO LIVER SIZE MEDIUM
11/21/85	14:14:46	0002920	453.0	OPAQUE LENS RIGHT EYE MARKED, PROLAPSED LENS RIGHT EYE MARKED, INTRAABDOMINAL MASS VENTRAL TO LIVER SIZE MEDIUM
12/19/85	8:21:44	0000337	454.0	INTRAABDOMINAL MASS VENTRAL TO LIVER SIZE MEDIUM, OPAQUE LENS RIGHT EYE MARKED
1/16/86	9:28:44	0000337	434.0	INTRAABDOMINAL MASS VENTRAL TO LIVER SIZE MEDIUM, SMALL LENS RIGHT EYE WITH OPACITY
1/29/86	7:42:10	0034567	409.0	INTRAABDOMINAL MASS VENTRAL TO LIVER SIZE MEDIUM, SMALL LENS RIGHT EYE WITH OPACITY, EUTHANIZED

**Appendix F (cont.): INDIVIDUAL ANIMAL HISTORIES**

STUDY: 0083009 CARCINOGENICITY BIOASSAY OF ISOBUTYL 2-CYANO-  
 COMPOUND: ISOBUTYL 2-CYANOACRYLATE ACRYLATE (IBC) IN MALE AND FEMALE RATS.  
 START DATE: 1/28/85

ANIMAL HISTORY

Animal ID: 84D00072 Species: D Sex: MALE Group: 10 UL/ANM

DATE	TIME	OPERATOR	WEIGHT (GRAMS)	CLINICAL OBSERVATIONS
2/14/85	9:03:54	0000337	438.0	NORMAL
3/14/85	8:46:08	0078478	441.0	NORMAL
4/11/85	8:39:56	0000337	434.0	NORMAL
5/09/85	8:01:58	0000337	448.0	INTRAABDOMINAL MASS VENTRAL TO LIVER MEDIUM
6/06/85	8:40:44	0010186	418.0	INTRAABDOMINAL MASS VENTRAL TO LIVER SIZE MEDIUM
7/02/85	7:34:06	0000337	418.0	INTRAABDOMINAL MASS VENTRAL TO LIVER SIZE MEDIUM
8/01/85	8:50:44	0001576	459.0	INTRAABDOMINAL MASS VENTRAL TO LIVER SIZE MEDIUM
8/29/85	7:51:30	0000337	446.0	INTRAABDOMINAL MASS VENTRAL TO LIVER SIZE MEDIUM
9/26/85	8:27:04	0000337	460.0	STAIN BROWN NOSE SLIGHT, INTRAABDOMINAL MASS VENTRAL TO LIVER SOFT SIZE SMALL
10/02/85	8:43:08	0000337		INTRAABDOMINAL MASS VENTRAL TO LIVER SIZE SMALL
10/16/85	8:00:56	0000337		INTRAABDOMINAL MASS VENTRAL TO LIVER SIZE MEDIUM
10/24/85	8:30:12	0034567	461.0	INTRAABDOMINAL MASS VENTRAL TO LIVER SIZE MEDIUM
11/06/85	8:20:34	0000337		INTRAABDOMINAL MASS VENTRAL TO LIVER SIZE MEDIUM
11/21/85	14:17:30	0002920	458.0	INTRAABDOMINAL MASS VENTRAL TO LIVER SIZE LARGE
12/19/85	8:23:56	0000337	464.0	INTRAABDOMINAL MASS VENTRAL TO LIVER SIZE LARGE
1/16/86	9:30:36	0000337	431.0	INTRAABDOMINAL MASS VENTRAL TO LIVER SIZE MEDIUM
1/29/86	7:44:52	0034567	404.0	INTRAABDOMINAL MASS SIZE MEDIUM, EUTHANIZED

## Appendix F (cont.): INDIVIDUAL ANIMAL HISTORIES

PAGE 36  
 DATE: 6/09/87  
 TIME: 14:40:13  
 EDS017 V4M11

STUDY: 0083009  
 COMPOUND: ISOBUTYL 2-CYANOACRYLATE  
 START DATE: 1/28/85

CARCINOGENICITY BIOASSAY OF ISOBUTYL 2-CYANO-  
 ACRYLATE (IBC) IN MALE AND FEMALE RATS.

## ANIMAL HISTORY

Animal ID: 84D00073 Species: D Sex: MALE Group: CONTROLS

DATE	TIME	OPERATOR	WEIGHT (GRAMS)	CLINICAL OBSERVATIONS
2/14/85	9:04:20	0000337	336.0	NORMAL
3/04/85	8:03:40	0000337		STAIN BROWN NOSE SLIGHT
3/12/85	8:08:46	0000337		NORMAL
3/14/85	8:46:34	0078478	338.0	NORMAL
4/11/85	8:41:14	0000337	342.0	NORMAL
5/09/85	8:04:12	0000337	344.0	NORMAL
6/06/85	8:43:02	0010186	356.0	NORMAL
7/02/85	7:35:00	0000337	352.0	NORMAL
8/01/85	8:53:00	0001576	362.0	NORMAL
8/29/85	7:52:24	0000337	353.0	NORMAL
9/26/85	8:28:54	0000337	363.0	NORMAL
10/24/85	8:31:26	0034567	362.0	NORMAL
11/06/85	8:22:28	0000337		CONJUNCTIVITIS LEFT EYE SLIGHT
11/21/85	14:18:24	0002920	354.0	NORMAL
12/19/85	8:24:48	0000337	355.0	NORMAL
1/16/86	9:31:38	0000337	343.0	NORMAL
1/29/86	7:47:14	0034567	321.0	NORMAL / EUTHANIZED

PAGE 37  
DATE: 6/09/87  
TIME: 14:40:13  
EDS017 V4M11

**Appendix F (cont.): INDIVIDUAL ANIMAL HISTORIES**

STUDY: 0083009  
COMPOUND: ISOBUTYL 2-CYANOACRYLATE  
START DATE: 1/28/85

CARCINOGENICITY BIOASSAY OF ISOBUTYL 2-CYANO-  
ACRYLATE (IBC) IN MALE AND FEMALE RATS.

ANIMAL HISTORY

Animal ID: 84D00074 Species: D Sex: MALE Group: 100 UL/ANM

DATE	TIME	OPERATOR	WEIGHT (GRAMS)	CLINICAL OBSERVATIONS
2/14/85	9:04:46	0000337	415.0	NORMAL
3/14/85	8:47:30	0078478	416.0	NORMAL
4/11/85	8:42:00	0000337	423.0	NORMAL
5/09/85	8:04:38	0000337	428.0	INTRABDOMINAL MASS VENTRAL TO LIVER SIZE LARGE
6/06/85	8:43:40	0010186	436.0	INTRABDOMINAL MASS VENTRAL TO LIVER SIZE LARGE
7/02/85	7:36:00	0000337	440.0	INTRABDOMINAL MASS VENTRAL TO LIVER SIZE LARGE
8/01/85	8:54:12	0001576	440.0	INTRABDOMINAL MASS VENTRAL TO LIVER SIZE LARGE
8/29/85	7:52:58	0000337	354.0	INTRABDOMINAL MASS VENTRAL TO LIVER SIZE LARGE
8/30/85	11:23:06	0000337		INTRABDOMINAL MASS VENTRAL TO LIVER SIZE LARGE



PAGE 38  
 DATE: 6/09/87  
 TIME: 14:40:13  
 EDS017 VAM11

**Appendix F (cont.): INDIVIDUAL ANIMAL HISTORIES**

STUDY: 0083009 ISOBUTYL 2-CYANOACRYLATE  
 COMPOUND: ISOBUTYL 2-CYANOACRYLATE  
 START DATE: 1/28/85

CARCINOGENICITY BIOASSAY OF ISOBUTYL 2-CYANO-  
 ACRYLATE (IBC) IN MALE AND FEMALE RATS.

ANIMAL HISTORY

Animal ID: 84D00075 Species: D Sex: MALE Group: CONTROLS

DATE	TIME	OPERATOR	WEIGHT (GRAMS)	CLINICAL OBSERVATIONS
2/14/85	9:05:14	0000337	376.0	NORMAL
3/14/85	8:47:54	0078478	376.0	NORMAL
4/11/85	8:42:46	0000337	377.0	NORMAL
5/09/85	8:06:18	0000337	379.0	NORMAL
6/06/85	8:44:30	0010186	383.0	NORMAL
7/02/85	7:36:44	0000337	383.0	NORMAL
8/01/85	8:54:46	0001576	386.0	NORMAL
8/29/85	7:54:50	0000337	380.0	NORMAL
9/26/85	8:29:12	0000337	385.0	NORMAL
10/24/85	8:31:48	0034567	383.0	NORMAL
11/21/85	14:19:38	0002920	372.0	NORMAL
12/19/85	8:25:08	0000337	372.0	NORMAL
1/16/86	9:32:02	0000337	362.0	NORMAL
1/29/86	7:49:02	0034567	336.0	NORMAL / EUTHANIZED

PAGE 39 @  
 DATE: 6/09/87  
 TIME: 14:40:13  
 EDS017 V4M11

**Appendix F (cont.): INDIVIDUAL ANIMAL HISTORIES**

CARCINOGENICITY BIOASSAY OF ISOBUTYL 2-CYANO-  
 ACRYLATE (IBC) IN MALE AND FEMALE RATS.

STUDY: 0083009  
 COMPOUND: ISOBUTYL 2-CYANOACRYLATE  
 START DATE: 1/28/85

ANIMAL HISTORY

Animal ID: 84D00076 Species: D Sex: MALE Group: 100 UL/ANM

DATE	TIME	OPERATOR	WEIGHT (GRAMS)	CLINICAL OBSERVATIONS
2/14/85	9:05:32	0000337	385.0	NORMAL
3/14/85	8:48:16	0078478	397.0	NORMAL
4/11/85	8:43:26	0000337	400.0	NORMAL
5/09/85	8:06:38	0000337	404.0	NORMAL
5/22/85	8:08:26	0000337		INTRABDOMINAL MASS VENTRAL TO LIVER SIZE SMALL
6/04/85	7:42:24	0000337		INTRABDOMINAL MASS VENTRAL TO LIVER SIZE LARGE
6/06/85	8:45:06	0010186	399.0	INTRABDOMINAL MASS VENTRAL TO LIVER SIZE MEDIUM
7/02/85	7:37:16	0000337	400.0	INTRABDOMINAL MASS VENTRAL TO LIVER SIZE MEDIUM
8/01/85	8:54:58	0001576	400.0	INTRABDOMINAL MASS VENTRAL TO LIVER SIZE MEDIUM
8/29/85	7:55:20	0000337	390.0	INTRABDOMINAL MASS VENTRAL TO LIVER SIZE MEDIUM
9/26/85	8:29:40	0000337	391.0	INTRABDOMINAL MASS VENTRAL TO LIVER SIZE MEDIUM
10/16/85	8:04:40	0000337		INTRABDOMINAL MASS VENTRAL TO LIVER SIZE LARGE
10/24/85	8:32:10	0034567	387.0	INTRABDOMINAL MASS VENTRAL TO LIVER SIZE LARGE
11/21/85	14:20:12	0002920	375.0	INTRABDOMINAL MASS VENTRAL TO LIVER SIZE LARGE
12/19/85	8:25:28	0000337	381.0	INTRABDOMINAL MASS VENTRAL TO LIVER SIZE LARGE
1/16/86	9:32:28	0000337	367.0	INTRABDOMINAL MASS VENTRAL TO LIVER SIZE LARGE
1/29/86	7:50:20	0034567	334.0	INTRABDOMINAL MASS VENTRAL TO LIVER SIZE LARGE, EUTHANIZED

**Appendix F (cont.): INDIVIDUAL ANIMAL HISTORIES**

PAGE 40  
 DATE: 6/09/87  
 TIME: 14:40:13  
 EDS017 V4M11

STUDY: 0083009  
 COMPOUND: ISOBUTYL 2-CYANOACRYLATE  
 START DATE: 1/28/85

CARCINOGENICITY BIOASSAY OF ISOBUTYL 2-CYANO-  
 ACRYLATE (IBC) IN MALE AND FEMALE RATS.

ANIMAL HISTORY

Animal ID: 84D00077 Species: D Sex: MALE Group: 100 UL/ANM

DATE	TIME	OPERATOR	WEIGHT (GRAMS)	CLINICAL OBSERVATIONS
2/14/85	9:05:50	0000337	459.0	NORMAL
3/14/85	8:48:38	0078478	452.0	NORMAL
4/11/85	8:44:20	0000337	461.0	STAIN BROWN NOSE SLIGHT
4/15/85	8:28:16	0067831		NORMAL
5/09/85	8:07:02	0000337	460.0	NORMAL
5/22/85	8:10:58	0000337		INTRAABDOMINAL MASS VENTRAL TO LIVER SIZE LARGE
6/06/85	8:45:58	0010186	462.0	INTRAABDOMINAL MASS VENTRAL TO LIVER SIZE LARGE
7/02/85	7:38:14	0000337	473.0	INTRAABDOMINAL MASS VENTRAL TO LIVER SIZE LARGE
8/01/85	8:55:34	0001576	452.0	INTRAABDOMINAL MASS VENTRAL TO LIVER SIZE LARGE
8/29/85	7:56:08	0000337	444.0	INTRAABDOMINAL MASS VENTRAL TO LIVER SIZE LARGE
9/26/85	8:30:28	0000337	445.0	INTRAABDOMINAL MASS VENTRAL TO LIVER SIZE LARGE
10/24/85	8:33:56	0034567	443.0	INTRAABDOMINAL MASS VENTRAL TO LIVER SIZE LARGE
11/21/85	14:21:18	0002920	422.0	INTRAABDOMINAL MASS VENTRAL TO LIVER SIZE LARGE
12/19/85	8:26:16	0000337	429.0	INTRAABDOMINAL MASS VENTRAL TO LIVER SIZE LARGE
1/16/86	9:33:16	0000337	413.0	INTRAABDOMINAL MASS VENTRAL TO LIVER SIZE LARGE
1/29/86	7:52:00	0034567	379.0	INTRAABDOMINAL MASS VENTRAL TO LIVER SIZE LARGE, EUTHANIZED

PAGE 41  
DATE: 6/09/87  
TIME: 14:40:13  
EDS017 V4M11

### Appendix F (cont.): INDIVIDUAL ANIMAL HISTORIES

STUDY: 0083009  
COMPOUND: ISOBUTYL 2-CYANOACRYLATE  
START DATE: 1/28/85

CARCINOGENICITY BIOASSAY OF ISOBUTYL 2-CYANO-  
ACRYLATE (IBC) IN MALE AND FEMALE RATS.

#### ANIMAL HISTORY

Animal ID: 84D00078 Species: D Sex: MALE Group: 100 UL/ANM

DATE	TIME	OPERATOR	WEIGHT (GRAMS)	CLINICAL OBSERVATIONS
2/14/85	9:06:14	0000337	445.0	INTERABDOMINAL MASS VENTRAL TO LIVER
2/28/85	7:58:22	0000337	421.0	INTERABDOMINAL MASS VENTRAL TO LIVER
3/14/85	8:49:02	0078478	424.0	INTRAABDOMINAL MASS VENTRAL TO LIVER, SIZE MEDIUM
4/03/85	9:18:08	0000337	424.0	INTRAABDOMINAL MASS VENTRAL TO LIVER, SIZE MEDIUM
4/11/85	8:45:14	0000337	428.0	INTRAABDOMINAL MASS VENTRAL TO LIVER, SIZE MEDIUM
4/25/85	8:31:32	0000337	433.0	INTRAABDOMINAL MASS VENTRAL TO LIVER, SIZE MEDIUM
5/09/85	8:08:20	0000337	430.0	INTRAABDOMINAL MASS VENTRAL TO LIVER, SIZE MEDIUM
5/17/85	7:55:18	0000337	437.0	INTRAABDOMINAL MASS VENTRAL TO LIVER, SIZE LARGE
6/06/85	8:47:12	0010186	437.0	INTRAABDOMINAL MASS VENTRAL TO LIVER, SIZE LARGE
7/02/85	7:39:02	0000337	440.0	INTRAABDOMINAL MASS VENTRAL TO LIVER, SIZE LARGE
8/01/85	8:56:16	0001576	434.0	INTRAABDOMINAL MASS VENTRAL TO LIVER, SIZE LARGE
8/29/85	7:56:56	0000337	410.0	INTRAABDOMINAL MASS VENTRAL TO LIVER, SIZE LARGE
9/26/85	8:34:50	0000337	401.0	INTRAABDOMINAL MASS VENTRAL TO LIVER, SIZE LARGE
10/24/85	8:35:54	0034567	385.0	INTRAABDOMINAL MASS VENTRAL TO LIVER, SIZE LARGE
11/21/85	14:22:26	0002920	367.0	INTRAABDOMINAL MASS VENTRAL TO LIVER, SIZE LARGE
12/13/85	9:48:24	0000337	343.0	INTRAABDOMINAL MASS VENTRAL TO LIVER, STAIN BROWN PERIANAL SLIGHT, STAIN BROWN HEAD MARKED, STAIN BROWN PERIANAL SLIGHT,
12/19/85	8:27:10	0000337	343.0	INTRAABDOMINAL MASS SPLENIC SIZE LARGE
1/03/86	9:46:22	0000337		INTRAABDOMINAL MASS VENTRAL TO LIVER, STAIN BROWN NOSE MODERATE, STAIN BROWN HEAD MARKED, STAIN BROWN PERIANAL SLIGHT, EMACIATED MODERATE, INTRAABDOMINAL MASS VENTRAL TO LIVER, SIZE LARGE

## Appendix F (cont.): INDIVIDUAL ANIMAL HISTORIES

PAGE 42  
DATE: 6/09/87  
TIME: 14:40:13  
EDS017 V4M11

STUDY: 0083009 ISOBUTYL 2-CYANOACRYLATE CARCINOGENICITY BIOASSAY OF ISOBUTYL 2-CYANO-  
COMPOUND: ISOBUTYL 2-CYANOACRYLATE ACRYLATE (IBC) IN MALE AND FEMALE RATS.

START DATE: 1/28/85

## ANIMAL HISTORY

Animal ID: 84D00079 Species: D Sex: MALE Group: 100 UL/ANM

DATE	TIME	OPERATOR	WEIGHT (GRAMS)	CLINICAL OBSERVATIONS
2/14/85	9:11:30	0000337	410.0	XYPHOID PROTUBERANCE
3/14/85	8:50:10	0078478	420.0	XYPHOID PROTUBERANCE MODERATE
4/11/85	8:46:46	0000337	422.0	XYPHOID PROTUBERANCE
5/09/85	8:09:38	0000337	425.0	XYPHOID PROTUBERANCE SLIGHT
6/04/85	7:46:28	0000337		XYPHOID PROTUBERANCE SLIGHT, INTRAABDOMINAL MASS VENTRAL TO LIVER SIZE LARGE
6/06/85	8:49:06	0010186	427.0	XYPHOID PROTUBERANCE SLIGHT, INTRAABDOMINAL MASS VENTRAL TO LIVER SIZE LARGE
7/02/85	7:39:50	0000337	432.0	INTRAABDOMINAL MASS VENTRAL TO LIVER SIZE LARGE, XYPHOID PROTUBERANCE SLIGHT
8/01/85	8:56:54	0001576	431.0	XYPHOID PROTUBERANCE SLIGHT, INTRAABDOMINAL MASS VENTRAL TO LIVER SIZE LARGE
8/29/85	7:57:56	0000337	417.0	XYPHOID PROTUBERANCE SMALL, INTRAABDOMINAL MASS VENTRAL TO LIVER SIZE LARGE
9/26/85	8:37:08	0000337	420.0	XYPHOID PROTUBERANCE MODERATE, INTRAABDOMINAL MASS VENTRAL TO LIVER SIZE LARGE
10/24/85	8:37:18	0034567	422.0	XYPHOID PROTUBERANCE MODERATE, INTRAABDOMINAL MASS VENTRAL TO LIVER SIZE LARGE
11/21/85	14:24:06	0002920	417.0	INTRAABDOMINAL MASS VENTRAL TO LIVER SIZE LARGE, XYPHOID PROTUBERANCE MODERATE
12/19/85	8:29:20	0000337	419.0	INTRAABDOMINAL MASS VENTRAL TO LIVER SIZE LARGE, XYPHOID PROTUBERANCE SLIGHT
1/16/86	9:34:02	0000337	406.0	INTRAABDOMINAL MASS VENTRAL TO LIVER SIZE LARGE, XYPHOID PROTUBERANCE SMALL
1/29/86	7:54:16	0084799	382.0	INTRAABDOMINAL MASS VENTRAL TO LIVER SIZE LARGE, XYPHOID PROTUBERANCE SMALL, EUTHANIZED

PAGE 43 0  
 DATE: 6/09/87  
 TIME: 1:40:13  
 EDS017 V4M11

**Appendix F (cont.): INDIVIDUAL ANIMAL HISTORIES**

STUDY: 0083009  
 COMPOUND: ISOBUTYL 2-CYANOACRYLATE  
 START DATE: 1/28/85

ANIMAL HISTORY  
 CARCINOGENICITY BIOASSAY OF ISOBUTYL 2-CYANO-  
 ACRYLATE (IBC) IN MALE AND FEMALE RATS.

Animal ID: 84D00080 Species: D Sex: MALE Group: 100 UL/ANM

DATE	TIME	OPERATOR	WEIGHT (GRAMS)	CLINICAL OBSERVATIONS
2/14/85	9:13:10	0000337	398.0	CORNEAL OPACITY RIGHT EYE SLIGHT
3/14/85	8:51:24	0078478	400.0	CORNEAL OPACITY RIGHT EYE SLIGHT
4/11/85	8:47:36	0000337	407.0	CORNEAL OPACITY RIGHT EYE SLIGHT
5/09/85	8:10:46	0000337	409.0	CORNEAL OPACITY RIGHT EYE SLIGHT
6/06/85	8:50:38	0010186	415.0	CORNEAL OPACITY RIGHT EYE SLIGHT
6/19/85	7:51:04	0000337		CORNEAL OPACITY RIGHT EYE SLIGHT,
6/20/85	7:27:22	0000337		CORNEAL OPACITY RIGHT EYE SLIGHT, STAIN BROWN NOSE SLIGHT, INTRAABDOMINAL MASS VENTRAL TO LIVER SIZE MEDIUM
7/02/85	7:40:48	0000337	419.0	CORNEAL OPACITY RIGHT EYE SLIGHT,
8/01/85	8:57:52	0001576	423.0	CORNEAL OPACITY RIGHT EYE SLIGHT, INTRAABDOMINAL MASS VENTRAL TO LIVER SIZE MEDIUM
8/13/85	8:49:08	0000337		CORNEAL OPACITY RIGHT EYE SLIGHT, INTRAABDOMINAL MASS VENTRAL TO LIVER SIZE MEDIUM, CORNEAL OPACITY RIGHT EYE SLIGHT
8/29/85	7:59:50	0000337	424.0	CORNEAL OPACITY RIGHT EYE SLIGHT, INTRAABDOMINAL MASS SIZE SMALL
9/26/85	8:38:24	0000337	420.0	CORNEAL OPACITY RIGHT EYE SLIGHT, INTRAABDOMINAL MASS VENTRAL TO LIVER SIZE MEDIUM
10/16/85	8:53:08	0000337		CORNEAL OPACITY RIGHT EYE SLIGHT, INTRAABDOMINAL MASS VENTRAL TO LIVER SIZE LARGE
10/24/85	8:38:52	0034567	409.0	DEATH

PAGE 44  
 DATE: 6/09/87  
 TIME: 14:40:13  
 EDS017 V4M11

**Appendix F (cont.): INDIVIDUAL ANIMAL HISTORIES**

STUDY: 0083009  
 COMPOUND: ISOBUTYL 2-CYANOACRYLATE  
 START DATE: 1/28/85

CARCINOGENICITY BIOASSAY OF ISOBUTYL 2-CYANO-  
 ACRYLATE (IBC) IN MALE AND FEMALE RATS.

ANIMAL HISTORY

Animal ID: 84D00081 Species: D Sex: MALE Group: 100 UL/ANM

DATE	TIME	OPERATOR	WEIGHT (GRAMS)	CLINICAL OBSERVATIONS
2/14/85	9:13:36	0000337	395.0	NORMAL
3/04/85	8:07:22	0000337		STAIN BROWN NOSE SLIGHT
3/12/85	8:13:28	0000337		NORMAL
3/14/85	8:51:52	0078478	402.0	NORMAL
4/11/85	8:48:36	0000337	403.0	NORMAL
5/09/85	8:11:10	0000337	408.0	NORMAL
6/06/85	8:51:02	0010186	415.0	NORMAL
7/02/85	7:45:40	0000337	420.0	SUBCUTANEOUS MASS PERIHUMERUS RIGHT SIDE SIZE LARGE
8/01/85	8:58:48	0001576	429.0	SUBCUTANEOUS MASS PERIHUMERUS RIGHT SIDE SIZE LARGE
8/13/85	8:52:06	0000337		SUBCUTANEOUS MASS RIGHT SIDE PERIHUMERUS SIZE LARGE
8/28/85	12:28:58	0000337		* No observations recorded.

PAGE 45  
DATE: 6/09/87  
TIME: 14:40:13  
EDS017 V4M11

### Appendix F (cont.): INDIVIDUAL ANIMAL HISTORIES

STUDY: 0083009  
COMPOUND: ISOBUTYL 2-CYANOACRYLATE  
START DATE: 1/28/85

ISOBUTYL 2-CYANOACRYLATE  
ACRYLATE (IBC) IN MALE AND FEMALE RATS.

#### ANIMAL HISTORY

Animal ID: 84D00082 Species: D Sex: MALE Group: 10 UL/ANN

DATE	TIME	OPERATOR	WEIGHT (GRAMS)	CLINICAL OBSERVATIONS
2/13/85	9:53:52	0000337		ALOPECIA PERIANAL SLIGHT, ALOPECIA BOTH HIND LEG SLIGHT
2/14/85	9:13:54	0000337	441.0	ALOPECIA PERIANAL SLIGHT, ALOPECIA BOTH HIND LEG SLIGHT
3/12/85	8:14:30	0000337		ALOPECIA PERIANAL SLIGHT, ALOPECIA BOTH HIND LEG SLIGHT, ALOPECIA MOUTH SLIGHT
3/14/85	8:53:50	0078478	446.0	ALOPECIA PERIANAL SLIGHT, ALOPECIA BOTH HIND LEG SLIGHT, ALOPECIA MOUTH SLIGHT
3/21/85	8:14:48	0000337		ALOPECIA BOTH HIND LEG MODERATE, ALOPECIA PERIANAL MODERATE, ALOPECIA MOUTH SLIGHT, ALOPECIA BOTH FRONT LEG SLIGHT
4/02/85	8:24:00	0000337		ALOPECIA BOTH HIND LEG SLIGHT, ALOPECIA PERIANAL SLIGHT, ALOPECIA MOUTH SLIGHT
4/11/85	8:49:44	0000337	450.0	ALOPECIA BOTH HIND LEG SLIGHT, ALOPECIA PERIANAL SLIGHT, ALOPECIA MOUTH SLIGHT
4/24/85	8:25:40	0000337		WIDESPREAD PATCHY ALOPECIA PRIMARILY OF VENTRAL ASPECT AND FACE, STAIN BROWN NOSE SLIGHT
5/09/85	8:11:48	0000337	451.0	WIDESPREAD PATCHY ALOPECIA PRIMARILY OF VENTRAL ASPECT AND FACE
6/06/85	8:51:26	0010186	447.0	WIDESPREAD PATCHY ALOPECIA PRIMARILY OF THE VENTRAL ASPECT AND FACE
7/02/85	7:47:54	0000337	445.0	WIDESPREAD PATCHY ALOPECIA PRIMARILY OF THE VENTRAL ASPECT AND FACE
8/01/85	9:00:28	0001576	439.0	WIDESPREAD PATCHY ALOPECIA PRIMARILY OF THE VENTRAL ASPECT AND FACE
8/29/85	8:01:02	0000337	436.0	WIDESPREAD PATCHY ALOPECIA
9/26/85	8:39:50	0084799	438.0	GENERALIZED PATCHY ALOPECIA WITH DERMAL LESIONS DORSAL TAIL
10/24/85	8:46:46	0034567	451.0	GENERALIZED PATCHY ALOPECIA WITH DERMAL LESIONS DORSAL TAIL
11/06/85	8:27:46	0084799		GENERALIZED PATCHY ALOPECIA WITH DORSAL LESIONS TAIL, INTRAABDOMINAL MASS VENTRAL TO LIVER SIZE LARGE, SUBCUTANEOUS MASS DORSAL MIDLINE SIZE SMALL
11/21/85	14:27:02	0002920	437.0	GENERALIZED PATCHY ALOPECIA MARKED, SCAB TAIL MARKED, INTRAABDOMINAL MASS VENTRAL TO LIVER SIZE MEDIUM, SUBCUTANEOUS MASS DORSAL MIDLINE SIZE MEDIUM
12/19/85	8:31:10	0084799	439.0	GENERALIZED PATCHY ALOPECIA MARKED, SCAB TAIL MARKED, INTRAABDOMINAL MASS VENTRAL TO LIVER SIZE MEDIUM, SUBCUTANEOUS MASS DORSAL MIDLINE SIZE SMALL
1/16/86	10:17:26	0000337	422.0	SCAB TAIL MARKED, INTRAABDOMINAL MASS VENTRAL TO LIVER SIZE MEDIUM, PATCHY GENERALIZED ALOPECIA MARKED, SUBCUTANEOUS MASS DORSAL MIDLINE SIZE SMALL
1/29/86	7:57:38	0034567	397.0	INTRAABDOMINAL MASS VENTRAL TO LIVER SIZE MEDIUM, GENERALIZED PATCHY ALOPECIA MARKED, SUBCUTANEOUS MASS DORSAL MIDLINE SIZE SMALL, EUTHANIZED



**Appendix F (cont.): INDIVIDUAL ANIMAL HISTORIES**

PAGE 46  
 DATE: 6/09/87  
 TIME: 14:40:13  
 EDS017 V4M11

STUDY: 0083009  
 COMPOUND: ISOBUTYL 2-CYANOACRYLATE  
 START DATE: 1/28/85  
 CARCINOGENICITY BIOASSAY OF ISOBUTYL 2-CYANO-  
 ACRYLATE (IBC) IN MALE AND FEMALE RATS.

ANIMAL HISTORY

Animal ID: 84D00083 Species: D Sex: MALE Group: 10 UL/ANM

DATE	TIME	OPERATOR	WEIGHT (GRAMS)	CLINICAL OBSERVATIONS
2/14/85	9:14:28	0000337	398.0	NORMAL
3/12/85	8:15:56	0000337		STAIN BROWN NOSE SLIGHT
3/14/85	8:55:14	0078478	405.0	NORMAL
4/11/85	8:50:32	0000337	405.0	INTRAABDOMINAL MASS ON LIVER, MEDIUM
4/25/85	8:55:10	0000337	410.0	INTRAABDOMINAL MASS VENTRAL TO LIVER, SIZE SMALL
5/09/85	8:14:26	0000337	404.0	INTRAABDOMINAL MASS VENTRAL TO LIVER SIZE MEDIUM
6/04/85	7:51:58	0000337		INTRAABDOMINAL MASS VENTRAL TO LIVER SIZE MEDIUM
6/06/85	8:52:42	0010186	410.0	INTRAABDOMINAL MASS VENTRAL TO LIVER SIZE MEDIUM
6/20/85	7:33:04	0000337		INTRAABDOMINAL MASS VENTRAL TO LIVER SIZE MEDIUM
7/02/85	7:48:56	0000337	413.0	INTRAABDOMINAL MASS VENTRAL TO LIVER SIZE MEDIUM
8/01/85	9:01:36	0001576	420.0	INTRAABDOMINAL MASS VENTRAL TO LIVER SIZE MEDIUM
8/29/85	8:02:16	0000337	411.0	INTRAABDOMINAL MASS VENTRAL TO LIVER SIZE MEDIUM
9/26/85	8:41:52	0000337	416.0	INTRAABDOMINAL MASS VENTRAL TO LIVER SIZE MEDIUM
10/24/85	8:48:00	0034567	415.0	INTRAABDOMINAL MASS VENTRAL TO LIVER SIZE MEDIUM
11/21/85	14:33:14	0002920	407.0	INTRAABDOMINAL MASS VENTRAL TO LIVER SIZE LARGE
12/19/85	8:34:40	0000337	405.0	INTRAABDOMINAL MASS VENTRAL TO LIVER SIZE MEDIUM
1/16/86	10:20:36	0000337	392.0	INTRAABDOMINAL MASS VENTRAL TO LIVER SIZE MEDIUM
1/29/86	8:02:08	0034567	367.0	INTRAABDOMINAL MASS VENTRAL TO LIVER SIZE MEDIUM, EUTHANIZED

PAGE 47  
 DATE: 6/09/87  
 TIME: 14:40:13  
 EDS017 V4M11

**Appendix F (cont.): INDIVIDUAL ANIMAL HISTORIES**

STUDY: 0083009 ISOBUTYL 2-CYANOACRYLATE CARCINOGENICITY BIOASSAY OF ISOBUTYL 2-CYANO-  
 COMPOUND: ISOBUTYL 2-CYANOACRYLATE ACRYLATE (IBC) IN MALE AND FEMALE RATS.  
 START DATE: 1/28/85

ANIMAL HISTORY

Animal ID: 84D00084 Species: D Sex: MALE Group: 10 UL/ANM

DATE	TIME	OPERATOR	WEIGHT (GRAMS)	CLINICAL OBSERVATIONS
2/14/85	9:14:52	0000337	434.0	NORMAL
3/04/85	8:09:10	0000337		STAIN BROWN NOSE SLIGHT
3/12/85	8:17:50	0000337		NORMAL
3/14/85	8:55:40	0078478	438.0	NORMAL
4/11/85	8:55:40	0000337	446.0	NORMAL
5/09/85	8:15:38	0000337	460.0	NORMAL
6/06/85	8:53:28	0010186	462.0	NORMAL
7/02/85	7:49:54	0000337	467.0	NORMAL
8/01/85	9:02:28	0001576	475.0	NORMAL
8/29/85	8:04:22	0000337	473.0	NORMAL
9/26/85	8:42:52	0000337	473.0	NORMAL
10/24/85	8:50:16	0034567	473.0	NORMAL
10/24/85	9:05:18	0034567	474.0	* No observations recorded.

**Appendix F (cont.): INDIVIDUAL ANIMAL HISTORIES**

PAGE 48  
 DATE: 6/09/87  
 TIME: 14:40:13  
 EDS017 V4M11

STUDY: 0083009  
 COMPOUND: ISOBUTYL 2-CYANOACRYLATE  
 START DATE: 1/28/85

CARCINOGENICITY BIOASSAY OF ISOBUTYL 2-CYANO-  
 ACRYLATE (IBC) IN MALE AND FEMALE RATS.

ANIMAL HISTORY

Animal ID: 84D00085 Species: D Sex: MALE Group: 100 UL/ANM

DATE	TIME	OPERATOR	WEIGHT (GRAMS)	CLINICAL OBSERVATIONS
2/14/85	9:15:26	0000337	369.0	XYPHOID PROTUBERANCE
3/14/85	8:56:20	0078478	377.0	XYPHOID PROTUBERANCE SLIGHT
4/11/85	8:56:14	0000337	383.0	XYPHOID PROTUBERANCE SMALL
5/09/85	8:15:58	0000337	387.0	XYPHOID PROTUBERANCE SMALL
6/04/85	7:54:18	0000337		XYPHOID PROTUBERANCE SMALL, INTRAABDOMINAL MASS VENTRAL TO LIVER SIZE MEDIUM
6/06/85	8:53:58	0010186	395.0	XYPHOID PROTUBERANCE SLIGHT, INTRAABDOMINAL MASS VENTRAL TO LIVER SIZE MEDIUM
7/02/85	7:50:24	0000337	405.0	XYPHOID PROTUBERANCE SLIGHT, INTRAABDOMINAL MASS VENTRAL TO LIVER SIZE MEDIUM
8/01/85	9:03:22	0001576	406.0	XYPHOID PROTUBERANCE SLIGHT, INTRAABDOMINAL MASS VENTRAL TO LIVER SIZE MEDIUM
8/29/85	8:04:48	0000337	405.0	XYPHOID PROTUBERANCE SLIGHT, INTRAABDOMINAL MASS VENTRAL TO LIVER SIZE MEDIUM
9/26/85	8:43:10	0000337	411.0	XYPHOID PROTUBERANCE MODERATE, INTRAABDOMINAL MASS VENTRAL TO LIVER SIZE LARGE
10/24/85	8:50:46	0034567	416.0	XYPHOID PROTUBERANCE MODERATE, INTRAABDOMINAL MASS VENTRAL TO LIVER SIZE LARGE
11/21/85	14:34:16	0002920	412.0	XYPHOID PROTUBERANCE MODERATE, INTRAABDOMINAL MASS VENTRAL TO LIVER SIZE LARGE
12/19/85	8:35:26	0000337	410.0	INTRAABDOMINAL MASS VENTRAL TO LIVER SIZE LARGE, XYPHOID PROTUBERANCE SLIGHT
1/16/86	10:21:26	0000337	403.0	INTRAABDOMINAL MASS VENTRAL TO LIVER SIZE LARGE, XYPHOID PROTUBERANCE SLIGHT
1/29/86	8:04:14	0034567	377.0	INTRAABDOMINAL MASS VENTRAL TO LIVER SIZE LARGE, XYPHOID PROTUBERANCE SLIGHT, EUTHANIZED

PAGE 49  
 DATE: 6/09/87  
 TIME: 14:40:13  
 EDS017 V4M11

**Appendix F (cont.): INDIVIDUAL ANIMAL HISTORIES**

STUDY: 0083009 ISOBUTYL 2-CYANOACRYLATE CARCINOGENICITY BIOASSAY OF ISOBUTYL 2-CYANO-  
 COMPOUND: ISOBUTYL 2-CYANOACRYLATE ACRYLATE (IBC) IN MALE AND FEMALE RATS.  
 START DATE: 1/28/85

ANIMAL HISTORY

Animal ID: 84D00086 Species: D Sex: MALE Group: CONTROLS

DATE	TIME	OPERATOR	WEIGHT (GRAMS)	CLINICAL OBSERVATIONS
2/14/85	9:16:18	0000337	428.0	NORMAL
3/04/85	8:10:38	0000337		STAIN BROWN NOSE SLIGHT
3/14/85	8:57:04	0078478	443.0	NORMAL
4/11/85	8:57:30	0000337	443.0	NORMAL
5/09/85	8:16:48	0000337	441.0	NORMAL
6/06/85	8:55:28	0010186	446.0	NORMAL
7/02/85	7:51:32	0000337	437.0	NORMAL
8/01/85	9:04:16	0001576	438.0	NORMAL
8/29/85	8:06:08	0000337	441.0	NORMAL
9/26/85	8:44:36	0000337	438.0	NORMAL
10/24/85	8:51:42	0034567	439.0	NORMAL
11/21/85	14:36:20	0002920	437.0	NORMAL
12/19/85	8:36:38	0000337	435.0	NORMAL
1/16/86	10:22:36	0000337	421.0	NORMAL
1/29/86	8:06:20	0034567	395.0	NORMAL / EUTHANIZED

## Appendix F (cont.): INDIVIDUAL ANIMAL HISTORIES

PAGE 50  
DATE: 6/09/87  
TIME: 14:40:13  
EDS017 V4M11

STUDY: 0083009  
COMPOUND: ISOBUTYL 2-CYANOACRYLATE  
START DATE: 1/28/85

CARCINOGENICITY BIOASSAY OF ISOBUTYL 2-CYANO-  
ACRYLATE (7BC) IN MALE AND FEMALE RATS.

## ANIMAL HISTORY

Animal ID: 84D00087 Species: D Sex: MALE Group: CONTROLS

DATE	TIME	OPERATOR	WEIGHT (GRAMS)	CLINICAL OBSERVATIONS
2/14/85	9:16:42	0000337	435.0	CORNEAL OPACITY RIGHT EYE SLIGHT
3/14/85	8:57:28	0078478	437.0	CORNEAL OPACITY RIGHT EYE SLIGHT
4/11/85	8:58:12	0000337	431.0	NORMAL
5/09/85	8:17:10	0000337	437.0	NORMAL
6/06/85	8:55:50	0010186	439.0	NORMAL
6/20/85	7:38:52	0000337		STAIN BROWN NOSE MODERATE
7/02/85	7:52:08	0000337	424.0	NORMAL
8/01/85	9:04:42	0001576	444.0	NORMAL
8/29/85	8:06:32	0000337	449.0	NORMAL
9/26/85	8:44:56	0000337	457.0	NORMAL
10/24/85	8:52:00	0034567	457.0	NORMAL
11/06/85	8:37:04	0000337		CONJUNCTIVITIS LEFT EYE SLIGHT
11/21/85	14:36:54	0002920	447.0	NORMAL
12/19/85	8:36:56	0000337	441.0	NORMAL
1/16/86	10:22:54	0000337	419.0	CONJUNCTIVITIS RIGHT EYE MARKED
1/29/86	8:07:26	0034567	389.0	CONJUNCTIVITIS RIGHT EYE MARKED, EUTHANIZED

PAGE 51  
 DATE: 6/09/87  
 TIME: 14:40:13  
 EDS017 VAM11

**Appendix F (cont.): INDIVIDUAL ANIMAL HISTORIES**

STUDY: 0083009  
 COMPOUND: ISOBUTYL 2-CYANOACRYLATE  
 START DATE: 1/28/85

CARCINOGENICITY BIOASSAY OF ISOBUTYL 2-CYANO-  
 ACRYLATE (IBC) IN MALE AND FEMALE RATS.

ANIMAL HISTORY

Animal ID: 84D00088 Species: D Sex: MALE Group: 10 UL/ANM

DATE	TIME	OPERATOR	WEIGHT (GRAMS)	CLINICAL OBSERVATIONS
2/14/85	9:17:06	0000337	398.0	NORMAL
3/14/85	8:58:22	0078478	401.0	NORMAL
4/11/85	8:59:22	0000337	401.0	NORMAL
5/09/85	8:17:32	0000337	406.0	NORMAL
6/06/85	8:56:18	0010186	413.0	NORMAL
6/20/85	7:39:54	0084799		INTRAABDOMINAL MASS VENTRAL TO LIVER SIZE MEDIUM
7/02/85	7:52:46	0000337	416.0	INTRAABDOMINAL MASS VENTRAL TO LIVER SIZE MEDIUM
8/01/85	9:05:00	0001576	415.0	NORMAL
8/29/85	8:07:00	0000337	424.0	INTRAABDOMINAL MASS VENTRAL TO LIVER SIZE MEDIUM
9/26/85	8:45:18	0000337	409.0	INTRAABDOMINAL MASS VENTRAL TO LIVER SIZE MEDIUM
10/24/85	8:52:26	0034567	416.0	INTRAABDOMINAL MASS VENTRAL TO LIVER SIZE MEDIUM
11/21/85	14:39:04	0002920	405.0	INTRAABDOMINAL MASS VENTRAL TO LIVER SIZE MEDIUM
12/19/85	8:37:20	0000337	406.0	INTRAABDOMINAL MASS VENTRAL TO LIVER SIZE MEDIUM
1/16/86	10:23:34	0084799	386.0	INTRAABDOMINAL MASS VENTRAL TO LIVER SIZE MEDIUM
1/29/86	8:09:10	0034567	346.0	INTRAABDOMINAL MASS VENTRAL TO LIVER SIZE MEDIUM, EUTHANIZED

## Appendix F (cont.): INDIVIDUAL ANIMAL HISTORIES

PAGE 52  
DATE: 6/09/87  
TIME: 14:40:13  
EDS017 V4M11

STUDY: 0083009 CARCINOGENICITY BIOASSAY OF ISOBUTYL 2-CYANO-  
COMPOUND: ISOBUTYL 2-CYANOACRYLATE ACRYLATE (IBC) IN MALE AND FEMALE RATS.  
START DATE: 1/28/85

## ANIMAL HISTORY

Animal ID: 84D00089 Species: D Sex: MALE Group: 100 UL/ANM

DATE	TIME	OPERATOR	WEIGHT (GRAMS)	CLINICAL OBSERVATIONS
2/14/85	9:17:22	0000337	461.0	NORMAL
3/04/85	8:12:16	0000337		STAIN BROWN NOSE SLIGHT
3/12/85	8:20:06	0000337		NORMAL
3/14/85	8:59:04	0078478	461.0	NORMAL
4/11/85	9:00:10	0000337	440.0	NORMAL
5/09/85	8:17:58	0000337	433.0	NORMAL
6/06/85	8:56:50	0010186	442.0	NORMAL
7/02/85	7:53:46	0000337	454.0	NORMAL
8/01/85	9:06:30	0001576	445.0	NORMAL
8/29/85	8:08:54	0000337	448.0	NORMAL
9/26/85	8:46:32	0000337	442.0	NORMAL
10/24/85	8:53:12	0034567	446.0	NORMAL
11/21/85	14:40:06	0002920	436.0	INTRABDOMINAL MASS VENTRAL TO LIVER SIZE MEDIUM
12/19/85	8:38:04	0000337	440.0	INTRABDOMINAL MASS VENTRAL TO LIVER SIZE LARGE
1/14/86	10:38:46	0000337		DEATH

PAGE 53  
 DATE: 6/09/87  
 TIME: 14:40:13  
 EDS017 V4M11

**Appendix F (cont.): INDIVIDUAL ANIMAL HISTORIES**

STUDY: 0083009 ISOBUTYL 2-CYANOACRYLATE CARCINOGENICITY BIOASSAY OF ISOBUTYL 2-CYANO-  
 COMPOUND: ISOBUTYL 2-CYANOACRYLATE ACRYLATE (IBC) IN MALE AND FEMALE RATS.  
 START DATE: 1/28/85

Animal ID: 84D00090 Species: D Sex: MALE Group: 10 UL/ANN

ANIMAL HISTORY

DATE	TIME	OPERATOR	WEIGHT (GRAMS)	CLINICAL OBSERVATIONS
2/14/85	9:17:38	0000337	422.0	NORMAL
3/14/85	8:59:24	0078478	435.0	NORMAL
4/11/85	9:01:52	0000337	435.0	NORMAL
5/09/85	8:18:22	0000337	432.0	NORMAL
5/22/85	8:20:20	0000337		INTRAABDOMINAL MASS VENTRAL TO LIVER SIZE MEDIUM
6/04/85	7:59:04	0000337		INTRAABDOMINAL MASS VENTRAL TO LIVER SIZE MEDIUM
6/06/85	8:57:16	0010186	427.0	INTRAABDOMINAL MASS VENTRAL TO LIVER SIZE LARGE
7/02/85	7:54:12	0000337	438.0	INTRAABDOMINAL MASS VENTRAL TO LIVER SIZE SMALL
8/01/85	9:07:14	0001576	432.0	INTRAABDOMINAL MASS VENTRAL TO LIVER SIZE MEDIUM
8/29/85	8:09:12	0084799	435.0	INTRAABDOMINAL MASS VENTRAL TO LIVER SIZE MEDIUM
9/26/85	8:46:56	0000337	429.0	INTRAABDOMINAL MASS VENTRAL TO LIVER SIZE LARGE
10/24/85	8:53:40	0034567	434.0	INTRAABDOMINAL MASS VENTRAL TO LIVER SIZE LARGE
11/21/85	14:59:42	0002920	427.0	INTRAABDOMINAL MASS VENTRAL TO LIVER SIZE LARGE
12/19/85	8:38:52	0000337	430.0	INTRAABDOMINAL MASS VENTRAL TO LIVER SIZE LARGE
1/16/86	10:24:24	0000337	423.0	INTRAABDOMINAL MASS VENTRAL TO LIVER SIZE LARGE
1/29/86	8:11:46	0034567	393.0	INTRAABDOMINAL MASS VENTRAL TO LIVER SIZE LARGE, EUTHANIZED



## Appendix F (cont.): INDIVIDUAL ANIMAL HISTORIES

PAGE 54  
DATE: 6/09/87  
TIME: 14:40:13  
EDS017 V4M11

STUDY: 0083009 ISOBUTYL 2-CYANOACRYLATE CARCINOGENICITY BIOASSAY OF ISOBUTYL 2-CYANO-  
COMPOUND: ISOBUTYL 2-CYANOACRYLATE ACRYLATE (IBC) IN MALE AND FEMALE RATS.  
START DATE: 1/28/85

## ANIMAL HISTORY

Animal ID: 84D00091 Species: D Sex: MALE Group: 100 UL/ANM

DATE	TIME	OPERATOR	WEIGHT (GRAMS)	CLINICAL OBSERVATIONS
2/14/85	9:17:54	0000337	367.0	XYPHOID PROTUBERANCE
2/17/85	8:08:32	0078478		XYPHOID PROTUBERANCE, SCAB BACK SLIGHT
2/19/85	8:33:52	0000337		XYPHOID PROTUBERANCE, SCAB BACK MODERATE
2/22/85	7:39:40	0000337		XYPHOID PROTUBERANCE, SCAB BACK SLIGHT
3/14/85	8:59:42	0078478	375.0	SCAB BACK SLIGHT, XYPHOID PROTUBERANCE SLIGHT
4/11/85	9:02:06	0000337	382.0	SCAB BACK SLIGHT, XYPHOID PROTUBERANCE SLIGHT
5/09/85	8:19:18	0000337	389.0	SCAB BACK SLIGHT, XYPHOID PROTUBERANCE MEDIUM
5/14/85	8:07:38	0000337		SCAB BACK SLIGHT, XYPHOID PROTUBERANCE MEDIUM, INTRAABDOMINAL MASS VENTRAL TO LIVER SIZE MEDIUM
5/22/85	8:23:46	0000337		SCAB BACK SLIGHT, XYPHOID PROTUBERANCE MEDIUM, INTRAABDOMINAL MASS VENTRAL TO LIVER SIZE MEDIUM
6/06/85	8:58:48	0010186	394.0	STAIN NOSE BROWN MODERATE, INTRAABDOMINAL MASS VENTRAL TO LIVER SIZE LARGE
7/02/85	7:55:38	0000337	398.0	XYPHOID PROTUBERANCE MODERATE, SCAB BACK SLIGHT, XYPHOID PROTUBERANCE MODERATE, SCAB BACK SLIGHT, INTRAABDOMINAL MASS VENTRAL TO LIVER SIZE LARGE
7/30/85	7:08:42	0034567		DEATH

PAGE 55  
 DATE: 6/09/87  
 TIME: 14:40:13  
 EDS017 V4M11

**Appendix F (cont.): INDIVIDUAL ANIMAL HISTORIES**

STUDY: 0083009 CARCINOGENICITY BIOASSAY OF ISOBUTYL 2-CYANO-  
 COMPOUND: ISOBUTYL 2-CYANOACRYLATE ACRYLATE (IBC) IN MALE AND FEMALE RATS.  
 START DATE: 1/28/85

ANIMAL HISTORY

Animal ID: 84D00092 Species: D Sex: MALE Group: 10 UL/ANN

DATE	TIME	OPERATOR	WEIGHT (GRAMS)	CLINICAL OBSERVATIONS
2/14/85	9:19:50	0000337	386.0	NORMAL
3/14/85	9:00:58	0078478	398.0	NORMAL
4/11/85	9:04:04	0000337	401.0	NORMAL
5/09/85	8:20:12	0000337	403.0	NORMAL
5/22/85	8:26:30	0000337		INTRABDOMINAL MASS VENTRAL TO LIVER SIZE LARGE
6/06/85	9:01:32	0010186	395.0	INTRABDOMINAL MASS VENTRAL TO LIVER SIZE MEDIUM
7/02/85	7:59:36	0000337	394.0	INTRABDOMINAL MASS VENTRAL TO LIVER SIZE MEDIUM
8/01/85	9:08:38	0001576	392.0	INTRABDOMINAL MASS VENTRAL TO LIVER SIZE MEDIUM
8/29/85	8:10:16	0000337	406.0	INTRABDOMINAL MASS VENTRAL TO LIVER SIZE MEDIUM
9/26/85	8:48:04	0000337	408.0	INTRABDOMINAL MASS VENTRAL TO LIVER SIZE MEDIUM
10/24/85	8:55:06	0034567	413.0	INTRABDOMINAL MASS VENTRAL TO LIVER SIZE MEDIUM
11/21/85	15:00:38	0002920	411.0	INTRABDOMINAL MASS VENTRAL TO LIVER SIZE MEDIUM
12/19/85	8:39:40	0000337	405.0	INTRABDOMINAL MASS VENTRAL TO LIVER SIZE MEDIUM
1/16/86	10:25:16	0000337	401.0	INTRABDOMINAL MASS VENTRAL TO LIVER SIZE MEDIUM
1/29/86	8:15:06	0034567	372.0	INTRABDOMINAL MASS VENTRAL TO LIVER SIZE MEDIUM, EUTHANIZED

**Appendix F (cont.): INDIVIDUAL ANIMAL HISTORIES**

PAGE 56  
 DATE: 6/09/87  
 TIME: 14:40:13  
 EDS017 V4M11

STUDY: 0083009  
 COMPOUND: ISOBUTYL 2-CYANOACRYLATE  
 START DATE: 1/28/85

CARCINOGENICITY BIOASSAY OF ISOBUTYL 2-CYANO-  
 ACRYLATE (IBC) IN MALE AND FEMALE RATS.

ANIMAL HISTORY

Animal ID: 84D00093 Species: D Sex: MALE Group: CONTROLS

DATE	TIME	OPERATOR	WEIGHT (GRAMS)	CLINICAL OBSERVATIONS
2/14/85	9:20:20	0000337	435.0	NORMAL
3/14/85	9:01:22	0078478	444.0	NORMAL
4/11/85	9:04:46	0000337	445.0	NORMAL
5/09/85	8:20:40	0000337	453.0	NORMAL
6/06/85	9:02:50	0010186	458.0	NORMAL
7/02/85	8:00:40	0000337	471.0	NORMAL
8/01/85	9:09:32	0001576	464.0	NORMAL
8/29/85	8:11:10	0000337	467.0	NORMAL
9/26/85	8:49:00	0000337	466.0	NORMAL
10/21/85	10:18:36	0072808		SWOLLEN LIP RIGHT SIDE OF FACE SLIGHT
10/24/85	8:56:54	0034567	473.0	SWOLLEN LIP RIGHT SIDE OF FACE SLIGHT
11/04/85	9:53:54	0000337		MASS MAXILLARY RIGHT SIDE SIZE MEDIUM
11/21/85	15:01:34	0002920	456.0	MASS MAXILLARY RIGHT SIDE SIZE MEDIUM
12/19/85	8:40:48	0000337	451.0	MAXILLARY MASS SIZE MEDIUM, MASS LEFT SCROTAL AREA SIZE SMALL
1/16/86	10:26:00	0000337	414.0	MAXILLARY MASS SIZE LARGE, CUTANEOUS MASS SCROTUM SIZE SMALL
1/29/86	8:17:54	0034567	360.0	MAXILLARY MASS SIZE LARGE, CUTANEOUS MASS SCROTUM SIZE SMALL, EUTHANIZED

PAGE 57  
 DATE: 6/09/87  
 TIME: 14:40:13  
 EDS017 V4M11

**Appendix F (cont.): INDIVIDUAL ANIMAL HISTORIES**

STUDY: 0083009  
 COMPOUND: ISOBUTYL 2-CYANOACRYLATE  
 START DATE: 1/28/85  
 CARCINOGENICITY BIOASSAY OF ISOBUTYL 2-CYANO-  
 ACRYLATE (IBC) IN MALE AND FEMALE RATS.

ANIMAL HISTORY

Animal ID: 84D00094 Species: D Sex: MALE Group: 100 UL/ANM

DATE	TIME	OPERATOR	WEIGHT (GRAMS)	CLINICAL OBSERVATIONS
2/14/85	9:20:46	0000337	428.0	NORMAL
2/21/85	8:13:00	0000337		STAIN BROWN NOSE SLIGHT
2/22/85	7:44:56	0000337		NORMAL
3/04/85	8:16:12	0000337		STAIN BROWN NOSE SLIGHT
3/12/85	8:25:34	0000337		NORMAL
3/14/85	9:01:42	0078478	439.0	NORMAL
4/02/85	8:31:46	0000337		STAIN BROWN NOSE SLIGHT
4/11/85	9:05:36	0000337	438.0	STAIN BROWN NOSE SLIGHT
5/07/85	7:31:38	0000337		NORMAL
5/09/85	8:21:26	0000337	436.0	NORMAL
5/14/85	9:07:38	0000337		INTRAABDOMINAL MASS VENTRAL TO LIVER SIZE MEDIUM
5/22/85	8:29:56	0000337		INTRAABDOMINAL MASS VENTRAL TO LIVER SIZE LARGE
6/06/85	9:03:20	0010186	447.0	INTRAABDOMINAL MASS VENTRAL TO LIVER SIZE LARGE
7/02/85	8:01:10	0000337	447.0	INTRAABDOMINAL MASS VENTRAL TO LIVER SIZE LARGE
8/01/85	9:09:50	0001576	445.0	INTRAABDOMINAL MASS VENTRAL TO LIVER SIZE LARGE
8/29/85	8:11:36	0000337	448.0	INTRAABDOMINAL MASS VENTRAL TO LIVER SIZE LARGE
9/26/85	8:49:22	0000337	452.0	INTRAABDOMINAL MASS VENTRAL TO LIVER SIZE LARGE
10/24/85	8:57:40	0034567	460.0	INTRAABDOMINAL MASS VENTRAL TO LIVER SIZE LARGE
11/21/85	15:03:54	0002920	445.0	INTRAABDOMINAL MASS VENTRAL TO LIVER SIZE LARGE
12/19/85	8:43:08	0000337	444.0	INTRAABDOMINAL MASS VENTRAL TO LIVER SIZE LARGE
1/16/86	10:27:50	0000337	438.0	INTRAABDOMINAL MASS VENTRAL TO LIVER SIZE LARGE
1/29/86	8:22:14	0034567	414.0	INTRAABDOMINAL MASS VENTRAL TO LIVER SIZE LARGE, EUTHANIZED

PAGE 58  
 DATE: 6/09/87  
 TIME: 14:40:13  
 EDS017 V4M11

**Appendix F (cont.): INDIVIDUAL ANIMAL HISTORIES**

STUDY: 0083009 ISOBUTYL 2-CYANOACRYLATE CARCINOGENICITY BIOASSAY OF ISOBUTYL 2-CYANO-  
 COMPOUND: ISOBUTYL 2-CYANOACRYLATE ACRYLATE (IBC) IN MALE AND FEMALE RATS.  
 START DATE: 1/28/85

ANIMAL HISTORY

Animal ID: 84D00095 Species: D Sex: MALE Group: 100 UL/ANM

DATE	TIME	OPERATOR	WEIGHT (GRAMS)	CLINICAL OBSERVATIONS
2/14/85	9:21:02	0000337	367.0	NORMAL
3/14/85	9:02:06	0078478	371.0	NORMAL
4/11/85	9:06:48	0000337	380.0	NORMAL
4/24/85	8:37:48	0000337		STAIN BROWN NOSE SLIGHT
5/07/85	7:32:08	0000337		NORMAL
5/09/85	8:21:50	0000337	382.0	NORMAL
5/14/85	9:08:22	0000337		INTRAABDOMINAL MASS VENTRAL TO LIVER SIZE MEDIUM
6/04/85	8:05:40	0000337		INTRAABDOMINAL MASS VENTRAL TO LIVER SIZE LARGE
6/06/85	9:04:04	0010186	383.0	INTRAABDOMINAL MASS VENTRAL TO LIVER SIZE MEDIUM
7/02/85	8:01:54	0000337	377.0	INTRAABDOMINAL MASS VENTRAL TO LIVER SIZE MEDIUM
8/01/85	9:10:20	0001576	386.0	INTRAABDOMINAL MASS VENTRAL TO LIVER SIZE MEDIUM, MASS LEFT EAR SMALL
8/29/85	8:12:28	0000337	390.0	INTRAABDOMINAL MASS VENTRAL TO LIVER SIZE MEDIUM, MASS LEFT EAR SMALL
9/26/85	8:50:38	0000337	386.0	INTRAABDOMINAL MASS VENTRAL TO LIVER SIZE MEDIUM, CUTANEOUS MASS RIGHT EAR SIZE MEDIUM

PAGE 59@  
 DATE: 6/09/87  
 TIME: 14:40:13  
 EDS017 V4M11

**Appendix F (cont.): INDIVIDUAL ANIMAL HISTORIES**

STUDY: 0083009  
 COMPOUND: ISOBUTYL 2-CYANOACRYLATE  
 START DATE: 1/28/85

CARCINOGENICITY BIOASSAY OF ISOBUTYL 2-CYANO-  
 ACRYLATE (IBC) IN MALE AND FEMALE RATS.

**ANIMAL HISTORY**

Animal ID: 84D00096 Species: D Sex: MALE Group: 10 UL/ANM

DATE	TIME	WEIGHT	OPERATOR	CLINICAL OBSERVATIONS
2/14/85	9:21:20	321.0	0000337	NORMAL
3/14/85	9:02:30	325.0	0078478	NORMAL
4/11/85	9:07:28	332.0	0000337	NORMAL
5/09/85	8:22:14	331.0	0000337	NORMAL
6/06/85	9:05:48	332.0	0010186	NORMAL
7/02/85	8:02:46	344.0	0000337	NORMAL
8/01/85	9:12:40	341.0	0001576	NORMAL
8/29/85	8:14:12	350.0	0000337	NORMAL
9/26/85	8:52:48	350.0	0000337	NORMAL
10/24/85	8:58:36	350.0	0034567	NORMAL
11/21/85	15:04:42	341.0	0002920	NORMAL
12/19/85	8:43:54	327.0	0000337	NORMAL
1/16/86	10:29:22	298.0	0000337	NORMAL
1/26/86	7:58:04	0078478		INCREASED RESPIRATION DEPTH MODERATE, DECREASED RESPIRATION RATE MODERATE, WHEEZING SLIGHT, STAIN RED NOSE MARKED
1/27/86	10:28:04	270.0	0084799	STAIN RED NOSE MARKED, GASPING MARKED, PALLOR MARKED, EMACIATED MODERATE, APNEA MODERATE, EUTHANIZED

**Appendix F (cont.): INDIVIDUAL ANIMAL HISTORIES**

PAGE 60  
 DATE: 6/09/87  
 TIME: 14:40:13  
 EDS017 VJML1

STUDY: 0083009  
 COMPOUND: ISOBUTYL 2-CYANOACRYLATE  
 START DATE: 1/28/85  
 CARCINOGENICITY BIOASSAY OF ISOBUTYL 2-CYANO-  
 ACRYLATE (IBC) IN MALE AND FEMALE RATS.

ANIMAL HISTORY

Animal ID: 84D00097 Species: D Sex: MALE Group: 100 UL/ANM

DATE	TIME	OPERATOR	WEIGHT (GRAMS)	CLINICAL OBSERVATIONS
2/14/85	9:21:38	0000337	403.0	INTERABDOMINAL MASS VENTRAL TO LIVER
2/28/85	8:02:36	0000337	400.0	INTERABDOMINAL MASS VENTRAL TO LIVER
3/14/85	9:02:52	0078478	402.0	INTRAABDOMINAL MASS VENTRAL TO LIVER, SIZE MEDIUM
4/03/85	9:20:24	0000337	408.0	INTRAABDOMINAL MASS VENTRAL TO LIVER, SIZE MEDIUM
4/11/85	9:08:04	0000337	411.0	INTRAABDOMINAL MASS VENTRAL TO LIVER, SIZE MEDIUM
4/25/85	8:39:04	0084799	415.0	INTRAABDOMINAL MASS VENTRAL TO LIVER, SIZE MEDIUM
5/09/85	8:22:34	0084799	416.0	INTRAABDOMINAL MASS VENTRAL TO LIVER, SIZE LARGE
6/06/85	9:06:08	0010186	419.0	INTRAABDOMINAL MASS VENTRAL TO LIVER, SIZE LARGE
7/02/85	8:03:26	0000337	416.0	INTRAABDOMINAL MASS VENTRAL TO LIVER, SIZE LARGE
8/01/85	9:13:02	0001576	421.0	INTRAABDOMINAL MASS VENTRAL TO LIVER, SIZE LARGE
8/29/85	8:14:42	0000337	412.0	INTRAABDOMINAL MASS VENTRAL TO LIVER, SIZE LARGE
9/26/85	8:53:06	0084799	400.0	INTRAABDOMINAL MASS VENTRAL TO LIVER, SIZE LARGE
10/24/85	8:59:52	0034567	392.0	INTRAABDOMINAL MASS VENTRAL TO LIVER, SIZE LARGE
11/21/85	15:05:02	0002920	387.0	INTRAABDOMINAL MASS VENTRAL TO LIVER, SIZE LARGE
12/19/85	8:44:10	0000337	395.0	INTRAABDOMINAL MASS VENTRAL TO LIVER, SIZE LARGE
1/16/86	10:30:14	0000337	379.0	INTRAABDOMINAL MASS VENTRAL TO LIVER, SIZE LARGE, SPLENIC MASS SIZE LARGE
1/29/86	8:24:20	0084799	358.0	INTRAABDOMINAL MASS VENTRAL TO LIVER, SIZE LARGE, SPLENIC MASS SIZE LARGE, EUTHANIZED

PAGE 61  
 DATE: 6/09/87  
 TIME: 14:40:13  
 EDS017 V4M11

**Appendix F (cont.): INDIVIDUAL ANIMAL HISTORIES**

STUDY: 0083009  
 COMPOUND: ISOBUTYL 2-CYANOACRYLATE  
 START DATE: 1/28/85

CARCINOGENICITY BIOASSAY OF ISOBUTYL 2-CYANO-  
 ACRYLATE (IBC) IN MALE AND FEMALE RATS.

ANIMAL HISTORY

Animal ID: 84D00098 Species: D Sex: MALE Group: CONTROLS

DATE	TIME	OPERATOR	WEIGHT (GRAMS)	CLINICAL OBSERVATIONS
2/14/85	9:23:36	0000337	439.0	NORMAL
3/14/85	9:04:34	0078478	452.0	NORMAL
4/11/85	9:09:24	0000337	455.0	NORMAL
5/09/85	8:24:02	0000337	458.0	NORMAL
6/06/85	9:36:40	0010186	466.0	NORMAL
7/02/85	8:04:44	0000337	462.0	NORMAL
8/01/85	9:14:26	0001576	464.0	NORMAL
8/29/85	8:15:50	0000337	459.0	NORMAL
9/26/85	8:54:08	0000337	459.0	NORMAL
10/24/85	9:00:28	0034567	476.0	NORMAL
11/21/85	15:08:34	0002920	451.0	NORMAL
12/19/85	8:45:32	0000337	441.0	NORMAL
1/16/86	10:31:38	0000337	426.0	NORMAL
1/29/86	8:27:36	0034567	389.0	NORMAL / EUTHANIZED



## Appendix F (cont.): INDIVIDUAL ANIMAL HISTORIES

PAGE 62  
DATE: 6/09/87  
TIME: 14:40:13  
EDS017 V4M11

STUDY: 0083009 ISOBUTYL 2-CYANOACRYLATE  
CARCINOGENICITY BIOASSAY OF ISOBUTYL 2-CYANO-  
ACRYLATE (IBC) IN MALE AND FEMALE RATS.

START DATE: 1/28/85

## ANIMAL HISTORY

Animal ID: 84D00099 Species: D Sex: MALE Group: 100 UL/ANM

DATE	TIME	OPERATOR	WEIGHT (GRAMS)	CLINICAL OBSERVATIONS
2/14/85	9:23:58	0000337	301.0	LIXIT DEHYDRATION
2/15/85	10:55:12	0000337	333.0	* No observations recorded.
3/14/85	9:05:14	0078478	371.0	NORMAL
4/11/85	9:10:14	0000337	372.0	NORMAL
5/09/85	8:24:28	0000337	347.0	NORMAL
6/06/85	9:37:08	0010186	386.0	NORMAL
6/25/85	7:06:14	0000337		INTRABDOMINAL MASS PERISPLENIC SIZE SMALL
7/02/85	8:05:14	0000337	391.0	INTRABDOMINAL MASS PERISPLENIC SIZE SMALL
8/01/85	9:14:40	0001576	422.0	INTRABDOMINAL MASS PERISPLENIC SIZE LARGE
8/01/85	10:36:48	0034567		* No observations recorded.

PAGE 63  
 DATE: 6/09/87  
 TIME: 14:40:13  
 EDS017 V4M11

**Appendix F (cont.): INDIVIDUAL ANIMAL HISTORIES**

CARCINOGENICITY BIOASSAY OF ISOBUTYL 2-CYANO-  
 ACRYLATE (IBC) IN MALE AND FEMALE RATS.

STUDY: 0083009  
 COMPOUND: ISOBUTYL 2-CYANOACRYLATE  
 START DATE: 1/28/85

ANIMAL HISTORY

Animal ID: 84D00100 Species: D Sex: MALE Group: 100 UL/ANM

DATE	TIME	OPERATOR	WEIGHT (GRAMS)	CLINICAL OBSERVATIONS
2/14/85	9:27:12	0000337	385.0	NORMAL
3/14/85	9:05:46	0078478	385.0	NORMAL
4/11/85	9:11:44	0000337	388.0	NORMAL
5/09/85	8:25:14	0000337	380.0	HEMORRHAGE ANTERIOR CHAMBER RIGHT EYE SLIGHT
6/06/85	9:37:22	0010186	388.0	PROLAPSED LENS RIGHT EYE MARKED, OPAQUE LENS RIGHT EYE MARKED
7/02/85	8:06:30	0000337	386.0	PROLAPSED LENS RIGHT EYE MARKED, OPAQUE LENS RIGHT EYE MARKED
8/01/85	9:16:20	0001576	390.0	OPAQUE LENS RIGHT EYE MARKED, PROLAPSED LENS RIGHT EYE MARKED,
8/29/85	8:16:36	0000337	390.0	OPAQUE LENS RIGHT EYE MARKED, PROLAPSED LENS RIGHT EYE MARKED, INTRAABDOMINAL MASS VENTRAL TO LIVER SIZE SMALL
9/26/85	8:54:32	0000337	385.0	INTRAABDOMINAL MASS VENTRAL TO LIVER SIZE SMALL, OPAQUE LENS RIGHT EYE MARKED, HYPEREMIA RIGHT EYE MODERATE
10/16/85	9:07:40	0000337		INTRAABDOMINAL MASS VENTRAL TO LIVER SIZE LARGE, OPAQUE LENS RIGHT EYE MARKED, HYPEREMIA RIGHT EYE MODERATE
10/24/85	9:00:50	0084799	392.0	OPAQUE LENS RIGHT EYE MARKED, HYPEREMIA RIGHT EYE MARKED,
11/21/85	15:09:42	0084799	386.0	INTRAABDOMINAL MASS VENTRAL TO LIVER SIZE LARGE, NECROSIS TAIL SLIGHT
12/19/85	8:45:56	0000337	389.0	INTRAABDOMINAL MASS VENTRAL TO LIVER SIZE LARGE, OPAQUE LENS RIGHT EYE MARKED, NECROSIS TAIL SLIGHT
1/14/86	10:43:16	0000337		NECROSIS TAIL SLIGHT, INTRAABDOMINAL MASS VENTRAL TO LIVER SIZE LARGE, OPAQUE LENS RIGHT EYE MARKED DEATH

PAGE 64  
 DATE: 6/09/87  
 TIME: 14:40:13  
 EDS017 V4M11

**Appendix F (cont.): INDIVIDUAL ANIMAL HISTORIES**

STUDY: 0083009 ISOBUTYL 2-CYANOACRYLATE CARCINOGENICITY BIOASSAY OF ISOBUTYL 2-CYANO-  
 COMPOUND: ISOBUTYL 2-CYANOACRYLATE ACRYLATE (IBC) IN MALE AND FEMALE RATS.

START DATE: 1/28/85

ANIMAL HISTORY

Animal ID: 84D00101 Species: D Sex: MALE Group: CONTROLS

DATE	TIME	OPERATOR	WEIGHT (GRAMS)	CLINICAL OBSERVATIONS
2/14/85	9:27:54	0000337	432.0	NORMAL
3/14/85	9:06:08	0078478	438.0	NORMAL
4/11/85	9:12:28	0000337	450.0	NORMAL
5/09/85	8:26:28	0000337	451.0	NORMAL
6/06/85	9:38:28	0010186	459.0	NORMAL
7/02/85	8:07:20	0000337	457.0	NORMAL
8/01/85	9:17:02	0001576	454.0	NORMAL
8/29/85	8:18:50	0000337	457.0	NORMAL
9/26/85	8:56:44	0000337	455.0	NORMAL
10/24/85	9:02:30	0034567	453.0	NORMAL
11/21/85	15:13:12	0002920	445.0	NORMAL
12/19/85	8:47:08	0000337	437.0	NORMAL
1/16/86	10:32:12	0000337	436.0	SPLENIC MASS SIZE LARGE
1/29/86	8:29:24	0034567	392.0	SPLENIC MASS SIZE LARGE, EUTHANIZED

**Appendix F (cont.): INDIVIDUAL ANIMAL HISTORIES**

STUDY: 0083009  
 COMPOUND: ISOBUTYL 2-CYANOACRYLATE  
 START DATE: 1/28/85  
 CARCINOGENICITY BIOASSAY OF ISOBUTYL 2-CYANO-  
 ACRYLATE (IBC) IN MALE AND FEMALE RATS.

**ANIMAL HISTORY**

Animal ID: 84D00102 Species: D Sex: MALE Group: 10 UL/ANM

DATE	TIME	OPERATOR	WEIGHT (GRAMS)	CLINICAL OBSERVATIONS
2/14/85	9:28:10	0000337	400.0	NORMAL
3/14/85	9:06:32	0078478	410.0	NORMAL
4/11/85	9:12:54	0000337	406.0	NORMAL
5/09/85	8:26:58	0000337	412.0	NORMAL
6/05/85	7:28:08	0000337		INTRAABDOMINAL MASS VENTRAL TO LIVER SIZE MEDIUM
6/06/85	9:39:02	0010186	426.0	INTRAABDOMINAL MASS VENTRAL TO LIVER SIZE MEDIUM
7/02/85	8:07:44	0000337	424.0	INTRAABDOMINAL MASS VENTRAL TO LIVER SIZE MEDIUM
8/01/85	9:17:28	0001576	428.0	INTRAABDOMINAL MASS VENTRAL TO LIVER SIZE MEDIUM
8/29/85	8:19:16	0000337	403.0	INTRAABDOMINAL MASS VENTRAL TO LIVER SIZE LARGE, PALLORED MARKED
8/30/85	11:30:18	0000337		INTRAABDOMINAL MASS VENTRAL TO LIVER SIZE LARGE, PALLORED MARKED

PAGE 66  
 DATE: 6/09/87  
 TIME: 14:40:13  
 EDS017 V4M11

**Appendix F (cont.): INDIVIDUAL ANIMAL HISTORIES**

CARCINOGENICITY BIOASSAY OF ISOBUTYL 2-CYANO-  
 ACRYLATE (IBC) IN MALE AND FEMALE RATS.

STUDY: 0083009  
 COMPOUND: ISOBUTYL 2-CYANOACRYLATE  
 START DATE: 1/28/85

ANIMAL HISTORY

Animal ID: 84D00103 Species: D Sex: MALE Group: 100 UL/ANM

DATE	TIME	WEIGHT OPERATOR (GRAMS)	CLINICAL OBSERVATIONS
2/14/85	9:29:06	0000337 377.0	CORNEAL OPACITY RIGHT EYE SLIGHT
3/14/85	9:06:54	0078478 384.0	CORNEAL OPACITY RIGHT EYE SLIGHT
4/11/85	9:13:36	0000337 388.0	CORNEAL OPACITY RIGHT EYE SLIGHT
5/09/85	8:27:18	0000337 397.0	CORNEAL OPACITY RIGHT EYE SLIGHT
6/06/85	9:40:04	0010186 409.0	CORNEAL OPACITY RIGHT EYE SLIGHT
7/02/85	8:08:42	0000337 403.0	CORNEAL OPACITY RIGHT EYE SLIGHT
8/01/85	9:18:02	0001576 416.0	CORNEAL OPACITY RIGHT EYE SLIGHT
8/29/85	8:21:10	0000337 412.0	CORNEAL OPACITY RIGHT EYE SLIGHT
9/26/85	8:57:08	0000337 419.0	CORNEAL OPACITY RIGHT EYE SLIGHT
10/24/85	9:02:50	0034567 415.0	CORNEAL OPACITY RIGHT EYE SLIGHT, INTRAABDOMINAL MASS VENTRAL TO LIVER SIZE LARGE
11/06/85	8:51:58	0000337	CORNEAL OPACITY RIGHT EYE SLIGHT, INTRAABDOMINAL MASS VENTRAL TO LIVER SIZE LARGE
11/21/85	15:13:54	0002920 404.0	CORNEAL OPACITY RIGHT EYE SLIGHT, INTRAABDOMINAL MASS VENTRAL TO LIVER SIZE LARGE
12/19/85	8:47:38	0000337 389.0	CORNEAL OPACITY RIGHT EYE SLIGHT, INTRAABDOMINAL MASS VENTRAL TO LIVER SIZE LARGE
12/19/85	8:48:42	0000337 388.0	CORNEAL OPACITY RIGHT EYE SLIGHT, NECROSIS TAIL SLIGHT, INTRAABDOMINAL MASS VENTRAL TO LIVER SIZE LARGE
1/16/86	10:34:00	0000337 356.0	CORNEAL OPACITY RIGHT EYE SLIGHT, NECROSIS TAIL SLIGHT, INTRAABDOMINAL MASS VENTRAL TO LIVER SIZE LARGE
1/30/86	7:26:48	0034567 325.0	CORNEAL OPACITY RIGHT EYE SLIGHT, NECROSIS TAIL SLIGHT, INTRAABDOMINAL MASS VENTRAL TO LIVER SIZE LARGE, EUTHANIZED

PAGE 670  
 DATE: 6/09/87  
 TIME: 14:40:13  
 EDS017 VAM11

**Appendix F (cont.): INDIVIDUAL ANIMAL HISTORIES**

STUDY: 0083009  
 COMPOUND: ISOBUTYL 2-CYANOACRYLATE  
 START DATE: 1/28/85

CARCINOGENICITY BIOASSAY OF ISOBUTYL 2-CYANO-  
 ACRYLATE (IBC) IN MALE AND FEMALE RATS.

ANIMAL HISTORY

Animal ID: 84D00104 Species: D Sex: MALE Group: 100 UL/ANM

DATE	TIME	OPERATOR	WEIGHT (GRAMS)	CLINICAL OBSERVATIONS
2/14/85	9:29:42	0000337	427.0	NORMAL
3/14/85	9:07:38	0078478	431.0	NORMAL
4/11/85	9:15:26	0000337	437.0	NORMAL
5/09/85	8:27:52	0000337	447.0	NORMAL
5/15/85	7:25:06	0000337		INTRAABDOMINAL MASS VENTRAL TO LIVER SIZE MEDIUM
6/06/85	9:41:38	0010186	459.0	INTRAABDOMINAL MASS VENTRAL TO LIVER SIZE MEDIUM
6/25/85	7:10:52	0000337		INTRAABDOMINAL MASS SIZE LARGE
7/02/85	8:09:44	0000337	458.0	STAIN BROWN NOSE MODERATE, INTRAABDOMINAL MASS VENTRAL TO LIVER SIZE LARGE
8/01/85	9:18:26	0001576	462.0	INTRAABDOMINAL MASS VENTRAL TO LIVER SIZE MEDIUM
8/29/85	8:21:32	0000337	468.0	INTRAABDOMINAL MASS VENTRAL TO LIVER SIZE LARGE
9/26/85	8:57:50	0000337	465.0	INTRAABDOMINAL MASS VENTRAL TO LIVER SIZE LARGE

**Appendix F (cont.): INDIVIDUAL ANIMAL HISTORIES**

PAGE 68  
 DATE: 6/09/87  
 TIME: 14:40:13  
 EDS017 V4M11

STUDY: 0083009  
 COMPOUND: ISOBUTYL 2-CYANOACRYLATE  
 START DATE: 1/28/85

CARCINOGENICITY BIOASSAY OF ISOBUTYL 2-CYANO-  
 ACRYLATE (IBC) IN MALE AND FEMALE RATS.

ANIMAL HISTORY

Animal ID: 84D00106 Species: D Sex: MALE Group: 10 UL/ANM

DATE	TIME	OPERATOR	WEIGHT (GRAMS)	CLINICAL OBSERVATIONS
2/14/85	9:30:04	0000337	381.0	SCAB RIGHT EAR MARKED
2/28/85	11:00:24	0084799		NORMAL
3/14/85	9:08:00	0078478	380.0	NORMAL
4/11/85	9:15:44	0000337	382.0	NORMAL
5/09/85	8:28:14	0000337	398.0	NORMAL
6/06/85	9:42:54	0010186	406.0	NORMAL
7/02/85	8:11:06	0000337	404.0	NORMAL
8/01/85	9:19:24	0001576	399.0	NORMAL
8/29/85	8:22:28	0000337	395.0	NORMAL
9/26/85	8:59:12	0000337	390.0	NORMAL
10/24/85	9:03:16	0034567	395.0	NORMAL
11/21/85	15:15:06	0002920	390.0	NORMAL
12/19/85	8:50:04	0000337	392.0	NORMAL
1/16/86	10:34:54	0000337	386.0	NORMAL
1/30/86	7:29:56	0034567	356.0	NORMAL / EUTHANIZED

PAGE 690  
 DATE: 6/09/87  
 TIME: 14:40:13  
 EDS017 V4M11

**Appendix F (cont.): INDIVIDUAL ANIMAL HISTORIES**

STUDY: 0083009  
 COMPOUND: ISOBUTYL 2-CYANOACRYLATE  
 START DATE: 1/28/85

CARCINOGENICITY BIOASSAY OF ISOBUTYL 2-CYANO-  
 ACRYLATE (IBC) IN MALE AND FEMALE RATS.

ANIMAL HISTORY

Animal ID: 84D00107 Species: D Sex: MALE Group: 100 UL/ANM

DATE	TIME	OPERATOR	WEIGHT (GRAMS)	CLINICAL OBSERVATIONS
2/14/85	9:33:18	0000337	385.0	CORNEAL OPACITY RIGHT EYE SLIGHT
3/14/85	9:10:06	0078478	390.0	CORNEAL OPACITY RIGHT EYE SLIGHT
4/11/85	9:17:10	0000337	401.0	CORNEAL OPACITY RIGHT EYE SLIGHT
5/09/85	8:28:34	0000337	407.0	CORNEAL OPACITY RIGHT EYE SLIGHT
6/06/85	9:43:36	0010186	407.0	CORNEAL OPACITY RIGHT EYE SLIGHT
6/12/85	7:36:40	0067831		CORNEAL OPACITY RIGHT EYE SLIGHT, MASS BELOW STERNUM
6/25/85	7:14:32	0000337		CORNEAL OPACITY RIGHT EYE SLIGHT
7/02/85	8:11:30	0000337	365.0	CORNEAL OPACITY RIGHT EYE SLIGHT
8/01/85	9:19:42	0001576	405.0	CORNEAL OPACITY RIGHT EYE SLIGHT
8/29/85	8:22:54	0000337	412.0	CORNEAL OPACITY RIGHT EYE SLIGHT
9/26/85	8:59:38	0000337	418.0	CORNEAL OPACITY RIGHT EYE SLIGHT
10/24/85	9:03:38	0034567	417.0	CORNEAL OPACITY RIGHT EYE SLIGHT, SCAB LEFT THORAX SLIGHT
11/06/85	8:55:44	0000337		CORNEAL OPACITY RIGHT EYE SLIGHT, SCAB LEFT THORAX SLIGHT, INTRAABDOMINAL MASS VENTRAL TO LIVER SIZE LARGE
11/21/85	15:15:26	0002920	410.0	CORNEAL OPACITY RIGHT EYE SLIGHT, SCAB LEFT THORAX SLIGHT, INTRAABDOMINAL MASS VENTRAL TO LIVER SIZE LARGE
12/19/85	8:50:22	0000337	413.0	CORNEAL OPACITY RIGHT EYE SLIGHT, SCAB LEFT THORAX SLIGHT, INTRAABDOMINAL MASS VENTRAL TO LIVER SIZE LARGE
1/16/86	10:35:16	0000337	418.0	CORNEAL OPACITY RIGHT EYE SLIGHT, SCAB LEFT THORAX SLIGHT, INTRAABDOMINAL MASS VENTRAL TO LIVER SIZE LARGE
1/30/86	7:31:06	0034567	396.0	CORNEAL OPACITY RIGHT EYE SLIGHT, SCAB LEFT THORAX SLIGHT, INTRAABDOMINAL MASS VENTRAL TO LIVER SIZE LARGE, EUTHANIZED



**Appendix F (cont.): INDIVIDUAL ANIMAL HISTORIES**

PAGE 70  
 DATE: 6/09/87  
 TIME: 14:40:13  
 EDS017 V4M11

STUDY: 0083009  
 COMPOUND: ISOBUTYL 2-CYANOACRYLATE  
 START DATE: 1/28/85

CARCINOGENICITY BIOASSAY OF ISOBUTYL 2-CYANO-  
 ACRYLATE (IBC) IN MALE AND FEMALE RATS.

ANIMAL HISTORY

Animal ID: 84D00108 Species: D Sex: MALE Group: 100 UL/ANM

DATE	TIME	OPERATOR	WEIGHT (GRAMS)	CLINICAL OBSERVATIONS
2/14/85	9:33:46	0000337	359.0	NORMAL
3/14/85	9:10:44	0078478	369.0	NORMAL
4/11/85	9:18:16	0000337	359.0	NORMAL
5/09/85	8:29:20	0000337	370.0	NORMAL
5/23/85	7:02:56	0000337		INTRABDOMINAL MASS VENTRAL TO LIVER SIZE MEDIUM
6/06/85	9:44:38	0010186	373.0	INTRABDOMINAL MASS VENTRAL TO LIVER SIZE MEDIUM
7/02/85	8:12:00	0000337	368.0	INTRABDOMINAL MASS VENTRAL TO LIVER SIZE MEDIUM
7/18/85	10:07:02	0010186		SWOLLEN MAXILLA (UPPER JAW) LEFT SIDE 15MM X 10MM
8/01/85	9:20:00	0001576	376.0	SWOLLEN MAXILLA (UPPER JAW) LEFT SIDE 15MM X 10MM, INTRABDOMINAL MASS VENTRAL TO LIVER SIZE MEDIUM
8/29/85	8:24:24	0000337	380.0	SWOLLEN MAXILLA LEFT SIDE, INTRABDOMINAL MASS VENTRAL TO LIVER SIZE MEDIUM
8/30/85	11:31:32	0000337		* No observations recorded.

**Appendix F (cont.): INDIVIDUAL ANIMAL HISTORIES**

STUDY: 0083009  
COMPOUND: ISOBUTYL 2-CYANOACRYLATE  
START DATE: 1/28/85  
CARCINOGENICITY BIOASSAY OF ISOBUTYL 2-CYANO-  
ACRYLATE (IBC) IN MALE AND FEMALE RATS.

**ANIMAL HISTORY**

Animal ID: 84D00109 Species: D Sex: MALE Group: 100 UL/ANN

DATE	TIME	OPERATOR	WEIGHT (GRAMS)	CLINICAL OBSERVATIONS
2/14/85	9:34:08	0000337	367.0	NORMAL
3/14/85	9:11:48	0078478	370.0	NORMAL
4/11/85	9:18:54	0000337	372.0	CORNEAL OPACITY BOTH EYE SLIGHT
5/09/85	8:29:54	0000337	376.0	CORNEAL OPACITY BOTH EYE SLIGHT
5/15/85	7:32:50	0000337		CORNEAL OPACITY BOTH EYE SLIGHT, INTRABDOMINAL MASS VENTRAL TO LIVER SIZE LARGE
5/19/85	9:07:42	0000337		CORNEAL OPACITY BOTH EYE SLIGHT, IN/CTIVE MARKED, INCREASED RESPIRATION RATE MARKED, CHROMODACRYORRHEA MARKED, DECREASED TEMPERATURE MARKED, INTRABDOMINAL MASS VENTRAL TO LIVER SIZE LARGE

## Appendix F (cont.): INDIVIDUAL ANIMAL HISTORIES

STUDY: 0083009  
 COMPOUND: ISOBUTYL 2-CYANOACRYLATE  
 START DATE: 1/28/85

CARCINOGENICITY BIOASSAY OF ISOBUTYL 2-CYANO-  
 ACRYLATE (IBC) IN MALE AND FEMALE RATS.

PAGE 72  
 DATE: 6/09/87  
 TIME: 14:40:13  
 EDS017 V4M11

## ANIMAL HISTORY

Animal ID: 84D00110 Species: D Sex: MALE Group: CONTROLS

DATE	TIME	OPERATOR	WEIGHT (GRAMS)	CLINICAL OBSERVATIONS
2/14/85	9:34:26	0000337	362.0	NORMAL
3/14/85	9:12:14	0078478	359.0	NORMAL
4/11/85	9:19:32	0000337	371.0	CORNEAL OPACITY LEFT EYE SLIGHT
5/09/85	8:30:20	0000337	377.0	CORNEAL OPACITY LEFT EYE SLIGHT
6/06/85	9:45:34	0010186	376.0	CORNEAL OPACITY LEFT EYE SLIGHT
7/02/85	8:12:52	0000337	388.0	CORNEAL OPACITY LEFT EYE SLIGHT
8/01/85	9:22:06	0001576	388.0	CORNEAL OPACITY LEFT EYE SLIGHT
8/29/85	8:25:56	0000337	392.0	CORNEAL OPACITY LEFT EYE SLIGHT
9/26/85	9:02:54	0000337	381.0	CORNEAL OPACITY LEFT EYE SLIGHT
10/24/85	9:04:36	0034567	384.0	CORNEAL OPACITY LEFT EYE SLIGHT
11/21/85	15:17:18	0002920	376.0	CORNEAL OPACITY LEFT EYE SLIGHT
12/19/85	8:51:36	0000337	376.0	CORNEAL OPACITY LEFT EYE SLIGHT
1/16/86	10:36:16	0000337	378.0	CORNEAL OPACITY LEFT EYE SLIGHT
1/30/86	7:33:40	0034567	354.0	CORNEAL OPACITY LEFT EYE SLIGHT, EUTHANIZED

PAGE 73  
 DATE: 6/09/87  
 TIME: 14:40:13  
 EDS017 V4M11

**Appendix F (cont.): INDIVIDUAL ANIMAL HISTORIES**

STUDY: 0083009 ISOBUTYL 2-CYANOACRYLATE CARCINOGENICITY BIOASSAY OF ISOBUTYL 2-CYANO-  
 COMPOUND: ISOBUTYL 2-CYANOACRYLATE ACRYLATE (IBC) IN MALE AND FEMALE RATS.  
 START DATE: 1/28/85

ANIMAL HISTORY

Animal ID: 84D00111 Species: D Sex: MALE Group: 10 UL/ANM

DATE	TIME	OPERATOR	WEIGHT (GRAMS)	CLINICAL OBSERVATIONS
2/14/85	9:34:48	0000337	403.0	NORMAL
3/14/85	9:13:18	0078478	409.0	NORMAL
4/11/85	9:20:00	0000337	412.0	NORMAL
5/09/85	8:30:48	0000337	426.0	NORMAL
6/05/85	7:35:08	0000337		INTRABDOMINAL MASS VENTRAL TO LIVER SIZE MEDIUM
6/06/85	9:46:00	0010186	428.0	INTRABDOMINAL MASS VENTRAL TO LIVER SIZE MEDIUM
7/02/85	8:13:32	0000337	430.0	INTRABDOMINAL MASS VENTRAL TO LIVER SIZE MEDIUM
8/01/85	9:22:28	0001576	434.0	INTRABDOMINAL MASS VENTRAL TO LIVER SIZE MEDIUM
8/29/85	8:26:30	0000337	433.0	SINTRAABDOMINAL MASS VENTRAL TO LIVER SIZE MEDIUM
9/26/85	9:03:24	0000337	429.0	INTRABDOMINAL MASS VENTRAL TO LIVER SIZE MEDIUM
10/24/85	9:54:22	0034567	430.0	INTRABDOMINAL MASS VENTRAL TO LIVER SIZE MEDIUM
11/21/85	15:17:54	0002920	427.0	INTRABDOMINAL MASS VENTRAL TO LIVER SIZE MEDIUM
12/19/85	8:52:00	0000337	440.0	INTRABDOMINAL MASS VENTRAL TO LIVER SIZE MEDIUM
1/16/86	10:36:32	0000337	437.0	INTRABDOMINAL MASS VENTRAL TO LIVER SIZE MEDIUM
1/30/86	7:35:00	0034567	397.0	INTRABDOMINAL MASS VENTRAL TO LIVER SIZE MEDIUM, EUTHANIZED

**Appendix F (cont.): INDIVIDUAL ANIMAL HISTORIES**

PAGE 74  
 DATE: 6/09/87  
 TIME: 14:40:13  
 EDS017 V4M11

STUDY: 0083009  
 COMPOUND: ISOBUTYL 2-CYANOACRYLATE  
 START DATE: 1/28/85

CARCINOGENICITY BIOASSAY OF ISOBUTYL 2-CYANO-  
 ACRYLATE (IBC) IN MALE AND FEMALE RATS.

ANIMAL HISTORY

Animal ID: 84D00112 Species: D Sex: MALE Group: CONTROLS

DATE	TIME	OPERATOR	WEIGHT (GRAMS)	CLINICAL OBSERVATIONS
2/14/85	9:35:18	0000337	395.0	SCAB RIGHT EAR MODERATE
2/28/85	11:01:58	0084799		NORMAL
3/14/85	9:13:36	0078478	393.0	NORMAL
4/11/85	9:20:52	0000337	403.0	NORMAL
5/09/85	8:31:08	0000337	414.0	NORMAL
6/06/85	9:47:06	0010186	417.0	NORMAL
7/02/85	8:14:12	0000337	407.0	NORMAL
8/01/85	9:23:00	0001576	403.0	NORMAL
8/29/85	8:27:36	0000337	401.0	NORMAL
9/26/85	9:04:12	0000337	401.0	NORMAL
10/24/85	9:55:10	0034567	407.0	NORMAL
11/21/85	15:19:36	0002920	397.0	NORMAL
12/19/85	8:52:46	0000337	394.0	NORMAL
1/16/86	10:38:22	0000337	384.0	NORMAL
1/30/86	7:37:10	0034567	362.0	NORMAL / EUTHANIZED

PAGE 75 ct  
 DATE: 6/09/87  
 TIME: 14:40:13  
 EDS017 V4M11

**Appendix F (cont.): INDIVIDUAL ANIMAL HISTORIES**

STUDY: 0083009 ISOBUTYL 2-CYANOACRYLATE CARCINOGENICITY BIOASSAY OF ISOBUTYL 2-CYANO-  
 COMPOUND: ISOBUTYL 2-CYANOACRYLATE ACRYLATE (IBC) IN MALE AND FEMALE RATS.  
 START DATE: 1/28/85

**ANIMAL HISTORY**

Animal ID: 84D00113 Species: D Sex: MALE Group: 10 UL/ANM

DATE	TIME	OPERATOR	WEIGHT (GRAMS)	CLINICAL OBSERVATIONS
2/14/85	9:36:00	0000337	405.0	NORMAL
3/14/85	9:14:32	0078478	391.0	NORMAL
4/11/85	9:21:26	0000337	394.0	NORMAL
5/09/85	8:31:28	0000337	402.0	NORMAL
6/06/85	9:47:34	0010186	414.0	NORMAL
7/02/85	8:14:32	0000337	412.0	NORMAL
8/01/85	9:23:26	0001576	403.0	NORMAL
8/29/85	9:16:50	0000337	405.0	INTRABDOMINAL MASS VENTRAL TO LIVER SIZE MEDIUM
9/26/85	9:04:34	0000337	411.0	NO MASS PALPABLE
10/16/85	9:14:02	0000337		INTRABDOMINAL MASS VENTRAL TO LIVER SIZE MEDIUM
10/24/85	9:55:26	0034567	414.0	NORMAL
11/21/85	15:20:20	0002920	403.0	INTRABDOMINAL MASS VENTRAL TO LIVER SIZE SMALL
12/19/85	8:53:10	0000337	413.0	INTRABDOMINAL MASS VENTRAL TO LIVER SIZE SMALL
1/16/86	10:38:40	0000337	391.0	INTRABDOMINAL MASS VENTRAL TO LIVER SIZE SMALL
1/30/86	7:39:02	0034567	358.0	INTRABDOMINAL MASS VENTRAL TO LIVER SIZE MEDIUM, STAIN YELLOW PERIANAL SLIGHT, STAIN BROWN NOSE SLIGHT, EUTHANIZED

## Appendix F (cont.): INDIVIDUAL ANIMAL HISTORIES

PAGE 76  
DATE: 6/09/87  
TIME: 14:40:13  
EDS017 V4M11

STUDY: 0083009  
COMPOUND: ISOBUTYL 2-CYANOACRYLATE  
START DATE: 1/28/85

CARCINOGENICITY BIOASSAY OF ISOBUTYL 2-CYANO-  
ACRYLATE (IBC) IN MALE AND FEMALE RATS.

## ANIMAL HISTORY

Animal ID: 84D00114 Species: D Sex: MALE Group: 100 UL/ANM

DATE	TIME	OPERATOR	WEIGHT (GRAMS)	CLINICAL OBSERVATIONS
2/14/85	9:36:26	0000337	359.0	CORNEAL OPACITY LEFT EYE SLIGHT
3/05/85	7:55:10	0000337		CORNEAL OPACITY LEFT EYE SLIGHT, SCAB RIGHT EAR SLIGHT
3/14/85	9:15:08	0078478	361.0	CORNEAL OPACITY LEFT EYE SLIGHT, SCAB RIGHT EAR SLIGHT
4/11/85	9:21:58	0000337	374.0	CORNEAL OPACITY LEFT EYE SLIGHT, SCAB RIGHT EAR SLIGHT
5/02/85	6:58:24	0000337		CORNEAL OPACITY LEFT EYE SLIGHT, SCAB RIGHT EAR SLIGHT, STAIN BROWN NOSE SLIGHT
5/07/85	7:34:06	0084799		CORNEAL OPACITY LEFT EYE SLIGHT, SCAB RIGHT EAR SLIGHT
5/09/85	8:31:50	0000337	383.0	CORNEAL OPACITY LEFT EYE SLIGHT, SCAB RIGHT EAR SLIGHT
6/06/85	9:47:58	0010186	417.0	CORNEAL OPACITY LEFT EYE SLIGHT
7/02/85	8:15:02	0000337	397.0	CORNEAL OPACITY LEFT EYE SLIGHT
8/01/85	9:23:46	0001576	400.0	CORNEAL OPACITY LEFT EYE SLIGHT
8/29/85	9:20:42	0000337	403.0	CORNEAL OPACITY LEFT EYE SLIGHT, STAIN BROWN NOSE SLIGHT, INTRAABDOMINAL MASS VENTRAL TO LIVER SIZE MEDIUM
9/26/85	9:06:32	0000337	394.0	CORNEAL OPACITY LEFT EYE SLIGHT, INTRAABDOMINAL MASS VENTRAL TO LIVER SIZE MEDIUM
10/16/85	9:15:32	0000337		CORNEAL OPACITY LEFT EYE SLIGHT, INTRAABDOMINAL MASS VENTRAL TO LIVER SIZE MEDIUM
10/24/85	9:56:42	0034567	383.0	CORNEAL OPACITY LEFT EYE SLIGHT, INTRAABDOMINAL MASS VENTRAL TO LIVER SIZE LARGE
11/21/85	15:22:00	0002920	356.0	CORNEAL OPACITY LEFT EYE SLIGHT, INTRAABDOMINAL MASS VENTRAL TO LIVER SIZE LARGE
12/19/85	9:32:08	0000337	329.0	CORNEAL OPACITY LEFT EYE SLIGHT, INTRAABDOMINAL MASS VENTRAL TO LIVER SIZE LARGE
1/03/86	9:52:58	0000337		CORNEAL OPACITY LEFT EYE SLIGHT, INTRAABDOMINAL MASS VENTRAL TO LIVER SIZE LARGE, PALLOR MODERATE, EMACIATED MARKED

PAGE 77  
 DATE: 6/09/87  
 TIME: 14:40:13  
 EDS017 V4M11

**Appendix F (cont.): INDIVIDUAL ANIMAL HISTORIES**

STUDY: 0083009 CARCINOGENICITY BIOASSAY OF ISOBUTYL 2-CYANO-  
 COMPOUND: ISOBUTYL 2-CYANOACRYLATE ACRYLATE (IBC) IN MALE AND FEMALE RATS.  
 START DATE: 1/28/85

ANIMAL HISTORY

Animal ID: 84D00115 Species: D Sex: MALE Group: 100 UL/ANM

DATE	TIME	OPERATOR	WEIGHT (GRAMS)	CLINICAL OBSERVATIONS
2/14/85	9:36:46	0000337	401.0	CORNEAL OPACITY BOTH EYE SLIGHT
3/14/85	9:17:00	0078478	407.0	CORNEAL OPACITY BOTH EYE SLIGHT
4/11/85	9:23:30	0000337	419.0	CORNEAL OPACITY BOTH EYE SLIGHT
5/09/85	8:32:30	0000337	426.0	CORNEAL OPACITY BOTH EYE SLIGHT
6/06/85	9:48:42	0010186	429.0	CORNEAL OPACITY BOTH EYE SLIGHT
7/02/85	8:15:32	0000337	429.0	CORNEAL OPACITY BOTH EYE SLIGHT
8/01/85	9:24:34	0001576	422.0	CORNEAL OPACITY BOTH EYE SLIGHT
8/29/85	9:24:20	0000337	417.0	CORNEAL OPACITY BOTH EYE SLIGHT
9/26/85	9:07:40	0000337	422.0	CORNEAL OPACITY BOTH EYE SLIGHT
10/24/85	9:57:40	0034567	424.0	CORNEAL OPACITY BOTH EYE SLIGHT
11/07/85	9:45:52	0000337		CORNEAL OPACITY BOTH EYE SLIGHT, INTRAABDOMINAL MASS VENTRAL TO LIVER SIZE MEDIUM
11/21/85	15:41:00	0084799	405.0	CORNEAL OPACITY BOTH EYE SLIGHT, INTRAABDOMINAL MASS VENTRAL TO LIVER SIZE MEDIUM
12/19/85	9:33:18	0000337	412.0	CORNEAL OPACITY BOTH EYE SLIGHT, INTRAABDOMINAL MASS VENTRAL TO LIVER SIZE MEDIUM
1/16/86	10:39:38	0000337	390.0	CORNEAL OPACITY BOTH EYE SLIGHT, INTRAABDOMINAL MASS VENTRAL TO LIVER SIZE LARGE
1/24/86	9:08:46	0084799		INTRAABDOMINAL MASS VENTRAL TO LIVER SIZE LARGE, STAIN YELLOW PERIANAL MARKED, STAIN YELLOW NOSE MARKED, STAIN YELLOW MOUTH MARKED



**Appendix F (cont.): INDIVIDUAL ANIMAL HISTORIES**

STUDY: 0083009  
 COMPOUND: ISOBUTYL 2-CYANOACRYLATE  
 START DATE: 1/28/85

CARCINOGENICITY BIOASSAY OF ISOBUTYL 2-CYANO-  
 ACRYLATE (IBC) IN MALE AND FEMALE RATS.

PAGE 78  
 DATE: 6/09/87  
 TIME: 14:40:13  
 EDS017 V4M11

ANIMAL HISTORY

Animal ID: 84D00117 Species: D Sex: MALE Group: CONTROLS

DATE	TIME	OPERATOR	WEIGHT (GRAMS)	CLINICAL OBSERVATIONS
2/14/85	9:37:22	0000337	441.0	NORMAL
3/14/85	9:17:36	0078478	440.0	NORMAL
4/11/85	9:24:38	0000337	450.0	NORMAL
5/09/85	8:33:08	0000337	458.0	NORMAL
6/06/85	9:49:18	0010186	460.0	NORMAL
7/02/85	8:16:10	0000337	463.0	NORMAL
8/01/85	9:25:08	0001576	457.0	NORMAL
8/29/85	9:25:18	0000337	456.0	NORMAL
9/26/85	9:08:00	0000337	462.0	NORMAL
10/24/85	9:58:08	0034567	466.0	NORMAL
11/21/85	15:44:06	0084799	460.0	NORMAL
12/19/85	9:34:04	0000337	459.0	NORMAL
1/14/86	10:44:08	0000337		MORIBUND

PAGE 79 0  
 DATE: 6/09/87  
 TIME: 14:40:13  
 EDS017 V4M11

**Appendix F (cont.): INDIVIDUAL ANIMAL HISTORIES**

STUDY: 0083009  
 COMPOUND: ISOBUTYL 2-CYANOACRYLATE  
 START DATE: 1/28/85

Animal ID: 84D00118 Species: D Sex: MALE Group: 10 UL/ANM

**ANIMAL HISTORY**

CARCINOGENICITY BIOASSAY OF ISOBUTYL 2-CYANO-  
 ACRYLATE (IBC) IN MALE AND FEMALE RATS.

DATE	TIME	OPERATOR	WEIGHT (GRAMS)	CLINICAL OBSERVATIONS
2/14/85	9:37:40	0000337	443.0	NORMAL
3/14/85	9:17:52	0078478	444.0	NORMAL
4/11/85	9:25:16	0000337	427.0	NORMAL
5/09/85	8:33:46	0000337	458.0	NORMAL
6/06/85	9:49:50	0010186	452.0	NORMAL
7/02/85	8:16:34	0000337	428.0	NORMAL
8/01/85	9:25:28	0001576	456.0	NORMAL
8/29/85	9:25:56	0000337	464.0	NORMAL
9/26/85	9:08:26	0000337	467.0	NORMAL
10/24/85	9:58:26	0034567	477.0	NORMAL
11/21/85	15:44:46	0084799	465.0	NORMAL
12/19/85	9:34:34	0000337	456.0	NORMAL
1/16/86	10:40:42	0000337	403.0	INTRAABDOMINAL MASS VENTRAL TO LIVER SIZE MEDIUM
1/30/86	8:04:24	0034567	352.0	INTRAABDOMINAL MASS VENTRAL TO LIVER SIZE MEDIUM, EMACIATED MARKED, PALLOR MODERATE, EUTHANIZED

## Appendix F (cont.): INDIVIDUAL ANIMAL HISTORIES

PAGE 80  
DATE: 6/09/87  
TIME: 14:40:13  
EDS017 V4M11

STUDY: 0083009  
COMPOUND: ISOBUTYL 2-CYANOACRYLATE  
START DATE: 1/28/85

CARCINOGENICITY BIOASSAY OF ISOBUTYL 2-CYANO-  
ACRYLATE (IBC) IN MALE AND FEMALE RATS.

## ANIMAL HISTORY

Animal ID: 84D00119 Species: D Sex: MALE Group: CONTROLS

DATE	TIME	OPERATOR	WEIGHT (GRAMS)	CLINICAL OBSERVATIONS
2/14/85	9:38:06	0000337	396.0	NORMAL
3/14/85	9:18:42	0078478	400.0	NORMAL
4/11/85	9:25:48	0000337	400.0	NORMAL
5/09/85	8:34:06	0000337	406.0	NORMAL
6/06/85	9:50:18	0010186	415.0	NORMAL
7/02/85	8:16:56	0000337	420.0	NORMAL
8/01/85	9:25:52	0001576	413.0	NORMAL
8/29/85	9:26:42	0000337	425.0	NORMAL
9/26/85	9:08:52	0000337	433.0	NORMAL
10/24/85	9:58:44	0034567	437.0	SKIN LESION MIDLINE OF THE BACK SMALL
11/21/85	15:45:16	0084799	433.0	SUBCUTANEOUS CYST DORSAL MIDLINE SMALL
12/19/85	9:34:52	0000337	433.0	PUSTULE SUBCUTANEOUS MIDLINE DORSAL SLIGHT
1/16/86	10:42:06	0000337	413.0	PUSTULE SUBCUTANEOUS MIDLINE DORSAL SLIGHT
1/30/86	8:06:16	0034567	371.0	NORMAL / EUTHANIZED

PAGE 81 0  
 DATE: 6/09/87  
 TIME: 14:40:13  
 EDS017 VAM11

**Appendix F (cont.): INDIVIDUAL ANIMAL HISTORIES**

STUDY: 0083009 ISOBUTYL 2-CYANOACRYLATE  
 COMPOUND: ISOBUTYL 2-CYANOACRYLATE  
 START DATE: 1/28/85  
 CARCINOGENICITY BIOASSAY OF ISOBUTYL 2-CYANO-  
 ACRYLATE (IBC) IN MALE AND FEMALE RATS.

ANIMAL HISTORY

Animal ID: 84D00120 Species: D Sex: MALE Group: CONTROLS

DATE	TIME	OPERATOR	WEIGHT (GRAMS)	CLINICAL OBSERVATIONS
2/14/85	9:38:24	0000337	409.0	NORMAL
3/14/85	9:19:14	0078478	419.0	NORMAL
4/11/85	9:26:20	0000337	424.0	NORMAL
5/09/85	8:34:30	0000337	428.0	NORMAL
6/06/85	9:50:46	0010186	431.0	NORMAL
7/02/85	8:17:22	0000337	403.0	NORMAL
8/01/85	9:26:08	0001576	432.0	NORMAL
8/29/85	9:27:28	0000337	442.0	NORMAL
9/26/85	9:09:12	0000337	442.0	OPAQUE LENS RIGHT EYE MODERATE, INTRAABDOMINAL MASS VENTRAL TO LIVER SIZE MEDIUM
10/16/85	9:21:34	0000337		CORNEAL OPACITY RIGHT EYE MODERATE, SUBCUTANEOUS MASS PERI HUMERUS RIGHT SIDE SIZE MEDIUM
10/24/85	10:00:20	0034567	439.0	CORNEAL OPACITY RIGHT EYE MODERATE, SUBCUTANEOUS MASS PERI HUMERUS RIGHT SIDE SIZE MEDIUM
11/08/85	8:03:30	0000337		CORNEAL OPACITY RIGHT EYE MODERATE, PERI HUMERUS MASS RIGHT SIDE SIZE MEDIUM
11/21/85	15:47:32	0084799	398.0	CORNEAL OPACITY RIGHT EYE MARKED, SUBCUTANEOUS MASS PERI HUMERUS SIZE MEDIUM
12/19/85	9:36:18	0000337	378.0	OPAQUE LENS RIGHT EYE MARKED, SUBCUTANEOUS MASS RIGHT HUMERUS SIZE LARGE, INTRAABDOMINAL MASS SOFT SIZE MEDIUM
1/14/86	10:46:22	0000337		MORIBUND

## Appendix F (cont.): INDIVIDUAL ANIMAL HISTORIES

PAGE 82  
DATE: 6/09/87  
TIME: 14:40:13  
EDS017 V4M11

STUDY: 0083009  
COMPOUND: ISOBUTYL 2-CYANOACRYLATE  
START DATE: 1/28/85

CARCINOGENICITY BIOASSAY OF ISOBUTYL 2-CYANO-  
ACRYLATE (IBC) IN MALE AND FEMALE RATS.

## ANIMAL HISTORY

Animal ID: 84D00121 Species: D Sex: MALE Group: CONTROLS

DATE	TIME	OPERATOR	WEIGHT (GRAMS)	CLINICAL OBSERVATIONS
2/14/85	9:38:40	0000337	404.0	NORMAL
3/14/85	9:19:34	0078478	409.0	NORMAL
4/11/85	9:26:52	0000337	411.0	NORMAL
5/09/85	8:34:50	0000337	424.0	NORMAL
6/06/85	9:51:12	0010186	431.0	NORMAL
7/02/85	8:17:44	0000337	433.0	NORMAL
8/01/85	9:26:30	0001576	420.0	NORMAL
8/29/85	9:28:24	0000337	422.0	NORMAL
9/26/85	9:11:18	0000337	418.0	NORMAL
10/22/85	8:35:12	0072808		OPACITY RIGHT EYE MODERATE
10/24/85	10:03:04	0034567	417.0	OPAQUE LENS LEFT EYE MARKED
11/21/85	15:49:40	0084799	401.0	INTRABDOMINAL MASS VENTRAL TO LIVER SIZE MEDIUM, OPAQUE LENS LEFT EYE MARKED
12/19/85	9:39:12	0000337	400.0	PROLAPSED LENS LEFT EYE MARKED, OPAQUE LENS LEFT EYE MARKED
1/16/86	10:43:00	0000337	376.0	OPAQUE LENS LEFT EYE MARKED
1/30/86	8:08:12	0034567	345.0	OPAQUE LENS LEFT EYE MARKED, EUTHANIZED

PAGE 83  
 DATE: 6/09/87  
 TIME: 14:40:13  
 EDS017 V4M11

**Appendix F (cont.): INDIVIDUAL ANIMAL HISTORIES**

CARCINOGENICITY BIOASSAY OF ISOBTUTYL 2-CYANO-  
 ACRYLATE (IBC) IN MALE AND FEMALE RATS.

ANIMAL HISTORY

STUDY: 0083009  
 COMPOUND: ISOBTUTYL 2-CYANOACRYLATE  
 START DATE: 1/28/85

Animal ID: 84D00122 Species: D Sex: MALE Group: 10 UL/ANM

DATE	TIME	OPERATOR	WEIGHT (GRAMS)	CLINICAL OBSERVATIONS
2/14/85	9:39:10	0000337	362.0	NORMAL
3/14/85	9:20:02	0078478	367.0	NORMAL
4/11/85	9:27:28	0000337	372.0	NORMAL
5/09/85	8:35:08	0000337	378.0	NORMAL
6/06/85	9:51:46	0010186	379.0	NORMAL
7/02/85	8:18:06	0000337	389.0	NORMAL
8/01/85	9:26:42	0001576	381.0	NORMAL
8/29/85	9:29:08	0000337	376.0	NORMAL
9/26/85	9:11:46	0000337	366.0	NORMAL
10/24/85	10:04:28	0034567	362.0	NORMAL
11/21/85	15:52:18	0084799	354.0	NORMAL
12/19/85	9:41:10	0000337	356.0	NORMAL
1/16/86	10:43:58	0000337	351.0	NORMAL
1/30/86	8:10:48	0034567	326.0	NORMAL / EUTHANIZED

**Appendix F (cont.): INDIVIDUAL ANIMAL HISTORIES**

PAGE 84  
 DATE: 6/09/87  
 TIME: 14:40:13  
 EDS017 V4M11

STUDY: 0083009  
 COMPOUND: ISOBUTYL 2-CYANOACRYLATE  
 START DATE: 1/28/85

CARCINOGENICITY BIOASSAY OF ISOBUTYL 2-CYANO-  
 ACRYLATE (IBC) IN MALE AND FEMALE RATS.

ANIMAL HISTORY

Animal ID: 84D00123 Species: D Sex: MALE Group: 10 UL/ANM

DATE	TIME	OPERATOR	WEIGHT (GRAMS)	CLINICAL OBSERVATIONS
2/14/85	9:39:32	0000337	399.0	SCAB RIGHT EAR SLIGHT
2/28/85	11:02:22	0084799		NORMAL
3/14/85	9:20:38	0078478	409.0	NORMAL
4/11/85	9:28:02	0000337	402.0	NORMAL
5/09/85	8:35:32	0000337	405.0	NORMAL
6/06/85	9:52:26	0010186	411.0	NORMAL
7/02/85	8:18:30	0000337	416.0	NORMAL
8/01/85	9:27:00	0001576	411.0	NORMAL
8/29/85	9:30:14	0000337	417.0	NORMAL
9/26/85	9:12:08	0000337	422.0	AGGRESSIVE MARKED
10/02/85	8:47:50	0000337		NORMAL
10/24/85	10:04:50	0034567	420.0	NORMAL
11/21/85	15:52:48	0084799	403.0	NORMAL
12/19/85	9:41:36	0000337	407.0	NORMAL
1/16/86	10:44:22	0000337	406.0	NORMAL
1/30/86	8:12:14	0034567	379.0	NORMAL / EUTHANIZED

**Appendix F (cont.): INDIVIDUAL ANIMAL HISTORIES**

STUDY: 0083009  
 COMPOUND: ISOBUTYL 2-CYANOACRYLATE  
 START DATE: 1/28/85  
 CARCINOGENICITY BIOASSAY OF ISOBUTYL 2-CYANO-  
 ACRYLATE (IBC) IN MALE AND FEMALE RATS.

ANIMAL HISTORY

Animal ID: 84D00124 Species: D Sex: MALE Group: CONTROLS

DATE	TIME	OPERATOR	WEIGHT (GRAMS)	CLINICAL OBSERVATIONS
2/14/85	9:40:28	0000337	375.0	OPAQUE LENS LEFT EYE MARKED, LEFT EYE SMALLER THAN NORMAL
3/14/85	9:25:58	0078478	377.0	OPAQUE LENS LEFT EYE MARKED, LEFT EYE SMALLER THAN NORMAL
4/11/85	9:28:42	0084799	383.0	PROLAPSED LENS LEFT EYE MARKED, OPAQUE LENS LEFT EYE MARKED
5/09/85	8:35:52	0000337	391.0	PROLAPSED LENS LEFT EYE MARKED, OPAQUE LENS LEFT EYE MARKED
6/06/85	9:53:06	0010186	393.0	PROLAPSED LENS LEFT EYE MARKED, OPAQUE LENS LEFT EYE MARKED, MICROPTHALMIA LEFT EYE MARKED
7/02/85	8:19:02	0000337	401.0	PROLAPSED LENS LEFT EYE MARKED, OPAQUE LENS LEFT EYE MARKED, MICROPTHALMIA LEFT EYE MARKED
7/18/85	10:15:00	0010186		INTRAABDOMINAL MASS MIDDLE ABDOMEN 20MM X 10MM OVAL
8/01/85	9:27:20	0001576	401.0	OPAQUE LEFT EYE MARKED, MICROPTHALMIA LEFT EYE MARKED, INTRAABDOMINAL MASS MIDDLE ABDOMEN 20MM X 10MM OVAL NEAR THE SPLEEN
8/29/85	9:31:22	0000337	396.0	OPACITY LEFT EYE MARKED, MICROPTHALMIA LEFT EYE MARKED, INTRAABDOMINAL MASS NEAR THE SPLEEN 20MM X 10MM MEDIUM
9/26/85	9:12:52	0000337	388.0	OPAQUE LENS LEFT EYE MARKED, MICROPTHALMIA LEFT EYE MODERATE, INTRAABDOMINAL MASS SPLENIC SIZE LARGE
10/11/85	8:09:42	0000337		LIVE ANIMAL SENT TO NECROPSY 26 SEP 1985 NOT REMOVED FROM CENSUS AT THAT TIME



## Appendix F (cont.): INDIVIDUAL ANIMAL HISTORIES

PAGE 86  
DATE: 6/09/87  
TIME: 14:40:13  
EDS017 V4M11

STUDY: 0083009  
COMPOUND: ISOBUTYL 2-CYANOACRYLATE  
START DATE: 1/28/85

CARCINOGENICITY BIOASSAY OF ISOBUTYL 2-CYANO-  
ACRYLATE (IBC) IN MALE AND FEMALE RATS.

## ANIMAL HISTORY

Animal ID: 84D00125 Species: D Sex: MALE Group: CONTROLS

DATE	TIME	OPERATOR	WEIGHT (GRAMS)	CLINICAL OBSERVATIONS
2/14/85	9:43:12	0000337	378.0	NORMAL
3/14/85	9:27:08	0078478	393.0	NORMAL
4/11/85	9:30:02	0000337	393.0	NORMAL
5/09/85	8:37:20	0000337	401.0	NORMAL
6/06/85	9:54:46	0010186	408.0	NORMAL
7/02/85	8:20:26	0000337	404.0	NORMAL
8/01/85	9:30:18	0001576	396.0	NORMAL
8/29/85	9:38:44	0000337	401.0	NORMAL
9/26/85	9:16:46	0000337	401.0	NORMAL
10/24/85	10:05:16	0034567	404.0	NORMAL
11/21/85	15:53:18	0084799	387.0	NORMAL
12/19/85	9:41:54	0000337	383.0	NORMAL
1/16/86	10:45:00	0000337	361.0	NORMAL
1/30/86	8:13:26	0034567	327.0	NORMAL / EUTHANIZED

PAGE 87  
DATE: 6/09/87  
TIME: 14:40:13  
EDS017 V4M11

**Appendix F (cont.): INDIVIDUAL ANIMAL HISTORIES**

STUDY: 0083009  
COMPOUND: ISOBUTYL 2-CYANOACRYLATE  
START DATE: 1/28/85  
CARCINOGENICITY BIOASSAY OF ISOBUTYL 2-CYANO-  
ACRYLATE (IBC) IN MALE AND FEMALE RATS.

ANIMAL HISTORY

Animal ID: 84D00127 Species: D Sex: MALE Group: CONTROLS

DATE	TIME	OPERATOR	WEIGHT (GRAMS)	CLINICAL OBSERVATIONS
2/14/85	9:43:28	0000337	395.0	NORMAL
3/14/85	9:27:36	0078478	394.0	NORMAL
4/11/85	9:3:14	0000337	410.0	NORMAL
5/09/85	8:37:36	0000337	410.0	NORMAL
6/06/85	9:55:10	0010186	416.0	NORMAL
7/02/85	8:20:56	0000337	418.0	NORMAL
8/01/85	9:30:30	0001576	425.0	NORMAL
8/29/85	9:39:22	0000337	424.0	NORMAL
9/26/85	9:17:00	0000337	425.0	NORMAL
10/24/85	10:05:40	0034567	430.0	NORMAL
11/21/85	15:53:40	0084799	414.0	NORMAL
12/19/85	9:42:10	0000337	411.0	NORMAL
1/16/86	10:45:26	0000337	409.0	NORMAL
1/30/86	8:14:32	0034567	387.0	NORMAL / EUTHANIZED

PAGE 88  
 DATE: 6/09/87  
 TIME: 14:40:13  
 EDS017 V4M11

**Appendix F (cont.): INDIVIDUAL ANIMAL HISTORIES**

STUDY: 0083009  
 COMPOUND: ISOBUTYL 2-CYANOACRYLATE  
 START DATE: 1/28/85  
 CARCINOGENICITY BIOASSAY OF ISOBUTYL 2-CYANO-  
 ACRYLATE (IBC) IN MALE AND FEMALE RATS.

ANIMAL HISTORY

Animal ID: 84D00128 Species: D Sex: MALE Group: 100 UL/ANM

DATE	TIME	OPERATOR	WEIGHT (GRAMS)	CLINICAL OBSERVATIONS
2/14/85	9:43:44	0000337	368.0	CORNEAL OPACITY BOTH EYE SLIGHT
3/14/85	9:28:02	0078478	369.0	CORNEAL OPACITY BOTH EYE SLIGHT
4/11/85	9:30:56	0000337	376.0	CORNEAL OPACITY BOTH EYE SLIGHT
5/09/85	8:37:58	0000337	379.0	CORNEAL OPACITY BOTH EYE SLIGHT
6/06/85	9:55:36	0010186	387.0	CORNEAL OPACITY BOTH EYE SLIGHT
7/02/85	8:21:22	0000337	392.0	CORNEAL OPACITY BOTH EYE SLIGHT, INTRAABDOMINAL MASS VENTRAL TO LIVER SIZE MEDIUM
8/01/85	9:30:50	0001576	380.0	CORNEAL OPACITY BOTH EYE SLIGHT, INTRAABDOMINAL MASS VENTRAL TO LIVER SIZE MEDIUM
8/29/85	9:40:14	0000337	371.0	CORNEAL OPACITY BOTH EYE SLIGHT, INTRAABDOMINAL MASS VENTRAL TO LIVER SIZE MEDIUM
9/26/85	9:17:26	0000337	383.0	CORNEAL OPACITY BOTH EYE SLIGHT, INTRAABDOMINAL MASS VENTRAL TO LIVER SIZE MEDIUM
10/24/85	10:06:06	0034567	383.0	CORNEAL OPACITY BOTH EYE SLIGHT, INTRAABDOMINAL MASS VENTRAL TO LIVER SIZE MEDIUM
11/21/85	15:54:02	0084799	371.0	CORNEAL OPACITY BOTH EYE SLIGHT, INTRAABDOMINAL MASS VENTRAL TO LIVER SIZE MEDIUM, CORNEAL OPACITY BOTH EYE SLIGHT
12/19/85	9:42:34	0000337	378.0	CORNEAL OPACITY BOTH EYE SLIGHT, INTRAABDOMINAL MASS VENTRAL TO LIVER SIZE MEDIUM
1/16/86	10:45:48	0000337	383.0	CORNEAL OPACITY BOTH EYE SLIGHT, INTRAABDOMINAL MASS VENTRAL TO LIVER SIZE MEDIUM
1/30/86	8:16:06	0034567	356.0	CORNEAL OPACITY BOTH EYE SLIGHT, INTRAABDOMINAL MASS VENTRAL TO LIVER SIZE MEDIUM, EUTHANIZED

PAGE 890  
DATE: 6/09/87  
TIME: 14:40:13  
EDS017 V4M11

**Appendix F (cont.): INDIVIDUAL ANIMAL HISTORIES**

STUDY: 0083009 ISOBUTYL 2-CYANOACRYLATE CARCINOGENICITY BIOASSAY OF ISOBUTYL 2-CYANO-  
ACRYLATE (IBC) IN MALE AND FEMALE RATS.

COMPOUND: ISOBUTYL 2-CYANOACRYLATE  
START DATE: 1/28/85

**ANIMAL HISTORY**

Animal ID: 84D00129 Species: D Sex: MALE Group: 100 UL/ANM

DATE	TIME	OPERATOR	WEIGHT (GRAMS)	CLINICAL OBSERVATIONS
2/14/85	9:44:12	0000337	382.0	NORMAL
3/14/85	9:28:26	0078478	385.0	NORMAL
4/11/85	9:31:52	0000337	386.0	NORMAL
5/09/85	8:38:26	0000337	409.0	NORMAL
5/23/85	7:16:06	0000337		INTRABDOMINAL MASS VENTRAL TO LIVER SIZE MEDIUM
6/05/85	7:48:20	0000337		INTRABDOMINAL MASS VENTRAL TO LIVER SIZE MEDIUM, HYPOTONIA MODERATE, DECREASED PREENING MODERATE, ROUGH COAT MODERATE, STAIN BROWN NOSE MODERATE
6/05/85	7:57:52	0000337		* No observations recorded.

## Appendix F (cont.): INDIVIDUAL ANIMAL HISTORIES

PAGE 90  
DATE: 6/09/87  
TIME: 14:40:13  
EDS017 V4M11

STUDY: 0083009  
COMPOUND: ISOBUTYL 2-CYANOACRYLATE  
START DATE: 1/28/85

CARCINOGENICITY BIOASSAY OF ISOBUTYL 2-CYANO-  
ACRYLATE (IBC) IN MALE AND FEMALE RATS.

## ANIMAL HISTORY

Animal ID: 84D00130 Species: D Sex: MALE Group: 10 UL/ANM

DATE	TIME	OPERATOR	WEIGHT (GRAMS)	CLINICAL OBSERVATIONS
2/14/85	9:44:40	0000337	390.0	NORMAL
3/05/85	8:00:46	0000337		STAIN BROWN NOSE SLIGHT
3/14/85	9:28:52	0078478	394.0	NORMAL
4/11/85	9:32:26	0000337	392.0	NORMAL
5/09/85	8:38:46	0000337	398.0	NORMAL
5/15/85	7:43:10	0000337		INTRAABDOMINAL MASS VENTRAL TO LIVER SIZE MEDIUM
6/06/85	9:56:24	0084799	404.0	CORNEAL OPACITY LEFT EYE SLIGHT, INTRAABDOMINAL MASS VENTRAL TO LIVER SIZE MEDIUM, EARS DISCOLORED ERYTHEMATOUS
6/25/85	7:44:14	0000337		CORNEAL OPACITY LEFT EYE SLIGHT, INTRAABDOMINAL MASS VENTRAL TO LIVER SIZE MEDIUM, EARS DISCOLORED ERYTHEMATOUS
7/02/85	8:23:56	0000337	404.0	CORNEAL OPACITY LEFT EYE SLIGHT, INTRAABDOMINAL MASS VENTRAL TO LIVER SIZE MEDIUM, EARS DISCOLORED ERYTHEMATOUS
8/01/85	9:31:36	0001576	404.0	BLOODY PREPUTIAL DISCHARGE SLIGHT CORNEAL OPACITY LEFT EYE SLIGHT, INTRAABDOMINAL MASS VENTRAL TO LIVER SIZE MEDIUM, CORNEAL OPACITY LEFT EYE SLIGHT
8/29/85	9:44:24	0000337	396.0	CORNEAL OPACITY LEFT EYE SLIGHT, INTRAABDOMINAL MASS VENTRAL TO LIVER SIZE MEDIUM
9/26/85	9:18:26	0000337	410.0	CORNEAL OPACITY LEFT EYE SLIGHT, INTRAABDOMINAL MASS VENTRAL TO LIVER SIZE MEDIUM
10/24/85	10:06:52	0034567	402.0	CORNEAL OPACITY LEFT EYE SLIGHT, INTRAABDOMINAL MASS VENTRAL TO LIVER SIZE MEDIUM
11/21/85	15:55:22	0084799	395.0	CORNEAL OPACITY LEFT EYE SLIGHT, INTRAABDOMINAL MASS VENTRAL TO LIVER SIZE MEDIUM
12/19/85	9:43:20	0000337	400.0	CORNEAL OPACITY LEFT EYE SLIGHT, INTRAABDOMINAL MASS VENTRAL TO LIVER SIZE MEDIUM
1/16/86	10:46:48	0084799	395.0	CORNEAL OPACITY LEFT EYE SLIGHT, INTRAABDOMINAL MASS VENTRAL TO LIVER SIZE MEDIUM
1/30/86	8:19:04	0034567	366.0	CORNEAL OPACITY LEFT EYE SLIGHT, INTRAABDOMINAL MASS VENTRAL TO LIVER SIZE MEDIUM, EUTHANIZED

PAGE 910  
 DATE: 6/09/87  
 TIME: 14:40:13  
 EDS017 V4M11

**Appendix F (cont.): INDIVIDUAL ANIMAL HISTORIES**

STUDY: 0083009  
 COMPOUND: ISOBUTYL 2-CYANOACRYLATE  
 START DATE: 1/28/85

Animal ID: 84D00131 Species: D Sex: MALE Group: 100 UL/ANM

CARCINOGENICITY BIOASSAY OF ISOBUTYL 2-CYANO-  
 ACRYLATE (IBC) IN MALE AND FEMALE RATS.

ANIMAL HISTORY

DATE TIME OPERATOR WEIGHT (GRAMS) CLINICAL OBSERVATIONS

DATE	TIME	OPERATOR	WEIGHT (GRAMS)	CLINICAL OBSERVATIONS
2/14/85	10:22:28	0000337	443.0	NORMAL
3/14/85	9:30:12	0078478	455.0	NORMAL
4/11/85	10:00:12	0000337	452.0	NORMAL
5/09/85	9:11:24	0000337	452.0	NORMAL
6/06/85	10:00:16	0010186	489.0	NORMAL
7/02/85	8:24:54	0000337	463.0	NORMAL
8/01/85	9:32:22	0001576	471.0	NORMAL
8/29/85	9:46:06	0000337	464.0	NORMAL
9/26/85	9:19:16	0084799	471.0	INTRAABDOMINAL MASS VENTRAL TO LIVER SIZE LARGE
10/24/85	10:07:40	0084799	476.0	INTRAABDOMINAL MASS VENTRAL TO LIVER SIZE LARGE
11/21/85	15:56:24	0084799	463.0	INTRAABDOMINAL MASS VENTRAL TO LIVER SIZE LARGE
12/19/85	9:46:22	0000337	462.0	INTRAABDOMINAL MASS VENTRAL TO LIVER SIZE LARGE
1/16/86	10:48:06	0000337	445.0	INTRAABDOMINAL MASS VENTRAL TO LIVER SIZE LARGE
1/30/86	8:22:02	0034567	418.0	INTRAABDOMINAL MASS VENTRAL TO LIVER SIZE LARGE, EUTHANIZED

## Appendix F (cont.): INDIVIDUAL ANIMAL HISTORIES

PAGE 92  
DATE: 6/09/87  
TIME: 14:40:13  
EDS017 V4M11

STUDY: 0083009 ISOBUTYL 2-CYANOACRYLATE CARCINOGENICITY BIOASSAY OF ISOBUTYL 2-CYANO-  
COMPOUND: ISOBUTYL 2-CYANOACRYLATE ACRYLATE (IBC) IN MALE AND FEMALE RATS.  
START DATE: 1/28/85

## ANIMAL HISTORY

Animal ID: 84D00132 Species: D Sex: MALE Group: 100 UL/ANM

DATE	TIME	OPERATOR	WEIGHT (GRAMS)	CLINICAL OBSERVATIONS
2/05/85	8:50:48	0084799		CORNEAL OPACITY LEFT EYE MODERATE
2/14/85	10:22:42	0000337	387.0	CORNEAL OPACITY LEFT EYE SLIGHT
3/14/85	9:30:32	0078478	405.0	CORNEAL OPACITY LEFT EYE SLIGHT
4/11/85	10:00:46	0000337	404.0	CORNEAL OPACITY LEFT EYE SLIGHT
5/09/85	9:12:02	0000337	407.0	CORNEAL OPACITY LEFT EYE SLIGHT
6/06/85	10:01:10	0010186	422.0	CORNEAL OPACITY LEFT EYE SLIGHT
7/02/85	8:59:00	0000337	428.0	CORNEAL OPACITY LEFT EYE SLIGHT
8/01/85	9:32:56	0001576	423.0	CORNEAL OPACITY LEFT EYE SLIGHT
8/29/85	9:47:38	0000337	405.0	CORNEAL OPACITY LEFT EYE SLIGHT, CONJUNCTIVITIS LEFT EYE SLIGHT
9/26/85	9:20:44	0000337	414.0	CORNEAL OPACITY LEFT EYE SLIGHT
10/24/85	10:08:30	0034567	419.0	CORNEAL OPACITY LEFT EYE SLIGHT, INTRAABDOMINAL MASS VENTRAL TO LIVER SIZE LARGE
11/21/85	15:57:20	0084799	418.0	CORNEAL OPACITY LEFT EYE SLIGHT, INTRAABDOMINAL MASS VENTRAL TO LIVER SIZE LARGE
12/19/85	9:47:28	0000337	416.0	CORNEAL OPACITY LEFT EYE SLIGHT, INTRAABDOMINAL MASS VENTRAL TO LIVER SIZE LARGE
1/16/86	10:49:00	0000337	421.0	CORNEAL OPACITY LEFT EYE SLIGHT, INTRAABDOMINAL MASS VENTRAL TO LIVER SIZE LARGE
1/30/86	8:24:00	0034567	394.0	CORNEAL OPACITY LEFT EYE SLIGHT, INTRAABDOMINAL MASS VENTRAL TO LIVER SIZE LARGE, EUTHANIZED

**Appendix F (cont.): INDIVIDUAL ANIMAL HISTORIES**

STUDY: 0083009  
COMPOUND: ISOBUTYL 2-CYANOACRYLATE  
START DATE: 1/28/85  
CARCINOGENICITY BIOASSAY OF ISOBUTYL 2-CYANO-  
ACRYLATE (IBC) IN MALE AND FEMALE RATS.

Animal ID: 84D00133 Species: D Sex: MALE Group: CONTROLS  
ANIMAL HISTORY

DATE	TIME	OPERATOR	WEIGHT (GRAMS)	CLINICAL OBSERVATIONS
2/14/85	10:23:16	0000337	423.0	NORMAL
3/14/85	9:31:10	0078478	430.0	NORMAL
4/11/85	10:01:20	0000337	440.0	NORMAL
5/09/85	9:12:32	0000337	428.0	NORMAL
6/06/85	10:01:34	0010186	437.0	NORMAL
7/02/85	8:59:26	0000337	432.0	NORMAL
8/01/85	9:33:14	0001576	434.0	NORMAL
8/29/85	9:48:34	0000337	425.0	NORMAL
9/26/85	9:21:20	0000337	427.0	NORMAL
10/24/85	10:10:16	0034567	434.0	NORMAL
11/21/85	15:58:24	0084799	420.0	NORMAL
12/19/85	9:48:16	0000337	425.0	NORMAL
1/16/86	10:49:48	0000337	417.0	NORMAL
1/30/86	8:26:12	0034567	391.0	NORMAL / EUTHANIZED



**Appendix F (cont.): INDIVIDUAL ANIMAL HISTORIES**

PAGE 94  
 DATE: 6/09/87  
 TIME: 14:40:13  
 EDS017 V4M11

STUDY: 0083009  
 COMPOUND: ISOBUTYL 2-CYANOACRYLATE  
 START DATE: 1/28/85

CARCINOGENICITY BIOASSAY OF ISOBUTYL 2-CYANO-  
 ACRYLATE (IBC) IN MALE AND FEMALE RATS.

ANIMAL HISTORY

Animal ID: 84D00134 Species: D Sex: MALE Group: 100 UL/ANM

DATE	TIME	OPERATOR	WEIGHT (GRAMS)	CLINICAL OBSERVATIONS
2/14/85	10:23:32	0000337	414.0	NORMAL
3/14/85	9:31:52	0078478	417.0	NORMAL
4/11/85	10:02:00	0000337	415.0	NORMAL
5/09/85	9:13:16	0000337	441.0	NORMAL
6/06/85	10:02:02	0010186	422.0	NORMAL
7/02/85	9:00:22	0000337	424.0	NORMAL
8/01/85	9:33:32	0001576	429.0	NORMAL
8/29/85	9:49:24	0000337	428.0	NORMAL
9/26/85	9:21:34	0000337	433.0	NORMAL
10/24/85	10:10:34	0034567	436.0	NORMAL
11/07/85	10:08:00	0000337		INTRABDOMINAL MASS VENTRAL TO LIVER SIZE MEDIUM
11/21/85	15:58:40	0084799	419.0	INTRABDOMINAL MASS VENTRAL TO LIVER SIZE MEDIUM
12/19/85	9:48:46	0000337	423.0	INTRABDOMINAL MASS VENTRAL TO LIVER SIZE MEDIUM
1/16/86	10:50:08	0000337	413.0	INTRABDOMINAL MASS VENTRAL TO LIVER SIZE MEDIUM
1/30/86	8:27:32	0034567	384.0	INTRABDOMINAL MASS VENTRAL TO LIVER SIZE MEDIUM, EUTHANIZED

**Appendix F (cont.): INDIVIDUAL ANIMAL HISTORIES**

STUDY: 0083009  
 COMPOUND: ISOBUTYL 2-CYANOACRYLATE  
 START DATE: 1/28/85  
 CARCINOGENICITY BIOASSAY OF ISOBUTYL 2-CYANO-  
 ACRYLATE (IBC) IN MALE AND FEMALE RATS.

ANIMAL HISTORY

Animal ID: 84D00136 Species: D Sex: MALE Group: 10 UL/ANM

DATE	TIME	OPERATOR	WEIGHT (GRAMS)	CLINICAL OBSERVATIONS
2/14/85	10:23:48	0000337	399.0	NORMAL
3/14/85	9:32:40	0078478	407.0	NORMAL
4/11/85	10:02:58	0000337	400.0	NORMAL
5/09/85	9:13:36	0000337	404.0	NORMAL
5/15/85	7:50:30	0000337		INTRAABDOMINAL MASS VENTRAL TO LIVER SIZE MEDIUM
5/23/85	7:43:22	0000337		INTRAABDOMINAL MASS VENTRAL TO LIVER SIZE LARGE
6/06/85	10:02:22	0010186	408.0	INTRAABDOMINAL MASS VENTRAL TO LIVER SIZE MEDIUM
6/25/85	7:49:52	0000337		INTRAABDOMINAL MASS VENTRAL TO LIVER SIZE LARGE
7/02/85	9:00:54	0000337	408.0	INTRAABDOMINAL MASS VENTRAL TO LIVER SIZE LARGE
8/01/85	9:34:32	0001576	403.0	INTRAABDOMINAL MASS VENTRAL TO LIVER SIZE LARGE
8/29/85	9:50:08	0000337	410.0	INTRAABDOMINAL MASS VENTRAL TO LIVER SIZE LARGE, CONJUNCTIVITIS LEFT EYE MODERATE
9/26/85	9:21:58	0000337	407.0	INTRAABDOMINAL MASS VENTRAL TO LIVER SIZE LARGE
10/24/85	10:10:54	0034567	410.0	INTRAABDOMINAL MASS VENTRAL TO LIVER SIZE LARGE
11/21/85	15:59:50	0084799	406.0	INTRAABDOMINAL MASS VENTRAL TO LIVER SIZE LARGE
12/19/85	9:49:44	0000337	402.0	INTRAABDOMINAL MASS VENTRAL TO LIVER SIZE MEDIUM
1/16/86	10:51:08	0000337	392.0	INTRAABDOMINAL MASS VENTRAL TO LIVER SIZE LARGE
2/03/86	7:36:12	0034567	374.0	INTRAABDOMINAL MASS VENTRAL TO LIVER SIZE LARGE, CONJUNCTIVITIS LEFT EYE MODERATE, EUTHANIZED

**Appendix F (cont.): INDIVIDUAL ANIMAL HISTORIES**

PAGE 96  
 DATE: 6/09/87  
 TIME: 14:40:13  
 EDS017 V4M11

STUDY: 0083009  
 COMPOUND: ISOBUTYL 2-CYANOACRYLATE  
 START DATE: 1/28/85

CARCINOGENICITY BIOASSAY OF ISOBUTYL 2-CYANO-  
 ACRYLATE (IBC) IN MALE AND FEMALE RATS.

ANIMAL HISTORY

Animal ID: 84D00137 Species: D Sex: MALE Group: 10 UL/ANM

DATE	TIME	OPERATOR	WEIGHT (GRAMS)	CLINICAL OBSERVATIONS
2/14/85	10:24:08	0000337	405.0	NORMAL
3/14/85	9:33:02	0078478	419.0	NORMAL
4/11/85	10:03:26	0000337	417.0	NORMAL
5/09/85	9:14:08	0000337	424.0	NORMAL
6/06/85	10:03:10	0010186	440.0	NORMAL
7/02/85	9:01:34	0000337	434.0	INTRAABDOMINAL MASS VENTRAL TO LIVER SIZE MEDIUM
8/01/85	9:35:02	0001576	431.0	INTRAABDOMINAL MASS VENTRAL TO LIVER SIZE MEDIUM
8/29/85	9:53:32	0000337	430.0	INTRAABDOMINAL MASS VENTRAL TO LIVER SIZE MEDIUM
9/26/85	9:22:44	0000337	422.0	INTRAABDOMINAL MASS VENTRAL TO LIVER SIZE LARGE
10/24/85	10:11:36	0034567	427.0	INTRAABDOMINAL MASS VENTRAL TO LIVER SIZE LARGE
11/21/85	16:00:42	0084799	416.0	INTRAABDOMINAL MASS VENTRAL TO LIVER SIZE LARGE
12/19/85	9:50:22	0000337	416.0	INTRAABDOMINAL MASS VENTRAL TO LIVER SIZE LARGE
1/16/86	10:52:14	0000337	414.0	INTRAABDOMINAL MASS VENTRAL TO LIVER SIZE LARGE, SUBCUTANEOUS MASS THORAX RIGHT SIDE
2/03/86	7:39:36	0034567	392.0	INTRAABDOMINAL MASS VENTRAL TO LIVER SIZE LARGE, SUBCUTANEOUS MASS RIGHT SIDE THORAX SIZE LARGE, EUTHANIZED

PAGE 97 of  
 DATE: 6/09/87  
 TIME: 14:40:13  
 EDS017 V4M11

**Appendix F (cont.): INDIVIDUAL ANIMAL HISTORIES**

STUDY: 0083009 ISOBUTYL 2-CYANOACRYLATE CARCINOGENICITY BIOASSAY OF ISOBUTYL 2-CYANO-  
 COMPOUND: ISOBUTYL 2-CYANOACRYLATE ACRYLATE (IBC) IN MALE AND FEMALE RATS.  
 START DATE: 1/28/85

ANIMAL HISTORY

Animal ID: 84D00138 Species: D Sex: MALE Group: CONTROLS

DATE	TIME	OPERATOR	WEIGHT (GRAMS)	CLINICAL OBSERVATIONS
2/14/85	10:24:42	0000337	385.0	NORMAL
3/14/85	9:33:28	0078478	386.0	NORMAL
4/11/85	10:04:10	0000337	385.0	NORMAL
5/09/85	9:14:46	0000337	397.0	NORMAL
6/06/85	10:03:38	0010186	389.0	NORMAL
7/02/85	9:03:38	0000337	411.0	NORMAL
8/01/85	9:35:32	0001576	419.0	NORMAL
8/29/85	9:56:36	0000337	423.0	NORMAL
9/26/85	9:23:46	0000337	422.0	NORMAL
10/24/85	10:12:34	0034567	435.0	NORMAL
11/21/85	16:01:40	0084799	431.0	NORMAL
12/19/85	9:51:06	0000337	436.0	NORMAL
1/16/86	10:54:06	0000337	440.0	NORMAL
2/03/86	7:43:10	0034567	409.0	NORMAL / EUTHANIZED

## Appendix F (cont.): INDIVIDUAL ANIMAL HISTORIES

STUDY: 0083009  
 COMPOUND: ISOBUTYL 2-CYANOACRYLATE  
 START DATE: 1/28/85

CARCINOGENICITY BIOASSAY OF ISOBUTYL 2-CYANO-  
 ACRYLATE (IBC) IN MALE AND FEMALE RATS.

PAGE 98  
 DATE: 6/09/87  
 TIME: 14:40:13  
 EDS017 V4M11

## ANIMAL HISTORY

Animal ID: 84D00139 Species: D Sex: MALE Group: 100 UL/ANM

DATE	TIME	OPERATOR	WEIGHT (GRAMS)	CLINICAL OBSERVATIONS
2/14/85	10:25:06	0000337	401.0	NORMAL
3/14/85	9:33:48	0078478	405.0	NORMAL
4/11/85	10:04:44	0000337	401.0	NORMAL
5/09/85	9:15:22	0000337	414.0	SCAB RIGHT EAR SLIGHT
5/15/85	7:55:10	0000337		SCAB RIGHT EAR SLIGHT, INTRAABDOMINAL MASS VENTRAL TO LIVER SIZE MEDIUM
6/06/85	10:04:00	0010186	417.0	INTRAABDOMINAL MASS VENTRAL TO LIVER SIZE LARGE
7/02/85	9:04:06	0000337	413.0	INTRAABDOMINAL MASS VENTRAL TO LIVER SIZE LARGE
8/01/85	9:35:58	0001576	415.0	INTRAABDOMINAL MASS VENTRAL TO LIVER SIZE LARGE
8/29/85	9:57:06	0000337	418.0	INTRAABDOMINAL MASS VENTRAL TO LIVER SIZE LARGE
9/26/85	9:24:12	0000337	407.0	INTRAABDOMINAL MASS VENTRAL TO LIVER SIZE LARGE
10/24/85	10:12:58	0034567	401.0	INTRAABDOMINAL MASS VENTRAL TO LIVER SIZE LARGE
11/05/85	8:03:12	0000337		SIXTY GRAM WEIGHT LOSS ELEVEN DAYS

PAGE 99 of  
 DATE: 6/09/87  
 TIME: 14:40:13  
 EDS017 V4M11

**Appendix F (cont.): INDIVIDUAL ANIMAL HISTORIES**

CARCINOGENICITY BIOASSAY OF ISOBUTYL 2-CYANO-ACRYLATE (IBC) IN MALE AND FEMALE RATS.

ANIMAL HISTORY

STUDY: 0083009  
 COMPOUND: ISOBUTYL 2-CYANOACRYLATE  
 START DATE: 1/28/85

Animal ID: 84D00140 Species: D Sex: MALE Group: 10 UL/ANM

DATE	TIME	OPERATOR	WEIGHT (GRAMS)	CLINICAL OBSERVATIONS
2/14/85	10:25:24	0000337	409.0	NORMAL
3/14/85	9:34:10	0078478	414.0	NORMAL
4/11/85	10:05:30	0000337	409.0	NORMAL
5/09/85	9:17:14	0000337	421.0	NORMAL
6/06/85	10:04:50	0010186	430.0	NORMAL
7/02/85	9:04:52	0000337	444.0	NORMAL
8/01/85	9:36:32	0001576	445.0	NORMAL
8/29/85	9:58:06	0000337	449.0	NORMAL
9/26/85	9:53:40	0000337	454.0	NORMAL
10/24/85	10:13:56	0034567	442.0	NORMAL
11/21/85	16:01:58	0084799	432.0	NORMAL
12/19/85	9:51:24	0000337	422.0	NORMAL
1/16/86	10:54:24	0000337	436.0	NORMAL
2/03/86	7:44:48	0034567	382.0	NORMAL / EUTHANIZED

## Appendix F (cont.): INDIVIDUAL ANIMAL HISTORIES

PAGE 100  
DATE: 6/09/87  
TIME: 14:40:13  
EDS017 V4M11

STUDY: 0083009  
COMPOUND: ISOBUTYL 2-CYANOACRYLATE  
START DATE: 1/28/85

CARCINOGENICITY BIOASSAY OF ISOBUTYL 2-CYANO-  
ACRYLATE (IBC) IN MALE AND FEMALE RATS.

## ANIMAL HISTORY

Animal ID: 84D00141 Species: D Sex: MALE Group: 10 UL/ANM

DATE	TIME	OPERATOR	WEIGHT (GRAMS)	CLINICAL OBSERVATIONS
2/14/85	10:25:38	0084799	393.0	PROLAPSED LENS RIGHT EYE MARKED, OPAQUE LENS RIGHT EYE MARKED
3/05/85	8:06:18	0000337		OPAQUE LENS RIGHT EYE
3/08/85	9:26:50	0000337		PROLAPSED LENS RIGHT EYE MARKED, OPAQUE LENS RIGHT EYE MARKED
3/14/85	9:34:28	0084799	405.0	PROLAPSED LENS RIGHT EYE MARKED, OPAQUE LENS RIGHT EYE MARKED
4/11/85	10:06:10	0000337	412.0	PROLAPSED LENS RIGHT EYE MARKED, OPAQUE LENS RIGHT EYE MARKED
5/09/85	9:18:14	0000337	424.0	PROLAPSED LENS RIGHT EYE MARKED, OPAQUE LENS RIGHT EYE MARKED
6/06/85	10:05:12	0010186	425.0	PROLAPSED LENS RIGHT EYE MARKED, OPAQUE LENS RIGHT EYE MARKED
6/25/85	7:54:36	0000337		PROLAPSED LENS RIGHT EYE MARKED, OPAQUE LENS RIGHT EYE MARKED, SCAB RIGHT EAR MODERATE
7/02/85	9:05:22	0000337	425.0	SCAB RIGHT EAR MODERATE, PROLAPSED LENS RIGHT EYE MARKED, OPAQUE LENS RIGHT EYE MARKED
8/01/85	9:36:54	0001576	426.0	SCAB RIGHT EAR SLIGHT, PROLAPSED LENS RIGHT EYE MARKED, OPAQUE LENS RIGHT EYE MARKED
8/21/85	9:33:52	0000337		PROLAPSED LENS RIGHT EYE MARKED, OPAQUE LENS RIGHT EYE MARKED
8/29/85	9:58:26	0000337	423.0	PROLAPSED LENS RIGHT EYE MARKED, OPAQUE LENS RIGHT EYE MARKED, MICROOPHTHALMIA RIGHT EYE
9/26/85	9:54:16	0000337	428.0	OPAQUE LENS RIGHT EYE MARKED, PROLAPSED LENS RIGHT EYE MARKED
10/24/85	10:14:16	0034567	434.0	OPAQUE LENS RIGHT EYE MARKED, MICROOPHTHALMIA RIGHT EYE SLIGHT
11/07/85	10:14:18	0000337		OPAQUE LENS RIGHT EYE MARKED, MICROOPHTHALMIA RIGHT EYE SLIGHT, INTRAABDOMINAL MASS VENTRAL TO LIVER SIZE LARGE
11/21/85	16:02:16	0084799	418.0	INTRAABDOMINAL MASS VENTRAL TO LIVER SIZE MEDIUM, OPAQUE LENS RIGHT EYE MARKED, MICROOPHTHALMIA RIGHT EYE MARKED
12/19/85	9:51:40	0000337	416.0	INTRAABDOMINAL MASS VENTRAL TO LIVER SIZE LARGE, OPAQUE LENS BOTH EYES MARKED, PROLAPSED LENS BOTH EYES MARKED
1/16/86	10:54:40	0000337	405.0	INTRAABDOMINAL MASS VENTRAL TO LIVER SIZE LARGE, OPAQUE LENS BOTH EYES MARKED WITH MICROOPHTHALMIA RIGHT EYE
2/03/86	7:46:58	0034567	380.0	INTRAABDOMINAL MASS VENTRAL TO LIVER SIZE LARGE, BILATERAL OPACITY, EUTHANIZED

PAGE 101  
 DATE: 6/09/87  
 TIME: 14:40:13  
 EDS017 V4M11

**Appendix F (cont.): INDIVIDUAL ANIMAL HISTORIES**

STUDY: 0083009 ISOBUTYL 2-CYANOACRYLATE CARCINOGENICITY BIOASSAY OF ISOBUTYL 2-CYANO-  
 COMPOUND: ISOBUTYL 2-CYANOACRYLATE ACRYLATE (IBC) IN MALE AND FEMALE RATS.  
 START DATE: 1/28/85

ANIMAL HISTORY

Animal ID: 84D00142 Species: D Sex: MALE Group: CONTROLS

DATE	TIME	OPERATOR	WEIGHT (GRAMS)	CLINICAL OBSERVATIONS
2/14/85	10:27:46	0000337	390.0	NORMAL
3/14/85	9:35:30	0078478	394.0	NORMAL
4/11/85	10:07:26	0000337	399.0	NORMAL
5/09/85	9:19:22	0000337	407.0	NORMAL
6/06/85	10:05:58	0010186	415.0	NORMAL
7/02/85	9:06:14	0000337	410.0	NORMAL
8/01/85	9:40:14	0001576	416.0	NORMAL
8/29/85	10:00:18	0000337	419.0	NORMAL
9/26/85	9:55:26	0000337	411.0	NORMAL
10/24/85	10:15:06	0034567	413.0	NORMAL
11/21/85	16:05:08	0084799	395.0	NORMAL
12/19/85	9:53:36	0000337	400.0	NORMAL
1/16/86	10:57:16	0000337	379.0	NORMAL
2/03/86	7:51:22	0034567	353.0	NORMAL / EUTHANIZED



PAGE 102  
 DATE: 6/09/87  
 TIME: 14:40:13  
 EDS017 V4M11

**Appendix F (cont.): INDIVIDUAL ANIMAL HISTORIES**

STUDY: 0083009  
 COMPOUND: ISOBUTYL 2-CYANOACRYLATE  
 START DATE: 1/28/85  
 CARCINOGENICITY BIOASSAY OF ISOBUTYL 2-CYANO-  
 ACRYLATE (IBC) IN MALE AND FEMALE RATS.

ANIMAL HISTORY

Animal ID: 84D00143 Species: D Sex: MALE Group: CONTROLS

DATE	TIME	OPERATOR	WEIGHT (GRAMS)	CLINICAL OBSERVATIONS
2/14/85	10:28:28	0000337	380.0	SCAB RIGHT EAR SLIGHT
3/14/85	9:35:42	0078478	385.0	SCAB RIGHT EAR SLIGHT
4/11/85	10:08:52	0000337	397.0	NORMAL
5/09/85	9:19:46	0000337	405.0	NORMAL
6/06/85	10:06:12	0010186	413.0	NORMAL
7/02/85	9:06:40	0000337	403.0	NORMAL
8/01/85	9:40:40	0001576	421.0	NORMAL
8/29/85	10:00:40	0000337	420.0	NORMAL
9/26/85	9:55:46	0000337	421.0	NORMAL
10/24/85	10:15:24	0034567	427.0	NORMAL
11/21/85	16:05:40	0084799	420.0	NORMAL
12/19/85	9:53:52	0000337	412.0	NORMAL
1/16/86	10:57:40	0000337	412.0	NORMAL
2/03/86	7:52:28	0034567	375.0	NORMAL / EUTHANIZED

**Appendix F (cont.): INDIVIDUAL ANIMAL HISTORIES**

STUDY: 0083009  
 COMPOUND: ISOBUTYL 2-CYANOACRYLATE  
 START DATE: 1/28/85  
 CARCINOGENICITY BIOASSAY OF ISOBUTYL 2-CYANO-  
 ACRYLATE (IBC) IN MALE AND FEMALE RATS.

Animal ID: 84D00144 Species: D Sex: MALE Group: 10 UL/ANM  
 ANIMAL HISTORY

Animal ID: 84D00144 Species: D Sex: MALE Group: 10 UL/ANM

DATE	TIME	OPERATOR	WEIGHT (GRAMS)	CLINICAL OBSERVATIONS
2/14/85	10:29:34	0000337	414.0	NORMAL
3/05/85	8:13:44	0000337		STAIN BROWN NOSE SLIGHT
3/14/85	9:37:58	0078478	423.0	NORMAL
4/11/85	10:12:04	0000337	416.0	NORMAL
4/16/85	7:50:40	0067831		CORNEAL OPACITY RIGHT EYE SLIGHT
5/09/85	9:20:16	0000337	418.0	NORMAL
6/06/85	10:06:34	0010186	425.0	NORMAL
7/02/85	9:07:06	0000337	431.0	NORMAL
8/01/85	9:41:02	0001576	435.0	NORMAL
8/29/85	10:01:08	0000337	437.0	NORMAL
9/26/85	9:56:08	0000337	435.0	NORMAL
10/24/85	10:15:44	0034567	434.0	NORMAL
11/21/85	16:06:00	0084799	419.0	NORMAL
12/19/85	9:55:06	0000337	422.0	NORMAL
1/16/86	10:57:58	0000337	420.0	NORMAL
2/03/86	7:54:10	0034567	388.0	NORMAL / EUTHANIZED

## Appendix F (cont.): INDIVIDUAL ANIMAL HISTORIES

STUDY: 0083009

COMPOUND: ISOBUTYL 2-CYANOACRYLATE

START DATE: 1/28/85

CARCINOGENICITY BIOASSAY OF ISOBUTYL 2-CYANO-  
ACRYLATE (IBC) IN MALE AND FEMALE RATS.PAGE 104  
DATE: 6/09/87  
TIME: 14:40:13  
EDS017 V4M11

## ANIMAL HISTORY

Animal ID: 84D00145 Species: D Sex: MALE Group: 10 UL/ANM

DATE	TIME	OPERATOR	WEIGHT (GRAMS)	CLINICAL OBSERVATIONS
2/14/85	10:29:50	0000337	382.0	NORMAL
3/14/85	9:38:24	0078478	383.0	NORMAL
4/11/85	10:12:40	0000337	386.0	NORMAL
5/09/85	9:20:52	0000337	390.0	NORMAL
6/06/85	10:06:54	0010186	387.0	NORMAL
7/02/85	9:07:32	0000337	398.0	NORMAL
8/01/85	9:41:30	0001576	401.0	NORMAL
8/29/85	10:01:38	0000337	396.0	NORMAL
9/26/85	9:56:30	0000337	400.0	NORMAL
10/24/85	10:16:04	0034567	403.0	NORMAL
11/21/85	16:06:16	0084799	393.0	NORMAL
12/19/85	9:55:24	0000337	388.0	NORMAL
1/16/86	10:58:12	0000337	376.0	NORMAL
2/03/86	7:56:16	0034567	354.0	INTRABDOMINAL MASS VENTRAL TO LIVER SIZE LARGE, EUTHANIZED

**Appendix F (cont.): INDIVIDUAL ANIMAL HISTORIES**

STUDY: 0083009 ISOBUTYL 2-CYANOACRYLATE CARCINOGENICITY BIOASSAY OF ISOBUTYL 2-CYANO-  
 COMPOUND: ISOBUTYL 2-CYANOACRYLATE ACRYLATE (IBC) IN MALE AND FEMALE RATS.  
 START DATE: 1/28/85

**ANIMAL HISTORY**

Animal ID: 84D00146 Species: D Sex: MALE Group: 10 UL/ANM

DATE	TIME	OPERATOR	WEIGHT (GRAMS)	CLINICAL OBSERVATIONS
2/14/85	10:30:10	0000337	407.0	NORMAL
3/14/85	9:38:42	0078478	409.0	NORMAL
4/11/85	10:13:14	0000337	416.0	NORMAL
5/09/85	9:22:40	0000337	424.0	SEBACEOUS CYST ABDOMINAL
5/23/85	7:53:40	0000337		NORMAL
6/06/85	10:07:26	0010186	434.0	NORMAL
7/02/85	9:08:02	0000337	429.0	SCAB ABDOMEN RIGHT SIDE SLIGHT
8/01/85	9:41:46	0001576	440.0	SCAB ABDOMEN RIGHT SIDE SLIGHT
8/29/85	10:02:02	0000337	441.0	SCAB ABDOMEN RIGHT SIDE SLIGHT
9/26/85	9:56:54	0000337	439.0	SCAB ABDOMEN RIGHT SIDE SLIGHT
10/24/85	10:16:46	0034567	403.0	SCAB ABDOMEN RIGHT SIDE SLIGHT
11/18/85	9:39:06	0000337		* No observations recorded.

**Appendix F (cont.): INDIVIDUAL ANIMAL HISTORIES**

PAGE 106  
 DATE: 6/09/87  
 TIME: 14:40:13  
 EDS017 VAM11

STUDY: 0083009  
 COMPOUND: ISOBUTYL 2-CYANOACRYLATE  
 START DATE: 1/28/85

CARCINOGENICITY BIOASSAY OF ISOBUTYL 2-CYANO-  
 ACRYLATE (IBC) IN MALE AND FEMALE RATS.

ANIMAL HISTORY

Animal ID: 84D00147 Species: D Sex: MALE Group: 10 UL/ANM

DATE	TIME	OPERATOR	WEIGHT (GRAMS)	CLINICAL OBSERVATIONS
2/14/85	10:30:30	0000337	360.0	NORMAL
3/14/85	9:38:58	0078478	367.0	NORMAL
4/11/85	10:13:46	0000337	369.0	NORMAL
5/09/85	9:25:24	0000337	378.0	NORMAL
6/06/85	10:07:44	0010166	398.0	NORMAL
7/02/85	9:09:54	0000337	398.0	NORMAL
8/01/85	9:42:34	0001576	412.0	SUBCUTANEOUS MASS PERI HUMEROUS LEFT SIDE SIZE LARGE
8/16/85	7:47:54	0000337		* No observations recorded.

PAGE 107 @  
 DATE: 6/09/87 r  
 TIME: 14:40:13 a  
 EDS017 V4M.1.1

**Appendix F (cont.): INDIVIDUAL ANIMAL HISTORIES**

STUDY: 0083009  
 COMPOUND: ISOBUTYL 2-CYANOACRYLATE  
 START DATE: 1/28/85  
 CARCINOGENICITY BIOASSAY OF ISOBUTYL 2-CYANO-  
 ACRYLATE (IBC) IN MALE AND FEMALE RATS.

**ANIMAL HISTORY**

Animal ID: 84D00148 Species: D Sex: MALE Group: CONTROLS

DATE	TIME	OPERATOR	WEIGHT (GRAMS)	CLINICAL OBSERVATIONS
2/14/85	10:30:46	0000337	417.0	NORMAL
3/14/85	9:39:14	0078478	430.0	NORMAL
4/11/85	10:14:54	0000337	420.0	NORMAL
5/09/85	9:25:38	0000337	413.0	PREPUTIAL FISTULA
6/06/85	10:07:58	0010186	428.0	PREPUTIAL FISTULA
7/02/85	9:10:22	0000337	430.0	PREPUTIAL FISTULA
8/01/85	9:45:38	0001576	420.0	PREPUICIAL FISTULA SMALL AND HEALING
8/29/85	10:03:20	0000337	419.0	PREPUTIAL FISTULA SMALL
9/26/85	9:57:56	0000337	411.0	PREPUTIAL FISTULA SLIGHT
10/24/85	10:17:26	0034567	412.0	PREPUTIAL FISTULA SLIGHT
11/21/85	16:06:32	0084799	398.0	PREPUTIAL FISTULA SMALL
12/19/85	9:55:44	0000337	389.0	PREPUTIAL FISTULA SMALL
1/16/86	10:58:32	0000337	387.0	PREPUTIAL FISTULA SIZE SMALL
2/03/86	7:59:56	0034567	366.0	PREPUTIAL FISTULA, EUTHANIZED

## Appendix F (cont.): INDIVIDUAL ANIMAL HISTORIES

PAGE 108  
DATE: 6/09/87  
TIME: 14:40:13  
EDS017 V4M11

STUDY: 0083009  
COMPOUND: ISOBUTYL 2-CYANOACRYLATE  
START DATE: 1/28/85

CARCINOGENICITY BIOASSAY OF ISOBUTYL 2-CYANO-  
ACRYLATE (IBC) IN MALE AND FEMALE RATS.

## ANIMAL HISTORY

Animal ID: 84D00149 Species: D Sex: MALE Group: 10 UL/ANM

DATE	TIME	OPERATOR	WEIGHT (GRAMS)	CLINICAL OBSERVATIONS
2/14/85	10:31:02	0000337	380.0	CORNEAL OPACITY RIGHT EYE SLIGHT
3/14/85	9:39:34	0078478	386.0	CORNEAL OPACITY RIGHT EYE SLIGHT
4/11/85	10:15:24	0000337	393.0	CORNEAL OPACITY RIGHT EYE SLIGHT
5/09/85	9:27:36	0000337	400.0	CORNEAL OPACITY RIGHT EYE SLIGHT
5/23/85	7:50:24	0000337		CORNEAL OPACITY RIGHT EYE SLIGHT, INTRAABDOMINAL MASS VENTRAL TO LIVER SIZE MEDIUM
6/05/85	9:16:08	0000337		INTRAABDOMINAL MASS VENTRAL TO LIVER SIZE LARGE, CORNEAL OPACITY RIGHT EYE SLIGHT
6/06/85	10:10:10	0010186	411.0	INTRAABDOMINAL MASS VENTRAL TO LIVER SIZE LARGE, CORNEAL OPACITY RIGHT EYE SLIGHT
7/02/85	9:11:16	0000337	393.0	CORNEAL OPACITY RIGHT EYE SLIGHT, INTRAABDOMINAL MASS VENTRAL TO LIVER SIZE LARGE
8/01/85	9:46:58	0001576	292.0	CORNEAL OPACITY RIGHT EYE SLIGHT, INTRAABDOMINAL MASS VENTRAL TO LIVER SIZE MEDIUM, DEHYDRATED SLIGHT, EMACIATED SLIGHT, ROUGH COAT MARKED, PORPHYRIN STAINED COAT MARKED
8/01/85	10:40:02	0034567		* No observations recorded.

PAGE 109  
 DATE: 6/09/87  
 TIME: 14:40:13  
 EDS017 V4M11

**Appendix F (cont.): INDIVIDUAL ANIMAL HISTORIES**

STUDY: 0083009  
 COMPOUND: ISOBUTYL 2-CYANOACRYLATE  
 START DATE: 1/28/85

CARCINOGENICITY BIOASSAY OF ISOBUTYL 2-CYANO-  
 ACRYLATE (IBC) IN MALE AND FEMALE RATS.

ANIMAL HISTORY

Animal ID: 84D00151 Species: D Sex: MALE Group: 100 UL/ANM

DATE	TIME	OPERATOR	WEIGHT (GRAMS)	CLINICAL OBSERVATIONS
2/06/85	7:54:08	0000337		NORMAL
2/14/85	10:31:30	0000337	397.0	INTERABDOMINAL MASS VENTRAL TO LIVER
2/28/85	8:09:38	0000337	405.0	INTERABDOMINAL MASS VENTRAL TO LIVER
3/05/85	8:16:20	0084799		INTRAABDOMINAL MASS VENTRAL TO LIVER, STAIN BROWN NOSE SLIGHT
3/13/85	8:02:40	0084799		INTRAABDOMINAL MASS VENTRAL TO LIVER
3/14/85	9:40:00	0078478	405.0	INTRAABDOMINAL MASS VENTRAL TO LIVER, SIZE MEDIUM
4/03/85	9:23:22	0000337	399.0	INTRAABDOMINAL MASS VENTRAL TO LIVER, SIZE MEDIUM
4/11/85	10:16:08	0000337	417.0	INTRAABDOMINAL MASS VENTRAL TO LIVER, SIZE MEDIUM
4/25/85	8:43:20	0000337	417.0	INTRAABDOMINAL MASS VENTRAL TO LIVER, SIZE MEDIUM
5/09/85	9:28:06	0084799	414.0	INTRAABDOMINAL MASS VENTRAL TO LIVER SIZE MEDIUM
5/23/85	7:54:58	0000337		INTRAABDOMINAL MASS VENTRAL TO LIVER SIZE LARGE
6/06/85	10:11:04	0010186	416.0	INTRAABDOMINAL MASS VENTRAL TO LIVER SIZE LARGE
7/02/85	9:12:08	0000337	417.0	CONJUNCTIVITIS LEFT EYE MODERATE,
8/01/85	9:52:16	0001576	422.0	INTRAABDOMINAL MASS VENTRAL TO LIVER SIZE LARGE
8/29/85	10:04:52	0000337	424.0	INTRAABDOMINAL MASS VENTRAL TO LIVER SIZE LARGE
8/30/85	11:33:04	0000337		INTRAABDOMINAL MASS VENTRAL TO LIVER SIZE LARGE, PALLOR MARKED



## Appendix F (cont.): INDIVIDUAL ANIMAL HISTORIES

STUDY: 0083009

COMPOUND: ISOBUTYL 2-CYANOACRYLATE

START DATE: 1/28/85

CARCINOGENICITY BIOASSAY OF ISOBUTYL 2-CYANO-  
ACRYLATE (IBC) IN MALE AND FEMALE RATS.PAGE 110  
DATE: 6/09/87  
TIME: 14:40:13  
EDS017 V4M11

## ANIMAL HISTORY

Animal ID: 84D00152 Species: D Sex: MALE Group: 100 UL/ANM

DATE	TIME	OPERATOR	WEIGHT (GRAMS)	CLINICAL OBSERVATIONS
2/14/85	10:33:08	0000337	425.0	NORMAL
3/14/85	9:41:28	0078478	432.0	NORMAL
4/11/85	10:17:06	0000337	432.0	NORMAL
5/09/85	9:29:26	0000337	434.0	NORMAL
5/15/85	8:02:44	0000337		INTRAABDOMINAL MASS VENTRAL TO LIVER SIZE MEDIUM
6/05/85	9:19:20	0000337		INTRAABDOMINAL MASS VENTRAL TO LIVER SIZE LARGE
6/06/85	10:11:52	0010186	443.0	INTRAABDOMINAL MASS VENTRAL TO LIVER SIZE LARGE
7/02/85	9:13:25	0000337	449.0	INTRAABDOMINAL MASS VENTRAL TO LIVER SIZE LARGE
8/01/85	9:52:50	0001576	446.0	INTRAABDOMINAL MASS VENTRAL TO LIVER SIZE LARGE
8/29/85	10:06:26	0084799	447.0	INTRAABDOMINAL MASS VENTRAL TO LIVER SIZE LARGE
9/26/85	9:58:44	0000337	450.0	INTRAABDOMINAL MASS VENTRAL TO LIVER SIZE LARGE
10/24/85	10:18:00	0034567	458.0	INTRAABDOMINAL MASS VENTRAL TO LIVER SIZE LARGE
11/21/85	16:07:58	0084799	441.0	INTRAABDOMINAL MASS VENTRAL TO LIVER SIZE LARGE
12/19/85	9:56:28	0000337	434.0	INTRAABDOMINAL MASS VENTRAL TO LIVER SIZE LARGE
1/16/86	10:59:14	0000337	427.0	PAPILLOMA ANGLE MOUTH LEFT SIDE SMALL, INTRAABDOMINAL MASS VENTRAL TO LIVER SIZE LARGE
2/03/86	8:01:58	0034567	394.0	INTRAABDOMINAL MASS VENTRAL TO LIVER SIZE LARGE, EUTHANIZED

PAGE 111 0  
 DATE: 6/09/87 CT  
 TIME: 14:40:13  
 EDS017 V4M11

**Appendix F (cont.): INDIVIDUAL ANIMAL HISTORIES**

STUDY: 0083009  
 COMPOUND: ISOBUTYL 2-CYANOACRYLATE  
 START DATE: 1/28/85

Animal ID: 84D00153 Species: D Sex: MALE Group: 100 UL/ANN

CARCINOGENICITY BIOASSAY OF ISOBUTYL 2-CYANO-  
 ACRYLATE (IBC) IN MALE AND FEMALE RATS.

ANIMAL HISTORY

DATE	TIME	OPERATOR	WEIGHT (GRAMS)	CLINICAL OBSERVATIONS
2/14/85	10:33:26	0000337	419.0	CORNEAL OPACITY LEFT EYE SLIGHT, SCAB RIGHT EAR SLIGHT
3/14/85	9:42:00	0078478	424.0	CORNEAL OPACITY LEFT EYE SLIGHT
4/11/85	10:18:08	0000337	419.0	CORNEAL OPACITY LEFT EYE SLIGHT
5/09/85	9:29:48	0000337	429.0	SUBCUTANEOUS MASS LEFT HUMEROUS SMALL
5/15/85	8:05:58	0000337		SUBCUTANEOUS MASS LEFT HUMEROUS SIZE MEDIUM
5/23/85	7:59:24	0084799		SUPPURATING MASS LEFT HUMEROUS SIZE MEDIUM
6/06/85	10:13:04	0010186	431.0	SUBCUTANEOUS MASS LEFT HUMEROUS MEDIUM
7/02/85	9:14:46	0000337	434.0	SUBCUTANEOUS MASS LEFT HUMEROUS MEDIUM
8/01/85	9:53:24	0001576	424.0	OPAQUE LENS LEFT EYE SLIGHT, SUBCUTANEOUS MASS LEFT HUMEROUS SIZE MEDIUM
8/15/85	6:53:18	0000337		OPAQUE LENS LEFT EYE MARKED,
8/29/85	10:07:52	0084799	429.0	SUBCUTANEOUS MASS LEFT HUMEROUS ERUPTED THROUGH SKIN SIZE MEDIUM
9/26/85	10:00:04	0000337	435.0	SUBCUTANEOUS MASS LEFT HUMEROUS SIZE SMALL, OPAQUE LENS LEFT EYE MARKED
10/24/85	10:19:20	0034567	440.0	OPAQUE LENS LEFT EYE MARKED, SUBCUTANEOUS MASS LEFT FOREARM SIZE SMALL
11/21/85	16:09:22	0084799	422.0	OPAQUE LENS LEFT EYE MARKED, SUBCUTANEOUS CYST LEFT FOREARM SMALL
12/19/85	9:57:16	0000337	420.0	OPAQUE LENS LEFT EYE MARKED, SUBCUTANEOUS MASS LEFT HUMEROUS SIZE SMALL
1/16/86	11:00:54	0000337	414.0	OPAQUE LENS LEFT EYE MARKED, SUBCUTANEOUS MASS LEFT FORE ARM SMALL
2/03/86	8:04:38	0034567	379.0	SUBCUTANEOUS MASS LEFT FOREARM, OPAQUE LENS LEFT EYE, EUTHANIZED

## Appendix F (cont.): INDIVIDUAL ANIMAL HISTORIES

PAGE 112  
 DATE: 6/09/87  
 TIME: 14:40:13  
 EDS017 V4M11

STUDY: 0083009 ISOBUTYL 2-CYANOACRYLATE CARCINOGENICITY BIOASSAY OF ISOBUTYL 2-CYANO-  
 COMPOUND: ISOBUTYL 2-CYANOACRYLATE ACRYLATE (IBC) IN MALE AND FEMALE RATS.  
 START DATE: 1/28/85

## ANIMAL HISTORY

Animal ID: 84D00154 Species: D Sex: MALE Group: 10 UL/ANN

DATE	TIME	OPERATOR	WEIGHT (GRAMS)	CLINICAL OBSERVATIONS
2/14/85	10:35:36	0000337	411.0	NORMAL
3/14/85	9:42:56	0078478	413.0	NORMAL
4/11/85	10:19:02	0000337	418.0	NORMAL
5/09/85	9:33:30	0000337	430.0	NORMAL
5/23/85	8:01:48	0000337		INTRABDOMINAL MASS VENTRAL TO LIVER SIZE MEDIUM
6/06/85	10:14:42	0010186	429.0	INTRABDOMINAL MASS VENTRAL TO LIVER SIZE MEDIUM
7/02/85	9:15:44	0000337	435.0	INTRABDOMINAL MASS VENTRAL TO LIVER SIZE LARGE
8/01/85	9:54:56	0001576	432.0	INTRABDOMINAL MASS VENTRAL TO LIVER SIZE LARGE
8/29/85	10:10:52	0000337	433.0	INTRABDOMINAL MASS VENTRAL TO LIVER SIZE LARGE
9/26/85	10:02:58	0000337	445.0	INTRABDOMINAL MASS VENTRAL TO LIVER SIZE LARGE
10/24/85	10:21:10	0034567	443.0	INTRABDOMINAL MASS VENTRAL TO LIVER SIZE LARGE
11/21/85	16:10:30	0084799	427.0	INTRABDOMINAL MASS VENTRAL TO LIVER SIZE LARGE
12/19/85	9:58:36	0000337	411.0	INTRABDOMINAL MASS VENTRAL TO LIVER SIZE LARGE
1/16/86	11:02:14	0000337	402.0	INTRABDOMINAL MASS VENTRAL TO LIVER SIZE LARGE
2/03/86	8:07:36	0034567	383.0	INTRABDOMINAL MASS VENTRAL TO LIVER SIZE LARGE, EUTHANIZED

**Appendix F (cont.): INDIVIDUAL ANIMAL HISTORIES**

STUDY: 0083009  
 COMPOUND: ISOBUTYL 2-CYANOACRYLATE  
 START DATE: 1/28/85  
 CARCINOGENICITY BIOASSAY OF ISOBUTYL 2-CYANO-  
 ACRYLATE (IBC) IN MALE AND FEMALE RATS.

ANIMAL HISTORY

Animal ID: 84D00155 Species: D Sex: MALE Group: CONTROLS

DATE	TIME	OPERATOR	WEIGHT (GRAMS)	CLINICAL OBSERVATIONS
2/14/85	10:35:52	0000337	421.0	NORMAL
3/14/85	9:43:16	0078478	407.0	NORMAL
4/11/85	10:20:00	0000337	412.0	NORMAL
5/09/85	9:33:44	0000337	425.0	NORMAL
6/06/85	10:15:38	0010186	425.0	NORMAL
7/02/85	9:16:34	0000337	427.0	NORMAL
8/01/85	9:55:32	0001576	423.0	NORMAL
8/29/85	10:12:18	0000337	423.0	NORMAL
9/26/85	10:04:52	0000337	432.0	NORMAL
10/24/85	10:22:28	0034567	437.0	NORMAL
11/21/85	16:11:50	0084799	424.0	NORMAL
12/19/85	9:59:28	0000337	426.0	NORMAL
1/16/86	11:02:58	0000337	413.0	NORMAL
2/03/86	8:09:36	0034567	387.0	NORMAL / EUTHANIZED

## Appendix F (cont.): INDIVIDUAL ANIMAL HISTORIES

PAGE 114  
DATE: 6/09/87  
TIME: 14:40:13  
EDS017 V4M11

STUDY: 0083009 ISOBUTYL 2-CYANOACRYLATE  
COMPOUND: ISOBUTYL 2-CYANOACRYLATE  
START DATE: 1/28/85

CARCINOGENICITY BIOASSAY OF ISOBUTYL 2-CYANO-  
ACRYLATE (IBC) IN MALE AND FEMALE RATS.

## AN.MAL HISTORY

Animal ID: 84D00156 Species: D Sex: MALE Group: 100 UL/ANM

DATE	TIME	OPERATOR	WEIGHT (GRAMS)	CLINICAL OBSERVATIONS
2/14/85	10:36:08	0000337	430.0	NORMAL
3/14/85	9:43:34	0078478	442.0	NORMAL
4/11/85	10:21:18	0000337	441.0	NORMAL
5/09/85	9:34:12	0000337	357.0	INTRABDOMINAL MASS VENTRAL TO LIVER SIZE LARGE
5/09/85	11:43:18	0000337		* No observations recorded.

PAGE 1150  
DATE: 6/09/87  
TIME: 14:40:13  
EDS017 V4M11

**Appendix F (cont.): INDIVIDUAL ANIMAL HISTORIES**

STUDY: 0083009  
COMPOUND: ISOBUTYL 2-CYANOACRYLATE  
START DATE: 1/28/85

CARCINOGENICITY BIOASSAY OF ISOBUTYL 2-CYANO-  
ACRYLATE (IBC) IN MALE AND FEMALE RATS.

**ANIMAL HISTORY**

Animal ID: 84D00157 Species: D Sex: MALE Group: 100 UL/ANM

DATE	TIME	OPERATOR	WEIGHT (GRAMS)	CLINICAL OBSERVATIONS
2/14/85	10:36:24	0000337	375.0	NORMAL
2/26/85	8:01:42	0078478		DEATH

## Appendix F (cont.): INDIVIDUAL ANIMAL HISTORIES

PAGE 116  
DATE: 6/09/87  
TIME: 14:40:13  
EDS017 VAM11

STUDY: 0083009  
COMPOUND: ISOBUTYL 2-CYANOACRYLATE  
START DATE: 1/28/85

CARCINOGENICITY BIOASSAY OF ISOBUTYL 2-CYANO-  
ACRYLATE (IBC) IN MALE AND FEMALE RATS.

ANIMAL HISTORY

Animal ID: 84D00150 Species: D Sex: MALE Group: CONTROLS

DATE	TIME	OPERATOR	WEIGHT (GRAMS)	CLINICAL OBSERVATIONS
2/14/85	10:36:44	0000337	382.0	NORMAL
3/14/85	12:10:32	0078478	386.0	NORMAL
4/11/85	10:22:10	0000337	393.0	NORMAL
5/09/85	9:39:20	0000337	401.0	NORMAL
6/06/85	10:16:04	0010186	387.0	NORMAL
7/02/85	9:17:02	0000337	419.0	NORMAL
8/0./85	9:55:48	0001576	417.0	NORMAL
8/29/85	10:12:28	0000337	413.0	NORMAL
9/26/85	10:05:18	0000337	418.0	NORMAL
10/24/85	10:22:50	0034567	423.0	NORMAL
11/21/85	16:12:14	0084799	413.0	NORMAL
12/19/85	9:59:42	0000337	406.0	NORMAL
1/16/86	11:03:14	0000337	399.0	NORMAL
2/03/86	8:11:06	0034567	380.0	NORMAL / EUTHANIZED

**Appendix F (cont.): INDIVIDUAL ANIMAL HISTORIES**

CARCINOGENICITY BIOASSAY OF ISOBUTYL 2-CYANO-  
 ACRYLATE (IBC) IN MALE AND FEMALE RATS.

STUDY: 0083009  
 COMPOUND: ISOBUTYL 2-CYANOACRYLATE  
 START DATE: 1/28/85

ANIMAL HISTORY

Animal ID: 84D00160 Species: D Sex: MALE Group: 10 UL/ANM

DATE	TIME	OPERATOR	WEIGHT (GRAMS)	CLINICAL OBSERVATIONS
2/14/85	10:37:06	0000337	453.0	NORMAL
3/05/85	8:20:56	0000337		STAIN BROWN NOSE SLIGHT
3/13/85	8:07:34	0067831		NORMAL
3/14/85	12:11:20	0078478	451.0	NORMAL
4/11/85	10:22:46	0000337	453.0	NORMAL
5/09/85	9:39:38	0000337	462.0	NORMAL
6/06/85	10:16:20	0010186	475.0	NORMAL
7/02/85	9:17:28	0000337	478.0	NORMAL
8/01/85	9:56:06	0001576	482.0	NORMAL
8/29/85	10:12:46	0000337	470.0	NORMAL
9/26/85	10:05:40	0000337	476.0	NORMAL
10/24/85	10:23:06	0034567	479.0	NORMAL
11/21/85	16:12:42	0084799	469.0	NORMAL
12/19/85	9:59:56	0000337	472.0	NORMAL
1/16/86	11:03:36	0000337	459.0	NORMAL
2/03/86	8:12:48	0034567	430.0	NORMAL / EUTHANIZED





## Appendix F (cont.): INDIVIDUAL ANIMAL HISTORIES

PAGE 118  
DATE: 6/09/87  
TIME: 14:40:13  
EDS017 V4M11

STUDY: 0083009 ISOBUTYL 2-CYANOACRYLATE  
COMPOUND: ISOBUTYL 2-CYANOACRYLATE  
START DATE: 1/28/85

CARCINOGENICITY BIOASSAY OF ISOBUTYL 2-CYANO-  
ACRYLATE (IBC) IN MALE AND FEMALE RATS.

## ANIMAL HISTORY

Animal ID: 84D00161 Species: D Sex: MALE Group: 100 UL/ANM

DATE	TIME	OPERATOR	WEIGHT (GRAMS)	CLINICAL OBSERVATIONS
2/14/85	10:37:38	0000337	357.0	CORNEAL OPACITY LEFT EYE MODERATE
3/14/85	12:12:14	0078478	358.0	CORNEAL OPACITY LEFT EYE MODERATE
4/11/85	10:23:38	0000337	360.0	CORNEAL OPACITY LEFT EYE MODERATE
5/09/85	9:39:54	0000337	369.0	CORNEAL OPACITY LEFT EYE MODERATE
6/06/85	10:16:52	0010186	375.0	CORNEAL OPACITY LEFT EYE MODERATE
7/02/85	9:17:56	0000337	370.0	CORNEAL OPACITY LEFT EYE MODERATE
8/01/85	9:56:32	0001576	369.0	CORNEAL OPACITY LEFT EYE MODERATE
8/29/85	10:13:30	0000337	369.0	CORNEAL OPACITY LEFT EYE MODERATE
9/26/85	10:05:56	0000337	372.0	CORNEAL OPACITY LEFT EYE MODERATE
10/24/85	10:23:22	0034567	379.0	CORNEAL OPACITY LEFT EYE MODERATE
11/21/85	16:13:08	0084799	356.0	CORNEAL OPACITY LEFT EYE MODERATE
12/19/85	10:00:14	0000337	358.0	CORNEAL OPACITY LEFT EYE MODERATE, INTRAABDOMINAL MASS VENTRAL TO LIVER SIZE MEDIUM
1/16/86	11:03:54	0084799	358.0	CORNEAL OPACITY LEFT EYE MODERATE, INTRAABDOMINAL MASS VENTRAL TO LIVER SIZE LARGE
2/03/86	8:15:56	0034567	327.0	CORNEAL OPACITY LEFT EYE MODERATE, EUTHANIZED

PAGE 1190  
 DATE: 6/09/87  
 TIME: 14:40:13  
 EDS017 V4M11

**Appendix F (cont.): INDIVIDUAL ANIMAL HISTORIES**

STUDY: 0083009 CARCINOGENICITY BIOASSAY OF ISOBUTYL 2-CYANO-  
 COMPOUND: ISOBUTYL 2-CYANOACRYLATE ACRYLATE (IBC) IN MALE AND FEMALE RATS.  
 START DATE: 1/28/85

ANIMAL HISTORY

Animal ID: 84D00162 Species: D Sex: MALE Group: CONTROLS

DATE	TIME	OPERATOR	WEIGHT (GRAMS)	CLINICAL OBSERVATIONS
2/14/85	10:38:20	0000337	375.0	NORMAL
3/05/85	8:22:24	0000337		STAIN BROWN NOSE MODERATE
3/13/85	8:09:26	0067831		NORMAL
3/14/85	12:12:34	0078478	380.0	NORMAL
4/11/85	10:24:26	0000337	388.0	NORMAL
5/09/85	9:40:12	0000337	394.0	NORMAL
6/06/85	10:17:24	0010186	395.0	NORMAL
7/02/85	9:18:20	0000337	395.0	NORMAL
8/01/85	9:56:52	0001576	394.0	NORMAL
8/29/85	10:14:02	0000337	390.0	NORMAL
9/26/85	10:06:32	0000337	398.0	NORMAL
10/24/85	10:23:38	0034567	401.0	NORMAL
11/21/85	16:13:48	0084799	383.0	NORMAL
12/19/85	10:01:34	0000337	382.0	NORMAL
1/16/86	11:04:46	0000337	382.0	NORMAL
2/03/86	8:18:08	0034567	356.0	NORMAL / EUTHANIZED

## Appendix F (cont.): INDIVIDUAL ANIMAL HISTORIES

PAGE 120  
DATE: 6/09/87  
TIME: 14:40:13  
EDS017 V4M11

STUDY: 0083009  
COMPOUND: ISOBUTYL 2-CYANOACRYLATE  
START DATE: 1/28/85

CARCINOGENICITY BIOASSAY OF ISOBUTYL 2-CYANO-  
ACRYLATE (IBC) IN MALE AND FEMALE RATS.

## ANIMAL HISTORY

Animal ID: 84D00163 Species: D Sex: MALE Group: CONTROLS

DATE	TIME	OPERATOR	WEIGHT (GRAMS)	CLINICAL OBSERVATIONS
2/14/85	10:38:34	0000337	448.0	NORMAL
3/14/85	12:12:54	0078478	444.0	NORMAL
4/11/85	10:25:16	0000337	449.0	NORMAL
5/09/85	9:40:30	0000337	460.0	NORMAL
6/06/85	10:17:42	0010186	479.0	NORMAL
7/02/85	9:18:48	0000337	472.0	NORMAL
8/01/85	9:57:10	0001576	478.0	NORMAL
8/29/85	10:14:22	0000337	465.0	NORMAL
9/26/85	10:06:48	0000337	471.0	NORMAL
10/24/85	10:23:54	0034567	479.0	NORMAL
11/21/85	16:14:06	0084799	475.0	NORMAL
12/19/85	10:01:48	0000337	475.0	NORMAL
1/16/86	11:05:06	0000337	444.0	NORMAL
2/03/86	8:20:00	0034567	391.0	INTRABDOMINAL MASS SPLENIC SIZE MEDIUM, PALLOR MODERATE, EUTHANIZED

PAGE 121  
 DATE: 6/09/87  
 TIME: 14:40:13  
 EDS017 V4M11.

**Appendix F (cont.): INDIVIDUAL ANIMAL HISTORIES**

STUDY: 0083009  
 COMPOUND: ISOBUTYL 2-CYANOACRYLATE  
 START DATE: 1/28/85  
 CARCINOGENICITY BIOASSAY OF ISOBUTYL 2-CYANO-  
 ACRYLATE (IBC) IN MALE AND FEMALE RATS.

**ANIMAL HISTORY**

Animal ID: 84D00164 Species: D Sex: MALE Group: CONTROLS

DATE	TIME	OPERATOR	WEIGHT (GRAMS)	CLINICAL OBSERVATIONS
2/14/85	10:39:00	0000337	398.0	IRRITABLE SLIGHT
2/25/85	7:56:34	0000337		NORMAL
3/14/85	12:15:38	0078478	404.0	NORMAL
4/11/85	10:26:08	0000337	410.0	NORMAL
5/09/85	9:40:50	0000337	423.0	NORMAL
6/06/85	10:18:02	0010186	429.0	NORMAL
7/02/85	9:19:16	0000337	430.0	NORMAL
8/01/85	9:57:30	0001576	429.0	NORMAL
8/29/85	10:14:42	0000337	426.0	NORMAL
9/26/85	10:07:10	0000337	435.0	NORMAL
10/24/85	10:24:14	0034567	431.0	NORMAL
11/07/85	10:27:50	0000337		CONJUNCTIVITIS BOTH EYE MODERATE, STAIN BROWN NOSE MODERATE
11/08/85	8:08:10	0000337		CONJUNCTIVITIS BOTH EYE MODERATE, STAIN BROWN NOSE MODERATE, STAIN BROWN PERIANAL SLIGHT, WEIGHT LOSS MARKED

PAGE 122  
 DATE: 6/09/87  
 TIME: 14:40:13  
 EDS017 V4M11

**Appendix F (cont.): INDIVIDUAL ANIMAL HISTORIES**

STUDY: 0083009  
 COMPOUND: ISOBUTYL 2-CYANOACRYLATE  
 START DATE: 1/28/85

CARCINOGENICITY BIOASSAY OF ISOBUTYL 2-CYANO-  
 ACRYLATE (IBC) IN MALE AND FEMALE RATS.

ANIMAL HISTORY

Animal ID: 84D00166 Species: D Sex: MALE Group: CONTROLS

DATE	TIME	OPERATOR	WEIGHT (GRAMS)	CLINICAL OBSERVATIONS
2/14/85	10:39:32	0000337	354.0	NORMAL
3/14/85	12:16:02	0078478	354.0	CORNEAL OPACITY LEFT EYE SLIGHT
4/11/85	10:26:58	0000337	355.0	CORNEAL OPACITY LEFT EYE SLIGHT
5/09/85	9:41:18	0000337	360.0	CORNEAL OPACITY LEFT EYE SLIGHT
6/06/85	10:18:26	0010186	371.0	CORNEAL OPACITY LEFT EYE SLIGHT
7/02/85	9:19:40	0000337	374.0	CORNEAL OPACITY LEFT EYE SLIGHT
8/01/85	9:57:46	0001576	381.0	SUBCUTANEOUS MASS LEFT SIDE SIZE SMALL, CORNEAL OPACITY LEFT EYE SLIGHT
8/29/85	10:14:58	0000337	382.0	CORNEAL OPACITY LEFT EYE SLIGHT, SUBCUTANEOUS MASS LEFT SIDE MEDIUM
9/26/85	10:08:32	0000337	392.0	CORNEAL OPACITY LEFT EYE SLIGHT, SUBCUTANEOUS MASS RIGHT SIDE SIZE LARGE
10/17/85	11:13:30	0000337		CORNEAL OPACITY LEFT EYE SLIGHT, SUBCUTANEOUS MASS RIGHT SIDE SIZE LARGE

**Appendix F (cont.): INDIVIDUAL ANIMAL HISTORIES**

STUDY: 0083009  
 COMPOUND: ISOBUTYL 2-CYANOACRYLATE  
 START DATE: 1/28/85  
 CARCINOGENICITY BIOASSAY OF ISOBUTYL 2-CYANO-  
 ACRYLATE (IBC) IN MALE AND FEMALE RATS.

ANIMAL HISTORY

Animal ID: 84D00168 Species: D Sex: MALE Group: 10 UL/ANN

DATE	TIME	OPERATOR	WEIGHT (GRAMS)	CLINICAL OBSERVATIONS
2/14/85	10:39:56	0000337	393.0	NORMAL
3/14/85	12:17:38	0078478	399.0	NORMAL
4/11/85	10:28:08	0000337	402.0	NORMAL
5/09/85	9:41:46	0000337	404.0	NORMAL
6/06/85	10:18:44	0010186	409.0	NORMAL
7/02/85	9:20:06	0000337	411.0	NORMAL
8/01/85	10:00:06	0001576	416.0	NORMAL
8/29/85	10:16:02	0000337	416.0	NORMAL
9/26/85	10:09:42	0000337	418.0	NORMAL
10/24/85	10:24:32	0034567	431.0	NORMAL
11/21/85	16:14:28	0084799	415.0	NORMAL
12/19/85	10:02:10	0000337	411.0	NORMAL
1/16/86	11:05:32	0000337	410.0	NORMAL
2/03/86	8:24:20	0034567	382.0	NORMAL / EUTHANIZED

## Appendix F (cont.): INDIVIDUAL ANIMAL HISTORIES

PAGE 124  
DATE: 6/09/87  
TIME: 14:40:13  
EDS017 V4M11

STUDY: 0083009 ISOBUTYL 2-CYANOACRYLATE CARCINOGENICITY BIOASSAY OF ISOBUTYL 2-CYANO-  
COMPOUND: ISOBUTYL 2-CYANOACRYLATE ACRYLATE (IBC) IN MALE AND FEMALE RATS.  
START DATE: 1/28/85

## ANIMAL HISTORY

Animal ID: 84D00169 Species: D Sex: MALE Group: 10 UL/ANM

DATE	TIME	OPERATOR	WEIGHT (GRAMS)	CLINICAL OBSERVATIONS
2/14/85	10:40:12	0000337	387.0	NORMAL
3/14/85	12:18:00	0078478	399.0	NORMAL
4/11/85	10:28:50	0000337	397.0	NORMAL
4/17/85	7:41:46	0000337		STAIN BROWN NOSE SLIGHT
5/02/85	6:52:16	0000337		NORMAL
5/09/85	9:42:04	0000337	404.0	NORMAL
6/06/85	10:19:10	0010186	412.0	NORMAL
7/02/85	9:20:32	0000337	416.0	NORMAL
8/01/85	10:00:38	0001576	429.0	NORMAL
8/29/85	10:16:54	0000337	423.0	NORMAL
9/26/85	10:10:06	0000337	422.0	NORMAL
10/22/85	8:59:48	0072808		CORNEAL OPACITY RIGHT EYE MODERATE
10/24/85	10:24:48	0034567	441.0	CORNEAL OPACITY RIGHT EYE MODERATE
11/21/85	16:14:42	0084799	425.0	CORNEAL OPACITY RIGHT EYE MODERATE
12/19/85	10:02:30	0000337	425.0	OPAQUE LENS RIGHT EYE MODERATE
1/16/86	11:05:52	0000337	414.0	OPAQUE LENS RIGHT EYE MARKED
2/05/86	7:39:56	0034567	390.0	OPAQUE LENS RIGHT EYE MARKED, EUTHANIZED

PAGE 125 @  
DATE: 6/09/87 ct  
TIME: 14:40:13 a l.  
EDS017 V4M11

**Appendix F (cont.): INDIVIDUAL ANIMAL HISTORIES**

STUDY: 0083009  
COMPOUND: ISOBUTYL 2-CYANOACRYLATE  
START DATE: 1/28/85

Species: D Sex: MALE Group: CONTROLS

CARCINOGENICITY BIOASSAY OF ISOBUTYL 2-CYANO-  
ACRYLATE (IBC) IN MALE AND FEMALE RATS.

ANIMAL HISTORY

Animal ID: 84D00170

Animal ID: 84D00170 Species: D Sex: MALE Group: CONTROLS

WEIGHT

CLINICAL OBSERVATIONS

DATE	TIME	OPERATOR	WEIGHT (GRAMS)	CLINICAL OBSERVATIONS
2/14/85	10:40:34	0000337	421.0	NORMAL
3/14/85	12:18:20	0078478	419.0	NORMAL
4/05/85	7:59:10	0000337		IRRITABLE SLIGHT SCALING BACK MODERATE
4/09/85	8:58:24	0000337		SCALING BACK MARKED
4/11/85	10:29:28	0000337	409.0	SCALING BACK MARKED
4/23/85	9:36:28	0000337		SCALING BACK MARKED



**Appendix F (cont.): INDIVIDUAL ANIMAL HISTORIES**

PAGE 126  
 DATE: 6/09/87  
 TIME: 14:40:13  
 EDS017 V4M11

STUDY: 0083009  
 COMPOUND: ISOBUTYL 2-CYANOACRYLATE  
 START DATE: 1/28/85

CARCINOGENICITY BIOASSAY OF ISOBUTYL 2-CYANO-  
 ACRYLATE (IBC) IN MALE AND FEMALE RATS.

ANIMAL HISTORY

Animal ID: 84D00171 Species: D Sex: MALE Group: 10 UL/ANM

DATE	TIME	OPERATOR	WEIGHT (GRAMS)	CLINICAL OBSERVATIONS
2/14/85	10:40:58	0000337	404.0	NORMAL
3/14/85	12:18:40	0078478	412.0	NORMAL
4/11/85	10:30:20	0000337	410.0	NORMAL
5/09/85	9:42:58	0000337	419.0	NORMAL
6/06/85	10:19:32	0010186	423.0	INTRAABDOMINAL MASS VENTRAL TO LIVER SIZE LARGE
7/02/85	9:21:02	0000337	421.0	INTRAABDOMINAL MASS VENTRAL TO LIVER SIZE LARGE
8/01/85	10:00:56	0001576	425.0	INTRAABDOMINAL MASS VENTRAL TO LIVER SIZE LARGE
8/29/85	10:17:14	0000337	413.0	INTRAABDOMINAL MASS VENTRAL TO LIVER SIZE MEDIUM
9/26/85	10:10:30	0000337	406.0	INTRAABDOMINAL MASS VENTRAL TO LIVER SIZE LARGE
10/24/85	10:25:16	0034567	407.0	INTRAABDOMINAL MASS VENTRAL TO LIVER SIZE LARGE
11/21/85	16:15:04	0084799	393.0	INTRAABDOMINAL MASS VENTRAL TO LIVER SIZE LARGE
12/19/85	10:03:12	0000337	393.0	INTRAABDOMINAL MASS SPLENIC SIZE LARGE
1/16/86	12:31:16	0000337	387.0	SPLENIC MASS SIZE LARGE
2/05/86	7:42:18	0034567	358.0	INTRAABDOMINAL MASS VENTRAL TO LIVER SIZE LARGE, EUTHANIZED

**Appendix F (cont.): INDIVIDUAL ANIMAL HISTORIES**

STUDY: 0083009  
 COMPOUND: ISOBUTYL 2-CYANOACRYLATE  
 START DATE: 1/28/85  
 CARCINOGENICITY BIOASSAY OF ISOBUTYL 2-CYANO-  
 ACRYLATE (IBC) IN MALE AND FEMALE RATS.

ANIMAL HISTORY

Animal ID: 84D00172 Species: D Sex: MALE Group: 100 UL/ANN

DATE	TIME	OPERATOR	WEIGHT (GRAMS)	CLINICAL OBSERVATIONS
2/07/85	10:54:44	0010186		STAIN BROWN NOSE MODERATE
2/14/85	10:41:12	0000337	373.0	NORMAL
3/14/85	12:19:02	0078478	380.0	NORMAL
4/11/85	10:31:08	0000337	383.0	NORMAL
5/09/85	9:43:18	0000337	386.0	CORNEAL OPACITY LEFT EYE MODERATE
6/06/85	10:21:38	0010186	394.0	CORNEAL OPACITY LEFT EYE MODERATE
7/02/85	9:22:06	0000337	399.0	CORNEAL OPACITY LEFT EYE MODERATE
8/01/85	10:01:56	0001576	405.0	CORNEAL OPACITY LEFT EYE SLIGHT
8/29/85	10:18:22	0000337	408.0	CORNEAL OPACITY LEFT EYE SLIGHT
9/26/85	10:11:22	0000337	407.0	CORNEAL OPACITY LEFT EYE SLIGHT, INTRAABDOMINAL MASS VENTRAL TO LIVER SIZE MEDIUM
10/24/85	10:25:52	0034567	415.0	CORNEAL OPACITY LEFT EYE SLIGHT, INTRAABDOMINAL MASS VENTRAL TO LIVER SIZE MEDIUM
11/21/85	16:15:44	0084799	398.0	CORNEAL OPACITY LEFT EYE SLIGHT, INTRAABDOMINAL MASS VENTRAL TO LIVER SIZE MEDIUM
12/19/85	10:08:48	0000337	393.0	CORNEAL OPACITY LEFT EYE SLIGHT, INTRAABDOMINAL MASS VENTRAL TO LIVER SIZE MEDIUM
1/16/86	12:32:54	0000337	369.0	CORNEAL OPACITY LEFT EYE SLIGHT, INTRAABDOMINAL MASS VENTRAL TO LIVER SIZE MEDIUM
1/22/86	9:11:24	0000337		DEATH

**Appendix F (cont.): INDIVIDUAL ANIMAL HISTORIES**

PAGE 128  
 DATE: 6/09/87  
 TIME: 14:40:13  
 EDS017 V4M11

STUDY: 0083009  
 COMPOUND: ISOBUTYL 2-CYANOACRYLATE  
 START DATE: 1/28/85  
 CARCINOGENICITY BIOASSAY OF ISOBUTYL 2-CYANO-  
 ACRYLATE (IBC) IN MALE AND FEMALE RATS.

ANIMAL HISTORY

Animal ID: 84000173 Species: D Sex: MALE Group: CONTROLS

DATE	TIME	OPERATOR	WEIGHT (GRAMS)	CLINICAL OBSERVATIONS
2/14/85	10:41:36	0000337	458.0	CORNEAL OPACITY LEFT EYE SLIGHT
3/06/85	8:45:40	0000337		CORNEAL OPACITY LEFT EYE SLIGHT, STAIN BROWN NOSE SLIGHT
3/13/85	8:12:42	0067831		CORNEAL OPACITY LEFT EYE SLIGHT
3/14/85	12:19:24	0078478	461.0	CORNEAL OPACITY LEFT EYE SLIGHT
4/05/85	8:02:42	0000337		CORNEAL OPACITY LEFT EYE MARKED
4/11/85	10:31:48	0000337	473.0	PROLAPSED LENS LEFT EYE MODERATE, OPAQUE LENS LEFT EYE MODERATE
5/09/85	9:43:50	0000337	466.0	PROLAPSED LENS LEFT EYE MARKED, OPAQUE LENS LEFT EYE MARKED
6/06/85	10:23:12	0010186	471.0	PROLAPSED LENS LEFT EYE MARKED, OPAQUE LENS LEFT EYE MARKED
7/02/85	9:22:44	0000337	474.0	PROLAPSED LENS LEFT EYE MARKED, OPAQUE LENS LEFT EYE MARKED
8/01/85	10:02:36	0001576	481.0	PROLAPSED LENS LEFT EYE MARKED, OPAQUE LENS LEFT EYE MARKED, HYPHEMIA LEFT EYE MODERATE
8/29/85	10:18:46	0000337	479.0	HYPHEMIA LEFT EYE MODERATE, PROLAPSED LENS LEFT EYE MARKED, OPAQUE LENS LEFT EYE MARKED
9/26/85	10:12:58	0000337	473.0	OPAEQUE LENS LEFT EYE MARKED
10/24/85	10:28:02	0034567	470.0	OPAEQUE LENS LEFT EYE MARKED
11/21/85	16:17:04	0084799	466.0	OPAEQUE LENS LEFT EYE MARKED
12/19/85	10:27:42	0000337	466.0	OPAEQUE LENS LEFT EYE MARKED
1/16/86	12:33:36	0000337	458.0	OPAEQUE LENS MARKED, CYST DORSAL SMALL
2/05/86	7:44:52	0034567	421.0	SMALL LENS LEFT EYE MODERATE, EUTHANIZED

**Appendix F (cont.): INDIVIDUAL ANIMAL HISTORIES**

STUDY: 0083009  
 COMPOUND: ISOBUTYL 2-CYANOACRYLATE  
 START DATE: 1/28/85  
 CARCINOGENICITY BIOASSAY OF ISOBUTYL 2-CYANO-  
 ACRYLATE (IBC) IN MALE AND FEMALE RATS.  
 ANIMAL HISTORY

Animal ID: 84000174 Species: D Sex: MALE Group: 10 UL/ANM

DATE	TIME	OPERATOR	WEIGHT (GRAMS)	CLINICAL OBSERVATIONS
2/14/85	10:42:54	0000337	412.0	NORMAL
3/14/85	12:19:54	0078478	415.0	NORMAL
4/11/85	10:34:06	0000337	420.0	NORMAL
5/09/85	9:45:08	0000337	424.0	NORMAL
6/06/85	10:23:54	0010186	424.0	NORMAL
7/02/85	9:24:02	0000337	425.0	NORMAL
8/01/85	10:03:28	0001576	430.0	NORMAL
8/29/85	10:21:04	0000337	425.0	NORMAL
9/26/85	10:13:50	0000337	413.0	NORMAL
10/24/85	10:28:26	0034567	424.0	NORMAL
11/21/85	16:17:48	0084799	406.0	NORMAL
12/19/85	10:10:30	0000337	410.0	NORMAL
1/16/86	12:35:14	0000337	399.0	NORMAL
2/05/86	7:46:56	0034567	376.0	NORMAL / EUTHANIZED

PAGE 100  
 DATE: 6/09/87  
 TIME: 14:40:13  
 EDS017 V4M11

**Appendix F (cont.): INDIVIDUAL ANIMAL HISTORIES**

STUDY: 0083009 ISOBUTYL 2-CYANOACRYLATE  
 COMPOUND: ISOBUTYL 2-CYANOACRYLATE  
 START DATE: 1/28/85

CARCINOGENICITY BIOASSAY OF ISOBUTYL 2-CYANO-  
 ACRYLATE (IBC) IN MALE AND FEMALE RATS.

ANIMAL HISTORY

Animal ID: 84D00175 Species: D Sex: MALE Group: CONTROLS

DATE	TIME	OPERATOR	WEIGHT (GRAMS)	CLINICAL OBSERVATIONS
2/14/85	10:43:14	0000337	415.0	NORMAL
3/14/85	12:20:12	0078478	419.0	NORMAL
4/11/85	10:34:38	0000337	425.0	NORMAL
5/09/85	9:45:30	0000337	433.0	NORMAL
6/06/85	10:24:16	0010186	433.0	NORMAL
7/02/85	9:24:34	0000337	440.0	NORMAL
8/01/85	10:03:42	0001576	445.0	NORMAL
8/29/85	10:21:28	0000337	449.0	NORMAL
9/26/85	10:14:16	0000337	450.0	NORMAL
10/24/85	10:28:46	0034567	456.0	NORMAL
11/21/85	16:18:12	0084799	445.0	NORMAL
12/19/85	10:10:48	0000337	438.0	NORMAL
1/16/86	12:35:30	0000337	444.0	NORMAL
2/05/86	7:47:46	0034567	428.0	NORMAL / EUTHANIZED

**Appendix F (cont.): INDIVIDUAL ANIMAL HISTORIES**

STUDY: 0083009  
 COMPOUND: ISOBUTYL 2-CYANOACRYLATE  
 START DATE: 1/28/85  
 CARCINOGENICITY BIOASSAY OF ISOBUTYL 2-CYANO-  
 ACRYLATE (IBC) IN MALE AND FEMALE RATS.  
 ANIMAL HISTORY

Animal ID: 84D00176 Species: D Sex: MALE Group: 10 UL/ANM

DATE	TIME	OPERATOR	WEIGHT (GRAMS)	CLINICAL OBSERVATIONS
2/14/85	10:44:10	0000337	355.0	NORMAL
3/14/85	12:20:30	0078478	358.0	NORMAL
4/11/85	10:36:30	0000337	364.0	NORMAL
5/09/85	9:45:50	0000337	366.0	NORMAL
6/06/85	10:24:34	0010186	378.0	NORMAL
7/02/85	9:25:32	0000337	372.0	INTRABDOMINAL MASS VENTRAL TO LIVER SIZE MEDIUM
8/01/85	10:04:04	0001576	371.0	INTRABDOMINAL MASS VENTRAL TO LIVER SIZE SMALL
8/15/85	7:06:20	0000337		INTRABDOMINAL MASS VENTRAL TO LIVER SIZE MEDIUM
8/29/85	11:41:26	0010186	369.0	INTRABDOMINAL MASS VENTRAL TO LIVER SIZE MEDIUM
9/26/85	10:14:34	0084799	369.0	INTRABDOMINAL MASS VENTRAL TO LIVER SIZE SMALL
10/16/85	9:49:04	0000337		INTRABDOMINAL MASS VENTRAL TO LIVER SIZE SMALL
10/24/85	10:29:02	0034567	370.0	INTRABDOMINAL MASS VENTRAL TO LIVER SIZE LARGE
11/21/85	16:18:54	0084799	382.0	INTRABDOMINAL MASS VENTRAL TO LIVER SIZE MEDIUM
12/19/85	10:11:16	0000337	389.0	INTRABDOMINAL MASS VENTRAL TO LIVER SIZE LARGE
1/16/86	12:35:46	0000337	373.0	INTRABDOMINAL MASS VENTRAL TO LIVER SIZE LARGE
2/05/86	7:49:04	0034567	326.0	INTRABDOMINAL MASS SPLENIC SIZE LARGE, PALLOR MARKED, EUTHANIZED

**Appendix F (cont.): INDIVIDUAL ANIMAL HISTORIES**

PAGE 13  
 DATE: 6/03/87  
 TIME: 14:40:13  
 EDS017 VqR11

STUDY: 0083009  
 COMPOUND: ISOBUTYL 2-CYANOACRYLATE  
 START DATE: 1/28/85

CARCINOGENICITY BIOASSAY OF ISOBUTYL 2-CYANOACRYLATE (IBC) IN MALE AND FEMALE RATS.

ANIMAL HISTORY

Animal ID: 84D00177 Species: D Sex: MALE Group: 100 UL/ANN

DATE	TIME	OPERATOR	WEIGHT (GRAMS)	CLINICAL OBSERVATIONS
2/14/85	10:44:26	0000337	384.0	NORMAL
3/14/85	12:21:06	0078478	388.0	NORMAL
4/11/85	10:37:08	0000337	400.0	NORMAL
5/09/85	9:46:08	0000337	402.0	NORMAL
6/06/85	10:24:50	0010186	406.0	NORMAL
7/02/85	9:28:00	0000337	411.0	NORMAL
8/01/85	10:04:40	0001576	406.0	NORMAL
8/29/85	11:45:16	0010186	417.0	NORMAL
9/26/85	10:15:38	0000337	416.0	NORMAL
10/24/85	10:29:54	0034567	421.0	NORMAL
11/21/85	16:19:32	0084799	417.0	NORMAL
12/19/85	10:11:58	0000337	415.0	NORMAL
1/16/86	12:36:32	0000337	397.0	INTRABDOMINAL MASS VENTRAL TO LIVER SIZE MEDIUM
2/05/86	7:51:50	0034567	380.0	INTRABDOMINAL MASS VENTRAL TO LIVER SIZE MEDIUM, EUTHANIZED

**Appendix F (cont.): INDIVIDUAL ANIMAL HISTORIES**

STUDY: 0083009  
 COMPOUND: ISOBUTYL 2-CYANOACRYLATE  
 START DATE: 1/28/85

CARCINOGENICITY BIOASSAY OF ISOBUTYL 2-CYANO-  
 ACRYLATE (IBC) IN MALE AND FEMALE RATS.

ANIMAL HISTORY

Animal ID: 84D00178 Species: D Sex: MALE Group: CONTROLS

DATE	TIME	OPERATOR	WEIGHT (GRAMS)	CLINICAL OBSERVATIONS
2/14/85	10:44:46	0000337	405.0	PAPILLOMA NOSE SLIGHT
3/14/85	12:21:28	0078478	411.0	PAPILLOMA NOSE SLIGHT
4/11/85	10:37:42	0000337	425.0	PAPILLOMA NOSE SLIGHT
5/09/85	9:46:30	0000337	431.0	PAPILLOMA NOSE SLIGHT
6/06/85	10:25:06	0010186	445.0	PAPILLOMA NOSE (RIGHT SIDE) SLIGHT
7/02/85	9:28:26	0000337	446.0	PAPILLOMA NOSE (RIGHT SIDE) SLIGHT
8/01/85	10:04:56	0001576	452.0	PAPILLOMA NOSE (RIGHT SIDE) SLIGHT, EAR SCAB RIGHT SIDE SLIGHT
8/29/85	11:45:42	0010186	456.0	STAIN NOSE BROWN SLIGHT
9/26/85	10:15:58	0000337	457.0	PAPILLOMA RIGHT NARES SLIGHT
10/24/85	10:30:24	0034567	459.0	PAPILLOMA RIGHT NARES SLIGHT
11/21/85	16:19:48	0084799	449.0	NASAL PAPILLOMA SMALL
12/19/85	10:12:12	0000337	444.0	PAPILLOMA NOSE SIZE SMALL
1/16/86	12:37:46	0000337	445.0	PAPILLOMA NOSE SIZE SMALL
2/05/86	7:53:44	0034567	432.0	PAPILLOMA NOSE SIZE SMALL, EUTHANIZED



**Appendix F (cont.): INDIVIDUAL ANIMAL HISTORIES**

PAGE 134  
 DATE: 6/09/87  
 TIME: 14:40:13  
 EDS017 V4M11

STUDY: 0083009  
 COMPOUND: ISOBUTYL 2-CYANOACRYLATE  
 START DATE: 1/28/85

CARCINOGENICITY BIOASSAY OF ISOBUTYL 2-CYANO-  
 ACRYLATE (IBC) IN MALE AND FEMALE RATS.

ANIMAL HISTORY

Animal ID: 84D00179 Species: D Sex: MALE Group: CONTROLS

DATE	TIME	OPERATOR	WEIGHT (GRAMS)	CLINICAL OBSERVATIONS
2/14/85	10:46:00	0000337	437.0	NORMAL
3/14/85	12:22:14	0078478	453.0	NORMAL
4/11/85	10:38:22	0000337	449.0	NORMAL
5/09/85	9:47:12	0000337	455.0	NORMAL
6/06/85	10:25:52	0010186	441.0	NORMAL
7/02/85	9:29:10	0000337	458.0	STAIN BROWN NOSE MODERATE
7/10/85	7:28:28	0000337		SUPURATING PREPUTIAL FISTULA LARGE
8/01/85	10:06:06	0001576	466.0	NORMAL
8/29/85	11:46:26	0010186	473.0	NORMAL
9/26/85	10:16:50	0000337	474.0	NORMAL
10/24/85	10:31:02	0034567	470.0	NORMAL
11/21/85	16:20:26	0084799	450.0	NORMAL
12/19/85	10:12:50	0000337	450.0	NORMAL
1/16/86	12:38:18	0000337	411.0	NORMAL
1/29/86	8:33:18	0034567	340.0	SPLENIC MASS SIZE LARGE, EMACIATED MARKED, PALLOR MODERATE, ROUGH COAT MODERATE, EUTHANIZED

**Appendix F (cont.): INDIVIDUAL ANIMAL HISTORIES**

STUDY: 0083009  
 COMPOUND: ISOBUTYL 2-CYANOACRYLATE  
 START DATE: 1/28/85  
 CARCINOGENICITY BIOASSAY OF ISOBUTYL 2-CYANO-  
 ACRYLATE (IBC) IN MALE AND FEMALE RATS.

Animal ID: 84D00180 Species: D Sex: MALE Group: 10 UL/ANM  
 ANIMAL HISTORY

Animal ID: 84D00180 Species: D Sex: MALE Group: 10 UL/ANM

DATE	TIME	OPERATOR	WEIGHT (GRAMS)	CLINICAL OBSERVATIONS
2/14/85	10:46:26	0000337	430.0	NORMAL
3/06/85	8:47:02	0000337		PAPILLOMA NOSE SMALL
3/14/85	12:22:30	0078478	427.0	PAPILLOMA NOSE SLIGHT
4/11/85	10:39:00	0000337	424.0	PAPILLOMA NOSE SLIGHT
5/08/85	8:03:16	0067831		NORMAL
5/09/85	9:47:54	0000337	431.0	PAPILLOMA NOSE SLIGHT
6/06/85	10:26:06	0010186	436.0	PAPILLOMA NOSE (DORSAL ASPECT) SLIGHT
7/02/85	9:29:48	0000337	438.0	PAPILLOMA NOSE (DORSAL ASPECT) SLIGHT
8/01/85	10:06:48	0001576	442.0	NORMAL
8/29/85	11:46:44	0010186	447.0	NORMAL
9/09/85	9:02:08	0000337		INTRABDOMINAL MASS MIDDLE ABDOMEN SIZE LARGE
9/09/85	12:04:16	0000337		* No observations recorded.

## Appendix F (cont.): INDIVIDUAL ANIMAL HISTORIES

PAGE 136  
DATE: 6/09/87  
TIME: 14:40:13  
EDS017 VAM11

STUDY: 0083009 ISOBUTYL 2-CYANOACRYLATE CARCINOGENICITY BIOASSAY OF ISOBUTYL 2-CYANO-  
COMPOUND: ISOBUTYL 2-CYANOACRYLATE ACRYLATE (IBC) IN MALE AND FEMALE RATS.  
START DATE: 1/28/85

## ANIMAL HISTORY

Animal ID: 84D00181 Species: D Sex: MALE Group: 100 UL/ANM

DATE	TIME	OPERATOR	WEIGHT (GRAMS)	CLINICAL OBSERVATIONS
2/14/85	10:46:40	0000337	432.0	SCAB RIGHT EAR MODERATE
3/13/85	8:15:32	0067831		NORMAL
3/14/85	12:23:24	0078478	446.0	NORMAL
4/11/85	10:39:54	0000337	445.0	INTRAABDOMINAL MASS VENTRAL TO LIVER, SIZE MEDIUM
4/17/85	7:50:22	0000337		INTRAABDOMINAL MASS VENTRAL TO LIVER, SIZE LARGE
4/25/85	8:47:30	0000337	446.0	INTRAABDOMINAL MASS VENTRAL TO LIVER, SIZE LARGE
5/09/85	9:48:36	0000337	442.0	INTRAABDOMINAL MASS VENTRAL TO LIVER, SIZE LARGE
5/10/85	9:53:28	0000337		* No observations recorded.

**Appendix F (cont.): INDIVIDUAL ANIMAL HISTORIES**

STUDY: 0083009  
 COMPOUND: ISOBUTYL 2-CYANOACRYLATE  
 START DATE: 1/28/85

CARCINOGENICITY BIORASSAY OF ISOBUTYL 2-CYANO-  
 ACRYLATE (IBC) IN MALE AND FEMALE RATS.

ANIMAL HISTORY

Animal ID: 84D00182 Species: D Sex: MALE Group: 10 UL/ANM

DATE	TIME	OPERATOR	WEIGHT (GRAMS)	CLINICAL OBSERVATIONS
2/14/85	10:47:28	0000337	450.0	NORMAL
3/14/85	12:23:58	0078478	447.0	NORMAL
4/11/85	10:43:18	0000337	445.0	NORMAL
5/09/85	9:50:42	0000337	458.0	NORMAL
6/06/85	10:26:36	0010186	456.0	NORMAL
7/02/85	9:31:08	0000337	458.0	NORMAL
8/01/85	10:07:34	0001576	459.0	NORMAL
8/29/85	11:47:02	0010186	454.0	NORMAL
9/26/85	10:17:28	0000337	450.0	NORMAL
10/24/85	10:31:26	0034567	452.0	NORMAL
11/07/85	10:36:16	0000337		INTRAABDOMINAL MASS VENTRAL TO LIVER SIZE MEDIUM
11/21/85	16:20:44	0084799	440.0	INTRAABDOMINAL MASS VENTRAL TO LIVER SIZE LARGE, PALLOR SLIGHT
11/24/85	12:38:26	0000337		INTRAABDOMINAL MASS VENTRAL TO LIVER SIZE LARGE, PALLOR MODERATE

## Appendix F (cont.): INDIVIDUAL ANIMAL HISTORIES

PAGE 138  
DATE: 6/09/87  
TIME: 14:40:13  
EDS017 V4M11

STUDY: 0083009 ISOBUTYL 2-CYANOACRYLATE CARCINOGENICITY BIOASSAY OF ISOBUTYL 2-CYANO-  
COMPOUND: ISOBUTYL 2-CYANOACRYLATE ACRYLATE (IBC) IN MALE AND FEMALE RATS.  
START DATE: 1/28/85

## ANIMAL HISTORY

DATE	TIME	OPERATOR	WEIGHT (GRAMS)	CLINICAL OBSERVATIONS
2/14/85	10:47:48	0000337	407.0	CONJUNCTIVITIS LEFT EYE MODERATE
2/20/85	7:39:06	0000337		CONJUNCTIVITIS LEFT EYE MARKED, CONJUNCTIVITIS RIGHT EYE MODERATE
3/06/85	8:48:58	0000337		CONJUNCTIVITIS LEFT EYE MODERATE, CONJUNCTIVITIS RIGHT EYE SLIGHT
3/14/85	12:24:20	0078478	416.0	CONJUNCTIVITIS LEFT EYE MODERATE
3/18/85	9:19:52	0034567		CONJUNCTIVITIS RIGHT EYE SLIGHT, CONJUNCTIVITIS LEFT EYE MODERATE
4/05/85	8:07:32	0000337		CONJUNCTIVITIS LEFT EYE MODERATE
4/11/85	10:43:46	0000337	411.0	CONJUNCTIVITIS LEFT EYE MODERATE
5/07/85	7:39:14	0000337		CONJUNCTIVITIS LEFT EYE MODERATE
5/09/85	9:51:02	0000337	425.0	CONJUNCTIVITIS LEFT EYE MARKED, CONJUNCTIVITIS RIGHT EYE SLIGHT
6/06/85	10:26:52	0010186	429.0	CONJUNCTIVITIS LEFT EYE MARKED, CONJUNCTIVITIS RIGHT EYE SLIGHT
7/02/85	9:31:38	0000337	419.0	CONJUNCTIVITIS LEFT EYE MARKED
7/10/85	7:31:28	0000337		CONJUNCTIVITIS LEFT EYE SLIGHT
8/01/85	10:08:00	0001576	434.0	CONJUNCTIVITIS RIGHT EYE SLIGHT
8/29/85	11:47:22	0010186	427.0	CONJUNCTIVITIS RIGHT EYE SLIGHT
9/26/85	10:19:32	0000337	428.0	NORMAL
10/24/85	10:31:44	0034567	447.0	NORMAL
11/07/85	10:38:52	0000337		CONJUNCTIVITIS RIGHT EYE MODERATE
11/21/85	16:22:20	0084799	448.0	NORMAL
12/19/85	10:13:02	0000337	447.0	CONJUNCTIVITIS RIGHT EYE MODERATE
1/16/86	12:39:00	0000337	442.0	CONJUNCTIVITIS RIGHT EYE SLIGHT
2/05/86	7:55:38	0034567	425.0	CONJUNCTIVITIS RIGHT EYE SLIGHT, EUTHANIZED

PAGE 139  
 DATE: 6/09/85  
 TIME: 14:40:13  
 EDS017 V4M1

**Appendix F (cont.): INDIVIDUAL ANIMAL HISTORIES**

STUDY: 0083009  
 COMPOUND: ISOBUTYL 2-CYANOACRYLATE  
 START DATE: 1/28/85

CARCINOGENICITY BIOASSAY OF ISOBUTYL 2-CYANO-  
 ACRYLATE (IBC) IN MALE AND FEMALE RATS.

ANIMAL HISTORY

Animal ID: 84D00185 Species: D Sex: MALE Group: 100 UL/ANM

DATE	TIME	OPERATOR	WEIGHT (GRAMS)	CLINICAL OBSERVATIONS
2/14/85	10:48:58	0000337	365.0	NORMAL
3/06/85	8:50:00	0000337		STAIN BROWN NOSE SLIGHT
3/13/85	8:16:40	0067031		NORMAL
3/14/85	12:24:54	0078478	361.0	NORMAL
4/11/85	10:45:08	0000337	366.0	NORMAL
5/09/85	9:52:28	0000337	374.0	NORMAL
6/06/85	10:27:12	0010186	378.0	NORMAL
7/02/85	9:32:22	0000337	367.0	NORMAL
8/01/85	10:08:28	001576	395.0	NORMAL
8/29/85	11:47:44	0010186	403.0	INTRABDOMINAL MASS VENTRAL TO LIVER SIZE SMALL
9/13/85	8:39:46	002920		INTRABDOMINAL MASS VENTRAL TO LIVER SIZE SMALL
9/26/85	10:20:14	0000337	398.0	INTRABDOMINAL MASS VENTRAL TO LIVER SIZE SMALL
10/24/85	10:32:08	0034567	400.0	INTRABDOMINAL MASS VENTRAL TO LIVER SIZE MEDIUM
11/21/85	16:23:04	0084799	387.0	INTRABDOMINAL MASS VENTRAL TO LIVER SIZE MEDIUM
12/19/85	10:13:30	0000337	402.0	INTRABDOMINAL MASS VENTRAL TO LIVER SIZE MEDIUM
1/02/86	9:38:36	0000337		INTRABDOMINAL MASS VENTRAL TO LIVER SIZE LARGE, PALLOR MARKED
1/03/86	9:59:22	0000337		INTRABDOMINAL MASS VENTRAL TO LIVER SIZE LARGE, PALLOR MARKED

**Appendix F (cont.): INDIVIDUAL ANIMAL HISTORIES**

PAGE 140  
 DATE: 6/09/87  
 TIME: 14:40:13  
 EDS017 V4M11

STUDY: 0083009 CARCINOGENICITY BIOASSAY OF ISOBUTYL 2-CYANO-  
 COMPOUND: ISOBUTYL 2-CYANOACRYLATE ACRYLATE (IBC) IN MALE AND FEMALE RATS.  
 START DATE: 1/28/85

ANIMAL HISTORY

Animal ID: 84D00186 Species: D Sex: MALE Group: 10 UL/ANM

DATE	TIME	OPERATOR	WEIGHT (GRAMS)	CLINICAL OBSERVATIONS
2/14/85	10:49:14	0000337	372.0	NORMAL
3/14/85	12:25:28	0078478	372.0	NORMAL
4/11/85	10:48:52	0000337	373.0	SCAB RIGHT EAR MODERATE
5/09/85	9:53:04	0000337	382.0	INTRAABDOMINAL MASS VENTRAL TO LIVER SIZE MEDIUM
6/06/85	10:27:32	0010186	387.0	INTRAABDOMINAL MASS VENTRAL TO LIVER SIZE MEDIUM
7/02/85	9:32:56	0000337	369.0	INTRAABDOMINAL MASS VENTRAL TO LIVER SIZE MEDIUM
8/01/85	10:08:44	0001576	387.0	INTRAABDOMINAL MASS VENTRAL TO LIVER SIZE MEDIUM
8/29/85	11:49:34	0010186	388.0	INTRAABDOMINAL MASS VENTRAL TO LIVER SIZE MEDIUM
9/26/85	10:21:04	0000337	392.0	INTRAABDOMINAL MASS VENTRAL TO LIVER SIZE MEDIUM
10/24/85	10:32:48	0034567	399.0	INTRAABDOMINAL MASS VENTRAL TO LIVER SIZE MEDIUM
11/21/85	16:23:42	0084799	388.0	INTRAABDOMINAL MASS VENTRAL TO LIVER SIZE SMALL
12/19/85	10:14:20	0000337	385.0	INTRAABDOMINAL MASS VENTRAL TO LIVER SIZE MEDIUM
1/16/86	12:39:28	0000337	386.0	INTRAABDOMINAL MASS VENTRAL TO LIVER SIZE MEDIUM
2/05/86	7:56:50	0034567	373.0	INTRAABDOMINAL MASS VENTRAL TO LIVER SIZE LARGE, EUTHANIZED

PAGE 141  
 DATE: 6/09/87  
 TIME: 14:40:13  
 EDS017 VAM111

**Appendix F (cont.): INDIVIDUAL ANIMAL HISTORIES**

STUDY: 0083009 ISOBUTYL 2-CYANOACRYLATE CARCINOGENICITY BIOASSAY OF ISOBUTYL 2-CYANO-  
 COMPOUND: ISOBUTYL 2-CYANOACRYLATE ACRYLATE (IBC) IN MALE AND FEMALE RATS.  
 START DATE: 1/28/85

**ANIMAL HISTORY**

Animal ID: 84000187 Species: D Sex: MALE Group: 100 UL/ANM

DATE	TIME	OPERATOR	WEIGHT (GRAMS)	CLINICAL OBSERVATIONS
2/14/85	10:49:36	0000337	383.0	NORMAL
3/14/85	12:25:48	0078478	386.0	NORMAL
4/11/85	10:50:26	0000337	392.0	NORMAL
5/09/85	9:55:00	0000337	398.0	NORMAL
6/06/85	10:29:04	0010186	410.0	NORMAL
7/02/85	9:33:38	0000337	381.0	NORMAL
8/01/85	10:09:10	0001576	431.0	NORMAL
8/29/85	11:50:14	0010186	420.0	NORMAL
9/26/85	10:21:56	0000337	414.0	NORMAL
10/24/85	10:33:32	0034567	419.0	NORMAL
11/21/85	16:24:28	0084799	411.0	NORMAL
12/12/85	9:36:38	0000337		INTRAABDOMINAL MASS VENTRAL TO LIVER SIZE LARGE
12/19/85	10:15:02	0000337	410.0	INTRAABDOMINAL MASS VENTRAL TO LIVER SIZE MEDIUM
1/16/86	12:40:16	0000337	406.0	INTRAABDOMINAL MASS VENTRAL TO LIVER SIZE MEDIUM
2/05/86	7:59:08	0034567	393.0	INTRAABDOMINAL MASS VENTRAL TO LIVER SIZE MEDIUM, EUTHANIZED



## Appendix F (cont.): INDIVIDUAL ANIMAL HISTORIES

PAGE 142  
DATE: 6/09/87  
TIME: 14:40:13  
EDS017 V4M11

STUDY: 0083009  
COMPOUND: ISOBUTYL 2-CYANOACRYLATE  
START DATE: 1/28/85

CARCINOGENICITY BIOASSAY OF ISOBUTYL 2-CYANO-  
ACRYLATE (IBC) IN MALE AND FEMALE RATS.

## ANIMAL HISTORY

Animal ID: 84D00188 Species: D Sex: MALE Group: 10 UL/ANM

DATE	TIME	OPERATOR	WEIGHT (GRAMS)	CLINICAL OBSERVATIONS
2/14/85	10:49:58	0000337	363.0	NORMAL
3/14/85	12:26:38	0078478	368.0	NORMAL
4/11/85	10:51:04	0000337	372.0	NORMAL
5/09/85	9:55:20	0000337	377.0	NORMAL
6/06/85	10:29:20	0010186	377.0	NORMAL
7/02/85	9:34:04	0000337	381.0	NORMAL
8/01/85	10:09:26	0001576	395.0	NORMAL
8/29/85	11:50:36	0010186	387.0	STAIN RIGHT EYE BROWN MARKED
9/26/85	10:22:22	0000337	387.0	NORMAL
10/24/85	10:33:46	0034567	391.0	NORMAL
11/21/85	16:24:54	0084799	378.0	NORMAL
12/19/85	10:16:16	0000337	380.0	NORMAL
1/16/86	12:41:10	0000337	375.0	NORMAL
2/05/86	8:01:34	0034567	355.0	NORMAL / EUTHANIZED

**Appendix F (cont.): INDIVIDUAL ANIMAL HISTORIES**

STUDY: 0083009  
 COMPOUND: ISOBUTYL 2-CYANOACRYLATE  
 START DATE: 1/28/85  
 CARCINOGENICITY BIOCASSAY OF ISOBUTYL 2-CYANO-  
 ACRYLATE (IBC) IN MALE AND FEMALE RATS.

ANIMAL HISTORY

Animal ID: 84D00189 Species: D Sex: MALE Group: CONTROLS

DATE	TIME	OPERATOR	WEIGHT (GRAMS)	CLINICAL OBSERVATIONS
2/14/85	10:50:18	0000337	419.0	NORMAL
3/14/85	12:27:08	0078478	422.0	NORMAL
4/11/85	10:51:34	0000337	433.0	NORMAL
5/09/85	9:55:40	0000337	437.0	NORMAL
6/06/85	10:29:38	0010186	445.0	NORMAL
7/02/85	9:34:34	0000337	439.0	NORMAL
8/01/85	10:09:38	0001576	446.0	NORMAL
8/29/85	11:51:22	0010186	442.0	NORMAL
9/26/85	10:22:50	0000337	443.0	NORMAL
10/24/85	10:34:06	0034567	444.0	IRRITABLE MARKED
11/21/85	16:25:14	0084799	447.0	NORMAL
12/19/85	10:16:44	0000337	438.0	NORMAL
1/16/86	12:41:38	0000337	435.0	NORMAL
2/05/86	8:03:04	0034567	412.0	NORMAL / EUTHANIZED

## Appendix F (cont.): INDIVIDUAL ANIMAL HISTORIES

PAGE 144  
DATE: 6/09/87  
TIME: 14:40:13  
EDS017 V4M11

STUDY: 0083009  
COMPOUND: ISOBUTYL 2-CYANOACRYLATE  
START DATE: 1/28/85

CARCINOGENICITY BIOASSAY OF ISOBUTYL 2-CYANO-  
ACRYLATE (IBC) IN MALE AND FEMALE RATS.

## ANIMAL HISTORY

Animal ID: 84D00190 Species: D Sex: MALE Group: 10 UL/ANM

DATE	TIME	OPERATOR	WEIGHT (GRAMS)	CLINICAL OBSERVATIONS
2/14/85	10:50:40	0000337	408.0	NORMAL
3/14/85	12:27:36	0078478	413.0	NORMAL
4/11/85	10:52:08	0000337	425.0	NORMAL
5/09/85	9:56:08	0000337	420.0	NORMAL
6/06/85	10:29:54	0010186	414.0	NORMAL
7/02/85	9:35:00	0000337	423.0	NORMAL
8/01/85	10:10:10	0001576	432.0	NORMAL
8/29/85	11:51:46	0010186	427.0	NORMAL
9/26/85	10:23:14	0000337	428.0	NORMAL
10/24/85	10:34:48	0034567	431.0	NORMAL
11/21/85	16:25:40	0084799	428.0	NORMAL
12/19/85	10:16:56	0000337	416.0	NORMAL
1/16/86	12:42:00	0000337	407.0	MULTIPLE PUSTULAR TAIL LESIONS
2/05/86	8:04:14	0034567	384.0	INTRABDOMINAL MASS VENTRAL TO LIVER SIZE LARGE, EUTHANIZED

**Appendix F (cont.): INDIVIDUAL ANIMAL HISTORIES**

STUDY: 0083009  
 COMPOUND: ISOBUTYL 2-CYANOACRYLATE  
 START DATE: 1/28/85  
 CARCINOGENICITY BIOASSAY OF ISOBUTYL 2-CYANO-  
 ACRYLATE (IBC) IN MALE AND FEMALE RATS.  
 ANIMAL HISTORY

Animal ID: 84D00191 Species: D Sex: MALE Group: 100 UL/ANM

DATE	TIME	OPERATOR	WEIGHT (GRAMS)	CLINICAL OBSERVATIONS
2/14/85	10:51:00	0000337	386.0	NORMAL
3/14/85	12:27:54	0078478	394.0	NORMAL
4/11/85	10:52:36	0000337	397.0	NORMAL
5/09/85	9:56:26	0084799	403.0	SUBCUTANEOUS MASS LATERAL LEFT SIDE SIZE SMALL
6/06/85	10:30:16	0010186	405.0	SUBCUTANEOUS MASS LEFT SIDE OF CHEST SIZE MEDIUM
7/02/85	9:35:30	0000337	403.0	SUBCUTANEOUS MASS LEFT SIDE OF CHEST SIZE LARGE
8/01/85	10:10:32	0001576	408.0	SUBCUTANEOUS MASS LEFT SIDE OF CHEST SIZE LARGE
8/01/85	10:41:44	0034567		* No observations recorded.

## Appendix F (cont.): INDIVIDUAL ANIMAL HISTORIES

STUDY: 0083009  
 COMPOUND: ISOBUTYL 2-CYANOACRYLATE  
 START DATE: 1/28/85

CARCINOGENICITY BIOASSAY OF ISOBUTYL 2-CYANO-  
 ACRYLATE (IBC) IN MALE AND FEMALE RATS.

PAGE 146  
 DATE: 6/09/87  
 TIME: 14:40:13  
 EDS017 V4M11

## ANIMAL HISTORY

Animal ID: 84D00192 Species: D Sex: MALE Group: 10 UL/ANM

DATE	TIME	OPERATOR	WEIGHT (GRAMS)	CLINICAL OBSERVATIONS
2/14/85	10:51:14	0000337	378.0	NORMAL
3/14/85	12:28:16	0078478	380.0	NORMAL
4/11/85	10:53:10	0000337	380.0	NORMAL
5/09/85	9:58:56	0000337	377.0	NORMAL
6/06/85	10:32:22	0010186	372.0	NORMAL
7/02/85	9:37:12	0000337	350.0	NORMAL
7/10/85	7:39:20	0000337		TACHYPNEA SLIGHT
8/01/85	10:12:00	0001576	368.0	NORMAL
8/29/85	11:53:36	0010186	364.0	NORMAL
9/26/85	10:23:32	0000337	361.0	NORMAL
10/24/85	10:35:06	0034567	371.0	NORMAL
11/21/85	16:26:00	0084799	368.0	NORMAL
12/19/85	10:17:18	0000337	362.0	NORMAL
1/16/86	12:43:06	0000337	361.0	NORMAL
2/05/86	8:07:48	0034567	340.0	NORMAL / EUTHANIZED

PAGE 1470  
DATE: 6/09/87  
TIME: 14:40:13  
EDS017 VANIL

**Appendix F (cont.): INDIVIDUAL ANIMAL HISTORIES**

STUDY: 0083009  
COMPOUND: ISOBUTYL 2-CYANOACRYLATE  
START DATE: 1/28/85  
CARCINOGENICITY BIOASSAY OF ISOBUTYL 2-CYANO-  
ACRYLATE (IBC) IN MALE AND FEMALE RATS.

**ANIMAL HISTORY**

Animal ID: 84D00193 Species: D Sex: MALE Group: 100 UL/ANN

DATE	TIME	OPERATOR	WEIGHT (GRAMS)	CLINICAL OBSERVATIONS
2/14/85	10:51:48	0000337	425.0	NORMAL
3/14/85	12:28:34	0078478	438.0	NORMAL
4/11/85	10:53:38	0000337	444.0	NORMAL
5/09/85	9:59:14	0000337	448.0	NORMAL
6/06/85	10:32:42	0010186	448.0	NORMAL
7/02/85	9:37:44	0000337	449.0	INTRABDOMINAL MASS VENTRAL TO LIVER SIZE LARGE
7/21/85	10:31:12	0001576	403.0	DEATH

**Appendix F (cont.): INDIVIDUAL ANIMAL HISTORIES**

PAGE 148  
 DATE: 6/09/87  
 TIME: 14:40:13  
 EDS017 V4M11

STUDY: 0083009  
 COMPOUND: ISOBUTYL 2-CYANOACRYLATE  
 START DATE: 1/28/85

CARCINOGENICITY BIOASSAY OF ISOBUTYL 2-CYANO-  
 ACRYLATE (IBC) IN MALE AND FEMALE RATS.

ANIMAL HISTORY

Animal ID: 84D00195 Species: D Sex: MALE Group: CONTROLS

DATE	TIME	OPERATOR	WEIGHT (GRAMS)	CLINICAL OBSERVATIONS
2/14/85	10:52:10	0000337	406.0	NORMAL
3/14/85	12:28:52	0078478	410.0	NORMAL
4/11/85	10:54:04	0000337	416.0	NORMAL
5/09/85	9:59:38	0000337	411.0	NORMAL
6/06/85	10:33:04	0010186	421.0	NORMAL
7/02/85	9:40:52	0000337	434.0	NORMAL
8/01/85	10:12:22	0001576	443.0	NORMAL
8/29/85	11:53:58	0010186	439.0	NORMAL
9/26/85	10:23:52	0000337	441.0	NORMAL
10/24/85	10:35:20	0034567	456.0	NORMAL
11/21/85	16:26:20	0084799	456.0	NORMAL
12/19/85	10:17:32	0000337	451.0	NORMAL
1/16/86	12:43:20	0000337	449.0	NORMAL
2/05/86	8:08:50	0034567	430.0	NORMAL / EUTHANIZED

PAGE 149  
 DATE: 6/09/87  
 TIME: 14:40:13  
 EDS017 VAM11

**Appendix F (cont.): INDIVIDUAL ANIMAL HISTORIES**

STUDY: 0083009  
 COMPOUND: ISOBUTYL 2-CYANOACRYLATE  
 START DATE: 1/28/85  
 CARCINOGENICITY BIOASSAY OF ISOBUTYL 2-CYANO-  
 ACRYLATE (IBC) IN MALE AND FEMALE RATS.

ANIMAL HISTORY

Animal ID: 84D00196 Species: D Sex: MALE Group: 10 UL/ANM

DATE	TIME	OPERATOR	WEIGHT (GRAMS)	CLINICAL OBSERVATIONS
2/14/85	10:52:30	0000337	412.0	NORMAL
2/25/85	8:09:38	0000337		STAIN BROWN NOSE SLIGHT
3/14/85	12:29:14	0078478	419.0	NORMAL
4/11/85	10:54:36	0000337	429.0	INTRAABDOMINAL MASS, SIZE SMALL
4/25/85	8:59:34	0000337	433.0	INTRAABDOMINAL MASS VENTRAL TO LIVER, SIZE SMALL
5/09/85	10:00:22	0084799	429.0	INTRAABDOMINAL MASS VENTRAL TO LIVER SIZE SMALL
5/28/85	8:42:28	0000337		INTRAABDOMINAL MASS VENTRAL TO LIVER SIZE MEDIUM
6/06/85	10:33:26	0010186	430.0	INTRAABDOMINAL MASS VENTRAL TO LIVER SIZE MEDIUM
7/02/85	9:41:22	0000337	433.0	INTRAABDOMINAL MASS VENTRAL TO LIVER SIZE MEDIUM
8/01/85	10:12:42	001576	439.0	INTRAABDOMINAL MASS VENTRAL TO LIVER SIZE LARGE
8/29/85	11:54:20	0010186	436.0	INTRAABDOMINAL MASS VENTRAL TO LIVER SIZE LARGE
9/26/85	10:25:04	0000337	452.0	INTRAABDOMINAL MASS VENTRAL TO LIVER SIZE LARGE
10/24/85	10:35:36	0034567	456.0	INTRAABDOMINAL MASS VENTRAL TO LIVER SIZE LARGE
11/21/85	16:26:38	0084799	458.0	INTRAABDOMINAL MASS VENTRAL TO LIVER SIZE LARGE
12/19/85	10:17:44	0000337	454.0	INTRAABDOMINAL MASS VENTRAL TO LIVER SIZE LARGE
1/16/86	12:43:36	0000337	439.0	INTRAABDOMINAL MASS VENTRAL TO LIVER SIZE LARGE
2/05/86	8:09:36	0034567	400.0	INTRAABDOMINAL MASS VENTRAL TO LIVER SIZE LARGE, EUTHANIZED



**Appendix F (cont.): INDIVIDUAL ANIMAL HISTORIES**

PAGE 150  
 DATE: 6/09/87  
 TIME: 14:40:13  
 EDS017 V4M11

STUDY: 0083009  
 COMPOUND: ISOBUTYL 2-CYANOACRYLATE  
 START DATE: 1/28/85

CARCINOGENICITY BIOASSAY OF ISOBUTYL 2-CYANO-  
 ACRYLATE (IBC) IN MALE AND FEMALE RATS.

ANIMAL HISTORY

Animal ID: 84D00197 Species: D Sex: MALE Group: CONTROLS

DATE	TIME	OPERATOR	WEIGHT (GRAMS)	CLINICAL OBSERVATIONS
2/14/85	10:53:16	0000337	352.0	NORMAL
3/14/85	12:29:54	0078478	360.0	NORMAL
4/11/85	11:00:20	0000337	371.0	STAIN BROWN NOSE MODERATE
4/17/85	8:00:58	0000337		NORMAL
5/09/85	10:02:04	0000337	387.0	NORMAL
6/06/85	10:34:22	0010186	376.0	NORMAL
7/02/85	9:42:08	0000337	382.0	NORMAL
8/01/85	10:14:48	0001576	383.0	NORMAL
8/29/85	11:54:58	0010186	388.0	NORMAL
9/26/85	10:25:46	0000337	388.0	DRAINING ABCESS LEFT ANGLE OF MOUTH MARKED
10/02/85	8:52:14	0000337		ABCESS LEFT ANGLE OF MOUTH MODERATE
10/16/85	9:56:14	0000337		NORMAL
10/24/85	10:36:10	0034567	393.0	NORMAL
11/21/85	16:27:16	0084799	384.0	NORMAL
12/19/85	10:18:28	0000337	383.0	NORMAL
1/16/86	12:44:34	0000337	385.0	NORMAL
2/05/86	8:11:22	0034567	364.0	NORMAL / EUTHANIZED

PAGE 1510  
 DATE: 6/09/87  
 TIME: 14:40:13  
 EDS017 V4M111

**Appendix F (cont.): INDIVIDUAL ANIMAL HISTORIES**

CARCINOGENICITY BIOASSAY OF ISOBUTYL 2-CYANO-  
 ACRYLATE (IBC) IN MALE AND FEMALE RATS.

STUDY: 0083009  
 COMPOUND: ISOBUTYL 2-CYANOACRYLATE  
 START DATE: 1/28/85

ANIMAL HISTORY

Animal ID: 84D00198 Species: D Sex: MALE Group: CONTROLS

DATE	TIME	OPERATOR	WEIGHT (GRAMS)	CLINICAL OBSERVATIONS
2/14/85	10:53:34	0000337	405.0	NORMAL
3/14/85	12:30:18	0078478	410.0	NORMAL
4/11/85	11:01:06	0000337	432.0	NORMAL
5/09/85	10:02:24	0000337	423.0	NORMAL
6/06/85	10:34:38	0010186	424.0	NORMAL
7/02/85	9:42:34	0000337	421.0	STAIN BROWN NOSE SLIGHT
7/10/85	7:47:30	0000337		NORMAL
8/01/85	10:15:18	0001576	405.0	NORMAL
8/29/85	11:55:14	0010186	413.0	NORMAL
9/26/85	10:28:04	0000337	407.0	NORMAL
10/24/85	10:36:28	0034567	408.0	NORMAL
11/21/85	16:27:34	0084799	401.0	NORMAL
12/19/85	10:18:48	0000337	409.0	MASS SPLENIC SIZE LARGE
1/16/86	12:45:06	0000337	406.0	SPLENIC MASS SIZE LARGE

## Appendix F (cont.): INDIVIDUAL ANIMAL HISTORIES

STUDY: 0083009  
 COMPOUND: ISOBUTYL 2-CYANOACRYLATE  
 START DATE: 1/28/85

CARCINOGENICITY BIOASSAY OF ISOBUTYL 2-CYANO-  
 ACRYLATE (IBC) IN MALE AND FEMALE RATS.

PAGE 152  
 DATE: 6/09/87  
 TIME: 14:40:13  
 EDS017 V4M11

## ANIMAL HISTORY

Animal ID: 84D00199 Species: D Sex: MALE Group: 100 UL/ANM

DATE	TIME	OPERATOR	WEIGHT (GRAMS)	CLINICAL OBSERVATIONS
2/14/85	10:53:46	0000337	371.0	NORMAL
3/14/85	12:30:52	0078478	380.0	NORMAL
4/11/85	11:02:04	0000337	388.0	NORMAL
5/09/85	10:02:50	0000337	388.0	NORMAL
5/28/85	8:45:38	0000337		INTRABDOMINAL MASS VENTRAL TO LIVER SIZE MEDIUM
6/06/85	10:34:52	0010186	391.0	INTRABDOMINAL MASS VENTRAL TO LIVER SIZE MEDIUM
7/02/85	9:43:06	0000337	401.0	INTRABDOMINAL MASS VENTRAL TO LIVER SIZE MEDIUM
8/01/85	10:15:48	0001576	402.0	INTRABDOMINAL MASS VENTRAL TO LIVER SIZE MEDIUM
8/29/85	11:55:30	0010186	395.0	INTRABDOMINAL MASS VENTRAL TO LIVER SIZE MEDIUM
9/26/85	10:28:26	0000337	401.0	INTRABDOMINAL MASS VENTRAL TO LIVER SIZE MEDIUM
10/16/85	9:57:50	0084799		MODERATE, STAIN YELLOW PERIANAL SLIGHT, ANEMIA MODERATE, INACTIVE MARKED, ROUGH COAT

Brown 1530  
 PAGE 1530  
 DATE: 6/09/87  
 TIME: 14:40:13  
 EDS017 V4M11

**Appendix F (cont.): INDIVIDUAL ANIMAL HISTORIES**

CARCINOGENICITY BIOASSAY OF ISOBUTYL 2-CYANO-  
 ACRYLATE (IBC) IN MALE AND FEMALE RATS.

STUDY: 0083009  
 COMPOUND: ISOBUTYL 2-CYANOACRYLATE  
 START DATE: 1/28/85

**ANIMAL HISTORY**

Animal ID: 84D00200 Species: D Sex: MALE Group: CONTROLS

DATE	TIME	OPERATOR	WEIGHT (GRAMS)	CLINICAL OBSERVATIONS
2/14/85	10:54:14	0000337	455.0	NORMAL
3/14/85	12:31:12	0078478	461.0	NORMAL
4/11/85	11:02:48	0000337	470.0	NORMAL
5/09/85	10:03:26	0000337	488.0	NORMAL
6/06/85	10:36:50	0010186	475.0	NORMAL
7/02/85	9:43:50	0000337	468.0	NORMAL
7/10/85	7:49:34	0000337		STAIN BROWN NOSE MODERATE
8/01/85	10:16:26	0001576	480.0	STAIN BROWN NOSE SLIGHT
8/29/85	11:56:06	0010186	475.0	NORMAL
9/13/85	8:54:58	0002920		NORMAL
9/26/85	10:29:10	0000337	481.0	NORMAL
10/24/85	10:36:48	0034567	483.0	NORMAL
11/21/85	16:27:54	0084799	471.0	NORMAL
12/19/85	10:20:26	0000337	433.0	NORMAL
12/24/85	11:20:14	0000337		CHROMODACRYORRHEA SLIGHT, STAIN CLEAR MOUTH MARKED



PAGE 154  
 DATE: 6/09/87  
 TIME: 14:40:13  
 EDS017 V4M11

**Appendix F (cont.): INDIVIDUAL ANIMAL HISTORIES**

STUDY: 0083009  
 COMPOUND: ISOBUTYL 2-CYANOACRYLATE  
 START DATE: 1/28/85

CARCINOGENICITY BIOASSAY OF ISOBUTYL 2-CYANO-  
 ACRYLATE (IBC) IN MALE AND FEMALE RATS.

ANIMAL HISTORY

Animal ID: 84D00201 Species: D Sex: MALE Group: 100 UL/ANM

DATE	TIME	OPERATOR	WEIGHT (GRAMS)	CLINICAL OBSERVATIONS
2/14/85	10:54:34	0000337	385.0	NORMAL
3/14/85	12:31:32	0078478	400.0	NORMAL
4/11/85	11:03:28	0000337	407.0	NORMAL
5/09/85	10:03:42	0000337	408.0	NORMAL
6/06/85	10:37:06	0010186	409.0	NORMAL
7/02/85	9:44:22	0000337	409.0	NORMAL
8/01/85	10:17:30	0001576	418.0	NORMAL
8/29/85	11:56:22	0010186	412.0	NORMAL
9/26/85	10:29:28	0000337	411.0	NORMAL
10/24/85	10:37:02	0034567	418.0	NORMAL
11/21/85	16:28:10	0084799	412.0	NORMAL
12/19/85	10:22:16	0000337	414.0	NORMAL
1/16/86	12:46:26	0000337	404.0	NORMAL
2/05/86	8:12:30	0084799	367.0	CORNEAL OPACITY LEFT EYE SLIGHT, EUTHANIZED

PAGE 155  
 DATE: 6/09/87  
 TIME: 14:40:13  
 EDS017 V4M11.

**Appendix F (cont.): INDIVIDUAL ANIMAL HISTORIES**

STUDY: 0083009  
 COMPOUND: ISOBUTYL 2-CYANOACRYLATE  
 START DATE: 1/28/85  
 CARCINOGENICITY BIOASSAY OF ISOBUTYL 2-CYANO-  
 ACRYLATE (IBC) IN MALE AND FEMALE RATS.  
 ANIMAL HISTORY

Animal ID: 84D00202 Species: D Sex: MALE Group: CONTROLS

DATE	TIME	OPERATOR	WEIGHT (GRAMS)	CLINICAL OBSERVATIONS
2/14/85	10:54:52	0000337	370.0	NORMAL
3/06/85	8:54:46	0000337		STAIN BROWN NOSE MODERATE
3/14/85	12:31:50	0078478	388.0	NORMAL
4/11/85	11:04:02	0000337	393.0	NORMAL
5/09/85	10:04:00	0000337	417.0	NORMAL
6/06/85	10:37:30	0010186	405.0	NORMAL
7/02/85	9:44:58	0000337	398.0	NORMAL
8/01/85	10:17:44	0001576	409.0	NORMAL
8/29/85	11:56:42	0010186	411.0	NORMAL
9/26/85	10:29:46	0000337	408.0	NORMAL
10/24/85	10:37:18	0034567	415.0	NORMAL
11/21/85	16:28:24	0084799	413.0	NORMAL
12/19/85	10:22:50	0000337	414.0	NORMAL
1/16/86	12:46:44	0000337	410.0	NORMAL
2/03/86	8:17:42	0034567	368.0	NORMAL / EUTHANIZED

**Appendix F (cont.): INDIVIDUAL ANIMAL HISTORIES**

PAGE 156  
 DATE: 6/09/87  
 TIME: 14:40:13  
 EDS017 V4M11

STUDY: 0083009  
 COMPOUND: ISOBUTYL 2-CYANOACRYLATE  
 START DATE: 1/28/85

CARCINOGENICITY BIOASSAY OF ISOBUTYL 2-CYANO-  
 ACRYLATE (IBC) IN MALE AND FEMALE RATS.

ANIMAL HISTORY

Animal ID: 84D00203 Species: D Sex: MALE Group: 10 UL/ANM

DATE	TIME	OPERATOR	WEIGHT (GRAMS)	CLINICAL OBSERVATIONS
2/14/85	10:55:22	0000337	398.0	NORMAL
3/14/85	12:32:12	0078478	415.0	NORMAL
4/11/85	11:04:38	0000337	421.0	NORMAL
5/09/85	10:04:20	0000337	417.0	NORMAL
6/06/85	10:38:18	0010186	420.0	NORMAL
7/02/85	9:45:48	0000337	416.0	INTRABDOMINAL MASS VENTRAL TO LIVER SIZE MEDIUM
7/10/85	7:51:14	0000337		INTRABDOMINAL MASS VENTRAL TO LIVER SIZE LARGE
8/01/85	10:18:22	0001576	420.0	INTRABDOMINAL MASS VENTRAL TO LIVER SIZE MEDIUM
8/29/85	11:57:12	0010186	427.0	INTRABDOMINAL MASS VENTRAL TO LIVER SIZE MEDIUM
9/26/85	10:30:10	0000337	425.0	INTRABDOMINAL MASS VENTRAL TO LIVER SIZE MEDIUM
10/24/85	10:37:48	0034567	387.0	PORPHYRIN STAINING FACE AND HEAD, PALLOR BOTH EYE SLIGHT, INTRABDOMINAL MASS VENTRAL TO LIVER SIZE LARGE
10/24/85	10:43:08	0034567	387.0	* No observations recorded.

PAGE 157  
 DATE: 6/09/87  
 TIME: 14:40:13  
 EDS017 V4M11

**Appendix F (cont.): INDIVIDUAL ANIMAL HISTORIES**

STUDY: 0083009  
 COMPOUND: ISOBUTYL 2-CYANOACRYLATE  
 START DATE: 1/28/85

CARCINOGENICITY BIOASSAY OF ISOBUTYL 2-CYANO-  
 ACRYLATE (IBC) IN MALE AND FEMALE RATS.

ANIMAL HISTORY

Animal ID: 84D00204 Species: D Sex: MALE Group: CONTROLS

DATE	TIME	OPERATOR	WEIGHT (GRAMS)	CLINICAL OBSERVATIONS
2/14/85	10:55:50	0000337	351.0	CORNEAL OPACITY RIGHT EYE MODERATE
3/14/85	12:32:32	0078478	355.0	CORNEAL OPACITY RIGHT EYE MARKED
4/11/85	11:05:22	0000337	359.0	CORNEAL OPACITY RIGHT EYE MARKED
5/09/85	10:04:34	0000337	360.0	CORNEAL OPACITY RIGHT EYE MARKED
6/06/85	10:38:36	0010186	366.0	CORNEAL OPACITY RIGHT EYE MODERATE
7/02/85	9:47:32	0000337	363.0	CORNEAL OPACITY RIGHT EYE MODERATE
8/01/85	10:19:16	0001576	362.0	CORNEAL OPACITY RIGHT EYE MODERATE
8/29/85	11:57:48	0010186	366.0	CORNEAL OPACITY RIGHT EYE SLIGHT
9/26/85	10:30:56	0000337	356.0	CORNEAL OPACITY RIGHT EYE SLIGHT
10/24/85	10:39:54	0034567	363.0	CORNEAL OPACITY RIGHT EYE SLIGHT
11/21/85	16:28:50	0084799	355.0	CORNEAL OPACITY RIGHT EYE SLIGHT
12/19/85	10:23:12	0000337	348.0	CORNEAL OPACITY RIGHT EYE SLIGHT
1/16/86	12:47:12	0000337	341.0	CORNEAL OPACITY RIGHT EYE SLIGHT
2/05/86	8:19:24	0034567	315.0	CORNEAL OPACITY RIGHT EYE SLIGHT, EUTHANIZED



PAGE 158  
 DATE: 6/09/87  
 TIME: 14:40:13  
 EDS017 V4M11

**Appendix F (cont.): INDIVIDUAL ANIMAL HISTORIES**

STUDY: 0083009 ISOBUTYL 2-CYANOACRYLATE  
 COMPOUND: ISOBUTYL 2-CYANOACRYLATE  
 START DATE: 1/28/85

CARCINOGENICITY BIOASSAY OF ISOBUTYL 2-CYANO-  
 ACRYLATE (IBC) IN MALE AND FEMALE RATS.

ANIMAL HISTORY

Animal ID: 84D00205 Species: D Sex: MALE Group: 10 UL/ANM

DATE	TIME	OPERATOR	WEIGHT (GRAMS)	CLINICAL OBSERVATIONS
2/14/85	10:56:06	0000337	395.0	NORMAL
3/14/85	12:33:22	0078478	398.0	NORMAL
4/11/85	11:06:18	0000337	395.0	NORMAL
5/09/85	10:04:58	0000337	405.0	NORMAL
6/06/85	10:39:08	0010186	410.0	NORMAL
7/02/85	9:47:58	0000337	414.0	NORMAL
8/01/85	10:19:42	0001576	415.0	NORMAL
8/29/85	11:58:10	0010186	417.0	NORMAL
9/26/85	10:31:30	0000337	416.0	NORMAL
10/24/85	10:40:12	0034567	431.0	NORMAL
11/21/85	16:29:20	0084799	425.0	NORMAL
12/19/85	10:23:26	0000337	433.0	NORMAL
1/16/86	12:47:36	0000337	423.0	NORMAL
2/05/86	8:20:58	0034567	385.0	NORMAL / EUTHANIZED

**Appendix F (cont.): INDIVIDUAL ANIMAL HISTORIES**

STUDY: 0083009  
COMPOUND: ISOBUTYL 2-CYANOACRYLATE  
START DATE: 1/28/85

CARCINOGENICITY BIOASSAY OF ISOBUTYL 2-CYANO-  
ACRYLATE (IBC) IN MALE AND FEMALE RATS.

**ANIMAL HISTORY**

Animal ID: 84D00206 Species: D Sex: MALE Group: 10 UL/ANM

DATE	TIME	OPERATOR	WEIGHT (GRAMS)	CLINICAL OBSERVATIONS
2/14/85	10:56:24	0000337	380.0	NORMAL
3/14/85	12:33:46	0078478	392.0	NORMAL
4/11/85	11:06:50	0000337	392.0	NORMAL
4/17/85	8:05:58	0000337		STAIN BROWN NOSE SLIGHT
5/02/85	6:55:06	0000337		NORMAL
5/09/85	10:05:24	0000337	404.0	NORMAL
5/28/85	8:50:22	0000337		INTRAABDOMINAL MASS VENTRAL TO LIVER SIZE SMALL
6/06/85	10:39:26	0010186	413.0	STAIN NOSE BROWN MODERATE, INTRAABDOMINAL MASS VENTRAL TO LIVER SIZE SMALL
7/02/85	9:48:46	0000337	412.0	INTRAABDOMINAL MASS VENTRAL TO LIVER SIZE MEDIUM
8/01/85	10:20:08	0001576	418.0	INTRAABDOMINAL MASS VENTRAL TO LIVER SIZE MEDIUM
8/29/85	11:58:28	0010186	412.0	INTRAABDOMINAL MASS VENTRAL TO LIVER SIZE MEDIUM
9/26/85	10:31:54	0000337	420.0	INTRAABDOMINAL MASS VENTRAL TO LIVER SIZE MEDIUM
10/24/85	10:40:28	0034567	430.0	INTRAABDOMINAL MASS VENTRAL TO LIVER SIZE MEDIUM
11/21/85	16:29:46	0084799	425.0	INTRAABDOMINAL MASS VENTRAL TO LIVER SIZE MEDIUM
12/19/85	10:23:46	0000337	424.0	INTRAABDOMINAL MASS VENTRAL TO LIVER SIZE LARGE
1/16/86	12:48:00	0000337	423.0	INTRAABDOMINAL MASS VENTRAL TO LIVER SIZE LARGE
2/05/86	8:23:06	0034567	385.0	INTRAABDOMINAL MASS VENTRAL TO LIVER SIZE LARGE, EUTHANIZED

## Appendix F (cont.): INDIVIDUAL ANIMAL HISTORIES

PAGE 160  
DATE: 6/09/87  
TIME: 14:40:13  
EDS017 V4M11

STUDY: 0083009  
COMPOUND: ISOBUTYL 2-CYANOACRYLATE  
START DATE: 1/28/85

CARCINOGENICITY BIOASSAY OF ISOBUTYL 2-CYANO-  
ACRYLATE (IBC) IN MALE AND FEMALE RATS.

## ANIMAL HISTORY

Animal ID: 84D00207 Species: D Sex: MALE Group: CONTROLS

DATE	TIME	OPERATOR	WEIGHT (GRAMS)	CLINICAL OBSERVATIONS
2/14/85	10:56:36	0000337	436.0	NORMAL
3/14/85	12:34:20	0078478	446.0	NORMAL
4/11/85	11:08:02	0000337	453.0	NORMAL
4/17/85	8:07:14	0000337		STAIN BROWN NOSE SLIGHT
5/02/85	6:53:54	0000337		NORMAL
5/09/85	10:05:40	0000337	464.0	NORMAL
6/06/85	10:40:44	0010186	380.0	STAIN NOSE BROWN SLIGHT, STAIN MOUTH BROWN SLIGHT
7/02/85	9:49:36	0000337	413.0	NORMAL
8/01/85	10:20:56	0001576	455.0	NORMAL
8/29/85	11:58:56	0010186	455.0	NORMAL
9/26/85	10:32:38	0000337	450.0	NORMAL
10/24/85	10:41:16	0034567	449.0	NORMAL
11/21/85	16:31:02	0084799	432.0	NORMAL
12/19/85	10:24:36	0000337	427.0	NORMAL
1/16/86	12:49:10	0000337	409.0	NORMAL
2/05/86	8:25:12	0034567	353.0	EMACIATED MODERATE, CONJUNCTIVITIS RIGHT EYE MODERATE, EUTHANIZED

PAGE 161  
 DATE: 6/09/87  
 TIME: 14:40:13  
 EDS017 V4M11

**Appendix F (cont.): INDIVIDUAL ANIMAL HISTORIES**

STUDY: 0083009 CARCINOGENICITY BIOASSAY OF ISOBUTYL 2-CYANO-  
 COMPOUND: ISOBUTYL 2-CYANOACRYLATE ACRYLATE (IBC) IN MALE AND FEMALE RATS.  
 START DATE: 1/28/85

ANIMAL HISTORY

Animal ID: 84D00208 Species: D Sex: MALE Group: CONTROLS

DATE	TIME	OPERATOR	WEIGHT (GRAMS)	CLINICAL OBSERVATIONS
2/14/85	10:56:52	0000337	371.0	NORMAL
3/14/85	12:34:40	0078478	386.0	NORMAL
4/11/85	11:08:20	0000337	386.0	NORMAL
5/09/85	10:05:58	0000337	398.0	NORMAL
6/06/85	10:42:42	0010186	395.0	NORMAL
7/02/85	9:50:42	0000337	400.0	NORMAL
8/01/85	10:21:16	0001576	401.0	NORMAL
8/29/85	11:59:12	0010186	401.0	NORMAL
9/26/85	10:32:56	0000337	397.0	NORMAL
10/24/85	10:41:34	0034567	398.0	NORMAL
11/21/85	16:31:12	0084799	394.0	NORMAL
12/19/85	10:24:56	0000337	394.0	NORMAL
1/16/86	12:49:24	0000337	394.0	NORMAL
2/05/86	8:26:50	0034567	368.0	NORMAL / EUTHANIZED

## Appendix F (cont.): INDIVIDUAL ANIMAL HISTORIES

PAGE 162  
DATE: 6/09/87  
TIME: 14:40:13  
EDS017 V4M11

STUDY: 0083009  
COMPOUND: ISOBUTYL 2-CYANOACRYLATE  
START DATE: 1/28/85

CARCINOGENICITY BIOASSAY OF ISOBUTYL 2-CYANO-  
ACRYLATE (IBC) IN MALE AND FEMALE RATS.

## ANIMAL HISTORY

Animal ID: 84D00209 Species: D Sex: MALE Group: CONTROLS

DATE	TIME	OPERATOR	WEIGHT (GRAMS)	CLINICAL OBSERVATIONS
2/14/85	10:57:10	0000337	404.0	NORMAL
3/14/85	12:35:00	0078478	417.0	NORMAL
4/11/85	11:08:50	0000337	425.0	NORMAL
5/09/85	10:06:14	0000337	436.0	NORMAL
6/06/85	10:43:10	0010186	439.0	NORMAL
7/02/85	9:51:14	0000337	437.0	NORMAL
8/01/85	10:21:38	0001576	442.0	NORMAL
8/29/85	11:59:42	0010186	444.0	IRRITABLE MODERATE
9/26/85	10:33:14	0000337	433.0	DRAINING ABCESS LEFT ANGLE OF MOUTH SLIGHT
10/16/85	12:18:12	0000337		NORMAL
10/24/85	10:41:52	0034567	436.0	NORMAL
11/21/85	16:31:36	0084799	432.0	NORMAL
12/19/85	10:25:10	0000337	435.0	NORMAL
1/16/86	12:49:42	0000337	431.0	NORMAL
2/05/86	8:28:06	0034567	404.0	NORMAL / EUTHANIZED

PAGE 00  
 DATE: 6/09/87  
 TIME: 14:40:13  
 EDS017 V4M11

**Appendix F (cont.): INDIVIDUAL ANIMAL HISTORIES**

STUDY: 0083009 CARCINOGENICITY BIOASSAY OF ISOBUTYL 2-CYANO-  
 COMPOUND: ISOBUTYL 2-CYANOACRYLATE ACRYLATE (IBC) IN MALE AND FEMALE RATS.  
 START DATE: 1/28/85

ANIMAL HISTORY

Animal ID: 64D00257 Species: D Sex: FEMALE Group: 10 UL/ANM

DATE	TIME	OPERATOR	WEIGHT (GRAMS)	CLINICAL OBSERVATIONS
2/15/85	8:10:44	0000337	235.0	CORNEAL OPACITY RIGHT EYE SLIGHT, CONJUNCTIVITIS BOTH EYE SLIGHT
2/25/85	8:18:20	0000337		CORNEAL OPACITY RIGHT EYE SLIGHT, STAIN CLEAR PERIANAL SLIGHT
3/15/85	7:46:34	0000337	248.0	CORNEAL OPACITY RIGHT EYE SLIGHT
3/25/85	8:28:14	0000337		CORNEAL OPACITY RIGHT EYE SLIGHT, CONJUNCTIVITIS BOTH EYE SLIGHT
4/12/85	7:44:22	0000337	242.0	CORNEAL OPACITY RIGHT EYE SLIGHT, CONJUNCTIVITIS BOTH EYE SLIGHT
4/17/85	8:11:40	0000337		CORNEAL OPACITY RIGHT EYE SLIGHT, CONJUNCTIVITIS BOTH EYE SLIGHT, STAIN CLEAR PERIANAL SLIGHT
5/10/85	6:31:26	0084799	250.0	CORNEAL OPACITY RIGHT EYE SLIGHT, CONJUNCTIVITIS BOTH EYE SLIGHT
6/07/85	6:49:14	0000337	254.0	CORNEAL OPACITY RIGHT EYE SLIGHT, CONJUNCTIVITIS BOTH EYE SLIGHT
7/03/85	7:08:06	0000337	262.0	CORNEAL OPACITY RIGHT EYE SLIGHT, CONJUNCTIVITIS BOTH EYE SLIGHT
7/10/85	8:42:38	0000337		CORNEAL OPACITY RIGHT EYE SLIGHT
8/02/85	7:42:16	0034567	266.0	CORNEAL OPACITY RIGHT EYE SLIGHT
8/30/85	9:24:28	0000337	272.0	CORNEAL OPACITY RIGHT EYE SLIGHT
9/13/85	9:05:06	0002920		CORNEAL OPACITY RIGHT EYE SLIGHT, CONJUNCTIVITIS LEFT EYE MODERATE
9/27/85	6:51:20	0000337	272.0	CORNEAL OPACITY RIGHT EYE SLIGHT, CONJUNCTIVITIS LEFT EYE MODERATE
10/25/85	7:47:34	0072808	274.0	CONJUNCTIVITIS BOTH EYE SLIGHT, CORNEAL OPACITY RIGHT EYE SLIGHT
11/22/85	7:53:36	0000337	283.0	CONJUNCTIVITIS BOTH EYE MARKED, CORNEAL OPACITY RIGHT EYE SLIGHT
12/20/85	7:22:20	0000337	292.0	CORNEAL OPACITY RIGHT EYE SLIGHT, CONJUNCTIVITIS LEFT EYE MODERATE, SUBCUTANEOUS MASS LEFT SIDE THORAX SIZE LARGE
1/13/86	9:54:32	0084799		CORNEAL OPACITY RIGHT EYE SLIGHT, CONJUNCTIVITIS LEFT EYE MARKED, STAIN YELLOW PERIANAL SLIGHT, SUBCUTANEOUS MASS LEFT SIDE THORAX SIZE LARGE

**Appendix F (cont.): INDIVIDUAL ANIMAL HISTORIES**

STUDY: 0083009  
 COMPOUND: ISOBUTYL 2-CYANOACRYLATE  
 START DATE: 1/28/85

CARCINOGENICITY BIOASSAY OF ISOBUTYL 2-CYANO-  
 ACRYLATE (IBC) IN MALE AND FEMALE RATS.

PAGE 3  
 DATE: 6/09/87  
 TIME: 14:40:13  
 EDS017 VAM11

ANIMAL HISTORY

Animal ID: 84D00260 Species: D Sex: FEMALE Group: 10 UL/ANM

DATE	TIME	OPERATOR	WEIGHT (GRAMS)	CLINICAL OBSERVATIONS
2/15/85	8:34:04	0000337	239.0	CORNEAL OPACITY LEFT EYE SLIGHT
3/15/85	7:48:20	0000337	247.0	CORNEAL OPACITY LEFT EYE SLIGHT
4/12/85	8:05:02	0000337	248.0	CORNEAL OPACITY LEFT EYE SLIGHT
5/10/85	7:35:38	0000337	255.0	CORNEAL OPACITY LEFT EYE SLIGHT
6/07/85	7:41:12	0000337	264.0	CORNEAL OPACITY LEFT EYE SLIGHT
7/03/85	7:10:28	0000337	277.0	CORNEAL OPACITY LEFT EYE SLIGHT
8/02/85	7:45:50	0034567	284.0	CORNEAL OPACITY LEFT EYE SLIGHT
8/30/85	9:25:20	0000337	285.0	CORNEAL OPACITY LEFT EYE SLIGHT
9/13/85	9:06:52	0002920		STAIN YELLOW PERIARIAL MODERATE, CORNEAL OPACITY LEFT EYE SLIGHT
9/25/85	8:34:58	0000337		CORNEAL OPACITY LEFT EYE SLIGHT, STAIN DARK PERIARIAL MARKED, EMACIATED MARKED
9/25/85	11:14:38	0000337		* No observations recorded.

PAGE 4  
 DATE: 6/09/87  
 TIME: 14:40:13  
 EDS017 VAM11

**Appendix F (cont.): INDIVIDUAL ANIMAL HISTORIES**

STUDY: 0083009  
 COMPOUND: ISOBUTYL 2-CYANOACRYLATE  
 START DATE: 1/28/85  
 CARCINOGENICITY BIOASSAY OF ISOBUTYL 2-CYANO-  
 ACRYLATE (IBC) IN MALE AND FEMALE RATS.

ANIMAL HISTORY

Animal ID: 84D00266 Species: D Sex: FEMALE Group: CONTROLS

DATE	TIME	OPERATOR	WEIGHT (GRAMS)	CLINICAL OBSERVATIONS
2/15/85	8:34:22	0000337	236.0	CORNEAL OPACITY LEFT EYE SLIGHT, CONJUNCTIVITIS RIGHT EYE SLIGHT
2/25/85	8:20:08	0000337		CORNEAL OPACITY LEFT EYE SLIGHT, CONJUNCTIVITIS RIGHT EYE MODERATE
3/15/85	7:48:44	0000337	245.0	CORNEAL OPACITY RIGHT EYE SLIGHT, CONJUNCTIVITIS RIGHT EYE SLIGHT
4/05/85	8:23:28	0084799		CORNEAL OPACITY RIGHT EYE SLIGHT, CONJUNCTIVITIS RIGHT EYE SLIGHT
4/12/85	8:05:34	0000337	250.0	CORNEAL OPACITY RIGHT EYE SLIGHT, CONJUNCTIVITIS RIGHT EYE SLIGHT
5/10/85	7:36:28	0000337	266.0	CORNEAL OPACITY RIGHT EYE SLIGHT, CONJUNCTIVITIS RIGHT EYE MODERATE
5/28/85	8:56:46	0000337		CORNEAL OPACITY RIGHT EYE SLIGHT, CONJUNCTIVITIS RIGHT EYE SLIGHT
6/07/85	7:41:32	0000337	275.0	CORNEAL OPACITY RIGHT EYE SLIGHT, CONJUNCTIVITIS RIGHT EYE SLIGHT, SUBCUTANEOUS MASS CERVICAL SIZE LARGE
7/03/85	7:11:24	0000337	287.0	CORNEAL OPACITY RIGHT EYE SLIGHT, CONJUNCTIVITIS RIGHT EYE MARKED, SUBCUTANEOUS MASS CERVICAL SIZE LARGE
8/02/85	7:46:28	0084799	282.0	CORNEAL OPACITY RIGHT EYE SLIGHT, CONJUNCTIVITIS RIGHT EYE MODERATE, SUBCUTANEOUS MASS CERVICAL SIZE LARGE
8/30/85	9:25:48	0000337	283.0	CORNEAL OPACITY RIGHT EYE SLIGHT, CONJUNCTIVITIS RIGHT EYE SLIGHT, SUBCUTANEOUS MASS CERVICAL SIZE LARGE
9/27/85	7:16:14	0084799	278.0	CORNEAL OPACITY RIGHT EYE SLIGHT, SUBCUTANEOUS MASS CERVICAL SIZE LARGE
10/02/85	8:58:24	0000337		CORNEAL OPACITY RIGHT EYE, CONJUNCTIVITIS RIGHT EYE MODERATE, SUBCUTANEOUS MASS CERVICAL SIZE LARGE
10/11/85	8:32:52	0000337		LIVE ANIMAL SENT TO NECROPSY 3 OCT 1985 NOT REMOVED FROM CENSUS AT THAT TIME



## Appendix F (cont.): INDIVIDUAL ANIMAL HISTORIES

PAGE 5  
DATE: 6/09/87  
TIME: 14:40:13  
EDS017 V4M11

STUDY: 0083009 CARCINOGENICITY BIOASSAY OF ISOBUTYL 2-CYANO-  
COMPOUND: ISOBUTYL 2-CYANOACRYLATE ACRYLATE (IBC) IN MALE AND FEMALE RATS.

START DATE: 1/28/85

## ANIMAL HISTORY

Animal ID: 84D00268 Species: D Sex: FEMALE Group: CONTROLS

DATE	TIME	OPERATOR	WEIGHT (GRAMS)	CLINICAL OBSERVATIONS
2/15/85	8:35:06	0000337	237.0	CORNEAL OPACITY LEFT EYE SLIGHT
2/25/85	8:21:22	0000337		CORNEAL OPACITY LEFT EYE SLIGHT, CONJUNCTIVITIS LEFT EYE SLIGHT
3/06/85	9:00:54	0000337		CORNEAL OPACITY LEFT EYE SLIGHT, CONJUNCTIVITIS LEFT EYE SLIGHT, STAIN BROWN NOSE SLIGHT
3/15/85	7:50:10	0000337	246.0	CORNEAL OPACITY LEFT EYE SLIGHT
4/12/85	8:06:48	0000337	247.0	CORNEAL OPACITY LEFT EYE SLIGHT
5/10/85	7:37:06	0000337	256.0	CORNEAL OPACITY LEFT EYE SLIGHT
6/07/85	7:46:16	0000337	256.0	CORNEAL OPACITY LEFT EYE SLIGHT
7/03/85	7:16:06	0000337	270.0	CORNEAL OPACITY LEFT EYE SLIGHT
8/02/85	7:49:18	0034567	272.0	CORNEAL OPACITY LEFT EYE SLIGHT
8/30/85	9:28:22	0000337	271.0	CORNEAL OPACITY LEFT EYE SLIGHT
9/13/85	9:12:06	0002920		CORNEAL OPACITY LEFT EYE SLIGHT, CONJUNCTIVITIS BOTH EYE SLIGHT
9/27/85	7:18:14	0000337	268.0	CORNEAL OPACITY LEFT EYE SLIGHT, CONJUNCTIVITIS BOTH EYE SLIGHT
10/25/85	7:49:30	0072808	277.0	CORNEAL OPACITY LEFT EYE SLIGHT, CONJUNCTIVITIS BOTH EYE SLIGHT
11/22/85	7:55:28	0000337	277.0	CORNEAL OPACITY LEFT EYE SLIGHT
12/20/85	8:32:02	0000337	278.0	CORNEAL OPACITY LEFT EYE SLIGHT
1/17/86	7:25:08	0000337	273.0	CORNEAL OPACITY LEFT EYE SLIGHT
2/07/86	7:43:08	0034567	258.0	CORNEAL OPACITY LEFT EYE SLIGHT, EUTHANIZED

PAGE 6  
 DATE: 6/09/87  
 TIME: 14:40:13  
 EDS017 V4M11

**Appendix F (cont.): INDIVIDUAL ANIMAL HISTORIES**

STUDY: 0083009  
 COMPOUND: ISOBUTYL 2-CYANOACRYLATE  
 START DATE: 1/28/85

CARCINOGENICITY BIOASSAY OF ISOBUTYL 2-CYANO-  
 ACRYLATE (IBC) IN MALE AND FEMALE RATS.

ANIMAL HISTORY

Animal ID: 84D00269 Species: D Sex: FEMALE Group: 100 UL/ANM

DATE	TIME	WEIGHT	OPERATOR	CLINICAL OBSERVATIONS
2/15/85	8:36:16	223.0	0000337	NORMAL
2/25/85	8:22:20		0000337	CONJUNCTIVITIS BOTH EYE SLIGHT
3/15/85	7:50:42	235.0	0000337	CONJUNCTIVITIS BOTH EYE SLIGHT
4/05/85	8:23:22		0000337	CONJUNCTIVITIS RIGHT EYE MODERATE
4/12/85	8:07:30	234.0	0000337	CONJUNCTIVITIS RIGHT EYE MODERATE
4/17/85	8:15:40		0084799	CONJUNCTIVITIS RIGHT EYE SLIGHT
5/10/85	7:37:34	256.0	0000337	CONJUNCTIVITIS RIGHT EYE SLIGHT
5/28/85	8:58:24		0000337	CONJUNCTIVITIS RIGHT EYE MODERATE
6/07/85	7:46:58	260.0	0000337	CONJUNCTIVITIS BOTH EYE MODERATE
7/03/85	7:16:40	266.0	0000337	CONJUNCTIVITIS BOTH EYE MODERATE
8/02/85	7:49:44	268.0	0034567	CONJUNCTIVITIS BOTH EYE MODERATE
8/30/85	9:28:46	276.0	0000337	CONJUNCTIVITIS RIGHT EYE MODERATE
9/13/85	9:13:48		0002920	CONJUNCTIVITIS LEFT EYE MARKED
9/27/85	7:18:46	277.0	0000337	CONJUNCTIVITIS RIGHT EYE SLIGHT
10/25/85	7:50:26	278.0	0072808	CONJUNCTIVITIS RIGHT EYE SLIGHT
11/22/85	7:56:00	284.0	0000337	NORMAL
12/20/85	8:32:16	278.0	0000337	NORMAL
1/17/86	8:03:26	279.0	0000337	NORMAL
2/07/86	7:44:28	259.0	0034567	CONJUNCTIVITIS RIGHT EYE MODERATE, EUTHANIZED

## Appendix F (cont.): INDIVIDUAL ANIMAL HISTORIES

PAGE 7  
DATE: 6/09/87  
TIME: 14:40:13  
EDS017 V4M11

STUDY: 0083009  
COMPOUND: ISOBUTYL 2-CYANOACRYLATE  
START DATE: 1/28/85

CARCINOGENICITY BIOASSAY OF ISOBUTYL 2-CYANO-  
ACRYLATE (IBC) IN MALE AND FEMALE RATS.

## ANIMAL HISTORY

Animal ID: 84D00270 Species: D Sex: FEMALE Group: 10 UL/ANM

DATE	TIME	OPERATOR	WEIGHT (GRAMS)	CLINICAL OBSERVATIONS
2/15/85	8:36:32	0000337	243.0	CONJUNCTIVITIS LEFT EYE SLIGHT
3/06/85	9:03:02	0000337		CONJUNCTIVITIS LEFT EYE SLIGHT, STAIN BROWN NOSE SLIGHT
3/15/85	7:51:00	0000337	261.0	CONJUNCTIVITIS LEFT EYE SLIGHT
4/12/85	8:08:02	0000337	255.0	CONJUNCTIVITIS LEFT EYE SLIGHT
4/17/85	8:16:46	0000337		CONJUNCTIVITIS BOTH EYE SLIGHT
5/10/85	7:38:20	0000337	270.0	CONJUNCTIVITIS LEFT EYE SLIGHT
6/07/85	7:47:36	0000337	270.0	CONJUNCTIVITIS LEFT EYE SLIGHT
7/03/85	7:17:26	0000337	278.0	CONJUNCTIVITIS LEFT EYE MODERATE
8/02/85	7:50:54	0034567	283.0	CONJUNCTIVITIS LEFT EYE MARKED
8/30/85	9:29:38	0000337	290.0	CONJUNCTIVITIS LEFT EYE MODERATE
9/27/85	7:19:40	0000337	293.0	CONJUNCTIVITIS LEFT EYE MODERATE
10/25/85	7:50:50	0072808	305.0	CONJUNCTIVITIS LEFT EYE MARKED
11/22/85	7:56:36	0000337	305.0	CONJUNCTIVITIS LEFT EYE MODERATE
12/20/85	8:32:38	0000337	306.0	CONJUNCTIVITIS LEFT EYE MODERATE
1/17/86	8:03:42	0000337	309.0	CONJUNCTIVITIS LEFT EYE MODERATE
2/07/86	7:46:24	0034567	293.0	CONJUNCTIVITIS LEFT EYE MODERATE, EUTHANIZED

## Appendix F (cont.): INDIVIDUAL ANIMAL HISTORIES

STUDY: 0083009 CARCINOGENICITY BIOASSAY OF ISOBUTYL 2-CYANO-  
COMPOUND: ISOBUTYL 2-CYANOACRYLATE ACRYLATE (IBC) IN MALE AND FEMALE RATS.  
START DATE: 1/28/85

## ANIMAL HISTORY

Animal ID: 84D00271 Species: D Sex: FEMALE Group: CONTROLS

DATE	TIME	OPERATOR	WEIGHT (GRAMS)	CLINICAL OBSERVATIONS
2/15/85	8:36:52	0000337	198.0	CORNEAL OPACITY LEFT EYE SLIGHT, CONJUNCTIVITIS BOTH EYE MODERATE
3/06/85	9:03:50	0000337		CORNEAL OPACITY LEFT EYE SLIGHT, CONJUNCTIVITIS BOTH EYE MARKED, STAIN CLEAR PERIANAL SLIGHT
3/15/85	7:51:26	0000337	203.0	CORNEAL OPACITY LEFT EYE SLIGHT, CONJUNCTIVITIS BOTH EYE MODERATE
3/25/85	8:32:20	0000337		CORNEAL OPACITY LEFT EYE SLIGHT, CONJUNCTIVITIS BOTH EYE MODERATE, STAIN BROWN NOSE SLIGHT
4/05/85	8:27:52	0000337		CORNEAL OPACITY LEFT EYE SLIGHT, CONJUNCTIVITIS BOTH EYE MODERATE, DEHYDRATED SLIGHT
4/12/85	8:08:58	0000337	197.0	CORNEAL OPACITY LEFT EYE SLIGHT, CONJUNCTIVITIS BOTH EYE MODERATE
4/17/85	8:18:14	0000337		CORNEAL OPACITY LEFT EYE SLIGHT, CONJUNCTIVITIS BOTH EYE MODERATE, DEHYDRATED SLIGHT
4/25/85	9:11:38	0000337	208.0	CORNEAL OPACITY LEFT EYE SLIGHT, CONJUNCTIVITIS BOTH EYE MARKED, TACHYPNEA MODERATE, ROUGH COAT MODERATE, EMACIATED MODERATE
5/02/85	7:02:40	0084799		CORNEAL OPACITY LEFT EYE SLIGHT, CONJUNCTIVITIS BOTH EYE MARKED, TACHYPNEA MODERATE, EMACIATED MODERATE
5/07/85	7:45:46	0000337		CORNEAL OPACITY LEFT EYE SLIGHT, CONJUNCTIVITIS BOTH EYE MARKED, TACHYPNEA MODERATE, EMACIATED MODERATE
5/10/85	7:38:50	0000337	206.0	CORNEAL OPACITY LEFT EYE SLIGHT, CONJUNCTIVITIS BOTH EYE MARKED, TACHYPNEA MODERATE
5/28/85	8:59:52	0000337		CORNEAL OPACITY LEFT EYE SLIGHT, CONJUNCTIVITIS EYE MARKED, EMACIATED SLIGHT
6/07/85	7:47:56	0000337	212.0	CORNEAL OPACITY LEFT EYE SLIGHT, CONJUNCTIVITIS BOTH EYE MODERATE
7/03/85	7:18:32	0000337	210.0	CORNEAL OPACITY LEFT EYE SLIGHT, CONJUNCTIVITIS BOTH EYE MARKED
8/02/85	7:51:20	0034567	218.0	CORNEAL OPACITY LEFT EYE SLIGHT, CONJUNCTIVITIS BOTH EYE MARKED
8/30/85	9:30:02	0000337	217.0	CORNEAL OPACITY LEFT EYE SLIGHT, CONJUNCTIVITIS BOTH EYE MARKED
9/27/85	7:20:14	0000337	217.0	CORNEAL OPACITY LEFT EYE SLIGHT, CONJUNCTIVITIS BOTH EYE MODERATE
10/25/85	7:51:14	0072808	224.0	CORNEAL OPACITY LEFT EYE SLIGHT, CONJUNCTIVITIS BOTH EYE MODERATE
11/22/85	7:56:58	0000337	228.0	CORNEAL OPACITY LEFT EYE SLIGHT, CONJUNCTIVITIS LEFT EYE SLIGHT
12/20/85	8:32:56	0000337	237.0	CORNEAL OPACITY LEFT EYE SLIGHT, CONJUNCTIVITIS LEFT EYE SLIGHT
1/17/86	8:04:08	0000337	235.0	CORNEAL OPACITY LEFT EYE SLIGHT, CONJUNCTIVITIS LEFT EYE SLIGHT
2/07/86	7:48:32	0034567	220.0	CORNEAL OPACITY LEFT EYE SLIGHT, CONJUNCTIVITIS BOTH EYE SLIGHT, EUTHANIZED

**Appendix F (cont.): INDIVIDUAL ANIMAL HISTORIES**

PAGE 9  
 DATE: 6/09/87  
 TIME: 14:40:13  
 EDS017 VAM11

STUDY: 0083009 ISOBUTYL 2-CYANOACRYLATE CARCINOGENICITY BIOASSAY OF ISOBUTYL 2-CYANO-  
 COMPOUND: ISOBUTYL 2-CYANOACRYLATE ACRYLATE (IBC) IN MALE AND FEMALE RATS.  
 START DATE: 1/28/85

ANIMAL HISTORY

Animal ID: 84D00272 Species: D Sex: FEMALE Group: 10 UL/ANM

DATE	TIME	OPERATOR	WEIGHT (GRAMS)	CLINICAL OBSERVATIONS
2/15/85	8:37:22	0000337	219.0	CORNEAL OPACITY BOTH EYE SLIGHT, CONJUNCTIVITIS BOTH EYE SLIGHT
3/15/85	7:52:10	0000337	230.0	CORNEAL OPACITY BOTH EYE SLIGHT, CONJUNCTIVITIS BOTH EYE SLIGHT
4/05/85	8:30:12	0000337	233.0	CORNEAL OPACITY BOTH EYE SLIGHT, CONJUNCTIVITIS LEFT EYE MODERATE
4/12/85	8:09:50	0000337	247.0	CORNEAL OPACITY BOTH EYE SLIGHT, CONJUNCTIVITIS LEFT EYE MODERATE
5/10/85	7:39:40	0000337	255.0	CORNEAL OPACITY BOTH EYE SLIGHT, CONJUNCTIVITIS BOTH EYE MARKED
6/07/85	7:49:08	0000337	267.0	CORNEAL OPACITY BOTH EYE SLIGHT, CONJUNCTIVITIS BOTH EYE MARKED
7/03/85	7:19:32	0000337	270.0	CORNEAL OPACITY BOTH EYE SLIGHT, CONJUNCTIVITIS BOTH EYE MODERATE
7/10/85	8:47:36	0000337	273.0	CORNEAL OPACITY BOTH EYE SLIGHT, CONJUNCTIVITIS BOTH EYE MODERATE
8/02/85	7:52:00	0034567	273.0	CORNEAL OPACITY BOTH EYE SLIGHT, CONJUNCTIVITIS BOTH EYE SLIGHT
8/30/85	9:30:38	0000337	273.0	CORNEAL OPACITY BOTH EYE SLIGHT, CONJUNCTIVITIS BOTH EYE SLIGHT
9/13/85	9:16:38	0002920	273.0	CORNEAL OPACITY BOTH EYE SLIGHT, CONJUNCTIVITIS BOTH EYE SLIGHT
9/27/85	7:20:38	0000337	282.0	CORNEAL OPACITY BOTH EYE SLIGHT, CONJUNCTIVITIS BOTH EYE MODERATE
10/25/85	7:52:04	0072808	280.0	CORNEAL OPACITY BOTH EYE SLIGHT, CONJUNCTIVITIS LEFT EYE MODERATE
11/22/85	7:57:50	0000337	284.0	CORNEAL OPACITY BOTH EYE SLIGHT
12/20/85	8:33:16	0000337	284.0	CORNEAL OPACITY BOTH EYE SLIGHT
1/17/86	8:04:30	0000337	267.0	CORNEAL OPACITY BOTH EYE SLIGHT, EUTHANIZED
2/07/86	7:49:56	0034567	267.0	CORNEAL OPACITY BOTH EYE SLIGHT, EUTHANIZED

PAGE 10  
 DATE: 6/09/87  
 TIME: 14:40:13  
 EDS017 V4M11

**Appendix F (cont.): INDIVIDUAL ANIMAL HISTORIES**

STUDY: 0083009 CARCINOGENICITY BIOASSAY OF ISOBUTYL 2-CYANO-  
 COMPOUND: ISOBUTYL 2-CYANOACRYLATE ACRYLATE (IBC) IN MALE AND FEMALE RATS.  
 START DATE: 1/28/85

ANIMAL HISTORY

Animal ID: 84D00273 Species: D Sex: FEMALE Group: 100 UL/ANM

DATE	TIME	OPERATOR	WEIGHT (GRAMS)	CLINICAL OBSERVATIONS
2/15/85	8:38:32	0000337	236.0	CORNEAL OPACITY LEFT EYE MODERATE, EXOPHTHALMOS LEFT EYE SLIGHT
3/06/85	9:05:42	0000337		CORNEAL OPACITY LEFT EYE MODERATE, EXOPHTHALMOS LEFT EYE SLIGHT, TACHYPNEA SLIGHT, WHEEZING SLIGHT
3/15/85	7:52:38	0000337	247.0	CORNEAL OPACITY LEFT EYE MODERATE, EXOPHTHALMOS LEFT EYE SLIGHT, TACHYPNEA SLIGHT
4/05/85	8:31:40	0000337		CORNEAL OPACITY LEFT EYE MODERATE, EXOPHTHALMOS LEFT EYE SLIGHT
4/12/85	8:10:34	0000337	245.0	CORNEAL OPACITY LEFT EYE MODERATE, EXOPHTHALMOS LEFT EYE SLIGHT
4/17/85	8:20:40	0000337		CORNEAL OPACITY LEFT EYE MODERATE, EXOPHTHALMOS LEFT EYE SLIGHT, CONJUNCTIVITIS LEFT EYE SLIGHT
5/10/85	7:40:12	0000337	258.0	CORNEAL OPACITY LEFT EYE SLIGHT, EXOPHTHALMOS LEFT EYE SLIGHT
5/28/85	9:02:10	0000337		CORNEAL OPACITY LEFT EYE SLIGHT, EXOPHTHALMOS LEFT EYE SLIGHT, INTRAABDOMINAL MASS VENTRAL TO LIVER SIZE SMALL
6/07/85	7:50:00	0000337	266.0	CORNEAL OPACITY LEFT EYE SLIGHT, EXOPHTHALMOS LEFT EYE SLIGHT
7/03/85	7:20:06	0000337	286.0	CORNEAL OPACITY LEFT EYE MARKED, EXOPHTHALMOS LEFT EYE SLIGHT
8/02/85	7:52:30	0034567	294.0	EXOPHTHALMOS LEFT EYE SLIGHT, OPAQUE LENS LEFT EYE MARKED
8/30/85	9:32:22	0000337	304.0	OPAQUE LENS LEFT EYE MARKED, INTRAABDOMINAL MASS VENTRAL TO LIVER SIZE SMALL
9/27/85	7:21:16	0000337	309.0	OPAQUE LENS LEFT EYE MARKED, INTRAABDOMINAL MASS VENTRAL TO LIVER SIZE SMALL
10/16/85	12:24:14	0084799		OPAQUE LENS LEFT EYE MARKED, INTRAABDOMINAL MASS VENTRAL TO LIVER SIZE MEDIUM
10/25/85	7:52:54	0084799	305.0	INTRAABDOMINAL MASS VENTRAL TO LIVER SIZE MEDIUM, OPAQUE LENS LEFT EYE MARKED
11/18/85	10:48:22	0000337		INTRAABDOMINAL MASS VENTRAL TO LIVER SIZE MEDIUM, OPAQUE LENS LEFT EYE MARKED, EMACIATED MODERATE

PAGE 11  
 DATE: 6/09/87  
 TIME: 14:40:13  
 EDS017 V4M11

**Appendix F (cont.): INDIVIDUAL ANIMAL HISTORIES**

STUDY: 0083009 ISOBUTYL 2-CYANOACRYLATE CARCINOGENICITY BIOASSAY OF ISOBUTYL 2-CYANO-  
 COMPOUND: ISOBUTYL 2-CYANOACRYLATE ACRYLATE (IBC) IN MALE AND FEMALE RATS.  
 START DATE: 1/28/85

ANIMAL HISTORY

Animal ID: 84D00275 Species: D Sex: FEMALE Group: 100 UL/ANM

DATE	TIME	OPERATOR	WEIGHT (GRAMS)	CLINICAL OBSERVATIONS
2/15/85	8:38:54	0000337	276.0	CONJUNCTIVITIS RIGHT EYE SLIGHT
2/25/85	8:25:46	0000337		CONJUNCTIVITIS RIGHT EYE MARKED
3/15/85	7:53:32	0000337	287.0	CONJUNCTIVITIS RIGHT EYE MODERATE
3/25/85	8:34:34	0000337		CONJUNCTIVITIS RIGHT EYE MARKED
4/05/85	8:32:56	0000337		CONJUNCTIVITIS RIGHT EYE MARKED, CONJUNCTIVITIS LEFT EYE MODERATE
4/12/85	8:11:38	0000337	296.0	CONJUNCTIVITIS RIGHT EYE MODERATE
4/17/85	8:21:42	0000337		CONJUNCTIVITIS RIGHT EYE MARKED
5/10/85	7:41:36	0000337	295.0	CONJUNCTIVITIS RIGHT EYE MARKED
5/28/85	9:05:00	0000337		CONJUNCTIVITIS RIGHT EYE MARKED, INTRAABDOMINAL MASS VENTRAL TO LIVER SIZE LARGE
6/07/85	7:52:42	0000337	300.0	CONJUNCTIVITIS RIGHT EYE MARKED, INTRAABDOMINAL MASS VENTRAL TO LIVER SIZE LARGE
6/14/85	7:20:08	0000337		CONJUNCTIVITIS RIGHT EYE MARKED, INTRAABDOMINAL MASS VENTRAL TO LIVER SIZE LARGE

PAGE 12  
 DATE: 6/09/87  
 TIME: 14:40:13  
 EDS017 VAM11

**Appendix F (cont.): INDIVIDUAL ANIMAL HISTORIES**

CARCINOGENICITY BIOASSAY OF ISOBUTYL 2-CYANO-  
 ACRYLATE (IBC) IN MALE AND FEMALE RATS.

STUDY: 0083009  
 COMPOUND: ISOBUTYL 2-CYANOACRYLATE  
 START DATE: 1/28/85

ANIMAL HISTORY

Animal ID: 84D00278 Species: D Sex: FEMALE Group: CONTROLS

DATE	TIME	OPERATOR	WEIGHT (GRAMS)	CLINICAL OBSERVATIONS
2/15/85	8:40:02	0000337	225.0	CONJUNCTIVITIS LEFT EYE MODERATE
2/25/85	8:26:28	0000337		CONJUNCTIVITIS LEFT EYE SLIGHT
3/15/85	7:54:12	0000337	237.0	CONJUNCTIVITIS LEFT EYE SLIGHT
3/25/85	8:35:16	0000337		CONJUNCTIVITIS BOTH EYE MODERATE
4/12/85	8:12:16	0000337	234.0	CONJUNCTIVITIS BOTH EYE SLIGHT
4/17/85	8:22:26	0000337		CONJUNCTIVITIS BOTH EYE MODERATE
5/10/85	7:41:58	0000337	246.0	CONJUNCTIVITIS LEFT EYE MODERATE
6/07/85	7:54:48	0000337	239.0	CONJUNCTIVITIS LEFT EYE SLIGHT
7/03/85	7:22:34	0000337	260.0	CONJUNCTIVITIS LEFT EYE SLIGHT
8/02/85	7:53:48	0034567	261.0	CONJUNCTIVITIS LEFT EYE SLIGHT
8/30/85	9:35:36	0000337	276.0	CONJUNCTIVITIS LEFT EYE SLIGHT
9/09/85	9:11:02	0084799		CONJUNCTIVITIS LEFT EYE MARKED, SUBCUTANEOUS MASS PERI HUMEROUS RIGHT LEG SIZE LARGE
9/27/85	7:22:54	0084799	283.0	CONJUNCTIVITIS LEFT EYE MARKED, SUBCUTANEOUS MASS RIGHT SIDE HUMERUS SIZE LARGE
10/17/85	11:17:38	0000337		CONJUNCTIVITIS LEFT EYE MARKED, SUBCUTANEOUS MASS RIGHT SIDE HUMERUS SIZE LARGE



## Appendix F (cont.): INDIVIDUAL ANIMAL HISTORIES

PAGE 13  
DATE: 6/09/87  
TIME: 14:40:13  
EDS017 V4M11

STUDY: 0083009  
COMPOUND: ISOBUTYL 2-CYANOACRYLATE  
START DATE: 1/28/85

CARCINOGENICITY BIOASSAY OF ISOBUTYL 2-CYANO-  
ACRYLATE (IBC) IN MALE AND FEMALE RATS.

## ANIMAL HISTORY

Animal ID: 84D00279 Species: D Sex: FEMALE Group: 10 UL/ANM

DATE	TIME	OPERATOR	WEIGHT (GRAMS)	CLINICAL OBSERVATIONS
2/15/85	8:40:34	0000337	231.0	CONJUNCTIVITIS BOTH EYE MODERATE
2/25/85	8:27:06	0000337		CONJUNCTIVITIS BOTH EYE MARKED
3/06/85	9:07:48	0000337		CONJUNCTIVITIS BOTH EYE MARKED, STAIN CLEAR PERIANAL SLIGHT, TACHYPNEA SLIGHT
3/15/85	7:54:46	0000337	241.0	CONJUNCTIVITIS BOTH EYE MARKED, STAIN CLEAR PERIANAL SLIGHT, TACHYPNEA SLIGHT
3/25/85	8:36:18	0000337		CONJUNCTIVITIS BOTH EYE MARKED, TACHYPNEA MODERATE
4/12/85	8:12:50	0000337	254.0	CONJUNCTIVITIS BOTH EYE MARKED
5/10/85	7:42:28	0000337	261.0	CONJUNCTIVITIS BOTH EYE MARKED
6/07/85	7:55:26	0000337	266.0	CONJUNCTIVITIS BOTH EYE MARKED
7/03/85	7:23:16	0000337	273.0	CONJUNCTIVITIS BOTH EYE MARKED
8/02/85	7:57:36	0034567	276.0	CONJUNCTIVITIS BOTH EYE MARKED
8/19/85	13:52:18	0000337		MORIBUND
8/20/85	8:15:20	0000337		* No observations recorded.

**Appendix F (cont.): INDIVIDUAL ANIMAL HISTORIES**

STUDY: 0083009 CARCINOGENICITY BIOASSAY OF ISOBUTYL 2-CYANO-  
 COMPOUND: ISOBUTYL 2-CYANOACRYLATE ACRYLATE (IBC) IN MALE AND FEMALE RATS.  
 START DATE: 1/28/85

ANIMAL HISTORY

Animal ID: 84D00280 Species: D Sex: FEMALE Group: CONTROLS

DATE	TIME	OPERATOR	WEIGHT (GRAMS)	CLINICAL OBSERVATIONS
2/15/85	8:41:00	0000337	235.0	CORNEAL OPACITY BOTH EYE SLIGHT
3/06/85	9:08:58	0000337		CORNEAL OPACITY BOTH EYE SLIGHT, TACHYPNEA SLIGHT, STAIN CLEAR PERIANAL SLIGHT
3/15/85	7:55:30	0000337	241.0	CORNEAL OPACITY BOTH EYE SLIGHT, TACHYPNEA SLIGHT, STAIN CLEAR PERIANAL SLIGHT
4/05/85	8:36:12	0000337		CORNEAL OPACITY BOTH EYE SLIGHT, TACHYPNEA SLIGHT, STAIN CLEAR PERIANAL SLIGHT
4/12/85	8:13:44	0000337	234.0	CORNEAL OPACITY BOTH EYE SLIGHT
4/17/85	8:24:32	0000337		CORNEAL OPACITY BOTH EYE SLIGHT, STAIN YELLOW PERIANAL SLIGHT
5/10/85	7:42:54	0000337	249.0	CORNEAL OPACITY BOTH EYE SLIGHT
6/07/85	7:56:14	0000337	207.0	CORNEAL OPACITY BOTH EYE SLIGHT
6/07/85	7:56:40	0000337	247.0	CORNEAL OPACITY BOTH EYE SLIGHT
7/03/85	7:23:46	0000337	254.0	CORNEAL OPACITY BOTH EYE SLIGHT
8/02/85	7:57:58	0034567	262.0	CORNEAL OPACITY BOTH EYE SLIGHT
8/30/85	9:36:04	0000337	274.0	CORNEAL OPACITY BOTH EYE SLIGHT
9/27/85	7:24:44	0000337	277.0	CORNEAL OPACITY BOTH EYE SLIGHT
10/23/85	9:26:30	0002920		CORNEAL OPACITY BOTH EYE SLIGHT, MASS PERIVAGINAL MODERATE
10/25/85	7:56:08	0072808	277.0	CORNEAL OPACITY BOTH EYE SLIGHT, PERIVAGINAL MASS MEDIUM
11/22/85	7:58:14	0000337	267.0	CORNEAL OPACITY BOTH EYE SLIGHT, SPLENIC MASS SIZE MEDIUM
12/12/85	9:42:12	0000337		CORNEAL OPACITY BOTH EYE SLIGHT, SPLENIC MASS SIZE MEDIUM, PALLOR MODERATE
12/20/85	8:33:34	0084799	258.0	PALLOR MODERATE, CORNEAL OPACITY BOTH EYE SLIGHT, INTRAABDOMINAL MASS SPLENIC SIZE LARGE, SUBCUTANEOUS MASS PERIGENITAL SIZE MEDIUM
1/17/86	8:04:52	0084799	260.0	PALLOR MODERATE, CORNEAL OPACITY EYE SLIGHT, SPLENIC MASS SIZE LARGE

PAGE 15  
 DATE: 6/09/87  
 TIME: 14:40:13  
 EDS017 V4M11

**Appendix F (cont.): INDIVIDUAL ANIMAL HISTORIES**

STUDY: 0083009  
 COMPOUND: ISOBUTYL 2-CYANOACRYLATE  
 START DATE: 1/28/85  
 CARCINOGENICITY BIOASSAY OF ISOBUTYL 2-CYANO-  
 ACRYLATE (IBC) IN MALE AND FEMALE RATS.

ANIMAL HISTORY

Animal ID: 84D00282 Species: D Sex: FEMALE Group: 10 UL/ANM

DATE	TIME	OPERATOR	WEIGHT (GRAMS)	CLINICAL OBSERVATIONS
2/15/85	8:41:20	0000337	227.0	NORMAL
3/15/85	8:17:40	0000337	236.0	NORMAL
4/12/85	8:14:38	0000337	237.0	NORMAL
5/10/85	7:43:18	0000337	242.0	NORMAL
6/07/85	7:57:02	0000337	239.0	NORMAL
7/03/85	7:24:14	0000337	238.0	NORMAL
8/02/85	7:58:20	0034567	244.0	NORMAL
8/30/85	9:36:26	0000337	262.0	INTRAABDOMINAL MASS VENTRAL TO LIVER SIZE SMALL
9/27/85	7:25:04	0000337	263.0	INTRAABDOMINAL MASS VENTRAL TO LIVER SIZE SMALL
10/25/85	7:57:56	0072808	260.0	INTRAABDOMINAL MASS VENTRAL TO LIVER SIZE SMALL
11/22/85	8:00:46	0000337	265.0	INTRAABDOMINAL MASS VENTRAL TO LIVER SIZE MEDIUM
12/20/85	8:36:08	0000337	262.0	INTRAABDOMINAL MASS VENTRAL TO LIVER SIZE LARGE
1/17/86	8:08:28	0000337	274.0	INTRAABDOMINAL MASS VENTRAL TO LIVER SIZE MEDIUM
2/07/86	7:51:08	0034567	246.0	INTRAABDOMINAL MASS VENTRAL TO LIVER SIZE MEDIUM, EUTHANIZED

**Appendix F (cont.): INDIVIDUAL ANIMAL HISTORIES**

STUDY: 0083009 CARCINOGENICITY BIOASSAY OF ISOBUTYL 2-CYANO-  
 COMPOUND: ISOBUTYL 2-CYANOACRYLATE ACRYLATE (IBC) IN MALE AND FEMALE RATS.  
 START DATE: 1/28/85

PAGE 160  
 DATE: 6/09/87  
 TIME: 14:40:13  
 EDS017 VAMILL

ANIMAL HISTORY

Animal ID: 84D00284 Species: D Sex: FEMALE Group: 10 UL/ANN

DATE	TIME	WEIGHT (GRAMS)	OPERATOR	CLINICAL OBSERVATIONS
2/15/85	8:41:42	221.0	0000337	CORNEAL OPACITY BOTH EYE SLIGHT, CONJUNCTIVITIS LEFT EYE SLIGHT
3/15/85	8:18:00	227.0	0000337	CORNEAL OPACITY BOTH EYE SLIGHT
4/12/85	8:15:22	225.0	0000337	CORNEAL OPACITY BOTH EYE SLIGHT, CONJUNCTIVITIS LEFT EYE SLIGHT
4/17/85	8:26:04		0000337	CORNEAL OPACITY BOTH EYE SLIGHT, CONJUNCTIVITIS LEFT EYE MODERATE, CONJUNCTIVITIS RIGHT EYE SLIGHT
5/10/85	7:43:40	237.0	0000337	CORNEAL OPACITY BOTH EYE SLIGHT, CONJUNCTIVITIS LEFT EYE MODERATE
6/07/85	7:57:18	242.0	0000337	CORNEAL OPACITY BOTH EYE SLIGHT, CONJUNCTIVITIS LEFT EYE MARKED
7/03/85	7:24:44	259.0	0000337	CORNEAL OPACITY BOTH EYE SLIGHT, CONJUNCTIVITIS LEFT EYE MARKED
8/02/85	7:58:42	263.0	0034567	CORNEAL OPACITY BOTH EYE SLIGHT, CONJUNCTIVITIS LEFT EYE MARKED
8/30/85	9:37:48	259.0	0000337	CORNEAL OPACITY BOTH EYE SLIGHT, CONJUNCTIVITIS LEFT EYE MARKED
9/27/85	7:25:56	269.0	0000337	CORNEAL OPACITY BOTH EYE SLIGHT, CONJUNCTIVITIS LEFT EYE MARKED
10/25/85	7:58:58	271.0	0072808	CORNEAL OPACITY BOTH EYE SLIGHT, CONJUNCTIVITIS LEFT EYE MARKED
11/22/85	8:01:56	275.0	0000337	CORNEAL OPACITY BOTH EYE SLIGHT, CONJUNCTIVITIS LEFT EYE SLIGHT
12/20/85	8:37:04	272.0	0000337	CORNEAL OPACITY BOTH EYE SLIGHT, CONJUNCTIVITIS LEFT EYE MODERATE
1/17/86	8:09:22	273.0	0000337	CORNEAL OPACITY BOTH EYE SLIGHT, CONJUNCTIVITIS LEFT EYE SLIGHT
2/07/86	7:54:30	262.0	0034567	CORNEAL OPACITY BOTH EYE SLIGHT, CONJUNCTIVITIS LEFT EYE SLIGHT, EUTHANIZED

PAGE 17  
 DATE: 6/09/87  
 TIME: 14:40:13  
 EDS017 V4M11

**Appendix F (cont.): INDIVIDUAL ANIMAL HISTORIES**

STUDY: 0083009 CARCINOGENICITY BIOASSAY OF ISOBUTYL 2-CYANO-  
 COMPOUND: ISOBUTYL 2-CYANOACRYLATE ACRYLATE (IBC) IN MALE AND FEMALE RATS.  
 START DATE: 1/28/85

ANIMAL HISTORY

Animal ID: 84D00285 Species: D Sex: FEMALE Group: CONTROLS

DATE	TIME	OPERATOR	WEIGHT (GRAMS)	CLINICAL OBSERVATIONS
2/15/85	8:42:26	0000337	237.0	CORNEAL OPACITY RIGHT EYE MODERATE, CORNEAL OPACITY LEFT EYE SLIGHT, CONJUNCTIVITIS RIGHT EYE MODERATE
2/25/85	8:29:04	0000337		CORNEAL OPACITY RIGHT EYE MODERATE, CORNEAL OPACITY LEFT EYE SLIGHT, CONJUNCTIVITIS RIGHT EYE SLIGHT
3/15/85	8:18:24	0000337	247.0	CORNEAL OPACITY RIGHT EYE MODERATE, CORNEAL OPACITY LEFT EYE SLIGHT, CONJUNCTIVITIS RIGHT EYE SLIGHT
4/12/85	8:16:18	0000337	245.0	CORNEAL OPACITY RIGHT EYE MODERATE, CORNEAL OPACITY LEFT EYE SLIGHT, CONJUNCTIVITIS RIGHT EYE SLIGHT
4/17/85	8:27:14	0000337		CORNEAL OPACITY RIGHT EYE MODERATE, CORNEAL OPACITY LEFT EYE SLIGHT, CONJUNCTIVITIS RIGHT EYE MODERATE
5/10/85	7:44:16	0000337	252.0	CORNEAL OPACITY RIGHT EYE MODERATE, CORNEAL OPACITY LEFT EYE SLIGHT, CONJUNCTIVITIS RIGHT EYE MODERATE
6/07/85	7:58:08	0000337	248.0	CORNEAL OPACITY RIGHT EYE MODERATE, CORNEAL OPACITY LEFT EYE SLIGHT, CONJUNCTIVITIS RIGHT EYE MODERATE
7/03/85	7:25:18	0000337	255.0	CORNEAL OPACITY RIGHT EYE MODERATE, CORNEAL OPACITY LEFT EYE SLIGHT, CONJUNCTIVITIS RIGHT EYE MODERATE
8/02/85	7:59:12	0034567	264.0	CORNEAL OPACITY RIGHT EYE MODERATE, CORNEAL OPACITY LEFT EYE SLIGHT, CONJUNCTIVITIS RIGHT EYE MODERATE
8/30/85	9:38:12	0000337	278.0	CORNEAL OPACITY RIGHT EYE MODERATE, CORNEAL OPACITY LEFT EYE SLIGHT, CONJUNCTIVITIS RIGHT EYE SLIGHT
9/27/85	7:26:18	0000337	280.0	CORNEAL OPACITY RIGHT EYE MODERATE, CORNEAL OPACITY LEFT EYE SLIGHT, CONJUNCTIVITIS RIGHT EYE SLIGHT
10/25/85	7:59:42	0072808	278.0	CORNEAL OPACITY RIGHT EYE MODERATE, CORNEAL OPACITY LEFT EYE SLIGHT, CONJUNCTIVITIS RIGHT EYE SLIGHT
11/22/85	8:02:30	0000337	287.0	CORNEAL OPACITY RIGHT EYE MODERATE, CORNEAL OPACITY LEFT EYE SLIGHT, CONJUNCTIVITIS RIGHT EYE SLIGHT
12/20/85	8:37:28	0000337	286.0	CORNEAL OPACITY RIGHT EYE MODERATE, CORNEAL OPACITY LEFT EYE SLIGHT
1/17/86	8:10:24	0000337	283.0	CORNEAL OPACITY RIGHT EYE MODERATE, CORNEAL OPACITY LEFT EYE SLIGHT
2/07/86	7:55:46	0034567	249.0	CORNEAL OPACITY RIGHT EYE MODERATE, CORNEAL OPACITY LEFT EYE SLIGHT, PALLOR MODERATE, EUTHANIZED

**Appendix F (cont.): INDIVIDUAL ANIMAL HISTORIES**

STUDY: 0083009  
 COMPOUND: ISOBUTYL 2-CYANOACRYLATE  
 START DATE: 1/28/85

CARCINOGENICITY BIOASSAY OF ISOBUTYL 2-CYANO-  
 ACRYLATE (IBC) IN MALE AND FEMALE RATS.

ANIMAL HISTORY

Animal ID: 84D00286 Species: D Sex: FEMALE Group: 100 UL/ANM

DATE	TIME	OPERATOR	WEIGHT (GfAMS)	CLINICAL OBSERVATIONS
2/15/85	8:43:02	0000337	207.0	CORNEAL OPACITY RIGHT EYE SLIGHT
3/15/85	8:18:46	0000337	216.0	CORNEAL OPACITY RIGHT EYE SLIGHT
4/12/85	8:17:12	0000337	222.0	CORNEAL OPACITY RIGHT EYE SLIGHT
5/10/85	7:44:52	0000337	234.0	CORNEAL OPACITY RIGHT EYE SLIGHT
6/07/85	7:58:36	0000337	236.0	CORNEAL OPACITY RIGHT EYE SLIGHT
7/03/85	7:25:58	0000337	234.0	CORNEAL OPACITY RIGHT EYE SLIGHT, INTRAABDOMINAL MASS VENTRAL TO LIVER SIZE SMALL
8/02/85	7:59:34	0034567	240.0	CORNEAL OPACITY RIGHT EYE SLIGHT, INTRAABDOMINAL MASS VENTRAL TO LIVER SIZE SMALL, OCULAR PALLOR SLIGHT
8/02/85	10:51:04	0034567	237.0	* No observations recorded.

## Appendix F (cont.): INDIVIDUAL ANIMAL HISTORIES

PAGE 19  
DATE: 6/09/87  
TIME: 14:40:13  
EDS017 V4M11

STUDY: 0083009  
COMPOUND: ISOBUTYL 2-CYANOACRYLATE  
START DATE: 1/28/85

CARCINOGENICITY BIOASSAY OF ISOBUTYL 2-CYANO-  
ACRYLATE (IBC) IN MALE AND FEMALE RATS.

## ANIMAL HISTORY

Animal ID: 84D00287 Species: D Sex: FEMALE Group: 10 UL/ANM

DATE	TIME	OPERATOR	WEIGHT (GRAMS)	CLINICAL OBSERVATIONS
2/04/85	7:58:52	0084799		CONJUNCTIVITIS LEFT EYE SLIGHT, PROLAPSED LENS LEFT EYE MARKED, OPAQUE LENS LEFT EYE MARKED
2/08/85	8:34:58	0000337		CONJUNCTIVITIS LEFT EYE MARKED, PROLAPSED LENS LEFT EYE, OPACITY LEFT EYE MARKED
2/15/85	8:43:48	0084799	229.0	PROLAPSED LENS LEFT EYE MARKED, OPAQUE LENS LEFT EYE MARKED, CONJUNCTIVITIS LEFT EYE MODERATE
3/06/85	9:11:06	0000337		PROLAPSED LENS LEFT EYE MARKED, OPAQUE LENS LEFT EYE MARKED, CONJUNCTIVITIS LEFT EYE MODERATE, TACHYPNEA MODERATE
3/15/85	8:19:04	0000337	230.0	PROLAPSED LENS LEFT EYE MARKED, OPAQUE LENS LEFT EYE MARKED, TACHYPNEA SLIGHT, WHEEZING SLIGHT, CONJUNCTIVITIS LEFT EYE MARKED
3/25/85	8:40:10	0000337		PROLAPSED LENS LEFT EYE MARKED, OPAQUE LENS LEFT EYE MARKED, TACHYPNEA MODERATE, CONJUNCTIVITIS LEFT EYE MARKED
4/12/85	8:17:40	0000337	229.0	CONJUNCTIVITIS LEFT EYE MARKED, PROLAPSED LENS LEFT EYE MARKED, OPAQUE LENS LEFT EYE MARKED
5/10/85	7:45:16	0000337	233.0	CONJUNCTIVITIS LEFT EYE MARKED, PROLAPSED LENS LEFT EYE MARKED, OPAQUE LENS LEFT EYE MARKED
6/07/85	7:59:00	0000337	237.0	CONJUNCTIVITIS LEFT EYE MARKED, PROLAPSED LENS LEFT EYE MARKED, OPAQUE LENS LEFT EYE MARKED
7/03/85	7:29:50	0000337	236.0	CONJUNCTIVITIS LEFT EYE MARKED, PROLAPSED LENS LEFT EYE MARKED, OPAQUE LENS LEFT EYE MARKED
7/10/85	8:53:34	0000337		CONJUNCTIVITIS LEFT EYE MARKED, PROLAPSED LENS LEFT EYE MARKED, OPAQUE LENS LEFT EYE MARKED, TACHYPNEA MODERATE
8/02/85	8:06:32	0084799	250.0	CONJUNCTIVITIS LEFT EYE MARKED, PROLAPSED LENS LEFT EYE MARKED, OPAQUE LENS LEFT EYE MARKED
8/30/85	9:38:40	0084799	268.0	CONJUNCTIVITIS LEFT EYE SLIGHT, PROLAPSED LENS LEFT EYE MARKED, OPAQUE LENS LEFT EYE MARKED
9/27/85	7:26:44	0000337	270.0	CONJUNCTIVITIS LEFT EYE SLIGHT, OPAQUE LENS LEFT EYE MARKED
10/25/85	8:00:40	0072808	278.0	CONJUNCTIVITIS LEFT EYE SLIGHT, OPAQUE LENS LEFT EYE MODERATE
11/22/85	8:02:52	0000337	278.0	CONJUNCTIVITIS LEFT EYE SLIGHT, OPAQUE LENS LEFT EYE MODERATE
12/20/85	8:38:00	0000337	288.0	CONJUNCTIVITIS LEFT EYE SLIGHT, OPAQUE LENS LEFT EYE MODERATE
1/17/86	8:10:46	0084799	298.0	CONJUNCTIVITIS LEFT EYE SLIGHT, OPAQUE LENS LEFT EYE MODERATE
2/07/86	7:57:12	0034567	270.0	CONJUNCTIVITIS LEFT EYE MARKED, OPAQUE LENS LEFT EYE MARKED, EUTHANIZED

**Appendix F (cont.): INDIVIDUAL ANIMAL HISTORIES**

CARCINOGENICITY BIOASSAY OF ISOBUTYL 2-CYANO-ACRYLATE (IBC) IN MALE AND FEMALE RATS.

STUDY: 0083009  
COMPOUND: ISOBUTYL 2-CYANOACRYLATE  
START DATE: 1/28/85

**ANIMAL HISTORY**

Animal ID: 84D00288 Species: D Sex: FEMALE Group: CONTROLS

DATE	TIME	OPERATOR	WEIGHT (GRAMS)	CLINICAL OBSERVATIONS
2/08/85	8:37:54	0000337		CORNEAL OPACITY BOTH EYE SLIGHT, CONJUNCTIVITIS BOTH EYE SLIGHT
2/15/85	8:46:46	0000337	222.0	CORNEAL OPACITY BOTH EYE SLIGHT
3/06/85	9:13:20	0000337		CORNEAL OPACITY BOTH EYE SLIGHT, STAIN BROWN NOSE SLIGHT
3/15/85	8:22:02	0000337	221.0	CORNEAL OPACITY BOTH EYE SLIGHT
4/12/85	8:19:50	0000337	228.0	CORNEAL OPACITY BOTH EYE SLIGHT
5/10/85	7:46:38	0000337	227.0	CORNEAL OPACITY BOTH EYE SLIGHT
6/07/85	8:00:24	0000337	220.0	CORNEAL OPACITY BOTH EYE SLIGHT
7/03/85	7:31:40	0000337	208.0	CORNEAL OPACITY BOTH EYE SLIGHT
8/02/85	8:10:42	0034567	192.0	CORNEAL OPACITY BOTH EYE SLIGHT
8/30/85	9:40:42	0000337	179.0	CORNEAL OPACITY BOTH EYE SLIGHT
9/09/85	12:08:30	0000337		ANIMAL HAS BECOME SEVERELY EMACIATED UNKNOWN CAUSE



## Appendix F (cont.): INDIVIDUAL ANIMAL HISTORIES

PAGE 21  
DATE: 6/09/87  
TIME: 14:40:13  
EDS017 V4M11

STUDY: 0083009 ISOBUTYL 2-CYANOACRYLATE CARCINOGENICITY BIOASSAY OF ISOBUTYL 2-CYANO-  
COMPOUND: ISOBUTYL 2-CYANOACRYLATE ACRYLATE (IBC) IN MALE AND FEMALE RATS.  
START DATE: 1/28/85

## ANIMAL HISTORY

Animal ID: 84D00289 Species: D Sex: FEMALE Group: 10 UL/ANM

DATE	TIME	OPERATOR	WEIGHT (GRAMS)	CLINICAL OBSERVATIONS
2/15/85	8:47:22	0000337	218.0	CORNEAL OPACITY LEFT EYE SLIGHT
3/15/85	8:24:42	0000337	215.0	CORNEAL OPACITY LEFT EYE SLIGHT
4/12/85	8:21:04	0000337	220.0	CORNEAL OPACITY LEFT EYE SLIGHT
5/10/85	7:46:58	0000337	216.0	CORNEAL OPACITY LEFT EYE SLIGHT
6/07/85	8:00:50	0000337	222.0	CORNEAL OPACITY LEFT EYE SLIGHT
7/03/85	7:32:34	0000337	233.0	CORNEAL OPACITY LEFT EYE SLIGHT
8/02/85	8:11:30	0034567	236.0	CORNEAL OPACITY LEFT EYE SLIGHT
8/30/85	9:41:46	0000337	242.0	CORNEAL OPACITY LEFT EYE SLIGHT
9/27/85	7:28:22	0000337	252.0	CORNEAL OPACITY LEFT EYE SLIGHT
10/25/85	8:02:26	0072808	247.0	CORNEAL OPACITY LEFT EYE SLIGHT
11/22/85	8:03:46	0000337	242.0	CORNEAL OPACITY LEFT EYE SLIGHT
12/20/85	8:38:46	0000337	245.0	CORNEAL OPACITY LEFT EYE SLIGHT
1/11/86	10:05:00	0067831		DEATH

PAGE 22  
 DATE: 6/09/87  
 TIME: 14:40:13  
 EDS017 V4M11

**Appendix F (cont.): INDIVIDUAL ANIMAL HISTORIES**

STUDY: 0083009  
 COMPOUND: ISOBUTYL 2-CYANOACRYLATE  
 START DATE: 1/28/85  
 CARCINOGENICITY BIOASSAY OF ISOBUTYL 2-CYANO-  
 ACRYLATE (IBC) IN MALE AND FEMALE RATS.

ANIMAL HISTORY

Animal ID: 84D00290 Species: D Sex: FEMALE Group: CONTROLS

DATE	TIME	OPERATOR	WEIGHT (GRAMS)	CLINICAL OBSERVATIONS
2/15/85	8:47:42	0000337	246.0	NORMAL
3/15/85	8:25:16	0000337	248.0	NORMAL
4/12/85	8:21:32	0000337	259.0	NORMAL
4/18/85	8:19:06	0000337		CONJUNCTIVITIS LEFT EYE SLIGHT
5/10/85	7:47:46	0000337	269.0	NORMAL
6/07/85	7:01:22	0000337	282.0	NORMAL
7/03/85	7:33:18	0000337	266.0	NORMAL
8/02/85	8:11:58	0034567	287.0	NORMAL
8/30/85	9:42:12	0000337	287.0	NORMAL
9/27/85	7:28:38	0000337	303.0	NORMAL
10/25/85	8:03:20	0072808	263.0	NORMAL
11/22/85	8:04:10	0000337	249.0	PALLOR MARKED
11/26/85	12:44:36	0000337		PALLOR MARKED

## Appendix F (cont.): INDIVIDUAL ANIMAL HISTORIES

PAGE 23  
DATE: 6/09/87  
TIME: 14:40:13  
EDS017 V4M11

STUDY: 0083009 ISOBUTYL 2-CYANOACRYLATE CARCINOGENICITY BIOASSAY OF ISOBUTYL 2-CYANO-  
COMPOUND: ISOBUTYL 2-CYANOACRYLATE ACRYLATE (IBC) IN MALE AND FEMALE RATS.  
START DATE: 1/28/85

## ANIMAL HISTORY

Animal ID: 84D00291 Species: D Sex: FEMALE Group: 10 UL/ANM

DATE	TIME	OPERATOR	WEIGHT (GRAMS)	CLINICAL OBSERVATIONS
2/15/85	8:48:02	0000337	242.0	CORNEAL OPACITY BOTH EYE SLIGHT
3/15/85	8:25:44	0000337	246.0	CORNEAL OPACITY BOTH EYE SLIGHT, CONJUNCTIVITIS LEFT EYE SLIGHT
4/12/85	8:22:16	0000337	259.0	CORNEAL OPACITY BOTH EYE SLIGHT
5/10/85	7:48:20	0000337	272.0	CORNEAL OPACITY BOTH EYE SLIGHT
5/29/85	7:10:06	0000337	276.0	CORNEAL OPACITY BOTH EYE SLIGHT, CONJUNCTIVITIS BOTH EYE SLIGHT
6/07/85	8:01:40	0000337	276.0	CORNEAL OPACITY BOTH EYE SLIGHT, CONJUNCTIVITIS BOTH EYE SLIGHT
7/03/85	7:33:58	0000337	276.0	CORNEAL OPACITY BOTH EYE SLIGHT, CONJUNCTIVITIS BOTH EYE SLIGHT
7/10/85	8:57:14	0000337	280.0	CORNEAL OPACITY BOTH EYE SLIGHT, CONJUNCTIVITIS LEFT EYE MODERATE
8/02/85	8:12:14	0034567	280.0	CORNEAL OPACITY BOTH EYE SLIGHT, CONJUNCTIVITIS LEFT EYE MODERATE
8/30/85	9:42:54	0000337	286.0	CORNEAL OPACITY BOTH EYE SLIGHT, CONJUNCTIVITIS LEFT EYE MODERATE
9/27/85	7:29:40	0000337	294.0	CORNEAL OPACITY BOTH EYE SLIGHT, CONJUNCTIVITIS LEFT EYE MODERATE
10/25/85	8:03:54	0072808	304.0	CORNEAL OPACITY BOTH EYE SLIGHT
11/22/85	8:05:22	0000337	305.0	CORNEAL OPACITY BOTH EYE SLIGHT
12/20/85	8:39:04	0000337	311.0	CORNEAL OPACITY BOTH EYE SLIGHT
1/17/86	8:11:34	0000337	310.0	CORNEAL OPACITY BOTH EYE SLIGHT
2/07/86	8:00:06	0034567	299.0	CORNEAL OPACITY BOTH EYE SLIGHT, INTRAABDOMINAL MASS VENTRAL TO LIVER SIZE MEDIUM, EUTHANIZED

**Appendix F (cont.): INDIVIDUAL ANIMAL HISTORIES**

STUDY: 0083009  
 COMPOUND: ISOBUTYL 2-CYANOACRYLATE  
 START DATE: 1/28/85  
 CARCINOGENICITY BIOASSAY OF ISOBUTYL 2-CYANO-  
 ACRYLATE (IBC) IN MALE AND FEMALE RATS.

ANIMAL HISTORY

Animal ID: 84D00292 Species: D Sex: FEMALE Group: 10 UL/ANM

DATE	TIME	OPERATOR	WEIGHT (GRAMS)	CLINICAL OBSERVATIONS
2/15/85	8:48:54	0000337	234.0	IRIS ABNORMALITY ( IRIS TEAR DORSAL ASPECT ) LEFT EYE MODERATE, CORNEAL OPACITY BOTH EYE SLIGHT
3/15/85	8:27:44	0000337	237.0	IRIS ABNORMALITY (TEAR IN DORSAL ASPECT) LEFT EYE MODERATE, CORNEAL OPACITY BOTH EYE SLIGHT
4/12/85	8:22:50	0000337	243.0	CORNEAL OPACITY BOTH EYE SLIGHT, IRIS ABNORMALITY (TEAR IN DORSAL ASPECT) SLIGHT
5/10/85	7:48:44	0000337	247.0	CORNEAL OPACITY BOTH EYE SLIGHT, IRIS ABNORMALITY (TEAR IN DORSAL ASPECT) SLIGHT
6/07/85	8:02:04	0084799	255.0	CORNEAL OPACITY BOTH EYE SLIGHT, IRIS ABNORMALITY (TEAR IN DORSAL ASPECT) SLIGHT
7/03/85	7:34:38	0000337	255.0	IRIS ABNORMALITY (TEAR IN DORSAL ASPECT) RIGHT EYE SLIGHT
8/02/85	8:12:38	0034567	256.0	IRIS ABNORMALITY (TEAR IN DORSAL ASPECT ) LEFT EYE SLIGHT
8/30/85	9:43:28	0000337	259.0	IRIS ABNORMALITY (TEAR IN DORSAL ASPECT) LEFT EYE SLIGHT, INTRAABDOMINAL MASS VENTRAL TO LIVER SIZE SMALL
9/27/85	7:30:10	0084799	265.0	IRIS ABNORMALITY (TEAR IN DORSAL ASPECT) LEFT EYE SLIGHT, INTRAABDOMINAL MASS VENTRAL TO LIVER SIZE SMALL
10/25/85	8:04:28	0084799	274.0	IRIS ABNORMALITY (TEAR LEFT EYE) SLIGHT, INTRAABDOMINAL MASS VENTRAL TO LIVER SIZE SMALL, ENLARGED GLOBE LEFT EYE MARKED
11/22/85	8:05:44	0000337	277.0	IRIS ABNORMALITY (TEAR) LEFT EYE SLIGHT, INTRAABDOMINAL MASS VENTRAL TO LIVER SIZE SMALL, ENLARGED GLOBE LEFT EYE MARKED
12/20/85	8:39:22	0000337	281.0	ENLARGED LEFT EYE, OPAQUE LENS LEFT EYE MODERATE, INTRAABDOMINAL MASS VENTRAL TO LIVER SIZE SMALL
1/17/86	8:11:52	0084799	281.0	ENLARGED GLOBE LEFT EYE, OPAQUE LENS LEFT EYE MARKED, INTRAABDOMINAL MASS VENTRAL TO LIVER SIZE SMALL
2/07/86	8:03:28	0034567	260.0	INTRAABDOMINAL MASS VENTRAL TO LIVER SIZE SMALL, ENLARGED GLOBE LEFT EYE, OPAQUE LENS LEFT EYE MARKED, EUTHANIZED

## Appendix F (cont.): INDIVIDUAL ANIMAL HISTORIES

PAGE 25  
DATE: 6/09/87  
TIME: 14:40:13  
EDS017 V4M11

STUDY: 0083009  
COMPOUND: ISOBUTYL 2-CYANOACRYLATE  
START DATE: 1/28/85

CARCINOGENICITY BIOASSAY OF ISOBUTYL 2-CYANO-  
ACRYLATE (IBC) IN MALE AND FEMALE RATS.

ANIMAL HISTORY

Animal ID: 84D00293 Species: D Sex: FEMALE Group: 10 UL/ANM

DATE	TIME	OPERATOR	WEIGHT (GRAMS)	CLINICAL OBSERVATIONS
2/15/85	8:51:24	0000337	208.0	NORMAL
3/15/85	8:31:22	0000337	213.0	NORMAL
3/19/85	7:40:36	0034567		CONJUNCTIVITIS RIGHT EYE SLIGHT
4/09/85	9:08:10	0000337		NORMAL
4/12/85	8:24:24	0000337	218.0	NORMAL
5/10/85	7:50:06	0000337	213.0	NORMAL
6/07/85	8:03:08	0000337	219.0	NORMAL
7/03/85	7:36:52	0000337	212.0	NORMAL
8/02/85	8:15:24	0034567	223.0	NORMAL
8/30/85	9:45:34	0000337	225.0	NORMAL
9/27/85	7:32:02	0000337	236.0	NORMAL
10/25/85	8:13:10	0072808	245.0	NORMAL
11/22/85	8:08:58	0000337	243.0	NORMAL
12/20/85	8:40:50	0000337	242.0	NORMAL
1/17/86	8:13:32	0000337	243.0	NORMAL
2/07/86	8:06:32	0034567	224.0	NORMAL / EUTHANIZED

PAGE 28D  
 DATE: 6/09/87  
 TIME: 14:40:13  
 EDS017 V4M1

### Appendix F (cont.): INDIVIDUAL ANIMAL HISTORIES

CARCINOGENICITY BIOASSAY OF ISOBUTYL 2-CYANO-  
 ACRYLATE (IBC) IN MALE AND FEMALE RATS.

STUDY: 0083009  
 COMPOUND: ISOBUTYL 2-CYANOACRYLATE  
 START DATE: 1/28/85

#### ANIMAL HISTORY

Animal ID: 84D00294 Species: D Sex: FEMALE Group: 10 UL/ANM

DATE	TIME	OPERATOR	WEIGHT (GRAMS)	CLINICAL OBSERVATIONS
2/15/85	8:52:14	0000337	239.0	CORNEAL OPACITY BOTH EYE SLIGHT
3/15/85	8:32:04	0000337	235.0	CORNEAL OPACITY BOTH EYE SLIGHT
4/09/85	9:07:04	0000337		CORNEAL OPACITY BOTH EYE SLIGHT, STAIN CLEAR PERIANAL SLIGHT
4/12/85	8:25:34	0000337	245.0	CORNEAL OPACITY BOTH EYE SLIGHT
5/10/85	7:50:24	0000337	249.0	CORNEAL OPACITY BOTH EYE SLIGHT
6/07/85	8:03:58	0000337	252.0	CORNEAL OPACITY BOTH EYE SLIGHT
7/03/85	7:37:28	0000337	250.0	CORNEAL OPACITY BOTH EYE SLIGHT, CONJUNCTIVITIS LEFT EYE MODERATE
8/02/85	8:15:54	0034567	267.0	CORNEAL OPACITY BOTH EYE SLIGHT, CONJUNCTIVITIS LEFT EYE SLIGHT, INTRAABDOMINAL MASS VENTRAL TO LIVER SIZE SMALL
8/30/85	9:46:12	0000337	266.0	CORNEAL OPACITY BOTH EYE SLIGHT, INTRAABDOMINAL MASS VENTRAL TO LIVER SIZE SMALL
9/13/85	9:28:58	0002920		CORNEAL OPACITY BOTH EYE SLIGHT, INTRAABDOMINAL MASS VENTRAL TO LIVER SIZE SMALL
9/27/85	7:32:24	0000337	277.0	CORNEAL OPACITY BOTH EYE SLIGHT, INTRAABDOMINAL MASS VENTRAL TO LIVER SIZE SMALL
10/25/85	8:13:32	0072808	277.0	CORNEAL OPACITY BOTH EYE SLIGHT, INTRAABDOMINAL MASS VENTRAL TO LIVER SIZE SMALL
11/22/85	8:09:24	0084799	275.0	CORNEAL OPACITY BOTH EYE SLIGHT, INTRAABDOMINAL MASS VENTRAL TO LIVER SIZE SMALL
12/20/85	8:41:12	0000337	272.0	CORNEAL OPACITY BOTH EYE SLIGHT, INTRAABDOMINAL MASS VENTRAL TO LIVER SIZE SMALL
1/17/86	8:13:46	0000337	266.0	CORNEAL OPACITY BOTH EYE SLIGHT, CONJUNCTIVITIS LEFT EYE SLIGHT, INTRAABDOMINAL MASS VENTRAL TO LIVER SIZE SMALL
2/07/86	8:08:20	0034567	247.0	CORNEAL OPACITY BOTH EYE SLIGHT, CONJUNCTIVITIS LEFT EYE SLIGHT, INTRAABDOMINAL MASS VENTRAL TO LIVER SIZE SMALL, EUTHANIZED

## Appendix F (cont.): INDIVIDUAL ANIMAL HISTORIES

STUDY: 0083009  
 COMPOUND: ISOBUTYL 2-CYANOACRYLATE  
 START DATE: 1/28/85

PAGE 27  
 DATE: 6/09/87  
 TIME: 14:40:13  
 EDS017 V4M11

CARCINOGENICITY BIOASSAY OF ISOBUTYL 2-CYANO-  
 ACRYLATE (IBC) IN MALE AND FEMALE RATS.

## ANIMAL HISTORY

Animal ID: 84D00296 Species: D Sex: FEMALE Group: 100 UL/ANM

DATE	TIME	OPERATOR	WEIGHT (GRAMS)	CLINICAL OBSERVATIONS
2/15/85	8:52:44	0000337	212.0	NORMAL
2/19/85	8:04:04	0000337		STAIN YELLOW PERIANAL SLIGHT
3/01/85	7:55:20	0000337		STAIN CLEAR PERIANAL SLIGHT, STAIN BROWN NOSE SLIGHT
3/15/85	8:32:20	0084799	211.0	STAIN BROWN NOSE SLIGHT, STAIN YELLOW PERIANAL MARKED, INTRAABDOMINAL MASS LARGE

**Appendix F (cont.): INDIVIDUAL ANIMAL HISTORIES**

STUDY: 0083009  
COMPOUND: ISOBUTYL 2-CYANOACRYLATE  
START DATE: 1/28/85  
CARCINOGENICITY BIOASSAY OF ISOBUTYL 2-CYANO-  
ACRYLATE (IBC) IN MALE AND FEMALE RATS.

Animal ID: 84D00297 Species: D Sex: FEMALE Group: 10 UL/ANM  
ANIMAL HISTORY

DATE	TIME	OPERATOR	WEIGHT (GRAMS)	CLINICAL OBSERVATIONS
2/15/85	8:53:04	0000337	261.0	CORNEAL OPACITY RIGHT EYE SLIGHT
3/15/85	8:44:34	0000337	262.0	CORNEAL OPACITY RIGHT EYE SLIGHT
4/12/85	8:26:12	0000337	278.0	CORNEAL OPACITY RIGHT EYE SLIGHT
5/10/85	7:50:48	0000337	285.0	CORNEAL OPACITY RIGHT EYE SLIGHT
6/07/85	8:04:22	0000337	291.0	CORNEAL OPACITY RIGHT EYE SLIGHT
7/03/85	7:38:38	0000337	289.0	CORNEAL OPACITY RIGHT EYE SLIGHT
8/02/85	8:16:20	0034567	304.0	CORNEAL OPACITY RIGHT EYE SLIGHT
8/30/85	9:48:46	0000337	300.0	CORNEAL OPACITY RIGHT EYE SLIGHT
9/27/85	7:33:58	0000337	303.0	CORNEAL OPACITY RIGHT EYE SLIGHT
10/25/85	8:14:32	0072808	306.0	CORNEAL OPACITY RIGHT EYE SLIGHT
11/22/85	8:10:12	0000337	308.0	CORNEAL OPACITY RIGHT EYE SLIGHT
12/20/85	8:42:00	0000337	304.0	CORNEAL OPACITY RIGHT EYE SLIGHT
1/17/86	8:14:56	0000337	303.0	CORNEAL OPACITY RIGHT EYE SLIGHT
2/07/86	8:10:44	0034567	289.0	CORNEAL OPACITY RIGHT EYE SLIGHT, EUTHANIZED



PAGE 29  
 DATE: 6/09/87  
 TIME: 14:40:13  
 EDS017 V4M11

**Appendix F (cont.): INDIVIDUAL ANIMAL HISTORIES**

STUDY: 0083009 CARCINOGENICITY BIOASSAY OF ISOBUTYL 2-CYANO-  
 COMPOUND: ISOBUTYL 2-CYANOACRYLATE ACRYLATE (IBC) IN MALE AND FEMALE RATS.

START DATE: 1/28/85

ANIMAL HISTORY

Animal ID: 84D00298 Species: D Sex: FEMALE Group: CONTROLS

DATE	TIME	OPERATOR	WEIGHT (GRAMS)	CLINICAL OBSERVATIONS
2/15/85	8:53:22	0000337	249.0	CORNEAL OPACITY LEFT EYE SLIGHT
2/19/85	8:05:52	0000337		CORNEAL OPACITY LEFT EYE SLIGHT, STAIN CLEAR PERIANAL SLIGHT
3/15/85	8:44:52	0000337	251.0	CORNEAL OPACITY LEFT EYE SLIGHT
4/12/85	8:26:58	0000337	252.0	CORNEAL OPACITY LEFT EYE SLIGHT
5/10/85	7:51:14	0000337	257.0	CORNEAL OPACITY LEFT EYE SLIGHT, CONJUNCTIVITIS RIGHT EYE SLIGHT
5/29/85	7:16:50	0000337		CORNEAL OPACITY LEFT EYE SLIGHT
6/07/85	8:04:40	0000337	262.0	CORNEAL OPACITY LEFT EYE SLIGHT
7/03/85	7:39:12	0000337	260.0	CORNEAL OPACITY LEFT EYE SLIGHT, CONJUNCTIVITIS RIGHT EYE SLIGHT, STAIN BROWN
8/02/85	8:17:46	0034567	263.0	NOSE SLIGHT
8/30/85	9:49:06	0000337	277.0	CORNEAL OPACITY LEFT EYE SLIGHT
9/27/85	7:34:30	0000337	291.0	CORNEAL OPACITY LEFT EYE SLIGHT, CONJUNCTIVITIS RIGHT EYE SLIGHT
10/25/85	8:15:16	0072808	294.0	CORNEAL OPACITY LEFT EYE SLIGHT
11/22/85	8:10:32	0000337	289.0	CORNEAL OPACITY LEFT EYE SLIGHT
12/20/85	8:42:14	0000337	286.0	CORNEAL OPACITY LEFT EYE SLIGHT
1/17/86	8:15:16	0000337	288.0	CORNEAL OPACITY LEFT EYE SLIGHT, CONJUNCTIVITIS RIGHT EYE MODERATE
2/07/86	8:12:04	0034567	279.0	CORNEAL OPACITY LEFT EYE SLIGHT, CONJUNCTIVITIS RIGHT EYE SLIGHT, EUTHANIZED

PAGE 30  
 DATE: 6/09/87  
 TIME: 14:40:13  
 EDS017 V4M11

**Appendix F (cont.): INDIVIDUAL ANIMAL HISTORIES**

STUDY: 0083009  
 COMPOUND: ISOBUTYL 2-CYANOACRYLATE  
 START DATE: 1/28/85  
 CARCINOGENICITY BIOASSAY OF ISOBUTYL 2-CYANO-  
 ACRYLATE (IBC) IN MALE AND FEMALE RATS.

ANIMAL HISTORY

Animal ID: 84D00299 Species: D Sex: FEMALE Group: CONTROLS

DATE	TIME	OPERATOR	WEIGHT (GRAMS)	CLINICAL OBSERVATIONS
2/15/85	8:53:42	0000337	224.0	NORMAL
3/15/85	8:46:54	0000337	232.0	NORMAL
4/12/85	8:27:54	0000337	238.0	NORMAL
5/10/85	7:51:46	0000337	251.0	NORMAL
6/07/85	8:05:04	0000337	238.0	IRRITABLE MODERATE
7/03/85	7:40:28	0000337	241.0	STAIN BROWN NOSE SLIGHT
8/02/85	8:18:24	0034567	255.0	NORMAL
8/30/85	9:49:26	0000337	259.0	NORMAL
9/27/85	7:35:00	0000337	264.0	NORMAL
10/25/85	8:15:46	0072808	262.0	NORMAL
11/22/85	8:11:06	0000337	255.0	NORMAL
12/20/85	8:42:34	0000337	258.0	NORMAL
1/17/86	8:15:54	0000337	249.0	NORMAL
2/07/86	8:13:34	0034567	210.0	CONJUNCTIVITIS RIGHT EYE MODERATE, STAIN BROWN NOSE MODERATE, EMACIATED MODERATE, EUTHANIZED

**Appendix F (cont.): INDIVIDUAL ANIMAL HISTORIES**

PAGE 31  
 DATE: 6/09/87  
 TIME: 14:40:13  
 EDS017 VAM11

STUDY: 0083009 ISOBUTYL 2-CYANOACRYLATE  
 COMPOUND: ISOBUTYL 2-CYANOACRYLATE  
 START DATE: 1/28/85

CARCINOGENICITY BIOASSAY OF ISOBUTYL 2-CYANO-  
 ACRYLATE (IBC) IN MALE AND FEMALE RATS.

ANIMAL HISTORY

Animal ID: 84D00300 Species: D Sex: FEMALE Group: 10 UL/ANM

DATE	TIME	OPERATOR	WEIGHT (GRAMS)	CLINICAL OBSERVATIONS
2/15/85	8:54:00	0000337	213.0	CORNEAL OPACITY BOTH EYE SLIGHT
3/15/85	8:47:12	0000337	212.0	CORNEAL OPACITY BOTH EYE SLIGHT
4/12/85	8:28:38	0000337	228.0	CORNEAL OPACITY BOTH EYE SLIGHT
5/10/85	7:52:04	0000337	225.0	CORNEAL OPACITY BOTH EYE SLIGHT
6/07/85	8:06:44	0000337	231.0	CORNEAL OPACITY BOTH EYE SLIGHT
7/03/85	7:41:58	0000337	227.0	CORNEAL OPACITY BOTH EYE SLIGHT
8/02/85	8:18:56	0034567	241.0	CORNEAL OPACITY BOTH EYE SLIGHT
8/30/85	9:49:52	0000337	239.0	CORNEAL OPACITY BOTH EYE SLIGHT
9/27/85	7:35:20	0000337	243.0	CORNEAL OPACITY BOTH EYE SLIGHT
10/25/85	8:16:12	0072808	248.0	CORNEAL OPACITY BOTH EYE SLIGHT
11/22/85	8:11:22	0000337	255.0	CORNEAL OPACITY BOTH EYE SLIGHT
12/20/85	8:42:48	0000337	258.0	CORNEAL OPACITY BOTH EYE SLIGHT
1/17/86	8:16:08	0000337	261.0	CORNEAL OPACITY BOTH EYE SLIGHT
2/07/86	8:15:40	0034567	259.0	CORNEAL OPACITY BOTH EYE SLIGHT, EUTHANIZED

**Appendix F (cont.): INDIVIDUAL ANIMAL HISTORIES**

STUDY: 0083009  
 COMPOUND: ISOBUTYL 2-CYANOACRYLATE  
 START DATE: 1/28/85  
 CARCINOGENICITY BIOASSAY OF ISOBUTYL 2-CYANO-  
 ACRYLATE (IBC) IN MALE AND FEMALE RATS.

ANIMAL HISTORY

Animal ID: 84D00301 Species: D Sex: FEMALE Group: CONTROLS

DATE	TIME	OPERATOR	WEIGHT (GRAMS)	CLINICAL OBSERVATIONS
2/15/85	8:54:20	0000337	199.0	PROLAPSED LENS RIGHT EYE MARKED, OPAQUE LENS RIGHT EYE MARKED, CORNEAL OPACITY BOTH EYE SLIGHT
3/07/85	9:48:30	0084799		CONJUNCTIVITIS LEFT EYE SLIGHT, CORNEAL OPACITY BOTH EYE SLIGHT, PROLAPSED LENS RIGHT EYE MARKED, OPAQUE LENS RIGHT EYE MARKED
3/15/85	8:47:30	0000337	195.0	CONJUNCTIVITIS LEFT EYE SLIGHT, CORNEAL OPACITY BOTH EYE SLIGHT, PROLAPSED LENS RIGHT EYE MARKED, OPAQUE LENS RIGHT EYE MARKED
4/12/85	8:29:16	0084799	205.0	CORNEAL OPACITY BOTH EYE SLIGHT, PROLAPSED LENS RIGHT EYE SLIGHT, OPAQUE LENS RIGHT EYE MARKED, MALOCCLUSION MODERATE
5/10/85	7:52:36	0000337	205.0	CORNEAL OPACITY BOTH EYE SLIGHT, PROLAPSED LENS RIGHT EYE SLIGHT, OPAQUE LENS RIGHT EYE MARKED, MALOCCLUSION MODERATE
5/20/85	7:22:46	0067831		CORNEAL OPACITY BOTH EYE SLIGHT, PROLAPSED LENS RIGHT EYE SLIGHT, OPAQUE LENS RIGHT EYE MARKED, MALOCCLUSION MODERATE
6/07/85	8:07:20	0000337	202.0	CORNEAL OPACITY BOTH EYE SLIGHT, PROLAPSED LENS RIGHT EYE SLIGHT, OPAQUE LENS RIGHT EYE SLIGHT, MALOCCLUSION MODERATE
7/03/85	7:42:38	0000337	178.0	CORNEAL OPACITY BOTH EYE SLIGHT, PROLAPSED LENS RIGHT EYE SLIGHT, PROLAPSED LENS RIGHT EYE MARKED, OPAQUE LENS RIGHT EYE MARKED, MALOCCLUSION MARKE
8/01/85	10:44:28	0034567		* No observations recorded.

## Appendix F (cont.): INDIVIDUAL ANIMAL HISTORIES

PAGE 33  
DATE: 6/09/87  
TIME: 14:40:13  
EDS017 V4M11

STUDY: 0083009 CARCINOGENICITY BIOASSAY OF ISOBUTYL 2-CYANO-  
COMPOUND: ISOBUTYL 2-CYANOACRYLATE ACRYLATE (IBC) IN MALE AND FEMALE RATS.  
START DATE: 1/28/85

## ANIMAL HISTORY

Animal ID: 84D00302 Species: D Sex: FEMALE Group: 100 UL/ANM

DATE	TIME	OPERATOR	WEIGHT (GRAMS)	CLINICAL OBSERVATIONS
2/15/85	8:55:56	0000337	239.0	CORNEAL OPACITY RIGHT EYE SLIGHT, CONJUNCTIVITIS BOTH EYE MARKED
2/19/85	8:09:00	0000337		CORNEAL OPACITY RIGHT EYE SLIGHT, CONJUNCTIVITIS BOTH EYE MARKED, TACHYPNEA SLIGHT
3/15/85	8:50:12	0000337	247.0	CORNEAL OPACITY RIGHT EYE SLIGHT, CONJUNCTIVITIS BOTH EYE MARKED, TACHYPNEA SLIGHT
3/19/85	7:45:40	0084799		CORNEAL OPACITY RIGHT EYE SLIGHT, CONJUNCTIVITIS BOTH EYE MARKED, TACHYPNEA SLIGHT, ROUGH COAT MODERATE
4/09/85	9:14:00	0000337		CONJUNCTIVITIS BOTH EYE MARKED, CORNEAL OPACITY RIGHT EYE SLIGHT
4/12/85	8:34:28	0000337	266.0	CONJUNCTIVITIS BOTH EYE MARKED, CORNEAL OPACITY RIGHT EYE SLIGHT
5/10/85	7:57:12	0000337	265.0	CONJUNCTIVITIS LEFT EYE MODERATE, CORNEAL OPACITY RIGHT EYE SLIGHT
5/29/85	7:22:06	0000337		CONJUNCTIVITIS BOTH EYE MODERATE, CORNEAL OPACITY RIGHT EYE SLIGHT
6/07/85	8:12:44	0000337	276.0	CONJUNCTIVITIS BOTH EYE MODERATE, CORNEAL OPACITY RIGHT EYE SLIGHT
7/03/85	7:46:24	0000337	273.0	CONJUNCTIVITIS BOTH EYE MODERATE, CORNEAL OPACITY RIGHT EYE SLIGHT
8/02/85	8:19:54	0084799	288.0	CONJUNCTIVITIS BOTH EYE MODERATE, CORNEAL OPACITY RIGHT EYE SLIGHT, SUBCUTANEOUS MASS MIDDLE BACK SIZE SMALL
8/30/85	9:50:24	0000337	290.0	CONJUNCTIVITIS BOTH EYE MODERATE, CORNEAL OPACITY RIGHT EYE SLIGHT, SUBCUTANEOUS MASS MIDDLE BACK SIZE SMALL
9/27/85	7:35:46	0000337	299.0	CORNEAL OPACITY RIGHT EYE SLIGHT, CONJUNCTIVITIS RIGHT EYE MODERATE, SUBCUTANEOUS MASS MIDDLE OF BACK SIZE SMALL
10/25/85	8:16:34	0072808	301.0	CORNEAL OPACITY RIGHT EYE SLIGHT, SUBCUTANEOUS MASS MIDDLE OF BACK SIZE MEDIUM
11/22/85	8:11:40	0084799	295.0	CORNEAL OPACITY RIGHT EYE SLIGHT, SUBCUTANEOUS MASS MIDDLE OF BACK SIZE MEDIUM
12/20/85	8:43:10	0000337	298.0	CORNEAL OPACITY RIGHT EYE SLIGHT, SUBCUTANEOUS MASS DORSAL SIZE MEDIUM
1/02/86	9:23:02	0000337		CORNEAL OPACITY RIGHT EYE SLIGHT, SUBCUTANEOUS MASS DORSAL SIZE MEDIUM, INTRAABDOMINAL MASS VENTRAL TO LIVER SIZE MEDIUM
1/17/86	8:16:56	0000337	290.0	CORNEAL OPACITY RIGHT EYE SLIGHT, SUBCUTANEOUS MASS DORSAL SIZE LARGE, INTRAABDOMINAL MASS VENTRAL TO LIVER SIZE MEDIUM, SPLENIC MASS SIZE LARGE
2/03/86	14:52:50	0000337	229.0	CORNEAL OPACITY RIGHT EYE SLIGHT, INTRAABDOMINAL MASS VENTRAL TO LIVER SIZE LARGE, SPLENIC MASS SIZE LARGE, CUTANEOUS MASS DORSAL LOWER RIGHT QUADRANT, EUTHANIZED

Appendix F (cont.): INDIVIDUAL ANIMAL HISTORIES

STUDY: 0083009 CARCINOGENICITY BIOASSAY OF ISOBUTYL 2-CYANO-  
COMPOUND: ISOBUTYL 2-CYANOACRYLATE ACRYLATE (IBC) IN MALE AND FEMALE RATS.  
START DATE: 1/28/85

ANIMAL HISTORY

Animal ID: 84D00303 Species: D Sex: FEMALE Group: 10 UL/ANM

DATE	TIME	OPERATOR	WEIGHT (GRAMS)	CLINICAL OBSERVATIONS
2/08/85	8:45:02	0000337		CONJUNCTIVITIS RIGHT EYE SLIGHT
2/15/85	8:56:22	0000337	235.0	NORMAL
3/15/85	9:18:28	0000337	240.0	CONJUNCTIVITIS RIGHT EYE SLIGHT
4/12/85	8:35:24	0000337	251.0	CONJUNCTIVITIS RIGHT EYE SLIGHT
5/10/85	7:59:30	0000337	251.0	CONJUNCTIVITIS RIGHT EYE SLIGHT
6/07/85	8:13:42	0000337	262.0	CONJUNCTIVITIS RIGHT EYE SLIGHT
7/03/85	7:47:06	0000337	266.0	CONJUNCTIVITIS RIGHT EYE SLIGHT
8/02/85	8:24:30	0034567	288.0	CONJUNCTIVITIS RIGHT EYE SLIGHT
8/30/85	9:51:50	0000337	292.0	NORMAL
9/27/85	7:37:56	0000337	292.0	NORMAL
10/25/85	8:19:06	0072808	295.0	NORMAL
11/22/85	8:12:54	0000337	297.0	NORMAL
12/20/85	8:44:20	0000337	307.0	NORMAL
1/17/86	8:20:20	0000337	299.0	NORMAL
2/07/86	8:17:58	0034567	289.0	NORMAL / EUTHANIZED

## Appendix F (cont.): INDIVIDUAL ANIMAL HISTORIES

PAGE 35  
DATE: 6/09/87  
TIME: 14:40:13  
EDS017 V4M11

STUDY: 0083009 CARCINOGENICITY BIOASSAY OF ISOBUTYL 2-CYANO-  
COMPOUND: ISOBUTYL 2-CYANOACRYLATE ACRYLATE (IBC) IN MALE AND FEMALE RATS.  
START DATE: 1/28/85

## ANIMAL HISTORY

Animal ID: 84D00305 Species: D Sex: FEMALE Group: 100 UL/ANM

DATE	TIME	OPERATOR	WEIGHT (GRAMS)	CLINICAL OBSERVATIONS
2/15/85	8:56:52	0000337	244.0	CORNEAL OPACITY RIGHT EYE SLIGHT, CONJUNCTIVITIS BOTH EYE MARKED
2/19/85	8:12:10	0000337		CORNEAL OPACITY RIGHT EYE SLIGHT, CONJUNCTIVITIS BOTH EYE MARKED, STAIN YELLOW PERIANAL SLIGHT
2/26/85	9:15:26	0000337		CORNEAL OPACITY RIGHT EYE SLIGHT, CONJUNCTIVITIS BOTH EYE MARKED, STAIN CLEAR PERIANAL SLIGHT
3/15/85	9:20:16	0000337	251.0	CORNEAL OPACITY RIGHT EYE SLIGHT, CONJUNCTIVITIS BOTH EYE MARKED, STAIN CLEAR PERIANAL SLIGHT
4/09/85	9:16:26	0000337		CORNEAL OPACITY RIGHT EYE SLIGHT, CONJUNCTIVITIS BOTH EYE SLIGHT
4/12/85	8:36:10	0000337	234.0	CORNEAL OPACITY RIGHT EYE SLIGHT, CONJUNCTIVITIS BOTH EYE MODERATE
5/10/85	7:59:48	0000337	279.0	CORNEAL OPACITY RIGHT EYE SLIGHT, CONJUNCTIVITIS BOTH EYE MODERATE
5/29/85	7:24:14	0000337		CORNEAL OPACITY RIGHT EYE SLIGHT, CONJUNCTIVITIS RIGHT EYE MODERATE
6/07/85	8:14:08	0000337	278.0	CORNEAL OPACITY RIGHT EYE SLIGHT, CONJUNCTIVITIS RIGHT EYE MODERATE
7/03/85	7:47:36	0000337	287.0	CORNEAL OPACITY RIGHT EYE SLIGHT
8/02/85	8:25:12	0034567	293.0	CORNEAL OPACITY RIGHT EYE SLIGHT
8/30/85	9:52:22	0000337	307.0	CORNEAL OPACITY RIGHT EYE SLIGHT, CONJUNCTIVITIS LEFT EYE SLIGHT
9/13/85	9:35:14	0002920		CORNEAL OPACITY RIGHT EYE SLIGHT, CONJUNCTIVITIS LEFT EYE SLIGHT,
9/27/85	7:38:14	0000337	309.0	CORNEAL OPACITY RIGHT EYE SLIGHT, CONJUNCTIVITIS LEFT EYE SLIGHT, INTRAABDOMINAL MASS VENTRAL TO LIVER SIZE SMALL
10/16/85	12:36:34	0000337		CORNEAL OPACITY RIGHT EYE SLIGHT, INTRAABDOMINAL MASS VENTRAL TO LIVER SIZE MEDIUM
10/25/85	8:19:20	0072808	318.0	CORNEAL OPACITY RIGHT EYE SLIGHT, INTRAABDOMINAL MASS VENTRAL TO LIVER SIZE MEDIUM
11/22/85	8:13:14	0000337	314.0	CORNEAL OPACITY RIGHT EYE SLIGHT, INTRAABDOMINAL MASS VENTRAL TO LIVER SIZE MEDIUM
12/20/85	8:44:56	0084799	311.0	CORNEAL OPACITY RIGHT EYE SLIGHT, INTRAABDOMINAL MASS VENTRAL TO LIVER SIZE MEDIUM
1/17/86	8:20:46	0000337	305.0	CORNEAL OPACITY RIGHT EYE SLIGHT, INTRAABDOMINAL MASS VENTRAL TO LIVER SIZE MEDIUM
2/07/86	8:19:30	0034567	275.0	CORNEAL OPACITY RIGHT EYE SLIGHT, CONJUNCTIVITIS LEFT EYE SLIGHT, INTRAABDOMINAL MASS VENTRAL TO LIVER SIZE MEDIUM, EUTHANIZED

**Appendix F (cont.): INDIVIDUAL ANIMAL HISTORIES**

STUDY: 0083009 CARCINOGENICITY BIOASSAY OF ISOBUTYL 2-CYANO-  
 COMPOUND: ISOBUTYL 2-CYANOACRYLATE ACRYLATE (IBC) IN MALE AND FEMALE RATS.  
 START DATE: 1/28/85

**ANIMAL HISTORY**

Animal ID: 84D00306 Species: D Sex: FEMALE Group: CONTROLS

DATE	TIME	OPERATOR	WEIGHT (GRAMS)	CLINICAL OBSERVATIONS
2/01/85	11:12:38	0084799		CORNEAL OPACITY RIGHT EYE SLIGHT
2/08/85	8:47:06	0000337		CORNEAL OPACITY RIGHT EYE SLIGHT
2/15/85	8:57:18	0000337	259.0	CORNEAL OPACITY RIGHT EYE SLIGHT
2/19/85	8:13:44	0000337		CORNEAL OPACITY RIGHT EYE SLIGHT
2/26/85	9:17:02	0000337		CORNEAL OPACITY RIGHT EYE SLIGHT, CONJUNCTIVITIS RIGHT EYE MODERATE
3/15/85	9:20:42	0000337	259.0	CORNEAL OPACITY RIGHT EYE SLIGHT, CONJUNCTIVITIS RIGHT EYE SLIGHT
4/12/85	8:37:02	0000337	237.0	CORNEAL OPACITY RIGHT EYE SLIGHT
5/10/85	8:00:06	0000337	283.0	CORNEAL OPACITY RIGHT EYE SLIGHT
6/07/85	8:14:32	0000337	290.0	CORNEAL OPACITY RIGHT EYE SLIGHT
7/03/85	7:48:24	0000337	287.0	CORNEAL OPACITY RIGHT EYE SLIGHT
8/02/85	8:25:46	0034567	296.0	CORNEAL OPACITY RIGHT EYE SLIGHT
8/30/85	9:53:40	0000337	305.0	CORNEAL OPACITY RIGHT EYE SLIGHT
9/27/85	7:40:06	0000337	307.0	CORNEAL OPACITY RIGHT EYE SLIGHT
10/25/85	8:20:40	0072808	305.0	CORNEAL OPACITY RIGHT EYE SLIGHT
11/22/85	8:14:08	0000337	302.0	CORNEAL OPACITY RIGHT EYE SLIGHT
12/20/85	8:45:50	0000337	303.0	CORNEAL OPACITY RIGHT EYE SLIGHT, CONJUNCTIVITIS RIGHT EYE MODERATE
1/17/86	8:21:48	0000337	298.0	CORNEAL OPACITY RIGHT EYE SLIGHT, CONJUNCTIVITIS RIGHT EYE MODERATE,
2/07/86	8:22:30	0034567	284.0	EUTHANIZED



**Appendix F (cont.): INDIVIDUAL ANIMAL HISTORIES**

PAGE 37  
 DATE: 6/09/87  
 TIME: 14:40:13  
 EDS017 VAM11

STUDY: 0083009 ISOBUTYL 2-CYANOACRYLATE CARCINOGENICITY BIOASSAY OF ISOBUTYL 2-CYANO-  
 COMPOUND: ISOBUTYL 2-CYANOACRYLATE ACRYLATE (IBC) IN MALE AND FEMALE RATS.  
 START DATE: 1/28/85

ANIMAL HISTORY

Animal ID: 84D00307 Species: D Sex: FEMALE Group: CONTROLS

DATE	TIME	OPERATOR	WEIGHT (GRAMS)	CLINICAL OBSERVATIONS
2/15/85	8:57:46	0000337	206.0	CONJUNCTIVITIS LEFT EYE MODERATE
2/19/85	8:15:24	0000337		NORMAL
2/26/85	9:18:00	0000337		STAIN YELLOW PERIANAL SLIGHT
3/15/85	9:21:10	0000337	211.0	NORMAL
4/12/85	8:37:42	0000337	215.0	NORMAL
5/10/85	8:00:38	0000337	221.0	CONJUNCTIVITIS LEFT EYE SLIGHT
5/29/85	7:25:50	0000337		NORMAL
6/07/85	8:15:02	0000337	226.0	NORMAL
7/03/85	7:48:56	0000337	226.0	NORMAL
8/02/85	8:26:10	0034567	242.0	NORMAL
8/30/85	9:54:04	0000337	251.0	CONJUNCTIVITIS LEFT EYE SLIGHT
9/13/85	9:36:38	0002920		CONJUNCTIVITIS LEFT EYE MARKED
9/27/85	7:40:26	0000337	254.0	CONJUNCTIVITIS LEFT EYE SLIGHT
10/25/85	8:21:06	0072808	262.0	NORMAL
11/22/85	8:14:28	0000337	267.0	NORMAL
12/20/85	8:46:22	0000337	266.0	NORMAL
1/17/86	8:22:10	0000337	264.0	NORMAL
2/07/86	8:23:36	0034567	241.0	NORMAL / EUTHANIZED

PAGE 38  
 DATE: 6/09/87  
 TIME: 14:40:13  
 EDS017 VAM11

**Appendix F (cont.): INDIVIDUAL ANIMAL HISTORIES**

CARCINOGENICITY BIOASSAY OF ISOBUTYL 2-CYANO-  
 ACRYLATE (IBC) IN MALE AND FEMALE RATS.

ANIMAL HISTORY

STUDY: 0083009  
 COMPOUND: ISOBUTYL 2-CYANOACRYLATE  
 START DATE: 1/28/85

Animal ID: 84D00308 Species: D Sex: FEMALE Group: 10 UL/ANM

DATE	TIME	OPERATOR	WEIGHT (GRAMS)	CLINICAL OBSERVATIONS
2/08/85	8:48:38	0000337		CORNEAL OPACITY BOTH EYE SLIGHT, CONJUNCTIVITIS BOTH EYE MARKED, TACHYPNEA SLIGHT
2/15/85	8:58:14	0000337	230.0	CONJUNCTIVITIS RIGHT EYE MARKED, CORNEAL OPACITY BOTH EYE SLIGHT, TACHYPNEA SLIGHT
2/19/85	8:16:22	0000337		CONJUNCTIVITIS BOTH EYE MARKED, CORNEAL OPACITY BOTH EYE SLIGHT, TACHYPNEA SLIGHT
2/26/85	9:18:54	0000337		CONJUNCTIVITIS BOTH EYE MARKED, CORNEAL OPACITY BOTH EYE SLIGHT
3/15/85	9:21:54	0000337	240.0	CONJUNCTIVITIS BOTH EYE MARKED, CORNEAL OPACITY BOTH EYE SLIGHT
4/12/85	8:38:20	0000337	252.0	CONJUNCTIVITIS BOTH EYE MARKED, CORNEAL OPACITY BOTH EYE SLIGHT
5/10/85	8:01:08	0000337	267.0	CONJUNCTIVITIS BOTH EYE MARKED, CORNEAL OPACITY BOTH EYE SLIGHT
6/07/85	9:15:20	0000337	263.0	CONJUNCTIVITIS BOTH EYE MARKED, CORNEAL OPACITY BOTH EYE SLIGHT
7/03/85	7:49:28	0000337	258.0	CONJUNCTIVITIS BOTH EYE MARKED, CORNEAL OPACITY BOTH EYE SLIGHT
8/02/85	8:27:20	0034567	270.0	CONJUNCTIVITIS BOTH EYE MARKED, CORNEAL OPACITY BOTH EYE SLIGHT
8/30/85	9:54:36	0000337	275.0	CONJUNCTIVITIS BOTH EYE MARKED, CORNEAL OPACITY BOTH EYE SLIGHT
9/27/85	7:40:54	0000337	275.0	CONJUNCTIVITIS BOTH EYE MARKED, CORNEAL OPACITY BOTH EYE SLIGHT
10/25/85	8:21:38	0072808	283.0	CONJUNCTIVITIS BOTH EYE MARKED, CORNEAL OPACITY BOTH EYE SLIGHT
11/22/85	8:14:46	0000337	284.0	CONJUNCTIVITIS BOTH EYE MARKED, CORNEAL OPACITY BOTH EYE SLIGHT
12/20/85	8:46:42	0000337	281.0	CONJUNCTIVITIS BOTH EYE MARKED, CORNEAL OPACITY BOTH EYE SLIGHT
1/17/86	8:22:30	0000337	285.0	CONJUNCTIVITIS RIGHT EYE MARKED, CORNEAL OPACITY BOTH EYE SLIGHT
2/07/86	8:24:34	0034567	270.0	CONJUNCTIVITIS RIGHT EYE MARKED, CORNEAL OPACITY BOTH EYE SLIGHT, CONJUNCTIVITIS LEFT EYE MODERATE, EUTHANIZED

## Appendix F (cont.): INDIVIDUAL ANIMAL HISTORIES

PAGE 39  
 DATE: 6/09/87  
 TIME: 14:40:13  
 EDS017 V4M11

STUDY: 0083009 ISOBUTYL 2-CYANOACRYLATE CARCINOGENICITY BIOASSAY OF ISOBUTYL 2-CYANO-  
 COMPOUND: ISOBUTYL 2-CYANOACRYLATE ACRYLATE (IBC) IN MALE AND FEMALE RATS.

START DATE: 1/28/85

## ANIMAL HISTORY

Animal ID: 84D00309 Species: D Sex: FEMALE Group: 10 UL/ANM

DATE	TIME	OPERATOR	WEIGHT (GRAMS)	CLINICAL OBSERVATIONS
2/15/85	8:59:18	0000337	201.0	NORMAL
3/15/85	9:22:22	0000337	214.0	NORMAL
4/09/85	9:38:46	0000337		CONJUNCTIVITIS RIGHT EYE SLIGHT
4/12/85	8:39:02	0000337	229.0	NORMAL
5/10/85	8:01:32	0000337	229.0	NORMAL
5/29/85	7:46:04	0000337		CONJUNCTIVITIS BOTH EYE SLIGHT, STAIN BROWN NOSE SLIGHT
6/07/85	8:15:44	0000337	235.0	NORMAL
7/03/85	7:49:58	0000337	230.0	NORMAL
8/02/85	8:27:46	0034567	248.0	NORMAL
8/30/85	9:55:14	0000337	258.0	NORMAL
9/27/85	7:41:16	0000337	268.0	NORMAL
10/25/85	8:22:20	0072808	279.0	NORMAL
11/22/85	8:15:06	0000337	295.0	NORMAL
12/20/85	8:47:00	0000337	289.0	NORMAL
1/17/86	8:23:02	0000337	288.0	NORMAL
2/07/86	8:26:52	0034567	267.0	NORMAL / EUTHANIZED

PAGE 40  
 DATE: 6/09/87  
 TIME: 14:40:13  
 EDS017 VAM11

### Appendix F (cont.): INDIVIDUAL ANIMAL HISTORIES

STUDY: 0083009 CARCINOGENICITY BIOASSAY OF ISOBUTYL 2-CYANO-  
 COMPOUND: ISOBUTYL 2-CYANOACRYLATE ACRYLATE (IBC) IN MALE AND FEMALE RATS.

START DATE: 1/28/85

#### ANIMAL HISTORY

Animal ID: 84D00310 Species: D Sex: FEMALE Group: 10 UL/ANN

DATE	TIME	OPERATOR	WEIGHT (GRAMS)	CLINICAL OBSERVATIONS
2/15/85	8:59:36	0000337	250.0	CORNEAL OPACITY LEFT EYE SLIGHT, CONJUNCTIVITIS BOTH EYE MARKED
3/15/85	9:22:42	0000337	259.0	CORNEAL OPACITY LEFT EYE SLIGHT, CONJUNCTIVITIS BOTH EYE MARKED
4/12/85	8:39:52	0000337	278.0	CORNEAL OPACITY LEFT EYE SLIGHT, CONJUNCTIVITIS BOTH EYE MARKED
5/10/85	8:01:56	0000337	274.0	CORNEAL OPACITY LEFT EYE SLIGHT, CONJUNCTIVITIS BOTH EYE MARKED
6/07/85	8:16:12	0000337	289.0	CORNEAL OPACITY LEFT EYE SLIGHT, CONJUNCTIVITIS BOTH EYE MARKED
7/03/85	7:50:26	0000337	284.0	CORNEAL OPACITY LEFT EYE SLIGHT, CONJUNCTIVITIS BOTH EYE MARKED
8/02/85	8:28:08	0034567	290.0	CORNEAL OPACITY LEFT EYE SLIGHT, CONJUNCTIVITIS BOTH EYE MARKED
8/30/85	9:55:28	0000337	297.0	CORNEAL OPACITY LEFT EYE SLIGHT, CONJUNCTIVITIS BOTH EYE MODERATE, INTRAABDOMINAL MASS VENTRAL TO LIVER SIZE SMALL
9/27/85	7:41:38	0000337	306.0	CORNEAL OPACITY LEFT EYE SLIGHT, CONJUNCTIVITIS BOTH EYE MARKED, INTRAABDOMINAL MASS VENTRAL TO LIVER SIZE SMALL
10/25/85	8:22:38	0072808	307.0	CORNEAL OPACITY LEFT EYE SLIGHT, CONJUNCTIVITIS BOTH EYE MARKED, INTRAABDOMINAL MASS VENTRAL TO LIVER SIZE SMALL
11/22/85	8:15:20	0000337	314.0	CORNEAL OPACITY LEFT EYE SLIGHT, CONJUNCTIVITIS BOTH EYE MODERATE, INTRAABDOMINAL MASS VENTRAL TO LIVER SIZE SMALL
12/20/85	8:47:16	0000337	299.0	CORNEAL OPACITY LEFT EYE SLIGHT, CONJUNCTIVITIS BOTH EYE MODERATE, INTRAABDOMINAL MASS VENTRAL TO LIVER SIZE SMALL
1/17/86	8:23:20	0000337	286.0	CORNEAL OPACITY LEFT EYE SLIGHT, CONJUNCTIVITIS BOTH EYE MODERATE, INTRAABDOMINAL MASS VENTRAL TO LIVER SIZE SMALL
2/07/86	8:27:48	0034567	255.0	CORNEAL OPACITY LEFT EYE SLIGHT, CONJUNCTIVITIS BOTH EYE MODERATE, INTRAABDOMINAL MASS VENTRAL TO LIVER SIZE SMALL, EUTHANIZED

**Appendix F (cont.): INDIVIDUAL ANIMAL HISTORIES**

PAGE 41  
 DATE: 6/09/87  
 TIME: 14:40:13  
 EDS017 V4M11

STUDY: 0083009  
 COMPOUND: ISOBUTYL 2-CYANOACRYLATE  
 START DATE: 1/28/85

CARCINOGENICITY BIOASSAY OF ISOBUTYL 2-CYANO-  
 ACRYLATE (IBC) IN MALE AND FEMALE RATS.

ANIMAL HISTORY

Animal ID: 84D00311 Species: D Sex: FEMALE Group: 100 UL/ANM

DATE	TIME	OPERATOR	WEIGHT (GRAMS)	CLINICAL OBSERVATIONS
2/01/85	11:15:34	0000337		CONJUNCTIVITIS LEFT EYE SLIGHT
2/15/85	9:00:08	0000337	222.0	CONJUNCTIVITIS LEFT EYE SLIGHT
2/26/85	9:21:16	0000337		CONJUNCTIVITIS LEFT EYE SLIGHT, STAIN YELLOW PERIANNAL SLIGHT
3/01/85	7:59:38	0000337		CONJUNCTIVITIS LEFT EYE SLIGHT
3/15/85	9:23:10	0000337	226.0	CONJUNCTIVITIS LEFT EYE SLIGHT
4/09/85	9:40:26	0000337		NORMAL
4/12/85	8:40:26	0000337	235.0	CONJUNCTIVITIS LEFT EYE SLIGHT
5/10/85	8:02:22	0000337	240.0	CONJUNCTIVITIS LEFT EYE SLIGHT
6/07/85	8:16:34	0000337	248.0	CONJUNCTIVITIS LEFT EYE SLIGHT
7/03/85	7:50:58	0000337	243.0	CONJUNCTIVITIS LEFT EYE SLIGHT
8/02/85	8:28:30	0034567	253.0	NORMAL
8/30/85	9:57:16	0000337	254.0	NORMAL
9/27/85	7:44:16	0000337	264.0	NORMAL
10/25/85	8:23:42	0072808	262.0	NORMAL
11/22/85	8:16:16	0000337	262.0	NORMAL
12/20/85	8:48:06	0000337	271.0	NORMAL
1/17/86	8:24:20	0000337	269.0	NORMAL
2/10/86	7:36:50	0034567	257.0	NORMAL / EUTHANIZED

PAGE 42  
 DATE: 6/09/87  
 TIME: 14:40:13  
 EDS017 V4M11

**Appendix F (cont.): INDIVIDUAL ANIMAL HISTORIES**

STUDY: 0083009 CARCINOGENICITY BIOASSAY OF ISOBUTYL 2-CYANO-  
 COMPOUND: ISOBUTYL 2-CYANOACRYLATE ACRYLATE (IBC) IN MALE AND FEMALE RATS.  
 START DATE: 1/28/85

ANIMAL HISTORY

Animal ID: 84D00312 Species: D Sex: FEMALE Group: 100 UL/ANM

DATE	TIME	OPERATOR	WEIGHT (GRAMS)	CLINICAL OBSERVATIONS
2/15/85	9:00:30	0000337	235.0	CORNEAL OPACITY BOTH EYE SLIGHT, CONJUNCTIVITIS BOTH EYE MARKED
2/26/85	9:22:18	0000337		CORNEAL OPACITY BOTH EYE SLIGHT, CONJUNCTIVITIS BOTH EYE MARKED, TACHYPNEA SLIGHT
3/01/85	8:00:42	0000337		CORNEAL OPACITY BOTH EYE SLIGHT, CONJUNCTIVITIS BOTH EYE MARKED
3/15/85	9:23:34	0000337	240.0	CORNEAL OPACITY BOTH EYE SLIGHT, CONJUNCTIVITIS BOTH EYE MARKED
4/12/85	8:42:10	0000337	254.0	CORNEAL OPACITY BOTH EYE SLIGHT, CONJUNCTIVITIS BOTH EYE MARKED
5/10/85	8:02:48	0000337	256.0	CORNEAL OPACITY LEFT EYE SLIGHT, CONJUNCTIVITIS BOTH EYE MARKED
6/07/85	8:16:56	0000337	261.0	CORNEAL OPACITY LEFT EYE SLIGHT, CONJUNCTIVITIS BOTH EYE MARKED
7/03/85	7:51:30	0000337	260.0	CORNEAL OPACITY LEFT EYE SLIGHT, CONJUNCTIVITIS BOTH EYE MARKED
8/02/85	8:29:24	0034567	269.0	CORNEAL OPACITY LEFT EYE SLIGHT, CONJUNCTIVITIS BOTH EYE MARKED
8/30/85	9:57:40	0000337	271.0	CORNEAL OPACITY LEFT EYE SLIGHT, CONJUNCTIVITIS BOTH EYE MARKED, SUBCUTANEOUS MASS LATERAL RIGHT SIDE SIZE SMALL
9/04/85	7:21:18	0000337		CORNEAL OPACITY LEFT EYE SLIGHT, CONJUNCTIVITIS BOTH EYE MARKED, SUBCUTANEOUS MASS LATERAL RIGHT SIDE SIZE SMALL
9/27/85	7:44:38	0084799	281.0	CORNEAL OPACITY LEFT EYE SLIGHT, CONJUNCTIVITIS BOTH EYE MODERATE, SUBCUTANEOUS MASS LATERAL RIGHT SIDE SIZE SMALL
10/25/85	8:24:02	0072808	284.0	CORNEAL OPACITY LEFT EYE SLIGHT, CONJUNCTIVITIS BOTH EYE MODERATE, SUBCUTANEOUS MASS LATERAL TO RIGHT SIDE SIZE MEDIUM
11/22/85	8:16:28	0000337	284.0	CORNEAL OPACITY LEFT EYE SLIGHT, CONJUNCTIVITIS BOTH EYE SLIGHT, SUBCUTANEOUS MASS LATERAL RIGHT SIDE SIZE MEDIUM
12/20/85	8:48:22	0000337	273.0	CORNEAL OPACITY LEFT EYE SLIGHT, CONJUNCTIVITIS BOTH EYE MODERATE, SUBCUTANEOUS MASS RIGHT SIDE ABDOMEN SIZE LARGE
1/17/86	8:24:56	0000337	272.0	CORNEAL OPACITY LEFT EYE SLIGHT, CONJUNCTIVITIS RIGHT EYE MODERATE, SUBCUTANEOUS MASS RIGHT SIDE ABDOMEN SIZE LARGE
2/10/86	7:38:20	0034567	254.0	CORNEAL OPACITY LEFT EYE SLIGHT, CONJUNCTIVITIS BOTH EYE MODERATE, SUBCUTANEOUS MASS RIGHT SIDE ABDOMEN SIZE LARGE, EUTHANIZED

## Appendix F (cont.): INDIVIDUAL ANIMAL HISTORIES

PAGE 43  
DATE: 6/09/87  
TIME: 14:40:13  
EDS017 VAM11

STUDY: 0083009 CARCINOGENICITY BIOASSAY OF ISOBUTYL 2-CYANO-  
COMPOUND: ISOBUTYL 2-CYANOACRYLATE ACRYLATE (IBC) IN MALE AND FEMALE RATS.  
START DATE: /28/85

## ANIMAL HISTORY

Animal ID: 84D00313 Species: D Sex: FEMALE Group: CONTROLS

DATE	TIME	OPERATOR	WEIGHT (GRAMS)	CLINICAL OBSERVATIONS
2/15/85	9:00:48	0000337	238.0	CORNEAL OPACITY RIGHT EYE SLIGHT
2/26/85	9:23:26	0000337		CORNEAL OPACITY RIGHT EYE SLIGHT, CONJUNCTIVITIS BOTH EYE SLIGHT
3/15/85	9:23:56	0000337	247.0	CORNEAL OPACITY RIGHT EYE SLIGHT
4/09/85	9:42:46	0000337		CORNEAL OPACITY RIGHT EYE SLIGHT, CONJUNCTIVITIS LEFT EYE SLIGHT
4/12/85	8:42:56	0000337	251.0	CORNEAL OPACITY RIGHT EYE SLIGHT
5/10/85	8:03:36	0000337	259.0	CORNEAL OPACITY RIGHT EYE SLIGHT, CONJUNCTIVITIS LEFT EYE SLIGHT
5/29/85	7:50:22	0000337		CORNEAL OPACITY RIGHT EYE SLIGHT
6/07/85	8:17:22	0000337	265.0	CORNEAL OPACITY RIGHT EYE SLIGHT
7/03/85	7:52:34	0000337	261.0	CORNEAL OPACITY RIGHT EYE SLIGHT
8/02/85	8:29:58	0034567	281.0	CORNEAL OPACITY RIGHT EYE SLIGHT
8/30/85	9:58:10	0000337	279.0	CORNEAL OPACITY RIGHT EYE SLIGHT
9/04/85	7:28:38	0000337		CORNEAL OPACITY RIGHT EYE SLIGHT, CONJUNCTIVITIS BOTH EYE MODERATE
9/27/85	7:46:02	0000337	291.0	CORNEAL OPACITY RIGHT EYE SLIGHT, CONJUNCTIVITIS LEFT EYE SLIGHT
10/25/85	9:01:28	0072808	298.0	CORNEAL OPACITY RIGHT EYE SLIGHT, CONJUNCTIVITIS LEFT EYE SLIGHT
11/22/85	8:17:46	0000337	296.0	CORNEAL OPACITY RIGHT EYE SLIGHT, CONJUNCTIVITIS LEFT EYE MARKED
12/20/85	8:49:50	0000337	293.0	CORNEAL OPACITY RIGHT EYE SLIGHT, CONJUNCTIVITIS LEFT EYE MODERATE
1/17/86	8:26:04	0000337	294.0	CORNEAL OPACITY RIGHT EYE SLIGHT, CONJUNCTIVITIS LEFT EYE MARKED
2/10/86	7:41:22	0034567	278.0	CORNEAL OPACITY RIGHT EYE SLIGHT, CONJUNCTIVITIS LEFT EYE MARKED, EUTHANIZED

## Appendix F (cont.): INDIVIDUAL ANIMAL HISTORIES

CARCINOGENICITY BIOASSAY OF ISOBUTYL 2-CYANO-  
ACRYLATE (IBC) IN MALE AND FEMALE RATS.STUDY: 0083009  
COMPOUND: ISOBUTYL 2-CYANOACRYLATE  
START DATE: 1/28/85

## ANIMAL HISTORY

Animal ID: 84D00314 Species: D Sex: FEMALE Group: 10 UL/ANM

DATE	TIME	OPERATOR	WEIGHT (GRAMS)	CLINICAL OBSERVATIONS
2/08/85	8:52:58	0000337		CORNEAL OPACITY RIGHT EYE SLIGHT, CONJUNCTIVITIS BOTH EYE MODERATE
2/15/85	9:01:12	0000337	227.0	CORNEAL OPACITY RIGHT EYE SLIGHT, CONJUNCTIVITIS BOTH EYE MARKED
3/15/85	9:24:34	0000337	229.0	CORNEAL OPACITY RIGHT EYE SLIGHT, CONJUNCTIVITIS LEFT EYE MODERATE
4/12/85	8:44:10	0000337	237.0	CORNEAL OPACITY RIGHT EYE SLIGHT, CONJUNCTIVITIS LEFT EYE MARKED
5/10/85	8:04:16	0000337	249.0	CONJUNCTIVITIS LEFT EYE MARKED
5/29/85	7:51:20	0000337		CONJUNCTIVITIS LEFT EYE MARKED, CONJUNCTIVITIS RIGHT EYE MODERATE, STAIN BROWN
				NOSE SLIGHT
6/07/85	8:17:50	0000337	253.0	CONJUNCTIVITIS LEFT EYE MARKED, CONJUNCTIVITIS RIGHT EYE MODERATE
7/03/85	7:53:06	0000337	255.0	CONJUNCTIVITIS LEFT EYE MARKED, CONJUNCTIVITIS RIGHT EYE MODERATE
8/02/85	8:30:36	0034567	265.0	CONJUNCTIVITIS LEFT EYE MARKED
8/30/85	9:58:32	0000337	271.0	CONJUNCTIVITIS LEFT EYE MARKED,
				INTRAABDOMINAL MASS VENTRAL TO LIVER SIZE SMALL
9/27/85	7:46:44	0000337	279.0	CONJUNCTIVITIS LEFT EYE MARKED,
				INTRAABDOMINAL MASS VENTRAL TO LIVER SIZE SMALL
10/25/85	9:01:50	0072808	277.0	CONJUNCTIVITIS LEFT EYE MARKED,
				INTRAABDOMINAL MASS VENTRAL TO LIVER SIZE SMALL
11/22/85	8:18:04	0000337	278.0	CONJUNCTIVITIS LEFT EYE SLIGHT,
				INTRAABDOMINAL MASS VENTRAL TO LIVER SIZE SMALL
12/20/85	8:51:08	0000337	278.0	CONJUNCTIVITIS BOTH EYE MODERATE,
				INTRAABDOMINAL MASS VENTRAL TO LIVER SIZE SMALL
1/17/86	8:26:28	0000337	276.0	INTRAABDOMINAL MASS VENTRAL TO LIVER SIZE SMALL
2/10/86	7:42:34	0084799	256.0	INTRAABDOMINAL MASS VENTRAL TO LIVER SIZE MEDIUM, EUTHANIZED



## Appendix F (cont.): INDIVIDUAL ANIMAL HISTORIES

PAGE 45  
DATE: 6/09/87  
TIME: 14:40:13  
EDS017 V4M11

STUDY: 0083009 ISOBUTYL 2-CYANOACRYLATE CARCINOGENICITY BIOASSAY OF ISOBUTYL 2-CYANO-  
COMPOUND: ISOBUTYL 2-CYANOACRYLATE ACRYLATE (IBC) IN MALE AND FEMALE RATS.  
START DATE: 1/28/85

## ANIMAL HISTORY

Animal ID: 84D00315 Species: D Sex: FEMALE Group: 100 UL/ANM

DATE	TIME	OPERATOR	WEIGHT (GRAMS)	CLINICAL OBSERVATIONS
2/15/85	9:01:32	0000337	241.0	CONJUNCTIVITIS RIGHT EYE MODERATE, CONJUNCTIVITIS LEFT EYE SLIGHT
2/19/85	8:21:54	0000337		CONJUNCTIVITIS RIGHT EYE MARKED, CONJUNCTIVITIS LEFT EYE MODERATE
3/15/85	9:25:10	0000337	238.0	CONJUNCTIVITIS BOTH EYE MARKED
4/09/85	9:44:46	0000337		CONJUNCTIVITIS LEFT EYE MODERATE, STAIN YELLOW PERIANAL SLIGHT
4/12/85	8:45:12	0000337	254.0	CONJUNCTIVITIS LEFT EYE MODERATE
5/10/85	8:04:48	0000337	265.0	CONJUNCTIVITIS BOTH EYE MARKED
6/07/85	8:18:32	0000337	273.0	CONJUNCTIVITIS BOTH EYE SLIGHT
7/03/85	7:53:42	0000337	266.0	CONJUNCTIVITIS RIGHT EYE MARKED, CONJUNCTIVITIS LEFT EYE SLIGHT
8/02/85	8:31:08	0034567	278.0	CONJUNCTIVITIS BOTH EYE MARKED
8/30/85	9:59:52	0000337	287.0	CONJUNCTIVITIS BOTH EYE MARKED
9/27/85	7:47:46	0000337	294.0	CONJUNCTIVITIS BOTH EYE MARKED
10/25/85	9:03:16	0072808	290.0	CONJUNCTIVITIS BOTH EYE MARKED
11/22/85	8:18:52	0000337	289.0	CONJUNCTIVITIS BOTH EYE MODERATE
12/20/85	8:52:06	0000337	293.0	CONJUNCTIVITIS BOTH EYE MODERATE
1/17/86	8:27:24	0000337	299.0	CONJUNCTIVITIS BOTH EYE MARKED
2/10/86	7:45:36	0034567	274.0	CONJUNCTIVITIS BOTH EYE MARKED, EUTHANIZED

PAGE 46  
 DATE: 6/09/87  
 TIME: 14:40:13  
 EDS017 VAM11

**Appendix F (cont.): INDIVIDUAL ANIMAL HISTORIES**

STUDY: 0083009  
 COMPOUND: ISOBUTYL 2-CYANOACRYLATE  
 START DATE: 1/28/85

CARCINOGENICITY BIOASSAY OF ISOBUTYL 2-CYANO-  
 ACRYLATE (IBC) IN MALE AND FEMALE RATS.

ANIMAL HISTORY

Animal ID: 84D00316 Species: D Sex: FEMALE Group: 10 UL/ANM

DATE	TIME	OPERATOR	WEIGHT (GRAMS)	CLINICAL OBSERVATIONS
2/15/85	9:02:06	0000337	258.0	NORMAL
3/15/85	9:25:38	0000337	263.0	NORMAL
4/12/85	8:46:06	0000337	276.0	NORMAL
5/10/85	8:05:16	0000337	274.0	NORMAL
6/07/85	8:21:24	0000337	277.0	NORMAL
7/03/85	7:54:50	0000337	281.0	NORMAL
8/02/85	8:31:58	0034567	284.0	NORMAL
8/30/85	10:00:12	0000337	286.0	NORMAL
9/27/85	7:48:14	0000337	290.0	NORMAL
10/25/85	9:03:54	0072808	290.0	CONJUNCTIVITIS RIGHT EYE SLIGHT
11/22/85	8:19:12	0000337	290.0	CONJUNCTIVITIS RIGHT EYE SLIGHT,
12/20/85	8:52:26	0000337	292.0	CONJUNCTIVITIS RIGHT EYE SLIGHT, INTRAABDOMINAL MASS VENTRAL TO LIVER SIZE SMALL
1/17/86	8:27:44	0000337	288.0	CONJUNCTIVITIS RIGHT EYE SLIGHT, INTRAABDOMINAL MASS VENTRAL TO LIVER SIZE SMALL
2/10/86	7:46:42	0034567	261.0	CONJUNCTIVITIS RIGHT EYE SLIGHT, PALLORED MARKED, INTRAABDOMINAL MASS VENTRAL TO LIVER SIZE SMALL, SPLENIC MASS SIZE MEDIUM, EUTHANIZED

**Appendix F (cont.): INDIVIDUAL ANIMAL HISTORIES**

PAGE 47  
 DATE: 6/09/87  
 TIME: 14:40:13  
 EDS017 VAM11

STUDY: 0083009  
 COMPOUND: ISOBUTYL 2-CYANOACRYLATE  
 START DATE: 1/28/85

CARCINOGENICITY BIOASSAY OF ISOBUTYL 2-CYANO-  
 ACRYLATE (IBC) IN MALE AND FEMALE RATS.

Animal ID: 84D00317 Species: D Sex: FEMALE Group: 10 UL/ANM

ANIMAL HISTORY

DATE	TIME	OPERATOR	WEIGHT (GRAMS)	CLINICAL OBSERVATIONS
2/08/85	8:54:48	0000337		
2/15/85	9:02:24	0000337	231.0	STAIN YELLOW PERIANAL SLIGHT
2/19/85	8:23:14	0000337		VAGINAL DISCHARGE BLOODY SLIGHT
3/15/85	9:25:56	0000337	238.0	STAIN YELLOW PERIANAL MODERATE
4/12/85	8:46:48	0000337	242.0	NORMAL
5/10/85	8:05:36	0000337	252.0	NORMAL
5/29/85	7:53:38	0000337		SCAB RIGHT EAR SLIGHT
6/07/85	8:19:46	0000337	251.0	NORMAL
7/03/85	7:55:18	0000337	251.0	NORMAL
8/02/85	8:32:18	0034567	263.0	NORMAL
8/30/85	10:00:26	0000337	267.0	NORMAL
9/27/85	7:48:32	0000337	271.0	NORMAL
10/25/85	9:04:36	0072808	269.0	NORMAL
11/22/85	8:19:38	0000337	275.0	NORMAL
12/20/85	8:53:50	0000337	284.0	NORMAL
1/17/86	8:29:02	0000337	266.0	NORMAL
2/10/86	7:49:50	0034567	253.0	NORMAL / EUTHANIZED

PAGE 48  
 DATE: 6/09/87  
 TIME: 14:40:13  
 EDS017 V4M11

**Appendix F (cont.): INDIVIDUAL ANIMAL HISTORIES**

STUDY: 0083009 ISOBUTYL 2-CYANOACRYLATE CARCINOGENICITY BIOASSAY OF ISOBUTYL 2-CYANO-  
 COMPOUND: ISOBUTYL 2-CYANOACRYLATE ACRYLATE (IBC) IN MALE AND FEMALE RATS.  
 START DATE: 1/28/85

ANIMAL HISTORY

Animal ID: 84D00319 Species: D Sex: FEMALE Group: 10 UL/ANM

DATE	TIME	OPERATOR	WEIGHT (GRAMS)	CLINICAL OBSERVATIONS
2/08/85	8:56:00	0000337		CORNEAL OPACITY LEFT EYE SLIGHT, STAIN YELLOW PERIANAL SLIGHT
2/15/85	9:04:30	0000337	256.0	CORNEAL OPACITY LEFT EYE SLIGHT, STAIN YELLOW PERIANAL SLIGHT
3/15/85	9:26:38	0000337	254.0	CORNEAL OPACITY LEFT EYE SLIGHT, STAIN YELLOW PERIANAL SLIGHT
4/09/85	9:46:54	0000337		CORNEAL OPACITY LEFT EYE SLIGHT, STAIN YELLOW PERIANAL SLIGHT, CONJUNCTIVITIS RIGHT EYE SLIGHT
4/12/85	8:47:26	0000337	266.0	CORNEAL OPACITY LEFT EYE SLIGHT, STAIN YELLOW PERIANAL SLIGHT, CONJUNCTIVITIS RIGHT EYE SLIGHT
5/10/85	8:07:24	0000337	269.0	CORNEAL OPACITY LEFT EYE SLIGHT, STAIN YELLOW PERIANAL SLIGHT
6/07/85	8:22:00	0000337	284.0	CORNEAL OPACITY LEFT EYE SLIGHT
7/03/85	7:56:04	0000337	293.0	CORNEAL OPACITY LEFT EYE SLIGHT
8/02/85	8:32:44	0034567	310.0	CORNEAL OPACITY LEFT EYE SLIGHT
8/30/85	10:00:50	0000337	308.0	CORNEAL OPACITY LEFT EYE SLIGHT
9/27/85	7:48:56	0000337	317.0	CORNEAL OPACITY LEFT EYE SLIGHT
10/25/85	9:04:58	0072808	309.0	CORNEAL OPACITY LEFT EYE SLIGHT
11/22/85	9:19:56	0000337	320.0	CORNEAL OPACITY LEFT EYE SLIGHT
12/20/85	8:54:06	0000337	322.0	CORNEAL OPACITY LEFT EYE SLIGHT
1/17/86	8:29:24	0000337	317.0	CORNEAL OPACITY LEFT EYE SLIGHT
2/10/86	7:50:48	0034567	300.0	CORNEAL OPACITY LEFT EYE SLIGHT, EUTHANIZED

## Appendix F (cont.): INDIVIDUAL ANIMAL HISTORIES

PAGE 49  
DATE: 6/09/87  
TIME: 14:40:13  
EDS017 V4M11

STUDY: 0083009  
COMPOUND: ISOBUTYL 2-CYANOACRYLATE  
START DATE: 1/28/85

CARCINOGENICITY BIOASSAY OF ISOBUTYL 2-CYANO-  
ACRYLATE (IBC) IN MALE AND FEMALE RATS.

## ANIMAL HISTORY

Animal ID: 84D00320 Species: D Sex: FEMALE Group: 100 UL/ANM

DATE	TIME	OPERATOR	WEIGHT (GRAMS)	CLINICAL OBSERVATIONS
2/15/85	9:05:28	0000337	258.0	CORNEAL OPACITY LEFT EYE SLIGHT, CONJUNCTIVITIS LEFT EYE MODERATE
3/15/85	9:27:08	0000337	266.0	CORNEAL OPACITY LEFT EYE SLIGHT, CONJUNCTIVITIS LEFT EYE MODERATE
4/12/85	8:48:14	0000337	270.0	CORNEAL OPACITY LEFT EYE SLIGHT, CONJUNCTIVITIS LEFT EYE MODERATE
5/10/85	8:08:50	0000337	272.0	CORNEAL OPACITY LEFT EYE SLIGHT, CONJUNCTIVITIS LEFT EYE SLIGHT
6/07/85	8:22:28	0000337	287.0	CORNEAL OPACITY LEFT EYE SLIGHT
7/03/85	7:56:50	0000337	284.0	CORNEAL OPACITY LEFT EYE SLIGHT
8/02/85	8:33:06	0034567	279.0	NORMAL
9/30/85	10:01:10	0000337	285.0	NORMAL
9/04/85	7:35:04	0000337	294.0	CONJUNCTIVITIS LEFT EYE MODERATE
9/27/85	7:49:14	0000337	294.0	CONJUNCTIVITIS LEFT EYE SLIGHT
10/25/85	9:05:20	0072808	297.0	CONJUNCTIVITIS LEFT EYE SLIGHT, INTRAABDOMINAL MASS VENTRAL TO LIVER SIZE LARGE
11/15/85	8:16:54	0000337		CONJUNCTIVITIS LEFT EYE, INTRAABDOMINAL MASS VENTRAL TO LIVER SIZE LARGE, STAIN YELLOW PERIANAL MODERATE, ANOREXIA MARKED

**Appendix F (cont.): INDIVIDUAL ANIMAL HISTORIES**

STUDY: 0083009  
 COMPOUND: ISOBUTYL 2-CYANOACRYLATE  
 START DATE: 1/28/85  
 CARCINOGENICITY BIOASSAY OF ISOBUTYL 2-CYANO-  
 ACRYLATE (IBC) IN MALE AND FEMALE RATS.

ANIMAL HISTORY

Animal ID: 84D00321 Species: D Sex: FEMALE Group: CONTROLS

DATE	TIME	OPERATOR	WEIGHT (GRAMS)	CLINICAL OBSERVATIONS
2/15/85	9:06:04	0000337	253.0	CONJUNCTIVITIS RIGHT EYE MARKED
3/15/85	9:27:32	0000337	256.0	CONJUNCTIVITIS RIGHT EYE MODERATE
4/12/85	8:49:04	0000337	263.0	CONJUNCTIVITIS RIGHT EYE MARKED
5/10/85	8:09:20	0000337	281.0	CONJUNCTIVITIS RIGHT EYE MARKED
6/07/85	8:23:16	0000337	289.0	CONJUNCTIVITIS RIGHT EYE MARKED
7/03/85	7:57:22	0000337	298.0	CONJUNCTIVITIS RIGHT EYE MARKED
8/02/85	8:33:50	0034567	305.0	CONJUNCTIVITIS RIGHT EYE MARKED
8/30/85	10:01:36	0000337	305.0	CONJUNCTIVITIS RIGHT EYE MARKED
9/27/85	7:49:44	0000337	321.0	CONJUNCTIVITIS RIGHT EYE SLIGHT
10/25/85	9:07:02	0072808	327.0	CONJUNCTIVITIS RIGHT EYE SLIGHT
11/22/85	8:20:12	0000337	323.0	CONJUNCTIVITIS RIGHT EYE SLIGHT
12/20/85	8:54:26	0000337	333.0	CONJUNCTIVITIS RIGHT EYE SLIGHT
1/17/86	8:29:44	0000337	330.0	ALOPECIA RIGHT EYE SLIGHT
2/10/86	7:52:00	0034567	327.0	ALOPECIA RIGHT EYE SLIGHT, EUTHANIZED

## Appendix F (cont.): INDIVIDUAL ANIMAL HISTORIES

PAGE 51  
DATE: 6/09/87  
TIME: 14:40:13  
EDS017 VAM11

STUDY: 0083009  
COMPOUND: ISOBUTYL 2-CYANOACRYLATE  
START DATE: 1/28/85

CARCINOGENICITY BIOASSAY OF ISOBUTYL 2-CYANO-  
ACRYLATE (IBC) IN MALE AND FEMALE RATS.

## ANIMAL HISTORY

Animal ID: 84D00322 Species: D Sex: FEMALE Group: 10 UL/ANN

DATE	TIME	OPERATOR	WEIGHT (GRAMS)	CLINICAL OBSERVATIONS
2/15/85	9:06:26	0000337	220.0	CORNEAL OPACITY RIGHT EYE SLIGHT
2/26/85	9:30:12	0000337		CORNEAL OPACITY RIGHT EYE SLIGHT, CONJUNCTIVITIS BOTH EYE SLIGHT
3/15/85	9:28:20	0000337	218.0	CORNEAL OPACITY RIGHT EYE SLIGHT
4/12/85	9:02:46	0000337	222.0	CORNEAL OPACITY RIGHT EYE SLIGHT
5/10/85	8:09:36	0000337	228.0	CORNEAL OPACITY RIGHT EYE SLIGHT
6/07/85	8:23:40	0000337	231.0	CORNEAL OPACITY RIGHT EYE SLIGHT
7/03/85	7:57:58	0000337	233.0	CORNEAL OPACITY RIGHT EYE, INTRAABDOMINAL MASS VENTRAL TO LIVER SIZE MEDIUM
8/02/85	8:34:14	0034567	243.0	CORNEAL OPACITY RIGHT EYE SLIGHT
8/30/85	10:01:58	0000337	246.0	CORNEAL OPACITY RIGHT EYE SLIGHT
9/27/85	7:50:10	0000337	264.0	CORNEAL OPACITY RIGHT EYE SLIGHT
10/25/85	9:08:46	0072808	261.0	CORNEAL OPACITY RIGHT EYE SLIGHT
10/29/85	8:37:24	0002920		CORNEAL OPACITY RIGHT EYE SLIGHT
11/22/85	8:20:30	0000337	268.0	CORNEAL OPACITY RIGHT EYE SLIGHT, INTRAABDOMINAL MASS SPLENIC SIZE LARGE
11/22/85	16:24:54	0010186		DEATH

PAGE 52  
 DATE: 6/09/87  
 TIME: 14:40:13  
 EDS017 VAM11

**Appendix F (cont.): INDIVIDUAL ANIMAL HISTORIES**

STUDY: 0083009 CARCINOGENICITY BIOASSAY OF ISOBUTYL 2-CYANO-  
 COMPOUND: ISOBUTYL 2-CYANOACRYLATE ACRYLATE (IBC) IN MALE AND FEMALE RATS.  
 START DATE: 1/28/85

ANIMAL HISTORY

Animal ID: 84D00323 Species: D Sex: FEMALE Group: 10 UL/ANN

DATE	TIME	OPERATOR	WEIGHT (GRAMS)	CLINICAL OBSERVATIONS
2/15/85	9:06:44	0000337	208.0	CORNEAL OPACITY RIGHT EYE SLIGHT, CONJUNCTIVITIS BOTH EYE MARKED
3/15/85	9:28:48	0000337	214.0	CORNEAL OPACITY RIGHT EYE SLIGHT, CONJUNCTIVITIS BOTH EYE MARKED, TACHYPNEA SLIGHT
4/09/85	9:50:16	0000337		CORNEAL OPACITY RIGHT EYE SLIGHT, CONJUNCTIVITIS BOTH EYE MARKED
4/12/85	9:03:16	0000337	222.0	CORNEAL OPACITY RIGHT EYE SLIGHT, CONJUNCTIVITIS BOTH EYE MARKED
5/10/85	8:09:58	0000337	225.0	CORNEAL OPACITY RIGHT EYE SLIGHT, CONJUNCTIVITIS BOTH EYE MARKED
5/29/85	7:57:40	0000337		CORNEAL OPACITY RIGHT EYE SLIGHT, CONJUNCTIVITIS BOTH EYE MARKED, INTRAABDOMINAL MASS VENTRAL TO LIVER SIZE SMALL
6/07/85	8:24:04	0000337	231.0	CORNEAL OPACITY RIGHT EYE SLIGHT, CONJUNCTIVITIS BOTH EYE MARKED, INTRAABDOMINAL MASS VENTRAL TO LIVER SIZE SMALL
7/03/85	8:00:40	0000337	240.0	CORNEAL OPACITY RIGHT EYE SLIGHT, CONJUNCTIVITIS BOTH EYE MARKED
7/03/85	8:17:36	0000337	239.0	CORNEAL OPACITY RIGHT EYE SLIGHT, CONJUNCTIVITIS BOTH EYE MARKED, INTRAABDOMINAL MASS VENTRAL TO LIVER SIZE SMALL
8/02/85	8:36:10	0034567	247.0	CORNEAL OPACITY RIGHT EYE SLIGHT, CONJUNCTIVITIS BOTH EYE MARKED, INTRAABDOMINAL MASS VENTRAL TO LIVER SIZE SMALL
8/30/85	10:02:24	0000337	253.0	CORNEAL OPACITY RIGHT EYE SLIGHT, CONJUNCTIVITIS BOTH EYE MARKED, INTRAABDOMINAL MASS VENTRAL TO LIVER SIZE SMALL
9/27/85	7:50:28	0000337	265.0	CORNEAL OPACITY RIGHT EYE SLIGHT, CONJUNCTIVITIS BOTH EYE MARKED, INTRAABDOMINAL MASS VENTRAL TO LIVER SIZE SMALL
10/25/85	9:09:04	0072808	273.0	CORNEAL OPACITY RIGHT EYE SLIGHT, CONJUNCTIVITIS BOTH EYE MARKED, INTRAABDOMINAL MASS VENTRAL TO LIVER SIZE SMALL
11/22/85	8:21:38	0000337	275.0	CORNEAL OPACITY RIGHT EYE SLIGHT, CONJUNCTIVITIS BOTH EYE SLIGHT, INTRAABDOMINAL MASS VENTRAL TO LIVER SIZE SMALL
12/20/85	8:55:02	0000337	275.0	CORNEAL OPACITY RIGHT EYE SLIGHT, CONJUNCTIVITIS BOTH EYE MODERATE, INTRAABDOMINAL MASS VENTRAL TO LIVER SIZE SMALL
1/17/86	8:30:44	0000337	284.0	CORNEAL OPACITY RIGHT EYE SLIGHT, CONJUNCTIVITIS BOTH EYE MODERATE, INTRAABDOMINAL MASS VENTRAL TO LIVER SIZE SMALL
2/10/86	7:53:18	0034567	267.0	CORNEAL OPACITY RIGHT EYE SLIGHT, CONJUNCTIVITIS BOTH EYE MODERATE, INTRAABDOMINAL MASS VENTRAL TO LIVER SIZE SMALL, EUTHANIZED



PAGE 53  
 DATE: 6/09/87  
 TIME: 14:40:13  
 EDS017 V4M11

**Appendix F (cont.): INDIVIDUAL ANIMAL HISTORIES**

STUDY: 0083009 CARCINOGENICITY BIOASSAY OF ISOBUTYL 2-CYANO-  
 COMPOUND: ISOBUTYL 2-CYANOACRYLATE ACRYLATE (IBC) IN MALE AND FEMALE RATS.  
 START DATE: 1/28/85

ANIMAL HISTORY

Animal ID: 84D00324 Species: D Sex: FEMALE Group: CONTROLS

DATE	TIME	OPERATOR	WEIGHT (GRAMS)	CLINICAL OBSERVATIONS
2/15/85	9:07:04	0000337	219.0	CONJUNCTIVITIS BOTH EYE MARKED, CORNEAL OPACITY LEFT EYE SLIGHT
3/15/85	9:29:20	0000337	223.0	CONJUNCTIVITIS BOTH EYE MARKED, CORNEAL OPACITY LEFT EYE SLIGHT
4/09/85	9:51:06	0000337		CONJUNCTIVITIS BOTH EYE MARKED, CORNEAL OPACITY LEFT EYE SLIGHT, STAIN YELLOW PERIANAL SLIGHT
4/12/85	9:04:06	0000337	230.0	CONJUNCTIVITIS BOTH EYE MARKED, CORNEAL OPACITY LEFT EYE SLIGHT, STAIN YELLOW PERIANAL SLIGHT
4/18/85	8:26:56	0000337		CONJUNCTIVITIS LEFT EYE MARKED, CORNEAL OPACITY LEFT EYE SLIGHT, STAIN CLEAR PERIANAL SLIGHT
5/02/85	7:07:04	0000337		CONJUNCTIVITIS BOTH EYE MARKED, CORNEAL OPACITY LEFT EYE SLIGHT, STAIN CLEAR PERIANAL SLIGHT
5/10/85	8:10:36	0000337	239.0	CONJUNCTIVITIS BOTH EYE MARKED, CORNEAL OPACITY LEFT EYE SLIGHT
6/07/85	8:25:34	0000337	245.0	CONJUNCTIVITIS BOTH EYE MARKED, CORNEAL OPACITY LEFT EYE SLIGHT
7/03/85	8:02:40	0084799	253.0	CORNEAL OPACITY LEFT EYE SLIGHT, CONJUNCTIVITIS LEFT EYE MODERATE
8/02/85	8:37:48	0034567	260.0	CORNEAL OPACITY LEFT EYE SLIGHT
8/30/85	10:03:20	0000337	255.0	CORNEAL OPACITY LEFT EYE SLIGHT
9/27/85	7:51:26	0000337	262.0	CORNEAL OPACITY LEFT EYE SLIGHT, CONJUNCTIVITIS RIGHT EYE SLIGHT
10/25/85	9:11:10	0072808	265.0	CORNEAL OPACITY LEFT EYE SLIGHT, CONJUNCTIVITIS LEFT EYE SLIGHT
11/22/85	8:22:46	0000337	260.0	CORNEAL OPACITY LEFT EYE SLIGHT, CONJUNCTIVITIS LEFT EYE MODERATE
12/20/85	8:55:46	0000337	267.0	CORNEAL OPACITY LEFT EYE SLIGHT, CONJUNCTIVITIS LEFT EYE MODERATE
1/13/86	10:04:34	0084799		CORNEAL OPACITY LEFT EYE SLIGHT, CONJUNCTIVITIS BOTH EYE MODERATE, STAIN YELLOW PERIANAL SLIGHT, EMACIATED MARKED

PAGE 54  
 DATE: 6/09/87  
 TIME: 14:40:13  
 EDS017 V4M11

**Appendix F (cont.): INDIVIDUAL ANIMAL HISTORIES**

STUDY: 0083009 CARCINOGENICITY BIOASSAY OF ISOBUTYL 2-CYANO-  
 COMPOUND: ISOBUTYL 2-CYANOACRYLATE ACRYLATE (IBC) IN MALE AND FEMALE RATS.  
 START DATE: 1/28/85

ANIMAL HISTORY

Animal ID: 84D00325 Species: D Sex: FEMALE Group: 100 UL/ANM

DATE	TIME	OPERATOR	WEIGHT (GRAMS)	CLINICAL OBSERVATIONS
2/15/85	9:07:54	0000337	236.0	CONJUNCTIVITIS RIGHT EYE MARKED
3/15/85	9:29:46	0000337	264.0	CONJUNCTIVITIS RIGHT EYE MARKED
4/12/85	9:05:02	0000337	248.0	CONJUNCTIVITIS RIGHT EYE MODERATE
5/10/85	8:11:18	0000337	253.0	CONJUNCTIVITIS RIGHT EYE MARKED
6/07/85	8:26:14	0000337	260.0	CONJUNCTIVITIS RIGHT EYE MARKED
7/03/85	8:03:40	0000337	259.0	CONJUNCTIVITIS RIGHT EYE MARKED
8/02/85	8:38:42	0034567	270.0	CONJUNCTIVITIS RIGHT EYE MARKED
8/30/85	10:03:40	0000337	279.0	CONJUNCTIVITIS RIGHT EYE SLIGHT
9/27/85	7:52:04	0000337	282.0	CONJUNCTIVITIS BOTH EYE SLIGHT
10/25/85	9:12:28	0072808	287.0	CONJUNCTIVITIS RIGHT EYE MARKED
11/22/85	8:23:06	0000337	285.0	CONJUNCTIVITIS RIGHT EYE SLIGHT
12/20/85	8:56:06	0000337	286.0	CONJUNCTIVITIS RIGHT EYE SLIGHT
1/17/86	8:32:20	0000337	283.0	NORMAL
2/10/86	7:56:50	0034567	258.0	NORMAL / EUTHANIZED

**Appendix F (cont.): INDIVIDUAL ANIMAL HISTORIES**

PAGE 55  
 DATE: 6/09/87  
 TIME: 14:40:13  
 EDS017 V4M11

STUDY: 0083009  
 COMPOUND: ISOBUTYL 2-CYANOACRYLATE  
 START DATE: 1/28/85

CARCINOGENICITY BIOASSAY OF ISOBUTYL 2-CYANO-  
 ACRYLATE (IBC) IN MALE AND FEMALE RATS.

ANIMAL HISTORY

Animal ID: 84D00326 Species: D Sex: FEMALE Group: 10 UL/ANM

DATE	TIME	OPERATOR	WEIGHT (GRAMS)	CLINICAL OBSERVATIONS
2/15/85	9:08:24	0000337	214.0	NORMAL
3/15/85	9:30:06	0000337	221.0	NORMAL
4/12/85	9:06:08	0000337	201.0	NORMAL
5/10/85	8:11:40	0000337	197.0	NORMAL
6/07/85	8:26:36	0000337	206.0	NORMAL
6/28/85	11:02:16	0000337		PROSTRATE, INACTIVE MARKED, TREMORS MODERATE, HYPOTONIA MARKED MODERATE, STAIN YELLOW PERIANAL MARKED

PAGE 56 @ t  
DATE: 6/09/87  
TIME: 14:40:13  
EDS017 V4M11

**Appendix F (cont.): INDIVIDUAL ANIMAL HISTORIES**

STUDY: 0083009  
COMPOUND: ISOBUTYL 2-CYANOACRYLATE  
START DATE: 1/28/85

CARCINOGENICITY BIOASSAY OF ISOBUTYL 2-CYANO-  
ACRYLATE (IBC) IN MALE AND FEMALE RATS.

**ANIMAL HISTORY**

Animal ID: 84D00327 Species: D Sex: FEMALE Group: 100 UL/ANM

DATE	TIME	OPERATOR	WEIGHT (GRAMS)	CLINICAL OBSERVATIONS
2/15/85	9:08:46	0000337	235.0	CORNEAL OPACITY BOTH EYE SLIGHT
2/26/85	9:33:00	0000337		CORNEAL OPACITY BOTH EYE SLIGHT, STAIN CLEAR PERIANAL SLIGHT
3/15/85	9:30:34	0000337	244.0	CORNEAL OPACITY BOTH EYE SLIGHT
4/12/85	9:07:18	0000337	259.0	CORNEAL OPACITY BOTH EYE SLIGHT
5/10/85	8:12:44	0000337	270.0	CORNEAL OPACITY BOTH EYE SLIGHT
6/07/85	8:28:32	0000337	273.0	CORNEAL OPACITY BOTH EYE SLIGHT
7/03/85	8:04:28	0000337	273.0	CORNEAL OPACITY BOTH EYE SLIGHT
8/02/85	9:35:48	0034567	279.0	CORNEAL OPACITY BOTH EYE SLIGHT
8/30/85	10:04:26	0000337	265.0	CORNEAL OPACITY BOTH EYE SLIGHT, INTRABDOMINAL MASS VENTRAL TO LIVER SIZE LARGE

## Appendix F (cont.): INDIVIDUAL ANIMAL HISTORIES

PAGE 57  
DATE: 6/09/87  
TIME: 14:40:13  
EDS017 V4M11

STUDY: 0083009  
COMPOUND: ISOBUTYL 2-CYANOACRYLATE  
START DATE: 1/28/85

CARCINOGENICITY BIOASSAY OF ISOBUTYL 2-CYANO-  
ACRYLATE (IBC) IN MALE AND FEMALE RATS.

## ANIMAL HISTORY

Animal ID: 84D00328 Species: D Sex: FEMALE Group: 10 UL/ANM

DATE	TIME	OPERATOR	WEIGHT (GRAMS)	CLINICAL OBSERVATIONS
2/15/85	9:09:12	0000337	232.0	CORNEAL OPACITY RIGHT EYE SLIGHT, CONJUNCTIVITIS LEFT EYE SLIGHT
3/15/85	9:32:02	0000337	238.0	CORNEAL OPACITY RIGHT EYE SLIGHT, CONJUNCTIVITIS LEFT EYE MODERATE
4/12/85	9:07:56	0000337	249.0	CORNEAL OPACITY RIGHT EYE SLIGHT, CONJUNCTIVITIS LEFT EYE MODERATE
5/10/85	8:13:10	0000337	251.0	CORNEAL OPACITY RIGHT EYE SLIGHT, CONJUNCTIVITIS LEFT EYE SLIGHT
6/07/85	8:28:58	0000337	268.0	CORNEAL OPACITY RIGHT EYE SLIGHT, CONJUNCTIVITIS LEFT EYE SLIGHT
7/03/85	8:05:10	0000337	270.0	CORNEAL OPACITY RIGHT EYE SLIGHT, CONJUNCTIVITIS LEFT EYE MODERATE
8/02/85	9:36:08	0034567	270.0	CORNEAL OPACITY RIGHT EYE SLIGHT, CONJUNCTIVITIS LEFT EYE MODERATE
8/30/85	10:07:30	0000337	274.0	CORNEAL OPACITY RIGHT EYE SLIGHT, CONJUNCTIVITIS LEFT EYE SLIGHT
9/27/85	7:52:32	0000337	272.0	CORNEAL OPACITY RIGHT EYE SLIGHT, CONJUNCTIVITIS LEFT EYE SLIGHT
10/25/85	9:13:00	0072808	276.0	CORNEAL OPACITY RIGHT EYE SLIGHT, CONJUNCTIVITIS LEFT EYE SLIGHT
11/22/85	8:23:36	0000337	265.0	CORNEAL OPACITY RIGHT EYE SLIGHT
12/20/85	8:56:24	0000337	249.0	CORNEAL OPACITY RIGHT EYE SLIGHT, PALLOR MODERATE, CONJUNCTIVITIS LEFT EYE SLIGHT
1/03/86	10:19:14	0000337		CORNEAL OPACITY RIGHT EYE SLIGHT, CONJUNCTIVITIS BOTH EYE MODERATE, PALLOR MARKED, EMACIATED MARKED

PAGE 58 of  
 DATE: 6/09/87  
 TIME: 14:40:13  
 EDS017 V4M11

**Appendix F (cont.): INDIVIDUAL ANIMAL HISTORIES**

CARCINOGENICITY BIOASSAY OF ISOBUTYL 2-CYANO-  
 ACRYLATE (IBC) IN MALE AND FEMALE RATS.

ANIMAL HISTORY

STUDY: 0083009  
 COMPOUND: ISOBUTYL 2-CYANOACRYLATE  
 START DATE: 1/28/85

Animal ID: 84D00329 Species: D Sex: FEMALE Group: CONTROLS

DATE	TIME	OPERATOR	WEIGHT (GRAMS)	CLINICAL OBSERVATIONS
2/15/85	9:09:32	0000337	229.0	NORMAL
3/15/85	9:32:34	0000337	250.0	NORMAL
4/12/85	9:08:32	0000337	243.0	NORMAL
5/10/85	8:13:36	0000337	251.0	NORMAL
6/07/85	8:29:20	0000337	261.0	NORMAL
7/03/85	8:05:56	0000337	266.0	NORMAL
8/02/85	9:37:06	0034567	275.0	NORMAL
8/30/85	10:08:02	0000337	283.0	NORMAL
9/27/85	7:52:54	0000337	283.0	NORMAL
10/25/85	9:13:26	0072808	290.0	NORMAL
11/22/85	8:24:14	0000337	299.0	NORMAL
12/20/85	8:57:12	0000337	293.0	NORMAL
1/17/86	8:32:56	0000337	286.0	NORMAL
2/10/86	7:57:56	0034567	272.0	NORMAL / EUTHANIZED

PAGE 59  
 DATE: 6/09/87  
 TIME: 14:40:13  
 EDS017 V4M11

**Appendix F (cont.): INDIVIDUAL ANIMAL HISTORIES**

STUDY: 0083009 ISOBUTYL 2-CYANOACRYLATE CARCINOGENICITY BIOASSAY OF ISOBUTYL 2-CYANO-  
 COMPOUND: ISOBUTYL 2-CYANOACRYLATE ACRYLATE (IBC) IN MALE AND FEMALE RATS.  
 START DATE: 1/28/85

ANIMAL HISTORY

Animal ID: 84D00330 Species: D Sex: FEMALE Group: CONTROLS

DATE	TIME	OPERATOR	WEIGHT (GRAMS)	CLINICAL OBSERVATIONS
2/15/85	9:09:50	0000337	251.0	NORMAL
3/15/85	9:33:00	0000337	259.0	NORMAL
4/12/85	9:09:02	0000337	271.0	NORMAL
5/10/85	8:14:02	0000337	274.0	NORMAL
6/07/85	8:29:40	0000337	290.0	NORMAL
7/03/85	8:06:24	0000337	295.0	NORMAL
8/02/85	9:37:30	0034567	300.0	NORMAL
8/30/85	10:08:20	0000337	304.0	NORMAL
9/27/85	7:53:10	0000337	304.0	NORMAL
10/25/85	9:14:04	0072808	309.0	CONJUNCTIVITIS LEFT EYE SLIGHT
11/22/85	8:24:30	0000337	305.0	NORMAL
12/20/85	8:57:32	0000337	301.0	NORMAL
1/17/86	8:33:14	0000337	294.0	NORMAL
2/07/86	10:04:44	0000337	233.0	EMACIATED MARKED, PALLOR MARKED, STAIN YELLOW PERIANAL MODERATE, EUTHANIZED

## Appendix F (cont.): INDIVIDUAL ANIMAL HISTORIES

CARCINOGENICITY BIOASSAY OF ISOBUTYL 2-CYANO-  
ACRYLATE (IBC) IN MALE AND FEMALE RATS.STUDY: 0083009  
COMPOUND: ISOBUTYL 2-CYANOACRYLATE  
START DATE: 1/28/85

## ANIMAL HISTORY

Animal ID: 84D00331 Species: D Sex: FEMALE Group: CONTROLS

DATE	TIME	OPERATOR	WEIGHT (GRAMS)	CLINICAL OBSERVATIONS
2/08/85	9:03:50	0000337		CORNEAL OPACITY RIGHT EYE MODERATE, CORNEAL OPACITY LEFT EYE SLIGHT, CONJUNCTIVITIS BOTH EYE MARKED
2/15/85	9:10:10	0000337	223.0	CORNEAL OPACITY RIGHT EYE MODERATE, CORNEAL OPACITY LEFT EYE SLIGHT, CONJUNCTIVITIS BOTH EYE MODERATE
3/15/85	9:33:12	0000337	223.0	CORNEAL OPACITY RIGHT EYE MODERATE, CORNEAL OPACITY LEFT EYE SLIGHT, CONJUNCTIVITIS BOTH EYE SLIGHT
4/09/85	9:56:06	0000337		CORNEAL OPACITY RIGHT EYE MODERATE, CORNEAL OPACITY LEFT EYE SLIGHT, CONJUNCTIVITIS LEFT EYE SLIGHT, STAIN YELLOW PERIANAL SLIGHT
4/12/85	9:09:36	0000337	233.0	CORNEAL OPACITY RIGHT EYE MODERATE, CORNEAL OPACITY LEFT EYE SLIGHT, CONJUNCTIVITIS LEFT EYE SLIGHT, STAIN YELLOW PERIANAL SLIGHT
4/18/85	8:29:00	0000337		CORNEAL OPACITY RIGHT EYE MODERATE, CORNEAL OPACITY LEFT EYE SLIGHT, CONJUNCTIVITIS BOTH EYE MODERATE, STAIN YELLOW PERIANAL SLIGHT
5/10/85	8:14:22	0000337	231.0	CORNEAL OPACITY RIGHT EYE MODERATE, CORNEAL OPACITY LEFT EYE SLIGHT
5/29/85	8:50:30	0000337		CORNEAL OPACITY RIGHT EYE MODERATE, CORNEAL OPACITY LEFT EYE SLIGHT, YELLOW PERIANAL SLIGHT
6/07/85	8:29:56	0000337	195.0	CORNEAL OPACITY RIGHT EYE MODERATE, CORNEAL OPACITY LEFT EYE SLIGHT, STAIN YELLOW PERIANAL SLIGHT, DEHYDRATED MARKED
6/10/85	8:47:02	0000337		CORNEAL OPACITY RIGHT EYE MODERATE, CORNEAL OPACITY LEFT EYE SLIGHT
7/03/85	8:06:44	0000337	241.0	CORNEAL OPACITY RIGHT EYE MODERATE, CORNEAL OPACITY LEFT EYE SLIGHT, CONJUNCTIVITIS BOTH EYE SLIGHT
8/02/85	9:37:48	0034567	254.0	CORNEAL OPACITY RIGHT EYE MODERATE, CORNEAL OPACITY LEFT EYE SLIGHT
8/30/85	10:08:40	0000337	255.0	CORNEAL OPACITY RIGHT EYE MODERATE, CORNEAL OPACITY LEFT EYE SLIGHT
9/04/85	7:42:08	0000337		CORNEAL OPACITY RIGHT EYE MODERATE, CORNEAL OPACITY LEFT EYE SLIGHT, CONJUNCTIVITIS LEFT EYE SLIGHT
9/27/85	7:53:24	0000337	266.0	CORNEAL OPACITY RIGHT EYE MODERATE, CORNEAL OPACITY LEFT EYE SLIGHT
10/25/85	9:14:38	0072808	272.0	CORNEAL OPACITY RIGHT EYE MODERATE, CORNEAL OPACITY LEFT EYE SLIGHT
11/22/85	8:24:56	0000337	275.0	CORNEAL OPACITY RIGHT EYE MODERATE, CORNEAL OPACITY LEFT EYE SLIGHT
12/20/85	8:57:44	0000337	255.0	CORNEAL OPACITY RIGHT EYE MODERATE, CORNEAL OPACITY LEFT EYE SLIGHT
1/17/86	8:33:30	0000337	262.0	CORNEAL OPACITY RIGHT EYE MODERATE, CORNEAL OPACITY LEFT EYE SLIGHT, SPLENIC MASS SIZE MEDIUM
2/07/86	10:08:02	0000337	241.0	CORNEAL OPACITY RIGHT EYE MODERATE, CORNEAL OPACITY LEFT EYE SLIGHT, PALLOR MARKED, SPLENIC MASS SIZE LARGE, EUTHANIZED



## Appendix F (cont.): INDIVIDUAL ANIMAL HISTORIES

PAGE 61  
DATE: 6/09/87  
TIME: 14:40:13  
EDS017 V4M11

STUDY: 0083009 ISOBUTYL 2-CYANOACRYLATE CARCINOGENICITY BIASSAY OF ISOBUTYL 2-CYANO-  
COMPOUND: ISOBUTYL 2-CYANOACRYLATE ACRYLATE (IBC) IN MALE AND FEMALE RATS.

START DATE: 1/28/85

## ANIMAL HISTORY

Animal ID: 84D00332 Species: D Sex: FEMALE Group: 10 UL/ANM

DATE	TIME	OPERATOR	WEIGHT (GRAMS)	CLINICAL OBSERVATIONS
2/08/85	9:04:50	0000337		CONJUNCTIVITIS BOTH EYE SLIGHT
2/15/85	9:10:42	0000337	226.0	CONJUNCTIVITIS BOTH EYE SLIGHT
2/19/85	8:29:58	0000337		NORMAL
2/26/85	9:35:40	0000337		CONJUNCTIVITIS BOTH EYE SLIGHT
3/15/85	9:33:38	0000337	227.0	CONJUNCTIVITIS LEFT EYE SLIGHT
4/12/85	9:10:18	0000337	239.0	CONJUNCTIVITIS LEFT EYE SLIGHT
5/10/85	8:14:52	0000337	233.0	CONJUNCTIVITIS LEFT EYE SLIGHT
6/07/85	8:31:52	0000337	247.0	CONJUNCTIVITIS LEFT EYE SLIGHT
7/03/85	8:08:00	0000337	259.0	CONJUNCTIVITIS LEFT EYE SLIGHT
8/02/85	9:38:34	0034567	262.0	CONJUNCTIVITIS LEFT EYE MODERATE
8/30/85	10:09:12	0000337	265.0	CONJUNCTIVITIS LEFT EYE MODERATE
9/04/85	7:43:08	0000337		CONJUNCTIVITIS LEFT EYE MODERATE
9/27/85	7:54:36	0000337	275.0	CONJUNCTIVITIS LEFT EYE MODERATE
10/25/85	9:14:58	0072808	277.0	CONJUNCTIVITIS LEFT EYE MODERATE
11/22/85	8:25:22	0000337	284.0	CONJUNCTIVITIS LEFT EYE MARKED
12/20/85	8:58:08	0000337	294.0	CONJUNCTIVITIS LEFT EYE SLIGHT
1/17/86	8:34:58	0000337	291.0	CONJUNCTIVITIS LEFT EYE SLIGHT
2/10/86	7:59:14	0034567	287.0	NORMAL / EUTHANIZED

**Appendix F (cont.): INDIVIDUAL ANIMAL HISTORIES**

STUDY: 0083009 ISOBUTYL 2-CYANOACRYLATE CARCINOGENICITY BIOASSAY OF ISOBUTYL 2-CYANO-  
 COMPOUND: ISOBUTYL 2-CYANOACRYLATE ACRYLATE (IBC) IN MALE AND FEMALE RATS.  
 START DATE: 1/28/85

ANIMAL HISTORY

Animal ID: 84D00334 Species: D Sex: FEMALE Group: CONTROLS

DATE	TIME	OPERATOR	WEIGHT (GRAMS)	CLINICAL OBSERVATIONS
2/15/85	9:11:08	0000337	204.0	NORMAL
3/15/85	9:34:08	0000337	204.0	NORMAL
3/19/85	7:59:22	0034567		CONJUNCTIVITIS RIGHT EYE SLIGHT
4/12/85	9:10:58	0000337	214.0	NORMAL
5/10/85	8:15:26	0000337	216.0	CONJUNCTIVITIS LEFT EYE SLIGHT
5/29/85	8:52:00	0000337		CONJUNCTIVITIS LEFT EYE MARKED
6/07/85	8:32:58	0000337	224.0	CONJUNCTIVITIS LEFT EYE MARKED
7/03/85	8:08:40	0000337	227.0	CONJUNCTIVITIS LEFT EYE MARKED
8/02/85	9:39:04	0034567	240.0	CONJUNCTIVITIS LEFT EYE MARKED
8/30/85	10:09:40	0000337	240.0	CONJUNCTIVITIS LEFT EYE MODERATE
9/04/85	7:44:16	0000337		CONJUNCTIVITIS LEFT EYE MODERATE
9/27/85	7:55:02	0000337	248.0	CONJUNCTIVITIS LEFT EYE MARKED
10/25/85	9:15:18	0072808	246.0	CONJUNCTIVITIS BOTH EYE MODERATE
10/29/85	8:49:54	0002920		CONJUNCTIVITIS BOTH EYE MARKED
11/22/85	8:25:40	0000337	250.0	CONJUNCTIVITIS BOTH EYE MARKED
12/03/85	12:37:22	0000337		CONJUNCTIVITIS BOTH EYE MARKED, STAIN YELLOW PERIANAL MARKED, EMACIATED MARKED

PAGE 63  
 DATE: 6/29/87  
 TIME: 14:40:13  
 EDS017 V4M11

**Appendix F (cont.): INDIVIDUAL ANIMAL HISTORIES**

STUDY: 0083009 CARCINOGENICITY BIOASSAY OF ISOBUTYL 2-CYANO-  
 COMPOUND: ISOBUTYL 2-CYANOACRYLATE ACRYLATE (IBC) IN MALE AND FEMALE RATS.  
 START DATE: 1/28/85

ANIMAL HISTORY

Animal ID: 84D00335 Species: D Sex: FEMALE Group: 10 UL/ANM

DATE	TIME	OPERATOR	WEIGHT (GRAMS)	CLINICAL OBSERVATIONS
2/15/85	9:11:26	0000337	225.0	CORNEAL OPACITY LEFT EYE SLIGHT
3/15/85	9:34:32	0000337	227.0	CORNEAL OPACITY LEFT EYE SLIGHT
4/12/85	9:11:40	0000337	230.0	CORNEAL OPACITY LEFT EYE SLIGHT
5/10/85	8:15:48	0000337	242.0	CORNEAL OPACITY LEFT EYE SLIGHT, CONJUNCTIVITIS LEFT EYE SLIGHT
6/07/85	8:33:24	0000337	267.0	CORNEAL OPACITY LEFT EYE SLIGHT
7/03/85	8:09:08	0000337	262.0	CORNEAL OPACITY LEFT EYE SLIGHT
8/02/85	9:39:38	0034567	264.0	CORNEAL OPACITY LEFT EYE SLIGHT
8/30/85	10:10:10	0000337	272.0	CORNEAL OPACITY LEFT EYE SLIGHT
9/27/85	7:55:34	0000337	286.0	CORNEAL OPACITY LEFT EYE SLIGHT
10/25/85	9:16:04	0072808	290.0	CORNEAL OPACITY LEFT EYE SLIGHT
11/22/85	8:25:54	0000337	287.0	CORNEAL OPACITY LEFT EYE SLIGHT
12/20/85	8:58:34	0000337	289.0	CORNEAL OPACITY LEFT EYE SLIGHT
1/17/86	8:35:16	0000337	296.0	CORNEAL OPACITY LEFT EYE SLIGHT
2/10/86	8:00:22	0034567	278.0	CORNEAL OPACITY LEFT EYE SLIGHT, CONJUNCTIVITIS LEFT EYE MODERATE, EUTHANIZED

PAGE 640  
 DATE: 6/09/87  
 TIME: 14:40:13  
 EDS017 VAM11.

**Appendix F (cont.): INDIVIDUAL ANIMAL HISTORIES**

STUDY: 0083009  
 COMPOUND: ISOBUTYL 2-CYANOACRYLATE  
 START DATE: 1/28/85  
 CARCINOGENICITY BIOASSAY OF ISOBUTYL 2-CYANO-  
 ACRYLATE (IBC) IN MALE AND FEMALE RATS.

**ANIMAL HISTORY**

Animal ID: 84D00336 Species: D Sex: FEMALE Group: CONTROLS

DATE	TIME	OPERATOR	WEIGHT (GRAMS)	CLINICAL OBSERVATIONS
2/15/85	9:11:48	0000337	226.0	NORMAL
3/15/85	9:34:52	0000337	224.0	NORMAL
4/12/85	9:12:10	0000337	235.0	NORMAL
5/10/85	8:16:20	0000337	239.0	CONJUNCTIVITIS BOTH EYE SLIGHT, CORNEAL OPACITY LEFT EYE SLIGHT
6/07/85	8:34:04	0000337	236.0	CORNEAL OPACITY LEFT EYE SLIGHT
7/03/85	8:09:44	0000337	244.0	CORNEAL OPACITY LEFT EYE SLIGHT
8/02/85	9:39:58	0034567	254.0	CORNEAL OPACITY LEFT EYE SLIGHT
8/30/85	10:10:30	0000337	264.0	CORNEAL OPACITY LEFT EYE SLIGHT
9/27/85	7:55:56	0000337	268.0	CORNEAL OPACITY LEFT EYE SLIGHT
10/25/85	9:16:34	0072808	270.0	CORNEAL OPACITY LEFT EYE SLIGHT
11/22/85	8:26:10	0000337	277.0	CORNEAL OPACITY LEFT EYE SLIGHT
12/20/85	8:58:52	0000337	284.0	CORNEAL OPACITY LEFT EYE SLIGHT
1/17/86	8:35:30	0000337	275.0	CORNEAL OPACITY LEFT EYE SLIGHT
2/10/86	8:02:22	0034567	267.0	CORNEAL OPACITY LEFT EYE SLIGHT, EUTHANIZED

## Appendix F (cont.): INDIVIDUAL ANIMAL HISTORIES

PAGE 65  
DATE: 6/09/87  
TIME: 14:40:13  
EDS017 V4M11

STUDY: 0083009  
COMPOUND: ISOBUTYL 2-CYANOACRYLATE  
START DATE: 1/28/85

CARCINOGENICITY BIOASSAY OF ISOBUTYL 2-CYANO-  
ACRYLATE (IBC) IN MALE AND FEMALE RATS.

ANIMAL HISTORY

Animal ID: 84D00337 Species: D Sex: FEMALE Group: 10 UL/ANM

DATE	TIME	OPERATOR	WEIGHT (GRAMS)	CLINICAL OBSERVATIONS
2/15/85	9:12:04	0000337	227.0	NORMAL
3/15/85	9:35:16	0000337	230.0	NORMAL
4/12/85	9:13:02	0000337	237.0	NORMAL
5/10/85	8:17:08	0000337	243.0	NORMAL
6/07/85	8:34:38	0000337	247.0	CONJUNCTIVITIS LEFT EYE SLIGHT
7/03/85	8:10:08	0000337	254.0	NORMAL
8/02/85	9:40:18	0034567	263.0	NORMAL
8/30/85	10:10:56	0000337	252.0	NORMAL
9/27/85	7:56:10	0000337	252.0	NORMAL
10/25/85	9:17:04	0072808	262.0	NORMAL
10/29/85	8:53:58	0002920	267.0	CONJUNCTIVITIS LEFT EYE SLIGHT
11/22/85	8:26:36	0000337	242.0	NORMAL
12/20/85	8:59:10	0000337	247.0	NORMAL
1/17/86	8:35:44	0000337	247.0	NORMAL
2/10/86	8:03:48	0034567	235.0	NORMAL / EUTHANIZED

**Appendix F (cont.): INDIVIDUAL ANIMAL HISTORIES**

STUDY: 0083009  
 COMPOUND: ISOBUTYL 2-CYANOACRYLATE  
 START DATE: 1/28/85  
 CARCINOGENICITY BIOASSAY OF ISOBUTYL 2-CYANO-  
 ACRYLATE (IBC) IN MALE AND FEMALE RATS.

ANIMAL HISTORY

Animal ID: 84D00338 Species: D Sex: FEMALE Group: 100 UL/ANM

DATE	TIME	OPERATOR	WEIGHT (GRAMS)	CLINICAL OBSERVATIONS
2/15/85	9:12:26	0000337	245.0	CORNEAL OPACITY RIGHT EYE MODERATE, CORNEAL OPACITY LEFT EYE SLIGHT
3/15/85	9:35:30	0000337	255.0	CORNEAL OPACITY RIGHT EYE MODERATE, CORNEAL OPACITY LEFT EYE SLIGHT
4/12/85	9:13:40	0000337	259.0	CORNEAL OPACITY RIGHT EYE MODERATE, CORNEAL OPACITY LEFT EYE SLIGHT
5/10/85	8:17:22	0000337	268.0	CORNEAL OPACITY RIGHT EYE MODERATE, CORNEAL OPACITY LEFT EYE SLIGHT
6/07/85	8:35:02	0000337	271.0	CORNEAL OPACITY RIGHT EYE MODERATE, CORNEAL OPACITY LEFT EYE SLIGHT
7/03/85	8:10:58	0000337	277.0	CORNEAL OPACITY RIGHT EYE MODERATE, CORNEAL OPACITY LEFT EYE SLIGHT
8/02/85	9:40:36	0034567	284.0	CORNEAL OPACITY RIGHT EYE MODERATE, CORNEAL OPACITY LEFT EYE SLIGHT, INTRAABDOMINAL MASS ADJACENT TO LIVER SIZE MEDIUM
8/15/85	7:27:20	0000337		CORNEAL OPACITY RIGHT EYE MODERATE, CORNEAL OPACITY LEFT EYE SLIGHT, INTRAABDOMINAL MASS VENTRAL TO LIVER SIZE LARGE
8/30/85	10:11:28	0000337	294.0	CORNEAL OPACITY RIGHT EYE MODERATE, CORNEAL OPACITY LEFT EYE SLIGHT, INTRAABDOMINAL MASS VENTRAL TO LIVER SIZE LARGE, INTRAABDOMINAL MASS INGUINAL AREA SIZE MEDIUM

## Appendix F (cont.): INDIVIDUAL ANIMAL HISTORIES

STUDY: J083009  
 COMPOUND: ISOBUTYL 2-CYANOACRYLATE  
 START DATE: 1/28/85

CARCINOGENICITY BIOASSAY OF ISOBUTYL 2-CYANO-  
 ACRYLATE (IBC) IN MALE AND FEMALE RATS.

ANIMAL HISTORY

PAGE 67  
 DATE: 6/09/87  
 TIME: 14:40:13  
 EDS017 VAM11

Animal ID: 84D00339 Species: D Sex: FEMALE Group: 10 UL/ANM

DATE	TIME	OPERATOR	WEIGHT (GRAMS)	CLINICAL OBSERVATIONS
2/15/85	9:12:48	0000337	236.0	CORNEAL OPACITY LEFT EYE SLIGHT
3/15/85	9:35:54	0000337	241.0	CORNEAL OPACITY LEFT EYE SLIGHT
4/12/85	9:14:18	0000337	246.0	CORNEAL OPACITY LEFT EYE SLIGHT, CONJUNCTIVITIS LEFT EYE SLIGHT
5/10/85	8:17:38	0000337	259.0	CORNEAL OPACITY LEFT EYE SLIGHT
5/29/85	8:54:16	0000337		CORNEAL OPACITY LEFT EYE SLIGHT, CONJUNCTIVITIS LEFT EYE SLIGHT
6/07/85	8:35:22	0000337	267.0	CORNEAL OPACITY LEFT EYE SLIGHT
7/03/85	8:11:32	0000337	269.0	CORNEAL OPACITY LEFT EYE SLIGHT
8/02/85	9:43:12	0034567	279.0	CORNEAL OPACITY LEFT EYE SLIGHT
8/30/85	10:14:04	0000337	284.0	CORNEAL OPACITY LEFT EYE SLIGHT
9/04/85	7:47:08	0000337		CORNEAL OPACITY LEFT EYE SLIGHT
9/27/85	7:56:26	0000337	290.0	CORNEAL OPACITY LEFT EYE SLIGHT
10/25/85	9:17:26	0072808	291.0	CORNEAL OPACITY LEFT EYE SLIGHT
11/22/85	8:26:54	0000337	295.0	CORNEAL OPACITY LEFT EYE SLIGHT
12/20/85	8:59:26	0000337	299.0	CORNEAL OPACITY LEFT EYE SLIGHT
1/17/86	8:36:04	0000337	296.0	CORNEAL OPACITY LEFT EYE SLIGHT
2/10/86	8:05:00	0034567	288.0	CORNEAL OPACITY LEFT EYE SLIGHT, EUTHANIZED

PAGE 68  
 DATE: 6/09/87  
 TIME: 14:40:13  
 EDS017 V4M11

**Appendix F (cont.): INDIVIDUAL ANIMAL HISTORIES**

STUDY: 0083009 CARCINOGENICITY BIOASSAY OF ISOBUTYL 2-CYANO-  
 COMPOUND: ISOBUTYL 2-CYANOACRYLATE ACRYLATE (IBC) IN MALE AND FEMALE RATS.  
 START DATE: 1/28/85

ANIMAL HISTORY

Animal ID: 84D00340 Species: D Sex: FEMALE Group: 10 UL/ANM

DATE	TIME	OPERATOR	WEIGHT (GRAMS)	CLINICAL OBSERVATIONS
2/15/85	9:13:06	0000337	221.0	CONJUNCTIVITIS BOTH EYE MARKED, TACHYPNEA SLIGHT
2/26/85	9:40:00	0000337		CONJUNCTIVITIS BOTH EYE MARKED, TACHYPNEA SLIGHT, STAIN CLEAR PERIANAL SLIGHT
3/01/85	8:05:48	0000337		CONJUNCTIVITIS BOTH EYE MARKED, TACHYPNEA MODERATE, STAIN CLEAR PERIANAL SLIGHT
3/15/85	9:36:10	0000337	224.0	CONJUNCTIVITIS BOTH EYE MARKED, TACHYPNEA SLIGHT
4/12/85	9:14:54	0000337	231.0	CONJUNCTIVITIS BOTH EYE MARKED
5/10/85	8:17:58	0000337	242.0	CONJUNCTIVITIS BOTH EYE MARKED
6/07/85	8:35:44	0000337	251.0	CONJUNCTIVITIS BOTH EYE MARKED
7/03/85	8:12:06	0000337	253.0	CONJUNCTIVITIS BOTH EYE MARKED
8/02/85	9:44:10	0034567	254.0	CONJUNCTIVITIS BOTH EYE MARKED
8/30/85	10:14:50	0000337	259.0	CONJUNCTIVITIS BOTH EYE MARKED
9/27/85	7:56:46	0000337	260.0	CONJUNCTIVITIS BOTH EYE MARKED
10/25/85	9:17:52	0072808	259.0	CONJUNCTIVITIS BOTH EYE MARKED
10/29/85	13:16:24	0002920		CONJUNCTIVITIS BOTH EYE MARKED, TACHYPNEA SLIGHT, DEHYDRATED SLIGHT
11/22/85	8:27:10	0000337	272.0	CONJUNCTIVITIS BOTH EYE MODERATE, TACHYPNEA SLIGHT
12/20/85	8:59:46	0000337	273.0	CONJUNCTIVITIS BOTH EYE MARKED, TACHYPNEA SLIGHT
1/17/86	8:36:20	0000337	265.0	CONJUNCTIVITIS BOTH EYE MARKED, TACHYPNEA SLIGHT
2/10/86	8:06:06	0034567	255.0	CONJUNCTIVITIS BOTH EYE MARKED, TACHYPNEA SLIGHT, EUTHANIZED



## Appendix F (cont.): INDIVIDUAL ANIMAL HISTORIES

PAGE 69  
DATE: 6/09/87  
TIME: 14:40:13  
EDS017 V4M11

STUDY: 0083009 ISOBUTYL 2-CYANOACRYLATE CARCINOGENICITY BIOASSAY OF ISOBUTYL 2-CYANO-  
COMPOUND: ISOBUTYL 2-CYANOACRYLATE ACRYLATE (IBC) IN MALE AND FEMALE RATS.

START DATE: 1/28/85

## ANIMAL HISTORY

Animal ID: 84D00341 Species: D Sex: FEMALE Group: CONTROLS

DATE	TIME	OPERATOR	WEIGHT (GRAMS)	CLINICAL OBSERVATIONS
2/15/85	9:13:54	0000337	212.0	CORNEAL OPACITY BOTH EYE SLIGHT, CONJUNCTIVITIS BOTH EYE MARKED
3/15/85	9:36:48	0000337	224.0	CORNEAL OPACITY BOTH EYE SLIGHT, CONJUNCTIVITIS BOTH EYE MARKED
4/12/85	9:15:54	0000337	237.0	CORNEAL OPACITY BOTH EYE SLIGHT, CONJUNCTIVITIS BOTH EYE SLIGHT
5/10/85	8:18:14	0000337	248.0	CORNEAL OPACITY BOTH EYE SLIGHT, CONJUNCTIVITIS RIGHT EYE MODERATE
5/29/85	8:55:38	0000337	255.0	CORNEAL OPACITY BOTH EYE SLIGHT, CONJUNCTIVITIS RIGHT EYE MARKED
6/07/85	8:36:00	0000337	264.0	CORNEAL OPACITY BOTH EYE SLIGHT, CONJUNCTIVITIS RIGHT EYE MARKED
7/03/85	8:12:38	0000337	264.0	CORNEAL OPACITY BOTH EYE SLIGHT, CONJUNCTIVITIS RIGHT EYE MARKED
8/02/85	9:44:48	0034567	264.0	CORNEAL OPACITY BOTH EYE SLIGHT
8/30/85	10:15:12	0000337	270.0	CORNEAL OPACITY BOTH EYE SLIGHT
9/04/85	7:48:42	0000337	274.0	CORNEAL OPACITY BOTH EYE SLIGHT, CONJUNCTIVITIS RIGHT EYE MARKED
9/27/85	7:57:04	0000337	274.0	CORNEAL OPACITY BOTH EYE SLIGHT
10/25/85	9:18:22	0072808	295.0	CORNEAL OPACITY BOTH EYE SLIGHT, SUBCUTANEOUS MASS LEFT INGUINAL AREA SIZE LARGE
10/29/85	9:00:32	0084799		CORNEAL OPACITY BOTH EYE SLIGHT, SUBCUTANEOUS MASS LEFT INGUINAL AREA SIZE LARGE, CONJUNCTIVITIS RIGHT EYE MODERATE
11/22/85	8:27:50	0000337	293.0	CORNEAL OPACITY BOTH EYE SLIGHT, SUBCUTANEOUS MASS LEFT INGUINAL AREA SIZE LARGE
12/20/85	9:00:42	0000337	287.0	CORNEAL OPACITY BOTH EYE SLIGHT, CONJUNCTIVITIS RIGHT EYE SLIGHT, SUBCUTANEOUS MASS LEFT INGUINAL AREA SOFT SIZE LARGE
1/17/86	8:37:06	0000337	297.0	CORNEAL OPACITY BOTH EYE SLIGHT, CONJUNCTIVITIS RIGHT EYE SLIGHT, SUBCUTANEOUS MASS LEFT INGUINAL AREA SOFT SIZE LARGE
2/10/86	8:07:36	0034567	275.0	CORNEAL OPACITY BOTH EYE SLIGHT, CONJUNCTIVITIS RIGHT EYE SLIGHT, SUBCUTANEOUS MASS LEFT INGUINAL AREA SIZE LARGE, EUTHANIZED

PAGE 70 @  
 DATE: 6/09/87  
 TIME: 14:40:13  
 EDS017 V4M11

**Appendix F (cont.): INDIVIDUAL ANIMAL HISTORIES**

STUDY: 0083009  
 COMPOUND: ISOBUTYL 2-CYANOACRYLATE  
 START DATE: 1/28/85

CARCINOGENICITY BIOASSAY OF ISOBUTYL 2-CYANO-  
 ACRYLATE (IBC) IN MALE AND FEMALE RATS.

ANIMAL HISTORY

Animal ID: 84D00342 Species: D Sex: FEMALE Group: 10 UL/ANM

DATE	TIME	OPERATOR	WEIGHT (GRAMS)	CLINICAL OBSERVATIONS
2/15/85	9:14:30	0000337	234.0	CONJUNCTIVITIS BOTH EYE MARKED
3/15/85	9:37:08	0000337	233.0	CONJUNCTIVITIS BOTH EYE MARKED
4/12/85	9:16:26	0000337	241.0	CONJUNCTIVITIS BOTH EYE MODERATE
5/10/85	8:18:50	0000337	253.0	CONJUNCTIVITIS BOTH EYE MODERATE
5/29/85	8:56:22	0000337		CONJUNCTIVITIS BOTH EYE MARKED
6/07/85	8:36:20	0000337	254.0	CONJUNCTIVITIS BOTH EYE MARKED
7/03/85	8:13:22	0000337	261.0	CONJUNCTIVITIS BOTH EYE MARKED
8/02/85	9:45:14	0034567	266.0	CONJUNCTIVITIS BOTH EYE MARKED
8/30/85	10:15:34	0000337	257.0	CONJUNCTIVITIS BOTH EYE SLIGHT
9/27/85	7:57:36	0000337	262.0	NORMAL
10/02/85	9:07:04	0000337		CONJUNCTIVITIS BOTH EYE MODERATE
10/25/85	9:21:48	0072808	272.0	CONJUNCTIVITIS RIGHT EYE MARKED
11/22/85	8:29:10	0000337	282.0	CONJUNCTIVITIS RIGHT EYE SLIGHT
12/20/85	9:02:04	0000337	291.0	CONJUNCTIVITIS RIGHT EYE MARKED
1/17/86	8:38:26	0000337	284.0	NORMAL
2/10/86	8:09:48	0034567	275.0	NORMAL / EUTHANIZED

**Appendix F (cont.): INDIVIDUAL ANIMAL HISTORIES**

PAGE 71  
 DATE: 6/09/87  
 TIME: 14:40:13  
 EDS017 V4M11

STUDY: 0083009 CARCINOGENICITY BIOASSAY OF ISOBUTYL 2-CYANO-  
 COMPOUND: ISOBUTYL 2-CYANOACRYLATE ACRYLATE (IBC) IN MALE AND FEMALE RATS.  
 START DATE: 1/28/85

ANIMAL HISTORY

Animal ID: 84D00343 Species: D Sex: FEMALE Group: 100 UL/ANM

DATE	TIME	OPERATOR	WEIGHT (GRAMS)	CLINICAL OBSERVATIONS
2/15/85	9:14:54	0000337	245.0	CORNEAL OPACITY RIGHT EYE SLIGHT
2/26/85	9:42:36	0000337		CORNEAL OPACITY RIGHT EYE SLIGHT, CONJUNCTIVITIS BOTH EYE SLIGHT
3/15/85	9:37:28	0000337	248.0	CORNEAL OPACITY RIGHT EYE SLIGHT, CONJUNCTIVITIS BOTH EYE SLIGHT
4/12/85	9:17:02	0000337	256.0	CORNEAL OPACITY RIGHT EYE SLIGHT, CONJUNCTIVITIS BOTH EYE SLIGHT
5/10/85	8:19:08	0000337	256.0	CORNEAL OPACITY RIGHT EYE SLIGHT, CONJUNCTIVITIS BOTH EYE SLIGHT
6/07/85	8:36:36	0084799	274.0	CORNEAL OPACITY RIGHT EYE SLIGHT, CONJUNCTIVITIS BOTH EYE SLIGHT, INTRAABDOMINAL MASS VENTRAL TO LIVER SIZE LARGE
7/03/85	8:13:48	0000337	274.0	CORNEAL OPACITY RIGHT EYE SLIGHT, CONJUNCTIVITIS BOTH EYE SLIGHT, INTRAABDOMINAL MASS VENTRAL TO LIVER SIZE LARGE
8/02/85	9:45:36	0034567	280.0	CORNEAL OPACITY RIGHT EYE SLIGHT, CONJUNCTIVITIS RIGHT EYE SLIGHT, INTRAABDOMINAL MASS VENTRAL TO LIVER SIZE LARGE
8/30/85	10:16:28	0000337	289.0	CORNEAL OPACITY RIGHT EYE SLIGHT, INTRAABDOMINAL MASS VENTRAL TO LIVER SIZE LARGE
9/27/85	7:58:10	0000337	286.0	CORNEAL OPACITY RIGHT EYE SLIGHT, INTRAABDOMINAL MASS VENTRAL TO LIVER SIZE LARGE
10/02/85	9:08:14	0000337		CORNEAL OPACITY RIGHT EYE SLIGHT, CONJUNCTIVITIS RIGHT EYE MARKED, INTRAABDOMINAL MASS VENTRAL TO LIVER SIZE LARGE
10/25/85	9:25:54	0072808	279.0	CORNEAL OPACITY RIGHT EYE SLIGHT, CONJUNCTIVITIS RIGHT EYE SLIGHT, INTRAABDOMINAL MASS VENTRAL TO LIVER SIZE LARGE
11/19/85	12:43:40	0000337		CORNEAL OPACITY RIGHT EYE SLIGHT, CONJUNCTIVITIS RIGHT EYE SLIGHT, INTRAABDOMINAL MASS VENTRAL TO LIVER SIZE LARGE

PAGE 72  
 DATE: 6/09/87  
 TIME: 14:40:13  
 EDS017 V4M11.

**Appendix F (cont.): INDIVIDUAL ANIMAL HISTORIES**

STUDY: 0083009  
 COMPOUND: ISOBUTYL 2-CYANOACRYLATE  
 START DATE: 1/28/85

CARCINOGENICITY BIOASSAY OF ISOBUTYL 2-CYANO-  
 ACRYLATE (IBC) IN MALE AND FEMALE RATS.

ANIMAL HISTORY

Animal ID: 84D00345 Species: D Sex: FEMALE Group: 10 UL/ANM

DATE	TIME	OPERATOR	WEIGHT (GRAMS)	CLINICAL OBSERVATIONS
2/15/85	9:15:14	0000337	244.0	CORNEAL OPACITY LEFT EYE SLIGHT
3/15/85	9:37:54	0000337	254.0	CORNEAL OPACITY LEFT EYE SLIGHT
4/12/85	9:17:36	0000337	265.0	CORNEAL OPACITY LEFT EYE SLIGHT
5/10/85	8:19:28	0000337	269.0	CORNEAL OPACITY LEFT EYE SLIGHT
6/07/85	8:38:38	0000337	276.0	CORNEAL OPACITY LEFT EYE SLIGHT
7/03/85	8:20:22	0000337	287.0	CORNEAL OPACITY LEFT EYE SLIGHT
8/02/85	9:47:16	0034567	288.0	CORNEAL OPACITY LEFT EYE SLIGHT
8/30/85	10:17:30	0000337	291.0	CORNEAL OPACITY LEFT EYE SLIGHT
9/27/85	7:59:28	0000337	294.0	CORNEAL OPACITY LEFT EYE SLIGHT
10/25/85	9:27:10	0072808	292.0	CORNEAL OPACITY LEFT EYE SLIGHT
11/22/85	8:29:34	0000337	279.0	CORNEAL OPACITY LEFT EYE SLIGHT
12/20/85	9:41:24	0000337	247.0	CORNEAL OPACITY LEFT EYE SLIGHT
1/13/86	10:07:24	0000337		CORNEAL OPACITY LEFT EYE SLIGHT, PALLOR MODERATE, EMACIATED MARKED, STAIN BROWN NOSE SLIGHT

**Appendix F (cont.): INDIVIDUAL ANIMAL HISTORIES**

PAGE 73  
 DATE: 6/09/87  
 TIME: 14:40:13  
 EDS017 VAM11

STUDY: 0083009  
 COMPOUND: ISOBUTYL 2-CYANOACRYLATE  
 START DATE: 1/28/85  
 CARCINOGENICITY BIOASSAY OF ISOBUTYL 2-CYANO-  
 ACRYLATE (IBC) IN MALE AND FEMALE RATS.

ANIMAL HISTORY

Animal ID: 84D00346 Species: D Sex: FEMALE Group: 10 UL/ANM

DATE	TIME	OPERATOR	WEIGHT (GRAMS)	CLINICAL OBSERVATIONS
2/15/85	9:15:40	0000337	215.0	CORNEAL OPACITY RIGHT EYE SLIGHT
3/15/85	9:38:14	0000337	212.0	CORNEAL OPACITY RIGHT EYE SLIGHT, CONJUNCTIVITIS LEFT EYE MARKED
4/12/85	9:18:08	0000337	225.0	CORNEAL OPACITY RIGHT EYE SLIGHT
5/10/85	8:19:44	0000337	230.0	CORNEAL OPACITY RIGHT EYE SLIGHT
6/07/85	8:38:58	0000337	239.0	CORNEAL OPACITY RIGHT EYE SLIGHT
7/03/85	8:20:40	0000337	250.0	CORNEAL OPACITY RIGHT EYE SLIGHT
8/02/85	9:47:46	0034567	262.0	CORNEAL OPACITY RIGHT EYE SLIGHT
8/30/85	10:17:46	0000337	270.0	CORNEAL OPACITY RIGHT EYE SLIGHT
9/27/85	7:59:40	0000337	279.0	CORNEAL OPACITY RIGHT EYE SLIGHT
10/25/85	9:27:36	0072808	285.0	CORNEAL OPACITY RIGHT EYE SLIGHT
11/22/85	8:29:56	0000337	298.0	CORNEAL OPACITY RIGHT EYE SLIGHT
12/20/85	9:42:32	0000337	281.0	CORNEAL OPACITY RIGHT EYE SLIGHT
1/17/86	8:42:50	0000337	235.0	CORNEAL OPACITY RIGHT EYE SLIGHT, STAIN BROWN HEAD SLIGHT
1/21/86	9:51:10	0000337		MORIBUND

PAGE 74  
 DATE: 6/09/87  
 TIME: 14:40:13  
 EDS017 V4M11

**Appendix F (cont.): INDIVIDUAL ANIMAL HISTORIES**

STUDY: 0083009  
 COMPOUND: ISOBUTYL 2-CYANOACRYLATE  
 START DATE: 1/28/85

CARCINOGENICITY BIOASSAY OF ISOBUTYL 2-CYANO-  
 ACRYLATE (IBC) IN MALE AND FEMALE RATS.

ANIMAL HISTORY

Animal ID: 84D00348 Species: D Sex: FEMALE Group: 100 UL/ANM

DATE	TIME	OPERATOR	WEIGHT (GRAMS)	CLINICAL OBSERVATIONS
2/15/85	9:15:58	0000337	251.0	CORNEAL OPACITY LEFT EYE MODERATE, CORNEAL OPACITY RIGHT EYE SLIGHT
3/15/85	9:38:44	0000337	259.0	CORNEAL OPACITY LEFT EYE MODERATE, CORNEAL OPACITY RIGHT EYE SLIGHT
4/12/85	9:18:50	0000337	266.0	CORNEAL OPACITY LEFT EYE MODERATE, CORNEAL OPACITY RIGHT EYE SLIGHT
5/10/85	8:20:04	0000337	269.0	CORNEAL OPACITY LEFT EYE MODERATE, CORNEAL OPACITY RIGHT EYE SLIGHT
6/07/85	8:39:18	0000337	280.0	CORNEAL OPACITY LEFT EYE MODERATE, CORNEAL OPACITY RIGHT EYE SLIGHT
7/03/85	8:21:10	0000337	285.0	CORNEAL OPACITY LEFT EYE MODERATE, CORNEAL OPACITY RIGHT EYE SLIGHT
8/02/85	9:48:08	0034567	289.0	CORNEAL OPACITY LEFT EYE MODERATE, CORNEAL OPACITY RIGHT EYE SLIGHT
8/30/85	10:18:12	0000337	298.0	CORNEAL OPACITY LEFT EYE MODERATE, CORNEAL OPACITY RIGHT EYE SLIGHT
9/27/85	8:00:12	0000337	308.0	CORNEAL OPACITY LEFT EYE MODERATE, CORNEAL OPACITY RIGHT EYE SLIGHT
10/25/85	9:27:58	0072808	302.0	CORNEAL OPACITY LEFT EYE MODERATE, CORNEAL OPACITY RIGHT EYE SLIGHT
11/22/85	8:30:22	0000337	319.0	CORNEAL OPACITY LEFT EYE MODERATE, CORNEAL OPACITY RIGHT EYE SLIGHT
12/20/85	9:42:56	0000337	321.0	CORNEAL OPACITY LEFT EYE MODERATE, CORNEAL OPACITY RIGHT EYE SLIGHT
1/17/86	8:43:52	0000337	327.0	CORNEAL OPACITY LEFT EYE MODERATE, CORNEAL OPACITY RIGHT EYE SLIGHT
2/12/86	7:38:36	0034567	306.0	CORNEAL OPACITY LEFT EYE MODERATE, CORNEAL OPACITY RIGHT EYE SLIGHT, EUTHANIZED

## Appendix F (cont.): INDIVIDUAL ANIMAL HISTORIES

PAGE 75  
DATE: 6/09/87  
TIME: 14:40:13  
EDS017 V4M11

STUDY: 0083009  
COMPOUND: ISOBUTYL 2-CYANOACRYLATE  
START DATE: 1/28/85  
CARCINOGENICITY BIOASSAY OF ISOBUTYL 2-CYANO-  
ACRYLATE (IBC) IN MALE AND FEMALE RATS.

## ANIMAL HISTORY

Animal ID: 84D00349 Species: D Sex: FEMALE Group: CONTROLS

DATE	TIME	OPERATOR	WEIGHT (GRAMS)	CLINICAL OBSERVATIONS
2/15/85	9:16:32	0000337	248.0	NORMAL
3/15/85	9:39:28	0000337	243.0	NORMAL
4/12/85	9:19:26	0000337	255.0	NORMAL
5/10/85	8:20:34	0000337	252.0	NORMAL
6/07/85	8:39:36	0000337	256.0	NORMAL
7/03/85	8:21:38	0000337	254.0	STAIN BROWN NOSE SLIGHT
8/02/85	9:48:30	0034567	268.0	NORMAL
8/30/85	10:18:36	0000337	275.0	NORMAL
9/27/85	8:00:46	0000337	286.0	NORMAL
10/25/85	9:28:28	0072808	289.0	NORMAL
11/22/85	8:30:42	0000337	278.0	NORMAL
12/20/85	9:43:12	0000337	267.0	CONJUNCTIVITIS LEFT EYE MODERATE
1/17/86	8:44:12	0000337	258.0	CONJUNCTIVITIS LEFT EYE MODERATE, SCAB BACK SLIGHT
2/12/86	7:40:12	0034567	221.0	CONJUNCTIVITIS BOTH EYE SLIGHT, EUTHANIZED

### Appendix F (cont.): INDIVIDUAL ANIMAL HISTORIES

STUDY: 0083009 ISOBUTYL 2-CYANOACRYLATE CARCINOGENICITY BIORASSAY OF ISOBUTYL 2-CYANO-  
 COMPOUND: ISOBUTYL 2-CYANOACRYLATE ACRYLATE (IBC) IN MALE AND FEMALE RATS.  
 START DATE: 1/28/85

#### ANIMAL HISTORY

Animal ID: 84000350 Species: D Sex: FEMALE Group: CONTROLS

DATE	TIME	OPERATOR	WEIGHT (GRAMS)	CLINICAL OBSERVATIONS
2/08/85	9:16:46	0000337		CONJUNCTIVITIS LEFT EYE SLIGHT
2/15/85	9:16:56	0000337	203.0	CONJUNCTIVITIS LEFT EYE SLIGHT
3/15/85	9:39:54	0000337	204.0	CONJUNCTIVITIS LEFT EYE SLIGHT
4/12/85	9:20:22	0000337	211.0	CONJUNCTIVITIS LEFT EYE SLIGHT
5/10/85	8:20:56	0000337	214.0	CONJUNCTIVITIS LEFT EYE SLIGHT
6/07/85	8:40:20	0000337	222.0	CONJUNCTIVITIS LEFT EYE SLIGHT
7/03/85	8:22:22	0000337	225.0	CONJUNCTIVITIS LEFT EYE SLIGHT
8/02/85	9:49:16	0034567	236.0	CONJUNCTIVITIS LEFT EYE MODERATE
8/30/85	10:19:02	0000337	239.0	NORMAL
9/04/85	7:54:20	0000337		CONJUNCTIVITIS BOTH EYE SLIGHT
9/27/85	8:01:12	0000337	250.0	NORMAL
10/25/85	9:28:48	0072808	247.0	CONJUNCTIVITIS LEFT EYE MODERATE
11/22/85	8:31:00	0000337	249.0	NORMAL
12/20/85	9:43:40	0000337	250.0	CONJUNCTIVITIS LEFT EYE SLIGHT
1/17/86	8:45:00	0000337	254.0	NORMAL
2/12/86	7:41:44	0034567	235.0	NORMAL / EUTHANIZED



PAGE 77  
 DATE: 6/09/87  
 TIME: 14:40:13  
 EDS017 V4M11

**Appendix F (cont.): INDIVIDUAL ANIMAL HISTORIES**

STUDY: 0083009  
 COMPOUND: ISOBUTYL 2-CYANOACRYLATE  
 START DATE: 1/28/85  
 CARCINOGENICITY BIOASSAY OF ISOBUTYL 2-CYANO-  
 ACRYLATE (IBC) IN MALE AND FEMALE RATS.

ANIMAL HISTORY

Animal ID: 84D00352 Species: D Sex: FEMALE Group: 100 UL/ANM

DATE	TIME	OPERATOR	WEIGHT (GRAMS)	CLINICAL OBSERVATIONS
2/08/85	9:17:34	0000337		CONJUNCTIVITIS RIGHT EYE SLIGHT, STAIN YELLOW PERIANAL SLIGHT
2/15/85	9:17:10	0000337	217.0	CONJUNCTIVITIS RIGHT EYE SLIGHT
2/26/85	9:46:30	0000337		CONJUNCTIVITIS RIGHT EYE SLIGHT, STAIN YELLOW PERIANAL MODERATE
3/15/85	9:40:14	0000337	217.0	CONJUNCTIVITIS RIGHT EYE SLIGHT
4/12/85	9:20:52	0000337	222.0	CONJUNCTIVITIS RIGHT EYE SLIGHT
5/10/85	8:21:14	0000337	221.0	CONJUNCTIVITIS RIGHT EYE SLIGHT
6/07/85	8:40:44	0000337	227.0	CONJUNCTIVITIS RIGHT EYE SLIGHT
7/03/85	8:22:54	0000337	237.0	CONJUNCTIVITIS RIGHT EYE SLIGHT
8/02/85	9:49:42	0034567	246.0	NORMAL
8/30/85	10:19:20	0000337	251.0	NORMAL
9/27/85	8:54:40	0000337	255.0	NORMAL
10/25/85	9:29:28	0072808	254.0	NORMAL
11/22/85	8:31:16	0000337	259.0	NORMAL
12/20/85	9:44:08	0000337	258.0	NORMAL
1/17/86	8:45:22	0000337	261.0	NORMAL
2/12/86	7:42:52	0034567	241.0	CONJUNCTIVITIS RIGHT EYE SLIGHT, EUTHANIZED

PAGE 78  
 DATE: 6/09/87  
 TIME: 14:40:13  
 EDS017 V4M11

**Appendix F (cont.): INDIVIDUAL ANIMAL HISTORIES**

STUDY: 0083009  
 COMPOUND: ISOBUTYL 2-CYANOACRYLATE  
 START DATE: 1/28/85

CARCINOGENICITY BIOASSAY OF ISOBUTYL 2-CYANO-  
 ACRYLATE (IBC) IN MALE AND FEMALE RATS.

**ANIMAL HISTORY**

Animal ID: 84D00353 Species: D Sex: FEMALE Group: CONTROLS

DATE	TIME	OPERATOR	WEIGHT (GRAMS)	CLINICAL OBSERVATIONS
2/15/85	9:18:02	0000337	232.0	NORMAL
3/15/85	9:40:42	0000337	236.0	NORMAL
4/12/85	9:21:28	0000337	244.0	NORMAL
5/10/85	8:21:30	0000337	249.0	NORMAL
6/07/85	8:41:04	0000337	203.0	NORMAL
7/03/85	8:23:22	0000337	255.0	CONJUNCTIVITIS BOTH EYE SLIGHT, TACHYPNEA SLIGHT
8/02/85	9:50:14	0034567	263.0	NORMAL
8/30/85	10:19:48	0000337	265.0	NORMAL
9/27/85	8:55:06	0000337	274.0	NORMAL
10/25/85	9:29:52	0072808	268.0	NORMAL
11/22/85	8:31:36	0000337	276.0	NORMAL
12/20/85	9:44:24	0000337	284.0	NORMAL
1/17/86	8:45:40	0000337	285.0	NORMAL
2/12/86	7:44:16	0034567	276.0	NORMAL / EUTHANIZED

Appendix F (cont.): INDIVIDUAL ANIMAL HISTORIES

PAGE 79  
 DATE: 6/09/87  
 TIME: 14:40:13  
 EDS017 V4M11

STUDY: 0083009 ISOBUTYL 2-CYANOACRYLATE CARCINOGENICITY BIASSAY OF ISOBUTYL 2-CYANO-  
 COMPOUND: ISOBUTYL 2-CYANOACRYLATE ACRYLATE (IBC) IN MALE AND FEMALE RATS.  
 START DATE: 1/28/85

ANIMAL HISTORY

Animal ID: 84D00354 Species: D Sex: FEMALE Group: CONTROLS

DATE	TIME	OPERATOR	WEIGHT (GRAMS)	CLINICAL OBSERVATIONS
2/15/85	9:19:00	0084799	221.0	CORNEAL OPACITY RIGHT EYE MODERATE, CONJUNCTIVITIS LEFT EYE MODERATE
2/27/85	8:23:38	0078478		CORNEAL OPACITY RIGHT EYE MODERATE, CONJUNCTIVITIS LEFT SLIGHT
3/15/85	9:41:08	0000337	222.0	CORNEAL OPACITY RIGHT EYE MODERATE
4/12/85	9:22:06	0000337	228.0	CORNEAL OPACITY RIGHT EYE MODERATE
5/10/85	8:21:48	0000337	234.0	CORNEAL OPACITY RIGHT EYE MODERATE
6/07/85	8:43:20	0000337	177.0	CORNEAL OPACITY RIGHT EYE MODERATE
7/03/85	8:25:04	0000337	235.0	CORNEAL OPACITY RIGHT EYE MODERATE
8/02/85	9:50:54	0034567	239.0	CORNEAL OPACITY RIGHT EYE MODERATE
8/30/85	10:20:12	0000337	245.0	CORNEAL OPACITY RIGHT EYE MODERATE
9/27/85	8:55:40	0000337	249.0	CORNEAL OPACITY RIGHT EYE MODERATE
10/25/85	9:30:12	0072808	256.0	CORNEAL OPACITY RIGHT EYE MODERATE, TACHYPNEA SLIGHT
11/22/85	8:31:56	0000337	248.0	CORNEAL OPACITY RIGHT EYE MODERATE, TACHYPNEA SLIGHT, SUBCUTANEOUS MASS LEFT INGUINAL AREA SIZE LARGE
12/20/85	9:44:40	0000337	257.0	CORNEAL OPACITY RIGHT EYE MODERATE, TACHYPNEA SLIGHT, SUBCUTANEOUS MASS LEFT INGUINAL AREA SIZE LARGE
1/17/86	8:46:00	0000337	269.0	CORNEAL OPACITY RIGHT EYE MODERATE, TACHYPNEA SLIGHT, SUBCUTANEOUS MASS LEFT INGUINAL AREA SIZE LARGE
2/12/86	7:45:12	0034567	248.0	CORNEAL OPACITY RIGHT EYE MODERATE, SUBCUTANEOUS MASS LEFT INGUINAL AREA SIZE LARGE, EUTHANIZED

PAGE 80  
 DATE: 6/09/87  
 TIME: 14:40:13  
 EDS017 V4M11

**Appendix F (cont.): INDIVIDUAL ANIMAL HISTORIES**

CARCINOGENICITY BIOASSAY OF ISOBUTYL 2-CYANO-  
 ACRYLATE (IBC) IN MALE AND FEMALE RATS.

STUDY: 0083009  
 COMPOUND: ISOBUTYL 2-CYANOACRYLATE  
 START DATE: 1/28/85

ANIMAL HISTORY

Animal ID: 84D00355 Species: D Sex: FEMALE Group: 100 UL/ANM

DATE	TIME	OPERATOR	WEIGHT (GRAMS)	CLINICAL OBSERVATIONS
2/01/85	11:23:20	0000337		CORNEAL OPACITY LEFT EYE SLIGHT, CONJUNCTIVITIS LEFT EYE SLIGHT
2/15/85	9:19:28	0000337	215.0	CORNEAL OPACITY LEFT EYE SLIGHT, CONJUNCTIVITIS LEFT EYE SLIGHT
3/15/85	9:41:38	0000337	219.0	CORNEAL OPACITY LEFT EYE SLIGHT, CONJUNCTIVITIS LEFT EYE SLIGHT
4/12/85	9:22:32	0000337	225.0	CORNEAL OPACITY LEFT EYE SLIGHT
5/10/85	8:22:10	0000337	231.0	NORMAL
5/29/85	9:02:34	0000337		CONJUNCTIVITIS LEFT EYE MODERATE
6/07/85	8:45:40	0000337	237.0	CONJUNCTIVITIS LEFT EYE MODERATE
7/03/85	8:26:12	0000337	240.0	CONJUNCTIVITIS LEFT EYE MODERATE
8/02/85	9:51:18	0034567	242.0	CONJUNCTIVITIS LEFT EYE MODERATE
8/30/85	10:20:36	0000337	243.0	CONJUNCTIVITIS LEFT EYE MARKED
9/27/85	8:55:54	0000337	262.0	CONJUNCTIVITIS LEFT EYE MARKED
10/25/85	9:31:10	0072808	268.0	CONJUNCTIVITIS LEFT EYE MARKED
11/22/85	8:32:56	0000337	272.0	CONJUNCTIVITIS LEFT EYE SLIGHT
12/20/85	9:46:28	0000337	273.0	CONJUNCTIVITIS LEFT EYE SLIGHT
1/17/86	8:47:14	0000337	279.0	CONJUNCTIVITIS LEFT EYE SLIGHT
2/12/86	7:47:38	0034567	265.0	CONJUNCTIVITIS LEFT EYE SLIGHT, EUTHANIZED

**Appendix F (cont.): INDIVIDUAL ANIMAL HISTORIES**

PAGE 81  
 DATE: 6/09/87  
 TIME: 14:40:13  
 EDS017 V4M11

STUDY: 0083009 CARCINOGENICITY BIOASSAY OF ISOBUTYL 2-CYANO-  
 COMPOUND: ISOBUTYL 2-CYANOACRYLATE ACRYLATE (IBC) IN MALE AND FEMALE RATS.  
 START DATE: 1/28/85

ANIMAL HISTORY

Animal ID: 84D00356 Species: D Sex: FEMALE Group: 100 UL/ANM

DATE	TIME	OPERATOR	WEIGHT (GRAMS)	CLINICAL OBSERVATIONS
2/01/85	11:24:42	0000337		CONJUNCTIVITIS BOTH EYE MARKED
2/15/85	9:19:48	0000337	241.0	CONJUNCTIVITIS BOTH EYE MARKED
2/27/85	8:24:58	0078478		CONJUNCTIVITIS BOTH EYE MODERATE
3/11/85	7:59:24	0000337		CONJUNCTIVITIS BOTH EYE MODERATE, STAIN BROWN NOSE SLIGHT
3/15/85	9:42:58	0000337	259.0	CONJUNCTIVITIS BOTH EYE MODERATE
4/12/85	9:23:22	0000337	271.0	CONJUNCTIVITIS BOTH EYE MODERATE
5/10/85	8:22:50	0000337	278.0	CONJUNCTIVITIS BOTH EYE MARKED
6/07/85	8:45:56	0000337	277.0	CONJUNCTIVITIS BOTH EYE MARKED
7/03/85	8:27:06	0000337	284.0	CONJUNCTIVITIS BOTH EYE MARKED
8/02/85	9:52:02	0034567	283.0	CONJUNCTIVITIS BOTH EYE MARKED
8/30/85	10:21:14	0000337	287.0	CONJUNCTIVITIS BOTH EYE MARKED
9/09/85	9:20:18	0000337		CONJUNCTIVITIS BOTH EYE MARKED, INTRAABDOMINAL MASS VENTRAL TO LIVER SIZE MEDIUM
9/27/85	8:56:12	0000337	291.0	CONJUNCTIVITIS BOTH EYE MARKED, INTRAABDOMINAL MASS VENTRAL TO LIVER SIZE MEDIUM
10/25/85	9:31:36	0072808	282.0	CONJUNCTIVITIS BOTH EYE MARKED, INTRAABDOMINAL MASS VENTRAL TO LIVER SIZE MEDIUM
11/22/85	8:33:22	0000337	255.0	CONJUNCTIVITIS BOTH EYE MARKED, INTRAABDOMINAL MASS VENTRAL TO LIVER SIZE MEDIUM, MALOCCLUDED INCISORS
12/20/85	9:46:50	0000337	256.0	CONJUNCTIVITIS BOTH EYE MARKED, INTRAABDOMINAL MASS VENTRAL TO LIVER SIZE MEDIUM
1/17/86	8:47:36	0084799	222.0	CONJUNCTIVITIS BOTH EYE MARKED, INTRAABDOMINAL MASS VENTRAL TO LIVER SIZE MEDIUM, MALOCCLUSION, SENT TO NECROPSY SEVERE WEIGHT LOSS

**Appendix F (cont.): INDIVIDUAL ANIMAL HISTORIES**

STUDY: 0083009 CARCINOGENICITY BIOASSAY OF ISOBUTYL 2-CYANO-  
 COMPOUND: ISOBUTYL 2-CYANOACRYLATE ACRYLATE (IBC) IN MALE AND FEMALE RATS.  
 START DATE: 1/28/85

**ANIMAL HISTORY**

Animal ID: 84D00357 Species: D Sex: FEMALE Group: 10 UL/ANN

DATE	TIME	OPERATOR	WEIGHT (GRAMS)	CLINICAL OBSERVATIONS
2/01/85	11:26:10	0000337		CORNEAL OPACITY LEFT EYE SLIGHT, XYPHOID PROTUBERANCE
2/15/85	9:20:10	0000337	229.0	CORNEAL OPACITY LEFT EYE SLIGHT, XYPHOID PROTUBERANCE SLIGHT
2/27/85	8:20:38	0078478		CORNEAL OPACITY LEFT EYE SLIGHT, XYPHOID PROTUBERANCE SLIGHT
2/27/85	8:25:50	0078478		CORNEAL OPACITY LEFT EYE SLIGHT, XYPHOID PROTUBERANCE SLIGHT, CONJUNCTIVITIS RIGHT EYE MODERATE
3/15/85	9:44:22	0000337	233.0	CORNEAL OPACITY LEFT EYE SLIGHT, CONJUNCTIVITIS RIGHT EYE MODERATE, XYPHOID PROTUBERANCE SLIGHT
4/12/85	9:24:04	0000337	248.0	CORNEAL OPACITY LEFT EYE SLIGHT, XYPHOID PROTUBERANCE
5/10/85	8:23:08	0000337	254.0	CORNEAL OPACITY LEFT EYE SLIGHT, CONJUNCTIVITIS RIGHT EYE SLIGHT, XYPHOID PROTUBERANCE SLIGHT
6/07/85	8:46:36	0000337	269.0	CORNEAL OPACITY LEFT EYE SLIGHT, CONJUNCTIVITIS BOTH EYE SLIGHT, XYPHOID PROTUBERANCE SLIGHT
7/03/85	8:27:56	0084799	273.0	CORNEAL OPACITY LEFT EYE SLIGHT, CONJUNCTIVITIS BOTH EYE SLIGHT, XYPHOID PROTUBERANCE SMALL
8/02/85	9:52:26	0034567	269.0	CORNEAL OPACITY LEFT EYE SLIGHT, XYPHOID PROTUBERANCE SLIGHT
8/30/85	10:21:32	0000337	270.0	CORNEAL OPACITY LEFT EYE SLIGHT, XYPHOID PROTUBERANCE SLIGHT
9/27/85	8:57:26	0000337	280.0	CORNEAL OPACITY LEFT SLIGHT, XYPHOID PROTUBERANCE SLIGHT
10/25/85	9:32:42	0072808	280.0	CORNEAL OPACITY LEFT SLIGHT, XYPHOID PROTUBERANCE SLIGHT
11/22/85	8:36:52	0000337	278.0	CORNEAL OPACITY LEFT EYE SLIGHT, XYPHOID PROTUBERANCE SLIGHT
12/20/85	9:48:44	0000337	282.0	CORNEAL OPACITY LEFT EYE SLIGHT, XYPHOID PROTUBERANCE SLIGHT
1/17/86	9:26:08	0000337	284.0	CORNEAL OPACITY LEFT EYE SLIGHT, XYPHOID PROTUBERANCE SLIGHT
2/12/86	7:49:00	0084799	271.0	SUBCUTANEOUS MASS LEFT THORAX SIZE MEDIUM, EUTHANIZED

## Appendix F (cont.): INDIVIDUAL ANIMAL HISTORIES

PAGE 83  
DATE: 6/09/87  
TIME: 14:40:13  
EDS017 V4M11

STUDY: 0083009  
COMPOUND: ISOBUTYL 2-CYANOACRYLATE  
START DATE: 1/28/85

CARCINOGENICITY BIOASSAY OF ISOBUTYL 2-CYANO-  
ACRYLATE (IBC) IN MALE AND FEMALE RATS.

## ANIMAL HISTORY

Animal ID: 84D00358 Species: D Sex: FEMALE Group: CONTROLS

DATE	TIME	OPERATOR	WEIGHT (GRAMS)	CLINICAL OBSERVATIONS
2/15/85	9:21:04	0000337	270.0	NORMAL
3/15/85	9:45:34	0000337	277.0	NORMAL
4/12/85	9:25:08	0000337	283.0	NORMAL
5/10/85	8:24:30	0000337	288.0	NORMAL
5/30/85	7:10:52	0000337		CONJUNCTIVITIS LEFT EYE SLIGHT
6/07/85	8:47:52	0000337	291.0	CONJUNCTIVITIS LEFT EYE SLIGHT
7/03/85	8:29:52	0000337	294.0	CONJUNCTIVITIS LEFT EYE SLIGHT
8/02/85	9:53:30	0034567	303.0	STAIN BROWN NOSE SLIGHT
8/30/85	10:22:28	0000337	299.0	NORMAL
9/27/85	8:58:22	0000337	303.0	NORMAL
10/25/85	9:34:08	0072808	297.0	NORMAL
11/22/85	8:38:16	0000337	306.0	NORMAL
12/20/85	9:49:32	0000337	304.0	NORMAL
1/17/86	9:26:52	0000337	306.0	NORMAL
2/12/86	7:52:02	0034567	288.0	NORMAL / EUTHANIZED

PAGE 84  
 DATE: 6/09/87  
 TIME: 14:40:13  
 EDS017 V4M11

**Appendix F (cont.): INDIVIDUAL ANIMAL HISTORIES**

STUDY: 0083009  
 COMPOUND: ISOBUTYL 2-CYANOACRYLATE  
 START DATE: 1/28/85

Animal ID: 84D00359 Species: D Sex: FEMALE Group: CONTROLS

ANIMAL HISTORY

DATE	TIME	OPERATOR	WEIGHT (GRAMS)	CLINICAL OBSERVATIONS
2/15/85	9:21:22	0000337	209.0	NORMAL
3/11/85	8:02:14	0000337		CONJUNCTIVITIS BOTH EYE SLIGHT
3/15/85	9:45:58	0000337	217.0	CONJUNCTIVITIS BOTH EYE SLIGHT
4/10/85	8:10:14	0072808		NORMAL
4/12/85	9:25:40	0000337	230.0	CORNEAL OPACITY BOTH EYE SLIGHT
5/10/85	8:24:46	0000337	240.0	CORNEAL OPACITY BOTH EYE SLIGHT
6/07/85	8:48:08	0000337	247.0	CORNEAL OPACITY BOTH EYE SLIGHT
7/03/85	8:30:42	0000337	243.0	CORNEAL OPACITY BOTH EYE SLIGHT
8/02/85	9:54:00	0034567	255.0	CORNEAL OPACITY BOTH EYE SLIGHT
8/30/85	10:22:42	0000337	259.0	CORNEAL OPACITY BOTH EYE SLIGHT
9/27/85	8:58:40	0000337	267.0	CORNEAL OPACITY BOTH EYE SLIGHT
10/25/85	9:35:00	0072808	265.0	CORNEAL OPACITY BOTH EYE SLIGHT
10/29/85	9:27:34	0002920		CORNEAL OPACITY BOTH EYE SLIGHT, CONJUNCTIVITIS RIGHT EYE SLIGHT
11/22/85	8:38:30	0000337	268.0	CORNEAL OPACITY BOTH EYE SLIGHT
12/20/85	9:49:48	0000337	257.0	CORNEAL OPACITY BOTH EYE SLIGHT
12/23/85	10:54:22	0000337		* No observations recorded.



**Appendix F (cont.): INDIVIDUAL ANIMAL HISTORIES**

PAGE 85  
 DATE: 6/09/87  
 TIME: 14:40:13  
 EDS017 V4M11

STUDY: 0083009 ISOBUTYL 2-CYANOACRYLATE CARCINOGENICITY BIOASSAY OF ISOBUTYL 2-CYANO-  
 COMPOUND: ISOBUTYL 2-CYANOACRYLATE ACRYLATE (IBC) IN MALE AND FEMALE RATS.  
 START DATE: 1/28/85

ANIMAL HISTORY

Animal ID: 84D00360 Species: D Sex: FEMALE Group: 100 UL/ANM

DATE	TIME	OPERATOR	WEIGHT (GRAMS)	CLINICAL OBSERVATIONS
2/15/85	9:21:50	0000337	204.0	CORNEAL OPACITY LEFT EYE SLIGHT
2/27/85	8:29:18	0078478		CORNEAL OPACITY LEFT EYE SLIGHT, VAGINAL DISCHARGE SLIGHT
2/28/85	11:02:58	0084799		CORNEAL OPACITY LEFT EYE SLIGHT
3/15/85	9:46:22	0000337	218.0	CORNEAL OPACITY LEFT EYE SLIGHT
4/12/85	9:26:48	0000337	217.0	CORNEAL OPACITY LEFT EYE SLIGHT, CONJUNCTIVITIS LEFT EYE SLIGHT
5/10/85	8:25:04	0000337	226.0	CORNEAL OPACITY LEFT EYE SLIGHT, CONJUNCTIVITIS LEFT EYE SLIGHT
6/07/85	8:48:42	0000337	227.0	CORNEAL OPACITY LEFT EYE SLIGHT, CONJUNCTIVITIS LEFT EYE SLIGHT
7/03/85	8:31:20	0000337	231.0	CORNEAL OPACITY LEFT EYE SLIGHT, CONJUNCTIVITIS LEFT EYE SLIGHT
8/02/85	9:54:28	0034567	237.0	CORNEAL OPACITY LEFT EYE SLIGHT
8/30/85	10:23:04	0000337	245.0	CORNEAL OPACITY LEFT EYE SLIGHT
9/27/85	8:59:14	0000337	252.0	CORNEAL OPACITY LEFT EYE SLIGHT
10/25/85	9:35:28	0072808	253.0	CORNEAL OPACITY LEFT EYE SLIGHT
11/22/85	8:38:50	0000337	247.0	CORNEAL OPACITY LEFT EYE SLIGHT
12/20/85	9:50:06	0000337	248.0	CORNEAL OPACITY LEFT EYE SLIGHT
1/17/86	9:27:04	0000337	258.0	CORNEAL OPACITY LEFT EYE SLIGHT
2/12/86	7:53:08	0034567	228.0	CORNEAL OPACITY LEFT EYE SLIGHT, EUTHANIZED

PAGE 86T  
 DATE: 6/09/87  
 TIME: 14:40:13a  
 EDS017 VAM11

**Appendix F (cont.): INDIVIDUAL ANIMAL HISTORIES**

STUDY: 0083009 ISOBUTYL 2-CYANOACRYLATE CARCINOGENICITY BIOASSAY OF ISOBUTYL 2-CYANO-  
 COMPOUND: ISOBUTYL 2-CYANOACRYLATE ACRYLATE (IBC) IN MALE AND FEMALE RATS.  
 START DATE: 1/28/85

**ANIMAL HISTORY**

Animal ID: 84D00361 Species: D Sex: FEMALE Group: 10 UL/ANM

DATE	TIME	OPERATOR	WEIGHT (GRAMS)	CLINICAL OBSERVATIONS
2/15/85	9:22:06	0000337	233.0	NORMAL
2/27/85	8:32:46	0078478		STAIN YELLOW PERIANAL SLIGHT
3/11/85	8:03:28	0000337		NORMAL
3/15/85	9:47:38	0000337	242.0	NORMAL
4/12/85	9:27:38	0000337	267.0	NORMAL
5/10/85	8:25:26	0000337	263.0	NORMAL
5/21/85	7:31:38	0000337		INTRAABDOMINAL MASS VENTRAL TO LIVER SIZE MEDIUM
5/30/85	7:12:40	0000337		INTRAABDOMINAL MASS VENTRAL TO LIVER SIZE MEDIUM
6/07/85	9:53:58	0000337	271.0	INTRAABDOMINAL MASS VENTRAL TO LIVER SIZE LARGE
7/03/85	8:32:00	0000337	277.0	INTRAABDOMINAL MASS VENTRAL TO LIVER SIZE MEDIUM
8/02/85	9:55:02	0034567	285.0	INTRAABDOMINAL MASS VENTRAL TO LIVER SIZE MEDIUM
8/30/85	11:37:56	0000337	290.0	INTRAABDOMINAL MASS VENTRAL TO LIVER SIZE MEDIUM
9/27/85	8:59:32	0000337	301.0	INTRAABDOMINAL MASS VENTRAL TO LIVER SIZE MEDIUM
10/25/85	9:35:58	0072808	301.0	INTRAABDOMINAL MASS VENTRAL TO LIVER SIZE MEDIUM
11/22/85	8:39:04	0000337	293.0	INTRAABDOMINAL MASS VENTRAL TO LIVER SIZE MEDIUM
12/20/85	9:50:24	0000337	291.0	INTRAABDOMINAL MASS VENTRAL TO LIVER SIZE MEDIUM
1/17/86	9:27:18	0000337	290.0	INTRAABDOMINAL MASS VENTRAL TO LIVER SIZE MEDIUM
1/29/86	8:44:52	0000337	233.0	INTRAABDOMINAL MASS VENTRAL TO LIVER SIZE MEDIUM, EMACIATED MARKED, CONJUNCTIVITIS BOTH EYE MARKED, EUTHANIZED

PAGE 87  
 DATE: 6/09/87  
 TIME: 14:40:13  
 EDS017 V4M11

**Appendix F (cont.): INDIVIDUAL ANIMAL HISTORIES**

STUDY: 0083009  
 COMPOUND: ISOBUTYL 2-CYANOACRYLATE  
 START DATE: 1/28/85

CARCINOGENICITY BIOASSAY OF ISOBUTYL 2-CYANO-  
 ACRYLATE (IBC) IN MALE AND FEMALE RATS.

ANIMAL HISTORY

Animal ID: 84D00363 Species: D Sex: FEMALE Group: 10 UL/ANM

DATE	TIME	OPERATOR	WEIGHT (GRAMS)	CLINICAL OBSERVATIONS
2/15/85	9:22:22	0000337	229.0	NORMAL
3/15/85	9:48:10	0000337	242.0	NORMAL
4/12/85	9:28:14	0000337	246.0	NORMAL
5/10/85	8:25:40	0000337	253.0	NORMAL
6/07/85	9:55:46	0000337	251.0	NORMAL
7/03/85	8:33:26	0000337	252.0	NORMAL
8/02/85	9:56:34	0034567	247.0	NORMAL
8/30/85	11:41:50	0000337	240.0	NORMAL
9/13/85	10:03:40	0002920		STAIN CLEAR MOUTH MARKED

PAGE 880  
 DATE: 6/09/87  
 TIME: 14:40:13  
 EDS017 VAM111

**Appendix F (cont.): INDIVIDUAL ANIMAL HISTORIES**

CARCINOGENICITY BIOASSAY OF ISOBUTYL 2-CYANO-  
 ACRYLATE (IBC) IN MALE AND FEMALE RATS.

STUDY: 0083009  
 COMPOUND: ISOBUTYL 2-CYANOACRYLATE  
 START DATE: 1/28/85

ANIMAL HISTORY

Animal ID: 84D00364 Species: D Sex: FEMALE Group: CONTROLS

DATE	TIME	OPERATOR	WEIGHT (GRAMS)	CLINICAL OBSERVATIONS
2/15/85	9:22:40	0000337	227.0	NORMAL
3/15/85	9:48:40	0000337	240.0	NORMAL
4/12/85	9:28:52	0000337	245.0	NORMAL
5/10/85	8:26:06	0000337	244.0	NORMAL
6/07/85	9:56:08	0000337	246.0	NORMAL
7/03/85	8:33:54	0000337	251.0	NORMAL
8/02/85	9:57:02	0034567	255.0	NORMAL
8/30/85	11:42:06	0000337	271.0	NORMAL
9/27/85	9:00:26	0000337	285.0	NORMAL
10/25/85	9:37:16	0072808	286.0	NORMAL
11/22/85	8:39:50	0000337	276.0	NORMAL
12/20/85	9:51:00	0000337	285.0	NORMAL
1/17/86	9:28:22	0000337	289.0	NORMAL
2/12/86	7:54:36	0034567	247.0	OPAQUE LENS LEFT EYE SLIGHT, EUTHANIZED
2/14/86	8:25:10	0000337		THIS ANIMAL TERM SACRIFICE 12 FEB 86 NOT REMOVED FROM CENSUS

## Appendix F (cont.): INDIVIDUAL ANIMAL HISTORIES

PAGE 89  
DATE: 6/09/87  
TIME: 14:40:13  
EDS017 V4M11

STUDY: 0083009  
COMPOUND: ISOBUTYL 2-CYANOACRYLATE  
START DATE: 1/28/85  
CARCINOGENICITY BIOASSAY OF ISOBUTYL 2-CYANO-  
ACRYLATE (IBC) IN MALE AND FEMALE RATS.

## ANIMAL HISTORY

DATE	TIME	OPERATOR	WEIGHT (GRAMS)	CLINICAL OBSERVATIONS
2/15/85	9:22:54	0000337	193.0	CONJUNCTIVITIS BOTH EYE MARKED
3/11/85	8:04:36	0000337		CONJUNCTIVITIS BOTH EYE MODERATE
3/15/85	9:49:04	0000337	200.0	CONJUNCTIVITIS BOTH EYE MODERATE
3/28/85	8:18:24	0000337		CONJUNCTIVITIS BOTH EYE MARKED, TACHYPNEA MODERATE
4/10/85	8:18:04	0072808		CONJUNCTIVITIS BOTH EYE MARKED
4/12/85	9:29:30	0000337	205.0	CONJUNCTIVITIS BOTH EYE MARKED
5/10/85	8:26:26	0000337	212.0	CONJUNCTIVITIS BOTH EYE MARKED
6/07/85	9:56:28	0000337	214.0	CONJUNCTIVITIS BOTH EYE MARKED
7/03/85	8:34:22	0000337	222.0	CONJUNCTIVITIS BOTH EYE MARKED
7/16/85	8:56:20	0010186		CONJUNCTIVITIS BOTH EYE MARKED
8/02/85	9:57:20	0034567	215.0	CONJUNCTIVITIS BOTH EYE MARKED
8/30/85	11:42:30	0000337	222.0	CONJUNCTIVITIS BOTH EYE MODERATE
9/27/85	9:00:44	0000337	233.0	CONJUNCTIVITIS RIGHT EYE MODERATE
10/25/85	9:37:46	0072808	227.0	CONJUNCTIVITIS BOTH EYE MARKED
11/22/85	8:40:04	0000337	225.0	INTRABDOMINAL MASS SPLENIC SIZE LARGE, PALLOR MODERATE
11/23/85	14:16:18	0000337		DEATH

**Appendix F (cont.): INDIVIDUAL ANIMAL HISTORIES**

STUDY: 0083009  
 COMPOUND: ISOBUTYL 2-CYANOACRYLATE  
 START DATE: 1/28/85  
 CARCINOGENICITY BIOASSAY OF ISOBUTYL 2-CYANO-  
 ACRYLATE (IBC) IN MALE AND FEMALE RATS.

**ANIMAL HISTORY**

Animal ID: 84D00367 Species: D Sex: FEMALE Group: 100 UL/ANM

DATE	TIME	OPERATOR	WEIGHT (GRAMS)	CLINICAL OBSERVATIONS
2/15/85	9:23:32	0000337	239.0	CONJUNCTIVITIS LEFT EYE SLIGHT
3/11/85	8:05:28	0000337		NORMAL
3/15/85	9:49:30	0000337	244.0	NORMAL
3/28/85	8:19:46	0000337		CONJUNCTIVITIS LEFT EYE MODERATE
4/10/85	8:19:54	0072808		CONJUNCTIVITIS LEFT EYE SLIGHT
4/12/85	9:30:18	0000337	254.0	NORMAL
5/10/85	8:26:52	0000337	260.0	CONJUNCTIVITIS LEFT EYE SLIGHT
5/21/85	7:34:30	0084799		CHROMODACRYORRHEA BOTH EYE MODERATE, STAIN YELLOW MOUTH SLIGHT, STAIN YELLOW PERIANAL SLIGHT
5/22/85	9:45:42	0000337		NORMAL
6/07/85	9:56:58	0000337	258.0	NORMAL
7/03/85	8:35:06	0000337	263.0	CONJUNCTIVITIS BOTH EYE SLIGHT
8/02/85	9:58:00	0034567	268.0	CONJUNCTIVITIS LEFT EYE SLIGHT
8/28/85	8:26:04	0000337		CONJUNCTIVITIS LEFT EYE MODERATE, CONJUNCTIVITIS RIGHT EYE SLIGHT
8/30/85	11:42:58	0000337	269.0	CONJUNCTIVITIS LEFT EYE SLIGHT
9/27/85	9:01:12	0000337	265.0	CONJUNCTIVITIS LEFT EYE MARKED
10/25/85	9:38:18	0072808	285.0	CONJUNCTIVITIS LEFT EYE SLIGHT
10/29/85	9:32:12	0002920		CONJUNCTIVITIS LEFT EYE MARKED
11/19/85	12:48:28	0000337		CONJUNCTIVITIS LEFT EYE MARKED, INTRAABDOMINAL MASS LOWER ABDOMEN SIZE LARGE

## Appendix F (cont.): INDIVIDUAL ANIMAL HISTORIES

PAGE 91  
DATE: 6/09/87  
TIME: 14:40:13  
EDS017 V4M11

STUDY: 0083009  
COMPOUND: ISOBUTYL 2-CYANOACRYLATE  
START DATE: 1/28/85

CARCINOGENICITY BIOASSAY OF ISOBUTYL 2-CYANO-  
ACRYLATE (IBC) IN MALE AND FEMALE RATS.

## ANIMAL HISTORY

Animal ID: 84D00368 Species: D Sex: FEMALE Group: CONTROLS

DATE	TIME	OPERATOR	WEIGHT (GRAMS)	CLINICAL OBSERVATIONS
2/15/85	9:23:56	0000337	257.0	NORMAL
2/27/85	8:38:08	0078478		STAIN YELLOW PERIANAL SLIGHT, VAGINAL DISCHARGE SLIGHT
3/01/85	8:12:56	0084799		STAIN YELLOW PERIANAL SLIGHT
3/11/85	8:06:52	0000337		NORMAL
3/15/85	9:51:44	0000337	269.0	NORMAL
4/12/85	9:31:14	0000337	284.0	NORMAL
5/10/85	8:27:18	0000337	298.0	NORMAL
6/07/85	9:57:12	0000337	304.0	NORMAL
7/03/85	8:35:52	0000337	309.0	NORMAL
8/02/85	9:59:16	0034567	310.0	NORMAL
8/30/85	11:43:16	0000337	289.0	NORMAL
9/27/85	9:01:34	0000337	298.0	NORMAL
10/08/85	10:18:02	0000337		BLEEDING PERIANAL MARKED

PAGE 920  
 DATE: 6/09/87  
 TIME: 14:40:13  
 EDS017 V4M11

**Appendix F (cont.): INDIVIDUAL ANIMAL HISTORIES**

STUDY: 0083009  
 COMPOUND: ISOBUTYL 2-CYANOACRYLATE  
 START DATE: 1/28/85  
 CARCINOGENICITY BIOASSAY OF ISOBUTYL 2-CYANO-  
 ACRYLATE (IBC) IN MALE AND FEMALE RATS.

ANIMAL HISTORY

Animal ID: 84D00369 Species: D Sex: FEMALE Group: CONTROLS

DATE	TIME	OPERATOR	WEIGHT (GRAMS)	CLINICAL OBSERVATIONS
2/15/85	9:24:14	0000337	187.0	NORMAL
3/15/85	9:53:00	0000337	189.0	NORMAL
4/12/85	9:31:36	0000337	198.0	NORMAL
5/10/85	8:27:40	0000337	240.0	NORMAL
6/07/85	9:57:34	0000337	196.0	NORMAL
7/03/85	8:36:26	0000337	201.0	NORMAL
8/02/85	9:59:40	0034567	197.0	NORMAL
8/30/85	11:43:34	0000337	204.0	NORMAL
9/27/85	9:01:54	0000337	206.0	NORMAL
10/25/85	9:38:58	0072808	216.0	NORMAL
11/22/85	8:42:10	0000337	219.0	NORMAL
12/20/85	9:51:18	0000337	214.0	NORMAL
1/17/86	9:28:58	0000337	215.0	NORMAL
2/12/86	7:56:44	0034567	203.0	NORMAL / EUTHANIZED



## Appendix F (cont.): INDIVIDUAL ANIMAL HISTORIES

STUDY: 0083009  
 COMPOUND: ISOBUTYL 2-CYANOACRYLATE  
 START DATE: 1/28/85

CARCINOGENICITY BIOASSAY OF ISOBUTYL 2-CYANO-  
 ACRYLATE (IBC) IN MALE AND FEMALE RATS.

PAGE 93  
 DATE: 6/09/87  
 TIME: 14:40:13  
 EDS017 VAM11

## ANIMAL HISTORY

Animal ID: 84D00371 Species: D Sex: FEMALE Group: CONTROLS

DATE	TIME	OPERATOR	WEIGHT (GRAMS)	CLINICAL OBSERVATIONS
2/15/85	9:24:30	0000337	222.0	CONJUNCTIVITIS BOTH EYE MODERATE
2/27/85	8:40:16	0078478		CONJUNCTIVITIS BOTH EYE MARKED
3/15/85	9:53:18	0000337	231.0	CONJUNCTIVITIS BOTH EYE MARKED
4/12/85	9:32:38	0000337	240.0	CONJUNCTIVITIS LEFT EYE MODERATE, CONJUNCTIVITIS RIGHT EYE SLIGHT
5/10/85	8:28:04	0000337	229.0	CONJUNCTIVITIS LEFT EYE MODERATE, CONJUNCTIVITIS RIGHT EYE SLIGHT
5/21/85	7:40:58	0000337		CONJUNCTIVITIS LEFT EYE MODERATE
6/07/85	9:58:36	0000337	257.0	CONJUNCTIVITIS LEFT EYE MODERATE, CONJUNCTIVITIS RIGHT EYE SLIGHT
7/03/85	8:36:52	0000337	263.0	CONJUNCTIVITIS LEFT EYE MARKED, CONJUNCTIVITIS RIGHT EYE SLIGHT
8/02/85	9:59:56	0034567	262.0	CONJUNCTIVITIS LEFT EYE MARKED, CONJUNCTIVITIS RIGHT EYE SLIGHT
8/30/85	11:44:00	0000337	260.0	NORMAL
9/27/85	9:02:12	0000337	271.0	NORMAL
10/25/85	9:39:20	0072808	278.0	CONJUNCTIVITIS BOTH EYE MODERATE
11/22/85	8:42:24	0000337	275.0	NORMAL
12/20/85	9:51:38	0000337	281.0	NORMAL
1/17/86	9:29:12	0000337	282.0	NORMAL
2/12/86	7:57:40	0034567	262.0	NORMAL / EUTHANIZED

PAGE 940  
DATE: 6/09/87  
TIME: 14:40:13  
EDS017 VAMLF

**Appendix F (cont.): INDIVIDUAL ANIMAL HISTORIES**

CARCINOGENICITY BIOASSAY OF ISOBUTYL 2-CYANO-  
ACRYLATE (IBC) IN MALE AND FEMALE RATS.

STUDY: 0083009  
COMPOUND: ISOBUTYL 2-CYANOACRYLATE  
START DATE: 1/28/85

Animal ID: 84D00373 Species: D Sex: FEMALE Group: 10 UL/ANN

ANIMAL HISTORY

DATE	TIME	OPERATOR	WEIGHT (GRAMS)	CLINICAL OBSERVATIONS
2/15/85	9:24:50	0000337	207.0	CORNEAL OPACITY RIGHT EYE SLIGHT
3/15/85	9:53:38	0000337	222.0	CORNEAL OPACITY RIGHT EYE SLIGHT
4/12/85	9:33:24	0000337	228.0	CORNEAL OPACITY RIGHT EYE SLIGHT
5/10/85	8:28:26	0000337	244.0	CORNEAL OPACITY RIGHT EYE SLIGHT
6/07/85	9:59:02	0000337	236.0	CORNEAL OPACITY RIGHT EYE SLIGHT
7/03/85	8:38:00	0000337	250.0	CORNEAL OPACITY RIGHT EYE SLIGHT
8/02/85	10:00:30	0034567	254.0	CORNEAL OPACITY RIGHT EYE SLIGHT
8/30/85	11:44:24	0000337	258.0	CORNEAL OPACITY RIGHT EYE SLIGHT
9/27/85	9:02:28	0000337	262.0	CORNEAL OPACITY RIGHT EYE SLIGHT
10/25/85	9:39:46	0072808	264.0	CORNEAL OPACITY RIGHT EYE SLIGHT
11/22/85	8:43:06	0000337	269.0	CORNEAL OPACITY RIGHT EYE SLIGHT
12/20/85	9:51:52	0000337	267.0	CORNEAL OPACITY RIGHT EYE SLIGHT
1/17/86	9:29:40	0000337	266.0	CORNEAL OPACITY RIGHT EYE SLIGHT
2/12/86	7:58:42	0034567	246.0	CORNEAL OPACITY RIGHT EYE SLIGHT, EUTHANIZED

PAGE 95  
 DATE: 6/09/87  
 TIME: 14:40:13  
 EDS017 VAM11

**Appendix F (cont.): INDIVIDUAL ANIMAL HISTORIES**

STUDY: 0083009  
 COMPOUND: ISOBUTYL 2-CYANOACRYLATE  
 START DATE: 1/28/85  
 CARCINOGENICITY BIOASSAY OF ISOBUTYL 2-CYANO-  
 ACRYLATE (IBC) IN MALE AND FEMALE RATS.

ANIMAL HISTORY

Animal ID: 84D00375 Species: D Sex: FEMALE Group: 100 UL/ANM

DATE	TIME	OPERATOR	WEIGHT (GRAMS)	CLINICAL OBSERVATIONS
2/15/85	9:25:14	0000337	221.0	CORNEAL OPACITY RIGHT EYE SLIGHT
3/15/85	9:53:58	0000337	225.0	CORNEAL OPACITY RIGHT EYE SLIGHT, CONJUNCTIVITIS LEFT EYE MODERATE
3/20/85	7:52:46	0000337		CORNEAL OPACITY RIGHT EYE SLIGHT, CONJUNCTIVITIS LEFT EYE SLIGHT
4/10/85	8:20:48	0072808		CORNEAL OPACITY RIGHT EYE SLIGHT
4/12/85	9:33:56	0000337	238.0	CORNEAL OPACITY RIGHT EYE SLIGHT, CONJUNCTIVITIS LEFT EYE SLIGHT
5/10/85	8:28:44	0000337	249.0	CORNEAL OPACITY RIGHT EYE SLIGHT, CONJUNCTIVITIS LEFT EYE SLIGHT
6/07/85	9:59:26	0000337	253.0	CORNEAL OPACITY RIGHT EYE SLIGHT
7/03/85	8:38:34	0000337	254.0	CORNEAL OPACITY RIGHT EYE SLIGHT
8/02/85	10:00:50	0034567	264.0	CORNEAL OPACITY RIGHT EYE SLIGHT
8/30/85	11:44:44	0000337	265.0	CORNEAL OPACITY RIGHT EYE SLIGHT
9/27/85	9:02:46	0000337	274.0	CORNEAL OPACITY RIGHT EYE SLIGHT, INTRAABDOMINAL MASS VENTRAL TO LIVER SIZE SMALL
10/25/85	9:40:14	0072808	280.0	CORNEAL OPACITY RIGHT EYE SLIGHT, INTRAABDOMINAL MASS VENTRAL TO LIVER SIZE SMALL
11/22/85	8:44:30	0000337	281.0	CORNEAL OPACITY RIGHT EYE SLIGHT, INTRAABDOMINAL MASS VENTRAL TO LIVER SIZE SMALL
12/20/85	9:52:12	0000337	281.0	CORNEAL OPACITY RIGHT EYE SLIGHT, CONJUNCTIVITIS BOTH EYE SLIGHT, INTRAABDOMINAL MASS VENTRAL TO LIVER SIZE MEDIUM
1/17/86	9:29:54	0000337	273.0	CORNEAL OPACITY RIGHT EYE SLIGHT, INTRAABDOMINAL MASS VENTRAL TT LIVER SIZE LARGE
2/12/86	8:00:30	0034567	243.0	CORNEAL OPACITY RIGHT EYE SLIGHT, CONJUNCTIVITIS LEFT EYE MODERATE, EUTHANIZED

STUDY: 0083009  
COMPOUND: ISOBUTYL 2-CYANOACRYLATE  
START DATE: 1/28/85

CARCINOGENICITY BIOASSAY OF ISOBUTYL 2-CYANO-  
ACRYLATE (IBC) IN MALE AND FEMALE RATS.

PAGE 96  
DATE: 6/09/87  
TIME: 14:40:13  
EDS017 V4M11

**Appendix F (cont.): INDIVIDUAL ANIMAL HISTORIES**

ANIMAL HISTORY

Animal ID: 84D00376 Species: D Sex: FEMALE Group: 100 UL/ANM

DATE	TIME	OPERATOR	WEIGHT (GRAMS)	CLINICAL OBSERVATIONS
2/13/85	7:54:20	0078478		DEATH

## Appendix F (cont.): INDIVIDUAL ANIMAL HISTORIES

PAGE 97  
DATE: 6/09/87  
TIME: 14:40:13  
EDS017 V4M11

STUDY: 0083009  
COMPOUND: ISOBUTYL 2-CYANOACRYLATE  
START DATE: 1/28/85

CARCINOGENICITY BIOASSAY OF ISOBUTYL 2-CYANO-  
ACRYLATE (IBC) IN MALE AND FEMALE RATS.

## ANIMAL HISTORY

Animal ID: 84D00378 Species: D Sex: FEMALE Group: CONTROLS

DATE	TIME	OPERATOR	WEIGHT (GRAMS)	CLINICAL OBSERVATIONS
2/15/85	9:25:34	0000337	213.0	CORNEAL OPACITY LEFT EYE SLIGHT
2/27/85	8:43:08	0078478		CORNEAL OPACITY LEFT EYE SLIGHT, CONJUNCTIVITIS LEFT EYE SLIGHT, TACHYPNEA SLIGHT
3/01/85	8:14:28	0000337		CORNEAL OPACITY LEFT EYE SLIGHT, CONJUNCTIVITIS LEFT EYE MODERATE
3/11/85	8:09:44	0000337		CORNEAL OPACITY LEFT EYE SLIGHT
3/15/85	9:54:28	0000337	228.0	CORNEAL OPACITY LEFT EYE SLIGHT
4/12/85	9:34:42	0000337	234.0	CORNEAL OPACITY LEFT EYE SLIGHT
5/10/85	8:29:10	0000337	233.0	CORNEAL OPACITY LEFT EYE SLIGHT, CONJUNCTIVITIS LEFT EYE SLIGHT
6/07/85	10:00:14	0000337	239.0	CORNEAL OPACITY LEFT EYE SLIGHT, CONJUNCTIVITIS BOTH EYE MODERATE
7/03/85	8:39:14	0000337	248.0	CORNEAL OPACITY LEFT EYE SLIGHT, CONJUNCTIVITIS BOTH EYE MODERATE
8/02/85	10:01:14	0034567	250.0	CORNEAL OPACITY LEFT EYE MARKED, TACHYPNEA SLIGHT
8/28/85	8:30:36	0000337		CONJUNCTIVITIS LEFT EYE MARKED
8/30/85	11:45:10	0000337	247.0	CONJUNCTIVITIS LEFT EYE MARKED
9/27/85	9:05:16	0000337	259.0	CONJUNCTIVITIS LEFT EYE SLIGHT
10/25/85	9:41:24	0072808	256.0	CONJUNCTIVITIS LEFT EYE MARKED
11/22/85	8:45:52	0000337	263.0	NORMAL
12/20/85	9:53:06	0000337	267.0	NORMAL
1/17/86	9:31:08	0000337	265.0	NORMAL
2/12/86	8:02:50	0034567	246.0	CONJUNCTIVITIS LEFT EYE MODERATE, EUTHANIZED

**Appendix F (cont.): INDIVIDUAL ANIMAL HISTORIES**

STUDY: 0083009  
COMPOUND: ISOBUTYL 2-CYANOACRYLATE  
START DATE: 1/28/85

CARCINOGENICITY BIOASSAY OF ISOBUTYL 2-CYANO-  
ACRYLATE (IBC) IN MALE AND FEMALE RATS.

ANIMAL HISTORY

Animal ID: 84D00380 Species: D Sex: FEMALE Group: 10 UL/ANM

DATE	TIME	OPERATOR	WEIGHT (GRAMS)	CLINICAL OBSERVATIONS
2/15/85	9:25:54	0000337	208.0	CORNEAL OPACITY LEFT EYE SLIGHT
2/27/85	8:44:26	0078478		CORNEAL OPACITY LEFT EYE SLIGHT, STAIN YELLOW PERIANAL SLIGHT
3/01/85	8:15:22	0000337		CORNEAL OPACITY LEFT EYE SLIGHT
3/15/85	9:54:48	0000337	211.0	CORNEAL OPACITY LEFT EYE SLIGHT
4/12/85	9:35:16	0000337	215.0	CORNEAL OPACITY LEFT EYE SLIGHT
5/10/85	8:29:38	0000337	217.0	CORNEAL OPACITY LEFT EYE SLIGHT
5/21/85	7:43:36	0000337		CORNEAL OPACITY LEFT EYE SLIGHT, CONJUNCTIVITIS BOTH EYE SLIGHT
6/07/85	10:00:58	0000337	220.0	CORNEAL OPACITY LEFT EYE SLIGHT
7/03/85	8:39:46	0000337	223.0	CORNEAL OPACITY LEFT EYE SLIGHT
8/02/85	10:01:56	0034567	230.0	CORNEAL OPACITY LEFT EYE SLIGHT
8/30/85	11:45:34	0000337	227.0	CORNEAL OPACITY LEFT EYE SLIGHT
9/27/85	9:05:40	0000337	243.0	CORNEAL OPACITY LEFT EYE SLIGHT
10/25/85	9:41:56	0072808	250.0	CORNEAL OPACITY LEFT EYE SLIGHT
11/22/85	8:46:46	0000337	257.0	CORNEAL OPACITY LEFT EYE SLIGHT
12/20/85	9:53:20	0000337	253.0	CORNEAL OPACITY LEFT EYE SLIGHT
1/17/86	9:31:20	0000337	260.0	CORNEAL OPACITY LEFT EYE SLIGHT
2/12/86	8:04:08	0034567	238.0	CORNEAL OPACITY LEFT EYE SLIGHT, EUTHANIZED

## Appendix F (cont.): INDIVIDUAL ANIMAL HISTORIES

PAGE 99  
DATE: 6/09/87  
TIME: 14:40:13  
EDS017 V4M11

STUDY: 0083009  
COMPOUND: ISOBUTYL 2-CYANOACRYLATE  
START DATE: 1/28/85  
CARCINOGENICITY BIOASSAY OF ISOBUTYL 2-CYANO-  
ACRYLATE (IBC) IN MALE AND FEMALE RATS.

## ANIMAL HISTORY

Animal ID: 84D00381 Species: D Sex: FEMALE Group: CONTROLS

DATE	TIME	OPERATOR	WEIGHT (GRAMS)	CLINICAL OBSERVATIONS
2/15/85	9:26:28	0000337	241.0	CORNEAL OPACITY LEFT EYE SLIGHT, CONJUNCTIVITIS BOTH EYE MODERATE
2/27/85	8:45:54	0078478		CORNEAL OPACITY LEFT EYE SLIGHT, CONJUNCTIVITIS RIGHT EYE MODERATE, CONJUNCTIVITIS LEFT EYE MARKED
3/15/85	9:55:10	0000337	249.0	CORNEAL OPACITY LEFT EYE SLIGHT, CONJUNCTIVITIS BOTH EYE MARKED
3/20/85	7:55:10	0000337		CORNEAL OPACITY LEFT EYE SLIGHT, CONJUNCTIVITIS LEFT EYE MARKED, CONJUNCTIVITIS RIGHT EYE SLIGHT
4/12/85	9:35:50	0000337	255.0	CORNEAL OPACITY LEFT EYE SLIGHT, CONJUNCTIVITIS LEFT EYE MARKED, CONJUNCTIVITIS RIGHT EYE SLIGHT
5/10/85	8:29:56	0000337	268.0	CORNEAL OPACITY BOTH EYE SLIGHT, CONJUNCTIVITIS LEFT EYE MARKED, CONJUNCTIVITIS RIGHT EYE SLIGHT
5/21/85	7:44:40	0000337		CORNEAL OPACITY BOTH EYE SLIGHT, CONJUNCTIVITIS LEFT EYE MARKED, CONJUNCTIVITIS RIGHT EYE MODERATE
5/30/85	7:22:22	0000337		CORNEAL OPACITY BOTH EYE SLIGHT, CONJUNCTIVITIS BOTH EYE MARKED
6/07/85	10:01:28	0000337	274.0	CORNEAL OPACITY BOTH EYE SLIGHT, CONJUNCTIVITIS BOTH EYE MARKED
7/03/85	8:40:18	0000337	278.0	CORNEAL OPACITY BOTH EYE SLIGHT, CONJUNCTIVITIS BOTH EYE MARKED
8/02/85	10:02:16	0034567	286.0	CORNEAL OPACITY BOTH EYE SLIGHT, CONJUNCTIVITIS BOTH EYE MARKED
8/30/85	11:45:50	0000337	282.0	CORNEAL OPACITY BOTH EYE SLIGHT, CONJUNCTIVITIS BOTH EYE MODERATE
9/27/85	9:05:58	0000337	293.0	CORNEAL OPACITY BOTH EYE SLIGHT, CONJUNCTIVITIS BOTH EYE MARKED
10/25/85	9:42:18	0072808	298.0	CORNEAL OPACITY BOTH EYE SLIGHT, CONJUNCTIVITIS BOTH EYE MARKED
11/22/85	8:47:02	0000337	303.0	CORNEAL OPACITY BOTH EYE SLIGHT, CONJUNCTIVITIS BOTH EYE MODERATE
12/20/85	9:53:40	0000337	308.0	CORNEAL OPACITY BOTH EYE SLIGHT, CONJUNCTIVITIS BOTH EYE MODERATE
1/17/86	9:31:36	0000337	298.0	CORNEAL OPACITY BOTH EYE SLIGHT, CONJUNCTIVITIS BOTH EYE MARKED
2/12/86	8:05:20	0034567	285.0	CORNEAL OPACITY BOTH EYE SLIGHT, CONJUNCTIVITIS BOTH EYE MARKED, EUTHANIZED

**Appendix F (cont.): INDIVIDUAL ANIMAL HISTORIES**

STUDY: 0083009 CARCINOGENICITY BIOASSAY OF ISOBUTYL 2-CYANO-  
 COMPOUND: ISOBUTYL 2-CYANOACRYLATE ACRYLATE (IBC) IN MALE AND FEMALE RATS.  
 START DATE: 1/28/85 ANIMAL HISTORY

Animal ID: 84D00383 Species: D Sex: FEMALE Group: 10 UL/ANM

DATE	TIME	OPERATOR	WEIGHT (GRAMS)	CLINICAL OBSERVATIONS
2/15/85	9:26:58	0000337	229.0	CORNEAL OPACITY RIGHT EYE MODERATE, CONJUNCTIVITIS BOTH EYE MARKED, INTERABDOMINAL MASS VENTRAL TO LIVER
2/28/85	8:22:48	0000337	232.0	CORNEAL OPACITY RIGHT EYE MODERATE, CONJUNCTIVITIS BOTH EYE MARKED, INTERABDOMINAL MASS VENTRAL TO LIVER
3/15/85	9:55:54	0000337	230.0	CORNEAL OPACITY RIGHT EYE MODERATE, CONJUNCTIVITIS BOTH EYE MARKED, INTRAABDOMINAL MASS VENTRAL TO LIVER, SIZE SMALL
4/03/85	9:31:44	0000337	238.0	CORNEAL OPACITY RIGHT EYE MODERATE, CONJUNCTIVITIS BOTH EYE MARKED, INTRAABDOMINAL MASS VENTRAL TO LIVER, SIZE SMALL
4/12/85	9:36:26	0000337	244.0	CONJUNCTIVITIS BOTH EYE MARKED, INTRAABDOMINAL MASS VENTRAL TO LIVER, SIZE SMALL
4/25/85	9:06:20	0084799	246.0	CONJUNCTIVITIS BOTH EYE MODERATE,
5/10/85	8:30:32	0000337	250.0	CONJUNCTIVITIS BOTH EYE MODERATE,
6/07/85	10:02:12	0000337	252.0	CONJUNCTIVITIS BOTH EYE MODERATE,
7/03/85	8:40:56	0084799	259.0	CONJUNCTIVITIS BOTH EYE MODERATE,
8/02/85	10:02:40	0034567	271.0	CONJUNCTIVITIS LEFT EYE, INTRAABDOMINAL MASS VENTRAL TO LIVER SIZE MEDIUM
8/15/85	7:34:46	0000337		CONJUNCTIVITIS BOTH EYE MARKED,
8/30/85	11:46:12	0000337	268.0	CONJUNCTIVITIS BOTH EYE MARKED,
9/27/85	9:06:20	0084799	273.0	CONJUNCTIVITIS BOTH EYE MARKED,
10/25/85	9:42:50	0072808	282.0	CONJUNCTIVITIS BOTH EYE MARKED,
10/29/85	9:36:50	0002920		CONJUNCTIVITIS RIGHT EYE SLIGHT,
11/22/85	8:47:24	0000337	293.0	CONJUNCTIVITIS BOTH EYE SLIGHT,
12/20/85	9:54:06	0000337	283.0	CONJUNCTIVITIS BOTH EYE SLIGHT,
1/17/86	9:32:00	0000337	286.0	CONJUNCTIVITIS BOTH EYE SLIGHT,
2/12/86	8:06:32	0034567	269.0	CONJUNCTIVITIS BOTH EYE MARKED, INTRAABDOMINAL MASS VENTRAL TO LIVER SIZE MEDIUM, EUTHANIZED



## Appendix F (cont.): INDIVIDUAL ANIMAL HISTORIES

PAGE 101  
DATE: 6/09/87  
TIME: 14:40:13  
EDS017 VAM11

STUDY: 0083009  
COMPOUND: ISOBUTYL 2-CYANOACRYLATE  
START DATE: 1/28/85

CARCINOGENICITY BIOASSAY OF ISOBUTYL 2-CYANO-  
ACRYLATE (IBC) IN MALE AND FEMALE RATS.

ANIMAL HISTORY

Animal ID: 84D00384 Species: D Sex: FEMALE Group: CONTROLS

DATE	TIME	OPERATOR	WEIGHT (GRAMS)	CLINICAL OBSERVATIONS
2/15/85	9:29:40	0000337	223.0	NORMAL
2/27/85	8:48:38	0078478		VAGINAL DISCHARGE SLIGHT
3/01/85	8:16:22	0000337		NORMAL
3/15/85	9:58:12	0000337	233.0	NORMAL
4/12/85	9:38:48	0000337	237.0	NORMAL
5/06/85	9:51:48	0000337		SCAB HEAD SLIGHT
5/10/85	8:34:38	0000337	240.0	SCAB HEAD SLIGHT
5/30/85	7:25:08	0000337		SCAB HEAD MARKED, SCAB NECK MARKED
5/31/85	8:48:58	0000337		SCAB HEAD MARKED, SCAB NECK MARKED

PAGE 102 0 t  
 DATE: 6/09/87  
 TIME: 14:40:13  
 EDS017 V4M11

**Appendix F (cont.): INDIVIDUAL ANIMAL HISTORIES**

CARCINOGENICITY BIOASSAY OF ISOBUTYL 2-CYANO-  
 ACRYLATE (IBC) IN MALE AND FEMALE RATS.

STUDY: 0083009  
 COMPOUND: ISOBUTYL 2-CYANOACRYLATE  
 START DATE: 1/28/85

ANIMAL HISTORY

Animal ID: 84D00386 Species: D Sex: FEMALE Group: 10 UL/ANM

DATE	TIME	OPERATOR	WEIGHT (GRAMS)	CLINICAL OBSERVATIONS
2/15/85	9:30:02	0000337	203.0	CORNEAL OPACITY BOTH EYE SLIGHT
3/15/85	10:00:20	0000337	205.0	CORNEAL OPACITY BOTH EYE SLIGHT
3/20/85	7:58:26	0000337		CORNEAL OPACITY BOTH EYE SLIGHT, STAIN BROWN NOSE SLIGHT
4/10/85	8:25:30	0072808		CORNEAL OPACITY BOTH EYE SLIGHT
4/12/85	9:39:32	0000337	212.0	CORNEAL OPACITY BOTH EYE SLIGHT
5/10/85	8:36:20	0000337	216.0	CORNEAL OPACITY BOTH EYE SLIGHT
6/07/85	10:03:36	0000337	221.0	CORNEAL OPACITY BOTH EYE SLIGHT
7/03/85	8:42:34	0000337	230.0	CORNEAL OPACITY BOTH EYE SLIGHT
8/02/85	10:07:16	0034567	231.0	CORNEAL OPACITY BOTH EYE SLIGHT
8/30/85	11:47:14	0000337	240.0	CORNEAL OPACITY BOTH EYE SLIGHT
9/27/85	9:07:38	0000337	251.0	CORNEAL OPACITY BOTH EYE SLIGHT
10/25/85	9:43:50	0072808	258.0	CORNEAL OPACITY BOTH EYE SLIGHT
11/22/85	8:48:34	0000337	251.0	CORNEAL OPACITY BOTH EYE SLIGHT
12/20/85	9:55:04	0000337	248.0	CORNEAL OPACITY BOTH EYE SLIGHT
1/17/86	9:32:38	0000337	242.0	CORNEAL OPACITY BOTH EYE SLIGHT
2/12/86	8:09:12	0034567	228.0	CORNEAL OPACITY BOTH EYE SLIGHT, EUTHANIZED



PAGE 103  
 DATE: 6/09/87  
 TIME: 14:40:13  
 EDS017 V4M11

**Appendix F (cont.): INDIVIDUAL ANIMAL HISTORIES**

STUDY: 0083009  
 COMPOUND: ISOBUTYL 2-CYANOACRYLATE  
 START DATE: 1/28/85  
 CARCINOGENICITY BIOASSAY OF ISOBUTYL 2-CYANO-  
 ACRYLATE (IBC) IN MALE AND FEMALE RATS.

**ANIMAL HISTORY**

Animal ID: 84D00387 Species: D Sex: FEMALE Group: CONTROLS

DATE	TIME	OPERATOR	WEIGHT (GRAMS)	CLINICAL OBSERVATIONS
2/15/85	9:30:24	0000337	203.0	NORMAL
2/27/85	8:50:34	0078478		CONJUNCTIVITIS LEFT EYE SLIGHT
3/11/85	8:14:52	0000337		NORMAL
3/15/85	10:00:46	0000337	207.0	NORMAL
4/12/85	9:40:12	0000337	211.0	CONJUNCTIVITIS LEFT EYE SLIGHT
5/10/85	8:36:36	0000337	220.0	NORMAL
5/30/85	7:27:54	0000337		CONJUNCTIVITIS LEFT EYE SLIGHT
6/07/85	10:04:02	0000337	226.0	NORMAL
7/03/85	8:43:14	0000337	232.0	* No observations recorded.
8/02/85	10:07:48	0034567	244.0	SUBCUTANEOUS MASS PERIVAGINAL SIZE MEDIUM, PERIVAGINAL FISTULE PURULENT DISCHARGE
8/28/85	8:34:46	0000337		FISTULA PERIVAGINAL PURULENT DISCHARGE
8/30/85	11:47:40	0000337		FISTULA PERIVAGINAL
9/27/85	9:07:56	0000337	246.0	FISTULA PERIVAGINAL PURULENT DISCHARGE
10/25/85	9:44:14	0084799	251.0	FISTULAE PERIVAGINAL PURULENT DISCHARGE
11/22/85	8:48:52	0000337	258.0	FISTULA PERIVAGINAL PURULENT DISCHARGE
12/20/85	9:55:16	0000337	262.0	FISTULAE PERIVAGINAL PURULENT DISCHARGE
12/28/85	11:13:40	0000337	255.0	PERIVAGINAL FISTULA
1/17/86	9:32:56	0000337	259.0	PERIVAGINAL FISTULA BLEEDING MODERATE
2/14/86	7:38:14	0000337	244.0	PERIVAGINAL FISTULA MODERATE
				CUTANEOUS MASS PERIVAGINAL FISTULATED SIZE MEDIUM, EUTHANIZED

**Appendix F (cont.): INDIVIDUAL ANIMAL HISTORIES**

STUDY: 0083009  
 COMPOUND: ISOBUTYL 2-CYANOACRYLATE  
 START DATE: 1/28/85  
 CARCINOGENICITY BIOASSAY OF ISOBUTYL 2-CYANO-  
 ACRYLATE (IBC) IN MALE AND FEMALE RATS.

**ANIMAL HISTORY**

Animal ID: 84D00388 Species: D Sex: FEMALE Group: CONTROLS

DATE	TIME	OPERATOR	WEIGHT (GRAMS)	CLINICAL OBSERVATIONS
2/15/85	9:30:40	0000337	236.0	NORMAL
3/15/85	10:01:12	0000337	238.0	NORMAL
4/12/85	9:40:44	0000337	252.0	NORMAL
5/10/85	8:37:12	0000337	250.0	NORMAL
6/07/85	10:04:30	0000337	260.0	NORMAL
7/03/85	8:46:32	0000337	270.0	STAIN BROWN NOSE SLIGHT
8/02/85	10:12:08	0084799	250.0	OCULAR PALLOR SLIGHT, INTRAABDOMINAL SPLEENIC MASS SIZE LARGE
8/02/85	10:47:46	0034567	248.0	* No observations recorded.

## Appendix F (cont.): INDIVIDUAL ANIMAL HISTORIES

PAGE 105  
DATE: 6/09/87  
TIME: 14:40:13  
EDS017 VAM11

STUDY: 0083009  
COMPOUND: ISOBUTYL 2-CYANOACRYLATE  
START DATE: 1/28/85  
CARCINOGENICITY BIOASSAY OF ISOBUTYL 2-CYANO-  
ACRYLATE (IBC) IN MALE AND FEMALE RATS.

## ANIMAL HISTORY

Animal ID: 84D00389 Species: D Sex: FEMALE Group: CONTROLS

DATE	TIME	OPERATOR	WEIGHT (GRAMS)	CLINICAL OBSERVATIONS
2/15/85	9:30:56	0000337	200.0	CORNEAL OPACITY LEFT EYE SLIGHT, CONJUNCTIVITIS BOTH EYE MARKED
2/27/85	8:52:04	0078478		CORNEAL OPACITY LEFT EYE SLIGHT, CONJUNCTIVITIS BOTH EYE MARKED, DEHYDRATED SLIGHT
3/01/85	8:17:52	0000337		CORNEAL OPACITY LEFT EYE SLIGHT, CONJUNCTIVITIS BOTH EYE MARKED, TACHYPNEA SLIGHT
3/11/85	8:15:10	0000337		CORNEAL OPACITY LEFT EYE SLIGHT, CONJUNCTIVITIS BOTH EYE MARKED, SCAB RIGHT EAR MODERATE
3/15/85	10:01:34	0000337	199.0	CORNEAL OPACITY LEFT EYE SLIGHT, CONJUNCTIVITIS BOTH EYE MARKED, SCAB RIGHT EAR MODERATE
4/12/85	9:41:22	0000337	205.0	CORNEAL OPACITY LEFT EYE SLIGHT, CONJUNCTIVITIS BOTH EYE MODERATE, SCAB RIGHT EAR MODERATE
5/10/85	8:37:24	0000337	208.0	CORNEAL OPACITY LEFT EYE SLIGHT, CONJUNCTIVITIS BOTH EYE MARKED, SCAB RIGHT EAR MODERATE
6/07/85	10:04:52	0000337	219.0	CORNEAL OPACITY LEFT EYE SLIGHT, CONJUNCTIVITIS BOTH EYE MARKED
7/03/85	8:47:20	0000337	222.0	CORNEAL OPACITY LEFT EYE SLIGHT, CONJUNCTIVITIS BOTH EYE MARKED
8/02/85	10:16:18	0034567	225.0	CORNEAL OPACITY LEFT EYE SLIGHT, CONJUNCTIVITIS BOTH EYE MARKED, ROUGH COAT MODERATE, TACHYPNEA SLIGHT, WHEEZING MODERATE
8/28/85	8:36:22	0000337		CORNEAL OPACITY LEFT EYE SLIGHT, CONJUNCTIVITIS BOTH EYE SLIGHT, ROUGH COAT MODERATE, TACHYPNEA SLIGHT, WHEEZING MODERATE
8/30/85	11:50:04	0000337	204.0	CORNEAL OPACITY LEFT EYE SLIGHT, CONJUNCTIVITIS BOTH EYE SLIGHT, ROUGH COAT MODERATE, TACHYPNEA SLIGHT, WHEEZING MODERATE
9/10/85	8:48:36	0084799		CORNEAL OPACITY LEFT EYE SLIGHT, ROUGH COAT MODERATE, TACHYPNEA SLIGHT, CARDIAC IRREGULARITY MODERATE
9/13/85	10:06:58	0002920		CORNEAL OPACITY LEFT EYE SLIGHT, ROUGH COAT MODERATE, TACHYPNEA SLIGHT, CARDIAC IRREGULARITY MODERATE

PAGE 1067  
 DATE: 6/09/87  
 TIME: 14:40:13  
 EDS017 V4M11.

**Appendix F (cont.): INDIVIDUAL ANIMAL HISTORIES**

STUDY: 0083009 ISOBUTYL 2-CYANOACRYLATE CARCINOGENICITY BIOASSAY OF ISOBUTYL 2-CYANO-  
 COMPOUND: ISOBUTYL 2-CYANOACRYLATE ACRYLATE (IBC) IN MALE AND FEMALE RATS.  
 START DATE: 1/28/85

ANIMAL HISTORY

Animal ID: 84D00390 Species: D Sex: FEMALE Group: CONTROLS

DATE	TIME	OPERATOR	WEIGHT (GRAMS)	CLINICAL OBSERVATIONS
2/15/85	9:31:14	0000337	234.0	CORNEAL OPACITY RIGHT EYE SLIGHT
3/15/85	10:05:14	0000337	250.0	CORNEAL OPACITY RIGHT EYE SLIGHT
4/12/85	9:43:30	0000337	255.0	CORNEAL OPACITY RIGHT EYE SLIGHT
5/10/85	8:38:50	0000337	252.0	CORNEAL OPACITY RIGHT EYE SLIGHT
6/07/85	10:05:38	0000337	267.0	CORNEAL OPACITY RIGHT EYE SLIGHT
7/03/85	8:47:58	0000337	269.0	CORNEAL OPACITY RIGHT EYE SLIGHT
8/02/85	10:16:42	0034567	272.0	CORNEAL OPACITY RIGHT EYE SLIGHT
8/30/85	11:51:46	0000337	273.0	CORNEAL OPACITY RIGHT EYE SLIGHT
9/27/85	9:10:16	0000337	273.0	CORNEAL OPACITY RIGHT EYE SLIGHT
10/25/85	9:46:50	0072808	266.0	CORNEAL OPACITY RIGHT EYE SLIGHT
10/29/85	9:42:14	0002920		CORNEAL OPACITY BOTH EYE SLIGHT
11/15/85	8:44:14	0000337		CORNEAL OPACITY BOTH EYE SLIGHT, ANOREXIC MARKED, ANEMIC MARKED

PAGE 107  
 DATE: 6/09/87  
 TIME: 14:40:13  
 EDS017 V4M11

**Appendix F (cont.): INDIVIDUAL ANIMAL HISTORIES**

STUDY: 0083009  
 COMPOUND: ISOBUTYL 2-CYANOACRYLATE  
 START DATE: 1/28/85

CARCINOGENICITY BIOASSAY OF ISOBUTYL 2-CYANO-  
 ACRYLATE (IBC) IN MALE AND FEMALE RATS.

ANIMAL HISTORY

Animal ID: 84D00391 Species: D Sex: FEMALE Group: CONTROLS

DATE	TIME	OPERATOR	WEIGHT (GRAMS)	CLINICAL OBSERVATIONS
2/15/85	9:31:36	0000337	228.0	CORNEAL OPACITY LEFT EYE SLIGHT
2/27/85	8:55:04	0078478		CORNEAL OPACITY LEFT EYE SLIGHT, WHEEZING SLIGHT
3/01/85	8:19:20	0000337		CORNEAL OPACITY LEFT EYE SLIGHT
3/15/85	10:03:34	0000337	237.0	CORNEAL OPACITY LEFT EYE SLIGHT
4/12/85	9:44:10	0000337	211.0	CORNEAL OPACITY LEFT EYE SLIGHT
5/10/85	8:39:14	0000337	238.0	CORNEAL OPACITY LEFT EYE SLIGHT
5/21/85	7:50:22	0000337		CORNEAL OPACITY LEFT EYE SLIGHT, CONJUNCTIVITIS LEFT EYE MODERATE
5/30/85	7:31:00	0000337		CORNEAL OPACITY LEFT EYE SLIGHT, CONJUNCTIVITIS LEFT EYE SLIGHT
6/07/85	10:06:06	0000337	263.0	CORNEAL OPACITY LEFT EYE SLIGHT
7/03/85	8:48:38	0000337	267.0	CORNEAL OPACITY LEFT EYE SLIGHT
8/02/85	10:19:08	0034567	274.0	CORNEAL OPACITY LEFT EYE SLIGHT
8/30/85	11:52:08	0000337	284.0	CORNEAL OPACITY LEFT EYE SLIGHT
9/27/85	9:10:32	0000337	293.0	CORNEAL OPACITY LEFT EYE SLIGHT
10/25/85	9:47:08	0072808	295.0	CORNEAL OPACITY LEFT EYE SLIGHT
11/22/85	8:50:30	0000337	292.0	CORNEAL OPACITY LEFT EYE SLIGHT, CONJUNCTIVITIS LEFT EYE SLIGHT
12/20/85	9:56:18	0000337	287.0	CORNEAL OPACITY LEFT EYE SLIGHT, CONJUNCTIVITIS LEFT EYE SLIGHT
1/17/86	9:34:04	0000337	277.0	CORNEAL OPACITY LEFT EYE SLIGHT, CONJUNCTIVITIS LEFT EYE MARKED
2/14/86	7:44:16	0000337	248.0	CORNEAL OPACITY LEFT EYE SLIGHT, CONJUNCTIVITIS LEFT EYE MARKED, EUTHANIZED

PAGE 108  
DATE: 6/09/87  
TIME: 14:40:13  
EDS017 V4M11.

### Appendix F (cont.): INDIVIDUAL ANIMAL HISTORIES

STUDY: 0083009 CARCINOGENICITY BIOASSAY OF ISOBUTYL 2-CYANO-  
COMPOUND: ISOBUTYL 2-CYANOACRYLATE ACRYLATE (IBC) IN MALE AND FEMALE RATS.  
START DATE: 1/28/85

#### ANIMAL HISTORY

Animal ID: 84D00392 Species: D Sex: FEMALE Group: 10 UL/ANM

DATE	TIME	OPERATOR	WEIGHT (GRAMS)	CLINICAL OBSERVATIONS
2/15/85	9:32:00	0000337	199.0	CORNEAL OPACITY LEFT EYE SLIGHT
3/15/85	10:06:00	0000337	205.0	CORNEAL OPACITY LEFT EYE SLIGHT
3/20/85	8:03:16	0000337		CORNEAL OPACITY LEFT EYE SLIGHT, STAIN YELLOW PERIANAL SLIGHT
4/10/85	8:29:06	0072808		CORNEAL OPACITY LEFT EYE SLIGHT
4/12/85	9:44:36	0000337	210.0	CORNEAL OPACITY LEFT EYE SLIGHT, STAIN YELLOW PERIANAL SLIGHT
5/10/85	8:39:30	0000337	220.0	CORNEAL OPACITY LEFT EYE SLIGHT
5/21/85	7:51:32	0000337		CORNEAL OPACITY LEFT EYE SLIGHT, INTRAABDOMINAL MASS VENTRAL TO LIVER SIZE SMALL
6/07/85	10:06:22	0000337	222.0	CORNEAL OPACITY LEFT EYE SLIGHT, INTRAABDOMINAL MASS VENTRAL TO LIVER SIZE SMALL
6/18/85	7:22:08	0000337		CORNEAL OPACITY LEFT SLIGHT, CONJUNCTIVITIS RIGHT EYE MODERATE, INTRAABDOMINAL MASS VENTRAL TO LIVER SIZE SMALL
7/03/85	8:49:04	0000337	228.0	CORNEAL OPACITY LEFT SLIGHT, INTRAABDOMINAL MASS VENTRAL TO LIVER SIZE SMALL
8/02/85	10:19:32	0084799	233.0	CORNEAL OPACITY LEFT EYE SLIGHT, INTRAABDOMINAL MASS VENTRAL TO LIVER SIZE SMALL
8/30/85	11:52:30	0000337	235.0	CORNEAL OPACITY LEFT EYE SLIGHT, INTRAABDOMINAL MASS VENTRAL TO LIVER SIZE SMALL
9/27/85	9:10:52	0000337	239.0	CORNEAL OPACITY LEFT EYE SLIGHT, INTRAABDOMINAL MASS VENTRAL TO LIVER SIZE SMALL
10/16/85	13:13:48	0000337		CORNEAL OPACITY LEFT EYE SLIGHT, INTRAABDOMINAL MASS VENTRAL TO LIVER SIZE MEDIUM
10/25/85	9:48:18	0072808	246.0	CORNEAL OPACITY LEFT EYE SLIGHT, INTRAABDOMINAL MASS VENTRAL TO LIVER SIZE SMALL
11/22/85	8:51:16	0000337	241.0	CORNEAL OPACITY LEFT EYE SLIGHT, INTRAABDOMINAL MASS VENTRAL TO LIVER SIZE SMALL
12/03/85	12:43:36	0000337		CORNEAL OPACITY LEFT EYE SLIGHT, INTRAABDOMINAL MASS VENTRAL TO LIVER SIZE SMALL, CORNEAL OPACITY LEFT EYE, STAIN BROWN PERIANAL MARKED, PALLOR MARKED, EMACIATED MARKED



**Appendix F (cont.): INDIVIDUAL ANIMAL HISTORIES**

PAGE 109  
 DATE: 6/09/87  
 TIME: 14:40:13  
 EDS017 V4M11

STUDY: 0083009 CARCINOGENICITY BIOASSAY OF ISOBUTYL 2-CYANO-  
 COMPOUND: ISOBUTYL 2-CYANOACRYLATE ACRYLATE (IBC) IN MALE AND FEMALE RATS.  
 START DATE: 1/28/85

ANIMAL HISTORY

Animal ID: 84D00393 Species: D Sex: FEMALE Group: 100 UL/ANM

DATE	TIME	WEIGHT OPERATOR (GRAMS)	CLINICAL OBSERVATIONS
2/15/85	10:37:30	244.0	CONJUNCTIVITIS BOTH EYE SLIGHT
3/11/85	8:18:38	0000337	CONJUNCTIVITIS BOTH EYE MODERATE, TACHYPNEA MODERATE
3/15/85	10:06:16	0000337	CONJUNCTIVITIS BOTH EYE MODERATE, TACHYPNEA MODERATE
4/12/85	9:45:36	0000337	CONJUNCTIVITIS BOTH EYE SLIGHT, TACHYPNEA SLIGHT
5/02/85	7:11:06	0000337	PURULENT VAGINAL DISCHARGE
5/07/85	9:09:24	0000337	NORMAL
5/10/85	8:40:06	0000337	NORMAL
5/21/85	7:54:24	0000337	CONJUNCTIVITIS RIGHT EYE MODERATE
6/07/85	10:07:28	0000337	CONJUNCTIVITIS RIGHT EYE SLIGHT
6/18/85	7:24:30	0000337	CONJUNCTIVITIS RIGHT EYE MODERATE, STAIN BROWN NOSE SLIGHT
7/03/85	8:50:22	0000337	NORMAL
8/02/85	10:20:34	0034567	NORMAL
8/28/85	8:41:00	0000337	CONJUNCTIVITIS RIGHT EYE MODERATE
8/30/85	11:54:02	0000337	CONJUNCTIVITIS RIGHT EYE MODERATE
9/27/85	9:11:44	0000337	CONJUNCTIVITIS RIGHT EYE MARKED
10/25/85	9:49:48	0072808	CONJUNCTIVITIS RIGHT EYE MARKED
11/22/85	8:52:52	0000337	CONJUNCTIVITIS RIGHT EYE SLIGHT
12/20/85	9:56:36	0000337	CONJUNCTIVITIS RIGHT EYE SLIGHT
1/17/86	9:34:24	0000337	CONJUNCTIVITIS RIGHT EYE MARKED
1/23/86	7:10:36	0000337	EMACIATED MODERATE, ROUGH COAT MARKED, CHROMODACRYORRHEA MARKED, STAIN YELLOW PERIANAL MODERATE

**Appendix F (cont.): INDIVIDUAL ANIMAL HISTORIES**

STUDY: 0083009  
 COMPOUND: ISOBUTYL 2-CYANOACRYLATE  
 START DATE: 1/28/85  
 CARCINOGENICITY BIOASSAY OF ISOBUTYL 2-CYANO-  
 ACRYLATE (IBC) IN MALE AND FEMALE RATS.

ANIMAL HISTORY

Animal ID: 84D00394 Species: D Sex: FEMALE Group: 100 UL/ANM

DATE	TIME	OPERATOR	WEIGHT (GRAMS)	CLINICAL OBSERVATIONS
2/15/85	10:37:54	0000337	222.0	CORNEAL OPACITY BOTH EYE SLIGHT
3/15/85	10:06:48	0000337	232.0	CORNEAL OPACITY BOTH EYE SLIGHT
4/12/85	9:46:40	0000337	242.0	CORNEAL OPACITY BOTH EYE SLIGHT
5/10/85	8:40:22	0000337	250.0	CORNEAL OPACITY BOTH EYE SLIGHT
6/07/85	10:07:50	0000337	261.0	CORNEAL OPACITY BOTH EYE SLIGHT
7/03/85	8:51:22	0000337	265.0	CORNEAL OPACITY BOTH EYE SLIGHT
8/02/85	10:20:54	0034567	260.0	CORNEAL OPACITY BOTH EYE SLIGHT
8/30/85	11:54:20	0000337	268.0	CORNEAL OPACITY BOTH EYE SLIGHT
9/27/85	9:12:02	0000337	275.0	CORNEAL OPACITY BOTH EYE SLIGHT
10/25/85	9:50:06	0072808	282.0	CORNEAL OPACITY BOTH EYE SLIGHT
11/22/85	8:53:14	0000337	274.0	CORNEAL OPACITY BOTH EYE SLIGHT
12/20/85	9:56:56	0000337	284.0	CORNEAL OPACITY BOTH EYE SLIGHT
1/17/86	9:34:46	0000337	281.0	CORNEAL OPACITY BOTH EYE SLIGHT
2/14/86	7:46:02	0000337	255.0	CORNEAL OPACITY BOTH EYE SLIGHT, EUTHANIZED

PAGE 111  
 DATE: 6/09/87  
 TIME: 14:40:13  
 EDS017 V4M11

**Appendix F (cont.): INDIVIDUAL ANIMAL HISTORIES**

STUDY: 0083009  
 COMPOUND: ISOBUTYL 2-CYANOACRYLATE  
 START DATE: 1/28/85  
 CARCINOGENICITY BIOASSAY OF ISOBUTYL 2-CYANO-  
 ACRYLATE (IBC) IN MALE AND FEMALE RATS.

ANIMAL HISTORY

Animal ID: 84D00395 Species: D Sex: FEMALE Group: CONTROLS

DATE	TIME	OPERATOR	WEIGHT (GRAMS)	CLINICAL OBSERVATIONS
2/15/85	10:38:16	0000337	249.0	CORNEAL OPACITY BOTH EYE SLIGHT
3/15/85	10:07:12	0000337	259.0	CORNEAL OPACITY BOTH EYE SLIGHT
4/12/85	9:47:42	0000337	263.0	CORNEAL OPACITY BOTH EYE SLIGHT
5/10/85	8:40:40	0000337	270.0	CORNEAL OPACITY BOTH EYE SLIGHT, CONJUNCTIVITIS RIGHT EYE SLIGHT
6/07/85	10:08:12	0000337	280.0	CORNEAL OPACITY BOTH EYE SLIGHT, CONJUNCTIVITIS RIGHT EYE SLIGHT
7/03/85	8:51:52	0000337	288.0	CORNEAL OPACITY BOTH EYE SLIGHT, CONJUNCTIVITIS RIGHT EYE SLIGHT
8/02/85	10:21:18	0034567	295.0	CORNEAL OPACITY BOTH EYE SLIGHT
8/30/85	11:54:48	0000337	299.0	CORNEAL OPACITY BOTH EYE SLIGHT
9/27/85	9:12:20	0000337	313.0	CORNEAL OPACITY BOTH EYE SLIGHT, CONJUNCTIVITIS RIGHT EYE MARKED
10/25/85	9:50:34	0072808	313.0	CORNEAL OPACITY BOTH EYE SLIGHT
11/22/85	8:53:28	0000337	315.0	CORNEAL OPACITY BOTH EYE SLIGHT
12/20/85	9:57:12	0000337	317.0	CORNEAL OPACITY BOTH EYE SLIGHT
1/17/86	9:35:36	0000337	311.0	CORNEAL OPACITY BOTH EYE SLIGHT, CONJUNCTIVITIS RIGHT EYE SLIGHT
2/14/86	7:47:28	0000337	284.0	CORNEAL OPACITY BOTH EYE SLIGHT, CONJUNCTIVITIS RIGHT EYE SLIGHT, EUTHANIZED

PAGE 112  
 DATE: 6/09/87  
 TIME: 14:40:13  
 EDS017 V4M11.

**Appendix F (cont.): INDIVIDUAL ANIMAL HISTORIES**

STUDY: 0083009  
 COMPOUND: ISOBUTYL 2-CYANOACRYLATE  
 START DATE: 1/28/85  
 CARCINOGENICITY BIOASSAY OF ISOBUTYL 2-CYANO-  
 ACRYLATE (IBC) IN MALE AND FEMALE RATS.

ANIMAL HISTORY

Animal ID: 84D00396 Species: D Sex: FEMALE Group: 100 UL/ANM

DATE	TIME	OPERATOR	WEIGHT (GRAMS)	CLINICAL OBSERVATIONS
2/15/85	10:38:34	0000337	209.0	NORMAL
3/15/85	10:07:50	0000337	221.0	CONJUNCTIVITIS LEFT EYE SLIGHT
3/20/85	8:07:02	0000337		NORMAL
4/12/85	9:48:36	0000337	228.0	NORMAL
5/10/85	8:41:08	0000337	229.0	CONJUNCTIVITIS LEFT EYE SLIGHT
6/07/85	10:09:08	0000337	238.0	CONJUNCTIVITIS LEFT EYE SLIGHT
7/03/85	8:52:32	0000337	252.0	CONJUNCTIVITIS BOTH EYE MODERATE
8/02/85	10:22:34	0034567	262.0	NORMAL
8/30/85	11:53:08	0000337	258.0	NORMAL
9/09/85	9:31:02	0000337		CONJUNCTIVITIS LEFT EYE MODERATE
9/27/85	9:12:58	0000337	263.0	CONJUNCTIVITIS LEFT EYE MODERATE
10/25/85	9:51:00	0072808	274.0	NORMAL
10/29/85	10:12:46	0002920		CONJUNCTIVITIS LEFT EYE MODERATE
11/22/85	8:55:10	0000337	277.0	NORMAL
12/20/85	9:57:44	0000337	279.0	NORMAL
1/17/86	9:36:08	0000337	280.0	CONJUNCTIVITIS LEFT EYE MARKED
2/14/86	7:48:46	0000337	250.0	CONJUNCTIVITIS LEFT EYE MARKED, EUTHANIZED

PAGE 113  
 DATE: 6/09/87  
 TIME: 14:40:13  
 EDS017 V4M11

**Appendix F (cont.): INDIVIDUAL ANIMAL HISTORIES**

STUDY: 0083009  
 COMPOUND: ISOBUTYL 2-CYANOACRYLATE  
 START DATE: 1/28/85  
 CARCINOGENICITY BIOASSAY OF ISOBUTYL 2-CYANO-  
 ACRYLATE (IBC) IN MALE AND FEMALE RATS.

ANIMAL HISTORY

Animal ID: 84D00397 Species: D Sex: FEMALE Group: CONTROLS

DATE	TIME	OPERATOR	WEIGHT (GRAMS)	CLINICAL OBSERVATIONS
2/15/85	10:39:30	0000337	240.0	CORNEAL OPACITY LEFT EYE SLIGHT
3/15/85	10:08:16	0000337	250.0	CORNEAL OPACITY LEFT EYE SLIGHT
4/12/85	9:49:04	0000337	265.0	CORNEAL OPACITY LEFT EYE SLIGHT
5/10/85	8:41:30	0000337	269.0	CORNEAL OPACITY LEFT EYE SLIGHT
6/07/85	10:09:28	0000337	270.0	CORNEAL OPACITY LEFT EYE SLIGHT
7/03/85	8:53:20	0000337	273.0	CORNEAL OPACITY LEFT EYE SLIGHT
8/02/85	10:23:02	0034567	279.0	CORNEAL OPACITY LEFT EYE SLIGHT
8/30/85	11:55:26	0000337	281.0	CORNEAL OPACITY LEFT EYE SLIGHT
9/27/85	9:13:16	0000337	281.0	CORNEAL OPACITY LEFT EYE SLIGHT
10/25/85	9:51:40	0072808	291.0	CORNEAL OPACITY LEFT EYE SLIGHT
11/22/85	8:55:32	0000337	281.0	CORNEAL OPACITY LEFT EYE SLIGHT
12/20/85	9:58:02	0000337	285.0	CORNEAL OPACITY LEFT EYE SLIGHT
1/17/86	9:36:28	0000337	259.0	CORNEAL OPACITY LEFT EYE SLIGHT, PALLOR MARKED, SPLENIC MASS SIZE LARGE

PAGE 114  
 DATE: 6/09/87  
 TIME: 14:40:13  
 EDS017 VAM11

**Appendix F (cont.): INDIVIDUAL ANIMAL HISTORIES**

STUDY: 0083009 ISOBUTYL 2-CYANOACRYLATE CARCINOGENICITY BIOASSAY OF ISOBUTYL 2-CYANO-  
 COMPOUND: ISOBUTYL 2-CYANOACRYLATE ACRYLATE (IBC) IN MALE AND FEMALE RATS.  
 START DATE: 1/28/85

ANIMAL HISTORY

Animal ID: 84D00398 Species: D Sex: FEMALE Group: 100 UL/ANN

DATE	TIME	OPERATOR	WEIGHT (GRAMS)	CLINICAL OBSERVATIONS
2/15/85	10:39:52	0000337	220.0	CORNEAL OPACITY RIGHT EYE SLIGHT
3/15/85	10:08:42	0000337	229.0	CORNEAL OPACITY RIGHT EYE SLIGHT
4/12/85	9:49:34	0000337	242.0	CORNEAL OPACITY RIGHT EYE SLIGHT
5/10/85	9:06:04	0000337	257.0	CORNEAL OPACITY RIGHT EYE SLIGHT
6/07/85	10:09:50	0000337	257.0	CORNEAL OPACITY RIGHT EYE SLIGHT
7/03/85	8:53:46	0000337	263.0	CORNEAL OPACITY RIGHT EYE SLIGHT, STAIN BROWN NOSE SLIGHT
8/02/85	10:23:20	0084799	268.0	CORNEAL OPACITY RIGHT EYE SLIGHT, OPAQUE LENS LEFT EYE MARKED, PROLAPSED LENS LEFT EYE MARKED
8/30/85	11:55:52	0000337	269.0	CORNEAL OPACITY RIGHT EYE SLIGHT, OPAQUE LENS LEFT EYE MARKED, PROLAPSED LENS LEFT EYE MARKED
9/27/85	9:13:36	0000337	279.0	CORNEAL OPACITY RIGHT EYE SLIGHT, OPAQUE LENS LEFT EYE MARKED, PROLAPSED LENS LEFT EYE MARKED
10/25/85	9:55:04	0072808	282.0	CORNEAL OPACITY RIGHT EYE SLIGHT, OPAQUE LENS LEFT EYE MARKED, PROLAPSED LENS LEFT EYE MARKED
11/22/85	8:55:46	0000337	290.0	CORNEAL OPACITY RIGHT EYE SLIGHT, OPAQUE LENS LEFT EYE MARKED, PROLAPSED LENS LEFT EYE MARKED,
12/20/85	9:58:22	0000337	296.0	INTRABDOMINAL MASS VENTRAL TO LIVER SIZE LARGE CORNEAL OPACITY RIGHT EYE SLIGHT, OPAQUE LENS LEFT EYE MARKED, INTRABDOMINAL MASS VENTRAL TO LIVER SIZE LARGE,
1/17/86	9:39:14	0000337	292.0	INGUINAL MASS LEFT SIDE SOFT SIZE MEDIUM CORNEAL OPACITY RIGHT EYE SLIGHT, OPAQUE LENS LEFT EYE MARKED, INTRABDOMINAL MASS VENTRAL TTTTIVER SIZE LARGE,
2/14/86	7:50:56	0000337	260.0	SUBCUTANEOUS MASS INGUINAL LEFT SIDE SOFT SIZE LARGE CORNEAL OPACITY RIGHT EYE SLIGHT, OPAQUE LENS LEFT EYE MARKED, INTRABDOMINAL MASS VENTRAL TO LIVER SIZE LARGE, SUBCUTANEOUS MASS LEFT INGUINAL AREA SIZE LARGE, EUTHANIZED

## Appendix F (cont.): INDIVIDUAL ANIMAL HISTORIES

PAGE 115  
DATE: 6/09/87  
TIME: 14:40:13  
EDS017 V4M11

STUDY: 0083009  
COMPOUND: ISOBUTYL 2-CYANOACRYLATE  
START DATE: 1/28/85

CARCINOGENICITY BIOASSAY OF ISOBUTYL 2-CYANO-  
ACRYLATE (IBC) IN MALE AND FEMALE RATS.

ANIMAL HISTORY

Animal ID: 84D00399 Species: D Sex: FEMALE Group: 10 UL/ANM

DATE	TIME	OPERATOR	WEIGHT (GRAMS)	CLINICAL OBSERVATIONS
2/15/85	10:40:30	0000337	247.0	CONJUNCTIVITIS BOTH EYE SLIGHT
3/11/85	8:23:50	0000337		CONJUNCTIVITIS RIGHT EYE MODERATE
3/15/85	10:08:56	0000337	259.0	CONJUNCTIVITIS RIGHT EYE MODERATE
3/20/85	8:09:42	0000337		CONJUNCTIVITIS BOTH EYE SLIGHT
4/12/85	9:50:02	0000337	268.0	CONJUNCTIVITIS RIGHT EYE SLIGHT
5/10/85	9:06:32	0000337	259.0	CONJUNCTIVITIS RIGHT EYE SLIGHT
5/21/85	8:06:30	0000337		CONJUNCTIVITIS RIGHT EYE MODERATE
5/30/85	7:38:18	0000337		NORMAL
6/07/85	10:10:16	0000337	282.0	CONJUNCTIVITIS BOTH EYE MODERATE
7/03/85	8:54:38	0000337	283.0	CONJUNCTIVITIS BOTH EYE SLIGHT
8/02/85	10:25:00	0034567	283.0	NORMAL
8/30/85	11:57:10	0000337	282.0	NORMAL
9/27/85	9:15:04	0000337	289.0	NORMAL
10/25/85	9:56:42	0072808	290.0	NORMAL
10/29/85	10:16:00	0002920		CONJUNCTIVITIS LEFT EYE MARKED
11/22/85	8:57:34	0000337	291.0	NORMAL
12/20/85	10:00:40	0000337	266.0	NORMAL
12/28/85	11:15:22	0000337		EMACIATED MARKED, PALLOR MARKED, ANOREXIA MARKED
12/29/85	9:16:40	0000337		EMACIATED MARKED, PALLOR MARKED, ANOREXIA MARKED

**Appendix F (cont.): INDIVIDUAL ANIMAL HISTORIES**

STUDY: 0083009 CARCINOGENICITY BIOASSAY OF ISOBUTYL 2-CYANO-  
 COMPOUND: ISOBUTYL 2-CYANOACRYLATE ACRYLATE (IBC) IN MALE AND FEMALE RATS.  
 START DATE: 1/28/85

ANIMAL HISTORY

Animal ID: 84D00400 Species: D Sex: FEMALE Group: 100 UL/ANM

DATE	TIME	OPERATOR	WEIGHT (GRAMS)	CLINICAL OBSERVATIONS
2/15/85	10:40:50	0000337	256.0	CORNEAL OPACITY BOTH EYE SLIGHT
2/27/85	9:00:42	0078478		CORNEAL OPACITY BOTH EYE SLIGHT, STAIN YELLOW PERIANGAL SLIGHT
3/11/85	8:52:20	0000337		CORNEAL OPACITY BOTH EYE SLIGHT
3/15/85	10:09:22	0000337	257.0	CORNEAL OPACITY BOTH EYE SLIGHT
4/12/85	9:50:38	0000337	238.0	CORNEAL OPACITY BOTH EYE SLIGHT
5/10/85	9:07:08	0000337	273.0	CORNEAL OPACITY BOTH EYE SLIGHT
6/07/85	10:10:52	0000337	283.0	CORNEAL OPACITY BOTH EYE SLIGHT
7/03/85	8:55:28	0000337	286.0	CORNEAL OPACITY BOTH EYE SLIGHT
8/02/85	10:26:10	0034567	295.0	CORNEAL OPACITY BOTH EYE SLIGHT
8/30/85	11:57:30	0000337	297.0	CORNEAL OPACITY BOTH EYE SLIGHT, INTRAABDOMINAL MASS VENTRAL TO LIVER SIZE MEDIUM
9/27/85	9:15:24	0000337	302.0	CORNEAL OPACITY BOTH EYE SLIGHT, INTRAABDOMINAL MASS VENTRAL TO LIVER SIZE MEDIUM
10/25/85	9:57:00	0072808	306.0	CORNEAL OPACITY BOTH EYE SLIGHT, INTRAABDOMINAL MASS VENTRAL TO LIVER SIZE MEDIUM
11/22/85	8:57:50	0000337	314.0	CORNEAL OPACITY BOTH EYE SLIGHT, INTRAABDOMINAL MASS VENTRAL TO LIVER SIZE LARGE
12/20/85	10:00:52	0000337	316.0	CORNEAL OPACITY BOTH EYE SLIGHT, INTRAABDOMINAL MASS VENTRAL TO LIVER SIZE LARGE
1/17/86	9:42:38	0000337	315.0	CORNEAL OPACITY BOTH EYE SLIGHT, INTRAABDOMINAL VENTRAL TO LIVER SIZE LARGE
2/14/86	7:55:04	0000337	293.0	CORNEAL OPACITY BOTH EYE SLIGHT, INTRAABDOMINAL MASS VENTRAL TO LIVER SIZE LARGE, EUTHANIZED



**Appendix F (cont.): INDIVIDUAL ANIMAL HISTORIES**

STUDY: 0083009  
 COMPOUND: ISOBUTYL 2-CYANOACRYLATE  
 START DATE: 1/28/85

CARCINOGENICITY BIOASSAY OF ISOBUTYL 2-CYANO-  
 ACRYLATE (IBC) IN MALE AND FEMALE RATS.

PAGE 117  
 DATE: 6/09/87  
 TIME: 14:40:13  
 EDS017 V4M11

ANIMAL HISTORY

Animal ID: 84D00401 Species: D Sex: FEMALE Group: 100 UL/ANM

DATE	TIME	OPERATOR	WEIGHT (GRAMS)	CLINICAL OBSERVATIONS
2/15/85	10:41:12	0000337	212.0	NORMAL
2/27/85	9:02:42	0078478		CONJUNCTIVITIS RIGHT EYE MODERATE, CONJUNCTIVITIS LEFT EYE SLIGHT
3/11/85	8:53:16	0000337		CONJUNCTIVITIS BOTH EYE SLIGHT
3/15/85	10:09:44	0000337	223.0	CONJUNCTIVITIS RIGHT EYE SLIGHT
4/12/85	9:51:06	0000337	231.0	CONJUNCTIVITIS BOTH EYE SLIGHT
5/10/85	9:07:24	0000337	238.0	CONJUNCTIVITIS RIGHT EYE MODERATE, CONJUNCTIVITIS LEFT EYE SLIGHT
5/21/85	8:08:54	0000337		CONJUNCTIVITIS BOTH EYE MODERATE, INTRAABDOMINAL MASS VENTRAL TO LIVER SIZE MEDIUM
6/07/85	10:11:18	0000337	247.0	CONJUNCTIVITIS BOTH EYE MODERATE, INTRAABDOMINAL MASS VENTRAL TO LIVER SIZE MEDIUM
6/18/85	7:28:38	0000337		CONJUNCTIVITIS RIGHT EYE MARKED, CONJUNCTIVITIS LEFT EYE MODERATE, STAIN BROWN
7/03/85	8:55:56	0084799	248.0	NOSE SLIGHT, INTRAABDOMINAL MASS VENTRAL TO LIVER SIZE MEDIUM
8/02/85	10:26:32	0034567	253.0	CONJUNCTIVITIS BOTH EYE MARKED, INTRAABDOMINAL MASS VENTRAL TO LIVER SIZE MEDIUM
8/30/85	11:58:42	0000337	252.0	CONJUNCTIVITIS BOTH EYE MARKED, INTRAABDOMINAL MASS VENTRAL TO LIVER SIZE SMALL
9/27/85	9:16:22	0000337	263.0	CONJUNCTIVITIS BOTH EYE MARKED, INTRAABDOMINAL MASS VENTRAL TO LIVER SIZE MEDIUM
10/25/85	9:58:12	0072808	264.0	CONJUNCTIVITIS RIGHT EYE MARKED, INTRAABDOMINAL MASS VENTRAL TO LIVER SIZE MEDIUM
10/29/85	10:17:14	0002920		STAIN URINE PERIANAL MODERATE, CONJUNCTIVITIS RIGHT EYE MARKED
11/22/85	8:58:52	0000337	263.0	INTRAABDOMINAL MASS VENTRAL TO LIVER SIZE MEDIUM
12/20/85	10:01:36	0084799	266.0	CONJUNCTIVITIS BOTH EYE MARKED, STAIN YELLOW PERIANAL MODERATE, INTRAABDOMINAL MASS VENTRAL TO LIVER SIZE MEDIUM
1/17/86	9:43:46	0000337	268.0	CONJUNCTIVITIS RIGHT EYE MARKED, INTRAABDOMINAL MASS VENTRAL TO LIVER SIZE MEDIUM
2/14/86	7:58:40	0000337	247.0	CONJUNCTIVITIS BOTH EYE MARKED, INTRAABDOMINAL MASS VENTRAL TO LIVER SIZE MEDIUM, EUTHANIZED

PAGE 118<sup>0</sup>  
 DATE: 6/09/87  
 TIME: 14:40:13  
 EDS017 V4M11

**Appendix F (cont.): INDIVIDUAL ANIMAL HISTORIES.**

STUDY: 0083009  
 COMPOUND: ISOBUTYL 2-CYANOACRYLATE  
 START DATE: 1/28/85

Animal ID: 84D00403 Species: D Sex: FEMALE Group: CONTROLS

ANIMAL HISTORY

DATE	TIME	OPERATOR	WEIGHT (GRAMS)	CLINICAL OBSERVATIONS
2/15/85	10:41:26	0000337	209.0	NORMAL
2/27/85	9:03:38	0078478		CONJUNCTIVITIS LEFT EYE SLIGHT
3/15/85	10:10:24	0000337	220.0	NORMAL
3/20/85	8:12:54	0000337		CONJUNCTIVITIS LEFT EYE SLIGHT
4/12/85	9:51:52	0000337	218.0	NORMAL
5/10/85	07:52	0000337	225.0	NORMAL
5/21/85	8:12:32	0000337		CONJUNCTIVITIS BOTH EYE MODERATE
6/07/85	10:13:14	0000337	232.0	CONJUNCTIVITIS BOTH EYE SLIGHT
7/03/85	9:35:10	0000337	236.0	CONJUNCTIVITIS BOTH EYE SLIGHT
8/02/85	10:28:18	0034567	252.0	CONJUNCTIVITIS BOTH EYE SLIGHT
8/30/85	11:59:50	0000337	262.0	CONJUNCTIVITIS BOTH EYE SLIGHT
9/09/85	9:36:38	0000337		NORMAL
9/27/85	9:18:04	0000337	263.0	CONJUNCTIVITIS BOTH EYE SLIGHT
10/25/85	9:59:34	0072808	265.0	CONJUNCTIVITIS BOTH EYE SLIGHT
11/22/85	9:00:36	0000337	278.0	NORMAL
12/20/85	10:03:04	0000337	272.0	CONJUNCTIVITIS RIGHT EYE MARKED
1/17/86	9:44:42	0000337	238.0	NORMAL
2/10/86	9:30:52	0000337	209.0	EMACIATED MODERATE, CONJUNCTIVITIS BOTH EYE MARKED, EUTHANIZED

**Appendix F (cont.): INDIVIDUAL ANIMAL HISTORIES**

PAGE 119  
 DATE: 6/09/87  
 TIME: 14:40:13  
 EDS017 V4M11

STUDY: 0083009  
 COMPOUND: ISOBUTYL 2-CYANOACRYLATE  
 START DATE: 1/28/85

CARCINOGENICITY BIOASSAY OF ISOBUTYL 2-CYANO-  
 ACRYLATE (IBC) IN MALE AND FEMALE RATS.

ANIMAL HISTORY

Animal ID: 84D00404 Species: D Sex: FEMALE Group: CONTROLS

DATE	TIME	OPERATOR	WEIGHT (GRAMS)	CLINICAL OBSERVATIONS
2/15/85	10:41:46	0000337	219.0	CORNEAL OPACITY BOTH EYE SLIGHT, CONJUNCTIVITIS BOTH EYE MARKED
2/27/85	9:06:56	0078478		CORNEAL OPACITY BOTH EYE SLIGHT, CONJUNCTIVITIS BOTH EYE MARKED, TACHYPNEA SLIGHT
3/11/85	8:55:02	0000337		CORNEAL OPACITY BOTH EYE SLIGHT, CONJUNCTIVITIS BOTH EYE MARKED
3/15/85	10:11:02	0000337	240.0	CORNEAL OPACITY BOTH EYE SLIGHT, CONJUNCTIVITIS BOTH EYE MARKED
4/12/85	9:52:30	0000337	234.0	CORNEAL OPACITY BOTH EYE SLIGHT, CONJUNCTIVITIS BOTH EYE MARKED
5/10/85	9:08:12	0000337	255.0	CORNEAL OPACITY BOTH EYE SLIGHT, CONJUNCTIVITIS BOTH EYE MARKED
5/30/85	7:42:34	0000337		CORNEAL OPACITY BOTH EYE SLIGHT, CONJUNCTIVITIS BOTH EYE MODERATE
6/07/85	10:13:36	0000337	280.0	CORNEAL OPACITY BOTH EYE SLIGHT, CONJUNCTIVITIS BOTH EYE MODERATE
7/03/85	9:35:40	0000337	261.0	CORNEAL OPACITY BOTH EYE SLIGHT
8/02/85	10:29:02	0034567	279.0	CORNEAL OPACITY BOTH EYE SLIGHT
8/28/85	8:48:52	0000337		CORNEAL OPACITY BOTH EYE SLIGHT, CONJUNCTIVITIS BOTH EYE MODERATE
8/30/85	12:00:24	0000337	270.0	CORNEAL OPACITY BOTH EYE SLIGHT
9/23/85	8:36:04	0000337		* No observations recorded.

**Appendix F (cont.): INDIVIDUAL ANIMAL HISTORIES**

STUDY: 0083009  
 COMPOUND: ISOBUTYL 2-CYANOACRYLATE  
 START DATE: 1/28/85  
 CARCINOGENICITY BIOASSAY OF ISOBUTYL 2-CYANO-  
 ACRYLATE (IBC) IN MALE AND FEMALE RATS.

**ANIMAL HISTORY**

Animal ID: 84D00406 Species: D Sex: FEMALE Group: 10 UL/ANM

DATE	TIME	OPERATOR	WEIGHT (GRAMS)	CLINICAL OBSERVATIONS
2/15/85	10:42:08	0000337	224.0	CORNEAL OPACITY RIGHT EYE SLIGHT
3/15/85	10:11:24	0000337	234.0	CORNEAL OPACITY RIGHT EYE SLIGHT
4/12/85	9:53:00	0000337	242.0	CORNEAL OPACITY BOTH EYE SLIGHT
5/10/85	9:08:46	0000337	246.0	CORNEAL OPACITY BOTH EYE SLIGHT, VAGINAL DISCHARGE BLOODY SLIGHT
5/30/85	7:43:24	0000337		CORNEAL OPACITY BOTH EYE SLIGHT
6/07/85	10:13:58	0000337	250.0	CORNEAL OPACITY BOTH EYE SLIGHT
7/03/85	9:36:16	0000337	255.0	CORNEAL OPACITY BOTH EYE SLIGHT, CONJUNCTIVITIS BOTH EYE SLIGHT
8/02/85	10:29:46	0034567	263.0	CORNEAL OPACITY BOTH EYE SLIGHT
8/30/85	12:01:14	0000337	259.0	CORNEAL OPACITY BOTH EYE SLIGHT
9/27/85	9:18:32	0000337	274.0	CORNEAL OPACITY BOTH EYE SLIGHT
10/25/85	10:00:26	0072808	273.0	CORNEAL OPACITY BOTH EYE SLIGHT
11/22/85	9:01:14	0000337	283.0	CORNEAL OPACITY BOTH EYE SLIGHT
12/20/85	10:03:30	0000337	280.0	CORNEAL OPACITY BOTH EYE SLIGHT
1/17/86	9:45:14	0000337	279.0	CORNEAL OPACITY BOTH EYE SLIGHT
2/14/86	8:00:56	0000337	263.0	CORNEAL OPACITY BOTH EYE SLIGHT, EUTHANIZED

## Appendix F (cont.): INDIVIDUAL ANIMAL HISTORIES

PAGE 121  
DATE: 6/09/87  
TIME: 14:40:13  
EDS017 V4M11

STUDY: 0083009  
COMPOUND: ISOBUTYL 2-CYANOACRYLATE  
START DATE: 1/28/85

CARCINOGENICITY BIOASSAY OF ISOBUTYL 2-CYANO-  
ACRYLATE (IBC) IN MALE AND FEMALE RATS.

## ANIMAL HISTORY

Animal ID: 84D00407 Species: D Sex: FEMALE Group: 10 UL/ANM

DATE	TIME	OPERATOR	WEIGHT (GRAMS)	CLINICAL OBSERVATIONS
2/15/85	10:42:34	0000337	253.0	CONJUNCTIVITIS LEFT EYE SLIGHT
2/27/85	9:08:26	0078478		CONJUNCTIVITIS BOTH EYE SLIGHT
3/15/85	10:11:48	0000337	262.0	NORMAL
4/12/85	9:53:48	0000337	274.0	NORMAL
5/10/85	9:09:56	0000337	284.0	NORMAL
6/07/85	10:14:14	0000337	297.0	SUBCUTANEOUS MASS LEFT THORAX SIZE LARGE
7/03/85	9:37:18	0000337	303.0	SUBCUTANEOUS MASS LEFT THORAX SIZE LARGE
8/02/85	10:30:08	0084799	312.0	SUBCUTANEOUS MASS LEFT THORAX SIZE LARGE
8/16/85	7:42:36	0000337		* No observations recorded.

PAGE 1227  
 DATE: 6/09/87  
 TIME: 14:40:13  
 EDS017 V4M11.1

**Appendix F (cont.): INDIVIDUAL ANIMAL HISTORIES**

STUDY: 0083009  
 COMPOUND: ISOBUTYL 2-CYANOACRYLATE  
 START DATE: 1/28/85  
 CARCINOGENICITY BIOASSAY OF ISOBUTYL 2-CYANO-  
 ACRYLATE (IBC) IN MALE AND FEMALE RATS.

ANIMAL HISTORY

Animal ID: 84D00409 Species: D Sex: FEMALE Group: CONTROLS

DATE	TIME	OPERATOR	WEIGHT (GRAMS)	CLINICAL OBSERVATIONS
2/15/85	10:42:54	0000337	219.0	CORNEAL OPACITY BOTH EYE SLIGHT, CONJUNCTIVITIS BOTH EYE SLIGHT
3/11/85	8:56:42	0000337		CORNEAL OPACITY BOTH EYE SLIGHT
3/15/85	10:13:06	0000337	230.0	CORNEAL OPACITY BOTH EYE SLIGHT
3/20/85	8:15:20	0000337		CORNEAL OPACITY BOTH EYE SLIGHT, CONJUNCTIVITIS BOTH EYE SLIGHT
4/12/85	9:54:12	0000337	233.0	CORNEAL OPACITY LEFT EYE SLIGHT, CONJUNCTIVITIS BOTH EYE SLIGHT
5/10/85	9:10:08	0000337	238.0	CORNEAL OPACITY LEFT EYE SLIGHT
5/30/85	7:45:04	0000337		CORNEAL OPACITY LEFT EYE SLIGHT, CONJUNCTIVITIS BOTH EYE MODERATE
6/07/85	10:16:52	0000337	244.0	CORNEAL OPACITY LEFT EYE SLIGHT, CONJUNCTIVITIS BOTH EYE MODERATE
7/03/85	9:39:10	0000337	249.0	CORNEAL OPACITY LEFT EYE SLIGHT, CONJUNCTIVITIS BOTH EYE MODERATE
8/02/85	10:31:44	0034567	262.0	CORNEAL OPACITY LEFT EYE SLIGHT
8/30/85	12:01:40	0000337	259.0	CORNEAL OPACITY RIGHT EYE SLIGHT
9/09/85	9:39:00	0000337		CORNEAL OPACITY RIGHT EYE SLIGHT, CONJUNCTIVITIS BOTH EYE SLIGHT
9/27/85	9:18:58	0000337	269.0	CORNEAL OPACITY RIGHT EYE SLIGHT, CONJUNCTIVITIS BOTH EYE SLIGHT
10/25/85	10:00:48	0072808	264.0	CORNEAL OPACITY RIGHT EYE SLIGHT, CONJUNCTIVITIS BOTH EYE SLIGHT
11/22/85	9:01:30	0000337	268.0	CORNEAL OPACITY RIGHT EYE SLIGHT
12/20/85	10:03:42	0000337	271.0	CORNEAL OPACITY RIGHT EYE SLIGHT
1/17/86	9:45:28	0000337	271.0	CORNEAL OPACITY RIGHT EYE SLIGHT
2/14/86	8:02:48	0000337	247.0	CORNEAL OPACITY RIGHT EYE SLIGHT, CONJUNCTIVITIS RIGHT EYE SLIGHT, EUTHANIZED

PAGE 123  
 DATE: 6/09/87  
 TIME: 14:40:13  
 EDS017 V4M11

**Appendix F (cont.): INDIVIDUAL ANIMAL HISTORIES**

STUDY: 0083009  
 COMPOUND: ISOBUTYL 2-CYANOACRYLATE  
 START DATE: 1/28/85

CARCINOGENICITY BIOASSAY OF ISOBUTYL 2-CYANO-  
 ACRYLATE (IBC) IN MALE AND FEMALE RATS.

ANIMAL HISTORY

Animal ID: 84D00410 Species: D Sex: FEMALE Group: CONTROLS

DATE	TIME	OPERATOR	WEIGHT (GRAMS)	CLINICAL OBSERVATIONS
2/15/85	10:43:14	0000337	212.0	CORNEAL OPACITY RIGHT EYE SLIGHT
3/15/85	10:13:32	0000337	220.0	CORNEAL OPACITY RIGHT EYE SLIGHT
4/12/85	9:55:02	0000337	220.0	CORNEAL OPACITY RIGHT EYE SLIGHT
5/10/85	9:10:32	0000337	236.0	CORNEAL OPACITY RIGHT EYE SLIGHT
6/07/85	10:17:20	0000337	238.0	CORNEAL OPACITY RIGHT EYE SLIGHT
7/03/85	9:39:38	0000337	251.0	CORNEAL OPACITY RIGHT EYE SLIGHT
8/02/85	10:32:40	0034567	251.0	CORNEAL OPACITY RIGHT EYE SLIGHT
8/30/85	12:02:46	0000337	249.0	CORNEAL OPACITY RIGHT EYE SLIGHT
9/27/85	9:19:16	0000337	257.0	CORNEAL OPACITY RIGHT EYE SLIGHT
10/25/85	10:01:12	0072808	260.0	CORNEAL OPACITY RIGHT EYE SLIGHT
11/22/85	9:01:50	0000337	263.0	CORNEAL OPACITY RIGHT EYE SLIGHT
12/20/85	10:03:56	0000337	268.0	CORNEAL OPACITY RIGHT EYE SLIGHT
1/17/86	9:45:44	0000337	270.0	CORNEAL OPACITY RIGHT EYE SLIGHT
2/14/86	8:04:08	0000337	252.0	CORNEAL OPACITY RIGHT EYE SLIGHT, EUTHANIZED

## Appendix F (cont.): INDIVIDUAL ANIMAL HISTORIES

STUDY: 0083009 ISOBUTYL 2-CYANOACRYLATE CARCINOGENICITY BIOASSAY OF ISOBUTYL 2-CYANO-  
COMPOUND: ISOBUTYL 2-CYANOACRYLATE ACRYLATE (IBC) IN MALE AND FEMALE RATS.  
START DATE: 1/28/85

## ANIMAL HISTORY

Animal ID: 84D00411 Species: D Sex: FEMALE Group: 100 UL/ANM

DATE	TIME	OPERATOR	WEIGHT (GRAMS)	CLINICAL OBSERVATIONS
2/15/85	10:43:34	0000337	249.0	NORMAL.
3/15/85	10:14:04	0000337	267.0	NORMAL
4/12/85	9:55:38	0000337	277.0	NORMAL
5/10/85	9:10:52	0000337	285.0	NORMAL
5/21/85	8:17:14	0000337	282.0	INTRAABDOMINAL MASS VENTRAL TO LIVER SIZE MEDIUM
6/07/85	10:17:46	0000337	282.0	INTRAABDOMINAL MASS VENTRAL TO LIVER SIZE MEDIUM
6/18/85	7:34:56	0000337	284.0	INTRAABDOMINAL MASS VENTRAL TO LIVER SIZE MEDIUM, PERITONEAL FISTULA
7/03/85	9:40:08	0000337	284.0	INTRAABDOMINAL MASS VENTRAL TO LIVER SIZE MEDIUM, PERITONEAL FISTULE
8/02/85	10:33:06	0084799	289.0	INTRAABDOMINAL MASS VENTRAL TO LIVER SIZE SMALL, PERIVAGINAL GLAND FISTULA VENTRAL ABDOMEN SIZE LARGE
8/30/85	12:03:10	0000337	288.0	INTRAABDOMINAL MASS VENTRAL TO LIVER SIZE MEDIUM, PERIVAGINAL FISTULA SMALL
9/27/85	9:19:44	0000337	289.0	INTRAABDOMINAL MASS VENTRAL TO LIVER SIZE MEDIUM, PERIVAGINAL FISTULA SMALL
10/25/85	10:01:38	0072808	292.0	INTRAABDOMINAL MASS VENTRAL TO LIVER SIZE SMALL, PERIVAGINAL FISUTULA SIZE SMALL
11/22/85	9:02:06	0000337	297.0	INTRAABDOMINAL MASS VENTRAL TO LIVER SIZE SMALL, PERIVAGINAL FISTULA SIZE SMALL
12/20/85	10:04:08	0084799	295.0	INTRAABDOMINAL MASS VENTRAL TO LIVER SIZE SMALL
1/17/86	9:46:00	0000337	294.0	SUBSCAPULAR MASS LEFT SIDE SMALL, PERIVAGINAL FISTULA SMALL INTRAABDOMINAL MASS VENTRAL TO LIVER SIZE SMALL, SUBSCAPULAR MASS LEFT SIDE SMALL, INGUINAL MASS LEFT SIDE SIZE SMALL
2/14/86	8:06:34	0000337	271.0	SUBCUTANEOUS MASS LEFT THORAX SIZE SMALL, INTRAABDOMINAL MASS VENTRAL TO LIVER SIZE SMALL, CUTANEOUS MASS FISTULATED PERIVAGINAL SIZE MEDIUM, EUTHANIZED



PAGE 125  
 DATE: 6/09/87  
 TIME: 14:40:13  
 EDS017 V4M11

**Appendix F (cont.): INDIVIDUAL ANIMAL HISTORIES**

STUDY: 0083009 CARCINOGENICITY BIOASSAY OF ISOBUTYL 2-CYANO-  
 COMPOUND: ISOBUTYL 2-CYANOACRYLATE ACRYLATE (IBC) IN MALE AND FEMALE RATS.  
 START DATE: 1/28/85

ANIMAL HISTORY

Animal ID: 84D00412 Species: D Sex: FEMALE Group: 100 UL/ANM

DATE	TIME	OPERATOR	WEIGHT (GRAMS)	CLINICAL OBSERVATIONS
2/15/85	10:44:00	0000337	228.0	CORNEAL OPACITY RIGHT EYE MARKED, EXOPHTHALMOS RIGHT EYE MARKED, CORNEAL OPACITY LEFT EYE MODERATE
3/15/85	10:14:18	0000337	229.0	CORNEAL OPACITY RIGHT EYE MARKED, EXOPHTHALMOS RIGHT EYE MARKED, CORNEAL OPACITY LEFT EYE MODERATE
4/12/85	9:56:16	0000337	241.0	CORNEAL OPACITY RIGHT EYE MARKED, EXOPHTHALMOS RIGHT EYE MARKED, CORNEAL OPACITY LEFT EYE MODERATE, CONJUNCTIVITIS LEFT EYE SLIGHT
5/10/85	9:11:12	0000337	245.0	CORNEAL OPACITY RIGHT EYE MARKED, EXOPHTHALMOS RIGHT EYE MARKED, CORNEAL OPACITY LEFT EYE MODERATE, CONJUNCTIVITIS LEFT EYE MODERATE
6/07/85	10:18:52	0000337	258.0	CORNEAL OPACITY RIGHT EYE MARKED, EXOPHTHALMOS RIGHT EYE MARKED, CORNEAL OPACITY LEFT EYE MODERATE
7/03/85	9:41:46	0000337	259.0	CORNEAL OPACITY RIGHT EYE MARKED, EXOPHTHALMOS RIGHT EYE MARKED, CORNEAL OPACITY LEFT EYE MODERATE
8/02/85	10:37:08	0034567	271.0	CORNEAL OPACITY RIGHT EYE MARKED, EXOPHTHALMOS RIGHT EYE MARKED, CORNEAL OPACITY LEFT EYE MODERATE
8/30/85	12:06:36	0000337	276.0	CORNEAL OPACITY RIGHT EYE MARKED, EXOPHTHALMOS RIGHT EYE MARKED, CORNEAL OPACITY LEFT EYE MODERATE
9/27/85	9:22:28	0000337	293.0	CORNEAL OPACITY RIGHT EYE MARKED, EXOPHTHALMOS RIGHT EYE MARKED, CORNEAL OPACITY LEFT EYE MODERATE
10/25/85	10:04:18	0072808	287.0	CORNEAL OPACITY RIGHT EYE MARKED, EXOPHTHALMOS RIGHT EYE MARKED, CORNEAL OPACITY LEFT EYE MODERATE
11/22/85	9:03:44	0000337	271.0	CORNEAL OPACITY RIGHT EYE MARKED, EXOPHTHALMOS RIGHT EYE MARKED, CORNEAL OPACITY LEFT EYE MODERATE
12/20/85	10:07:16	0000337	277.0	CORNEAL OPACITY RIGHT EYE MARKED, EXOPHTHALMOS RIGHT EYE MARKED, CORNEAL OPACITY LEFT EYE MODERATE,
1/17/86	9:48:42	0000337	254.0	INTRABDOMINAL MASS VENTRAL TO LIVER SIZE LARGE
1/21/86	9:52:44	0000337		OPAQUE LENS BOTH EYES MODERATE, INTRABDOMINAL MASS VENTRAL TO LIVER SIZE LARGE DEATH

PAGE 126  
 DATE: 6/09/87  
 TIME: 14:40:13  
 EDS017 VM11.

**Appendix F (cont.): INDIVIDUAL ANIMAL HISTORIES**

CARCINOGENICITY BIOASSAY OF ISOBUTYL 2-CYANO-  
 ACRYLATE (IBC) IN MALE AND FEMALE RATS.

**ANIMAL HISTORY**

STUDY: 0083009  
 COMPOUND: ISOBUTYL 2-CYANOACRYLATE  
 START DATE: 1/28/85

Animal ID: 84D00413 Species: D Sex: FEMALE Group: 100 UL/ANM

DATE	TIME	OPERATOR	WEIGHT (GRAMS)	CLINICAL OBSERVATIONS
2/15/85	10:44:20	0000337	232.0	CORNEAL OPACITY LEFT EYE SLIGHT
3/15/85	10:14:42	0000337	251.0	CORNEAL OPACITY LEFT EYE SLIGHT
4/12/85	9:57:24	0000337	261.0	CORNEAL OPACITY LEFT EYE SLIGHT
5/10/85	9:11:48	0000337	264.0	CORNEAL OPACITY LEFT EYE SLIGHT
6/07/85	10:19:24	0000337	267.0	CORNEAL OPACITY LEFT EYE SLIGHT
7/03/85	9:42:36	0000337	273.0	CORNEAL OPACITY LEFT EYE SLIGHT
8/02/85	10:37:36	0034567	276.0	CORNEAL OPACITY LEFT EYE SLIGHT
8/30/85	12:07:02	0000337	283.0	CORNEAL OPACITY LEFT EYE SLIGHT
9/09/85	9:42:10	0084799	287.0	CORNEAL OPACITY LEFT EYE SLIGHT, PERIVAGINAL FISTULA SIZE SMALL
9/27/85	9:24:00	0000337	288.0	CORNEAL OPACITY LEFT EYE SLIGHT, PERIVAGINAL FISTULA SMALL
10/25/85	10:04:48	0072808	288.0	CORNEAL OPACITY LEFT EYE SLIGHT, PERIVAGINAL FISTULA SMALL
11/22/85	9:04:06	0000337	280.0	CORNEAL OPACITY LEFT EYE SLIGHT, PERIVAGINAL FISTULA SMALL, INTRAABDOMINAL MASS VENTRAL TO LIVER SIZE SMALL
12/20/85	10:08:26	0000337	276.0	CORNEAL OPACITY LEFT EYE SLIGHT, INTRAABDOMINAL MASS VENTRAL TO LIVER SIZE MEDIUM, PERIVAGINAL FISTULA SMALL
1/03/86	10:25:42	0000337		CORNEAL OPACITY LEFT EYE SLIGHT, PERIVAGINAL MASS SIZE MEDIUM, INTRAABDOMINAL MASS VENTRAL TO LIVER SIZE MEDIUM
1/16/86	12:52:46	0000337		CORNEAL OPACITY LEFT EYE SLIGHT, PERIVAGINAL MASS SUPURATING SIZE LARGE, INTRAABDOMINAL MASS VENTRAL TO LIVER SIZE MEDIUM

**Appendix F (cont.): INDIVIDUAL ANIMAL HISTORIES**

PAGE 127  
 DATE: 6/09/87  
 TIME: 14:40:13  
 EDS017 V4M11

STUDY: 0083009  
 COMPOUND: ISOBUTYL 2-CYANOACRYLATE  
 START DATE: 1/28/85  
 CARCINOGENICITY BIORASSAY OF ISOBUTYL 2-CYANO-  
 ACRYLATE (IBC) IN MALE AND FEMALE RATS.

ANIMAL HISTORY

Animal ID: 84D00414 Species: D Sex: FEMALE Group: CONTROLS

DATE	TIME	OPERATOR	WEIGHT (GRAMS)	CLINICAL OBSERVATIONS
2/15/85	10:44:36	0000337	227.0	CORNEAL OPACITY RIGHT EYE SLIGHT
3/15/85	10:15:04	0000337	242.0	CORNEAL OPACITY RIGHT EYE SLIGHT
4/10/85	8:35:34	0072808		CORNEAL OPACITY RIGHT EYE SLIGHT
4/12/85	9:58:00	0000337	252.0	CORNEAL OPACITY RIGHT EYE SLIGHT
5/10/85	9:12:26	0000337	252.0	CORNEAL OPACITY RIGHT EYE SLIGHT
6/07/85	10:19:42	0000337	259.0	CORNEAL OPACITY RIGHT EYE SLIGHT
7/03/85	9:43:04	0000337	264.0	CORNEAL OPACITY RIGHT EYE SLIGHT
8/02/85	10:37:58	0034567	273.0	CORNEAL OPACITY RIGHT EYE SLIGHT
8/28/85	8:53:46	0000337		CORNEAL OPACITY RIGHT EYE SLIGHT, SUBCUTANEOUS MASS RIGHT THORAX SIZE MEDIUM
8/30/85	12:07:32	0084799	272.0	CORNEAL OPACITY RIGHT EYE SLIGHT, SUBCUTANEOUS MASS RIGHT THORAX SIZE MEDIUM
9/27/85	9:25:00	0000337	275.0	CORNEAL OPACITY RIGHT EYE SLIGHT, SUBCUTANEOUS MASS RIGHT THORAX SIZE LARGE
10/25/85	10:05:40	0072808	281.0	CORNEAL OPACITY RIGHT EYE SLIGHT, SUBCUTANEOUS MASS RIGHT THORAX SIZE LARGE
11/19/85	12:54:56	0000337		SUBCUTANEOUS MASS RIGHT SIDE THORAX SIZE LARGE CORNEAL OPACITY RIGHT EYE SLIGHT, SUBCUTANEOUS MASS RIGHT SIDE THORAX SIZE LARGE

PAGE 128  
 DATE: 6/09/87  
 TIME: 14:40:13M  
 EDS017 V4M11

**Appendix F (cont.): INDIVIDUAL ANIMAL HISTORIES**

STUDY: 0083009  
 COMPOUND: ISOBUTYL 2-CYANOACRYLATE  
 START DATE: 1/28/85

Animal ID: 84D00415 Species: D Sex: FEMALE Group: 10 UL/ANM

**ANIMAL HISTORY**

CARCINOGENICITY BIOASSAY OF ISOBUTYL 2-CYANO-  
 ACRYLATE (IBC) IN MALE AND FEMALE RATS.

DATE	TIME	OPERATOR	WEIGHT (GRAMS)	CLINICAL OBSERVATIONS
2/15/85	10:44:56	0000337	236.0	CONJUNCTIVITIS RIGHT EYE MARKED
3/11/85	8:59:34	0000337		CONJUNCTIVITIS RIGHT EYE MODERATE
3/15/85	10:15:24	0000337	239.0	CONJUNCTIVITIS BOTH EYE SLIGHT
4/12/85	9:58:28	0000337	244.0	CONJUNCTIVITIS RIGHT EYE MODERATE
5/10/85	9:12:42	0000337	244.0	CONJUNCTIVITIS RIGHT EYE MARKED
5/21/85	8:21:18	0084799		CONJUNCTIVITIS BOTH EYE MARKED
5/21/85	8:23:00	0000337		CONJUNCTIVITIS BOTH EYE MARKED
5/30/85	7:50:24	0000337	254.0	CONJUNCTIVITIS RIGHT EYE MARKED, CONJUNCTIVITIS LEFT EYE MODERATE
6/07/85	10:20:02	0000337		NORMAL
6/18/85	8:29:30	0000337		CONJUNCTIVITIS BOTH EYE MODERATE
7/03/85	9:43:34	0000337	254.0	CONJUNCTIVITIS BOTH EYE MODERATE
7/16/85	9:12:12	0010186		PALLOR HEAD TAIL FRONT LEG HIND LEG MARKED
7/17/85	8:05:12	0010186		* No observations recorded.

**Appendix F (cont.): INDIVIDUAL ANIMAL HISTORIES**

PAGE 129  
 DATE: 6/09/87  
 TIME: 14:40:13  
 EDS017 V4M11

STUDY: 0083009  
 COMPOUND: ISOBUTYL 2-CYANOACRYLATE  
 START DATE: 1/28/85  
 CARCINOGENICITY BIOASSAY OF ISOBUTYL 2-CYANO-  
 ACRYLATE (IBC) IN MALE AND FEMALE RATS.

ANIMAL HISTORY

Animal ID: 84D00416 Species: D Sex: FEMALE Group: 100 UL/ANN

DATE	TIME	OPERATOR	WEIGHT (GRAMS)	CLINICAL OBSERVATIONS
2/15/85	10:45:12	0000337	220.0	CORNEAL OPACITY LEFT EYE SLIGHT
3/15/85	10:15:48	0000337	224.0	CORNEAL OPACITY LEFT EYE SLIGHT
4/12/85	9:59:44	0000337	226.0	CORNEAL OPACITY LEFT EYE SLIGHT
5/10/85	9:13:00	0000337	231.0	CORNEAL OPACITY LEFT EYE SLIGHT
6/07/85	10:20:32	0000337	229.0	CORNEAL OPACITY LEFT EYE SLIGHT
7/03/85	9:44:02	0000337	243.0	CORNEAL OPACITY LEFT EYE SLIGHT
8/02/85	10:38:26	0034567	247.0	CORNEAL OPACITY LEFT EYE SLIGHT
8/30/85	12:09:00	0000337	248.0	CORNEAL OPACITY LEFT EYE SLIGHT
9/27/85	9:26:32	0000337	256.0	CORNEAL OPACITY LEFT EYE SLIGHT
10/16/85	13:23:42	0000337		CORNEAL OPACITY LEFT EYE SLIGHT, INTRAABDOMINAL MASS VENTRAL TO LIVER SIZE MEDIUM
10/25/85	10:07:16	0072808	248.0	CORNEAL OPACITY LEFT EYE SLIGHT, INTRAABDOMINAL M.SS VENTRAL TO LIVER SIZE LARGE
11/05/85	12:12:48	0000337		CORNEAL OPACITY LEFT EYE SLIGHT, INTRAABDOMINAL MASS VENTRAL TO LIVER SIZE LARGE, STAIN YELLOW PERIANAL MODERATE

**Appendix F (cont.): INDIVIDUAL ANIMAL HISTORIES**

STUDY: 0083009 CARCINOGENICITY BIOASSAY OF ISOBUTYL 2-CYANO-  
 COMPOUND: ISOBUTYL 2-CYANOACRYLATE ACRYLATE (IBC) IN MALE AND FEMALE RATS.  
 START DATE: 1/28/85

ANIMAL HISTORY

Animal ID: 84D00417 Species: D Sex: FEMALE Group: 100 UL/ANM

DATE	TIME	OPERATOR	WEIGHT (GRAMS)	CLINICAL OBSERVATIONS
2/15/85	10:45:34	0000337	247.0	CORNEAL OPACITY LEFT EYE SLIGHT
3/15/85	10:16:18	0000337	253.0	CORNEAL OPACITY LEFT EYE SLIGHT
4/12/85	10:00:24	0000337	263.0	CORNEAL OPACITY LEFT EYE SLIGHT
5/10/85	9:13:22	0000337	266.0	CORNEAL OPACITY LEFT EYE SLIGHT
5/21/85	8:24:30	0084799		CORNEAL OPACITY LEFT EYE SLIGHT, INTRAABDOMINAL MASS VENTRAL TO LIVER SIZE LARGE
6/05/85	9:29:36	0084799		INTRAABDOMINAL MASS VENTRAL TO LIVER SIZE LARGE, CORNEAL OPACITY LEFT EYE SLIGHT
6/07/85	10:20:54	0000337	271.0	CORNEAL OPACITY LEFT EYE SLIGHT, INTRAABDOMINAL MASS VENTRAL TO LIVER SIZE LARGE
7/03/85	9:44:36	0084799	280.0	CORNEAL OPACITY LEFT EYE SLIGHT, INTRAABDOMINAL MASS VENTRAL TO LIVER SIZE LARGE
8/02/85	10:38:56	0034567	279.0	CORNEAL OPACITY LEFT EYE MODERATE, INTRAABDOMINAL MASS VENTRAL TO LIVER SIZE SMALL
8/30/85	12:09:38	0000337	281.0	CORNEAL OPACITY LEFT EYE MODERATE, INTRAABDOMINAL MASS VENTRAL TO LIVER SIZE SMALL
9/27/85	9:26:52	0000337	292.0	CORNEAL OPACITY LEFT EYE MODERATE, INTRAABDOMINAL MASS VENTRAL TO LIVER SIZE SMALL
10/16/85	13:41:16	0000337		CORNEAL OPACITY LEFT EYE MODERATE, INTRAABDOMINAL MASS VENTRAL TO LIVER SIZE LARGE
10/25/85	10:08:06	0072808	296.0	CORNEAL OPACITY LEFT EYE MODERATE, INTRAABDOMINAL MASS VENTRAL TO LIVER SIZE LARGE
11/22/85	9:07:02	0000337	275.0	CORNEAL OPACITY LEFT EYE MODERATE, INTRAABDOMINAL MASS SIZE LARGE
12/20/85	10:09:52	0000337	272.0	CORNEAL OPACITY LEFT EYE MODERATE
1/17/86	9:50:44	0000337	270.0	CORNEAL OPACITY LEFT EYE MODERATE, SPLENIC MASS SIZE MEDIUM
2/14/86	8:11:00	0000337	258.0	CORNEAL OPACITY LEFT EYE MODERATE, INTRAABDOMINAL MASS VENTRAL TO LIVER SIZE SMALL, EUTHANIZED

**Appendix F (cont.): INDIVIDUAL ANIMAL HISTORIES**

PAGE 131  
 DATE: 6/09/87  
 TIME: 14:40:13  
 EDS017 V4M11

STUDY: 0083009  
 COMPOUND: ISOBUTYL 2-CYANOACRYLATE  
 START DATE: 1/28/85  
 CARCINOGENICITY BIASSAY OF ISOBUTYL 2-CYANO-  
 ACRYLATE (IBC) IN MALE AND FEMALE RATS.

ANIMAL HISTORY

Animal ID: 84D00418 Species: D Sex: FEMALE Group: 10 UL/ANM

DATE	TIME	OPERATOR	WEIGHT (GRAMS)	CLINICAL OBSERVATIONS
2/15/85	10:45:48	0000337	218.0	CORNEAL OPACITY LEFT EYE SLIGHT
3/15/85	10:16:36	0000337	227.0	CORNEAL OPACITY LEFT EYE SLIGHT
4/12/85	10:00:44	0000337	244.0	CORNEAL OPACITY LEFT EYE SLIGHT
5/10/85	9:13:38	0000337	234.0	CORNEAL OPACITY LEFT EYE SLIGHT
6/07/85	10:22:18	0000337	245.0	CORNEAL OPACITY LEFT EYE SLIGHT
7/03/85	9:45:50	0000337	254.0	CORNEAL OPACITY LEFT EYE SLIGHT
8/02/85	10:40:16	0034567	259.0	CORNEAL OPACITY LEFT EYE SLIGHT
8/30/85	12:10:22	0000337	262.0	CORNEAL OPACITY LEFT EYE SLIGHT
9/27/85	9:28:00	0000337	274.0	CORNEAL OPACITY LEFT EYE SLIGHT
10/25/85	10:09:46	0072808	271.0	CORNEAL OPACITY LEFT EYE SLIGHT
11/22/85	9:08:30	0000337	270.0	CORNEAL OPACITY LEFT EYE SLIGHT
12/20/85	10:10:58	0000337	280.0	CORNEAL OPACITY LEFT EYE SLIGHT, INTRAABDOMINAL MASS VENTRAL TO LIVER SIZE MEDIUM
1/17/86	9:51:46	0000337	255.0	CORNEAL OPACITY LEFT EYE SLIGHT, INTRAABDOMINAL MASS VENTRAL TO LIVER SIZE MEDIUM, SPLENIC MASS SIZE LARGE
1/17/86	12:31:24	0000337		* No observations recorded.

**Appendix F (cont.): INDIVIDUAL ANIMAL HISTORIES**

STUDY: 0083009  
 COMPOUND: ISOBUTYL 2-CYANOACRYLATE  
 START DATE: 1/28/85  
 CARCINOGENICITY BIOASSAY OF ISOBUTYL 2-CYANO-  
 ACRYLATE (IBC) IN MALE AND FEMALE RATS.

ANIMAL HISTORY

Animal ID: 84D00419 Species: D Sex: FEMALE Group: 100 UL/ANM

DATE	TIME	OPERATOR	WEIGHT (GRAMS)	CLINICAL OBSERVATIONS
2/15/85	10:46:10	0000337	217.0	CORNEAL OPACITY RIGHT EYE SLIGHT, CONJUNCTIVITIS RIGHT EYE MARKED
3/11/85	9:02:00	0000337		CORNEAL OPACITY RIGHT EYE SLIGHT, CONJUNCTIVITIS RIGHT EYE MARKED, STAIN CLEAR PERIANAL SLIGHT
3/15/85	10:16:56	0000337	226.0	CORNEAL OPACITY RIGHT EYE SLIGHT, CONJUNCTIVITIS RIGHT EYE MARKED
4/12/85	10:01:20	0000337	231.0	CORNEAL OPACITY RIGHT EYE SLIGHT, CONJUNCTIVITIS RIGHT EYE MARKED
5/10/85	9:13:58	0000337	237.0	CORNEAL OPACITY RIGHT EYE SLIGHT, CONJUNCTIVITIS RIGHT EYE MARKED
6/07/85	10:23:48	0000337	245.0	CORNEAL OPACITY RIGHT EYE SLIGHT, CONJUNCTIVITIS RIGHT EYE MARKED
7/03/85	9:46:14	0000337	252.0	CORNEAL OPACITY RIGHT EYE SLIGHT, CONJUNCTIVITIS RIGHT EYE MARKED
8/02/85	10:40:38	0034567	261.0	CORNEAL OPACITY RIGHT EYE SLIGHT, CONJUNCTIVITIS RIGHT EYE MARKED
8/30/85	12:10:46	0000337	264.0	CORNEAL OPACITY RIGHT EYE SLIGHT, CONJUNCTIVITIS RIGHT EYE MARKED
9/09/85	9:46:46	0000337		CORNEAL OPACITY RIGHT EYE SLIGHT
9/27/85	9:28:12	0000337	271.0	CORNEAL OPACITY RIGHT EYE SLIGHT
10/25/85	10:10:20	0072808	276.0	CORNEAL OPACITY RIGHT EYE SLIGHT
11/22/85	9:08:44	0000337	278.0	CORNEAL OPACITY RIGHT EYE SLIGHT
12/20/85	10:12:04	0000337	284.0	CORNEAL OPACITY RIGHT EYE SLIGHT
1/17/86	9:53:06	0000337	287.0	CORNEAL OPACITY RIGHT EYE SLIGHT, CONJUNCTIVITIS LEFT EYE SLIGHT
2/14/86	8:14:50	0000337	268.0	CORNEAL OPACITY RIGHT EYE SLIGHT, CONJUNCTIVITIS LEFT EYE MODERATE, EUTHANIZED



## Appendix F (cont.): INDIVIDUAL ANIMAL HISTORIES

PAGE 133  
DATE: 6/09/87  
TIME: 14:40:13  
EDS017 V4M11

STUDY: 0083009  
COMPOUND: ISOBUTYL 2-CYANOACRYLATE  
START DATE: 1/28/85

CARCINOGENICITY BIOASSAY OF ISOBUTYL 2-CYANO-  
ACRYLATE (IBC) IN MALE AND FEMALE RATS.

ANIMAL HISTORY

Animal ID: 84D00420 Species: D Sex: FEMALE Group: CONTROLS

DATE	TIME	OPERATOR	WEIGHT (GRAMS)	CLINICAL OBSERVATIONS
2/15/85	10:46:38	0000337	244.0	NORMAL
2/27/85	9:14:42	0078478		STAIN YELLOW PERIANAL SLIGHT
3/11/85	9:03:12	0000337		NORMAL
3/15/85	10:17:40	0000337	238.0	CONJUNCTIVITIS BOTH EYE SLIGHT
3/20/85	8:22:26	0000337		NORMAL
4/12/85	10:02:00	0000337	246.0	NORMAL
5/10/85	9:14:20	0000337	247.0	NORMAL
6/07/85	10:24:04	0000337	253.0	NORMAL
7/03/85	9:46:40	0000337	264.0	NORMAL
8/02/85	10:40:54	0034567	276.0	NORMAL
8/30/85	12:11:08	0000337	277.0	NORMAL
9/27/85	9:28:38	0000337	281.0	NORMAL
10/25/85	10:10:50	0072808	283.0	NORMAL
11/22/85	9:09:00	0000337	284.0	NORMAL
12/20/85	10:12:18	0000337	288.0	NORMAL
1/17/86	9:53:36	0000337	280.0	NORMAL
2/14/86	8:16:06	0000337	272.0	NORMAL / EUTHANIZED

PAGE 134  
 DATE: 6/09/87  
 TIME: 14:40:13  
 EDS017 V4M11

**Appendix F (cont.): INDIVIDUAL ANIMAL HISTORIES**

STUDY: 0083009  
 COMPOUND: ISOBUTYL 2-CYANOACRYLATE  
 START DATE: 1/28/85

CARCINOGENICITY BIOASSAY OF ISOBUTYL 2-CYANO-  
 ACRYLATE (IBC) IN MALE AND FEMALE RATS.

ANIMAL HISTORY

Animal ID: 84D00422 Species: D Sex: FEMALE Group: 10 UL/ANM

DATE	TIME	OPERATOR	WEIGHT (GRAMS)	CLINICAL OBSERVATIONS
2/15/85	10:46:54	0000337	244.0	CONJUNCTIVITIS LEFT EYE SLIGHT, CORNEAL OPACITY BOTH EYE SLIGHT
3/15/85	10:18:04	0000337	247.0	CONJUNCTIVITIS LEFT EYE SLIGHT, CORNEAL OPACITY BOTH EYE SLIGHT
4/12/85	10:03:16	0000337	224.0	CONJUNCTIVITIS BOTH EYE SLIGHT, CORNEAL OPACITY BOTH EYE SLIGHT
5/06/85	9:54:04	0000337		CONJUNCTIVITIS BOTH EYE MARKED, CORNEAL OPACITY BOTH EYE SLIGHT, DEHYDRATED
5/07/85	13:43:56	0000337		MAP:ED

\* No observations recorded.

**Appendix F (cont.): INDIVIDUAL ANIMAL HISTORIES**

PAGE 135  
 DATE: 6/09/87  
 TIME: 14:40:13  
 EDS017 V4M11

STUDY: 0083009  
 COMPOUND: ISOBUTYL 2-CYANOACRYLATE  
 START DATE: 1/28/85  
 CARCINOGENICITY BIOASSAY OF ISOBUTYL 2-CYANO-  
 ACRYLATE (IBC) IN MALE AND FEMALE RATS.

ANIMAL HISTORY

Animal ID: 84D00423 Species: D Sex: FEMALE Group: 100 UL/ANM

DATE	TIME	OPERATOR	WEIGHT (GRAMS)	CLINICAL OBSERVATIONS
2/15/85	10:47:26	0000337	237.0	CORNEAL OPACITY LEFT EYE SLIGHT
3/11/85	9:04:12	0000337		CORNEAL OPACITY LEFT EYE SLIGHT, CONJUNCTIVITIS BOTH EYE SLIGHT, TACHYPNEA MARKED
3/15/85	10:18:26	0000337	240.0	CORNEAL OPACITY LEFT EYE SLIGHT, TACHYPNEA SLIGHT
4/10/85	8:57:20	0072808		CORNEAL OPACITY LEFT EYE SLIGHT
4/12/85	10:03:56	0000337	270.0	CORNEAL OPACITY LEFT EYE SLIGHT
5/10/85	9:14:48	0000337	244.0	CORNEAL OPACITY LEFT EYE SLIGHT, CONJUNCTIVITIS RIGHT EYE SLIGHT, INTRAABDOMINAL MASS VENTRAL TO LIVER SIZE LARGE

**Appendix F (cont.): INDIVIDUAL ANIMAL HISTORIES**

STUDY: 0083009  
 COMPOUND: ISOBUTYL 2-CYANOACRYLATE  
 START DATE: 1/28/85  
 CARCINOGENICITY BIOASSAY OF ISOBUTYL 2-CYANO-  
 ACRYLATE (IBC) IN MALE AND FEMALE RATS.

ANIMAL HISTORY

Animal ID: 84D00424 Species: D Sex: FEMALE Group: 100 UL/ANN

DATE	TIME	OPERATOR	WEIGHT (GRAMS)	CLINICAL OBSERVATIONS
2/15/85	10:47:44	0000337	242.0	CORNEAL OPACITY RIGHT EYE SLIGHT
2/27/85	9:16:20	0078478		CORNEAL OPACITY RIGHT EYE SLIGHT, CONJUNCTIVITIS RIGHT EYE SLIGHT
3/11/85	9:05:20	0000337		CORNEAL OPACITY RIGHT EYE SLIGHT, CONJUNCTIVITIS BOTH EYE SLIGHT
3/15/85	10:19:06	0000337	251.0	CORNEAL OPACITY RIGHT EYE SLIGHT, CONJUNCTIVITIS BOTH EYE SLIGHT
4/12/85	10:04:24	0000337	257.0	CORNEAL OPACITY RIGHT EYE SLIGHT, CONJUNCTIVITIS RIGHT EYE SLIGHT
5/10/85	9:17:44	0000337	264.0	CORNEAL OPACITY RIGHT EYE SLIGHT
5/21/85	8:37:10	0000337		CORNEAL OPACITY RIGHT EYE SLIGHT, CONJUNCTIVITIS BOTH EYE MODERATE
5/30/85	7:55:50	0000337		CORNEAL OPACITY RIGHT EYE SLIGHT, CONJUNCTIVITIS LEFT EYE MODERATE
6/07/85	10:24:44	0000337	264.0	CORNEAL OPACITY RIGHT EYE SLIGHT, CONJUNCTIVITIS LEFT EYE MODERATE
7/03/85	9:47:08	0000337	269.0	CORNEAL OPACITY RIGHT EYE SLIGHT, CONJUNCTIVITIS LEFT EYE MODERATE
8/02/85	10:41:10	0034567	268.0	CORNEAL OPACITY RIGHT EYE SLIGHT, CONJUNCTIVITIS LEFT EYE MODERATE
8/30/85	12:11:32	0000337	258.0	CORNEAL OPACITY RIGHT EYE SLIGHT, CONJUNCTIVITIS LEFT EYE MODERATE
9/09/85	9:47:58	0000337		CORNEAL OPACITY RIGHT EYE SLIGHT, CONJUNCTIVITIS BOTH EYE MARKED
9/27/85	9:29:00	0000337	257.0	CORNEAL OPACITY RIGHT EYE SLIGHT, CONJUNCTIVITIS BOTH EYE MARKED
10/25/85	10:11:22	0084799	221.0	CORNEAL OPACITY RIGHT EYE SLIGHT, CONJUNCTIVITIS BOTH EYE MARKED, PROSTRATE
10/25/85	10:13:38	0072808	221.0	* No observations recorded.

**Appendix F (cont.): INDIVIDUAL ANIMAL HISTORIES**

PAGE 137  
 DATE: 6/09/87  
 TIME: 14:40:13  
 EDS017 V4M11

STUDY: 0083009 CARCINOGENICITY BIOASSAY OF ISOBUTYL 2-CYANO-  
 COMPOUND: ISOBUTYL 2-CYANOACRYLATE ACRYLATE (IBC) IN MALE AND FEMALE RATS.  
 START DATE: 1/28/85

ANIMAL HISTORY

Animal ID: 84D00425 Species: D Sex: FEMALE Group: 10 UL/ANM

DATE	TIME	OPERATOR	WEIGHT (GRAMS)	CLINICAL OBSERVATIONS
2/15/85	10:48:00	0000337	201.0	CONJUNCTIVITIS BOTH EYE MARKED
3/15/85	10:19:38	0000337	208.0	CONJUNCTIVITIS BOTH EYE MARKED
4/12/85	10:06:00	0000337	211.0	CONJUNCTIVITIS LEFT EYE MARKED, CONJUNCTIVITIS RIGHT EYE SLIGHT
5/10/85	9:18:06	0000337	214.0	CONJUNCTIVITIS BOTH EYE MARKED, SCAB RIGHT EAR SLIGHT
5/21/85	8:38:40	0000337		CONJUNCTIVITIS BOTH EYE MARKED, SCAB RIGHT EAR SLIGHT, EMACIATED SLIGHT
5/30/85	7:57:10	0000337		CONJUNCTIVITIS BOTH EYE MARKED, SCAB RIGHT EAR SLIGHT
6/07/85	10:25:06	0000337	221.0	CONJUNCTIVITIS BOTH EYE MARKED
6/18/85	8:35:32	0000337		CONJUNCTIVITIS BOTH EYE SLIGHT
7/03/85	9:47:36	0000337	220.0	CONJUNCTIVITIS BOTH EYE SLIGHT
8/02/85	10:41:46	0034567	231.0	CONJUNCTIVITIS BOTH EYE SLIGHT
8/28/85	9:04:20	0000337		CONJUNCTIVITIS RIGHT EYE MARKED, STAIN YELLOW PERIANAL SLIGHT
8/30/85	12:12:06	0000337	231.0	CONJUNCTIVITIS RIGHT EYE SLIGHT
9/09/85	9:49:02	0000337		CONJUNCTIVITIS RIGHT EYE MODERATE
9/27/85	9:29:30	0000337	249.0	CONJUNCTIVITIS RIGHT EYE SLIGHT
10/25/85	10:16:04	0072808	248.0	CONJUNCTIVITIS RIGHT EYE MODERATE
10/30/85	9:47:48	0002920		CONJUNCTIVITIS RIGHT EYE MODERATE, STAIN URINE PERIANAL MODERATE
11/22/85	9:09:28	0000337	249.0	CONJUNCTIVITIS RIGHT EYE MODERATE, STAIN URINE PERIANAL MODERATE
12/20/85	10:12:34	0000337	246.0	CONJUNCTIVITIS RIGHT EYE MODERATE, STAIN URINE PERIANAL SLIGHT
1/17/86	9:53:58	0000337	244.0	CONJUNCTIVITIS RIGHT EYE MODERATE, STAIN URINE PERIANAL MODERATE, ROUGH COAT MARKED
1/17/86	12:34:58	0000337		

\* No observations recorded.

PAGE 138  
 DATE: 6/09/87  
 TIME: 14:40:13  
 EDS017 V4M11

**Appendix F (cont.): INDIVIDUAL ANIMAL HISTORIES**

STUDY: 0083009 ISOBUTYL 2-CYANOACRYLATE CARCINOGENICITY BIOASSAY OF ISOBUTYL 2-CYANO-  
 COMPOUND: ISOBUTYL 2-CYANOACRYLATE ACRYLATE (IBC) IN MALE AND FEMALE RATS.  
 START DATE: 1/28/85

ANIMAL HISTORY

Animal ID: 84D00426 Species: D Sex: FEMALE Group: 10 UL/ANM

DATE	TIME	OPERATOR	WEIGHT (GRAMS)	CLINICAL OBSERVATIONS
2/15/85	10:48:18	0000337	210.0	NORMAL
2/27/85	9:18:34	0078478		STAIN YELLOW PERIANAL SLIGHT
3/01/85	8:24:46	0000337		STAIN CLEAR PERIANAL SLIGHT
3/15/85	10:20:02	0000337	216.0	NORMAL
4/12/85	10:06:48	0000337	227.0	NORMAL
5/10/85	9:19:28	0000337	230.0	NORMAL
6/07/85	10:25:32	0000337	237.0	NORMAL
6/18/85	8:36:38	0084799		INTRABDOMINAL MASS VENTRAL TO LIVER SIZE SMALL, CONJUNCTIVITIS RIGHT EYE SLIGHT
7/03/85	9:48:08	0000337	242.0	INTRABDOMINAL MASS VENTRAL TO LIVER SIZE SMALL, CONJUNCTIVITIS RIGHT EYE
8/02/85	10:42:08	0034567	246.0	CONJUNCTIVITIS RIGHT EYE SLIGHT, INTRABDOMINAL MASS VENTRAL TO LIVER SIZE SMALL
8/28/85	9:06:38	0000337		SUSPECTED LEUKEMIA
8/28/85	12:32:10	0000337		* No observations recorded.

## Appendix F (cont.): INDIVIDUAL ANIMAL HISTORIES

STUDY: 0083009  
 COMPOUND: ISOBUTYL 2-CYANOACRYLATE  
 START DATE: 1/28/85

CARCINOGENICITY BIOASSAY OF ISOBUTYL 2-CYANO-  
 ACRYLATE (IBC) IN MALE AND FEMALE RATS.

PAGE 139  
 DATE: 6/09/87  
 TIME: 14:40:13  
 EDS017 V4M11

## ANIMAL HISTORY

Animal ID: 84D00427 Species: D Sex: FEMALE Group: CONTROLS

DATE	TIME	OPERATOR	WEIGHT (GRAMS)	CLINICAL OBSERVATIONS
2/15/85	10:48:48	0000337	198.0	CONJUNCTIVITIS BOTH EYE MODERATE
3/11/85	9:07:38	0000337		CONJUNCTIVITIS BOTH EYE MODERATE, STAIN CLEAR PERIANAL SLIGHT
3/15/85	10:20:30	0000337	201.0	CONJUNCTIVITIS BOTH EYE MODERATE
3/20/85	8:26:34	0000337		CONJUNCTIVITIS RIGHT EYE MARKED, CONJUNCTIVITIS LEFT EYE MODERATE
4/12/85	10:07:10	0000337	211.0	CONJUNCTIVITIS RIGHT EYE MARKED, CONJUNCTIVITIS LEFT EYE MODERATE
5/10/85	9:19:44	0000337	215.0	CONJUNCTIVITIS BOTH EYE MODERATE
5/21/85	8:40:50	0000337		CONJUNCTIVITIS BOTH EYE MARKED
6/07/85	10:25:52	0000337	220.0	CONJUNCTIVITIS BOTH EYE SLIGHT
6/18/85	8:40:04	0000337		CONJUNCTIVITIS RIGHT EYE MARKED, CONJUNCTIVITIS LEFT EYE MODERATE
7/03/85	9:50:08	0000337	227.0	CONJUNCTIVITIS RIGHT EYE MARKED, CONJUNCTIVITIS LEFT EYE MODERATE
8/02/85	10:45:12	0034567	238.0	CONJUNCTIVITIS BOTH EYE SLIGHT
8/30/85	12:12:36	0000337	243.0	CONJUNCTIVITIS BOTH EYE SLIGHT
9/09/85	9:49:42	0000337		NORMAL
9/27/85	9:29:50	0000337	253.0	CONJUNCTIVITIS BOTH EYE SLIGHT
10/25/85	10:16:38	0072808	254.0	CONJUNCTIVITIS BOTH EYE SLIGHT
10/30/85	9:49:26	0002920		CONJUNCTIVITIS BOTH EYE SLIGHT, IRRITABLE MODERATE
11/22/85	9:10:14	0000337	262.0	NORMAL
12/20/85	10:13:10	0000337	252.0	NORMAL
1/02/86	9:31:04	0000337		PERIVAGINAL FISTULA BLEEDING MODERATE
1/17/86	9:54:52	0000337	245.0	PERIVAGINAL FISTULA MODERATE
2/14/86	8:17:22	0000337	225.0	CONJUNCTIVITIS RIGHT EYE MODERATE, PALLOR MODERATE, PERIVAGINAL MASS FISTULATED SIZE MEDIUM, EUTHANIZED

PAGE 140  
 DATE: 6/09/87  
 TIME: 14:40:13  
 EDS017 V4M11

**Appendix F (cont.): INDIVIDUAL ANIMAL HISTORIES**

STUDY: 0083009  
 COMPOUND: ISOBUTYL 2-CYANOACRYLATE  
 START DATE: 1/28/85

CARCINOGENICITY BIOASSAY OF ISOBUTYL 2-CYANO-  
 ACRYLATE (IBC) IN MALE AND FEMALE RATS.

ANIMAL HISTORY

Animal ID: 84D00428 Species: n Sex: FEMALE Group: CONTROLS

DATE	TIME	OPERATOR	WEIGHT (GRAMS)	CLINICAL OBSERVATIONS
2/15/85	10:49:20	0000337	199.0	CORNEAL OPACITY BOTH EYE MODERATE, XYPHOID PROTUBERANCE SLIGHT
3/15/85	10:20:50	0000337	211.0	CORNEAL OPACITY BOTH EYE MODERATE, XYPHOID PROTUBERANCE SLIGHT
3/20/85	8:27:34	0084799		CORNEAL OPACITY BOTH EYE MODERATE, XYPHOID PROTUBERANCE, FISTULA LOWER ABDOMEN
4/10/85	9:06:36	0072808		CORNEAL OPACITY BOTH EYE MODERATE, XYPHOID PROTUBERANCE, FISTULA PROTUBERANCE
4/12/85	10:07:46	0000337	212.0	CORNEAL OPACITY BOTH EYE MODERATE, XYPHOID PROTUBERANCE, PERIVAGINAL FISTULA
4/23/85	9:40:14	0000337		CORNEAL OPACITY BOTH EYE MODERATE, XYPHOID PROTUBERANCE, PERIVAGINAL FISTULA, VAGINAL PURULENCE



## Appendix F (cont.): INDIVIDUAL ANIMAL HISTORIES

PAGE 141  
DATE: 6/09/87  
TIME: 14:40:13  
EDS017 V4M11

JUDY: 0083009  
COMPOUND: ISOBUTYL 2-CYANOACRYLATE  
START DATE: 1/28/85

CARCINOGENICITY BIOASSAY OF ISOBUTYL 2-CYANO-  
ACRYLATE (IBC) IN MALE AND FEMALE RATS.

ANIMAL HISTORY

Animal ID: 84D00429 Species: D Sex: FEMALE Group: 10 UL/ANM

DATE	TIME	OPERATOR	WEIGHT (GRAMS)	CLINICAL OBSERVATIONS
2/15/85	10:50:08	0000337	225.0	CORNEAL OPACITY BOTH EYE MODERATE
3/15/85	10:22:00	0000337	227.0	CORNEAL OPACITY BOTH EYE MODERATE
4/12/85	10:10:34	0000337	237.0	CORNEAL OPACITY BOTH EYE MODERATE
5/10/85	9:20:14	0000337	236.0	CORNEAL OPACITY BOTH EYE MODERATE
6/07/85	10:26:10	0000337	256.0	CORNEAL OPACITY BOTH EYE MODERATE
7/03/85	9:50:38	0000337	251.0	CORNEAL OPACITY BOTH EYE MODERATE
8/02/85	10:45:54	0034567	268.0	CORNEAL OPACITY BOTH EYE MODERATE
8/30/85	12:12:58	0000337	264.0	CORNEAL OPACITY BOTH EYE MODERATE
9/27/85	9:30:20	0000337	274.0	CORNEAL OPACITY BOTH EYE MODERATE
10/25/85	10:17:20	0072808	283.0	CORNEAL OPACITY BOTH EYE MODERATE
11/22/85	9:10:56	0000337	280.0	CORNEAL OPACITY BOTH EYE MODERATE
12/20/85	10:13:30	0000337	281.0	CORNEAL OPACITY BOTH EYE MODERATE
1/17/86	9:55:36	0000337	274.0	CORNEAL OPACITY BOTH EYE MODERATE
2/14/86	8:21:14	0000337	263.0	CORNEAL OPACITY BOTH EYE MODERATE, EUTHANIZED

**Appendix F (cont.): INDIVIDUAL ANIMAL HISTORIES**

STUDY: 0083009  
COMPOUND: ISOBUTYL 2-CYANOACRYLATE  
START DATE: 1/28/85

CARCINOGENICITY BIOASSAY OF ISOBUTYL 2-CYANO-  
ACRYLATE (IBC) IN MALE AND FEMALE RATS.

**ANIMAL HISTORY**

Animal ID: 84D00430 Species: D Sex: FEMALE Group: 100 UL/ANM

DATE	TIME	OPERATOR	WEIGHT (GRAMS)	CLINICAL OBSERVATIONS
2/15/85	10:50:30	0000337	227.0	NORMAL
3/15/85	10:22:22	0000337	228.0	NORMAL
4/12/85	10:11:00	0000337	244.0	NORMAL
5/10/85	9:20:34	0000337	241.0	NORMAL
6/07/85	10:26:30	0000337	246.0	NORMAL
7/03/85	9:51:06	0000337	260.0	NORMAL
7/09/85	12:47:12	0069406		* No observations recorded.

PAGE 143  
 DATE: 6/09/87  
 TIME: 14:40:13  
 EDS017 V4M11

**Appendix F (cont.): INDIVIDUAL ANIMAL HISTORIES**

STUDY: 0083009  
 COMPOUND: ISOBUTYL 2-CYANOACRYLATE  
 START DATE: 1/28/85  
 CARCINOGENICITY BIOASSAY OF ISOBUTYL 2-CYANO-  
 ACRYLATE (IBC) IN MALE AND FEMALE RATS.

ANIMAL HISTORY

Animal ID: 84D00431 Species: D Sex: FEMALE Group: 100 UL/ANM

DATE	TIME	OPERATOR	WEIGHT (GRAMS)	CLINICAL OBSERVATIONS
2/15/85	10:50:48	0000337	246.0	NORMAL
3/15/85	10:22:46	0000337	253.0	CONJUNCTIVITIS LEFT EYE SLIGHT
3/20/85	8:33:26	0000337		NORMAL
4/12/85	10:11:28	0000337	263.0	CONJUNCTIVITIS LEFT EYE SLIGHT
5/10/85	9:20:54	0000337	266.0	CONJUNCTIVITIS LEFT EYE MODERATE
5/30/85	8:01:10	0000337		CONJUNCTIVITIS LEFT EYE SLIGHT
6/07/85	10:26:50	0000337	271.0	NORMAL
7/03/85	9:51:26	0000337	251.0	NORMAL
7/08/85	6:57:12	0000337		INTRABDOMINAL MASS LOWER ABDOMEN IRREGULAR SHAPE SIZE LARGE

PAGE 144  
 DATE: 6/09/87  
 TIME: 14:40:13  
 EDS017 V4M11

**Appendix F (cont.): INDIVIDUAL ANIMAL HISTORIES**

STUDY: 0083009 ISOBUTYL 2-CYANOACRYLATE CARCINOGENICITY BIOASSAY OF ISOBUTYL 2-CYANO-  
 COMPOUND: ISOBUTYL 2-CYANOACRYLATE ACRYLATE (IBC) IN MALE AND FEMALE RATS.  
 START DATE: 1/28/85

ANIMAL HISTORY

Animal ID: 84D00432 Species: D Sex: FEMALE Group: 100 UL/ANM

DATE	TIME	OPERATOR	WEIGHT (GRAMS)	CLINICAL OBSERVATIONS
2/15/85	10:51:28	0000337	226.0	NORMAL
2/27/85	9:21:50	0078478		NORMAL
3/15/85	10:23:12	0000337	238.0	NORMAL
4/12/85	10:11:54	0000337	240.0	NORMAL
5/10/85	9:21:26	0000337	241.0	NORMAL
5/30/85	8:01:54	0000337		CONJUNCTIVITIS BOTH EYE SLIGHT
6/07/85	10:27:18	0000337	245.0	NORMAL
7/03/85	9:52:50	0000337	250.0	NORMAL
7/09/85	12:46:06	0069406		ANIMAL REMOVED BY MISTAKE.
8/02/85	10:46:16	0034567	259.0	NORMAL
8/30/85	12:13:14	0000337	264.0	NORMAL
9/27/85	9:30:40	0000337	273.0	NORMAL
10/25/85	10:17:42	0072808	273.0	NORMAL
11/22/85	9:11:16	0000337	284.0	NORMAL
12/20/85	10:14:00	0000337	283.0	NORMAL
1/17/86	9:56:02	0000337	283.0	NORMAL
1/23/86	13:26:50	0084799		* No observations recorded.

**Appendix G: GROSS NECROPSY OBSERVATIONS, INCIDENCE SUMMARY**

LETTERMAN ARMY INSTITUTE OF RESEARCH  
 DIV OF RES SUPP, PATH SERV GP  
 PRESIDIO OF SAN FRANCISCO, CA 94129  
 SPECIES: RAT/FISCHER-344

INCIDENCE SUMMARY REPORT FOR GROSS NECROPSY OBSERVATIONS  
 STUDY NUMBER: GLP83009  
 REPORT FOR UNSCHEDULED DEATHS: DAY 374 TO DAY 755 OF STUDY  
 STUDY START DATE: 23-JAN-84

PRINTED: 21-NOV-89  
 PAGE: 1

STUDY TYPE: CHRONIC/2 YR CARCINOGENIC

NOTE: CTLs = CONTROLS FROM GROUP(S): 3  
 ANIMAL SEX: GROUP: 1 2  
 NO. IN GROUP: 13 27 16

--- MALES ---  
 CTLs 1 2  
 13 27 16

--- FEMALES ---  
 CTLs 1 2  
 22 21 19

WHOLE BODY	MALES	FEMALES
NO GROSS LESIONS RECOGNIZED	0	0
POST MORTEM AUTOLYSIS	0	2
STAINED HAIR	0	0
FAT GENERALLY YELLOW	0	0
THIN WATERY BLOOD	0	0
POSSIBLE MECHANICAL INJURY	0	0
JAUNDICED	0	0
MINIMAL BODY FAT	0	0
TOTAL:	0	2
ADRENAL		
ENLARGED, UNILATERALLY	1	0
DISCOLORATION	0	0
ENLARGED, BILATERALLY	0	1
TOTAL:	1	1
PERICARDIAL CAV.		
BLOOD-TINGED FLUID	0	0
TOTAL:	0	0
CECUM		
MASS(ES)	0	1
ADHERED TO PERITONEAL WALL	0	1
TOTAL:	0	2
COLON		
ADHERED TO PERITONEAL WALL	0	0
TOTAL:	0	0
PLEURAL CAVITY		
FLUID-FILLED	0	1
HEMOTHROAX	0	1
GROWTH(S) / MASS(ES)	0	0
TOTAL:	0	2
PERITONEAL CAV.		
ADHESION(S)	0	6
FLUID-FILLED	0	3
RED FOCI IN BODY FAT	0	1
ROUGHENED PERITONEAL SURFACE	0	1
FRANK BLOOD PRESENT	0	0
GROWTH(S) / MASS(ES)	0	1
TOTAL:	0	12

## Appendix G (cont.): GROSS NECROPSY OBSERVATIONS, INCIDENCE SUMMARY

LETTERMAN ARMY INSTITUTE OF RESEARCH  
 DIV OF RES SUPP, PATH SERV GP  
 PRESIDIO OF SAN FRANCISCO, CA 94129  
 SPECIES: RAT/FISCHER-344

INCIDENCE SUMMARY REPORT FOR GROSS NECROPSY OBSERVATIONS  
 STUDY NUMBER: GLP83009  
 REPORT FOR UNSCHEDULED DEATHS: DAY 374 TO DAY 755 OF STUDY  
 STUDY START DATE: 23-JAN-84

PRINTED: 21-NOV-89  
 PAGE: 2

STUDY TYPE: CHRONIC/2 YR CARCINOGENIC

	-- MALES --		-- FEMALES --	
	CTLS	NO. IN GROUP	CTLS	NO. IN GROUP
NOTE: CTLs = CONTROLS				
FROM GROUP(S): 3				
ANIMAL SEX:				
GROUP:	13	27	13	27
NO. IN GROUP:	13	27	13	27
DIAPHRAGM				
GROWTH(S)/MASS(ES)	0	1	0	0
TOTAL:	0	1	0	0
DUODENUM				
ADHERED TO LIVER	0	0	0	1
DISTENDED	0	1	0	0
GROWTH(S) / MASS(ES)	0	1	0	0
TOTAL:	0	2	0	1
EAR				
NECROSIS	0	1	0	0
TOTAL:	0	1	0	0
EYES & OPTIC N.				
OCCULAR DISCHARGE	0	0	0	2
CORNEAL OPACITY	1	1	2	1
ROUGH CORNEAL SURFACE	0	1	0	0
STAINED HAIR	0	0	0	1
CRUSTY MATERIAL, PERIORBITAL	1	1	0	2
HYPOPIOM	0	0	0	0
CORNEAL VASCULARIZATION	0	0	1	0
TOTAL:	2	3	3	6
HEART				
MODULE	0	0	0	0
TOTAL:	0	0	0	0
ILEUM				
GROWTH(S) / MASS(ES)	0	1	0	0
ADHESION(S)	0	0	0	2
HEMORRHAGE(S)	0	0	1	0
TOTAL:	0	1	1	2
JEJUNUM				
DISTENDED	0	1	0	0
ADHERED TO PERITONEUM	0	1	0	0
ENLARGED	0	0	0	1
HEMORRHAGE(S)	0	0	1	0
GROWTH(S) / MASS(ES)	0	1	0	0
TOTAL:	0	3	1	1
KIDNEY				
CYST	0	0	1	0

**Appendix G (cont.): GROSS NECROPSY OBSERVATIONS, INCIDENCE SUMMARY**

LETTERMAN ARMY INSTITUTE OF RESEARCH  
 DIV OF RES SUPP, PAIN SERV GP  
 PRESIDIO OF SAN FRANCISCO, CA 94129  
 SPECIES: RAT/FISCHER-344

INCIDENCE SUMMARY REPORT FOR GROSS NECROPSY OBSERVATIONS  
 STUDY NUMBER: GLP83009  
 REPORT FOR UNSCHEDULED DEATHS: DAY 374 TO DAY 755 OF STUDY  
 STUDY START DATE: 23-JAN-84

STUDY TYPE: CHRONIC/2 YR CARCINOGENIC

NOTE: CTLS = CONTROLS FROM GROUP(S): 3      ANIMAL SEX:      CTLS      1      2      2      2  
 FROM GROUP(S): 3      NO. IN GROUP:      CTLS      13      27      16      22      21      19

KIDNEY

	MALES	FEMALES
FIRM WHITE MASS	1 0 0	0 0 0
GRANULAR SURFACE	1 2 2	3 0 2
HEMORRHAGE	0 1 0	0 0 0
PITTED SURFACE	0 0 1	0 0 0
DISCOLORATION	2 4 7	5 3 6
TOTAL:	4 7 10	9 3 8

LIVER

	MALES	FEMALES
PROMINENT LOBULAR MARKINGS	1 5 4	5 4 5
ENLARGED	0 3 2	2 0 1
GRANULAR SURFACE	1 5 3	4 2 2
SWOLLEN	0 0 1	0 0 0
ADHESION(S)	0 25 14	2 16 15
GROWTH(S) / MASS(ES)	0 5 1	0 10 0
DISCOLORATION	2 1 4	2 3 2
MODULE(S)	1 0 0	1 1 0
TOTAL:	5 44 29	16 36 25

LYMPH NODES

	MALES	FEMALES
ENLARGED	0 1 0	0 0 0
DISCOLORATION	0 1 0	0 1 0
TOTAL:	0 2 0	0 1 0

LUNGS

	MALES	FEMALES
CONGESTED / RED	0 2 0	1 1 0
HEMORRHAGE(S)	0 1 0	0 0 0
DISCOLORATION	1 2 2	3 0 3
TOTAL:	1 5 2	4 1 3

MAMMARY GLAND

	MALES	FEMALES
DISCOLORATION	0 1 0	1 0 0
TOTAL:	0 1 0	1 0 0

MAXILLA

	MALES	FEMALES
SOFT TISSUE MASS	0 1 0	0 0 0
TOTAL:	0 1 0	0 0 0

OVARIES

	MALES	FEMALES
PARA-OVARIAN CYST(S)	0 0 0	1 3 1
TOTAL:	0 0 0	1 3 1

PITUITARY GLAND

	MALES	FEMALES
CYST(S)	0 1 0	0 0 0

**Appendix G (cont.): GROSS NECROPSY OBSERVATIONS, INCIDENCE SUMMARY**

LETTERMAN ARMY INSTITUTE OF RESEARCH  
 DIV OF RES SUPP, PATN SERV GP  
 PRESIDIO OF SAN FRANCISCO, CA 94129  
 SPECIES: RAT/FISCHER-344

INCIDENCE SUMMARY REPORT FOR GROSS NECROPSY OBSERVATIONS  
 STUDY NUMBER: GLP83009  
 REPORT FOR UNSCHEDULED DEATHS: DAY 374 TO DAY 755 OF STUDY  
 STUDY START DATE: 23-JAN-84

PRINTED: 21-NOV-89  
 PAGE: 4  
 STUDY TYPE: CHRONIC/2 YR CARCINOGENIC

NOTE: CTLS = CONTROLS FROM GROUP(S): 3 ANIMAL SEX: MALES CTLS 1 2 13 27 16 FEMALES CTLS 1 2 22 21 19

	MALES			FEMALES		
	CTLS	1	2	CTLS	1	2
	NO. IN GROUP	13	27	22	21	19
<b>PITUITARY GLAND</b>						
ENLARGED	5	4	1	10	5	6
DISCOLORATION	0	4	1	4	2	5
GROWTH(S) / MASS(ES)	0	0	1	0	0	0
HEMORRHAGIC	0	0	0	0	1	0
TOTAL:	5	9	3	14	8	11
<b>RECTUM</b>						
MUCHOID DISCHARGE	0	0	0	1	0	0
TOTAL:	0	0	0	1	0	0
<b>SALIVARY GLAND</b>						
GROWTH(S) / MASS(ES)	0	0	0	1	0	0
TOTAL:	0	0	0	1	0	0
<b>SM INTESTINE</b>						
ADHERED TO MASS	0	0	0	0	2	0
TOTAL:	0	0	0	0	2	0
<b>SKIN</b>						
ABSCESSES	0	0	1	1	1	0
ALOPECIA	1	0	0	0	0	0
SUBCUTANEOUS MASS	2	2	3	1	2	3
ULCER(S) / EROSION(S)	0	0	0	1	0	0
DISCOLORATION	0	0	0	1	0	0
TOTAL:	3	2	4	4	3	3
<b>SPLEEN</b>						
PROMINENT FIBROUS CAPSULE	0	1	0	0	0	0
ENLARGED (SPLENOHEGALY)	3	8	9	9	6	9
FRACTURED	0	1	2	0	0	0
GRANULAR SURFACE	1	0	0	0	0	0
GROWTH(S) / MASS(ES)	0	0	0	0	1	0
INFARCT(S)	0	0	1	0	0	0
DISCOLORATION	0	1	1	1	0	1
FIBROUS ADHESION(S)	0	2	0	1	0	0
TOTAL:	4	13	13	10	7	10
<b>SUBCUTIS</b>						
MASS/MASSES	0	1	0	0	0	0
TOTAL:	0	1	0	0	0	0
<b>STOMACH</b>						
GROWTH(S) / MASS(ES)	0	1	1	0	0	0





**Appendix G (cont.): GROSS NECROPSY OBSERVATIONS, INCIDENCE SUMMARY**

LETTERMAN ARMY INSTITUTE OF RESEARCH  
 DIV OF RES SUPP, PATH SERV GP  
 PRESIDIO OF SAN FRANCISCO, CA 94129  
 SPECIES: RAT/FISCHER-344

INCIDENCE SUMMARY REPORT FOR GROSS NECROPSY OBSERVATIONS  
 STUDY NUMBER: GLP83009  
 REPORT FOR UNSCHEDULED DEATHS: DAY 374 TO DAY 755 OF STUDY  
 STUDY START DATE: 23-JAN-84

PRINTED: 21-NOV-89  
 PAGE: 6

STUDY TYPE: CHRONIC/2 YR CARCINOGENIC

NOTE: CTLs = CONTROLS FROM GROUP(S): 3 ANIMAL SEX: GROUP: NO. IM GROUP:

	-- MALES --		-- FEMALES --	
	CTLs	IM	CTLs	IM
VAGINA	13	27	22	21
MUCOID DISCHARGE	0	0	0	1
PURULENT DISCHARGE	0	0	0	1
TOTAL:	0	0	0	1

**Appendix G (cont.): GROSS NECROPSY OBSERVATIONS, INCIDENCE SUMMARY**  
 LETTERMAN ARMY INSTITUTE OF RESEARCH INCIDENCE SUMMARY REPORT FOR GROSS NECROPSY OBSERVATIONS PRINTED: 21-NOV-89  
 DIV OF RES SUPP, PATH SERV GP STUDY NUMBER: GLP83009 PAGE: 1  
 PRESIDIO OF SAN FRANCISCO, CA 94129 REPORT FOR FINAL SACRIFICE  
 SPECIES: RAT/FISCHER-344 STUDY START DATE: 23-JAN-84 STUDY TYPE: CHRONIC/2 YR CARCINOGENIC

NOTE: CTLs = CONTROLS ANIMAL SEX: MALES FEMALES  
 FROM GROUP(S): 3 GROUP: CTLs 1 2 CTLs 1 2  
 NO. IN GROUP: 44 23 39 29 19 33

WHOLE BODY	MALES	FEMALES
NO GROSS LESIONS RECOGNIZED	0 0 0	1 0 0
TOTAL:	0 0 0	1 0 0
ADRENAL		
ENLARGED, UNILATERALLY	2 0 2	0 0 0
DISCOLORATION	1 0 1	0 0 2
TOTAL:	3 0 3	0 0 2
CECUM		
ADHESION(S)	0 2 0	0 0 0
TOTAL:	0 2 0	0 0 0
PERITONEAL CAV.		
ADHESION(S)	0 0 0	0 1 0
GROWTH(S) / MASS(ES)	0 1 2	0 0 0
CYST	0 1 0	0 0 0
TOTAL:	0 2 2	0 1 0
DIAPHRAGM		
HERNIA	0 0 0	1 0 0
TOTAL:	0 0 0	1 0 0
DUODENUM		
ADHERED TO LIVER	0 0 0	0 4 1
GROWTH(S) / MASS(ES)	0 1 0	0 0 0
THICKENED	0 0 0	0 1 0
TOTAL:	0 1 0	0 5 1
EYES & OPTIC N.		
CORNEAL OPACITY	0 0 0	1 1 1
LENS CATARACT	3 3 3	0 0 1
MICROPTHALMIA	0 0 1	0 0 0
TOTAL:	3 3 4	1 1 2
HEART		
MODULE	0 0 0	1 0 0
TOTAL:	0 0 0	1 0 0
ILEUM		
ADHESION(S)	0 1 0	0 0 0
TOTAL:	0 1 0	0 0 0
JEJUNUM		
ADHERED TO LIVER.	0 0 0	0 1 0



**Appendix G (cont.): GROSS NECROPSY OBSERVATIONS, INCIDENCE SUMMARY**

LETTERMAN ARMY INSTITUTE OF RESEARCH  
 DIV OF RES SUPP, PATH SERV GP  
 PRESIDIO OF SAN FRANCISCO, CA 94129  
 SPECIES: RAT/FISCHER-344

INCIDENCE SUMMARY REPORT FOR GROSS NECROPSY OBSERVATIONS  
 STUDY NUMBER: GLP83009  
 REPORT FOR FINAL SACRIFICE

STUDY START DATE: 23-JAN-84  
 STUDY TYPE: CHRONIC/2 YR CARCINOGENIC

PRINTED: 21-NOV-89  
 PAGE: 3

NOTE: CTLS = CONTROLS FROM GROUP(S): 3 ANIMAL SEX: MALES  
 CTLS 1 2  
 44 23 39

CTLS 1 2  
 29 19 33

	MALES	CTLS	MALES	CTLS	CTLS	CTLS
PAWS/FEET						
GROWTH(S) / MASS(ES)	1	0	0	0	0	0
TOTAL:	1	0	0	0	0	0
PITUITARY GLAND						
CYST(S)	0	0	0	0	2	0
ENLARGED	9	4	8	8	11	7
DISCOLORATION	3	3	5	9	5	5
NODULE	0	1	0	0	0	0
TOTAL:	12	8	13	13	16	12
PERINEAL						
MASS(S)/GROWTH(S)	0	0	0	0	1	0
TOTAL:	0	0	0	0	1	0
SM INTESTINE						
ADHESION(S)	0	3	0	0	0	0
GROWTH(S)/MASS(S)	0	2	0	0	0	0
TOTAL:	0	5	0	0	0	0
SKIN						
ABSCESS(ES)	1	0	0	0	2	0
SUBCUTANEOUS MASS	3	0	1	1	4	2
ULCER(S) / EROSION(S)	1	0	1	1	0	0
EPIDERMAL "HORN"	0	0	1	1	0	0
SUBCUTANEOUS MODULE(S)	0	1	0	0	0	0
GROWTH(S) / MASS(ES)	3	0	0	0	0	1
TOTAL:	8	1	3	3	6	3
SPLEEN						
PROMINENT FIBROUS CAPSULE	0	2	0	0	0	0
ENLARGED (SPLENOHEGALY)	3	2	7	2	4	2
ADHERED TO PERITONEAL WALL	0	0	0	0	0	1
STRICTURE	1	1	1	1	0	0
NODULE	2	1	1	1	0	0
DISCOLORATION	0	1	1	1	0	1
TOTAL:	6	7	10	10	4	4
TAIL						
DERMATITIS	0	1	0	0	0	0
ULCERATION	1	0	0	0	0	0
TOTAL:	1	1	0	0	0	0
TESTES						
ATROPHIC / SMALL, UNILATERALLY	6	3	4	4	0	0

**Appendix G (cont.): GROSS NECROPSY OBSERVATIONS, INCIDENCE SUMMARY**  
 LETTERMAN ARMY INSTITUTE OF RESEARCH  
 DIV OF RES SUPP, PATH SERV GP  
 PRESIDIO OF SAN FRANCISCO, CA 94129  
 SPECIES: RAT/FISCHER-344

INCIDENCE SUMMARY REPORT FOR GROSS NECROPSY OBSERVATIONS  
 STUDY NUMBER: GLP83009  
 REPORT FOR FINAL SACRIFICE  
 STUDY START DATE: 23-JAN-84  
 STUDY TYPE: CHRONIC/2 YR CARCINOGENIC

NOTE: CTLs = CONTROLS FROM GROUP(S): 3  
 ANIMAL SEX: MALES  
 GROUP: CTLs 1 2  
 NO. IN GROUP: 44 23 39

TESTES  
 ENLARGED ..... 21 10 12  
 GROWTH(S) / MASS(ES) ..... 40 22 37  
 DISCOLORATION ..... 1 1 1  
 TOTAL: ..... 68 36 54

THYROID  
 ENLARGED ..... 0 1 1  
 GROWTH(S) / MASS(ES) ..... 1 0 0  
 TOTAL: ..... 1 1 1

THYMUS  
 GENERALIZED ATROPHY ..... 0 1 0  
 TOTAL: ..... 0 1 0

UTERUS  
 HYDROMETRA ..... 1 0 4  
 POLYP ..... 4 4 5  
 GROWTH(S)/MASS(S) ..... 2 0 1  
 HYPOPLASIA ..... 1 0 0  
 CYST(S) ..... 0 1 1  
 TOTAL: ..... 8 5 11

VAGINA  
 ABSCESS ..... 0 1 0  
 TOTAL: ..... 0 1 0

--- FEMALES ---  
 CTLs 1 2  
 29 19 33

**Appendix H: MICROSCOPIC OBSERVATIONS, INCIDENCE SUMMARY**

LETTERMAN ARMY INSTITUTE OF RESEARCH  
 DIV OR RES SUPP, PATH SERV GP  
 PRESIDIO OF SAN FRANCISCO, CA 94129  
 SPECIES: RAT/FISCHER-344

INCIDENCE SUMMARY OF MICROSCOPIC OBSERVATIONS(ALL NEOPLASMS)  
 STUDY NUMBER: GLP83009  
 PATHOLOGIST(S): WELLS, PAUL W., Smith, Catherine D

PRINTED: 22-NOV-89  
 PAGE: 1

STUDY START DATE: 23-JAN-84  
 STUDY TYPE: CHRONIC/2 YR CARCINOGENIC

NOTES: ANIMALS = ALL DEAD FROM 30-JAN-85 TO 15-FEB-86  
 CTLS = CONTROLS FROM GROUP(S): 3

ANIMAL SEX:  
 DOSAGE GROUP: CTLS 1 2  
 NO. IN GROUP: 57 50 55

--- M A L E S --- F E M A L E S ---  
 --- A F F E C T E D ---  
 --- C T L S ---

T I S S U E S	W I T H	F I N D I N G S	N O.	I N	G R O U P	N U M B E R	E X A M I N E D	N U M B E R	E X A M I N E D	N U M B E R	E X A M I N E D
BRAIN			57	50	55	51	40	52	51	40	52
-B- ASTROCYTOMA			1	0	0	0	0	0	0	0	0
-I- PITUITARY TUMOR INVASION			1	0	1	0	1	4	0	1	4
-M- LARGE GRANULE LYMPHOCYTE LEUKEMIA, METASTATIC			0	1	0	0	0	0	0	0	0
TRACHEA			57	49	55	50	40	52	50	40	52
-M- PRESENCE OF METASTATIC NEOPLASM			0	0	0	1	0	0	1	0	0
THYROID GLANDS			57	47	53	50	37	47	50	37	47
-B- ADENOMA, FOLLICULAR			0	0	1	0	0	0	0	0	0
-B- PARA-FOLLICULAR CELL ADENOMA			11	9	10	6	8	5	6	8	5
-M- PARA-FOLLICULAR CELL ADENOCARCINOMA			0	0	0	2	0	1	2	0	1
-M- FOLLICULAR ADENOCARCINOMA			0	0	1	0	0	0	0	0	0
PARATHYROID			48	38	45	45	31	37	45	31	37
ESOPHAGUS			57	50	55	50	40	51	50	40	51
SALIVARY GLAND			57	50	55	51	39	50	51	39	50
-M- ADENOCARCINOMA			0	0	0	1	0	0	1	0	0
LACRIMAL GLAND			57	50	55	51	40	52	51	40	52
EXORBITAL LACRIM			54	47	53	49	38	50	49	38	50
HEART			57	50	55	51	40	52	51	40	52
-M- ATRIO-CAVAL EPITHELIAL MESOTHELIOMA			0	0	0	0	0	0	0	0	0
-M- LARGE GRANULAR LYMPHOCYTE LEUKEMIA, METASTATIC			0	3	2	0	0	1	0	0	1
-M- PRESENCE OF METASTATIC NEOPLASM			0	0	0	0	0	1	0	0	1
AORTA			57	50	55	51	40	52	51	40	52
LUNGS			57	50	55	51	40	52	51	40	52
-M- LARGE GRANULAR LYMPHOCYTE LEUKEMIA, METASTATIC			3	7	13	10	4	8	10	4	8
-M- PRESENCE OF METASTATIC NEOPLASM			0	0	0	1	1	1	1	1	1
-B- BRONCHIOLAR/ALVEOLAR ADENOMA			1	1	1	0	0	0	0	0	0
-M- PRESENCE OF METASTATIC SARCOMA			0	1	0	0	1	0	0	1	0

NOTE: ENTRIES FLAGGED WITH A - (MINUS) ARE SIGNIFICANTLY DIFFERENT FROM CONTROL AT THE 0.05 LEVEL USING KOLMOGOROV-SHIRNOV TWO-TAILED TEST.

**Appendix B (cont.): MICROSCOPIC OBSERVATIONS, INCIDENCE SUMMARY**

LETTERMAN ARMY INSTITUTE OF RESEARCH INCIDENCE SUMMARY OF MICROSCOPIC OBSERVATIONS (ALL NEOPLASMS) PRINTED: 22-NOV-89  
 DIV OF RES SUPP, PATH SERV GP STUDY NUMBER: GLP83009 PAGE: 2  
 PRESIDIO OF SAN FRANCISCO, CA 94129 PATHOLOGIST(S): MELLICK, PAUL W., Smith, Catherine D  
 SPECIES: RAT/FISCHER-344 STUDY START DATE: 23-JAN-84 STUDY TYPE: CHRONIC/2 YR CARCINOGENIC

NOTES: ANIMALS = ALL DEAD FROM 30-JAN-85 TO 15-FEB-86  
 CTLS = CONTROLS FROM GROUP(S): 3 ANIMAL SEX: -- A N I M A L S A F F E C T E D --  
 T I S S U E S W I T H F I N D I N G S NO. IN GROUP: -- MALES -- -- FEMALES --  
 CTLS 1 2 CTLS 1 2  
 57 50 55 51 40 52

THYMUS ..... NUMBER EXAMINED: 56 47 50 48 38 45  
 -M- LARGE GRANULAR LYMPHOCYTE LEUKEMIA, METASTATIC 2 4 1 2 0 2  
 -B- ADENOMA, ENDOCRINE ORIGIN, NOT OTHERWISE SPECIFIED 1 0 0 0 0 0  
 -B- THYMOMA 1 0 0 0 0 0  
 -M- ADENOCARCINOMA, NOT OTHERWISE SPECIFIED, SITE OF ORIGIN 0 0 1 0 0 0  
 UNDETERMINED

SPLEEN ..... NUMBER EXAMINED: 57 49 54 51 40 52  
 -M- LARGE GRANULAR LYMPHOCYTE LEUKEMIA, METASTATIC 5 10 16 14 7 11  
 -M- PRESENCE OF METASTATIC SARCOMA 0 2 2 0 1 0  
 -M- PRESENCE OF METASTATIC NEOPLASM 0 0 1 0 0 1

LYMPH NODES ..... NUMBER EXAMINED: 57 49 55 51 40 51  
 -M- LARGE GRANULAR LYMPHOCYTE LEUKEMIA, METASTATIC 3 7 10 7 3 9  
 -M- PRESENCE OF METASTATIC NEOPLASM 1 0 0 1 1 0  
 -M- PRESENCE OF METASTATIC SARCOMA 0 0 0 0 2 0

LIVER ..... NUMBER EXAMINED: 57 50 55 51 40 52  
 -M- LARGE GRANULAR LYMPHOCYTE LEUKEMIA, METASTATIC 4 8 15 14 6 11  
 -M- PRESENCE OF METASTATIC SARCOMA 0 12 3 0 12 0  
 -M- HEPATOCELLULAR CARCINOMA 0 0 2 0 2 0  
 -M- PRESENCE OF METASTATIC NEOPLASM 0 0 0 0 0 1

KIDNEY ..... NUMBER EXAMINED: 57 49 55 51 40 51  
 -M- SARCOMA NOT OTHERWISE SPECIFIED 1 0 0 0 0 0  
 -M- LARGE GRANULAR LYMPHOCYTE LEUKEMIA, METASTATIC 0 4 2 0 0 0  
 -M- PRESENCE OF METASTATIC SARCOMA 0 0 1 0 0 0  
 -M- PRESENCE OF METASTATIC NEOPLASM 0 0 0 0 1 0

URINARY BLADDER ..... NUMBER EXAMINED: 56 48 53 49 39 48  
 -B- TRANSITIONAL CELL PAPILLOMA 0 0 0 0 1 0

UTERUS ..... NUMBER EXAMINED: 51 40 51  
 -M- ENDOMETRIAL SARCOMA 2 1 0  
 -M- LARGE GRANULE LYMPHOCYTE LEUKEMIA, METASTATIC 0 0 2  
 -M- LEIOMYOSARCOMA 0 1 0

NOTE: ENTRIES FLAGGED WITH A - (MINUS) ARE SIGNIFICANTLY DIFFERENT FROM CONTROL AT THE 0.05 LEVEL USING KOLMOGOROV-SMIRNOV TWO-TAILED TEST.



**Appendix H (cont.): MICROSCOPIC OBSERVATIONS, INCIDENCE SUMMARY**

LETTERMAN ARMY INSTITUTE OF RESEARCH  
 DIV OF RES SUPP, PATH SERV GP  
 PRESIDIO OF SAN FRANCISCO, CA 94129  
 SPECIES: RAT/FISCHER-344

INCIDENCE SUMMARY OF MICROSCOPIC OBSERVATIONS (ALL NEOPLASMS)  
 STUDY NUMBER: GLP83009  
 PATHOLOGIST(S): MELLICK, PAUL W., Smith, Catherine D  
 STUDY START DATE: 23-JAN-84

PRINTED: 22-NOV-89  
 PAGE: 3

STUDY TYPE: CHRONIC/2 YR CARCINOGENIC

NOTES: ANIMALS = ALL DEAD FROM 30-JAN-85 TO 15-FEB-86  
 CTL5 = CONTROLS FROM GROUP(S): 3

T I S U E S	W I T H F I N D I N G S		A N I M A L S A F F E C T E D	
	CTL5	NO. IN GROUP	MALES	FEMALES
PROSTATE	57	48	55	
-M- PRESENCE OF METASTATIC SARCOMA	0	0	1	
COAG GL	56	47	55	
SEMINAL VESICLE	57	49	54	
-M- PRESENCE OF METASTATIC SARCOMA	0	0	1	
EDIDIDYMIS	57	49	54	
-M- PRESENCE OF METASTATIC SARCOMA	0	1	1	
TESTES	57	50	55	
-B-MESOTHELIOMA	1	0	0	
-B- INTERSTITIAL CELL ADENOMA	51	43	47	
-M- PRESENCE OF METASTATIC SARCOMA	0	0	1	
-M- PRESENCE OF METASTATIC NEOPLASM	0	0	1	
OVARIES	57	47	55	
-M- LARGE GRANULE LYMPHOCYTE LEUKEMIA, METASTATIC	0	3	0	
-M- PRESENCE OF METASTATIC NEOPLASM	0	0	0	
DUODENUM	57	48	55	
-M- PRESENCE OF METASTATIC SARCOMA	0	3	0	
-M- PRESENCE OF METASTATIC NEOPLASM	0	0	0	
JEJUNUM	57	48	55	
-M- PRESENCE OF METASTATIC SARCOMA	0	2	2	
-M- PRESENCE OF METASTATIC NEOPLASM	0	0	0	
ILEUM	57	46	53	
-M- LARGE GRANULAR LYMPHOCYTE LEUKEMIA, METASTATIC	1	2	1	
-M- PRESENCE OF METASTATIC SARCOMA	0	3	0	
-M- PRESENCE OF METASTATIC NEOPLASM	0	0	0	
PANCREAS	57	48	55	
-B- ISLET CELL ADENOMA	6	6	8	
-M- PRESENCE OF METASTATIC SARCOMA	0	3	1	
-M- LARGE GRANULAR LYMPHOCYTE LEUKEMIA, METASTATIC	0	1	3	
-M- PRESENCE OF METASTATIC NEOPLASM	0	0	0	

NOTE: ENTRIES FLAGGED WITH A - (MINUS) ARE SIGNIFICANTLY DIFFERENT FROM CONTROL AT THE 0.05 LEVEL USING KOLMOGOROV-SMIRNOV TWO-TAILED TEST.

**Appendix H (cont.): MICROSCOPIC OBSERVATIONS, INCIDENCE SUMMARY**

LETTERMAN ARMY INSTITUTE OF RESEARCH INCIDENCE SUMMARY OF MICROSCOPIC OBSERVATIONS(ALL NEOPLASMS) PRINTED: 22-NOV-89  
 DIV OF RES SUPP, PATH SERV GP STUDY NUMBER: GLP83009 PAGE: 4  
 PRESIDIO OF SAN FRANCISCO, CA 94129 PATHOLOGIST(S): MELLICK, PAUL W., Smith, Catherine D  
 SPECIES: RAT/FISCHER-344 STUDY START DATE: 23-JAN-84 STUDY TYPE: CHRONIC/2 YR CARCINOGENIC

NOTES: ANIMALS = ALL DEAD FROM 30-JAN-85 TO 15-FEB-86  
 CTLS = CONTROLS FROM GROUP(S): 3 ANIMAL SEX: A F F E C T E D  
 CTLS WITH FINDINGS NO. IN GROUP: 57 50 55 -- MALES -- CTLS 1 2 -- FEMALES --  
 51 40 52

T I S S U E S	W I T H	F I N D I N G S	NO. IN GROUP:	57	50	55	CTLS	1	2	51	40	52
CECUM	.....	NUMBER EXAMINED:	56	45	54	48	40	47				
-N- PRESENCE OF METASTATIC SARCOMA	.....		0	1	0	0	0	0				
-B- ADENOMATOUS POLYP	.....		0	0	0	1	0	0				
RECTUM	.....	NUMBER EXAMINED:	56	44	54	49	37	48				
-I- FIBROSARCOMA, LOCALLY INVASIVE	.....		0	0	0	1	1	1				
COLON	.....	NUMBER EXAMINED:	57	46	54	50	39	50				
-N- PRESENCE OF METASTATIC SARCOMA	.....		0	1	0	0	0	0				
-B- POLYP, CYSTIC, WITH MUCINOUS EPITHELIAL HYPERPLASIA AND OSSEOUS METAPLASIA AND/OR MINERALIZATION OF STROMA	.....		0	2	0	0	0	0				
STOMACH	.....	NUMBER EXAMINED:	57	49	55	50	40	51				
-N- LARGE GRANULE LYMPHOCYTE LEUKEMIA, METASTATIC	.....		0	2	0	0	0	0				
-M- PRESENCE OF METASTATIC SARCOMA	.....		0	1	1	0	2	0				
-B- SQUAMOUS CELL PAPILLOMA	.....		0	1	0	0	0	0				
SKELETAL MUSCLE	.....	NUMBER EXAMINED:	57	49	54	51	40	49				
SCIATIC NERVE	.....	NUMBER EXAMINED:	56	42	52	51	39	44				
TONGUE	.....	NUMBER EXAMINED:	56	50	54	51	40	52				
SKIN	.....	NUMBER EXAMINED:	55	47	50	51	39	52				
-B- KERATOACANTHOMA, ANATOMIC SITE TO BE SPECIFIED	.....		1	1	0	1	2	1				
-B- BASAL CELL TUMOR	.....		1	0	1	0	0	0				
-M- BASAL CELL CARCINOMA	.....		1	0	0	0	0	0				
-B- FIBROMA	.....		3	3	1	1	0	0				
-B- SQUAMOUS PAPILLOMA	.....		1	0	1	0	0	0				
-B- PREPUTIAL GLAND ADENOMA	.....		1	0	0	0	0	0				
-B- CLITORAL GLAND ADENOMA	.....		0	0	0	2	1	0				
-M- NEUROFIBROSARCOMA, SUBCUTANEOUS, LOCATION TO BE SPECIFIED	.....		0	0	2	0	0	0				
-M- FIBROSARCOMA	.....		0	0	0	1	1	2				
MAMMARY GLANDS	.....	NUMBER EXAMINED:	53	48	50	49	40	51				
-B- FIBROADENOMA	.....		1	0	0	5	4	2				
-M- MAMMARY ADENOCARCINOMA	.....		0	0	0	1	1	2				

NOTE: ENTRIES FLAGGED WITH A - (MINUS) ARE SIGNIFICANTLY DIFFERENT FROM CONTROL AT THE 0.05 LEVEL USING KOLMOGOROV-SMIRNOV TWO-TAILED TEST.

**Appendix B (cont.): MICROSCOPIC OBSERVATIONS, INCIDENCE SUMMARY**

LETTERMAN ARMY INSTITUTE OF RESEARCH INCIDENCE SUMMARY OF MICROSCOPIC OBSERVATIONS(ALL NEOPLASMS) PRINTED: 22-NOV-69  
 DIV OF RES SUPP, PATH SERV GP STUDY NUMBER: GLP83009 PAGE: 5  
 PRESIDIO OF SAN FRANCISCO, CA 94129 PATHOLOGIST(S): MELLICK, PAUL W., Smith, Catherine D  
 SPECIES: RAT/FISCHER-344 STUDY START DATE: 23-JAN-84 STUDY TYPE: CHRONIC/2 YR CARCINOGENIC

NOTES: ANIMALS = ALL DEAD FROM 30-JAN-85 TO 15-FEB-86  
 CTLs = CONTROLS FROM GROUP(S): 3  
 --- A M I M A L S A F F E C T E D ---  
 --- MALES --- FEMALES ---  
 T I S S U E S W I T H F I N D I N G S N O . I N G R O U P : C T L S 1 2 C T L S 1 2  
 57 50 55 57 50 55 51 40 52

TISSUES WITH FINDINGS	NO. IN GROUP	NUMBER EXAMINED	MALES	FEMALES
NOSE/TURBINATES	57 49 53	57 49 53	51	40 52
BONE, STERNUM	57 50 55	57 50 55	50	38 51
-N- LARGE GRANULE LYMPHOCYTE LEUKEMIA, METASTATIC	0 4 2	0 4 2	0	0 1
BONE, FEMUR	57 48 55	57 48 55	51	40 51
-N- LARGE GRANULE LYMPHOCYTE LEUKEMIA, METASTATIC	0 4 2	0 4 2	0	0 1
BONE VERT	57 50 55	57 50 55	51	40 52
-N- LARGE GRANULE LYMPHOCYTE LEUKEMIA, METASTATIC	4 3	4 3	0	0 1
SPINAL CORD	56 50 55	56 50 55	51	40 52
ADRENAL	57 50 55	57 50 55	51	40 50
-B- CORTICAL ADENOMA	1 0 0	1 0 0	1	0 1
-M- MEDULLARY CARCINOMA	1 0 0	1 0 0	0	0 0
-B- PHEOCHROMOCYTOMA	6 2 3	6 2 3	1	0 1
-N- LARGE GRANULE LYMPHOCYTE LEUKEMIA, METASTATIC	1 2 2	1 2 2	0	1 3
PITUITARY GLAND	54 46 55	54 46 55	50	40 47
-B- ADENOMA	38 24 28	38 24 28	30	22 23
-M- ADENOCARCINOMA	1 0 0	1 0 0	0	0 0
-N- LARGE GRANULE LYMPHOCYTE LEUKEMIA, METASTATIC	1 0 2	1 0 2	0	0 0
EYES & OPTIC N.	57 46 55	57 46 55	48	37 51
EAR	56 49 54	56 49 54	51	40 52
-M- FIBROSARCOMA, SUBCUTANEOUS, EXTERNAL EAR, ADJACENT TO EAR TAG	0 1 0	0 1 0	0	0 0
-I- PITUITARY TUMOR INVASION	0 0 1	0 0 1	0	0 0
AD SEBACIOUS	56 49 53	56 49 53	50	38 51
ABDOMINAL WALL	0 0 0	0 0 0	0	0 0
THORAX	0 0 0	0 0 0	0	2 0
-N- PRESENCE OF METASTATIC SARCOMA IN THORACIC WALL.	0 0 0	0 0 0	0	0 1 0

NOTE: ENTRIES FLAGGED WITH A - (MINUS) ARE SIGNIFICANTLY DIFFERENT FROM CONTROL AT THE 0.05 LEVEL USING KOLMOGOROV-SMIRNOV TWO-TAILED TEST.

**Appendix H (cont.): MICROSCOPIC OBSERVATIONS, INCIDENCE SUMMARY**

LETTERMAN ARMY INSTITUTE OF RESEARCH INCIDENCE SUMMARY OF MICROSCOPIC OBSERVATIONS(ALL NEOPLASMS) PRINTED: 22-NOV-89  
 DIV OF RES SUPP, PATH SERV GP STUDY NUMBER: GLP83009 PAGE: 6  
 PRESIDIO OF SAN FRANCISCO, CA 94129 PATHOLOGIST(S): MELLICK, PAUL W., Smith, Catherine D  
 SPECIES: RAT/FISCHER-344 STUDY START DATE: 23-JAN-84 STUDY TYPE: CHRONIC/2 YR CARCINOGENIC

NOTES: ANIMALS = ALL DEAD FROM 30-JAN-85 TO 15-FEB-86  
 CTLS = CONTROLS FROM GROUP(S): 3  
 --- ANIMALS AFFECTED ---  
 --- MALES ---  
 CTLS 1 2  
 57 50 55  
 --- FEMALES ---  
 CTLS 1 2  
 51 40 52

T I S S U E S	W I T H	F I N D I N G S	ANIMAL SEX:	DOSE GROUP:	NO. IN GROUP:	NUMBER EXAMINED:	NUMBER EXAMINED:	NUMBER EXAMINED:	NUMBER EXAMINED:	NUMBER EXAMINED:	CTLS	CTLS
WHOLE BODY						57	50	54			51	40
-W-		GRANULAR LYMPHOCYTTIC LEUKEMIA				5	10	16			14	6
MED ASTINUM						4	6	2			1	2
-W-		PRESENCE OF METASTATIC SARCOMA				0	4	0			0	2
-W-		PRESENCE OF METASTATIC NEOPLASM				0	0	0			0	0
ABDOMINAL CAVITY						0	16	9			0	12
-W-		SARCOMA, CELLULAR DIFFERENTIATION UNSPECIFIED				0	15	4			0	12
-W-		MESOTHELIOMA				0	0	1			0	0
-B-		LIPOMA				0	0	1			0	0
DIAPHRAGM						0	42	19			0	40
-W-		PRESENCE OF METASTATIC SARCOMA				0	8	2			0	10
-W-		PRESENCE OF METASTATIC NEOPLASM				0	0	0			0	2

NOTE: ENTRIES FLAGGED WITH A - (MINUS) ARE SIGNIFICANTLY DIFFERENT FROM CONTROL AT THE 0.05 LEVEL USING KOLMOGOROV-SHIRNOV TWO-TAILED TEST.

**Appendix B (cont.): MICROSCOPIC OBSERVATIONS, INCIDENCE SUMMARY**

LETTERMAN ARMY INSTITUTE OF RESEARCH INCIDENCE SUMMARY OF MICROSCOPIC OBSERVATIONS(MALIGNANT NEOPLASMS) PRINTED: 22-NOV-89  
 DIV OF RES SUPP, PATH SERV GP STUDY NUMBER: GLP83009 PAGE: 1  
 PRESIDIO OF SAN FRANCISCO, CA 94129 PATHOLOGIST(S): MELLICK, PAUL W., Smith, Catherine D  
 SPECIES: RAT/FISCHER-344 STUDY START DATE: 23-JAN-84 STUDY TYPE: CHRONIC/2 YR CARCINOGENIC

NOTES: ANIMALS = ALL DEAD FROM 30-JAN-85 TO 15-FEB-86  
 CTL5 = CONTROLS FROM GROUP(S): 3 ANIMAL SEX: -- A N I M A L S A F F E C T E D --  
 T I S S U E S W I T H F I N D I N G S NO. IN GROUP: CTL5 1 2 -- MALES -- CTL5 1 2 -- FEMALES --  
 57 50 55 57 50 55 51 40 52

Tissue	Number Examined	Number with Finding	Number with Finding (%)
BRAIN	57	50	88
-I-PITUITARY TUMOR INVASION	1	0	0
-M- LARGE GRANULE LYMPHOCYTE LEUKEMIA, METASTATIC	0	1	100
TRACHEA	57	49	86
-M- PRESENCE OF METASTATIC NEOPLASM	0	0	0
THYROID GLANDS	57	47	83
-M- PARA-FOLLICULAR CELL ADENOCARCINOMA	0	0	0
-M- FOLLICULAR ADENOCARCINOMA	0	0	0
PARATHYROID	48	38	79
ESOPHAGUS	57	50	88
SALIVARY GLAND	57	50	88
-M- ADENOCARCINOMA	0	0	0
LACRIMAL GLAND	57	50	88
EXORBITAL LACRIM	54	47	87
HEART	57	50	88
-M- ATRIO-CAVAL EPITHELIAL MESOTHELIOMA	0	0	0
-M- LARGE GRANULAR LYMPHOCYTE LEUKEMIA, METASTATIC	0	3	5
-M- PRESENCE OF METASTATIC NEOPLASM	0	0	0
AORTA	57	50	88
LUNGS	57	50	88
-M- LARGE GRANULAR LYMPHOCYTE LEUKEMIA, METASTATIC	3	7	13
-M- PRESENCE OF METASTATIC NEOPLASM	0	0	0
-M- PRESENCE OF METASTATIC SARCOMA	0	1	2
THYRUS	56	47	84
-M- LARGE GRANULAR LYMPHOCYTE LEUKEMIA, METASTATIC	2	4	7
-M- ADENOCARCINOMA, NOT OTHERWISE SPECIFIED, SITE OF ORIGIN UNDETERMINED	0	0	0

NOTE: ENTRIES FLAGGED WITH A - (MINUS) ARE SIGNIFICANTLY DIFFERENT FROM CONTROL AT THE 0.05 LEVEL USING KOLMOGOROV-SMIRNOV TWO-TAILED TEST.

**Appendix B (cont.): MICROSCOPIC OBSERVATIONS, INCIDENCE SUMMARY**

LETTERMAN ARMY INSTITUTE OF RESEARCH  
 DIV OF RES SUPP, PATM SERV GP  
 PIEDMONT OF SAN FRANCISCO, CA 94129  
 SPECIES: RAT/FISCHER-344

INCIDENCE SUMMARY OF MICROSCOPIC OBSERVATIONS (MALIGNANT NEOPLASMS)  
 STUDY NUMBER: GLP83009  
 PATHOLOGIST(S): MELLICK, PAUL W., Smith, Catherine D  
 STUDY START DATE: 23-JAN-84  
 STUDY TYPE: CHRONIC/2 YR CARCINOGENIC

PRINTED: 22-NOV-89  
 PAGE: 2

NOTES: ANIMALS = ALL DEAD FROM 30-JAN-85 TO 15-FEB-86  
 CTLs = CONTROLS FROM GROUP(S): 3  
 ANIMAL SEX: --- ANIMALS AFFECTED ---  
 --- MALES --- FEMALES ---  
 CTLs 1 2 CTLs 1 2  
 DOSAGE GROUP: 57 50 55 51 40 52  
 NO. IN GROUP: 57 50 55 51 40 52

T I S S U E S	W I T H	F I N D I N G S	NUMBER EXAMINED:	NUMBER EXAMINED:	NUMBER EXAMINED:	NUMBER EXAMINED:	NUMBER EXAMINED:	NUMBER EXAMINED:	NUMBER EXAMINED:
SPLEEN			57	49	54	51	40	52	
-N- LARGE GRANULAR LYMPHOCYTE LEUKEMIA, METASTATIC			5	10	16	14	7	11	
-N- PRESENCE OF METASTATIC SARCOMA			0	2	2	0	1	0	
-N- PRESENCE OF METASTATIC NEOPLASM			0	0	1	0	0	1	
LYMPH NODES			57	49	55	51	40	51	
-N- LARGE GRANULAR LYMPHOCYTE LEUKEMIA, METASTATIC			3	7	10	7	3	9	
-N- PRESENCE OF METASTATIC NEOPLASM			1	0	0	1	1	0	
-N- PRESENCE OF METASTATIC SARCOMA			0	0	0	0	0	0	
LIVER			57	50	55	51	40	52	
-N- LARGE GRANULAR LYMPHOCYTE LEUKEMIA, METASTATIC			4	8	15	14	6	11	
-N- PRESENCE OF METASTATIC SARCOMA			0	12	3	0	12	0	
-N- HEPATOCELLULAR CARCINOMA			0	0	2	0	2	0	
-N- PRESENCE OF METASTATIC NEOPLASM			0	0	0	0	0	1	
KIDNEY			57	49	55	51	40	51	
-N- SARCOMA NOT OTHERWISE SPECIFIED			1	0	0	0	0	0	
-N- LARGE GRANULAR LYMPHOCYTE LEUKEMIA, METASTATIC			0	4	2	0	0	0	
-N- PRESENCE OF METASTATIC SARCOMA			0	0	1	0	0	0	
-N- PRESENCE OF METASTATIC NEOPLASM			0	0	0	0	0	1	
URINARY BLADDER			56	48	53	49	39	48	
UTERUS									
-N- ENDOMETRIAL SARCOMA						51	40	51	
-N- LARGE GRANULE LYMPHOCYTE LEUKEMIA, METASTATIC						2	1	0	
-N- LEIOMYOSARCOMA						0	0	2	
PROSTATE			57	48	55				
-N- PRESENCE OF METASTATIC SARCOMA			0	0	1				
COAG GL			56	47	55				
SEMINAL VESICLE			57	49	54				
-N- PRESENCE OF METASTATIC SARCOMA			0	0	1				

NOTE: ENTRIES FLAGGED WITH A - (MINUS) ARE SIGNIFICANTLY DIFFERENT FROM CONTROL AT THE 0.05 LEVEL USING KOLMOGOROV-SMIRNOV TWO-TAILED TEST.

**Appendix H (cont.): MICROSCOPIC OBSERVATIONS, INCIDENCE SUMMARY**

LETTERMAN ARMY INSTITUTE OF RESEARCH INCIDENCE SUMMARY OF MICROSCOPIC OBSERVATIONS(MALIGNANT NEOPLASMS) PRINTED: 22-NOV-89  
 DIV OF RES SUPP, PATH SERV GP STUDY NUMBER: GLP83009 PAGE: 3  
 PRESIDIO OF SAN FRANCISCO, CA 94129 PATHOLOGIST(S): MELLICK, PAUL W., Smith, Catherine D  
 SPECIES: RAT/FISCHER-344 STUDY START DATE: 23-JAN-84 STUDY TYPE: CHRONIC/2 YR CARCINOGENIC

NOTES: ANIMALS = ALL DEAD FROM 30-JAN-85 TO 15-FEB-86  
 CTLs = CONTROLS FROM GROUP(S): 3 ANIMAL SEX: -- A N I M A L S A F F E C T E D --  
 -- MALES -- -- FEMALES --  
 T I S S U E S W I T H F I N D I N G S NO. IN GROUP: CTLs 1 2 CTLs 1 2  
 57 50 55 57 50 55

EDIDYDYMIS	NUMBER EXAMINED:	57	49	54
-N- PRESENCE OF METASTATIC SARCOMA		0	1	1
TESTES	NUMBER EXAMINED:	57	50	55
-N- PRESENCE OF METASTATIC SARCOMA		0	0	1
-N- PRESENCE OF METASTATIC NEOPLASM		0	0	1
OVARIES	NUMBER EXAMINED:	51	40	51
-N- LARGE GRANULE LYMPHOCYTE LEUKEMIA, METASTATIC		0	0	2
-N- PRESENCE OF METASTATIC NEOPLASM		0	0	1
DUODENUM	NUMBER EXAMINED:	57	47	55
-N- PRESENCE OF METASTATIC SARCOMA		0	3	0
-N- PRESENCE OF METASTATIC NEOPLASM		0	0	0
JEJUNUM	NUMBER EXAMINED:	57	48	55
-N- PRESENCE OF METASTATIC SARCOMA		0	2	2
-N- PRESENCE OF METASTATIC NEOPLASM		0	0	0
ILEUM	NUMBER EXAMINED:	57	46	53
-N- LARGE GRANULAR LYMPHOCYTE LEUKEMIA, METASTATIC		1	2	1
-N- PRESENCE OF METASTATIC SARCOMA		0	3	0
-N- PRESENCE OF METASTATIC NEOPLASM		0	0	0
PANCREAS	NUMBER EXAMINED:	57	48	55
-N- PRESENCE OF METASTATIC SARCOMA		0	3	1
-N- LARGE GRANULAR LYMPHOCYTE LEUKEMIA, METASTATIC		0	1	3
-N- PRESENCE OF METASTATIC NEOPLASM		0	0	1
CECUM	NUMBER EXAMINED:	56	45	54
-N- PRESENCE OF METASTATIC SARCOMA		0	1	0
RECTUM	NUMBER EXAMINED:	56	44	54
-I- FIBROSARCOMA, LOCALLY INVASIVE		0	0	0
COLON	NUMBER EXAMINED:	57	46	54
-N- PRESENCE OF METASTATIC SARCOMA		0	1	0

NOTE: ENTRIES FLAGGED WITH A - (MINUS) ARE SIGNIFICANTLY DIFFERENT FROM CONTROL AT THE 0.05 LEVEL USING KOLMOGOROV-SMIRNOV TWO-TAILED TEST.

**Appendix H (cont.): MICROSCOPIC OBSERVATIONS, INCIDENCE SUMMARY**

LETTERMAN ARMY INSTITUTE OF RESEARCH DIV OF RES SUPP, PAIN SERV GP PRESIDIO OF SAN FRANCISCO, CA 94129 SPECIES: RAT/FISCHER-344  
 INCIDENCE SUMMARY OF MICROSCOPIC OBSERVATIONS(MALIGNANT NEOPLASMS) STUDY NUMBER: GLP83009 PATHOLOGIST(S): MELLICK, PAUL W., Smith, Catherine D  
 PRINTED: 22-NOV-89 PAGE: 4  
 STUDY START DATE: 23-JAN-84 STUDY TYPE: CHRONIC/2 YR CARCINOGENIC

NOTES: ANIMALS = ALL DEAD FROM 30-JAN-85 TO 15-FEB-86  
 CTL5 = CONTROLS FROM GROUP(S): 3  
 T I S S U E S W I T H F I N D I N G S  
 --- ANIMALS AFFECTED ---  
 --- MALES ---  
 CTL5 1 2  
 57 50 55  
 --- FEMALES ---  
 CTL5 1 2  
 51 40 52

T I S S U E S	W I T H	F I N D I N G S	ANIMAL SEX	NUMBER EXAMINED	MALES	FEMALES
			ANIMAL SEX	NUMBER EXAMINED	MALES	FEMALES
			DOSAGE GROUP	NUMBER EXAMINED	MALES	FEMALES
			NO. IN GROUP	NUMBER EXAMINED	MALES	FEMALES
STOMACH				57	49	55
-N- LARGE GRANULE LYMPHOCYTE LEUKEMIA, METASTATIC				0	2	0
-N- PRESENCE OF METASTATIC SARCOMA				0	1	1
SKELETAL MUSCLE				57	49	54
SCIATIC NERVE				56	42	52
TONGUE				56	50	54
SKIN				55	47	50
-N- BASAL CELL CARCINOMA				1	0	0
-N- NEUROFIBROSARCOMA, SUBCUTANEOUS, LOCATION TO BE SPECIFIED				0	0	2
-N- FIBROSARCOMA				0	0	0
MAMMARY GLANDS				53	48	50
-N- MAMMARY ADENOCARCINOMA				0	0	0
NOSE/TURBINATES				57	49	53
BONE, STERNUM				57	50	55
-N- LARGE GRANULE LYMPHOCYTE LEUKEMIA, METASTATIC				0	4	2
BONE, FEMUR				57	48	55
-N- LARGE GRANULE LYMPHOCYTE LEUKEMIA, METASTATIC				0	4	2
BONE VERT				57	50	55
-N- LARGE GRANULE LYMPHOCYTE LEUKEMIA, METASTATIC				0	4	3
SPINAL CORD				56	50	55
ADRENAL				57	50	55
-N- MEDULLARY CARCINOMA				1	0	0
-N- LARGE GRANULE LYMPHOCYTE LEUKEMIA, METASTATIC				1	2	2
PITUITARY GLAND				54	46	55
-N- ADENOCARCINOMA				1	0	0
-N- LARGE GRANULE LYMPHOCYTE LEUKEMIA, METASTATIC				1	0	2

NOTE: ENTRIES FLAGGED WITH A - (MINUS) ARE SIGNIFICANTLY DIFFERENT FROM CONTROL AT THE 0.05 LEVEL USING KOLMOGOROV-SMIRNOV TWO-TAILED TEST.



**Appendix B (cont.): MICROSCOPIC OBSERVATIONS, INCIDENCE SUMMARY**

LETTERMAN ARMY INSTITUTE OF RESEARCH INCIDENCE SUMMARY OF MICROSCOPIC OBSERVATIONS (MALIGNANT NEOPLASMS) PRINTED: 22-NOV-89  
 DIV OF RES SUPP, PATH SERV GP STUDY NUMBER: GLP83009 PAGE: 5  
 PRESIDIO OF SAN FRANCISCO, CA 94129 PATHOLOGIST(S): WELICK, PAUL M., Smith, Catherine D  
 SPECIES: RAT/FISCHER-344 STUDY START DATE: 23-JAN-84 STUDY TYPE: CHRONIC/2 YR CARCINOGENIC

NOTES: ANIMALS = ALL DEAD FROM 30-JAN-85 TO 15-FEB-86  
 CTLS = CONTROLS FROM GROUP(S): 3  
 T I S S U E S W I T H F I N D I N G S

	--- M A L E S ---		--- F E M A L E S ---	
	CTLS	NO. IN GROUP	CTLS	NO. IN GROUP
---	57	50	51	40
---	55	55	52	52

	NUMBER EXAMINED:	57	46	55	48	37	51
EYES & OPTIC N.	NUMBER EXAMINED:	57	46	55	48	37	51
EAR	NUMBER EXAMINED:	56	49	54	51	40	52
-M- FIBROSARCOMA, SUBCUTANEOUS, EXTERNAL EAR, ADJACENT TO EAR TAG		0	1	0	0	0	0
-1- PITUITARY TUMOR INVASION		0	0	1	0	0	0
AD SEBACEOUS	NUMBER EXAMINED:	56	49	53	50	38	51
ABDOMINAL WALL	NUMBER EXAMINED:	0	0	0	0	0	0
THORAX	NUMBER EXAMINED:	0	0	0	0	2	0
-M- PRESENCE OF METASTATIC SARCOMA IN THORACIC WALL.		0	0	0	0	1	0
WHOLE BODY	NUMBER EXAMINED:	57	50	54	51	40	52
-M- LARGE GRANULAR LYMPHOCTIC LEUKEMIA		5	10	16	14	6	11
MEDIASTINUM	NUMBER EXAMINED:	4	6	2	1	2	2
-M- PRESENCE OF METASTATIC SARCOMA		0	4	0	0	2	0
-M- PRESENCE OF METASTATIC NEOPLASM		0	0	0	0	0	1
ABDOMINAL CAVITY	NUMBER EXAMINED:	0	16	9	0	12	1
-M- SARCOMA, CELLULAR DIFFERENTIATION UNSPECIFIED		0	15	4	0	12	0
-M- MESOTHELIOMA		0	0	1	0	0	1
DIAPHRAGM	NUMBER EXAMINED:	0	42	19	0	40	25
-M- PRESENCE OF METASTATIC SARCOMA		0	8	2	0	10	0
-M- PRESENCE OF METASTATIC NEOPLASM		0	0	0	0	2	0

NOTE: ENTRIES FLAGGED WITH A - (MINUS) ARE SIGNIFICANTLY DIFFERENT FROM CONTROL AT THE 0.05 LEVEL USING KOLMOGOROV-SMIRNOV TWO-TAILED TEST.

**Appendix H (cont.): MICROSCOPIC OBSERVATIONS, INCIDENCE SUMMARY**

LETTERMAN ARMY INSTITUTE OF RESEARCH INCIDENCE SUMMARY OF MICROSCOPIC OBSERVATIONS (BENIGN NEOPLASMS) PRINTED: 22-NOV-89  
 DIV OF RES SUPP, PATH SERV GP STUDY NUMBER: GLP83009 PAGE: 1  
 PRESIDIO OF SAN FRANCISCO, CA 94129 PATHOLOGIST(S): MELLICK, PAUL W., Smith, Catherine D  
 SPECIES: RAT/FISCHER-344 STUDY START DATE: 23-JAN-84 STUDY TYPE: CHRONIC/2 YR CARCINOGENIC

NOTES: ANIMALS = ALL DEAD FROM 30-JAN-85 TO 15-FEB-86  
 CTLs = CONTROLS FROM GROUP(S): 3 ANIMAL SEX:  
 T I S S U E S W I T H F I N D I N G S NO. IN GROUP: DOSAGE GROUP: -- A N I M A L S A F F E C T E D --  
 CTLs 1 2 -- MALES -- -- FEMALES --  
 57 50 55 57 50 55 51 40 52

T I S S U E S	W I T H	F I N D I N G S	NO. IN GROUP:	DOSAGE GROUP:	ANIMAL SEX:	CTLs	MALES	FEMALES	CTLs	FEMALES	
BRAIN			NUMBER EXAMINED:			57	50	55	51	40	52
-B- ASTROCYTOMA						1	0	0	0	0	0
TRACHEA			NUMBER EXAMINED:			57	49	55	50	40	52
THYROID GLANDS			NUMBER EXAMINED:			57	47	53	50	37	47
-B- ADENOMA, FOLLICULAR			NUMBER EXAMINED:			0	0	1	0	0	0
-B- PARA-FOLLICULAR CELL ADENOMA			NUMBER EXAMINED:			11	9	10	6	8	5
PARATHYROID			NUMBER EXAMINED:			48	38	45	45	31	37
ESOPHAGUS			NUMBER EXAMINED:			57	50	55	50	40	51
SALIVARY GLAND			NUMBER EXAMINED:			57	50	55	51	39	50
LACRIMAL GLAND			NUMBER EXAMINED:			57	50	55	51	40	52
EXORBITAL LACRIM			NUMBER EXAMINED:			54	47	53	49	38	50
HEART			NUMBER EXAMINED:			57	50	55	51	40	52
AORTA			NUMBER EXAMINED:			57	50	55	51	40	52
LUNGS			NUMBER EXAMINED:			57	50	55	51	40	52
-B- BRONCHIOLAR/ALVEOLAR ADENOMA			NUMBER EXAMINED:			1	1	1	0	0	0
THYRUS			NUMBER EXAMINED:			56	47	50	48	38	45
-B- ADENOMA, ENDOCRINE ORIGIN, NOT OTHERWISE SPECIFIED			NUMBER EXAMINED:			1	0	0	0	0	0
-B- THYRUS			NUMBER EXAMINED:			1	0	0	0	0	0
SPLEEN			NUMBER EXAMINED:			57	49	54	51	40	52
LYMPH NODES			NUMBER EXAMINED:			57	49	55	51	40	51
LIVER			NUMBER EXAMINED:			57	50	55	51	40	52

NOTE: ENTRIES FLAGGED WITH A - (MINUS) ARE SIGNIFICANTLY DIFFERENT FROM CONTROL AT THE 0.05 LEVEL USING KOLMOGOROV-SMIRNOV TWO-TAILED TEST.

**Appendix H (cont.): MICROSCOPIC OBSERVATIONS, INCIDENCE SUMMARY**

LETTERMAN ARMY INSTITUTE OF RESEARCH INCIDENCE SUMMARY OF MICROSCOPIC OBSERVATIONS(BENIGN NEOPLASMS) PRINTED: 22-NOV-89  
 DIV OF RES SUPP, PATH SERV GP STUDY NUMBER: GLP83009 PAGE: 2  
 PRESIDIO OF SAN FRANCISCO, CA 94129 PATHOLOGIST(S): MELLICK, PAUL M., Smith, Catherine D  
 SPECIES: RAT/FISCHER-344 STUDY START DATE: 23-JAN-84 STUDY TYPE: CHRONIC/2 YR CARCINOGENIC

NOTES: ANIMALS = ALL DEAD FROM 30-JAN-85 TO 15-FEB-86  
 CTLs = CONTROLS FROM GROUP(S): 3  
 T I S S U E S W I T H F I N D I N G S

	-- ANIMALS AFFECTED --		-- MALES --		-- FEMALES --			
	CTLs	NO. IN GROUP	CTLs	NO. IN GROUP	CTLs	NO. IN GROUP		
KIDNEY		NUMBER EXAMINED:	57	49	55	51	40	51
URINARY BLADDER		NUMBER EXAMINED:	56	48	53	49	39	48
-B- TRANSITIONAL CELL PAPILLOMA			0	0	0	0	1	0
UTERUS		NUMBER EXAMINED:				51	40	51
PROSTATE		NUMBER EXAMINED:	57	48	55			
COAG GL		NUMBER EXAMINED:	56	47	55			
SEMINAL VESICLE		NUMBER EXAMINED:	57	49	54			
EDIDYMNIS		NUMBER EXAMINED:	57	49	54			
TESTES		NUMBER EXAMINED:	57	50	55			
-B- MESOTHELIOMA			1	0	0			
-B- INTERSTITIAL CELL ADENOMA			51	43	47			
OVARIES		NUMBER EXAMINED:				51	40	51
DUODENUM		NUMBER EXAMINED:	57	47	55	49	40	49
JEJUNUM		NUMBER EXAMINED:	57	48	55	48	40	50
ILEUM		NUMBER EXAMINED:	57	46	53	48	40	50
PANCREAS		NUMBER EXAMINED:	57	48	55	50	40	51
-B- ISLET CELL ADENOMA			6	6	8	1	0	3
CECUM		NUMBER EXAMINED:	56	45	54	48	40	47
-B- ADENOMATOUS POLYP			0	0	0	1	0	0
RECTUM		NUMBER EXAMINED:	56	44	54	49	37	48
COLON		NUMBER EXAMINED:	57	46	54	50	39	50
-B- POLYP, CYSTIC, WITH MUCINOUS EPITHELIAL HYPERPLASIA AND OSSEOUS METAPLASIA AND/OR MINERALIZATION OF STROMA			0	2	0	0	0	0

NOTE: ENTRIES FLAGGED WITH A - (MINUS) ARE SIGNIFICANTLY DIFFERENT FROM CONTROL AT THE 0.05 LEVEL USING KOLMOGOROV-SHIRNOV TWO-TAILED TEST.

**Appendix H (cont.): MICROSCOPIC OBSERVATIONS, INCIDENCE SUMMARY**

LETTERMAN ARMY INSTITUTE OF RESEARCH DIVISION OF R.S. SUPP, PATH SERV GP  
 INCIDENCE SUMMARY OF MICROSCOPIC OBSERVATIONS (BENIGN NEOPLASMS)  
 STUDY NUMBER: GLP83009  
 PRINTED: 22-NOV-89  
 PAGE: 3  
 PRESIDIO OF SAN FRANCISCO, CA 94129  
 PATHOLOGIST(S): MELLICK, PAUL W., Smith, Catherine D  
 STUDY START DATE: 23-JAN-84  
 STUDY TYPE: CHRONIC/2 YR CARCINOGENIC  
 SPECIES: RAT/FISCHER-344

NOTES: ANIMALS = ALL DEAD FROM 30-JAN-85 TO 15-FEB-86  
 CTLS = CONTROLS FROM GROUP(S): 3  
 --- ANIMALS AFFECTED ---  
 --- MALES ---  
 --- FEMALES ---  
 CTLS 1 2 CTLS 1 2  
 57 50 55 51 40 52

T I S S U E S	W I T N	F I N D I N G S	ANIMAL SEX	DOSE GROUP	NO. IN GROUP	CTLS	MALES	FEMALES
STOMACH	.....	NUMBER EXAMINED:				57	49	55
-B- SQUAMOUS CELL PAPILLOMA	.....					0	1	0
SKELETAL MUSCLE	.....	NUMBER EXAMINED:				57	49	54
SCIATIC NERVE	.....	NUMBER EXAMINED:				56	42	52
TONGUE	.....	NUMBER EXAMINED:				56	50	54
SKIN	.....	NUMBER EXAMINED:				55	47	50
-B- KERATOCARCINOMA, ANATOMIC SITE TO BE SPECIFIED	.....					1	1	0
-B- BASAL CELL TUMOR	.....					1	0	1
-B- FIBROMA	.....					3	3	1
-B- SQUAMOUS PAPILLOMA	.....					1	0	1
-B- PREPUTIAL GLAND ADENOMA	.....					1	0	0
-B- CLITORAL GLAND ADENOMA	.....					0	0	0
MAMMARY GLANDS	.....	NUMBER EXAMINED:				53	48	50
-B- FIBROADENOMA	.....					1	0	0
NOSE/TURBINATES	.....	NUMBER EXAMINED:				57	49	53
BONE, STERNUM	.....	NUMBER EXAMINED:				57	50	55
BONE, FEMUR	.....	NUMBER EXAMINED:				57	48	55
BONE VERT	.....	NUMBER EXAMINED:				57	50	55
SPINAL CORD	.....	NUMBER EXAMINED:				56	50	55
ADRENAL	.....	NUMBER EXAMINED:				57	50	55
-B- CORTICAL ADENOMA	.....					1	0	0
-B- PNEUROMYOCYTOXIA	.....					6	2	3
PITUITARY GLAND	.....	NUMBER EXAMINED:				54	46	55
-B- ADENOMA	.....					38	24	28

NOTE: ENTRIES FLAGGED WITH A - (MINUS) ARE SIGNIFICANTLY DIFFERENT FROM CONTROL AT THE 0.05 LEVEL USING KOLMOGOROV-SHIRNOV TWO-TAILED TEST.

**Appendix B (cont.): MICROSCOPIC OBSERVATIONS, INCIDENCE SUMMARY**

LETTERMAN ARMY INSTITUTE OF RESEARCH INCIDENCE SUMMARY OF MICROSCOPIC OBSERVATIONS(BENIGN NEOPLASMS) PRINTED: 22-NOV-89  
 DIV OF RES SUPP, PATH SERV GP STUDY NUMBER: GLP83009 PAGE: 4  
 PRESIDIO OF SAN FRANCISCO, CA 94129 PATHOLOGIST(S): MELLICK, PAUL W., Smith, Catherine D  
 SPECIES: RAT/FISCHER-344 STUDY START DATE: 23-JAN-84 STUDY TYPE: CHRONIC/2 YR CARCINOGENIC

NOTES: ANIMALS = ALL DEAD FROM 30-JAN-85 TO 15-FEB-86  
 CTLS = CONTROLS FROM GROUP(S): 3 ANIMAL SEX:  
 --- MALES ---  
 CTLS 1 2  
 --- FEMALES ---  
 CTLS 1 2  
 T I S S U E S W I T H F I N D I N G S N O . I N G R O U P : 57 50 55  
 --- A M I M A L S A F F E C T E D ---  
 CTLS 51 40 52

	NUMBER EXAMINED:	57	46	55		48	37	51
EYES & OPTIC N.	NUMBER EXAMINED:	56	49	54		51	40	52
EAR	NUMBER EXAMINED:	56	49	53		50	38	51
AD SEBACIOUS	NUMBER EXAMINED:	0	0	0		0	0	0
ABDOMINAL WALL	NUMBER EXAMINED:	0	0	0		0	2	0
THORAX	NUMBER EXAMINED:	57	50	54		51	40	52
WHOLE BODY	NUMBER EXAMINED:	4	6	2		1	2	2
MEDIASTINUM	NUMBER EXAMINED:	0	16	9		0	12	1
ABDOMINAL CAVITY	NUMBER EXAMINED:	0	0	1		0	0	0
-B- LIPOMA	NUMBER EXAMINED:	0	42	19		0	40	25
DIAPHRAGM	NUMBER EXAMINED:							

NOTE: ENTRIES FLAGGED WITH A - (MINUS) ARE SIGNIFICANTLY DIFFERENT FROM CONTROL AT THE 0.05 LEVEL USING KOLMOGOROV-SMIRNOV TWO-TAILED TEST.

**Appendix B (cont.): MICROSCOPIC OBSERVATIONS, INCIDENCE SUMMARY**

LETTERMAN ARMY INSTITUTE OF RESEARCH  
 DIV OF RES SUPP, PATH SERV GP  
 PRESIDIO OF SAN FRANCISCO, CA 94129  
 SPECIES: RAT/FISCHER-344

INCIDENCE SUMMARY OF MICROSCOPIC OBSERVATIONS(NON-NEOPLASMS)  
 STUDY NUMBER: GLP83009  
 PATHOLOGIST(S): WELICK, PAUL W., Smith, Catherine D  
 STUDY START DATE: 23-JAN-84

PRINTED: 22-NOV-89  
 PAGE: 1

NOTES: ANIMALS = ALL DEAD FROM 30-JAN-85 TO 15-FEB-86  
 CTLS = CONTROLS FROM GROUP(S): 3  
 STUDY TYPE: CHRONIC/2 YR CARCINOGENIC

T I S S U E S	W I T H	F I N D I N G S	NO. IN GROUP	-- A N I M A L S		A F F E C T E D	
				CTLS	NO.	MALES	FEMALES
BRAIN		NUMBER EXAMINED:	57	50	55	51	40
-HYDROCEPHALUS			0	1	0	1	0
-LIQUIFACTION NECROSIS			0	1	1	1	0
-PERIVASCULAR LYMPHOCYtic CELLULAR INFILTRATION			0	1	0	0	0
-GLIOSIS			0	1	0	0	0
-HISTIOCYtic INFILTRATION, PERIVASCULAR			0	1	0	0	0
TRACHEA		NUMBER EXAMINED:	57	49	55	50	40
-NON-SUPPURATIVE TRACHEITIS			2	2	0	2	0
-SUPPURATIVE TRACHEITIS			2	1	0	0	0
THYROID GLANDS		NUMBER EXAMINED:	57	47	53	50	37
-FOLLICULAR HYPERTROPHY/HYPERPLASIA			0	0	1	0	0
-PARA-FOLLICULAR CELL HYPERPLASIA ("C" CELL, LIGHT CELL)			10	4	17	14	8
-COLLOID CYST(S)			0	5	3	0	1
PARATHYROID		NUMBER EXAMINED:	48	38	45	45	31
ESOPHAGUS		NUMBER EXAMINED:	57	50	55	50	40
-NECROMORRHAGIC ESOPHAGITIS			0	1	0	0	0
SALIVARY GLAND		NUMBER EXAMINED:	57	50	55	51	39
-ATROPHY AND LOSS OF ACINAR TISSUE			2	3	1	2	0
-INFLAMMATION, SUBACUTE			0	1	0	0	0
LACRIMAL GLAND		NUMBER EXAMINED:	57	50	55	51	40
-INFLAMMATION, SUBACUTE TO CHRONIC			7	2	0	8	1
-ATROPHY AND/OR LOSS OF ACINAR TISSUE			0	0	1	1	2
EXORBITAL LACRIM		NUMBER EXAMINED:	54	47	53	49	38
-ACINAR ATROPHY			1	0	1	12	13
-SUBACUTE INFLAMMATION			1	0	0	1	1
HEART		NUMBER EXAMINED:	57	50	55	51	40
-CARDIOMYOPATHY			55	48	54	37	38
-MEDIAL HYPERTROPHY OF MUSCULAR ARTERIES			22	20	18	10	4
-MURAL THROMBUS			1	0	0	0	0

NOTE: ENTRIES FLAGGED WITH A - (MINUS) ARE SIGNIFICANTLY DIFFERENT FROM CONTROL AT THE 0.05 LEVEL USING KOLMOGOROV-SMIRNOV TWO-TAILED TEST.

**Appendix B (cont.): MICROSCOPIC OBSERVATIONS, INCIDENCE SUMMARY**

LETTERMAN ARMY INSTITUTE OF RESEARCH      INCIDENCE SUMMARY OF MICROSCOPIC OBSERVATIONS(NON-NEOPLASMS)      PRINTED: 22-NOV-89  
 DIV OF RES SUPP, PATH SERV GP      STUDY NUMBER: GLP83009      PAGE: 2  
 PRESIDIO OF SAN FRANCISCO, CA 94129      PATHOLOGIST(S): MELLICK, PAUL W., Smith, Catherine D  
 SPECIES: RAT/FISCHER-344      STUDY START DATE: 23-JAN-84      STUDY TYPE: CHRONIC/2 YR CARCINOGENIC

NOTES: ANIMALS = ALL DEAD FROM 30-JAN-85 TO 15-FEB-86      --- ANIMALS AFFECTED ---  
 CTLS = CONTROLS FROM GROUP(S): 3      --- MALES ---      --- FEMALES ---  
 ANIMAL SEX:      CTLS 1 2      CTLS 1 2  
 DOSAGE GROUP:      57 50 55      51 40 52  
 NO. IN GROUP:      57 50 55      51 40 52

T I S S U E S   W I T H   F I N D I N G S	57	50	55	51	40	52
AORTA	57	50	55	51	40	52
LUNGS	57	50	55	51	40	52
-FOCAL HYPERPLASTIC PROLIFERATION OF TYPE 2 ALVEOLAR EPITHELIAL CELLS WITH OR WITHOUT INFLAMMATORY CELL INFILTRATION	0	1	2	0	0	1
-PLEURITIS WITH SUBADJACENT CHRONIC PNEUMONIA	0	0	0	0	0	0
-PULMONARY EDEMA	0	1	0	0	1	0
-VASCULAR CONGESTION	4	1	0	1	1	0
-THROMBUS	0	0	0	0	0	0
-IMMEREALIZATION OF PULMONARY ARTERIES	27	19	33	17	11	23
-PNEUMONIA, GRANULOMATOUS	0	0	0	3	0	0
-PNEUMONIA, INTERSTITIAL, CHRONIC	2	3	4	4	6	5
-PERIVASCULAR LYMPHOID AGGREGATIONS (CUFFING)	2	0	0	0	0	0
-ALVEOLAR HEMORRHAGE	3	4	6	2	1	5
-PERIBRONCHIAL LYMPHOID HYPERTROPHY	7	2	1	1	0	0
THYRUS	56	47	50	48	38	45
-PLEURITIS	0	0	0	0	0	0
SPLEEN	57	49	54	51	40	52
-LYMPHOID HYPERTROPHY OF THE SPLENIC CORPUSCLES	0	1	1	0	0	0
-FIBROSIS CAPSULAR	1	9	4	1	6	1
-INFARCTION, CHRONIC	6	2	8	3	4	4
-EXTRAMEDULLARY HEMATOPOIESIS	2	3	1	6	9	0
-HEMOSIDERIN PIGMENTATION (RED PULP)	1	0	1	5	4	0
-SMOOTH MUSCLE HYPERTROPHY, CAPSULE AND TRABECULAE	1	0	0	2	0	0
-HISTIOCYTIC INFILTRATE, CAPSULE AND OMENTUM	2	0	0	0	0	0
-BENIGN HYPERTROPHIC NODULE	2	1	1	0	0	0
-COMPOUND RELATED INFLAMMATORY REACTION	0	1	0	0	1	0
LYMPH NODES	57	49	55	51	40	51
-LYMPHOID HYPERTROPHY	1	0	0	0	0	0
-RED BLOOD CELLS, MEMOSIDERIN AND/OR ERYTHROPHAGOCYTOSIS WITHIN MEDULLARY SINUSES	12	-24	18	15	-28	17
-HISTIOCYTIC INFILTRATION, SUBCAPSULAR AND MEDULLARY SINUSES	1	1	3	4	1	0
-REACTIVE HYPERTROPHY	8	-25	-29	7	-25	-24
-DILATED AND/OR CYSTIC MEDULLARY SINUSES	0	3	8	0	2	6

NOTE: ENTRIES FLAGGED WITH A - (MINUS) ARE SIGNIFICANTLY DIFFERENT FROM CONTROL AT THE 0.05 LEVEL USING KOLMOGOROV-SMIRNOV TWO-TAILED TEST.

**Appendix B (cont.): MICROSCOPIC OBSERVATIONS, INCIDENCE SUMMARY**

LETTERMAN ARMY INSTITUTE OF RESEARCH INCIDENCE SUMMARY OF MICROSCOPIC OBSERVATIONS(NON-NEOPLASMS) PRINTED: 22-NOV-89  
 DIV OF RES SUPP, PATH SERV GP STUDY NUMBER: GLP83009 PAGE: 3  
 PRESIDIO OF SAN FRANCISCO, CA 94129 PATHOLOGIST(S): MELLICK, PAUL W., Smith, Catherine D  
 SPECIES: RAT/FISCHER-344 STUDY START DATE: 23-JAN-84 STUDY TYPE: CHRONIC/2 YR CARCINOGENIC

NOTES: ANIMALS = ALL DEAD FROM 30-JAN-85 TO 15-FEB-86  
 CTLs = CONTROLS FROM GROUP(S): 3 ANIMAL SEX: --- MALES AFFECTED ---  
 T I S S U E S W I T H F I N D I N G S N O . I N G R O U P : D O S A G E G R O U P : C T L S 1 2 C T L S 1 2 F E M A L E S  
 --- A M I M A L S A F F E C T E D ---  
 57 50 55 57 50 55 51 40 52  
 0 -48 -52 0 -48 -45 0 -40 -45  
 12 14 17 12 14 17 19 24 -35  
 3 9 11 3 9 11 24 23 30  
 25 22 21 25 22 21 15 14 20  
 0 0 2 0 0 2 8 -17 12  
 3 6 5 3 6 5 4 3 4  
 1 1 2 1 1 2 1 1 4  
 9 4 4 9 4 4 3 1 0  
 1 0 0 1 0 0 1 1 1  
 21 9 23 21 9 23 3 2 1  
 3 4 11 3 4 11 9 7 4  
 0 1 11 0 1 11 3 3 0  
 9 10 14 9 10 14 10 3 2  
 13 4 3 13 4 3 3 1 1  
 2 4 3 2 4 3 3 7 6  
 0 0 3 0 0 3 1 0 0  
 12 7 16 12 7 16 24 15 27

ISSUES WITH FINDINGS	NO. IN GROUP	DOSAGE GROUP	CTLS	MALES	CTLS	FEMALES
LIVER	57	50	55	51	40	52
-COMPOUND RELATED INFLAMMATORY REACTION	0	-48	-52	0	-40	-45
-BILE DUCTULE EPITHELIAL HYPERPLASIA AND/OR CHOLANGIOFIBROSIS	56	48	55	19	24	-35
-HEPATITIS	12	14	17	24	23	30
-FOCUS OF CELLULAR ALTERATION - BASOPHILIC	3	9	11	15	14	20
-HEPATOCTYIC VACUOLIZATION	25	22	21	8	-17	12
-TELANGIECTASIS	0	0	2	0	0	2
-NECROSIS	3	6	5	4	3	4
-FIBROSIS CAPSULAR NO COMPOUND	1	1	2	1	1	4
-FOCUS OF CELLULAR ALTERATION - CLEAR CELLS	9	4	4	3	1	0
-PERIPORTAL MONONUCLEAR CELLULAR INFILTRATION	1	0	0	1	1	1
-CYSTIC DEGENERATION	21	9	23	3	2	1
-HEPATOCTYIC DEGENERATIVE CHANGES (NON-NECROTIC)	3	4	11	9	7	4
-NECROSIS, HEPATOCTYIC, INDIVIDUAL CELLS	0	1	11	3	3	0
-BENIGN HYPERPLASTIC NODULE(S)	9	10	14	10	3	2
-FOCUS OF CELLULAR ALTERATION - EOSINOPHILIC CELLS	13	4	3	3	1	1
-NECROSIS, PERIACINAR	2	4	3	3	7	6
-FIBROSIS, PARENCHYMAL (SCARPING)	0	0	3	1	0	0
-HEPATOCTYIC COALESCING MICROVESICULAR (FATTY) CHANGE LEADING TO NECROSIS AND MINERALIZATION	12	7	16	24	15	27
KIDNEY	57	49	55	51	40	51
-PROGRESSIVE RENAL DISEASE	57	-48	55	44	34	51
-HEMORRHAGE, ACUTE	0	0	1	1	0	0
-NEMOSIDEROSIS (BROWN GRANULAR PIGMENT) IN TUBULAR EPITHELIAL CELLS	0	0	0	1	0	0
-CYST(S) CORTICAL	1	0	0	1	0	0
-INFARCT, CHRONIC WITH FIBROSIS; WITH OR WITHOUT MINERALIZATION	1	0	0	0	0	0
-FIBROSIS, CAPSULE	0	1	0	0	0	0
URINARY BLADDER	56	48	53	49	39	48
-CHRONIC INFLAMMATORY CELL INFILTRATION	0	0	2	0	0	3
UTERUS	51	40	51	51	40	51
-COMPOUND RELATED INFLAMMATORY REACTION	0	0	0	0	0	0
-DILATATION OF THE UTERINE LUMEN (HYDROMETRA)	4	0	4	4	0	4
-PYOMETRA	0	0	0	0	0	0
-ENDOMETRIAL STROMAL POLYP	11	7	9	11	7	9
-CYSTIC DILATATION OF THE ENDOMETRIAL GLANDS	12	5	9	12	5	9
-LYMPHOCTYIC INFILTRATE	1	0	3	1	0	3
-ENDOMETRITIS, SUBACUTE	0	2	2	0	2	2



**Appendix H (cont.): MICROSCOPIC OBSERVATIONS, INCIDENCE SUMMARY**

LETTERMAN ARMY INSTITUTE OF RESEARCH DIV OF RES SUPP, PATN SERV GP  
 PRESIDIO OF SAN FRANCISCO, CA 94129  
 SPECIES: RAT/FISCHER-344

INCIDENCE SUMMARY OF MICROSCOPIC OBSERVATIONS(NON-NEOPLASMS)  
 STUDY NUMBER: GLP83009  
 PATHOLOGIST(S): MELLICK, PAUL W., Smith, Catherine D  
 STUDY START DATE: 23-JAN-84

PRINTED: 22-NOV-89  
 PAGE: 4

STUDY TYPE: CHRONIC/2 YR CARCINOGENIC

NOTES: ANIMALS = ALL DEAD FROM 30-JAN-85 TO 15-FEB-86  
 CTLs = CONTROLS FROM GROUP(S): 3

ANIMAL SEX: --- A N I M A L S A F F E C T E D ---  
 --- MALES --- --- FEMALES ---  
 CTLs 1 2 CTLs 1 2  
 DOSAGE GROUP: 57 50 55 51 40 52  
 NO. IM GROUP:

T I S U E S W I T H F I N D I N G S

UTERUS ..... NUMBER EXAMINED: 51 40 51  
 -DEGENERATION, NECROSIS AND CHRONIC INFLAMMATION OF UTERINE STROMA 1 0 0

PROSTATE	57	48	55	51	40	51
NUMBER EXAMINED:	3	0	0	0	1	2
-ACUTE SUPPURATIVE PROSTATITIS	40	28	36	51	40	52
-CHRONIC PROSTATITIS	49	32	47	51	40	52
-BENIGN HYPERPLASIA	4	2	0	0	0	0
-MICROCALCULI, PROSTATIC URETHRA						
COAG GL	56	47	55			
NUMBER EXAMINED:	57	49	54			
SEMINAL VESICLE	35	27	31			
NUMBER EXAMINED:	57	49	54			
-GENERALIZED ATROPHY	57	50	55			
EDIDIDYNSIS	6	2	0			
NUMBER EXAMINED:	4	6	3			
TESTES	5	0	1			
NUMBER EXAMINED:	57	47	55			
-TUBULAR ATROPHY	57	47	55			
NUMBER EXAMINED:	0	7	0			
-INTERSTITIAL CELL HYPERPLASIA	0	0	0			
-PERIARTERITIS NODOSA	0	0	0			
OVARIES	0	0	0			
NUMBER EXAMINED:	57	47	55			
-FOLLICULAR CYST(S)	0	7	0			
-CYSTIC CORPORA LUTEA	0	0	0			
-PARA-OVARIAN CYST(S)	0	0	0			
-INFLAMMATORY CELL INFILTRATION	0	0	0			
DUODENUM	57	47	55			
NUMBER EXAMINED:	0	7	0			
-COMPOUND RELATED INFLAMMATORY REACTION	0	0	0			
-MUCOSAL EROSION/ULCERATION	0	0	0			
-PRESENCE OF MUCOSAL EPITHELIAL CELLS WITHIN INTESTINAL WALL AND ADJACENT FIBROUS/GRANULOMATOUS INFLAMMATORY REACTION	0	0	0			
JEJUNUM	57	48	55			
NUMBER EXAMINED:	0	16	0			
-COMPOUND RELATED INFLAMMATORY REACTION	0	0	1			
-ACUTE PERITONITIS	1	0	1			
-ENTERITIS, SUBACUTE	0	0	1			
-MUCOSAL EROSION/ULCERATION	0	2	1			
-PRESENCE OF MUCOSAL EPITHELIAL CELLS WITHIN INTESTINAL WALL AND ADJACENT FIBROUS/GRANULOMATOUS INFLAMMATORY REACTION	0	1	0			
-FIBROVASCULAR ADHESION, SEROSA	0	1	1			

NOTE: ENTRIES FLAGGED WITH A - (MINUS) ARE SIGNIFICANTLY DIFFERENT FROM CONTROL AT THE 0.05 LEVEL USING KOLMOGOROV-SHIRNOV TWO-TAILED TEST.

**Appendix B (cont.): MICROSCOPIC OBSERVATIONS, INCIDENCE SUMMARY**  
 LETTERMAN ARMY INSTITUTE OF RESEARCH INCIDENCE SUMMARY OF MICROSCOPIC OBSERVATIONS (NON-NEOPLASMS) PRINTED: 22-NOV-89  
 DIV OF RES SUPP, PATN SERV GP STUDY NUMBER: GLP83009 PAGE: 5  
 PRESIDIO OF SAN FRANCISCO, CA 94129 PATHOLOGIST(S): MELLICK, PAUL W., Smith, Catherine D. STUDY TYPE: CHRONIC/2 YR CARCINOGENIC  
 SPECIES: RAT/FISCHER-344 STUDY START DATE: 23-JAN-84

NOTES: ANIMALS = ALL DEAD FROM 30-JAN-85 TO 15-FEB-86  
 CTLS = CONTROLS FROM GROUP(S): 3  
 T I S S U E S W I T H F I N D I N G S

	--- ANIMALS AFFECTED ---		NUMBER EXAMINED
	--- MALES ---	--- FEMALES ---	
	CTLS	CTLS	
ILEUM	57	46	53
-COMPOUND RELATED INFLAMMATORY REACTION	0	7	0
-MUCOSAL EROSION/ULCERATION	0	3	0
-LYMPHOID HYPERPLASIA	0	1	0
PANCREAS	57	48	55
-ACINAR (EXOCRINE) /TROPY	16	10	18
-CHRONIC INFLAMMATION	7	6	4
-PERIARTERITIS MODOSA	1	1	1
-ACINAR HYPERPLASIA	1	0	0
-COMPOUND RELATED INFLAMMATORY REACTION	0	3	0
-CYSTIC DUCT	0	0	0
CECUM	56	45	54
-COMPOUND RELATED INFLAMMATORY REACTION	0	4	0
-PERIARTERITIS MODOSA, ARTERIES IN CECAL WALL OR MESENTERY	0	0	0
-REACTIVE LYMPHOID HYPERPLASIA, SUBMUCOSA	0	1	0
-EDEMA OF THE SUBMUCOSA AND/OR LAMINA PROPRIA	0	0	1
-MONONUCLEAR CELLULAR INFILTRATION	0	0	1
RECTUM	56	44	54
-COMPOUND RELATED INFLAMMATORY REACTION	0	4	0
-PERIARTERITIS MODOSA, ARTERIES IN CECAL WALL OR MESENTERY	0	0	0
-REACTIVE LYMPHOID HYPERPLASIA, SUBMUCOSA	0	1	0
-EDEMA OF THE SUBMUCOSA AND/OR LAMINA PROPRIA	0	0	1
-MONONUCLEAR CELLULAR INFILTRATION	0	0	1
COLON	57	46	54
-COMPOUND RELATED INFLAMMATORY REACTION	0	3	0
-CHRONIC COLITIS WITH MUCOUS GLAND HYPERPLASIA AND HYPERSECRETION	0	1	0
STOMACH	57	49	55
-COMPOUND RELATED INFLAMMATORY REACTION	0	6	0
-SEROSAL FIBROSIS	0	3	0
-ULCERATION, NON-GLANDULAR AREA	1	1	2
-MUCOSAL AND/OR SUBMUCOSAL EDEMA	0	4	7
-EROSION AND/OR ULCERATION OF THE GLANDULAR MUCOSA	0	0	1
SKELETAL MUSCLE	57	49	54
-ACUTE MYOSITIS	0	0	0
-CHRONIC MYOSITIS	0	1	1
-CHRONIC INFLAMMATION RESTRICTED TO FASCIA	0	1	2

NOTE: ENTRIES FLAGGED WITH A - (MINUS) ARE SIGNIFICANTLY DIFFERENT FROM CONTROL AT THE 0.05 LEVEL USING KOLMOGOROV-SMIRNOV TWO-TAILED TEST.

**Appendix H (cont.): MICROSCOPIC OBSERVATIONS, INCIDENCE SUMMARY**  
 LETTERMAN ARMY INSTITUTE OF RESEARCH  
 DIV OF RES SUPP, PATH SERV GP  
 PRESIDIO OF SAN FRANCISCO, CA 94129  
 SPECIES: RAT/FISCHER-344

INCIDENCE SUMMARY OF MICROSCOPIC OBSERVATIONS(NON-NEOPLASMS)  
 STUDY NUMBER: GLP83009  
 PATHOLOGIST(S): MELLICK, PAUL W., Smith, Catherine D  
 STUDY START DATE: 23-JAN-84

STUDY TYPE: CHRONIC/2 YR CARCINOGENIC  
 PRINTED: 22-NOV-89  
 PAGE: 6

NOTES: ANIMALS = ALL DEAD FROM 30-JAN-85 TO 15-FEB-86  
 CTLS = CONTROLS FROM GROUP(S): 3  
 ANIMAL SEX:  
 DOSAGE GROUP:  
 NO. IN GROUP:

T I S S U E S	W I T H		F I N D I N G S		A F F E C T E D	
	MALES	FEMALES	MALES	FEMALES	MALES	FEMALES
SCIATIC NERVE	56	42	52	51	39	44
TONGUE	56	50	54	51	40	52
-MONONUCLEAR CELLULAR INFILTRATION	2	0	1	0	1	0
-PERIARTERITIS	1	3	0	1	0	0
-MEDIAL HYPERTROPHY AND MINERALIZATION OF MEDIUM-SIZED MUSCULAR ARTERIES	0	1	0	0	0	0
SKIN	55	47	50	51	39	52
-COMPOUND PRESENT WITH ASSOCIATED INFLAMMATION/FIBROSIS	0	0	0	0	0	0
-INFLAMMATORY EXUDATE ON SKIN SURFACE	1	0	0	0	0	0
-PROCEDURE RELATED GRANULOMATOUS CELLULITIS SUBCUTIS	0	0	0	0	0	0
-NON-SUPPURATIVE DERMATITIS	0	0	0	0	0	0
-CELLULITIS	3	0	0	0	0	1
-EROSION/ULCERATION OF THE SKIN SURFACE	0	0	1	1	0	0
-ACANTHOSIS	1	0	0	0	0	0
-HYPERKERATOSIS	1	0	0	0	0	0
-INFLAMMATION, NOT OTHERWISE SPECIFIED, PREPUITAL GLAND	0	3	0	0	0	0
-EPIDERMAL INCLUSION CYST(S)	0	1	0	1	0	0
MAMMARY GLANDS	53	48	50	49	40	51
-HYPERPLASIA AND/OR HYPERTROPHY OF THE ACINAR TISSUE	26	23	24	42	35	45
-GALACTOCELE(S)	5	3	2	1	0	0
-DILATATION (ECTASIA) OF DUCTS AND DUCTULES	23	19	19	36	31	39
NOSE/TURBINATES	57	49	53	51	40	52
-ACUTE INFLAMMATION	1	0	0	0	0	1
-SUBACUTE INFLAMMATION	2	1	0	1	0	1
-MIXED INFLAMMATORY CELL INFILTRATION, NASAL CAVITY, SINUSES, TURBINATES, NASO-LACRIMAL DUCTS	31	20	28	20	23	31
BONE, STERNUM	57	50	55	50	38	51
-MYELOID NISTIOCYTOSIS	2	1	1	1	0	0
-HYPERPLASIA, MYELOID	2	1	1	1	3	0
-MYELOFIBROSIS/OSTEOSCLEROSIS	1	0	0	0	0	0

NOTE: ENTRIES FLAGGED WITH A - (MINUS) ARE SIGNIFICANTLY DIFFERENT FROM CONTROL AT THE 0.05 LEVEL USING KOLMOGOROV-SMIRNOV TWO-TAILED TEST.

**Appendix H (cont.): MICROSCOPIC OBSERVATIONS, INCIDENCE SUMMARY**

LETTERMAN ARMY INSTITUTE OF RESEARCH      INCIDENCE SUMMARY OF MICROSCOPIC OBSERVATIONS(NON-NEOPLASMS)      PRINTED: 22-NOV-89  
 DIV OF RES SUPP, PATH SERV GP      STUDY NUMBER: GLP83009      PAGE: 7  
 PRESIDIO OF SAN FRANCISCO, CA 94129      PATHOLOGIST(S): MELLICK, PAUL W., Smith, Catherine D  
 SPECIES: RAT/FISCHER-344      STUDY START DATE: 23-JAN-84      STUDY TYPE: CHRONIC/2 YR CARCINOGENIC

NOTES: ANIMALS = ALL DEAD FROM 30-JAN-85 TO 15-FEB-86      -- ANIMALS AFFECTED --  
 CTL5 = CONTROLS FROM GROUP(S): 3      -- MALES --      -- FEMALES --  
 T I S S U E S      W I T H      F I N D I N G S      M O . I N      G R O U P      C T L S      1      2      C T L S      1      2

	57	48	55	51	40	51
BONE, FEMUR	57	48	55	51	40	51
-HYPERPLASIA MYELOID	2	1	1	1	7	2
-MYELOID NISTIOCTOSIS	2	0	1	1	0	0
-MYELOFIBROSIS/OSTEOSCLEROSIS	2	0	0	0	0	0
BONE VERT	57	50	55	51	40	52
-MYELOID NISTIOCTOSIS	2	1	1	1	0	0
-HYPERPLASIA, MYELOID	2	1	0	0	4	0
-MYELOFIBROSIS/OSTEOSCLEROSIS	1	0	0	0	0	0
SPINAL CORD	56	50	55	51	40	52
ADRENAL	57	50	55	51	40	50
-LIPIDOSIS	3	6	5	0	1	2
-FOCUS OF CELLULAR ALTERATION, EOSINOPHILIC	12	1	0	1	1	0
-FOCUS OF CELLULAR ALTERATION, VACUOLATED	23	-7	-8	31	17	-16
-FOCUS OF CELLULAR ALTERATION, BASOPHILIC	0	0	0	0	0	2
-CORTICAL MODULAR HYPERPLASIA	9	5	10	3	2	6
-FIBROSIS, CAPSULE	0	0	1	1	0	0
-EXTRAMEDULLARY HEMATOPOIESIS	0	0	0	0	1	0
-NECROSIS	0	0	0	0	0	1
PITUITARY GLAND	54	46	55	50	40	47
-CYST(S)	1	8	7	7	4	13
-HEMORRHAGE	1	0	1	1	3	0
EYES & OPTIC N.	57	46	55	48	37	51
-CORNEAL MINERALIZATION	4	3	4	3	8	7
-RETINAL ATROPHY AND/OR DEGENERATION, UNILATERAL OR BILATERAL	10	6	10	9	8	9
-CORNEAL PIGMENTATION	0	0	0	0	0	0
-CORNEAL VASCULARIZATION	2	2	2	7	15	4
-CHRONIC KERATITIS	1	0	0	0	1	1
-IRIDOCYCLITIS	0	1	0	0	1	1
-METAPLASTIC BONE FORMATION AND/OR MINERALIZATION, SCLERA	39	29	32	16	13	10
-LENTICULAR DEGENERATIVE CHANGES COMPATIBLE WITH CATARACT	9	13	10	12	6	3
-CHRONIC CONJUNCTIVITIS	0	0	0	0	0	4

NOTE: ENTRIES FLAGGED WITH A - (MINUS) ARE SIGNIFICANTLY DIFFERENT FROM CONTROL AT THE 0.05 LEVEL USING KOLMOGOROV-SMIRNOV TWO-TAILED TEST.

Appendix H (cont.): MICROSCOPIC OBSERVATIONS, INCIDENCE SUMMARY

LETTERMAN ARMY INSTITUTE OF RESEARCH DIV OF RES SUPP, PATM SERV GP PRESIDIO OF SAN FRANCISCO, CA 94129  
 INCIDENCE SUMMARY OF MICROSCOPIC OBSERVATIONS(NON-NEOPLASMS) STUDY NUMBER: GLP83009  
 PATHOLOGIST(S): MELLICK, PAUL W., Smith, Catherine D  
 STUDY START DATE: 23-JAN-84 STUDY TYPE: CHRONIC/2 YR CARCINOGENIC

PRINTED: 22-NOV-89  
 PAGE: 8

NOTES: ANIMALS = ALL DEAD FROM 30-JAN-85 TO 15-FEB-86  
 CTL5 = CONTROLS FROM GROUP(S): 3  
 T I S S U E S W I T H F I N D I N G S  
 --- ANIMALS AFFECTED ---  
 --- MALES ---  
 CTL5 1 2 CTL5 1 2  
 57 50 55 51 40 52

	NUMBER EXAMINED:	56	49	54	51	40	52
EAR		0	2	0	1	0	0
-OTITIS MEDIA, SUPPURATIVE OR NON-SUPPURATIVE							
AD SEBACIOUS		56	49	53	50	38	51
ABDOMINAL WALL		0	0	0	0	0	0
-INFECTION AND INFLAMMATION SEVERE INVOLVING THE MUSCULATURE AND PERITONEAL SURFACE		0	0	0	0	0	0
THORAX		0	0	0	0	2	0
WHOLE BODY		57	50	54	51	40	52
-INFLAMMATION OF BROWN FAT, (LOCATION SPECIFIED IN COMMENTS)		1	0	0	4	0	2
MEDIASTINUM		4	6	2	1	2	2
-CHRONIC INFLAMMATION		1	2	2	1	0	1
-REACTIVE HYPERPLASIA, LYMPH NODE		3	1	0	0	1	0
ABDOMINAL CAVITY		0	16	9	0	12	1
-CHRONIC INFLAMMATION DUE TO THE PRESENCE OF TEST COMPOUND (SITE SPECIFIED IN COMMENTS)		0	1	3	0	0	0
DIAPHRAGM		0	42	19	0	40	25
-COMPOUND RELATED INFLAMMATORY REACTION		0	41	18	0	38	25

NOTE: ENTRIES FLAGGED WITH A - (MINUS) ARE SIGNIFICANTLY DIFFERENT FROM CONTROL AT THE 0.05 LEVEL USING KOLMOGOROV-SMIRNOV TWO-TAILED TEST.

**Appendix I: GLOSSARY OF TERMS  
FOR PATHOLOGY FINDINGS**

**GENERAL DIAGNOSES**

In this study there were a few lesions which occurred repeatedly and involved numerous organs and tissues. The histologic characteristics of these lesions had very little to do with their location or organ of involvement. Repetition of morphologic descriptions and diagnostic criteria for these lesions under each organ in this glossary would be redundant. Therefore, these lesions are described here under the heading of "General Diagnoses," and will be referred to as appropriate under the organs in which they occurred.

1. COMPOUND-RELATED INFLAMMATORY REACTION - The test material was applied directly to the capsular surface of the liver as a liquid, and allowed to polymerize. In many instances, especially in animals in the high dose group, the unpolymerized material ran off the liver and adhered to adjacent abdominal viscera where polymerization occurred. In histologic sections, the test material is a clear, slightly yellow homogeneous crystalline material. The material stimulates a granulomatous foreign-body inflammatory reaction characterized by infiltration of macrophages, lymphocytes, and large multinucleated foreign-body giant cells within abundant fibrous connective tissue. Usually this lesion is limited to the serosal surface of abdominal viscera. In some cases, there is necrosis of underlying tissues and penetration of the serosal surface by the inflammatory response accompanied by regenerative hyperplasia of cells of the organ involved. The most probable reason for the necrosis, when it occurred, is the local compromise of circulation by the presence of the test material or the reaction to it. No attempt is made to grade the severity of such lesions. They are simply coded as "Present." This diagnosis is used only when there is unequivocal evidence of the presence of test material. In cases where test material is not present, a different diagnosis such as "Fibrosis" or "Chronic Inflammation" is used, as appropriate.

2. LARGE GRANULAR LYMPHOCYTE LEUKEMIA - This is a common neoplastic disease of Fischer-344 rats. Although the primary site for this lesion is probably the spleen, leukemic involvement frequently occurs early in the disease, and neoplastic lymphocytes can be found in vascular spaces of virtually every organ and tissue in the body. The neoplastic cells are large, round lymphoid cells with abundant, finely

**Appendix I (cont.): GLOSSARY OF TERMS  
FOR PATHOLOGY FINDINGS**

granular, weakly eosinophilic cytoplasm. Mitotic figures, many of which are large and bizarre, are numerous. Because of the characteristics of the Xyblon computerized data acquisition system, the primary site for this neoplastic disease is coded under *WHOLE BODY*, thus documenting the presence of the disease regardless of the organs involved. It is coded as a metastatic lesion only in those organs in which it alters normal histologic architecture or constitutes a significant histologic feature. Using this method of computer entry, it is possible to tabulate the occurrence of this disease and document the significant organs involved, without causing duplication in incidence data.

3. PRESENCE OF METASTATIC SARCOMA - A number of the animals developed sarcomas within the fibrous, granulomatous reaction incited by the test material. The sarcomas involve many organs in some animals, either through local invasion of malignant cells or by metastasis. The histologic characteristics of these tumors are extremely variable. The entire spectrum of histologic differentiation of mesenchymal tissue is represented in this group of tumors. Some tumors are well-differentiated fibrosarcomas, osteosarcomas, or myxosarcomas, while others are very anaplastic and poorly differentiated. In some lesions, multiple types of histologic differentiation occur in the same tumor. The liver is the most frequent location for these lesions, but it is not involved in every case. Therefore, the primary site for these lesions is coded as the *ABDOMINAL CAVITY*, and the involvement of each individual organ is coded as a metastatic lesion. Using this method of computer entry it is possible to tabulate the occurrence of these sarcomas and document the organs involved without causing duplication of incidence data. The morphologic characteristics and histologic differentiation of each tumor are documented under the *ABDOMINAL CAVITY* using the "special histologic comments" feature of the Xyblon program. This diagnosis is used only when it is certain that the sarcoma developed within the reaction to the test material. Sarcomas that developed outside the abdominal cavity or in areas remote to the application of the test material are not included under this diagnosis.

4. PRESENCE OF METASTATIC NEOPLASM - This diagnosis is used in cases in which neoplastic cells (other than sarcoma or large granular lymphocyte leukemia) are present in organs or tissues other than those of the site of origin. The lesion

**Appendix I (cont.): GLOSSARY OF TERMS  
FOR PATHOLOGY FINDINGS**

is coded as + with the two-letter abbreviation of the organ of origin. Example: an adenocarcinoma of the thyroid that has metastasized to the lung is coded under lung as *PRESENCE OF METASTATIC NEOPLASM +TH.*

**BRAIN**

1. **ASTROCYTOMA** - A neoplastic proliferation of astrocytes. The tumor is composed of large and medium-sized cells with large vesicular nuclei and cytoplasm that is not usually intensely stained. Cytoplasm consists of numerous fibrils which are tangled and crisscross in various directions. No particular growth pattern is characteristic. These tumors are usually small and well demarcated from adjacent tissue which may be compressed or undergo liquefaction necrosis.
2. **HYDROCEPHALUS** - Enlargement or dilation of the ventricles of the brain at the expense of adjacent parenchyma which undergoes pressure atrophy or liquefaction necrosis.
3. **LIQUEFACTION NECROSIS** - A necrotic area in the central nervous system. Necrotic tissue has been liquified. The area appears microscopically as an unlined empty space with frayed and irregular edges. Cells immediately adjacent to the liquified area may show evidence of necrosis. Pink-staining proteinaceous precipitate, lipofuscin-laden "gitter" cells, red blood cells, neutrophils, and remnants of destroyed tissue may or may not be present. The severity of the lesion is graded based on size of the necrotic area:
  - 1 = Diameter is less than that of a 40X microscopic field.
  - 2 = Diameter is less than a 20X field.
  - 3 = Diameter is less than a 10X field.
  - 4 = Diameter is less than a 4X field.
4. **PITUITARY TUMOR INVASION** - Presence of neoplastic cells from the anterior pituitary in, or adjacent to and compressing brain tissue. These tumors do not usually metastasize but may compress and destroy brain tissue locally. Infiltration of meninges and ventricular spaces of the brain may occur and is included under this diagnosis.
5. **PERIVASCULAR LYMPHOCYTIC CELLULAR INFILTRATION** - Presence of non-neoplastic lymphocytes in perivascular spaces.



**Appendix I (cont.): GLOSSARY OF TERMS  
FOR PATHOLOGY FINDINGS**

Severity grade criteria:

- 1 = Detectable.
- 2 = Involvement of an area up to size of 20X microscopic field.
- 3 = Cuffs are three cell layers thick and involve area greater than 20X microscopic field.
- 4 = Cuffs are more than three cells thick and/or area of involvement is greater than 10X microscopic field.

6. GLIOSIS - Non-neoplastic proliferation of fibrous astrocytes and possibly other glial cells. Appears microscopically as a focal or diffuse increase in glial nuclei and increased density of internuclear areas. This lesion frequently occurs at the periphery of areas of liquefaction necrosis but is not limited to such areas.

Severity grade criteria:

- 1 = Detectable, area less than one 40X field.
- 2 = Area less than one 20X field.
- 3 = Area less than one 10X field.
- 4 = Area less than one 4X field.
- 5 = Area greater than one 4X field.

7. LARGE GRANULAR LYMPHOCYTE LEUKEMIA, METASTATIC - See "General Diagnoses" above.

8. HISTIOCYTIC INFILTRATION, PERIVASCULAR - Presence of non-neoplastic histiocytes in perivascular spaces. The lesion is coded as "Present."

**TRACHEA**

Tracheal glands are dilated in almost every animal examined in the second year of this study. Since this change is universal in animals in all treatment groups, it is considered a normal aging change for this population and is not coded.

1. NONSUPPURATIVE TRACHEITIS - Presence of mononuclear inflammatory cells within or beneath the tracheal epithelium and/or within the tracheal wall.

**Appendix I (cont.): GLOSSARY OF TERMS  
FOR PATHOLOGY FINDINGS**

Severity grade criteria:

- 1 = Presence of a few mononuclear cells within or beneath the tracheal epithelium.
- 2 = Inflammatory cell infiltration of the tracheal mucosa is prominent. Submucosal glands may be infiltrated.
- 3 = Diffuse infiltration of the mucosa and submucosa with inflammatory cells in the tracheal lumen.
- 4 = Same as Grade 3 plus destruction of mucosal and/or submucosal structures.
- 5 = Inflammatory infiltrate and destruction of normal structure throughout the thickness of the tracheal wall.

2. PRESENCE OF METASTATIC NEOPLASM - See "General Diagnoses" above.

3. SUPPURATIVE TRACHEITIS - An acute inflammatory process characterized primarily by neutrophils within the trachea.

Severity grade criteria:

- 1 = Presence of a few neutrophils within and beneath the tracheal epithelium.
- 2 = Neutrophilic infiltration of tracheal mucosa and submucosa is prominent. Submucosal glands may be infiltrated.
- 3 = Neutrophils are present in the tracheal lumen and diffusely infiltrate mucosa and submucosa.
- 4 = Similar to Grade 3 plus destruction of mucosal and submucosal structures.
- 5 = Neutrophilic infiltrate and destruction of normal structure throughout the thickness of the tracheal wall.

**THYROID GLANDS**

1. FOLLICULAR HYPERTROPHY/HYPERPLASIA - Non-neoplastic proliferation of thyroid follicular cells. Cells may be increased in size, number, or both. Hyperplastic epithelium may form follicles containing colloid, or form papillary fronds supporting multiple layers of cells that extend into large follicles. The lesion is coded as "Present."

2. ADENOMA, FOLLICULAR - A benign tumor of thyroid follicular cells characterized primarily by cords of cells or cells

**Appendix I (cont.): GLOSSARY OF TERMS  
FOR PATHOLOGY FINDINGS**

forming follicular structures. These tumors are well-demarcated, expansile lesions which cause compression and atrophy of adjacent thyroid parenchyma.

3. PARAFOLLICULAR CELL HYPERPLASIA (C-CELL HYPERPLASIA) - Focal or diffuse non-neoplastic proliferation of parafollicular cells. Foci of hyperplastic cells are no larger than a normal thyroid follicle. There is no compression of adjacent thyroid tissue. Severity grade criteria:

- 1 = One to three nodules or less than 25% diffuse glandular involvement.
- 2 = Three to six nodules or less than 50% diffuse involvement.
- 3 = Six to ten nodules or more than 50% diffuse involvement.
- 4 = More than ten nodules or more than 75% diffuse involvement.

4. PARAFOLLICULAR CELL ADENOMA - Benign tumor of parafollicular or "C" cells. These tumors are usually solid in cellular arrangement, and are large enough to compress adjacent tissue. There is no evidence of invasion of the thyroid capsule or adjacent tissues. Cellular pleomorphism may be prominent, but cells are usually uniform and slightly elongated with ovoid or almost spherical nuclei. Cytoplasm is sparse, homogeneous, or finely granulated and stained weakly eosinophilic. Mitotic figures are rare.

5. PARAFOLLICULAR CELL ADENOCARCINOMA - Malignant neoplastic proliferation of parafollicular or "C" cells. Cellular morphology may vary little from adenoma described above. Fusiform and palisade patterns occur frequently. Criteria for malignancy is based on invasion of thyroid capsule and/or infiltration of adjacent tissue or metastasis.

6. FOLLICULAR ADENOCARCINOMA - Malignant neoplastic proliferation of follicular cells of the thyroid. Microscopic patterns are similar to those of follicular adenomas. There is usually very little structural and cellular pleomorphism, and moderate, even low mitotic activity. The consistent feature that distinguishes follicular adenocarcinomas from the analogous type of benign tumor is their invasiveness. These tumors invade the thyroid capsule, adjacent tissues, lymphatics, and blood vessels.

**Appendix I (cont.): GLOSSARY OF TERMS  
FOR PATHOLOGY FINDINGS**

7. COLLOID CYST - Presence of greatly enlarged (over twice the size of an average follicle) colloid-filled cystic space within the thyroid gland. Epithelial cells lining such cysts are usually flattened. One or more colloid cysts may occur within a single thyroid gland.

**PARATHYROID GLANDS**

No gross or microscopic lesions were recognized in parathyroid glands of rats used in this study.

**ESOPHAGUS**

1. NECROHEMORRHAGIC ESOPHAGITIS - Necrosis and hemorrhage accompanied by acute suppurative inflammation in the esophagus. This was an uncommon lesion in Study GLP 83009. When it did occur, it could be attributed to obstruction of the esophagus by test material and attendant granulomatous inflammatory response and fibrosis at, or near, the esophageal hiatus of the diaphragm. Severity grade criteria:

- 1 = Small focal area of necrosis limited to the esophageal mucosa and a mild local neutrophilic infiltrate.
- 2 = Large area of necrosis extending through the mucosa into the submucosa with prominent suppurative exudate and hemorrhage.
- 3 = Similar to grade 2 but necrosis and hemorrhage extend into the muscular wall of the esophagus.
- 4 = Necrosis, hemorrhage, and suppurative exudate extend throughout the thickness of the esophageal wall. There is destruction of large amounts of esophageal tissue throughout its thickness.

**SALIVARY GLANDS**

Parotid, mandibular, and sublingual glands were examined routinely. The gland in which the following lesions were observed are identified by notations in the special histologic comments on the Xybyon program.

1. ATROPHY AND LOSS OF ACINAR TISSUE - This lesion consists of absence of acinar secretory cells. Affected lobules consist of ductal structures in a fibrovascular stroma. Such lesions are usually focal, affecting a small lobule of salivary tissue.

**Appendix I (cont.): GLOSSARY OF TERMS  
FOR PATHOLOGY FINDINGS**

Severity grade criteria:

- 1 = One lobule affected.
- 2 = Two or three lobules affected.
- 3 = Four to six lobules affected.
- 4 = More than six lobules affected.

2. INFLAMMATION, SUBACUTE - Presence of focal or diffuse infiltrations of inflammatory cells (primarily lymphocytes, macrophages, and plasma cells) possibly accompanied by minimal to moderate loss of glandular tissue through necrosis. Severity grade criteria:

- 1 = One to three foci of mononuclear cells no larger than the diameter of a secretory acinus.
- 2 = Four to six mononuclear foci.
- 3 = Six to ten inflammatory cell foci or up to two foci of necrosis no larger than the diameter of a secretory acinus.
- 4 = More than ten inflammatory cell foci and/or more than three foci of necrosis or diffuse inflammatory involvement of more than 50% of the salivary gland.

3. ADENOCARCINOMA - Malignant neoplastic growth of salivary glandular or ductal epithelium. Neoplastic cells are arranged in cords, nests, or acini often forming papillary fronds or large glandular spaces filled with granular basophilic secretory product. Cells are cuboidal to columnar with pale-staining granular cytoplasm and round to slightly oval vesicular nuclei. Neoplastic cells are usually rather well differentiated and without pleomorphism. Mitotic figures are not numerous. A small amount of fibrous stroma is present and neoplastic epithelial cells infiltrate this tissue. In some of the cystic glandular spaces there are red blood cells and brightly eosinophilic rhomboid hemoglobin crystals.

**LACRIMAL GLAND (HARDERIAN GLAND)**

1. INFLAMMATION, SUBACUTE TO CHRONIC - Presence of focal or diffuse infiltrations of lymphocytes, macrophages, and plasma cells, possibly accompanied by minimal to moderate loss of glandular tissue through either necrosis or atrophy. Fibrosis may or may not be present. In most cases there is intraductal accumulation of inspissated secretory material.

**Appendix I (cont.): GLOSSARY OF TERMS  
FOR PATHOLOGY FINDINGS**

Severity grade criteria:

- 1 = One to three foci of mononuclear cells no larger than the diameter of a secretory acinus.
- 2 = Four to six mononuclear foci; fibrosis may be present.
- 3 = Six to ten mononuclear foci with or without fibrosis and no more than two necrotic foci no larger than the diameter of a secretory acinus.
- 4 = More than ten inflammatory/fibrotic foci and/or three or more foci of necrosis, or diffuse inflammation and fibrosis of more than 50% of the gland.

2. ATROPHY AND/OR LOSS OF ACINAR TISSUE - Absence of acinar secretory cells. Affected lobules consist of ductal structures in a fibrovascular stroma. Such lesions are usually focal, affecting a small lobule of lacrimal gland tissue. Severity grade criteria:

- 1 = One lobule affected.
- 2 = Two or three lobules affected.
- 3 = Four to six lobules affected.
- 4 = More than six lobules affected.

**EXORBITAL LACRIMAL GLAND**

1. ACINAR ATROPHY - Microscopic appearance and grading criteria are identical to that of the Harderian gland described above.

2. INFLAMMATION, SUBACUTE TO CHRONIC - Microscopic appearance and grading criteria are identical to that of the Harderian gland described above.

**HEART**

1. CARDIOMYOPATHY - This is a very common lesion in aging Fischer-344 rats. In younger animals, it is usually seen as mild to moderate focal myocarditis. As the rats age, the disease progresses to myocardial degeneration characterized by vacuolation and atrophy of myocardial cells followed by fibrosis and loss of myocardial fibers. The heart is not uniformly affected by these changes.

**Appendix I (cont.): GLOSSARY OF TERMS  
FOR PATHOLOGY FINDINGS**

Severity grade criteria:

- 1 = One to five small foci of lymphocytes between myocardial fibers or around blood vessels.
- 2 = Six to ten foci of lymphocytes and/or minimal to mild vacuolar change in myocardial fibers. Fibrosis may be present but is limited to less than 25% of the section.
- 3 = More than ten foci of lymphocytes and/or vacuolization of myofibers. Mild fibrosis involving no more than 50% of the section.
- 4 = More than half of the section is involved in degeneration and fibrosis. Moderate to severe myofiber atrophy is present.

2. ATRIOCAVAL EPITHELIAL MESOTHELIOMA - This lesion was not observed in the second year of Study GLP 83009. In the first year of this study, one rat developed this unusual tumor. The lesion was completely described and discussed in the interim report that covered the first year of this two-year study.

3. MEDIAL HYPERTROPHY OF MUSCULAR ARTERIES - Thickening of the muscular medial layer of the arteries in the myocardium. Severity grade criteria:

- 1 = Minimal detectable thickening.
- 2 = Mild thickening, less than twice normal thickness.
- 3 = Moderate thickening of the media, greater than twice the normal thickness, often producing distortion of arterial lumen.
- 4 = Marked thickening of the media, approximately three times the normal thickness, with marked distortion and constriction of the arterial lumen.

4. MURAL THROMBUS - Lesion consists of a mass of fibrin intermixed with red blood cells and neutrophils attached to the endocardial surface. Adjacent myocardial cells may undergo degeneration and necrosis and infiltration of inflammatory cells. The lesion is graded as "Present."

5. LARGE GRANULAR LYMPHOCYTE LEUKEMIA - See "General Diagnoses" above.

**Appendix I (cont.): GLOSSARY OF TERMS  
FOR PATHOLOGY FINDINGS**

6. PRESENCE OF METASTATIC NEOPLASM - See "General Diagnoses" above.

**LUNGS**

1. FOCAL HYPERPLASTIC PROLIFERATION OF TYPE 2 ALVEOLAR EPITHELIAL CELLS WITH OR WITHOUT INFLAMMATORY CELL INFILTRATION - Non-neoplastic proliferation of alveolar type 2 cells. This lesion frequently occurs in centriacinar regions of the lung at the junction of conducting airways and exchange tissue. It also occurs near pulmonary adenomas in alveoli whose ventilation has been obstructed by the tumor. In these areas, alveolar septae are lined continuously by type 2 epithelium. Affected alveoli are frequently collapsed. Type 2 cell proliferation is frequently accompanied by infiltration of alveolar macrophages both within affected alveolar lumens and within the interstitium. Severity grade criteria:

- 1 = Focal lesion less than the diameter of a 20X microscopic field.
- 2 = Lesion is larger than the diameter of a 20X field but smaller than that of a 4X field.
- 3 = As many as three focal lesions with diameters no larger than that of a 4X field may be present.
- 4 = More than four focal lesions with diameters as large as a 4X field are present.

2. PLEURITIS WITH SUBJACENT CHRONIC PNEUMONIA - Presence of inflammatory cells and fibrin on and in the visceral pleura. Inflammatory cells, fibrin, and possibly the replacement of type 1 alveolar epithelium with type 2 cells are present in adjacent pulmonary parenchyma. Severity grade criteria for this lesion are as follows:

- 1 = Area of inflammation is less than the diameter of a 20X microscopic field.
- 2 = Area of inflammation is greater than a 20X field but less than a 10X field.
- 3 = Involvement of more than 75% of a lung lobe.
- 4 = Involvement of the entire area of 2 or more lobes.

3. PULMONARY EDEMA - Presence of protein-rich (pink-staining) fluid within pulmonary alveoli.



**Appendix I (cont.): GLOSSARY OF TERMS  
FOR PATHOLOGY FINDINGS**

Severity grade criteria:

- 1 = Edema fluid in up to 10 alveoli.
- 2 = Edema fluid in 10-50 alveoli.
- 3 = Edema fluid in 25% to 50% of the alveoli in one lobe.
- 4 = Edema fluid in 25% to 50% of alveoli in 2 or 3 lobes.
- 5 = Edema fluid in more than 50% of the alveoli in all lobes.

4. VASCULAR CONGESTION - Pulmonary vascular spaces are distended with large amounts of blood. Since the animals that were euthanized were killed by exsanguination while under barbiturate anesthesia, the amount of blood in the pulmonary vasculature is extremely variable. Animals that died naturally have much more blood in their lungs. For these reasons, vascular congestion was coded only when the congestion constituted a prominent histologic characteristic of the lung.

5. THROMBUS - Presence of a mass of fibrin mixed with red blood cells and leukocytes attached to the luminal wall of a vessel. Tissues supplied by the thrombosed vessel may undergo ischemic necrosis and infiltration of inflammatory cells. Severity grade criteria for this lesion are as follows:

- 1 = Thrombus is present; secondary ischemic changes involve fewer than 50 alveoli.
- 2 = Thrombus is present; secondary ischemic changes involve up to 25% of a lung lobe
- 3 = Thrombus is present in one to three lobes with ischemic change affecting less than 50% of the tissues in affected lobes.
- 4 = Thrombus is present in three or more lobes and/or ischemic change affects more than 50% of the tissue in involved lobes.

6. MINERALIZATION OF PULMONARY ARTERIES - Focal dense deposits of mineral within the wall of large to medium-sized arteries in the lung. Severity grade criteria for this lesion are as follows:

- 1 = A single focus of mineral which produces no distortion of the vessel wall.

**Appendix I (cont.): GLOSSARY OF TERMS  
FOR PATHOLOGY FINDINGS**

- 2 = Two or three small foci of mineralization which produce no distortion of the vessel wall.
- 3 = Four or more small foci of mineral which distort the vessel wall minimally, or one larger focus which causes moderate distortion of the vessel wall.
- 4 = More than one large focus which causes moderate distortion of the vessel wall.

7. PNEUMONIA, GRANULOMATOUS - The infiltration of lymphocytes, macrophages, and neutrophils with variable numbers of large multinucleated giant cells. Necrosis may be present in the center of granulomas. These lesions are usually focal or multifocal and are located within centriacinar areas, proximal alveoli, alveolar ducts, and terminal bronchioles. Severity grade criteria for this lesion are as follows:

- 1 = Less than 10% of the lung tissue affected.
- 2 = 10% to 25% of the lung tissue affected.
- 3 = 25% to 50% of the lung tissue affected.
- 4 = More than 50% of the lung tissue is affected.

8. PNEUMONIA, INTERSTITIAL, CHRONIC - Presence of chronic inflammation within the pulmonary parenchyma. These inflammatory lesions usually do not have any particular anatomic orientation. They may be focal, multifocal, or diffuse. Lesions consist of infiltrations of macrophages, lymphocytes, and neutrophils into the interstitium and alveoli, and the replacement of the normal mature type 1 alveolar epithelial cells with type 2 pneumocytes. Fibrosis of the interstitium may be present in older lesions. Multinucleated giant cells are not present. Severity grade criteria for this lesion are as follows:

- 1 = Less than 10% of the lung tissue affected.
- 2 = 10% to 25% of the lung tissue affected.
- 3 = 25% to 50% of the lung tissue affected.
- 4 = More than 50% of the lung tissue is affected.

9. PERIVASCULAR LYMPHOID AGGREGATIONS (CUFFING) - Presence of lymphoid tissue, lymphocytes, primitive reticular cells, and plasma cells in perivascular connective tissue. This diagnosis is used only when definite vascular orientation of the lymphoid tissue is evident. Since severity grading of such a lesion is irrelevant, the lesion is coded only as being "Present."

**Appendix I (cont.): GLOSSARY OF TERMS  
FOR PATHOLOGY FINDINGS**

10. **LARGE GRANULAR LYMPHOCYTE LEUKEMIA, METASTATIC** - Presence of neoplastic lymphocytes within the vascular spaces, perivascular tissues, and parenchyma of the lung. This lesion is coded only when large numbers of neoplastic cells constitute a prominent histologic feature and/or when the normal histologic structure of the lung is destroyed or effaced by the presence of neoplastic cells.

11. **PRESENCE OF METASTATIC NEOPLASM** - Presence of neoplastic cells (other than lymphocytes or sarcoma cells which have a specific diagnosis) anywhere within the lung. Lesion is coded as + with the two-letter abbreviation for the organ or tissue of the primary site. Example: + TH indicates metastatic neoplasm from the thyroid.

12. **ALVEOLAR HEMORRHAGE** - Presence of red blood cells within the alveolar spaces of the lung. In almost all instances in this study, this lesion is caused by aspiration of blood at the time of euthanasia, and is unrelated to the experimental treatment. Severity grade criteria for this lesion are as follows:

- 1 = Blood in less than 10 alveoli.
- 2 = Blood in 10 to 50 alveoli.
- 3 = Blood in 25% of the alveoli.
- 4 = Blood in 25% to 50% of the alveoli.

13. **PERIBRONCHIAL LYMPHOID HYPERPLASIA** - Normal non-neoplastic lymphoid aggregates were present in peribronchial connective tissues of nearly every animal in this study. This lesion is coded only when the amount of lymphoid tissue appears to be excessive. Usually in such cases there are other inflammatory lesions in the lungs. Severity grade criteria for this lesion are as follows:

- 1 = Detectable increase in lymphoid tissue limited to airway submucosa and/or peribronchial connective tissue.
- 2 = Increase in submucosal lymphoid tissue which extends through the airway epithelium.
- 3 = Increase in submucosal and peribronchial lymphoid tissue which distorts or compresses airway lumens or adjacent parenchyma.
- 4 = Increase in lymphoid tissue which causes moderate to marked compression of airway lumens and adjacent parenchyma.

**Appendix I (cont.): GLOSSARY OF TERMS  
FOR PATHOLOGY FINDINGS**

14. BRONCHIOLAR/ALVEOLAR ADENOMA - Benign tumor of bronchiolar epithelial or alveolar epithelial origin. These lesions are usually small focal proliferations of cuboidal to columnar epithelial cells which compress adjacent pulmonary tissue. Cells are frequently arranged in long serpentine cords. Cells that are usually very well differentiated and uniform have poorly stained clear cytoplasm and small basally located ovoid nuclei. Few mitotic figures are present.

15. PRESENCE OF METASTATIC SARCOMA - Presence of neoplastic mesenchymal cells anywhere within the parenchyma of the lung or on the pleural surface. The primary site for these tumors in this study is the abdominal cavity where the tumors develop in the fibrous connective tissue constituting part of the granulomatous foreign-body reaction incited by the presence of the test material. The pulmonary lesions are coded as + AC indicating presence of the metastatic sarcoma in the lung with the primary site being the abdominal cavity. Histologic characteristics of the tumor are documented in special histologic comments under *Abdominal Cavity*.

**THYMUS**

1. PLEURITIS - Presence of acute, subacute, or chronic inflammatory reaction on the surface of the thymus. This lesion includes the infiltration of neutrophils, mononuclear inflammatory cells, and the proliferation of fibroblasts on the surface of the thymus. Severity grade criteria for this lesion are as follows:

- 1 = Inflammatory lesion less than the diameter of one 40X microscopic field.
- 2 = Inflammatory lesion less than the diameter of one 20X microscopic field.
- 3 = Inflammation involves 25% to 50% of the thymus.
- 4 = Inflammation involves more than 50% of the thymus.

2. ADENOMA, ENDOCRINE ORIGIN, NOT OTHERWISE SPECIFIED - A small (less than 1 mm in diameter) circumscribed proliferation of cells characterized by finely granular weakly eosinophilic cytoplasm and small, round to ovoid nuclei. Cells are arranged in small nests and cords separated by delicate fibrovascular stroma. The lesion is situated within thymic tissue. Histologically, the cells comprising this small adenoma resemble parafollicular

**Appendix I (cont.): GLOSSARY OF TERMS  
FOR PATHOLOGY FINDINGS**

("C" cells) of the thyroid or cells from the parathyroid glands. Carotid or aortic body origin cannot be ruled out. Only one such lesion was observed in Study GLP 83009.

3. THYMOMA - Benign neoplastic proliferation of thymic epithelial cells. The lesion is a well-demarcated, un-encapsulated proliferation of round to oval cells having eosinophilic cytoplasm with poorly demarcated cellular boundaries and fairly dense round to ovoid nuclei. Mitotic figures are rare. Cells are arranged in nests and bundles separated by very fine fibrous stroma. There are a few widely scattered cells or clusters of cells which are partially keratinized. The lesion is confined to one fairly large lobule of the thymus. There was only lesion of this type observed in Study GLP 83009.

4. ADENOCARCINOMA, NOT OTHERWISE SPECIFIED, SITE OF ORIGIN UNDETERMINED - This unusual lesion situated within the thymus consists primarily of proliferating epithelial cells and very few lymphocytes. Epithelial cells are arranged in small nests or cords with some papillary forms. The lesion is well demarcated from adjacent fat, but is not encapsulated. Cells have large round to oval vesicular nuclei and abundant eosinophilic cytoplasm with indistinct plasma membranes. Mitotic figures are rare. Scattered throughout the tumor are a few spaces filled with eosinophilic material, a few degenerating epithelial cells, and inflammatory cells. There was only one lesion of this type observed in Study GLP 83009.

**SPLEEN**

Because of the method of euthanasia used in this study, the amount of blood in the spleen varies considerably. Since this feature has nothing to do with the experimental treatment or toxic effects of the test material, no diagnoses of "splenic congestion" or other indication of the amount of blood in the spleen are recorded.

1. LYMPHOID HYPERPLASIA OF SPLENIC CORPUSCLES - Non-neoplastic proliferation of lymphoid cells in splenic white pulp and perifollicular areas. Severity grade criteria for this lesion are as follows:

- 1 = Detectable increase in diameter of splenic corpuscles that exceeds that of the average spleen.

**Appendix I (cont.): GLOSSARY OF TERMS  
FOR PATHOLOGY FINDINGS**

- 2 = Increase in diameter of splenic corpuscles up to twice normal size.
- 3 = Increase in diameter of splenic corpuscles two to three times normal size.
- 4 = Marked increase in diameter of splenic corpuscles such that white pulp areas are nearly confluent.

2. FIBROSIS, CAPSULAR - Non-neoplastic proliferation of fibrous connective tissue in the splenic capsule. This may be part of an adhesion caused by the test material, but this diagnosis is not used when test material is present. If test material is present, diagnosis #11 below is used. Severity grade criteria for *Fibrosis, Capsular* are as follows:

- 1 = Focal area of fibrosis less than diameter of one 40X microscopic field.
- 2 = Two or three focal areas of fibrosis, similar to those in grade 1, or one area involving 10% to 25% of the surface of a cross-section of spleen.
- 3 = Fibrosis involving between 25% to 50% of the surface of a splenic cross-section.
- 4 = Fibrosis involving more than 50% of the surface of a splenic cross-section.

3. INFARCTION, CHRONIC - Sharply demarcated area(s) of splenic parenchyma comprised primarily of fibrous connective tissue and/or splenic reticular network with variable numbers of red blood cells and hemosiderin-laden macrophages. Severity grade criteria for this lesion are as follows:

- 1 = One focal area of infarction approximating the area of one 40X microscopic field.
- 2 = One or more areas of infarction whose total area is between 10% to 25% of the cross-sectional area of the spleen.
- 3 = One or more areas of infarction occupying 25% to 50% of the cross-sectional area of the spleen.
- 4 = One or more areas of infarction occupying more than 50% of the cross-sectional area of the spleen.

4. LARGE GRANULAR LYMPHOCYTE LEUKEMIA, METASTATIC - This common neoplastic disease of Fischer-344 rats usually begins in the spleen. In very early cases, there is a decreased

**Appendix I (cont.): GLOSSARY OF TERMS  
FOR PATHOLOGY FINDINGS**

number of normal lymphoid cells in white pulp (lymphoid depletion), and proliferation of neoplastic lymphocytes in red pulp areas. Neoplastic cells are large, round, and have abundant finely granular, weakly eosinophilic cytoplasm and large round vesicular nuclei. Mitotic figures are numerous and some of these are large and bizarre. As the disease progresses, the numbers of neoplastic cells increase greatly, causing severe splenic enlargement. Infarction and necrosis are common in severely affected spleens. Because of the features of the Xybyon® program, the primary site for this entity was coded under *Whole Body*, and each organ having significant involvement was coded as having a metastatic lesion.

5. EXTRAMEDULLARY HEMATOPOIESIS - In most of the animals in this study, only a few hematopoietic cells are present in the spleen. This diagnosis is used only in the few animals having fairly large numbers of hematopoietic cells in the spleen. No attempt is made to indicate the severity of this change. The lesion is indicated as "Present."

6. HEMOSIDERIN PIGMENTATION (RED PULP) - Most rats in this study have small amounts of hemosiderin pigment in splenic red pulp. However, this finding is coded only when there appears to be substantially more pigment present than in the average rat spleen. The change is graded as "Present" with no attempt to quantify it with a severity grade.

7. SMOOTH MUSCLE HYPERTROPHY, CAPSULE AND TRABECULAE - Presence of increased size of smooth muscle cells within trabeculae and capsule increasing the thickness of these structures. Change coded as "Present" with no attempt to grade severity.

8. HISTIOCYTIC INFILTRATE, CAPSULE AND OMENTUM - Presence of histiocytes on the splenic capsule and adjacent omentum. Graded as "Present."

9. BENIGN HYPERTROPHIC NODULE - One or more sharply demarcated nodules which elevate the splenic capsule and consist of non-neoplastic proliferation of lymphoid cells. Some of these structures may resemble greatly enlarged splenic corpuscles except that the central artery is usually absent. This lesion is graded as "Present."

10. PRESENCE OF METASTATIC SARCOMA - See comments and

**Appendix I (cont.): GLOSSARY OF TERMS  
FOR PATHOLOGY FINDINGS**

description under "General Diagnoses" above.

11. COMPOUND-RELATED INFLAMMATORY REACTION - See comments and description above under "General Diagnoses."

12. PRESENCE OF METASTATIC NEOPLASM - See comments and description above under "General Diagnoses."

**LYMPH NODES**

In routine histologic evaluation of animals from this study, the mediastinal nodes, mesenteric nodes, and nodes in the cervical connective tissue adjacent to salivary glands (collectively referred to as "cervical nodes") were examined. Diagnoses for all nodes are coded under the single heading "lymph nodes" in the Xyblon computer program. The specific nodes having a coded lesion are annotated in "special histologic comments" section of the program.

1. LYMPHOID HYPERPLASIA - Non-neoplastic proliferation of lymphoid cells in cortical and perifollicular areas of the lymph node. Severity grade criteria for this change are as follows:

- 1 = Detectable increase in diameter of lymphoid follicles.
- 2 = Increase of lymphoid follicles up to twice normal size.
- 3 = Increase of lymphoid follicles to two or three times normal size.
- 4 = Nearly confluent proliferation of lymphoid cells in cortex of the node.

2. RED BLOOD CELLS, HEMOSIDERIN AND/OR ERYTHROPHAGOCYTOSIS WITHIN MEDULLARY SINUSES - Finding is self-explanatory. Graded as "Present."

3. LARGE GRANULAR LYMPHOCYTE LEUKEMIA, METASTATIC - See description and comments under "General Diagnoses" above.

4. HISTIOCYTIC INFILTRATION, SUBCAPSULAR AND MEDULLARY SINUSES - Lymph nodes from most rats in this study have moderate numbers of histiocytic cells in medullary areas. This finding is coded only when these cells are very numerous. The change is coded as "Present."



**Appendix I (cont.): GLOSSARY OF TERMS  
FOR PATHOLOGY FINDINGS**

5. REACTIVE HYPERPLASIA -- Non-neoplastic, noninflammatory increase in cellularity in lymph nodes. Lymphoid follicles are increased in size and number. There are increased numbers of cells in perifollicular areas of the cortex. Medullary cords and sinuses frequently contain large numbers of plasma cells. Eosinophilic protein-rich edema fluid may be present. Change is coded as "Present."

6. PRESENCE OF METASTATIC NEOPLASM - See description and comments under "General Diagnosis" above.

7. DILATED AND/OR CYSTIC MEDULLARY SINUSES - Self-explanatory. Coded as "Present."

8. PRESENCE OF METASTATIC SARCOMA - See description and comments under "General Diagnoses" above.

**LIVER**

1. COMPOUND RELATED INFLAMMATORY REACTION - See description and comments under "General Diagnoses" above.

2. BILE DUCTULE EPITHELIAL HYPERPLASIA/CHOLANGIOFIBROSIS - Non-neoplastic proliferation of bile ducts frequently accompanied by periportal fibrosis. Fibrosis is considered a part of this lesion and is not coded separately. This is a very frequently observed lesion in rats in this study. The change is usually fairly uniform in different lobes of the liver. Severity grading is based on the number of bile ductule cross sections (lumens) in the average portal triad:

- 1 = Three lumens.
- 2 = Four to 15 lumens.
- 3 = 15 to 25 lumens.
- 4 = More than 25 lumens.

3. HEPATITIS - Subacute inflammatory lesions in the liver. These lesions are usually focal or multifocal in this study. They consist of small focal accumulations of macrophages, lymphocytes, and occasional neutrophils within the hepatic parenchyma. Necrosis or degeneration of hepatocytes within these inflammatory cell foci are observed occasionally. Severity grade criteria are based on the number of inflammatory cell foci present:

- 1 = One to three foci.

**Appendix I (cont.): GLOSSARY OF TERMS  
FOR PATHOLOGY FINDINGS**

- 2 = Four to 10 foci.
- 3 = Ten to 20 foci.
- 4 = More than 20 foci.

4. NON-NEOPLASTIC FOCI AND AREAS OF CELLULAR ALTERATION - Three distinctive foci or areas of cellular alteration are present in livers of rats in this study. These lesions are named for the morphologic characteristics of their component cell populations, e.g., basophilic cell foci, clear cell foci, or eosinophilic cell foci. These lesions usually consist of a uniform cell type, although they may occasionally contain mixtures of cell types. Lesions equal to or smaller than the size of a liver lobule are *foci* while a lesion larger than a lobule is called an *area*. Cellular arrangement within these lesions varies little from normal hepatic parenchyma. The cellular appearance and staining characteristics within these lesions is distinctly different from adjacent normal cells. Hepatic cords of the lesion merge imperceptibly with those of the surrounding tissue without compression. Foci or areas of cellular alteration may be single or multiple, and different morphologic types may occur in the same liver section. Their distribution within the liver is not uniform, and they may coexist with any other type of hepatic lesion.

4A. FOCUS OF CELLULAR ALTERATION, BASOPHILIC CELLS - Cells are usually slightly smaller than normal and cytoplasm is distinctly basophilic in hematoxylin and eosin stained sections. The plates of hepatocytes may be tortuous due to increased numbers of cells.

4B. FOCUS OF CELLULAR ALTERATION, CLEAR CELLS - A sharply demarcated focus or area of cells having a clear zone around the nucleus in which, in appropriately stained sections, glycogen can be demonstrated. Cells may be of normal size or enlarged.

4C. FOCUS OF CELLULAR ALTERATION, EOSINOPHILIC CELLS - A well-demarcated focus or area of hepatocytes which have acidophilic cytoplasm causing a "ground glass" appearance. Inclusions may be present in the cytoplasm. Such cells are usually enlarged with enlarged nuclei and prominent nucleoli. Cords may be slightly irregular. Severity grade criteria for these lesions are as follows:

- 1 = One focus.

**Appendix I (cont.): GLOSSARY OF TERMS  
FOR PATHOLOGY FINDINGS**

- 2 = Two to four foci, or one area alone or in combination with 1 to 4 foci.
- 3 = Five to eight foci, or two to three areas.
- 4 = Eight or more foci, or four or more areas.

5. HEPATOCYTIC VACUOLATION - Presence of small to large intracytoplasmic vacuoles within hepatocytes. In sections appropriately prepared and stained, fat can be demonstrated. Such change is not uniform within the liver. Severity grade criteria for this change are as follows:

- 1 = Minimal detectable involvement.
- 2 = 10% to 20% of the hepatocytes are vacuolated.
- 3 = 20% to 40% of the hepatocytes are vacuolated.
- 4 = More than 40% of the hepatocytes are vacuolated.

6. TELANGIECTASIS - Dilatation of hepatic sinusoids. Dilated sinusoids are usually filled with blood. Severity grade criteria for this lesion are as follows:

- 1 = Focal dilatation of sinusoids occupying a diameter of one 40X microscopic field.
- 2 = Widely scattered multiple foci occupying an area of one 40X microscopic field.
- 3 = 10% to 20% of the liver section affected.
- 4 = More than 20% of the liver section affected.

7. NECROSIS - Death of hepatocytes. This diagnosis is used to indicate necrosis of hepatocytes without any particular anatomic pattern. Necrosis is designated as either focal or multifocal, and a severity grade is indicated. See *Necrosis, Periacinar and Necrosis, Hepatocytic, Individual Cells* below for necrotic lesions having specific anatomic patterns of distribution. Severity grade criteria for the diagnosis, *Necrosis*, are as follows:

- 1 = Necrotic area is no larger than a 40X microscopic field.
- 2 = Combined areas of focal or multifocal necrotic lesions are less than 10% of the liver section.
- 3 = Combined areas of focal or multifocal necrotic lesions are 10% to 20% of the liver section.
- 4 = Combined areas of focal or multifocal necrotic lesions are 20% to 40% of the liver section.

**Appendix I (cont.): GLOSSARY OF TERMS  
FOR PATHOLOGY FINDINGS**

5 = Combined areas of focal or multifocal necrotic lesions are greater than 40% of the liver section.

8. FIBROSIS, CAPSULAR, (NO COMPOUND) - Presence of increased fibrous connective tissue on the capsule of the liver. There is minimal inflammatory cell infiltration and no foreign-body giant cells. This lesion is coded as "Present."

9. PERIportal MONONUCLEAR CELLULAR INFILTRATION - Presence of lymphocytes, macrophages, and plasma cells in the periportal connective tissue. Severity grade criteria for this lesion are as follows:

- 1 = Small, widely scattered foci not to exceed more than three foci per liver section.
- 2 = Four to six small foci of mononuclear cells.
- 3 = Six to 10 small foci or presence of three or more foci that are as large as a liver lobule.
- 4 = More than ten small foci or more than four large foci.

10. CYSTIC DEGENERATION - Presence of focal or multifocal areas characterized by cysts with pale eosinophilic amorphous material, hepatocytes that are enlarged by the presence of clear cytoplasmic vacuoles, and an occasional necrotic hepatocyte. There may be slight peripheral compression of adjacent hepatic parenchyma. The lesion is coded as "Present."

11. HEPATOCYTIC DEGENERATIVE CHANGES (NON-NECROTIC) - Presence of diffuse areas in which hepatocytes show some or all of the following changes: cellular enlargement, nuclear enlargement, nuclear hyperchromasia, multiple nuclei, microvesicular cytoplasmic change. Affected hepatocytes are in normal arrangement and necrosis is not present. This change occurs most frequently in livers severely affected with large granular lymphocyte leukemia. Severity grade criteria are based on both the number of hepatocytes affected (percent of sectional area) and the severity of the cytological abnormalities listed above:

- 1 = Minimal cytological abnormality affecting less than 10% of the section.
- 2 = Mild cytological abnormalities and/or more than 20% of the section affected.

**Appendix I (cont.): GLOSSARY OF TERMS  
FOR PATHOLOGY FINDINGS**

- 3 = Moderate cytological abnormalities and/or more than 40% of the section affected.
- 4 = Marked cytological abnormalities and/or more than 50% of the section affected.

12. NECROSIS, HEPATOCYTIC, INDIVIDUAL CELLS - Presence of coagulative necrosis of individual hepatocytes. There is no specific anatomic orientation or pattern to the necrotic lesion. This lesion is most frequently observed in cases of large granular lymphocyte leukemia or the nonspecific multifocal hepatitis described in diagnosis #3 above. Occasionally, necrotic cells are present within areas of hepatocytic vacuolization and adjacent to areas of compound-related inflammatory reaction. Severity grade criteria are based on the number of necrotic hepatocytes per high power microscopic field:

- 1 = One to three necrotic cells per high power field. The area affected is limited to that of a 20X field.
- 2 = One to three necrotic cells per high power field, with large diffuse areas of involvement.
- 3 = Four to six necrotic hepatocytes per high power field; diffuse area of involvement.
- 4 = More than seven necrotic hepatocytes per high power field; diffuse involvement. If necrosis involves foci of hepatocytes rather than individual cells, the diagnosis of NECROSIS (#7 above) is used with appropriate distribution modifier and severity grade.

13. BENIGN HYPERPLASTIC NODULE(S) - Spherical proliferation of hepatocytes without cytologic atypia. Normal hepatic architecture is present but it may be distorted; portal triads may be present. There is mild compression of adjacent parenchyma. Hepatocytes within a focus of hyperplasia are usually uniform and have a homogeneous growth pattern, but features such as hypertrophy, cytoplasmic vacuolation, and increased numbers of mitoses may be present. Often the distinction between focal hyperplasia and a focus of cellular alteration rests solely on the degree of cytologic alteration and compression of adjacent parenchyma. Hyperplastic lesions may reach several millimeters in diameter and are frequently seen as relatively distinct lesions in histologic sections. The lesion is coded as "Present" with an indication of multifocal distribution if multiple lesions are present.

**Appendix I (cont.): GLOSSARY OF TERMS  
FOR PATHOLOGY FINDINGS**

14. NECROSIS, PERIACINAR - Coagulative necrosis of hepatocytes with a definite orientation around central veins. In more severe cases the necrotic change may bridge from central vein to central vein, or from central vein to portal areas. Stromal collapse may occur; the necrotic area may be filled with blood. Variable numbers and types of inflammatory cells may be present. Adjacent lobules and/or the capsule may be distorted. Changes are usually uniform with most or all the lobules affected. Severity grade criteria:

- 1 = Minimal detectable necrosis around central veins.
- 2 = Definite necrosis involving nearly all periacinar hepatocytes in nearly all lobules.
- 3 = Bridging of periacinar areas by necrotic cells and accompanying inflammatory cells.
- 4 = Necrosis and bridging of periacinar areas with stromal collapse and blood pooling.

15. LARGE GRANULAR LYMPHOCYTE LEUKEMIA, METASTATIC - See comments and description under "General Diagnoses" above.

16. FIBROSIS, PARENCHYMAL (SCARRING) - Presence of fibrous connective tissue and minimal inflammatory cell infiltrate within the liver parenchyma. This lesion occurs most frequently near areas of compound-related inflammatory reaction. Severity grade criteria:

- 1 = An area of fibrosis no larger than that of a 40X microscopic field.
- 2 = A fibrotic area as large as a 20X microscopic field.
- 3 = A fibrotic area as large as 2 to 4 liver lobules.
- 4 = A fibrotic area larger than 5 liver lobules.

17. HEPATOCYTE COALESCING MICROVESICULAR (FATTY) CHANGE LEADING TO NECROSIS AND MINERALIZATION - Microscopically, this lesion consists of microvesicular cytoplasmic change in hepatocytes, rupture and disintegration of affected cells, consequent enlargement of adjacent sinusoids, and the presence of nearly colorless to light blue mineralized crystals. The lesion usually has a focal or multifocal distribution. Frozen sections stained with oil-red-O or Sudan Black demonstrate the presence of fat in vacuolated hepatocytes near the dilated sinusoids. Numerous crystals

**Appendix I (cont.): GLOSSARY OF TERMS  
FOR PATHOLOGY FINDINGS**

are present in these areas. Sections stained with Alizarin Red-S and Von Kossa stain demonstrate that the crystals contain both calcium and phosphate. Periodic Acid-Schiff stains are noncontributory. The interpretation of these findings is that fatty degenerative changes in hepatocytes lead to necrosis and subsequent saponification of the accumulated lipid. Severity grade criteria:

- 1 = Changes occur in small widely scattered foci.
- 2 = Foci are more numerous and have a random distribution. At least one focus per 20X microscopic field is present, but is restricted to one liver lobe.
- 3 = At least one focus per 20X field is present in more than one liver lobe.
- 4 = Large numbers of foci (one per 40X field) are present in one or more hepatic lobes.

18. PRESENCE OF METASTATIC SARCOMA - See comments and description under "General Diagnoses" above.

19. HEPATOCELLULAR CARCINOMA - Malignant neoplasm of hepatocytic origin. Diagnostic criteria for hepatocellular carcinoma are well documented in the literature. The criteria followed in this study were those of Maronpot et al., Toxicologic Pathology, 14:263-273, 1986. Criteria of importance include cellular atypia, irregular shape, local invasiveness, haphazardly arranged cells, broad sheets of cells, trabecular patterns, and glandlike formations. Vascular invasion or metastases are not essential for making the diagnosis of carcinoma, but may be present. Hemorrhage and necrosis may be present.

20. PRESENCE OF METASTATIC NEOPLASM - See descriptions and comments under "General Diagnoses" above.

**KIDNEY**

1. PROGRESSIVE RENAL DISEASE - A progressive complex of degenerative changes affecting all anatomic components of the renal cortex and medulla. Interstitial changes begin as small aggregates of mononuclear inflammatory cells and progress to interstitial fibrosis and focal mineralization. Tubular epithelial cells undergo degenerative changes such as cytoplasmic vacuolization and accumulation of hyaline droplets. Cells may become flattened due to accumulation of

**Appendix I (cont.): GLOSSARY OF TERMS  
FOR PATHOLOGY FINDINGS**

eosinophilic fluid in the lumen, or they may become basophilic and hyperplastic during regenerative attempts. Tubular basement membranes are frequently thickened. Ultimately, both tubular dilatation and atrophy occur. Glomerular changes consist of thickening of Bowman's capsule, pericapsular fibrosis, hypercellularity of the glomerular capillary tuft, and thickening of the mesangial matrix. These changes progress to glomerular sclerosis and/or atrophy with cystic dilatation of Bowman's space. Hyalinization of arteriole walls and mineralization of tubular basement membranes and necrotic tubular epithelial cells may be present in severe stages of the disease. Severity grade criteria:

- 1 = There are occasional aggregates of lymphocytes near small vessels and between tubules. An occasional tubule may be dilated and contain a hyaline cast.
- 2 = More tubules are dilated and contain casts. Tubules have degenerative changes and basement membranes are thickened. Glomeruli may be hypercellular. Up to 25% of the renal cortex is affected.
- 3 = Numerous tubules are dilated and contain hyaline material. Tubular regeneration may be present. Interstitial and periglomerular fibrosis is present. Glomerular tufts are thickened and hypercellular and a few glomeruli are atrophied and dilated. Renal capsular surface is irregular. Up to 50% of the kidney is involved.
- 4 = Tubular dilatation, casts, necrosis, and mineralization are widespread. Marked interstitial fibrosis, glomerular atrophy and dilatation, and irregularities of the capsular surface are present. There is hyalinization of small vessel walls. More than 50% of the kidney is involved.

2. SARCOMA, NOT OTHERWISE SPECIFIED - Presence of a malignant mesenchymal tumor within the kidney. Only one such lesion was detected in this study in an animal that did not have a sarcoma that developed within the fibrous reaction to the test material. The animal having this lesion is a male in the control group. This lesion is a well-differentiated fibrosarcoma. Since no other lesion of this type can be found in this animal, it is assumed that the kidney is the



**Appendix I (cont.): GLOSSARY OF TERMS  
FOR PATHOLOGY FINDINGS**

primary site.

3. HEMORRHAGE, ACUTE - Presence of extravasated blood within the kidney. Probably this lesion is induced during necropsy procedures. The lesion is coded only as "Present."

4. HEMOSIDEROSIS (BROWN GRANULAR PIGMENT) IN TUBULAR EPITHELIAL CELLS - Self-explanatory. This lesion is coded as "Present."

5. CYST(S), CORTICAL - Presence of one or more cystic spaces within the renal cortex. Cysts are lined by flattened epithelium and may be either empty or filled with pale homogeneous eosinophilic fluid. While this may be a manifestation of progressive renal disease, this lesion is coded separately if the cysts are more than three times the diameter of a renal tubule. The lesion is coded as "Present."

6. INFARCT, CHRONIC WITH FIBROSIS, WITH OR WITHOUT MINERALIZATION - Presence of well-demarcated, usually wedge-shaped areas in the cortex composed primarily of fibrous connective tissue and a few pigment-laden macrophages. A few degenerating or necrotic tubular epithelial cells and mineral deposits may be present. At the periphery of the lesion there may be an infiltration of mononuclear inflammatory cells and occasional areas of tubular regeneration. The lesion is coded as "Present."

7. LARGE GRANULAR LYMPHOCYTE LEUKEMIA, METASTATIC - See description and comments under "General Diagnoses" above.

8. FIBROSIS, CAPSULE - Proliferation of non-neoplastic fibrous connective tissue with minimal infiltration of mononuclear inflammatory cells in the renal capsule. The lesion is coded as "Present."

9. PRESENCE OF METASTATIC SARCOMA - See description and comments under "General Diagnoses" above.

10. PRESENCE OF METASTATIC NEOPLASM - See description and comments under "General Diagnoses" above.

**URINARY BLADDER**

1. TRANSITIONAL CELL PAPILLOMA - The presence of a neoplastic

**Appendix I (cont.): GLOSSARY OF TERMS  
FOR PATHOLOGY FINDINGS**

proliferation of transitional epithelium. The cells comprising this tumor are well-differentiated transitional epithelial cells. They are arranged in anastomosing fronds which protrude into the lumen of the urinary bladder. Mitotic figures are not very numerous. An occasional tumor cell is undergoing coagulative necrosis. The tumor is highly vascularized. There is no evidence of neoplastic infiltration into the submucosa of the bladder nor invasion of vessels or lymphatics.

2. CHRONIC INFLAMMATORY CELL INFILTRATION - Presence of lymphocytes, macrophages, and plasma cells within the mucosa and submucosa of the urinary bladder. . Severity grade criteria:

- 1 = Minimal detectable inflammatory cell infiltration into the submucosa.
- 2 = Mild inflammatory cell infiltration which may involve both mucosa and submucosa. Less than 25% of the circumference of the bladder is involved.
- 3 = Moderate infiltration of the mucosa and submucosa causing thickening of these layers and/or involving 25% to 50% of the circumference of the bladder.
- 4 = Marked thickening of mucosa and submucosa by inflammatory cells involving more than 50% of the circumference of the bladder.

**PROSTATE**

1. ACUTE SUPPURATIVE PROSTATITIS - Acute infiltration of neutrophils into glandular or interstitial tissues of the prostate. Necrosis may be present in more severe cases. Severity grade criteria:

- 1 = Minimal detectable suppurative inflammation involving less than 10% of the prostate.
- 2 = Neutrophilic infiltration involving 10% to 25% of the prostate.
- 3 = Neutrophilic infiltration involving 25% to 50% of the prostate. Small areas of necrosis may be present.
- 4 = Infiltration of neutrophils involves more than 50% of the prostate. Necrotic areas up to the diameter of a 20X microscopic field may be

**Appendix I (cont.): GLOSSARY OF TERMS  
FOR PATHOLOGY FINDINGS**

present.

2. CHRONIC PROSTATITIS - Infiltration of lymphocytes, macrophages, plasma cells, and a few neutrophils into glandular or interstitial areas of the prostate. The secretory product is frequently inspissated in affected areas and appears as small eosinophilic or basophilic particles intermixed with inflammatory cells. Mineralization may be present. This lesion frequently coexists with hyperplastic changes in the glandular epithelium but the hyperplasia is coded separately since either lesion can occur independently. Severity grade criteria:

- 1 = Minimal detectable inflammatory cell infiltration.
- 2 = Inflammatory cell infiltration involves 10% to 25% of the prostate.
- 3 = Inflammatory cell infiltration involves 25% to 50% of the prostate.
- 4 = Inflammatory cell infiltration involves more than 50% of the prostate..

3. BENIGN HYPERPLASIA - Hyperplastic proliferation of the glandular epithelium of the prostate. Secretory cells are larger and more numerous than normal. They may be piled two to three cell layers thick on the basement membrane. There is no cellular atypia and cells are distributed in normal anatomic arrangement. This change may exist with, or independent of inflammatory lesions and thus is coded separately. Severity grade criteria:

- 1 = Hyperplastic changes involve up to 10% of the glandular epithelium.
- 2 = Hyperplastic changes involve 10% to 25% of the epithelium.
- 3 = Hyperplastic changes involve 25% to 50% of the epithelium.
- 4 = Hyperplastic changes involve more than 50% of the epithelium.

4. MICROCALICULI, PROSTATIC URETHRA - Presence of particulate material in the prostatic urethra. The material consists of an amalgam of proteinaceous or mineralized material that has variable staining characteristics presumably due to variations in mineral content. There may be mild infiltrations of mononuclear inflammatory cells within and beneath the urethral epithelium. The lesion is coded as

**Appendix I (cont.): GLOSSARY OF TERMS  
FOR PATHOLOGY FINDINGS**

"Present."

5. PRESENCE OF METASTATIC SARCOMA - See descriptions and comments under "General Diagnoses" above.

**COAGULATING GLAND**

No lesions were recognized in the coagulating glands of rats used in this study.

**SEMINAL VESICLE**

1. GENERALIZED ATROPHY - Presence of atrophic changes in the glandular epithelium of the seminal vesicle. Epithelial cells in affected glands are low columnar to cuboidal, smaller than in normal actively secreting glands, and the meager cytoplasm stains weakly eosinophilic. Glandular lumens contain very little secretory product in contrast to normal glands which are distended with this material. This change is coded as "Present."

2. PRESENCE OF METASTATIC SARCOMA - See descriptions and comments under "General Diagnoses" above.

**EPIDIDYMS**

1. PRESENCE OF METASTATIC SARCOMA - See descriptions and comments under "General Diagnoses" above.

**TESTES**

1. TUBULAR ATROPHY - The cells lining seminiferous tubules are reduced in number, and the tubules are reduced in diameter. This change is invariably present in cases of interstitial cell adenoma of the testis. Consequently, this lesion is not coded when an interstitial cell tumor is present, since the presence of the tumor itself indicates that tubular atrophy is present. Tubular atrophy is coded when testicular neoplasia was not present. Severity grade criteria for tubular atrophy are as follows:

- 1 - There is absence or reduction in the number of spermatozoa or spermatids in seminiferous tubules.
- 2 - In addition to criteria in grade 1, there is reduction in the innermost layers of spermatogenic cells. A few large multinucleated cells (degenerating

**Appendix I (cont.): GLOSSARY OF TERMS  
FOR PATHOLOGY FINDINGS**

spermatocytes) may be free in the tubular lumens.

- 3 = Only a few spermatogenic cells are present along with a complete layer of Sertoli cells on the basement membrane. Multinucleated cells may be present.
- 4 = There is complete absence of spermatogenic cells. Seminiferous tubules contain only Sertoli cells.

2. **INTERSTITIAL CELL HYPERPLASIA** - There is focal or multifocal proliferation of interstitial cells. These are large cells with round nuclei and abundant eosinophilic cytoplasm which may be finely vacuolated. They are situated between seminiferous tubules. The change is considered hyperplasia when foci of interstitial cells are no larger than the diameter of a seminiferous tubule and there is no compression of adjacent tissue. Foci of interstitial cells larger than the diameter of a tubule, or that compress adjacent tissue are coded as interstitial adenomas. If both adenoma and hyperplasia is present, only the adenoma is coded. Severity grade criteria:

- 1 = One to three foci of hyperplastic interstitial cells are present.
- 2 = Four to six foci are present.
- 3 = Seven to ten foci are present.
- 4 = More than ten foci are present.

3. **MESOTHELIOMA** - Neoplastic proliferation of mesothelial cells, arranged in multiple papillary fronds, arising from the tunica albuginea of the testis. The papillary structures are supported by a connective tissue stalk that contains blood vessels. The neoplastic mesothelial cells may be arranged in a single layer of flattened cells, or the cells may be cuboidal and piled up to form small nodules. Mitotic figures are usually infrequent.

4. **INTERSTITIAL CELL ADENOMA** - A benign tumor of interstitial (Leydig) cells. These tumors are composed of cells of four distinct morphologic types. The most common is a medium-sized hexagonal cell with distinct cell boundaries having eosinophilic cytoplasm surrounding a regular, round or oval vesicular nucleus. The nucleus has a delicate chromatin network and a single small basophilic nucleolus. The second cell type is larger with finely or coarsely vacuolated cytoplasm. A third cell type is small, elongated or spindle

**Appendix I (cont.): GLOSSARY OF TERMS  
FOR PATHOLOGY FINDINGS**

shaped, with granular eosinophilic cytoplasm and variably-sized, round, oval, or spindle-shaped nuclei which may be vesicular or pyknotic. The fourth type of cell resembles a lymphocyte with scanty cytoplasm and a small round nucleus with a "wheel-like" chromatin pattern. Neoplastic cells are arranged in cords, fascicles, islands, and nests, and usually show an endocrine pattern of vascularity. The stroma is usually delicate, but may be hyalinized or even calcified. These tumors are highly vascular and often there are large, distended endothelial-lined spaces filled with blood. Invariably, there are secondary lesions in the testis when interstitial cell adenoma is present. Atrophic or degenerative changes affecting seminiferous tubules are almost always present, and hemorrhage, necrosis, and mineralization may occur within the tumor. These lesions are not coded separately when interstitial adenoma is present.

5. PERIARTERITIS NODOSA - An acute, subacute, or chronic inflammatory lesion involving small or medium-sized muscular arteries in the testis. This lesion is characterized by sub-endothelial edema, damage to the elastic membrane, fibrinoid or hyaline necrosis of the media, and inflammatory cell infiltration into all layers of the arterial wall. Inflammatory cells are most abundant in the adventitia and are composed of neutrophils, lymphocytes, and plasma cells with fewer macrophages and eosinophils. It occurs as a focal or segmental lesion with some areas of an artery severely affected, and other areas essentially normal. No attempt is made to grade the severity of this lesion. It is coded as "Present."

6. PRESENCE OF METASTATIC SARCOMA - See descriptions and comments under "General Diagnoses" above.

7. PRESENCE OF METASTATIC NEOPLASM - See descriptions and comments under "General Diagnoses" above.

**UTERUS**

1. COMPOUND-RELATED INFLAMMATORY REACTION - See descriptions and comments under "General Diagnoses" above.

2. DILATATION OF THE UTERINE LUMEN (HYDROMETRA) - There is dilatation of the uterine lumen which is usually empty. The endometrium and underlying stroma may be slightly atrophic. The lesion is coded as "Present."

**Appendix I (cont.): GLOSSARY OF TERMS  
FOR PATHOLOGY FINDINGS**

3. PYOMETRA - There is suppurative inflammation involving the uterine lumen, endometrium, endometrial glands, and stroma. Small foci or areas of necrosis may be present in areas severely affected. Severity grade criteria:

- 1 = Presence of a few neutrophils within the endometrium.
- 2 = Moderate numbers of neutrophils are present within the endometrium, endometrial glands, and stroma.
- 3 = Neutrophilic infiltration as in grade 2 and presence of neutrophils within the uterine lumen.
- 4 = Changes as in grade 3 plus distention of the uterine lumen with suppurative exudate and/or the extension of inflammatory process into the uterine musculature.

4. ENDOMETRIAL STROMAL POLYP - These lesions consist of polypoid masses which protrude from the uterine wall into the lumen. The mass is covered by essentially normal endometrial surface epithelium. Within the mass there are relatively normal-appearing uterine glands; some may be dilated and cystic. The mass consists primarily of dense or loosely arranged fibrovascular stroma containing collagen and numerous small vessels. Some smooth muscle cells may be present. A few mitotic figures may be present in both stroma and epithelium. Focal ulceration of the epithelium accompanied by inflammatory cell infiltration may be present. The lesion is coded as "Present."

5. CYSTIC DILATATION OF ENDOMETRIAL GLANDS - Self-explanatory. Coded as "Present."

6. LYMPHOCYTIC INFILTRATE - Presence of lymphocytes within the endometrium, stroma, or uterine wall. Severity grade criteria:

- 1 = There are a few lymphocytes within the endometrium.
- 2 = There is mild lymphocytic infiltrate in the endometrium and around uterine glands.
- 3 = There are moderate numbers of lymphocytes in the endometrium and endometrial stroma.
- 4 = The lymphocytic infiltrate involves endometrium, stroma, and extends into the uterine musculature.

**Appendix I (cont.): GLOSSARY OF TERMS  
FOR PATHOLOGY FINDINGS**

7. **ENDOMETRIAL STROMAL SARCOMA** - A malignant proliferation of endometrial stromal cells. These are usually highly cellular masses which may protrude into the uterine lumen or invade the uterine musculature. Cells are usually spindle-shaped with elongated dense hyperchromatic nuclei and scanty amounts of cytoplasm which are either weakly eosinophilic or nearly colorless. Cells are arranged in a variety of patterns including parallel arrays, interlacing bundles, or haphazard proliferations. Cells often are fairly anaplastic and mitotic figures may be numerous. Hemorrhage and necrosis are common especially in the large polypoid masses. The surface epithelium and endometrial glands are usually normal, although inflammation and degeneration of these components may occur. These tumors differ from stromal polyps in their increased cellularity, cellular atypia, and invasiveness. No metastatic lesions of this type were observed in this study.

8. **ENDOMETRITIS, SUBACUTE** - Subacute inflammatory reaction involving the endometrium. There is infiltration of neutrophils, lymphocytes, macrophages, and plasma cells into the endometrial epithelium, underlying stroma, and uterine glands. This lesion differs from pyometra (Diagnosis #3) in that the inflammatory cell population is mixed and no suppurative exudate is present in the uterine lumen. The mixed cell population differentiates this lesion from the pure lymphocytic infiltrate described in Diagnosis #6 above. Severity grade criteria for this lesion:

- 1 = There is minimal infiltration of mixed inflammatory cells in the endometrium.
- 2 = There is mild infiltration of inflammatory cells in endometrium, and into and around uterine glands.
- 3 = There is moderate infiltration of inflammatory cells in endometrium and all areas of the stroma. Minimal amounts of necrosis may be present in these areas.
- 4 = There are marked mixed inflammatory cell infiltrate and areas of necrosis that involve endometrium, stroma, and uterine musculature.

9. **LARGE GRANULAR LYMPHOCYTE LEUKEMIA, METASTATIC** - See descriptions and comments under "General Diagnoses" above.

10. **DEGENERATION, NECROSIS AND INFLAMMATION OF UTERINE STROMA** - This unusual lesion is characterized by an abundance of necrotic debris and fibrin within the uterine lumen,



**Appendix I (cont.): GLOSSARY OF TERMS  
FOR PATHOLOGY FINDINGS**

degeneration, necrosis, and proliferation of endometrial stromal cells, dilatation of endometrial glands, moderate mixed inflammatory cell infiltration into all layers of the uterine wall, and the presence of many large cells with abundant poorly stained cytoplasm. These cells are situated primarily on the luminal surface of the uterus but in some areas extend through the stroma and infiltrate the uterine musculature. Sections stained with periodic acid-Schiff, alcian blue, and mucicarmine stains failed to characterize the cytoplasmic content of these cells. Their identity and character remain unknown. This unusual lesion was observed in only one rat, a female in the Control group that survived until terminal sacrifice. The morphologic characteristics of this lesion do not correspond to the criteria of the other more readily recognized uterine lesions observed in this study, hence this descriptive diagnosis is given.

11. LEIOMYOSARCOMA - A malignant neoplasm of smooth muscle origin. This is a highly cellular tumor characterized by spindle cells arranged in interlacing bundles, and situated in the wall of the uterus. The cells are large and spindle to fusiform with moderate amounts of eosinophilic cytoplasm and elongated nuclei with blunt or rounded ends. The cells are well differentiated and mitotic figures are not numerous. The tumor infiltrates and separates adjacent normal smooth muscle cells in an irregular fashion and invades the adjacent endometrial stroma.

**OVARIES**

No attempt is made to document ovarian changes that occur as a result of different stages of the estrus cycle, or that result from normal variations in hormonal stimulation. Only changes considered abnormal are documented in this study.

1. FOLLICULAR CYSTS - Presence of large cystic structures in the ovarian cortex. Cysts are lined by a layer of granulosa cells which varies considerably in thickness. Degeneration and atrophy of the lining cell layers are common and there may be a few degenerating cells free within the pale eosinophilic fluid that fills the cystic lumen. The cysts are coded as "Present."

2. CYSTIC CORPORA LUTEA - Presence of cystic structures in the ovarian cortex. Cysts are lined by a layer of luteal

**Appendix I (cont.): GLOSSARY OF TERMS  
FOR PATHOLOGY FINDINGS**

cells that varies considerably in thickness. Degeneration, atrophy, and infiltration of a very few mononuclear inflammatory cells may occur. The lumen of the cyst may be empty or filled with pale eosinophilic fluid. The cysts are coded as "Present."

3. PARA-OVARIAN CYST(S) - Presence of a cystic structure located adjacent to the ovary but does not involve ovarian tissue. Frequently this lesion consists only of a thin fibrous strand of tissue (the wall of the cyst) which may be lined by a single layer of flat "endothelial-like" cells. Ovaries adjacent to these cysts may be small and atrophic. Para-ovarian cysts are coded as "Present."

4. INFLAMMATORY CELL INFILTRATION - The presence of lymphocytes, macrophages, plasma cells, or (rarely) neutrophils within ovarian tissues. This lesion is observed infrequently. Severity grade criteria are subjective assessments of the number of inflammatory cells present:

- 1 = Minimal inflammatory cells present.
- 2 = Mild inflammatory cell infiltration.
- 3 = Moderate inflammatory cell infiltration.
- 4 = Marked inflammatory cell infiltration.

5. LARGE GRANULAR LYMPHOCYTE LEUKEMIA, METASTATIC - See descriptions and comments under "General Diagnoses" above.

6. PRESENCE OF METASTATIC NEOPLASM - See descriptions and comments under "General Diagnoses" above.

**DUODENUM**

1. COMPOUND-RELATED INFLAMMATORY REACTION - See description and comments under "General Diagnoses" above.

2. PRESENCE OF METASTATIC SARCOMA - See descriptions and comments under "General Diagnoses" above.

3. PRESENCE OF METASTATIC NEOPLASM - See descriptions and comments under "General Diagnoses" above.

4. MUCOSAL EROSION/ULCERATION - Necrosis and sloughing of the epithelium on the mucosal surface. In an erosion, the necrosis is limited to the epithelial layer; the basement membrane is intact. An ulceration consists of necrosis that

**Appendix I (cont.): GLOSSARY OF TERMS  
FOR PATHOLOGY FINDINGS**

involves the surface epithelium, extends through the basement membrane, and affects the underlying submucosa. In both lesions, tissues adjacent to necrotic areas are infiltrated with neutrophils, lymphocytes, and macrophages. In chronic ulcers, there may be fibrous connective tissue proliferation and regenerating mucosal epithelium at the periphery of the lesion. These lesions are coded as "Present."

5. PRESENCE OF MUCOSAL EPITHELIAL CELLS WITHIN INTESTINAL WALL AND ADJACENT FIBROUS/GRANULOMATOUS INFLAMMATORY REACTION - In some animals the test material adhered to the intestinal wall inciting the usual foreign-body inflammatory response. In some of these animals, there is chronic ulceration of the epithelium at this location. Microscopic examination reveals the presence of regenerating intestinal epithelial cells in the submucosa, within the muscular layers, in subserosal locations, and within the adjacent chronic granulomatous inflammatory tissue. These entrapped cells have essentially normal histologic characteristics except for their location and occasional degenerative or atrophic changes. There are no indications of cellular atypia, nuclear pleomorphism, or abnormal mitotic activity characteristic of neoplasia. This change is interpreted as regeneration of intestinal epithelium which has migrated into, and become entrapped in an ongoing chronic inflammatory response that affects the entire thickness of the intestinal wall. This lesion is coded as "Present."

**JEJUNUM**

1. COMPOUND-RELATED INFLAMMATORY REACTION - See "General Diagnoses" above.

2. ACUTE PERITONITIS - The presence of neutrophils, fibrin, necrotic debris, and mononuclear inflammatory cells on the serosal surface. No test material, foreign-body giant cells, or fibrosis are present. Severity grade is based on subjective assessment of the intensity and extent of the inflammatory process:

- 1 = Minimal inflammation.
- 2 = Mild inflammation.
- 3 = Moderate inflammation.
- 4 = Marked inflammation.

3. ENTERITIS, SUBACUTE - Consists of the infiltration of

**Appendix I (cont.): GLOSSARY OF TERMS  
FOR PATHOLOGY FINDINGS**

lymphocytes, macrophages, plasma cells, and a few neutrophils into the mucosa, lamina propria, submucosa, and muscular wall of the jejunum. In more severe cases there may be small areas of necrosis in the layers involved. Severity grade criteria:

- 1 = Minimal inflammatory cell infiltration in mucosa and/or lamina propria.
- 2 = Mild inflammatory cell infiltration with edema, in mucosa, lamina propria, and extending into the submucosa.
- 3 = A moderate inflammatory infiltrate and edema involves mucosa, lamina propria and submucosa causing increased thickness of these layers. Small foci or areas of necrosis may be present in the mucosa.
- 4 = A marked inflammatory cell infiltrate accompanied by edema, involves mucosa, lamina propria, submucosa, and extends into the muscular coats. Foci or areas of necrosis are present in the mucosa and lamina propria and may involve deeper layers.

4. MUCOSAL EROSION/ULCERATION - Except for location in the jejunum, this lesion is similar to that described in Diagnosis #4 under *DUODENUM* above.

5. PRESENCE OF MUCOSAL EPITHELIAL CELLS WITHIN INTESTINAL WALL AND ADJACENT FIBROUS/GRANULOMATOUS INFLAMMATORY REACTION - Except for location in the jejunum this lesion is similar to that described in Diagnosis #5 under *DUODENUM* above.

6. PRESENCE OF METASTATIC SARCOMA - See "General Diagnoses" above.

7. FIBROVASCULAR ADHESION, SEROSA - Self-explanatory. Minimal inflammatory cell infiltration, no test material and no foreign-body giant cells are present. Lesion is coded as "Present."

8. PRESENCE OF METASTATIC NEOPLASM - See "General Diagnoses" above.

**ILEUM**

1. COMPOUND-RELATED INFLAMMATORY REACTION - See "General

**Appendix I (cont.): GLOSSARY OF TERMS  
FOR PATHOLOGY FINDINGS**

Diagnoses" above.

2. LARGE GRANULAR LYMPHOCYTE LEUKEMIA, METASTATIC - See "General Diagnoses" above.
3. PRESENCE OF METASTATIC SARCOMA - See "General Diagnoses" above.
4. LYMPHOID HYPERPLASIA - This change involves the gut-associated lymphoid tissue in the ileum, and consists of increased size and number of lymphoid follicles, increased number of large, pale, immature lymphocytes in germinal centers and perifollicular areas, increased mitotic activity in lymphoid cells, and the extension of lymphoid cells from the submucosa into the lamina propria and mucosal layers of the ileum. This change is coded as "Present."
5. PRESENCE OF METASTATIC NEOPLASM - See "General Diagnoses" above.

**PANCREAS**

1. ACINAR (EXOCRINE) ATROPHY - This lesion consists of the absence or reduction in number of acinar secretory cells. Affected lobules contain only ductal structures in a fibrovascular stroma. Such lesions are usually focal affecting a small lobule of pancreatic tissue. Severity grade criteria:

- 1 = One lobule affected.
- 2 = Two or three lobules affected.
- 3 = Four to six lobules affected.
- 4 = More than six lobules affected.

2. CHRONIC INFLAMMATION - Infiltration of neutrophils, lymphocytes, macrophages, and plasma cells into acinar areas, stromal tissues, and serosal surfaces of the pancreas. There may be variable amounts of edema, fibrin deposition, fibrosis, tissue necrosis, and mineralized deposits in necrotic areas depending on the severity and age of the lesion. Severity grade criteria:

- 1 = Minimal focal to multifocal inflammatory cell infiltration.
- 2 = Mild focal to diffuse inflammatory cell infiltrate with or without fibrosis, affecting

**Appendix I (cont.): GLOSSARY OF TERMS  
FOR PATHOLOGY FINDINGS**

up to 50% of the pancreas.

3 = A few small foci of necrosis may be present along with moderate inflammatory cell infiltration and fibrosis.

4 = Numerous foci or large areas of necrosis which may be accompanied by mineralization. Inflammatory cell infiltrate and fibrosis are marked and diffuse.

3. ISLET CELL ADENOMA - Benign neoplastic proliferation of pancreatic islet cells. These adenomas are usually nearly spherical proliferations of medium-sized, well-differentiated islet cells. The cells are arranged in small nests, packets, or short cords supported by very delicate fibrovascular stroma. Cytoplasm is weakly eosinophilic and has distinct cellular boundaries. Nuclei are round and fairly small with condensed chromatin. Mitotic figures are sparse. The tumors are discrete and compress adjacent tissues slightly.

4. PERIARTERITIS NODOSA - An acute, subacute, or chronic inflammatory lesion involving small to medium-sized muscular arteries in the pancreas. The lesion is characterized by subendothelial edema, hyaline, or fibrinoid necrosis of the media, and infiltration of all layers of the arterial wall by inflammatory cells. Inflammatory cell infiltration is most prevalent in the adventitia and consists of neutrophils, lymphocytes, and plasma cells with fewer macrophages and eosinophils. The lesion is usually focal or segmental with some areas of an artery being severely affected and other areas essentially normal. The lesion is coded as "Present."

5. ACINAR HYPERPLASIA - Focal or multifocal non-neoplastic proliferation of pancreatic acinar secretory cells. Within an affected lobule, there are increased numbers of secretory cells which are either normal size or slightly smaller than normal. The cells are crowded, but are arranged in essentially normal fashion relative to basement membranes. Hyperplastic cells are usually slightly hyperchromatic but often lack normal numbers of zymogen granules. Severity grade criteria:

- 1 = One pancreatic lobule is affected.
- 2 = Two or three lobules are affected.
- 3 = Four to six lobules are affected.
- 4 = More than six lobules are affected.

6. COMPOUND-RELATED INFLAMMATORY REACTION - See "General

**Appendix I (cont.): GLOSSARY OF TERMS  
FOR PATHOLOGY FINDINGS**

Diagnoses" above.

7. PRESENCE OF METASTATIC SARCOMA - See "General Diagnoses" above.

8. LARGE GRANULAR LYMPHOCYTE LEUKEMIA, METASTATIC - See "General Diagnoses" above.

9. PRESENCE OF METASTATIC NEOPLASM - See "General Diagnoses" above.

10. CYSTIC DUCT - Cystic dilatation of one or more ducts within the pancreas. Dilated area is more than three times the diameter of a normal duct. The lumen is usually empty and the lining epithelium may be flattened and atrophic. The lesion is coded as "Present."

**CECUM**

1. COMPOUND-RELATED INFLAMMATORY REACTION - See "General Diagnoses" above.

2. PERIARTERITIS NODOSA, ARTERIES IN CECAL WALL OR MESENTERY - See descriptions and comments for Diagnosis #4 under PANCREAS above. The characteristics of the arterial changes are similar in both organs.

3. PRESENCE OF METASTATIC SARCOMA - See "General Diagnoses" above.

4. ADENOMATOUS POLYP - This lesion is a large polypoid mass attached to the wall of the cecum by a broad base. The intraluminal surface of the mass is covered by well-differentiated epithelium arranged in long tortuous tubular glands. The lamina propria between glands is slightly separated by edema and a mild uniform infiltration of lymphocytes and a few plasma cells. The bulk of the mass consists of the underlying stroma which is characterized by numerous endothelial-lined spaces that vary considerably in size and shape. Most of the vascular spaces are small and slit-like, although there are a few that are larger and irregular in shape. Most of these spaces are empty. Between the vascular spaces there are numerous loosely-arranged fibrocytes and small foci of mononuclear inflammatory cells. A few small muscular arteries are present in this area. Only one lesion of this type was observed in this study. It occurred in a female rat in the control group.

**Appendix I (cont.): GLOSSARY OF TERMS  
FOR PATHOLOGY FINDINGS**

5. REACTIVE LYMPHOID HYPERPLASIA, SUBMUCOSA - This change is essentially identical to that in the ILEUM. See diagnosis #4 under ILEUM above for a detailed description.

6. EDEMA OF THE SUBMUCOSA AND/OR LAMINA PROPRIA - The cellular elements and connective tissue in the submucosa and lamina propria are separated by the presence of weakly eosinophilic edema fluid. This lesion is coded as "Present."

7. MONONUCLEAR CELL INFILTRATION - The lamina propria and submucosa are infiltrated by small numbers of lymphocytes, plasma cells, and macrophages. The lesion is coded as "Present."

**RECTUM**

1. FIBROSARCOMA, LOCALLY INVASIVE - These tumors are highly cellular and consist of spindle cells with varying amounts of eosinophilic cytoplasm and oval to elongated nuclei. Mitotic figures may be very numerous and large bizarre forms occur occasionally. The cells are arranged in broad sheets, parallel arrays, and interlacing bundles. In more anaplastic tumors, a definite cellular pattern may be difficult to detect. Sections stained with Masson's trichrome stain usually reveal the presence of abundant collagen. The most probable primary site for this tumor is the inguinal or perineal subcutaneous tissue. Three fibrosarcomas were present in this location in Study GLP 83009. All three animals were females; one in the control group, one in the high-dose group and one in the low-dose group. In all three animals, the tumors were confined to the inguinal or perineal subcutis with local invasion of adjacent pelvic viscera. In none of these cases was there evidence of the sarcoma elsewhere in the abdominal cavity. No test material or granulomatous inflammatory lesions were observed in association with these perirectal tumors.

**COLON**

1. COMPOUND-RELATED INFLAMMATORY REACTION - See "General Diagnoses" above.

2. CHRONIC COLITIS WITH MUCOUS GLAND HYPERPLASIA AND HYPERSECRETION - The mucosa, lamina propria, and submucosa are infiltrated with lymphocytes, macrophages, plasma cells, and an occasional neutrophil. Many of the glands in the



**Appendix I (cont.): GLOSSARY OF TERMS  
FOR PATHOLOGY FINDINGS**

mucosa are distended with mucus. Small amounts of mucus adhere to the mucosal surface and are present in the lumen. Epithelial cells in the mucosal glands are hyperplastic. Severity grade criteria are not applicable since only two animals in this study had this lesion.

3. PRESENCE OF METASTATIC SARCOMA - See "General Diagnoses" above.

4. POLYP, CYSTIC, WITH MUCINOUS EPITHELIAL HYPERPLASIA AND OSSEOUS METAPLASIA AND/OR MINERALIZATION OF THE STROMA - These unusual lesions consist of large polypoid growths which extend into the lumen of the colon. The mass is covered by colonic epithelium which in some areas is ulcerated and accompanied by a chronic inflammatory response consisting of mononuclear cell infiltration and fibrosis. Within the mass are numerous large cystic spaces that are lined by flattened epithelium containing numerous mucus-secreting cells. These cystic cavities are distended with mucus that contains a few inflammatory cells and small particles of cellular debris. The stroma between the mucus-filled cysts consists of numerous slit-like endothelial-lined vascular spaces, fibrous connective tissue which is very dense in some areas and loosely arranged and edematous in others, and a multifocal to diffuse infiltration of mononuclear inflammatory cells. In some areas the dense fibrous stroma is mineralized and in other places there are spicules of metaplastic bone. The adjacent colonic mucosa is ulcerated, infiltrated with inflammatory cells, and contains areas of fibrous connective tissue proliferation and foci of hyperplastic (regenerating) epithelial cells. These lesions occur in only two animals; both males in the high-dose group. In both cases there are serosal adhesions of the colon that could be attributed to the presence of the test material. In one case, the cecum and its cystic polypoid mass are adhered to the surface of the liver. It is probable that the presence of the test material and the reaction to it contributed to the development of these unusual lesions in the colon. The lesion is coded as "Present."

**STOMACH**

Mucosal glandular dilatation was observed microscopically in almost every rat that was necropsied during the second year of this study. Since this change is universally present in all three experimental groups, it is

**Appendix I (cont.): GLOSSARY OF TERMS  
FOR PATHOLOGY FINDINGS**

considered as a normal aging change and is not coded.

1. COMPOUND-RELATED INFLAMMATORY REACTION - See "General Diagnoses" above.
2. SEROSAL FIBROSIS - The presence of fibrous connective tissue proliferation on the serosal surface. Minimal numbers of inflammatory cells may be present. There is no test material or foreign-body giant cells. The lesion is coded as "Present."
3. ULCERATION, NONGLANDULAR AREA - There is necrosis and sloughing of the squamous epithelial lining of the non-glandular portion of the stomach. Mononuclear inflammatory cell infiltration, edema, and proliferation of small amounts of fibrous connective tissue may be present at the periphery of the ulcer and in underlying stomach wall. The lesion is coded as "Present."
4. MUCOSAL AND/OR SUBMUCOSAL EDEMA - Cellular elements of the stomach mucosa and/or submucosa are separated by the presence of pale eosinophilic edema fluid. This lesion may occur in either the glandular or squamous-lined portions of the stomach. The lesion is coded as "Present."
5. LARGE GRANULAR LYMPHOCYTE LEUKEMIA - See "General Diagnoses" above.
6. PRESENCE OF METASTATIC SARCOMA - See "General Diagnoses" above.
7. SQUAMOUS CELL PAPILLOMA - There is a well-defined proliferation of the squamous epithelium of the stomach. The proliferating epithelial cells are well differentiated and are arranged in blunt papillary projections which extend into the lumen. The surface of the growth is usually keratinized. Proliferation of basal cells can be seen. The growth does not extend beyond the basement membrane. The mucosa and submucosa adjacent to papillomas are usually infiltrated by mononuclear inflammatory cells.
8. EROSION AND/OR ULCERATION OF THE GLANDULAR MUCOSA - There is necrosis and sloughing of the epithelial cells in the glandular portion of the stomach mucosa. In an erosion, the necrosis is confined to the epithelial lining; in the case of ulceration, the necrotic process extends beyond the basement membrane to involve the underlying submucosa. Adjacent to

**Appendix I (cont.): GLOSSARY OF TERMS  
FOR PATHOLOGY FINDINGS**

the area of necrosis, there is usually infiltration of mononuclear inflammatory cells and, in chronic cases, fibrous connective tissue proliferation. Severity grade criteria:

- 1 = Small focal area of necrosis less than the diameter of a 20X microscopic field.
- 2 = An area of necrosis less than the diameter of a 10X microscopic field.
- 3 = The necrotic area extends beyond the basement membrane and occupies an area as large as a 10X microscopic field.
- 4 = The ulcerated area is greater than the diameter of a 4X microscopic field.

**SKELETAL MUSCLE**

1. ACUTE MYOSITIS - This is acute inflammation of skeletal muscle tissue. Muscle fibers are separated by infiltration of neutrophils and fewer macrophages and lymphocytes. In more severe cases there is coagulative necrosis of muscle fibers and phagocytosis of the necrotic cellular debris. Severity grade criteria:

- 1 = Minimal detectable infiltration of neutrophils.
- 2 = Mild infiltration of neutrophils and a few macrophages in an area up to the diameter of a 10X microscopic field.
- 3 = Coagulative necrosis of muscle tissue with neutrophil infiltration. The size of the necrotic area is less than a 20X microscopic field.
- 4 = Necrosis of muscle and neutrophilic infiltration. The necrotic area exceeds the diameter of a 20X field.

2. CHRONIC MYOSITIS - Consists of chronic inflammation of skeletal muscle. Muscle cells are separated by infiltration of mononuclear inflammatory cells in which large macrophages predominate. In more severe cases there is necrosis of muscle fibers and the phagocytosis of necrotic debris by macrophages. Muscle fiber regeneration and fibrous connective tissue proliferation may be present. Severity grade criteria:

- 1 = Minimal detectable infiltration of mononuclear inflammatory cells.

**Appendix I (cont.): GLOSSARY OF TERMS  
FOR PATHOLOGY FINDINGS**

- 2 = Mild infiltration of mononuclear inflammatory cells. Fibrosis may be present. The lesion is focal and does not exceed the diameter of a 10X microscopic field.
- 3 = There is necrosis of muscle cells with phagocytosis of debris by macrophages. Regeneration may be present. The area of necrosis is less than that of a 20X microscopic field.
- 4 = Lesion is similar to grade 3; the necrotic area is larger than a 20X field.

3. CHRONIC INFLAMMATION RESTRICTED TO FASCIA - This lesion consists of infiltration of lymphocytes, macrophages, and plasma cells into the fascia dividing bundles of skeletal muscle fibers. In addition, there may be increased amounts of fibrous tissue in these septae. There is no damage or inflammatory cell infiltration into adjacent muscle bundles. Severity grade criteria:

- 1 = Minimal inflammatory cell infiltration involving an area smaller than a 20X microscopic field.
- 2 = Mild inflammatory cell infiltration involving an area smaller than a 10X field.
- 3 = Inflammatory cell infiltration involving an area larger than a 10X field.
- 4 = Inflammatory cell infiltration involving an area larger than a 4X field.

**SCIATIC NERVE**

No lesions were observed in sciatic nerves of rats on this study.

**TONGUE**

1. MONONUCLEAR CELLULAR INFILTRATION - There is focal, multifocal, or diffuse infiltration of mononuclear inflammatory cells between skeletal muscle fibers in the tongue. Severity grades are based on subjective assessment of the number of cells present:

- 1 = Minimal
- 2 = Mild
- 3 = Moderate
- 4 = Marked

**Appendix I (cont.): GLOSSARY OF TERMS  
FOR PATHOLOGY FINDINGS**

2. PERIARTERITIS - Inflammatory cell infiltration of the adventitia of small to medium-sized arteries and adjacent tissues. Severity grades are based on subjective assessment:

- 1 = Minimal
- 2 = Mild
- 3 = Moderate
- 4 = Marked

3. MEDIAL HYPERTROPHY AND MINERALIZATION OF MEDIUM-SIZED MUSCULAR ARTERIES - There is thickening of the muscular layer of the arterial wall. Several vessels in the same tongue section are often affected. Hyalinization and mineralization of hypertrophied muscle may be present. The lesion is coded as "Present."

**SKIN**

1. COMPOUND-RELATED INFLAMMATORY REACTION - See "General Diagnoses" above.

2. INFLAMMATORY EXUDATE ON SKIN SURFACE - There is a mixture of neutrophils, macrophages, fibrin, and cellular debris on the surface of the skin. Severity grades are based on the amount of surface area involved relative to different microscopic magnifications:

- 1 = Area is less than the diameter of a 20X field.
- 2 = Area is less than the diameter of a 10X field.
- 3 = Area is less than the diameter of a 4X field.
- 4 = Area is larger than the diameter of a 4X field.

2. PROCEDURE-RELATED GRANULOMATOUS CELLULITIS, SUBCUTIS - Compound-related inflammatory reactions in the subcutis are similar to those in other locations. See "General Diagnoses" above.

3. NONSUPPURATIVE DERMATITIS - There is a subacute inflammatory process involving the epidermis and dermis. The predominant change involves infiltration of lymphocytes, macrophages, plasma cells, and fewer neutrophils and eosinophils into these areas. The inflammatory cells are present within the epidermis, along the basement membrane, and between adnexal structures in the dermis. Severity grades are based on the amount of inflammatory cell infiltration:

**Appendix I (cont.): GLOSSARY OF TERMS  
FOR PATHOLOGY FINDINGS**

- 1 = Minimal detectable inflammatory cell infiltrate.
- 2 = Mild diffuse infiltrate.
- 3 = Moderate numbers of inflammatory cells
- 4 = Affected area is nearly solidly infiltrated.

4. CELLULITIS - An acute, subacute, or chronic inflammatory process in subcutaneous tissue characterized by inflammatory cell infiltration. Necrosis, cellular debris, and fibrin may be present in more severe cases. No test material or foreign-body giant cells are present. Severity grade criteria:

- 1 = Minimum detectable inflammatory cell infiltration in the subcutaneous tissues.
- 2 = Mild inflammatory cell infiltration. May be focal (less than the diameter of a 10X field) or diffuse.
- 3 = Moderate numbers of inflammatory cells distributed either focally or diffusely. Small foci of necrosis, less than the diameter of a 40X field may be present.
- 4 = Marked inflammatory cell infiltration and/or large areas of necrosis.

5. KERATOACANTHOMA (INVERTED PAPILLOMA), ANATOMIC SITE TO BE SPECIFIED - A benign, well-encapsulated tumor, typically raised above the surrounding epidermis, with a central crater or pore that is filled with keratin. The neoplastic epidermis lining the crater contains many keratinized pearls, which are particularly numerous near the center of the tumor. There is sharp demarcation between tumor epithelium and the surrounding dermis. The anatomic location is documented using the special histologic comment feature of the Xybion program.

6. EROSION/ULCERATION OF THE SKIN SURFACE - An erosion is necrosis and sloughing of the surface epithelium. The basement membrane is intact. An ulceration is necrosis of the skin which extends beyond the basement membrane to involve the underlying dermis. Usually, there is infiltration of neutrophils, lymphocytes, and macrophages at the periphery of such lesions. In chronic cases there may be fibrosis and attempts at epithelial regeneration as well. The lesion is coded as "Present."

**Appendix I (cont.): GLOSSARY OF TERMS  
FOR PATHOLOGY FINDINGS**

7. **BASAL CELL TUMOR** - Benign tumor of basal cell origin. Basal cells are usually arranged in long serpentine ribbons or small nests. The tumors are well demarcated from adjacent tissues in the dermis. The tumor cells are small with small amounts of lightly basophilic cytoplasm and round to oval vesicular nuclei. Mitotic figures are rare. There is a minimal amount of fine fibrous stroma. There is no evidence of invasion or metastasis.

8. **BASAL CELL CARCINOMA** - A malignant neoplasm of basal cell origin. Cellular morphology and growth patterns are very similar to the benign basal cell tumor. Criterion that distinguishes malignant tumors is their invasiveness of adjacent tissue. Tumor cells are not confined by the enveloping capsule and invade adjacent tissue.

9. **FIBROMA** - Benign tumor of fibrous connective tissue. These are well-demarcated proliferations of well-differentiated fibrocytes. Cells are arranged in parallel fashion or interlacing bundles. Nuclei are small and elongated. Mitotic figures are rare. These tumors are not highly cellular and contain an abundance of mature collagen.

10. **ACANTHOSIS** - A non-neoplastic thickening of the epidermis. The entire layer of the epidermis is thickened. The rete ridges are elongated, irregular, and extend into the dermis for a variable distance. Severity grade criteria:

- 1 = Epidermis is twice normal thickness.
- 2 = Epidermis is three times normal thickness.
- 3 = Epidermis is four times normal thickness.
- 4 = Epidermis is more than four times normal thickness.

11. **HYPERKERATOSIS** - Thickening of the stratum corneum by keratin accumulation. Severity grade criteria:

- 1 = Stratum corneum is twice normal thickness.
- 2 = Stratum corneum is three times normal thickness.
- 3 = Stratum corneum is four times normal thickness.
- 4 = Stratum corneum is more than four times normal thickness.

12. **SQUAMOUS PAPILLOMA** - A small superficial pedunculated nodule consisting of neoplastic masses of mature keratinizing epithelial cells. Cells are in progressive stages of

**Appendix I (cont.): GLOSSARY OF TERMS  
FOR PATHOLOGY FINDINGS**

keratinization often occurring in concentric whorls. There is no evidence of deeper invasion. The superficial location and the mature, highly keratinized, noninvasive growth distinguish papillomas from carcinomas. These tumors have a central core of dermis covered by layers of stratified squamous epithelium with marked hyperkeratosis and parakeratosis.

13. PREPUTIAL GLAND ADENOMA - Well-differentiated, benign tumor of the preputial gland. Adenomas are composed primarily of glandular tissue with small nests of squamous cells scattered about. Eosinophilic granules are very prominent in the cytoplasm of acinar cells. These tumors grow in lobular fashion with smooth borders, and they may become very large.

14. CLITORAL GLAND ADENOMA - Well-differentiated, benign tumor of the clitoral gland, the female counterpart of the male preputial gland described above. Microscopic characteristics are similar to those of preputial gland adenomas.

15. INFLAMMATION, NOT OTHERWISE SPECIFIED, PREPUTIAL GLAND - Presence of lymphocytes, macrophages, neutrophils, or plasma cells within the preputial gland. This lesion is coded as "Present."

16. NEUROFIBROSARCOMA, SUBCUTANEOUS, LOCATION TO BE SPECIFIED - Microscopically, these tumors are composed of spindle-shaped cells arranged in circular whorls or wavy fasciculi. They closely resemble fibrosarcomas but differ in that cells tend to have the form of plump spindles and retain the whorled, curly arrangement. The location of these tumors is documented in the special histologic comments feature of the Xybion program.

17. FIBROSARCOMA - Malignant neoplasm of fibrous connective tissue. Tumor cells with their collagenous fibrils are arranged haphazardly and run aimlessly in a variety of directions. Fasciculi of cells lying in the same plane are often seen. A high degree of cellularity, hyperchromatic staining of nuclei, and a tendency for the nuclei to be plump, stellate, and bizarre indicate malignancy. Mitotic figures may be very numerous.

18. EPIDERMAL INCLUSION CYST - One or more small cysts



**Appendix I (cont.): GLOSSARY OF TERMS  
FOR PATHOLOGY FINDINGS**

located within the dermis and surrounded by a thin fibrous capsule. The cyst wall consists of flattened squamous epithelium without adnexal structures. The cyst is filled with concentrically laminated masses of keratin and amorphous cellular debris. Intense inflammatory reaction may occur around these lesions if the cyst ruptures. This lesion is coded as "Present."

**MAMMARY GLANDS**

1. **HYPERPLASIA AND/OR HYPERTROPHY OF ACINAR TISSUE -** Increased size and number of mammary secretory cells. These cells are arranged in lobules. In hyperplastic glands, the lobules become larger and closer together. Cells are cuboidal to low columnar, and crowded together on the basement membrane to the point that mild piling up of cells occurs. Often these cells are actively secreting and acini become distended with slightly basophilic granular or foamy secretory product. Mammary hyperplasia occurs in both sexes although it is more prevalent and usually more severe in females. The same severity grade criteria are used for both sexes:

- 1 = Foci of acinar cells are widely scattered. Most are less than the diameter of a 40X microscopic field.
- 2 = Acinar foci are more numerous but small. The largest are larger than a 40X field but smaller than a 20X field.
- 3 = Extensive acinar tissue is present. It is nearly confluent but there are a few uninvolved areas.
- 4 = Confluent secretory tissue is present.

2. **GALACTOCOELE -** Marked cystic dilatation of a mammary duct. The dilated duct is lined by flattened ductal epithelium and is filled with secretory product. The lesion is coded as "Present."

3. **FIBROADENOMA -** A benign tumor of mammary origin in which there is proliferation of both epithelial and connective tissue components. Histologically, fibroadenomas vary considerably in their structural composition. Either the epithelial or the connective tissue component may predominate. Usually there is a concomitant growth of connective tissue stroma, glandular and ductal cells. Ducts

**Appendix I (cont.): GLOSSARY OF TERMS  
FOR PATHOLOGY FINDINGS**

may become surrounded by layers of fibrous connective tissue and the histological appearance becomes that of single acini or tubules separated from each other by concentric layers of loose connective tissue. The secretory epithelium is usually only one cell layer thick and bears the same relation to myoepithelium and basement membrane as it does in the normal mammary gland.

4. DILATATION (ECTASIA) OF DUCTS AND DUCTULES - Dilatation of mammary ducts occurs independently of mammary acinar hyperplasia and is therefore coded independently. Dilated ducts often contain pale eosinophilic secretory material. This lesion is coded as "Present."

5. MAMMARY ADENOCARCINOMA - A malignant tumor that is derived from glandular epithelium. The epithelium is arranged in glandlike structures surrounding a lumen. Acinar spaces may be orderly and regular or may vary considerably in size and shape. Eosinophilic or basophilic secretion is often present in glandular spaces. The epithelium varies from low cuboidal to tall columnar cells and may be several cell layers thick. Nuclei are large and mitotic figures are numerous. In some adenocarcinomas, the acinar spaces are completely filled with tumor cells and no lumens are present. Stroma within cell masses is usually scanty. Papillary projections can form, however. Stromal invasion by neoplastic epithelial cells is common. Necrosis and mononuclear inflammatory cell infiltration can occur and are more frequent in larger tumors.

**NOSE/TURBINATES**

1. ACUTE INFLAMMATION - Presence of suppurative inflammation within the nasal cavity. Necrosis may be present in more severe lesions. Severity grade criteria:

- 1 = Minimal detectable infiltration of neutrophils.
- 2 = Mild infiltration of neutrophils.
- 3 = Moderate infiltration of neutrophils.  
Suppurative exudate is present within nasal passages.
- 4 = Marked neutrophilic infiltration. Suppurative exudate is present in nasal passages. Necrosis with destruction of nasal tissues is present.

**Appendix I (cont.): GLOSSARY OF TERMS  
FOR PATHOLOGY FINDINGS**

2. SUBACUTE INFLAMMATION - Infiltration of lymphocytes, macrophages, and plasma cells into tissue of the nasal cavity. Necrosis may be present in more severe lesions. Severity grade criteria:

- 1 = Minimal infiltration of mononuclear inflammatory cells.
- 2 = Mild mononuclear cell infiltration.
- 3 = Moderate mononuclear infiltration. Exudate is present in nasal passages.
- 4 = Marked mononuclear cell infiltration. Exudate is present in nasal passages. Necrosis with destruction of nasal tissues is present.

3. MIXED INFLAMMATORY CELL INFILTRATION, NASAL CAVITY, SINUSES, TURBINATES OR NASOLACRIMAL DUCTS - This diagnosis is used primarily for small focal inflammatory lesions in the nasal cavity. The exact location of the lesion is documented in the special histologic comments of the Xyblon program. Most of the lesions coded under this diagnosis are inflammatory foci adjacent to nasolacrimal ducts. Inflammatory cell foci are very common in this location in rats used in Study GLP 83009. Severity grade criteria:

- 1 = Minimal inflammatory cell infiltration.
- 2 = Mild inflammatory cell infiltration.
- 3 = Moderate inflammatory cell infiltration; cellular exudate is present within a natural anatomic space, e.g., the lumen of the nasolacrimal duct.
- 4 = Marked inflammatory cell infiltrate. Exudate is present within a natural anatomic space. Small amounts of necrosis may be present.

**BONE**

Bone and bone marrow were examined from the **STERNUM**, **FEMUR**, and **VERTEBRAE** as well as incidental locations such as the nasal cavity, and middle and inner ear. The diagnoses coded for bone marrow from all these sites are described below.

1. MYELOID HISTIOCYTOSIS - This is an unusual lesion that affects bone marrow uniformly in an affected animal. The marrow contains large numbers of large histiocyte-like cells. No microorganisms were detected in sections stained by

**Appendix I (cont.): GLOSSARY OF TERMS  
FOR PATHOLOGY FINDINGS**

Gomori's Methenamine Silver stain, Periodic Acid-Schiff (PAS), Giemsa, or Goodpasture stains. Cells contained diastase-resistant PAS-positive material. Whether this lesion is inflammatory or neoplastic in nature is unknown. The lesion is coded as "Present."

2. **HYPERPLASIA, MYELOID** - This change in bone marrow consists of excess non-neoplastic proliferation of granulocytic precursors. Erythroid precursors are present but usually reduced in number. The myeloid proliferation may be multifocal or diffuse. The change is coded as "Present."

3. **MYELOFIBROSIS/OSTEOSCLEROSIS** - All normal marrow elements are greatly reduced in number and are replaced by hypocellular loosely arranged fibrous tissue. The lesion is coded as "Present."

4. **LARGE GRANULAR LYMPHOCYTE LEUKEMIA** - See "General Diagnoses" above.

**SPINAL CORD**

No gross or microscopic lesions were observed the the spinal cords of rats used in Study GLP 83009.

**ADRENAL GLANDS**

1. **CORTICAL ADENOMA** - A benign tumor of adrenal cortical cells. The tumor cells are arranged in a discrete nodule which compresses adjacent cortical tissue. Within the tumor, the cells lack their normal orderly arrangement and relationship to basement membrane and vasculature. They are arranged in short cords, or nests separated by delicate fibrovascular stroma. Tumor cells may be either larger or smaller than their non-neoplastic counterparts and the tinctorial qualities of their cytoplasm vary considerably. The presence of lipid vacuoles is quite common as is slight granular basophilia. Mitotic figures are rare. Adenomas are well-vascularized and irregular, blood-filled, endothelial-lined spaces and hemorrhage are common findings.

2. **LIPIDOSIS** - Presence of intracytoplasmic lipid vacuoles in cortical cells. This change may be uniform or multifocal. Severity grade is based on the amount of the adrenal cortex involved:

**Appendix I (cont.): GLOSSARY OF TERMS  
FOR PATHOLOGY FINDINGS**

- 1 = Less than 25% of the cortical cells are vacuolated.
- 2 = 25% to 50% of the cells are affected.
- 3 = 50% to 75% of the cortex is affected.
- 4 = More than 75% of the cortex is affected.

3. FOCI OF CELLULAR ALTERATION - These are degenerative lesions affecting cells of the adrenal cortex. The changes are focal. Affected cells may be either larger or smaller than normal and have different tinctorial qualities as follows:

3A. FOCUS OF CELLULAR ALTERATION, EOSINOPHILIC - Degenerative cortical cells are slightly larger than normal and their cytoplasm is granular and eosinophilic. There is slight compression of adjacent normal cortical cells.

3B. FOCUS OF CELLULAR ALTERATION, VACUOLATED - Degenerative cortical cells may be slightly larger than normal and their cytoplasm is vacuolated. There is usually slight compression of adjacent cortical cells.

3C. FOCUS OF CELLULAR ALTERATION, BASOPHILIC - Degenerative cortical cells may be slightly smaller than normal and their cytoplasm has a slight basophilic granularity. Severity grade criteria for foci of cellular alteration:

- 1 = One focus.
- 2 = Two or three foci.
- 3 = Four to six foci.
- 4 = More than six foci.

4. CORTICAL NODULAR HYPERPLASIA - Nodular proliferation of adrenal cortical cells. Cells may be slightly larger than normal and cytoplasm may be finely vacuolated. These small nodules are usually located at the surface of the adrenal and are surrounded by a thin extension of the adrenal capsule. This change is coded as "Present."

5. FIBROSIS, CAPSULE - Proliferation of fibrous connective tissue in the adrenal capsule. There are minimal numbers of mononuclear inflammatory cells present. Severity grade criteria are based on the proportion of the adrenal capsule involved:

- 1 = Minimal capsular fibrosis; less than 10% of capsule is involved.

**Appendix I (cont.): GLOSSARY OF TERMS  
FOR PATHOLOGY FINDINGS**

- 2 = 10% to 25% of the capsule is involved.
- 3 = 25% to 50% of the capsule is fibrotic.
- 4 = More than 50% of the capsule is fibrotic.

6. MEDULLARY CARCINOMA (MALIGNANT PHEOCHROMOCYTOMA) - Malignant tumor of the adrenal medulla. The cells resemble normal medullary cells but usually they have less cytoplasm and the nuclei are hyperchromatic. The cells are arranged in nests and sometimes in trabecular fashion. Usually the cells are of one type although there are occasional small basophilic cells, with transitions to larger cells having abundant cytoplasm and large nuclei. The only criteria that are used to differentiate malignant from benign tumors of the adrenal medulla is invasion of the capsule and infiltration of tissues outside the adrenal gland or metastasis.

7. PHEOCHROMOCYTOMA - Benign tumor of the adrenal medulla. Morphologic characteristics are similar to that of medullary carcinoma described above. The benign tumors may become quite large but are confined to the adrenal gland.

8. LARGE GRANULAR LYMPHOCYTE LEUKEMIA - See "General Diagnoses" above.

9. EXTRAMEDULLARY HEMATOPOIESIS - Presence of erythrocytic precursors within the adrenal gland. This change is coded as "Present."

10. NECROSIS - Coagulative or liquefactive necrosis in the adrenal cortex or medulla. Severity grade criteria:

- 1 = Focus of necrosis less than the diameter of a 40X microscopic field.
- 2 = Necrosis of less than 25% of an adrenal gland.
- 3 = Necrosis of 25% to 50% of an adrenal gland.
- 4 = Necrosis of more than 50% of an adrenal gland.

**PITUITARY GLAND**

1. ADENOMA - A benign tumor of the anterior pituitary gland. Proliferating cells of the anterior pituitary gland vary considerably in their cytological characteristics and in their tinctorial qualities. Using only hematoxylin and eosin staining, it is not possible to identify cell types accurately or to identify the type of hormone that may be

**Appendix I (cont.): GLOSSARY OF TERMS  
FOR PATHOLOGY FINDINGS**

secreted. Pituitary tumor cells are usually arranged in short cords or nests separated by very fine fibrovascular stroma. They are highly vascular and irregular, blood-filled, endothelial-lined spaces occur frequently as does hemorrhage. Metastases occur rarely but large tumors may infiltrate adjacent tissue and compress overlying tissue of the brain which undergoes compression atrophy.

2. CYST(S) - Presence of spaces within the pituitary that are usually filled with pale eosinophilic fluid. The spaces may be lined with endothelium or flattened epithelial cells. Rarely, a ciliated cell may be observed. Cysts in the pituitary may be single or multiple. They are coded as "Present."

3. ADENOCARCINOMA - A malignant tumor of the anterior pituitary gland. Morphologically, malignant tumors of the pituitary can be distinguished from their benign counterparts only by their invasiveness. Metastases are very rare. If the tumor cells infiltrate tissues outside the confines of the pituitary gland, it is coded as an adenocarcinoma.

4. LARGE GRANULAR LYMPHOCYTE LEUKEMIA - See "General Diagnoses" above.

**EYES AND OPTIC NERVE**

1. CORNEAL MINERALIZATION - Presence of small spicules of mineral within the cornea. Usually this is accompanied by vascularization and occasionally by infiltration of a few inflammatory cells. Severity grade criteria:

- 1 = Presence of one focus of mineral.
- 2 = Presence of two or three mineralized foci.
- 3 = Four to six foci present.
- 4 = More than six mineralized foci present.

2. RETINAL ATROPHY AND/OR DEGENERATION - Consists of variable reduction of cellular elements and disorganization of the different layers of the retina. This is a progressive condition that increases in severity as the animal ages. The condition may be unilateral or bilateral. Severity grade criteria:

- 1 = Perceptible reduction in the number of cells in the retina.

**Appendix I (cont.): GLOSSARY OF TERMS  
FOR PATHOLOGY FINDINGS**

- 2 = Multifocal disorganization of retinal layers.
- 3 = Diffuse disorganization of retinal layers.  
Some parts of layers may be recognizable.
- 4 = No recognizable retinal tissue is present. The retina consists of a band of fibrous tissue.

3. CORNEAL PIGMENTATION - Presence of pigment within the cornea. Pigment may be hemosiderin or melanin. It is present within histiocytic cells and usually accompanies inflammatory lesions in the cornea. Such pigment accumulations are usually focal. Severity grade criteria is based on the number of pigmented foci present:

- 1 = One pigmented focus is present.
- 2 = Two or three pigmented foci are present.
- 3 = Four to six pigmented foci are present.
- 4 = More than six pigmented foci are present.

4. CORNEAL VASCULARIZATION - Presence of endothelial-lined vascular spaces beneath the epithelium or within the corneal stroma. Severity grade criteria are based on the number of vascular cross sections present:

- 1 = One vascular cross section.
- 2 = Two or three vascular cross sections.
- 3 = Four to six vascular cross sections.
- 4 = More than six vascular cross sections.

5. CHRONIC KERATITIS - Chronic inflammation involving the cornea. One or more of the following histologic findings may be present: mononuclear inflammatory cell infiltration beneath the epithelium and into the stroma, erosion or ulceration of the epithelium, proliferation of vascular structures (see corneal vascularization above), presence of pigment, necrosis of cellular elements, and presence of scar tissue. Severity grade criteria are based on the degree of corneal damage and the amount of the cornea involved:

- 1 = Minimal to mild mononuclear inflammatory cell infiltration.
- 2 = Moderate inflammatory cell infiltrate with vascular proliferation or pigment deposition.
- 3 = Similar to grade 2 plus minimal necrosis or scar tissue proliferation.
- 4 = Marked chronic inflammatory changes involving 50% or more of the cornea.



**Appendix I (cont.): GLOSSARY OF TERMS  
FOR PATHOLOGY FINDINGS**

6. IRIDOCYCLITIS - Inflammation of the iris and/or ciliary body. This was a very unusual lesion in this study. It affected only three rats in which it consisted of mild infiltration of the uveal tract with mononuclear inflammatory cells. Severity grade criteria:

- 1 = Minimal infiltration of uveal tract with mononuclear inflammatory cells.
- 2 = Mild mononuclear infiltration of uveal tract.
- 3 = Criteria not established.
- 4 = Criteria not established.

7. METAPLASTIC BONE FORMATION AND/OR MINERALIZATION, SCLERA - This very common finding consists of focal proliferation of plaques of metaplastic bone or deposition of mineral, or both, in the dense fibrous tissue of the sclera. There are no inflammatory lesions associated with these changes. These changes are coded as "Present."

8. LENTICULAR DEGENERATIVE CHANGES COMPATIBLE WITH CATARACT - A cataract is opacity of the lens that can be detected grossly. Microscopically, this lesion may consist of some or all of the following degenerative changes in the lens: abnormal proliferation of lens epithelium which may become redundant and disorganized, disorganization of lens fibers in the cortex with aggregation into spherical masses or globules of material which may become mineralized, increased density, disorganization, and possibly liquefaction of nuclear fibers. These changes are coded collectively under this diagnosis and are designated as "Present."

9. CHRONIC CONJUNCTIVITIS - Chronic inflammation of the conjunctiva. This lesion is characterized primarily by the infiltration of mononuclear inflammatory cells into the conjunctival membrane. Fibrosis may be present. Severity grade criteria are based on the amount of cellular infiltration present:

- 1 = Minimal mononuclear cell infiltrate.
- 2 = Mild mononuclear cell infiltrate.
- 3 = Moderate mononuclear cell infiltrate.
- 4 = Marked mononuclear cell infiltrate.

**EAR**

1. OTITIS MEDIA, SUPPURATIVE OR NONSUPPURATIVE - Acute or

**Appendix I (cont.): GLOSSARY OF TERMS  
FOR PATHOLOGY FINDINGS**

subacute inflammation of middle ear structures. Microscopically, this lesion consists of infiltration of neutrophils (suppurative) or mononuclear inflammatory cells (nonsuppurative) into the structures of the middle ear. Severity grade criteria:

- 1 = Minimal inflammatory cell infiltration.
- 2 = Mild inflammatory cell infiltration into tissues surrounding the cavities of the middle ear.
- 3 = Moderate inflammatory cell infiltrate; presence of cellular exudate within the cavities of the middle ear.
- 4 = As in Grade 3 above plus necrosis and destruction of middle ear structures.

2. FIBROSARCOMA, SUBCUTANEOUS, EXTERNAL EAR, ADJACENT TO EAR TAG - Histological characteristics of this tumor are similar to fibrosarcomas described under the SKIN. There was one such tumor adjacent to the ear tag in one animal.

3. PITUITARY TUMOR INVASION - There is an infiltration of cells from a pituitary tumor within the cranial cavity adjacent to the structures of the middle and inner ear near the origin of the acoustic nerve. Cellular characteristics and arrangement of tumor cells are similar to that described for adenoma under the PITUITARY GLAND.

**AUDITORY SEBACEOUS GLAND**

No gross or microscopic lesions were recognized in the auditory sebaceous glands of rats in Study GLP 83009.

**ABDOMINAL WALL**

1. INFECTION AND INFLAMMATION, SEVERE, INVOLVING MUSCULATURE AND PERITONEAL SURFACE - This diagnosis is self-explanatory. This lesion was not observed in animals necropsied during the second year of this study. This diagnosis is described in the interim report of Study GLP 83009, which covers the findings of the first year of this two-year study.

**THORAX**

1. PRESENCE OF METASTATIC SARCOMA IN THORACIC WALL - See "General Diagnoses" above.

**Appendix I (cont.): GLOSSARY OF TERMS  
FOR PATHOLOGY FINDINGS**

**WHOLE BODY**

1. LARGE GRANULAR LYMPHOCYTE LEUKEMIA - Since neoplastic cells from this disease may occur in virtually every organ and tissue of the body, the primary site for the lesion is coded under *WHOLE BODY*. See "General Diagnoses" above for microscopic description and criteria for coding metastases.
2. INFLAMMATION OF BROWN FAT - This lesion consists of infiltration of inflammatory cells and proliferation of fibrous connective tissue in brown fat. The lesion can occur in brown fat deposits anywhere in the body. For this reason it is coded under *WHOLE BODY* and its location is specified in the special histologic comments section of the Xybian program. The lesion is coded as "Present."

**MEDIASTINUM**

1. CHRONIC INFLAMMATION - The presence of lymphocytes, macrophages, plasma cells, and the proliferation of fibrous connective tissue within the mediastinal tissues. Severity grade is based on a subjective impression of the intensity and extent of the inflammatory lesion:
  - 1 = Minimal detectable infiltration of inflammatory cells.
  - 2 = Mild inflammatory response limited to a small focal area in the mediastinum.
  - 3 = Moderate inflammatory response; not all tissues in the mediastinum are involved.
  - 4 = Marked inflammatory response involving most of the tissues in the mediastinum.
2. REACTIVE HYPERPLASIA, LYMPH NODE - Lymph nodes in the mediastinum are enlarged due to the presence of increased numbers of non-neoplastic lymphoid cells. Microscopic appearance is similar to that described as reactive hyperplasia under *LYMPH NODES* above. The separate diagnosis under *MEDIASTINUM* is used in the few instances of marked reactive hyperplasia of mediastinal nodes to explain and document this change. The lesion is coded as "Present."
3. PRESENCE OF METASTATIC SARCOMA - See "General Diagnoses" above.
4. PRESENCE OF METASTATIC NEOPLASM - See "General Diagnoses"

**Appendix I (cont.): GLOSSARY OF TERMS  
FOR PATHOLOGY FINDINGS**

above.

**ABDOMINAL CAVITY**

1. SARCOMA, CELLULAR DIFFERENTIATION UNSPECIFIED - As explained under "General Diagnoses" above, this diagnosis is used for those sarcomas that develop within the fibrous connective tissue reaction incited by the test material. Since no single organ is involved in every case of sarcoma, the lesion is coded under **ABDOMINAL CAVITY** as the primary site. In each case, the histologic differentiation of the neoplasm is described using the special histologic comments section of the Xybyon program. The lesion is coded as "Presence of Metastatic Sarcoma" under each specific organ that is involved. Using this method of computer entry, it is possible to document the presence of the lesion in multiple sites and indicate its histologic differentiation without causing duplications in incidence data.

2. CHRONIC INFLAMMATION DUE TO THE PRESENCE OF TEST COMPOUND - This designation is used in the few cases in which the lesion is located in sites where it is impossible or impractical to specify a particular organ or tissue. Examples of this situation are lesions located in the mesentery, omentum, or other areas not routinely examined microscopically. The exact location of the lesion is documented using the special histologic comments section of the Xybyon program. Whenever possible, the diagnosis is entered directly for a specific organ.

3. MESOTHELIOMA - Proliferation of malignant cells from serosal surfaces of the abdominal cavity. This tumor can be located on any serosal surface of the abdominal cavity. It is composed of multiple papillary fronds of malignant mesothelial cells arising from the serosal surface. The papillary structures have a supporting stalk of connective tissue containing blood vessels. Covering the stalk are the malignant mesothelial cells which may exist as a single layer or they may be piled up into small nodules. The cells are usually small, either flat or low cuboidal, with scanty amounts of cytoplasm, and round to oval vesicular nuclei. Usually mitotic figures are infrequent. The locations of these lesions in the abdominal cavity are specified using the special histologic comments section of the Xybyon program.

3. LIPOMA - A benign tumor of adipose tissue. These are

**Appendix I (cont.): GLOSSARY OF TERMS FOR PATHOLOGY FINDINGS**

usually well-circumscribed lesions within the mesentery or omentum. They consist of a nodule of fat cells surrounded by a thin connective tissue capsule. Occasionally there are foci or areas of necrosis and mineralization within the nodule.

**DIAPHRAGM**

1. PRESENCE OF METASTATIC SARCOMA - See "General Diagnoses" above.
2. COMPOUND-RELATED INFLAMMATORY REACTION - See "General Diagnoses" above.
3. PRESENCE OF METASTATIC NEOPLASM - See "General Diagnoses" above.

**Appendix J: PATHOLOGY INDIVIDUAL ANIMAL DATA**

Since the XYBION animal-numbering system employed for compilation of pathology data was incompatible with the TOXSYS numbering system used during the in-life phase of the study, animals were renumbered for the pathology data as follows:

<b>Group 1</b>							
<b>Males</b>				<b>Females</b>			
<u>Path#</u>	<u>TOX#</u>	<u>Path#</u>	<u>TOX#</u>	<u>Path#</u>	<u>TOX#</u>	<u>Path#</u>	<u>TOX#</u>
	(84D00-)		(84D00-)		(84D00-)		(84D00-)
1	001	35	100	205	226	239	348
2	002	36	103	206	230	240	352
3	009	37	104	207	232	241	355
4	010	38	105	208	236	242	356
5	013	39	107	209	237	243	360
6	022	40	108	210	238	244	367
7	024	41	109	211	241	245	370
8	031	42	114	212	258	246	372
9	043	43	115	213	259	247	375
10	044	44	116	214	262	248	376
11	045	45	128	215	263	249	377
12	048	46	129	216	265	250	379
13	050	47	131	217	267	251	382
14	055	48	132	218	269	252	385
15	061	49	134	219	273	253	393
16	062	50	139	220	275	254	394
17	065	51	150	221	277	255	396
18	067	52	151	222	281	256	398
19	068	53	152	223	286	257	400
20	069	54	153	224	296	258	401
21	074	55	156	225	302	259	405
22	076	56	157	226	304	260	408
23	077	57	161	227	305	261	411
24	078	58	165	228	311	262	412
25	079	59	167	229	312	263	413
26	080	60	172	230	315	264	416
27	081	61	177	231	318	265	417
28	085	62	181	232	320	266	419
29	089	63	185	233	325	267	423
30	091	64	187	234	327	268	424
31	094	65	191	235	333	269	430
32	095	66	193	236	338	270	431
33	097	67	199	237	343	271	432
34	099	68	201	238	347	272	433

## Appendix J (cont.): PATHOLOGY INDIVIDUAL ANIMAL DATA

Group 2							
Males				Females			
<u>Path#</u>	<u>TOX#</u>	<u>Path#</u>	<u>TOX#</u>	<u>Path#</u>	<u>TOX#</u>	<u>Path#</u>	<u>TOX#</u>
(84D00-)		(84D00-)		(84D00-)		(84D00-)	
69	003	103	113	273	228	307	322
70	004	104	118	274	229	308	323
71	005	105	122	275	231	309	326
72	011	106	123	276	234	310	328
73	012	107	126	277	239	311	332
74	014	108	130	278	244	312	335
75	015	109	136	279	246	313	337
76	025	110	137	280	247	314	339
77	026	111	140	281	249	315	340
78	029	112	141	282	250	316	342
79	033	113	144	283	251	317	344
80	034	114	145	284	257	318	345
81	038	115	146	285	260	319	346
82	041	116	147	286	270	320	351
83	046	117	149	287	272	321	357
84	049	118	154	288	279	322	361
85	051	119	159	289	282	323	363
86	053	120	160	290	284	324	366
87	059	121	168	291	287	325	373
88	060	122	169	292	289	326	380
89	063	123	171	293	291	327	383
90	070	124	174	294	292	328	386
91	071	125	176	295	293	329	392
92	072	126	180	296	294	330	399
93	082	127	182	297	297	331	406
94	083	128	186	298	300	332	407
95	084	129	188	299	303	333	415
96	088	130	190	300	308	334	418
97	090	131	192	301	309	335	421
98	092	132	194	302	310	336	422
99	096	133	196	303	314	337	425
100	102	134	203	304	316	338	426
101	106	135	205	305	317	339	429
102	111	136	206	306	319	340	434

## Appendix J (cont.): PATHOLOGY INDIVIDUAL ANIMAL DATA

Group 3							
Males				Females			
<u>Path#</u>	<u>TOX#</u>	<u>Path#</u>	<u>TOX#</u>	<u>Path#</u>	<u>TOX#</u>	<u>Path#</u>	<u>TOX#</u>
(84D00-)	(84D00-)	(84D00-)	(84D00-)	(84D00-)	(84D00-)	(84D00-)	(84D00-)
137	006	171	117	341	227	375	336
138	007	172	119	342	233	376	341
139	008	173	120	343	235	377	349
140	016	174	121	344	240	378	350
141	017	175	124	345	242	379	353
142	018	176	125	346	243	380	354
143	019	177	127	347	245	381	358
144	021	178	133	348	248	382	359
145	023	179	138	349	252	383	362
146	027	180	142	350	253	384	364
147	028	181	143	351	254	385	365
148	030	182	148	352	255	386	368
149	032	183	155	353	261	387	369
150	035	184	158	354	264	388	371
151	036	185	162	355	266	389	374
152	039	186	163	356	268	390	378
153	040	187	164	357	271	391	381
154	042	188	166	358	278	392	384
155	047	189	170	359	280	393	387
156	052	190	173	360	285	394	388
157	054	191	175	361	288	395	389
158	056	192	178	362	290	396	390
159	058	193	179	363	298	397	391
160	064	194	183	364	299	398	395
161	066	195	189	365	301	399	397
162	073	196	195	366	306	400	403
163	075	197	197	367	307	401	404
164	086	198	198	368	313	402	409
165	087	199	200	369	321	403	410
166	093	200	202	370	324	404	414
167	098	201	204	371	329	405	420
168	101	202	207	372	330	406	427
169	110	203	208	373	331	407	428
170	112	204	209	374	334		



Appendix J (cont.): PATHOLOGY INDIVIDUAL ANIMAL DATA

LETTERMAN ARMY INSTITUTE OF RESEARCH  
 DIV OF RES SUPP, PATH SERV GP  
 SPECIES: RAT/FISCHER-344  
 STUDY START DATE: 23-JAN-84  
 STUDY NUMBER: GLP83009  
 PRINTED: 21-NOV-89  
 PAGE: 14  
 STUDY TYPE: CHRONIC/2 YR CARCINOGENIC

ANIMAL NUMBER: 13/PRETEST-  
 DATE OF DEATH: 27-JAN-86  
 STUDY DAY OF DEATH: 736  
 SEX: MALE  
 DOSE GROUP: 1  
 SACRIFICE STATUS: FINAL SACRIFICE  
 STUDY WEEK OF DEATH: 106  
 TERMINAL BODY WEIGHT: 397.00 (GMS)

<< GROSS ORGAN OBSERVATIONS >>  
 SEVERITY GROSS FREE-TEXT COMMENTS  
 ORGAN NAME  
 TESTES ENLARGED  
 TESTES GROWTH(S) / MASS(ES) PRESENT RIGHT, 2.5 X 1.5CM  
 LIVER ADHESION(S) PRESENT BILATERAL, MULTIPLE VARIABLY SIZED, YELLOW AND BLACK  
 KIDNEY GRANULAR SURFACE PRESENT DIAPHRAGM AND VENTRAL PERITONEAL WALL  
 PITUITARY GLAND ENLARGED PRESENT .5CM DIAMETER, MOTTLED RED AND BLACK

<< MICROSCOPIC TISSUE OBSERVATIONS >>  
 DISTRIBUTION (SEVERITY) / SPECIAL COMMENTS

HEART  
 -CARDIOMYOPATHY NOT SPECIFIED(MILD)

LYMPH NODES  
 -RED BLOOD CELLS, HEMOSIDERIN AND/OR ERYTHROPHAGOCYTOSIS WITHIN RBC'S PRESENT IN MEDIASTINAL NODES ONLY.  
 MEDULLARY SINUSES NOT SPECIFIED (PRESENT)

LIVER  
 -COMPOUND RELATED INFLAMMATORY REACTION NOT SPECIFIED (PRESENT)  
 -BILE DUCTULE EPITHELIAL HYPERPLASIA AND/OR CHOLANGIOFIBROSIS NOT SPECIFIED(MILD)  
 -HEPATOCTIC VACUOLIZATION MULTI-FOCAL(MILD)  
 -FOCUS OF CELLULAR ALTERATION - EOSINOPHILIC CELLS MULTI-FOCAL(MILD)

KIDNEY  
 -PROGRESSIVE RENAL DISEASE NOT SPECIFIED(MARKED)

PROSTATE  
 -CHRONIC PROSTATITIS NOT SPECIFIED(MILD)

TESTES  
 -B- INTERSTITIAL CELL ADENOMA (PRESENT)

MAMMARY GLANDS

Appendix J (cont.): **PATHOLOGY INDIVIDUAL ANIMAL DATA**

LETTERMAN ARMY INSTITUTE OF RESEARCH  
DIV OF RES SUPP, PATH SERV GP  
SPECIES: RAT/FISCHER-344

INDIVIDUAL ANIMAL DATA REPORT  
STUDY NUMBER: GLP83009  
STUDY START DATE: 23-JAN-84

PRINTED: 21-NOV-89  
PAGE: 15

STUDY TYPE: CHRONIC/2 YR CARCINOGENIC

ANIMAL NUMBER: 13/PRETEST# 13 SEX: MALE DOSE GROUP: 1 SACRIFICE STATUS: FINAL SACRIFICE  
DATE OF DEATH: 27-JAN-86 STUDY DAY OF DEATH: 736 STUDY WEEK OF DEATH: 106 TERMINAL BODY WEIGHT: 397.00 (GMS)

TISSUE / HISTOPATHOLOGIC FINDINGS << MICROSCOPIC TISSUE OBSERVATIONS >>  
DISTRIBUTION (SEVERITY) / SPECIAL COMMENTS

MAMMARY GLANDS .....  
-HYPERPLASIA AND/OR HYPERTROPHY OF THE ACINAR TISSUE ..... NOT SPECIFIED(TRACE)  
-DILATATION (ECTASIA) OF DUCTS AND DUCTULES ..... NOT SPECIFIED (PRESENT)

ADRENAL .....  
-FOCUS OF CELLULAR ALTERATION, VACUOLATED ..... NOT SPECIFIED(TRACE)

PITUITARY GLAND .....  
-B- ADENOMA ..... (PRESENT)

EYES & OPTIC N. ....  
-CORNEAL MINERALIZATION ..... MILD DEGENERATIVE CHANGES NOTED IN LENS ON SECTION # 198.  
-METAPLASTIC BONE FORMATION AND/OR MINERALIZATION, SCLERA ..... NOT SPECIFIED(TRACE)  
-LENTICULAR DEGENERATIVE CHANGES COMPATIBLE WITH CATARACT ..... NOT SPECIFIED (PRESENT)

DIAPHRAGM ..... MISCELLANEOUS TISSUE  
-COMPOUND RELATED INFLAMMATORY REACTION ..... NOT SPECIFIED (PRESENT)

**Appendix J (cont.): PATHOLOGY INDIVIDUAL ANIMAL DATA**

LETTERMAN ARMY INSTITUTE OF RESEARCH  
 DIV OF RES SUPP, PATH SERV GP  
 SPECIES: RAT/FISCHER-344

INDIVIDUAL ANIMAL DATA REPORT  
 STUDY NUMBER: GLP83009  
 STUDY START DATE: 23-JAN-84

PRINTED: 21-NOV-89  
 PAGE: 16  
 STUDY TYPE: CHRONIC/2 YR CARCINOGENIC

ANIMAL NUMBER: 14/PRETEST= 14 SEX: MALE DOSE GROUP: 1 SACRIFICE STATUS: FINAL SACRIFICE  
 DATE OF DEATH: 27-JAN-86 STUDY DAY OF DEATH: 736 STUDY WEEK OF DEATH: 106 TERMINAL BODY WEIGHT: 377.00 (GMS)

ORGAN NAME SEVERITY GROSS OBSERVATIONS  
 KEYWORDS / PHRASES  
 ADHESION(S) PRESENT DIAPHRAGM, STOMACH, INTESTINE AND VENTRAL ABDOMINAL WALL  
 GROWTH(S) / MASS(ES) PRESENT TWO MASSES, ONE IS .5CM DIAMETER AND MODULAR. THE OTHER  
 IS 1CM DIAMETER, DARK AND BLOOD FILLED.  
 PROMINENT FIBROUS CAPSULE PRESENT FOCAL, .5 X .25CM  
 STRICTURE PRESENT  
 ENLARGED PRESENT RIGHT, 3 X 1.75CM  
 GROWTH(S) / MASS(ES) PRESENT BILATERAL, YELLOW AND BLACK  
 LENS CATARACT PRESENT LEFT

SEVERITY GROSS FREE-TEXT COMMENTS

<< GROSS ORGAN OBSERVATIONS >>

TISSUE / HISTOPATHOLOGIC FINDINGS OBSERVATIONS >>  
 DISTRIBUTION (SEVERITY) / SPECIAL COMMENTS

THYROID GLANDS ..... NOT SPECIFIED (TRACE)  
 -PARA-FOLLICULAR CELL HYPERPLASIA ("C" CELL, LIGHT CELL)

SALIVARY GLAND ..... FOCAL (TRACE)  
 -ATROPHY AND LOSS OF ACINAR TISSUE

EXORBITAL LACRIM ..... TISSUE IS MISSING

HEART ..... NOT SPECIFIED (MILD)  
 -CARDIOMYOPATHY ..... NOT SPECIFIED (TRACE)  
 -MEDIAL HYPERTROPHY OF MUSCULAR ARTERIES

SPLEEN ..... FOCAL (TRACE)  
 -FIBROSIS CAPSULAR

LYMPH NODES ..... REACTIVE HYPERPLASIA NOTED IN CERVICAL LYMPH NODE.  
 -RED BLOOD CELLS, HEMOSIDERIN AND/OR ERYTHROPHAGOCYTOSIS WITHIN RBC'S AND PIGMENT ARE PROMINENT IN MEDIASTINAL NODE.  
 MEDULLARY SINUSES ..... NOT SPECIFIED (PRESENT)  
 -REACTIVE HYPERPLASIA ..... NOT SPECIFIED (PRESENT)

LIVER .....

Appendix J (cont.): **PATHOLOGY INDIVIDUAL ANIMAL DATA**

LETTERMAN ARMY INSTITUTE OF RESEARCH  
 DIV OF RES SUPP, PATH SERV GP  
 STUDY NUMBER: GLP83009  
 STUDY START DATE: 23-JAN-84  
 STUDY TYPE: CHRONIC/2 YR CARCINOGENIC

PRINTED: 21-NOV-89  
 PAGE: 17

ANIMAL NUMBER: 14/PRETEST= 14 SEX: MALE DOSE GROUP: 1 SACRIFICE STATUS: FINAL SACRIFICE  
 DATE OF DEATH: 27-JAN-86 STUDY DAY OF DEATH: 736 STUDY WEEK OF DEATH: 106 TERMINAL BODY WEIGHT: 377.00 (GMS)

TISSUE / HISTOPATHOLOGIC FINDINGS << MICROSCOPIC TISSUE OBSERVATIONS >>  
 DISTRIBUTION (SEVERITY) / SPECIAL COMMENTS

LIVER ..... NOT SPECIFIED (PRESENT)  
 -COMPOUND RELATED INFLAMMATORY REACTION ..... NOT SPECIFIED (MODERATE)  
 -BILE DUCTULE EPITHELIAL HYPERPLASIA AND/OR CHOLANGIOFIBROSIS ..... FOCAL(TRACE)  
 -FOCUS OF CELLULAR ALTERATION - CLEAR CELLS ..... SECONDARY NEOPLASM FROM ORGAN ABDOMINAL CAVITY  
 -N- PRESENCE OF METASTATIC SARCOMA

KIDNEY ..... NOT SPECIFIED(TRACE)  
 -PROGRESSIVE RENAL DISEASE

SEMINAL VESICLE ..... NOT SPECIFIED (PRESENT)  
 -GENERALIZED ATROPHY

TESTES ..... (PRESENT)  
 -B- INTERSTITIAL CELL ADENOMA

JEJUNUM ..... NOT SPECIFIED (PRESENT)  
 -COMPOUND RELATED INFLAMMATORY REACTION

STOMACH ..... NOT SPECIFIED (PRESENT)  
 -COMPOUND RELATED INFLAMMATORY REACTION

SKELETAL MUSCLE ..... NOT SPECIFIED(TRACE)  
 -CHRONIC MYOSITIS

SCIATIC NERVE ..... TISSUE IS MISSING

PITUITARY GLAND ..... (PRESENT)  
 -B- ADENOMA

EYES & OPTIC N. .... NOT SPECIFIED(MARKED)  
 -RETINAL ATROPHY AND/OR DEGENERATION, UNILATERAL OR BILATERAL  
 -METAPLASTIC BONE FORMATION AND/OR MINERALIZATION, SCLERA

Appendix J (cont.): PATHOLOGY INDIVIDUAL ANIMAL DATA

LETTERMAN ARMY INSTITUTE OF RESEARCH  
DIV OF RES SUPP, PATH SERV GP  
SPECIES: RAT/FISCHER-344

INDIVIDUAL ANIMAL DATA REPORT  
STUDY NUMBER: GLP83009

PRINTED: 21-NOV-89  
PAGE: 18

STUDY START DATE: 23-JAN-84

STUDY TYPE: CHRONIC/2 YR CARCINOGENIC

ANIMAL NUMBER: 14/PRETEST-14 SEX: MALE DOSE GROUP: 1 SACRIFICE STATUS: FINAL SACRIFICE

DATE OF DEATH: 27-JAN-86 STUDY DAY OF DEATH: 736 STUDY WEEK OF DEATH: 106 TERMINAL BODY WEIGHT: 377.00 (GMS)

TISSUE / HISTOPATHOLOGIC FINDINGS  
MICROSCOPIC TISSUE OBSERVATIONS  
DISTRIBUTION (SEVERITY) / SPECIAL COMMENTS

EYES & OPTIC N. .... NOT SPECIFIED (PRESENT)  
-LENTICULAR DEGENERATIVE CHANGES COMPATIBLE WITH CATARACT

ABDOMINAL CAVITY ..... MISCELLANEOUS TISSUE  
SARCOMA INVOLVES PRIMARILY LIVER AND DIAPHRAGM. IN MANY AREAS  
THERE IS OSTEOID PRODUCTION, AND SOME OF THE OSTEOID IS  
MINERALIZED. THE MOST APPROPRIATE HISTOLOGICAL CLASSIFICATION  
FOR THIS LESION IS OSTEOSARCOMA. CHRONIC INFLAMMATORY RESPONSE  
IS PRESENT IN THE MESENTERY ADJACENT TO THE SMALL INTESTINE.  
(PRESENT)

-M- SARCOMA, CELLULAR DIFFERENTIATION UNSPECIFIED  
DIAPHRAGM ..... MISCELLANEOUS TISSUE  
-M- PRESENCE OF METASTATIC SARCOMA  
-COMPOUND RELATED INFLAMMATORY REACTION  
SECONDARY NEOPLASM FROM ORGAN ABDOMINAL CAVITY  
NOT SPECIFIED (PRESENT)

**Appendix J (cont.): PATHOLOGY INDIVIDUAL ANIMAL DATA**

LETTERMAN ARMY INSTITUTE OF RESEARCH  
 DIV OF RES SUPP, PATH SERV GP  
 SPECIES: RAT/FISCHER-344  
 ANIMAL NUMBER: 15/PRETEST= 15 SEX: MALE DOSE GROUP: 1 SACRIFICE STATUS: FINAL SACRIFICE  
 DATE OF DEATH: 27-JAN-86 STUDY DAY OF DEATH: 736 STUDY WEEK OF DEATH: 106 TERMINAL BODY WEIGHT: 376.00 (GMS)  
 STUDY START DATE: 23-JAN-84 STUDY TYPE: CHRONIC/2 YR CARCINOGENIC  
 INDIVIDUAL ANIMAL DATA REPORT  
 STUDY NUMBER: GLP83009  
 PRINTED: 21-NOV-89  
 PAGE: 19

<< GROSS ORGAN OBSERVATIONS >>  
 SEVERITY GROSS FREE-TEXT COMMENTS  
 LIVER ADHESION(S) PRESENT DIAPHRAGM, STOMACH, OMENTUM, VENTRAL ABDOMINAL WALL  
 LIVER GROWTH(S) / MASS(ES) PRESENT 2CM DIAMETER, FIRM, WHITE  
 TESTES ENLARGED PRESENT 3 X 1.75CM  
 TESTES GROWTH(S) / MASS(ES) PRESENT BILATERAL  
 TESTES GROWTH(S) / MASS(ES) PRESENT BILATERAL, YELLOW AND BLACK

<< MICROSCOPIC TISSUE OBSERVATIONS >>  
 DISTRIBUTION (SEVERITY) / SPECIAL COMMENTS

THYROID GLANDS ..... NOT SPECIFIED (PRESENT)  
 -COLLOID CYST(S) .....

HEART ..... NOT SPECIFIED(MILD)  
 -CARDIOMYOPATHY .....

LUNGS ..... NOT SPECIFIED(TRACE)  
 -MINERALIZATION OF PULMONARY ARTERIES .....

LYMPH NODES ..... REACTIVE HYPERPLASIA NOTED IN CERVICAL LYMPH NODE.  
 -REACTIVE HYPERPLASIA .....

LIVER ..... NOT SPECIFIED (PRESENT)  
 -COMPOUND RELATED INFLAMMATORY REACTION ..... NOT SPECIFIED(MILD)  
 -BILE DUCTULE EPITHELIAL HYPERPLASIA AND/OR CHOLANGIOFIBROSIS ..... NOT SPECIFIED(MILD)  
 -HEPATITIS ..... MULTI-FOCAL(MILD)  
 -HEPATOCTYIC VACUOLIZATION ..... MULTI-FOCAL(TRACE)  
 -M- PRESENCE OF METASTATIC SARCOMA ..... SECONDARY NEOPLASM FROM ORGAN ABDOMINAL CAVITY

KIDNEY ..... NOT SPECIFIED(MARKEG)  
 -PROGRESSIVE RENAL DISEASE .....

PROSTATE .....

Appendix J (cont.): PATHOLOGY INDIVIDUAL ANIMAL DATA

LETTERMAN ARMY INSTITUTE OF RESEARCH  
 DIV OF RES SUPP, PATH SERV GP  
 SPECIES: RAT/FISCHER-344  
 ANIMAL NUMBER: 15/PRETEST= 15 SEX: MALE DOSE GROUP: 1 SACRIFICE STATUS: FINAL SACRIFICE  
 DATE OF DEATH: 27-JAN-86 STUDY DAY OF DEATH: 736 STUDY WEEK OF DEATH: 106 TERMINAL BODY WEIGHT: 376.00 (GMS)  
 STUDY START DATE: 23-JAN-84 STUDY TYPE: CHRONIC/2 YR CARCINOGENIC  
 PRINTED: 21-NOV-89  
 PAGE: 20

<< M I C R O S C O P I C T I S S U E O B S E R V A T I O N S >>  
 TISSUE / HISTOPATHOLOGIC FINDINGS ..... DISTRIBUTION (SEVERITY) / SPECIAL COMMENTS .....

- PROSTATE ..... NOT SPECIFIED (MILD)
- CHRONIC PROSTATITIS ..... NOT SPECIFIED (TRACE)
- BENIGN HYPERPLASIA
- SEMINAL VESICLE ..... NOT SPECIFIED (PRESENT)
- GENERALIZED ATROPHY
- TESTES ..... (PRESENT)
- B- INTERSTITIAL CELL ADENOMA
- JEJUNUM ..... NOT SPECIFIED (PRESENT)
- COMPOUND RELATED INFLAMMATORY REACTION
- PANCREAS ..... FOCAL (TRACE)
- ACINAR (EXOCRINE) ATROPHY ..... FOCAL (TRACE)
- CHRONIC INFLAMMATION ..... (PRESENT)
- B- ISLET CELL ADENOMA
- STOMACH ..... NOT SPECIFIED (PRESENT)
- COMPOUND RELATED INFLAMMATORY REACTION
- MAMMARY GLANDS ..... NOT SPECIFIED (TRACE)
- HYPERPLASIA AND/OR HYPERTROPHY OF THE ACINAR TISSUE ..... NOT SPECIFIED (PRESENT)
- DILATATION (ECTASIA) OF DUCTS AND DUCTULES
- ADRENAL ..... ONLY ONE ADRENAL GLAND SAVED FOR HISTOLOGIC EXAMINATION.
- PITUITARY GLAND ..... (PRESENT)
- B- ADENOMA
- EYES & OPTIC N. .... NOT SPECIFIED (PRESENT)
- METAPLASTIC BONE FORMATION AND/OR MINERALIZATION, SCLERA

Appendix J (cont.): PATHOLOGY INDIVIDUAL ANIMAL DATA

LETTERMAN ARMY INSTITUTE OF RESEARCH  
DIV OF RES SUPP, PATH SERV GP  
SPECIES: RAT/FISCHER-344

PRINTED: 21-NOV-89  
PAGE: 21

INDIVIDUAL ANIMAL DATA REPORT  
STUDY NUMBER: GLP83009

STUDY START DATE: 23-JAN-84

STUDY TYPE: CHRONIC/2 YR CARCINOGENIC

ANIMAL NUMBER: 15/PRETEST#

SEX: MALE

DOSE GROUP: 1

SACRIFICE STATUS: FINAL SACRIFICE

DATE OF DEATH: 27-JAN-86

STUDY DAY OF DEATH: 736

STUDY WEEK OF DEATH: 106

TERMINAL BODY WEIGHT: 376.00 (GMS)

TISSUE / HISTOPATHOLOGIC FINDINGS

<< M I C R O S C O P I C T I S S U E O B S E R V A T I O N S >>

DISTRIBUTION (SEVERITY) / SPECIAL COMMENTS

ABDOMINAL CAVITY

MISCELLANEOUS TISSUE

THE SARCOMA INVOLVES PRIMARILY LIVER AND DIAPHRAGM. IN MANY AREAS IT IS FORMING OSTEOID, SOME OF WHICH IS MINERALIZED. THESE AREAS ARE TYPICAL OF OSTEOSARCOMA. IN ONE SMALLER AREA THERE IS NO OSTEOID, AND THE MICROSCOPIC APPEARANCE IS THAT OF A FAIRLY WELL-DIFFERENTIATED FIBROSARCOMA.

-M- SARCOMA, CELLULAR DIFFERENTIATION UNSPECIFIED

DIAPHRAGM

MISCELLANEOUS TISSUE

SECONDARY NEOPLASM FROM ORGAN ABDOMINAL CAVITY NOT SPECIFIED (PRESENT)

-M- PRESENCE OF METASTATIC SARCOMA

-COMPOUND RELATED INFLAMMATORY REACTION



Appendix J (cont.): **PATHOLOGY INDIVIDUAL ANIMAL DATA**

LETTERMAN ARMY INSTITUTE OF RESEARCH  
 DIV OF RES SUPP, PATH SERV GP  
 SPECIES: RAT/FISCHER-344

INDIVIDUAL ANIMAL DATA REPORT  
 STUDY NUMBER: GLP83009

STUDY START DATE: 23-JAN-84

ANIMAL NUMBER: 16/PRETEST# 16 SEX: MALE DOSE GROUP: 1 SACRIFICE STATUS: SACRIFICED MORIBUND  
 DATE OF DEATH: 11-DEC-85 STUDY DAY OF DEATH: 689 STUDY WEEK OF DEATH: 99 TERMINAL BODY WEIGHT: 370.00 (GMS)

STUDY TYPE: CHRONIC/2 YR CARCINOGENIC

ORGAN NAME << GROSS ORGAN OBSERVATIONS >>  
 SEVERITY GROSS FREE-TEXT COMMENTS  
 LIVER ADHESION(S) PRESENT DIAPHRAGM, VENTRAL ABDOMINAL WALL  
 LIVER GROWTH(S) / MASS(ES) PRESENT LARGE, FIRM, WHITE, INVOLVES MOST OF LIVER AND HAS A  
 2CM DIAMETER NODULE EXTENDING THROUGH THE DIAPHRAGM  
 INTO THE THORACIC CAVITY.  
 TESTES GROWTH(S) / MASS(ES) PRESENT BILATERAL, MULTIPLE VARIABLY SIZED, YELLOW  
 PITUITARY GLAND DISCOLORATION PRESENT FOCAL, BLACK, .2CM DIAMETER

TISSUE / HISTOPATHOLOGIC FINDINGS << MICROSCOPIC TISSUE OBSERVATIONS >>  
 DISTRIBUTION (SEVERITY) / SPECIAL COMMENTS

THYROID GLANDS (PRESENT)  
 -B- PARA-FOLLICULAR CELL ADENOMA  
 HEART NOT SPECIFIED(MILD)  
 -CARDIOMYOPATHY  
 LYMPH NODES REACTIVE HYPERPLASIA NOTED IN CERVICAL LYMPH NODE.  
 -REACTIVE HYPERPLASIA NOT SPECIFIED (PRESENT)  
 LIVER NOT SPECIFIED (PRESENT)  
 -COMPOUND RELATED INFLAMMATORY REACTION NOT SPECIFIED(MILD)  
 -BILE DUCTULE EPITHELIAL HYPERPLASIA AND/OR CHOLANGIOFIBROSIS MULTI-FOCAL(MILD)  
 -HEPATOCTYIC VACUOLIZATION NOT SPECIFIED(TRACE)  
 -FOCUS OF CELLULAR ALTERATION - CLEAR CELLS  
 -N- PRESENCE OF METASTATIC SARCOMA SECONDARY NEOPLASIA FROM ORGAN ABDOMINAL CAVITY  
 KIDNEY NOT SPECIFIED(MILD)  
 -PROGRESSIVE RENAL DISEASE  
 PROSTATE NOT SPECIFIED(TRACE)  
 -CHRONIC PROSTATITIS  
 -BENIGN HYPERPLASIA NOT SPECIFIED(TRACE)  
 SEMINAL VESICLE

**Appendix J (cont.): PATHOLOGY INDIVIDUAL ANIMAL DATA**

LETTERMAN ARMY INSTITUTE OF RESEARCH  
 DIV OF RES SUPP, PATH SERV GP  
 SPECIES: RAT/FISCHER-344  
 STUDY NUMBER: GLP83009  
 STUDY START DATE: 23-JAN-84  
 STUDY TYPE: CHRONIC/2 YR CARCINOGENIC  
 PRINTED: 21-NOV-89  
 PAGE: 23  
 ANIMAL NUMBER: 16/PRETEST-16  
 SEX: MALE  
 DOSE GROUP: 1  
 SACRIFICE STATUS: SACRIFICED MORIBUND  
 DATE OF DEATH: 11-DEC-85  
 STUDY DAY OF DEATH: 689  
 STUDY WEEK OF DEATH: 99  
 TERMINAL BODY WEIGHT: 370.00 (GMS)  
 TISSUE / HISTOPATHOLOGIC FINDINGS  
 << MICROSCOPIC TISSUE OBSERVATIONS >>  
 DISTRIBUTION (SEVERITY) / SPECIAL COMMENTS

SEMINAL VESICLE ..... NOT SPECIFIED (PRESENT)  
 -GENERALIZED ATROPHY

TESTES ..... (PRESENT)  
 -B- INTERSTITIAL CELL ADENOMA

PANCREAS ..... FOCAL(MILD)  
 -ACINAR (EXOCRINE) ATROPHY

MAMMARY GLANDS ..... NOT SPECIFIED(MILD)  
 -HYPERPLASIA AND/OR HYPERTROPHY OF THE ACINAR TISSUE  
 -GALACTOCELE(S) ..... NOT SPECIFIED (PRESENT)  
 -DILATATION (ECTASIA) OF DUCTS AND DUCTULES ..... NOT SPECIFIED (PRESENT)

PITUITARY GLAND ..... (PRESENT)  
 -B- ADENOMA

EYES & OPTIC N. .... NOT SPECIFIED (PRESENT)  
 -METAPLASTIC BONE FORMATION AND/OR MINERALIZATION, SCLERA

MEDIASTINUM ..... MISCELLANEOUS TISSUE  
 -M- PRESENCE OF METASTATIC SARCOMA ..... SECONDARY NEOPLASM FROM ORGAN

ABDOMINAL CAVITY ..... MISCELLANEOUS TISSUE  
 THIS SARCOMA INVOLVES PRIMARILY THE LIVER. IT EXTENDED THROUGH  
 THE DIAPHRAGM INTO THE THORACIC CAVITY. THE NEOPLASM IS POORLY  
 DIFFERENTIATED. IN SOME AREAS IT HAS MYXOMATOUS APPEARANCE.  
 ELSEWHERE IT IS HIGHLY ANAPLASTIC.  
 -M- SARCOMA, CELLULAR DIFFERENTIATION UNSPECIFIED (PRESENT)

Appendix J (cont.): PATHOLOGY INDIVIDUAL ANIMAL DATA

LETTERMAN ARMY INSTITUTE OF RESEARCH  
DIV OF RES SUPP, PATH SERV GP  
SPECIES: RAT/FISCHER-344

INDIVIDUAL ANIMAL DATA REPORT  
STUDY NUMBER: GLP83009  
STUDY START DATE: 23-JAN-84

PRINTED: 21-NOV-89  
PAGE: 24

STUDY TYPE: CHRONIC/2 YR CARCINOGENIC

ANIMAL NUMBER: 16/PRETEST= 16 SEX: MALE DOSE GROUP: 1 SACRIFICE STATUS: SACRIFICED MORIBUND  
DATE OF DEATH: 11-DEC-85 STUDY DAY OF DEATH: 689 STUDY WEEK OF DEATH: 99 TERMINAL BODY WEIGHT: 370.00 (GMS)

<< MICROSCOPIC TISSUE OBSERVATIONS >>  
TISSUE / HISTOPATHOLOGIC FINDINGS DISTRIBUTION (SEVERITY) / SPECIAL COMMENTS

DIAPHRAGM

MISCELLANEOUS TISSUE

GROSS DESCRIPTION INDICATES THAT THE SARCOMA EXTENDED THROUGH THE DIAPHRAGM INTO THE THORACIC CAVITY. SECTION #21 IS FROM THE TUMOR IN THE THORAX AND SECTION #22 IS FROM THE LIVER MASS. NEITHER SECTION HAS TISSUE FROM THE DIAPHRAGM.

Appendix J (cont.): PATHOLOGY INDIVIDUAL ANIMAL DATA

LETTERMAN ARMY INSTITUTE OF RESEARCH DIV OF RES SUPP, PATH SERV GP SPECIES: RAY/FISCHER-344

INDIVIDUAL ANIMAL DATA REPORT STUDY NUMBER: GLP83009 STUDY START DATE: 23-JAN-84

PRINTED: 21-NOV-89 PAGE: 26

STUDY TYPE: CHRONIC/2 YR CARCINOGENIC

ANIMAL NUMBER: 18/PRETEST= 18 SEX: MALE DOSE GROUP: 1 SACRIFICE STATUS: FINAL SACRIFICE DATE OF DEATH: 27-JAN-86 STUDY DAY OF DEATH: 736 STUDY WEEK OF DEATH: 106 TERMINAL BODY WEIGHT: 369.00 (GMS)

ORGAN NAME << GROSS ORGAN OBSERVATIONS >> SEVERITY GROSS FREE-TEXT COMMENTS

SPLEEN PROMINENT FIBROUS CAPSULE PRESENT .5CM AREA LIVER ADHESION(S) PRESENT DIAPHRAGM, SMALL INTESTINE AND VENTRAL ABDOMINAL WALL TESTES GROWTH(S) / MASS(ES) PRESENT BILATERAL, YELLOW

TISSUE / HISTOPATHOLOGIC FINDINGS << MICROSCOPIC TISSUE OBSERVATIONS >> DISTRIBUTION (SEVERITY) / SPECIAL COMMENTS

THYROID GLANDS (PRESENT) -B- PARA-FOLLICULAR CELL ADENOMA

EXORBITAL LACRIM TISSUE IS MISSING

HEART NOT SPECIFIED(TRACE) -CARDIOMYOPATHY NOT SPECIFIED(TRACE) -MEDIAL HYPERTROPHY OF MUSCULAR ARTERIES

LUNGS NOT SPECIFIED(TRACE) -MINERALIZATION OF PULMONARY ARTERIES

SPLEEN NOT SPECIFIED(TRACE) -FIBROSIS CAPSULAR

LIVER NOT SPECIFIED (PRESENT) -COMPOUND RELATED INFLAMMATORY REACTION NOT SPECIFIED(MILD) -BILE DUCTULE EPITHELIAL HYPERPLASIA AND/OR CHOLANGIOFIBROSIS MULTI-FOCAL(TRACE) -HEPATOCTYIC VACUOLIZATION

KIDNEY NOT SPECIFIED(MILD) -PROGRESSIVE RENAL DISEASE

SEMINAL VESICLE

**Appendix J (cont.): PATHOLOGY INDIVIDUAL ANIMAL DATA**

LETTERMAN ARMY INSTITUTE OF RESEARCH  
 DIV OF RES SUPP, PATH SERV GP  
 SPECIES: RAT/FISCHER-344

INDIVIDUAL ANIMAL DATA REPORT  
 STUDY NUMBER: GLP83009

PRINTED: 21-NOV-89  
 PAGE: 27

STUDY START DATE: 23-JAN-84  
 STUDY TYPE: CHRONIC/2 YR CARCINOGENIC

ANIMAL NUMBER: 15/PRETEST#  
 DOSE GROUP: 1  
 SACRIFICE STATUS: FINAL SACRIFICE

DATE OF DEATH: 27-JAN-86  
 SEX: MALE  
 STUDY WEEK OF DEATH: 736  
 TERMINAL BODY WEIGHT: 369.00 (GMS)

<< M I C R O S C O P I C T I S S U E O B S E R V A T I O N S >>  
 TISSUE / HISTOPATHOLOGIC FINDINGS  
 DISTRIBUTION (SEVERITY) / SPECIAL COMMENTS

- SEMINAL VESICLE ..... NOT SPECIFIED (PRESENT)
- GENERALIZED ATROPHY
- TESTES ..... (PRESENT)
- B- INTERSTITIAL CELL ADENOMA
- JEJUNUM ..... ADHESION TO BODY WALL NOTED.
- COMPOUND RELATED INFLAMMATORY REACTION ..... NOT SPECIFIED (PRESENT)
- MAMMARY GLANDS ..... NOT SPECIFIED (TRACE)
- HYPERPLASIA AND/OR HYPERTROPHY OF THE ACINAR TISSUE
- NOSE/TURBINATES ..... CELLULAR INFILTRATE INVOLVES NASO-LACRIMAL DUCTS BILATERALLY.
- MIXED INFLAMMATORY CELL INFILTRATION, NASAL CAVITY, SINUSES, ..... NOT SPECIFIED (MODERATE)
- TURBINATES, NASO-LACRIMAL DUCTS
- PITUITARY GLAND ..... (PRESENT)
- B- ADENOMA
- EYES & OPTIC N. ....
- METAPLASTIC BONE FORMATION AND/OR MINERALIZATION, SCLERA ..... NOT SPECIFIED (PRESENT)
- LENTICULAR DEGENERATIVE CHANGES COMPATIBLE WITH CATARACT ..... NOT SPECIFIED (PRESENT)
- DIAPHRAGM ..... MISCELLANEOUS TISSUE
- COMPOUND RELATED INFLAMMATORY REACTION ..... NOT SPECIFIED (PRESENT)

**Appendix J (cont.): PATHOLOGY INDIVIDUAL ANIMAL DATA**

LETTERMAN ARMY INSTITUTE OF RESEARCH  
 DIV OF RES SU-P, PATH SERV GP  
 SPECIES: RAT/FISCHER-344  
 STUDY NUMBER: 19/PRETEST-19  
 DATE OF DEATH: 27-JAN-86  
 STUDY START DATE: 23-JAN-86  
 DOSE GROUP: 1  
 SEX: MALE  
 STUDY WEEK OF DEATH: 736  
 SACRIFICE STATUS: FINAL SACRIFICE  
 TERMINAL BODY WEIGHT: 377.00 (GMS)  
 STUDY TYPE: CHRONIC/2 YR CARCINOGENIC

INDIVIDUAL ANIMAL DATA REPORT  
 STUDY NUMBER: GLP83009  
 PRINTED: 21-NOV-89  
 PAGE: 28

ORGAN NAME: << GROSS ORGAN OBSERVATIONS >>  
 KEYWORDS / PHRASES SEVERITY GROSS FREE-TEXT COMMENTS  
 TAIL PRESENT CHRONIC  
 TESTES ENLARGED PRESENT BILATERAL, 2.5 X 1.5CM  
 TESTES GROWTH(S) / MASS(ES) PRESENT BILATERAL, YELLOW  
 LIVER ADHESION(S) PRESENT DIAPHRAGM

TISSUE / HISTOPATHOLOGIC FINDINGS << MICROSCOPIC TISSUE OBSERVATIONS >>  
 DISTRIBUTION (SEVERITY) / SPECIAL COMMENTS

- HEART ..... NOT SPECIFIED(MILD)
- CARDIOMYOPATHY
- LYMPH NODES ..... BROWN PIGMENT PRESENT IN MEDIASTINAL NODE ONLY.
- RED BLOOD CELLS, HEMOSIDERIN AND/OR ERYTHROPHAGOCYTOSIS WITHIN MEDULLARY SINUSES NOT SPECIFIED (PRESENT)
- LIVER ..... NOT SPECIFIED (PRESENT)
- COMPOUND RELATED INFLAMMATORY REACTION NOT SPECIFIED(MILD)
- BILE DUCTULE EPITHELIAL HYPERPLASIA AND/OR CHOLANGIOFIBROSIS MULTI-FOCAL(TRACE)
- HEPATOCTYIC VACUOLIZATION
- KIDNEY ..... NOT SPECIFIED(MILD)
- PROGRESSIVE RENAL DISEASE
- SEMINAL VESICLE ..... NOT SPECIFIED (PRESENT)
- GENERALIZED ATROPHY (PRESENT)
- TESTES ..... (PRESENT)
- B- INTERSTITIAL CELL ADENOMA
- ILEUM ..... NOT SPECIFIED (PRESENT)
- COMPOUND RELATED INFLAMMATORY REACTION

Appendix J (cont.): PATHOLOGY INDIVIDUAL ANIMAL DATA

LETTERMAN ARMY INSTITUTE OF RESEARCH  
DIV OF RES SUPP, PATH SERV GP  
SPECIES: RAT/FISCHER-344

INDIVIDUAL ANIMAL DATA REPORT  
STUDY NUMBER: GLP83009

PRINTED: 21-NOV-89  
PAGE: 29

STUDY START DATE: 23-JAN-84

STUDY TYPE: CHRONIC/2 YR CARCINOGENIC

ANIMAL NUMBER: 19/PRETEST# 19 SEX: MALE DOSE GROUP: 1 SACRIFICE STATUS: FINAL SACRIFICE  
DATE OF DEATH: 27-JAN-86 STUDY DAY OF DEATH: 736 STUDY WEEK OF DEATH: 106 TERMINAL BODY WEIGHT: 377.00 (GMS)

TISSUE / HISTOPATHOLOGIC FINDINGS << M I C R O S C O P I C T I S S U E O B S E R V A T I O N S >>  
DISTRIBUTION (SEVERITY) / SPECIAL COMMENTS

SKIN ..... A CYSTIC CAVITY FILLED WITH KERATIN AND SUPPURATIVE EXUDATE,  
-B- KERATOACANTHOMA, ANATOMIC SITE TO BE SPECIFIED COMPATIBLE WITH KERATOACANTHOMA, PRESENT ON SKIN OF THE TAIL.  
(PRESENT)

PITUITARY GLAND ..... NOT SPECIFIED (PRESENT)  
-CYST(S)

ABDOMINAL CAVITY ..... MISCELLANEOUS TISSUE  
INTRA-ABDOMINAL ADHESIONS WERE THE ONLY GROSS OR MICROSCOPIC  
FINDINGS THAT CORRESPOND TO THE INTRA-ABDOMINAL "MASS" REPORTED  
CLINICALLY.

-CHRONIC INFLAMMATION DUE TO THE PRESENCE OF TEST COMPOUND (SITE NOT SPECIFIED (PRESENT)  
SPECIFIED IN COMMENTS)

DIAPHRAGM ..... MISCELLANEOUS TISSUE  
-COMPOUND RELATED INFLAMMATORY REACTION NOT SPECIFIED (PRESENT)

Appendix J (cont.): PATHOLOGY INDIVIDUAL ANIMAL DATA

LETTERMAN ARMY INSTITUTE OF RESEARCH INDIVIDUAL ANIMAL DATA REPORT PRINTED: 21-NOV-89  
DIV OF RES SUPP, PATH SERV GP STUDY NUMBER: GLP83009 PAGE: 30  
SPECIES: RAT/FISCHER-344 STUDY START DATE: 23-JAN-84 STUDY TYPE: CHRONIC/2 YR CARCINOGENIC

ANIMAL NUMBER: 20/PRETEST- DOSE GROUP: 1 SACRIFICE STATUS: SACRIFICED MORIBUND  
DATE OF DEATH: 03-OCT-85 STUDY DAY OF DEATH: 620 STUDY WEEK OF DEATH: 89 TERMINAL BODY WEIGHT: 410.00 (GMS)

<< GROSS ORGAN OBSERVATIONS >>  
SEVERITY GROSS FREE-TEXT COMMENTS  
PERITONEAL CAV. ADHESION(S) PRESENT SEVERAL LOOPS OF SMALL INTESTINE ADHERED TO LIVER  
THYROID ENLARGED MARKED 6 X 4 X 3MM, WHITE WITH DISSEMINATED HEMORRHAGES  
LIVER ADHESION(S) PRESENT DIAPHRAGM  
PITUITARY GLAND ENLARGED MILD 3MM DIAMETER, BLACK WITH WHITE CAPSULE, SOFT

<< MICROSCOPIC TISSUE OBSERVATIONS >>  
TISSUE / HISTOPATHOLOGIC FINDINGS DISTRIBUTION (SEVERITY) / SPECIAL COMMENTS

THYROID GLANDS ..... (PRESENT)  
-B- PARA-FOLLICULAR CELL ADENOMA

HEART ..... NOT SPECIFIED(MILD)  
-CARDIOMYOPATHY

LYMPH NODES ..... REACTIVE HYPERPLASIA INVOLVES CERVICAL LYMPH NODES.  
RBC'S ARE PRESENT IN MEDIASTINAL NODES.  
-RED BLOOD CELLS, HEMOSIDERIN AND/OR ERYTHROPHAGOCYTOSIS WITHIN NOT SPECIFIED (PRESENT)  
MEDULLARY SINUSES NOT SPECIFIED (PRESENT)  
-REACTIVE HYPERPLASIA

LIVER ..... NOT SPECIFIED (PRESENT)  
-COMPOUND RELATED INFLAMMATORY REACTION NOT SPECIFIED (MODERATE)  
-BILE DUCTULE EPITHELIAL HYPERPLASIA AND/OR CHOLANGIOFIBROSIS MULTI-FOCAL(MILD)  
-HEPATITIS

KIDNEY ..... NOT SPECIFIED(MILD)  
-PROGRESSIVE RENAL DISEASE

PROSTATE ..... NOT SPECIFIED(MILD)  
-CHRONIC PROSTATITIS NOT SPECIFIED(TRACE)  
-BENIGN HYPERPLASIA NOT SPECIFIED (PRESENT)  
-MICROCALCULI, PROSTATIC URETHRA

TESTES .....



Appendix J (cont.): PATHOLOGY INDIVIDUAL ANIMAL DATA

LETTERMAN ARMY INSTITUTE OF RESEARCH  
 DIV OF RES SUPP, PATH SERV GP  
 SPECIES: RAT/FISCHER-344

INDIVIDUAL ANIMAL DATA REPORT  
 STUDY NUMBER: GLP83009  
 STUDY START DATE: 23-JAN-84

PRINTED: 21-NOV-89  
 PAGE: 31

STUDY TYPE: CHRONIC/2 YR CARCINOGENIC

ANIMAL NUMBER: 20/PRETEST-  
 DATE OF DEATH: 03-OCT-85

20 SEX: MALE  
 DOSE GROUP: 1  
 SACRIFICE STATUS: SACRIFICED MORIBUND

STUDY DAY OF DEATH: 620  
 STUDY WEEK OF DEATH: 89  
 TERMINAL BODY WEIGHT: 410.00 (GMS)

TISSUE / HISTOPATHOLOGIC FINDINGS  
 << MICROSCOPIC TISSUE OBSERVATIONS >>  
 DISTRIBUTION (SEVERITY) / SPECIAL COMMENTS

TESTES  
 -INTERSTITIAL CELL HYPERPLASIA ..... MULTI-FOCAL(MILD)

ILEUM  
 -COMPOUND RELATED INFLAMMATORY REACTION ..... NOT SPECIFIED (PRESENT)

MAMMARY GLANDS  
 -DILATATION (ECTASIA) OF DUCTS AND DUCTULES ..... NOT SPECIFIED (PRESENT)

ADRENAL  
 -FOCUS OF CELLULAR ALTERATION, VACUOLATED ..... NOT SPECIFIED(MILD)

PITUITARY GLAND  
 -B- ADENOMA ..... (PRESENT)

EYES & OPTIC N.  
 -LENTICULAR DEGENERATIVE CHANGES COMPATIBLE WITH CATARACT ..... MILD DEGENERATIVE CHANGES ARE IN THE LENS OF ONE EYE.  
 NOT SPECIFIED (PRESENT)

DIAPHRAGM  
 -COMPOUND RELATED INFLAMMATORY REACTION ..... MISCELLANEOUS TISSUE  
 NOT SPECIFIED (PRESENT)



Appendix J (cont.): PATHOLOGY INDIVIDUAL ANIMAL DATA

LETTERMAN ARMY INSTITUTE OF RESEARCH  
DIV OF RES SUPP, PATH SERV GP  
SPECIES: RAT/FISCHER-344

INDIVIDUAL ANIMAL DATA REPORT  
STUDY NUMBER: GLP83009  
STUDY START DATE: 23-JAN-84

PRINTED: 21-NOV-89  
PAGE: 33

STUDY TYPE: CHRONIC/2 YR CARCINOGENIC

ANIMAL NUMBER: 21/PRETEST-      DOSE GROUP: 1      SACRIFICE STATUS: SACRIFICED MORIBUND  
DATE OF DEATH: 30-AUG-85      STUDY DAY OF DEATH: 586      STUDY WEEK OF DEATH: 84      TERMINAL BODY WEIGHT: 354.00 (GMS)

<< M I C R O S C O P I C      T I S S U E      O B S E R V A T I O N S      >>  
TISSUE / HISTOPATHOLOGIC FINDINGS      DISTRIBUTION (SEVERITY) / SPECIAL COMMENTS

PROSTATE ..... NOT SPECIFIED(SEVERE)  
-CHRONIC PROSTATITIS ..... NOT SPECIFIED (PRESENT)  
-MICROCALCULI, PROSTATIC URETHRA

SEMINAL VESICLE ..... NOT SPECIFIED (PRESENT)  
-GENERALIZED ATROPHY

TESTES ..... (PRESENT)  
-B- INTERSTITIAL CELL ADENOMA

DUODENUM ..... RE-EXAMINATION OF FIXED TISSUE IN ATTEMPT TO DEMONSTRATE  
ADHESION OF SMALL INTESTINE WERE UNSUCCESSFUL. HOWEVER, THERE IS  
A SMALL FIBROUS ADHESION ON PERITONEAL SURFACE PRESENT IN  
SECTION #12W WHICH PROBABLY REPRESENTS THE LESION DESCRIBED  
GROSSLY.

RECTUM ..... TISSUE IS MISSING  
NOSE/TURBINATES ..... CELLULAR INFILTRATE IS ADJACENT NASO-LACRIMAL DUCT.  
-MIXED INFLAMMATORY CELL INFILTRATION, NASAL CAVITY, SINUSES,      NOT SPECIFIED(TRACE)  
TURBINATES, NASO-LACRIMAL DUCTS

PITUITARY GLAND ..... TISSUE IS MISSING

Appendix J (cont.): PATHOLOGY INDIVIDUAL ANIMAL DATA

LETTERMAN ARMY INSTITUTE OF RESEARCH  
DIV OF RES SUPP, PATH SERV GP  
SPECIES: RAT/FISCHER-344

INDIVIDUAL ANIMAL DATA REPORT  
STUDY NUMBER: GLP83009

PRINTED: 21-NOV-89  
PAGE: 34

STUDY START DATE: 23-JAN-84

STUDY TYPE: CHRONIC/2 YR CARCINOGENIC

ANIMAL NUMBER: 22/PRETEST-22 SEX: MALE DOSE GROUP: 1 SACRIFICE STATUS: FINAL SACRIFICE  
DATE OF DEATH: 29-JAN-86 STUDY DAY OF DEATH: 738 STUDY WEEK OF DEATH: 106 TERMINAL BODY WEIGHT: 334.00 (GMS)

ORGAN NAME << GROSS ORGAN OBSERVATIONS >>  
SEVERITY GROSS FREE-TEXT COMMENTS

LIVER ADMESION(S) PRESENT RIGHT VENTRAL ABDOMINAL WALL  
KIDNEY GRANULAR SURFACE PRESENT BILATERAL  
SPLEEN NODULE PRESENT .3CM DIAMETER  
TESTES ENLARGED PRESENT BILATERAL, 3 X 1.5CM  
TESTES GROWTH(S) / MASS(ES) PRESENT MULTIPLE, VARIABLY SIZED, YELLOW/BLACK  
THYMUS GENERALIZED ATROPHY PRESENT  
THYROID ENLARGED PRESENT .6CM DIAMETER, MOTTLED RED AND WHITE  
CECUM ADMESION(S) PRESENT ABDOMINAL WALL  
SM INTESTINE ADMESION(S) PRESENT SEVERAL LOOPS ADHERED TOGETHER

TISSUE / HISTOPATHOLOGIC FINDINGS << MICROSCOPIC TISSUE OBSERVATIONS >>  
DISTRIBUTION (SEVERITY) / SPECIAL COMMENTS

THYROID GLANDS ..... (PRESENT)  
-B- PARA-FOLLICULAR CELL ADENOMA

PARATHYROID ..... TISSUE IS MISSING

HEART .....  
-CARDIOMYOPATHY ..... NOT SPECIFIED(MILD)  
-MEDIAL HYPERTROPHY OF MUSCULAR ARTERIES ..... NOT SPECIFIED(TRACE)

LUNGS .....  
-MINERALIZATION OF PULMONARY ARTERIES ..... NOT SPECIFIED(TRACE)

SPLEEN .....  
-BENIGN HYPERTROPHIC NODULE ..... NOT SPECIFIED (PRESENT)

LYMPH NODES ..... MARKED REACTIVE HYPERPLASIA NOTED IN CERVICAL LYMPH NODE.  
-REACTIVE HYPERPLASIA ..... NOT SPECIFIED (PRESENT)

LIVER .....

**Appendix J (cont.): PATHOLOGY INDIVIDUAL ANIMAL DATA**

LETTERMAN ARMY INSTITUTE OF RESEARCH  
 DIV OF RES SUPP, PATH SERV GP  
 SPECIES: RAT/FISCHER-344  
 STUDY START DATE: 23-JAN-84  
 ANIMAL NUMBER: 22/PRETEST# 22 SEX: MALE DOSE GROUP: 1 SACRIFICE STATUS: FINAL SACRIFICE  
 DATE OF DEATH: 29-JAN-86 STUDY DAY OF DEATH: 738 STUDY WEEK OF DEATH: 106 TERMINAL BODY WEIGHT: 334.00 (GMS)  
 << M I C R O S C O P I C T I S S U E O B S E R V A T I O N S >>  
 TISSUE / HISTOPATHOLOGIC FINDINGS DISTRIBUTION (SEVERITY) / SPECIAL COMMENTS

PRINTED: 21-NOV-89  
 PAGE: 35  
 STUDY TYPE: CHRONIC/2 YR CARCINOGENIC

- LIVER ..... NOT SPECIFIED (PRESENT)
- COMPOUND RELATED INFLAMMATORY REACTION ..... NOT SPECIFIED(MODERATE)
- BILE DUCTULE EPITHELIAL HYPERTROPHY AND/OR CHOLANGIOFIBROSIS ..... MULTI-FOCAL(TRACE)
- HEPATITIS ..... MULTI-FOCAL(MODERATE)
- HEPATOCTYIC VACUOLIZATION ..... NOT SPECIFIED (PRESENT)
- CYSTIC DEGENERATION
- KIDNEY ..... NOT SPECIFIED(MARKED)
- PROGRESSIVE RENAL DISEASE
- PROSTATE ..... NOT SPECIFIED(MILD)
- BENIGN HYPERPLASIA
- SEMINAL VESTICLE ..... NOT SPECIFIED (PRESENT)
- GENERALIZED ATROPHY
- TESTES ..... (PRESENT)
- B- INTERSTITIAL CELL ADENOMA
- JEJUNUM ..... NOT SPECIFIED (PRESENT)
- COMPOUND RELATED INFLAMMATORY REACTION
- CECUM ..... NOT SPECIFIED (PRESENT)
- COMPOUND RELATED INFLAMMATORY REACTION
- SKIN ..... TISSUE IS MISSING
- MAMMARY GLANDS ..... TISSUE IS MISSING
- ADRENAL ..... NOT SPECIFIED(TRACE)
- FOCUS OF CELLULAR ALTERATION, VACUOLATED
- DIAPHRAGM ..... MISCELLANEOUS TISSUE

Appendix J (cont.): PATHOLOGY INDIVIDUAL ANIMAL DATA

LETTERMAN ARMY INSTITUTE OF RESEARCH  
DIV OF RES SUPP, PATH SERV GP  
SPECIES: RAT/FISCHER-344

INDIVIDUAL ANIMAL DATA REPORT  
STUDY NUMBER: GLP83009  
STUDY START DATE: 23-JAN-84

PRINTED: 21-NOV-89  
PAGE: 36

STUDY TYPE: CHRONIC/2 YR CARCINOGENIC

ANIMAL NUMBER: 22/PRETEST=

22 SEX: MALE

DOSE GROUP: 1

SACRIFICE STATUS: FINAL SACRIFICE

DATE OF DEATH: 29-JAN-86

STUDY DAY OF DEATH: 738

STUDY WEEK OF DEATH: 105

TERMINAL BODY WEIGHT: 334.00 (GMS)

TISSUE / HISTOPATHOLOGIC FINDINGS  
<< MICROSCOPIC TISSUE OBSERVATIONS >>  
DISTRIBUTION (SEVERITY) / SPECIAL COMMENTS

DIAPHRAGM ..... MISCELLANEOUS TISSUE  
-COMPOUND RELATED INFLAMMATORY REACTION NOT SPECIFIED (PRESENT)

Appendix J (cont.): **PATHOLOGY INDIVIDUAL ANIMAL DATA**

LETTERMAN ARMY INSTITUTE OF RESEARCH  
 DIV OF RES SUPP, PATH SERV GP  
 SPECIES: RAT/FISCHER-344

INDIVIDUAL ANIMAL DATA REPORT  
 STUDY NUMBER: GLP83009

PRINTED: 21-NOV-89  
 PAGE: 37

ANIMAL NUMBER: 23/PRETEST= 23 SEX: MALE DOSE GROUP: 1 SACRIFICE STATUS: FINAL SACRIFICE  
 DATE OF DEATH: 29-JAN-86 STUDY DAY OF DEATH: 736 STUDY WEEK OF DEATH: 106 TERMINAL BODY WEIGHT: 379.00 (GMS)  
 STUDY START DATE: 23-JAN-84 STUDY TYPE: CHRONIC/2 YR CARCINOGENIC

ORGAN NAME << GROSS ORGAN OBSERVATIONS >>  
 SEVERITY GROSS FREE-TEXT COMMENTS  
 SPLEEN ENLARGED (SPLENOMEGALY) MARKED 8.5 X 2.5CM  
 LIVER ADHESION(S) PRESENT STOMACH, DIAPHRAGM, VENTRAL ABDOMINAL WALL  
 LIVER DISCOLORATION PRESENT WHITE, MULTIFOCAL, LOBULAR  
 KIDNEY GRANULAR SURFACE PRESENT  
 KIDNEY DISCOLORATION PRESENT PINPOINT, WHITE  
 LUNGS HEMORRHAGE(S) PRESENT MULTIFOCAL

TISSUE / HISTOPATHOLOGIC FINDINGS << MICROSCOPIC TISSUE OBSERVATIONS >>  
 DISTRIBUTION (SEVERITY) / SPECIAL COMMENTS

PARATHYROID ..... TISSUE IS MISSING

HEART .....  
 -CARDIOMYOPATHY ..... NOT SPECIFIED(MILD)  
 -N- LARGE GRANULAR LYMPHOCYTE LEUKEMIA, METASTATIC (PRESENT)

LUNGS .....  
 -MINERALIZATION OF PULMONARY ARTERIES .....  
 -N- LARGE GRANULAR LYMPHOCYTE LEUKEMIA, METASTATIC NOT SPECIFIED(TRACE)  
 -ALVEOLAR HEMORRHAGE MULTI-FOCAL (PRESENT)

THYMUS .....  
 -N- LARGE GRANULAR LYMPHOCYTE LEUKEMIA, METASTATIC (PRESENT)

SPLEEN .....  
 -N- LARGE GRANULAR LYMPHOCYTE LEUKEMIA, METASTATIC (PRESENT)

LYMPH NODES ..... LGLL PRESENT IN CERVICAL, MEDIASTINAL, AND MESENTERIC NODES.  
 -N- LARGE GRANULAR LYMPHOCYTE LEUKEMIA, METASTATIC (PRESENT)

LIVER .....  
 -COMPOUND RELATED INFLAMMATORY REACTION ..... NOT SPECIFIED (PRESENT)

**Appendix J (cont.): PATHOLOGY INDIVIDUAL ANIMAL DATA**

LETTERMAN ARMY INSTITUTE OF RESEARCH  
 DIV OF RES SUPP, PATH SERV GP  
 SPECIES: RAT/FISCHER-344  
 STUDY START DATE: 23-JAN-84  
 STUDY NUMBER: GLP83009  
 PRINTED: 21-NOV-89  
 PAGE: 38  
 STUDY TYPE: CHRONIC/2 YR CARCINOGENIC

ANIMAL NUMBER: 23/PRETEST-  
 DATE OF DEATH: 29-JAN-86  
 SEX: MALE  
 DOSE GROUP: 1  
 SACRIFICE STATUS: FINAL SACRIFICE  
 STUDY WEEK OF DEATH: 106  
 TERMINAL BODY WEIGHT: 379.00 (GMS)

TISSUE / HISTOPATHOLOGIC FINDINGS  
 << M I C R O S C O P I C T I S S U E O B S E R V A T I O N S >>  
 DISTRIBUTION (SEVERITY) / SPECIAL COMMENTS

LIVER .....  
 -BILE DUCTULE EPITHELIAL HYPERPLASIA AND/OR CHOLANGIOFIBROSIS ..... NOT SPECIFIED(MILD)  
 -NECROSIS, PERIACINAR ..... MULTI-FOCAL(TRACE)  
 -N- LARGE GRANULAR LYMPHOCYTE LEUKEMIA, METASTATIC ..... (PRESENT)

KIDNEY .....  
 -PROGRESSIVE RENAL DISEASE ..... NOT SPECIFIED(MODERATE)  
 -N- LARGE GRANULAR LYMPHOCYTE LEUKEMIA, METASTATIC ..... (PRESENT)

PROSTATE .....  
 -CHRONIC PROSTATITIS ..... NOT SPECIFIED(TRACE)  
 -BENIGN HYPERPLASIA ..... NOT SPECIFIED(TRACE)

SEMINAL VESICLE .....  
 -GENERALIZED ATROPHY ..... NOT SPECIFIED (PRESENT)

TESTES .....  
 -B- INTERSTITIAL CELL ADENOMA ..... (PRESENT)

PANCREAS .....  
 -ACINAR (EXOCRINE) ATROPHY ..... NOT SPECIFIED(TRACE)

STOMACH .....  
 -COMPOUND RELATED INFLAMMATORY REACTION ..... NOT SPECIFIED (PRESENT)

SCIATIC NERVE .....  
 TISSUE IS MISSING

MAMMARY GLANDS .....  
 -HYPERPLASIA AND/OR HYPERTROPHY OF THE ACINAR TISSUE ..... NOT SPECIFIED(TRACE)

NOSE/TURBINATES .....  
 -MIXED INFLAMMATORY CELL INFILTRATION, NASAL CAVITY, SINUSES, ..... CELLULAR INFILTRATE IS ADJACENT TO NASO-LACRIMAL DUCT.  
 TURBINATES, NASO-LACRIMAL DUCTS ..... NOT SPECIFIED(TRACE)

BONE, STERNUM .....



Appendix J (cont.): PATHOLOGY INDIVIDUAL ANIMAL DATA

LETTERMAN ARMY INSTITUTE OF RESEARCH  
DIV OF RES SUPP, PATH SERV GP  
SPECIES: RAT/FISCHER-344

INDIVIDUAL ANIMAL DATA REPORT  
STUDY NUMBER: GLP83009  
STUDY START DATE: 23-JAN-84

PRINTED: 21-NOV-89  
PAGE: 39

STUDY TYPE: CHRONIC/2 YR CARCINOGENIC

ANIMAL NUMBER: 23/PRETEST-23 SEX: MALE DOSE GROUP: 1 SACRIFICE STATUS: FINAL SACRIFICE  
DATE OF DEATH: 29-JAN-86 STUDY DAY OF DEATH: 738 STUDY WEEK OF DEATH: 106 TERMINAL BODY WEIGHT: 379.00 (GMS)

TISSUE / HISTOPATHOLOGIC FINDINGS << MICROSCOPIC TISSUE OBSERVATIONS >>  
DISTRIBUTION (SEVERITY) / SPECIAL COMMENTS

BONE, STERNUM .....  
-M- LARGE GRANULE LYMPHOCYTE LEUKEMIA, METASTATIC (PRESENT)

BONE, FEMUR .....  
-M- LARGE GRANULE LYMPHOCYTE LEUKEMIA, METASTATIC (PRESENT)

BONE VERT .....  
-M- LARGE GRANULE LYMPHOCYTE LEUKEMIA, METASTATIC (PRESENT)

EYES & OPTIC N. ....  
-METAPLASTIC BONE FORMATION AND/OR MINERALIZATION, SCLERA NOT SPECIFIED (PRESENT)

WHOLE BODY .....  
-M- LARGE GRANULAR LYMPHOCYTIC LEUKEMIA (PRESENT)

DIAPHRAGM ..... MISCELLANEOUS TISSUE  
-COMPOUND RELATED INFLAMMATORY REACTION NOT SPECIFIED (PRESENT)

Appendix J (cont.): PATHOLOGY INDIVIDUAL ANIMAL DATA

LETTERMAN ARMY INSTITUTE OF RESEARCH  
DIV OF RES SUPP, PATH SERV GP  
SPECIES: RAT/FISCHER-344

INDIVIDUAL ANIMAL DATA REPORT  
STUDY NUMBER: GLP83009

PRINTED: 21-NOV-89  
PAGE: 40

STUDY START DATE: 23-JAN-84

STUDY TYPE: CHRONIC/2 YR CARCINOGENIC

ANIMAL NUMBER: 24/PRETEST- 24 SEX: MALE DOSE GROUP: 1 SACRIFICE STATUS: SACRIFICED MORIBUND  
DATE OF DEATH: 03-JAN-86 STUDY DAY OF DEATH: 712 STUDY WEEK OF DEATH: 102 TERMINAL BODY WEIGHT: 315.00 (GMS)

ORGAN NAME << GROSS ORGAN OBSERVATIONS >>  
SEVERITY GROSS FREE-TEXT COMMENTS

LIVER ADHESION(S) PRESENT DIAPHRAGM, VENTRAL ABDOMINAL WALL, STOMACH  
TESTES ENLARGED PRESENT LEFT, 3 X 2CM  
TESTES GROWTH(S) / MASS(ES) PRESENT MULTIPLE VARIABLY SIZED, YELLOW/BLACK  
PITUITARY GLAND DISCOLORATION PRESENT FOCAL, BLACK, .2CM DIAMETER

TISSUE / HISTOPATHOLOGIC FINDINGS << MICROSCOPIC TISSUE OBSERVATIONS >>  
DISTRIBUTION (SEVERITY) / SPECIAL COMMENTS

- BRAIN
  - PERIVASCULAR LYMPHOCYTTIC CELLULAR INFILTRATION
  - GLIOSIS
- HEART
  - CARDIOMYOPATHY
  - MEDIAL HYPERTROPHY OF MUSCULAR ARTERIES
- LUNGS
  - MINERALIZATION OF PULMONARY ARTERIES
- LIVER
  - COMPOUND RELATED INFLAMMATORY REACTION
  - BILE DUCTULE EPITHELIAL HYPERPLASIA AND/OR CHOLANGIOFIBROSIS
- KIDNEY
  - PROGRESSIVE RENAL DISEASE
- PROSTATE
  - CHRONIC PROSTATITIS
- TESTES
  - B- INTERSTITIAL CELL ADENOMA

MULTI-FOCAL(MILD)  
DIFFUSE(MILD)

NOT SPECIFIED(MILD)  
NOT SPECIFIED(TRACE)

NOT SPECIFIED(TRACE)

NOT SPECIFIED (PRESENT)  
NOT SPECIFIED(MILD)

NOT SPECIFIED(MILD)

NOT SPECIFIED(TRACE)

(PRESENT)

Appendix J (cont.): PATHOLOGY INDIVIDUAL ANIMAL DATA

LETTERMAN ARMY INSTITUTE OF RESEARCH  
DIV OF RES SUPP, PATH SERV GP  
SPECIES: RAT/FISCHER-344

INDIVIDUAL ANIMAL DATA REPORT  
STUDY NUMBER: GLP83009  
STUDY START DATE: 23-JAN-84

PRINTED: 21-NOV-89  
PAGE: 41  
STUDY TYPE: CHRONIC/2 YR CARCINOGENIC

ANIMAL NUMBER: 24/PRETEST=      DOSE GROUP: 1      SACRIFICE STATUS: SACRIFICED MORIBUND  
DATE OF DEATH: 03-JAN-86      STUDY DAY OF DEATH: 712      STUDY WEEK OF DEATH: 102      TERMINAL BODY WEIGHT: 315.00 (GMS)

<< M I C R O S C O P I C      T I S S U E      O B S E R V A T I O N S      >>  
TISSUE / HISTOPATHOLOGIC FINDINGS      DISTRIBUTION (SEVERITY) / SPECIAL COMMENTS

STOMACH      .....      THERE IS ADHESION OF STOMACH TO LIVER.  
-COMPOUND RELATED INFLAMMATORY REACTION      NOT SPECIFIED (PRESENT)

DIAPHRAGM      .....      MISCELLANEOUS TISSUE  
-COMPOUND RELATED INFLAMMATORY REACTION      NOT SPECIFIED (PRESENT)

**Appendix J (cont.): PATHOLOGY INDIVIDUAL ANIMAL DATA**

LETTERMAN ARMY INSTITUTE OF RESEARCH  
 DIV OF RES SUPP, PATH SERV GP  
 SPECIES: RAT/FISCHER-344  
 ANIMAL NUMBER: 25/PRETEST= 25 SEX: MALE DOSE GROUP: 1 SACRIFICE STATUS: FINAL SACRIFICE  
 DATE OF DEATH: 29-JAN-86 STUDY DAY OF DEATH: 738 STUDY WEEK OF DEATH: 106 TERMINAL BODY WEIGHT: 382.00 (GMS)  
 STUDY START DATE: 23-JAN-84  
 STUDY TYPE: CHRONIC/2 YR CARCINOGENIC  
 PRINTED: 21-NOV-89  
 PAGE: 42

INDIVIDUAL ANIMAL DATA REPORT  
 STUDY NUMBER: GLP83009

ORGAN NAME      <<    G R O S S    O R G A N    O B S E R V A T I O N S    >>  
 KEYWORDS / PHRASES      SEVERITY    GROSS FREE-TEXT COMMENTS

TESTES      ENLARGED      PRESENT    BILATERAL, 2.75 X 1.75CM  
 TESTES      GROWTH(S) / MASS(ES)      PRESENT    BILATERAL, MULTIPLE VARIABLY SIZED, YELLOW  
 LIVER      ADHESION(S)      PRESENT    DIAPHRAGM  
 ILEUM      ADHESION(S)      PRESENT    LIVER  
 LIVER      GROWTH(S) / MASS(ES)      PRESENT    .8CM DIAMETER, FIRM WHITE

<<    M I C R O S C O P I C    T I S S U E    O B S E R V A T I O N S    >>  
 TISSUE / HISTOPATHOLOGIC FINDINGS      DISTRIBUTION (SEVERITY) / SPECIAL COMMENTS

THYROID GLANDS  
 -PARA-FOLLICULAR CELL HYPERPLASIA ("C" CELL, LIGHT CELL)      NOT SPECIFIED(MODERATE)

PARATHYROID  
 TISSUE IS MISSING

HEART  
 -CARDIOMYOPATHY      NOT SPECIFIED(MILD)  
 -MEDIAL HYPERTROPHY OF MUSCULAR ARTERIES      NOT SPECIFIED(TRACE)

LUNGS  
 -MINERALIZATION OF PULMONARY ARTERIES      NOT SPECIFIED(TRACE)

LIVER  
 -COMPOUND RELATED INFLAMMATORY REACTION      NOT SPECIFIED (PRESENT)  
 -BILE DUCTULE EPITHELIAL HYPERPLASIA AND/OR CHOLANGIOFIBROSIS      NOT SPECIFIED(MILD)  
 -HEPATOCTYTIC VACUOLIZATION      MULTI-FOCAL(MILD)  
 -FOCUS OF CELLULAR ALTERATION - CLEAR CELLS      NOT SPECIFIED(TRACE)  
 -BENIGN HYPERPLASTIC MODULE(S)      FOCAL(MILD)  
 -FOCUS OF CELLULAR ALTERATION - EOSINOPHILIC CELLS      MULTI-FOCAL(TRACE)  
 -W- PRESENCE OF METASTATIC SARCOMA      SECONDARY NEOPLASM FROM ORGAN ABDOMINAL CAVITY

KIDNEY

**Appendix J (cont.): PATHOLOGY INDIVIDUAL ANIMAL DATA**

LETTERMAN ARMY INSTITUTE OF RESEARCH  
 DIV OF RES SUPP, PATH SERV GP  
 SPECIES: RAT/FISCHER-344  
 ANIMAL NUMBER: 25/PRETEST  
 DATE OF DEATH: 29-JAN-86  
 STUDY DAY OF DEATH: 738  
 SEX: MALE  
 DOSE GROUP: 1  
 SACRIFICE STATUS: FINAL SACRIFICE  
 STUDY WEEK OF DEATH: 106  
 TERMINAL BODY WEIGHT: 382.00 (GMS)  
 STUDY START DATE: 23-JAN-84  
 STUDY TYPE: CHRONIC/2 YR CARCINOGENIC  
 << M I C R O S C O P I C T I S S U E O B S E R V A T I O N S >>  
 TISSUE / HISTOPATHOLOGIC FINDINGS  
 DISTRIBUTION (SEVERITY) / SPECIAL COMMENTS

PRINTED: 21-NOV-89  
 PAGE: 43

KIDNEY ..... NOT SPECIFIED(MODERATE)  
 -PROGRESSIVE RENAL DISEASE  
 PROSTATE ..... NOT SPECIFIED(MILD)  
 -CHRONIC PROSTATITIS  
 -BENIGN HYPERPLASIA  
 SEMINAL VESICLE ..... NOT SPECIFIED (PRESENT)  
 -GENERALIZED ATROPHY  
 TESTES ..... (PRESENT)  
 -B- INTERSTITIAL CELL ADENOMA  
 ILEUM ..... NOT SPECIFIED (PRESENT)  
 -COMPOUND RELATED INFLAMMATORY REACTION  
 STOMACH ..... NOT SPECIFIED (PRESENT)  
 -MUCOSAL AND/OR SUBMUCOSAL EDEMA  
 MAMMARY GLANDS ..... NOT SPECIFIED(TRACE)  
 -HYPERPLASIA AND/OR HYPERTROPHY OF THE ACINAR TISSUE  
 NOSE/TURBINATES ..... THE CELLULAR INFILTRATE IS ADJACENT THE NASO-LACRIMAL DUCT.  
 -MIXED INFLAMMATORY CELL INFILTRATION, NASAL CAVITY, SINUSES,  
 TURBINATES, NASO-LACRIMAL DUCTS  
 EYES & OPTIC N. .... NOT SPECIFIED (PRESENT)  
 -METAPLASTIC BONE FORMATION AND/OR MINERALIZATION, SCLERA  
 ABDOMINAL CAVITY ..... MISCELLANEOUS TISSUE

Appendix J (cont.): PATHOLOGY INDIVIDUAL ANIMAL DATA

LETTERMAN ARMY INSTITUTE OF RESEARCH  
DIV OF RES SUPP, PATH SERV GP  
SPECIES: RAT/FISCHER-344

INDIVIDUAL ANIMAL DATA REPORT  
STUDY NUMBER: GLP63009  
STUDY START DATE: 23-JAN-84

PRINTED: 21-NOV-89  
PAGE: 44  
STUDY TYPE: CHRONIC/2 YR CARCINOGENIC

ANIMAL NUMBER: 25/PRETEST  
DATE OF DEATH: 29-JAN-86

25 SEX: MALE  
STUDY DAY OF DEATH: 738

DOSE GROUP: 1  
SACRIFICE STATUS: FINAL SACRIFICE

STUDY WEEK OF DEATH: 106  
TERMINAL BODY WEIGHT: 382.00 (GMS)

<< MICROSCOPIC TISSUE OBSERVATIONS >>  
DISTRIBUTION (SEVERITY) / SPECIAL COMMENTS

ABDOMINAL CAVITY ..... THE SARCOMA IS A SMALL LESION LIMITED TO THE LIVER. IT IS VERY  
POORLY DIFFERENTIATED AND ANAPLASTIC WITH NUMEROUS LARGE  
MULTINUCLEATED TUMOR GIANT CELLS.  
(PRESENT)

-M- SARCOMA, CELLULAR DIFFERENTIATION UNSPECIFIED

DIAPHRAGM ..... MISCELLANEOUS TISSUE  
-COMPOUND RELATED INFLAMMATORY REACTION NOT SPECIFIED (PRESENT)

Appendix J (cont.): PATHOLOGY INDIVIDUAL ANIMAL DATA

LETTERMAN ARMY INSTITUTE OF RESEARCH  
 DIV OF RES SUPP, PATH SERV GP  
 SPECIES: RAT/FISCHER-344  
 STUDY START DATE: 23-JAN-84  
 STUDY NUMBER: GLP83009  
 PRINTED: 21-NOV-89  
 PAGE: 45

ANIMAL NUMBER: 26/PREST-26 SEX: MALE DOSE GROUP: 1 SACRIFICE STATUS: FOUND DEAD  
 DATE OF DEATH: 24-OCT-85 STUDY DAY OF DEATH: 641 STUDY WEEK OF DEATH: 92 TERMINAL BODY WEIGHT: 409.00 (GMS)  
 STUDY TYPE: CHRONIC/2 YR CARCINOGENIC

ORGAN NAME << GROSS ORGAN OBSERVATIONS >>  
 SEVERITY GROSS FREE-TEXT COMMENTS  
 LIVER PRESENT ADHESION(S) PRESENT DIAPHRAGM, VENTRAL ABDOMINAL WALL, INTESTINES  
 TESTES PRESENT GROWTH(S) / MASS(ES) PRESENT DIFFUSE, VARIABLY SIZED, IRREGULAR, BLACK/RED/WHITE  
 TESTES ENLARGED PRESENT 4 X 2 X 1CM, GELATINOUS  
 SEMINAL VESICLE ATROPHY / SMALL PRESENT FLACID, GRAY  
 LUNGS CONGESTED / RED MARKED  
 TRACHEA FOOD STUFF PRESENT MILD

TISSUE / HISTOPATHOLOGIC FINDINGS << MICROSCOPIC TISSUE OBSERVATIONS >>  
 DISTRIBUTION (SEVERITY) / SPECIAL COMMENTS

TRACHEA ..... TISSUE IS AUTOLYTIC  
 THYROID GLANDS ..... TISSUE IS AUTOLYTIC  
 PARATHYROID ..... TISSUE IS MISSING  
 HEART ..... NOT SPECIFIED(MILD)  
 -CARDIOMYOPATHY .....  
 LUNGS ..... NOT SPECIFIED(TRACE)  
 -MINERALIZATION OF PULMONARY ARTERIES .....  
 THYMUS ..... TISSUE IS MISSING  
 LIVER ..... NOT SPECIFIED (PRESENT)  
 -COMPOUND RELATED INFLAMMATORY REACTION .....  
 -BILE DUCTULE EPITHELIAL HYPERPLASIA AND/OR CHOLANGIOFIBROSIS .....  
 KIDNEY ..... NOT SPECIFIED(MILD)  
 -PROGRESSIVE RENAL DISEASE .....  
 PROSTATE ..... NOT SPECIFIED(MILD)

Appendix J (cont.): PATHOLOGY INDIVIDUAL ANIMAL DATA

LETTERMAN ARMY INSTITUTE OF RESEARCH  
 DIV OF RES SUPP, PATH SERV GP  
 SPECIES: RAT/FISCHER-344  
 STUDY START DATE: 23-JAN-84  
 STUDY NUMBER: GLP83009  
 PRINTED: 21-NOV-89  
 PAGE: 46  
 STUDY TYPE: CHRONIC/2 YR CARCINOGENIC

ANIMAL NUMBER: 26/PRETEST= 26 SEX: MALE DOSE GROUP: 1 SACRIFICE STATUS: FOUND DEAD  
 DATE OF DEATH: 24-OCT-85 STUDY DAY OF DEATH: 641 STUDY WEEK OF DEATH: 92 TERMINAL BODY WEIGHT: 409.00 (GMS)

TISSUE / HISTOPATHOLOGIC FINDINGS << MICROSCOPIC TISSUE OBSERVATIONS >>  
 DISTRIBUTION (SEVERITY) / SPECIAL COMMENTS

PROSTATE ..... NOT SPECIFIED (MILD)  
 -CHRONIC PROSTATITIS ..... NOT SPECIFIED (TRACE)  
 -BENIGN HYPERPLASIA

SEMINAL VESICLE ..... NOT SPECIFIED (PRESENT)  
 -GENERALIZED ATROPHY

TESTES ..... (PRESENT)  
 -B- INTERSTITIAL CELL ADENOMA

DUODENUM ..... TISSUE IS AUTOLYTIC

JEJUNUM ..... COMPOUND RELATED INFLAMMATORY REACTION AND ADHESION TO BODY WALL.  
 -COMPOUND RELATED INFLAMMATORY REACTION ..... NOT SPECIFIED (PRESENT)

ILEUM ..... TISSUE IS AUTOLYTIC

CECUM ..... TISSUE IS AUTOLYTIC

RECTUM ..... TISSUE IS AUTOLYTIC

COLON ..... TISSUE IS AUTOLYTIC

MAMMARY GLANDS ..... NOT SPECIFIED (MODERATE)  
 -HYPERPLASIA AND/OR HYPERTROPHY OF THE ACIMAR TISSUE ..... NOT SPECIFIED (PRESENT)  
 -DILATATION (ECTASIA) OF DUCTS AND DUCTULES

PITUITARY GLAND ..... (PRESENT)  
 -B- ADENOMA



Appendix J (cont.): PATHOLOGY INDIVIDUAL ANIMAL DATA

LETTERMAN ARMY INSTITUTE OF RESEARCH  
DIV OF RES SUPP, PATH SERV GP  
SPECIES: RAT/FISCHER-344

INDIVIDUAL ANIMAL DATA REPORT  
STUDY NUMBER: GLP83009  
STUDY START DATE: 23-JAN-84

PRINTED: 21-NOV-89  
PAGE: 47

STUDY TYPE: CHRONIC/2 YR CARCINOGENIC

ANIMAL NUMBER: 26/PRETEST-26 SEX: MALE DOSE GROUP: 1 SACRIFICE STATUS: FOUND DEAD  
DATE OF DEATH: 24-OCT-85 STUDY DAY OF DEATH: 641 STUDY WEEK OF DEATH: 92 TERMINAL BODY WEIGHT: 409.00 (GMS)

<< MICROSCOPIC TISSUE OBSERVATIONS >>  
TISSUE / HISTOPATHOLOGIC FINDINGS  
DISTRIBUTION (SEVERITY) / SPECIAL COMMENTS

EYES & OPTIC N. .... TISSUE IS AUTOLYTIC

DIAPHRAGM ..... MISCELLANEOUS TISSUE NOT SPECIFIED (PRESENT)  
-COMPOUND RELATED INFLAMMATORY REACTION

Appendix J (cont.): PATHOLOGY INDIVIDUAL ANIMAL DATA

LETTERMAN ARMY INSTITUTE OF RESEARCH  
DIV OF RES SUPP, PATH SERV GP  
SPECIES: RAT/FISCHER-344

INDIVIDUAL ANIMAL DATA REPORT  
STUDY NUMBER: GLP83009  
STUDY START DATE: 23-JAN-84

PRINTED: 21-NOV-89  
PAGE: 48

STUDY TYPE: CHRONIC/2 YR CARCINOGENIC

ANIMAL NUMBER: 27/PRETEST-27 SEX: MALE DOSE GROUP: 1 SACRIFICE STATUS: SACRIFICED MORIBUND  
DATE OF DEATH: 28-AUG-85 STUDY DAY OF DEATH: 584 STUDY WEEK OF DEATH: 84 TERMINAL BODY WEIGHT: 426.00 (GMS)

ORGAN NAME << GROSS ORGAN OBSERVATIONS >> SEVERITY GROSS FREE-TEXT COMMENTS

SKIN SUBCUTANEOUS MASS PRESENT LEFT AXILLARY REGION, FIRM, WHITE, 6 X 5 X 4CM  
TESTES GROWTH(S) / MASS(ES) PRESENT BILATERAL

TESTES ATROPHIC / SMALL, UNILATERALLY MODERATE RIGHT, 1 X .5CM  
TESTES ENLARGED TRACE LEFT, 2 X 1CM  
LIVER ADHESION(S) PRESENT DIAPHRAGM, VENTRAL ABDOMINAL WALL  
CECUM ADHERED TO PERITONEAL WALL PRESENT

TISSUE / HISTOPATHOLOGIC FINDINGS << MICROSCOPIC TISSUE OBSERVATIONS >> DISTRIBUTION (SEVERITY) / SPECIAL COMMENTS

HEART ..... NOT SPECIFIED(MILD)  
-CARDIOMYOPATHY ..... NOT SPECIFIED(TRACE)  
-MEDIAL HYPERTROPHY OF MUSCULAR ARTERIES .....  
LUNGS ..... NOT SPECIFIED(MILD)  
-PERIBRONCHIAL LYMPHOID HYPERPLASIA ..... RBC'S LIMITED TO MEDIASTINAL NODE.  
LYMPH NODES ..... NOT SPECIFIED (PRESENT)  
-RED BLOOD CELLS, HEMOSIDERIN AND/OR ERYTHROPHAGOCYTOSIS WITHIN ..... NOT SPECIFIED (PRESENT)  
MEDULLARY SINUSES .....  
LIVER ..... NOT SPECIFIED (PRESENT)  
-COMPOUND RELATED INFLAMMATORY REACTION ..... NOT SPECIFIED(MILD)  
-BILE DUCTULE EPITHELIAL HYPERPLASIA AND/OR CHOLANGIOFIBROSIS .....  
KIDNEY ..... NOT SPECIFIED(MILD)  
-PROGRESSIVE RENAL DISEASE .....  
PROSTATE ..... NOT SPECIFIED(TRACE)  
-BENIGN HYPERPLASIA .....  
TESTES ..... NOT SPECIFIED(TRACE)

**Appendix J (cont.): PATHOLOGY INDIVIDUAL ANIMAL DATA**

LETTERMAN ARMY INSTITUTE OF RESEARCH  
 DIV OF RES SUPP, PATH SERV GP  
 SPECIES: RAT/FISCHER-344  
 STUDY START DATE: 23-JAN-84  
 INDIVIDUAL ANIMAL DATA REPORT  
 STUDY NUMBER: GLP83009  
 PRINTED: 21-NOV-89  
 PAGE: 49  
 STUDY TYPE: CHRONIC/2 YR CARCINOGENIC

ANIMAL NUMBER: 27/PRETEST\* DOSE GROUP: 1 SACRIFICE STATUS: SACRIFICED MORIBUND  
 DATE OF DEATH: 28-AUG-85 STUDY DAY OF DEATH: 584 STUDY WEEK OF DEATH: 84 TERMINAL BODY WEIGHT: 426.00 (GMS)

<< MICROSCOPIC TISSUE OBSERVATIONS >>  
 TISSUE / HISTOPATHOLOGIC FINDINGS  
 DISTRIBUTION (SEVERITY) / SPECIAL COMMENTS

TESTES ..... (PRESENT)  
 -B- INTERSTITIAL CELL ADENOMA

SECUM ..... COMPOUND RELATED INFLAMMATORY REACTION AND ADHESION TO BODY WALL.  
 -CONFOUND RELATED INFLAMMATORY REACTION NOT SPECIFIED (PRESENT)

SKIN ..... THE MASS IN THE LEFT AXILLARY REGION IS A SUBCUTANEOUS FIBROMA.  
 -B- FIBROMA (PRESENT)

NOSE/TURBINATES ..... CELLULAR INFILTRATE INVOLVES NASO-LACRIMAL DUCT.  
 -MIXED INFLAMMATORY CELL INFILTRATION, NASAL CAVITY, SINUSES, NOT SPECIFIED(KILO)  
 TURBINATES, NASO-LACRIMAL DUCTS

EYES & OPTIC N. .... NOT SPECIFIED (PRESENT)  
 -METAPLASTIC BONE FORMATION AND/OR MINERALIZATION, SCLERA

DIAPHRAGM ..... MISCELLANEOUS TISSUE  
 -COMPOUND RELATED INFLAMMATORY REACTION NOT SPECIFIED (PRESENT)

**Appendix J (cont.): PATHOLOGY INDIVIDUAL ANIMAL DATA**

LETTERMAN ARMY INSTITUTE OF RESEARCH  
 DIV OF RES SUPP, PATH SERV GP  
 SPECIES: RAT/FISCHER-344  
 INDIVIDUAL ANIMAL DATA REPORT  
 STUDY NUMBER: GLP83009  
 STUDY START DATE: 23-JAN-84  
 PRINTED: 21-NOV-89  
 PAGE: 50  
 STUDY TYPE: CHRONIC/2 YR CARCINOGENIC

ANIMAL NUMBER: 28/PRETEST  
 DATE OF DEATH: 29-JAN-86  
 DOSE GROUP: 1  
 SEX: MALE  
 STUDY DAY OF DEATH: 738  
 STUDY WEEK OF DEATH: 106  
 SACRIFICE STATUS: FINAL SACRIFICE  
 TERMINAL BODY WEIGHT: 377.00 (GMS)

ORGAN NAME: << GROSS ORGAN OBSERVATIONS >>  
 KEYWORDS / PHRASES: SEVERITY GROSS FREE-TEXT COMMENTS  
 LIVER: ADMETION(S) PRESENT STOMACH, DIAPHRAGM, VENTRAL ABDOMINAL WALL  
 TESTES: DISCOLORATION PRESENT LEFT, RED  
 TESTES: GROWTH(S) / MASSES PRESENT MULTIPLE, VARIABLY SIZED, YELLOW

TISSUE / HISTOPATHOLOGIC FINDINGS: << MICROSCOPIC TISSUE OBSERVATIONS >>  
 DISTRIBUTION (SEVERITY) / SPECIAL COMMENTS

- LACRIMAL GLAND ..... NOT SPECIFIED (TRACE)
- INFLAMMATION, SUBACUTE TO CHRONIC
- HEART ..... NOT SPECIFIED (MILD)
- CARDIOMYOPATHY
- LYMPH NODES ..... RBC'S AND PIGMENT PRESENT IN MEDIASTINAL NODES. RBC'S ONLY  
 PRESENT IN MESENTERIC NODE.  
 NOT SPECIFIED (PRESENT)
- RED BLOOD CELLS, MEMOSIDERIN AND/OR ERYTHROPHAGOCYTOSIS WITHIN  
 MEDULLARY SINUSES
- LIVER ..... NOT SPECIFIED (PRESENT)  
 -COMPOUND RELATED INFLAMMATORY REACTION  
 -BILE DUCTULE EPITHELIAL HYPERPLASIA AND/OR CHOLANGIOFIBROSIS  
 -HEPATITIS MULTI-FOCAL (TRACE)  
 -HEPATOCTYIC VACUOLIZATION MULTI-FOCAL (TRACE)  
 -CYSTIC DEGENERATION NOT SPECIFIED (PRESENT)  
 -BENIGN HYPERPLASTIC MODULE(S) NOT SPECIFIED (TRACE)
- KIDNEY ..... NOT SPECIFIED (MILD)  
 -PROGRESSIVE RENAL DISEASE
- PROSTATE ..... NOT SPECIFIED (TRACE)  
 -CHRONIC PROSTATITIS  
 -BENIGN HYPERPLASIA
- SEMINAL VESICLE .....

**Appendix J (cont.): PATHOLOGY INDIVIDUAL ANIMAL DATA**

LETTERMAN ARMY INSTITUTE OF RESEARCH  
 DIV OF RES SUPP, PATH SERV GP  
 SPECIES: RAT/FISCHER-344  
 STUDY START DATE: 23-JAN-84  
 STUDY NUMBER: GLP3009  
 PRINTED: 21-NOV-89  
 PAGE: 51  
 STUDY TYPE: CHRONIC/2 YR CARCINOGENIC

ANIMAL NUMBER: 26/PRETEST= 26 SEX: MALE DOSE GROUP: 1 SACRIFICE STATUS: FINAL SACRIFICE  
 DATE OF DEATH: 29-JAN-86 STUDY DAY OF DEATH: 738 STUDY WEEK OF DEATH: 106 TERMINAL BODY WEIGHT: 377.00 (GMS)

<< MICROSCOPIC TISSUE OBSERVATIONS >>  
 TISSUE / HISTOPATHOLOGIC FINDINGS: DISTRIBUTION (SEVERITY) / SPECIAL COMMENTS

SEMINAL VESICLE ..... NOT SPECIFIED (PRESENT)  
 -GENERALIZED ATROPHY

TESTES ..... (PRESENT)  
 -B- INTERSTITIAL CELL ADENOMA

PANCREAS ..... FOCAL(MILD)  
 -ACINAR (EXOCRINE) ATROPHY (PRESENT)  
 -B- ISLET CELL ADENOMA

STOMACH ..... NOT SPECIFIED (PRESENT)  
 -SEROSAL FIBROSIS NOT SPECIFIED (PRESENT)  
 -MUCOSAL AND/OR SUBMUCOSAL EDEMA

MAMMARY GLANDS ..... NOT SPECIFIED (TRACE)  
 -HYPERPLASIA AND/OR HYPERTROPHY OF THE ACINAR TISSUE

NOSE/TURBINATES ..... CELLULAR INFILTRATE IS ADJACENT TO THE NASO-LACRIMAL DUCT.  
 -MIXED INFLAMMATORY CELL INFILTRATION, NASAL CAVITY, SINUSES, NOT SPECIFIED (TRACE)  
 TURBINATES, NASO-LACRIMAL DUCTS

EYES & OPTIC N. .... NOT SPECIFIED (PRESENT)  
 -METAPLASTIC BONE FORMATION AND/OR MINERALIZATION, SCLERA

DIAPHRAGM ..... MISCELLANEOUS TISSUE  
 -COMPOUND RELATED INFLAMMATORY REACTION NOT SPECIFIED (PRESENT)

**Appendix J (cont.): PATHOLOGY INDIVIDUAL ANIMAL DATA**

LETTERMAN ARMY INSTITUTE OF RESEARCH  
 DIV OF RES SUPP, PATH SERV GP  
 SPECIES: RAT/FISCHER-344

INDIVIDUAL ANIMAL DATA REPORT  
 STUDY NUMBER: GLP83009

PRINTED: 21-NOV-89  
 PAGE: 52

STUDY START DATE: 23-JAN-84

STUDY TYPE: CHRONIC/2 YR CARCINOGENIC

ANIMAL NUMBER: 29/PRETEST#  
 DATE OF DEATH: 14-JAN-86  
 SEX: MALE  
 DOSE GROUP: 1  
 SACRIFICE STATUS: FOUND DEAD  
 STUDY DAY OF DEATH: 723  
 STUDY WEEK OF DEATH: 104  
 TERMINAL BODY WEIGHT: 433.00 (GMS)

ORGAN NAME SEVERITY GROSS FREE-TEXT COMMENTS

SPLEEN ENLARGED (SPLENOmegaly) MILD 4.5CM LONG  
 LIVER ADMESION(S) PRESENT DIAPHRAGH, VENTRAL ABDOMINAL WALL  
 LIVER GRANULAR SURFACE PRESENT  
 LIVER ENLARGED PRESENT  
 KIDNEY DISCOLORATION PRESENT GREEN/BROWN  
 KIDNEY GRANULAR SURFACE PRESENT PITTED SURFACE  
 TESTES ATROPHIC / SMALL, UNILATERALLY PRESENT RIGHT, 1 X .5CM  
 TESTES ENLARGED PRESENT LEFT, 2.5 X 1.5CM  
 LUNGS DISCOLORATION PRESENT MOTTLED WHITE AND RED  
 MOTTLED RED AND BLACK

ORGAN OBSERVATIONS  
 SEVERITY GROSS FREE-TEXT COMMENTS

PARATHYROID TISSUE OBSERVATIONS  
 TISSUE IS MISSING

HEART NOT SPECIFIED(MILD)  
 -CARDIOMYOPATHY NOT SPECIFIED(TRACE)  
 -MEDIAL HYPERTROPHY OF MUSCULAR ARTERIES

LUNGS DIFFUSE(MILD)  
 -PULMONARY EDEMA DIFFUSE (PRESENT)  
 -VASCULAR CONGESTION DIFFUSE (PRESENT)  
 -ALVEOLAR HEMORRHAGE

SPLEEN (PRESENT)  
 -W- LARGE GRANULAR LYMPHOCYTE LEUKEMIA, METASTATIC

LYMPH NODES (PRESENT)  
 -W- LARGE GRANULAR LYMPHOCYTE LEUKEMIA, METASTATIC  
 THERE ARE MANY NEOPLASTIC LYMPHOCYTES IN MEDULLARY SINUSES OF THE MESENTERIC NODE BUT THE NODAL ARCHITECTURE HAS NOT BEEN ALTERED. MILD REACTIVE HYPERPLASTIC CHANGES ARE ALSO PRESENT.

-W- LARGE GRANULAR LYMPHOCYTE LEUKEMIA, METASTATIC (PRESENT)

(PRESENT)

DISTRIBUTION (SEVERITY) / SPECIAL COMMENTS

**Appendix J (cont.): PATHOLOGY INDIVIDUAL ANIMAL DATA**

LETTERMAN ARMY INSTITUTE OF RESEARCH  
 DIV OF RES SUPP, PATH SERV GP  
 SPECIES: RAT/FISCHER-344  
 STUDY START DATE: 23-JAN-84  
 ANIMAL NUMBER: 29/PRETEST-29 SEX: MALE DOSE GROUP: 1 SACRIFICE STATUS: FOUND DEAD  
 DATE OF DEATH: 14-JAN-86 STUDY DAY OF DEATH: 723 STUDY WEEK OF DEATH: 104 TERMINAL BODY WEIGHT: 433.00 (GMS)  
 TISSUE / HISTOPATHOLOGIC FINDINGS << MICROSCOPIC TISSUE OBSERVATIONS >>  
 DISTRIBUTION (SEVERITY) / SPECIAL COMMENTS

PRINTED: 21-NOV-89  
 PAGE: 53

STUDY TYPE: CHRONIC/2 YR CARCINOGENIC

Lymph nodes ..... NOT SPECIFIED (PRESENT)  
 -REACTIVE HYPERPLASIA

Liver .....  
 -COMPOUND RELATED INFLAMMATORY REACTION ..... NOT SPECIFIED (PRESENT)  
 -BILE DUCTULE EPITHELIAL HYPERPLASIA AND/OR CHOLANGIOFIBROSIS ..... NOT SPECIFIED(MILD)  
 -FOCUS OF CELLULAR ALTERATION - BASOPHILIC MULTI-FOCAL(TRACE)  
 -HEPATOCYTTIC VACUOLIZATION MULTI-FOCAL(MODERATE)

Kidney ..... NOT SPECIFIED(MARKED)  
 -PROGRESSIVE RENAL DISEASE

Prostate ..... NOT SPECIFIED(TRACE)  
 -BENIGN HYPERPLASIA

Seminal vesicle ..... NOT SPECIFIED (PRESENT)  
 -GENERALIZED ATROPHY

Testes ..... (PRESENT)  
 -B- INTERSTITIAL CELL ADENOMA

Pancreas ..... NOT SPECIFIED(TRACE)  
 -CHRONIC INFLAMMATION

Mammary glands ..... NOT SPECIFIED(TRACE)  
 -HYPERPLASIA AND/OR HYPERTROPHY OF THE ACINAR TISSUE

Adrenal ..... NOT SPECIFIED (PRESENT)  
 -CORTICAL NODULAR HYPERPLASIA

Eyes & optic n. .... NOT SPECIFIED (PRESENT)  
 -METAPLASTIC BONE FORMATION AND/OR MINERALIZATION, SCLERA

Appendix J (cont.): PATHOLOGY INDIVIDUAL ANIMAL DATA

LETTERMAN ARMY INSTITUTE OF RESEARCH  
DIV OF RES SUPP, PATH SERV GP  
SPECIES: RAT/FISCHER-344

INDIVIDUAL ANIMAL DATA REPORT  
STUDY NUMBER: GLP83009

PRINTED: 21-NOV-89  
PAGE: 54

STUDY START DATE: 23-JAN-84

STUDY TYPE: CHRONIC/2 YR CARCINOGENIC

ANIMAL NUMBER: 29/PRETEST-      DOSE GROUP: 1      SACRIFICE STATUS: FOUND DEAD  
DATE OF DEATH: 14-JAN-86      STUDY DAY OF DEATH: 723      STUDY WEEK OF DEATH: 104      TERMINAL BODY WEIGHT: 433.00 (GMS)

TISSUE / HISTOPATHOLOGIC FINDINGS      <<      M I C R O S C O P I C      T I S S U E      O B S E R V A T I O N S      >>  
.....      DISTRIBUTION (SEVERITY) / SPECIAL COMMENTS      .....

WHOLE BODY ..... THIS ANIMAL HAS AN EARLY CASE OF LARGE GRANULE LYMPHOCYTE  
LEUKEMIA. ALTHOUGH SMALL NUMBERS OF NEOPLASTIC LYMPHOCYTES ARE  
PRESENT IN VASCULAR SPACES OF MANY ORGANS, THE PRIMARY ORGANE  
INVOLVED, IN THIS CASE, IS THE SPLEEN. THE LESION WAS NOT CODED  
FOR OTHER ORGANS WHICH HAD MINIMAL MORPHOLOGIC ALTERATION.  
(PRESENT)

-M- LARGE GRANULAR LYMPHOCYTTIC LEUKEMIA

DIAPHRAGM ..... MISCELLANEOUS TISSUE NOT SPECIFIED (PRESENT)  
-COMPOUND RELATED INFLAMMATORY REACTION



**Appendix J (cont.): PATHOLOGY INDIVIDUAL ANIMAL DATA**

LETTERMAN ARMY INSTITUTE OF RESEARCH  
 DIV OF RES SUPP, PATH SERV GP  
 SPECIES: RAY/FISCHER-344  
 INDIVIDUAL ANIMAL DATA REPORT  
 STUDY NUMBER: GLP83009  
 STUDY START DATE: 23-JAN-84  
 PRINTED: 21-NOV-89  
 PAGE: 55

ANIMAL NUMBER: 30/PRETEST  
 DATE OF DEATH: 30-JUL-85  
 STUDY DAY OF DEATH: 555  
 SEX: MALE  
 DOSE GROUP: 1  
 SACRIFICE STATUS: FOUND DEAD  
 STUDY WEEK OF DEATH: 80  
 TERMINAL BODY WEIGHT: 271.00 (GMS)  
 STUDY TYPE: CHRONIC/2 YR CARCINOGENIC

ORGAN NAME	SEVERITY	GROSS OBSERVATIONS	GROSS FREE-TEXT COMMENTS
TESTES	PRESENT	RIGHT, SOFT, 1.5 X .8CM	
TESTES	PRESENT	SUBCAPSULAR, INFERIOR POLE, WHITE, .5CM DIAMETER	
LIVER	PRESENT	VENTRAL ABDOMINAL WALL	
PERITONEAL CAV.	PRESENT	SMALL INTESITINE TO EACH OTHER AND LIVER AT RANDOM SITES	
PITUITARY GLAND	MARKED	RED BLACK, 7MM DIAMETER	

TISSUE / HISTOPATHOLOGIC FINDINGS  
 << MICROSCOPIC TISSUE OBSERVATIONS >>  
 DISTRIBUTION (SEVERITY) / SPECIAL COMMENTS

BRAIN  
 -HYDROCEPHALUS  
 NOT SPECIFIED (PRESENT)

TRACHEA  
 -SUPPURATIVE TRACHEITIS  
 SUPPURATIVE TRACHEITIS IS LIMITED TO THE ANTERIOR ASPECT NEAR THE LARYNX.  
 NOT SPECIFIED(MODERATE)

SALIVARY GLAND  
 -INFLAMMATION, SUBACUTE  
 DIFFUSE(MODERATE)

HEART  
 -CARDIOMYOPATHY  
 NOT SPECIFIED(TRACE)

LUNGS  
 -MINERALIZATION OF PULMONARY ARTERIES  
 NOT SPECIFIED(TRACE)

LYMPH NODES  
 -RED BLOOD CELLS, HEMOSIDERIN AND/OR ERYTHROPHAGOCYTOSIS WITHIN MEDULLARY SINUSES  
 -REACTIVE HYPERPLASIA  
 RBC'S ARE PRESENT IN THE MEDIASTINAL NODES NEAR THYMUS.  
 CERVICAL NODES NEAR SALIVARY GLANDS HAVE REACTIVE HYPERPLASIA.  
 NOT SPECIFIED (PRESENT)

LIVER  
 -COMPOUND RELATED INFLAMMATORY REACTION  
 NOT SPECIFIED (PRESENT)

Appendix J (cont.): PATHOLOGY INDIVIDUAL ANIMAL DATA

LETTERMAN ARMY INSTITUTE OF RESEARCH  
DIV OF RES SUPP, PATH SERV GP  
SPECIES: RAT/FISCHER-344

INDIVIDUAL ANIMAL DATA REPORT  
STUDY NUMBER: GLP03009  
STUDY START DATE: 23-JAN-84

PRINTED: 21-NOV-89  
PAGE: 56

STUDY TYPE: CHRONIC/2 YR CARCINOGENIC

ANIMAL NUMBER: 30/PRETEST-30 SEX: MALE DOSE GROUP: 1 SACRIFICE STATUS: FOUND DEAD  
DATE OF DEATH: 30-JUL-85 STUDY DAY OF DEATH: 555 STUDY WEEK OF DEATH: 80 TERMINAL BODY WEIGHT: 271.00 (GMS)

TISSUE / HISTOPATHOLOGIC FINDINGS << MICROSCOPIC TISSUE OBSERVATIONS >>  
DISTRIBUTION (SEVERITY) / SPECIAL COMMENTS

LIVER .....  
-BILE DUCTULE EPITHELIAL HYPERPLASIA AND/OR CHOLANGIOFIBROSIS ..... NOT SPECIFIED(MILD)  
-HEPATITIS ..... MULTI-FOCAL(TRACE)  
-HEPATOCTYIC VACUOLIZATION ..... MULTI-FOCAL(MILD)

KIDNEY ..... NOT SPECIFIED(TRACE)  
-PROGRESSIVE RENAL DISEASE .....

PROSTATE .....  
-CHRONIC PROSTATITIS ..... NOT SPECIFIED(MILD)  
-BENIGN HYPERPLASIA ..... NOT SPECIFIED(TRACE)

SEMINAL VESICLE ..... NOT SPECIFIED (PRESENT)  
-GENERALIZED ATROPHY .....

TESTES ..... NOT SPECIFIED(MARKED)  
-TUBULAR ATROPHY .....

DUODENUM ..... NOT SPECIFIED (PRESENT)  
-COMPOUND RELATED INFLAMMATORY REACTION .....

JEJUNUM ..... NOT SPECIFIED (PRESENT)  
-COMPOUND RELATED INFLAMMATORY REACTION .....

CECUM ..... TISSUE IS MISSING  
..... TISSUE IS MISSING

RECTUM ..... TISSUE IS MISSING  
..... TISSUE IS MISSING

SKIN ..... NOT SPECIFIED (PRESENT)  
-INFLAMMATION, NOT OTHERWISE SPECIFIED, PREPUTIAL GLAND .....

MAMMARY GLANDS .....

Appendix J (cont.): PATHOLOGY INDIVIDUAL ANIMAL DATA

LETTERMAN ARMY INSTITUTE OF RESEARCH  
 DIV OF RES SUPP, PATH SERV GP  
 SPECIES: RAY/FISCHER-344  
 STUDY START DATE: 23-JAN-84  
 STUDY NUMBER: GLP83009  
 PRINTED: 21-NOV-89  
 PAGE: 57

ANIMAL NUMBER: 30/PRETEST-  
 DATE OF DEATH: 30-JUL-85  
 STUDY DAY OF DEATH: 555  
 SEX: MALE  
 DOSE GROUP: 1  
 SACRIFICE STATUS: FOUND DEAD  
 STUDY WEEK OF DEATH: 80  
 TERMINAL BODY WEIGHT: 271.00 (GMS)

STUDY TYPE: CHRONIC/2 YR CARCINOGENIC

<< MICROSCOPIC TISSUE OBSERVATIONS >>  
 DISTRIBUTION (SEVERITY) / SPECIAL COMMENTS

MAMMARY GLANDS ..... NOT SPECIFIED (PRESENT)  
 -DILATATION (ECTASIA) OF DUCTS AND DUCTULES .....  
 NOSE/TURBINATES ..... INFLAMMATION INVOLVES VENTRAL ASPECTS OF NASAL CAVITY AND  
 -SUBACUTE INFLAMMATION ..... NASO-LACRIMAL DUCT.  
 ADRENAL ..... NOT SPECIFIED(MODERATE)  
 -FOCUS OF CELLULER ALTERATION, EOSINOPHILIC .....  
 PITUITARY GLAND ..... NOT SPECIFIED(MODERATE)  
 -B- ADENOMA ..... (PRESENT)

DIAPHRAGM ..... MISCELLANEOUS TISSUE  
 -COMPOUND RELATED INFLAMMATORY REACTION ..... NOT SPECIFIED (PRESENT)

Appendix J (cont.): PATHOLOGY INDIVIDUAL ANIMAL DATA

LETTERMAN ARMY INSTITUTE OF RESEARCH  
DIV OF RES SUPP, PATH SERV GP  
SPECIES: RAT/FISCHER-344

INDIVIDUAL ANIMAL DATA REPORT  
STUDY NUMBER: GLP83009

PRINTED: 21-NOV-89  
PAGE: 58

STUDY START DATE: 23-JAN-84 STUDY TYPE: CHRONIC/2 YR CARCINOGENIC

ANIMAL NUMBER: 31/PRETEST= 31 SEX: MALE DOSE GROUP: 1 SACRIFICE STATUS: FINAL SACRIFICE  
DATE OF DEATH: 29-JAN-86 STUDY DAY OF DEATH: 738 STUDY WEEK OF DEATH: 106 TERMINAL BODY WEIGHT: 414.00 (GMS)

<< GROSS ORGAN OBSERVATIONS >>  
SEVERITY GROSS FREE-TEXT COMMENTS  
.....  
LIVER ADHESION(S) PRESENT DIAPHRAGM AND VENTRAL ABDOMINAL WALL  
SM INTESTINE ADHESION(S) PRESENT SEVERAL LOOPS  
PITUITARY GLAND MODULE PRESENT 2MM DIAMETER, WHITE AND RED  
TESTES GROWTH(S) / MASS(ES) PRESENT BILATERAL, MULTIPLE VARIABLY SIZED, YELLOW/BLACK

<< MICROSCOPIC TISSUE OBSERVATIONS >>  
DISTRIBUTION (SEVERITY) / SPECIAL COMMENTS  
.....

THYROID GLANDS ..... (PRESENT)  
-B- PARA-FOLLICULAR CELL ADENOMA

HEART ..... NOT SPECIFIED(MILD)  
-CARDIOMYOPATHY

LIVER ..... NOT SPECIFIED (PRESENT)  
-COMPOUND RELATED INFLAMMATORY REACTION  
-BILE DUCTULE EPITHELIAL HYPERPLASIA AND/OR CHOLANGIOFIBROSIS  
-HEPATITIS NOT SPECIFIED(MILD)  
-FOCUS OF CELLULAR ALTERATION - CLEAR CELLS NOT SPECIFIED(TRACE)

KIDNEY ..... NOT SPECIFIED(MILD)  
-PROGRESSIVE RENAL DISEASE

PROSTATE ..... NOT SPECIFIED(TRACE)  
-BENIGN HYPERPLASIA

TESTES ..... (PRESENT)  
-B- INTERSTITIAL CELL ADENOMA

DUODENUM ..... NOT SPECIFIED (PRESENT)  
-COMPOUND RELATED INFLAMMATORY REACTION

PANCREAS .....

Appendix J (cont.): PATHOLOGY INDIVIDUAL ANIMAL DATA

LETTERMAN ARMY INSTITUTE OF RESEARCH  
 DIV OF RES SUPP, PATH SERV GP  
 SPECIES: RAT/FISCHER-344

INDIVIDUAL ANIMAL DATA REPORT  
 STUDY NUMBER: GLP83009  
 STUDY START DATE: 23-JAN-84

PRINTED: 21-NOV-89  
 PAGE: 59

ANIMAL NUMBER: 31/PRETEST  
 DOSE GROUP: 1  
 SACRIFICE STATUS: FINAL SACRIFICE

DATE OF DEATH: 29-JAN-86  
 STUDY DAY OF DEATH: 738  
 STUDY WEEK OF DEATH: 106  
 TERMINAL BODY WEIGHT: 414.00 (GMS)

STUDY TYPE: CHRONIC/2 YR CARCINOGENIC

TISSUE / HISTOPATHOLOGIC FINDINGS  
 << M I C R O S C O P I C T I S S U E O B S E R V A T I O N S >>  
 DISTRIBUTION (SEVERITY) / SPECIAL COMMENTS

- PANCREAS ..... (PRESENT)
- B- ISLET CELL ADENOMA ..... (PRESENT)
- MAMMARY GLANDS ..... NOT SPECIFIED(MODERATE)
- HYPERPLASIA AND/OR HYPERTROPHY OF THE ACINAR TISSUE ..... NOT SPECIFIED (PRESENT)
- DILATATION (ECTASIA) OF DUCTS AND DUCTULES
- NOSE/TURBINATES ..... THE CELLULAR INFILTRATE IS UNILATERAL AND INVOLVES THE NASO-LACRIMAL DUCT.
- MIXED INFLAMMATORY CELL INFILTRATION, NASAL CAVITY, SINUSES, TURBINATES, NASO-LACRIMAL DUCTS ..... NOT SPECIFIED(MILD)
- ADRENAL ..... NOT SPECIFIED(TRACE)
- LIPIDOSIS ..... MULTI-FOCAL(TRACE)
- FOCUS OF CELLULAR ALTERATION, VACUOLATED ..... (PRESENT)
- PITUITARY GLAND ..... NOT SPECIFIED (PRESENT)
- B- ADENOMA
- CYST(S)
- EYES & OPTIC N. .... MILD DEGENERATIVE CHANGES NOTED IN LENS IN ONE EYE.
- CORNEAL VASCULARIZATION ..... NOT SPECIFIED(MILD)
- LENTICULAR DEGENERATIVE CHANGES COMPATIBLE WITH CATARACT ..... NOT SPECIFIED (PRESENT)
- EAR ..... SEVERE SUPPURATIVE OTITIS MEDIA PRESENT UNILATERALLY.
- OTITIS MEDIA, SUPPURATIVE OR NON-SUPPURATIVE ..... NOT SPECIFIED(MARKED)
- ABDOMINAL CAVITY ..... MISCELLANEOUS TISSUE
- ..... THE ONLY GROSS OR HISTOLOGIC LESIONS CORRESPONDING TO THE
- ..... "LARGE INTRA-ABDOMINAL MASS" NOTED CLINICALLY WERE ADHESIONS
- ..... OF LIVER, SMALL INTESTINE, AND DIAPHRAGM.
- DIAPHRAGM ..... MISCELLANEOUS TISSUE
- COMPOUND RELATED INFLAMMATORY REACTION ..... NOT SPECIFIED (PRESENT)

**Appendix J (cont.): PATHOLOGY INDIVIDUAL ANIMAL DATA**

LETTERMAN ARMY INSTITUTE OF RESEARCH  
 DIV OF RES SUPP, PATH SERV GP  
 SPECIES: RAT/FISCHER-344  
 STUDY NUMBER: GLP3009  
 STUDY START DATE: 23-JAN-84  
 STUDY TYPE: CHRONIC/2 YR CARCINOGENIC  
 PRINTED: 21-NOV-89  
 PAGE: 60

ANIMAL NUMBER: 32/PRETEST-  
 DATE OF DEATH: 26-SEP-85  
 SEX: MALE  
 DOSE GROUP: 1  
 SACRIFICE STATUS: SACRIFICED MORIBUND  
 STUDY WEEK OF DEATH: 88  
 TERMINAL BODY WEIGHT: 384.00 (GMS)

<< GROSS ORGAN OBSERVATIONS >>  
 SEVERITY GROSS FREE-TEXT COMMENTS

LIVER  
 JEJUNUM  
 TESTES  
 EAR

ADHESION(S)  
 ADHERED TO PERITONEUM  
 ATROPHIC / SMALL, UNILATERALLY  
 NECROSIS

PRESENT  
 PRESENT  
 PRESENT

DIAPHRAGM, VENTRAL ABDOMINAL WALL, OMENTUM OF SMALL INTESTINE  
 RIGHT, 1.5 X 1CM  
 1.5CM DIAMETER AREA SURROUNDIN EAR TAG ON RIGHT EAR

TISSUE / HISTOPATHOLOGIC FINDINGS  
 << MICROSCOPIC TISSUE OBSERVATIONS >>  
 DISTRIBUTION (SEVERITY) / SPECIAL COMMENTS

- PARATHYROID ..... TISSUE IS MISSING
- HEART ..... NOT SPECIFIED(MILD)
- CARDIOMYOPATHY ..... NOT SPECIFIED(MODERATE)
- MEDIAL HYPERTROPHY OF MUSCULAR ARTERIES
- LUNGS ..... NOT SPECIFIED(TRACE)
- MINERALIZATION OF PULMONARY ARTERIES
- LYMPH NODES ..... RBC'S AND REACTIVE HYPERPLASIA NOTED IN CERVICAL NODE.
- RED BLOOD CELLS, HEMOSIDERIN AND/OR ERYTHROPHAGOCYTOSIS WITHIN ..... NOT SPECIFIED (PRESENT)
- MEDULLARY SINUSES ..... NOT SPECIFIED (PRESENT)
- REACTIVE HYPERPLASIA
- LIVER ..... NOT SPECIFIED (PRESENT)
- COMPOUND RELATED INFLAMMATORY REACTION ..... NOT SPECIFIED(MILD)
- BILE DUCTULE EPITHELIAL HYPERPLASIA AND/OR CHOLANGIOFIBROSIS ..... MULTI-FOCAL(MILD)
- HEPATOCTYTIC VACUOLIZATION
- KIDNEY ..... NOT SPECIFIED(TRACE)
- PROGRESSIVE RENAL DISEASE
- TESTES ..... NOT SPECIFIED(MARKED)
- TUBULAR ATROPHY

**Appendix J (cont.): PATHOLOGY INDIVIDUAL ANIMAL DATA**

LETTERMAN ARMY INSTITUTE OF RESEARCH  
 DIV OF RES SUPP, PATH SERV GP  
 SPECIES: RAT/FISCHER-344

INDIVIDUAL ANIMAL DATA REPORT  
 STUDY NUMBER: GLP83009  
 STUDY START DATE: 23-JAN-84

PRINTED: 21-NOV-89  
 PAGE: 61  
 STUDY TYPE: CHRONIC/2 YR CARCINOGENIC

ANIMAL NUMBER: 32/PRETEST  
 DOSE GROUP: 1  
 SACRIFICE STATUS: SACRIFICED MORIBUND

DATE OF DEATH: 26-SEP-85  
 STUDY DAY OF DEATH: 613  
 STUDY WEEK OF DEATH: 88  
 TERMINAL BODY WEIGHT: 384.00 (GMS)

<< M I C R O S C O P I C T I S S U E O B S E R V A T I O N S >>  
 TISSUE / HISTOPATHOLOGIC FINDINGS  
 DISTRIBUTION (SEVERITY) / SPECIAL COMMENTS

- TESTES ..... NOT SPECIFIED(MODERATE)
- INTERSTITIAL CELL HYPERPLASIA
- JEJUNUM ..... NOT SPECIFIED (PRESENT)
- COMPOUND RELATED INFLAMMATORY REACTION
- ILEUM ..... NOT SPECIFIED (PRESENT)
- COMPOUND RELATED INFLAMMATORY REACTION
- MAMMARY GLANDS ..... NOT SPECIFIED (PRESENT)
- DILATATION (ECTASIA) OF DUCTS AND DUCTULES
- PITUITARY GLAND ..... (PRESENT)
- B- ADENOMA
- EAR ..... THE FIBROSARCOMA IS WELL-DIFFERENTIATED AND WAS LOCATED  
 ADJACENT TO AND SURROUNDING THE EAR TAG.
- M- FIBROSARCOMA, SUBCUTANEOUS, EXTERNAL EAR, ADJACENT TO EAR TAG(PRESENT)
- DIAPHRAGM ..... MISCELLANEOUS TISSUE
- COMPOUND RELATED INFLAMMATORY REACTION ..... NOT SPECIFIED (PRESENT)

**Appendix J (cont.): PATHOLOGY INDIVIDUAL ANIMAL DATA**

LETTERMAN ARMY INSTITUTE OF RESEARCH  
 DIV OF RES SUPP, PATH SERV GP  
 SPECIES: RAT/FISCHER-344  
 STUDY START DATE: 23-JAN-84  
 ANIMAL NUMBER: 33/PRETEST-  
 DATE OF DEATH: 29-JAN-86  
 SEX: MALE  
 DOSE GROUP: 1  
 SACRIFICE STATUS: FINAL SACRIFICE  
 STUDY WEEK OF DEATH: 106  
 TERMINAL BODY WEIGHT: 358.00 (GMS)  
 STUDY TYPE: CHRONIC/2 YR CARCINOGENIC

PRINTED: 21-NOV-89  
 PAGE: 62

<< GROSS ORGAN OBSERVATIONS >>  
 SEVERITY GROSS FREE-TEXT COMMENTS  
 LIVER ADHESION(S) PRESENT VENTRAL ABDOMINAL WALL  
 LIVER GROWTH(S) / MASS(ES) PRESENT YELLOW/GRAY, .6CM DIAMETER  
 PERITONEAL CAV. CYST PRESENT 1CM DIAMETER, IN MESENTERY  
 SM INTESTINE GROWTH(S)/MASS(S) PRESENT INVOLVES SEVERAL LOOPS, 3 X 2CM, ADHERED TO LIVER, YELLOW  
 TESTES GROWTH(S) / MASS(ES) PRESENT BILATERAL, MULTIPLE VARIABLY SIZED, YELLOW

<< MICROSCOPIC TISSUE OBSERVATIONS >>  
 DISTRIBUTION (SEVERITY) / SPECIAL COMMENTS

THYROID GLANDS  
 -B- PARA-FOLLICULAR CELL ADENOMA (PRESENT)

HEART  
 -CARDIOMYOPATHY NOT SPECIFIED(MODERATE)  
 -MEDIAL HYPERTROPHY OF MUSCULAR ARTERIES NOT SPECIFIED(MILD)

LUNGS  
 -MINERALIZATION OF PULMONARY ARTERIES NOT SPECIFIED(TRACE)  
 SPLEEN  
 -FIBROSIS CAPSULAR FOCAL(TRACE)

LYMPH NODES  
 REACTIVE HYPERPLASIA NOTED IN CERVICAL NODES.  
 BOTH MEDIASTINAL AND MESENTERIC NODES HAVE GREATLY DILATED  
 SINUSOIDS. SECTION #22 IDENTIFIED GROSSLY AS A "MESENTERIC  
 CYST" IS A MESENTERIC LYMPH NODE WITH GREATLY DILATED SINUSOIDS.  
 NOT SPECIFIED (PRESENT)  
 NOT SPECIFIED (PRESENT)

LIVER  
 -COMPOUND RELATED INFLAMMATORY REACTION NOT SPECIFIED (PRESENT)



Appendix J (cont.): PATHOLOGY INDIVIDUAL ANIMAL DATA

LETTERMAN ARMY INSTITUTE OF RESEARCH  
 DIV OF RES SUPP, PATH SERV GP  
 SPECIES: RAT/FISCHER-344

INDIVIDUAL ANIMAL DATA REPORT  
 STUDY NUMBER: GLP83009  
 STUDY START DATE: 23-JAN-64

PRINTED: 21-NOV-89  
 PAGE: 63  
 STUDY TYPE: CHRONIC/2 YR CARCINOGENIC

ANIMAL NUMBER: 33/PRETEST-  
 DATE OF DEATH: 29-JAN-86

33 SEX: MALE  
 STUDY DAY OF DEATH: 738

DOSE GROUP: 1  
 STUDY WEEK OF DEATH: 106

SACRIFICE STATUS: FINAL SACRIFICE  
 TERMINAL BODY WEIGHT: 358.00 (GMS)

<< M I C R O S C O P I C T I S S U E O B S E R V A T I O N S >>  
 TISSUE / HISTOPATHOLOGIC FINDINGS  
 DISTRIBUTION (SEVERITY) / SPECIAL COMMENTS

LIVER ..... NOT SPECIFIED(MILD)  
 -BILE DUCTULE EPITHELIAL HYPERPLASIA AND/OR CHOLANGIOFIBROSIS ..... MULTI-FOCAL(MILD)  
 -HEPATITIS ..... MULTI-FOCAL (PRESENT)  
 -CYSTIC DEGENERATION ..... MULTI-FOCAL(MILD)  
 -BENIGN HYPERPLASTIC MODULE(S) ..... SECONDARY NEOPLASIA FROM ORGAN  
 -N- PRESENCE OF METASTATIC SARCOMA

KIDNEY ..... NOT SPECIFIED(TRACE)  
 -PROGRESSIVE RENAL DISEASE

PROSTATE ..... NOT SPECIFIED(MODERATE)  
 -CHRONIC PROSTATITIS ..... NOT SPECIFIED(MILD)  
 -BENIGN HYPERPLASIA

SEMINAL VESICLE ..... NOT SPECIFIED (PRESENT)  
 -GENERALIZED ATROPHY

TESTES ..... (PRESENT)  
 -B- INTERSTITIAL CELL ADENOMA

PANCREAS ..... FOCAL(TRACE)  
 -ACINAR (EXOCRINE) ATROPHY

COLON ..... CYSTIC POLYP OF LARGE INTESTINAL ORIGIN IS PRESENT AND IS ADHERED TO THE LIVER AT ONE POINT. THERE ARE AREAS OF MUCOSAL ULCERATION ADJACENT TO THE PROLIFERATIVE POLYPOID MASS.

-CHRONIC COLITIS WITH MUCOUS GLAND HYPERPLASIA AND HYPERSECRETION MULTI-FOCAL(MODERATE)  
 -B- POLYP, CYSTIC, WITH MUCINOUS EPITHELIAL HYPERPLASIA AND OSSEOUS METAPLASIA AND/OR MINERALIZATION OF STROMA (PRESENT)

MAMMARY GLANDS ..... NOT SPECIFIED(TRACE)  
 -HYPERPLASIA AND/OR HYPERTROPHY OF THE ACINAR TISSUE

ADRENAL .....

Appendix J (cont.): PATHOLOGY INDIVIDUAL ANIMAL DATA

LETTERMAN ARMY INSTITUTE OF RESEARCH  
DIV OF RES SUPP, PATH SERV GP  
SPECIES: RAT/FISCHER-344

INDIVIDUAL ANIMAL DATA REPORT  
STUDY NUMBER: GLP83009  
STUDY START DATE: 23-JAN-84

PRINTED: 21-NOV-89  
PAGE: 64

STUDY TYPE: CHRONIC/2 YR CARCINOGENIC

ANIMAL NUMBER: 33/PRETEST-33 SEX: MALE DOSE GROUP: 1 SACRIFICE STATUS: FINAL SACRIFICE  
DATE OF DEATH: 29-JAN-86 STUDY DAY OF DEATH: 738 STUDY WEEK OF DEATH: 106 TERMINAL BODY WEIGHT: 358.00 (GMS)

TISSUE / HISTOPATHOLOGIC FINDINGS << MICROSCOPIC TISSUE OBSERVATIONS >>  
DISTRIBUTION (SEVERITY) / SPECIAL COMMENTS

ADRENAL ..... NOT SPECIFIED (PRESENT)  
-CORTICAL MODULAR HYPERPLASIA (PRESENT)  
-B- PNEUROMYOTOMA

PITUITARY GLAND ..... (PRESENT)  
-B- ADENOMA

EYES & OPTIC N. .... NOT SPECIFIED (PRESENT)  
-LENTICULAR DEGENERATIVE CHANGES COMPATIBLE WITH CATARACT

EAR ..... NOT SPECIFIED (TRACE)  
-OTITIS MEDIA, SUPPURATIVE OR NON-SUPPURATIVE

ABDOMINAL CAVITY ..... MISCELLANEOUS TISSUE  
THE SARCOMA IS LIMITED TO LIVER AND DIAPHRAGM. IT IS HIGHLY  
ANAPLASTIC AND POORLY DIFFERENTIATED. THERE ARE NUMEROUS LARGE  
MULTINUCLEATED NEOPLASTIC GIANT CELLS (PRESENT)

-M- SARCOMA, CELLULAR DIFFERENTIATION UNSPECIFIED  
DIAPHRAGM ..... MISCELLANEOUS TISSUE  
-M- PRESENCE OF METASTATIC SARCOMA SECONDARY NEOPLASM FROM ORGAN  
-COMPOUND RELATED INFLAMMATORY REACTION NOT SPECIFIED (PRESENT)

**Appendix J (cont.): PATHOLOGY INDIVIDUAL ANIMAL DATA**

LETTERMAN ARMY INSTITUTE OF RESEARCH  
 DIV OF RES SUPP, PATH SERV GP  
 STUDY NUMBER: GLP83009  
 STUDY START DATE: 23-JAN-84  
 STUDY TYPE: CHRONIC/2 YR CARCINOGENIC  
 PRINTED: 21-NOV-89  
 PAGE: 65

ANIMAL NUMBER: 34/PRETEST= 34 SEX: MALE DOSE GROUP: 1 SACRIFICE STATUS: SACRIFICED MORTIBUND  
 DATE OF DEATH: 01-JUL-85 STUDY DAY OF DEATH: 526 STUDY WEEK OF DEATH: 76 TERMINAL BODY WEIGHT: 422.00 (GMS)

ORGAN NAME << GROSS ORGAN OBSERVATIONS >>  
 SEVERITY GROSS FREE-TEXT COMMENTS

PERITONEAL CAV. PRESENT FIRM, WHITE, 6 X 4 X 3CM, APPROXIMATELY A 10CM LENGTH OF THE MIDDLE SMALL INTESTINE IS ADHERED TO MASS WINDING FROM ONE SIDE TO THE OTHER.  
 SEVERITY GROSS FREE-TEXT COMMENTS

SPLEEN FIBROUS ADHESION(S) PRESENT ABDOMINAL WALL  
 LIVER ADHESION(S) PRESENT DIAPHRAGM  
 PITUITARY GLAND CYST(S) PRESENT 1MM DIAMETER

TISSUE / HISTOPATHOLOGIC FINDINGS << MICROSCOPIC TISSUE OBSERVATIONS >>  
 DISTRIBUTION (SEVERITY) / SPECIAL COMMENTS

THYROID GLANDS NOT SPECIFIED (PRESENT)  
 -COLLOID CYST(S) TISSUE IS MISSING

PARATHYROID THE SARCOMA IS LIMITED TO THE SURFACE OF THE SPLENIC CAPSULE.  
 -N- PRESENCE OF METASTATIC SARCOMA SECONDARY NEOPLASM FROM ORGAN ABDOMINAL CAVITY  
 -COMPOUND RELATED INFLAMMATORY REACTION NOT SPECIFIED (PRESENT)

LYMPH NODES REACTIVE HYPERPLASIA AND RBC'S NOTED IN BOTH MEDIASTINAL AND MESENTERIC NODES.  
 -RED BLOOD CELLS, HEMOSIDERIN AND/OR ERYTHROPHAGOCYTOSIS WITHIN NOT SPECIFIED (PRESENT)  
 MEDULLARY SINUSES NOT SPECIFIED (PRESENT)  
 -REACTIVE HYPERPLASIA NOT SPECIFIED (PRESENT)

LIVER NOT SPECIFIED (PRESENT)  
 -COMPOUND RELATED INFLAMMATORY REACTION NOT SPECIFIED (MILD)  
 -BILE DUCTULE EPITHELIAL HYPERPLASIA AND/OR CHOLANGIOFIBROSIS SECONDARY NEOPLASM FROM ORGAN ABDOMINAL CAVITY  
 -N- PRESENCE OF METASTATIC SARCOMA

PROSTATE NOT SPECIFIED (TRACE)  
 -BENIGN HYPERPLASIA

TESTES

Appendix J (cont.): PATHOLOGY INDIVIDUAL ANIMAL DATA

LETTERMAN ARMY INSTITUTE OF RESEARCH  
DIV OF RES SUPP, PATH SERV GP  
SPECIES: RAT/FISCHER-344

INDIVIDUAL ANIMAL DATA REPORT  
STUDY NUMBER: GLP83009  
STUDY START DATE: 23-JAN-84

PRINTED: 21-NOV-89  
PAGE: 66

STUDY TYPE: CHRONIC/2 YR CARCINOGENIC

ANIMAL NUMBER: 34/PRETEST= 34 SEX: MALE DOSE GROUP: 1 SACRIFICE STATUS: SACRIFICED MORTIBUND  
DATE OF DEATH: 01-JUL-85 STUDY DAY OF DEATH: 526 STUDY WEEK OF DEATH: 76 TERMINAL BODY WEIGHT: 422.00 (GMS)

TISSUE / HISTOPATHOLOGIC FINDINGS << MICROSCOPIC TISSUE OBSERVATIONS >>  
DISTRIBUTION (SEVERITY) / SPECIAL COMMENTS

- TESTES ..... NOT SPECIFIED(MILD)
- INTERSTITIAL CELL HYPERPLASIA
- DUODENUM ..... SECONDARY NEOPLASM FROM ORGAN ABDOMINAL CAVITY
- N- PRESENCE OF METASTATIC SARCOMA
- JEJUNUM ..... SECONDARY NEOPLASM FROM ORGAN ABDOMINAL CAVITY
- N- PRESENCE OF METASTATIC SARCOMA
- ILEUM ..... NOT SPECIFIED (PRESENT)
- LYMPHOID HYPERPLASIA
- PANCREAS ..... NOT SPECIFIED(TRACE)
- ACINAR (EXOCRINE) ATROPHY
- N- PRESENCE OF METASTATIC SARCOMA
- CECUM ..... NOT SPECIFIED (PRESENT)
- COMPOUND RELATED INFLAMMATORY REACTION
- COLON ..... SECONDARY NEOPLASM FROM ORGAN ABDOMINAL CAVITY
- N- PRESENCE OF METASTATIC SARCOMA
- NOSE/TURBINATES ..... CELLULAR INFILTRATE INVOLVES NASO-LACRIMAL DUCT.
- MIXED INFLAMMATORY CELL INFILTRATION, NASAL CAVITY, SINUSES,  
TURBINATES, NASO-LACRIMAL DUCTS
- ADRENAL ..... DIFFUSE(TRACE)
- LIPIDOSIS
- PITUITARY GLAND ..... NOT SPECIFIED (PRESENT)
- CYST(S)

Appendix J (cont.): PATHOLOGY INDIVIDUAL ANIMAL DATA

LETTERMAN ARMY INSTITUTE OF RESEARCH  
DIV OF RES SUPP, PATH SERV GP  
SPECIES: RAT/FISCHER-344

INDIVIDUAL ANIMAL DATA REPORT  
STUDY NUMBER: GLP83009

PRINTED: 21-NOV-89  
PAGE: 67

STUDY START DATE: 23-JAN-84

STUDY TYPE: CHRONIC/2 YR CARCINOGENIC

ANIMAL NUMBER: 34/PRETEST-  
DATE OF DEATH: 01-JUL-85

34 SEX: MALE  
STUDY DAY OF DEATH: 526

DOSE GROUP: 1  
STUDY WEEK OF DEATH: 76

SACRIFICE STATUS: SACRIFICED MORIBUND  
TERMINAL BODY WEIGHT: 422.00 (GMS)

<< MICROSCOPIC TISSUE OBSERVATIONS >>  
DISTRIBUTION (SEVERITY) / SPECIAL COMMENTS

TISSUE / HISTOPATHOLOGIC FINDINGS

ABDOMINAL CAVITY

MISCELLANEOUS TISSUE

IN MOST AREAS THE TUMOR IS A WELL-DIFFERENTIATED FIBROSARCOMA.  
IT IS PRESENT IN LIVER, DIAPHRAGM, SPLEEN, DUODENUM, ILEUM,  
PANCREAS AND COLON.  
(PRESENT)

-M- SARCOMA, CELLULAR DIFFERENTIATION UNSPECIFIED

DIAPHRAGM

MISCELLANEOUS TISSUE

SECONDARY NEOPLASM FROM ORGAN ABDOMINAL CAVITY  
NOT SPECIFIED (PRESENT)

-N- PRESENCE OF METASTATIC SARCOMA  
-COMPOUND RELATED INFLAMMATORY REACTION

Appendix J (cont.): PATHOLOGY INDIVIDUAL ANIMAL DATA

LETTERMAN ARMY INSTITUTE OF RESEARCH  
 DIV OF RES SUPP, PATH SERV GP  
 SPECIES: RAT/FISCHER-344  
 STUDY START DATE: 23-JAN-84  
 STUDY TYPE: CHRONIC/2 YR CARCINOGENIC  
 ANIMAL NUMBER: 35/PRETEST=  
 DATE OF DEATH: 14-JAN-86  
 SEX: MALE  
 DOSE GROUP: 1  
 SACRIFICE STATUS: FOUND DEAD  
 STUDY WEEK OF DEATH: 104  
 TERMINAL BODY WEIGHT: 385.00 (GMS)

PRINTED: 21-NOV-89  
 PAGE: 68

ORGAN NAME  
 SEVERITY GROSS FREE-TEXT COMMENTS  
 << GROSS ORGAN OBSERVATIONS >>  
 KEYWORDS / PHRASES  
 ATROPHIC / SMALL, UNILATERALLY  
 ENLARGED  
 GROWTH(S) / MASS(ES)  
 ADHESION(S)  
 CONGESTED / RED  
 CORNEAL OPACITY  
 DISCOLORATION  
 RIGHT, .3CM DIAMETER  
 LEFT, 3 X 1.5CM  
 SOFT, BLACK, 1.5 X 1CM  
 DIAPHRAGM  
 RIGHT  
 DARK, HEMORRHAGIC

TISSUE / HISTOPATHOLOGIC FINDINGS  
 << MICROSCOPIC TISSUE OBSERVATIONS >>  
 DISTRIBUTION (SEVERITY) / SPECIAL COMMENTS

HEART  
 -CARDIOMYOPATHY  
 -MEDIAL HYPERTROPHY OF MUSCULAR ARTERIES  
 NOT SPECIFIED(MILD)  
 NOT SPECIFIED(TRACE)  
 LYMPH NODES  
 REACTIVE HYPERPLASIA INVOLVES CERVICAL AND MESENTERIC NODES.  
 ABC'S WERE PRESENT IN MESENTERIC NODES BUT NOT IN OTHER NODES  
 EXAMINED.  
 NOT SPECIFIED (PRESENT)  
 NOT SPECIFIED (PRESENT)  
 -RED BLOOD CELLS, HEMOSIDERIN AND/OR ERYTHROPHAGOCYTOSIS WITHIN  
 MEDULLARY SINUSES  
 -REACTIVE HYPERPLASIA  
 NOT SPECIFIED (PRESENT)  
 LIVER  
 -COMPOUND RELATED INFLAMMATORY REACTION  
 -BILE DUCTULE EPITHELIAL HYPERPLASIA AND/OR CHOLANGIOFIBROSIS  
 -BENIGN HYPERPLASTIC NODULE(S)  
 NOT SPECIFIED (PRESENT)  
 KIDNEY  
 -PROGRESSIVE RENAL DISEASE  
 NOT SPECIFIED(TRACE)  
 PROSTATE  
 -CHRONIC PROSTATITIS  
 NOT SPECIFIED(MILD)

Appendix J (cont.): PATHOLOGY INDIVIDUAL ANIMAL DATA

LETTERMAN ARMY INSTITUTE OF RESEARCH  
 DIV OF RES SUPP, PATH SERV GP  
 SPECIES: RAT/FISCHER-344  
 STUDY NUMBER: GLP83009  
 STUDY START DATE: 23-JAN-84  
 STUDY TYPE: CHRONIC/2 YR CARCINOGENIC  
 ANIMAL NUMBER: 35/PRETEST  
 35 SEX: MALE DOSE GROUP: 1 SACRIFICE STATUS: FOUND DEAD  
 DATE OF DEATH: 14-JAN-86 STUDY DAY OF DEATH: 723 STUDY WEEK OF DEATH: 104 TERMINAL BODY WEIGHT: 385.00 (GMS)  
 TISSUE / HISTOPATHOLOGIC FINDINGS << MICROSCOPIC TISSUE OBSERVATIONS >>  
 DISTRIBUTION (SEVERITY) / SPECIAL COMMENTS

PRINTED: 21-NOV-89  
PAGE: 69

- PROSTATE ..... NOT SPECIFIED(MILD)
- BENIGN HYPERPLASIA
- COAG GL ..... TISSUE IS MISSING
- S-ANAL VESICLE ..... NOT SPECIFIED (PRESENT)
- GENERALIZED ATROPHY
- TESTES ..... (PRESENT)
- B- INTERSTITIAL CELL ADENOMA
- JEJUNUM ..... NOT SPECIFIED (PRESENT)
- COMPOUND RELATED INFLAMMATORY REACTION
- MUCOSAL EROSION/ULCERATION
- PRESENCE OF MUCOSAL EPITHELIAL CELLS WITHIN INTESTINAL WALL AND ADJACENT FIBROUS/GRANULOMATOUS INFLAMMATORY REACTION
- ILEUM ..... NOT SPECIFIED (PRESENT)
- MUCOSAL EROSION/ULCERATION
- MAMMARY GLANDS ..... NOT SPECIFIED (TRACE)
- HYPERPLASIA AND/OR HYPERTROPHY OF THE ACINAR TISSUE
- DILATATION (ECTASIA) OF DUCTS AND DUCTULES
- NOSE/TURBINATES ..... THE CELLULAR INFILTRATE INVOLVES THE NASO-LACCRIMAL DUCT.
- MIXED INFLAMMATORY CELL INFILTRATION, NASAL CAVITY, SINUSES, TURBINATES, NASO-LACCRIMAL DUCTS
- BONE, FEMUR ..... TISSUE IS MISSING
- PITUITARY GLAND ..... (PRESENT)
- B- ADENOMA

Appendix J (cont.): PATHOLOGY INDIVIDUAL ANIMAL DATA

LETTERMAN ARMY INSTITUTE OF RESEARCH  
DIV OF RES SUPP, PATH SERV GP  
SPECIES: RAT/FISCHER-344

INDIVIDUAL ANIMAL DATA REPORT  
STUDY NUMBER: GLP83009  
STUDY START DATE: 23-JAN-84

PRINTED: 21-NOV-89  
PAGE: 70

STUDY TYPE: CHRONIC/2 YR CARCINOGENIC

ANIMAL NUMBER: 35/PRETEST-      DOSE GROUP: 1      SACRIFICE STATUS: FOUND DEAD  
DATE OF DEATH: 14-JAN-86      STUDY DAY OF DEATH: 723      STUDY WEEK OF DEATH: 104      TERMINAL BODY WEIGHT: 385.00 (GMS)

TISSUE / HISTOPATHOLOGIC FINDINGS      <<      M I C R O S C O P I C      T I S S U E      O B S E R V A T I O N S      >>  
.....      DISTRIBUTION (SEVERITY) / SPECIAL COMMENTS      .....

EYES & OPTIC N.      .....      ALL OCCULAR LESIONS CODED UNVOLVE ONLY THE RIGHT EYE. THE LEFT  
.....      EYE IS ESSENTIALLY NORMAL.  
-RETINAL ATROPHY AND/OR DEGENERATION, UNILATERAL OR BILATERAL      DIFFUSE(MODERATE)  
-IRIDOCYCLITIS      .....      DIFFUSE(MILD)  
-LENTICULAR DEGENERATIVE CHANGES COMPATIBLE WITH CATARACT      NOT SPECIFIED (PRESENT)



**Appendix J (cont.): PATHOLOGY INDIVIDUAL ANIMAL DATA**

LETTERMAN ARMY INSTITUTE OF RESEARCH  
 DIV OF RES SUPP, PATH SERV GP  
 SPECIES: RAT/FISCHER-344  
 INDIVIDUAL ANIMAL DATA REPORT  
 STUDY NUMBER: GLP83009  
 PRINTED: 21-NOV-89  
 PAGE: 71

ANIMAL NUMBER: 36/PRETEST-  
 DATE OF DEATH: 30-JAN-86  
 STUDY DAY OF DEATH: 739  
 SEX: MALE  
 DOSE GROUP: 1  
 SACRIFICE STATUS: FINAL SACRIFICE  
 STUDY WEEK OF DEATH: 106  
 TERMINAL BODY WEIGHT: 325.00 (GMS)  
 STUDY START DATE: 23-JAN-84  
 STUDY TYPE: CHRONIC/2 YR CARCINOGENIC

ORGAN NAME  
 LIVER  
 SKIN  
 KIDNEY  
 TESTES  
 PITUITARY GLAND

<< GROSS ORGAN OBSERVATIONS >>  
 KEYWORDS / PHRASES SEVERITY GROSS FREE-TEXT COMMENTS

ADHESION(S) PRESENT DIAPHRAGM, SMALL INTESTINE, VENTRAL ABDOMINAL WALL  
 SUBCUTANEOUS MODULE(S) PRESENT SEVERAL, FIRM, WHITE, 2-3MM DIAMETER, LEFT AXILLA  
 GRANULAR SURFACE PRESENT  
 GROWTH(S) / MASS(ES) PRESENT LEFT, MULTIPLE VARIABLY SIZED, YELLOW/BLACK  
 ENLARGED PRESENT DARK RED, .6CM DIAMETER

TISSUE / HISTOPATHOLOGIC FINDINGS << MICROSCOPIC TISSUE OBSERVATIONS >>  
 DISTRIBUTION (SEVERITY) / SPECIAL COMMENTS

THYROID GLANDS  
 -B- PARA-FOLLICULAR CELL ADENOMA (PRESENT)

HEART  
 -CARDIOMYOPATHY NOT SPECIFIED(MILD)

LIVER  
 -COMPOUND RELATED INFLAMMATORY REACTION NOT SPECIFIED (PRESENT)  
 -BILE DUCTULE EPITHELIAL HYPERPLASIA AND/OR CHOLANGIOFIBROSIS NOT SPECIFIED(MILD)  
 -HEPATOCTYIC VACUOLIZATION MULTI-FOCAL(MILD)  
 -CYSTIC DEGENERATION FOCAL (PRESENT)

KIDNEY  
 -PROGRESSIVE RENAL DISEASE NOT SPECIFIED(MARKED)

PROSTATE  
 -CHRONIC PROSTATITIS NOT SPECIFIED(MODERATE)  
 -BENIGN HYPERPLASIA NOT SPECIFIED(MILD)

TESTES  
 -B- INTERSTITIAL CELL ADENOMA (PRESENT)

JEJUNUM

Appendix J (cont.): PATHOLOGY INDIVIDUAL ANIMAL DATA

LETTERMAN ARMY INSTITUTE OF RESEARCH  
 DIV OF RES SUPP, PATH SERV GP  
 SPECIES: RAY/FISCHER-344  
 STUDY START DATE: 23-JAN-84  
 STUDY NUMBER: GLP83009  
 PRINTED: 21-NOV-89  
 PAGE: 72  
 STUDY TYPE: CHRONIC/2 YR CARCINOGENIC

ANIMAL NUMBER: 36/PRETEST-36  
 DATE OF DEATH: 30-JAN-86  
 STUDY DAY OF DEATH: 739  
 SEX: MALE  
 DOSE GROUP: 1  
 SACRIFICE STATUS: FINAL SACRIFICE  
 STUDY WEEK OF DEATH: 106  
 TERMINAL BODY WEIGHT: 325.00 (GMS)

<< MICROSCOPIC TISSUE OBSERVATIONS >>  
 DISTRIBUTION (SEVERITY) / SPECIAL COMMENTS

- TISSUE / HISTOPATHOLOGIC FINDINGS
- JEJUNUM ..... NOT SPECIFIED (PRESENT)
- COMPOUND RELATED INFLAMMATORY REACTION
- ILEUM ..... NOT SPECIFIED (PRESENT)
- COMPOUND RELATED INFLAMMATORY REACTION
- COLON ..... NOT SPECIFIED (PRESENT)
- COMPOUND RELATED INFLAMMATORY REACTION
- MAMMARY GLANDS ..... SUBCUTANEOUS MODULES OBSERVED GROSSLY IN THE AXILLA CONSIST OF HYPERPLASTIC MAMMARY TISSUE. NOT SPECIFIED (PRESENT)
- HYPERPLASIA AND/OR HYPERTROPHY OF THE ACINAR TISSUE
- DILATATION (ECTASIA) OF DUCTS AND DUCTULES
- NOSE/TURBINATES ..... CELLULAR INFILTRATE IS LOCATED ADJACENT TO MASO-LACRIMAL DUCTS.
- MIXED INFLAMMATORY CELL INFILTRATION, NASAL CAVITY, SINUSES, TURBINATES, MASO-LACRIMAL DUCTS
- PITUITARY GLAND ..... NOT SPECIFIED (MILD)
- B- ADENOMA (PRESENT)
- EYES & OPTIC N. .... NOT SPECIFIED (PRESENT)
- METAPLASTIC BONE FORMATION AND/OR MINERALIZATION, SCLERA
- LENTICULAR DEGENERATIVE CHANGES COMPATIBLE WITH CATARACT
- DIAPHRAGM ..... MISCELLANEOUS TISSUE
- COMPOUND RELATED INFLAMMATORY REACTION

**Appendix J (cont.): PATHOLOGY INDIVIDUAL ANIMAL DATA**

LETTERMAN ARMY INSTITUTE OF RESEARCH  
 DIV OF RES SUPP, PATH SERV GP  
 SPECIES: RAT/FISCHER-344  
 STUDY START DATE: 23-JAN-84  
 STUDY NUMBER: GLP83009  
 PRINTED: 21-NOV-89  
 PAGE: 73  
 ANIMAL NUMBER: 37/PRETEST-1  
 DOSE GROUP: 1  
 SACRIFICE STATUS: SACRIFICED MORIBUND  
 DATE OF DEATH: 26-SEP-85  
 STUDY DAY OF DEATH: 613  
 STUDY WEEK OF DEATH: 88  
 TERMINAL BODY WEIGHT: 463.00 (GMS)  
 STUDY TYPE: CHRONIC/2 YR CARCINOGENIC

ORGAN NAME: << GROSS ORGAN OBSERVATIONS >>  
 SEVERITY GROSS FREE-TEXT COMMENTS  
 LIVER ADHESION(S) PRESENT DIAPHRAGM, VENTRAL ABDOMINAL WALL, STOMACH  
 LIVER GROWTH(S) / MASS(ES) PRESENT FIRM, WHITE, IRREGULAR, 4 X 3.5 X 3.5CM  
 TESTES DISCOLORATION PRESENT RIGHT, DIFFUSELY PURPLE  
 STOMACH GROWTH(S) / MASS(ES) PRESENT WHITE, FIRM, IRREGULAR, 1CM DIAMETER, IN LUMEN

TISSUE / HISTOPATHOLOGIC FINDINGS << MICROSCOPIC TISSUE OBSERVATIONS >>  
 DISTRIBUTION (SEVERITY) / SPECIAL COMMENTS

HEART  
 -CARDIOMYOPATHY NOT SPECIFIED(MILD)  
 -MEDIAL HYPERTROPHY OF MUSCULAR ARTERIES NOT SPECIFIED(TRACE)

LUNGS  
 -MINERALIZATION OF PULMONARY ARTERIES NOT SPECIFIED(TRACE)  
 -FIBROSIS CAPSULAR FOCAL(MILD)

LYMPH NODES  
 -RED BLOOD CELLS, HEMOSIDERIN AND/OR ERYTHROPHAGOCYTOSIS WITHIN REACTIVE HYPERPLASIA AND RBC'S ARE NOTED IN CERVICAL, MEDIASTINAL, AND MESENTERIC LYMPH NODES.  
 -MEDULLARY SINUSES NOT SPECIFIED (PRESENT)  
 -REACTIVE HYPERPLASIA NOT SPECIFIED (PRESENT)

LIVER  
 -COMPOUND RELATED INFLAMMATORY REACTION NOT SPECIFIED (PRESENT)  
 -BILE DUCTULE EPITHELIAL HYPERPLASIA AND/OR CHOLANGIOFIBROSIS NOT SPECIFIED(MILD)  
 -HEPATOCTYIC VACUOLIZATION MULTI-FOCAL(TRACE)  
 -N- PRESENCE OF METASTATIC SARCOMA SECONDARY NEOPLASM FROM ORGAN

KIDNEY  
 -PROGRESSIVE RENAL DISEASE NOT SPECIFIED(TRACE)

PROSTATE

Appendix J (cont.): PATHOLOGY INDIVIDUAL ANIMAL DATA

LETTERMAN ARMY INSTITUTE OF RESEARCH  
 DIV OF RES SUPP, PATH SERV GP  
 SPECIES: RAT/FISCHER-344  
 ANIMAL NUMBER: 37/PRETEST#  
 DATE OF DEATH: 26-SEP-85  
 STUDY DAY OF DEATH: 613  
 SEX: MALE  
 DOSE GROUP: 1  
 STUDY WEEK OF DEATH: 88  
 TERMINAL BODY WEIGHT: 463.00 (GMS)

INDIVIDUAL ANIMAL DATA REPORT  
 STUDY NUMBER: GLP83009  
 STUDY START DATE: 23-JAN-84  
 DOSE GROUP: 1  
 STUDY WEEK OF DEATH: 88  
 TERMINAL BODY WEIGHT: 463.00 (GMS)

STUDY TYPE: CHRONIC/2 YR CARCINOGENIC

SACRIFICE STATUS: SACRIFICED MORIBUND

TISSUE / HISTOPATHOLOGIC FINDINGS  
 << MICROSCOPIC TISSUE OBSERVATIONS >>  
 DISTRIBUTION (SEVERITY) / SPECIAL COMMENTS

PRINTED: 21-NOV-89  
PAGE: 74

PROSTATE ..... NOT SPECIFIED (TRACE)  
-CHRONIC PROSTATITIS

TESTES ..... (PRESENT)  
-B- INTERSTITIAL CELL ADENOMA

STOMACH ..... (PRESENT)  
-M- PRESENCE OF METASTATIC SARCOMA

ADRENAL ..... NOT SPECIFIED (TRACE)  
-LIPIDOSIS

PITUITARY GLAND ..... (PRESENT)  
-B- ADENOMA

ABDOMINAL CAVITY ..... MISCELLANEOUS TISSUE  
IN MOST AREAS OF THE SARCOMA, NEOPLASTIC CELLS ARE POORLY DIFFERENTIATED AND ANAPLASTIC. THERE ARE NUMEROUS LARGE MULTI-NUCLEATED TUMOR GIANT CELLS IN SOME AREAS. IN THE SUBMUCOSA OF THE STOMACH, HOWEVER, THE TUMOR IS FAIRLY WELL-DIFFERENTIATED AND TYPICAL OF A FIBROSARCOMA.

-M- SARCOMA, CELLULAR DIFFERENTIATION UNSPECIFIED

DIAPHRAGM ..... MISCELLANEOUS TISSUE  
-M- PRESENCE OF METASTATIC SARCOMA  
-COMPOUND RELATED INFLAMMATORY REACTION  
SECONDARY NEOPLASM FROM ORGAN  
NOT SPECIFIED (PRESENT)

**Appendix J (cont.): PATHOLOGY INDIVIDUAL ANIMAL DATA**

LETTERMAN ARMY INSTITUTE OF RESEARCH  
 DIV OF RES SUPP, PATH SERV GP  
 SPECIES: RAT/FISCHER-344  
 STUDY START DATE: 23-JAN-84  
 STUDY NUMBER: GLP83009  
 PRINTED: 21-NOV-89  
 PAGE: 77

ANIMAL NUMBER: 39/PRETEST-  
 DATE OF DEATH: 30-JAN-86  
 DOSE GROUP: 1  
 SACRIFICE STATUS: FINAL SACRIFICE  
 STUDY WEEK OF DEATH: 106  
 TERMINAL BODY WEIGHT: 396.00 (GMS)  
 STUDY TYPE: CHRONIC/2 YR CARCINOGENIC

ORGAN NAME	KEYWORDS / PHRASES	SEVERITY	GROSS OBSERVATIONS	FREE-TEXT COMMENTS
TESTES	ATROPHIC / SMALL, UNILATERALLY GROWN(S) / MASS(ES)	PRESENT	RIGHT, 1.5 X 1CM	
LIVER	ADHESION(S)	PRESENT	LEFT, MULTIPLE VARIABLY SIZED, YELLOW	
PITUITARY GLAND	ENLARGED	MILD	VENTRAL ABDOMINAL WALL	.4CM DIAMETER, DARK RED

TISSUE / HISTOPATHOLOGIC FINDINGS  
 << MICROSCOPIC TISSUE OBSERVATIONS >>  
 DISTRIBUTION (SEVERITY) / SPECIAL COMMENTS

BRAIN	-HISTIOCYTIC INFILTRATION, PERIVASCULAR	FOCAL (PRESENT)
HEART	-CARDIOMYOPATHY	NOT SPECIFIED(MODERATE)
LYMPH NODES	-REACTIVE HYPERPLASIA	MARKED REACTIVE HYPERPLASIA NOTED IN CERVICAL LYMPH NODES ADJACENT TO SALIVARY GLANDS. NOT SPECIFIED (PRESENT)
LIVER	-COMPOUND RELATED INFLAMMATORY REACTION -BILE DUCTULE EPITHELIAL HYPERPLASIA AND/OR CHOLANGIOFIBROSIS -FOCUS OF CELLULAR ALTERATION - BASOPHILIC -BENIGN HYPERPLASTIC NODULE(S) -HEPATOCYTE COALESCING MICROVESICULAR (FATTY) CHANGE LEADING TO NECROSIS AND MINERALIZATION	NOT SPECIFIED (PRESENT) NOT SPECIFIED(MODERATE) MULTI-FOCAL(MILD) MULTI-FOCAL(MILD)
KIDNEY	-PROGRESSIVE RENAL DISEASE	NOT SPECIFIED(MODERATE)
PROSTATE	-CHRONIC PROSTATITIS -BENIGN HYPERPLASIA	NOT SPECIFIED(TRACE) NOT SPECIFIED(TRACE)
TESTES		

Appendix J (cont.): **PATHOLOGY INDIVIDUAL ANIMAL DATA**

LETTERMAN ARMY INSTITUTE OF RESEARCH  
DIV OF RES SUPP, PATH SERV 6P  
SPECIES: RAT/FISCHER-344

INDIVIDUAL ANIMAL DATA REPORT  
STUDY NUMBER: GLP83009  
STUDY START DATE: 23-JAN-84

PRINTED: 21-NOV-89  
PAGE: 78

STUDY TYPE: CHRONIC/2 YR CARCINOGENIC

ANIMAL NUMBER: 39/PRETEST= 39 SEX: MALE DOSE GROUP: 1 SACRIFICE STATUS: FINAL SACRIFICE  
DATE OF DEATH: 30-JAN-86 STUDY DAY OF DEATH: 739 STUDY WEEK OF DEATH: 106 TERMINAL BODY WEIGHT: 396.00 (GMS)

TISSUE / HISTOPATHOLOGIC FINDINGS << MICROSCOPIC TISSUE OBSERVATIONS >>  
DISTRIBUTION (SEVERITY) / SPECIAL COMMENTS

TESTES ..... (PRESENT)  
-B- INTERSTITIAL CELL ADENOMA

TONGUE .....  
-PERIARITIS ..... FOCAL (TRACE)

MAMMARY GLANDS .....  
-HYPERPLASIA AND/OR HYPERTROPHY OF THE ACINAR TISSUE ..... NOT SPECIFIED (TRACE)  
-DILATATION (ECTASIA) OF DUCTS AND DUCTULES ..... NOT SPECIFIED (PRESENT)

NOSE/TURBINATES ..... CELLULAR INFILTRATE IS ADJACENT TO NASO-LACRIMAL DUCT.  
-MIXED INFLAMMATORY CELL INFILTRATION, NASAL CAVITY, SINUSES, ..... NOT SPECIFIED (TRACE)  
TURBINATES, NASO-LACRIMAL DUCTS

PITUITARY GLAND .....  
-B- ADENOMA ..... (PRESENT)

ABDOMINAL CAVITY ..... MISCELLANEOUS TISSUE  
THERE WERE NO GROSS OR MICROSCOPIC FINDINGS OTHER THAN ADHESION  
OF THE LIVER TO THE VENTRAL BODY WALL THAT WOULD ACCOUNT FOR  
THE "LARGE INTRA-ABDOMINAL MASS" NOTED CLINICALLY.



**Appendix J (cont.): PATHOLOGY INDIVIDUAL ANIMAL DATA**

LETTERMAN ARMY INSTITUTE OF RESEARCH  
 DIV OF RES SUPP, PATH SERV GP  
 SPECIES: RAT/FISCHER-344  
 STUDY START DATE: 23-JAN-84  
 STUDY NUMBER: GLP83009  
 PRINTED: 21-NOV-89  
 PAGE: 80  
 STUDY TYPE: CHRONIC/2 YR CARCINOGENIC

ANIMAL NUMBER: 40/PRETEST  
 DOSE GROUP: 1  
 SACRIFICE STATUS: SACRIFICED MORIBUND  
 DATE OF DEATH: 30-AUG-85  
 STUDY DAY OF DEATH: 586  
 STUDY WEEK OF DEATH: 84  
 TERMINAL BODY WEIGHT: 375.00 (GMS)

TISSUE / HISTOPATHOLOGIC FINDINGS  
 << M I C R O S C O P I C T I S S U E O B S E R V A T I O N S >>  
 DISTRIBUTION (SEVERITY) / SPECIAL COMMENTS

EDIDYMNIS ..... TISSUE IS MISSING

TESTES ..... (PRESENT)

-B- INTERSTITIAL CELL ADENOMA ..... (PRESENT)

JEJUNUM ..... NOT SPECIFIED (PRESENT)

-COMPOUND RELATED INFLAMMATORY REACTION ..... NOT SPECIFIED (PRESENT)

ILEUM ..... NOT SPECIFIED (PRESENT)

-COMPOUND RELATED INFLAMMATORY REACTION ..... NOT SPECIFIED (PRESENT)

PANCREAS ..... NOT SPECIFIED (PRESENT)

-COMPOUND RELATED INFLAMMATORY REACTION ..... NOT SPECIFIED (PRESENT)

SKIN ..... MASS NEAR THE LEFT MAXILLARY AREA IS AN EPIDERMAL INCLUSION CYST.  
 -EPIDERMAL INCLUSION CYST(S) ..... NOT SPECIFIED (PRESENT)

NOSE/TURBINATES ..... TISSUE IS MISSING

BONE, STERNUM ..... NOT SPECIFIED (PRESENT)

-MYELOID HISTIOCYTOSIS ..... NOT SPECIFIED (PRESENT)

BONE VERT ..... NOT SPECIFIED (PRESENT)

-MYELOID HISTIOCYTOSIS ..... NOT SPECIFIED (PRESENT)

PITUITARY GLAND ..... NOT SPECIFIED (PRESENT)

-CYST(S) ..... NOT SPECIFIED (PRESENT)

EYES & OPTIC N. .... METAPLASTIC BONE FORMATION AND/OR MINERALIZATION, SCLERA ..... NOT SPECIFIED (PRESENT)

-METAPLASTIC BONE FORMATION AND/OR MINERALIZATION, SCLERA ..... NOT SPECIFIED (PRESENT)

DIAPHRAGM ..... MISCELLANEOUS TISSUE



Appendix J (cont.): PATHOLOGY INDIVIDUAL ANIMAL DATA

LETTERMAN ARMY INSTITUTE OF RESEARCH  
DIV OF RES SUPP, PATH SERV GP  
SPECIES: RAT/FISCHER-344

INDIVIDUAL ANIMAL DATA REPORT  
STUDY NUMBER: GLP83009  
STUDY START DATE: 23-JAN-84

PRINTED: 21-NOV-89  
PAGE: 81

STUDY TYPE: CHRONIC/2 YR CARCINOGENIC

ANIMAL NUMBER: 40/PRETEST-      DOSE GROUP: 1      SACRIFICE STATUS: SACRIFICED MORIBUND  
DATE OF DEATH: 30-AUG-85      STUDY DAY OF DEATH: 586      STUDY WEEK OF DEATH: 84      TERMINAL BODY WEIGHT: 375.00 (GMS)

<< MICROSCOPIC TISSUE OBSERVATIONS >>  
TISSUE / HISTOPATHOLOGIC FINDINGS      DISTRIBUTION (SEVERITY) / SPECIAL COMMENTS

DIAPHRAGM ..... MISCELLANEOUS TISSUE  
-COMPOUND RELATED INFLAMMATORY REACTION ..... NOT SPECIFIED (PRESENT)

**Appendix J (cont.): PATHOLOGY INDIVIDUAL ANIMAL DATA**

LETTERMAN ARMY INSTITUTE OF RESEARCH  
 DIV OF RES SUPP, PATH SERV GP  
 SPECIES: RAY/FISCHER-344  
 STUDY START DATE: 23-JAN-84  
 STUDY NUMBER: GLP03009  
 PRINTED: 21-NOV-89  
 PAGE: 82

ANIMAL NUMBER: 41/PRETEST-  
 DATE OF DEATH: 19-MAY-85  
 STUDY DAY OF DEATH: 483  
 SEX: MALE  
 DOSE GROUP: 1  
 STUDY WEEK OF DEATH: 69  
 SACRIFICE STATUS: SACRIFICED MORIBUND  
 TERMINAL BODY WEIGHT: 341.00 (GMS)

STUDY TYPE: CHRONIC/2 YR CARCINOGENIC

ORGAN NAME  
 KEYWORDS / PHRASES  
 GROSS ORGAN OBSERVATIONS  
 SEVERITY GROSS FREE-TEXT COMMENTS

LIVER  
 DIAPHRAGM  
 KIDNEY  
 PERITONEAL CAV.  
 PLEURAL CAVITY

GROWTH(S) / MASS(ES)  
 GROWTH(S)/MASS(ES)  
 HEMORRHAGE  
 FLUID-FILLED  
 FLUID-FILLED

PRESENT FIRM, WHITE, MULTILOBULATED, 4CM DIAMETER  
 PRESENT MULTIPLE, FIRM, WHITE, .2CM DIAMETER  
 PRESENT AROUND CAPSULE OF MEDIAL/ANTERIOR PORTION OF RIGHT KIDNEY  
 PRESENT CONTAINED ABOUT 1ML UNCLOTED BLOOD  
 PRESENT CONTAINED ABOUT 8ML UNCLOTED BLOOD

TISSUE / HISTOPATHOLOGIC FINDINGS  
 << MICROSCOPIC TISSUE OBSERVATIONS >>  
 DISTRIBUTION (SEVERITY) / SPECIAL COMMENTS

LUNGS  
 -MINERALIZATION OF PULMONARY ARTERIES  
 NOT SPECIFIED (TRACE)

SPLEEN  
 -EXTRAMEDULLARY HEMATOPOIESIS  
 NOT SPECIFIED (PRESENT)

LYMPH NODES  
 -REACTIVE HYPERPLASIA  
 REACTIVE HYPERPLASIA INVOLVES THE MESENTERIC LYMPH NODE.  
 NOT SPECIFIED (PRESENT)

LIVER  
 -BILE DUCTULE EPITHELIAL HYPERPLASIA AND/OR CHOLANGIOFIBROSIS  
 NOT SPECIFIED (TRACE)  
 -FOCUS OF CELLULAR ALTERATION - BASOPHILIC  
 NOT SPECIFIED (TRACE)  
 -M- PRESENCE OF METASTATIC SARCOMA  
 SECONDARY NEOPLASM FROM ORGAN

KIDNEY  
 -PROGRESSIVE RENAL DISEASE  
 NOT SPECIFIED (TRACE)

TESTES  
 -INTERSTITIAL CELL HYPERPLASIA  
 MULTI-FOCAL (MILD)

MAMMARY GLANDS  
 -HYPERPLASIA AND/OR HYPERTROPHY OF THE ACINAR TISSUE  
 NOT SPECIFIED (MILD)  
 -DILATATION (ECTASIA) OF DUCTS AND DUCTULES  
 NOT SPECIFIED (PRESENT)

**Appendix J (cont.): PATHOLOGY INDIVIDUAL ANIMAL DATA**

LETTERMAN ARMY INSTITUTE OF RESEARCH  
 DIV OF RES SUPP, PATH SERV GP  
 SPECIES: RAT/FISCHER-344  
 STUDY START DATE: 23-JAN-84  
 STUDY NUMBER: GLP83009  
 PRINTED: 21-NOV-89  
 PAGE: 83

ANIMAL NUMBER: 41/PRETEST= 41 SEX: MALE DOSE GROUP: 1 SACRIFICE STATUS: SACRIFICED MORIBUND  
 DATE OF DEATH: 19-MAY-85 STUDY DAY OF DEATH: 483 STUDY WEEK OF DEATH: 69 TERMINAL BODY WEIGHT: 341.00 (GMS)  
 STUDY TYPE: CHRONIC/2 YR CARCINOGENIC

<< MICROSCOPIC TISSUE OBSERVATIONS >>  
 TISSUE / HISTOPATHOLOGIC FINDINGS DISTRIBUTION (SEVERITY) / SPECIAL COMMENTS

EYES & OPTIC N. .... TISSUE IS MISSING  
 EXTENSIVE ARTIFACTS MAKE EVALUATION OF EYES IMPOSSIBLE.

MEDIASTINUM ..... MISCELLANEOUS TISSUE  
 -M- PRESENCE OF METASTATIC SARCOMA SECONDARY NEOPLASM FROM ORGAN

ABDOMINAL CAVITY ..... MISCELLANEOUS TISSUE  
 A SARCOMA IS PRESENT IN SEVERAL AREAS OF THE ABDOMINAL CAVITY  
 AND ITS HISTOLOGIC APPEARANCE AND DIFFERENTIATION VARIES FROM  
 ONE AREA TO ANOTHER. IN SOME AREAS IT RESEMBLES FIBROSARCOMA  
 AND MASSON'S TRICHOME STAIN CONFIRMED THE PRESENCE OF COLLAGEN.  
 ELSEWHERE IT RESEMBLES RHABDOMYOSARCOMA, BUT SECTIONS STAINED  
 WITH PHOSPHOTUNGSTIC ACID-HEMATOXYLIN FAILED TO DEMONSTRATE  
 CROSS STRIATIONS IN TUMOR CELLS. IN ANOTHER AREA, THE TUMOR IS  
 HIGHLY VASCULARIZED, RESEMBLING HEMANGIOSARCOMA (SECTION #22).  
 (PRESENT)

-M- SARCOMA, CELLULAR DIFFERENTIATION UNSPECIFIED

DIAPHRAGM ..... MISCELLANEOUS TISSUE  
 -M- PRESENCE OF METASTATIC SARCOMA SECONDARY NEOPLASM FROM ORGAN

**Appendix J (cont.): PATHOLOGY INDIVIDUAL ANIMAL DATA**

LETTERMAN ARMY INSTITUTE OF RESEARCH  
 DIV OF RES SUPP, PATH SERV GP  
 SPECIES: RAT/FISCHER-344  
 ANIMAL NUMBER: 42/PRETEST#  
 DATE OF DEATH: 03-JAN-86  
 STUDY START DATE: 23-JAN-84  
 DOSE GROUP: 1  
 SEX: MALE  
 STUDY DAY OF DEATH: 712  
 SACRIFICE STATUS: SACRIFICED MORIBUND  
 STUDY WEEK OF DEATH: 102  
 TERMINAL BODY WEIGHT: 308.00 (GMS)  
 STUDY TYPE: CHRONIC/2 YR CARCINOGENIC

PRINTED: 21-NOV-89  
 PAGE: 84

ORGAN NAME  
 KEYWORDS / PHRASES  
 << G R O S S O R G A N O B S E R V A T I O N S >>  
 SEVERITY GROSS FREE-TEXT COMMENTS  
 SPLEEN ENLARGED (SPLENOMEGALY) MODERATE 5.5 X 2 X 2CM  
 LIVER ADHESION(S) PRESENT DIAPHRAGM, VENTRAL ABDOMINAL WALL, INTESTINES  
 LIVER PROMINENT LOBULAR MARKINGS PRESENT  
 LIVER GRANULAR SURFACE PRESENT  
 KIDNEY DISCOLORATION PRESENT  
 KIDNEY GRANULAR SURFACE PRESENT  
 PITUITARY GLAND ENLARGED MARKED 5 X 8MM, MOTTLED GRAY  
 GRAY/BROWN  
 PITTED

TISSUE / HISTOPATHOLOGIC FINDINGS  
 << M I C R O S C O P I C T I S S U E O B S E R V A T I O N S >>  
 DISTRIBUTION (SEVERITY) / SPECIAL COMMENTS

HEART  
 -CARDIOMYOPATHY  
 -MEDIAL HYPERTROPHY OF MUSCULAR ARTERIES  
 NOT SPECIFIED(MILD)  
 NOT SPECIFIED(MILD)  
 LUNGS  
 -MIMERIALIZATION OF PULMONARY ARTERIES  
 -W- LARGE GRANULAR LYMPHOCYTE LEUKEMIA, METASTATIC  
 NOT SPECIFIED(TRACE)  
 (PRESENT)  
 SPLEEN  
 -FIBROSIS CAPSULAR  
 -W- LARGE GRANULAR LYMPHOCYTE LEUKEMIA, METASTATIC  
 FOCAL(TRACE)  
 (PRESENT)  
 LYMPH NODES  
 -RED BLOOD CELLS, HEMOSIDERIN AND/OR ERYTHROPHAGOCYTOSIS WITHIN  
 MEDULLARY SINUSES  
 -REACTIVE HYPERPLASIA  
 THE REACTIVE HYPERPLASIA AND RBC'S IN MEDULLARY SINUSES WERE  
 FOUND IN CERVICAL LYMPH NODES ONLY.  
 NOT SPECIFIED (PRESENT)  
 NOT SPECIFIED (PRESENT)  
 LIVER  
 -COMPOUND RELATED INFLAMMATORY REACTION  
 -BILE DUCTULE EPITHELIAL HYPERPLASIA AND/OR CHOLANGIOFIBROSIS  
 NOT SPECIFIED (PRESENT)  
 NOT SPECIFIED(MILD)

Appendix J (cont.): PATHOLOGY INDIVIDUAL ANIMAL DATA

LETTERMAN ARMY INSTITUTE OF RESEARCH  
DIV OF RES SUPP, PATH SERV GP  
SPECIES: RAT/FISCHER-344

INDIVIDUAL ANIMAL DATA REPORT  
STUDY NUMBER: GLP83009  
STUDY START DATE: 23-JAN-64

PRINTED: 21-NOV-69  
PAGE: 85

STUDY TYPE: CHRONIC/2 YR CARCINOGENIC

ANIMAL NUMBER: 42/PRETEST= 42 SEX: MALE DOSE GROUP: 1 SACRIFICE STATUS: SACRIFICED MORIBUND  
DATE OF DEATH: 03-JAN-66 STUDY DAY OF DEATH: 712 STUDY WEEK OF DEATH: 102 TERMINAL BODY WEIGHT: 308.00 (GMS)

TISSUE / HISTOPATHOLOGIC FINDINGS << MICROSCOPIC TISSUE OBSERVATIONS >>  
DISTRIBUTION (SEVERITY) / SPECIAL COMMENTS

LIVER .....  
-FOCUS OF CELLULAR ALTERATION - BASOPHILIC ..... NOT SPECIFIED(TRACE)  
-HEPATOCTYIC VACUOLIZATION ..... DIFFUSE(MODERATE)  
-M- LARGE GRANULAR LYMPHOCYTE LEUKEMIA, METASTATIC (PRESENT)

KIDNEY ..... NOT SPECIFIED(MODERATE)  
-PROGRESSIVE RENAL DISEASE

TESTES ..... NOT SPECIFIED(MILD)  
-INTERSTITIAL CELL HYPERPLASIA

DUODENUM .....  
GROSS DESCRIPTION INDICATES ADHESION OF LIVER TO SMALL  
INTESTINE. HISTOLOGICAL EVIDENCE OF SMALL INTESTINAL ADHESION  
WAS NOT DEMONSTRATED ON ORIGINAL SECTIONS SUBMITTED OR ON  
RE-TRIM. THERE IS AMPLE DEMONSTRATION OF COMPOUND-RELATED  
INFLAMMATORY REACTION ON THE CAPSULE OF THE LIVER.

NOSE/TURBINATES ..... INFILTRATE ADJACENT NASO-LACRIMAL DUCT.  
-MIXED INFLAMMATORY CELL INFILTRATION, NASAL CAVITY, SINUSES, NOT SPECIFIED(MILD)  
TURBINATES, NASO-LACRIMAL DUCTS

ADRENAL ..... NOT SPECIFIED(TRACE)  
-FOCUS OF CELLULAR ALTERATION, VACUOLATED

PITUITARY GLAND ..... (PRESENT)  
-B- ADENOMA

EYES & OPTIC N. .....  
-CORNEAL VASCULARIZATION ..... DIFFUSE(MILD)  
-METAPLASTIC BONE FORMATION AND/OR MINERALIZATION, SCLERA NOT SPECIFIED (PRESENT)

WHOLE BODY ..... (PRESENT)  
-M- LARGE GRANULAR LYMPHOCYTTIC LEUKEMIA

DIAPHRAGM ..... MISCELLANEOUS TISSUE

Appendix J (cont.): PATHOLOGY INDIVIDUAL ANIMAL DATA

LETTERMAN ARMY INSTITUTE OF RESEARCH  
DIV OF RES SUPP, PATH SERV GP  
SPECIES: RAT/FISCHER-344

INDIVIDUAL ANIMAL DATA REPORT  
STUDY NUMBER: GLP83009  
STUDY START DATE: 23-JAN-84

PRINTED: 21-NOV-89  
PAGE: 86

STUDY TYPE: CHRONIC/2 YR CARCINOGENIC

ANIMAL NUMBER: 42/PRETEST=  
DATE OF DEATH: 03-JAN-86

42 SEX: MALE  
STUDY DAY OF DEATH: 712

DOSE GROUP: 1  
STUDY WEEK OF DEATH: 102

SACRIFICE STATUS: SACRIFICED MORIBUND  
TERMINAL BODY WEIGHT: 308.00 (GMS)

<< MICROSCOPIC TISSUE OBSERVATIONS >>  
DISTRIBUTION (SEVERITY) / SPECIAL COMMENTS

DIAPHRAGM ..... MISCELLANEOUS TISSUE NOT SPECIFIED (PRESENT)  
-COMPOUND RELATED INFLAMMATORY REACTION

Appendix J (cont.): PATHOLOGY INDIVIDUAL ANIMAL DATA

LETTERMAN ARMY INSTITUTE OF RESEARCH
DIV OF RES SUPP, PATH SERV GP
SPECIES: RAT/FISCHER-344
INDIVIDUAL ANIMAL DATA REPORT
STUDY NUMBER: GLP83009
STUDY START DATE: 23-JAN-84
STUDY TYPE: CHRONIC/2 YR CARCINOGENIC
PRINTED: 21-NOV-89
PAGE: 87

ANIMAL NUMBER: 43/PRETEST=
DATE OF DEATH: 24-JAN-86
DOSE GROUP: 1
SACRIFICE STATUS: SACRIFICED MORIBUND
STUDY WEEK OF DEATH: 105
TERMINAL BODY WEIGHT: 359.00 (GMS)

ORGAN NAME
KEYWORDS / PHRASES
GROSS ORGAN OBSERVATIONS
SEVERITY GROSS FREE-TEXT COMMENTS
EYES & OPTIC N.
PERITONEAL CAV.
STOMACH
PERITONEAL CAV.
SPLEEN
SPLEEN
LIVER
TESTES

CRUSTY MATERIAL, PERIORBITAL
FLUID-FILLED
DISTENDED
ADHESION(S)
ENLARGED (SPLENOMEGALY)
DISCOLORATION
ADHESION(S)
GROWTH(S) / MASS(ES)
PRESENT
PRESENT
MARKED
MODERATE
PRESENT
PRESENT
PRESENT
PRESENT
RED
36ML, RED
INVOLVES SEVERAL LOOPS OF SMALL INTESTINE
5 X 1 X 1CM
THREE AREAS, FOCAL, FIRM, WHITE, RAISED, .2-.3CM DIAMETER
DIAPHRAGM
BILATERAL, MULTIPLE VARIABLY SIZED, DARK RED/WHITE

TISSUE / HISTOPATHOLOGIC FINDINGS
MICROSCOPIC TISSUE
OBSERVATIONS
DISTRIBUTION (SEVERITY) / SPECIAL COMMENTS

ESOPHAGUS
-MECROHEMORRHAGIC ESOPHAGITIS
DIFFUSE(MARKED)
SALIVARY GLAND
-ATROPHY AND LOSS OF ACINAR TISSUE
DIFFUSE ATROPHY OF ACINAR TISSUE IS PRESENT IN PAROTID GLAND.
DIFFUSE(MILD)

HEART
-CARDIOMYOPATHY
-MEDIAL HYPERTROPHY OF MUSCULAR ARTERIES
NOT SPECIFIED(MILD)
NOT SPECIFIED(TRACE)

LUNGS
-MINERALIZATION OF PULMONARY ARTERIES
-PNEUMONIA, INTERSTITIAL, CHRONIC
NOT SPECIFIED(TRACE)
MULTI-FOCAL(MILD)

SPLEEN
-INFARCTION, CHRONIC
-N- LARGE GRANULAR LYMPHOCYTE LEUKEMIA, METASTATIC
-EXTRAMEDULLARY HEMATOPOIESIS
-N- PRESENCE OF METASTATIC SARCOMA
NOT SPECIFIED(MILD)
(PRESENT)
NOT SPECIFIED (PRESENT)
SECONDARY NEOPLASM FROM ORGAN

Appendix J (cont.): PATHOLOGY INDIVIDUAL ANIMAL DATA

LETTERMAN ARMY INSTITUTE OF RESEARCH  
DIV OF RES SUPP, PATH SERV 6P  
SPECIES: RAT/FISCHER-344

PRINTED: 21-NOV-89  
PAGE: 86

INDIVIDUAL ANIMAL DATA REPORT  
STUDY NUMBER: GLP63009  
STUDY START DATE: 23-JAN-84

STUDY TYPE: CHRONIC/2 YR CARCINOGENIC

ANIMAL NUMBER: 43/PRETEST-43 SEX: MALE DOSE GROUP: 1 SACRIFICE STATUS: SACRIFICED MORIBUND  
DATE OF DEATH: 24-JAN-86 STUDY DAY OF DEATH: 733 STUDY WEEK OF DEATH: 105 TERMINAL BODY WEIGHT: 359.00 (GMS)

TISSUE / HISTOPATHOLOGIC FINDINGS  
MICROSCOPIC TISSUE OBSERVATIONS  
DISTRIBUTION (SEVERITY) / SPECIAL COMMENTS

LYMPH NODES  
-RED BLOOD CELLS, MEMOSIDERIN AND/OR ERYTHROPHAGOCYTOSIS WITHIN MEDULLARY SINUSES  
-N- LARGE GRANULAR LYMPHOCYTE LEUKEMIA, METASTATIC  
-REACTIVE HYPERPLASIA  
(PRESENT)  
NOT SPECIFIED (PRESENT)

LIVER  
-COMPOUND RELATED INFLAMMATORY REACTION  
-BILE DUCTULE EPITHELIAL HYPERPLASIA AND/OR CHOLANGIOFIBROSIS  
-NECROSIS, PERIACINAR  
-N- PRESENCE OF METASTATIC SARCOMA  
NOT SPECIFIED (PRESENT)  
NOT SPECIFIED (MODERATE)  
MULTI-FOCAL(TRACE)  
SECONDARY NEOPLASM FROM ORGAN

KIDNEY  
-PROGRESSIVE RENAL DISEASE  
NOT SPECIFIED(MILD)

PROSTATE  
-CHRONIC PROSTATITIS  
-BENIGN HYPERPLASIA  
NOT SPECIFIED(TRACE)  
NOT SPECIFIED(TRACE)

SEMINAL VESICLE  
-GENERALIZED ATROPHY  
NOT SPECIFIED (PRESENT)

EDIDYMS  
-N- PRESENCE OF METASTATIC SARCOMA  
SECONDARY NEOPLASM FROM ORGAN

TESTES  
-B- INTERSTITIAL CELL ADENOMA  
(PRESENT)

PANCREAS  
-CHRONIC INFLAMMATION  
-N- PRESENCE OF METASTATIC SARCOMA  
DIFFUSE(TRACE)  
(PRESENT)



**Appendix J (cont.): PATHOLOGY INDIVIDUAL ANIMAL DATA**

LETTERMAN ARMY INSTITUTE OF RESEARCH  
 DIV OF RES SUPP, PATH SERV GP  
 SPECIES: RAT/FISCHER-344  
 INDIVIDUAL ANIMAL DATA REPORT  
 STUDY NUMBER: GLP83009  
 STUDY START DATE: 23-JAN-84  
 PRINTED: 21-NOV-89  
 PAGE: 89  
 STUDY TYPE: CHRONIC/2 YR CARCINOGENIC

ANIMAL NUMBER: 43/PRETEST= 43 SEX: MALE DOSE GROUP: 1 SACRIFICE STATUS: SACRIFICED MORIBUND  
 DATE OF DEATH: 24-JAN-86 STUDY DAY OF DEATH: 733 STUDY WEEK OF DEATH: 105 TERMINAL BODY WEIGHT: 359.00 (GMS)

← MICROSCOPIC TISSUE OBSERVATIONS →  
 TISSUE / HISTOPATHOLOGIC FINDINGS  
 DISTRIBUTION (SEVERITY) / SPECIAL COMMENTS

CECUM ..... METASTATIC SARCOMA PRESENT IN MESENTERY ADJACENT TO CECUM. THIS LESION IS CODED UNDER "ABDOMINAL CAVITY"

STOMACH .....  
 -ULCERATION, NON-GLANDULAR AREA .....  
 -MUCOSAL AND/OR SUBMUCOSAL EDEMA .....  
 MULTI-FOCAL (PRESENT)  
 DIFFUSE (PRESENT)

SCIATIC NERVE ..... TISSUE IS MISSING

TONGUE .....  
 -MEDIAL HYPERTROPHY AND MINERALIZATION OF MEDIUM-SIZED MUSCULAR ARTERIES ..... NOT SPECIFIED (PRESENT)

MAMMARY GLANDS .....  
 -HYPERPLASIA AND/OR HYPERTROPHY OF THE ACINAR TISSUE ..... NOT SPECIFIED (TRACE)  
 -GALACTOCELE(S) ..... NOT SPECIFIED (PRESENT)

NOSE/TURBINATES .....  
 -MIXED INFLAMMATORY CELL INFILTRATION, NASAL CAVITY, SINUSES, TURBINATES, NASO-LACRIMAL DUCTS ..... CELLULAR INFILTRATE IS ADJACENT NASO-LACRIMAL DUCT.  
 ..... NOT SPECIFIED (TRACE)

PITUITARY GLAND ..... TISSUE IS MISSING

EYES & OPTIC N. ....  
 -RETINAL ATROPHY AND/OR DEGENERATION, UNILATERAL OR BILATERAL ..... NOT SPECIFIED (MILD)  
 -METAPLASTIC BONE FORMATION AND/OR MINERALIZATION, SCLERA ..... NOT SPECIFIED (PRESENT)  
 -LENTICULAR DEGENERATIVE CHANGES COMPATIBLE WITH CATARACT ..... NOT SPECIFIED (PRESENT)

WHOLE BODY ..... LESIONS OF LGLL ARE VERY SUBTLE IN THIS CASE. A FEW NEOPLASTIC LYMPHOCYTES ARE PRESENT IN THE SPLEEN AND IN HEPATIC SINUSOIDS.  
 -M- LARGE GRANULAR LYMPHOCYTIC LEUKEMIA (PRESENT)

Appendix J (cont.): PATHOLOGY INDIVIDUAL ANIMAL DATA

LETTERMAN ARMY INSTITUTE OF RESEARCH  
DIV OF RES SUPP, PATH SERV GP  
SPECIES: RAT/FISCHER-344

INDIVIDUAL ANIMAL DATA REPORT  
STUDY NUMBER: GLP3009  
STUDY START DATE: 23-JAN-84

PRINTED: 21-NOV-89  
PAGE: 90

STUDY TYPE: CHRONIC/2 YR CARCINOGENIC

ANIMAL NUMBER: 43/PRETEST=

43 SEX: MALE

DOSE GROUP: 1

SACRIFICE STATUS: SACRIFICED MOR(BUND

DATE OF DEATH: 24-JAN-86

STUDY DAY OF DEATH: 733

STUDY WEEK OF DEATH: 105

TERMINAL BODY WEIGHT: 359.00 (GMS)

TISSUE / HISTOPATHOLOGIC FINDINGS  
--<< MICROSCOPIC TISSUE OBSERVATIONS >>  
DISTRIBUTION (SEVERITY) / SPECIAL COMMENTS

MEDIASTINUM ..... MISCELLANEOUS TISSUE  
INFLAMMATION INVOLVES BROWN FAT SURROUNDING THYMUS.  
-CHRONIC INFLAMMATION  
DIFFUSE(MILD)

ABDOMINAL CAVITY ..... MISCELLANEOUS TISSUE  
THERE IS NO LARGE TUMOR MASS IN THIS CASE YET SMALL MODULES OF  
SARCOMA ARE PRESENT IN SEVERAL LOCATIONS. IN MANY OF THESE  
LESIONS THERE IS INFILTRATION OF INFLAMMATORY CELLS INTO THE  
NEOPLASTIC TISSUE. TUMOR DIFFERENTIATION IS PRIMARILY THAT OF  
FIBROSARCOMA. IN SEVERAL AREAS THERE IS MATERIAL RESEMBLING  
OSTEOID.  
(PRESENT)

-M- SARCOMA, CELLULAR DIFFERENTIATION UNSPECIFIED  
DIAPHRAGM ..... MISCELLANEOUS TISSUE  
NOT SPECIFIED (PRESENT)  
-COMPOUND RELATED INFLAMMATORY REACTION

Appendix J (cont.): PATHOLOGY INDIVIDUAL ANIMAL DATA

LETTERMAN ARMY INSTITUTE OF RESEARCH  
 DIV OF RES SUPP, PATH SERV GP  
 SPECIES: RAT/FISCHER-344

INDIVIDUAL ANIMAL DATA REPORT  
 STUDY NUMBER: GLP83009  
 STUDY START DATE: 23-JAN-84

PRINTED: 21-NOV-89  
 PAGE: 92  
 STUDY TYPE: CHRONIC/2 YR CARCINOGENIC

ANIMAL NUMBER: 45/PRETEST-45  
 DATE OF DEATH: 30-JAN-86  
 SEX: MALE  
 DOSE GROUP: 1  
 SACRIFICE STATUS: FINAL SACRIFICE  
 STUDY WEEK OF DEATH: 106  
 TERMINAL BODY WEIGHT: 356.00 (GMS)

ORGAN NAME: << GROSS ORGAN OBSERVATIONS >>  
 KEYWORDS / PHRASES SEVERITY GROSS FREE-TEXT COMMENTS  
 TESTES GROWTH(S) / MASSES) PRESENT BILATERAL, MULTIPLE VARIABLY SIZED, YELLOW/BLACK  
 LIVER ADHESION(S) PRESENT DIAPHRAGM, STOMACH, INTESTINE, AND VENTRAL ABDOMINAL WALL  
 DUODENUM GROWTH(S) / MASSES) PRESENT .5CM DIAMETER, FIRM, WHITE, ATTACHED TO SEROSA

TISSUE / HISTOPATHOLOGIC FINDINGS << MICROSCOPIC TISSUE OBSERVATIONS >>  
 DISTRIBUTION (SEVERITY) / SPECIAL COMMENTS

HEART  
 -CARDIOMYOPATHY NOT SPECIFIED(MILD)

LUNGS  
 -FOCAL HYPERPLASTIC PROLIFERATION OF TYPE 2 ALVEOLAR EPITHELIAL NOT SPECIFIED(MILD)  
 CELLS WITH OR WITHOUT INFLAMMATORY CELL INFILTRATION

LYMPH NODES  
 -RED BLOOD CELLS, HEMOSIDERIN AND/OR ERYTHROPHAGOCYTOSIS WITHIN MEDULLARY SINUSES RBC'S AND PIGMENT NOTED IN MEDIASTINAL NODES ONLY.  
 NOT SPECIFIED (PRESENT)

LIVER  
 -COMPOUND RELATED INFLAMMATORY REACTION NOT SPECIFIED (PRESENT)  
 -BILE DUCTULE EPITHELIAL HYPERPLASIA AND/OR CHOLANGIOFIBROSIS NOT SPECIFIED(MILD)  
 -FOCUS OF CELLULAR ALTERATION - BASOPHILIC FOCAL(TRACE)  
 -HEPATOCTYIC VACUOLIZATION MULTI-FOCAL(TRACE)  
 -CYSTIC DEGENERATION NOT SPECIFIED (PRESENT)  
 -HEPATOCTYE COALESCING MICROVESICULAR (FATTY) CHANGE LEADING TO MULTI-FOCAL(TRACE)  
 NECROSIS AND MINERALIZATION

KIDNEY  
 -PROGRESSIVE RENAL DISEASE NOT SPECIFIED(MILD)

SEMINAL VESICLE  
 -GENERALIZED ATROPHY NOT SPECIFIED (PRESENT)

TESTES

Appendix J (cont.): PATHOLOGY INDIVIDUAL ANIMAL DATA

LETTERMAN ARMY INSTITUTE OF RESEARCH  
DIV OF RES SUPP, PATN SERV GP  
SPECIES: RAT/FISCHER-344

INDIVIDUAL ANIMAL DATA REPORT  
STUDY NUMBER: GLP83009

PRINTED: 21-NOV-89  
PAGE: 93

STUDY START DATE: 23-JAN-84

STUDY TYPE: CHRONIC/2 YR CARCINOGENIC

ANIMAL NUMBER: 45/PRETEST-45 SEX: MALE DOSE GROUP: 1 SACRIFICE STATUS: FINAL SACRIFICE  
DATE OF DEATH: 30-JAN-86 STUDY DAY OF DEATH: 739 STUDY WEEK OF DEATH: 106 TERMINAL BODY WEIGHT: 356.00 (GMS)

TISSUE / HISTOPATHOLOGIC FINDINGS << M I C R O S C O P I C T I S S U E O B S E R V A T I O N S >>  
DISTRIBUTION (SEVERITY) / SPECIAL COMMENTS

TESTES ..... (PRESENT)  
-B- INTERSTITIAL CELL ADENOMA

DUODENUM .....  
-M- PRESENCE OF METASTATIC SARCOMA SECONDARY NEOPLASM FROM ORGAN

PANCREAS ..... NOT SPECIFIED (TRACE)  
-ACINAR (EXOCRINE) ATROPHY

STOMACH ..... SEROSAL FIBROSIS AND ADHESION TO LIVER NOTED.  
-SEROSAL FIBROSIS NOT SPECIFIED (PRESENT)

PITUITARY GLAND ..... (PRESENT)  
-B- ADENOMA

ABDOMINAL CAVITY ..... MISCELLANEOUS TISSUE  
THE SARCOMA IS A SMALL LESION RESTRICTED TO THE WALL OF THE  
DUODENUM (SECTION # 12). IT IS A FAIRLY DIFFERENTIATED  
FIBROSARCOMA.  
-M- SARCOMA, CELLULAR DIFFERENTIATION UNSPECIFIED (PRESENT)

DIAPHRAGM ..... MISCELLANEOUS TISSUE  
-COMPOUND RELATED INFLAMMATORY REACTION NOT SPECIFIED (PRESENT)

Appendix J (cont.): PATHOLOGY INDIVIDUAL ANIMAL DATA

LETTERMAN ARMY INSTITUTE OF RESEARCH  
DIV OF RES SUPP, PATH SERV GP  
SPECIES: RAT/FISCHER-344  
INDIVIDUAL ANIMAL DATA REPORT  
STUDY NUMBER: GLP03009  
STUDY START DATE: 23-JAN-84  
PRINTED: 21-NOV-89  
PAGE: 94

ANIMAL NUMBER: 46/PRETEST= 46 SEX: MALE DOSE GROUP: 1 SACRIFICE STATUS: SACRIFICED MORIBUND  
DATE OF DEATH: 05-JUN-85 STUDY DAY OF DEATH: 500 STUDY WEEK OF DEATH: 72 TERMINAL BODY WEIGHT: 372.00 (GMS)  
STUDY TYPE: CHRONIC/2 YR CARCINOGENIC

ORGAN NAME << GROSS ORGAN OBSERVATIONS >>  
KEYWORDS / PHRASES SEVERITY GROSS FREE-TEXT COMMENTS  
ADHESION(S) PRESENT VENTRAL ABDOMINAL WALL  
FIBROUS ADHESION(S) PRESENT LEFT KIDNEY

TISSUE / HISTOPATHOLOGIC FINDINGS << MICROSCOPIC TISSUE OBSERVATIONS >>  
DISTRIBUTION (SEVERITY) / SPECIAL COMMENTS

- HEART ..... NOT SPECIFIED(MILD)
- CARDIOMYOPATHY ..... NOT SPECIFIED(TRACE)
- MEDIAL HYPERTROPHY OF MUSCULAR ARTERIES ..... NOT SPECIFIED(TRACE)
- SPLEEN ..... REACTIVE HYPERPLASIA IS IN CERVICAL NODE.
- FIBROSIS CAPSULAR ..... RBC'S AND HEUSIDERIN PRESENT IN MEDIASTINAL NODE.
- LYMPH NODES ..... NOT SPECIFIED (PRESENT)
- RED BLOOD CELLS, HEUSIDERIN AND/OR ERYTHROPHAGOCYTOSIS WITHIN MEDULLARY SINUSES ..... NOT SPECIFIED (PRESENT)
- REACTIVE HYPERPLASIA ..... NOT SPECIFIED (PRESENT)
- LIVER ..... NOT SPECIFIED (PRESENT)
- COMPOUND RELATED INFLAMMATORY REACTION ..... NOT SPECIFIED(MILD)
- BILE DUCTULE EPITHELIAL HYPERPLASIA AND/OR CHOLANGIOFIBROSIS ..... MULTI-FOCAL(TRACE)
- HEPATOCTYIC VACUOLIZATION ..... MULTI-FOCAL(TRACE)
- NECROSIS ..... NOT SPECIFIED(MILD)
- KIDNEY ..... NOT SPECIFIED (PRESENT)
- PROGRESSIVE RENAL DISEASE ..... NOT SPECIFIED (PRESENT)
- FIBROSIS, CAPSULE ..... NOT SPECIFIED(TRACE)
- PROSTATE ..... NOT SPECIFIED(TRACE)
- BENIGN HYPERPLASIA

Appendix J (cont.): PATHOLOGY INDIVIDUAL ANIMAL DATA

LETTERMAN ARMY INSTITUTE OF RESEARCH  
DIV OF RES SUPP, PATH SERV GP  
SPECIES: RAT/FISCHER-344

PRINTED: 21-NOV-89  
PAGE: 95

INDIVIDUAL ANIMAL DATA REPORT  
STUDY NUMBER: GLP83009  
STUDY START DATE: 23-JAN-84

STUDY TYPE: CHRONIC/2 YR CARCINOGENIC  
ANIMAL NUMBER: 46/PRETEST=  
DATE OF DEATH: 05-JUN-85

SEX: MALE DOSE GROUP: 1 SACRIFICE STATUS: SACRIFICED MORIBUND  
STUDY DAY OF DEATH: 500 STUDY WEEK OF DEATH: 72 TERMINAL BODY WEIGHT: 372.00 (GMS)

TISSUE OBSERVATIONS  
<< MICROSCOPIC TISSUE OBSERVATIONS >>  
DISTRIBUTION (SEVERITY) / SPECIAL COMMENTS

TESTES ..... INTERSTITIAL ADENOMA IS VERY SMALL AND PROBABLY GROSSLY UNDETECTABLE.

- INTERSTITIAL CELL HYPERPLASIA  
-B- INTERSTITIAL CELL ADENOMA (PRESENT)

PANCREAS ..... FOCAL(MILD)  
-CHRONIC INFLAMMATION (PRESENT)  
-B- ISLET CELL ADENOMA

ADRENAL ..... DIFFUSE(MILD)  
-LIPIDOSIS

**Appendix J (cont.): PATHOLOGY INDIVIDUAL ANIMAL DATA**

LETTERMAN ARMY INSTITUTE OF RESEARCH  
 DIV OF RES SUPP, PATH SERV GP  
 SPECIES: RAT/FISCHER-344  
 STUDY NUMBER: GLP83009  
 STUDY START DATE: 23-JAN-84  
 PRINTED: 21-NOV-89  
 PAGE: 96  
 STUDY TYPE: CHRONIC/2 YR CARCINOGENIC

INDIVIDUAL ANIMAL DATA REPORT  
 ANIMAL NUMBER: 47/PRETEST-  
 DATE OF DEATH: 30-JAN-86  
 SEX: MALE  
 DOSE GROUP: 1  
 SACRIFICE STATUS: FINAL SACRIFICE  
 STUDY WEEK OF DEATH: 106  
 TERMINAL BODY WEIGHT: 418.00 (GMS)

ORGAN NAME  
 KEYWORDS / PHRASES  
 GROSS ORGAN OBSERVATIONS  
 SEVERITY GROSS FREE-TEXT COMMENTS  
 KIDNEY  
 GRANULAR SURFACE  
 GROWTH(S) / MASS(ES)  
 DISCOLORATION  
 ADHESION(S)  
 DISCOLORATION  
 ADHESION(S)  
 TESTES  
 TRACHE  
 PRESENT  
 BILATERAL, MULTIPLE VARIABLY SIZED, YELLOW  
 SPLEEN  
 PRESENT  
 MULTI-FOCAL, WHITE, .2CM DIAMETER  
 LIVER  
 PRESENT  
 DIAPHRAGM, VENTRAL ABDOMINAL WALL, INTESTINES, STOMACH  
 PITUITARY GLAND  
 PRESENT  
 FOCAL, .2CM DIAMETER, BLACK  
 CECUM  
 PRESENT  
 LEFT LATERAL ABDOMINAL WALL  
 SM INTESTINE  
 PRESENT  
 SEVERAL LOOPS ADHERED TOGETHER AND RIGHT LATERAL  
 ABDOMINAL WALL

TISSUE / HISTOPATHOLOGIC FINDINGS  
 MICROSCOPIC TISSUE OBSERVATIONS  
 DISTRIBUTION (SEVERITY) / SPECIAL COMMENTS

THYROID GLANDS  
 -COLLOID CYST(S)  
 NOT SPECIFIED (PRESENT)

HEART  
 -CARDIOMYOPATHY  
 NOT SPECIFIED(MILD)

LYMPH NODES  
 -RED BLOOD CELLS, HEMOSIDERIN AND/OR ERYTHROPHAGOCYTOSIS WITHIN  
 MEDULLARY SINUSES  
 REACTIVE HYPERPLASIA  
 -DILATED AND/OR CYSTIC MEDULLARY SINUSES  
 NOT SPECIFIED (PRESENT)

LIVER  
 -COMPOUND RELATED INFLAMMATORY REACTION  
 -BILE DUCTULE EPITHELIAL HYPERPLASIA AND/OR CHOLANGIOFIBROSIS  
 -HEPATITIS  
 -FOCUS OF CELLULAR ALTERATION - BASOPHILIC  
 -BENIGN HYPERPLASTIC MODULE(S)  
 -FOCUS OF CELLULAR ALTERATION - EOSINOPHILIC CELLS  
 REACTIVE HYPERPLASIA AND DILATED SINUSOIDS NOTED IN CERVICAL  
 NODE. RBC'S AND PIGMENT ARE PRESENT IN MEDIASTINAL NODE.  
 NOT SPECIFIED (PRESENT)

Appendix J (cont.): PATHOLOGY INDIVIDUAL ANIMAL DATA

LETTERMAN ARMY INSTITUTE OF RESEARCH  
 DIV OF RES SUPP, PATH SERV GP  
 SPECIES: RAT/FISCHER-344

INDIVIDUAL ANIMAL DATA REPORT  
 STUDY NUMBER: GLP03009  
 STUDY START DATE: 23-JAN-84

PRINTED: 21-NOV-89  
 PAGE: 97

STUDY TYPE: CHRONIC/2 YR CARCINOGENIC

ANIMAL NUMBER: 47/PRETEST-  
 DATE OF DEATH: 30-JAN-86

DOSE GROUP: 1  
 STUDY WEEK OF DEATH: 106

SACRIFICE STATUS: FINAL SACRIFICE  
 TERMINAL BODY WEIGHT: 418.00 (GMS)

<< M I C R O S C O P I C T I S S U E O B S E R V A T I O N S >>  
 TISSUE / HISTOPATHOLOGIC FINDINGS

LIVER  
 -HEPATOCYTE COALESCING MICROVESICULAR (FATTY) CHANGE LEADING TO MULTI-FOCAL(TRACE)  
 NECROSIS AND MINERALIZATION

KIDNEY  
 -PROGRESSIVE RENAL DISEASE NOT SPECIFIED(MODERATE)

PROSTATE  
 -CHRONIC PROSTATITIS NOT SPECIFIED(MILD)  
 -BENIGN HYPERTROPHY NOT SPECIFIED(TRACE)

TESTES  
 -B- INTERSTITIAL CELL ADENOMA (PRESENT)

JEJUNUM  
 -COMPOUND RELATED INFLAMMATORY REACTION NOT SPECIFIED (PRESENT)

ILEUM  
 -COMPOUND RELATED INFLAMMATORY REACTION NOT SPECIFIED (PRESENT)

CECUM  
 -COMPOUND RELATED INFLAMMATORY REACTION NOT SPECIFIED (PRESENT)

MAMMARY GLANDS  
 -HYPERPLASIA AND/OR HYPERTROPHY OF THE ACINAR TISSUE NOT SPECIFIED(MILD)

NOSE/TURBINATES  
 -MIXED INFLAMMATORY CELL INFILTRATION, NASAL CAVITY, SINUSES, NOT SPECIFIED(MILD)  
 TURBINATES, MASO-LACRIMAL DUCTS

ADRENAL  
 -LIPIDOSIS NOT SPECIFIED(TRACE)

EYES & OPTIC N. NOT SPECIFIED(TRACE)

CELLULAR INFILTRATE IS BILATERAL AND INVOLVES MASO-LACRIMAL DUCTS.



Appendix J (cont.): PATHOLOGY INDIVIDUAL ANIMAL DATA

LETTERMAN ARMY INSTITUTE OF RESEARCH  
DIV OF RES SUPP, PATH SERV GP  
SPECIES: RAT/FISCHER-344

INDIVIDUAL ANIMAL DATA REPORT  
STUDY NUMBER: GLP83009  
STUDY START DATE: 23-JAN-84

PRINTED: 21-NOV-89  
PAGE: 98

STUDY TYPE: CHRONIC/2 YR CARCINOGENIC

ANIMAL NUMBER: 47/PRETEST# 47 SEX: MALE DOSE GROUP: 1 SACRIFICE STATUS: FINAL SACRIFICE  
DATE OF DEATH: 30-JAN-86 STUDY DAY OF DEATH: 739 STUDY WEEK OF DEATH: 106 TERMINAL BODY WEIGHT: 418.00 (GMS)

<< MICROSCOPIC TISSUE OBSERVATIONS >>  
TISSUE / HISTOPATHOLOGIC FINDINGS DISTRIBUTION (SEVERITY) / SPECIAL COMMENTS

EYES & OPTIC N. ....  
-METAPLASTIC BONE FORMATION AND/OR MINERALIZATION, SCLERA NOT SPECIFIED (PRESENT)  
-LENTICULAR DEGENERATIVE CHANGES COMPATIBLE WITH CATARACT NOT SPECIFIED (PRESENT)

DIAPHRAGM ..... MISCELLANEOUS TISSUE  
-COMPOUND RELATED INFLAMMATORY REACTION NOT SPECIFIED (PRESENT)

Appendix J (cont.): PATHOLOGY INDIVIDUAL ANIMAL DATA

LETTERMAN ARMY INSTITUTE OF RESEARCH  
 DIV OF RES SUPP, PATH SERV GP  
 SPECIES: RAT/FISCHER-344

INDIVIDUAL ANIMAL DATA REPORT  
 STUDY NUMBER: GLP83009

STUDY START DATE: 23-JAN-84

ANIMAL NUMBER: 48/PRETEST= 48 SEX: MALE DOSE GROUP: 1 SACRIFICE STATUS: FINAL SACRIFICE  
 DATE OF DEATH: 30-JAN-86 STUDY DAY OF DEATH: 739 STUDY WEEK OF DEATH: 106 TERMINAL BODY WEIGHT: 394.00 (GMS)

PRINTED: 21-NOV-89  
 PAGE: 99

STUDY TYPE: CHRONIC/2 YR CARCINOGENIC

ORGAN NAME	KEYWORDS / PHRASES	ORGAN OBSERVATIONS	SEVERITY	GROSS FREE-TEXT COMMENTS
PANCREAS	GROWTH(S) / MASS(ES)	PRESENT		.2CM DIAMETER, FOCAL, WHITE
SM INTESTINE	GROWTH(S)/MASS(S)	PRESENT		PEDUNCULATED, DARK, INTRALUMINAL, .5CM DIAMETER
LYMPH NODES	ENLARGED	PRESENT		GRAY, .7CM DIAMETER, MESENTERIC
LIVER	ADHESION(S)	PRESENT		DIAPHRAGM, VENTRAL ABDOMINAL WALL, SMALL INTESTINE
TESTES	GROWTH(S) / MASS(ES)	PRESENT		BILATERAL, MULTIPLE VARIABLY SIZED, WHITE/YELLOW

TISSUE / HISTOPATHOLOGIC FINDINGS  
 << MICROSCOPIC TISSUE OBSERVATIONS >>  
 DISTRIBUTION (SEVERITY) / SPECIAL COMMENTS

TRACHEA .....  
 -NON-SUPPURATIVE TRACHEITIS ..... FOCAL(TRACE)

PARATHYROID ..... TISSUE IS MISSING

EXORBITAL LACRIM ..... TISSUE IS MISSING

HEART .....  
 -CARDIOMYOPATHY ..... NOT SPECIFIED(MILD)

LYMPH NODES .....  
 REACTIVE HYPERPLASIA NOTED IN CERVICAL NODES.  
 MARKED REACTIVE HYPERPLASIA AND DILATED SINUSOIDS WITH FIBROSIS  
 IS PRESENT IN MESENTERIC NODES. PIGMENT IS PRESENT IN  
 MACROPHAGES IN MEDIASTINAL NODES.  
 NOT SPECIFIED (PRESENT)

-RED BLOOD CELLS, HEMOSIDERIN AND/OR ERYTHROPHAGOCYTOSIS WITHIN  
 MEDULLARY SINUSES  
 -REACTIVE HYPERPLASIA  
 -DILATED AND/OR CYSTIC MEDULLARY SINUSES  
 NOT SPECIFIED (PRESENT)  
 NOT SPECIFIED (PRESENT)

LIVER .....  
 -COMPOUND RELATED INFLAMMATORY REACTION  
 -BILE DUCTULE EPITHELIAL HYPERPLASIA AND/OR CHOLANGIOFIBROSIS  
 -HEPATITIS  
 MULTI-FOCAL(TRACE)

**Appendix J (cont.): PATHOLOGY INDIVIDUAL ANIMAL DATA**

LETTERMAN ARMY INSTITUTE OF RESEARCH  
 DIV OF RES SUPP, PATH SERV GP  
 SPECIES: RAT/FISCHER-344  
 STUDY START DATE: 23-JAN-84  
 STUDY NUMBER: GLP83009  
 PRINTED: 21-NOV-89  
 PAGE: 100  
 STUDY TYPE: CHRONIC/2 YR CARCINOGENIC

ANIMAL NUMBER: 48/PRETEST= 48 SEX: MALE DOSE GROUP: 1 SACRIFICE STATUS: FINAL SACRIFICE  
 DATE OF DEATH: 30-JAN-86 STUDY DAY OF DEATH: 739 STUDY WEEK OF DEATH: 106 TERMINAL BODY WEIGHT: 394.00 (GMS)

TISSUE / HISTOPATHOLOGIC FINDINGS << M I C R O S C O P I C T I S S U E O B S E R V A T I O N S >>  
 DISTRIBUTION (SEVERITY) / SPECIAL COMMENTS

- LIVER ..... MULTI-FOCAL(MILD)  
 -HEPATOCTYIC VACUOLIZATION ..... NOT SPECIFIED (PRESENT)  
 -CYSTIC DEGENERATION ..... FOCAL(TRACE)  
 -BENIGN HYPERPLASTIC MODULE(S)
- KIDNEY ..... NOT SPECIFIED(TRACE)  
 -PROGRESSIVE RENAL DISEASE
- PROSTATE ..... NOT SPECIFIED(MODERATE)  
 -CHRONIC PROSTATITIS ..... NOT SPECIFIED(TRACE)  
 -BENIGN HYPERPLASIA
- TESTES ..... (PRESENT)  
 -B- INTERSTITIAL CELL ADENOMA
- ILEUM ..... SECONDARY NEOPLASM FROM ORGAN  
 -N- PRESENCE OF METASTATIC SARCOMA ..... NOT SPECIFIED (PRESENT)  
 -MUCOSAL EROSION/ULCERATION
- PANCREAS ..... (PRESENT)  
 -B- ISLET CELL ADENOMA ..... NOT SPECIFIED (PRESENT)  
 -PERIARTERITIS NODOSA
- TONGUE ..... FOCAL(TRACE)  
 -PERIARTERITIS
- MAMMARY GLANDS ..... NOT SPECIFIED(TRACE)  
 -HYPERPLASIA AND/OR HYPERTROPHY OF THE ACINAR TISSUE ..... NOT SPECIFIED (PRESENT)  
 -DILATATION (ECTASIA) OF DUCTS AND DUCTULES
- BONE, STERNUM ..... NOT SPECIFIED (PRESENT)  
 -HYPERPLASIA, MYELOID
- BONE, FEMUR .....

Appendix J (cont.): PATHOLOGY INDIVIDUAL ANIMAL DATA

LETTERMAN ARMY INSTITUTE OF RESEARCH  
DIV OF RES SUPP, PATH SERV GP  
SPECIES: RAT/FISCHER-344

INDIVIDUAL ANIMAL DATA REPORT  
STUDY NUMBER: GLP83009  
STUDY START DATE: 23-JAN-84

PRINTED: 21-NOV-89  
PAGE: 101

STUDY TYPE: CHRONIC/2 YR CARCINOGENIC

ANIMAL NUMBER: 48/PRETEST-  
DATE OF DEATH: 30-JAN-86  
SEX: MALE  
DOSE GROUP: 1  
SACRIFICE STATUS: FINAL SACRIFICE  
STUDY DAY OF DEATH: 739  
STUDY WEEK OF DEATH: 106  
TERMINAL BODY WEIGHT: 394.00 (GMS)

TISSUE / HISTOPATHOLOGIC FINDINGS  
MICROSCOPIC TISSUE OBSERVATIONS  
DISTRIBUTION (SEVERITY) / SPECIAL COMMENTS

BONE, FEMUR  
-HYPERPLASIA MYELOID NOT SPECIFIED (PRESENT)

BONE VERT  
-HYPERPLASIA, MYELOID NOT SPECIFIED (PRESENT)

EYES & OPTIC N.  
-METAPLASTIC BONE FORMATION AND/OR MINERALIZATION, SCLERA NOT SPECIFIED (PRESENT)

ABDOMINAL CAVITY  
MISCELLANEOUS TISSUE  
SARCOMA LIMITED TO A FOCAL AREA IN THE ILEUM. DIFFERENTIATION IS POOR. THIS IS AN EARLY NEOPLASTIC CHANGE. (PRESENT)

-M- SARCOMA, CELLULAR DIFFERENTIATION UNSPECIFIED  
DIAPHRAGM  
-COMPOUND RELATED INFLAMMATORY REACTION MISCELLANEOUS TISSUE NOT SPECIFIED (PRESENT)

**Appendix J (cont.): PATHOLOGY INDIVIDUAL ANIMAL DATA**

LETTERMAN ARMY INSTITUTE OF RESEARCH  
 DIV OF RES SUPP, PATH SERV GP  
 SPECIES: RAT/FISCHER-344  
 STUDY START DATE: 23-JAN-84  
 STUDY NUMBER: GLP83009  
 PRINTED: 21-NOV-89  
 PAGE: 102  
 STUDY TYPE: CHRONIC/2 YR CARCINOGENIC

ANIMAL NUMBER: 49/PRETEST= 49 SEX: MALE DOSE GROUP: 1 SACRIFICE STATUS: FINAL SACRIFICE  
 DATE OF DEATH: 30-JAN-86 STUDY DAY OF DEATH: 739 STUDY WEEK OF DEATH: 106 TERMINAL BODY WEIGHT: 384.00 (GMS)

<< GROSS ORGAN OBSERVATIONS >>  
 SEVERITY GROSS FREE-TEXT COMMENTS  
 ENLARGED PRESENT BILATERAL, 2.5 X 1.5CM  
 GROWTH(S) / MASS(ES) PRESENT BILATERAL, MULTIPLE VARIABLY SIZED, YELLOW/BLACK  
 ADHESION(S) PRESENT VENTRAL ABDOMINAL WALL AND DIAPHRAGM

<< MICROSCOPIC TISSUE OBSERVATIONS >>  
 DISTRIBUTION (SEVERITY) / SPECIAL COMMENTS

HEART ..... NOT SPECIFIED(TRACE)  
 -CARDIOMY .....  
 LYMPH NODES ..... RBC'S PRESENT IN MESENTERIC NODE.  
 -RED BLOOD CELLS, HEMOSIDERIN AND/OR ERYTHROPHAGOCYTOSIS WITHIN .....  
 MEDULLARY SINUSES ..... NOT SPECIFIED (PRESENT)

LIVER .....  
 -COMPOUND RELATED INFLAMMATORY REACTION ..... NOT SPECIFIED (PRESENT)  
 -BILE DUCTULE EPITHELIAL HYPERPLASIA AND/OR CHOLANGIOFIBROSIS ..... NOT SPECIFIED(MILD)  
 -HEPATOCTYIC VACUOLIZATION ..... MULTI-FOCAL(TRACE)

KIDNEY .....  
 -PROGRESSIVE RENAL DISEASE ..... NOT SPECIFIED(MILD)

PROSTATE .....  
 -BENIGN HYPERPLASIA ..... NOT SPECIFIED(TRACE)

SEMINAL VESICLE .....  
 -GENERALIZED ATROPHY ..... NOT SPECIFIED (PRESENT)

TESTES .....  
 -B- INTERSTITIAL CELL ADENOMA ..... (PRESENT)

TONGUE .....

Appendix J (cont.): PATHOLOGY INDIVIDUAL ANIMAL DATA

LETTERMAN ARMY INSTITUTE OF RESEARCH  
DIV OF RES SUPP, PATH SERV GP  
SPECIES: RAT/FISCHER-344

INDIVIDUAL ANIMAL DATA REPORT  
STUDY NUMBER: GLP83009  
STUDY START DATE: 23-JAN-84

PRINTED: 21-NOV-89  
PAGE: 103

STUDY TYPE: CHRONIC/2 YR CARCINOGENIC

ANIMAL NUMBER: 49/PRETEST= 49 SEX: MALE DOSE GROUP: 1 SACRIFICE STATUS: FINAL SACRIFICE  
DATE OF DEATH: 30-JAN-86 STUDY DAY OF DEATH: 739 STUDY WEEK OF DEATH: 106 TERMINAL BODY WEIGHT: 364.00 (GMS)

<< MICROSCOPIC TISSUE OBSERVATIONS >>  
TISSUE / HISTOPATHOLOGIC FINDINGS DISTRIBUTION (SEVERITY) / SPECIAL COMMENTS

TONGUE ..... MULTI-FOCAL(MILD)  
-PERIARTERITIS

MAMMARY GLANDS ..... NOT SPECIFIED(MILO)  
-HYPERPLASIA AND/OR HYPERTROPHY OF THE ACINAR TISSUE

PITUITARY GLAND ..... (PRESENT)  
-B- ADENOMA

EYES & OPTIC N. .... NOT SPECIFIED (PRESENT)  
-METAPLASTIC BONE FORMATION AND/OR MINERALIZATION, SCLERA

DIAPHRAGM ..... MISCELLANEOUS TISSUE  
-COMPOUND RELATED INFLAMMATORY REACTION NOT SPECIFIED (PRESENT)

**Appendix J (cont.): PATHOLOGY INDIVIDUAL ANIMAL DATA**

LETTERMAN ARMY INSTITUTE OF RESEARCH  
 DIV OF RES SUPP, PATH SERV GP  
 SPECIES: RAT/FISCHER-344  
 INDIVIDUAL ANIMAL DATA REPORT  
 STUDY NUMBER: GLP83009  
 STUDY START DATE: 23-JAN-84  
 PRINTED: 21-NOV-89  
 PAGE: 104  
 STUDY TYPE: CHRONIC/2 YR CARCINOGENIC

ANIMAL NUMBER: 50/PRETEST-50  
 DATE OF DEATH: 05-NOV-85  
 SEX: MALE  
 DOSE GROUP: 1  
 SACRIFICE STATUS: SACRIFICED MORIBUND  
 STUDY WEEK OF DEATH: 94  
 TERMINAL BODY WEIGHT: 440.00 (GMS)

ORGAN NAME: << GROSS ORGAN OBSERVATIONS >>  
 KEYWORDS / PHRASES SEVERITY GROSS FREE-TEXT COMMENTS

TESTES ATROPHIC / SMALL, UNILATERALLY PRESENT RIGHT, 1.5 X 1.5CM  
 SEMINAL VESICLE TRANSPARENT, SOFT, FLACCID PRESENT  
 LIVER ADHESION(S) PRESENT  
 LIVER GROWTH(S) / MASS(ES) PRESENT  
 PERITONEAL CAV. ADHESION(S) PRESENT  
 DIAPHRAGM, VENTRAL ABDOMINAL WALL FIRM, WHITE, MEDIAL LOBE, 3 X 3 X 2CM, EXTENDS FROM VISCERAL SURFACE THROUGH THE DIAPHRAGM INTO THE THORACIC CAVITY.  
 SMALL INTESTINE LOOSELY ADHERED TO PERITONEUM

TISSUE / HISTOPATHOLOGIC FINDINGS << MICROSCOPIC TISSUE OBSERVATIONS >>  
 DISTRIBUTION (SEVERITY) / SPECIAL COMMENTS

HEART  
 -CARDIOMYOPATHY  
 -MEDIAL HYPERTROPHY OF MUSCULAR ARTERIES  
 NOT SPECIFIED(MILD)  
 NOT SPECIFIED(TRACE)

LUNGS  
 -M- PRESENCE OF METASTATIC SARCOMA  
 THE METASTATIC SARCOMA IS EMBEDDED IN, AND INVADING THE PLEURA. THERE IS NO PULMONARY PARENCHYMAL INVOLVEMENT IN LUNG SECTIONS EXAMINED.  
 SECONDARY NEOPLASM FROM ORGAN ABDOMINAL CAVITY  
 TISSUE IS MISSING

THYRUS  
 TISSUE IS MISSING

SPLEEN  
 LGLL IS EARLY AND CHANGES ARE SUBTLE. HOWEVER, RED PULP AREAS CONTAIN NUMEROUS NEOPLASTIC LYMPHOCYTES.  
 (PRESENT)

-M- LARGE GRANULAR LYMPHOCYTE LEUKEMIA, METASTATIC

LYMPH NODES  
 SEVERAL LYMPH NODES IN THE MEDIASTINUM CONTAIN NUMEROUS RBC'S. THE REACTIVE HYPERPLASIA IS IN MESENTERIC NODES.  
 NOT SPECIFIED (PRESENT)

-RED BLOOD CELLS, HEMOSIDERIN AND/OR ERYTHROPHAGOCYTOSIS WITHIN MEDULLARY SINUSES  
 -REACTIVE HYPERPLASIA  
 NOT SPECIFIED (PRESENT)

LIVER  
 -COMPOUND RELATED INFLAMMATORY REACTION  
 NOT SPECIFIED (PRESENT)  
 -BILE DUCTULE EPITHELIAL HYPERPLASIA AND/OR CHOLANGIOFIBROSIS  
 NOT SPECIFIED(MILD)

**Appendix J (cont.): PATHOLOGY INDIVIDUAL ANIMAL DATA**

LETTERMAN ARMY INSTITUTE OF RESEARCH  
 DIV OF RES SUPP, PATH SERV GP  
 SPECIES: RAT/FISCHER-344

INDIVIDUAL ANIMAL DATA REPORT  
 STUDY NUMBER: GLP83009  
 STUDY START DATE: 23-JAN-84

PRINTED: 21-NOV-89  
 PAGE: 105

STUDY TYPE: CHRONIC/2 YR CARCINOGENIC

ANIMAL NUMBER: 50/PRETEST= 50 SEX: MALE DOSE GROUP: 1  
 DATE OF DEATH: 05-NOV-85 STUDY DAY OF DEATH: 653 STUDY WEEK OF DEATH: 94

SACRIFICE STATUS: SACRIFICED MORIBUND  
 TERMINAL BODY WEIGHT: 440.00 (GMS)

<< M I C R O S C O P I C T I S S U E O B S E R V A T I O N S >>  
 TISSUE / HISTOPATHOLOGIC FINDINGS DISTRIBUTION (SEVERITY) / SPECIAL COMMENTS

- LIVER ..... (PRESENT)  
 -M- LARGE GRANULAR LYMPHOCYTE LEUKEMIA, METASTATIC  
 -N- PRESENCE OF METASTATIC SARCOMA  
 SECONDARY NEOPLASM FROM ORGAN ABDOMINAL CAVITY
- KIDNEY ..... NOT SPECIFIED(MILD)  
 -PROGRESSIVE RENAL DISEASE
- SEMINAL VESICLE ..... NOT SPECIFIED (PRESENT)  
 -GENERALIZED ATROPHY
- TESTES ..... (PRESENT)  
 -B- INTERSTITIAL CELL ADENOMA
- PANCREAS ..... FOCAL(TRACE)  
 -ACINAR (EXOCRINE) ATROPHY
- CECUM ..... TISSUE IS MISSING
- RECTUM ..... TISSUE IS MISSING
- COLON ..... TISSUE IS MISSING
- MAMMARY GLANDS ..... NOT SPECIFIED(TRACE)  
 -HYPERPLASIA AND/OR HYPERTROPHY OF THE ACINAR TISSUE  
 FOCAL (PRESENT)
- NOSE/TURBINATES ..... CELLULAR INFILTRATE INVOLVES NASO-LACRIMAL DUCTS BILATERALLY.  
 -MIXED INFLAMMATORY CELL INFILTRATION, NASAL CAVITY, SINUSES, NOT SPECIFIED(MILD)  
 TURBINATES, NASO-LACRIMAL DUCTS
- ADRENAL ..... DIFFUSE(TRACE)  
 -LIPIDOSIS
- EYES & OPTIC N. ....



Appendix J (cont.): PATHOLOGY INDIVIDUAL ANIMAL DATA

LETTERMAN ARMY INSTITUTE OF RESEARCH  
DIV OF RES SUPP, PATH SERV GP  
SPECIES: RAT/FISCHER-344

INDIVIDUAL ANIMAL DATA REPORT  
STUDY NUMBER: GLP83009  
STUDY START DATE: 23-JAN-84

PRINTED: 21-NOV-89  
PAGE: 106

STUDY TYPE: CHRONIC/2 YR CARCINOGENIC

ANIMAL NUMBER: 50/PRETEST-      DOSE GROUP: 1      SACRIFICE STATUS: SACRIFICED MORIBUND  
DATE OF DEATH: 05-NOV-85      STUDY DAY OF DEATH: 653      STUDY WEEK OF DEATH: 94      TERMINAL BODY WEIGHT: 440.00 (GMS)

<< MICROSCOPIC TISSUE OBSERVATIONS >>  
TISSUE / HISTOPATHOLOGIC FINDINGS      DISTRIBUTION (SEVERITY) / SPECIAL COMMENTS

EYES & OPTIC N.      .....      NOT SPECIFIED (PRESENT)  
-METAPLASTIC BONE FORMATION AND/OR MINERALIZATION, SCLERA

WHOLE BODY      .....      (PRESENT)  
-M- LARGE GRANULAR LYMPHOCYTTIC LEUKEMIA

MEDIASTINUM      .....      MISCELLANEOUS TISSUE  
SARCOMA IS PRESENT IN MEDIASTINAL FAT ADJACENT TO THE THYMUS.  
-M- PRESENCE OF METASTATIC SARCOMA      .....      SECONDARY NEOPLASM FROM ORGAN ABDOMINAL CAVITY

ABDOMINAL CAVITY      .....      MISCELLANEOUS TISSUE  
THE SARCOMA INVOLVES PRIMARILY THE LIVER. IT IS HIGHLY  
-M- SARCOMA, CELLULAR DIFFERENTIATION UNSPECIFIED      .....      ANAPLASTIC. IN SOME AREAS IT RESEMBLES RHABDOMYOSARCOMA. IN  
ANOTHER AREA IT IS MYXOMATOUS.  
(PRESENT)

Appendix J (cont.): PATHOLOGY INDIVIDUAL ANIMAL DATA

LETTERMAN ARMY INSTITUTE OF RESEARCH  
 DIV OF RES SUPP, PATH SERV GP  
 SPECIES: RAT/FISCHER-344

INDIVIDUAL ANIMAL DATA REPORT  
 STUDY NUMBER: GLP83009  
 STUDY START DATE: 23-JAN-84

PRINTED: 21-NOV-89  
 PAGE: 108  
 STUDY TYPE: CHRONIC/2 YR CARCINOGENIC

ANIMAL NUMBER: 52/PRETEST-52 SEX: MALE DOSE GROUP: 1 SACRIFICE STATUS: SACRIFICED MORIBUND  
 DATE OF DEATH: 30-AUG-85 STUDY DAY OF DEATH: 586 STUDY WEEK OF DEATH: 84 TERMINAL BODY WEIGHT: 418.00 (GMS)

ORGAN NAME	KEYWORDS / PHRASES	GROSS ORGAN OBSERVATIONS	SEVERITY	GROSS FREE-TEXT COMMENTS
LUNGS	MEMORRHAGE(S)		PRESENT	MULTIFOCAL, PETICHIAL
TESTES	ENLARGED		PRESENT	LEFT
TESTES	GROWTH(S) / MASS(ES)		PRESENT	LEFT, COALESCING, IRREGULAR, YELLOW/WHITE, SURROUNDED BY CLEAR YELLOW FLUID.
SPLEEN	ENLARGED (SPLENOHEGALY)		MARKED	9 X 3 X 1CM
LIVER	ADHESION(S)		PRESENT	DIAPHRAGM
LIVER	PROMINENT LOBULAR MARKINGS		PRESENT	ENLARGED
LIVER	DISCOLORATION		PRESENT	YELLOW MOTTLED
KIDNEY	DISCOLORATION		PRESENT	DIFFUSELY BROWN
PERITONEAL CAV.	ADHESION(S)		PRESENT	SECTION OF SMALL INTESTINE ADHERED TO PERITONEAL WALL AND LIVER.

TISSUE / HISTOPATHOLOGIC FINDINGS  
 << MICROSCOPIC TISSUE OBSERVATIONS >>  
 DISTRIBUTION (SEVERITY) / SPECIAL COMMENTS

PARATHYROID ..... TISSUE IS MISSING

HEART .....  
 -CARDIOMYOPATHY ..... NOT SPECIFIED(MODERATE)  
 -MEDIAL HYPERTROPHY OF MUSCULAR ARTERIES ..... NOT SPECIFIED(TRACE)

LUNGS .....  
 -W- LARGE GRANULAR LYMPHOCYTE LEUKEMIA, METASTATIC ..... (PRESENT)  
 -ALVEOLAR HEMORRHAGE ..... MULTI-FOCAL (PRESENT)

SPLEEN .....  
 -W- LARGE GRANULAR LYMPHOCYTE LEUKEMIA, METASTATIC ..... (PRESENT)

LYMPH NODES .....  
 -RED BLOOD CELLS, HEMOSIDERIN AND/OR ERYTHROPHAGOCYTOSIS WITHIN ..... REACTIVE HYPERPLASIA AND RBC'S NOTED IN MEDIASTINAL NODES.  
 MEDULLARY SINUSES ..... NOT SPECIFIED (PRESENT)  
 -REACTIVE HYPERPLASIA ..... NOT SPECIFIED (PRESENT)

LIVER .....

**Appendix J (cont.): PATHOLOGY INDIVIDUAL ANIMAL DATA**

LETTERMAN ARMY INSTITUTE OF RESEARCH  
 DIV OF RES SUPP, PATH SERV GP  
 SPECIES: RAT/FISCHER-344  
 STUDY START DATE: 23-JAN-84  
 STUDY NUMBER: GLP83009  
 PRINTED: 21-NOV-89  
 PAGE: 109  
 STUDY TYPE: CHRONIC/2 YR CARCINOGENIC  
 ANIMAL NUMBER: 52/PRETEST= 52 SEX: MALE DOSE GROUP: 1 SACRIFICE STATUS: SACRIFICED MORIBUND  
 DATE OF DEATH: 30-AUG-85 STUDY DAY OF DEATH: 586 STUDY WEEK OF DEATH: 84 TERMINAL BODY WEIGHT: 418.00 (GMS)  
 << M I C R O S C O P I C T I S S U E O B S E R V A T I O N S >>  
 TISSUE / HISTOPATHOLOGIC FINDINGS DISTRIBUTION (SEVERITY) / SPECIAL COMMENTS

LIVER ..... NOT SPECIFIED (PRESENT)  
 -COMPOUND RELATED INFLAMMATORY REACTION NOT SPECIFIED (MILD)  
 -BILE DUCTULE EPITHELIAL HYPERPLASIA AND/OR CHOLANGIOFIBROSIS NOT SPECIFIED (PRESENT)  
 -CYSTIC DEGENERATION DIFFUSE (MILD)  
 -HEPATOCTYIC DEGENERATIVE CHANGES (NON-NECROTIC) MULTI-FOCAL (TRACE)  
 -NECROSIS, HEPATOCTYIC, INDIVIDUAL CELLS FOCAL (TRACE)  
 -BENIGN HYPERPLASTIC NODULE(S) (PRESENT)  
 -N- LARGE GRANULAR LYMPHOCYTE LEUKEMIA, METASTATIC

KIDNEY ..... NOT SPECIFIED (MILD)  
 -PROGRESSIVE RENAL DISEASE

PROSTATE ..... NOT SPECIFIED (TRACE)  
 -CHRONIC PROSTATITIS NOT SPECIFIED (TRACE)  
 -BENIGN HYPERPLASIA

TESTES ..... (PRESENT)  
 -B- INTERSTITIAL CELL ADENOMA

JEJUNUM ..... NOT SPECIFIED (PRESENT)  
 -FIBROVASCULAR ADHESION, SEROSA

SKIN ..... NOT SPECIFIED (PRESENT)  
 -INFLAMMATION, NOT OTHERWISE SPECIFIED, PREPUTIAL GLAND

ADRENAL ..... NOT SPECIFIED (PRESENT)  
 -CORTICAL NODULAR HYPERPLASIA  
 -N- LARGE GRANULE LYMPHOCYTE LEUKEMIA, METASTATIC (PRESENT)

WHOLE BODY ..... (PRESENT)  
 -M- LARGE GRANULAR LYMPHOCYTTIC LEUKEMIA

DIAPHRAGM ..... MISCELLANEOUS TISSUE

Appendix J (cont.): PATHOLOGY INDIVIDUAL ANIMAL DATA

LETTERMAN ARMY INSTITUTE OF RESEARCH  
DIV OF RES SUPP, PATH SERV GP  
SPECIES: RAT/FISCHER-344

INDIVIDUAL ANIMAL DATA REPORT  
STUDY NUMBER: GLP83009

PRINTED: 21-NOV-89  
PAGE: 110

STUDY START DATE: 23-JAN-84

STUDY TYPE: CHRONIC/2 YR CARCINOGENIC

ANIMAL NUMBER: 52/PRETEST=  
DATE OF DEATH: 30-AUG-85

52 SEX: MALE  
STUDY DAY OF DEATH: 586

DOSE GROUP: 1  
STUDY WEEK OF DEATH: 84

SACRIFICE STATUS: SACRIFICED MORIBUND  
TERMINAL BODY WEIGHT: 418.00 (GMS)

TISSUE / HISTOPATHOLOGIC FINDINGS  
--<< MICROSCOPIC TISSUE OBSERVATIONS -->>  
DISTRIBUTION (SEVERITY) / SPECIAL COMMENTS

DIAPHRAGM ..... MISCELLANEOUS TISSUE  
-COMPOUND RELATED INFLAMMATORY REACTION ..... NOT SPECIFIED (PRESENT)

**Appendix J (cont.): PATHOLOGY INDIVIDUAL ANIMAL DATA**

LETTERMAN ARMY INSTITUTE OF RESEARCH  
 DIV OF RES SUPP, PATH SERV GP  
 SPECIES: RAT/FISCHER-344  
 INDIVIDUAL ANIMAL DATA REPORT  
 STUDY NUMBER: GLP83009  
 STUDY START DATE: 23-JAN-84  
 PRINTED: 21-NOV-89  
 PAGE: 111  
 STUDY TYPE: CHRONIC/2 YR CARCINOGENIC

ANIMAL NUMBER: 53/PRETEST#  
 DATE OF DEATH: 03-FEB-86  
 SEX: MALE  
 DOSE GROUP: 1  
 SACRIFICE STATUS: FINAL SACRIFICE  
 STUDY DAY OF DEATH: 743  
 STUDY WEEK OF DEATH: 107  
 TERMINAL BODY WEIGHT: 394.00 (GMS)

ORGAN NAME  
 KEYWORDS / PHRASES  
 GROSS ORGAN OBSERVATIONS  
 SEVERITY GROSS FREE-TEXT COMMENTS

KIDNEY  
 TESTES  
 TESTES  
 TESTES  
 LYMPH NODES  
 LIVER  
 LIVER

GRANULAR SURFACE  
 ENLARGED  
 ATROPHIC / SMALL, UNILATERALLY  
 GROWTH(S) / MASS(ES)  
 ENLARGED  
 ADHESION(S)  
 MODULE(S)

MILD  
 PRESENT  
 PRESENT  
 PRESENT  
 PRESENT  
 PRESENT  
 PRESENT

LEFT, 3 X 1.75CM  
 RIGHT, 1 X .75CM  
 LEFT, MULTIPLE VARIABLY SIZED, YELLOW/BLACK  
 CERVICAL, REDDISH, .4CM DIAMETER  
 DIAPHRAGM, VENTRAL ABDOMINAL WALL  
 .7CM DIAMETER

TISSUE / HISTOPATHOLOGIC FINDINGS  
 MICROCOPIC TISSUE  
 OBSERVATIONS  
 DISTRIBUTION (SEVERITY) / SPECIAL COMMENTS

THYROID GLANDS  
 -COLLOID CYST(S)

HEART  
 -CARDIOMYOPATHY

LIVER  
 -COMPOUND RELATED INFLAMMATORY REACTION  
 -BILE DUCTULE EPITHELIAL HYPERPLASIA AND/OR CHOLANGIOFIBROSIS  
 -HEPATITIS  
 -FOCUS OF CELLULAR ALTERATION - BASOPHILIC  
 -BENIGN HYPERPLASTIC MODULE(S)  
 -FOCUS OF CELLULAR ALTERATION - EOSINOPHILIC CELLS

KIDNEY  
 -PROGRESSIVE RENAL DISEASE

PROSTATE  
 -CHRONIC PROSTATITIS

NOT SPECIFIED (PRESENT)  
 THE FOCAL AREA OF DISCOLORATION NOTED IN THE RIGHT VENTRICLE DURING TISSUE TRIMMING IS AN AREA OF FIBROSIS. THIS IS PROBABLY A MANIFESTATION OF ADVANCED CARDIOMYOPATHY.  
 NOT SPECIFIED(MODERATE)  
 NOT SPECIFIED (PRESENT)  
 NOT SPECIFIED(MODERATE)  
 MULTI-FOCAL(TRACE)  
 NOT SPECIFIED(TRACE)  
 NOT SPECIFIED(TRACE)  
 NOT SPECIFIED(MILD)  
 NOT SPECIFIED(MARKED)  
 NOT SPECIFIED(TRACE)

Appendix J (cont.): PATHOLOGY INDIVIDUAL ANIMAL DATA

LETTERMAN ARMY INSTITUTE OF RESEARCH  
DIV OF RES SUPP, PATH SERV GP  
SPECIES: RAT/FISCHER-344

INDIVIDUAL ANIMAL DATA REPORT  
STUDY NUMBER: GLP83009  
STUDY START DATE: 23-JAN-84

PRINTED: 21-NOV-89  
PAGE: 112

STUDY TYPE: CHRONIC/2 YR CARCINOGENIC

ANIMAL NUMBER: 53/PRETEST# 53 SEX: MALE DOSE GROUP: 1 SACRIFICE STATUS: FINAL SACRIFICE  
DATE OF DEATH: 03-FEB-86 STUDY DAY OF DEATH: 743 STUDY WEEK OF DEATH: 107 TERMINAL BODY WEIGHT: 394.00 (GMS)

TISSUE / HISTOPATHOLOGIC FINDINGS << MICROSCOPIC TISSUE OBSERVATIONS >>  
DISTRIBUTION (SEVERITY) / SPECIAL COMMENTS

PROSTATE ..... NOT SPECIFIED(TRACE)  
-BENIGN HYPERPLASIA

TESTES ..... (PRESENT)  
-B- INTERSTITIAL CELL ADENOMA

PANCREAS ..... FOCAL(MILD)  
-CHRONIC INFLAMMATION (PRESENT)  
-B- ISLET CELL ADENOMA

NOSE/TURBINATES ..... THE INFLAMMATORY CELL INFILTRATE INVOLVES NASO-LACRIMAL DUCTS  
BILATERALLY  
-MIXED INFLAMMATORY CELL INFILTRATION, NASAL CAVITY, SINUSES, NOT SPECIFIED(MILD)  
TURBINATES, NASO-LACRIMAL DUCTS

ADRENAL ..... NOT SPECIFIED(TRACE)  
-FOCUS OF CELLULAR ALTERATION, VACUOLATED

PITUITARY GLAND ..... NOT SPECIFIED (PRESENT)  
-CYST(S)

EYES & OPTIC N. .... NOT SPECIFIED (PRESENT)  
-METAPLASTIC BONE FORMATION AND/OR MINERALIZATION, SCLERA

ABDOMINAL CAVITY ..... MISCELLANEOUS TISSUE  
THERE IS NO GROSS OR HISTOLOGIC LESION THAT CORRESPONDS TO THE  
"LARGE INTRA-ABDOMINAL MASS" NOTED CLINICALLY. THIS FINDING MAY  
BE EXPLAINED BY THE ADHESION OF THE LIVER TO THE VENTRAL  
ABDOMINAL WALL DESCRIBED GROSSLY.

**Appendix J (cont.): PATHOLOGY INDIVIDUAL ANIMAL DATA**

LETTERMAN ARMY INSTITUTE OF RESEARCH  
 DIV OF RES SUPP, PATH SERV GP  
 SPECIES: RAT/FISCHER-344  
 STUDY NUMBER: GLP83009  
 STUDY START DATE: 23-JAN-84  
 STUDY TYPE: CHRONIC/2 YR CARCINOGENIC  
 PRINTED: 21-NOV-89  
 PAGE: 113

ANIMAL NUMBER: 54/PRETEST-  
 DATE OF DEATH: 03-FEB-86  
 STUDY DAY OF DEATH: 743  
 SEX: MALE  
 DOSE GROUP: 1  
 SACRIFICE STATUS: FINAL SACRIFICE  
 STUDY WEEK OF DEATH: 107  
 TERMINAL BODY WEIGHT: 379.00 (GMS)

ORGAN NAME  
 EYES & OPTIC N.  
 LIVER  
 TESTES  
 GROSS ORGAN OBSERVATIONS  
 SEVERITY GROSS FREE-TEXT COMMENTS  
 PRESENT RIGHT  
 PRESENT STOMACH, DIAPHRAGM, VENTRAL ABDOMINAL WALL  
 PRESENT BILATERAL, MULTIPLE VARIABLY SIZED, YELLOW

TISSUE / HISTOPATHOLOGIC FINDINGS  
 << MICROSCOPIC TISSUE OBSERVATIONS >>  
 DISTRIBUTION (SEVERITY) / SPECIAL COMMENTS

- HEART ..... NOT SPECIFIED(MODERATE)
- CARDIOMYOPATHY
- LUNGS ..... NOT SPECIFIED(TRACE)
- MINERALIZATION OF PULMONARY ARTERIES
- SPLEEN ..... NOT SPECIFIED(TRACE)
- INFARCTION, CHRONIC
- LIVER ..... NOT SPECIFIED (PRESENT)
- COMPOUND RELATED INFLAMMATORY REACTION  
 -BILE DUCTULE EPITHELIAL HYPERPLASIA AND/OR CHOLANGIOFIBROSIS  
 -HEPATITIS  
 -CYSTIC DEGENERATION  
 MULTI-FOCAL(MILD)  
 FOCAL (PRESENT)
- KIDNEY ..... NOT SPECIFIED(MILD)
- PROGRESSIVE RENAL DISEASE
- SEMINAL VESICLE ..... NOT SPECIFIED (PRESENT)
- GENERALIZED ATROPHY
- TESTES ..... (PRESENT)
- B- INTERSTITIAL CELL ADENOMA
- DUODENUM .....

**Appendix J (cont.): PATHOLOGY INDIVIDUAL ANIMAL DATA**

LETTERMAN ARMY INSTITUTE OF RESEARCH  
 DIV OF RES SUPP, PATH SERV GP  
 SPECIES: RAT/FISCHER-344  
 STUDY START DATE: 23-JAN-84  
 INDIVIDUAL ANIMAL DATA REPORT  
 STUDY NUMBER: GLP83009  
 PRINTED: 21-NOV-89  
 PAGE: 114  
 STUDY TYPE: CHRONIC/2 YR CARCINOGENIC

ANIMAL NUMBER: 54/PRETEST= 54 SEX: MALE DOSE GROUP: 1 SACRIFICE STATUS: FINAL SACRIFICE  
 DATE OF DEATH: 03-FEB-86 STUDY DAY OF DEATH: 743 STUDY WEEK OF DEATH: 107 TERMINAL BODY WEIGHT: 379.00 (GMS)

<< MICROSCOPIC TISSUE OBSERVATIONS >>  
 TISSUE / HISTOPATHOLOGIC FINDINGS DISTRIBUTION (SEVERITY) / SPECIAL COMMENTS

DUODENUM ..... NOT SPECIFIED (PRESENT)  
 -COMPOUND RELATED INFLAMMATORY REACTION

JEJUNUM ..... NOT SPECIFIED (PRESENT)  
 -COMPOUND RELATED INFLAMMATORY REACTION

PANCREAS ..... NOT SPECIFIED (TRACE)  
 -ACINAR (EXOCRINE) ATROPHY

COLON ..... NOT SPECIFIED (PRESENT)  
 -COMPOUND RELATED INFLAMMATORY REACTION

STOMACH ..... FOCAL (PRESENT)  
 -SEROSAL FIBROSIS (PRESENT)  
 -B- SQUAMOUS CELL PAPILLOMA

SKIN ..... TISSUE IS MISSING  
 NOSE/TURBINATES ..... INFLAMMATORY INFILTRATE IS ADJACENT NASO-LACRIMAL DUCTS  
 BILATERALLY.  
 -MIXED INFLAMMATORY CELL INFILTRATION, NASAL CAVITY, SINUSES,  
 TURBINATES, NASO-LACRIMAL DUCTS NOT SPECIFIED (MILD)

ADRENAL ..... NOT SPECIFIED (PRESENT)  
 -CORTICAL NODULAR HYPERPLASIA

EYES & OPTIC N. .... DEGENERATIVE CHANGES IN LENS AND RETINAL ARE LIMITED TO ONE  
 EYE (SECTION 198)  
 -RETINAL ATROPHY AND/OR DEGENERATION, UNILATERAL OR BILATERAL  
 NOT SPECIFIED (MARKED)  
 -METAPLASTIC BONE FORMATION AND/OR MINERALIZATION, SCLERA  
 NOT SPECIFIED (PRESENT)  
 -LENTICULAR DEGENERATIVE CHANGES COMPATIBLE WITH CATARACT  
 NOT SPECIFIED (PRESENT)

DIAPHRAGM ..... MISCELLANEOUS TISSUE  
 -COMPOUND RELATED INFLAMMATORY REACTION NOT SPECIFIED (PRESENT)



Appendix J (cont.): **PATHOLOGY INDIVIDUAL ANIMAL DATA**

LETTERMAN ARMY INSTITUTE OF RESEARCH  
 DIV OF RES SUPP, PATH SERV GP  
 SPECIES: RAT/FISCHER-344

INDIVIDUAL ANIMAL DATA REPORT  
 STUDY NUMBER: GLP83009  
 STUDY START DATE: 23-JAN-84

PRINTED: 21-NOV-89  
 PAGE: 115  
 STUDY TYPE: CHRONIC/2 YR CARCINOGENIC

ANIMAL NUMBER: 55/PRETEST# 55 SEX: MALE DOSE GROUP: 1 SACRIFICE STATUS: FOUND DEAD  
 DATE OF DEATH: 09-MAY-85 STUDY DAY OF DEATH: 473 STUDY WEEK OF DEATH: 68 TERMINAL BODY WEIGHT: 354.00 (GMS)

<< GROSS ORGAN OBSERVATIONS >>  
 SEVERITY GROSS FREE-TEXT COMMENTS

PERTONEAL CAV.	FLUID-FILLED	PRESENT	3-4ML DARK RED
SPLEEN	ENLARGED (SPLENOHEGALY)	MARKED	7 X 2 X 1CM
SPLEEN	PROMINENT FIBROUS CAPSULE	MILD	
SPLEEN	FRACTURED	PRESENT	IN MIDBODY OF MESENTERIC SURFACE WITH CLOTTED BLOOD IN
LIVER	PROMINENT LOBULAR MARKINGS	PRESENT	
LIVER	ENLARGED	MILD	
LIVER	ADHESION(S)	PRESENT	DIAPHRAGM, VENTRAL ABDOMINAL WALL, IMTESTINES
TESTES	ATROPHIC / SMALL, UNILATERALLY	PRESENT	1.5 X 1CM, RIGHT
TESTES	GROWTH(S) / MASS(ES)	PRESENT	ONE, WHITE, SUBCAPSULAR, .1CM DIAMETER, WELL DEMARCATED
EYES & OPTIC N.	ROUGH CORNEAL SURFACE	TRACE	CENTRAL AREA
PITUITARY GLAND	ENLARGED	MARKED	6MM DIAMETER, DARK RED

TISSUE / HISTOPATHOLOGIC FINDINGS << MICROSCOPIC TISSUE OBSERVATIONS >>  
 DISTRIBUTION (SEVERITY) / SPECIAL COMMENTS

HEART  
 -CARDIOMYOPATHY ..... NOT SPECIFIED (TRACE)

LUNGS  
 -N- LARGE GRANULAR LYMPHOCYTE LEUKEMIA, METASTATIC ..... (PRESENT)

SPLEEN  
 -FIBROSIS CAPSULAR ..... NOT SPECIFIED (MODERATE)  
 -N- LARGE GRANULAR LYMPHOCYTE LEUKEMIA, METASTATIC ..... (PRESENT)

LYMPH NODES  
 -N- LARGE GRANULAR LYMPHOCYTE LEUKEMIA, METASTATIC ..... (PRESENT)

LIVER  
 -COMPOUND RELATED INFLAMMATORY REACTION ..... NOT SPECIFIED (PRESENT)

Appendix J (cont.): PATHOLOGY INDIVIDUAL ANIMAL DATA

LETTERMAN ARMY INSTITUTE OF RESEARCH INDIVIDUAL ANIMAL DATA REPORT PRINTED: 21-NOV-89  
DIV OF RES SUPP, PATH SERV GP STUDY NUMBER: GLP83009 PAGE: 116  
SPECIES: RAT/FISCHER-344 STUDY START DATE: 23-JAN-84 STUDY TYPE: CHRONIC/2 YR CARCINOGENIC

ANIMAL NUMBER: 55/PRETEST# DOSE GROUP: 1 SACRIFICE STATUS: FOUND DEAD 354.00 (GMS)  
DATE OF DEATH: 09-MAY-85 STUDY DAY OF DEATH: 473 STUDY WEEK OF DEATH: 68 TERMINAL BODY WEIGHT: 354.00 (GMS)

TISSUE / HISTOPATHOLOGIC FINDINGS OBSERVATIONS / SPECIAL COMMENTS  
<< MICROSCOPIC TISSUE DISTRIBUTION (SEVERITY) / SPECIAL COMMENTS

LIVER ..... NOT SPECIFIED(MILD)  
-BILE DUCTULE EPITHELIAL HYPERPLASIA AND/OR CHOLANGIOFIBROSIS ..... DIFFUSE(MILD)  
-HEPATOCTYIC VACUOLIZATION ..... DIFFUSE(MILD)  
-HEPATOCTYIC DEGENERATIVE CHANGES (NON-NECROTIC) ..... MULTI-FOCAL(MILD)  
-NECROSIS, PERIACINAR ..... (PRESENT)  
-M- LARGE GRANULAR LYMPHOCYTE LEUKEMIA, METASTATIC

KIDNEY ..... NOT SPECIFIED(TRACE)  
-PROGRESSIVE RENAL DISEASE

PROSTATE ..... NOT SPECIFIED(TRACE)  
-CHRONIC PROSTATITIS ..... NOT SPECIFIED(TRACE)  
-BENIGN HYPERPLASIA

TESTES ..... (PRESENT)  
-B- INTERSTITIAL CELL ADENOMA

DUODENUM ..... NOT SPECIFIED (PRESENT)  
-COMPOUND RELATED INFLAMMATORY REACTION

JEJUNUM ..... NOT SPECIFIED (PRESENT)  
-COMPOUND RELATED INFLAMMATORY REACTION

ILEUM ..... TISSUE IS AUTOLYTIC

STOMACH ..... NOT SPECIFIED (PRESENT)  
-MUCOSAL AND/OR SUBMUCOSAL EDEMA ..... (PRESENT)  
-M- LARGE GRANULE LYMPHOCYTE LEUKEMIA, METASTATIC

SKIN ..... NOT SPECIFIED (PRESENT)  
-INFLAMMATION, NOT OTHERWISE SPECIFIED, PREPUTIAL GLAND

MAMMARY GLANDS

Appendix J (cont.): PATHOLOGY INDIVIDUAL ANIMAL DATA

LETTERMAN ARMY INSTITUTE OF RESEARCH  
 DIV OF RES SUPP, PATH SERV GP  
 SPECIES: RAY/FISCHER-344  
 STUDY START DATE: 23-JAN-84  
 STUDY NUMBER: GLP83009  
 PRINTED: 21-NOV-89  
 PAGE: 117  
 STUDY TYPE: CHRONIC/2 YR CARCINOGENIC  
 ANIMAL NUMBER: 55/PRETEST-  
 DATE OF DEATH: 09-MAY-85  
 STUDY DAY OF DEATH: 473  
 SEX: MALE  
 DOSE GROUP: 1  
 SACRIFICE STATUS: FOUND DEAD  
 TERMINAL BODY WEIGHT: 354.00 (GMS)

TISSUE / HISTOPATHOLOGIC FINDINGS  
 << MICROSCOPIC TISSUE OBSERVATIONS >>  
 DISTRIBUTION (SEVERITY) / SPECIAL COMMENTS

- MAMMARY GLANDS ..... NOT SPECIFIED (PRESENT)
- DILATATION (ECTASIA) OF DUCTS AND DUCTULES
- BONE, STERNUM ..... (PRESENT)
- N- LARGE GRANULE LYMPHOCYTE LEUKEMIA, METASTATIC
- BONE, FEMUR ..... (PRESENT)
- N- LARGE GRANULE LYMPHOCYTE LEUKEMIA, METASTATIC
- BONE VERT ..... (PRESENT)
- M- LARGE GRANULE LYMPHOCYTE LEUKEMIA, METASTATIC
- ADRENAL ..... NOT SPECIFIED (PRESENT)
- CORTICAL NODULAR HYPERPLASIA
- PITUITARY GLAND ..... (PRESENT)
- B- ADENOMA
- EYES & OPTIC N. .... BOTH EYES ARE BADLY DISTORTED BY PROCESSING ARTIFACT. ONE EYE (SECTION #19A) HAS MINERAL DEPOSITS IN THE CORNEA WHICH PROBABLY ACCOUNT FOR CHANGES NOTED GROSSLY. BOTH EYES HAVE METAPLASTIC BONE IN THE SCLERA. THESE EYES CANNOT BE EVALUATED CRITICALLY FOR OTHER CHANGES BECAUSE OF THE ARTIFACTS. EVALUATED NOT SPECIFIED (TRACE)
- CORNEAL MINERALIZATION
- METAPLASTIC BONE FORMATION AND/OR MINERALIZATION, SCLERA
- WHOLE BODY ..... (PRESENT)
- M- LARGE GRANULAR LYMPHOCYTTIC LEUKEMIA
- DIAPHRAGM ..... MISCELLANEOUS TISSUE
- COMPOUND RELATED INFLAMMATORY REACTION ..... NOT SPECIFIED (PRESENT)

**Appendix J (cont.): PATHOLOGY INDIVIDUAL ANIMAL DATA**

LETTERMAN ARMY INSTITUTE OF RESEARCH  
 DIV OF RES SUPP, PATH SERV GP  
 SPECIES: RAT/FISCHER-344  
 STUDY START DATE: 23-JAN-84  
 STUDY NUMBER: GLP83009  
 PRINTED: 21-NOV-89  
 PAGE: 118  
 STUDY TYPE: CHRONIC/2 YR CARCINOGENIC

ANIMAL NUMBER: 56/PRETEST-56  
 DATE OF DEATH: 26-FEB-85  
 STUDY DAY OF DEATH: 401  
 SEX: MALE  
 DOSE GROUP: 1  
 SACRIFICE STATUS: FOUND DEAD  
 STUDY WEEK OF DEATH: 58  
 TERMINAL BODY WEIGHT: 375.00 (GMS)

<< GROSS ORGAN OBSERVATIONS >>  
 SEVERITY GROSS FREE-TEXT COMMENTS

ADHESION(S) PRESENT DIAPHRAGM, VENTRAL ABDOMINAL WALL, INTESTINES  
 DISCOLORATION PRESENT BLACK, CERVICAL  
 MAMMARY GLAND PRESENT BLACK PIGMENTED  
 PERICARDIAL CAV. PRESENT GREATLY DISTENDED, SOME CLOTTED BLOOD  
 PLEURAL CAVITY PRESENT 4-5ML, CLOTTED  
 WHOLE BODY POST MORTEM AUTOLYSIS. MARKED

<< MICROSCOPIC TISSUE OBSERVATIONS >>  
 DISTRIBUTION (SEVERITY) / SPECIAL COMMENTS

THYROID GLANDS	TISSUE IS MISSING
PARATHYROID	TISSUE IS MISSING
HEART	NOT SPECIFIED (TRACE)
-CARDIOMYOPATHY	
THYMUS	TISSUE IS AUTOLYTIC
SPLEEN	TISSUE IS AUTOLYTIC
LYMPH NODES	TISSUE IS AUTOLYTIC
LIVER	NOT SPECIFIED (PRESENT)
-COMPOUND RELATED INFLAMMATORY REACTION	
KIDNEY	TISSUE IS AUTOLYTIC
URINARY BLADDER	TISSUE IS AUTOLYTIC

Appendix J (cont.): PATHOLOGY INDIVIDUAL ANIMAL DATA

LETTERMAN ARMY INSTITUTE OF RESEARCH  
 DIV OF RES SUPP, PATH SERV GP  
 SPECIES: RAT/FISCHER-344  
 STUDY START DATE: 23-JAN-84  
 STUDY TYPE: CHRONIC/2 YR CARCINOGENIC  
 ANIMAL NUMBER: 56/PRETEST= 56 SEX: MALE DOSE GROUP: 1 SACRIFICE STATUS: FOUND DEAD  
 DATE OF DEATH: 26-FEB-85 STUDY DAY OF DEATH: 401 STUDY WEEK OF DEATH: 58 TERMINAL BODY WEIGHT: 375.00 (GMS)

TISSUE / HISTOPATHOLOGIC FINDINGS  
 << MICROSCOPIC TISSUE OBSERVATIONS >>  
 DISTRIBUTION (SEVERITY) / SPECIAL COMMENTS

PROSTATE ..... TISSUE IS AUTOLYTIC  
 COAG GL ..... TISSUE IS MISSING  
 DUODENUM ..... TISSUE IS AUTOLYTIC  
 JEJUNUM ..... TISSUE IS AUTOLYTIC  
 ILEUM ..... TISSUE IS AUTOLYTIC  
 PANCREAS ..... TISSUE IS AUTOLYTIC  
 CECUM ..... TISSUE IS AUTOLYTIC  
 RECTUM ..... TISSUE IS AUTOLYTIC  
 COLON ..... TISSUE IS AUTOLYTIC  
 STOMACH ..... TISSUE IS AUTOLYTIC  
 SCIATIC NERVE ..... TISSUE IS MISSING  
 SKIN ..... TISSUE IS MISSING  
 MAMMARY GLANDS ..... TISSUE IS MISSING  
 PITUITARY GLAND ..... TISSUE IS MISSING  
 EYES & OPTIC N. .... TISSUE IS AUTOLYTIC

PRINTED: 21-NOV-89  
 PAGE: 119

Appendix J (cont.): PATHOLOGY INDIVIDUAL ANIMAL DATA

LETTERMAN ARMY INSTITUTE OF RESEARCH  
DIV OF RES SUPP, PATH SERV GP  
SPECIES: RAT/FISCHER-344

INDIVIDUAL ANIMAL DATA REPORT  
STUDY NUMBER: GLP83009

PRINTED: 21-NOV-89  
PAGE: 120

STUDY START DATE: 23-JAN-84

STUDY TYPE: CHRONIC/2 YR CARCINOGENIC

ANIMAL NUMBER: 56/PRETEST# 56 SEX: MALE DOSE GROUP: 1 SACRIFICE STATUS: FOUND DEAD  
DATE OF DEATH: 26-FEB-85 STUDY DAY OF DEATH: 401 STUDY WEEK OF DEATH: 58 TERMINAL BODY WEIGHT: 375.00 (GMS)

<< M I C R O S C O P I C T I S S U E O B S E R V A T I O N S >>  
DISTRIBUTION (SEVERITY) / SPECIAL COMMENTS

MEDIASTINUM ..... MISCELLANEOUS TISSUE  
SEE COMMENT UNDER ABDOMINAL CAVITY.  
-N- PRESENCE OF METASTATIC SARCOMA ..... SECONDARY NEOPLASM FROM ORGAN ABDOMINAL CAVITY  
ABDOMINAL CAVITY ..... MISCELLANEOUS TISSUE  
AUTOLYTIC CHANGES ARE PRESENT IN ALL TISSUES. HOWEVER, THERE IS  
A HIGHLY CELLULAR NEOPLASM IN MANY AREAS OF THE BODY,  
PARTICULARLY IN THE MEDIASTINUM. THE DIAPHRAGM IS INVOLVED.  
PROBABLY THE SARCOMA ORIGINATED IN THE ABDOMINAL CAVITY NEAR THE  
DIAPHRAGM AND EXTENDED INTO THE MEDIASTINUM.  
-M- SARCOMA, CELLULAR DIFFERENTIATION UNSPECIFIED (PRESENT)  
DIAPHRAGM ..... MISCELLANEOUS TISSUE  
-N- PRESENCE OF METASTATIC SARCOMA ..... SECONDARY NEOPLASM FROM ORGAN ABDOMINAL CAVITY  
-COMPOUND RELATED INFLAMMATORY REACTION NOT SPECIFIED (PRESENT)

Appendix J (cont.): PATHOLOGY INDIVIDUAL ANIMAL DATA

LETTERMAN ARMY INSTITUTE OF RESEARCH INDIVIDUAL ANIMAL DATA REPORT PRINTED: 21-NOV-89  
DIV OF RES SUPP, PATH SERV GP STUDY NUMBER: GLP83009 PAGE: 121  
SPECIES: RAT/FISCHER-344 STUDY START DATE: 23-JAN-84 STUDY TYPE: CHRONIC/2 YR CARCINOGENIC

ANIMAL NUMBER: 57/PRETEST= 57 SEX: MALE DOSE GROUP: 1 SACRIFICE STATUS: FINAL SACRIFICE  
DATE OF DEATH: 03-FEB-86 STUDY DAY OF DEATH: 743 STUDY WEEK OF DEATH: 107 TERMINAL BODY WEIGHT: 327.00 (GMS)

ORGAN NAME << GROSS ORGAN OBSERVATIONS >> SEVERITY GROSS FREE-TEXT COMMENTS  
LIVER ADHESION(S) PRESENT DUODENUM, DIAPHRAGM  
KIDNEY GRANULAR SURFACE TRACE  
TESTES GROWTH(S) / MASS(ES) PRESENT BILATERAL, MULTIPLE VARIABLY SIZED, YELLOW  
PITUITARY GLAND ENLARGED PRESENT DARK RED, .4CM DIAMETER

TISSUE / HISTOPATHOLOGIC FINDINGS << MICROSCOPIC TISSUE OBSERVATIONS >> DISTRIBUTION (SEVERITY) / SPECIAL COMMENTS

THYROID GLANDS ..... (PRESENT)  
-B- PARA-FOLLICULAR CELL ADENOMA

HEART ..... NOT SPECIFIED(MILD)  
-CARDIOMYOPATHY ..... NOT SPECIFIED(TRACE)  
-MEDIAL HYPERTROPHY OF MUSCULAR ARTERIES

LIVER ..... NOT SPECIFIED(MODERATE)  
-BILE DUCTULE EPITHELIAL HYPERPLASIA AND/OR CHOLANGIOFIBROSIS MULTI-FOCAL(TRACE)  
-HEPATITIS MULTI-FOCAL(TRACE)  
-FOCUS OF CELLULAR ALTERATION - BASOPHILIC FOCAL(MARKED)  
-HEPATOCTYTIC VACUOLIZATION NOT SPECIFIED (PRESENT)  
-FIBROSIS CAPSULAR NO COMPOUND MULTI-FOCAL(MILD)  
-HEPATOCTYTE COALESCING MICROVESICULAR (FATTY) CHANGE LEADING TO NECROSIS AND MINERALIZATION

KIDNEY ..... NOT SPECIFIED(MODERATE)  
-PROGRESSIVE RENAL DISEASE

PROSTATE ..... NOT SPECIFIED(MILD)  
-CHRONIC PROSTATITIS NOT SPECIFIED(TRACE)  
-BENIGN HYPERPLASIA

SEMINAL VESICLE .....

Appendix J (cont.): PATHOLOGY INDIVIDUAL ANIMAL DATA

LETTERMAN ARMY INSTITUTE OF RESEARCH  
DIV OF RES SUPP, PATH SERV GP  
SPECIES: RAT/FISCHER-344

INDIVIDUAL ANIMAL DATA REPORT  
STUDY NUMBER: GLP83009

PRINTED: 21-NOV-89  
PAGE: 122

STUDY START DATE: 23-JAN-84

STUDY TYPE: CHRONIC/2 YR CARCINOGENIC

ANIMAL NUMBER: 57/PRETEST-57 SEX: MALE DOSE GROUP: 1 SACRIFICE STATUS: FINAL SACRIFICE  
DATE OF DEATH: 03-FEB-86 STUDY DAY OF DEATH: 743 STUDY WEEK OF DEATH: 107 TERMINAL BODY WEIGHT: 327.00 (GMS)

TISSUE / HISTOPATHOLOGIC FINDINGS << MICROSCOPIC TISSUE OBSERVATIONS >>  
DISTRIBUTION (SEVERITY) / SPECIAL COMMENTS

SEMINAL VESICLE ..... NOT SPECIFIED (PRESENT)  
-GENERALIZED ATROPHY

TESTES ..... (PRESENT)  
-B- INTERSTITIAL CELL ADENOMA

CECUM ..... NOT SPECIFIED (PRESENT)  
-REACTIVE LYMPHOID HYPERPLASIA, SUBMUCOSA

STOMACH ..... NOT SPECIFIED (PRESENT)  
-COMPOUND RELATED INFLAMMATORY REACTION

SKELETAL MUSCLE ..... SKELETAL MUSCLE SECTION FROM THE LEG IS MISSING. SKELETAL  
MUSCLE IN OTHER LOCATIONS, EG. PARAVERTEBRAL, IS NORMAL.

SCIATIC NERVE ..... TISSUE IS MISSING

MAMMARY GLANDS ..... NOT SPECIFIED (MILD)  
-HYPERPLASIA AND/OR HYPERTROPHY OF THE ACINAR TISSUE

BONE, FEMUR ..... TISSUE IS MISSING

ADRENAL ..... (PRESENT)  
-B- PHEOCHROMOCYTOMA

PITUITARY GLAND ..... (PRESENT)  
-B- ADENOMA

EYES & OPTIC N. ..... NOT SPECIFIED (PRESENT)  
-METAPLASTIC BONE FORMATION AND/OR MINERALIZATION, SCLERA



Appendix J (cont.): PATHOLOGY INDIVIDUAL ANIMAL DATA

LETTERMAN ARMY INSTITUTE OF RESEARCH  
DIV OF RES SUPP, PATH SERV GP  
SPECIES: RAT/FISCHER-344

INDIVIDUAL ANIMAL DATA REPORT  
STUDY NUMBER: GLP83009  
STUDY START DATE: 23-JAN-84

PRINTED: 21-NOV-89  
PAGE: 123

STUDY TYPE: CHRONIC/2 YR CARCINOGENIC

ANIMAL NUMBER: 57/PRETEST-      DOSE GROUP: 1      SACRIFICE STATUS: FINAL SACRIFICE  
DATE OF DEATH: 03-FEB-86      STUDY DAY OF DEATH: 743      STUDY WEEK OF DEATH: 107      TERMINAL BODY WEIGHT: 327.00 (GMS)

<< M I C R O S C O P I C      T I S S U E      O B S E R V A T I O N S      >>  
TISSUE / HISTOPATHOLOGIC FINDINGS      DISTRIBUTION (SEVERITY) / SPECIAL COMMENTS

DIAPHRAGM ..... MISCELLANEOUS TISSUE  
THERE IS A FIBROUS CONNECTIVE TISSUE REACTION ON THE ABDOMINAL SURFACE OF THE DIAPHRAGM WITH ADHESION TO THE CAPSULAR SURFACE OF THE LIVER. NO COMPOUND IS PRESENT IN SECTION EXAMINED.  
NOT SPECIFIED (PRESENT)

-COMPOUND RELATED INFLAMMATORY REACTION



Appendix J (cont.): PATHOLOGY INDIVIDUAL ANIMAL DATA

LETTERMAN ARMY INSTITUTE OF RESEARCH  
DIV OF RES SUPP, PATH SERV GP  
SPECIES: RAT/FISCHER-344

INDIVIDUAL ANIMAL DATA REPORT  
STUDY NUMBER: GLP83009

PRINTED: 21-NOV-89  
PAGE: 128

STUDY START DATE: 23-JAN-84

STUDY TYPE: CHRONIC/2 YR CARCINOGENIC

ANIMAL NUMBER: 60/PRETEST# 60 SEX: MALE DOSE GROUP: 1 SACRIFICE STATUS: FOUND DEAD  
DATE OF DEATH: 22-JAN-86 STUDY DAY OF DEATH: 731 STUDY WEEK OF DEATH: 105 TERMINAL BODY WEIGHT: 336.00 (GMS)

<< MICROSCOPIC TISSUE OBSERVATIONS >>  
TISSUE / HISTOPATHOLOGIC FINDINGS DISTRIBUTION (SEVERITY) / SPECIAL COMMENTS

LYMPH NODES ..... (PRESENT)  
-N- LARGE GRANULAR LYMPHOCYTE LEUKEMIA, METASTATIC

LIVER ..... NOT SPECIFIED (PRESENT)  
-COMPOUND RELATED INFLAMMATORY REACTION NOT SPECIFIED(MILD)  
-BILE DUCTULE EPITHELIAL HYPERPLASIA AND/OR CHOLANGIOFIBROSIS NOT SPECIFIED(MODERATE)  
-HEPATOCTYIC DEGENERATIVE CHANGES (NON-NECROTIC) (PRESENT)  
-N- LARGE GRANULAR LYMPHOCYTE LEUKEMIA, METASTATIC

KIDNEY ..... NOT SPECIFIED(MODERATE)  
-PROGRESSIVE RENAL DISEASE (PRESENT)  
-N- LARGE GRANULAR LYMPHOCYTE LEUKEMIA, METASTATIC

URINARY BLADDER ..... TISSUE IS AUTOLYTIC

PROSTATE ..... TISSUE IS AUTOLYTIC

COAG GL ..... TISSUE IS AUTOLYTIC

SEMINAL VESICLE ..... TISSUE IS AUTOLYTIC

TESTES ..... (PRESENT)  
-B- INTERSTITIAL CELL ADENOMA

DUODENUM ..... TISSUE IS AUTOLYTIC

JEJUNUM ..... TISSUE IS AUTOLYTIC

ILEUM ..... TISSUE IS AUTOLYTIC

Appendix J (cont.): PATHOLOGY INDIVIDUAL ANIMAL DATA

LETTERMAN ARMY INSTITUTE OF RESEARCH  
 DIV OF RES SUPP, PATH SERV GP  
 SPECIES: RAT/FISCHER-344

INDIVIDUAL ANIMAL DATA REPORT  
 STUDY NUMBER: GLP83009

STUDY START DATE: 23-JAN-84

STUDY TYPE: CHRONIC/2 YR CARCINOGENIC

PRINTED: 21-NOV-89  
 PAGE: 129

ANIMAL NUMBER: 60/PRETEST= 60 SEX: MALE DOSE GROUP: 1 SACRIFICE STATUS: FOUND D AD  
 DATE OF DEATH: 22-JAN-86 STUDY DAY OF DEATH: 731 STUDY WEEK OF DEATH: 105 TERMINAL BODY WEIGHT: 336.00 (GMS)

<< MICROSCOPIC TISSUE OBSERVATIONS >>  
 TISSUE / HISTOPA/HOLOGIC FINDINGS DISTRIBUTION (SEVERITY) / SPECIAL COMMENTS

PANCREAS ..... TISSUE IS AUTOLYTIC

CFCUM ..... TISSUE IS AUTOLYTIC

RECTUM ..... TISSUE IS AUTOLYTIC

COLON ..... TISSUE IS AUTOLYTIC

SCIATIC NERVE ..... TISSUE IS MISSING

MAMMARY GLANDS .....  
 -HYPERPLASIA AND/OR HYPERTROPHY OF THE ACINAR TISSUE ..... NOT SPECIFIED (TRACE)  
 -DILATATION (ECTASIA) OF DUCTS AND DUCTULES ..... NOT SPECIFIED (PRESENT)

NOSE/TURBINATES .....  
 -MIXED INFLAMMATORY CELL INFILTRATION, NASAL CAVITY, SINUSES, ..... INFLAMMATORY INFILTRATE INVOLVES NASO-LACRIMAL DUCT.  
 TURBINATES, NASO-LACRIMAL DUCTS ..... NOT SPECIFIED (MILD)

BONE, STERNUM .....  
 -N- LARGE GRANULE LYMPHOCYTE LEUKEMIA, METASTATIC ..... (PRESENT)

BONE, FEMUR .....  
 -N- LARGE GRANULE LYMPHOCYTE LEUKEMIA, METASTATIC ..... (PRESENT)

BONE VERT .....  
 -N- LARGE GRANULE LYMPHOCYTE LEUKEMIA, METASTATIC ..... (PRESENT)

ADRENAL .....  
 -N- LARGE GRANULE LYMPHOCYTE LEUKEMIA, METASTATIC ..... (PRESENT)

PITUITARY GLAND ..... TISSUE IS MISSING

Appendix J (cont.): PATHOLOGY INDIVIDUAL ANIMAL DATA

LETTERMAN ARMY INSTITUTE OF RESEARCH  
DIV OF RES SUPP, PATH SERV GP  
SPECIES: RAT/FISCHER-344

INDIVIDUAL ANIMAL DATA REPORT  
STUDY NUMBER: GLP83009  
STUDY START DATE: 23-JAN-84

PRINTED: 21-NOV-89  
PAGE: 130  
STUDY TYPE: CHRONIC/2 YR CARCINOGENIC

ANIMAL NUMBER: 60/PRETEST# 60 SEX: MALE DOSE GROUP: 1 SACRIFICE STATUS: FOUND DEAD  
DATE OF DEATH: 22-JAN-86 STUDY DAY OF DEATH: 731 STUDY WEEK OF DEATH: 105 TERMINAL BODY WEIGHT: 336.00 (GMS)

TISSUE / HISTOPATHOLOGIC FINDINGS  
    << MICROSCOPIC TISSUE OBSERVATIONS >>  
    DISTRIBUTION (SEVERITY) / SPECIAL COMMENTS

EYES & OPTIC N. .... TISSUE IS AUTOLYTIC

WHOLE BODY ..... THIS IS AN EXTENSIVE CASE OF LARGE GRANULE LYMPHOCYTE LEUKEMIA.  
NEOPLASTIC CELLS OF THIS TYPE ARE PRESENT IN VIRTUALLY EVERY ORGAN. THE CONDITION WAS CODED ONLY IN THOSE ORGANS WHICH ARE EXTENSIVELY INVOLVED. AUTOLYTIC CHANGES PRECLUDED DETAILED HISTOLOGIC EVALUATION OF THOSE ORGANS INDICATED.  
(PRESENT)

-M- LARGE GRANULAR LYMPHOCYTIC LEUKEMIA

DIAPHRAGM ..... MISCELLANEOUS TISSUE NOT SPECIFIED (PRESENT)  
-COMPOUND RELATED INFLAMMATORY REACTION

Appendix J (cont.): PATHOLOGY INDIVIDUAL ANIMAL DATA

LETTERMAN ARMY INSTITUTE OF RESEARCH  
 DIV OF RES SUPP, PATH SERV GP  
 SPECIES: RAT/FISCHER-344  
 STUDY START DATE: 23-JAN-84  
 STUDY NUMBER: GLP83009  
 PRINTED: 21-NOV-89  
 PAGE: 131  
 STUDY TYPE: CHRONIC/2 YR CARCINOGENIC  
 ANIMAL NUMBER: 61/PRETEST-  
 DATE OF DEATH: 05-FEB-86  
 SEX: MALE  
 DOSE GROUP: 1  
 SACRIFICE STATUS: FINAL SACRIFICE  
 STUDY DAY OF DEATH: 745  
 STUDY WEEK OF DEATH: 107  
 TERMINAL BODY WEIGHT: 380.00 (GMS)

<< GROSS ORGAN OBSERVATIONS >>  
 SEVERITY GROSS FREE-TEXT COMMENTS  
 ORGANS / PHRASES  
 LIVER ADHESION(S) PRESENT DIAPHRAGM, VENTRAL ABDOMINAL WALL, INTESTINES  
 PERITONEAL CAV. GROWTH(S) / MASS(ES) PRESENT CYSTIC, 1.5CM DIAMETER, INTESTINES ADHERED AT VARIOUS POINTS  
 TESTES ATROPHIC / SMALL, UNILATERALLY PRESENT LEFT, 1.5 X 1CM  
 TESTES ENLARGED PRESENT RIGHT, 3 X 1.75  
 TESTES GROWTH(S) / MASS(ES) PRESENT RIGHT, MULTIPLE VARIABLY SIZED, YELLOW/BLACK  
 SPLEEN ENLARGED (SPLENOMEGALY) TRACE 4.5 X 1CM  
 PITUITARY GLAND DISCOLORATION PRESENT FOCAL, RAISED, TWO .2CM DIAMETER, DARK RED

<< MICROSCOPIC TISSUE OBSERVATIONS >>  
 DISTRIBUTION (SEVERITY) / SPECIAL COMMENTS  
 TISSUE / HISTOPATHOLOGIC FINDINGS

- HEART ..... NOT SPECIFIED(MILD)
- CARDIOMYOPATHY
- LUNGS ..... NOT SPECIFIED(TRACE)
- MINERALIZATION OF PULMONARY ARTERIES
- SPLEEN ..... NOT SPECIFIED (PRESENT)
- EXTRAMEDULLARY HEMATOPOIESIS
- LYMPH NODES ..... REACTIVE HYPERPLASIA, RBC'S AND PIGMENT NOTED IN MEDIASTINAL NODE.
- RED BLOOD CELLS, HEMOSIDERIN AND/OR ERYTHROPHAGOCYTOSIS WITHIN MEDULLARY SINUSES NOT SPECIFIED (PRESENT)
- REACTIVE HYPERPLASIA NOT SPECIFIED (PRESENT)
- LIVER ..... NOT SPECIFIED (PRESENT)
- COMPOUND RELATED INFLAMMATORY REACTION NOT SPECIFIED (MILD)
- BILE DUCTULE EPITHELIAL HYPERPLASIA AND/OR CHOLANGIOFIBROSIS MULTI-FOCAL(TRACE)
- HEPATITIS FOCAL(TRACE)
- NECROSIS NOT SPECIFIED (PRESENT)
- CYSTIC DEGENERATION

**Appendix J (cont.): PATHOLOGY INDIVIDUAL ANIMAL DATA**

LETTERMAN ARMY INSTITUTE OF RESEARCH  
 DIV OF RES SUPP, PATH SERV GP  
 SPECIES: RAT/FISCHER-344  
 STUDY START DATE: 23-JAN-84  
 STUDY NUMBER: GLP83009  
 STUDY TYPE: CHRONIC/2 YR CARCINOGENIC  
 PRINTED: 21-NOV-89  
 PAGE: 132

ANIMAL NUMBER: 61/PRETEST= 61 SEX: MALE DOSE GROUP: 1 SACRIFICE STATUS: FINAL SACRIFICE  
 DATE OF DEATH: 05-FEB-86 STUDY DAY OF DEATH: 745 STUDY WEEK OF DEATH: 107 TERMINAL BODY WEIGHT: 380.00 (GMS)

<< MICROSCOPIC TISSUE OBSERVATIONS >>  
 DISTRIBUTION (SEVERITY) / SPECIAL COMMENTS

TISSUE / HISTOPATHOLOGIC FINDINGS

LIVER .....  
 -BENIGN HYPERPLASTIC NODULE(S) ..... NOT SPECIFIED(MILD)  
 -HEPATOCTYE COALESCING MICROVESICULAR (FATTY) CHANGE LEADING TO MULTI-FOCAL(TRACE)  
 NECROSIS AND MINERALIZATION

KIDNEY .....  
 -PROGRESSIVE RENAL DISEASE ..... NOT SPECIFIED(MILD)

PROSTATE .....  
 -CHRONIC PROSTATITIS ..... NOT SPECIFIED(TRACE)  
 -BENIGN HYPERPLASIA ..... NOT SPECIFIED(TRACE)

SEMINAL VESICLE .....  
 -GENERALIZED ATROPHY ..... NOT SPECIFIED (PRESENT)

TESTES .....  
 -8- INTERSTITIAL CELL ADENOMA ..... (PRESENT)

PANCREAS .....  
 -ACINAR (EXOCRINE) ATROPHY ..... MULTI-FOCAL(MILD)

COLON .....  
 -8- POLYP, CYSTIC, WITH MUCINOUS EPITHELIAL HYPERPLASIA AND (PRESENT)  
 OSSEOUS METAPLASIA AND/OR MINERALIZATION OF STROMA

NOSE/TURBINATES .....  
 CELLULAR INFILTRATE INVOLVES NASAL SEPTUM AND TURBINATE UNILATERALLY.  
 -MIXED INFLAMMATORY CELL INFILTRATION, NASAL CAVITY, SINUSES, NOT SPECIFIED(MILD)  
 TURBINATES, NASO-LACRIMAL DUCTS

PITUITARY GLAND .....  
 -8- ADENOMA ..... (PRESENT)

EYES & OPTIC N. ....

Appendix J (cont.): PATHOLOGY INDIVIDUAL ANIMAL DATA

LETTERMAN ARMY INSTITUTE OF RESEARCH  
DIV OF RES SUPP, PATH SERV GP  
SPECIES: RAT/FISCHER-344

INDIVIDUAL ANIMAL DATA REPORT  
STUDY NUMBER: GLP83009

PRINTED: 21-NOV-89  
PAGE: 133

STUDY START DATE: 23-JAN-84

STUDY TYPE: CHRONIC/2 YR CARCINOGENIC

ANIMAL NUMBER: 61/PRETEST-      DOSE GROUP: 1      SACRIFICE STATUS: FINAL SACRIFICE  
DATE OF DEATH: 05-FEB-86      STUDY DAY OF DEATH: 745      STUDY WEEK OF DEATH: 107      TERMINAL BODY WEIGHT: 380.00 (GMS)

<<      M I C R O S C O P I C      T I S S U E      O B S E R V A T I O N S      >>  
TISSUE / HISTOPATHOLOGIC FINDINGS      DISTRIBUTION (SEVERITY) / SPECIAL COMMENTS

EYES & OPTIC N. ....  
-RETINAL ATROPHY AND/OR DEGENERATION, UNILATERAL OR BILATERAL      NOT SPECIFIED (TRACE)  
-METAPLASTIC BONE FORMATION AND/OR MINERALIZATION, SCLERA      NOT SPECIFIED (PRESENT)  
-LENTICULAR DEGENERATIVE CHANGES COMPATIBLE WITH CATARACT      NOT SPECIFIED (PRESENT)

DIAPHRAGM ..... MISCELLANEOUS TISSUE  
-COMPOUND RELATED INFLAMMATORY REACTION      NOT SPECIFIED (PRESENT)



Appendix J (cont.): PATHOLOGY INDIVIDUAL ANIMAL DATA

LETTERMAN ARMY INSTITUTE OF RESEARCH  
DIV OF RES SUPP, PATH SERV GP  
SPECIES: RAT/FISCHER-344

INDIVIDUAL ANIMAL DATA REPORT  
STUDY NUMBER: GLP83009  
STUDY START DATE: 23-JAN-84

PRINTED: 21-NOV-89  
PAGE: 134  
STUDY TYPE: CHRONIC/2 YR CARCINOGENIC

ANIMAL NUMBER: 62/PRETEST=  
DATE OF DEATH: 10-MAY-85

62 SEX: MALE  
STUDY DAY OF DEATH: 474

DOSE GROUP: 1  
STUDY WEEK OF DEATH: 68

SACRIFICE STATUS: SACRIFICED MORIBUND  
TERMINAL BODY WEIGHT: 438.00 (GMS)

ORGAN NAME  
LIVER  
LIVER  
PERITONEAL CAV.  
CECUM  
JEJUNUM

<< GROSS ORGAN OBSERVATIONS >>  
SEVERITY GROSS FREE-TEXT COMMENTS

GROWTH(S) / MASS(ES)  
ADHESION(S)  
ROUGHENED PERITONEAL SURFACE  
MASS(ES)  
GROWTH(S) / MASS(ES)

FIRM, WHITE, MULTIMODULAR, 4CM DIAMETER  
DIAPHRAGM TO LIVER AND MASS  
AREA OVERLYING MASS  
BRIGHT RED, .5CM DIAMETER  
RED, 5 X 1CM, SMALL SECTION OF INTESTINE IS INCORPORATED INTO

TISSUE / HISTOPATHOLOGIC FINDINGS

<< MICROSCOPIC TISSUE OBSERVATIONS >>  
DISTRIBUTION (SEVERITY) / SPECIAL COMMENTS

HEART  
-CARDIOMYOPATHY

NOT SPECIFIED(TRACE)

LYMPH NODES

NUMEROUS RBC'S ARE PRESENT IN MEDIASTINAL NODE. FEWER ARE PRESENT IN MESENTERIC NODE.

-RED BLOOD CELLS, HEMOSIDERIN AND/OR ERYTHROPHAGOCYTOSIS WITHIN MEDULLARY SINUSES

NOT SPECIFIED (PRESENT)

LIVER

-COMPOUND RELATED INFLAMMATORY REACTION  
-BILE DUCTULE EPITHELIAL HYPERPLASIA AND/OR CHOLANGIOFIBROSIS  
-M- PRESENCE OF METASTATIC SARCOMA

NOT SPECIFIED (PRESENT)  
NOT SPECIFIED(MILD)  
SECONDARY NEOPLASM FROM ORGAN ABDOMINAL CAVITY

KIDNEY

-PROGRESSIVE RENAL DISEASE

NOT SPECIFIED(TRACE)

PROSTATE

-BENIGN HYPERPLASIA

TESTES

-B- INTERSTITIAL CELL ADENOMA

(PRESENT)

DUODENUM

NOT SPECIFIED(TRACE)

Appendix J (cont.): PATHOLOGY INDIVIDUAL ANIMAL DATA

LETTERMAN ARMY INSTITUTE OF RESEARCH INDIVIDUAL ANIMAL DATA REPORT PRINTED: 21-NOV-89  
DIV OF RES SUPP, PATH SERV GP STUDY NUMBER: GLP83009 PAGE: 135  
SPECIES: RAT/FISCHER-344 STUDY START DATE: 23-JAN-84 STUDY TYPE: CHRONIC/2 YR CARCINOGENIC

ANIMAL NUMBER: 62/PRETEST# DOSE GROUP: 1 SACRIFICE STATUS: SACRIFICED MORIBUND  
DATE OF DEATH: 10-MAY-85 STUDY DAY OF DEATH: 474 STUDY WEEK OF DEATH: 68 TERMINAL BODY WEIGHT: 438.00 (GMS)

TISSUE / HISTOPATHOLOGIC FINDINGS << M I C R O S C O P I C T I S S U E O B S E R V A T I O N S >>  
DISTRIBUTION (SEVERITY) / SPECIAL COMMENTS

DUODENUM ..... NOT SPECIFIED (PRESENT)  
-COMPOUND RELATED INFLAMMATORY REACTION  
-N- PRESENCE OF METASTATIC SARCOMA  
..... SECONDARY NEOPLASM FROM ORGAN ABDOMINAL CAVITY

ILEUM ..... SECONDARY NEOPLASM FROM ORGAN ABDOMINAL CAVITY  
-N- PRESENCE OF METASTATIC SARCOMA

PANCREAS ..... NOT SPECIFIED (PRESENT)  
-COMPOUND RELATED INFLAMMATORY REACTION  
-N- PRESENCE OF METASTATIC SARCOMA  
..... SECONDARY NEOPLASM FROM ORGAN ABDOMINAL CAVITY

CECUM ..... SECONDARY NEOPLASM FROM ORGAN  
-N- PRESENCE OF METASTATIC SARCOMA

COLON ..... NOT SPECIFIED (PRESENT)  
-COMPOUND RELATED INFLAMMATORY REACTION

NOSE/TURBINATES ..... CELLULAR INFILTRATE INVOLVES THE NASAL SEPTUM AND THE TURBINATE  
UNILATERALLY.  
NOT SPECIFIED(TRACE)

MIXED INFLAMMATORY CELL INFILTRATION, NASAL CAVITY, SINUSES,  
TURBINATES, NASO-LACRIMAL DUCTS  
PITUITARY GLAND .....  
-B- ADENOMA (PRESENT)  
-CYST(S) NOT SPECIFIED (PRESENT)

ABDOMINAL CAVITY ..... MISCELLANEOUS TISSUE

Appendix J (cont.): PATHOLOGY INDIVIDUAL ANIMAL DATA

LETTERMAN ARMY INSTITUTE OF RESEARCH  
DIV OF RES SUPP, PATH SERV GP  
SPECIES: RAT/FISCHER-344

INDIVIDUAL ANIMAL DATA REPORT  
STUDY NUMBER: GLP83009  
STUDY START DATE: 23-JAN-84

PRINTED: 21-NOV-89  
PAGE: 136  
STUDY TYPE: CHRONIC/2 YR CARCINOGENIC

ANIMAL NUMBER: 62/PRETEST=  
DATE OF DEATH: 10-MAY-85 STUDY DAY OF DEATH: 474 SEX: MALE  
DOSE GROUP: 1 SACRIFICE STATUS: SACRIFICED MORIBUND

STUDY WEEK OF DEATH: 68 TERMINAL BODY WEIGHT: 438.00 (GMS)

<< MICROSCOPIC TISSUE OBSERVATIONS >>  
DISTRIBUTION (SEVERITY) / SPECIAL COMMENTS

ABDOMINAL CAVITY

A SARCOMA IS PRESENT IN MANY SITES IN THE ABDOMINAL CAVITY.  
THERE IS EXTENSIVE HEPATIC INVOLVEMENT WHERE THE NEOPLASM  
RESEMBLES A MEURFIBROSARCOMA. ELSEWHERE IT IS EITHER POORLY  
DIFFERENTIATED OR RESEMBLES FIBROSARCOMA. IN SECTION #24 IT IS  
IMPLANTED ON THE PERITONEAL SURFACE OF THE ABDOMINAL WALL. THERE  
IS EXTENSIVE INVOLVEMENT OF THE INTESTINAL TRACT AT SEVERAL  
LEVELS.  
(PRESENT)

-M- SARCOMA, CELLULAR DIFFERENTIATION UNSPECIFIED

DIAPHRAGM

MISCELLANEOUS TISSUE  
SECONDARY NEOPLASM FROM ORGAN ABDOMINAL CAVITY  
NOT SPECIFIED (PRESENT)

-M- PRESENCE OF METASTATIC SARCOMA

-COMPOUND RELATED INFLAMMATORY REACTION

**Appendix J (cont.): PATHOLOGY INDIVIDUAL ANIMAL DATA**

LETTERMAN ARMY INSTITUTE OF RESEARCH  
 DIV OF RES SUPP, PATH SERV GP  
 SPECIES: RAT/FISCHER-344  
 STUDY START DATE: 23-JAN-64  
 STUDY NUMBER: GLP83009  
 PRINTED: 21-NOV-89  
 PAGE: 137  
 ANIMAL NUMBER: 63/PRETEST= 63 SEX: MALE DOSE GROUP: 1 SACRIFICE STATUS: SACRIFICED MORIBUND  
 DATE OF DEATH: 03-JAN-66 STUDY DAY OF DEATH: 712 STUDY WEEK OF DEATH: 102 TERMINAL BODY WEIGHT: 378.00 (GMS)  
 STUDY TYPE: CHRONIC/2 YR CARCINOGENIC

ORGAN NAME << GROSS ORGAN OBSERVATIONS >>  
 KEYWORDS / PHRASES SEVERITY GROSS FREE-TEXT COMMENTS  
 LIVER GRANULAR SURFACE PRESENT RED MOTTLED  
 LIVER ENLARGED MODERATE  
 LIVER ADHESION(S) PRESENT DIAPHRAGM, VENTRAL ABDOMINAL WALL, STOMACH  
 LUNGS DISCOLORATION PRESENT RED, FOCAL, MULTIPLE, .2-.3CM DIAMETER  
 SPLEEN ENLARGED (SPLENOmegaly) MARKED 7.5 X 2.5 X 1.5CM  
 TESTES GROWTH(S) / MASS(ES) PRESENT NUMEROUS, IRREGULAR, VARIABLY SIZED, YELLOW  
 KIDNEY DISCOLORATION PRESENT GREEN/BROWN WITH MULTIPLE PINPOINT WHITE FOCI

TISSUE / HISTOPATHOLOGIC FINDINGS << MICROSCOPIC TISSUE OBSERVATIONS >>  
 DISTRIBUTION (SEVERITY) / SPECIAL COMMENTS

HEART  
 -CARDIOMYOPATHY NOT SPECIFIED(MILD)  
 -MEDIAL HYPERTROPHY OF MUSCULAR ARTERIES NOT SPECIFIED(TRACE)

LUNGS  
 -PNEUMONIA, INTERSTITIAL, CHRONIC MULTI-FOCAL(MILD)  
 -N- LARGE GRANULAR LYMPHOCYTE LEUKEMIA, METASTATIC (PRESENT)  
 -ALVEOLAR HEMORRHAGE MULTI-FOCAL (PRESENT)

THYMUS  
 -N- LARGE GRANULAR LYMPHOCYTE LEUKEMIA, METASTATIC (PRESENT)

SPLEEN  
 -N- LARGE GRANULAR LYMPHOCYTE LEUKEMIA, METASTATIC (PRESENT)

LYMPH NODES  
 -N- LARGE GRANULAR LYMPHOCYTE LEUKEMIA, METASTATIC (PRESENT)

LIVER  
 -COMPOUND RELATED INFLAMMATORY REACTION NOT SPECIFIED (PRESENT)

Appendix J (cont.): PATHOLOGY INDIVIDUAL ANIMAL DATA

LETTERMAN ARMY INSTITUTE OF RESEARCH  
 DIV OF RES SUPP, PATH SERV GP  
 SPECIES: RAT/FISCHER-344  
 STUDY START DATE: 23-JAN-84  
 STUDY NUMBER: GLP83009  
 STUDY TYPE: CHRONIC/2 YR CARCINOGENIC  
 ANIMAL NUMBER: 63/PRETEST= 63 SEX: MALE DOSE GROUP: 1 SACRIFICE STATUS: SACRIFICED MORIBUND  
 DATE OF DEATH: 03-JAN-86 STUDY DAY OF DEATH: 712 STUDY WEEK OF DEATH: 102 TERMINAL BODY WEIGHT: 378.00 (GMS)  
 TISSUE / HISTOPATHOLOGIC FINDINGS << MICROSCOPIC TISSUE OBSERVATIONS >>  
 DISTRIBUTION (SEVERITY) / SPECIAL COMMENTS

- LIVER .....  
 -HEPATOCTYIC DEGENERATIVE CHANGES (NON-NECROTIC) ..... DIFFUSE(MODERATE)  
 -NECROSIS, PERIACINAR ..... NOT SPECIFIED(MODERATE)  
 -N- LARGE GRANULAR LYMPHOCYTE LEUKEMIA, METASTATIC ..... (PRESENT)
- KIDNEY .....  
 -PROGRESSIVE RENAL DISEASE ..... NOT SPECIFIED(TRACE)  
 -N- LARGE GRANULAR LYMPHOCYTE LEUKEMIA, METASTATIC ..... (PRESENT)
- PROSTATE .....  
 -CHRONIC PROSTATITIS ..... NOT SPECIFIED(TRACE)  
 -BENIGN HYPERPLASIA ..... NOT SPECIFIED(MILD)
- SEMINAL VESICLE .....  
 -GENERALIZED ATROPHY ..... NOT SPECIFIED (PRESENT)
- TESTES .....  
 -B- INTERSTITIAL CELL ADENOMA ..... (PRESENT)
- DUODENUM .....  
 -COMPOUND RELATED INFLAMMATORY REACTION ..... NOT SPECIFIED (PRESENT)
- ILEUM .....  
 -N- LARGE GRANULAR LYMPHOCYTE LEUKEMIA, METASTATIC ..... (PRESENT)
- PANCREAS .....  
 -CHRONIC INFLAMMATION ..... NOT SPECIFIED(TRACE)
- MAMMARY GLANDS .....  
 -HYPERPLASIA AND/OR HYPERTROPHY OF THE ACINAR TISSUE ..... NOT SPECIFIED(TRACE)  
 -DILATATION (ECTASIA) OF DUCTS AND DUCTULES ..... NOT SPECIFIED (PRESENT)
- BONE, STERNUM .....

Appendix J (cont.): PATHOLOGY INDIVIDUAL ANIMAL DATA

LETTERMAN ARMY INSTITUTE OF RESEARCH  
 DIV OF RES SUPP, PATH SERV GP  
 SPECIES: RAT/FISCHER-344

INDIVIDUAL ANIMAL DATA REPORT  
 STUDY NUMBER: GLP83009

PRINTED: 21-NOV-89  
 PAGE: 139

STUDY START DATE: 23-JAN-84  
 STUDY TYPE: CHRONIC/2 YR CARCINOGENIC

ANIMAL NUMBER: 63/PRETEST=  
 DATE OF DEATH: 03-JAN-86  
 SEX: MALE  
 DOSE GROUP: 1  
 SACRIFICE STATUS: SACRIFICED MORIBUND

STUDY DAY OF DEATH: 712  
 STUDY WEEK OF DEATH: 102  
 TERMINAL BODY WEIGHT: 378.00 (GMS)

<< M I C R O S C O P I C T I S S U E O B S E R V A T I O N S >>  
 TISSUE / HISTOPATHOLOGIC FINDINGS  
 DISTRIBUTION (SEVERITY) / SPECIAL COMMENTS

BONE, STERNUM ..... (PRESENT)  
 -M- LARGE GRANULE LYMPHOCYTE LEUKEMIA, METASTATIC

BONE, FEMUR ..... (PRESENT)  
 -M- LARGE GRANULE LYMPHOCYTE LEUKEMIA, METASTATIC

BONE VERT ..... (PRESENT)  
 -M- LARGE GRANULE LYMPHOCYTE LEUKEMIA, METASTATIC

ADRENAL ..... FOCAL (TRACE)  
 -FOCUS OF CELLULAR ALTERATION, VACUOLATED

EYES & OPTIC N. .... THE LENS OF ONE EYE (SECTION #19A) IS MISSING DUE TO PROCESSING ARTIFACT.

-METAPLASTIC BONE FORMATION AND/OR MINERALIZATION, SCLERA NOT SPECIFIED (PRESENT)

WHOLE BODY ..... NEOPLASTIC LYMPHOCYTES ARE PRESENT IN MANY ORGANS AND TISSUES.  
 -M- LARGE GRANULAR LYMPHOCYTTIC LEUKEMIA (PRESENT)

DIAPHRAGM ..... MISCELLANEOUS TISSUE  
 -COMPOUND RELATED INFLAMMATORY REACTION NOT SPECIFIED (PRESENT)

**Appendix J (cont.): PATHOLOGY INDIVIDUAL ANIMAL DATA**

LETTERMAN ARMY INSTITUTE OF RESEARCH  
 DIV OF RES SUPP, PATH SERV GP  
 SPECIES: RAT/FISCHER-344

INDIVIDUAL ANIMAL DATA REPORT  
 STUDY NUMBER: GLP83009

PRINTED: 21-NOV-89  
 PAGE: 140

STUDY START DATE: 23-JAN-84

STUDY TYPE: CHRONIC/2 YR CARCINOGENIC

ANIMAL NUMBER: 64/PRETEST# 64 SEX: MALE DOSE GROUP: 1 SACRIFICE STATUS: FINAL SACRIFICE  
 DATE OF DEATH: 05-FEB-86 STUDY DAY OF DEATH: 745 STUDY WEEK OF DEATH: 107 TERMINAL BODY WEIGHT: 393.00 (GMS)

ORGAN NAME	KEYWORDS / PHRASES	SEVERITY	GROSS ORGAN OBSERVATIONS >>	GROSS FREE-TEXT COMMENTS
LIVER	ADHESION(S)	PRESENT	DIAPHRAGM, VENTRAL ABDOMINAL WALL, INTESTINES	
LIVER	NODULE(S)	PRESENT	SLIGHTLY PALE, RAISED, LOBULAR, 1.25CM DIAMETER	
TESTES	ENLARGED	PRESENT	RIGHT, 3 X 1.75CM	
TESTES	GROWTH(S) / MASS(ES)	PRESENT	BILATERAL, MULTIPLE VARIABLY SIZED, YELLOW/BLACK	
PITUITARY GLAND	DISCOLORATION	PRESENT	DARK RED, .2CM DIAMETER, FOCAL	

<< MICROSCOPIC TISSUE OBSERVATIONS >>  
 DISTRIBUTION (SEVERITY) / SPECIAL COMMENTS

TISSUE / HISTOPATHOLOGIC FINDINGS	TISSUE IS MISSING
PARATHYROID	
HEART	
-CARDIOMYOPATHY	NOT SPECIFIED(TRACE)
-MEDIAL HYPERTROPHY OF MUSCULAR ARTERIES	NOT SPECIFIED(TRACE)
LUNGS	
-MINERALIZATION OF PULMONARY ARTERIES	NOT SPECIFIED(TRACE)
SPLEEN	
-FIBROSIS CAPSULAR	FOCAL(TRACE)
LYMPH NODES	
-REACTIVE HYPERPLASIA	REACTIVE HYPERPLASIA INCLUDING THE PRESENCE OF MAST CELLS ARE NOTED IN CERVICAL AND MESENTERIC NODES. NOT SPECIFIED (PRESENT)
LIVER	
	VACUOLIZATION OF HEPATOCYTES AND SUBSEQUENT DEGENERATION AND MINERALIZATION ARE MARKED IN ONE AREA. THESE CHANGES PROBABLY ACCOUNT FOR THE GROSS APPEARANCE DESCRIBED AS A SLIGHTLY PALE RAISED LOBULAR NODULE.
-COMPOUND RELATED INFLAMMATORY REACTION	NOT SPECIFIED (PRESENT)
-BILE DUCTULE EPITHELIAL HYPERPLASIA AND/OR CHOLANGIOFIBROSIS	NOT SPECIFIED(MODERATE)
-HEPATITIS	MULTI-FOCAL(TRACE)
-HEPATOCYTTIC VACUOLIZATION	NOT SPECIFIED(SEVERE)

Appendix J (cont.): PATHOLOGY INDIVIDUAL ANIMAL DATA

LETTERMAN ARMY INSTITUTE OF RESEARCH  
 DIV OF RES SUPP, PATH SERV GP  
 SPECIES: RAT/FISCHER-344

INDIVIDUAL ANIMAL DATA REPORT  
 STUDY NUMBER: GLP83009

STUDY START DATE: 23-JAN-84

PRINTED: 21-NOV-89  
 PAGE: 141

ANIMAL NUMBER: 64/PRETEST# 64 SEX: MALE DOSE GROUP: 1 SACRIFICE STATUS: FINAL SACRIFICE  
 DATE OF DEATH: 05-FEB-86 STUDY DAY OF DEATH: 745 STUDY WEEK OF DEATH: 107 TERMINAL BODY WEIGHT: 393.00 (GMS)

STUDY TYPE: CHRONIC/2 YR CARCINOGENIC

<< MICROSCOPIC TISSUE OBSERVATIONS >>  
 TISSUE / HISTOPATHOLOGIC FINDINGS DISTRIBUTION (SEVERITY) / SPECIAL COMMENTS

- LIVER ..... MULTI-FOCAL(MILD)
- NECROSIS ..... NOT SPECIFIED(MILD)
- HEPATOCYTE COALESCING MICROVESICULAR (FATTY) CHANGE LEADING TO NECROSIS AND MINERALIZATION
- KIDNEY ..... NOT SPECIFIED(MILD)
- PROGRESSIVE RENAL DISEASE
- PROSTATE ..... NOT SPECIFIED(TRACE)
- CHRONIC PROSTATITIS ..... NOT SPECIFIED(MILD)
- BENIGN HYPERPLASIA
- SEMINAL VESICLE ..... NOT SPECIFIED (PRESENT)
- GENERALIZED ATROPHY
- TESTES ..... (PRESENT)
- B- INTERSTITIAL CELL ADENOMA
- JEJUNUM ..... NOT SPECIFIED (PRESENT)
- COMPOUND RELATED INFLAMMATORY REACTION
- SKELETAL MUSCLE ..... NOT SPECIFIED (PRESENT)
- CHRONIC INFLAMMATION RESTRICTED TO FASCIA
- MAMMARY GLANDS ..... NOT SPECIFIED (PRESENT)
- DILATATION (ECTASIA) OF DUCTS AND DUCTULES
- PITUITARY GLAND ..... (PRESENT)
- B- ADENOMA
- EYES & OPTIC N. .... NOT SPECIFIED (PRESENT)
- METAPLASTIC BONE FORMATION AND/OR MINERALIZATION, SCLERA
- DIAPHRAGM ..... MISCELLANEOUS TISSUE



Appendix J (cont.): PATHOLOGY INDIVIDUAL ANIMAL DATA

LETTERMAN ARMY INSTITUTE OF RESEARCH  
DIV OF RES SUPP, PATH SERV GP  
SPECIES: RAT/FISCHER-344

INDIVIDUAL ANIMAL DATA REPORT  
STUDY NUMBER: GLP83009  
STUDY START DATE: 23-JAN-84

PRINTED: 21-NOV-89  
PAGE: 142  
STUDY TYPE: CHRONIC/2 YR CARCINOGENIC

ANIMAL NUMBER: 64/PRETEST= 64 SEX: MALE DOSE GROUP: 1 SACRIFICE STATUS: FINAL SACRIFICE  
DATE OF DEATH: 05-FEB-86 STUDY DAY OF DEATH: 745 STUDY WEEK OF DEATH: 107 TERMINAL BODY WEIGHT: 393.00 (GMS)

TISSUE / HISTOPATHOLOGIC FINDINGS << M I C R O S C O P I C T I S S U E O B S E R V A T I O N S >>  
DISTRIBUTION (SEVERITY) / SPECIAL COMMENTS

DIAPHRAGM ..... MISCELLANEOUS TISSUE  
-COMPOUND RELATED INFLAMMATORY REACTION ..... NOT SPECIFIED (PRESENT)

Appendix J (cont.): PATHOLOGY INDIVIDUAL ANIMAL DATA

LETTERMAN ARMY INSTITUTE OF RESEARCH  
DIV OF RES SUPP, PATH SERV GP  
SPECIES: RAT/FISCHER-344

PRINTED: 21-NOV-89  
PAGE: 143

INDIVIDUAL ANIMAL DATA REPORT

STUDY NUMBER: GLP83009

STUDY START DATE: 23-JAN-84

STUDY TYPE: CHRONIC/2 YR CARCINOGENIC

ANIMAL NUMBER: 65/PRETEST# 65 SEX: MALE DOSE GROUP: 1 SACRIFICE STATUS: SACRIFICED MORIBUND  
DATE OF DEATH: 01-AUG-85 STUDY DAY OF DEATH: 557 STUDY WEEK OF DEATH: 80 TERMINAL BODY WEIGHT: 408.00 (GMS)

ORGAN NAME << GROSS ORGAN OBSERVATIONS >>  
SEVERITY GROSS FREE-TEXT COMMENTS

LIVER PRESENT DIAPHRAGM, VENTRAL ABDOMINAL WALL, INTESTINES  
SUBCUTIS PRESENT ULCERATED, FIRM, 1.5 CM X 1.5 CM LATERAL ABDOMEN

TISSUE / HISTOPATHOLOGIC FINDINGS << MICROSCOPIC TISSUE OBSERVATIONS >>  
DISTRIBUTION (SEVERITY) / SPECIAL COMMENTS

HEART  
-CARDIOMYOPATHY NOT SPECIFIED(MILD)

LUNGS  
-MINERALIZATION OF PULMONARY ARTERIES NOT SPECIFIED(TRACE)  
-PERIBRONCHIAL LYMPHOID HYPERPLASIA MULTI-FOCAL(TRACE)

LIVER  
-COMPOUND RELATED INFLAMMATORY REACTION NOT SPECIFIED (PRESENT)  
-BILE DUCTULE EPITHELIAL HYPERPLASIA AND/OR CHOLANGIOFIBROSIS NOT SPECIFIED(MILD)  
-FOCUS OF CELLULAR ALTERATION - BASOPHILIC NOT SPECIFIED(TRACE)  
-NECROSIS MULTI-FOCAL(MILD)

KIDNEY  
-PROGRESSIVE RENAL DISEASE NOT SPECIFIED(MILD)

TESTES  
-B- INTERSTITIAL CELL ADENOMA (PRESENT)

DUODENUM  
-COMPOUND RELATED INFLAMMATORY REACTION NOT SPECIFIED (PRESENT)

PANCREAS  
-COMPOUND RELATED INFLAMMATORY REACTION NOT SPECIFIED (PRESENT)

Appendix J (cont.): PATHOLOGY INDIVIDUAL ANIMAL DATA

LETTERMAN ARMY INSTITUTE OF RESEARCH  
 DIV OF RES SUPP, PATH SERV GP  
 SPECIES: RAT/FISCHER-344

INDIVIDUAL ANIMAL DATA REPORT  
 STUDY NUMBER: GLP83009

STUDY START DATE: 23-JAN-84  
 STUDY TYPE: CHRONIC/2 YR CARCINOGENIC

ANIMAL NUMBER: 65/PRETEST#  
 DOSE GROUP: 1  
 SACRIFICE STATUS: SACRIFICED MORIBUND

DATE OF DEATH: 01-AUG-85  
 SEX: MALE  
 STUDY WEEK OF DEATH: 80  
 TERMINAL BODY WEIGHT: 408.00 (GMS)

TISSUE / HISTOPATHOLOGIC FINDINGS  
 << M I C R O S C O P I C T I S S U E O B S E R V A T I O N S >>  
 DISTRIBUTION (SEVERITY) / SPECIAL COMMENTS

PRINTED: 21-NOV-89  
 PAGE: 144

SKIN ..... THE MASS ON THE LATERAL ABDOMEN IS A FIBROMA.  
 -B- FIBROMA (PRESENT)

PITUITARY GLAND ..... NOT SPECIFIED (PRESENT)  
 -CYST(S)

EYES & OPTIC N. .... NOT SPECIFIED (PRESENT)  
 -METAPLASTIC BONE FORMATION AND/OR MINERALIZATION, SCLERA

DIAPHRAGM ..... MISCELLANEOUS TISSUE  
 -COMPOUND RELATED INFLAMMATORY REACTION NOT SPECIFIED (PRESENT)

**Appendix J (cont.): PATHOLOGY INDIVIDUAL ANIMAL DATA**

LETTERMAN ARMY INSTITUTE OF RESEARCH  
 DIV OF RES SUPP, PATH SERV GP  
 SPECIES: RAT/FISCHER-344

INDIVIDUAL ANIMAL DATA REPORT  
 STUDY NUMBER: GLP83009  
 STUDY START DATE: 23-JAN-84

PRINTED: 21-NOV-89  
 PAGE: 145  
 STUDY TYPE: CHRONIC/2 YR CARCINOGENIC

ANIMAL NUMBER: 66/PRETEST= 66 SEX: MALE DOSE GROUP: 1 SACRIFICE STATUS: FOUND DEAD  
 DATE OF DEATH: 21-JUL-85 STUDY DAY OF DEATH: 546 STUDY WEEK OF DEATH: 78 TERMINAL BODY WEIGHT: 402.00 (GMS)

<< GROSS ORGAN OBSERVATIONS >>  
 SEVERITY GROSS FREE-TEXT COMMENTS

ORGAN NAME KEYWORDS / PHRASES PRESENT RIGHT FLANK, 1.5 X 1CM, SOFT BUT FIRM WHITE SOLID SMOOTH  
 SKIN SUBCUTANEOUS MASS MASS LOOSELY ATTACHED TO ABDOMINAL MUSCULATURE

TESTES GROWTH(S) / MASS(ES) PRESENT IRREGULAR, VARIABLY SIZED, ANTERIOR HALF, YELLOW/WHITE  
 ILEUM GROWTH(S) / MASS(ES) PRESENT 3 X 3 X 4CM DILATION OF ILEUM LOCATED 1/3 LENGTH PROXIMAL  
 TO ILEOCECAL JUNCTION. MASS IS SOLID TISSUE WITH MUCOID-  
 HEMORRHAGIC APPEARANCE.

DUODENUM DISTENDED PRESENT  
 JEJUNUM DISTENDED PRESENT  
 PITUITARY GLAND DISCOLORATION PRESENT

DARK RED, SLIGHTLY RAISED, POSTERIOR SIDE, .2CM DIAMETER

<< MICROSCOPIC TISSUE OBSERVATIONS >>  
 TISSUE / HISTOPATHOLOGIC FINDINGS DISTRIBUTION (SEVERITY) / SPECIAL COMMENTS

SALIVARY GLAND ..... ATROPHY INVOLVES PAROTID GLAND.  
 -ATROPHY AND LOSS OF ACINAR TISSUE ..... DIFFUSE(TRACE)

HEART ..... NOT SPECIFIED(MILD)

-CARDIOMYOPATHY .....

LYMPH NODES ..... REACTIVE HYPERPLASIA AND HISTIOCYTIC INFILTRATION ARE PRESENT  
 IN SEVERAL NODES IN THE MEDIASTINUM. HISTIOCYTIC INFILTRATION  
 IS ALSO PRESENT IN THE MESENTERIC NODE. STIOCYTIC INFILTRATION  
 NOT SPECIFIED (PRESENT)  
 NOT SPECIFIED (PRESENT)

-HISTIOCYTIC INFILTRATION, SUBCAPSULAR AND MEDULLARY SINUSES  
 -REACTIVE HYPERPLASIA

LIVER ..... NOT SPECIFIED (PRESENT)  
 -COMPOUND RELATED INFLAMMATORY REACTION  
 -BILE DUCTULE EPITHELIAL HYPERPLASIA AND/OR CHOLANGIOFIBROSIS  
 -HEPATOCTIC VACUOLIZATION  
 -N- PRESENCE OF METASTATIC SARCOMA

KIDNEY ..... NOT SPECIFIED(TRACE)  
 -PROGRESSIVE RENAL DISEASE

SEMINAL VESICLE ..... NOT SPECIFIED(TRACE)

**Appendix J (cont.): PATHOLOGY INDIVIDUAL ANIMAL DATA**

LETTERMAN ARMY INSTITUTE OF RESEARCH  
 DIV OF RES SUPP, PATH SERV GP  
 SPECIES: RAT/FISCHER-344

INDIVIDUAL ANIMAL DATA REPORT  
 STUDY NUMBER: GLP83009

PRINTED: 21-NOV-89  
 PAGE: 146

STUDY START DATE: 23-JAN-84

STUDY TYPE: CHRONIC/2 YR CARCINOGENIC

ANIMAL NUMBER: 66/PRETEST= 66 SEX: MALE DOSE GROUP: 1 SACRIFICE STATUS: FOUND DEAD  
 DATE OF DEATH: 21-JUL-85 STUDY DAY OF DEATH: 546 STUDY WEEK OF DEATH: 78 TERMINAL BODY WEIGHT: 402.00 (GMS)

<< MICROSCOPIC TISSUE OBSERVATIONS >>  
 TISSUE / HISTOPATHOLOGIC FINDINGS

SEMINAL VESICLE ..... NOT SPECIFIED (PRESENT)  
 -GENERALIZED ATROPHY

TESTES ..... (PRESENT)  
 -B- INTERSTITIAL CELL ADENOMA

JEJUNUM ..... NOT SPECIFIED (PRESENT)  
 -MUCOSAL EROSION/ULCERATION  
 -N- PRESENCE OF METASTATIC SARCOMA

ILEUM ..... SECONDARY NEOPLASM FROM ORGAN ABDOMINAL CAVITY  
 -N- PRESENCE OF METASTATIC SARCOMA  
 -MUCOSAL EROSION/ULCERATION

STOMACH ..... NOT SPECIFIED (PRESENT)  
 -COMPOUND RELATED INFLAMMATORY REACTION

SKIN ..... THE SUBCUTANEOUS MASS IN THE RIGHT FLANK IS A WELL-DEMARCATED,  
 WELL-DIFFERENTIATED FIBROMA. MASSON'S TRICHROME STAIN  
 DEMONSTRATES ABUNDANT MATURE COLLAGEN WITHIN THE TUMOR. PAS,  
 IRON AND GIEMSA STAINS ARE NON-CONTRIBUTORY.  
 (PRESENT)

PITUITARY GLAND ..... (PRESENT)  
 -B- ADENOMA

EYES & OPTIC N. ..... NOT SPECIFIED (TRACE)  
 -CORNEAL MINERALIZATION  
 -METAPLASTIC BONE FORMATION AND/OR MINERALIZATION, SCLERA

MEDIASTINUM ..... MISCELLANEOUS TISSUE  
 -CHRONIC INFLAMMATION  
 -REACTIVE HYPERPLASIA, LYMPH NODE

Appendix J (cont.): PATHOLOGY INDIVIDUAL ANIMAL DATA

LETTERMAN ARMY INSTITUTE OF RESEARCH  
DIV OF RES SUPP. PATH SERV GP  
SPECIES: RAT/FISCHER-344

INDIVIDUAL ANIMAL DATA REPORT  
STUDY NUMBER: GLP83009

PRINTED: 21-NOV-89  
PAGE: 147

STUDY START DATE: 23-JAN-84

STUDY TYPE: CHRONIC/2 YR CARCINOGENIC

ANIMAL NUMBER: 66/PRETEST= 66 SEX: MALE DOSE GROUP: 1 SACRIFICE STATUS: FOUND DEAD  
DATE OF DEATH: 21-JUL-85 STUDY DAY OF DEATH: 546 STUDY WEEK OF DEATH: 78 TERMINAL BODY WEIGHT: 402.00 (GMS)

TISSUE / HISTOPATHOLOGIC FINDINGS << MICROSCOPIC TISSUE OBSERVATIONS >>  
DISTRIBUTION (SEVERITY) / SPECIAL COMMENTS

ABDOMINAL CAVITY ..... MISCELLANEOUS TISSUE  
THE MASS INVOLVING SMALL INTESTINE AND LIVER IS A SARCOMA. IN  
MANY AREAS, THIS NEOPLASM HAS MIXOMATOUS DIFFERENTIATION.  
MASSON'S TRICHRONE STAIN DEMONSTRATES SLIGHT TO MODERATE  
AMOUNTS OF COLLAGEN IN ASSOCIATION WITH THE NEOPLASTIC CELLS.  
THERE ARE A FEW HISTIOCYTIC CELLS CONTAINING IRON POSITIVE  
PIGMENT. PAS AND GIEMSA STAINS ARE NON-CONTRIBUTORY.  
(PRESENT)

-M- SARCOMA, CELLULAR DIFFERENTIATION UNSPECIFIED

**Appendix J (cont.): PATHOLOGY INDIVIDUAL ANIMAL DATA**

LETTERMAN ARMY INSTITUTE OF RESEARCH  
 DIV OF RES SUPP, PATH SERV GP  
 SPECIES: RAT/FISCHER-344  
 ANIMAL NUMBER: 67/PRETEST-  
 DATE OF DEATH: 16-OCT-85 STUDY DAY OF DEATH: 633 SEX: MALE DOSE GROUP: 1 SACRIFICE STATUS: SACRIFICED MORIBUND  
 STUDY START DATE: 23-JAN-84 STUDY NUMBER: GLP83009 STUDY TYPE: CHRONIC/2 YR CARCINOGENIC  
 PRINTED: 21-NOV-89  
 PAGE: 148  
 TERMINAL BODY WEIGHT: 337.00 (GMS)

ORGAN NAME	KEYWORDS / PHRASES	SEVERITY	GROSS OBSERVATIONS	FREE-TEXT COMMENTS
SPLEEN	ENLARGED (SPLENOMEGALY)	MARKED	7 X 2 X 1CM	
PERITONEAL CAV.	RED FOCI IN BODY FAT	PRESENT	DIFFUSE	
LIVER	ADHESION(S)	PRESENT	DIAPHRAGM, VENTRAL ABDOMINAL WALL	
LIVER	PROMINENT LOBULAR MARKINGS	PRESENT		
LIVER	GRANULAR SURFACE	PRESENT		
LYMPH NODES	ENLARGED	MARKED	MESENTERIC	
TESTES	GELATINOUS CONSISTENCY	PRESENT	BILATERAL	
SEMINAL VESICLE	TRANSPARENT, SOFT, FLACCID	PRESENT	BILATERAL	

TISSUE / HISTOPATHOLOGIC FINDINGS  
 << MICROSCOPIC TISSUE OBSERVATIONS >>  
 DISTRIBUTION (SEVERITY) / SPECIAL COMMENTS

BRAIN ..... THERE IS A FOCAL CAVITATION IN THE LATERAL PART OF THE THALAMUS WHICH IS FILLED WITH BLOOD. FOCAL(MILD)

-LIGUIFACTION NECROSIS ..... NOT SPECIFIED(MODERATE)

TRACHEA .....  
 -NON-SUPPURATIVE TRACHEITIS ..... NOT SPECIFIED (PRESENT)

THYROID GLANDS .....  
 -COLLOID CYST(S) ..... TISSUE IS MISSING

PARATHYROID .....  
 HEART .....  
 -CARDIOMYOPATHY .....  
 -W- LARGE GRANULAR LYMPHOCYTE LEUKEMIA, METASTATIC ..... NOT SPECIFIED(MILD) (PRESENT)

LUNGS .....  
 -W- LARGE GRANULAR LYMPHOCYTE LEUKEMIA, METASTATIC ..... (PRESENT)

THYMUS .....

**Appendix J (cont.): PATHOLOGY INDIVIDUAL ANIMAL DATA**

LETTERMAN ARMY INSTITUTE OF RESEARCH  
 DIV OF RES SUPP. PATH SERV GP  
 SPECIES: RAT/FISCHER-344  
 STUDY START DATE: 23-JAN-84  
 STUDY NUMBER: GLP83009  
 PRINTED: 21-NOV-89  
 PAGE: 149

ANIMAL NUMBER: 67/PRETEST-67 SEX: MALE DOSE GROUP: 1 SACRIFICE STATUS: SACRIFICED MORIBUND  
 DATE OF DEATH: 16-OCT-85 STUDY DAY OF DEATH: 633 STUDY WEEK OF DEATH: 91 TERMINAL BODY WEIGHT: 337.00 (GMS)  
 STUDY TYPE: CHRONIC/2 YR CARCINOGENIC

TISSUE / HISTOPATHOLOGIC FINDINGS  
 << MICROSCOPIC TISSUE OBSERVATIONS >>  
 DISTRIBUTION (SEVERITY) / SPECIAL COMMENTS

- THYMUS ..... (PRESENT)
- N- LARGE GRANULAR LYMPHOCYTE LEUKEMIA, METASTATIC
- SPLEEN ..... (PRESENT)
- N- LARGE GRANULAR LYMPHOCYTE LEUKEMIA, METASTATIC
- LYMPH NODES ..... ALL LYMPH NODES EXAMINED MICROSCOPICALLY (CERVICAL, MEDIASTINAL AND MESENTERIC) WERE COMPLETELY EFFACED BY NEOPLASTIC LYMPHOCYTE PROLIFERATION. (PRESENT)
- N- LARGE GRANULAR LYMPHOCYTE LEUKEMIA, METASTATIC
- LIVER ..... NOT SPECIFIED (PRESENT)
- COMPOUND RELATED INFLAMMATORY REACTION NOT SPECIFIED (MILD)
- BILE DUCTULE EPITHELIAL HYPERPLASIA AND/OR CHOLANGIOFIBROSIS MULTI-FOCAL (MILD)
- NECROSIS (PRESENT)
- N- LARGE GRANULAR LYMPHOCYTE LEUKEMIA, METASTATIC
- KIDNEY ..... NOT SPECIFIED (MILD)
- PROGRESSIVE RENAL DISEASE (PRESENT)
- N- LARGE GRANULAR LYMPHOCYTE LEUKEMIA, METASTATIC
- URINARY BLADDER ..... THERE IS NEOPLASTIC LYMPHOCYtic INFILTRATION IN THE SUB-MUCOSA OF THE URINARY BLADDER.
- PROSTATE ..... NOT SPECIFIED (TRACE)
- BENIGN HYPERPLASIA
- TESTES ..... (PRESENT)
- B- INTERSTITIAL CELL ADENOMA
- ILEUM ..... (PRESENT)
- N- LARGE GRANULAR LYMPHOCYTE LEUKEMIA, METASTATIC
- PANCREAS ..... (PRESENT)



Appendix J (cont.): PATHOLOGY INDIVIDUAL ANIMAL DATA

LETTERMAN ARMY INSTITUTE OF RESEARCH  
DIV OF RES SUPP, PATH SERV GP  
SPECIES: RAT/FISCHER-344

INDIVIDUAL ANIMAL DATA REPORT  
STUDY NUMBER: GLP83009

PRINTED: 21-NOV-89  
PAGE: 150

STUDY START DATE: 23-JAN-84

STUDY TYPE: CHRONIC/2 YR CARCINOGENIC

ANIMAL NUMBER: 67/PRETEST# 67 SEX: MALE DOSE GROUP: 1 SACRIFICE STATUS: SACRIFICED MORIBUND  
DATE OF DEATH: 16-OCT-85 STUDY DAY OF DEATH: 633 STUDY WEEK OF DEATH: 91 TERMINAL BODY WEIGHT: 337.00 (GMS)

TISSUE / HISTOPATHOLOGIC FINDINGS << M I C R O S C O P I C T I S S U E O B S E R V A T I O N S >>  
DISTRIBUTION (SEVERITY) / SPECIAL COMMENTS

PANCREAS .....  
-N- LARGE GRANULAR LYMPHOCYTE LEUKEMIA, METASTATIC (PRESENT)

STOMACH .....  
-N- LARGE GRANULE LYMPHOCYTE LEUKEMIA, METASTATIC (PRESENT)

SCIATIC NERVE ..... TISSUE IS MISSING

MAMMARY GLANDS .....  
-DILATATION (ECTASIA) OF DUCTS AND DUCTULES FOCAL (PRESENT)

PITUITARY GLAND .....  
-CYST(S) NOT SPECIFIED (PRESENT)

EYES & OPTIC N. ....  
-METAPLASTIC BONE FORMATION AND/OR MINERALIZATION, SCLERA NOT SPECIFIED (PRESENT)

WHOLE BODY .....  
VIRTUALLY EVERY ORGAN AND TISSUE IN THIS ANIMAL CONTAINS AT LEAST A FEW NEOPLASTIC LYMPHOCYTES. THE LESION WAS CODED ONLY IN THOSE ORGANS AND TISSUES THAT WERE SO EXTENSIVELY INVOLVED AS TO DISTORT TISSUE ARCHITECTURE. (PRESENT)

-M- LARGE GRANULAR LYMPHOCYTTIC LEUKEMIA  
DIAPHRAGM ..... MISCELLANEOUS TISSUE  
-COMPOUND RELATED INFLAMMATORY REACTION NOT SPECIFIED (PRESENT)

**Appendix J (cont.): PATHOLOGY INDIVIDUAL ANIMAL DATA**

LETTERMAN ARMY INSTITUTE OF RESEARCH  
 DIV OF RES SUPP, PATH SERV GP  
 SPECIES: RAT/FISCHER-344

INDIVIDUAL ANIMAL DATA REPORT  
 STUDY NUMBER: GLP83009  
 STUDY START DATE: 23-JAN-84

PRINTED: 21-NOV-89  
 PAGE: 151  
 STUDY TYPE: CHRONIC/2 YR CARCINOGENIC

ANIMAL NUMBER: 68/PRETEST=  
 DATE OF DEATH: 05-FEB-86 STUDY DAY OF DEATH: 745  
 DOSE GROUP: 1 SACRIFICE STATUS: FINAL SACRIFICE  
 STUDY WEEK OF DEATH: 107 TERMINAL BODY WEIGHT: 367.00 (GMS)

<< GROSS ORGAN OBSERVATIONS >>  
 SEVERITY GROSS FREE-TEXT COMMENTS  
 ORGANS / PHRASES  
 EYES & OPTIC N. PRESENT RIGHT  
 LIVER ADHESION(S) PRESENT DIAPHRAGM, VENTRAL ABDOMINAL WALL  
 TESTES GROWTH(S) / MASS(ES) PRESENT BILATERAL, MULTIPLE VARIABLY SIZED, YELLOW

<< MICROSCOPIC TISSUE OBSERVATIONS >>  
 DISTRIBUTION (SEVERITY) / SPECIAL COMMENTS  
 THYROID GLANDS (PRESENT)  
 -B- PARA-FOLLICULAR CELL ADENOMA  
 HEART NOT SPECIFIED(TRACE)  
 -CARDIOMYOPATHY  
 LUNGS NOT SPECIFIED(TRACE)  
 -MINERALIZATION OF PULMONARY ARTERIES  
 SPLEEN NOT SPECIFIED(TRACE)  
 -FIBROSIS CAPSULAR  
 LYMPH NODES RBC'S AND PIGMENT PRESENT IN MEDIASTINAL NODE ONLY.  
 -RED BLOOD CELLS, HEMOSIDERIN AND/OR ERYTHROPHAGOCYTOSIS WITHIN NOT SPECIFIED (PRESENT)  
 MEDULLARY SINUSES  
 LIVER NOT SPECIFIED (PRESENT)  
 -COMPOUND RELATED INFLAMMATORY REACTION NOT SPECIFIED(MILD)  
 -BILE DUCTULE EPITHELIAL HYPERPLASIA AND/OR CHOLANGIOFIBROSIS NOT SPECIFIED(MARKED)  
 -HEPATOCYTE COALESCING MICROVESICULAR (FATTY) CHANGE LEADING TO NECROSIS AND MINERALIZATION  
 KIDNEY NOT SPECIFIED(MILD)  
 -PROGRESSIVE RENAL DISEASE  
 PROSTATE

**Appendix J (cont.): PATHOLOGY INDIVIDUAL ANIMAL DATA**

LETTERMAN ARMY INSTITUTE OF RESEARCH  
 DIV OF RES SUPP, PATH SERV GP  
 SPECIES: RAT/FISCHER-344  
 STUDY NUMBER: GLP83009  
 STUDY START DATE: 23-JAN-84  
 STUDY TYPE: CHRONIC/2 YR CARCINOGENIC  
 PRINTED: 21-NOV-89  
 PAGE: 152

ANIMAL NUMBER: 68/PRETEST-  
 DATE OF DEATH: 05-FEB-86  
 SEX: MALE  
 DOSE GROUP: 1  
 SACRIFICE STATUS: FINAL SACRIFICE  
 STUDY WEEK OF DEATH: 745  
 TERMINAL BODY WEIGHT: 367.00 (GMS)

<< MICROSCOPIC TISSUE OBSERVATIONS >>  
 DISTRIBUTION (SEVERITY) / SPECIAL COMMENTS

- PROSTATE ..... NOT SPECIFIED (TRACE)
- CHRONIC PROSTATITIS
- SEMINAL VESICLE ..... NOT SPECIFIED (PRESENT)
- GENERALIZED ATROPHY
- TESTES ..... (PRESENT)
- B- INTERSTITIAL CELL ADENOMA
- SKELETAL MUSCLE ..... TISSUE IS MISSING
- SCIATIC NERVE ..... TISSUE IS MISSING
- MAMMARY GLANDS ..... NOT SPECIFIED (PRESENT)
- DILATATION (ECTASIA) OF DUCTS AND DUCTULES
- EYES & OPTIC N. ....
- RETINAL ATROPHY AND/OR DEGENERATION, UNILATERAL OR BILATERAL
- METAPLASTIC BONE FORMATION AND/OR MINERALIZATION, SCLERA
- LENTICULAR DEGENERATIVE CHANGES COMPATIBLE WITH CATARACT
- DIAPHRAGM ..... MISCELLANEOUS TISSUE
- COMPOUND RELATED INFLAMMATORY REACTION

**Appendix J (cont.): PATHOLOGY INDIVIDUAL ANIMAL DATA**

LETTERMAN ARMY INSTITUTE OF RESEARCH  
 DIV OF RES SUPP, PATH SERV GP  
 SPECIES: RAT/FISCHER-344  
 STUDY START DATE: 23-JAN-84  
 STUDY NUMBER: GLP83009  
 PRINTED: 21-NOV-89  
 PAGE: 163  
 STUDY TYPE: CHRONIC/2 YR CARCINOGENIC

ANIMAL NUMBER: 79/PRETEST-79  
 DATE OF DEATH: 19-DEC-85  
 SEX: MALE  
 DOSE GROUP: 2  
 SACRIFICE STATUS: FOUND DEAD  
 STUDY WEEK OF DEATH: 697  
 TERMINAL BODY WEIGHT: 420.00 (GMS)

ORGAN NAME  
 KEYWORDS / PHRASES  
 GROSS ORGAN OBSERVATIONS  
 SEVERITY GROSS FREE-TEXT COMMENTS

PERITONEAL CAV. FRANK BLOOD PRESENT PRESENT  
 SPLEEN ENLARGED (SPLENOMEGALY) MARKED 6 X 3CM  
 LIVER FRACTURED PRESENT  
 LIVER ADHESION(S) PRESENT  
 LIVER SWOLLEN MODERATE  
 KIDNEY PITTED SURFACE PRESENT  
 TESTES GROWTH(S) / MASS(ES) PRESENT

VENTRAL ABDOMINAL WALL, 1CM AREA  
 DIFFUSE  
 RIGHT, WHITE, SUBCAPSULAR, 1CM DIAMETER

TISSUE / HISTOPATHOLOGIC FINDINGS  
 OBSERVATIONS  
 DISTRIBUTION (SEVERITY) / SPECIAL COMMENTS

HEART  
 -CARDIOMYOPATHY NOT SPECIFIED(MODERATE)

SPLEEN  
 -N- LARGE GRANULAR LYMPHOCYTE LEUKEMIA, METASTATIC (PRESENT)

LYMPH NODES  
 REACTIVE HYPERPLASIA NOTED IN CERVICAL NODES. NORMAL MODAL ARCHITECTURE OF MEDIASTINAL AND MESENTERIC NODES IS COMPLETELY EFFACED BY METASTATIC LGLL.  
 (PRESENT)  
 NOT SPECIFIED (PRESENT)

LIVER  
 -COMPOUND RELATED INFLAMMATORY REACTION NOT SPECIFIED (PRESENT)  
 -BILE DUCTULE EPITHELIAL HYPERPLASIA AND/OR CHOLANGIOFIBROSIS NOT SPECIFIED(MILD)  
 -NECROSIS, HEPATOCYTTIC, INDIVIDUAL CELLS MULTI-FOCAL(TRACE)  
 -N- LARGE GRANULAR LYMPHOCYTE LEUKEMIA, METASTATIC (PRESENT)

KIDNEY  
 -PROGRESSIVE RENAL DISEASE NOT SPECIFIED(MODERATE)

PROSTATE

**Appendix J (cont.): PATHOLOGY INDIVIDUAL ANIMAL DATA**

LETTERMAN ARMY INSTITUTE OF RESEARCH  
 DIV OF RES SUPP. PATH SERV GP  
 SPECIES: RAT/FISCHER-344

INDIVIDUAL ANIMAL DATA REPORT  
 STUDY NUMBER: GLP83009  
 STUDY START DATE: 23-JAN-84

ANIMAL NUMBER: 79/PRETEST= 79 SEX: MALE DOSE GROUP: 2 SACRIFICE STATUS: FOUND DEAD  
 DATE OF DEATH: 19-DEC-85 STUDY DAY OF DEATH: 697 STUDY WEEK OF DEATH: 100 TERMINAL BODY WEIGHT: 420.00 (GMS)

STUDY TYPE: CHRONIC/2 YR CARCINOGENIC  
 << MICROSCOPIC TISSUE OBSERVATIONS >>

TISSUE / HISTOPATHOLOGIC FINDINGS  
 DISTRIBUTION (SEVERITY) / SPECIAL COMMENTS

PROSTATE ..... NOT SPECIFIED(MILD)  
 -BENIGN HYPERPLASIA

TESTES ..... (PRESENT)  
 -B- INTERSTITIAL CELL ADENOMA

NOSE/TURBINATES ..... CELLULAR INFILTRATE IS ADJACENT NASO-LACRIMAL DUCTS.  
 -MIXED INFLAMMATORY CELL INFILTRATION, NASAL CAVITY, SINUSES, NOT SPECIFIED(MILD)  
 -TURBINATES, NASO-LACRIMAL DUCTS

BONE, STERNUM ..... NOT SPECIFIED (PRESENT)  
 -MYELOID HISTIOCYTOSIS

BONE, FEMUR ..... NOT SPECIFIED (PRESENT)  
 -MYELOID HISTIOCYTOSIS

BONE VERT ..... NOT SPECIFIED (PRESENT)  
 -MYELOID HISTIOCYTOSIS

EYES & OPTIC N. .... DIFFUSE(MARKED)  
 -RETINAL ATROPHY AND/OR DEGENERATION, UNILATERAL OR BILATERAL NOT SPECIFIED (PRESENT)  
 -METAPLASTIC BONE FORMATION AND/OR MINERALIZATION, SCLERA NOT SPECIFIED (PRESENT)  
 -LENTICULAR DEGENERATIVE CHANGES COMPATIBLE WITH CATARACT

WHOLE BODY ..... (PRESENT)  
 -M- LARGE GRANULAR LYMPHOCYTTIC LEUKEMIA

**Appendix J (cont.): PATHOLOGY INDIVIDUAL ANIMAL DATA**

LETTERMAN ARMY INSTITUTE OF RESEARCH  
 DIV OF RES SUPP, PATH SERV GP  
 SPECIES: RAT/FISCHER-344  
 STUDY START DATE: 23-JAN-84  
 STUDY NUMBER: GLP83009  
 PRINTED: 21-NOV-89  
 PAGE: 165  
 STUDY TYPE: CHRONIC/2 YR CARCINOGENIC

ANIMAL NUMBER: 80/PRETEST= 80 SEX: MALE  
 DATE OF DEATH: 27-JAN-86 STUDY DAY OF DEATH: 736  
 DOSE GROUP: 2  
 SACRIFICE STATUS: FINAL SACRIFICE  
 STUDY WEEK OF DEATH: 106 TERMINAL BODY WEIGHT: 381.00 (GMS)

ORGAN NAME SEVERITY GROSS OBSERVATIONS  
 KEYWORDS / PHRASES OBSERVATIONS >>  
 GROSS OBSERVATIONS >>  
 SKIN PRESENT TOP OF HEAD BETWEEN EARS, 4MM DIAMETER  
 LIVER PRESENT 1.5CM AREA, VENTRAL PERITONEAL WALL  
 TESTES ENLARGED 3.5 X 2CM  
 TESTES GROWTH(S) / MASS(ES) PRESENT ENTIRE TESTICLE, RIGHT, MOTTLED RED AND BLACK.

TISSUE / HISTOPATHOLOGIC FINDINGS  
 << MICROSCOPIC TISSUE OBSERVATIONS >>  
 DISTRIBUTION (SEVERITY) / SPECIAL COMMENTS

THYROID GLANDS ..... (PRESENT)  
 -B- PARA-FOLLICULAR CELL ADENOMA .....  
 LACRIMAL GLAND ..... NOT SPECIFIED(TRACE)  
 -ATROPHY AND/OR LOSS OF ACINAR TISSUE .....  
 EXORBITAL LACRIM ..... NOT SPECIFIED(TRACE)  
 -ACINAR ATROPHY .....  
 HEART ..... NOT SPECIFIED(MILD)  
 -CARDIOMYOPATHY .....  
 LUNGS ..... NOT SPECIFIED(TRACE)  
 -MINERALIZATION OF PULMONARY ARTERIES .....  
 LYMPH NODES ..... REACTIVE HYPERPLASIA NOTED IN CERVICAL NODE.  
 -REACTIVE HYPERPLASIA ..... NOT SPECIFIED (PRESENT)

LIVER ..... NOT SPECIFIED (PRESENT)  
 -COMPOUND RELATED INFLAMMATORY REACTION .....  
 -BILE DUCTULE EPITHELIAL HYPERPLASIA AND/OR CHOLANGIOFIBROSIS .....  
 -FOCUS OF CELLULAR ALTERATION - BASOPHILIC .....  
 -HEPATOCTYIC VACUOLIZATION .....  
 -BENIGN HYPERPLASTIC MODULE(S) .....  
 KIDNEY ..... FOCAL(TRACE)

Appendix J (cont.): PATHOLOGY INDIVIDUAL ANIMAL DATA

LETTERMAN ARMY INSTITUTE OF RESEARCH  
DIV OF RES SUPP, PATH SERV GP  
SPECIES: RAT/FISCHER-344

INDIVIDUAL ANIMAL DATA REPORT  
STUDY NUMBER: GLP83009  
STUDY START DATE: 23-JAN-84

PRINTED: 21-NOV-89  
PAGE: 166  
STUDY TYPE: CHRONIC/2 YR CARCINOGENIC

ANIMAL NUMBER: 80/PRETEST 80 SEX: MALE DOSE GROUP: 2 SACRIFICE STATUS: FINAL SACRIFICE  
DATE OF DEATH: 27-JAN-86 STUDY DAY OF DEATH: 736 STUDY WEEK OF DEATH: 106 TERMINAL BODY WEIGHT: 381.00 (GMS)

TISSUE / HISTOPATHOLOGIC FINDINGS << M I C R O S C O P I C T I S S U E O B S E R V A T I O N S >>  
DISTRIBUTION (SEVERITY) / SPECIAL COMMENTS

KIDNEY ..... NOT SPECIFIED(MODERATE)  
-PROGRESSIVE RENAL DISEASE

PROSTATE ..... NOT SPECIFIED(MILD)  
-CHRONIC PROSTATITIS  
-BENIGN HYPERPLASIA

TESTES ..... (PRESENT)  
-B- INTERSTITIAL CELL ADENOMA

SKIN ..... LESION ON TOP OF THE HEAD IS A BASAL CELL TUMOR WHICH APPEARS  
TO BE BEIGN HISTOLOGICALLY.  
-B- BASAL CELL TUMOR (PRESENT)

PITUITARY GLAND ..... (PRESENT)  
-B- ADENOMA

AD SEBACIOUS ..... TISSUE IS MISSING

ABDOMINAL CAVITY ..... MISCELLANEOUS TISSUE  
TEST MATERIAL AND ASSOCIATED GRANULOMATOUS REACTION IS PRESENT  
BETWEEN LIVER AND SKELETAL MUSCLE TISSUE. THIS PROBABLY IS THE  
ADHESION TO THE VENTRAL PERITONEAL WALL NOTED GROSSLY.  
-CHRONIC INFLAMMATION DUE TO THE PRESENCE OF TEST COMPOUND (SITE NOT SPECIFIED (PRESENT)  
SPECIFIED IN COMMENTS)

**Appendix J (cont.): PATHOLOGY INDIVIDUAL ANIMAL DATA**

LETTERMAN ARMY INSTITUTE OF RESEARCH  
 DIV OF RES SUPP, PATH SERV GP  
 SPECIES: RAT/FISCHER-344  
 STUDY START DATE: 23-JAN-84  
 STUDY NUMBER: GLP83009  
 PRINTED: 21-NOV-89  
 PAGE: 167  
 STUDY TYPE: CHRONIC/2 YR CARCINOGENIC

ANIMAL NUMBER: 81/PRETEST-  
 DATE OF DEATH: 27-JAN-86  
 DOSE GROUP: 2  
 STUDY WEEK OF DEATH: 106  
 SACRIFICE STATUS: FINAL SACRIFICE  
 TERMINAL BODY WEIGHT: 368.00 (GMS)

<< GROSS ORGAN OBSERVATIONS >>  
 SEVERITY GROSS FREE-TEXT COMMENTS  
 LIVER ADMETON(S) PRESENT 1.5 X 1CM AREA, VENTRAL PERITONEAL WALL  
 KIDNEY GRANULAR SURFACE PRESENT BILATERAL  
 TUITARY GLAND ENLARGED PRESENT 6MM DIAMETER, MOTTLED RED AND BLACK

TISSUE / HISTOPATHOLOGIC FINDINGS  
 << MICROSCOPIC TISSUE OBSERVATIONS >>  
 DISTRIBUTION (SEVERITY) / SPECIAL COMMENTS

- HEART ..... NOT SPECIFIED(MILD)
- LUNGS ..... NOT SPECIFIED(TRACE)
- MINERALIZATION OF PULMONARY ARTERIES
- LYMPH NODES ..... RBC'S, PIGMENT AND REACTIVE HYPERPLASIA NOTED IN SEVERAL NODES IN THE CERVICAL AREA.  
 -RED BLOOD CELLS, HEMOSIDERIN AND/OR ERYTHROPHAGOCYTOSIS WITHIN NOT SPECIFIED (PRESENT)  
 MEDULLARY SINUSES NOT SPECIFIED (PRESENT)  
 -REACTIVE HYPERPLASIA
- LIVER ..... NOT SPECIFIED (PRESENT)  
 -COMPOUND RELATED INFLAMMATORY REACTION NOT SPECIFIED(MILD)  
 -BILE DUCTULE EPITHELIAL HYPERPLASIA AND/OR CHOLANGIOFIBROSIS MULTI-FOCAL(TRACE)  
 -HEPATOCTYIC VACUOLIZATION NOT SPECIFIED (PRESENT)  
 -CYSTIC DEGENERATION MULTI-FOCAL(TRACE)  
 -NECROSIS, HEPATOCTYIC, INDIVIDUAL CELLS
- KIDNEY ..... NOT SPECIFIED(MODERATE)  
 -PROGRESSIVE RENAL DISEASE
- PROSTATE ..... NOT SPECIFIED(MILD)  
 -CHRONIC PROSTATITIS NOT SPECIFIED(TRACE)  
 -BENIGN HYPERPLASIA
- TESTES .....



Appendix J (cont.): PATHOLOGY INDIVIDUAL ANIMAL DATA

LETTERMAN ARMY INSTITUTE OF RESEARCH  
DIV OF RES SUPP, PATH SERV GP  
SPECIES: RAT/FISCHER-344

INDIVIDUAL ANIMAL DATA REPORT  
STUDY NUMBER: GLP83009

PRINTED: 21-NOV-89  
PAGE: 168

STUDY START DATE: 23-JAN-84

STUDY TYPE: CHRONIC/2 YR CARCINOGENIC

ANIMAL NUMBER: 81/PRETEST-  
DATE OF DEATH: 27-JAN-86

81 SEX: MALE  
STUDY DAY OF DEATH: 736

DOSE GROUP: 2  
STUDY WEEK OF DEATH: 106

SACRIFICE STATUS: FINAL SACRIFICE  
TERMINAL BODY WEIGHT: 368.00 (GMS)

<< MICROSCOPIC TISSUE  
DISTRIBUTION (SEVERITY) / SPECIAL COMMENTS

OBSERVATIONS >>

TESTES

-PERIARTERITIS NODOSA

NOT SPECIFIED (PRESENT)

NOSE/TURBINATES

-MIXED INFLAMMATORY CELL INFILTRATION, NASAL CAVITY, SINUSES,  
TURBINATES, NASO-LACRIMAL DUCTS

CELLULAR INFILTRATE IS ADJACENT NASO-LACRIMAL DUCT.  
NOT SPECIFIED(MILD)

ADRENAL

-LIPIDOSIS

DIFFUSE(MILD)

PITUITARY GLAND

-B- ADENOMA

(PRESENT)

**Appendix J (cont.): PATHOLOGY INDIVIDUAL ANIMAL DATA**

LETTERMAN ARMY INSTITUTE OF RESEARCH  
 DIV OF RES SUPP, PATH SERV GP  
 SPECIES: RAT/FISCHER-344  
 STUDY NUMBER: GLP83009  
 STUDY START DATE: 23-JAN-84  
 STUDY TYPE: CHRONIC/2 YR CARCINOGENIC  
 PRINTED: 21-NOV-89  
 PAGE: 169  
 ANIMAL NUMBER: 82/PRETEST= 82 SEX: MALE DOSE GROUP: 2 SACRIFICE STATUS: SACRIFICED MORIBUND  
 DATE OF DEATH: 11-DEC-85 STUDY DAY OF DEATH: 689 STUDY WEEK OF DEATH: 99 TERMINAL BODY WEIGHT: 317.00 (GMS)

ORGAN NAME	KEYWORDS / PHRASES	ORGAN OBSERVATIONS	SEVERITY	GROSS FREE-TEXT COMMENTS
LIVER	ADHESION(S)	PRESENT		VENTRAL ABDOMINAL WALL
TESTES	GROWTH(S) / MASS(ES)	PRESENT		LEFT, MULTIPLE VARIABLY SIZED
TESTES	ATROPHIC / SMALL, UNILATERALLY	PRESENT		RIGHT, 1.5 X .75CM
JEJUNUM	GROWTH(S) / MASS(ES)	PRESENT		WHITE, 1CM DIAMETER
KIDNEY	DISCOLORATION	PRESENT		MINUTE, MULTIPLE, FOCAL, TAN
PITUITARY GLAND	ENLARGED	PRESENT		1 X .75CM, WHITE WITH MULTIPLE PINPOINT BLACK FOCI

TISSUE / HISTOPATHOLOGIC FINDINGS  
 << MICROSCOPIC TISSUE OBSERVATIONS >>  
 DISTRIBUTION (SEVERITY) / SPECIAL COMMENTS

- HEART ..... NOT SPECIFIED(MILD)
- CARDIOMYOPATHY
- LUNGS ..... FOCAL(TRACE)
- MINERALIZATION OF PULMONARY ARTERIES
- ALVEOLAR HEMORRHAGE ..... MULTI-FOCAL (PRESENT)
- SPLEEN ..... NOT SPECIFIED(MILD)
- LYMPHOID HYPERPLASIA OF THE SPLENIC CORPUSCLES
- LYMPH NODES ..... REACTIVE HYPERPLASIA NOTED IN CERVICAL NODES.
- ..... REACTIVE HYPERPLASIA, RBC'S AND PIGMENT PRESENT IN MEDIASTINAL NODES.
- RED BLOOD CELLS, HEMOSIDERIN AND/OR ERYTHROPHAGOCYTOSIS WITHIN ..... NOT SPECIFIED (PRESENT)
- MEDULLARY SINUSES ..... NOT SPECIFIED (PRESENT)
- REACTIVE HYPERPLASIA
- LIVER ..... NOT SPECIFIED (PRESENT)
- COMPOUND RELATED INFLAMMATORY REACTION ..... NOT SPECIFIED(MILD)
- BILE DUCTULE EPITHELIAL HYPERPLASIA AND/OR CHOLANGIOFIBROSIS ..... MULTI-FOCAL(MILD)
- NECROSIS ..... NOT SPECIFIED(TRACE)
- BENIGN HYPERPLASTIC NODULE(S)

**Appendix J (cont.): PATHOLOGY INDIVIDUAL ANIMAL DATA**

LETTERMAN ARMY INSTITUTE OF RESEARCH  
 DIV OF RES SUPP, PATH SERV GP  
 SPECIES: RAT/FISCHER-344

INDIVIDUAL ANIMAL DATA REPORT  
 STUDY NUMBER: GLP83009  
 STUDY START DATE: 23-JAN-84

82 SEX: MALE  
 DOSE GROUP: 2  
 SACRIFICE STATUS: SACRIFICED MORIBUND

11-DEC-85 STUDY DAY OF DEATH: 689  
 STUDY WEEK OF DEATH: 99  
 TERMINAL BODY WEIGHT: 317.00 (GMS)

82/PRETEST  
 STUDY DAY OF DEATH: 689  
 STUDY WEEK OF DEATH: 99

ANIMAL NUMBER: 82/PRETEST  
 DATE OF DEATH: 11-DEC-85

PRINTED: 21-NOV-89  
 PAGE: 170  
 STUDY TYPE: CHRONIC/2 YR CARCINOGENIC

TERMINAL BODY WEIGHT: 317.00 (GMS)

DOSE GROUP: 2

STUDY DAY OF DEATH: 689

STUDY WEEK OF DEATH: 99

ANIMAL NUMBER: 82/PRETEST

**TISSUE / HISTOPATHOLOGIC FINDINGS**

<< MICROSCOPIC TISSUE OBSERVATIONS >>

DISTRIBUTION (SEVERITY) / SPECIAL COMMENTS

SECONDARY NEOPLASM FROM ORGAN ABDOMINAL CAVITY

NOT SPECIFIED(MILD)

NOT SPECIFIED(TRACE)

NOT SPECIFIED(TRACE)

(PRESENT)

SECONDARY NEOPLASM FROM ORGAN ABDOMINAL CAVITY

NOT SPECIFIED (PRESENT)

CELLULAR INFILTRATE IS ADJACENT NASO-LACRIMAL DUCT.  
 NOT SPECIFIED(TRACE)

MISCELLANEOUS TISSUE  
 DIFFUSE(MILD)

MISCELLANEOUS TISSUE

MISCELLANEOUS TISSUE

MISCELLANEOUS TISSUE

MISCELLANEOUS TISSUE

SECONDARY NEOPLASM FROM ORGAN ABDOMINAL CAVITY

NOT SPECIFIED (PRESENT)

NOT SPECIFIED (PRESENT)

NOT SPECIFIED (PRESENT)

NOT SPECIFIED (PRESENT)

CELLULAR INFILTRATE IS ADJACENT NASO-LACRIMAL DUCT.  
 NOT SPECIFIED(TRACE)

MISCELLANEOUS TISSUE  
 DIFFUSE(MILD)

MISCELLANEOUS TISSUE

MISCELLANEOUS TISSUE

MISCELLANEOUS TISSUE

MISCELLANEOUS TISSUE

SECONDARY NEOPLASM FROM ORGAN ABDOMINAL CAVITY

NOT SPECIFIED (PRESENT)

NOT SPECIFIED (PRESENT)

NOT SPECIFIED (PRESENT)

NOT SPECIFIED (PRESENT)

CELLULAR INFILTRATE IS ADJACENT NASO-LACRIMAL DUCT.  
 NOT SPECIFIED(TRACE)

MISCELLANEOUS TISSUE  
 DIFFUSE(MILD)

MISCELLANEOUS TISSUE

MISCELLANEOUS TISSUE

MISCELLANEOUS TISSUE

MISCELLANEOUS TISSUE

SECONDARY NEOPLASM FROM ORGAN ABDOMINAL CAVITY

NOT SPECIFIED (PRESENT)

NOT SPECIFIED (PRESENT)

NOT SPECIFIED (PRESENT)

NOT SPECIFIED (PRESENT)

CELLULAR INFILTRATE IS ADJACENT NASO-LACRIMAL DUCT.  
 NOT SPECIFIED(TRACE)

MISCELLANEOUS TISSUE  
 DIFFUSE(MILD)

MISCELLANEOUS TISSUE

MISCELLANEOUS TISSUE

MISCELLANEOUS TISSUE

MISCELLANEOUS TISSUE

SECONDARY NEOPLASM FROM ORGAN ABDOMINAL CAVITY

NOT SPECIFIED (PRESENT)

NOT SPECIFIED (PRESENT)

NOT SPECIFIED (PRESENT)

NOT SPECIFIED (PRESENT)

CELLULAR INFILTRATE IS ADJACENT NASO-LACRIMAL DUCT.  
 NOT SPECIFIED(TRACE)

MISCELLANEOUS TISSUE  
 DIFFUSE(MILD)

MISCELLANEOUS TISSUE

MISCELLANEOUS TISSUE

MISCELLANEOUS TISSUE

MISCELLANEOUS TISSUE

SECONDARY NEOPLASM FROM ORGAN ABDOMINAL CAVITY

NOT SPECIFIED (PRESENT)

NOT SPECIFIED (PRESENT)

NOT SPECIFIED (PRESENT)

NOT SPECIFIED (PRESENT)

CELLULAR INFILTRATE IS ADJACENT NASO-LACRIMAL DUCT.  
 NOT SPECIFIED(TRACE)

MISCELLANEOUS TISSUE  
 DIFFUSE(MILD)

MISCELLANEOUS TISSUE

MISCELLANEOUS TISSUE

MISCELLANEOUS TISSUE

MISCELLANEOUS TISSUE

Appendix J (cont.): PATHOLOGY INDIVIDUAL ANIMAL DATA

LETTERMAN ARMY INSTITUTE OF RESEARCH  
DIV OF RES SUPP. PATH SERV GP  
SPECIES: RAT/FISCHER-344

INDIVIDUAL ANIMAL DATA REPORT  
STUDY NUMBER: GLP83009  
STUDY START DATE: 23-JAN-84

PRINTED: 21-NOV-89  
PAGE: 171  
STUDY TYPE: CHRONIC/2 YR CARCINOGENIC

ANIMAL NUMBER: 82/PRETEST-82 SEX: MALE DOSE GROUP: 2 SACRIFICE STATUS: SACRIFICED MORIBUND  
DATE OF DEATH: 11-DEC-85 STUDY DAY OF DEATH: 669 STUDY WEEK OF DEATH: 99 TERMINAL BODY WEIGHT: 317.00 (GMS)

<< MICROSCOPIC TISSUE OBSERVATIONS >>  
DISTRIBUTION (SEVERITY) / SPECIAL COMMENTS

ABDOMINAL CAVITY ..... THE PRIMARY SITE FOR THE SARCOMA IS THE LIVER WITH INFILTRATION INTO ADJACENT DIAPHRAGM. A FOCAL METASTATIC LESION IS ALSO PRESENT IN THE WALL OF THE JEJUNUM. THE NEOPLASTIC GROWTH IS A FAIRLY WELL-DIFFERENTIATED SARCOMA IN MOST SITES. THERE IS ONE AREA IN THE LIVER IN WHICH SARCOMA CELLS ARE MORE ANAPLASTIC. IN THIS AREA MASSON'S TRICHOME STAIN DEMONSTRATES ABUNDANT COLLAGEN AROUND MOST OF THE TUMOR CELLS. RETICULIN STAIN DEMONSTRATES MANY RETICULIN FIBERS SURROUNDING INDIVIDUAL CELLS. PAS STAIN REVEALS PAS POSITIVE MATERIAL IN RESIDUAL HEPATOCYTES BUT NOT IN NEOPLASTIC CELLS. CONGO RED, BILE STAIN AND PTAH STAINS ARE NEGATIVE. THESE FEATURES ALL SUPPORT THE DIAGNOSIS OF SARCOMA RATHER THAN HEPATOCELLULAR CARCINOMA. (PRESENT)

-M- SARCOMA, CELLULAR DIFFERENTIATION UNSPECIFIED

DIAPHRAGM ..... MISCELLANEOUS TISSUE  
-M- PRESENCE OF METASTATIC SARCOMA SECONDARY NEOPLASM FROM ORGAN ABDOMINAL CAVITY  
-COMPOUND RELATED INFLAMMATORY REACTION NOT SPECIFIED (PRESENT)

**Appendix J (cont.): PATHOLOGY INDIVIDUAL ANIMAL DATA**

LETTERMAN ARMY INSTITUTE OF RESEARCH  
 DIV OF RES SUPP, PATH SERV GP  
 SPECIES: RAT/FISCHER-344  
 STUDY START DATE: 23-JAN-84  
 ANIMAL NUMBER: 83/PRETEST#  
 DATE OF DEATH: 27-JAN-86  
 SEX: MALE  
 DOSE GROUP: 2  
 SACRIFICE STATUS: FINAL SACRIFICE  
 STUDY WEEK OF DEATH: 106  
 TERMINAL BODY WEIGHT: 366.00 (GMS)  
 STUDY TYPE: CHRONIC/2 YR CARCINOGENIC

PRINTED: 21-NOV-89  
 PAGE: 172

ORGAN NAME  
 KEYWORDS / PHRASES  
 ENLARGED  
 GROWTH(S) / MASSES)  
 ADHESION(S)  
 GROSS ORGAN OBSERVATIONS  
 SEVERITY GROSS FREE-TEXT COMMENTS  
 PRESENT BILATERAL, RIGHT 2.75 X 1.75CM, LEFT 2.5 X 1.5CM  
 PRESENT BILATERAL, MULTIPLE, VARIABLY SIZED, RED, BLACK AND YELLOW  
 PRESENT LEFT VENTRAL PERITONEAL WALL, 1.5 X 1CM AREA

TISSUE / HISTOPATHOLOGIC FINDINGS  
 << MICROSCOPIC TISSUE OBSERVATIONS >>  
 DISTRIBUTION (SEVERITY) / SPECIAL COMMENTS

THYROID GLANDS  
 -PARA-FOLLICULAR CELL HYPERPLASIA ("C" CELL, LIGHT CELL) MULTI-FOCAL(TRACE)

HEART  
 -CARDIOMYOPATHY NOT SPECIFIED(MILD)  
 -MEDIAL HYPERTROPHY OF MUSCULAR ARTERIES NOT SPECIFIED(TRACE)

LYMPH NODES  
 -REACTIVE HYPERPLASIA REACTIVE HYPERPLASIA NOTED IN CERVICAL NODES.  
 NOT SPECIFIED (PRESENT)

LIVER  
 -COMPOUND RELATED INFLAMMATORY REACTION NOT SPECIFIED (PRESENT)  
 -BILE DUCTULE EPITHELIAL HYPERPLASIA AND/OR CHOLANGIOFIBROSIS NOT SPECIFIED(MILD)  
 -HEPATITIS MULTI-FOCAL(TRACE)  
 -HEPATOCTYIC VACUOLIZATION MULTI-FOCAL(MILD)  
 -HEPATOCTYIC COALESCING MICROVESICULAR (FATTY) CHANGE LEADING TO NECROSIS AND MINERALIZATION MULTI-FOCAL(TRACE)

KIDNEY  
 -PROGRESSIVE RENAL DISEASE NOT SPECIFIED(MILD)

PROSTATE  
 -CHRONIC PROSTATITIS NOT SPECIFIED(MILD)

TESTES

Appendix J (cont.): PATHOLOGY INDIVIDUAL ANIMAL DATA

LETTERMAN ARMY INSTITUTE OF RESEARCH  
 DIV OF RES SUPP, PATH SERV GP  
 SPECIES: RAT/FISCHER-344  
 STUDY START DATE: 23-JAN-84  
 STUDY TYPE: CHRONIC/2 YR CARCINOGENIC  
 ANIMAL NUMBER: 83/PRETEST= 83 SEX: MALE DOSE GROUP: 2 SACRIFICE STATUS: FINAL SACRIFICE  
 DATE OF DEATH: 27-JAN-86 STUDY DAY OF DEATH: 736 STUDY WEEK OF DEATH: 106 TERMINAL BODY WEIGHT: 366.00 (GMS)  
 << MICROSCOPIC TISSUE OBSERVATIONS >>  
 TISSUE / HISTOPATHOLOGIC FINDINGS DISTRIBUTION (SEVERITY) / SPECIAL COMMENTS

PRINTED: 21-NOV-89  
PAGE: 173

TESTES ..... (PRESENT)  
-0- INTERSTITIAL CELL ADENOMA

EYES & OPTIC N. .... NOT SPECIFIED (MILD)  
-RETINAL ATROPHY AND/OR DEGENERATION, UNILATERAL OR BILATERAL NOT SPECIFIED (PRESENT)  
-LENTICULAR DEGENERATIVE CHANGES COMPATIBLE WITH CATARACT

ABDOMINAL CAVITY ..... MISCELLANEOUS TISSUE  
TEST COMPOUND AND ASSOCIATED GRANULOMATOUS RESPONSE IS NOTED  
BETWEEN LIVER AND SKELETAL MUSCLE. THIS IS PROBABLY THE ADHESION  
TO THE LEFT VENTRAL PERITONEAL WALL NOTED GROSSLY.  
-CHRONIC INFLAMMATION DUE TO THE PRESENCE OF TEST COMPOUND (SITE NOT SPECIFIED (PRESENT)  
SPECIFIED IN COMMENTS)

**Appendix J (cont.): PATHOLOGY INDIVIDUAL ANIMAL DATA**

LETTERMAN ARMY INSTITUTE OF RESEARCH  
 DIV OF RES SUPP, PATH SERV GP  
 SPECIES: RAT/FISCHER-344

INDIVIDUAL ANIMAL DATA REPORT  
 STUDY NUMBER: GLP83009

STUDY START DATE: 23-JAN-84

PRINTED: 21-NOV-89  
 PAGE: 174  
 STUDY TYPE: CHRONIC/2 YR CARCINOGENIC

ANIMAL NUMBER: 84/PRETEST-84 SEX: MALE DOSE GROUP: 2 SACRIFICE STATUS: FINAL SACRIFICE  
 DATE OF DEATH: 27-JAN-86 STUDY DAY OF DEATH: 736 STUDY WEEK OF DEATH: 106 TERMINAL BODY WEIGHT: 422.00 (GMS)

ORGAN NAME SEVERITY GROSS FREE-TEXT COMMENTS  
 LIVER PRESENT VENTRAL ABDOMINAL WALL  
 LIVER PRESENT  
 LIVER PRESENT  
 SPLEEN MODERATE 6 X 1.5CM

KEYWORDS / PHRASES O B S E R V A T I O N S >>  
 ADHESION(S)  
 PROMINENT LOBULAR MARKINGS  
 GRANULAR SURFACE  
 ENLARGED (SPLENOHEGALY)

TISSUE / HISTOPATHOLOGIC FINDINGS O B S E R V A T I O N S >>  
 M I C R O S C O P I C T I S S U E DISTRIBUTION (SEVERITY) / SPECIAL COMMENTS

THYROID GLANDS ..... NOT SPECIFIED(TRACE)  
 -PARA-FOLLICULAR CELL HYPERPLASIA ("C" CELL, LIGHT CELL)  
 HEART ..... NOT SPECIFIED(MODERATE)  
 -CARDIOMYOPATHY ..... NOT SPECIFIED(TRACE)  
 -MEDIAL HYPERTROPHY OF MUSCULAR ARTERIES  
 LUNGS ..... NOT SPECIFIED(MODERATE)  
 -FOCAL HYPERPLASTIC PROLIFERATION OF TYPE 2 ALVEOLAR EPITHELIAL  
 CELLS WITH OR WITHOUT INFLAMMATORY CELL INFILTRATION  
 -MINERALIZATION OF PULMONARY ARTERIES  
 -N- LARGE GRANULAR LYMPHOCYTE LEUKEMIA, METASTATIC  
 -B- BRONCHIOLAR/ALVEOLAR ADENOMA  
 SPLEEN ..... (PRESENT)  
 -N- LARGE GRANULAR LYMPHOCYTE LEUKEMIA, METASTATIC  
 LYMPH NODES ..... LGLL NOTED IN MEDIASTINAL NODES.  
 -N- LARGE GRANULAR LYMPHOCYTE LEUKEMIA, METASTATIC (PRESENT)  
 LIVER ..... NOT SPECIFIED (PRESENT)  
 -COMPOUND RELATED INFLAMMATORY REACTION  
 -BILE DUCTULE EPITHELIAL HYPERPLASIA AND/OR CHOLANGIOFIBROSIS  
 -NECROSIS, HEPATOCYTTIC, INDIVIDUAL CELLS NOT SPECIFIED(MODERATE)  
 NOT SPECIFIED(TRACE)

Appendix J (cont.): PATHOLOGY INDIVIDUAL ANIMAL DATA

LETTERMAN ARMY INSTITUTE OF RESEARCH  
 DIV OF RES SUPP, PATH SERV GP  
 SPECIES: RAT/FISCHER-344  
 ANIMAL NUMBER: 84/PRETEST= 84 SEX: MALE DOSE GROUP: 2 SACRIFICE STATUS: FINAL SACRIFICE  
 DATE OF DEATH: 27-JAN-86 STUDY DAY OF DEATH: 736 STUDY WEEK OF DEATH: 106 TERMINAL BODY WEIGHT: 422.00 (GMS)  
 STUDY START DATE: 23-JAN-84 STUDY NUMBER: GLP83009  
 STUDY TYPE: CHRONIC/2 YR CARCINOGENIC  
 << MICROSCOPIC TISSUE OBSERVATIONS >>  
 TISSUE / HISTOPATHOLOGIC FINDINGS DISTRIBUTION (SEVERITY) / SPECIAL COMMENTS

PRINTED: 21-NOV-89  
PAGE: 175

- LIVER ..... (PRESENT)
  - M- LARGE GRANULAR LYMPHOCYTE LEUKEMIA, METASTATIC
- KIDNEY ..... NOT SPECIFIED(MILD)
  - PROGRESSIVE RENAL DISEASE
- PROSTATE ..... NOT SPECIFIED(TRACE)
  - BENIGN HYPERPLASIA
- TESTES ..... (PRESENT)
  - B- INTERSTITIAL CELL ADENOMA
- NOSE/TURBINATES ..... CELLULAR INFILTRATE IS ASSOCIATED WITH MASO-LACRIMAL DUCT.
  - MIXED INFLAMMATORY CELL INFILTRATION, NASAL CAVITY, SINUSES, NOT SPECIFIED(TRACE)
  - TURBINATES, MASO-LACRIMAL DUCTS
- ADRENAL ..... NOT SPECIFIED (PRESENT)
  - CORTICAL NODULAR HYPERPLASIA
- PITUITARY GLAND ..... NOT SPECIFIED (PRESENT)
  - CYST(S)
  - M- LARGE GRANULE LYMPHOCYTE LEUKEMIA, METASTATIC
- EYES & OPTIC N. .... NOT SPECIFIED(TRACE)
  - CORNEAL MINERALIZATION
  - RETINAL ATROPHY AND/OR DEGENERATION, UNILATERAL OR BILATERAL
  - METAPLASTIC BONE FORMATION AND/OR MINERALIZATION, SCLERA
- WHOLE BODY ..... (PRESENT)
  - M- LARGE GRANULAR LYMPHOCYTOIC LEUKEMIA



**Appendix J (cont.): PATHOLOGY INDIVIDUAL ANIMAL DATA**

LETTERMAN ARMY INSTITUTE OF RESEARCH  
 DIV OF RES SUPP, PATH SERV GP  
 SPECIES: RAT/FISCHER-344  
 PRINTED: 21-NOV-89  
 PAGE: 176  
 STUDY NUMBER: GLP83009  
 STUDY START DATE: 23-JAN-84  
 STUDY TYPE: CHRONIC/2 YR CARCINOGENIC  
 ANIMAL NUMBER: 85/PRETEST= 85 SEX: MALE DOSE GROUP: 2 SACRIFICE STATUS: SACRIFICED MORIBUND  
 DATE OF DEATH: 23-DEC-85 STUDY DAY OF DEATH: 701 STUDY WEEK OF DEATH: 101 TERMINAL BODY WEIGHT: 334.00 (GMS)

<< GROSS ORGAN OBSERVATIONS >>  
 SEVERITY GROSS FREE-TEXT COMMENTS  
 KEYWORDS / PHRASES  
 LIVER ADHESION(S) PRESENT MULTIPLE, SEROSAL  
 HEART MODULE PRESENT RAISED, .2 X .3CM, WHITE  
 LIVER GRANULAR SURFACE PRESENT UNEVEN  
 SPLEEN ENLARGED (SPLENOHEGALY) MARKED 6 X 2 X 1CM  
 SPLEEN INFARCT(S) PRESENT MULTIPLE, VARIABLY SIZED  
 KIDNEY DISCOLORATION PRESENT WHITE, MULTIPLE, MINUTE, CORTEX  
 PITUITARY GLAND GROWTH(S) / MASS(ES) PRESENT .2CM DIAMETER, WHITE

<< MICROSCOPIC TISSUE OBSERVATIONS >>  
 DISTRIBUTION (SEVERITY) / SPECIAL COMMENTS

PARATHYROID ..... TISSUE IS MISSING

HEART .....  
 -CARDIOMYOPATHY ..... NOT SPECIFIED (MODERATE)  
 -W- LARGE GRANULAR LYMPHOCYTE LEUKEMIA, METASTATIC (PRESENT)

LUNGS ..... (PRESENT)  
 -W- LARGE GRANULAR LYMPHOCYTE LEUKEMIA, METASTATIC

SPLEEN .....  
 -INFARCTION, CHRONIC .....  
 -W- LARGE GRANULAR LYMPHOCYTE LEUKEMIA, METASTATIC MULTI-FOCAL (MODERATE) (PRESENT)

LYMPH NODES ..... REACTIVE HYPERPLASIA NOTED IN CERVICAL NODES.  
 -W- LARGE GRANULAR LYMPHOCYTE LEUKEMIA, METASTATIC (PRESENT)  
 -REACTIVE HYPERPLASIA NOT SPECIFIED (PRESENT)  
 -DILATED AND/OR CYSTIC MEDULLARY SINUSES NOT SPECIFIED (PRESENT)

LIVER .....  
 -COMPOUND RELATED INFLAMMATORY REACTION NOT SPECIFIED (PRESENT)  
 -BILE DUCTULE EPITHELIAL HYPERPLASIA AND/OR CHOLANGIOFIBROSIS NOT SPECIFIED (MILD)

Appendix J (cont.): PATHOLOGY INDIVIDUAL ANIMAL DATA

LETTERMAN ARMY INSTITUTE OF RESEARCH  
 DIV OF RES SUPP, PATH SERV GP  
 SPECIES: RAT/FISCHER-344

INDIVIDUAL ANIMAL DATA REPORT  
 STUDY NUMBER: GLP83009  
 STUDY START DATE: 23-JAN-84

PRINTED: 21-NOV-89  
 PAGE: 177

STUDY TYPE: CHRONIC/2 YR CARCINOGENIC

ANIMAL NUMBER: 85/PRETEST#  
 DATE OF DEATH: 23-DEC-85

85 SEX: MALE  
 STUDY DAY OF DEATH: 701

DOSE GROUP: 2  
 STUDY WEEK OF DEATH: 101

SACRIFICE STATUS: SACRIFICED MORIBUND  
 TERMINAL BODY WEIGHT: 334.00 (GMS)

<< M I C R O S C O P I C T I S S U E O B S E R V A T I O N S >>  
 TISSUE / HISTOPATHOLOGIC FINDINGS

LIVER ..... MULTI-FOCAL(TRACE)  
 -HEPATOCTYIC VACUOLIZATION ..... NOT SPECIFIED(MODERATE)  
 -HEPATOCTYIC DEGENERATIVE CHANGES (NON-NECROTIC) ..... MULTI-FOCAL(TRACE)  
 -NECROSIS, HEPATOCTYIC, INDIVIDUAL CELLS ..... (PRESENT)  
 -N- LARGE GRANULAR LYMPHOCYTE LEUKEMIA, METASTATIC

KIDNEY ..... NOT SPECIFIED(MODERATE)  
 -PROGRESSIVE RENAL DISEASE

PROSTATE ..... NOT SPECIFIED(TRACE)  
 -CHRONIC PROSTATITIS ..... NOT SPECIFIED(MILD)  
 -BENIGN HYPERPLASIA

PANCREAS ..... (PRESENT)  
 -B- ISLET CELL ADENOMA

MAMMARY GLANDS ..... NOT SPECIFIED (PRESENT)  
 -DILATATION (ECTASIA) OF DUCTS AND DUCTULES

NOSE/TURBINATES ..... CELLULAR INFILTRATE IS UNILATERAL AND INVOLVES NASO-LACRIMAL DUCT.  
 -MIXED INFLAMMATORY CELL INFILTRATION, NASAL CAVITY, SINUSES, NOT SPECIFIED(MILD)  
 TURBINATES, NASO-LACRIMAL DUCTS

PITUITARY GLAND ..... (PRESENT)  
 -B- ADENOMA

EYES & OPTIC N. .... NOT SPECIFIED (PRESENT)  
 -LENTICULAR DEGENERATIVE CHANGES COMPATIBLE WITH CATARACT

WHOLE BODY ..... (PRESENT)  
 -N- LARGE GRANULAR LYMPHOCYTIC LEUKEMIA

DIAPHRAGM ..... MISCELLANEOUS TISSUE

Appendix J (cont.): PATHOLOGY INDIVIDUAL ANIMAL DATA

LETTERMAN ARMY INSTITUTE OF RESEARCH  
DIV OF RES SUPP, PATH SERV GP  
SPECIES: RAT/FISCHER-344

INDIVIDUAL ANIMAL DATA REPORT  
STUDY NUMBER: GLP83009  
STUDY START DATE: 23-JAN-84

PRINTED: 21-NOV-89  
PAGE: 178  
STUDY TYPE: CHRONIC/2 YR CARCINOGENIC

ANIMAL NUMBER: 85/PRETEST= 85 SEX: MALE DOSE GROUP: 2 SACRIFICE STATUS: SACRIFICED MORIBUND  
DATE OF DEATH: 23-DEC-85 STUDY DAY OF DEATH: 701 STUDY WEEK OF DEATH: 101 TERMINAL BODY WEIGHT: 334.00 (GMS)

<< M I C R O S C O P I C T I S S U E O B S E R V A T I O N S >>  
TISSUE / HISTOPATHOLOGIC FINDINGS DISTRIBUTION (SEVERITY) / SPECIAL COMMENTS

DIAPHRAGM ..... MISCELLANEOUS TISSUE  
-COMPOUND RELATED INFLAMMATORY REACTION NOT SPECIFIED (PRESENT)

**Appendix J (cont.): PATHOLOGY INDIVIDUAL ANIMAL DATA**

LETTERMAN ARMY INSTITUTE OF RESEARCH  
 DIV OF RES SUPP, PATH SERV GP  
 SPECIES: RAT/FISCHER-344  
 STUDY START DATE: 23-JAN-84  
 STUDY NUMBER: GLP83009  
 PRINTED: 21-NOV-89  
 PAGE: 179  
 STUDY TYPE: CHRONIC/2 YR CARCINOGENIC

ANIMAL NUMBER: 86/PRETEST= 86 SEX: MALE DOSE GROUP: 2 SACRIFICE STATUS: SACRIFICED MORIBUND  
 DATE OF DEATH: 16-JAN-86 STUDY DAY OF DEATH: 725 STUDY WEEK OF DEATH: 104 TERMINAL BODY WEIGHT: 395.00 (GMS)

<< GROSS ORGAN OBSERVATIONS >>  
 SEVERITY GROSS FREE-TEXT COMMENTS

ORGAN NAME	KEYWORDS / PHRASES	OBSERVATIONS
LIVER	ADHESION(S)	PRESENT
LIVER	ENLARGED	PRESENT
LIVER	GRANULAR SURFACE	PRESENT
PERITONEAL CAV.	ENLARGED (SPLENOMEGALY)	MARKED
LUNGS	FLUID-FILLED	8.5 X 2 X 1CM
LUNGS	DISCOLORATION	RED, 4ML
KIDNEY	DISCOLORATION	FOCAL, DIFFUSE, BLACK, RIGHT AND LEFT LOBES VARIABLY SIZED
KIDNEY	GRANULAR SURFACE	BROWN/GREEN
TESTES	GROWTH(S) / MASS(ES)	PITTED SURFACE
		BILATERAL, MULTIPLE VARIABLY SIZED, WHITE/RED/BLACK

<< MICROSCOPIC TISSUE OBSERVATIONS >>  
 DISTRIBUTION (SEVERITY) / SPECIAL COMMENTS

PARATHYROID	TISSUE IS MISSING
HEART	NOT SPECIFIED(MILD)
-CARDIOMYOPATHY	
LUNGS	(PRESENT)
-N- LARGE GRANULAR LYMPHOCYTE LEUKEMIA, METASTATIC	
-ALVEOLAR HEMORRHAGE	MULTI-FOCAL (PRESENT)
SPLEEN	(PRESENT)
-N- LARGE GRANULAR LYMPHOCYTE LEUKEMIA, METASTATIC	
LYMPH NODES	RBC'S AND PIGMENT PRESENT IN MEDIASTINAL NODES. REACTIVE HYPERPLASIA NOTED IN CERVICAL NODES.
-RED BLOOD CELLS, HEMOSIDERIN AND/OR ERYTHROPHAGOCYTOSIS WITHIN MEDULLARY SINUSES	NOT SPECIFIED (PRESENT)
-REACTIVE HYPERPLASIA	NOT SPECIFIED (PRESENT)
LIVER	

Appendix J (cont.): PATHOLOGY INDIVIDUAL ANIMAL DATA

LETTERMAN ARMY INSTITUTE OF RESEARCH  
DIV OF RES SUPP, PATH SERV GP  
SPECIES: RAT/FISCHER-344

INDIVIDUAL ANIMAL DATA REPORT  
STUDY NUMBER: GLP83009  
STUDY START DATE: 23-JAN-84

PRINTED: 21-NOV-89  
PAGE: 180

STUDY TYPE: CHRONIC/2 YR CARCINOGENIC

ANIMAL NUMBER: 86/PRETEST-86 SEX: MALE DOSE GROUP: 2 SACRIFICE STATUS: SACRIFICED MORIBUND  
DATE OF DEATH: 16-JAN-86 STUDY DAY OF DEATH: 725 STUDY WEEK OF DEATH: 104 TERMINAL BODY WEIGHT: 395.00 (GMS)

TISSUE / HISTOPATHOLOGIC FINDINGS << MICROSCOPIC TISSUE OBSERVATIONS >>  
DISTRIBUTION (SEVERITY) / SPECIAL COMMENTS

LIVER  
-COMPOUND RELATED INFLAMMATORY REACTION NOT SPECIFIED (PRESENT)  
-BILE DUCTULE EPITHELIAL HYPERPLASIA AND/OR CHOLANGIOFIBROSIS NOT SPECIFIED (MILD)  
-CYSTIC DEGENERATION MULTI-FOCAL (PRESENT)  
-HEPATOCTYIC DEGENERATIVE CHANGES (NON-NECROTIC) NOT SPECIFIED (MODERATE)  
-NECROSIS, PERIACINAR NOT SPECIFIED (MODERATE)  
-N- LARGE GRANULAR LYMPHOCYTE LEUKEMIA, METASTATIC (PRESENT)

KIDNEY  
-PROGRESSIVE RENAL DISEASE NOT SPECIFIED (MODERATE)

PROSTATE  
-BENIGN HYPERPLASIA NOT SPECIFIED (MILD)

SEMINAL VESICLE  
-GENERALIZED ATROPHY NOT SPECIFIED (PRESENT)

TESTES  
-B- INTERSTITIAL CELL ADENOMA (PRESENT)

MAMMARY GLANDS  
-HYPERPLASIA AND/OR HYPERTROPHY OF THE ACINAR TISSUE NOT SPECIFIED (MILD)  
-DILATATION (ECTASIA) OF DUCTS AND DUCTULES NOT SPECIFIED (PRESENT)

ADRENAL  
-FOCUS OF CELLULAR ALTERATION, VACUOLATED NOT SPECIFIED (TRACE)  
-CORTICAL MODULAR HYPERPLASIA NOT SPECIFIED (PRESENT)  
-N- LARGE GRANULE LYMPHOCYTE LEUKEMIA, METASTATIC (PRESENT)

PITUITARY GLAND  
-B- ADENOMA (PRESENT)

Appendix J (cont.): PATHOLOGY INDIVIDUAL ANIMAL DATA

LETTERMAN ARMY INSTITUTE OF RESEARCH  
DIV OF RES SUPP. PATH SERV GP  
SPECIES: RAT/FISCHER-344

INDIVIDUAL ANIMAL DATA REPORT  
STUDY NUMBER: GLP83009  
STUDY START DATE: 23-JAN-84

PRINTED: 21-NOV-89  
PAGE: 181

STUDY TYPE: CHRONIC/2 YR CARCINOGENIC

ANIMAL NUMBER: 86/PRETEST-86 SEX: MALE DOSE GROUP: 2 SACRIFICE STATUS: SACRIFICED MORIBUND  
DATE OF DEATH: 16-JAN-86 STUDY DAY OF DEATH: 725 STUDY WEEK OF DEATH: 104 TERMINAL BODY WEIGHT: 395.00 (GMS)

<< MICROSCOPIC TISSUE OBSERVATIONS >>  
DISTRIBUTION (SEVERITY) / SPECIAL COMMENTS

EYES & OPTIC N. .... ONLY ONE EYE IS SUITABLE FOR HISTOLOGIC EVALUATION.  
-METAPLASTIC BONE FORMATION AND/OR MINERALIZATION, SCLERA ..... NOT SPECIFIED (PRESENT)

WHOLE BODY .....  
-M- LARGE GRANULAR LYMPHOCYTTIC LEUKEMIA ..... (PRESENT)

**Appendix J (cont.): PATHOLOGY INDIVIDUAL ANIMAL DATA**

LETTERMAN ARMY INSTITUTE OF RESEARCH  
 DIV OF RES SUPP, PATH SERV GP  
 SPECIES: RAT/FISCHER-344  
 STUDY NUMBER: GLP83009  
 STUDY START DATE: 23-JAN-84  
 STUDY TYPE: CHRONIC/2 YR CARCINOGENIC  
 PRINTED: 21-NOV-89  
 PAGE: 182  
 ANIMAL NUMBER: 87/PRETEST= 87 SEX: MALE DOSE GROUP: 2 SACRIFICE STATUS: SACRIFICED MORIBUND  
 DATE OF DEATH: 26-SEP-85 STUDY DAY OF DEATH: 613 STUDY WEEK OF DEATH: 88 TERMINAL BODY WEIGHT: 453.00 (GMS)  
 << GROSS ORGAN OBSERVATIONS >>  
 SEVERITY GROSS FREE-TEXT COMMENTS  
 SKIN SUBCUTANEOUS MASS PRESENT LEFT POSTERIOR FOREARM, SOFT, 3CM DIAMETER  
 LIVER ADHESION(S) PRESENT VENTRAL ABDOMINAL WALL, 1.3CM DIAMETER AREA  
 TESTES GROWTH(S) / MASSES PRESENT MULTIPLE, IRREGULAR, BILATERAL, WHITE, .1-.2CM DIAMETER

<< MICROSCOPIC TISSUE OBSERVATIONS >>  
 DISTRIBUTION (SEVERITY) / SPECIAL COMMENTS

THYROID GLANDS  
 -PARA-FOLLICULAR CELL HYPERPLASIA ("C" CELL, LIGHT CELL) FOCAL(TRACE)

HEART  
 -CARDIOMYOPATHY NOT SPECIFIED(MILD)  
 -MEDIAL HYPERTROPHY OF MUSCULAR ARTERIES NOT SPECIFIED(TRACE)

LUNGS  
 -MINERALIZATION OF PULMONARY ARTERIES NOT SPECIFIED(TRACE)

LYMPH NODES  
 -RED BLOOD CELLS, HEMOSIDERIN AND/OR ERYTHROPHAGOCYTOSIS WITHIN RBC'S AND REACTIVE HYPERPLASIA NOTED IN CERVICAL NODES.  
 MEDULLARY SINUSES NOT SPECIFIED (PRESENT)  
 -REACTIVE HYPERPLASIA NOT SPECIFIED (PRESENT)

LIVER  
 -COMPOUND RELATED INFLAMMATORY REACTION NOT SPECIFIED (PRESENT)  
 -BILE DUCTULE EPITHELIAL HYPERPLASIA AND/OR CHOLANGIOFIBROSIS NOT SPECIFIED(MILD)  
 -HEPATITIS MULTI-FOCAL(TRACE)  
 -HEPATOCTYIC VACUOLIZATION MULTI-FOCAL(MILD)  
 -FOCUS OF CELLULAR ALTERATION - CLEAR CELLS NOT SPECIFIED(TRACE)  
 -HEPATOCTYE COALESCING MICROVESICULAR (FATTY) CHANGE LEADING TO MULTI-FOCAL(MODERATE)  
 NECROSIS AND MINERALIZATION

KIDNEY

Appendix J (cont.): PATHOLOGY INDIVIDUAL ANIMAL DATA

LETTERMAN ARMY INSTITUTE OF RESEARCH  
 DIV OF RES SUPP, PATH SERV GP  
 SPECIES: RAT/FISCHER-344  
 STUDY START DATE: 23-JAN-84  
 ANIMAL NUMBER: 87/PRETEST-87 SEX: MALE DOSE GROUP: 2 SACRIFICE STATUS: SACRIFICED MORIBUND  
 DATE OF DEATH: 26-SEP-85 STUDY DAY OF DEATH: 613 STUDY WEEK OF DEATH: 88 TERMINAL BODY WEIGHT: 453.00 (GMS)  
 << MICROSCOPIC TISSUE OBSERVATIONS >>  
 TISSUE / HISTOPATHOLOGIC FINDINGS DISTRIBUTION (SEVERITY) / SPECIAL COMMENTS

INDIVIDUAL ANIMAL DATA REPORT  
 STUDY NUMBER: GLP83009  
 PRINTED: 21-NOV-89  
 PAGE: 183  
 STUDY TYPE: CHRONIC/2 YR CARCINOGENIC

KIDNEY ..... NOT SPECIFIED(MILD)  
 -PROGRESSIVE RENAL DISEASE

TESTES ..... (PRESENT)  
 -B- INTERSTITIAL CELL ADENOMA

SKIN ..... NEUROFIBROSARCOMA IS IN THE SUBCUTANEOUS TISSUE OF THE LEFT FOREARM.  
 -M- NEUROFIBROSARCOMA, SUBCUTANEOUS, LOCATION TO BE SPECIFIED (PRESENT)

NOSE/TURBINATES ..... CELLULAR INFILTRATE INVOLVES NASO-LACRIMAL DUCT UNILATERALLY  
 -MIXED INFLAMMATORY CELL INFILTRATION, NASAL CAVITY, SINUSES, NOT SPECIFIED(TRACE)  
 TURBINATES, NASO-LACRIMAL DUCTS

EYES & OPTIC N. .... NOT SPECIFIED (PRESENT)  
 -METAPLASTIC BONE FORMATION AND/OR MINERALIZATION, SCLERA



**Appendix J (cont.): PATHOLOGY INDIVIDUAL ANIMAL DATA**

LETTERMAN ARMY INSTITUTE OF RESEARCH  
 DIV OF RES SUPP, PATH SERV GP  
 SPECIES: RAT/FISCHER-344  
 STUDY START DATE: 23-JAN-84  
 STUDY NUMBER: GLP83009  
 PRINTED: 21-NOV-89  
 PAGE: 184  
 STUDY TYPE: CHRONIC/2 YR CARCINOGENIC

ANIMAL NUMBER: 88/PRETEST-  
 DATE OF DEATH: 09-JAN-86  
 STUDY DAY OF DEATH: 718  
 SEX: MALE  
 DOSE GROUP: 2  
 SACRIFICE STATUS: SACRIFICED MORIBUND  
 STUDY WEEK OF DEATH: 103  
 TERMINAL BODY WEIGHT: 336.00 (GMS)

ORGAN NAME  
 LIVER  
 LIVER  
 LIVER  
 LIVER  
 SPLEEN  
 KIDNEY  
 LUNGS

KEYWORDS / PHRASES  
 ADHESION(S)  
 ENLARGED  
 GRANULAR SURFACE  
 DISCOLORATION  
 ENLARGED (SPLENOMEGALY)  
 DISCOLORATION  
 DISCOLORATION

SEVERITY  
 PRESENT  
 MODERATE  
 PRESENT  
 PRESENT  
 MARKED  
 PRESENT  
 PRESENT

GROSS ORGAN OBSERVATIONS  
 VENTRAL ABDOMINAL WALL  
 RED, FOCAL  
 6 X 2 X 2CM  
 GREEN/BROWN, BILATERAL  
 FOCAL .3 X .2CM, YELLOW, VISCERAL SURFACE OF UPPER LEFT LOBE

TISSUE / HISTOPATHOLOGIC FINDINGS  
 THYROID GLANDS  
 PARATHYROID  
 HEART  
 -CARDIOMYOPATHY  
 -MEDIAL HYPERTROPHY OF MUSCULAR ARTERIES  
 LUNGS  
 -FOCAL HYPERPLASTIC PROLIFERATION OF TYPE 2 ALVEOLAR EPITHELIAL CELLS WITH OR WITHOUT INFLAMMATORY CELL INFILTRATION  
 -N- LARGE GRANULAR LYMPHOCYTE LEUKEMIA, METASTATIC  
 SPLEEN  
 -N- LARGE GRANULAR LYMPHOCYTE LEUKEMIA, METASTATIC  
 LYMPH NODES  
 -DILATED AND/OR CYSTIC MEDULLARY SINUSES  
 LIVER  
 -COMPOUND RELATED INFLAMMATORY REACTION

OBSERVATIONS  
 DISTRIBUTION (SEVERITY) / SPECIAL COMMENTS  
 TISSUE IS MISSING  
 TISSUE IS MISSING  
 NOT SPECIFIED(MILD)  
 NOT SPECIFIED(MILD)  
 NOT SPECIFIED(MODERATE)  
 (PRESENT)  
 (PRESENT)  
 DILATED SINUSOIDS NOTED IN MESENTERIC NODES.  
 NOT SPECIFIED (PRESENT)  
 NOT SPECIFIED (PRESENT)

Appendix J (cont.): PATHOLOGY INDIVIDUAL ANIMAL DATA

LETTERMAN ARMY INSTITUTE OF RESEARCH  
 DIV OF RES SUPP, PATH SERV GP  
 SPECIES: RAT/FISCHER-344  
 STUDY START DATE: 23-JAN-84  
 INDIVIDUAL ANIMAL DATA REPORT  
 STUDY NUMBER: GLP83009  
 PRINTED: 21-NOV-89  
 PAGE: 185

ANIMAL NUMBER: 08/PRETEST-08 SEX: MALE DOSE GROUP: 2 SACRIFICE STATUS: SACRIFICED MORIBUND  
 DATE OF DEATH: 09-JAN-86 STUDY DAY OF DEATH: 718 STUDY WEEK OF DEATH: 103 TERMINAL BODY WEIGHT: 336.00 (GMS)  
 STUDY TYPE: CHRONIC/2 YR CARCINOGENIC

<< M I C R O S C O P I C T I S S U E O B S E R V A T I O N S >>  
 TISSUE / HISTOPATHOLOGIC FINDINGS DISTRIBUTION (SEVERITY) / SPECIAL COMMENTS

LIVER .....  
 -BILE DUCTULE EPITHELIAL HYPERPLASIA AND/OR CHOLANGIOFIBROSIS ..... NOT SPECIFIED(MODERATE)  
 -NECROSIS ..... MULTI-FOCAL(MILD)  
 -CYSTIC DEGENERATION ..... NOT SPECIFIED (PRESENT)  
 -HEPATOCYTTIC DEGENERATIVE CHANGES (NON-NECROTIC) ..... DIFFUSE(MILD)  
 -M- LARGE GRANULAR LYMPHOCYTE LEUKEMIA, METASTATIC (PRESENT)  
 -HEPATOCYTE COALESCING MICROVESICULAR (FATTY) CHANGE LEADING TO MULTI-FOCAL(TRACE)  
 NECROSIS AND MINERALIZATION

KIDNEY .....  
 -PROGRESSIVE RENAL DISEASE ..... NOT SPECIFIED(MILD)

PROSTATE .....  
 -CHRONIC PROSTATITIS ..... NOT SPECIFIED(MILD)  
 -BENIGN HYPERPLASIA ..... NOT SPECIFIED(TRACE)

SEMINAL VESICLE .....  
 -GENERALIZED ATROPHY ..... NOT SPECIFIED (PRESENT)

TESTES .....  
 -INTERSTITIAL CELL HYPERPLASIA ..... MULTI-FOCAL(MILD)

COLON .....  
 INFLAMMATION AND NECROSIS IS PRESENT IN MESENTERY OF THE COLON.  
 THIS LESION IS PROBABLY DUE TO THE PRESENCE OF TEST MATERIAL.  
 THE LESION IS CODED UNDER ABDOMINAL CAVITY.

PITUITARY GLAND .....  
 -B- ADENOMA ..... (PRESENT)

EYES & OPTIC N. ....  
 -METAPLASTIC BONE FORMATION AND/OR MINERALIZATION, SCLERA ..... NOT SPECIFIED (PRESENT)

WHOLE BODY .....

Appendix J (cont.): PATHOLOGY INDIVIDUAL ANIMAL DATA

LETTERMAN ARMY INSTITUTE OF RESEARCH  
DIV OF RES SUPP, PATH SERV GP  
SPECIES: RAT/FISCHER-344  
INDIVIDUAL ANIMAL DATA REPORT  
STUDY NUMBER: GLP83009  
STUDY START DATE: 23-JAN-84  
PRINTED: 21-NOV-89  
PAGE: 186  
STUDY TYPE: CHRONIC/2 YR CARCINOGENIC

ANIMAL NUMBER: 88/PRETEST#  
DATE OF DEATH: 09-JAN-86  
SEX: MALE  
DOSE GROUP: 2  
SACRIFICE STATUS: SACRIFICED MORIBUND  
STUDY DAY OF DEATH: 718  
STUDY WEEK OF DEATH: 103  
TERMINAL BODY WEIGHT: 336.00 (GMS)

TISSUE / HISTOPATHOLOGIC FINDINGS  
MICROSCOPIC TISSUE OBSERVATIONS >>  
DISTRIBUTION (SEVERITY) / SPECIAL COMMENTS

WHOLE BODY  
-M- LARGE GRANULAR LYMPHOCYTTIC LEUKEMIA (PRESENT)

ABDOMINAL CAVITY  
MISCELLANEOUS TISSUE  
NECROSIS AND INFLAMMATION IS PRESENT IN THE MESENTERY OF THE COLON.

-CHRONIC INFLAMMATION DUE TO THE PRESENCE OF TEST COMPOUND (SITE NOT SPECIFIED (PRESENT))

Appendix J (cont.): PATHOLOGY INDIVIDUAL ANIMAL DATA

LETTERMAN ARMY INSTITUTE OF RESEARCH  
DIV OF RES SUPP, PATH SERV GP  
SPECIES: RAT/FISCHER-344

INDIVIDUAL ANIMAL DATA REPORT  
STUDY NUMBER: GLP83009  
STUDY START DATE: 23-JAN-84

PRINTED: 21-NOV-89  
PAGE: 187  
STUDY TYPE: CHRONIC/2 YR CARCINOGENIC

ANIMAL NUMBER: 89/PRETEST-89 SEX: MALE DOSE GROUP: 2 SACRIFICE STATUS: FINAL SACRIFICE  
DATE OF DEATH: 27-JAN-86 STUDY DAY OF DEATH: 736 STUDY WEEK OF DEATH: 106 TERMINAL BODY WEIGHT: 428.00 (GMS)

<< GROSS ORGAN OBSERVATIONS >>  
SEVERITY GROSS FREE-TEXT COMMENTS

LIVER PRESENT VENTRAL ABDOMINAL WALL  
ADHESION(S)  
KIDNEY GRANULAR SURFACE MILD  
TESTES ENLARGED PRESENT BILATERAL, 2.5 X 1.5CM  
TESTES GROWTH(S) / MASS(ES) PRESENT BILATERAL, YELLOW AND BLACK  
PITUITARY GLAND ENLARGED PRESENT .5CM DIAMETER, RED AND BLACK

<< MICROSCOPIC TISSUE OBSERVATIONS >>  
DISTRIBUTION (SEVERITY) / SPECIAL COMMENTS

THYROID GLANDS  
-M- FOLLICULAR ADENOCARCINOMA (PRESENT)

HEART  
-CARDIOMYOPATHY NOT SPECIFIED(MILD)

LYMPH NODES REACTIVE HYPERPLASIA, RBC'S, PIGMENT. AND HISTIOCYTES ARE NOTED  
IN MEDIASTINAL NODE.  
NOT SPECIFIED (PRESENT)

-RED BLOOD CELLS, HEMOSIDERIN AND/OR ERYTHROPHAGOCYTOSIS WITHIN  
MEDULLARY SINUSES  
-HISTIOCYTIC INFILTRATION, SUBCAPSULAR AND MEDULLARY SINUSES NOT SPECIFIED (PRESENT)  
-REACTIVE HYPERPLASIA NOT SPECIFIED (PRESENT)

LIVER  
-COMPOUND RELATED INFLAMMATORY REACTION NOT SPECIFIED (PRESENT)  
-BILE DUCTULE EPITHELIAL HYPERPLASIA AND/OR CHOLANGIOFIBROSIS NOT SPECIFIED(MODERATE)  
-HEPATITIS NOT SPECIFIED(TRACE)  
-CYSTIC DEGENERATION FOCAL (PRESENT)

KIDNEY  
-PROGRESSIVE RENAL DISEASE NOT SPECIFIED(MODERATE)

PROSTATE

Appendix J (cont.): PATHOLOGY INDIVIDUAL ANIMAL DATA

LETTERMAN ARMY INSTITUTE OF RESEARCH  
DIV OF RES SUPP, PATH SERV GP  
SPECIES: RAT/FISCHER-344

INDIVIDUAL ANIMAL DATA REPORT  
STUDY NUMBER: GLP83009  
STUDY START DATE: 23-JAN-84

PRINTED: 21-NOV-89  
PAGE: 188  
STUDY TYPE: CHRONIC/2 YR CARCINOGENIC

ANIMAL NUMBER: 89/PRETEST-89 SEX: MALE DOSE GROUP: 2 SACRIFICE STATUS: FINAL SACRIFICE  
DATE OF DEATH: 27-JAN-86 STUDY DAY OF DEATH: 736 STUDY WEEK OF DEATH: 106 TERMINAL BODY WEIGHT: 428.00 (GMS)

TISSUE / HISTOPATHOLOGIC FINDINGS << MICROSCOPIC TISSUE OBSERVATIONS >>  
DISTRIBUTION (SEVERITY) / SPECIAL COMMENTS

PROSTATE ..... NOT SPECIFIED(MILO)  
-BENIGN HYPERPLASIA

SEMINAL VESICLE ..... NOT SPECIFIED (PRESENT)  
-GENERALIZED ATROPHY

TESTES ..... (PRESENT)  
-B- INTERSTITIAL CELL ADENOMA

SKIN ..... TISSUE IS MISSING

MAMMARY GLANDS ..... TISSUE IS MISSING

ADRENAL ..... NOT SPECIFIED (PRESENT)  
-CORTICAL MODULAR HYPERPLASIA

PITUITARY GLAND ..... (PRESENT)  
-B- ADENOMA

**Appendix J (cont.): PATHOLOGY INDIVIDUAL ANIMAL DATA**

LETTERMAN ARMY INSTITUTE OF RESEARCH  
 DIV OF RES SUPP, PATH SERV GP  
 SPECIES: RAT/FISCHER-344  
 STUDY START DATE: 23-JAN-84  
 STUDY NUMBER: GLP83009  
 PRINTED: 21-NOV-89  
 PAGE: 189  
 ANIMAL NUMBER: 90/PRETEST= 90 SEX: MALE DOSE GROUP: 2 SACRIFICE STATUS: SACRIFICED MORIBUND  
 DATE OF DEATH: 23-DEC-85 STUDY DAY OF DEATH: 701 STUDY WEEK OF DEATH: 101 TERMINAL BODY WEIGHT: 311.00 (GMS)  
 STUDY TYPE: CHRONIC/2 YR CARCINOGENIC

<< GROSS ORGAN OBSERVATIONS >>  
 SEVERITY GROSS FREE-TEXT COMMENTS  
 TESTES ATROPHIC / SMALL, UNILATERALLY PRESENT RIGHT  
 TESTES GROWTH(S) / MASS(ES) PRESENT MULTIPLE, IRREGULAR, WHITE  
 STOMACH GROWTH(S) / MASS(ES) PRESENT SEROSAL SURFACE, MULTIPLE, MODULAR, WHITE WITH YELLOW CENTER,  
 -25-2CM DIAMETER  
 KIDNEY DISCOLORATION PRESENT DIFFUSELY BROWN  
 WHOLE BODY JAUNDICED PRESENT RIGHT  
 EYES & OPTIC N. HYPOPIGMENT MARKED PALE BROWN/YELLOW  
 LIVER DISCOLORATION PRESENT

<< MICROSCOPIC TISSUE OBSERVATIONS >>  
 TISSUE / HISTOPATHOLOGIC FINDINGS DISTRIBUTION (SEVERITY) / SPECIAL COMMENTS

THYROID GLANDS ..... NOT SPECIFIED(TRACE)  
 -PARA-FOLLICULAR CELL HYPERPLASIA ("C" CELL, LIGHT CELL)  
 HEART ..... NOT SPECIFIED(MILD)  
 -CARDIOMYOPATHY  
 LUNGS ..... NOT SPECIFIED(TRACE)  
 -MINERALIZATION OF PULMONARY ARTERIES  
 -N- LARGE GRANULAR LYMPHOCYTE LEUKEMIA, METASTATIC  
 THYMUS ..... TISSUE IS MISSING  
 SPLEEN ..... (PRESENT)  
 -N- LARGE GRANULAR LYMPHOCYTE LEUKEMIA, METASTATIC  
 -N- PRESENCE OF METASTATIC SARCOMA  
 SECONDARY NEOPLASM FROM ORGAN ABDOMINAL CAVITY

Appendix J (cont.): PATHOLOGY INDIVIDUAL ANIMAL DATA

LETTERMAN ARMY INSTITUTE OF RESEARCH INDIVIDUAL ANIMAL DATA REPORT PRINTED: 21-NOV-89
DIV OF RES SUPP, PATH SERV GP STUDY NUMBER: GLP83009 PAGE: 190
SPECIES: RAT/FISCHER-344 STUDY START DATE: 23-JAN-84 STUDY TYPE: CHRONIC/2 YR CARCINOGENIC
ANIMAL NUMBER: 90/PRETEST= 90 SEX: MALE DOSE GROUP: 2 SACRIFICE STATUS: SACRIFICED MORIBUND
DATE OF DEATH: 23-DEC-85 STUDY DAY OF DEATH: 701 STUDY WEEK OF DEATH: 101 TERMINAL BODY WEIGHT: 311.00 (GMS)

TISSUE / HISTOPATHOLOGIC FINDINGS << MICROSCOPIC TISSUE OBSERVATIONS >>
DISTRIBUTION (SEVERITY) / SPECIAL COMMENTS

LYMPH NODES REACTIVE HYPERPLASIA AND HISTIOCYTIC INFILTRATION NOTED IN
CERVICAL NODES. MEDULLARY SINUSES OF MEDIASTINAL NODES ARE
GREATLY DILATED AND CONTAIN NUMEROUS HISTIOCYTE. HISTIOCYTIC
INFILTRATION IS ALSO PRESENT IN MESENTERIC NODES.
NOT SPECIFIED (PRESENT)
NOT SPECIFIED (PRESENT)
NOT SPECIFIED (PRESENT)

LIVER
-COMPOUND RELATED INFLAMMATORY REACTION
-BILE DUCTULE EPITHELIAL HYPERPLASIA AND/OR CHOLANGIOFIBROSIS
-CYSTIC DEGENERATION
-HEPATOCTYIC DEGENERATIVE CHANGES (NON-NECROTIC)
-NECROSIS, HEPATOCTYIC, INDIVIDUAL CELLS
-N- LARGE GRANULAR LYMPHOCYTE LEUKEMIA, METASTATIC
-FIBROSIS, PARENCHYMAL (SCARRING)

KIDNEY
-PROGRESSIVE RENAL DISEASE
NOT SPECIFIED(MILD)

URINARY BLADDER
TISSUE IS MISSING

PROSTATE
-CHRONIC PROSTATITIS
-BENIGN HYPERPLASIA
NOT SPECIFIED(TRACE)
NOT SPECIFIED(TRACE)

SEMINAL VESICLE
-GENERALIZED ATROPHY
NOT SPECIFIED (PRESENT)

TESTES
-B- INTERSTITIAL CELL ADENOMA
(PRESENT)

PANCREAS

**Appendix J (cont.):      PATHOLOGY INDIVIDUAL ANIMAL DATA**

LETTERMAN ARMY INSTITUTE OF RESEARCH      INDIVIDUAL ANIMAL DATA REPORT      PRINTED: 21-NOV-89  
 DIV OF RES SUPP, PATH SERV GP      STUDY NUMBER: GLP83009      PAGE: 191  
 SPECIES: RAT/FISCHER-344      STUDY START DATE: 23-JAN-84      STUDY TYPE: CHRONIC/2 YR CARCINOGENIC

ANIMAL NUMBER: 90/PRETEST      DOSE GROUP: 2      SACRIFICE STATUS: SACRIFICED MORIBUND  
 DATE OF DEATH: 23-DEC-85      STUDY DAY OF DEATH: 701      STUDY WEEK OF DEATH: 101      TERMINAL BODY WEIGHT: 311.00 (GMS)

<<    M I C R O S C O P I C    T I S S U E    O B S E R V A T I O N S    >>  
 -----  
 TISSUE / HISTOPATHOLOGIC FINDINGS      DISTRIBUTION (SEVERITY) / SPECIAL COMMENTS

- PANCREAS .....
- ACINAR (EXOCRINE) ATROPHY .....
- CHRONIC INFLAMMATION .....
- STOMACH .....
- ULCERATION, NON-GLANDULAR AREA .....
- MUCOSAL AND/OR SUBMUCOSAL EDEMA .....
- W- PRESENCE OF METASTATIC SARCOMA .....
- MAMMARY GLANDS .....
- HYPERPLASIA AND/OR HYPERTROPHY OF THE ACINAR TISSUE .....
- NOSE/TURBINATES .....
- MIXED INFLAMMATORY CELL INFILTRATION, NASAL CAVITY, SINUSES, TURBINATES, NASO-LACRIMAL DUCTS .....
- EYES & OPTIC N. ....
- RETINAL ATROPHY AND/OR DEGENERATION, UNILATERAL OR BILATERAL .....
- METAPLASTIC BONE FORMATION AND/OR MINERALIZATION, SCLERA .....
- LENTICULAR DEGENERATIVE CHANGES COMPATIBLE WITH CATARACT .....
- AD SEBACIOUS .....
- WHOLE BODY .....
- M- LARGE GRANULAR LYMPHOCTIC LEUKEMIA .....
- ABDOMINAL CAVITY .....
- M- SARCOMA, CELLULAR DIFFERENTIATION UNSPECIFIED .....
- ..... MISCELLANEOUS TISSUE
- ..... THE LARGEST TUMOR MASS AND MOST PROBABLE PRIMARY SITE IS IN THE WALL OF THE STOMACH. IN ALL LOCATIONS, THE NEOPLASTIC GROWTHS ARE WELL-DIFFERENTIATED FIBROSARCOMA.
- ..... (PRESENT)

MULTI-FOCAL(MILD)  
 MULTI-FOCAL(MILD)  
 MULTI-FOCAL (PRESENT)  
 NOT SPECIFIED (PRESENT)  
 SECONDARY NEOPLASIA FROM ORGAN ABDOMINAL CAVITY  
 NOT SPECIFIED(TRACE)  
 CELLULAR INFILTRATE IS BILATERAL AND INVOLVES NASO-LACRIMAL DUCTS.  
 NOT SPECIFIED(MILD)  
 NOT SPECIFIED(MARKED)  
 NOT SPECIFIED (PRESENT)  
 NOT SPECIFIED (PRESENT)  
 TISSUE IS MISSING  
 (PRESENT)  
 (PRESENT)



**Appendix J (cont.): PATHOLOGY INDIVIDUAL ANIMAL DATA**

LETTERMAN ARMY INSTITUTE OF RESEARCH  
 DIV OF RES SUPP, PATH SERV GP  
 SPECIES: RAT/FISCHER-344

INDIVIDUAL ANIMAL DATA REPORT  
 STUDY NUMBER: GLP83009

PRINTED: 21-NOV-89  
 PAGE: 192

STUDY START DATE: 23-JAN-84

STUDY TYPE: CHRONIC/2 YR CARCINOGENIC

ANIMAL NUMBER: 91/PRETEST-  
 DATE OF DEATH: 29-JAN-86  
 SEX: MALE  
 STUDY DAY OF DEATH: 738  
 JOSE GROUP: 2  
 SACRIFICE STATUS: FINAL SACRIFICE  
 STUDY WEEK OF DEATH: 106  
 TERMINAL BODY WEIGHT: 409.00 (GMS)

ORGAN NAME  
 PERITONEAL CAV.  
 LIVER  
 PITUITARY GLAND  
 TESTES  
 EYES & OPTIC N.

<< GROSS ORGAN OBSERVATIONS >>  
 SEVERITY GROSS FREE-TEXT COMMENTS  
 PRESENT WITHIN FATTY TISSUE, YELLOW, FIRM, IRREGULARLY SHAPED,  
 1.5 X 1CM  
 PRESENT VENTRAL ABDOMINAL WALL  
 PRESENT FOCAL, .2CM DIAMETER, BLACK  
 PRESENT BILATERAL, YELLOW/BLACK, CLEAR RED FLUID FILLED.  
 PRESENT RIGHT

<< MICROSCOPIC TISSUE OBSERVATIONS >>  
 DISTRIBUTION (SEVERITY) / SPECIAL COMMENTS

THYROID GLANDS  
 -PARA-FOLLICULAR CELL HYPERPLASIA ("C" CELL, LIGHT CELL)  
 PARATHYROID  
 TISSUE IS MISSING  
 HEART  
 -CARDIOMYOPATHY  
 NOT SPECIFIED(MILD)  
 LUNGS  
 -MINERALIZATION OF PULMONARY ARTERIES  
 NOT SPECIFIED(TRACE)  
 LYMPH NODES  
 -REACTIVE HYPERPLASIA  
 -DILATED AND/OR CYSTIC MEDULLARY SINUSES  
 REACTIVE HYPERPLASIA NOTED IN CERVICAL NODES.  
 DILATED SINUSES NOTED IN MEDIASTINAL NODE.  
 NOT SPECIFIED (PRESENT)  
 NOT SPECIFIED (PRESENT)  
 LIVER  
 -COMPOUND RELATED INFLAMMATORY REACTION  
 -BILE DUCTULE EPITHELIAL HYPERPLASIA AND/OR CHOLANGIOFIBROSIS  
 NOT SPECIFIED (PRESENT)  
 NOT SPECIFIED(MILD)  
 KIDNEY  
 -PROGRESSIVE RENAL DISEASE  
 NOT SPECIFIED(TRACE)  
 PROSTATE

**Appendix J (cont.): PATHOLOGY INDIVIDUAL ANIMAL DATA**

LETTERMAN ARMY INSTITUTE OF RESEARCH  
 DIV OF RES SUPP, PATH SERV GP  
 SPECIES: RAT/FISCHER-344

INDIVIDUAL ANIMAL DATA REPORT  
 STUDY NUMBER: GLP83009

STUDY START DATE: 23-JAN-84

PRINTED: 21-NOV-89  
 PAGE: 193

STUDY TYPE: CHRONIC/2 YR CARCINOGENIC

ANIMAL NUMBER: 91/PRETEST= 91 SEX: MALE DOSE GROUP: 2 SACRIFICE STATUS: FINAL SACRIFICE  
 DATE OF DEATH: 29-JAN-86 STUDY DAY OF DEATH: 738 STUDY WEEK OF DEATH: 106 TERMINAL BODY WEIGHT: 409.00 (GMS)

<< M I C R O S C O P I C T I S S U E O B S E R V A T I O N S >>  
 TISSUE / HISTOPATHOLOGIC FINDINGS DISTRIBUTION (SEVERITY) / SPECIAL COMMENTS

PROSTATE ..... NOT SPECIFIED (TRACE)  
 -CHRONIC PROSTATITIS ..... NOT SPECIFIED (TRACE)  
 -BENIGN HYPERPLASIA

TESTES ..... (PRESENT)  
 -B- INTERSTITIAL CELL ADENOMA

PANCREAS ..... NOT SPECIFIED (MILD)  
 -ACINAR (EXOCRINE) ATROPHY

STOMACH ..... NOT SPECIFIED (PRESENT)  
 -MUCOSAL AND/OR SUBMUCOSAL EDEMA

MAMMARY GLANDS ..... NOT SPECIFIED (TRACE)  
 -HYPERPLASIA AND/OR HYPERTROPHY OF THE ACINAR TISSUE

NOSE/TURBINATES ..... CELLULAR INFILTRATE INVOLVES NASO-LACRIMAL DUCT.  
 -MIXED INFLAMMATORY CELL INFILTRATION, NASAL CAVITY, SINUSES, NOT SPECIFIED (MILD)  
 TURBINATES, NASO-LACRIMAL DUCTS

ADRENAL ..... NOT SPECIFIED (PRESENT)  
 -CORTICAL NODULAR HYPERPLASIA

EYES & OPTIC N. .... NOT SPECIFIED (MODERATE)  
 -RETINAL ATROPHY AND/OR DEGENERATION, UNILATERAL OR BILATERAL NOT SPECIFIED (PRESENT)  
 -METAPLASTIC BONE FORMATION AND/OR MINERALIZATION, SCLERA NOT SPECIFIED (PRESENT)  
 -LENTICULAR DEGENERATIVE CHANGES COMPATIBLE WITH CATARACT

ABDOMINAL CAVITY ..... MISCELLANEOUS TISSUE  
 -B- LIPOMA (PRESENT)

**Appendix J (cont.): PATHOLOGY INDIVIDUAL ANIMAL DATA**

LETTERMAN ARMY INSTITUTE OF RESEARCH  
 DIV OF RES SUPP, PATH SERV GP  
 SPECIES: RAT/FISCHER-344  
 STUDY START DATE: 23-JAN-84  
 STUDY NUMBER: GLP83009  
 PRINTED: 21-NOV-89  
 PAGE: 194

ANIMAL NUMBER: 92/PRETEST-  
 DATE OF DEATH: 29-JAN-86  
 SEX: MALE  
 DOSE GROUP: 2  
 SACRIFICE STATUS: FINAL SACRIFICE  
 STUDY WEEK OF DEATH: 106  
 TERMINAL BODY WEIGHT: 404.00 (GMS)

ORGAN NAME  
 LIVER  
 PITUITARY GLAND  
 PITUITARY GLAND  
 TESTES  
 GROSS ORGAN OBSERVATIONS >>  
 KEYWORDS / PHRASES SEVERITY GROSS FREE-TEXT COMMENTS  
 ADHESION(S) PRESENT VENTRAL ABDOMINAL WALL  
 DISCOLORATION PRESENT FOCAL, .3CM DIAMETER, DARK RED  
 ENLARGED TRACE  
 GROWTH(S) / MASS(ES) PRESENT BILATERAL, MULTIPLE VARIABLY SIZED, YELLOW

TISSUE / HISTOPATHOLOGIC FINDINGS  
 << MICROSCOPIC TISSUE OBSERVATIONS >>  
 DISTRIBUTION (SEVERITY) / SPECIAL COMMENTS

THYROID GLANDS  
 -PARA-FOLLICULAR CELL HYPERPLASIA (\*CM CELL, LIGHT CELL) MULTI-FOCAL(MILD)

EXORBITAL LACRIM TISSUE IS MISSING

HEART  
 -CARDIOMYOPATHY NOT SPECIFIED(TRACE)  
 -MEDIAL HYPERTROPHY OF MUSCULAR ARTERIES NOT SPECIFIED(TRACE)

LUNGS  
 -PNEUMONIA, INTERSTITIAL, CHRONIC FOCAL(TRACE)

LIVER  
 -COMPOUND RELATED INFLAMMATORY REACTION  
 -BILE DUCTULE EPITHELIAL HYPERPLASIA AND/OR CHOLANGIOFIBROSIS NOT SPECIFIED (PRESENT)  
 -HEPATITIS MULTI-FOCAL(TRACE)  
 -HEPATOCTYIC VACUOLIZATION MULTI-FOCAL(TRACE)  
 -CYSTIC DEGENERATION NOT SPECIFIED (PRESENT)

KIDNEY  
 -PROGRESSIVE RENAL DISEASE NOT SPECIFIED(MODERATE)

PROSTATE

**Appendix J (cont.): PATHOLOGY INDIVIDUAL ANIMAL DATA**

LETTERMAN ARMY INSTITUTE OF RESEARCH  
 DIV OF RES SUPP, PATH SERV GP  
 SPECIES: RAT/FISCHER-344  
 STUDY START DATE: 23-JAN-84  
 INDIVIDUAL ANIMAL DATA REPORT  
 STUDY NUMBER: GLP83009  
 PRINTED: 21-NOV-89  
 PAGE: 195  
 STUDY TYPE: CHRONIC/2 YR CARCINOGENIC  
 ANIMAL NUMBER: 92/PRETEST#  
 DOSE GROUP: 2  
 SACRIFICE STATUS: FINAL SACRIFICE  
 DATE OF DEATH: 29-JAN-86  
 STUDY DAY OF DEATH: 738  
 STUDY WEEK OF DEATH: 106  
 TERMINAL BODY WEIGHT: 404.00 (GMS)  
 << MICROSCOPIC TISSUE OBSERVATIONS >>  
 TISSUE / HISTOPATHOLOGIC FINDINGS  
 DISTRIBUTION (SEVERITY) / SPECIAL COMMENTS

- PROSTATE ..... NOT SPECIFIED(MODERATE)
- BENIGN HYPERPLASIA
- TESTES ..... (PRESENT)
- B- INTERSTITIAL CELL ADENOMA
- PANCREAS ..... MULTI-FOCAL(MILD)
- ACINAR (EXOCRINE) ATROPHY (PRESENT)
- B- ISLET CELL ADENOMA
- NOSE/TURBINATES ..... CELLULAR INFILTRATE IS ADJACENT NASO-LACRIMAL DUCT.
- MIXED INFLAMMATORY CELL INFILTRATION, NASAL CAVITY, SINUSES, NOT SPECIFIED(MILD)
- TURBINATES, NASO-LACRIMAL DUCTS
- ADRENAL ..... NOT SPECIFIED(TRACE)
- FOCUS OF CELLULAR ALTERATION, VACUOLATED (PRESENT)
- PITUITARY GLAND
- B- ADENOMA
- EYES & OPTIC N. .... NOT SPECIFIED (PRESENT)
- METAPLASTIC BONE FORMATION AND/OR MINERALIZATION, SCLERA

Appendix J (cont.): PATHOLOGY INDIVIDUAL ANIMAL DATA

LETTERMAN ARMY INSTITUTE OF RESEARCH  
 DIV OF RES SUPP, PATH SERV GP  
 SPECIES: RAT/FISCHER-344  
 STUDY START DATE: 23-JAN-84  
 STUDY NUMBER: GLP83009  
 PRINTED: 21-NOV-89  
 PAGE: 196  
 STUDY TYPE: CHRONIC/2 YR CARCINOGENIC

ANIMAL NUMBER: 93/PRETEST= 93 SEX: MALE DOSE GROUP: 2 SACRIFICE STATUS: FINAL SACRIFICE  
 DATE OF DEATH: 29-JAN-86 STUDY DAY OF DEATH: 738 STUDY WEEK OF DEATH: 105 TERMINAL BODY WEIGHT: 397.00 (GMS)

<< GROSS ORGAN OBSERVATIONS >>  
 SEVERITY GROSS FREE-TEXT COMMENTS

SKIN EPIDERMAL "HORN" PRESENT .5CM DIAMETER, MID-DORSAL BACK  
 LIVER ADHESION(S) PRESENT VENTRAL ABDOMINAL WALL  
 TESTES GROWTH(S) / MASS(ES) PRESENT BILATERAL, MULTIPLE VARIABLY SIZED, YELLOW

<< MICROSCOPIC TISSUE OBSERVATIONS >>  
 DISTRIBUTION (SEVERITY) / SPECIAL COMMENTS

THYROID GLANDS ..... (PRESENT)  
 -B-ADENOMA, FOLLICULAR  
 HEART ..... NOT SPECIFIED(MILD)  
 -CARDIOMYOPATHY

LIVER ..... NOT SPECIFIED(MODERATE)  
 -BILI DUCTULE EPITHELIAL HYPERPLASIA AND/OR CHOLANGIOFIBROSIS  
 -FOCUS OF CELLULAR ALTERATION - BASOPHILIC  
 -FIBROSIS CAPSULAR NO COMPOUND  
 -NECROSIS, HEPATOCYTTIC, INDIVIDUAL CELLS

KIDNEY ..... NOT SPECIFIED(MILD)  
 -PROGRESSIVE RENAL DISEASE

PROSTATE ..... NOT SPECIFIED(MILD)  
 -CHRONIC PROSTATITIS

SEMINAL VESICLE ..... NOT SPECIFIED (PRESENT)  
 GENERALIZED ATROPHY

TESTES ..... (PRESENT)  
 -B- INTERSTITIAL CELL ADENOMA

PANCREAS .....

Appendix J (cont.): PATHOLOGY INDIVIDUAL ANIMAL DATA

LETTERMAN ARMY INSTITUTE OF RESEARCH  
 DIV OF RES SUPP, PATH SERV GP  
 SPECIES: RAT/FISCHER-344  
 STUDY START DATE: 23-JAN-84  
 ANIMAL NUMBER: 93/PRETEST= 93 SEX: MALE DOSE GROUP: 2 SACRIFICE STATUS: FINAL SACRIFICE  
 DATE OF DEATH: 29-JAN-86 STUDY DAY OF DEATH: 738 STUDY WEEK OF DEATH: 106 TERMINAL BODY WEIGHT: 397.00 (GMS)  
 TISSUE / HISTOPATHOLOGIC FINDINGS << MICROSCOPIC TISSUE OBSERVATIONS >>  
 DISTRIBUTION (SEVERITY) / SPECIAL COMMENTS

PRINTED: 21-NOV-89  
PAGE: 197

STUDY TYPE: CHRONIC/2 YR CARCINOGENIC

PANCREAS ..... FOCAL (TRACE)  
-ACINAR (EXOCRINE) ATROPHY

SKIN ..... LESION DESCRIBED GROSSLY AS EPIDERMAL "HORN" IS A SQUAMOUS PAPILLOMA. RIBED GROSSLY AS EPIDERMAL "HORN" IS A SQUAMOUS (PRESENT)

MAMMARY GLANDS ..... NOT SPECIFIED (MARKED)  
-HYPERPLASIA AND/OR HYPERTROPHY OF THE ACINAR TISSUE

PITUITARY GLAND ..... (PRESENT)  
-B- ADENOMA

EYES & OPTIC N. .... NOT SPECIFIED (PRESENT)  
-METAPLASTIC BONE FORMATION AND/OR MINERALIZATION, SCLERA

Appendix J (cont.): PATHOLOGY INDIVIDUAL ANIMAL DATA

LETTERMAN ARMY INSTITUTE OF RESEARCH  
 DIV OF RES SUPP, PATH SERV GP  
 SPECIES: RAT/FISCHER-344  
 STUDY START DATE: 23-JAN-84  
 STUDY NUMBER: GLP83009  
 PRINTED: 21-NOV-89  
 PAGE: 198  
 STUDY TYPE: CHRONIC/2 YR CARCINOGENIC

ANIMAL NUMBER: 94/PRETEST# 94 SEX: MALE DOSE GROUP: 2 SACRIFICE STATUS: FINAL SACRIFICE  
 DATE OF DEATH: 29-JAN-86 STUDY DAY OF DEATH: 738 STUDY WEEK OF DEATH: 106 TERMINAL BODY WEIGHT: 367.00 (GMS)

ORGAN NAME << GROSS ORGAN OBSERVATIONS >>  
 SEVERITY GROSS FREE-TEXT COMMENTS  
 LIVER ADHESION(S) PRESENT VENTRAL ABDOMINAL WALL  
 TESTES DISCOLORATION PRESENT LEFT, RED  
 TESTES ENLARGED PRESENT BILATERAL, 2.5 X 1.5CM  
 TESTES GROWTH(S) / MASS(ES) PRESENT MULTIPLE, VARIABLY SIZED, YELLOW/BLACK

TISSUE / HISTOPATHOLOGIC FINDINGS << MICROSCOPIC TISSUE OBSERVATIONS >>  
 DISTRIBUTION (SEVERITY) / SPECIAL COMMENTS

BRAIN ..... A SMALL FRAGMENT OF ESSENTIALLY NORMAL APPEARING PITUITARY  
 TISSUE IS SITUATED WITHIN BRAIN TISSUE IN THE VENTRAL THALAMUS.  
 THIS FINDING IS INTERPRETED AS ARTIFACT.

THYROID GLANDS ..... (PRESENT)  
 -B- PARA-FOLLICULAR CELL ADENOMA

HEART .....  
 -CARDIOMYOPATHY ..... NOT SPECIFIED(TRACE)  
 -MEDIAL HYPERTROPHY OF MUSCULAR ARTERIES ..... NOT SPECIFIED(TRACE)

LUNGS .....  
 -MINERALIZATION OF PULMONARY ARTERIES ..... NOT SPECIFIED(TRACE)

LYMPH NODES ..... REACTIVE HYPERPLASIA NOTED IN CERVICAL NODES.  
 -REACTIVE HYPERPLASIA ..... NOT SPECIFIED (PRESENT)

LIVER .....  
 -COMPOUND RELATED INFLAMMATORY REACTION ..... NOT SPECIFIED (PRESENT)  
 -BILE DUCTULE EPITHELIAL HYPERPLASIA AND/OR CHOLANGIOFIBROSIS ..... NOT SPECIFIED(MODERATE)  
 -HEPATITIS ..... MULTI-FOCAL(TRACE)  
 -HEPATOCTYIC VACUOLIZATION ..... MULTI-FOCAL(MILD)  
 -FOCUS OF CELLULAR ALTERATION - CLEAR CELLS ..... NOT SPECIFIED(MILD)

KIDNEY .....

Appendix J (cont.): PATHOLOGY INDIVIDUAL ANIMAL DATA

LETTERMAN ARMY INSTITUTE OF RESEARCH  
 DIV OF RES SUPP, PATH SERV GP  
 SPECIES: RAT/FISCHER-344  
 STUDY NUMBER: GLP83009  
 STUDY START DATE: 23-JAN-84  
 STUDY TYPE: CHRONIC/2 YR CARCINOGENIC  
 ANIMAL NUMBER: 94/PRETEST# 94 SEX: MALE DOSE GROUP: 2 SACRIFICE STATUS: FINAL SACRIFICE  
 DATE OF DEATH: 29-JAN-86 STUDY DAY OF DEATH: 738 STUDY WEEK OF DEATH: 106 TERMINAL BODY WEIGHT: 367.00 (GMS)  
 << MICROSCOPIC TISSUE OBSERVATIONS >>  
 TISSUE / HISTOPATHOLOGIC FINDINGS DISTRIBUTION (SEVERITY) / SPECIAL COMMENTS

PRINTED: 21-NOV-89  
PAGE: 199

KIDNEY ..... NOT SPECIFIED(MODERATE)  
-PROGRESSIVE RENAL DISEASE

PROSTATE ..... NOT SPECIFIED(TRACE)  
-BENIGN HYPERPLASIA

SERINAL VESICLE ..... NOT SPECIFIED (PRESENT)  
-GENERALIZED ATROPHY

TESTES ..... (PRESENT)  
-B- INTERSTITIAL CELL ADENOMA

PANCREAS ..... NOT SPECIFIED(TRACE)  
-ACINAR (EXOCRINE) ATROPHY  
-CHRONIC INFLAMMATION  
FOCAL(MILD)

MAMMARY GLANDS ..... NOT SPECIFIED(TRACE)  
-HYPERPLASIA AND/OR HYPERTROPHY OF THE ACINAR TISSUE

NOSE/TURBINATES ..... CELLULAR INFILTRATE NOTED ADJACENT TO NASO-LACRIMAL DUCT.  
-MIXED INFLAMMATORY CELL INFILTRATION, NASAL CAVITY, SINUSES, NOT SPECIFIED(TRACE)  
TURBINATES, NASO-LACRIMAL DUCTS



Appendix J (cont.): PATHOLOGY INDIVIDUAL ANIMAL DATA

LETTERMAN ARMY INSTITUTE OF RESEARCH  
 DIV OF RES SUPP, PATH SERV GP  
 SPECIES: RAT/FISCHER-344  
 STUDY NUMBER: GLP83009  
 STUDY START DATE: 23-JAN-84  
 PRINTED: 21-NOV-89  
 PAGE: 200  
 STUDY TYPE: CHRONIC/2 YR CARCINOGENIC

ANIMAL NUMBER: 95/PRETEST  
 DATE OF DEATH: 24-OCT-85  
 DOSE GROUP: 2  
 STUDY WEEK OF DEATH: 92  
 SACRIFICE STATUS: SACRIFICED MORIBUND  
 TERMINAL BODY WEIGHT: 474.00 (GMS)

ORGAN NAME: SPLEEN  
 KEYWORDS / PHRASES: ENLARGED (SPLENO-MEGALY)  
 SEVERITY: MODERATE  
 GROSS ORGAN OBSERVATIONS: 6 X 1.5 X 1CM  
 TISSUE OBSERVATIONS: PRESENT  
 DISTRIBUTION (SEVERITY) / SPECIAL COMMENTS: DARK RED  
 RED, FIRM, .5 X .1CM, IN MESENTERY NEAR STOMACH

- THYROID GLANDS ..... (PRESENT)
- B- PARA-FOLLICULAR CELL ADENOMA
- HEART ..... (PRESENT)
- CARDIOMYOPATHY
- MEDIAL HYPERTROPHY OF MUSCULAR ARTERIES
- LUNGS ..... (PRESENT)
- N- LARGE GRANULAR LYMPHOCYTE LEUKEMIA, METASTATIC
- SPLEEN ..... (PRESENT)
- INFARCTION, CHRONIC
- N- LARGE GRANULAR LYMPHOCYTE LEUKEMIA, METASTATIC
- LYMPH NODES ..... (PRESENT)
- N- LARGE GRANULAR LYMPHOCYTE LEUKEMIA, METASTATIC
- LIVER ..... (PRESENT)
- COMPOUND RELATED INFLAMMATORY REACTION
- BILE DUCTULE EPITHELIAL HYPERPLASIA AND/OR CHOLANGIOFIBROSIS
- CYSTIC DEGENERATION
- HEPATOCTYIC DEGENERATIVE CHANGES (NON-NECROTIC)
- NECROSIS, HEPATOCTYIC, INDIVIDUAL CELLS

**Appendix J (cont.): PATHOLOGY INDIVIDUAL ANIMAL DATA**

LETTERMAN ARMY INSTITUTE OF RESEARCH  
 DIV OF RES SUPP, PATH SERV GP  
 SPECIES: RAT/FISCHER-344  
 STUDY START DATE: 23-JAN-84  
 STUDY NUMBER: GLP83009  
 PRINTED: 21-NOV-89  
 PAGE: 201  
 STUDY TYPE: CHRONIC/2 YR CARCINOGENIC

ANIMAL NUMBER: 95/PRETEST-  
 DATE OF DEATH: 24-OCT-85  
 STUDY DAY OF DEATH: 641  
 DOSE GROUP: 2  
 SACRIFICE STATUS: SACRIFICED MORIBUND  
 STUDY WEEK OF DEATH: 92  
 TERMINAL BODY WEIGHT: 474.00 (GMS)

TISSUE / HISTOPATHOLOGIC FINDINGS  
 << M I C R O S C O P I C T I S S U E O B S E R V A T I O N S >>  
 DISTRIBUTION (SEVERITY) / SPECIAL COMMENTS

LIVER .....  
 -BENIGN HYPERPLASTIC MODULE(S) ..... FOCAL(TRACE)  
 -M- LARGE GRANULAR LYMPHOCYTE LEUKEMIA, METASTATIC (PRESENT)

KIDNEY .....  
 -PROGRESSIVE RENAL DISEASE ..... NOT SPECIFIED(TRACE)

PROSTATE .....  
 -BENIGN HYPERPLASIA ..... NOT SPECIFIED(MILD)

TESTES .....  
 -B- INTERSTITIAL CELL ADENOMA ..... (PRESENT)

PANCREAS .....  
 -A- INAR (EXOCRINE) ATROPHY ..... THE MASS IN THE MESENTERY ADJACENT TO THE DUODENUM IS AN ISLET  
 -B- ISLET CELL ADENOMA ..... NOT SPECIFIED(TRACE)  
 (PRESENT)

NOSE/TURBINATES ..... TISSUE IS MISSING

ADRENAL .....  
 -LIPIDOSIS ..... NOT SPECIFIED(TRACE)

PITUITARY GLAND .....  
 -CYST(S) ..... NOT SPECIFIED (PRESENT)  
 -HEMORRHAGE ..... NOT SPECIFIED (PRESENT)

WHOLE BODY .....  
 -M- LARGE GRANULAR LYMPHOCYTIC LEUKEMIA ..... (PRESENT)

**Appendix J (cont.): PATHOLOGY INDIVIDUAL ANIMAL DATA**

LETTERMAN ARMY INSTITUTE OF RESEARCH  
 DIV OF RES SUPP, PATH SERV GP  
 SPECIES: RAT/FISCHER-344  
 ANIMAL NUMBER: 96/PRETEST-  
 DATE OF DEATH: 29-JAN-86  
 STUDY START DATE: 23-JAN-84  
 DOSE GROUP: 2  
 STUDY WEEK OF DEATH: 106  
 TERMINAL BODY WEIGHT: 346.00 (GMS)  
 SACRIFICE STATUS: FINAL SACRIFICE  
 STUDY TYPE: CHRONIC/2 YR CARCINOGENIC

PRINTED: 21-NOV-89  
 PAGE: 202

<< GROSS ORGAN OBSERVATIONS >>  
 SEVERITY GROSS FREE-TEXT COMMENTS  
 LIVER PRESENT VENTRAL ABDOMINAL WALL  
 THYROID PRESENT .8 X .5CM, MOTTLED RED, LEFT. .2MM DIAMETER, MOTTLED RED, RIGHT  
 ADRENAL PRESENT ENLARGED, UNILATERALLY  
 TESTES PRESENT GROWTH(S) / MASS(ES)  
 KIDNEY PRESENT GRANULAR SURFACE

<< MICROSCOPIC TISSUE OBSERVATIONS >>  
 DISTRIBUTION (SEVERITY) / SPECIAL COMMENTS

THYROID GLANDS  
 -B- PARA-FOLLICULAR CELL ADENOMA (PRESENT)  
 HEART  
 -CARDIOMYOPATHY NOT SPECIFIED(MILD)  
 -MEDIAL HYPERTROPHY OF MUSCULAR ARTERIES NOT SPECIFIED(TRACE)  
 LUNGS  
 -MINERALIZATION OF PULMONARY ARTERIES NOT SPECIFIED(TRACE)  
 SPLEEN  
 -FIBROSIS CAPSULAR FOCAL(TRACE)  
 -BENIGN HYPERTROPHIC NODULE NOT SPECIFIED (PRESENT)  
 LYMPH NODES  
 -REACTIVE HYPERPLASIA REACTIVE HYPERPLASIA INVOLVES CERVICAL NODES.  
 NOT SPECIFIED (PRESENT)  
 LIVER  
 -COMPOUND RELATED INFLAMMATORY REACTION NOT SPECIFIED (PRESENT)  
 -BILE DUCTULE EPITHELIAL HYPERPLASIA AND/OR CHOLANGIOFIBROSIS NOT SPECIFIED(MILD)  
 -HEPATOCTIC VACUOLIZATION MULTI-FOCAL(MILD)  
 -FOCUS OF CELLULAR ALTERATION - CLEAR CELLS NOT SPECIFIED(TRACE)

**Appendix J (cont.): PATHOLOGY INDIVIDUAL ANIMAL DATA**

LETTERMAN ARMY INSTITUTE OF RESEARCH  
 DIV OF RES SUPP, PATH SERV GP  
 SPECIES: RAT/FISCHER-344  
 INDIVIDUAL ANIMAL DATA REPORT  
 STUDY NUMBER: GLP83009  
 STUDY START DATE: 23-JAN-84  
 PRINTED: 21-NOV-89  
 PAGE: 203  
 STUDY TYPE: CHRONIC/2 YR CARCINOGENIC

ANIMAL NUMBER: 96/PRETEST= 96 SEX: MALE DOSE GROUP: 2 SACRIFICE STATUS: FINAL SACRIFICE  
 DATE OF DEATH: 29-JAN-86 STUDY DAY OF DEATH: 738 STUDY WEEK OF DEATH: 106 TERMINAL BODY WEIGHT: 346.00 (GMS)

<< M I C R O S C O P I C T I S S U E O B S E R V A T I O N S >>  
 TISSUE / HISTOPATHOLOGIC FINDINGS DISTRIBUTION (SEVERITY) / SPECIAL COMMENTS

LIVER ..... NOT SPECIFIED (PRESENT)  
 -CYSTIC DEGENERATION

KIDNEY ..... NOT SPECIFIED(MODERATE)  
 -PROGRESSIVE RENAL DISEASE

PROSTATE ..... NOT SPECIFIED(TRACE)  
 -CHRONIC PROSTATITIS  
 -BENIGN HYPERPLASIA

SEMINAL VESICLE ..... NOT SPECIFIED (PRESENT)  
 -GENERALIZED ATROPHY

TESTES ..... (PRESENT)  
 -B- INTERSTITIAL CELL ADENOMA

SKELETAL MUSCLE ..... TISSUE IS MISSING

SCIATIC NERVE ..... TISSUE IS MISSING

MAMMARY GLANDS ..... NOT SPECIFIED(TRACE)  
 -HYPERPLASIA AND/OR HYPERTROPHY OF THE ACINAR TISSUE

ADRENAL ..... (PRESENT)  
 -B- PHEOCHROMOCYTOMA

PITUITARY GLAND ..... (PRESENT)  
 -B- ADENOMA

EYES & OPTIC N. .... NOT SPECIFIED (PRESENT)  
 -LENTICULAR DEGENERATIVE CHANGES COMPATIBLE WITH CATARACT

**Appendix J (cont.): PATHOLOGY INDIVIDUAL ANIMAL DATA**

LETTERMAN ARMY INSTITUTE OF RESEARCH  
 DIV OF RES SUPP, PATH SERV GP  
 SPECIES: RAT/FISCHER-344

INDIVIDUAL ANIMAL DATA REPORT  
 STUDY NUMBER: GLP83009

STUDY START DATE: 23-JAN-84

ANIMAL NUMBER: 97/PRETEST-97 SEX: MALE DOSE GROUP: 2 SACRIFICE STATUS: FINAL SACRIFICE  
 DATE OF DEATH: 29-JAN-86 STUDY DAY OF DEATH: 738 STUDY WEEK OF DEATH: 106 TERMINAL BODY WEIGHT: 393.00 (GMS)

STUDY TYPE: CHRONIC/2 YR CARCINOGENIC

ORGAN NAME                   << GROSS ORGAN OBSERVATIONS >>  
 SEVERITY GROSS FREE-TEXT COMMENTS  
 LIVER                   ADHESION(S)                   PRESENT   VENTRAL ABDOMINAL WALL  
 PITUITARY GLAND       DISCOLORATION               PRESENT   FOCAL, .1CM DIAMETER, BLACK  
 TESTES                ATROPHIC / SMALL, UNILATERALLY   PRESENT   LEFT, 1.5 X 1CM  
 TESTES                ENLARGED                       PRESENT   2.5 X 1.75CM  
 TESTES                GROWTH(S) / MASS(ES)       PRESENT   BILATERAL, MULTIPLE VARIABLY SIZED, YELLOW

TISSUE / HISTOPATHOLOGIC FINDINGS                   << MICROSCOPIC TISSUE OBSERVATIONS >>  
 DISTRIBUTION (SEVERITY) / SPECIAL COMMENTS

THYROID GLANDS .....  
 -FOLLICULAR HYPERTROPHY/HYPERPLASIA ..... NOT SPECIFIED (PRESENT)  
 -PARA-FOLLICULAR CELL HYPERPLASIA ("C" CELL, LIGHT CELL) ..... NOT SPECIFIED (TRACE)

HEART .....  
 -CARDIOMYOPATHY ..... NOT SPECIFIED (MODERATE)

LUNGS .....  
 -MINERALIZATION OF PULMONARY ARTERIES ..... NOT SPECIFIED (MILD)  
 -PERIBRONCHIAL LYMPHOID HYPERPLASIA ..... NOT SPECIFIED (MILD)

LYMPH NODES .....  
 -RED BLOOD CELLS, HEMOSIDERIN AND/OR ERYTHROPHAGOCYTOSIS WITHIN ..... HEMOSIDERIN PIGMENT IS PRESENT IN MEDIASTINAL NODE.  
 MEDULLARY SINUSES ..... NOT SPECIFIED (PRESENT)

LIVER .....  
 -COMPOUND RELATED INFLAMMATORY REACTION ..... NOT SPECIFIED (PRESENT)  
 -BILE DUCTULE EPITHELIAL HYPERPLASIA AND/OR CHOLANGIOFIBROSIS ..... NOT SPECIFIED (MILD)  
 -HEPATOCTYIC VACUOLIZATION ..... MULTI-FOCAL (MILD)  
 -TELANGIECTASIS ..... NOT SPECIFIED (MILD)  
 -CYSTIC DEGENERATION ..... NOT SPECIFIED (PRESENT)  
 -BENIGN HYPERPLASTIC NODULE(S) ..... NOT SPECIFIED (MILD)

**Appendix J (cont.): PATHOLOGY INDIVIDUAL ANIMAL DATA**

LETTERMAN ARMY INSTITUTE OF RESEARCH  
 DIV OF RES SUPP, PATH SERV GP  
 SPECIES: RAT/FISCHER-344  
 STUDY START DATE: 23-JAN-84  
 STUDY NUMBER: GLP83009  
 PRINTED: 21-NOV-89  
 PAGE: 205  
 STUDY TYPE: CHRONIC/2 YR CARCINOGENIC

ANIMAL NUMBER: 97/PRETEST#  
 DOSE GROUP: 2  
 SACRIFICE STATUS: FINAL SACRIFICE  
 DATE OF DEATH: 29-JAN-86  
 STUDY DAY OF DEATH: 738  
 STUDY WEEK OF DEATH: 106  
 TERMINAL BODY WEIGHT: 393.00 (GMS)

<< M I C R O S C O P I C T I S S U E O B S E R V A T I O N S >>  
 TISSUE / HISTOPATHOLOGIC FINDINGS  
 DISTRIBUTION (SEVERITY) / SPECIAL COMMENTS

- LIVER .....  
 -HEPATOCTE COALESCING MICROVESICULAR (FATTY) CHANGE LEADING TO MULTI-FOCAL(MODERATE)  
 NECROSIS AND MINERALIZATION
- KIDNEY .....  
 -PROGRESSIVE RENAL DISEASE  
 NOT SPECIFIED(MODERATE)
- PROSTATE .....  
 -CHRONIC PROSTATITIS  
 -BENIGN HYPERPLASIA  
 NOT SPECIFIED(MILD)  
 NOT SPECIFIED(TRACE)
- SEMINAL VESICLE .....  
 -GENERALIZED ATROPHY  
 NOT SPECIFIED (PRESENT)
- EDIDIDYMS .....  
 TISSUE IS MISSING
- TESTES .....  
 -B- INTERSTITIAL CELL ADENOMA  
 (PRESENT)
- MAMMARY GLANDS .....  
 -HYPERPLASIA AND/OR HYPERTROPHY OF THE ACIMAR TISSUE  
 -DILATATION (ECTASIA) OF DUCTS AND DUCTULES  
 NOT SPECIFIED(MILD)  
 NOT SPECIFIED (PRESENT)
- NOSE/TURBINATES .....  
 -MIXED INFLAMMATORY CELL INFILTRATION, NASAL CAVITY, SINUSES,  
 TURBINATES, MASO-LACRIMAL DUCTS  
 CELLULAR INFILTRATE INVOLVES MASO-LACRIMAL DUCTS BILATERALLY.  
 NOT SPECIFIED(MILD)
- ADRENAL .....  
 -CORTICAL MODULAR HYPERPLASIA  
 NOT SPECIFIED (PRESENT)
- PITUITARY GLAND .....  
 -B- ADENOMA  
 (PRESENT)
- EYES & OPTIC N. ....

Appendix J (cont.): PATHOLOGY INDIVIDUAL ANIMAL DATA

LETTERMAN ARMY INSTITUTE OF RESEARCH INDIVIDUAL ANIMAL DATA REPORT PRINTED: 21-NOV-89  
 DIV OF RES SUPP, PATH SERV GP STUDY NUMBER: GLP83009 PAGE: 206  
 SPECIES: RAT/FISCHER-344 STUDY START DATE: 23-JAN-84 STUDY TYPE: CHRONIC/2 YR CARCINOGENIC

ANIMAL NUMBER: 97/PRETEST- DOSE GROUP: 2 SACRIFICE STATUS: FINAL SACRIFICE  
 DATE OF DEATH: 29-JAN-86 STUDY DAY OF DEATH: 738 STUDY WEEK OF DEATH: 106 TERMINAL BODY WEIGHT: 393.00 (GMS)

<< MICROSCOPIC TISSUE OBSERVATIONS >>  
 TISSUE / HISTOPATHOLOGIC FINDINGS DISTRIBUTION (SEVERITY) / SPECIAL COMMENTS

EYES & OPTIC N. .... NOT SPECIFIED (TRACE)  
 -RETINAL ATROPHY AND/OR DEGENERATION, UNILATERAL OR BILATERAL NOT SPECIFIED (PRESENT)  
 -LENTICULAR DEGENERATIVE CHANGES COMPATIBLE WITH CATARACT

**Appendix J (cont.): PATHOLOGY INDIVIDUAL ANIMAL DATA**

LETTERMAN ARMY INSTITUTE OF RESEARCH  
 DIV OF RES SUPP, PATH SERV GP  
 SPECIES: RAT/FISCHER-344  
 STUDY START DATE: 23-JAN-84  
 STUDY NUMBER: GLP83009  
 PRINTED: 21-NOV-89  
 PAGE: 207  
 STUDY TYPE: CHRONIC/2 YR CARCINOGENIC  
 ANIMAL NUMBER: 98/PRETEST=  
 DATE OF DEATH: 29-JAN-86  
 SEX: MALE  
 DOSE GROUP: 2  
 SACRIFICE STATUS: FINAL SACRIFICE  
 STUDY WEEK OF DEATH: 106  
 TERMINAL BODY WEIGHT: 372.00 (GMS)

ORGAN NAME  
 KEYWORDS / PHRASES  
 GROSS ORGAN OBSERVATIONS >>  
 SEVERITY GROSS FREE-TEXT COMMENTS  
 PERITONEAL CAV. GROWTH(S) / MASS(ES) PRESENT BROWN CAULIFLOWER, INVOLVES OMENTUM AND BILATERALLY INVOLVES TESTES AND SCROTAL SACS  
 TESTES ENLARGED PRESENT BILATERAL, 2.5 X 1.5CM  
 TESTES GROWTH(S) / MASS(ES) PRESENT BILATERAL, MULTIPLE VARIABLY SIZED, YELLOW/BLACK  
 LIVER ADHESION(S) PRESENT VENTRAL ABDOMINAL WALL

TISSUE / HISTOPATHOLOGIC FINDINGS  
 << MICROSCOPIC TISSUE OBSERVATIONS >>  
 DISTRIBUTION (SEVERITY) / SPECIAL COMMENTS

- THYROID GLANDS ..... (PRESENT)
- B- PARA-FOLLICULAR CELL ADENOMA
- SALIVARY GLAND ..... FOCAL ACINAR ATROPHY IS PRESENT IN PAROTID GLAND.
- ATROPHY AND LOSS OF ACINAR TISSUE FOCAL(TRACE)
- HEART ..... NOT SPECIFIED(MODERATE)
- CARDIOMYOPATHY
- LUNGS ..... NOT SPECIFIED(TRACE)
- MINERALIZATION OF PULMONARY ARTERIES
- SPLEEN ..... SECONDARY NEOPLASM FROM ORGAN ABDOMINAL CAVITY
- W- PRESENCE OF METASTATIC NEOPLASM
- LIVER ..... NOT SPECIFIED (PRESENT)
- COMPOUND RELATED INFLAMMATORY REACTION NOT SPECIFIED(MILD)
- BILE DUCTULE EPITHELIAL HYPERPLASIA AND/OR CHOLANGIOFIBROSIS MULTI-FOCAL(MILD)
- HEPATITIS MULTI-FOCAL(TRACE)
- BENIGN HYPERPLASTIC MODULE(S)
- KIDNEY ..... NOT SPECIFIED(MILD)
- PROGRESSIVE RENAL DISEASE
- PROSTATE .....



Appendix J (cont.): PATHOLOGY INDIVIDUAL ANIMAL DATA

LETTERMAN ARMY INSTITUTE OF RESEARCH  
 DIV OF RES SUPP, PATH SERV GP  
 SPECIES: RAT/FISCHER-344  
 STUDY START DATE: 23-JAN-84  
 STUDY NUMBER: GLP83009  
 PRINTED: 21-NOV-89  
 PAGE: 208

ANIMAL NUMBER: 98/PRETEST= 98 SEX: MALE DOSE GROUP: 2 SACRIFICE STATUS: FINAL SACRIFICE  
 DATE OF DEATH: 29-JAN-86 STUDY DAY OF DEATH: 738 STUDY WEEK OF DEATH: 106 TERMINAL BODY WEIGHT: 372.00 (GMS)  
 STUDY TYPE: CHRONIC/2 YR CARCINOGENIC

TISSUE / HISTOPATHOLOGIC FINDINGS  
 << MICROSCOPIC TISSUE OBSERVATIONS >>  
 DISTRIBUTION (SEVERITY) / SPECIAL COMMENTS

PROSTATE ..... NOT SPECIFIED (TRACE)  
 -CHRONIC PROSTATITIS ..... NOT SPECIFIED (TRACE)  
 -BENIGN HYPERPLASIA

SEMINAL VESICLE ..... NOT SPECIFIED (PRESENT)  
 -GENERALIZED ATROPHY

TESTES ..... (PRESENT)  
 -B- INTERSTITIAL CELL ADENOMA ..... SECONDARY NEOPLASM FROM ORGAN  
 -N- PRESENCE OF METASTATIC NEOPLASM

PANCREAS ..... NOT SPECIFIED (TRACE)  
 -ACINAR (EXOCRINE) ATROPHY ..... (PRESENT)  
 -B- ISLET CELL ADENOMA ..... SECONDARY NEOPLASM FROM ORGAN  
 -N- PRESENCE OF METASTATIC NEOPLASM

MAMMARY GLANDS ..... NOT SPECIFIED (MODERATE)  
 -HYPERPLASIA AND/OR HYPERTROPHY OF THE ACINAR TISSUE ..... NOT SPECIFIED (PRESENT)  
 -DILATATION (ECTASIA) OF DUCTS AND DUCTULES

NOSE TURBINATES ..... CELLULAR INFILTRATE INVOLVES NASO-LACRIMAL DUCTS.  
 -MIA- ) INFLAMMATORY CELL INFILTRATION, NASAL CAVITY, SINUSES, NOT SPECIFIED (TRACE)  
 TURBINATES, NASO-LACRIMAL DUCTS

BONE, STERNUM ..... MULTI-FOCAL (PRESENT)  
 -HYPERPLASIA, MYELOID

BONE, FEMUR ..... MULTI-FOCAL (PRESENT)  
 -HYPERPLASIA MYELOID

PITUITARY GLAND ..... (PRESENT)  
 -B- ADENOMA ..... NOT SPECIFIED (PRESENT)  
 -CYST(S)

EYES & OPTIC N. ....

Appendix J (cont.): PATHOLOGY INDIVIDUAL ANIMAL DATA

LETTERMAN ARMY INSTITUTE OF RESEARCH  
DIV OF RES SUPP, PATH SERV GP  
SPECIES: RAT/FISCHER-344

INDIVIDUAL ANIMAL DATA REPORT  
STUDY NUMBER: GLP83009

PRINTED: 21-NOV-89  
PAGE: 209

STUDY START DATE: 23-JAN-84

STUDY TYPE: CHRONIC/2 YR CARCINOGENIC

ANIMAL NUMBER: 98/PRETEST#  
DATE OF DEATH: 29-JAN-86

98 SEX: MALE  
STUDY DAY OF DEATH: 738

DOSE GROUP: 2  
STUDY WEEK OF DEATH: 106

SACRIFICE STATUS: FINAL SACRIFICE  
TERMINAL BODY WEIGHT: 372.00 (GMS)

TISSUE / HISTOPATHOLOGIC FINDINGS

<< M I C R O S C O P I C T I S S U E O B S E R V A T I O N S >>  
DISTRIBUTION (SEVERITY) / SPECIAL COMMENTS

EYES & OPTIC N. .... NOT SPECIFIED (PRESENT)  
-METAPLASTIC BONE FORMATION AND/OR MINERALIZATION, SCLERA

ABDOMINAL CAVITY ..... MISCELLANEOUS TISSUE (PRESENT)  
-M- MESOTHELIOMA

DIAPHRAGM ..... MISCELLANEOUS TISSUE NOT SPECIFIED (PRESENT)  
-COMPOUND RELATED INFLAMMATORY REACTION

**Appendix J (cont.): PATHOLOGY INDIVIDUAL ANIMAL DATA**

LETTERMAN ARMY INSTITUTE OF RESEARCH  
 DIV OF RES SUPP, PATH SERV GP  
 SPECIES: RAT/FISCHER-344  
 STUDY START DATE: 23-JAN-84  
 STUDY NUMBER: GLP83009  
 PRINTED: 21-NOV-89  
 PAGE: 210  
 STUDY TYPE: CHRONIC/2 YR CARCINOGENIC

ANIMAL NUMBER: 99/PRETEST-  
 DATE OF DEATH: 27-JAN-86  
 SEX: MALE  
 DOSE GROUP: 2  
 SACRIFICE STATUS: SACRIFICED MORIBUND  
 STUDY WEEK OF DEATH: 106  
 TERMINAL BODY WEIGHT: 236.00 (GMS)

<< GROSS ORGAN OBSERVATIONS >>  
 SEVERITY GROSS FREE-TEXT COMMENTS

ORGAN NAME	KEYWORDS / PHRASES	OBSERVATIONS	SEVERITY	GROSS FREE-TEXT COMMENTS
THYROID	ENLARGED		PRESENT	
PERITONEAL CAV.	FLUID-FILLED		PRESENT	LEFT, DARK RED, .4CM DIAMETER
LIVER	PROMINENT LOBULAR MARKINGS		PRESENT	2ML, RED
LIVER	ADHESION(S)		PRESENT	VENTRAL ABDOMINAL WALL AND SMALL INTESTINE
SPLEEN	ENLARGED (SPLENOHEGALY)		PRESENT	6.5 X 1.75CM
KIDNEY	GRANULAR SURFACE		TRACE	
TAIL	NECROSIS		PRESENT	3CM LENGTH AT DISTAL END DRY, BLACK AND ATROPHIED
TESTES	ATROPHIC / SMALL, BILATERALLY		PRESENT	1.5 X 1CM
TESTES	GROWTH(S) / MASS(ES)		PRESENT	BILATERAL, MULTIPLE VARIABLY SIZED, YELLOW AND BLACK

<< HISTOPATHOLOGIC FINDINGS >>  
 TISSUE OBSERVATIONS / SPECIAL COMMENTS

THYROID GLANDS  
 -B- PARA-FOLLICULAR CELL ADENOMA (PRESENT)

HEART  
 -CARDIOMYOPATHY NOT SPECIFIED(MILD)

THYMUS  
 TISSUE IS MISSING

SPLEEN  
 -INFARCTION, CHRONIC FOCAL(TRACE)  
 -EXTRAMEDULLARY HEMATOPOIESIS NOT SPECIFIED (PRESENT)

LIVER  
 -COMPOUND RELATED INFLAMMATORY REACTION NOT SPECIFIED (PRESENT)  
 -BILE DUCTULE EPITHELIAL HYPERPLASIA AND/OR CHOLANGIOFIBROSIS NOT SPECIFIED(MILD)  
 -NECROSIS MULTI-FOCAL(MODERATE)  
 -CYSTIC DEGENERATION NOT SPECIFIED (PRESENT)

KIDNEY

Appendix J (cont.): PATHOLOGY INDIVIDUAL ANIMAL DATA

LETTERMAN ARMY INSTITUTE OF RESEARCH  
DIV OF RES SUPP, PATH SERV GP  
SPECIES: RAT/FISCHER-344

INDIVIDUAL ANIMAL DATA REPORT  
STUDY NUMBER: GLP83009  
STUDY START DATE: 23-JAN-84

PRINTED: 21-NOV-89  
PAGE: 211

STUDY TYPE: CHRONIC/2 YR CARCINOGENIC

ANIMAL NUMBER: 99/PRETEST= 99 SEX: MALE DOSE GROUP: 2 SACRIFICE STATUS: SACRIFICED MORIBUND  
DATE OF DEATH: 27-JAN-86 STUDY DAY OF DEATH: 736 STUDY WEEK OF DEATH: 106 TERMINAL BODY WEIGHT: 236.00 (GMS)

TISSUE / HISTOPATHOLOGIC FINDINGS << MICROSCOPIC TISSUE OBSERVATIONS >>  
DISTRIBUTION (SEVERITY) / SPECIAL COMMENTS

KIDNEY .....  
-PROGRESSIVE RENAL DISEASE ..... NOT SPECIFIED(MODERATE)

PROSTATE .....  
-BENIGN HYPERPLASIA ..... NOT SPECIFIED(TRACE)

SEMINAL VESICLE .....  
-GENERALIZED ATROPHY ..... NOT SPECIFIED (PRESENT)

TESTES .....  
-B- INTERSTITIAL CELL ADENOMA ..... (PRESENT)

SKIN .....  
-EROSION/ULCERATION OF THE SKIN SURFACE ..... SECTION #21 IS FROM THE TAIL LESION AND CONSISTS OF NECROTIC EPIDERMIS AND MINIMAL INFLAMMATION. FROM GROSS DESCRIPTION AND MICROSCOPIC APPEARANCE INFARCTION AND NECROSIS OF THE DISTAL END IF THE TAIL IS SUSPECTED.  
NOT SPECIFIED (PRESENT)

MAMMARY GLANDS .....  
-HYPERPLASIA AND/OR HYPERTROPHY OF THE ACINAR TISSUE ..... NOT SPECIFIED(TRACE)  
-DILATATION (ECTASIA) OF DUCTS AND DUCTULES ..... NOT SPECIFIED (PRESENT)

EYES & OPTIC N. ....  
-METAPLASTIC BONE FORMATION AND/OR MINERALIZATION, SCLERA ..... NOT SPECIFIED (PRESENT)

DIAPHRAGM .....  
-COMPOUND RELATED INFLAMMATORY REACTION ..... MISCELLANEOUS TISSUE  
NOT SPECIFIED (PRESENT)

**Appendix J (cont.): PATHOLOGY INDIVIDUAL ANIMAL DATA**

LETTERMAN ARMY INSTITUTE OF RESEARCH  
 DIV OF RES SUPP, PATH SERV GP  
 SPECIES: RAT/FISCHER-344  
 STUDY START DATE: 23-JAN-84  
 STUDY NUMBER: GLP83009  
 STUDY TYPE: CHRONIC/2 YR CARCINOGENIC  
 ANIMAL NUMBER: 100/PRETEST-  
 DATE OF DEATH: 30-AUG-85  
 STUDY DAY OF DEATH: 586  
 SEX: MALE  
 DOSE GROUP: 2  
 SACRIFICE STATUS: SACRIFICED MORIBUND  
 STUDY WEEK OF DEATH: 84  
 TERMINAL BODY WEIGHT: 411.00 (GMS)

ORGAN NAME  
 LIVER  
 LIVER  
 LIVER  
 WHOLE BODY  
 WHOLE BODY  
 SPLEEN  
 SPLEEN  
 KIDNEY  
 << GROSS ORGAN OBSERVATIONS >>  
 SEVERITY GROSS FREE-TEXT COMMENTS  
 PROMINENT LOBULAR MARKINGS PRESENT  
 ADHESION(S) PRESENT  
 DISCOLORATION PRESENT  
 STAINED HAIR PRESENT  
 FAT GENERALLY YELLOW PRESENT  
 ENLARGED (SPLENOHEGALY) MODERATE  
 FRACTURED PRESENT  
 ISCOLORATION PRESENT  
 VENTRAL ABDOMINAL WALL AND DIAPHRAGM  
 YELLOW MOTTLING  
 YELLOW, WATERY FECAL MATERIAL  
 6 X 2 X 1CM  
 MESENTERIC SURFACE, SURROUNDED BY CLOTTING  
 DIFFUSELY BROWN

TISSUE / HISTOPATHOLOGIC FINDINGS  
 << MICROSCOPIC TISSUE OBSERVATIONS >>  
 DISTRIBUTION (SEVERITY) / SPECIAL COMMENTS

HEART  
 -CARDIOMYOPATHY NOT SPECIFIED(MILD)  
 LUNGS  
 -MINERALIZATION OF PULMONARY ARTERIES NOT SPECIFIED(TRACE)  
 -W- LARGE GRANULAR LYMPHOCYTE LEUKEMIA, METASTATIC (PRESENT)  
 SPLEEN  
 -INFARCTION, CHRONIC MULTI-FOCAL(MODERATE)  
 -W- LARGE GRANULAR LYMPHOCYTE LEUKEMIA, METASTATIC (PRESENT)  
 LYMPH NODES  
 -RED BLOOD CELLS, HEMOSIDERIN AND/OR ERYTHROPHAGOCYTOSIS WITHIN RBC'S, PIGMENT, DILATED SINUSOIDS, AND REACTIVE HYPERPLASIA  
 MEDULLARY SINUSES NOTED IN MEDIASTINAL AND MESENTERIC NODES.  
 -REACTIVE HYPERPLASIA NOT SPECIFIED (PRESENT)  
 -DILATED AND/OR CYSTIC MEDULLARY SINUSES NOT SPECIFIED (PRESENT)  
 LIVER  
 -COMPOUND RELATED INFLAMMATORY REACTION NOT SPECIFIED (PRESENT)

Appendix J (cont.): PATHOLOGY INDIVIDUAL ANIMAL DATA

LETTERMAN ARMY INSTITUTE OF RESEARCH  
DIV OF RES SUPP. PATH SERV GP  
SPECIES: RAT/FISCHER-344

INDIVIDUAL ANIMAL DATA REPORT  
STUDY NUMBER: GLP83009  
STUDY START DATE: 23-JAN-84

PRINTED: 03-JAN-90  
PAGE: 2

STUDY TYPE: CHRONIC/2 YR CARCINOGENIC

ANIMAL NUMBER: 100/PRETEST# 100 SEX: MALE DOSE GROUP: 2 SACRIFICE STATUS: SACRIFICED MORIBUND  
DATE OF DEATH: 30-AUG-85 STUDY DAY OF DEATH: 586 STUDY WEEK OF DEATH: 84 TERMINAL BODY WEIGHT: 411.00 (GMS)

<< MICROSCOPIC TISSUE OBSERVATIONS >>  
DISTRIBUTION (SEVERITY) / SPECIAL COMMENTS

LIVER .....  
 -BILE DUCTULE EPITHELIAL HYPERPLASIA AND/OR CHOLANGIOFIBROSIS ..... NOT SPECIFIED(MODERATE)  
 -NECROSIS ..... MULTI-FOCAL(MODERATE)  
 -HEPATOCTYIC DEGENERATIVE CHANGES (NON-NECROTIC) ..... NOT SPECIFIED(MODERATE)  
 -N- LARGE GRANULAR LYMPHOCYTE LEUKEMIA, METASTATIC (PRESENT)

KIDNEY .....  
 -PROGRESSIVE RENAL DISEASE ..... NOT SPECIFIED(TRACE)

PROSTATE .....  
 -CHRONIC PROSTATITIS ..... NOT SPECIFIED(TRACE)

TESTES .....  
 -B- INTERSTITIAL CELL ADENOMA ..... (PRESENT)

MAMMARY GLANDS .....  
 -HYPERPLASIA AND/OR HYPERTROPHY OF THE ACINAR TISSUE ..... NOT SPECIFIED(TRACE)  
 -DILATATION (ECTASIA) OF DUCTS AND DUCTULES ..... NOT SPECIFIED (PRESENT)

NOSE/TURBINATES .....  
 -MIXED INFLAMMATORY CELL INFILTRATION, NASAL CAVITY, SINUSES, ..... CELLULAR INFILTRATE NEAR NASO-LACRIMAL DUCT.  
 TURBINATES, NASO-LACRIMAL DUCTS ..... NOT SPECIFIED(TRACE)

PITUITARY GLAND .....  
 -CYST(S) ..... NOT SPECIFIED (PRESENT)

WHOLE BODY .....  
 -M- LARGE GRANULAR LYMPHOCYTIC LEUKEMIA ..... (PRESENT)

Appendix J (cont.): PATHOLOGY INDIVIDUAL ANIMAL DATA

LETTERMAN ARMY INSTITUTE OF RESEARCH  
 DIV OF RES SUPP, PATH SERV GP  
 SPECIES: RAT/FISCHER-344  
 STUDY START DATE: 23-JAN-84  
 STUDY TYPE: CHRONIC/2 YR CARCINOGENIC  
 PRINTED: 21-NOV-89  
 PAGE: 214

INDIVIDUAL ANIMAL DATA REPORT  
 STUDY NUMBER: GLP83009  
 DOSE GROUP: 2  
 SACRIFICE STATUS: FINAL SACRIFICE  
 ANIMAL NUMBER: 101/PRETEST-  
 DATE OF DEATH: 30-JAN-86  
 STUDY DAY OF DEATH: 739  
 STUDY WEEK OF DEATH: 106  
 TERMINAL BODY WEIGHT: 356.00 (GMS)

<< GROSS ORGAN OBSERVATIONS >>  
 SEVERITY GROSS FREE-TEXT COMMENTS  
 PRESENT RIGHT, MULTIPLE VARIABLY SIZED, YELLOW

ORGAN NAME  
 KEYWORDS / PHRASES  
 GROWTH(S) / MASS(ES)

<< MICROSCOPIC TISSUE OBSERVATIONS >>  
 DISTRIBUTION (SEVERITY) / SPECIAL COMMENTS

THYROID GLANDS  
 -PARA-FOLLICULAR CELL HYPERPLASIA ("C" CELL, LIGHT CELL) NOT SPECIFIED(TRACE)

PARATHYROID  
 TISSUE IS MISSING

EXORBITAL LACRIM  
 TISSUE IS MISSING

HEART  
 -CARDIOMYOPATHY NOT SPECIFIED(TRACE)

LUNGS  
 -MINERALIZATION OF PULMONARY ARTERIES NOT SPECIFIED(TRACE)

LYMPH NODES  
 -RED BLOOD CELLS, HEOSIDERIN AND/OR ERYTHROPHAGOCYTOSIS WITHIN RBC'S AND PIGMENT NOTED IN MEDIASTINAL NODE.  
 -MEDULLARY SINUSES NOT SPECIFIED (PRESENT)

LIVER  
 -BILE DUCTULE EPITHELIAL HYPERPLASIA AND/OR CHOLANGIOFIBROSIS NOT SPECIFIED(MILD)  
 -HEPATOCTYCE COALESCING MICROVESICULAR (FATTY) CHANGE LEADING TO MULTI-FOCAL(TRACE)  
 NECROSIS AND MINERALIZATION

KIDNEY  
 -PROGRESSIVE RENAL DISEASE NOT SPECIFIED(MODERATE)  
 -HEMORRHAGE, ACUTE, NOT SPECIFIED (PRESENT)

SEMINAL VESICLE

Appendix J (cont.): PATHOLOGY INDIVIDUAL ANIMAL DATA

LETTERMAN ARMY INSTITUTE OF RESEARCH  
DIV OF RES SUPP, PATH SERV GP  
SPECIES: RAT/FISCHER-344

INDIVIDUAL ANIMAL DATA REPORT  
STUDY NUMBER: GLP83009  
STUDY START DATE: 23-JAN-84

PRINTED: 21-NOV-89  
PAGE: 215

STUDY TYPE: CHRONIC/2 YR CARCINOGENIC

ANIMAL NUMBER: 101/PRETEST= 101 SEX: MALE DOSE GROUP: 2 SACRIFICE STATUS: FINAL SACRIFICE  
DATE OF DEATH: 30-JAN-86 STUDY DAY OF DEATH: 739 STUDY WEEK OF DEATH: 106 TERMINAL BODY WEIGHT: 356.00 (GMS)

TISSUE / HISTOPATHOLOGIC FINDINGS << MICROSCOPIC TISSUE OBSERVATIONS >>  
DISTRIBUTION (SEVERITY) / SPECIAL COMMENTS

SEMINAL VESICLE ..... NOT SPECIFIED (PRESENT)  
-GENERALIZED ATROPHY

TESTES ..... (PRESENT)  
-B- INTERSTITIAL CELL ADENOMA

MAMMARY GLANDS ..... NOT SPECIFIED (PRESENT)  
-DILATATION (ECTASIA) OF DUCTS AND DUCTULES

NOSE/TURBINATES ..... CELLULAR INFILTRATE IS ADJACENT NASO-LACRIMAL DUCT.  
-MIXED INFLAMMATORY CELL INFILTRATION, NASAL CAVITY, SINUSES, NOT SPECIFIED(MILD)  
TURBINATES, NASO-LACRIMAL DUCTS



**Appendix J (cont.): PATHOLOGY INDIVIDUAL ANIMAL DATA**

LETTERMAN ARMY INSTITUTE OF RESEARCH  
 DIV OF RES SUPP, PATH SERV GP  
 SPECIES: RAT/FISCHER-344  
 STUDY START DATE: 23-JAN-84  
 STUDY TYPE: CHRONIC/2 YR CARCINOGENIC  
 PRINTED: 21-NOV-89  
 PAGE: 216

INDIVIDUAL ANIMAL DATA REPORT  
 STUDY NUMBER: GLP83009  
 ANIMAL NUMBER: 102/PRETEST# 102 SEX: MALE DOSE GROUP: 2 SACRIFICE STATUS: FINAL SACRIFICE  
 DATE OF DEATH: 30-JAN-86 STUDY DAY OF DEATH: 739 STUDY WEEK OF DEATH: 106 TERMINAL BODY WEIGHT: 397.00 (GMS)

ORGAN NAME << GROSS ORGAN OBSERVATIONS >>  
 SEVERITY GROSS FREE-TEXT COMMENTS  
 LIVER ADHESION(S) PRESENT DIAPHRAGM, VENTRAL ABDOMINAL WALL  
 TESTES ENLARGED PRESENT RIGHT, 2.5 X 1.75CM  
 PITUITARY GLAND GROWTH(S) / MASS(ES) PRESENT BILATERAL, MULTIPLE VARIABLY SIZED, YELLOW/BLACK  
 ENLARGED PRESENT .5CM DIAMETER, DARK RED MOTTLED

TISSUE / HISTOPATHOLOGIC FINDINGS << MICROSCOPIC TISSUE OBSERVATIONS >>  
 DISTRIBUTION (SEVERITY) / SPECIAL COMMENTS

THYROID GLANDS  
 -PARA-FOLLICULAR CELL HYPERPLASIA ("C" CELL, LIGHT CELL) NOT SPECIFIED (TRACE)  
 -COLLOID CYST(S) NOT SPECIFIED (PRESENT)

HEART  
 -CARDIOMYOPATHY NOT SPECIFIED (TRACE)

LIVER  
 -COMPOUND RELATED INFLAMMATORY REACTION NOT SPECIFIED (PRESENT)  
 -BILE DUCTULE EPITHELIAL HYPERPLASIA AND/OR CHOLANGIOFIBROSIS NOT SPECIFIED (MILD)  
 -HEPATITIS MULTI-FOCAL (MILD)  
 -HEPATOCYTTIC VACUOLIZATION MULTI-FOCAL (TRACE)

KIDNEY  
 -PROGRESSIVE RENAL DISEASE NOT SPECIFIED (MILD)

PROSTATE  
 -CHRONIC PROSTATITIS NOT SPECIFIED (MODERATE)  
 -BENIGN HYPERPLASIA NOT SPECIFIED (TRACE)

TESTES  
 -B- INTERSTITIAL CELL ADENOMA (PRESENT)

Appendix J (cont.): PATHOLOGY INDIVIDUAL ANIMAL DATA

LETTERMAN ARMY INSTITUTE OF RESEARCH  
DIV OF RES SUPP, PATH SERV GP  
SPECIES: RAT/FISCHER-344

INDIVIDUAL ANIMAL DATA REPORT  
STUDY NUMBER: GLP83009

STUDY START DATE: 23-JAN-84

PRINTED: 21-NOV-89  
PAGE: 217

STUDY TYPE: CHRONIC/2 YR CARCINOGENIC

ANIMAL NUMBER: 102/PRETEST=

102 SEX: MALE

DOSE GROUP: 2

SACRIFICE STATUS: FINAL SACRIFICE

DATE OF DEATH: 30-JAN-86

STUDY DAY OF DEATH: 739

STUDY WEEK OF DEATH: 106

TERMINAL BODY WEIGHT: 397.00 (GMS)

TISSUE / HISTOPATHOLOGIC FINDINGS  
.....  
.....  
.....

<< MICROSCOPIC TISSUE OBSERVATIONS >>  
DISTRIBUTION (SEVERITY) / SPECIAL COMMENTS  
.....  
.....

SCIATIC NERVE ..... TISSUE IS MISSING

MAMMARY GLANDS .....

-HYPERPLASIA AND/OR HYPERTROPHY OF THE ACINAR TISSUE  
-DILATATION (ECTASIA) OF DUCTS AND DUCTULES

NOT SPECIFIED(MILD)  
NOT SPECIFIED (PRESENT)

ADRENAL .....

-FOCUS OF CELLULAR ALTERATION, VACUOLATED  
-FIBROSIS, CAPSULE

NOT SPECIFIED(TRACE)  
NOT SPECIFIED(TRACE)

PITUITARY GLAND .....

-8- ADENOMA

(PRESENT)

EYES & OPTIC N. ....

-METAPLASTIC BONE FORMATION AND/OR MINERALIZATION, SCLERA

NOT SPECIFIED (PRESENT)

EAR .....

THE PITUITARY TUMOR IS LOCATED WITHIN THE CRANIAL CAVITY  
ADJACENT TO THE INNER EAR NEAR THE ORIGIN OF THE ACOUSTIC NERVE.  
IN SECTIONS EXAMINED IT DOES NOT ERODE THE BONE NOR DOES IT  
ACTUALLY INVADE INNER EAR STRUCTURES.  
(PRESENT)

-1- PITUITARY TUMOR INVASION

DIAPHRAGM .....

-COMPOUND RELATED INFLAMMATORY REACTION

MISCELLANEOUS TISSUE  
NOT SPECIFIED (PRESENT)

**Appendix J (cont.): PATHOLOGY INDIVIDUAL ANIMAL DATA**

LETTERMAN ARMY INSTITUTE OF RESEARCH  
 DIV OF RES SUPP, PATH SERV GP  
 SPECIES: RAT/FISCHER-344  
 STUDY START DATE: 23-JAN-84  
 STUDY NUMBER: GLP83009  
 PRINTED: 21-NOV-89  
 PAGE: 218  
 STUDY TYPE: CHRONIC/2 YR CARCINOGENIC  
 ANIMAL NUMBER: 103/PRETEST= 103 SEX: MALE DOSE GROUP: 2 SACRIFICE STATUS: FINAL SACRIFICE  
 DATE OF DEATH: 30-JAN-86 STUDY DAY OF DEATH: 739 STUDY WEEK OF DEATH: 106 TERMINAL BODY WEIGHT: 358.00 (GMS)

<< GROSS ORGAN OBSERVATIONS >>  
 SEVERITY GROSS FREE-TEXT COMMENTS  
 LIVER ADHESION(S) PRESENT VENTRAL ABDOMINAL WALL  
 TESTES ATROPHIC / SMALL, UNILATERALLY PRESENT RIGHT, 1.5 X 1CM  
 TESTES GROWTH(S) / MASS(ES) PRESENT BILATERAL, MULTIPLE VARIABLY SIZED, YELLOW/BLACK  
 JEJUNUM DIVERTICULUM PRESENT 4 X 3CM, THICK WALLED

TISSUE / HISTOPATHOLOGIC FINDINGS  
 << MICROSCOPIC TISSUE OBSERVATIONS >>  
 DISTRIBUTION (SEVERITY) / SPECIAL COMMENTS

THYROID GLANDS  
 -PARA-FOLLICULAR CELL HYPERPLASIA ("C" CELL, LIGHT CELL) NOT SPECIFIED(TRACE)

HEART  
 -CARDIOMYOPATHY NOT SPECIFIED(MODERATE)

SPLEEN  
 -INFARCTION, CHRONIC NOT SPECIFIED(TRACE)

LYMPH NODES  
 -REACTIVE HYPERPLASIA REACTIVE HYPERPLASIA IS NOTED IN CERVICAL, MEDIASTINAL AND MESENTERIC NODES.  
 NOT SPECIFIED (PRESENT)

LIVER  
 -COMPOUND RELATED INFLAMMATORY REACTION NOT SPECIFIED (PRESENT)  
 -BILE DUCTULE EPITHELIAL HYPERPLASIA AND/OR CHOLANGIOFIBROSIS NOT SPECIFIED(MILD)  
 -HEPATOCTYIC VACUOLIZATION NOT SPECIFIED(MODERATE)  
 -CYSTIC DEGENERATION NOT SPECIFIED (PRESENT)  
 -BENIGN HYPERPLASTIC MODULE(S) NOT SPECIFIED(TRACE)

KIDNEY  
 -PROGRESSIVE RENAL DISEASE NOT SPECIFIED(MODERATE)

PROSTATE

Appendix J (cont.): PATHOLOGY INDIVIDUAL ANIMAL DATA

LETTERMAN ARMY INSTITUTE OF RESEARCH  
DIV OF RES SUPP, PATH SERV GP  
SPECIES: RAT/FISCHER-344

INDIVIDUAL ANIMAL DATA REPORT  
STUDY NUMBER: GLP83009

PRINTED: 21-NOV-89  
PAGE: 219

STUDY START DATE: 23-JAN-84

STUDY TYPE: CHRONIC/2 YR CARCINOGENIC

ANIMAL NUMBER: 103/PRETEST# 103 SEX: MALE DOSE GROUP: 2 SACRIFICE STATUS: FINAL SACRIFICE  
DATE OF DEATH: 30-JAN-86 STUDY DAY OF DEATH: 739 STUDY WEEK OF DEATH: 106 TERMINAL BODY WEIGHT: 358.00 (GMS)

TISSUE / HISTOPATHOLOGIC FINDINGS << MICROSCOPIC TISSUE OBSERVATIONS >>  
DISTRIBUTION (SEVERITY) / SPECIAL COMMENTS

PROSTATE ..... NOT SPECIFIED (TRACE)  
-BENIGN HYPERPLASIA

SEMINAL VESICLE ..... NOT SPECIFIED (PRESENT)  
-GENERALIZED ATROPHY

TESTES ..... (PRESENT)  
-B- INTERSTITIAL CELL ADENOMA

JEJUNUM ..... LESIONS CODED UNDER JEJUNUM CORRESPOND TO LESION DESCRIBED GROSSLY AS A DIVERTICULUM. THERE IS ULCERATION, NECROSIS AND INFLAMMATION THROUGHOUT THE ENTIRE THICKNESS OF THE INTESTINAL WALL. THERE IS CONSIDERABLE DILATION OF THE INTESTINAL LUMEN POSSIBLY BECAUSE OF COMPROMISE OF INNERVATION OR BECAUSE OF OBSTRUCTION DUE TO NECROSIS AND INFLAMMATION. THE INITIATING CAUSE OF THIS LESION IS NOT APPARENT IN SECTIONS EXAMINED.

-ACUTE PERITONITIS  
-ENTERITIS, SUBACUTE  
-MUCOSAL EROSION/ULCERATION  
-FIBROVASCULAR ADHESION, SEROSA

PANCREAS ..... (PRESENT)  
-B- ISLET CELL ADENOMA

CECUM ..... NOT SPECIFIED (PRESENT)  
-EDEMA OF THE SUBMUCOSA AND/OR LAMINA PROPRIA  
-MONONUCLEAR CELLULAR INFILTRATION

MAMMARY GLANDS ..... NOT SPECIFIED (PRESENT)  
-DILATATION (ECTASIA) OF DUCTS AND DUCTULES

Appendix J (cont.): PATHOLOGY INDIVIDUAL ANIMAL DATA

LETTERMAN ARMY INSTITUTE OF RESEARCH  
DIV OF RES SUPP, PATH SERV GP  
SPECIES: RAT/FISCHER-344

INDIVIDUAL ANIMAL DATA REPORT  
STUDY NUMBER: GLP83009  
STUDY START DATE: 23-JAN-84

PRINTED: 21-NOV-89  
PAGE: 220

STUDY TYPE: CHRONIC/2 YR CARCINOGENIC

ANIMAL NUMBER: 103/PRETEST-103 SEX: MALE DOSE GROUP: 2 SACRIFICE STATUS: FINAL SACRIFICE  
DATE OF DEATH: 30-JAN-86 STUDY DAY OF DEATH: 739 STUDY WEEK OF DEATH: 106 TERMINAL BODY WEIGHT: 358.00 (GMS)

<< M I C R O S C O P I C T I S S U E O B S E R V A T I O N S >>  
TISSUE / HISTOPATHOLOGIC FINDINGS ..... DISTRIBUTION (SEVERITY) / SPECIAL COMMENTS .....

NOSE/TURBINATES ..... CELLULAR INFILTRATE IS BILATERAL AND INVOLVES NASO-LACRIMAL DUCTS.  
-MIXED INFLAMMATORY CELL INFILTRATION, NASAL CAVITY, SINUSES, NOT SPECIFIED(MILD)  
TURBINATES, NASO-LACRIMAL DUCTS

ADRENAL ..... NOT SPECIFIED (PRESENT)  
-CORTICAL MODULAR HYPERPLASIA

EYES & OPTIC N. .... NOT SPECIFIED (PRESENT)  
-METAPLASTIC BONE FORMATION AND/OR MINERALIZATION, SCLERA

**Appendix J (cont.): PATHOLOGY INDIVIDUAL ANIMAL DATA**

LETTERMAN ARMY INSTITUTE OF RESEARCH  
 DIV OF RES SUPP, PATH SERV GP  
 STUDY NUMBER: GLP83009  
 SPECIES: RAT/FISCHER-344  
 STUDY START DATE: 23-JAN-84  
 STUDY TYPE: CHRONIC/2 YR CARCINOGENIC  
 ANIMAL NUMBER: 104/PRETEST= 104 SEX: MALE DOSE GROUP: 2 SACRIFICE STATUS: FINAL SACRIFICE  
 DATE OF DEATH: 30-JAN-86 STUDY DAY OF DEATH: 739 STUDY WEEK OF DEATH: 106 TERMINAL BODY WEIGHT: 352.00 (GMS)

PRINTED: 21-NOV-89  
 PAGE: 221

<< GROSS ORGAN OBSERVATIONS >>  
 SEVERITY GROSS FREE-TEXT COMMENTS  
 TESTES PRESENT LEFT, MULTIPLE VARIABLY SIZED, YELLOW/BLACK  
 MAMMARY GLAND PRESENT AXILLARY REGION, BILATERAL, YELLOW  
 PITUITARY GLAND PRESENT DARK RED, .5CM DIAMETER  
 KIDNEY PRESENT BILATERAL  
 ADRENAL PRESENT .5CM DIAMETER  
 LIVER PRESENT BETWEEN MEDIAL AND LEFT LATERAL LOBES  
 SPLEEN ENLARGED (SPLENOMEGALY) MARKED 7 X 2 CM

<< MICROSCOPIC TISSUE OBSERVATIONS >>  
 DISTRIBUTION (SEVERITY) / SPECIAL COMMENTS

THYROID GLANDS ..... NOT SPECIFIED(TRACE)  
 -PARA-FOLLICULAR CELL HYPERPLASIA ("C" CELL, LIGHT CELL)  
 HEART ..... ONE FAIRLY LARGE FOCAL AREA OF FIBROSIS IS PRESENT IN THE LEFT VENTRICLE. THIS MAY BE A HEALED INFARCT. IT IS PROBABLY ONE OF THE MANY MANIFESTATIONS OF THE CARDIOMYOPATHY THAT IS COMMON IN THE FISCHER 344 STRAIN OF RAT.  
 -CARDIOMYOPATHY NOT SPECIFIED(MODERATE)  
 -MEDIAL HYPERTROPHY OF MUSCULAR ARTERIES NOT SPECIFIED(MILD)  
 LUNGS ..... (PRESENT)  
 -M- LARGE GRANULAR LYMPHOCYTE LEUKEMIA, METASTATIC  
 THYRUS ..... TISSUE IS MISSING  
 NO THYMIC TISSUE WAS PRESENT IN THE MEDIASTINAL TISSUE SUBMITTED FOR HISTOLOGIC EXAMINATION.  
 SPLEEN ..... FOCAL(TRACE)  
 -FIBROSIS CAPSULAR  
 -M- LARGE GRANULAR LYMPHOCYTE LEUKEMIA, METASTATIC (PRESENT)

**Appendix J (cont.): PATHOLOGY INDIVIDUAL ANIMAL DATA**

LETTERMAN ARMY INSTITUTE OF RESEARCH  
 DIV OF RES SUPP, PATH SERV GP  
 SPECIES: RAT/FISCHER-344  
 STUDY NUMBER: GLP83009  
 STUDY START DATE: 23-JAN-84  
 STUDY TYPE: CHRONIC/2 YR CARCINOGENIC  
 PRINTED: 21-NOV-89  
 PAGE: 222

ANIMAL NUMBER: 104/PRETEST= 104 SEX: MALE DOSE GROUP: 2 SACRIFICE STATUS: FINAL SACRIFICE  
 DATE OF DEATH: 30-JAN-86 STUDY DAY OF DEATH: 739 STUDY WEEK OF DEATH: 106 TERMINAL BODY WEIGHT: 352.00 (GMS)

TISSUE / HISTOPATHOLOGIC FINDINGS  
 << MICROSCOPIC TISSUE OBSERVATIONS >>  
 DISTRIBUTION (SEVERITY) / SPECIAL COMMENTS

LYMPH NODES ..... REACTIVE HYPERPLASIA IS NOTED IN CERVICAL NODES. THE  
 MEDIASTINAL NODE IS ALMOST COMPLETELY EFFACED BY THE PRESENCE OF  
 NEOPLASTIC LYMPHOCYTES (LGLL). THERE ARE A FEW NEOPLASTIC  
 LYMPHOCYTES IN MESENTERIC NODES BUT THE BASIC NODAL  
 ARCHITECTURE REMAINS INTACT.  
 (PRESENT)  
 NOT SPECIFIED (PRESENT)

-N- LARGE GRANULAR LYMPHOCYTE LEUKEMIA, METASTATIC  
 -REACTIVE HYPERPLASIA

LIVER .....  
 -COMPOUND RELATED INFLAMMATORY REACTION  
 -BILE DUCTULE EPITHELIAL HYPERPLASIA AND/OR CHOLANGIOFIBROSIS  
 -CYSTIC DEGENERATION  
 -N- LARGE GRANULAR LYMPHOCYTE LEUKEMIA, METASTATIC

KIDNEY .....  
 -PROGRESSIVE RENAL DISEASE  
 NOT SPECIFIED(MODERATE)

PROSTATE .....  
 -CHRONIC PROSTATITIS  
 -BENIGN HYPERPLASIA  
 NOT SPECIFIED(MODERATE)  
 NOT SPECIFIED(TRACE)

SEMINAL VESICLE .....  
 -GENERALIZED ATROPHY  
 NOT SPECIFIED (PRESENT)

TESTES .....  
 -B- INTERSTITIAL CELL ADENOMA  
 (PRESENT)

PANCREAS .....  
 -ACINAR (EXOCRINE) ATROPHY  
 -N- LARGE GRANULAR LYMPHOCYTE LEUKEMIA, METASTATIC  
 NOT SPECIFIED(MARKED)  
 (PRESENT)

STOMACH .....

**Appendix J (cont.): PATHOLOGY INDIVIDUAL ANIMAL DATA**

LETTERMAN ARMY INSTITUTE OF RESEARCH  
 DIV OF RES SUPP, PATH SERV GP  
 SPECIES: RAT/FISCHER-344  
 STUDY START DATE: 23-JAN-84  
 STUDY NUMBER: GLP83009  
 PRINTED: 21-NOV-89  
 PAGE: 223  
 STUDY TYPE: CHRONIC/2 YR CARCINOGENIC

ANIMAL NUMBER: 104/PRETEST-104  
 DATE OF DEATH: 30-JAN-86  
 SEX: MALE  
 DOSE GROUP: 2  
 SACRIFICE STATUS: FINAL SACRIFICE  
 STUDY WEEK OF DEATH: 106  
 TERMINAL BODY WEIGHT: 352.00 (GMS)

TISSUE / HISTOPATHOLOGIC FINDINGS  
 << P I C R O S C O P I C T I S S U E O B S E R V A T I O N S >>  
 DISTRIBUTION (SEVERITY) / ECIAL COMMENTS

- STOMACH ..... NOT SPECIFIED (PRESENT)
  - MUCOSAL AND/OR SUBMUCOSAL EDEMA
  - MAMMARY GLANDS .....
  - HYPERPLASIA AND/OR HYPERTROPHY OF THE ACINAR TISSUE
  - GALACTOCELE(S)
  - DILATATION (ECTASIA) OF DUCTS AND DUCTULES
  - NOSE/TURBINATES .....
  - MIXED INFLAMMATORY CELL INFILTRATION, NASAL CAVITY, SINUSES, TURBINATES, NASO-LACRIMAL DUCTS
  - ADRENAL .....
  - FOCUS OF CELLULAR ALTERATION, VACUOLATED
  - M- LARGE GRANULE LYMPHOCYTE LEUKEMIA, METASTATIC
  - PITUITARY GLAND .....
  - B- ADENOMA (PRESENT)
  - EYES & OPTIC N. ....
  - METAPLASTIC BONE FORMATION AND/CX MINERALIZATION, SCLERA
  - WHOLE BODY .....
  - M- LARGE GRANULAR LYMPHOCYTTIC LEUKEMIA (PRESENT)
- THE CELLULAR INFILTRATE INVOLVES THE VENTRO-LATERAL ASPECT OF OF THE NASAL CAVITY.  
 NOT SPECIFIED (MILD)  
 NOT SPECIFIED (PRESENT)  
 NOT SPECIFIED (PRESENT)  
 NOT SPECIFIED (PRESENT)  
 NOT SPECIFIED (TRACE)  
 NOT SPECIFIED (PRESENT)  
 NOT SPECIFIED (PRESENT)



Appendix J (cont.): PATHOLOGY INDIVIDUAL ANIMAL DATA

LETTERMAN ARMY INSTITUTE OF RESEARCH  
 DIV OF RES SUPP, PATH SERV GP  
 SPECIES: RAT/FISCHER-344  
 PRINTED: 21-NOV-89  
 PAGE: 224

INDIVIDUAL ANIMAL DATA REPORT  
 STUDY NUMBER: GLP83009  
 STUDY START DATE: 23-JAN-84  
 STUDY TYPE: CHRONIC/2 YR CARCINOGENIC

ANIMAL NUMBER: 105/PRETEST#  
 DATE OF DEATH: 30-JAN-86  
 SEX: MALE  
 DOSE GROUP: 2  
 SACRIFICE STATUS: FINAL SACRIFICE  
 STUDY WEEK OF DEATH: 739  
 TERMINAL BODY WEIGHT: 326.00 (GMS)

<< GROSS ORGAN OBSERVATIONS >>  
 SEVERITY GROSS FREE-TEXT COMMENTS  
 PRESENT DIAPHRAGM  
 PRESENT BILATERAL, MULTIPLE VARIABLY SIZED, YELLOW/BLACK

ADHESION(S)  
 GROWTH(S) / MASS(ES)

<< MICROSCOPIC TISSUE OBSERVATIONS >>  
 DISTRIBUTION (SEVERITY) / SPECIAL COMMENTS

PARATHYROID ..... TISSUE IS MISSING

HEART ..... NOT SPECIFIED(TRACE)  
 -CARDIOMYOPATHY

SPLEEN ..... FOCAL(TRACE)  
 -FIBROSIS CAPSULAR

LYMPH NODES ..... REACTIVE HYPERPLASIA NOTED IN ONE OF THE CERVICAL NODES.  
 -REACTIVE HYPERPLASIA NOT SPECIFIED (PRESENT)

LIVER ..... NOT SPECIFIED (PRESENT)  
 -COMPOUND RELATED INFLAMMATORY REACTION NOT SPECIFIED(MODERATE)  
 -BILE DUCTULE EPITHELIAL HYPERPLASIA AND/OR CHOLANGIOFIBROSIS NOT SPECIFIED(TRACE)  
 -FOCUS OF CELLULAR ALTERATION - BASOPHILIC NOT SPECIFIED (PRESENT)  
 -CYSTIC DEGENERATION

KIDNEY ..... NOT SPECIFIED(MODERATE)  
 -PROGRESSIVE RENAL DISEASE

PROSTATE ..... NOT SPECIFIED(TRACE)  
 -BENIGN HYPERPLASIA

SEMINAL VESTICLE ..... NOT SPECIFIED (PRESENT)  
 -GENERALIZED ATROPHY

TESTES .....

Appendix J (cont.): PATHOLOGY INDIVIDUAL ANIMAL DATA

LETTERMAN ARMY INSTITUTE OF RESEARCH  
DIV OF RES SUPP, PATH SERV GP  
SPECIES: RAT/FISCHER-344

INDIVIDUAL ANIMAL DATA REPORT  
STUDY NUMBER: GLP83009

PRINTED: 21-NOV-89  
PAGE: 225

STUDY START DATE: 23-JAN-84

STUDY TYPE: CHRONIC/2 YR CARCINOGENIC

ANIMAL NUMBER: 105/PRETEST-105 SEX: MALE DOSE GROUP: 2  
DATE OF DEATH: 30-JAN-86 STUDY DAY OF DEATH: 739 STUDY WEEK OF DEATH: 106

SACRIFICE STATUS: FINAL SACRIFICE  
TERMINAL BODY WEIGHT: 326.00 (GMS)

<< MICROSCOPIC TISSUE OBSERVATIONS >>

TISSUE / HISTOPATHOLOGIC FINDINGS  
DISTRIBUTION (SEVERITY) / SPECIAL COMMENTS

TESTES ..... (PRESENT)

COLON ..... TISSUE IS MISSING

STOMACH ..... NOT SPECIFIED (PRESENT)

MAMMARY GLANDS ..... NOT SPECIFIED(MILD)

NOSE/TURBINATES ..... CELLULAR INFILTRATE IS ADJACENT TO NASO-LACRIMAL DUCT.  
-MIXED INFLAMMATORY CELL INFILTRATION, NASAL CAVITY, SINUSES,  
TURBINATES, NASO-LACRIMAL DUCTS NOT SPECIFIED(MILD)

PITUITARY GLAND ..... (PRESENT)

EYES & OPTIC N. .... NOT SPECIFIED (PRESENT)

DIAPHRAGM ..... MISCELLANEOUS TISSUE  
-COMPOUND RELATED INFLAMMATORY REACTION NOT SPECIFIED (PRESENT)

..... NOT SPECIFIED (PRESENT)

..... NOT SPECIFIED (PRESENT)

..... MISCELLANEOUS TISSUE

..... NOT SPECIFIED (PRESENT)

Appendix J (cont.): PATHOLOGY INDIVIDUAL ANIMAL DATA

LETTERMAN ARMY INSTITUTE OF RESEARCH  
 DIV OF RES SUPP, PATH SERV GP  
 SPECIES: RAT/FISCHER-344

INDIVIDUAL ANIMAL DATA REPORT  
 STUDY NUMBER: GLP83009  
 STUDY START DATE: 23-JAN-84

PRINTED: 21-NOV-89  
 PAGE: 226  
 STUDY TYPE: CHRONIC/2 YR CARCINOGENIC

ANIMAL NUMBER: 106/PRETEST-106  
 DOSE GROUP: 2  
 SACRIFICE STATUS: FINAL SACRIFICE  
 DATE OF DEATH: 30-JAN-86  
 STUDY DAY OF DEATH: 739  
 STUDY WEEK OF DEATH: 106  
 TERMINAL BODY WEIGHT: 379.00 (GMS)

ORGAN NAME << GROSS ORGAN OBSERVATIONS >>  
 KEYWORDS / PHRASES SEVERITY GROSS FREE-TEXT COMMENTS

LIVER ADHESION(S) PRESENT VENTRAL ABDOMINAL WALL AND DIAPHRAGM  
 LIVER MODULE(S) PRESENT FOCAL  
 TESTES GROWTH(S) / MASS(ES) PRESENT BILATERAL, MULTIPLE VARIABLY SIZED, YELLOW/WHITE

TISSUE / HISTOPATHOLOGIC FINDINGS << MICROSCOPIC TISSUE OBSERVATIONS >>  
 DISTRIBUTION (SEVERITY) / SPECIAL COMMENTS

- HEART ..... NOT SPECIFIED(M:LD)
- CARDIOMYOPATHY
- LUNGS ..... NOT SPECIFIED(TRACE)
- MINERALIZATION OF PULMONARY ARTERIES
- LIVER ..... NOT SPECIFIED (PRESENT)
- COMPOUND RELATED INFLAMMATORY REACTION NOT SPECIFIED(MODERATE)
- BILE DUCTULE EPITHELIAL HYPERPLASIA AND/OR CHOLANGIOFIBROSIS MULTI-FOCAL(TRACE)
- HEPATOCTYIC VACUOLIZATION NOT SPECIFIED (PRESENT)
- CYSTIC DEGENERATION MULTI-FOCAL(TRACE)
- HEPATOCTYCE COALESCING MICROVESICULAR (FATTY) CHANGE LEADING TO NECROSIS AND MINERALIZATION
- KIDNEY ..... NOT SPECIFIED(MODERATE)
- PROGRESSIVE RENAL DISEASE
- PROSTATE ..... FOCAL(TRACE)
- CHRONIC PROSTATITIS
- TESTES ..... (PRESENT)
- B- INTERSTITIAL CELL ADENOMA

Appendix J (cont.): PATHOLOGY INDIVIDUAL ANIMAL DATA

LETTERMAN ARMY INSTITUTE OF RESEARCH  
DIV OF RES SUPP. PATH SERV GP  
SPECIES: RAT/FISCHER-344

INDIVIDUAL ANIMAL DATA REPORT  
STUDY NUMBER: GLP83009  
STUDY START DATE: 23-JAN-84

PRINTED: 21-NOV-89  
PAGE: 227

STUDY TYPE: CHRONIC/2 YR CARCINOGENIC

ANIMAL NUMBER: 106/PRETEST= 106 SEX: MALE DOSE GROUP: 2 SACRIFICE STATUS: FINAL SACRIFICE  
DATE OF DEATH: 30-JAN-86 STUDY DAY OF DEATH: 739 STUDY WEEK OF DEATH: 106 TERMINAL BODY WEIGHT: 379.00 (GMS)

TISSUE / HISTOPATHOLOGIC FINDINGS << MICROSCOPIC TISSUE OBSERVATIONS >>  
DISTRIBUTION (SEVERITY) / SPECIAL COMMENTS

SKIN ..... TISSUE IS MISSING

MAMMARY GLANDS ..... TISSUE IS MISSING

ADRENAL ..... (PRESENT)  
-B- PHEOCHROMOCYTOMA

PITUITARY GLAND ..... (PRESENT)  
-B- ADENOMA

EYES & OPTIC N. .... NOT SPECIFIED (PRESENT)  
-METAPLASTIC BONE FORMATION AND/OR MINERALIZATION, SCLERA

Appendix J (cont.): PATHOLOGY INDIVIDUAL ANIMAL DATA

LETTERMAN ARMY INSTITUTE OF RESEARCH DIV OF RES SUPP, PATH SERV GP SPECIES: RAT/FISCHER-364 ANIMAL NUMBER: 108/PRETEST= 108 SEX: MALE STUDY DAY OF DEATH: 739 STUDY START DATE: 23-JAN-84 DOSE GROUP: 2 SACRIFICE STATUS: FINAL SACRIFICE DATE OF DEATH: 30-JAN-86 STUDY DAY OF DEATH: 739 STUDY WEEK OF DEATH: 106 TERMINAL BODY WEIGHT: 366.00 (GMS) PRINTED: 21-NOV-89 PAGE: 229 STUDY TYPE: CHRONIC/2 YR CARCINOGENIC

ORGAN NAME << GROSS ORGAN OBSERVATIONS >> SEVERITY GROSS FREE-TEXT COMMENTS LIVER GRANULAR SURFACE PRESENT LIVER PROMINENT LOBULAR MARKINGS PRESENT LIVER ADHESION(S) PRESENT TESTES GROWTH(S) / MASS(ES) PRESENT VENTRAL ABDOMINAL WALL BILATERL, MULTIPLE VARIABLY SIZED, YELLOW/BLACK

TISSUE / HISTOPATHOLOGIC FINDINGS << MICROSCOPIC TISSUE OBSERVATIONS >> DISTRIBUTION (SEVERITY) / SPECIAL COMMENTS

- THYROID GLANDS (PRESENT)
-B- PARA-FOLLICULAR CELL ADENOMA
HEART
-CARDIOMYOPATHY
-MEDIAL HYPERTROPHY OF MUSCULAR ARTERIES
NOT SPECIFIED(TRACE)
NOT SPECIFIED(TRACE)
LUNGS
-MINERALIZATION OF PULMONARY ARTERIES
NOT SPECIFIED(TRACE)
LYMPH NODES
-RED BLOOD CELLS, HEMOSIDERIN AND/OR ERYTHROPHAGOCYTOSIS WITHIN MEDULLARY SINUSES
-REACTIVE HYPERPLASIA
REACTIVE HYPERPLASIA NOTED IN CERVICAL NODES.
PIGMENT PRESENT IN MEDIASTINAL NODES.
NOT SPECIFIED (PRESENT)
NOT SPECIFIED (PRESENT)
LIVER
-COMPOUND RELATED INFLAMMATORY REACTION
-BILE DUCTULE EPITHELIAL HYPERPLASIA AND/OR CHOLANGIOFIBROSIS
-HEPATITIS
-FOCUS OF CELLULAR ALTERATION - BASOPHILIC
-HEPATOCTYIC DEGENERATIVE CHANGES (NON-NECROTIC)
-HEPATOCTYIC COALESCING MICROVESICULAR (FATTY) CHANGE LEADING TO NECROSIS AND MINERALIZATION
KIDNEY

**Appendix J (cont.): PATHOLOGY INDIVIDUAL ANIMAL DATA**

LETTERMAN ARMY INSTITUTE OF RESEARCH  
 DIV OF RES SUPP, PATH SERV GP  
 SPECIES: RAT/FISCHER-344  
 ANIMAL NUMBER: 108/PRETEST=  
 DATE OF DEATH: 30-JAN-86  
 STUDY START DATE: 23-JAN-84  
 STUDY NUMBER: GLP83009  
 STUDY TYPE: CHRONIC/2 YR CARCINOGENIC  
 108 SEX: MALE DOSE GROUP: 2 SACRIFICE STATUS: FINAL SACRIFICE  
 STUDY DAY OF DEATH: 739 STUDY WEEK OF DEATH: 106 TERMINAL BODY WEIGHT: 366.00 (GMS)

PRINTED: 21-NOV-89  
 PAGE: 230  
 << MICROSCOPIC TISSUE OBSERVATIONS >>  
 DISTRIBUTION (SEVERITY) / SPECIAL COMMENTS

- KIDNEY ..... NOT SPECIFIED(MODERATE)
- PROGRESSIVE RENAL DISEASE
- PROSTATE ..... NOT SPECIFIED(MILD)
- BENIGN HYPERPLASIA
- SEMINAL VESICLE ..... NOT SPECIFIED (PRESENT)
- GENERALIZED ATROPHY
- TESTES ..... (PRESENT)
- B- INTERSTITIAL CELL ADENOMA
- PANCREAS ..... NOT SPECIFIED(TRACE)
- ACINAR (EXOCRINE) ATROPHY
- PITUITARY GLAND ..... NOT SPECIFIED (PRESENT)
- CYST(S)

Appendix J (cont.): PATHOLOGY INDIVIDUAL ANIMAL DATA

LETTERMAN ARMY INSTITUTE OF RESEARCH  
 DIV OF RES SUPP, PATH SERV GP  
 SPECIES: RAT/FISCHER-344  
 STUDY START DATE: 23-JAN-84  
 STUDY TYPE: CHRONIC/2 YR CARCINOGENIC  
 PRINTED: 21-NOV-89  
 PAGE: 231  
 ANIMAL NUMBER: 109/PRETEST= 109 SEX: MALE DOSE GROUP: 2 SACRIFICE STATUS: FINAL SACRIFICE  
 DATE OF DEATH: 03-FEB-86 STUDY DAY OF DEATH: 743 STUDY WEEK OF DEATH: 107 TERMINAL BODY WEIGHT: 374.00 (GMS)

<< GROSS ORGAN OBSERVATIONS >>  
 SEVERITY GROSS FREE-TEXT COMMENTS

ORGAN NAME  
 LIVER PRESENT VENTRAL ABDOMINAL WALL  
 KIDNEY TRACE  
 TESTES PRESENT LEFT, 3.5 X 2CM  
 TESTES PRESENT BILATERAL, MULTIPLE VARIABLY SIZED, YELLOW/BLACK

<< MICROSCOPIC TISSUE OBSERVATIONS >>  
 DISTRIBUTION (SEVERITY) / SPECIAL COMMENTS

TISSUE / HISTOPATHOLOGIC FINDINGS  
 PARATHYROID ..... TISSUE IS MISSING

HEART ..... NOT SPECIFIED (TRACE)  
 -CARDIOMYOPATHY

LUNGS ..... NOT SPECIFIED (TRACE)  
 -MINERALIZATION OF PULMONARY ARTERIES

LYMPH NODES ..... RBC'S, PIGMENT AND REACTIVE HYPERPLASIA NOTED IN CERVICAL NODES.  
 -RED BLOOD CELLS, HEMOSIDERIN AND/OR ERYTHROPHAGOCYTOSIS WITHIN  
 MEDULLARY SINUSES NOT SPECIFIED (PRESENT)  
 -REACTIVE HYPERPLASIA NOT SPECIFIED (PRESENT)

LIVER ..... NOT SPECIFIED (PRESENT)  
 -COMPOUND RELATED INFLAMMATORY REACTION  
 -BILE DUCTULE EPITHELIAL HYPERPLASIA AND/OR CHOLANGIOFIBROSIS NOT SPECIFIED (MILD)  
 -CYSTIC DEGENERATION NOT SPECIFIED (PRESENT)

KIDNEY ..... NOT SPECIFIED (MODERATE)  
 -PROGRESSIVE RENAL DISEASE

PROSTATE ..... NOT SPECIFIED (TRACE)  
 -BENIGN HYPERPLASIA

SEMINAL VESICLE .....

Appendix J (cont.): PATHOLOGY INDIVIDUAL ANIMAL DATA

LETTERMAN ARMY INSTITUTE OF RESEARCH  
 DIV OF RES SUPP, PATH SERV GP  
 SPECIES: RAT/FISCHER-344  
 STUDY START DATE: 23-JAN-84  
 STUDY NUMBER: GLP83009  
 PRINTED: 21-NOV-89  
 PAGE: 232

ANIMAL NUMBER: 109/PRETEST-  
 DATE OF DEATH: 03-FEB-86  
 STUDY DAY OF DEATH: 743  
 SEX: MALE  
 DOSE GROUP: 2  
 SACRIFICE STATUS: FINAL SACRIFICE  
 STUDY WEEK OF DEATH: 107  
 TERMINAL BODY WEIGHT: 374.00 (GMS)

STUDY TYPE: CHRONIC/2 YR CARCINOGENIC

TISSUE / HISTOPATHOLOGIC FINDINGS  
 << M I C R O S C O P I C T I S S U E O B S E R V A T I O N S >>  
 DISTRIBUTION (SEVERITY) / SPECIAL COMMENTS

SEMINAL VESICLE ..... NOT SPECIFIED (PRESENT)  
 -GENERALIZED ATROPHY

TESTES ..... (PRESENT)  
 -B- INTERSTITIAL CELL ADENOMA

PANCREAS ..... NOT SPECIFIED (TRACE)  
 -ACINAR (EXOCRINE) ATROPHY

ADRENAL ..... NOT SPECIFIED (PRESENT)  
 -CORTICAL NODULAR HYPERPLASIA

EYES & OPTIC N. .... NOT SPECIFIED (PRESENT)  
 -METAPLASTIC BONE FORMATION AND/OR MINERALIZATION, SCLERA



Appendix J (cont.): PATHOLOGY INDIVIDUAL ANIMAL DATA

LETTERMAN ARMY INSTITUTE OF RESEARCH DIV OF RES SUPP, PATH SERV GP SPECIES: RAT/FISCHER-344 STUDY START DATE: 23-JAN-84 STUDY NUMBER: GLP83009 PRINTED: 21-NOV-89 PAGE: 233

ANIMAL NUMBER: 110/PRETEST= 110 SEX: MALE DOSE GROUP: 2 SACRIFICE STATUS: FINAL SACRIFICE DATE OF DEATH: 03-FEB-86 STUDY DAY OF DEATH: 743 STUDY WEEK OF DEATH: 107 TERMINAL BODY WEIGHT: 392.00 (GMS) STUDY TYPE: CHRONIC/2 YR CARCINOGENIC

ORGAN NAME << GROSS ORGAN OBSERVATIONS >> SEVERITY GROSS FREE-TEXT COMMENTS SKIN PRESENT FIRM, WHITE, 4 X 5CM, RIGHT THORACIC WALL SPLEEN SUBCUTANEOUS MASS MODULE PRESENT MULTIPLE, WHITE, SUBCAPSULAR DISCOLORATION PRESENT LIGHT RED LIVER ADHESION(S) PRESENT DIAPHRAGM, VENTRAL ABDOMINAL WALL TESTES GROWTH(S) / MASS(ES) PRESENT BILATRAL, MULTIPLE VARIABLY SIZED, YELLOW

TISSUE / HISTOPATHOLOGIC FINDINGS << MICROSCOPIC TISSUE OBSERVATIONS >> DISTRIBUTION (SEVERITY) / SPECIAL COMMENTS

PARATHYROID TISSUE IS MISSING HEART NOT SPECIFIED(MILD) NOT SPECIFIED(TRACE) MEDIAL HYPERTROPHY OF MUSCULAR ARTERIES LUNGS NOT SPECIFIED(TRACE) MINERALIZATION OF PULMONARY ARTERIES SPLEEN MULTI-FOCAL(MODERATE) INFARCTION, CHRONIC LYMPH NODES REACTIVE HYPERPLASIA NOTED IN CERVICAL NODES. REACTIVE HYPERPLASIA (PRESENT) NOT SPECIFIED (TRACE) LIVER NOT SPECIFIED (PRESENT) COMPOUND RELATED INFLAMMATORY REACTION NOT SPECIFIED(MILD) MULTI-FOCAL(TRACE) BILE DUCTULE EPITHELIAL HYPERPLASIA AND/OR CHOLANGIOFIBROSIS HEPATITIS MULTI-FOCAL(MILD) BENIGN HYPERPLASTIC MODULE(S) FIBROSIS, PARENCHYMAL (SCARRING) FOCAL(TRACE) KIDNEY

Appendix J (cont.): PATHOLOGY INDIVIDUAL ANIMAL DATA

LETTERMAN ARMY INSTITUTE OF RESEARCH  
DIV OF RES SUPP, PATH SERV GP  
SPECIES: RAT/FISCHER-344

INDIVIDUAL ANIMAL DATA REPORT  
STUDY NUMBER: GLP83009  
STUDY START DATE: 23-JAN-84

PRINTED: 21-NOV-89  
PAGE: 234

STUDY TYPE: CHRONIC/2 YR CARCINOGENIC

ANIMAL NUMBER: 110/PRETEST-110 SEX: MALE DOSE GROUP: 2 SACRIFICE STATUS: FINAL SACRIFICE  
DATE OF DEATH: 03-FEB-86 STUDY DAY OF DEATH: 743 STUDY WEEK OF DEATH: 107 TERMINAL BODY WEIGHT: 392.00 (GMS)

TISSUE / HISTOPATHOLOGIC FINDINGS << MICROSCOPIC TISSUE OBSERVATIONS >>  
DISTRIBUTION (SEVERITY) / SPECIAL COMMENTS

KIDNEY ..... NOT SPECIFIED(MODERATE)  
-PROGRESSIVE RENAL DISEASE

PROSTATE ..... NOT SPECIFIED(TRACE)  
-CHRONIC PROSTATITIS  
-BENIGN HYPERPLASIA

SEMINAL VESICLE ..... NOT SPECIFIED (PRESENT)  
-GENERALIZED ATROPHY

TESTES ..... (PRESENT)  
-B- INTERSTITIAL CELL ADENOMA

SKIN ..... THE SUBCUTANEOUS MASS IN THE RIGHT THORACIC WALL IS A FIBROMA.  
-B- FIBROMA (PRESENT)

MAMMARY GLANDS ..... NOT SPECIFIED(TRACE)  
-HYPERPLASIA AND/OR HYPERTROPHY OF THE ACINAR TISSUE

PITUITARY GLAND ..... (PRESENT)  
-B- ADENOMA FOCAL (PRESENT)  
-CYST(S)

EYES & OPTIC N. .... NOT SPECIFIED (PRESENT)  
-METAPLASTIC BONE FORMATION AND/OR MINERALIZATION, SCLERA

THORAX ..... MISCELLANEOUS TISSUE  
THE MASS ON THE RIGHT THORACIC WALL IS A FIBROMA. IT WAS CODED  
UNDER SKIN.

Appendix J (cont.): PATHOLOGY INDIVIDUAL ANIMAL DATA

LETTERMAN ARMY INSTITUTE OF RESEARCH
INDIVIDUAL ANIMAL DATA REPORT
DIV OF RES SUPP, PATH SERV GP
SPECIES: RAT/FISCHER-344
STUDY NUMBER: GLP83009
STUDY START DATE: 23-JAN-84
STUDY TYPE: CHRONIC/2 YR CARCINOGENIC
ANIMAL NUMBER: 111/PRETEST-
DOSE GROUP: 2
SACRIFICE STATUS: FINAL SACRIFICE
DATE OF DEATH: 03-FEB-86
STUDY DAY OF DEATH: 743
STUDY WEEK OF DEATH: 107
TERMINAL BODY WEIGHT: 382.00 (GMS)

<< GROSS ORGAN OBSERVATIONS >>
KEYWORDS / PHRASES SEVERITY GROSS FREE-TEXT COMMENTS
ADHESION(S) PRESENT DIAPHRAGM
GRANULAR SURFACE TRACE
GROWTH(S) / MASS(ES) PRESENT BILATERAL, MULTIPLE VARIABLY SIZED, YELLOW

<< MICROSCOPIC TISSUE OBSERVATIONS >>
DISTRIBUTION (SEVERITY) / SPECIAL COMMENTS

HEART
-CARDIOMYOPATHY NOT SPECIFIED(MILD)
-MEDIAL HYPERTROPHY OF MUSCULAR ARTERIES NOT SPECIFIED(MILD)

LUNGS
-MINERALIZATION OF PULMONARY ARTERIES NOT SPECIFIED(TRACE)
-PNEUMONIA, INTERSTITIAL, CHRONIC FOCAL(MILD)

THYRUS
THIS UNUSUAL LESION CONSISTS PRIMARILY OF PROLIFERATING EPITHELIAL CELLS AND VERY FEW LYMPHOCYTES. MOST OF THE EPITHELIAL CELLS ARE ARRANGED IN SMALL NESTS OR CORDS WITH SOME PAPILLARY FORMS. THE LESION IS WELL-DEMARCATED FROM ADJACENT FAT BUT IS NOT ENCAPSULATED. CELLS HAVE LARGE ROUND TO OVAL VESICULAR NUCLEI AND ABUNDANT EOSINOPHILIC CYTOPLASM WITH INDISTINCT PLASMA MEMBRANES. MITOTIC FIGURES ARE RARE. SCATTERED THROUGHOUT ARE A FEW SPACES FILLED WITH EOSINOPHILIC MATERIAL CONTAINING A FEW DEGENERATING EPITHELIAL AND INFLAMMATORY CELLS. (PRESENT)

-M- ADENOCARCINOMA, NOT OTHERWISE SPECIFIED, SITE OF ORIGIN UNDETERMINED

LIVER
-COMPOUND RELATED INFLAMMATORY REACTION NOT SPECIFIED (PRESENT)
-BILE DUCTULE EPITHELIAL HYPERPLASIA AND/OR CHOLANGIOFIBROSIS NOT SPECIFIED(MILD)
-HEPATITIS MULTI-FOCAL(TRACE)

Appendix J (cont.): PATHOLOGY INDIVIDUAL ANIMAL DATA

LETTERMAN ARMY INSTITUTE OF RESEARCH  
DIV OF RES SUPP, PATH SERV GP  
SPECIES: RAT/FISCHER-344

INDIVIDUAL ANIMAL DATA REPORT  
STUDY NUMBER: GLP83009  
STUDY START DATE: 23-JAN-84

PRINTED: 21-NOV-89  
PAGE: 236

STUDY TYPE: CHRONIC/2 YR CARCINOGENIC

ANIMAL NUMBER: 111/PRETEST# 111 SEX: MALE DOSE GROUP: 2 SACRIFICE STATUS: FINAL SACRIFICE  
DATE OF DEATH: 03-FEB-86 STUDY DAY OF DEATH: 743 STUDY WEEK OF DEATH: 107 TERMINAL BODY WEIGHT: 382.00 (GMS)

TISSUE / HISTOPATHOLOGIC FINDINGS << MICROSCOPIC TISSUE OBSERVATIONS >>  
DISTRIBUTION (SEVERITY) / SPECIAL COMMENTS

LIVER .....  
-FOCUS OF CELLULAR ALTERATION - BASOPHILIC ..... MULTI-FOCAL(TRACE)  
-BENIGN HYPERPLASTIC NODULE(S) ..... MULTI-FOCAL(TRACE)  
-FOCUS OF CELLULAR ALTERATION - EOSINOPHILIC CELLS ..... MULTI-FOCAL(TRACE)

KIDNEY .....  
-PROGRESSIVE RENAL DISEASE ..... NOT SPECIFIED(MILD)

PROSTATE .....  
-CHRONIC PROSTATITIS ..... NOT SPECIFIED(MILD)  
-BENIGN HYPERPLASIA ..... NOT SPECIFIED(TRACE)

SEMINAL VESICLE .....  
-GENERALIZED ATROPHY ..... NOT SPECIFIED (PRESENT)

TESTES .....  
-B- INTERSTITIAL CELL ADENOMA ..... (PRESENT)

PANCREAS .....  
-ACINAR (EXOCRINE) ATROPHY ..... NOT SPECIFIED(TRACE)

DIAPHRAGM .....  
-COMPOUND RELATED INFLAMMATORY REACTION ..... MISCELLANEOUS TISSUE  
NOT SPECIFIED (PRESENT)

**Appendix J (cont.): PATHOLOGY INDIVIDUAL ANIMAL DATA**

LETTERMAN ARMY INSTITUTE OF RESEARCH  
 DIV OF RES SUPP, PATH SERV GP  
 SPECIES: RAT/FISCHER-344

INDIVIDUAL ANIMAL DATA REPORT  
 STUDY NUMBER: GLP83009

PRINTED: 21-NOV-89  
 PAGE: 237

STUDY START DATE: 23-JAN-84

STUDY TYPE: CHRONIC/2 YR CARCINOGENIC

ANIMAL NUMBER: 112/PRETEST= 112 SEX: MALE DOSE GROUP: 2 SACRIFICE STATUS: FINAL SACRIFICE  
 DATE OF DEATH: 03-FEB-86 STUDY DAY OF DEATH: 743 STUDY WEEK OF DEATH: 107 TERMINAL BODY WEIGHT: 380.00 (GMS)

<< GROSS ORGAN OBSERVATIONS >>  
 SEVERITY GROSS FREE-TEXT COMMENTS  
 -----  
 ORGAN NAME  
 -----  
 EYES & OPTIC N. MICROPTHALMIA PRESENT LEFT  
 EYES & OPTIC N. LENS CATARACT PRESENT BILATERAL  
 TESTES ENLARGED PRESENT 2.5 X 1.5CM, BILATERAL  
 TESTES GROWTH(S) / MASS(ES) PRESENT BILATERAL, MULTIPLE VARIABLY SIZED, YELLOW  
 LIVER ADHESION(S) PRESENT DIAPHRAGM, VENTRAL ABDOMINAL WALL

<< MICROSCOPIC TISSUE OBSERVATIONS >>  
 DISTRIBUTION (SEVERITY) / SPECIAL COMMENTS  
 -----

THYROID GLANDS  
 -8- PARA-FOLLICULAR CELL ADENOMA (PRESENT)

HEART  
 -CARDIOMYOPATHY NOT SPECIFIED(MODERATE)

LUNGS  
 -MINERALIZATION OF PULMONARY ARTERIES NOT SPECIFIED(TRACE)

LYMPH NODES  
 -REACTIVE HYPERPLASIA REACTIVE HYPERPLASIA NOTED IN CERVICAL AND MESENTERIC NODES.  
 -DILATED AND/OR CYSTIC MEDULLARY SINUSES SOME OF THE SINUSES IN THE MESENTERIC NODES ARE GREATLY DILATED.  
 NOT SPECIFIED (PRESENT)  
 NOT SPECIFIED (PRESENT)

LIVER  
 -COMPOUND RELATED INFLAMMATORY REACTION NOT SPECIFIED (PRESENT)  
 -BILE DUCTULE EPITHELIAL HYPERPLASIA AND/OR CHOLANGIOFIBROSIS NOT SPECIFIED(MODERATE)  
 -HEPATITIS NOT SPECIFIED(MILD)

KIDNEY  
 -PROGRESSIVE RENAL DISEASE NOT SPECIFIED(MODERATE)

PROSTATE

**Appendix J (cont.): PATHOLOGY INDIVIDUAL ANIMAL DATA**

LETTERMAN ARMY INSTITUTE OF RESEARCH  
 DIV OF RES SUPP, PATH SERV GP  
 SPECIES: RAT/FISCHER-344

INDIVIDUAL ANIMAL DATA REPORT  
 STUDY NUMBER: GLP83009

PRINTED: 21-NOV-89  
 PAGE: 238

STUDY START DATE: 23-JAN-84      STUDY TYPE: CHRONIC/2 YR CARCINOGENIC  
 ANIMAL NUMBER: 112/PRETEST      DOSE GROUP: 2      SACRIFICE STATUS: FINAL SACRIFICE  
 DATE OF DEATH: 03-FEB-86      STUDY DAY OF DEATH: 743      STUDY WEEK OF DEATH: 107      TERMINAL BODY WEIGHT: 380.00 (GMS)

TISSUE / HISTOPATHOLOGIC FINDINGS      <<      M I C R O S C O P I C      T I S S U E      O B S E R V A T I O N S      >>  
 DISTRIBUTION (SEVERITY) / SPECIAL COMMENTS

- PROSTATE ..... NOT SPECIFIED(MILD)  
 -CHRONIC PROSTATITIS ..... NOT SPECIFIED(TRACE)  
 -BENIGN HYPERPLASIA
- SEMINAL VESICLE ..... NOT SPECIFIED (PRESENT)  
 -GENERALIZED ATROPHY
- TESTES ..... (PRESENT)  
 -B- INTERSTITIAL CELL ADENOMA
- PANCREAS ..... NOT SPECIFIED(MILD)  
 -ACINAR (EXOCRINE) ATROPHY
- SKIN ..... TISSUE IS MISSING
- MAMMARY GLANDS ..... TISSUE IS MISSING
- NOSE/TURBINATES ..... CELLULAR INFILTRATE INVOLVES NASO-LACRIMAL DUCT.  
 -MIXED INFLAMMATORY CELL INFILTRATION, NASAL CAVITY, SINUSES, NOT SPECIFIED(MILD)  
 TURBINATES, NASO-LACRIMAL DUCTS
- ADRENAL ..... NOT SPECIFIED (PRESENT)  
 -CORTICAL NODULAR HYPERPLASIA
- PITUITARY GLAND ..... (PRESENT)  
 -B- ADENOMA
- EYES & OPTIC N. ..... NOT SPECIFIED(MODERATE)  
 -RETINAL ATROPHY AND/OR DEGENERATION, UNILATERAL OR BILATERAL NOT SPECIFIED (PRESENT)  
 -METAPLASTIC BONE FORMATION AND/OR MINERALIZATION, SCLERA NOT SPECIFIED (PRESENT)  
 -LENTICULAR DEGENERATIVE CHANGES COMPATIBLE WITH CATARACT
- DIAPHRAGM ..... MISCELLANEOUS TISSUE

Appendix J (cont.): PATHOLOGY INDIVIDUAL ANIMAL DATA

LETTERMAN ARMY INSTITUTE OF RESEARCH  
DIV OF RES SUPP, PATH SERV GP  
SPECIES: RAT/FISCHER-344

INDIVIDUAL ANIMAL DATA REPORT  
STUDY NUMBER: GLP83009  
STUDY START DATE: 23-JAN-84

PRINTED: 21-NOV-89  
PAGE: 239

STUDY TYPE: CHRONIC/2 YR CARCINOGENIC

ANIMAL NUMBER: 112/PRETEST#  
DATE OF DEATH: 03-FEB-86

112 SEX: MALE  
STUDY DAY OF DEATH: 743

DOSE GROUP: 2  
STUDY WEEK OF DEATH: 107

SACRIFICE STATUS: FINAL SACRIFICE  
TERMINAL BODY WEIGHT: 380.00 (GMS)

TISSUE / HISTOPATHOLOGIC FINDINGS

<< MICROSCOPIC TISSUE OBSERVATIONS >>  
DISTRIBUTION (SEVERITY) / SPECIAL COMMENTS

DIAPHRAGM ..... MISCELLANEOUS TISSUE  
-COMPOUND RELATED INFLAMMATORY REACTION NOT SPECIFIED (PRESENT)

**Appendix J (cont.): PATHOLOGY INDIVIDUAL ANIMAL DATA**

LETTERMAN ARMY INSTITUTE OF RESEARCH  
 DIV OF RES SUPP, PATH SERV GP  
 SPECIES: RAT/FISCHER-344

INDIVIDUAL ANIMAL DATA REPORT  
 STUDY NUMBER: GLP83009  
 STUDY START DATE: 23-JAN-84

PRINTED: 21-NOV-89  
 PAGE: 240

ANIMAL NUMBER: 113/PRETEST-      DOSE GROUP: 2      SACRIFICE STATUS: FINAL SACRIFICE  
 DATE OF DEATH: 03-FEB-86      STUDY DAY OF DEATH: 743      STUDY WEEK OF DEATH: 107      TERMINAL BODY WEIGHT: 386.00 (GMS)  
 STUDY TYPE: CHRONIC/2 YR CARCINOGENIC

<< GROSS ORGAN OBSERVATIONS >>  
 SEVERITY GROSS FREE-TEXT COMMENTS  
 PRESENT DIAPHRAGM, VENTRAL ABDOMINAL WALL  
 PRESENT BILATERAL, MULTIPLE VARIABLY SIZED, YELLOW

ADHESION(S)  
 GROWTH(S) / MASS(ES)  
 KEYWORDS / PHRASES  
 OBSERVATIONS >>  
 DISTRIBUTION (SEVERITY) / SPECIAL COMMENTS

TISSUE / HISTOPATHOLOGIC FINDINGS  
 THYROID GLANDS  
 -COLLOID CYST(S)

PARATHYROID  
 HEART  
 -CARDIOMYOPATHY

LUNGS  
 -MINERALIZATION OF PULMONARY ARTERIES

LYMPH NODES  
 -RED BLOOD CELLS, HEMOSIDERIN AND/OR ERYTHROPHAGOCYTOSIS WITHIN MEDULLARY SINUSES

LIVER  
 -COMPOUND RELATED INFLAMMATORY REACTION  
 -BILE DUCTULE EPITHELIAL HYPERPLASIA AND/OR CHOLANGIOFIBROSIS

-HEPATITIS  
 -CYSTIC DEGENERATION  
 -M- HEPATOCELLULAR CARCINOMA

KIDNEY  
 -PROGRESSIVE RENAL DISEASE

PROSTATE

NOT SPECIFIED (PRESENT)  
 TISSUE IS MISSING  
 NOT SPECIFIED(MILD)  
 NOT SPECIFIED(TRACE)  
 RBC'S AND PIGMENT NOTED IN MEDIASTINAL NODE.  
 NOT SPECIFIED (PRESENT)  
 NOT SPECIFIED(MILD)  
 MULTI-FOCAL(MILD)  
 NOT SPECIFIED (PRESENT)  
 (PRESENT)  
 NOT SPECIFIED(MODERATE)



Appendix J (cont.): PATHOLOGY INDIVIDUAL ANIMAL DATA

LETTERMAN ARMY INSTITUTE OF RESEARCH DIV OF RES SUPP, PATH SERV GP SPECIES: RAT/FISCHER-344 STUDY START DATE: 23-JAN-84 STUDY NUMBER: GLP83009

PRINTED: 21-NOV-89 PAGE: 241

STUDY TYPE: CHRONIC/2 YR CARCINOGENIC

ANIMAL NUMBER: 113/PRETEST= 113 SEX: MALE DOSE GROUP: 2 SACRIFICE STATUS: FINAL SACRIFICE DATE OF DEATH: 03-FEB-86 STUDY DAY OF DEATH: 743 STUDY WEEK OF DEATH: 107 TERMINAL BODY WEIGHT: 386.00 (GMS)

TISSUE / HISTOPATHOLOGIC FINDINGS << MICROSCOPIC TISSUE OBSERVATIONS >> DISTRIBUTION (SEVERITY) / SPECIAL COMMENTS

- PROSTATE ..... NOT SPECIFIED(MILD) NOT SPECIFIED(TRACE)
-CHRONIC PROSTATITIS
-BENIGN HYPERPLASIA
SEMINAL VESICLE ..... NOT SPECIFIED (PRESENT)
-GENERALIZED ATROPHY
TESTES ..... (PRESENT)
-B- INTERSTITIAL CELL ADENOMA
PANCREAS ..... FOCAL(MILD)
-ACINAR (EXOCRINE) ATROPHY
SKIN ..... TISSUE IS MISSING
MAMMARY GLANDS ..... TISSUE IS MISSING
PITUITARY GLAND ..... (PRESENT)
-B- ADENOMA
DIAPHRAGM ..... MISCELLANEOUS TISSUE
-COMPOUND RELATED INFLAMMATORY REACTION NOT SPECIFIED (PRESENT)

Appendix J (cont.): PATHOLOGY INDIVIDUAL ANIMAL DATA

LETTERMAN ARMY INSTITUTE OF RESEARCH  
DIV OF RES SUPP, PATH SERV GP  
SPECIES: RAT/FISCHER-344  
INDIVIDUAL ANIMAL DATA REPORT  
STUDY NUMBER: GLP83009  
STUDY START DATE: 23-JAN-84  
PRINTED: 21-NOV-89  
PAGE: 242  
STUDY TYPE: CHRONIC/2 YR CARCINOGENIC

ANIMAL NUMBER: 114/PRETEST-  
DATE OF DEATH: 03-FEB-86  
114 SEX: MALE  
DOSE GROUP: 2  
SACRIFICE STATUS: FINAL SACRIFICE  
STUDY DAY OF DEATH: 743  
STUDY WEEK OF DEATH: 107  
TERMINAL BODY WEIGHT: 354.00 (GMS)

<< GROSS ORGAN OBSERVATIONS >>  
SEVERITY GROSS FREE-TEXT COMMENTS  
KEYWORDS / PHRASES  
ENLARGED (SPLENOHEGALY) MARKED 7.5 X 2CM  
ADHESION(S) PRESENT VENTRAL ABDOMINAL WALL  
TESTES GROWTH(S) / MASS(ES) PRESENT BILATERAL, MULTIPLE VARIABLY SIZED, YELLOW/BLACK  
LIVER GROWTH(S) / MASS(ES) PRESENT TAN, .25CM DIAMETER

<< MICROSCOPIC TISSUE OBSERVATIONS >>  
DISTRIBUTION (SEVERITY) / SPECIAL COMMENTS

- HEART ..... NOT SPECIFIED(MILD)
- CARDIOMYOPATHY
- LUNGS ..... NOT SPECIFIED(TRACE)
- MINERALIZATION OF PULMONARY ARTERIES
- PNEUMONIA, INTERSTITIAL, CHRONIC
- N- LARGE GRANULAR LYMPHOCYTE LEUKEMIA, METASTATIC
- ALVEOLAR HEMORRHAGE
- SPLEEN ..... (PRESENT)
- N- LARGE GRANULAR LYMPHOCYTE LEUKEMIA, METASTATIC
- LYMPH NODES ..... (PRESENT)
- N- LARGE GRANULAR LYMPHOCYTE LEUKEMIA, METASTATIC
- LIVER ..... NOT SPECIFIED (PRESENT)
- COMPOUND RELATED INFLAMMATORY REACTION
- BILE DUCTULE EPITHELIAL HYPERPLASIA AND/OR CHOLANGIOFIBROSIS
- FOCUS OF CELLULAR ALTERATION - BASOPHILIC
- HEPATOCTYIC VACUOLIZATION
- NECROSIS
- CYSTIC DEGENERATION
- BENIGN HYPERPLASTIC NODULE(S)

Appendix J (cont.): PATHOLOGY INDIVIDUAL ANIMAL DATA

LETTERMAN ARMY INSTITUTE OF RESEARCH  
 DIV OF RES SUPP. PATH SERV GP  
 SPECIES: RAT/FISCHER-344  
 ANIMAL NUMBER: 114/PRETEST= 114 SEX: MALE DOSE GROUP: 2 SACRIFICE STATUS: FINAL SACRIFICE  
 DATE OF DEATH: 03-FEB-86 STUDY DAY OF DEATH: 743 STUDY WEEK OF DEATH: 107 TERMINAL BODY WEIGHT: 354.00 (GMS)  
 STUDY START DATE: 23-JAN-84 STUDY TYPE: CHRONIC/2 YR CARCINOGENIC  
 STUDY NUMBER: GLP83009  
 PRINTED: 21-NOV-89  
 PAGE: 243  
 << MICROSCOPIC TISSUE OBSERVATIONS >>  
 TISSUE / HISTOPATHOLOGIC FINDINGS DISTRIBUTION (SEVERITY) / SPECIAL COMMENTS

LIVER ..... (PRESENT)  
 -N- LARGE GRANULAR LYMPHOCYTE LEUKEMIA, METASTATIC  
 KIDNEY ..... NOT SPECIFIED(MILD)  
 -PROGRESSIVE RENAL DISEASE  
 PROSTATE ..... NOT SPECIFIED(MILD)  
 -BENIGN HYPERPLASIA  
 SEMINAL VESICLE ..... NOT SPECIFIED (PRESENT)  
 -GENERALIZED ATROPHY  
 TESTES ..... (PRESENT)  
 -B- INTERSTITIAL CELL ADENOMA  
 SKIN ..... TISSUE IS MISSING  
 MAMMARY GLANDS ..... TISSUE IS MISSING  
 NOSE/TURBINATES ..... CELLULAR INFILTRAT IS ADJACENT NASO-LACRIMAL DUCT.  
 -MIXED INFLAMMATORY CELL INFILTRATION, NASAL CAVITY, SINUSES, NOT SPECIFIED(MILD)  
 TURBINATES, NASO-LACRIMAL DUCTS  
 EYES & OPTIC N. .... NOT SPECIFIED(TRACE)  
 -CORNEAL MINERALIZATION NOT SPECIFIED (PRESENT)  
 -METAPLASTIC BONE FORMATION AND/OR MINERALIZATION, SCLERA  
 WHOLE BODY ..... (PRESENT)  
 -M- LARGE GRANULAR LYMPHOCYTIC LEUKEMIA

**Appendix J (cont.): PATHOLOGY INDIVIDUAL ANIMAL DATA**

LETTERMAN ARMY INSTITUTE OF RESEARCH  
 DIV OF RES SUPP, PATH SERV GP  
 SPECIES: RAT/FISCHER-344  
 STUDY START DATE: 23-JAN-84  
 STUDY NUMBER: GLP83009  
 PRINTED: 03-JAN-90  
 PAGE: 1  
 STUDY TYPE: CHRONIC/2 YR CARCINOGENIC

ANIMAL NUMBER: 115/PRETEST-  
 DATE OF DEATH: 18-NOV-85  
 DOSE GROUP: 2  
 STUDY WEEK OF DEATH: 96  
 SACRIFICE STATUS: FOUND DEAD  
 TERMINAL BODY WEIGHT: 301.00 (GMS)

<< GROSS ORGAN OBSERVATIONS >>  
 SEVERITY GROSS FREE-TEXT COMMENTS  
 PRESENT VENTRAL ABDOMINAL WALL  
 PRESENT SUBCUTANEOUS, LEFT NECK AND SHOULDER AREA.  
 PRESENT RED, ALSO AROUND NARES AND ON FOREFEET  
 MODERATE  
 PRESENT INTRA-ABDOMINAL, BILATERAL

ADHESION(S)  
 ABSCESS(ES)  
 EYES & OPTIC N.  
 WHOLE BODY  
 TESTES

KEYWORDS / PHRASES  
 ADHESION(S)  
 ABSCESS(ES)  
 EYES & OPTIC N.  
 WHOLE BODY  
 TESTES

<< MICROSCOPIC TISSUE OBSERVATIONS >>  
 DISTRIBUTION (SEVERITY) / SPECIAL COMMENTS

TISSUE / HISTOPATHOLOGIC FINDINGS

THYROID GLANDS ..... TISSUE IS AUTOLYTIC

HEART .....  
 -CARDIOMYOPATHY ..... NOT SPECIFIED(MILD)  
 -MEDIAL HYPERTROPHY OF MUSCULAR ARTERIES ..... NOT SPECIFIED(TRACE)

LUNGS .....  
 -MINERALIZATION OF PULMONARY ARTERIES ..... NOT SPECIFIED(MILD)

SPLEEN ..... TISSUE IS AUTOLYTIC

LYMPH NODES ..... RBC'S AND PIGMENT NOTED IN MEDIASTINAL NODES.  
 -RED BLOOD CELLS, HEMOSIDERIN AND/OR ERYTHROPHAGOCYTOSIS WITHIN ..... NOT SPECIFIED (PRESENT)  
 MEDULLARY SINUSES

LIVER .....  
 -COMPOUND RELATED INFLAMMATORY REACTION ..... NOT SPECIFIED (PRESENT)  
 -BILE DUCTULE EPITHELIAL HYPERPLASIA AND/OR CHOLANGIOFIBROSIS ..... NOT SPECIFIED(MODERATE)  
 -HEPATOCTYIC VACUOLIZATION ..... MULTI-FOCAL(TRACE)  
 -HEPATOCTYIC COALESCING MICROVESICULAR (FATTY) CHANGE LEADING TO ..... MULTI-FOCAL(TRACE)  
 NECROSIS AND MINERALIZATION

KIDNEY .....

**Appendix J (cont.): PATHOLOGY INDIVIDUAL ANIMAL DATA**

LETTERMAN ARMY INSTITUTE OF RESEARCH  
 DIV OF RES SUPP, PATH SERV GP  
 SPECIES: RAT/FISCHER-344

INDIVIDUAL ANIMAL DATA REPORT  
 STUDY NUMBER: GLP83009

PRINTED: 03-JAN-90  
 PAGE: 2

STUDY START DATE: 23-JAN-84

STUDY TYPE: CHRONIC/2 YR CARCINOGENIC

ANIMAL NUMBER: 115/PRETEST- 115 SEX: MALE DOSE GROUP: 2 SACRIFICE STATUS: FOUND DEAD  
 DATE OF DEATH: 18-NOV-85 STUDY DAY OF DEATH: 666 STUDY WEEK OF DEATH: 96 TERMINAL BODY WEIGHT: 301.00 (GMS)

TISSUE / HISTOPATHOLOGIC FINDINGS << MICROSCOPIC TISSUE OBSERVATIONS >>  
 DISTRIBUTION (SEVERITY) / SPECIAL COMMENTS

KIDNEY ..... NOT SPECIFIED(MODERATE)  
 -PROGRESSIVE RENAL DISEASE

URINARY BLADDER ..... TISSUE IS AUTOLYTIC

PROSTATE ..... NOT SPECIFIED(MILD)  
 -CHRONIC PROSTATITIS

SEMINAL VESICLE ..... TISSUE IS AUTOLYTIC

ILEUM ..... TISSUE IS AUTOLYTIC

CECUM ..... TISSUE IS AUTOLYTIC

RECTUM ..... TISSUE IS AUTOLYTIC

SCIATIC NERVE ..... TISSUE IS MISSING

TONGUE ..... TISSUE IS MISSING

SKIN ..... THERE IS NO TISSUE SPECIMEN FOR THIS ANIMAL THAT CORRESPONDS TO  
 THE SUBCUTANEOUS ABSCESS DESCRIBED GROSSLY.

NOSE/TURBINATES ..... TISSUE IS MISSING

ADRENAL ..... NOT SPECIFIED(MILD)  
 -FOCUS OF CELLULAR ALTERATION, VACUOLATED

PITUITARY GLAND ..... (PRESENT)  
 -B- ADENOMA

EYES & OPTIC N. .... LENTICULAR DEGENERATION IS BILATERAL. AUTOLYTIC CHANGE MAKES  
 EVALUATION OF THE RETINA IMPOSSIBLE.  
 -LENTICULAR DEGENERATIVE CHANGES COMPATIBLE WITH CATARACT  
 NOT SPECIFIED (PRESENT)

Appendix J (cont.): **PATHOLOGY INDIVIDUAL ANIMAL DATA**

LETTERMAN ARMY INSTITUTE OF RESEARCH  
DIV OF RES SUPP, PATH SERV GP  
SPECIES: RAT/FISCHER-344

INDIVIDUAL ANIMAL DATA REPORT  
STUDY NUMBER: GLP83009  
STUDY START DATE: 23-JAN-84

PRINTED: 03-JAN-90  
PAGE: 3

STUDY TYPE: CHRONIC/2 YR CARCINOGENIC

ANIMAL NUMBER: 115/PRETEST#  
DATE OF DEATH: 18-NOV-85  
SEX: MALE  
DOSE GROUP: 2  
STUDY WEEK OF DEATH: 666  
SACRIFICE STATUS: FOUND DEAD  
TERMINAL BODY WEIGHT: 301.00 (GMS)

TISSUE / HISTOPATHOLOGIC FINDINGS  
MICROSCOPIC TISSUE OBSERVATIONS >>  
DISTRIBUTION (SEVERITY) / SPECIAL COMMENTS

EAR ..... TISSUE IS MISSING

**Appendix J (cont.): PATHOLOGY INDIVIDUAL ANIMAL DATA**

LETTERMAN ARMY INSTITUTE OF RESEARCH  
 DIV OF RES SUPP, PATH SERV GP  
 SPECIES: RAT/FISCHER-344  
 STUDY START DATE: 23-JAN-84  
 STUDY NUMBER: GLP63009  
 PRINTED: 21-NOV-89  
 PAGE: 247  
 STUDY TYPE: CHRONIC/2 YR CARCINOGENIC

ANIMAL NUMBER: 116/PRETEST#  
 DATE OF DEATH: 16-AUG-85  
 DOSE GROUP: 2  
 STUDY WEEK OF DEATH: 82  
 SACRIFICE STATUS: SACRIFICED MORIBUND  
 TERMINAL BODY WEIGHT: 411.00 (GMS)

<< GROSS ORGAN OBSERVATIONS >>  
 SEVERITY GROSS FREE-TEXT COMMENTS  
 SKIN PRESENT LEFT AXILLARY REGION, FIRM 4 X 4 X 5CM  
 HEART PRESENT RIGHT VENTRICLE, PALE WHITE, .2CM DIAMETER  
 LIVER PRESENT VENTRAL ABDOMINAL WALL, LEFT LATERAL AND MEDIAL LOBES, 1CM AREA

TISSUE / HISTOPATHOLOGIC FINDINGS  
 << MICROSCOPIC TISSUE OBSERVATIONS >>  
 DISTRIBUTION (SEVERITY) / SPECIAL COMMENTS

HEART  
 THE ONLY HISTOLOGIC LESIONS NOTED IN TWO SECTIONS OF HEART ARE MYOCARDIAL DEGENERATION AND FIBROSIS TYPICAL OF CARDIOMYOPATHY THAT IS COMMON IN THIS STRAIN OF RAT. THE LESION NOTED GROSSLY IS PROBABLY PART OF THIS COMPLEX.  
 NOT SPECIFIED(MILD)

LUNGS  
 -MINERALIZATION OF PULMONARY ARTERIES  
 NOT SPECIFIED(TRACE)

SPLEEN  
 -FIBROSIS CAPSULAR  
 NOT SPECIFIED(MILD)

LYMPH NODES  
 -RED BLOOD CELLS, HEMOSIDERIN AND/OR ERYTHROPHAGOCYTOSIS WITHIN MEDULLARY SINUSES  
 RBC'S AND PIGMENT NOTED IN MEDIASTINAL NODES.  
 NOT SPECIFIED (PRESENT)

LIVER  
 -COMPOUND RELATED INFLAMMATORY REACTION  
 -BILE DUCTULE EPITHELIAL HYPERPLASIA AND/OR CHOLANGIOFIBROSIS  
 NOT SPECIFIED (PRESENT)  
 NOT SPECIFIED(MILD)

KIDNEY  
 -PROGRESSIVE RENAL DISEASE  
 NOT SPECIFIED(TRACE)

PROSTATE  
 -CHROMIC PROSTATITIS  
 -BENIGN HYPERPLASIA  
 NOT SPECIFIED(MILD)  
 NOT SPECIFIED(TRACE)

TESTES

Appendix J (cont.): PATHOLOGY INDIVIDUAL ANIMAL DATA

LETTERMAN ARMY INSTITUTE OF RESEARCH  
DIV OF RES SUPP, PATH SERV GP  
SPECIES: RAT/FISCHER-344

INDIVIDUAL ANIMAL DATA REPORT  
STUDY NUMBER: GLP03009

PRINTED: 21-NOV-89  
PAGE: 248

STUDY START DATE: 23-JAN-84

STUDY TYPE: CHRONIC/2 YR CARCINOGENIC

ANIMAL NUMBER: 116/PRETEST#  
DOSE GROUP: 2  
SACRIFICE STATUS: SACRIFICED MORIBUND  
DATE OF DEATH: 16-AUG-85  
STUDY DAY OF DEATH: 572  
STUDY WEEK OF DEATH: 82  
TERMINAL BODY WEIGHT: 411.00 (GMS)

<< M I C R O S C O P I C T I S S U E O B S E R V A T I O N S >>  
TISSUE / HISTOPATHOLOGIC FINDINGS  
DISTRIBUTION (SEVERITY) / SPECIAL COMMENTS

TESTES  
- INTERSTITIAL CELL HYPERPLASIA  
FOCAL (TRACE)

PANCREAS  
- ACINAR (EXOCRINE) ATROPHY  
- B- ISLET CELL ADENOMA  
MULTI-FOCAL (MILD)  
(PRESENT)

SKIN  
- M- NEUROFIBROSARCOMA, SUBCUTANEOUS, LOCATION TO BE SPECIFIED  
SARCOMA IS IN THE SUBCUTIS IN THE AXILLARY REGION. THERE IS NO HISTOLOGIC EVIDENCE OF THE PRESENCE OF THE TEST MATERIAL. NO EVIDENCE OF NEOPLASIA WAS OBSERVED IN THE ABDOMINAL CAVITY. ALL INDICATIONS ARE THAT THE PRIMARY SITE FOR THIS LESION IS THE SUBCUTIS IN THE AXILLARY AREA.  
(PRESENT)

MAMMARY GLANDS  
- HYPERPLASIA AND/OR HYPERTROPHY OF THE ACINAR TISSUE  
- DILATATION (ECTASIA) OF DUCTS AND DUCTULES  
NOT SPECIFIED (TRACE)  
NOT SPECIFIED (PRESENT)

NOSE/TURBINATES  
- MIXED INFLAMMATORY CELL INFILTRATION, NASAL CAVITY, SINUSES, TURBINATES, NASO-LACRIMAL DUCTS  
CELLULAR INFILTRATE IS BILATERAL AND INVOLVES NASO-LACRIMAL DUCTS.  
NOT SPECIFIED (MILD)

PITUITARY GLAND  
- CYST(S)  
NOT SPECIFIED (PRESENT)



**Appendix J (cont.): PATHOLOGY INDIVIDUAL ANIMAL DATA**

LETTERMAN ARMY INSTITUTE OF RESEARCH  
 DIV OF RES SUPP, PATH SERV GP  
 SPECIES: RAT/FISCHER-344

INDIVIDUAL ANIMAL DATA REPORT  
 STUDY NUMBER: GLP83009  
 STUDY START DATE: 23-JAN-84

PRINTED: 21-NOV-89  
 PAGE: 249  
 STUDY TYPE: CHRONIC/2 YR CARCINOGENIC

ANIMAL NUMBER: 117/PRETEST= 117 SEX: MALE DOSE GROUP: 2 SACRIFICE STATUS: SACRIFICED MORIBUND  
 DATE OF DEATH: 01-AUG-85 STUDY DAY OF DEATH: 557 STUDY WEEK OF DEATH: 80 TERMINAL BODY WEIGHT: 292.00 (GMS)

<< GROSS ORGAN OBSERVATIONS >>  
 SEVERITY GROSS FREE-TEXT COMMENTS

SKIN SUBCUTANEOUS MASS PRESENT MULTIPLE, FIRM, WHITE, .1-.2CM DIAMETER, ADJACENT TO SUBMANDIBULAR LYMPH NODES

LIVER ADHESION(S) PRESENT VENTRAL ABDOMINAL WALL AT XYPHOID PROCESS

<< MICROSCOPIC TISSUE OBSERVATIONS >>  
 DISTRIBUTION (SEVERITY) / SPECIAL COMMENTS

LUNGS -MINERALIZATION OF PULMONARY ARTERIES NOT SPECIFIED(TRACE)

SPLEEN -HEMOSIDERIN PIGMENTATION (RED PULP) NOT SPECIFIED (PRESENT)

LYMPH NODES -RED BLOOD CELLS, HEMOSIDERIN AND/OR ERYTHROPHAGOCYTOSIS WITHIN MEDULLARY SINUSES RBC'S AND PIGMENT NOTED IN MESENTERIC NODE. NOT SPECIFIED (PRESENT)

LIVER -COMPOUND RELATED INFLAMMATORY REACTION NOT SPECIFIED (PRESENT)  
 -BILE DUCTULE EPITHELIAL HYPERPLASIA AND/OR CHOLANGIOFIBROSIS NOT SPECIFIED(MILD)

KIDNEY -PROGRESSIVE RENAL DISEASE NOT SPECIFIED(TRACE)

PROSTATE -CHRONIC PROSTATITIS NOT SPECIFIED(MILD)  
 -BENIGN HYPERPLASIA NOT SPECIFIED(TRACE)

SEMINAL VESICLE -GENERALIZED ATROPHY NOT SPECIFIED (PRESENT)

**Appendix J (cont.):      PATHOLOGY INDIVIDUAL ANIMAL DATA**

LETTERMAN ARMY INSTITUTE OF RESEARCH  
DIV OF RES SUPP, PATH SERV GP  
SPECIES: RAT/FISCHER-344

INDIVIDUAL ANIMAL DATA REPORT  
STUDY NUMBER: GLP83009

PRINTED: 21-NOV-89  
PAGE: 250

STUDY START DATE: 23-JAN-84

STUDY TYPE: CHRONIC/2 YR CARCINOGENIC

ANIMAL NUMBER: 117/PRETEST      DOSE GROUP: 2      SACRIFICE STATUS: SACRIFICED MORIBUND  
DATE OF DEATH: 01-AUG-85      STUDY DAY OF DEATH: 557      STUDY WEEK OF DEATH: 80      TERMINAL BODY WEIGHT: 292.00 (GMS)

TISSUE / HISTOPATHOLOGIC FINDINGS      <<      M I C R O S C O P I C      T I S S U E      O B S E R V A T I O N S      >>  
.....  
DISTRIBUTION (SEVERITY) / SPECIAL COMMENTS

MAMMARY GLANDS ..... DILATED MAMMARY DUCTS ARE PRESENT IN SECTION #15 ADJACENT TO  
ABDOMINAL SKIN AND IN SECTION #21 WHICH IS DESCRIBED GROSSLY  
AS MULTIPLE FIRM WHITE FOCI ADJACENT TO SUBMANDIBULAR LYMPH  
NODES.  
NOT SPECIFIED (PRESENT)

-DILATATION (ECTASIA) OF DUCTS AND DUCTULES

PITUITARY GLAND ..... (PRESENT)  
-B- ADENOMA

DIAPHRAGM ..... MISCELLANEOUS TISSUE  
-COMPOUND RELATED INFLAMMATORY REACTION ..... NOT SPECIFIED (PRESENT)

**Appendix J (cont.): PATHOLOGY INDIVIDUAL ANIMAL DATA**

LETTERMAN ARMY INSTITUTE OF RESEARCH  
 DIV OF RES SUPP, PATH SERV GP  
 SPECIES: RAT/FISCHER-344  
 STUDY START DATE: 23-JAN-64  
 STUDY NUMBER: GLP83009  
 PRINTED: 21-NOV-89  
 PAGE: 251  
 STUDY TYPE: CHRONIC/2 YR CARCINOGENIC

ANIMAL NUMBER: 118/PRETEST= 118 SEX: MALE DOSE GROUP: 2 SACRIFICE STATUS: FINAL SACRIFICE  
 DATE OF DEATH: 03-FEB-86 STUDY DAY OF DEATH: 743 STUDY WEEK OF DEATH: 107 TERMINAL BODY WEIGHT: 383.00 (GMS)

<< GROSS ORGAN OBSERVATIONS >>  
 SEVERITY GROSS FREE-TEXT COMMENTS  
 SPLEEN ENLARGED (SPLENOHEGALY) MILD 5 X 1CM  
 TESTES ENLARGED PRESENT BILATERAL, 2.5 X 1.5CM  
 TESTES GROWTH(S) / MASS(ES) PRESENT BILATERAL, MULTIPLE VARIABLY SIZED, YELLOW  
 KIDNEY GRANULAR SURFACE TRACE  
 LIVER ADHESION(S) PRESENT DIAPHRAGM, VENTRAL ABDOMINAL WALL

<< MICROSCOPIC TISSUE OBSERVATIONS >>  
 DISTRIBUTION (SEVERITY) / SPECIAL COMMENTS

- HEART ..... NOT SPECIFIED(TRACE)
- CARDIOMYOPATHY ..... NOT SPECIFIED(TRACE)
- MEDIAL HYPERTROPHY OF MUSCULAR ARTERIES
- LUNGS ..... NOT SPECIFIED(TRACE)
- MINERALIZATION OF PULMONARY ARTERIES
- SPLEEN ..... (PRESENT)
- M- LARGE GRANULAR LYMPHOCYTE LEUKEMIA, METASTATIC
- LIVER ..... NOT SPECIFIED (PRESENT)
- COMPOUND RELATED INFLAMMATORY REACTION
- BILE DUCTULE EPITHELIAL HYPERPLASIA AND/OR CHOLANGIOFIBROSIS
- HEPATITIS
- FOCUS OF CELLULAR ALTERATION - BASOPHILIC
- HEPATOCTYIC VACUOLIZATION
- NECROSIS, HEPATOCTYIC, INDIVIDUAL CELLS
- HEPATOCTYIC COALESCING MICROVESICULAR (FATTY) CHANGE LEADING TO NECROSIS AND MINERALIZATION
- KIDNEY ..... NOT SPECIFIED(MODERATE)
- PROGRESSIVE RENAL DISEASE
- PROSTATE .....

**Appendix J (cont.): PATHOLOGY INDIVIDUAL ANIMAL DATA**

LETTERMAN ARMY INSTITUTE OF RESEARCH  
 DIV OF RES SUPP, PATH SERV GP  
 SPECIES: RAT/FISCHER-344  
 STUDY START DATE: 23-JAN-84  
 STUDY NUMBER: GLP83009  
 PRINTED: 21-NOV-89  
 PAGE: 252  
 STUDY TYPE: CHRONIC/2 YR CARCINOGENIC

ANIMAL NUMBER: 118/PRETEST#  
 DOSE GROUP: 2  
 SACRIFICE STATUS: FINAL SACRIFICE  
 DATE OF DEATH: 03-FEB-86  
 STUDY DAY OF DEATH: 743  
 STUDY WEEK OF DEATH: 107  
 TERMINAL BODY WEIGHT: 383.00 (GMS)

<< M I C R O S C O P I C T I S S U E O B S E R V A T I O N S >>  
 TISSUE / HISTOPATHOLOGIC FINDINGS  
 DISTRIBUTION (SEVERITY) / SPECIAL COMMENTS

- PROSTATE ..... NOT SPECIFIED (TRACE)
- CHRONIC PROSTATITIS ..... NOT SPECIFIED (TRACE)
- BENIGN HYPERPLASIA ..... NOT SPECIFIED (TRACE)
- SEMINAL VESICLE ..... NOT SPECIFIED (PRESENT)
- GENERALIZED ATROPHY ..... (PRESENT)
- TESTES ..... NOT SPECIFIED (PRESENT)
- B- INTERSTITIAL CELL ADENOMA ..... (PRESENT)
- STOMACH ..... NOT SPECIFIED (PRESENT)
- MUCOSAL AND/OR SUBMUCOSAL EDEMA ..... NOT SPECIFIED (PRESENT)
- MAMMARY GLANDS ..... NOT SPECIFIED (TRACE)
- HYPERPLASIA AND/OR HYPERTROPHY OF THE ACINAR TISSUE ..... NOT SPECIFIED (PRESENT)
- DILATATION (ECTASIA) OF DUCTS AND DUCTULES ..... (PRESENT)
- PITUITARY GLAND ..... (PRESENT)
- B- ADENOMA ..... (PRESENT)
- EYES & OPTIC N. .... NOT SPECIFIED (PRESENT)
- METAPLASTIC BONE FORMATION AND/OR MINERALIZATION, SCLERA ..... (PRESENT)
- WHOLE BODY ..... MISCELLANEOUS TISSUE
- M- LARGE GRANULAR LYMPHOCYTTIC LEUKEMIA ..... NOT SPECIFIED (PRESENT)
- DIAPHRAGM ..... MISCELLANEOUS TISSUE
- COMPOUND RELATED INFLAMMATORY REACTION ..... NOT SPECIFIED (PRESENT)

**Appendix J (cont.): PATHOLOGY INDIVIDUAL ANIMAL DATA**

LETTERMAN ARMY INSTITUTE OF RESEARCH  
 DIV OF RES SUPP, PATH SERV GP  
 SPECIES: RAT/FISCHER-344  
 STUDY NUMBER: GLP83009  
 STUDY START DATE: 23-JAN-84  
 STUDY TYPE: CHRONIC/2 YR CARCINOGENIC  
 ANIMAL NUMBER: 120/PRETEST= 120 SEX: MALE DOSE GROUP: 2 SACRIFICE STATUS: FINAL SACRIFICE  
 DATE OF DEATH: 03-FEB-86 STUDY DAY OF DEATH: 743 STUDY WEEK OF DEATH: 107 TERMINAL BODY WEIGHT: 430.00 (GMS)

PRINTED: 21-NOV-89  
 PAGE: 254

<< GROSS ORGAN OBSERVATIONS >>  
 SEVERITY GROSS FREE-TEXT COMMENTS  
 ORGAN NAME  
 LIVER PRESENT DIAPHRAGM, VENTRAL ABDOMINAL WALL  
 TESTES PRESENT BILATERAL, MULTIPLE VARIABLY SIZED, YELLOW

<< MICROSCOPIC TISSUE OBSERVATIONS >>  
 DISTRIBUTION (SEVERITY) / SPECIAL COMMENTS

THYROID GLANDS  
 -PARA-FOLLICULAR CELL HYPERPLASIA ("C" CELL, LIGHT CELL) NOT SPECIFIED(TRACE)

HEART  
 -CARDIOMYOPATHY NOT SPECIFIED(MILD)

LUNGS  
 -MINERALIZATION OF PULMONARY ARTERIES NOT SPECIFIED(TRACE)

LYMPH NODES  
 REACTIVE HYPERPLASIA NOTED IN CERVICAL LYMPH NODES.  
 RBC'S AND DILATED MEDULLARY SINUSES ARE PRESENT IN MEDIASTINAL  
 NODES. MEDULLARY SINUSES IN THE MESENTERIC NODES ARE ALSO  
 DILATED.  
 NOT SPECIFIED (PRESENT)

-RED BLOOD CELLS, HEMOSIDERIN AND/OR ERYTHROPHAGOCYTOSIS WITHIN  
 MEDULLARY SINUSES  
 -REACTIVE HYPERPLASIA  
 -DILATED AND/OR CYSTIC MEDULLARY SINUSES  
 NOT SPECIFIED (PRESENT)  
 NOT SPECIFIED (PRESENT)  
 NOT SPECIFIED (PRESENT)

LIVER  
 -COMPOUND RELATED INFLAMMATORY REACTION  
 -BILE DUCTULE EPITHELIAL HYPERPLASIA AND/OR CHOLANGIOFIBROSIS  
 -HEPATOCTYIC VACUOLIZATION  
 -CYSTIC DEGENERATION  
 -HEPATOCTYIC COALESCING MICROVESICULAR (FATTY) CHANGE LEADING TO  
 NECROSIS AND MINERALIZATION  
 NOT SPECIFIED (PRESENT)  
 NOT SPECIFIED(MODERATE)  
 NOT SPECIFIED(TRACE)  
 NOT SPECIFIED (PRESENT)  
 MULTI-FOCAL(TRACE)

KIDNEY

Appendix J (cont.): PATHOLOGY INDIVIDUAL ANIMAL DATA

LETTERMAN ARMY INSTITUTE OF RESEARCH  
DIV OF RES SUPP, PATH SERV GP  
SPECIES: RAT/FISCHER-344

INDIVIDUAL ANIMAL DATA REPORT  
STUDY NUMBER: GLP83009  
STUDY START DATE: 23-JAN-84

PRINTED: 21-NOV-89  
PAGE: 255  
STUDY TYPE: CHRONIC/2 YR CARCINOGENIC

ANIMAL NUMBER: 120/PRETEST= 120 SEX: MALE DOSE GROUP: 2 SACRIFICE STATUS: FINAL SACRIFICE  
DATE OF DEATH: 03-FEB-86 STUDY DAY OF DEATH: 743 STUDY WEEK OF DEATH: 107 TERMINAL BODY WEIGHT: 430.00 (GMS)

TISSUE / HISTOPATHOLOGIC FINDINGS << MICROSCOPIC TISSUE OBSERVATIONS >>  
DISTRIBUTION (SEVERITY) / SPECIAL COMMENTS

KIDNEY ..... NOT SPECIFIED(MODERATE)  
-PROGRESSIVE RENAL DISEASE

PROSTATE ..... NOT SPECIFIED(TRACE)  
-CHRONIC PROSTATITIS  
-BENIGN HYPERPLASIA

SEMINAL VESICLE ..... NOT SPECIFIED (PRESENT)  
-GENERALIZED ATROPHY

TESTES ..... (PRESENT)  
-B- INTERSTITIAL CELL ADENOMA

MAMMARY GLANDS ..... NOT SPECIFIED(TRACE)  
-HYPERPLASIA AND/OR HYPERTROPHY OF THE ACINAR TISSUE

NOSE/TURBINATES ..... CELLULAR INFILTRATE IS ADJACENT NASO-LACRIMAL DUCT.  
-MIXED INFLAMMATORY CELL INFILTRATION, NASAL CAVITY, SINUSES,  
TURBINATES, NASO-LACRIMAL DUCTS NOT SPECIFIED(MILD)

PITUITARY GLAND ..... (PRESENT)  
-B- ADENOMA

EYES & OPTIC N. ..... NOT SPECIFIED (PRESENT)  
-METAPLASTIC BONE FORMATION AND/OR MINERALIZATION, SCLERA

DIAPHRAGM ..... MISCELLANEOUS TISSUE  
-COMPOUND RELATED INFLAMMATORY REACTION NOT SPECIFIED (PRESENT)

**Appendix J (cont.): PATHOLOGY INDIVIDUAL ANIMAL DATA**

LETTERMAN ARMY INSTITUTE OF RESEARCH  
 DIV OF RES SUPP, PATH SERV GP  
 SPECIES: RAT/FISCHER-344

INDIVIDUAL ANIMAL DATA REPORT  
 STUDY NUMBER: GLP83009

PRINTED: 21-NOV-89  
 PAGE: 256

STUDY START DATE: 23-JAN-84

STUDY TYPE: CHRONIC/2 YR CARCINOGENIC

ANIMAL NUMBER: 121/PRETEST= 121 SEX: MALE DOSE GROUP: 2 SACRIFICE STATUS: FINAL SACRIFICE  
 DATE OF DEATH: 03-FEB-86 STUDY DAY OF DEATH: 743 STUDY WEEK OF DEATH: 107 TERMINAL BODY WEIGHT: 382.00 (GMS)

ORGAN NAME << GROSS ORGAN OBSERVATIONS >>  
 SEVERITY GROSS FREE-TEXT COMMENTS  
 LIVER PROMINENT LOBULAR MARKINGS PRESENT DIFFUSE  
 LIVER ADHESION(S) PRESENT DIAPHRAGM  
 TESTES GROWTH(S) / MASS(ES) PRESENT BILATERAL, MULTIPLE VARIABLY SIZED, YELLOW  
 SPLEEN ENLARGED (SPLENOMEGALY) MODERATE 6 X 1.5CM

TISSUE / HISTOPATHOLOGIC FINDINGS << MICROSCOPIC TISSUE OBSERVATIONS >>  
 DISTRIBUTION (SEVERITY) / SPECIAL COMMENTS

HEART  
 -CARDIOMYOPATHY NOT SPECIFIED(MILD)  
 -MEDIAL HYPERTROPHY OF MUSCULAR ARTERIES NOT SPECIFIED(TRACE)

SPLEEN  
 -M- LARGE GRANULAR LYMPHOCYTE LEUKEMIA, METASTATIC (PRESENT)

LIVER  
 -COMPOUND RELATED INFLAMMATORY REACTION NOT SPECIFIED (PRESENT)  
 -BILE DUCTULE EPITHELIAL HYPERPLASIA AND/OR CHOLANGIOFIBROSIS NOT SPECIFIED(MODERATE)  
 -FOCUS OF CELLULAR ALTERATION - BASOPHILIC NOT SPECIFIED(TRACE)  
 -CYSTIC DEGENERATION NOT SPECIFIED (PRESENT)  
 -BENIGN HYPERPLASTIC MODULE(S) NOT SPECIFIED(TRACE)  
 -M- LARGE GRANULAR LYMPHOCYTE LEUKEMIA, METASTATIC (PRESENT)  
 -HEPATOCYTE COALESCING MICROVESICULAR (FATTY) CHANGE LEADING TO NECROSIS AND MINERALIZATION NOT SPECIFIED(TRACE)

KIDNEY  
 -PROGRESSIVE RENAL DISEASE NOT SPECIFIED(MILD)

PROSTATE  
 -CHRONIC PROSTATITIS NOT SPECIFIED(MILD)  
 -BENIGN HYPERPLASIA NOT SPECIFIED(MILD)

TESTES

Appendix J (cont.): PATHOLOGY INDIVIDUAL ANIMAL DATA

LETTERMAN ARMY INSTITUTE OF RESEARCH  
 DIV OF RES SUPP, PATH SERV GP  
 SPECIES: RAT/FISCHER-344

INDIVIDUAL ANIMAL DATA REPORT  
 STUDY NUMBER: GLP83009  
 STUDY START DATE: 23-JAN-84

PRINTED: 21-NOV-89  
 PAGE: 257  
 STUDY TYPE: CHRONIC/2 YR CARCINOGENIC

ANIMAL NUMBER: 121/PRETEST= 121 SEX: MALE DOSE GROUP: 2 SACRIFICE STATUS: FINAL SACRIFICE  
 DATE OF DEATH: 03-FEB-86 STUDY DAY OF DEATH: 743 STUDY WEEK OF DEATH: 107 TERMINAL BODY WEIGHT: 382.00 (GMS)

TISSUE / HISTOPATHOLOGIC FINDINGS  
 << MICROSCOPIC TISSUE OBSERVATIONS >>  
 DISTRIBUTION (SEVERITY) / SPECIAL COMMENTS

TESTES ..... (PRESENT)

-B- INTERSTITIAL CELL ADENOMA

MAMMARY GLANDS ..... NOT SPECIFIED (TRACE)

-HYPERPLASIA AND/OR HYPERTROPHY OF THE ACINAR TISSUE

NOSE/TURBINATES ..... CELLULAR INFILTRATE INVOLVES NASO-LACRIMAL DUCTS.

-MIXED INFLAMMATORY CELL INFILTRATION, NASAL CAVITY, SINUSES, NOT SPECIFIED (TRACE)

TURBINATES, NASO-LACRIMAL DUCTS

ADRENAL ..... NOT SPECIFIED (TRACE)

-FOCUS OF CELLULAR ALTERATION, VACUOLATED

EYES & OPTIC N. .... NOT SPECIFIED (PRESENT)

-METAPLASTIC BONE FORMATION AND/OR MINERALIZATION, SCLERA

WHOLE BODY ..... (PRESENT)

-N- LARGE GRANULAR LYMPHOCYTTIC LEUKEMIA

DIAPHRAGM ..... MISCELLANEOUS TISSUE

-COMPOUND RELATED INFLAMMATORY REACTION NOT SPECIFIED (PRESENT)



Appendix J (cont.): PATHOLOGY INDIVIDUAL ANIMAL DATA

LETTERMAN ARMY INSTITUTE OF RESEARCH INDIVIDUAL ANIMAL DATA REPORT PRINTED: 21-NOV-89  
DIV OF RES SUPP, PATH SERV GP STUDY NUMBER: GLP83009 PAGE: 258  
SPECIES: RAT/FISCHER-344 STUDY START DATE: 23-JAN-84 STUDY TYPE: CHRONIC/2 YR CARCINOGENIC

ANIMAL NUMBER: 122/PRETEST-122 SEX: MALE DOSE GROUP: 2 SACRIFICE STATUS: FINAL SACRIFICE  
DATE OF DEATH: 05-FEB-86 STUDY DAY OF DEATH: 745 STUDY WEEK OF DEATH: 107 TERMINAL BODY WEIGHT: 390.00 (GMS)

<< GROSS ORGAN OBSERVATIONS >>  
KEYWORDS / PHRASES SEVERITY GROSS FREE-TEXT COMMENTS  
ADHESION(S) PRESENT LEFT VENTRAL ABDOMINAL WALL  
LENS CATARACT PRESENT LEFT  
GROWTH(S) / MASS(ES) PRESENT RIGHT, MULTIPLE VARIABLY SIZED, YELLOW

<< MICROSCOPIC TISSUE OBSERVATIONS >>  
TISSUE / HISTOPATHOLOGIC FINDINGS DISTRIBUTION (SEVERITY) / SPECIAL COMMENTS

HEART ..... NOT SPECIFIED(MODERATE)  
-CARDIOMYOPATHY

LYMPH NODES ..... RBC'S NOTED IN CERVICAL NODE.  
-RED BLOOD CELLS, HEOSIDERIN AND/OR ERYTHROPHAGOCYTOSIS WITHIN ..... NOT SPECIFIED (PRESENT)  
MEDULLARY SINUSES

LIVER ..... NOT SPECIFIED (PRESENT)  
-COMPOUND RELATED INFLAMMATORY REACTION ..... NOT SPECIFIED(MILD)  
-BILE DUCTULE EPITHELIAL HYPERPLASIA AND/OR CHOLANGIOFIBROSIS ..... NOT SPECIFIED(TRACE)  
-HEPATITIS ..... NOT SPECIFIED(MILD)  
-HEPATOCTYIC VACUOLIZATION ..... NOT SPECIFIED(MODERATE)  
-HEPATOCTYIC COALESCING MICROVESICULAR (FATTY) CHANGE LEADING TO  
NECROSIS AND MINERALIZATION

KIDNEY ..... NOT SPECIFIED(MODERATE)  
-PROGRESSIVE RENAL DISEASE

PROSTATE ..... NOT SPECIFIED(TRACE)  
-CHRONIC PROSTATITIS ..... NOT SPECIFIED(TRACE)  
-BENIGN HYPERPLASIA

TESTES ..... (PRESENT)  
-B- INTERSTITIAL CELL ADENOMA

Appendix J (cont.): PATHOLOGY INDIVIDUAL ANIMAL DATA

LETTERMAN ARMY INSTITUTE OF RESEARCH  
DIV OF RES SUPP, PATH SERV GP  
SPECIES: RAT/FISCHER-344

INDIVIDUAL ANIMAL DATA REPORT  
STUDY NUMBER: GLP83009  
STUDY START DATE: 23-JAN-84

PRINTED: 21-NOV-89  
PAGE: 259  
STUDY TYPE: CHRONIC/2 YR CARCINOGENIC

ANIMAL NUMBER: 122/PRETEST-      122 SEX: MALE      DOSE GROUP: 2      SACRIFICE STATUS: FINAL SACRIFICE  
DATE OF DEATH: 05-FEB-86      STUDY DAY OF DEATH: 745      STUDY WEEK OF DEATH: 107      TERMINAL BODY WEIGHT: 390.00 (GMS)

<<      M I C R O S C O P I C      T I S S U E      O B S E R V A T I O N S      >>  
.....  
TISSUE / HISTOPATHOLOGIC FINDINGS      DISTRIBUTION (SEVERITY) / SPECIAL COMMENTS      .....

NOSE/TURBINATES .....  
-MIXED INFLAMMATORY CELL INFILTRATION, NASAL CAVITY, SINUSES, .....  
TURBINATES, NASO-LACRIMAL DUCTS      CELLULAR INFILTRATE INVOLVES NASO-LACRIMAL DUCTS.  
NOT SPECIFIED(TRACE)

EYES & OPTIC N. ....  
-CORNEAL MINERALIZATION      NOT SPECIFIED(TRACE)  
-RETINAL ATROPHY AND/OR DEGENERATION, UNILATERAL OR BILATERAL      NOT SPECIFIED(MARKED)  
-CORNEAL VASCULARIZATION      NOT SPECIFIED(TRACE)  
-LENTICULAR DEGENERATIVE CHANGES COMPATIBLE WITH CATARACT      NOT SPECIFIED (PRESENT)

Appendix J (cont.): PATHOLOGY INDIVIDUAL ANIMAL DATA

LETTERMAN ARMY INSTITUTE OF RESEARCH  
DIV OF RES SUPP, PATH SERV GP  
SPECIES: RAT/FISCHER-344

INDIVIDUAL ANIMAL DATA REPORT  
STUDY NUMBER: GLP83009  
STUDY START DATE: 23-JAN-84

PRINTED: 21-NOV-89  
PAGE: 260  
STUDY TYPE: CHRONIC/2 YR CARCINOGENIC

ANIMAL NUMBER: 123/PRETEST= 123 SEX: MALE DOSE GROUP: 2 SACRIFICE STATUS: FINAL SACRIFICE  
DATE OF DEATH: 05-FEB-86 STUDY DAY OF DEATH: 745 STUDY WEEK OF DEATH: 107 TERMINAL BODY WEIGHT: 350.00 (GMS)

ORGAN NAME SEVERITY GROSS FREE-TEXT COMMENTS  
TESTES ENLARGED PRESENT BILATERAL, 2.75 X 1.75  
TESTES GROWTH(S) / MASS(ES) PRESENT BILATERAL, MULTIPLE VARIABLY SIZED, YELLOW/BLACK  
LIVER ADHESION(S) PRESENT DIAPHRAGM, VENTRAL ABDOMINAL WALL  
LIVER MODULE(S) PRESENT RIGHT LATERAL LOBE, MULTIPLE, DIFFUSE, YELLOW/RED,  
ENLARGED 4 X 2.5 X 2CM

KEYWORDS / PHRASES O B S E R V A T I O N S >>  
<< G R O S S O R G A N O B S E R V A T I O N S >>  
O B S E R V A T I O N S >>  
D I S T R I B U T I O N ( S E V E R I T Y ) / S P E C I A L C O M M E N T S

TISSUE / HISTOPATHOLOGIC FINDINGS  
<< M I C R O S C O P I C T I S S U E O B S E R V A T I O N S >>  
D I S T R I B U T I O N ( S E V E R I T Y ) / S P E C I A L C O M M E N T S  
THYROID GLANDS ..... NOT SPECIFIED (TRACE)  
-PARA-FOLLICULAR CELL HYPERPLASIA ("C" CELL, LIGHT CELL)  
HEART ..... NOT SPECIFIED (MILD)  
-CARDIOMYOPATHY  
LUNGS ..... PARTS OF TWO LOBES OF LUNG ARE POORLY PERFUSED AND THERE IS  
COLLAPSE OF ALVEOLI. THIS IS A FIXATION ARTIFACT ONLY.  
-MINERALIZATION OF PULMONARY ARTERIES  
-ALVEOLAR HEMORRHAGE  
LYMPH NODES ..... REACTIVE HYPERPLASIA NOTED IN CERVICAL AND MEDIASTINAL NODES.  
-REACTIVE HYPERPLASIA  
LIVER ..... NOT SPECIFIED (PRESENT)  
-COMPOUND RELATED INFLAMMATORY REACTION  
-BILE DUCTULE EPITHELIAL HYPERPLASIA AND/OR CHOLANGIOFIBROSIS  
-HEPATITIS  
-CYSTIC DEGENERATION  
-M- HEPATOCELLULAR CARCINOMA  
KIDNEY ..... NOT SPECIFIED (MODERATE)  
-PROGRESSIVE RENAL DISEASE  
PROSTATE .....

Appendix J (cont.): PATHOLOGY INDIVIDUAL ANIMAL DATA

LETTERMAN ARMY INSTITUTE OF RESEARCH  
DIV OF RES SUPP, PATH SERV GP  
SPECIES: RAT/FISCHER-344

INDIVIDUAL ANIMAL DATA REPORT  
STUDY NUMBER: GLP83009  
STUDY START DATE: 23-JAN-84

PRINTED: 21-NOV-89  
PAGE: 261

ANIMAL NUMBER: 123/PRETEST# 123 SEX: MALE DOSE GROUP: 2 SACRIFICE STATUS: FINAL SACRIFICE  
DATE OF DEATH: 05-FEB-86 STUDY DAY OF DEATH: 745 STUDY WEEK OF DEATH: 107 TERMINAL BODY WEIGHT: 358.00 (GMS)  
STUDY TYPE: CHRONIC/2 YR CARCINOGENIC

<< M I C R O S C O P I C T I S S U E O B S E R V A T I O N S >>  
TISSUE / HISTOPATHOLOGIC FINDINGS ..... DISTRIBUTION (SEVERITY) / SPECIAL COMMENTS .....

PROSTATE ..... NOT SPECIFIED(TRACE)  
-BENIGN HYPERPLASIA

TESTES ..... (PRESENT)  
-B- INTERSTITIAL CELL ADENOMA

ILEUM ..... TISSUE IS MISSING

SKELETAL MUSCLE ..... NOT SPECIFIED (PRESENT)  
-CHRONIC INFLAMMATION RESTRICTED TO FASCIA

TONGUE ..... DIFFUSE(TRACE)  
-MONONUCLEAR CELLULAR INFILTRATION

DIAPHRAGM ..... MISCELLANEOUS TISSUE  
-COMPOUND RELATED INFLAMMATORY REACTION ..... NOT SPECIFIED (PRESENT)

**Appendix J (cont.): PATHOLOGY INDIVIDUAL ANIMAL DATA**

LETTERMAN ARMY INSTITUTE OF RESEARCH  
 DIV OF RES SUPP, PATH SERV GP  
 SPECIES: RAT/FISCHER-344  
 PRINTED: 21-NOV-89  
 PAGE: 262  
 STUDY NUMBER: GLP83009  
 STUDY TYPE: CHRONIC/2 YR CARCINOGENIC

ANIMAL NUMBER: 124/PRETEST= 124 SEX: MALE DOSE GROUP: 2 SACRIFICE STATUS: FINAL SACRIFICE  
 DATE OF DEATH: 05-FEB-86 STUDY DAY OF DEATH: 745 STUDY WEEK OF DEATH: 107 TERMINAL BODY WEIGHT: 376.00 (GMS)

ORGAN NAME << GROSS ORGAN OBSERVATIONS >>  
 SEVERITY GROSS FREE-TEXT COMMENTS  
 LIVER ADHESION(S) PRESENT DIAPHRAGM, VENTRAL ABDOMINAL WALL  
 TESTES ATROPHIC / SMALL, UNILATERALLY PRESENT LEFT, 1.5 X 1CM  
 TESTES GROWTH(S) / MASS(ES) PRESENT RIGHT, MULTIPLE VARIABLY SIZED, YELLOW/BLACK  
 LIVER NODULE(S) PRESENT RAISED, .5CM DIAMETER

TISSUE / HISTOPATHOLOGIC FINDINGS << MICROSCOPIC TISSUE OBSERVATIONS >>  
 DISTRIBUTION (SEVERITY) / SPECIAL COMMENTS

THYROID GLANDS  
 -PARA-FOLLICULAR CELL HYPERPLASIA ("C" CELL, LIGHT CELL) NOT SPECIFIED(TRACE)  
 -COLLOID CYST(S) NOT SPECIFIED (PRESENT)

HEART  
 -CARDIOMYOPATHY NOT SPECIFIED(MILD)

LUNGS  
 -MINERALIZATION OF PULMONARY ARTERIES NOT SPECIFIED(TRACE)  
 THYMUS TISSUE IS MISSING

LIVER  
 -COMPOUND RELATED INFLAMMATORY REACTION NOT SPECIFIED (PRESENT)  
 -BILE DUCTULE EPITHELIAL HYPERPLASIA AND/OR CHOLANGIOFIBROSIS NOT SPECIFIED(MODERATE)  
 -HEPATOCYTTIC VACUOLIZATION MULTI-FOCAL(TRACE)  
 -BENIGN HYPERPLASTIC NODULE(S) NOT SPECIFIED(MILD)  
 -HEPATOCYTE COALESCING MICROVESICULAR (FATTY) CHANGE LEADING TO MULTI-FOCAL(TRACE)  
 NECROSIS AND MINERALIZATION

KIDNEY  
 -PROGRESSIVE RENAL DISEASE NOT SPECIFIED(MILD)

PROSTATE

**Appendix J (cont.): PATHOLOGY INDIVIDUAL ANIMAL DATA**

LETIERMAN ARMY INSTITUTE OF RESEARCH  
 DIV OF RES SUPP, PATH SERV GP  
 SPECIES: RAT/FISCHER-344  
 STUDY NUMBER: GLP83009  
 STUDY START DATE: 23-JAN-84  
 PRINTED: 21-NOV-89  
 PAGE: 263  
 STUDY TYPE: CHRONIC/2 YR CARCINOGENIC

ANIMAL NUMBER: 124/PRETEST-124 SEX: MALE DO-E GROUP: 2 SACRIFICE STATUS: FINAL SACRIFICE  
 DATE OF DEATH: 05-FEB-86 STUDY DAY OF DEATH: 745 STUDY WEEK OF DEATH: 107 TERMINAL BODY WEIGHT: 376.00 (GMS)

<< MICROSCOPIC TISSUE OBSERVATIONS >>  
 TISSUE / HISTOPATHOLOGIC FINDINGS  
 DISTRIBUTION (SEVERITY) / SPECIAL COMMENTS

PROSTATE .....  
 -CHRONIC PROSTATITIS ..... NOT SPECIFIED (TRACE)  
 -BENIGN HYPERPLASIA ..... NOT SPECIFIED (TRACE)

SEMINAL VESICLE .....  
 -GENERALIZED ATROPHY ..... NOT SPECIFIED (PRESENT)

TESTES ..... (PRESENT)  
 -B- INTERSTITIAL CELL ADENOMA

NOSE/TURBINATES .....  
 -MIXED INFLAMMATORY CELL INFILTRATION, NASAL CAVITY, SINUSES, ..... CELLULAR INFILTRATE INVOLVES NASO-LACRIMAL DUCT.  
 TURBINATES, NASO-LACRIMAL DUCTS ..... NOT SPECIFIED (TRACE)

ADRENAL .....  
 -FOCUS OF CELLULAR ALTERATION, VACUOLATED ..... NOT SPECIFIED (TRACE)

EYES & OPTIC N. ....  
 -METAPLASTIC BONE FORMATION AND/OR MINERALIZATION, SCLERA ..... NOT SPECIFIED (PRESENT)

DIAPHRAGM ..... MISCELLANEOUS TISSUE  
 -COMPOUND RELATED INFLAMMATORY REACTION ..... NOT SPECIFIED (PRESENT)

Appendix J (cont.): PATHOLOGY INDIVIDUAL ANIMAL DATA

LETTERMAN ARMY INSTITUTE OF RESEARCH DIV OF RES SUPP, PATH SERV GP SPECIES: RAT/FISCHER-344 STUDY START DATE: 23-JAN-84 STUDY NUMBER: GLP83009 PRINTED: 21-NOV-89 PAGE: 264

ANIMAL NUMBER: 125/PRETEST-125 SEX: MALE DOSE GROUP: 2 SACRIFICE STATUS: FINAL SACRIFICE DATE OF DEATH: 05-FEB-86 STUDY DAY OF DEATH: 745 STUDY WEEK OF DEATH: 107 TERMINAL BODY WEIGHT: 326.00 (GMS) STUDY TYPE: CHRONIC/2 YR CARCINOGENIC

ORGAN NAME: LIVER, SPLEEN, TESTES, PITUITARY GLAND, KIDNEY. GROSS ORGAN OBSERVATIONS: SEVERITY, GROSS, FREE-TEXT COMMENTS. KEYWORDS / PHRASES: ADHESION(S), ENLARGED (SPLENOHEGALY), GROWTH(S) / MASS(ES), DISCOLORATION, GRANULAR SURFACE. PRESENT: MILD, RIGHT, MULTIPLE VARIABLY SIZED, YELLOW FOCAL, RAISED, RED, .3CM DIAMETER. TRACE: VENTRAL ABDOMINAL WALL, 5 X 1.5CM.

TISSUE / HISTOPATHOLOGIC FINDINGS: MICROSCOPIC TISSUE OBSERVATIONS >> DISTRIBUTION (SEVERITY) / SPECIAL COMMENTS

THYROID GLANDS: -PARA-FOLLICULAR CELL HYPERPLASIA (MC CELL, LIGHT CELL) NOT SPECIFIED(TRACE)

HEART: -CARDIOMYOPATHY NOT SPECIFIED(TRACE); -N- LARGE GRANULAR LYMPHOCYTE LEUKEMIA, METASTATIC (PRESENT)

LUNGS: -PNEUMONIA, INTERSTITIAL, CHRONIC; -N- LARGE GRANULAR LYMPHOCYTE LEUKEMIA, METASTATIC (PRESENT); MULTI-FOCAL(TRACE)

THYMUS: -N- LARGE GRANULAR LYMPHOCYTE LEUKEMIA, METASTATIC (PRESENT)

SPLEEN: -INFARCTION, CHRONIC; -N- LARGE GRANULAR LYMPHOCYTE LEUKEMIA, METASTATIC (PRESENT); NOT SPECIFIED(MODERATE)

LYMPH NODES: -N- LARGE GRANULAR LYMPHOCYTE LEUKEMIA, METASTATIC (PRESENT); LARGE GRANULE LYMPHOCYTE LEUKEMIA WAS PRESENT ON MOST NODES INCLUDING MULTIPLE SITES ADJACENT TO SALIVARY GLANDS, ADJACENT TO THE THYROID, IN THE MEDIASTINUM AND IN MESENTERIC NODES.

LIVER: -N- LARGE GRANULAR LYMPHOCYTE LEUKEMIA, METASTATIC (PRESENT)

**Appendix J (cont.): PATHOLOGY INDIVIDUAL ANIMAL DATA**

LETTERMAN ARMY INSTITUTE OF RESEARCH  
 DIV OF RES SUPP, PATH SERV GP  
 SPECIES: RAT/FISCHER-344

INDIVIDUAL ANIMAL DATA REPORT  
 STUDY NUMBER: GLP83009

PRINTED: 21-NOV-89  
 PAGE: 265

STUDY START DATE: 23-JAN-84

STUDY TYPE: CHRONIC/2 YR CARCINOGENIC

ANIMAL NUMBER: 125/PRETEST= 125 SEX: MALE DOSE GROUP: 2 SACRIFICE STATUS: FINAL SACRIFICE  
 DATE OF DEATH: 05-FEB-86 STUDY DAY OF DEATH: 745 STUDY WEEK OF DEATH: 107 TERMINAL BODY WEIGHT: 326.00 (GMS)

TISSUE / HISTOPATHOLOGIC FINDINGS << MICROSCOPIC TISSUE OBSERVATIONS >>  
 DISTRIBUTION (SEVERITY) / SPECIAL COMMENTS

LIVER ..... NOT SPECIFIED (PRESENT)  
 -COMPOUND RELATED INFLAMMATORY REACTION ..... NOT SPECIFIED (MODERATE)  
 -BILE DUCTULE EPITHELIAL HYPERPLASIA AND/OR CHOLANGIOFIBROSIS ..... NOT SPECIFIED (MILD)  
 -HEPATO CYTIC DEGENERATIVE CHANGES (NON-NECROTIC) ..... MULTI-FOCAL (MILD)  
 -NECROSIS, PERIACINAR ..... (PRESENT)  
 -N- LARGE GRANULAR LYMPHOCYTE LEUKEMIA, METASTATIC

KIDNEY ..... NOT SPECIFIED (MILD)  
 -PROGRESSIVE RENAL DISEASE ..... (PRESENT)  
 -N- LARGE GRANULAR LYMPHOCYTE LEUKEMIA, METASTATIC

URINARY BLADDER ..... NOT SPECIFIED (TRACE)  
 -CHRONIC INFLAMMATORY CELL INFILTRATION

PROSTATE ..... NOT SPECIFIED (TRACE)  
 -CHRONIC PROSTATITIS ..... NOT SPECIFIED (TRACE)  
 -BENIGN HYPERPLASIA

TESTES ..... (PRESENT)  
 -B- INTERSTITIAL CELL ADENOMA

ILEUM ..... (PRESENT)  
 -N- LARGE GRANULAR LYMPHOCYTE LEUKEMIA, METASTATIC

PANCREAS ..... (PRESENT)  
 -N- LARGE GRANULAR LYMPHOCYTE LEUKEMIA, METASTATIC

NOSE/TURBINATES ..... CELLULAR INFILTRATE IS ADJACENT TO NASO-LACRIMAL DUCTS.  
 -MIXED INFLAMMATORY CELL INFILTRATION, NASAL CAVITY, SINUSES, ..... NOT SPECIFIED (TRACE)  
 TURBINATES, NASO-LACRIMAL DUCTS

BONE, STERNUM ..... (PRESENT)  
 -N- LARGE GRANULE LYMPHOCYTE LEUKEMIA, METASTATIC

BONE, FEMUR ..... (PRESENT)



Appendix J (cont.): PATHOLOGY INDIVIDUAL ANIMAL DATA

LETTERMAN ARMY INSTITUTE OF RESEARCH  
 DIV OF RES SUPP, PATH SERV GP  
 SPECIES: RAT/FISCHER-344

INDIVIDUAL ANIMAL DATA REPORT  
 STUDY NUMBER: GLP83009  
 STUDY START DATE: 23-JAN-84

PRINTED: 21-NOV-89  
 PAGE: 266

STUDY TYPE: CHRONIC/2 YR CARCINOGENIC

ANIMAL NUMBER: 125/PRETEST-125 SEX: MALE DOSE GROUP: 2 SACRIFICE STATUS: FINAL SACRIFICE  
 DATE OF DEATH: 05-FEB-86 STUDY DAY OF DEATH: 745 STUDY WEEK OF DEATH: 107 TERMINAL BODY WEIGHT: 326.00 (GMS)

TISSUE / HISTOPATHOLOGIC FINDINGS << MICROSCOPIC TISSUE OBSERVATIONS >>  
 DISTRIBUTION (SEVERITY) / SPECIAL COMMENTS

BONE, FEMUR ..... (PRESENT)  
 -N- LARGE GRANULE LYMPHOCYTE LEUKEMIA, METASTATIC

BONE VERT ..... (PRESENT)  
 -M- LARGE GRANULE LYMPHOCYTE LEUKEMIA, METASTATIC

ADRENAL ..... NOT SPECIFIED(MILD)  
 -LIPIDOSIS

PITUITARY GLAND ..... (PRESENT)  
 -B- ADENOMA  
 -M- LARGE GRANULE LYMPHOCYTE LEUKEMIA, METASTATIC

EYES & OPTIC N. .... NOT SPECIFIED(TRACE)  
 -RETINAL ATROPHY AND/OR DEGENERATION, UNILATERAL OR BILATERAL

WHOLE BODY ..... (PRESENT)  
 -M- LARGE GRANULAR LYMPHOCYTIC LEUKEMIA

**Appendix J (cont.): PATHOLOGY INDIVIDUAL ANIMAL DATA**

LETTERMAN ARMY INSTITUTE OF RESEARCH  
 DIV OF RES SUPP, PATH SERV GP  
 SPECIES: RAT/FISCHER-344  
 STUDY NUMBER: GLP83009  
 STUDY START DATE: 23-JAN-84  
 PRINTED: 21-NOV-89  
 PAGE: 267  
 STUDY TYPE: CHRONIC/2 YR CARCINOGENIC  
 ANIMAL NUMBER: 126/PRETEST= 126 SEX: MALE DOSE GROUP: 2 SACRIFICE STATUS: SACRIFICED MORIBUND  
 DATE OF DEATH: 09-SEP-85 STUDY DAY OF DEATH: 596 STUDY WEEK OF DEATH: 86 TERMINAL BODY WEIGHT: 373.00 (GMS)

<< GROSS ORGAN OBSERVATIONS >>  
 SEVERITY GROSS FREE-TEXT COMMENTS  
 PERITONEAL CAV. GROWTH(S) / MASS(ES) PRESENT MULTIPLE RAISED, DISSEMINATED, FIRM, WHITE, COVERING MESENTERY  
 TESTES ENLARGED PRESENT INTESITINE, PERIOMEUM LIVER, AND DIAPHRAGM. MESENTERIC ROOT  
 TESTES GROWTH(S) / MASS(ES) PRESENT THICKENED WITH SCIRRHOUS TISSUE.  
 LIVER GROWTH(S) / MASS(ES) PRESENT BILATERAL, IRREGULAR, YELLOW/WHITE  
 LIVER ADHESION(S) PRESENT FIRM, WHITE  
 DIAPHRAGM, VENTRAL ABDOMINAL WALL, STOMACH. ALSO INVOLVES  
 MASS, SPLEEN AND MESENTERY

<< MICROSCOPIC TISSUE OBSERVATIONS >>  
 TISSUE / HISTOPATHOLOGIC FINDINGS DISTRIBUTION (SEVERITY) / SPECIAL COMMENTS

- HEART  
 -CARDIOMYOPATHY NOT SPECIFIED(MILD)
- LUNGS  
 -MINERALIZATION OF PULMONARY ARTERIES NOT SPECIFIED(TRACE)
- SPLEEN  
 -N- PRESENCE OF METASTATIC SARCOMA SECONDARY NEOPLASIA FROM ORGAN ABDOMINAL CAVITY
- LYMPH NODES  
 REACTIVE HYPERPLASIA NOTED IN CERVICAL NODES.  
 RBC'S, PIGMENT AND HISTIOCYTIC INFILTRATION PRESENT IN  
 MEDIASTINAL NODES. MESENTERIC NODES ARE MISSING.  
 NOT SPECIFIED (PRESENT)
- RED BLOOD CELLS, HEMOSIDERIN AND/OR ERYTHROPHAGOCYTOSIS WITHIN  
 MEDULLARY SINUSES  
 -HISTIOCYTIC INFILTRATION, SUBCAPSULAR AND MEDULLARY SINUSES  
 -REACTIVE HYPERPLASIA  
 NOT SPECIFIED (PRESENT)  
 NOT SPECIFIED (PRESENT)
- LIVER  
 -COMPOUND RELATED INFLAMMATORY REACTION  
 -BILE DUCTULE EPITHELIAL HYPERPLASIA AND/OR CHOLANGIOFIBROSIS  
 NOT SPECIFIED (PRESENT)  
 NOT SPECIFIED(MILD)

Appendix J (cont.): PATHOLOGY INDIVIDUAL ANIMAL DATA

LETTERMAN ARMY INSTITUTE OF RESEARCH  
 DIV OF RES SUPP, PATH SERV GP  
 SPECIES: RAT/FISCHER-344  
 STUDY START DATE: 23-JAN-84  
 STUDY NUMBER: GLP83009  
 PRINTED: 21-NOV-89  
 PAGE: 268  
 STUDY TYPE: CHRONIC/2 YR CARCINOGENIC  
 ANIMAL NUMBER: 126/PRETEST# 126 SEX: MALE DOSE GROUP: 2 SACRIFICE STATUS: SACRIFICED MORIBUND  
 DATE OF DEATH: 09-SEP-85 STUDY DAY OF DEATH: 596 STUDY WEEK OF DEATH: 86 TERMINAL BODY WEIGHT: 373.00 (GMS)

TISSUE / HISTOPATHOLOGIC FINDINGS << MICROSCOPIC TISSUE OBSERVATIONS >>  
 DISTRIBUTION (SEVERITY) / SPECIAL COMMENTS

- LIVER .....  
 -HEPATOCTYIC VACUOLIZATION .....  
 -CYSTIC DEGENERATION .....  
 -N- PRESENCE OF METASTATIC SARCOMA
- KIDNEY .....  
 -PROGRESSIVE RENAL DISEASE .....  
 -N- PRESENCE OF METASTATIC SARCOMA
- PROSTATE .....  
 -BENIGN HYPERPLASIA .....  
 -N- PRESENCE OF METASTATIC SARCOMA
- SEMINAL VESICLE .....  
 -GENERALIZED ATROPHY .....  
 -N- PRESENCE OF METASTATIC SARCOMA
- EDIDIDYMS .....  
 -N- PRESENCE OF METASTATIC SARCOMA
- TESTES .....  
 -B- INTERSTITIAL CELL ADENOMA .....  
 -N- PRESENCE OF METASTATIC SARCOMA
- JEJUNUM .....  
 -N- PRESENCE OF METASTATIC SARCOMA
- PANCREAS .....  
 -B- ISLET CELL ADENOMA .....  
 -N- PRESENCE OF METASTATIC SARCOMA
- STOMACH .....  
 -N- PRESENCE OF METASTATIC SARCOMA

DIFFUSE(MILD)  
 NOT SPECIFIED (PRESENT)  
 SECONDARY NEOPLASM FROM ORGAN ABDOMINAL CAVITY

NOT SPECIFIED(TRACE)  
 SECONDARY NEOPLASM FROM ORGAN ABDOMINAL CAVITY

NOT SPECIFIED(TRACE)  
 SECONDARY NEOPLASM FROM ORGAN ABDOMINAL CAVITY

NOT SPECIFIED (PRESENT)  
 SECONDARY NEOPLASM FROM ORGAN ABDOMINAL CAVITY

SECONDARY NEOPLASM FROM ORGAN ABDOMINAL CAVITY

(PRESENT)  
 SECONDARY NEOPLASM FROM ORGAN ABDOMINAL CAVITY

SECONDARY NEOPLASM FROM ORGAN ABDOMINAL CAVITY

(PRESENT)  
 SECONDARY NEOPLASM FROM ORGAN ABDOMINAL CAVITY

Appendix J (cont.): **PATBIOLOGY INDIVIDUAL ANIMAL DATA**

LETTERMAN ARMY INSTITUTE OF RESEARCH  
DIV OF RES SUPP, PATH SERV GP  
SPECIES: RAT/FISCHER-344

INDIVIDUAL ANIMAL DATA REPORT

STUDY NUMBER: GLP83009

STUDY START DATE: 23-JAN-84

PRINTED: 21-NOV-89  
PAGE: 269

STUDY TYPE: CHRONIC/2 YR CARCINOGENIC

ANIMAL NUMBER: 126/PRETEST=

126 SEX: MALE

DATE OF DEATH: 09-SEP-85

STUDY DAY OF DEATH: 596

DOSE GROUP: 2

SACRIFICE STATUS: SACRIFICED MORIBUND

STUDY WEEK OF DEATH: 86

TERMINAL BODY WEIGHT: 373.00 (GMS)

TISSUE / HISTOPATHOLOGIC FINDINGS

<< M I C R O S C O P I C T I S S U E O B S E R V A T I O N S >>  
DISTRIBUTION (SEVERITY) / SPECIAL COMMENTS

STOMACH

- ULCERATION, NON-GLANDULAR AREA
- MUCOSAL AND/OR SUBMUCOSAL EDEMA

NOT SPECIFIED (PRESENT)  
NOT SPECIFIED (PRESENT)

MAMMARY GLANDS

- HYPERPLASIA AND/OR HYPERTROPHY OF THE ACINAR TISSUE
- GALACTOCELE(S)
- DILATATION (ECTASIA) OF DUCTS AND DUCTULES

NOT SPECIFIED (TRACE)  
NOT SPECIFIED (PRESENT)  
NOT SPECIFIED (PRESENT)

ABDOMINAL CAVITY

MISCELLANEOUS TISSUE  
THE SARCOMA IS PRESENT IN LIVER AND THERE ARE MULTIPLE METASTASES OR IMPLANTS WITHIN OR ON THE SURFACES OF MANY ABDOMINAL ORGANS. IN ALL AREAS THE TUMOR IS A WELL-DIFFERENTIATED OSTEOSARCOMA WITH ABUNDANT OSTEOID PRODUCTION AND EXTENSIVE MINERALIZATION.  
(PRESENT)

-M- SARCOMA, CELLULAR DIFFERENTIATION UNSPECIFIED

DIAPHRAGM

-N- PRESENCE OF METASTATIC SARCOMA

MISCELLANEOUS TISSUE  
SECONDARY NEOPLASM FROM ORGAN ABDOMINAL CAVITY

Appendix J (cont.): PATHOLOGY INDIVIDUAL ANIMAL DATA

LETTERMAN ARMY INSTITUTE OF RESEARCH  
 DIV OF RES SUPP, PATH SERV GP  
 SPECIES: RAT/FISCHER-344  
 STUDY START DATE: 23-JAN-84  
 STUDY NUMBER: GLP83009  
 PRINTED: 21-NOV-89  
 PAGE: 270  
 ANIMAL NUMBER: 127/PRETEST-127 SEX: MALE DOSE GROUP: 2 SACRIFICE STATUS: SACRIFICED MORIBUND  
 DATE OF DEATH: 26-NOV-85 STUDY DAY OF DEATH: 674 STUDY WEEK OF DEATH: 97 TERMINAL BODY WEIGHT: 425.00 (GMS)  
 STUDY TYPE: CHRONIC/2 YR CARCINOGENIC

ORGAN NAME SEVERITY GROSS FREE-TEXT COMMENTS  
 << GROSS ORGAN OBSERVATIONS >>  
 KEYWORDS / PHRASES SEVERITY GROSS FREE-TEXT COMMENTS  
 SPLEEN ENLARGED (SPLENOMEGALY) MARKED 9 X 2.5 X 1.5CM  
 SPLEEN DISCOLORATION PRESENT FOCAL, RED/YELLOW, .5CM DIAMETER, LATERAL ASPECT  
 TESTES GROWTH(S) / MASS(ES) PRESENT MULTIPLE, IRREGULAR, .1-.4CM DIAMETER, YELLOW/WHITE, BILATERAL  
 TESTES ATROPHIC / SMALL, UNILATERALLY PRESENT RIGHT, 1.5 X 1CM  
 TESTES ENLARGED PRESENT LEFT, 2.5 X 1.5CM  
 LIVER ADHESION(S) PRESENT DIAPHRAGM, VENTRAL ABDOMINAL WALL  
 LIVER DISCOLORATION PRESENT MEDIAL LOBE, FOCAL, PALE, SLIGHTLY RAISED, .5CM DIAMETER  
 LIVER PROMINENT LOBULAR MARKINGS PRESENT  
 KIDNEY DISCOLORATION PRESENT DARK BROWN WITH MULTIPLE PINPOINT LIGHT BROWN FOCI

TISSUE / HISTOPATHOLOGIC FINDINGS << MICROSCOPIC TISSUE OBSERVATIONS >>  
 DISTRIBUTION (SEVERITY) / SPECIAL COMMENTS

HEART  
 -CARDIOMYOPATHY NOT SPECIFIED(MODERATE)  
 -MEDIAL HYPERTROPHY OF MUSCULAR ARTERIES NOT SPECIFIED(MILD)

LUNGS  
 -N- LARGE GRANULAR LYMPHOCYTE LEUKEMIA, METASTATIC (PRESENT)

SPLEEN  
 -INFARCTION, CHRONIC  
 -N- LARGE GRANULAR LYMPHOCYTE LEUKEMIA, METASTATIC MULTI-FOCAL(MILD)  
 (PRESENT)

LYMPH NODES  
 -N- LARGE GRANULAR LYMPHOCYTE LEUKEMIA, METASTATIC (PRESENT)

LIVER  
 -COMPOUND RELATED INFLAMMATORY REACTION NOT SPECIFIED (PRESENT)  
 -BILE DUCTULE EPITHELIAL HYPERPLASIA AND/OR CHOLANGIOFIBROSIS NOT SPECIFIED(MARKED)  
 -CYSTIC DEGENERATION NOT SPECIFIED (PRESENT)

**Appendix J (cont.): PATHOLOGY INDIVIDUAL ANIMAL DATA**

LETTERMAN ARMY INSTITUTE OF RESEARCH  
 DIV OF RES SUPP, PATH SERV GP  
 SPECIES: RAT/FISCHER-344  
 STUDY START DATE: 23-JAN-84  
 STUDY NUMBER: GLP83009  
 PRINTED: 21-NOV-89  
 PAGE: 271  
 STUDY TYPE: CHRONIC/2 YR CARCINOGENIC

ANIMAL NUMBER: 127/PRETEST-  
 DATE OF DEATH: 26-NOV-85  
 DOSE GROUP: 2  
 SACRIFICE STATUS: SACRIFICED MORIBUND  
 SEX: MALE  
 STUDY WEEK OF DEATH: 97  
 TERMINAL BODY WEIGHT: 425.00 (GMS)

TISSUE / HISTOPATHOLOGIC FINDINGS  
 << M I C R O S C O P I C T I S S U E O B S E R V A T I O N S >>  
 DISTRIBUTION (SEVERITY) / SPECIAL COMMENTS

LIVER .....  
 -HEPATOCTIC DEGENERATIVE CHANGES (NON-NECROTIC) ..... NOT SPECIFIED(MODERATE)  
 -NECROSIS, HEPATOCTIC, INDIVIDUAL CELLS ..... MULTI-FOCAL(MILD)  
 -FOCUS OF CELLULAR ALTERATION - EOSINOPHILIC CELLS ..... NOT SPECIFIED(TRACE)  
 -N- LARGE GRANULAR LYMPHOCYTE LEUKEMIA, METASTATIC ..... (PRESENT)

KIDNEY ..... NOT SPECIFIED(MILD)  
 -PROGRESSIVE RENAL DISEASE

PROSTATE ..... NOT SPECIFIED(TRACE)  
 -BENIGN HYPERPLASIA

SEMINAL VESICLE ..... NOT SPECIFIED (PRESENT)  
 -GENERALIZED ATROPHY

TESTES ..... (PRESENT)  
 -B- INTERSTITIAL CELL ADENOMA

PANCREAS ..... DIFFUSE(TRACE)  
 -CHRONIC INFLAMMATION

MAMMARY GLANDS ..... NOT SPECIFIED(MODERATE)  
 -HYPERPLASIA AND/OR HYPERTROPHY OF THE ACINAR TISSUE ..... NOT SPECIFIED (PRESENT)  
 -DILATATION (ECTASIA) OF DUCTS AND DUCTULES

NOSE/TURBINATES ..... INFLAMMATORY INFILTRATE IS UNILATERAL AND INVOLVES NASO-LACRIMAL DUCT.  
 -MIXED INFLAMMATORY CELL INFILTRATION, NASAL CAVITY, SINUSES, FOCAL(TRACE)  
 TURBINATES, NASO-LACRIMAL DUCTS

BONE VERT ..... SPINAL CORD IN LUMBAR SEGMENT IS MISSING IN BOTH ORIGINAL AND RECU. FOCAL INFILTRATION OF LGLL IS NOTED BENEATH THE DURA IM THE LUMBAR SEGMENT.  
 -N- LARGE GRANULE LYMPHOCYTE LEUKEMIA, METASTATIC ..... (PRESENT)

ADRENAL .....

Appendix J (cont.): PATHOLOGY INDIVIDUAL ANIMAL DATA

LETTERMAN ARMY INSTITUTE OF RESEARCH  
DIV OF RES SUPP, PATH SERV GP  
SPECIES: RAT/FISCHER-344

INDIVIDUAL ANIMAL DATA REPORT  
STUDY NUMBER: GLP83009  
STUDY START DATE: 23-JAN-84

PRINTED: 21-NOV-89  
PAGE: 272

STUDY TYPE: CHRONIC/2 YR CARCINOGENIC

ANIMAL NUMBER: 127/PRETEST-      DOSE GROUP: 2      SACRIFICE STATUS: SACRIFICED MORIBUND  
DATE OF DEATH: 26-NOV-85      STUDY DAY OF DEATH: 674      STUDY WEEK OF DEATH: 97      TERMINAL BODY WEIGHT: 425.00 (GMS)

TISSUE / HISTOPATHOLOGIC FINDINGS      <<      M I C R O S C O P I C      T I S S U E      O B S E R V A T I O N S      >>  
DISTRIBUTION (SEVERITY) / SPECIAL COMMENTS

ADRENAL ..... (PRESENT)  
-B- PNEUROMOCYTOMA

EYES & OPTIC N. .... NOT SPECIFIED (PRESENT)  
-METAPLASTIC BONE FORMATION AND/OR MINERALIZATION, SCLERA

WHOLE BODY ..... (PRESENT)  
-M- LARGE GRANULAR LYMPHOCTIC LEUKEMIA

DIAPHRAGM ..... MISCELLANEOUS TISSUE  
-COMPOUND RELATED INFLAMMATORY REACTION      NOT SPECIFIED (PRESENT)

**Appendix J (cont.): PATHOLOGY INDIVIDUAL ANIMAL DATA**

LETTERMAN ARMY INSTITUTE OF RESEARCH  
 DIV OF RES SUPP, PATH SERV GP  
 SPECIES: RAT/FISCHER-344  
 STUDY NUMBER: GLP83009  
 STUDY START DATE: 23-JAN-84  
 STUDY TYPE: CHRONIC/2 R CARCINOGENIC  
 PRINTED: 21-NOV-89  
 P. GE: 273

ANIMAL NUMBER: 128/PRETEST= 128 SEX: MALE DOSE GROUP: 2 SACRIFICE STATUS: FINAL SACRIFICE  
 DATE OF DEATH: 05-FEB-86 STUDY DAY OF DEATH: 745 STUDY WEEK OF DEATH: 107 TERMINAL BODY WEIGHT: 373.00 (GMS)  
 << GROSS ORGAN OBSERVATIONS >>  
 SEVERITY GROSS FREE-TEXT COMMENTS  
 ORGAN NAME  
 LIVER ADHESION(S) PRESENT VENTRAL ABDOMINAL WALL  
 LIVER MODULE(S) PRESENT SLIGHTLY PALE, .6CM DIAMETER  
 TESTES ENLARGED PRESENT RIGHT, 3 X 1.75CM  
 TESTES GROWTH(S) / MASS(ES) PRESENT BILATERAL, MULTIPLE VARIABLY SIZED, YELLOW/BLACK  
 PITUITARY GLAND DISCOLORATION PRESENT FOCAL, DARK RED, .3CM DIAMETER

TISSUE / HISTOPATHOLOGIC FINDINGS  
 << MICROSCOPIC TISSUE OBSERVATIONS >>  
 DISTRIBUTION (SEVERITY) / SPECIAL COMMENTS

HEART ..... NOT SPECIFIED(MILD)  
 -CARDIOMYOPATHY  
 LYMPH NODES ..... REACTIVE HYPERPLASIA NOTED IN CERVICAL NODES.  
 -REACTIVE HYPERPLASIA  
 LIVER ..... NOT SPECIFIED (PRESENT)  
 -COMPOUND RELATED INFLAMMATORY REACTION  
 -BILE DUCTULE EPITHELIAL HYPERPLASIA AND/OR CHOLANGIOFIBROSIS  
 -FOCUS OF CELLULAR ALTERATION - BASOPHILIC  
 -HEPATOCTYIC VACUOLIZATION  
 -BENIGN HYPERPLASTIC NODULE(S)  
 -HEPATOCTYTE COALESCING MICROVESICULAR (FATTY) CHANGE LEADING TO NECROSIS AND MINERALIZATION  
 KIDNEY ..... NOT SPECIFIED(MILD)  
 -PROGRESSIVE RENAL DISEASE  
 PROSTATE ..... NOT SPECIFIED(MILD)  
 -CHRONIC PROSTATITIS  
 -BENIGN HYPERPLASIA  
 SEMINAL VESICLE ..... NOT SPECIFIED(TRACE)



**Appendix J (cont.): PATHOLOGY INDIVIDUAL ANIMAL DATA**

LETTERMAN ARMY INSTITUTE OF RESEARCH  
 DIV OF RES SUPP, PATH SERV GP  
 SPECIES: RAT/FISCHER-344  
 STUDY START DATE: 23-JAN-84  
 ANIMAL NUMBER: 128/PRETEST= 128 SEX: MALE DOSE GROUP: 2 SACRIFICE STATUS: FINAL SACRIFICE  
 DATE OF DEATH: 05-FEB-86 STUDY DAY OF DEATH: 745 STUDY WEEK OF DEATH: 107 TERMINAL BODY WEIGHT: 373.00 (GMS)  
 TISSUE / HISTOPATHOLOGIC FINDINGS << M I C R O S C O P I C T I S S U E O B S E R V A T I O N S >>  
 DISTRIBUTION (SEVERITY) / SPECIAL COMMENTS

PRINTED: 21-NOV-89  
 PAGE: 274

STUDY TYPE: CHRONIC/2 YR CARCINOGENIC

SEMINAL VESICLE ..... NOT SPECIFIED (PRESENT)  
 -GENERALIZED ATROPHY

TESTES ..... (PRESENT)  
 -B- INTERSTITIAL CELL ADENOMA

PANCREAS ..... (PRESENT)  
 -B- ISLET CELL ADENOMA

MAMMARY GLANDS ..... NOT SPECIFIED (TRACE)  
 -HYPERPLASIA AND/OR HYPERTROPHY OF THE ACINAR TISSUE  
 -DILATATION (ECTASIA) OF DUCTS AND DUCTULES NOT SPECIFIED (PRESENT)

NOSE/TURBINATES ..... CELLULAR INFILTRATE INVOLVES NASO-LACRIMAL DUCT.  
 -MIXED INFLAMMATORY CELL INFILTRATION, NASAL CAVITY, SINUSES, NOT SPECIFIED (MODERATE)  
 TURBINATES, NASO-LACRIMAL DUCTS

PITUITARY GLAND ..... (PRESENT)  
 -B- ADENOMA

EYES & OPTIC N. .... NOT SPECIFIED (MILD)  
 -RETINAL ATROPHY AND/OR DEGENERATION, UNILATERAL OR BILATERAL

Appendix J (cont.): PATHOLOGY INDIVIDUAL ANIMAL DATA

LETTERMAN ARMY INSTITUTE OF RESEARCH  
 DIV OF RES SUPP, PATH SERV GP  
 SPECIES: RAT/FISCHER-344  
 ANIMAL NUMBER: 129/PRETEST= 129 SEX: MALE DOSE GROUP: 2 SACRIFICE STATUS: FINAL SACRIFICE  
 DATE OF DEATH: 05-FEB-86 STUDY DAY OF DEATH: 745 STUDY WEEK OF DEATH: 107 TERMINAL BODY WEIGHT: 355.00 (GMS)  
 STUDY START DATE: 23-JAN-84 STUDY TYPE: CHRONIC/2 YR CARCINOGENIC  
 PRINTED: 21-NOV-89  
 PAGE: 275

<< GROSS ORGAN OBSERVATIONS >>  
 KEYWORDS / PHRASES SEVERITY GROSS FREE-TEXT COMMENTS  
 ADHESION(S) PRESENT MESENTERY  
 GROWTH(S) / MASS(ES) PRESENT BILATERAL, MULTIPLE VARIABLY SIZED, YELLOW

<< MICROSCOPIC TISSUE OBSERVATIONS >>  
 TISSUE / HISTOPATHOLOGIC FINDINGS DISTRIBUTION / SEVERITY / SPECIAL COMMENTS

HEART ..... NOT SPECIFIED(TRACE)  
 -CARDIOMYOPATHY

LYMPH NODES ..... REACTIVE HYPERPLASIA NOTED IN CERVICAL NODES.  
 RBC'S AND PIGMENT NOTED IN MEDIASTINAL NODE.  
 -RED BLOOD CELLS, HEMOSIDERIN AND/OR ERYTHROPHAGOCYTOSIS WITHIN NOT SPECIFIED (PRESENT)  
 MEDULLARY SINUSES NOT SPECIFIED (PRESENT)  
 -REACTIVE HYPERPLASIA NOT SPECIFIED (PRESENT)

LIVER ..... NOT SPECIFIED (PRESENT)  
 -COMPOUND RELATED INFLAMMATORY REACTION NOT SPECIFIED (MILD)  
 -BILE DUCTULE EPITHELIAL HYPERPLASIA AND/OR CHOLANGIOFIBROSIS NOT SPECIFIED(TRACE)  
 -HEPATOCTYCLE COALESCING MICROVESICULAR (FATTY) CHANGE LEADING TO NECROSIS AND MINERALIZATION

KIDNEY ..... NOT SPECIFIED(MILD)  
 -PROGRESSIVE RENAL DISEASE

PROSTATE ..... NOT SPECIFIED(TRACE)  
 -CHRONIC PROSTATITIS NOT SPECIFIED(TRACE)  
 -BENIGN HYPERPLASIA

TESTES ..... (PRESENT)  
 -B- INTERSTITIAL CELL ADENOMA

PANCREAS .....

Appendix J (cont.): PATHOLOGY INDIVIDUAL ANIMAL DATA

LETTERMAN ARMY INSTITUTE OF RESEARCH  
DIV OF RES SUPP, PATH SERV GP  
SPECIES: RAT/FISCHER-344

PRINTED: 21-NOV-89  
PAGE: 276

INDIVIDUAL ANIMAL DATA REPORT  
STUDY NUMBER: CLP83009

STUDY START DATE: 23-JAN-84

STUDY TYPE: CHRONIC/2 YR CARCINOGENIC

ANIMAL NUMBER: 129/PRETEST= 129 SEX: MALE DOSE GROUP: 2 SACRIFICE STATUS: FINAL SACRIFICE

DATE OF DEATH: 05-FEB-86 STUDY DAY OF DEATH: 745 STUDY WEEK OF DEATH: 107 TERMINAL BODY WEIGHT: 355.00 (GMS)

TISSUE / HISTOPATHOLOGIC FINDINGS << MICROSCOPIC TISSUE OBSERVATIONS >> DISTRIBUTION (SEVERITY) / SPECIAL COMMENTS

PANCREAS ..... NOT SPECIFIED(MILD)  
-ACINAR (EXOCRINE) ATROPHY

MAMMARY GLANDS ..... NOT SPECIFIED(TRACE)  
-HYPERPLASIA AND/OR HYPERTROPHY OF THE ACINAR TISSUE

EYES & OPTIC N. .... NOT SPECIFIED (PRESENT)  
-METAPLASTIC BONE FORMATION AND/OR MINERALIZATION, SCLERA

Appendix J (cont.): PATHOLOGY INDIVIDUAL ANIMAL DATA

LETTERMAN ARMY INSTITUTE OF RESEARCH  
 DIV OF RES SUPP. PATH SERV GP  
 SPECIES: RAT/FISCHER-344  
 ANIMAL NUMBER: 130/PRETEST-  
 DATE OF DEATH: 05-FEB-86  
 STUDY START DATE: 23-JAN-84  
 DOSE GROUP: 2  
 STUDY WEEK OF DEATH: 107  
 SACRIFICE STATUS: FINAL SACRIFICE  
 TERMINAL BODY WEIGHT: 384.00 (GMS)  
 STUDY TYPE: CHRONIC/2 YR CARCINOGENIC

PRINTED: 21-NOV-89  
 PAGE: 277

INDIVIDUAL ANIMAL DATA REPORT  
 STUDY NUMBER: GLP83009  
 STUDY START DATE: 23-JAN-84  
 DOSE GROUP: 2  
 STUDY WEEK OF DEATH: 107  
 SACRIFICE STATUS: FINAL SACRIFICE  
 TERMINAL BODY WEIGHT: 384.00 (GMS)  
 STUDY TYPE: CHRONIC/2 YR CARCINOGENIC

ORGAN NAME  
 SEVERITY  
 GROSS ORGAN OBSERVATIONS  
 KEYWORDS / PHRASES  
 ADMESION(S)  
 ENLARGED (SPLENOMEGALY)  
 GROWTH(S) / MASS(ES)  
 ENLARGED  
 GRANULAR SURFACE  
 PRESENT  
 MARKED  
 PRESENT  
 PRESENT  
 PRESENT  
 VENTRAL ABDOMINAL WALL  
 7 X 1.75CM  
 BILATERAL, MULTIPLE VARIABLY SIZED, YELLOW

TISSUE / HISTOPATHOLOGIC FINDINGS  
 OBSERVATIONS  
 DISTRIBUTION (SEVERITY) / SPECIAL COMMENTS

THYROID GLANDS  
 -PARA-FOLLICULAR CELL HYPERPLASIA ("C" CELL, LIGHT CELL)  
 NOT SPECIFIED (TRACE)

HEART  
 -CARDIOMYOPATHY  
 -MEDIAL HYPERTROPHY OF MUSCULAR ARTERIES  
 NOT SPECIFIED (MILD)  
 NOT SPECIFIED (MILD)

LUNGS  
 -M- LARGE GRANULAR LYMPHOCYTE LEUKEMIA, METASTATIC  
 (PRESENT)

SPLEEN  
 -M- LARGE GRANULAR LYMPHOCYTE LEUKEMIA, METASTATIC  
 (PRESENT)

LYMPH NODES  
 -M- LARGE GRANULAR LYMPHOCYTE LEUKEMIA, METASTATIC  
 -REACTIVE HYPERPLASIA  
 REACTIVE HYPERPLASIA NOTED IN CERVICAL NODES.  
 METASTATIC LGLL NOTED IN MEDIASTINAL NODES.  
 (PRESENT)  
 NOT SPECIFIED (PRESENT)

LIVER  
 -COMPOUND RELATED INFLAMMATORY REACTION  
 -BILE DUCTULE EPITHELIAL HYPERPLASIA AND/OR CHOLANGIOFIBROSIS  
 -CYSTIC DEGENERATION  
 -HEPATOCTYIC DEGENERATIVE CHANGES (NON-NECROTIC)  
 NOT SPECIFIED (PRESENT)  
 NOT SPECIFIED (MILD)  
 NOT SPECIFIED (PRESENT)  
 NOT SPECIFIED (MODERATE)

Appendix J (cont.): PATHOLOGY INDIVIDUAL ANIMAL DATA

LETTERMAN ARMY INSTITUTE OF RESEARCH  
 DIV OF RES SUPP, PATH SERV GP  
 SPECIES: RAT/FISCHER-344  
 STUDY START DATE: 23-JAN-84  
 STUDY NUMBER: GLP83009  
 PRINTED: 21-NOV-89  
 PAGE: 278  
 STUDY TYPE: CHRONIC/2 YR CARCINOGENIC  
 ANIMAL NUMBER: 130/PRETEST=  
 DATE OF DEATH: 05-FEB-86  
 SEX: MALE  
 DOSE GROUP: 2  
 SACRIFICE STATUS: FINAL SACRIFICE  
 STUDY DAY OF DEATH: 745  
 STUDY WEEK OF DEATH: 107  
 TERMINAL BODY WEIGHT: 384.00 (GMS)

TISSUE / HISTOPATHOLOGIC FINDINGS  
 << M I C R O S C O P I C T I S S U E O B S E R V A T I O N S >>  
 DISTRIBUTION (SEVERITY) / SPECIAL COMMENTS

- LIVER ..... NOT SPECIFIED(MODERATE)
- NECROSIS, PERIACINAR (PRESENT)
- N- LARGE GRANULAR LYMPHOCYTE LEUKEMIA, METASTATIC
- KIDNEY ..... NOT SPECIFIED(MODERATE)
- PROGRESSIVE RENAL DISEASE (PRESENT)
- N- LARGE GRANULAR LYMPHOCYTE LEUKEMIA, METASTATIC
- PROSTATE ..... NOT SPECIFIED(TRACE)
- CHRONIC PROSTATITIS NOT SPECIFIED(TRACE)
- BENIGN HYPERPLASIA NOT SPECIFIED(TRACE)
- SEMINAL VESICLE ..... NOT SPECIFIED (PRESENT)
- GENERALIZED ATROPHY (PRESENT)
- TESTES ..... (PRESENT)
- B- INTERSTITIAL CELL ADENOMA (PRESENT)
- PANCREAS ..... NOT SPECIFIED(TRACE)
- ACINAR (EXOCRINE) ATROPHY (PRESENT)
- N- LARGE GRANULAR LYMPHOCYTE LEUKEMIA, METASTATIC
- MAMMARY GLANDS ..... NOT SPECIFIED(MODERATE)
- HYPERPLASIA AND/OR HYPERTROPHY OF THE ACINAR TISSUE (PRESENT)
- BONE, STERNUM ..... (PRESENT)
- N- LARGE GRANULE LYMPHOCYTE LEUKEMIA, METASTATIC
- BONE, FEMUR ..... (PRESENT)
- N- LARGE GRANULE LYMPHOCYTE LEUKEMIA, METASTATIC
- BONE VERT ..... (PRESENT)

Appendix J (cont.): PATHOLOGY INDIVIDUAL ANIMAL DATA

LETTERMAN ARMY INSTITUTE OF RESEARCH  
DIV OF RES SUPP, PATH SERV GP  
SPECIES: RAT/FISCHER-344

INDIVIDUAL ANIMAL DATA REPORT  
STUDY NUMBER: GLP83009  
STUDY START DATE: 23-JAN-84

PRINTED: 21-NOV-89  
PAGE: 279  
STUDY TYPE: CHRONIC/2 YR CARCINOGENIC

ANIMAL NUMBER: 130/PRETEST# 130 SEX: MALE DOSE GROUP: 2 SACRIFICE STATUS: FINAL SACRIFICE  
DATE OF DEATH: 05-FEB-86 STUDY DAY OF DEATH: 745 STUDY WEEK OF DEATH: 107 TERMINAL BODY WEIGHT: 384.00 (GMS)

<< MICROSCOPIC TISSUE OBSERVATIONS >>  
DISTRIBUTION (SEVERITY) / SPECIAL COMMENTS

BONE VERT .....  
-M- LARGE GRANULE LYMPHOCYTE LEUKEMIA, METASTATIC (PRESENT)

PITUITARY GLAND .....  
-B- ADENOMA (PRESENT)

EYES & OPTIC N. ....  
-METAPLASTIC BONE FORMATION AND/OR MINERALIZATION, SCLERA NOT SPECIFIED (PRESENT)

WHOLE BODY .....  
-M- LARGE GRANULAR LYMPHOCYTTIC LEUKEMIA (PRESENT)

**Appendix J (cont.): PATHOLOGY INDIVIDUAL ANIMAL DATA**

LETTERMAN ARMY INSTITUTE OF RESEARCH  
 DIV OF RES SUPP, PATH SERV GP  
 SPECIES: RAT/FISCHER-344

INDIVIDUAL ANIMAL DATA REPORT  
 STUDY NUMBER: GLP83009

PRINTED: 21-NOV-89  
 PAGE: 280

STUDY START DATE: 23-JAN-84

STUDY TYPE: CHRONIC/2 YR CARCINOGENIC

ANIMAL NUMBER: 131/PRETEST= 131 SEX: MALE DOSE GROUP: 2 SACRIFICE STATUS: FINAL SACRIFICE  
 DATE OF DEATH: 05-FEB-86 STUDY DAY OF DEATH: 745 STUDY WEEK OF DEATH: 107 TERMINAL BODY WEIGHT: 340.00 (GMS)

<< GROSS ORGAN OBSERVATIONS >>  
 SEVERITY GROSS FREE-TEXT COMMENTS  
 KEYWORDS / PHRASES  
 ADHESION(S)  
 LIVER PRESENT VENTRAL ABDOMINAL WALL  
 SPLEEN STRICTURE PRESENT FOCAL, .3CM DIAMETER  
 ADRENAL DISCOLORATION PRESENT FOCAL, .1CM DIAMETER, BLACK  
 TESTES GROWTH(S) / MASS(ES) PRESENT BILATERAL, MULTIPLE VARIABLY SIZED, YELLOW/BLACK

<< MICROSCOPIC TISSUE OBSERVATIONS >>  
 DISTRIBUTION (SEVERITY) / SPECIAL COMMENTS  
 TISSUE / HISTOPATHOLOGIC FINDINGS

PARATHYROID ..... TISSUE IS MISSING  
 HEART ..... NOT SPECIFIED (TRACE)  
 -CARDIOMYOPATHY  
 LUNGS ..... NOT SPECIFIED (TRACE)  
 -MINERALIZATION OF PULMONARY ARTERIES  
 LYMPH NODES ..... DILATED SINUSES NOTED IN MESENTERIC NODES.  
 -DILATED AND/OR CYSTIC MEDULLARY SINUSES ..... NOT SPECIFIED (PRESENT)  
 LIVER .....  
 -COMPOUND RELATED INFLAMMATORY REACTION ..... NOT SPECIFIED (PRESENT)  
 -BILE DUCTULE EPITHELIAL HYPERPLASIA AND/OR CHOLANGIOFIBROSIS ..... NOT SPECIFIED (MILD)  
 -HEPATITIS ..... MULTI-FOCAL (MILD)  
 -HEPATOCTYE COALESCING MICROVESICULAR (FATTY) CHANGE LEADING TO ..... MULTI-FOCAL (MILD)  
 NECROSIS AND MINERALIZATION  
 KIDNEY ..... NOT SPECIFIED (MILD)  
 -PROGRESSIVE RENAL DISEASE  
 SEMINAL VESICLE ..... NOT SPECIFIED (PRESENT)  
 -GENERALIZED ATROPHY  
 TESTES .....

Appendix J (cont.): PATHOLOGY INDIVIDUAL ANIMAL DATA

LETTERMAN ARMY INSTITUTE OF RESEARCH  
 DIV OF RES SUPP, PATH SERV GP  
 SPECIES: RAT/FISCHER-344

INDIVIDUAL ANIMAL DATA REPORT  
 STUDY NUMBER: GLP83009

STUDY START DATE: 23-JAN-84

PRINTED: 21-NOV-89  
 PAGE: 281

ANIMAL NUMBER: 131/PRETEST= 131 SEX: MALE DOSE GROUP: 2 SACRIFICE STATUS: FINAL SACRIFICE  
 DATE OF DEATH: 05-FEB-86 STUDY DAY OF DEATH: 745 STUDY WEEK OF DEATH: 107 TERMINAL BODY WEIGHT: 340.00 (GMS)

STUDY TYPE: CHRONIC/2 YR CARCINOGENIC

TISSUE / HISTOPATHOLOGIC FINDINGS << MICROSCOPIC TISSUE OBSERVATIONS >>  
 DISTRIBUTION (SEVERITY) / SPECIAL COMMENTS

- TESTES ..... (PRESENT)
- B- INTERSTITIAL CELL ADENOMA
- PANCREAS ..... FOCAL(MODERATE)
- ACINAR (EXOCRINE) ATROPHY ..... NOT SPECIFIED (PRESENT)
- PERIARTERITIS NODOSA
- ADRENAL ..... NOT SPECIFIED (PRESENT)
- CORTICAL MODULAR HYPERPLASIA
- EYES & OPTIC N. .... NOT SPECIFIED (PRESENT)
- METAPLASTIC BONE FORMATION AND/OR MINERALIZATION, SCLERA
- MEDIASTINUM ..... MISCELLANEOUS TISSUE
- CHRONIC INFLAMMATION ..... NOT SPECIFIED(TRACE)
- DIAPHRAGM ..... MISCELLANEOUS TISSUE
- COMPOUND RELATED INFLAMMATORY REACTION ..... NOT SPECIFIED (PRESENT)



**Appendix J (cont.): PATHOLOGY INDIVIDUAL ANIMAL DATA**

LETTERMAN ARMY INSTITUTE OF RESEARCH  
 DIV OF RES SUPP, PATH SERV GP  
 SPECIES: RAT/FISCHER-344

PRINTED: 21-NOV-89  
 PAGE: 283

INDIVIDUAL ANIMAL DATA REPORT  
 STUDY NUMBER: GLP83009  
 STUDY START DATE: 23-JAN-84

ANIMAL NUMBER: 133/PRETEST= 133 SEX: MALE DOSE GROUP: 2 SACRIFICE STATUS: FINAL SACRIFICE  
 DATE OF DEATH: 05-FEB-86 STUDY DAY OF DEATH: 745 STUDY WEEK OF DEATH: 107 TERMINAL BODY WEIGHT: 400.00 (GMS)

STUDY TYPE: CHRONIC/2 YR CARCINOGENIC

ORGAN NAME SEVERITY GROSS FREE-TEXT COMMENTS  
 TESTES PRESENT RIGHT, ONE .2CM DIAMETER, YELLOW  
 LIVER PRESENT VENTRAL ABDOMINAL WALL  
 PITUITARY GLAND PRESENT DARK RED, .4MM DIAMETER

TISSUE / HISTOPATHOLOGIC FINDINGS OBSERVATIONS / SPECIAL COMMENTS  
 << MICROSCOPIC TISSUE OBSERVATIONS >>

- THYROID GLANDS (PRESENT)
- B- PARA-FOLLICULAR CELL ADENOMA
- HEART NOT SPECIFIED(TRACE)
- CARDIOMYOPATHY
- LUNGS NOT SPECIFIED(TRACE)
- MINERALIZATION OF PULMONARY ARTERIES
- LIVER NOT SPECIFIED (PRESENT)
- COMPOUND RELATED INFLAMMATORY REACTION NOT SPECIFIED(MILD)
- BILE DUCTULE EPITHELIAL HYPERPLASIA AND/OR CHOLANGIOFIBROSIS NOT SPECIFIED(TRACE)
- FOCUS OF CELLULAR ALTERATION - BASOPHILIC FOCAL(TRACE)
- TELANGIECTASIS FOCAL(MILD)
- FOCUS OF CELLULAR ALTERATION - CLEAR CELLS NOT SPECIFIED(MILD)
- BENIGN HYPERPLASTIC NODULE(S)
- KIDNEY NOT SPECIFIED(MODERATE)
- PROGRESSIVE RENAL DISEASE
- PROSTATE NOT SPECIFIED(MODERATE)
- CHRONIC PROSTATITIS NOT SPECIFIED(TRACE)
- BENIGN HYPERPLASIA
- TESTES

Appendix J (cont.): **PATHOLOGY INDIVIDUAL ANIMAL DATA**

LETTERMAN ARMY INSTITUTE OF RESEARCH  
 DIV OF RES SUPP, PATH SERV GP  
 SPECIES: RAT/FISCHER-344

INDIVIDUAL ANIMAL DATA REPORT  
 STUDY NUMBER: GLP83009

STUDY START DATE: 23-JAN-84

ANIMAL NUMBER: 133/PRETEST=  
 DATE OF DEATH: 05-FEB-86

133 SEX: MALE  
 STUDY DAY OF DEATH: 745

DOSE GROUP: 2  
 STUDY WEEK OF DEATH: 107

SACRIFICE STATUS: FINAL SACRIFICE  
 TERMINAL BODY WEIGHT: 400.00 (GMS)

STUDY TYPE: CHRONIC/2 YR CARCINOGENIC

<< MICROSCOPIC TISSUE OBSERVATIONS >>  
 DISTRIBUTION (SEVERITY) / SPECIAL COMMENTS

PRINTED: 21-NOV-89  
 PAGE: 284

- TESTES ..... NOT SPECIFIED (TRACE)
- INTERSTITIAL CELL HYPERPLASIA
- SKELETAL MUSCLE ..... NOT SPECIFIED (MILD)
- CHRONIC MYOSITIS
  - CHRONIC INFLAMMATION RESTRICTED TO FASCIA
- SKIN ..... THERE IS DIFFUSE INFILTRATION OF HISTIOCYTIC CELLS IN THE FASCIA ADJACENT TO THE PANNICULUS MUSCLE. THIS IS SIMILAR TO THE LESION THAT WAS OBSERVED AND CODED UNDER SKELETAL MUSCLE.
- ADRENAL ..... NOT SPECIFIED (TRACE)
- LIPIDOSIS
- PITUITARY GLAND ..... (PRESENT)
- B- ADEHOMA
- EYES & OPTIC N. .... NOT SPECIFIED (PRESENT)
- METAPLASTIC BONE FORMATION AND/OR MINERALIZATION, SCLERA

Appendix J (cont.): PATHOLOGY INDIVIDUAL ANIMAL DATA

LETTERMAN ARMY INSTITUTE OF RESEARCH  
 DIV OF RES SUPP, PATH SERV GP  
 SPECIES: RAT/FISCHER-344  
 STUDY START DATE: 23-JAN-84  
 STUDY NUMBER: GLP83009  
 PRINTED: 21-NOV-89  
 PAGE: 285

ANIMAL NUMBER: 134/PRETEST-134  
 DATE OF DEATH: 24-OCT-85  
 SEX: MALE  
 DOSE GROUP: 2  
 SACRIFICE STATUS: SACRIFICED MORIBUND  
 STUDY WEEK OF DEATH: 92  
 TERMINAL BODY WEIGHT: 387.00 (GMS)  
 STUDY TYPE: CHRONIC/2 YR CARCINOGENIC

ORGAN NAME	KEYWORDS / PHRASES	ORGAN OBSERVATIONS	SEVERITY	GROSS FREE-TEXT COMMENTS
SPLEEN	ENLARGED (SPLENOMEGALY)	MARKED		
TESTES	ENLARGED	6.5 X 1.5 X 1CM		
TESTES	ATROPHIC / SMALL, UNILATERALLY	PRESENT LEFT, 2.5 X 1.5CM		
TESTES	GROWTH(S) / MASS(ES)	PRESENT RIGHT, 1.5 X 1CM		
LIVER	ADHESION(S)	PRESENT BILATERAL, MULTIPLE VARIABLY SIZED, YELLOW/WHITE		
LIVER	PROMINENT LOBULAR MARKINGS	PRESENT DIAPHRAGM		

TISSUE / HISTOPATHOLOGIC FINDINGS  
 << MICROSCOPIC ISSUE OBSERVATIONS >>  
 DISTRIBUTION (SEVERITY) / SPECIAL COMMENTS

THYROID GLANDS  
 -B- PARA-FOLLICULAR CELL ADENOMA (PRESENT)

HEART  
 -CARDIOMYOPATHY NOT SPECIFIED (TRACE)

LUNGS  
 -M- LARGE GRANULAR LYMPHOCYTE LEUKEMIA, METASTATIC (PRESENT)  
 -ALVEOLAR HEMORRHAGE MULTI-FOCAL (PRESENT)

SPLEEN  
 -N- LARGE GRANULAR LYMPHOCYTE LEUKEMIA, METASTATIC (PRESENT)

LYMPH NODES  
 -N- LARGE GRANULAR LYMPHOCYTE LEUKEMIA, METASTATIC LGLL NOTED IN MEDIASTINAL NODES.  
 (PRESENT)

LIVER  
 -COMPOUND RELATED INFLAMMATORY REACTION NOT SPECIFIED (PRESENT)  
 -BILE DUCTULE EPITHELIAL HYPERPLASIA AND/OR CHOLANGIOFIBROSIS NOT SPECIFIED (MODERATE)  
 -HEPATOCTYIC VACUOLIZATION MULTI-FOCAL (TRACE)  
 -HEPATOCTYIC DEGENERATIVE CHANGES (NON-NECROTIC) NOT SPECIFIED (MODERATE)  
 -NECROSIS, HEPATOCTYIC, INDIVIDUAL CELLS MULTI-FOCAL (MILD)

Appendix J (cont.): PATHOLOGY INDIVIDUAL ANIMAL DATA

LETTERMAN ARMY INSTITUTE OF RESEARCH  
 DIV OF RES SUPP, PATH SERV GP  
 SPECIES: RAT/FISCHER-344

INDIVIDUAL ANIMAL DATA REPORT  
 STUDY NUMBER: GLP83009  
 STUDY START DATE: 23-JAN-84

PRINTED: 21-NOV-89  
 PAGE: 286  
 STUDY TYPE: CHRONIC/2 YR CARCINOGENIC

ANIMAL NUMBER: 134/PRETEST  
 DOSE GROUP: 2  
 SACRIFICE STATUS: SACRIFICED MORIBUND

DATE OF DEATH: 24-OCT-85  
 STUDY DAY OF DEATH: 641  
 STUDY WEEK OF DEATH: 92  
 TERMINAL BODY WEIGHT: 387.00 (GMS)

SEX: MALE  
 OBSERVATIONS >>

TISSUE / HISTOPATHOLOGIC FINDINGS  
 << M I C R O S C O P I C T I S S U E O B S E R V A T I O N S >>  
 DISTRIBUTION (SEVERITY) / SPECIAL COMMENTS

LIVER  
 -W- LARGE GRANULAR LYMPHOCYTE LEUKEMIA, METASTATIC (PRESENT)  
 -FIBROSIS, PARENCHYMAL (SCARRING) FOCAL(TRACE)

KIDNEY  
 -PROGRESSIVE RENAL DISEASE NOT SPECIFIED(MILD)

URINARY BLADDER  
 -CHRONIC INFLAMMATORY CELL INFILTRATION FOCAL(TRACE)

PROSTATE  
 -CHRONIC PROSTATITIS NOT SPECIFIED(MILD)  
 -BENIGN HYPERPLASIA NOT SPECIFIED(MILD)

SEMINAL VESICLE  
 -GENERALIZED ATROPHY NOT SPECIFIED (PRESENT)

TESTES  
 -B- INTERSTITIAL CELL ADENOMA (PRESENT)

PANCREAS  
 -ACINAR (EXOCRINE) ATROPHY DIFFUSE(MODERATE)  
 -CHRONIC INFLAMMATION DIFFUSE(MILD)

STOMACH  
 -MUCOSAL AND/OR SUBMUCOSAL EDEMA NOT SPECIFIED (PRESENT)  
 -EROSION AND/OR ULCERATION OF THE GLANDULAR MUCOSA FOCAL(MILD)

MAMMARY GLANDS  
 -HYPERPLASIA AND/OR HYPERTROPHY OF THE ACINAR TISSUE NOT SPECIFIED(TRACE)  
 -DILATATION (ECTASIA) OF DUCTS AND DUCTULES NOT SPECIFIED (PRESENT)

Appendix J (cont.): PATHOLOGY INDIVIDUAL ANIMAL DATA

LETTERMAN ARMY INSTITUTE OF RESEARCH  
DIV OF RES SUPP, PATH SERV GP  
SPECIES: RAT/FISCHER-344

INDIVIDUAL ANIMAL DATA REPORT  
STUDY NUMBER: GLP83009

PRINTED: 21-NOV-89  
PAGE: 287

STUDY START DATE: 23-JAN-84

STUDY TYPE: CHRONIC/2 YR CARCINOGENIC

ANIMAL NUMBER: 134/PRETEST= 134 SEX: MALE DOSE GROUP: 2 SACRIFICE STATUS: SACRIFICED MORIBUND  
DATE OF DEATH: 24-OCT-85 STUDY DAY OF DEATH: 641 STUDY WEEK OF DEATH: 92 TERMINAL BODY WEIGHT: 387.00 (GMS)

<< MICROSCOPIC TISSUE OBSERVATIONS >>  
DISTRIBUTION (SEVERITY) / SPECIAL COMMENTS

NOSE/TURBINATES ..... CELLULAR INFILTRATE IS ADJACENT NASO-LACRIMAL DUCT.  
-MIXED INFLAMMATORY CELL INFILTRATION, NASAL CAVITY, SINUSES,  
TURBINATES, NASO-LACRIMAL DUCTS NOT SPECIFIED(MILD)

EYES & OPTIC N. ....  
-CORNEAL MINERALIZATION FOCAL(TRACE)  
-CORNEAL VASCULARIZATION NOT SPECIFIED(MILD)

WHOLE BODY .....  
-M- LARGE GRANULAR LYMPHOCYTTIC LEUKEMIA (PRESENT)

DIAPHRAGM ..... MISCELLANEOUS TISSUE  
-COMPOUND RELATED INFLAMMATORY REACTION NOT SPECIFIED (PRESENT)

Appendix J (cont.): PATHOLOGY INDIVIDUAL ANIMAL DATA

LETTERMAN ARMY INSTITUTE OF RESEARCH  
 DIV OF RES SUPP, PATH SERV GP  
 SPECIES: RAT/FISCHER-344

INDIVIDUAL ANIMAL DATA REPORT  
 STUDY NUMBER: GLP83009

STUDY START DATE: 23-JAN-84

STUDY TYPE: CHRONIC/2 YR CARCINOGENIC

PRINTED: 21-NOV-89  
 PAGE: 288

ANIMAL NUMBER: 135/PRETEST  
 DATE OF DEATH: 05-FEB-86  
 SEX: MALE  
 DOSE GROUP: 2  
 SACRIFICE STATUS: FINAL SACRIFICE

STUDY DAY OF DEATH: 745  
 STUDY WEEK OF DEATH: 107  
 TERMINAL BODY WEIGHT: 385.00 (GMS)

ORGAN NAME  
 TESTES  
 LIVER  
 LIVER  
 PITUITARY GLAND

GROSS ORGAN OBSERVATIONS  
 KEYWORDS / PHRASES  
 SEVERITY GROSS FREE-TEXT COMMENTS  
 GROWTH(S) / MASS(ES)  
 ADHESION(S)  
 MODULE(S)  
 ENLARGED

PRESENT RIGHT, ONE .3CM DIAMETER, YELLOW  
 PRESENT VENTRAL ABDOMINAL WALL  
 PRESENT RAISED, .6CM DIAMETER  
 PRESENT DARK RED, .5 X .6CM

TISSUE / HISTOPATHOLOGIC FINDINGS  
 MICROSCOPIC TISSUE OBSERVATIONS  
 DISTRIBUTION (SEVERITY) / SPECIAL COMMENTS

HEART  
 -CARDIOMYOPATHY  
 LUNGS  
 -MINERALIZATION OF PULMONARY ARTERIES  
 -ALVEOLAR HEMORRHAGE

THYMUS  
 LYMPH NODES  
 -REACTIVE HYPERPLASIA

LIVER  
 -COMPOUND RELATED INFLAMMATORY REACTION  
 -BILE DUCTULE EPITHELIAL HYPERPLASIA AND/OR CHOLANGIOFIBROSIS  
 -HEPATITIS  
 -FOCUS OF CELLULAR ALTERATION - BASOPHILIC  
 -BENIGN HYPERPLASTIC NODULE(S)

KIDNEY  
 -PROGRESSIVE RENAL DISEASE

PROSTATE  
 -CHRONIC PROSTATITIS  
 -BENIGN HYPERPLASIA

NOT SPECIFIED(MILD)  
 NOT SPECIFIED(TRACE)  
 NOT SPECIFIED (PRESENT)  
 TISSUE IS MISSING  
 REACTIVE HYPERPLASIA NOTED IN CERVICAL NODES.  
 NOT SPECIFIED (PRESENT)  
 THE NODULE DESCRIBED GROSSLY IS A BENIGN HYPERTROPHIC NODULE.  
 NOT SPECIFIED (PRESENT)  
 NOT SPECIFIED(MODERATE)  
 MULTI-FOCAL(TRACE)  
 MULTI-FOCAL(TRACE)  
 NOT SPECIFIED(MILD)  
 NOT SPECIFIED(MODERATE)  
 NOT SPECIFIED(MILD)  
 NOT SPECIFIED(TRACE)

Appendix J (cont.): PATHOLOGY INDIVIDUAL ANIMAL DATA

LETTERMAN ARMY INSTITUTE OF RESEARCH  
 DIV OF RES SUPP, PATH SERV GP  
 SPECIES: RAT/FISCHER-344  
 ANIMAL NUMBER: 135/PRETEST-  
 DATE OF DEATH: 05-FEB-86  
 TISSUE / HISTOPATHOLOGIC FINDINGS

INDIVIDUAL ANIMAL DATA REPORT  
 STUDY NUMBER: GLP83009  
 STUDY START DATE: 23-JAN-84  
 DOSE GROUP: 2  
 SEX: MALE  
 STUDY DAY OF DEATH: 745  
 SACRIFICE STATUS: FINAL SACRIFICE  
 TERMINAL BODY WEIGHT: 385.00 (GMS)

STUDY TYPE: CHRONIC/2 YR CARCINOGENIC  
 OBSERVATIONS  
 DISTRIBUTION (SEVERITY) / SPECIAL COMMENTS

PRINTED: 21-NOV-89  
PAGE: 289

TESTES ..... A SMALL YELLOW GROWTH WAS DESCRIBED IN THE RIGHT TESTIS. NO  
 NO CORRESPONDING LESION WAS PRESENT IN HISTOLOGIC SECTIONS OF  
 TESTIS. THIS LESION WAS PROBABLY A SMALL INTERSTITIAL ADENOMA  
 THAT WAS NOT INCLUDED IN THE PLANE OF SECTION.

ADRENAL ..... MULTI-FOCAL(MILD)  
 -FOCUS OF CELLULAR ALTERATION, VACUOLATED

PITUITARY GLAND ..... (PRESENT)  
 -B- ADENOMA

EYES & OPTIC N. .... NOT SPECIFIED (PRESENT)  
 -METAPLASTIC BONE FORMATION AND/OR MINERALIZATION, SCLERA

Appendix J (cont.): **PATHOLOGY INDIVIDUAL ANIMAL DATA**

LETTERMAN ARMY INSTITUTE OF RESEARCH  
 DIV OF RES SUPP, PATH SERV GP  
 SPECIES: RAT/FISCHER-344  
 STUDY START DATE: 23-JAN-84  
 INDIVIDUAL ANIMAL DATA REPORT  
 STUDY NUMBER: GLP83009  
 PRINTED: 21-NOV-89  
 PAGE: 290  
 ANIMAL NUMBER: 136/PRETEST= 136 SEX: MALE DOSE GROUP: 2 SACRIFICE STATUS: FINAL SACRIFICE  
 DATE OF DEATH: 05-FEB-86 STUDY DAY OF DEATH: 745 STUDY WEEK OF DEATH: 107 TERMINAL BODY WEIGHT: 385.00 (GMS)  
 STUDY TYPE: CHRONIC/2 YR CARCINOGENIC

ORGAN NAME << GROSS ORGAN OBSERVATIONS >>  
 SEVERITY GROSS FREE-TEXT COMMENTS  
 LIVER PRESENT VENTRAL ABDOMINAL WALL  
 LIVER GROWTH(S) / MASS(ES) PRESENT SEMI-FIRM, WHITE, 2.5CM DIAMETER  
 TESTES ATROPHIC / SMALL, UNILATERALLY PRESENT RIGHT, 1.5 X 1CM  
 TESTES GROWTH(S) / MASS(ES) PRESENT BILATERAL, MULTIPLE VARIABLY SIZED, YELLOW  
 PITUITARY GLAND ENLARGED PRESENT PALE, .4CM DIAMETER

TISSUE / HISTOPATHOLOGIC FINDINGS << MICROSCOPIC TISSUE OBSERVATIONS >>  
 DISTRIBUTION (SEVERITY) / SPECIAL COMMENTS

BRAIN  
 THERE IS A LESION IN THE VENTRAL PART OF THE MEDULLA OBLONGATA CONSISTING OF NECROSIS, LARGE IRREGULAR BLOOD FILLED SPACES THAT ARE NOT LINED BY ENDOTHELIUM, AND AN ADJACENT INFILTRATION OF MONONUCLEAR INFLAMMATORY CELLS, MANY OF WHICH ARE FILLED WITH BROWN GRANULAR PIGMENT. ALTHOUGH NO PITUITARY TUMOR CELLS ARE PRESENT IN THE SECTION AVAILABLE, THERE IS A LARGE PITUITARY ADENOMA PRESENT IN SECTION #18. THE LESION IN THE BRAIN IS MOST LIKELY THE RESULT OF MECHANICAL PRESSURE EXERTED BY THE ADJACENT PITUITARY TUMOR.  
 FOCAL(MILD)  
 (PRESENT)

-LIQUIFICATION NECROSIS  
 -1-PITUITARY TUMOR INVASION  
 THYROID GLANDS ..... NOT SPECIFIED(TRACE)  
 -PARA-FOLLICULAR CELL HYPERPLASIA (<math>4\mu\text{m}</math> CELL, LIGHT CELL)  
 HEART ..... NOT SPECIFIED(MILD)  
 -CARDIOMYOPATHY ..... NOT SPECIFIED(TRACE)  
 -MEDIAL HYPERTROPHY OF MUSCULAR ARTERIES  
 LUNGS ..... NOT SPECIFIED(TRACE)  
 -MINERALIZATION OF PULMONARY ARTERIES  
 LYMPH NODES ..... REACTIVE HYPERPLASIA NOTED IN CERVICAL NODES.  
 -REACTIVE HYPERPLASIA ..... NOT SPECIFIED (PRESENT)  
 LIVER .....



**Appendix J (cont.): PATHOLOGY INDIVIDUAL ANIMAL DATA**

LETTERMAN ARMY INSTITUTE OF RESEARCH  
 DIV OF RES SUPP, PATH SERV GP  
 SPECIES: RAT/FISCHER-344  
 INDIVIDUAL ANIMAL DATA REPORT  
 STUDY NUMBER: GLP83009  
 STUDY START DATE: 23-JAN-84  
 PRINTED: 21-NOV-89  
 PAGE: 291  
 STUDY TYPE: CHRONIC/2 YR CARCINOGENIC

ANIMAL NUMBER: 136/PRETEST= 136 SEX: MALE DOSE GROUP: 2 SACRIFICE STATUS: FINAL SACRIFICE  
 DATE OF DEATH: 05-FEB-86 STUDY DAY OF DEATH: 745 STUDY WEEK OF DEATH: 107 TERMINAL BODY WEIGHT: 385.00 (GMS)

<< MICROSCOPIC TISSUE OBSERVATIONS >>  
 TISSUE / HISTOPATHOLOGIC FINDINGS DISTRIBUTION (SEVERITY) / SPECIAL COMMENTS

- LIVER .....  
 -BILE DUCTULE EPITHELIAL HYPERPLASIA AND/OR CHOLANGIOFIBROSIS ..... NOT SPECIFIED(MODERATE)  
 -FIBROSIS CAPSULAR NO COMPOUND ..... NOT SPECIFIED (PRESENT)  
 -NECROSIS, HEPATOCYTTIC, INDIVIDUAL CELLS ..... NOT SPECIFIED(TRACE)  
 -FOCUS OF CELLULAR ALTERATION - EOSINOPHILIC CELLS ..... NOT SPECIFIED(TRACE)  
 -M- PRESENCE OF METASTATIC SARCOMA ..... SECONDARY NEOPLASIA FROM ORGAN ABDOMINAL CAVITY
- KIDNEY .....  
 -PROGRESSIVE RENAL DISEASE ..... NOT SPECIFIED(MODERATE)
- PROSTATE .....  
 -CHRONIC PROSTATITIS ..... NOT SPECIFIED(MILD)  
 -BENIGN HYPERPLASIA ..... NOT SPECIFIED(TRACE)
- TESTES .....  
 -B- INTERSTITIAL CELL ADENOMA ..... (PRESENT)
- MAMMARY GLANDS .....  
 -DILATATION (ECTASIA) OF DUCTS AND DUCTULES ..... NOT SPECIFIED (PRESENT)
- ADRENAL .....  
 -LIPIDOSIS ..... NOT SPECIFIED(MILD)  
 -CORTICAL NODULAR HYPERPLASIA ..... NOT SPECIFIED (PRESENT)
- PITUITARY GLAND .....  
 -B- ADENOMA ..... (PRESENT)
- EYES & OPTIC N. ....  
 -METAPLASTIC BONE FORMATION AND/OR MINERALIZATION, SCLERA ..... NOT SPECIFIED (PRESENT)

Appendix J (cont.): PATHOLOGY INDIVIDUAL ANIMAL DATA

LETTERMAN ARMY INSTITUTE OF RESEARCH  
 DIV OF RES SUPP, PATH SERV GP  
 SPECIES: RAT/FISCHER-344  
 STUDY START DATE: 23-JAN-84  
 ANIMAL NUMBER: 136/PRETEST=  
 DATE OF DEATH: 05-FEB-86  
 STUDY DAY OF DEATH: 745  
 SEX: MALE  
 DOSE GROUP: 2  
 SACRIFICE STATUS: FINAL SACRIFICE  
 STUDY WEEK OF DEATH: 107  
 TERMINAL BODY WEIGHT: 385.00 (GMS)  
 STUDY TYPE: CHRONIC/2 YR CARCINOGENIC  
 << M I C R O S C O P I C T I S S U E O B S E R V A T I O N S >>  
 TISSUE / HISTOPATHOLOGIC FINDINGS  
 DISTRIBUTION (SEVERITY) / SPECIAL COMMENTS  
 ABDOMINAL CAVITY ..... MISCELLANEOUS TISSUE  
 A LARGE SARCOMA IS SITUATED WITHIN THE LIVER PARENCHYMA AND  
 ABUTS ADJACENT SKELETAL MUSCLE OF THE ABDOMINAL WALL.  
 HISTOLOGIC CHARACTERISTICS OF THIS NEOPLASM ARE THOSE OF A  
 POORLY DIFFERENTIATED FIBROSARCOMA. LARGE AREAS OF THIS  
 NEOPLASM ARE UNDERGOING NECROSIS AND HEMORRHAGE.  
 (PRESENT)  
 -M- SARCOMA, CELLULAR DIFFERENTIATION UNSPECIFIED

PRINTED: 21-NOV-89  
PAGE: 292

**Appendix J (cont.): PATHOLOGY INDIVIDUAL ANIMAL DATA**

LETTERMAN ARMY INSTITUTE OF RESEARCH  
 DIV OF RES SUPP, PATH SERV GP  
 SPECIES: RAT/FISCHER-344

INDIVIDUAL ANIMAL DATA REPORT  
 STUDY NUMBER: GLP83009

PRINTED: 21-NOV-89  
 PAGE: 305

STUDY START DATE: 23-JAN-84

STUDY TYPE: CHRONIC/2 YR CARCINOGENIC

ANIMAL NUMBER: 148/PRETEST= 148 SEX: MALE DOSE GROUP: 3 SACRIFICE STATUS: SACRIFICED MORIBUND  
 DATE OF DEATH: 18-DEC-85 STUDY DAY OF DEATH: 696 STUDY WEEK OF DEATH: 100 TERMINAL BODY WEIGHT: 333.00 (GMS)

ORGAN NAME << GROSS ORGAN OBSERVATIONS >>  
 SEVERITY GRSS FREE-TEXT COMMENTS

THYROID GROWTH(S) / PHRASES PRESENT WHITE, .3 X .4CM, RIGHT POSTERIOR ASPECT  
 TESTES GROWTH(S) / MASSES PRESENT LEFT, MULTIPLE VARIABLY SIZED, YELLOW

TISSUE / HISTOPATHOLOGIC FINDINGS << MICROSCOPIC TISSUE OBSERVATIONS >>  
 DISTRIBUTION (SEVERITY) / SPECIAL COMMENTS

- THYROID GLANDS ..... (PRESENT)
- B- PARA-FOLLICULAR CELL ADENOMA ..... TISSUE IS MISSING  
 THERE IS A LARGE THYROID ADENOMA PRESENT. PARATHYROID TISSUE  
 COULD NOT BE FOUND.
- PARATHYROID ..... NOT SPECIFIED(MILD)
- HEART ..... NOT SPECIFIED(TRACE)
- CARDIOMYOPATHY ..... EXTRAMEDULLARY HEMATOPOIESIS IS EXCESSIVE. ALL BONE MARROW  
 CONTAINS NUMEROUS HISTIOCYTTIC CELLS THE CHARACTER OF WHICH IS  
 UNKNOWN. SEE COMMENT CONCERNING BONE MARROW FOR ADDITIONAL  
 INFORMATION.
- LUNGS ..... NOT SPECIFIED (PRESENT)
- MINERALIZATION OF PULMONARY ARTERIES ..... NOT SPECIFIED(MILD)  
 MULTI-FOCAL(TRACE)  
 NOT SPECIFIED (PRESENT)
- SPLEEN ..... NOT SPECIFIED (PRESENT)
- EXTRAMEDULLARY HEMATOPOIESIS ..... NOT SPECIFIED(MILD)
- LIVER ..... NOT SPECIFIED(MILD)  
 -BILE DUCTULE EPITHELIAL HYPERPLASIA AND/OR CHOLANGIOFIBROSIS  
 -HEPATOCTYIC VACUOLIZATION  
 -CYSTIC DEGENERATION
- KIDNEY ..... NOT SPECIFIED(MILD)
- PROGRESSIVE RENAL DISEASE
- PROSTATE ..... NOT SPECIFIED(MILD)

Appendix J (cont.): PATHOLOGY INDIVIDUAL ANIMAL DATA

LETTERMAN ARMY INSTITUTE OF RESEARCH  
 DIV OF RES SUPP, PATH SERV GP  
 SPECIES: RAT/FISCHER-344

INDIVIDUAL ANIMAL DATA REPORT  
 STUDY NUMBER: GLP83009

PRINTED: 21-NOV-89  
 PAGE: 306

STUDY START DATE: 23-JAN-84

STUDY TYPE: CHRONIC/2 YR CARCINOGENIC

ANIMAL NUMBER: 148/PRETEST-  
 DATE OF DEATH: 18-DEC-85

148 SEX: MALE  
 STUDY DAY OF DEATH: 696

DOSE GROUP: 3  
 SACRIFICE STATUS: SACRIFICED MORIBUND

STUDY WEEK OF DEATH: 100  
 TERMINAL BODY WEIGHT: 333.00 (GMS)

TISSUE / HISTOPATHOLOGIC FINDINGS  
 << MICROSCOPIC TISSUE

OBSERVATIONS  
 DISTRIBUTION (SEVERITY) / SPECIAL COMMENTS

PROSTATE  
 -CHRONIC PROSTATITIS  
 -BENIGN HYPERPLASIA

NOT SPECIFIED(MILD)  
 NOT SPECIFIED(TRACE)

SEMINAL VESICLE  
 -GENERALIZED ATROPHY

NOT SPECIFIED (PRESENT)

TESTES  
 -B- INTERSTITIAL CELL ADENOMA

(PRESENT)

PANCREAS  
 -B- ISLET CELL ADENOMA

(PRESENT)

MAMMARY GLANDS  
 -HYPERPLASIA AND/OR HYPERTROPHY OF THE ACINAR TISSUE  
 -DILATATION (ECTASIA) OF DUCTS AND DUCTULES

NOT SPECIFIED(TRACE)  
 NOT SPECIFIED (PRESENT)

BONE, STERNUM

MYELOID HISTIOCYTOSIS IS A PROVISIONAL DIAGNOSIS. THIS LESION WAS PRESENT IN ALL SECTIONS OF BONE MARROW. IT CONSISTED OF NUMEROUS HISTIOCYTIC CELLS IN THE BONE MARROW. NO MICRO-ORGANISMS WERE DETECTED BY GMS, PAS, GIEMSA OR GOODPASTURE STAINS. CELLS CONTAINED DIASTASE RESISTANT PAS-POSITIVE MATERIAL. CHARACTER OF LESION IS UNKNOWN. CONSULT WITH MTP PATHOLOGISTS DID NOT CLARIFY IF THIS LESION IS NEOPLASTIC OR INFLAMMATORY.  
 NOT SPECIFIED (PRESENT)

-MYELOID HISTIOCYTOSIS

BONE, FEMUR  
 -MYELOID HISTIOCYTOSIS

NOT SPECIFIED (PRESENT)

BONE VERT  
 -MYELOID HISTIOCYTOSIS

NOT SPECIFIED (PRESENT)

PITUITARY GLAND

Appendix J (cont.): PATHOLOGY INDIVIDUAL ANIMAL DATA

LETTERMAN ARMY INSTITUTE OF RESEARCH  
DIV OF RES SUPP, PATH SERV GP  
SPECIES: RAT/FISCHER-344

INDIVIDUAL ANIMAL DATA REPORT  
STUDY NUMBER: GLP83009  
STUDY START DATE: 23-JAN-84

PRINTED: 21-NOV-89  
PAGE: 307  
STUDY TYPE: CHRONIC/2 YR CARCINOGENIC

ANIMAL NUMBER: 148/PRETEST-      DOSE GROUP: 3      SACRIFICE STATUS: SACRIFICED MORIBUND  
DATE OF DEATH: 18-DEC-85      STUDY DAY OF DEATH: 696      STUDY WEEK OF DEATH: 100      TERMINAL BODY WEIGHT: 333.00 (GMS)

TISSUE / HISTOPATHOLOGIC FINDINGS      <<      M I C R O S C O P I C      T I S S U E      O B S E R V A T I O N S      >>  
DISTRIBUTION (SEVERITY) / SPECIAL COMMENTS

PITUITARY GLAND ..... (PRESENT)  
-B- ADENOMA

EYES & OPTIC N. .... CATARACTS WERE SUBCAPSULAR AND BILATERAL.  
-METAPLASTIC BONE FORMATION AND/OR MINERALIZATION, SCLERA      NOT SPECIFIED (PRESENT)  
-LENTICULAR DEGENERATIVE CHANGES COMPATIBLE WITH CATARACT      NOT SPECIFIED (PRESENT)

**Appendix J (cont.): PATHOLOGY INDIVIDUAL ANIMAL DATA**

LETTERMAN ARMY INSTITUTE OF RESEARCH  
 DIV OF RES SUPP, PATH SERV GP  
 SPECIES: RAT/FISCHER-344

INDIVIDUAL ANIMAL DATA REPORT  
 STUDY NUMBER: GLP83009

STUDY START DATE: 23-JAN-84

ANIMAL NUMBER: 149/PRETEST-149  
 DATE OF DEATH: 19-SEP-85  
 SEX: MALE  
 DOSE GROUP: 3  
 STUDY WEEK OF DEATH: 87  
 SACRIFICE STATUS: SACRIFICED MORIBUND  
 TERMINAL BODY WEIGHT: 484.00 (GMS)

STUDY TYPE: CHRONIC/2 YR CARCINOGENIC

ORGAN NAME: << GROSS ORGAN OBSERVATIONS >>  
 SEVERITY GROSS FREE-TEXT COMMENTS  
 TESTES: ENLARGED MARKED LEFT, 2.5 X 1.5CM  
 TESTES: GROWTH(S) / MASS(ES) PRESENT IRREGULAR, WHITE, COALESCING, HEMORRHAGIC, LEFT  
 TESTES: ATROPHIC / SMALL, UNILATERALLY MODERATE 1 X .5CM, RIGHT  
 SKIN: SUBCUTANEOUS MASS PRESENT LEFT INGUINAL REGION, 7 X 6CM, FIRM, WHITE

TISSUE / HISTOPATHOLOGIC FINDINGS << MICROSCOPIC TISSUE OBSERVATIONS >>  
 DISTRIBUTION (SEVERITY) / SPECIAL COMMENTS

- EXORBITAL LACRIM ..... NOT SPECIFIED (TRACE)
- ACINAR ATROPHY .....
- HEART .....
- CARDIOMYOPATHY ..... NOT SPECIFIED (MILD)
- SPLEEN .....
- INFARCTION, CHRONIC ..... NOT SPECIFIED (TRACE)
- LIVER .....
- BILE DUCTULE EPITHELIAL HYPERPLASIA AND/OR CHOLANGIOFIBROSIS .....
- FOCUS OF CELLULAR ALTERATION - BASOPHILIC .....
- CYSTIC DEGENERATION .....
- BENIGN HYPERPLASTIC NODULE(S) .....
- KIDNEY .....
- PROGRESSIVE RENAL DISEASE .....
- PROSTATE .....
- CHRONIC PROSTATITIS .....
- BENIGN HYPERPLASIA .....
- TESTES .....

PRINTED: 21-NOV-89  
 PAGE: 308

Appendix J (cont.): PATHOLOGY INDIVIDUAL ANIMAL DATA

LETTERMAN ARMY INSTITUTE OF RESEARCH  
DIV OF RES SUPP, PATH SERV GP  
SPECIES: RAT/FISCHER-344

PRINTED: 21-NOV-89  
PAGE: 309

INDIVIDUAL ANIMAL DATA REPORT  
STUDY NUMBER: GLP83009  
STUDY START DATE: 23-JAN-84

STUDY TYPE: CHRONIC/2 YR CARCINOGENIC

ANIMAL NUMBER: 149/PRETEST=  
DATE OF DEATH: 19-SEP-85

149 SEX: MALE  
STUDY DAY OF DEATH: 606

DOSE GROUP: 3  
STUDY WEEK OF DEATH: 87

SACRIFICE STATUS: SACRIFICED MORIBUND  
TERMINAL BODY WEIGHT: 484.00 (GMS)

TISSUE / HISTOPATHOLOGIC FINDINGS

<< MICROSCOPIC TISSUE OBSERVATIONS >>  
DISTRIBUTION (SEVERITY) / SPECIAL COMMENTS

TESTES ..... (PRESENT)  
-B- INTERSTITIAL CELL ADENOMA

JEJUNUM ..... MULTI-FOCAL(MILD)  
-ENTERITIS, SUBACUTE

SKIN ..... THE FIBROMA WAS LOCATED IN THE LEFT INGUINAL REGION.  
-B- FIBROMA (PRESENT)

**Appendix J (cont.): PATHOLOGY INDIVIDUAL ANIMAL DATA**

LETTERMAN ARMY INSTITUTE OF RESEARCH  
 DIV OF RES SUPP, PATH SERV GP  
 SPECIES: RAT/FISCHER-344  
 STUDY START DATE: 23-JAN-84  
 STUDY NUMBER: GLP83009  
 PRINTED: 21-NOV-89  
 PAGE: 310  
 STUDY TYPE: CHRONIC/2 YR CARCINOGENIC

ANIMAL NUMBER: 150/PRETEST= 150 SEX: MALE DOSE GROUP: 3 SACRIFICE STATUS: FINAL SACRIFICE  
 DATE OF DEATH: 27-JAN-86 STUDY DAY OF DEATH: 736 STUDY WEEK OF DEATH: 106 TERMINAL BODY WEIGHT: 368.00 (GMS)

<< GROSS ORGAN OBSERVATIONS >>  
 SEVERITY GROSS FREE-TEXT COMMENTS

ORGAN NAME	KEYWORDS / PHRASES	OBSERVATIONS	SEVERITY	GROSS FREE-TEXT COMMENTS
SKIN	ULCER(S) / EROSION(S)	PRESENT	PRESENT	LEFT REAR HOCK, CHRONIC, .5CM DIAMETER
SKIN	SUBCUTANEOUS MASS	PRESENT	PRESENT	RIGHT AXILLA, 1CM DIAMETER
LIVER	PROMINENT LOBULAR MARKINGS	PRESENT	PRESENT	
KIDNEY	GRANULAR SURFACE	PRESENT	PRESENT	
TESTES	ENLARGED	PRESENT	PRESENT	2.5 X 1.5CM, LEFT
TESTES	GROWTH(S) / MASS(ES)	PRESENT	PRESENT	LEFT, YELLOW AND BLACK
TESTES	ATROPHIC / SMALL, UNILATERALLY	PRESENT	PRESENT	RIGHT, 1.5 X .8CM
PITUITARY GLAND	ENLARGED	PRESENT	PRESENT	.6CM DIAMETER, MOTTLED RED

<< MICROSCOPIC TISSUE OBSERVATIONS >>  
 DISTRIBUTION (SEVERITY) / SPECIAL COMMENTS

TISSUE / HISTOPATHOLOGIC FINDINGS	OBSERVATIONS	DISTRIBUTION (SEVERITY) / SPECIAL COMMENTS
LACRIMAL GLAND	-INFLAMMATION, SUBACUTE TO CHRONIC	MULTI-FOCAL (TRACE)
HEART	-CARDIOMYOPATHY	NOT SPECIFIED (MILD)
	-MEDIAL HYPERTROPHY OF MUSCULAR ARTERIES	NOT SPECIFIED (TRACE)
LUNGS	-MINERALIZATION OF PULMONARY ARTERIES	NOT SPECIFIED (TRACE)
	-PERIBRONCHIAL LYMPHOID HYPERPLASIA	NOT SPECIFIED (TRACE)
LYMPH NODES	-LIMPHOCYTTIC INFILTRATION, SUBCAPSULAR AND MEDULLARY SINUSES	NOT SPECIFIED (PRESENT)
LIVER	-BILE DUCTULE EPITHELIAL HYPERPLASIA AND/OR CHOLANGIOFIBROSIS	NOT SPECIFIED (MILD)
	-HEPATOCTYIC VACUOLIZATION	MULTI-FOCAL (TRACE)
	-PERIPORTAL MONONUCLEAR CELLULAR INFILTRATION	NOT SPECIFIED (TRACE)
KIDNEY		



Appendix J (cont.): PATHOLOGY INDIVIDUAL ANIMAL DATA

LETTERMAN ARMY INSTITUTE OF RESEARCH  
 DIV OF RES SUPP, PATH SERV GP  
 SPECIES: RAT/FISCHER-344  
 STUDY START DATE: 23-JAN-84  
 STUDY NUMBER: GLP83009  
 PRINTED: 21-NOV-89  
 PAGE: 311  
 STUDY TYPE: CHRONIC/2 YR CARCINOGENIC  
 ANIMAL NUMBER: 150/PRETEST-150 SEX: MALE DOSE GROUP: 3 SACRIFICE STATUS: FINAL SACRIFICE  
 DATE OF DEATH: 27-JAN-86 STUDY DAY OF DEATH: 736 STUDY WEEK OF DEATH: 106 TERMINAL BODY WEIGHT: 368.00 (GMS)  
 TISSUE / HISTOPATHOLOGIC FINDINGS << MICROSCOPIC TISSUE OBSERVATIONS >>  
 DISTRIBUTION (SEVERITY) / SPECIAL COMMENTS

- KIDNEY ..... NOT SPECIFIED(MARKED)
- PROGRESSIVE RENAL DISEASE
- PROSTATE ..... NOT SPECIFIED(MODERATE)
- CHRONIC PROSTATITIS ..... NOT SPECIFIED(TRACE)
- BENIGN HYPERPLASIA
- SEMINAL VESICLE ..... NOT SPECIFIED (PRESENT)
- GENERALIZED ATROPHY
- TESTES ..... TUBULAR ATROPHY WAS SEVERE IN TESTIS THAT HAD NO INTERSTITIAL CELL ADENOMA.
- TUBULAR ATROPHY ..... NOT SPECIFIED(MARKED)
- B- INTERSTITIAL CELL ADENOMA (PRESENT)
- PERIARTERITIS NODOSA ..... NOT SPECIFIED (PRESENT)
- PANCREAS ..... NOT SPECIFIED(TRACE)
- ACINAR (EXOCRINE) ATROPHY
- SKIN ..... THE LARGE SUBCUTANEOUS MASS IN THE RIGHT AXILLARY REGION IS ON SECTION #21 AND IS A BASAL CELL CARCINOMA. THE LESION NOTED GROSSLY ON THE LEFT HOCK IS ON SECTION #22 AND CONSISTS OF FIBRINO-MECROTIC EXUDATE. NOT SPECIFIED(MARKED) (PRESENT)
- INFLAMMATORY EXUDATE ON SKIN SURFACE
- M- BASAL CELL CARCINOMA
- MAMMARY GLANDS ..... NOT SPECIFIED(MODERATE)
- HYPERPLASIA AND/OR HYPERTROPHY OF THE ACINAR TISSUE ..... NOT SPECIFIED (PRESENT)
- DILATATION (ECTASIA) OF DUCTS AND DUCTULES
- ADRENAL ..... NOT SPECIFIED(MILD)
- FOCUS OF CELLULAR ALTERATION, VACUOLATED
- PITUITARY GLAND .....

Appendix J (cont.): PATHOLOGY INDIVIDUAL ANIMAL DATA

LETTERMAN ARMY INSTITUTE OF RESEARCH  
DIV OF RES SUPP, PATH SERV GP  
SPECIES: RAT/FISCHER-344

INDIVIDUAL ANIMAL DATA REPORT  
STUDY NUMBER: GLP83009  
STUDY START DATE: 23-JAN-84

PRINTED: 21-NOV-89  
PAGE: 312

STUDY TYPE: CHRONIC/2 YR CARCINOGENIC

ANIMAL NUMBER: 150/PRETEST= 150 SEX: MALE DOSE GROUP: J SACRIFICE STATUS: FINAL SACRIFICE  
DATE OF DEATH: 27-JAN-86 STUDY DAY OF DEATH: 736 STUDY WEEK OF DEATH: 106 TERMINAL BODY WEIGHT: 368.00 (GMS)

TISSUE / HISTOPATHOLOGIC FINDINGS << MICROSCOPIC TISSUE OBSERVATIONS >>  
DISTRIBUTION (SEVERITY) / SPECIAL COMMENTS

PITUITARY GLAND ..... (PRESENT)  
-B- ADENOMA

EYES & OPTIC N. .... NOT SPECIFIED (PRESENT)  
-METAPLASTIC BONE FORMATION AND/OR MINERALIZATION, SCLERA

**Appendix J (cont.): PATHOLOGY INDIVIDUAL ANIMAL DATA**

LETTERMAN ARMY INSTITUTE OF RESEARCH  
 DIV OF RES SUPP, PATH SERV GP  
 SPECIES: RAT/FISCHER-344

INDIVIDUAL ANIMAL DATA REPORT  
 STUDY NUMBER: GLP83009

PRINTED: 21-NOV-89  
 PAGE: 313

STUDY START DATE: 23-JAN-84  
 STUDY TYPE: CHRONIC/2 YR CARCINOGENIC

ANIMAL NUMBER: 151/PRETEST-151 SEX: MALE DOSE GROUP: 3 SACRIFICE STATUS: SACRIFICED MORIBUND  
 DATE OF DEATH: 03-DEC-85 STUDY DAY OF DEATH: 681 STUDY WEEK OF DEATH: 98 TERMINAL BODY WEIGHT: 372.00 (GMS)

ORGAN NAME OBSERVATIONS SEVERITY GROSS FREE-TEXT COMMENTS  
 SPLEEN ENLARGED (SPLENOHEGALY) MODERATE  
 SPLEEN GRANULAR SURFACE PRESENT  
 PITUITARY GLAND ENLARGED MARKED 8 X 6MM, DARK RED

KEYWORDS / PHRASES  
 << MICROSCOPIC TISSUE OBSERVATIONS >>  
 DISTRIBUTION (SEVERITY) / SPECIAL COMMENTS

- THYROID GLANDS ..... (PRESENT)
- B- PARA-FOLLICULAR CELL ADENOMA.....
- HEART ..... NOT SPECIFIED(MILD)
- CARDIOMYOPATHY.....
- LUNGS ..... NOT SPECIFIED(TRACE)
- MINERALIZATION OF PULMONARY ARTERIES.....
- THYMUS ..... TISSUE IS MISSING  
 SEARCH OF WET TISSUE AND IMBEDDING TISSUES THAT SHOULD HAVE  
 CONTAINED THYMUS FAILED TO DEMONSTRATE THAT TISSUE.
- SPLEEN ..... (PRESENT)
- N- LARGE GRANULAR LYMPHOCYTE LEUKEMIA, METASTATIC.....
- LYMPH NODES ..... (PRESENT)
- N- LARGE GRANULAR LYMPHOCYTE LEUKEMIA, METASTATIC.....
- LIVER ..... NOT SPECIFIED(MILD)
- BILE DUCTULE EPITHELIAL HYPERPLASIA AND/OR CHOLANGIOFIBROSIS.....
- N- LARGE GRANULAR LYMPHOCYTE LEUKEMIA, METASTATIC.....
- KIDNEY .....

Appendix J (cont.): PATHOLOGY INDIVIDUAL ANIMAL DATA

LETTERMAN ARMY INSTITUTE OF RESEARCH  
DIV OF RES SUPP, PATH SERV GP  
SPECIES: RAT/FISCHER-344

INDIVIDUAL ANIMAL DATA REPORT  
STUDY NUMBER: GLP63009  
STUDY START DATE: 23-JAN-84

PRINTED: 21-NOV-89  
PAGE: 314  
STUDY TYPE: CHRONIC/2 YR CARCINOGENIC

ANIMAL NUMBER: 151/PRETEST-  
DATE OF DEATH: 03-DEC-85  
SEX: MALE  
DOSE GROUP: 3  
SACRIFICE STATUS: SACRIFICED MORIBUND  
STUDY DAY OF DEATH: 681  
STUDY WEEK OF DEATH: 98  
TERMINAL BODY WEIGHT: 372.00 (GMS)

<< MICROSCOPIC TISSUE OBSERVATIONS >>  
TISSUE / HISTOPATHOLOGIC FINDINGS  
DISTRIBUTION (SEVERITY) / SPECIAL COMMENTS

KIDNEY ..... NOT SPECIFIED(MODERATE)  
-PROGRESSIVE RENAL DISEASE

PROSTATE ..... NOT SPECIFIED(MILD)  
-CHRONIC PROSTATITIS  
-BENIGN HYPERPLASIA

PANCREAS ..... NOT SPECIFIED(MILD)  
-ACINAR (EXOCRINE) ATROPHY

MAMMARY GLANDS ..... GREATLY DILATED MAMMARY DUCTS ARE PRESENT IN NON-NEOPLASTIC  
SUBCUTANEOUS CONNECTIVE TISSUE ADJACENT TO THE FIBROADENOMA.  
-B- FIBROADENOMA (PRESENT)  
-DILATATION (ECTASIA) OF DUCTS AND DUCTULES NOT SPECIFIED (PRESENT)

ADRENAL ..... NOT SPECIFIED(MILD)  
-FOCUS OF CELLULAR ALTERATION, VACUOLATED

EYES & OPTIC N. .... NOT SPECIFIED (PRESENT)  
-METAPLASTIC BONE FORMATION AND/OR MINERALIZATION, SCLERA

WHOLE BODY ..... (PRESENT)  
-M- LARGE GRANULAR LYMPHOCYTTIC LEUKEMIA

Appendix J (cont.): PATHOLOGY INDIVIDUAL ANIMAL DATA

LETTERMAN ARMY INSTITUTE OF RESEARCH  
DIV OF RES SUPP, PATH SERV GP  
SPECIES: RAT/FISCHER-344

INDIVIDUAL ANIMAL DATA REPORT  
STUDY NUMBER: GLP83009

PRINTED: 21-NOV-89  
PAGE: 315

STUDY START DATE: 23-JAN-84

STUDY TYPE: CHRONIC/2 YR CARCINOGENIC

ANIMAL NUMBER: 152/PRETEST= 152 SEX: MALE DOSE GROUP: 3 SACRIFICE STATUS: SACRIFICED MORIBUND  
DATE OF DEATH: 16-JAN-86 STUDY DAY OF DEATH: 725 STUDY WEEK OF DEATH: 104 TERMINAL BODY WEIGHT: 316.00 (GMS)

ORGAN NAME KEYWORDS / PHRASES ORGAN OBSERVATIONS SEVERITY GROSS FREE-TEXT COMMENTS  
PITUITARY GLAND ENLARGED PRESENT .9CM DIAMETER

TISSUE / HISTOPATHOLOGIC FINDINGS MICROSCOPIC TISSUE OBSERVATIONS DISTRIBUTION (SEVERITY) / SPECIAL COMMENTS

HEART -CARDIOMYOPATHY NOT SPECIFIED(MODERATE)

LIVER -BILE DUCTULE EPITHELIAL HYPERPLASIA AND/OR CHOLANGIOFIBROSIS NOT SPECIFIED(MILD)  
-HEPATITIS NOT SPECIFIED(TRACE)

KIDNEY -PROGRESSIVE RENAL DISEASE NOT SPECIFIED(MODERATE)

PROSTATE -ACUTE SUPPURATIVE PROSTATITIS NOT SPECIFIED(MODERATE)  
-BENIGN HYPERPLASIA NOT SPECIFIED(MILD)

SEMINAL VESICLE -GENERALIZED ATROPHY NOT SPECIFIED (PRESENT)

TESTES -INTERSTITIAL CELL HYPERPLASIA FOCAL(TRACE)

NOSE/TURBINATES -SUBACUTE INFLAMATION ADJACENT TO NASAL LACRIMAL DUCT.  
-SUBACUTE INFLAMATION FOCAL(MILD)

ADRENAL -FOCUS OF CELLULAR ALTERATION, EOSINOPHILIC NOT SPECIFIED(MILD)

PITUITARY GLAND

Appendix J (cont.): PATHOLOGY INDIVIDUAL ANIMAL DATA

LETTERMAN ARMY INSTITUTE OF RESEARCH  
DIV OF RES SUPP, PATH SERV GP  
SPECIES: RAT/FISCHER-344

INDIVIDUAL ANIMAL DATA REPORT  
STUDY NUMBER: GLP83009  
STUDY START DATE: 23-JAN-84

PRINTED: 21-NOV-89  
PAGE: 316

STUDY TYPE: CHRONIC/2 YR CARCINOGENIC

ANIMAL NUMBER: 152/PRETEST-  
DATE OF DEATH: 16-JAN-86

152 SEX: MALE  
STUDY DAY OF DEATH: 725

DOSE GROUP: 3  
SACRIFICE STATUS: SACRIFICED MORIBUND  
STUDY WEEK OF DEATH: 104  
TERMINAL BODY WEIGHT: 316.00 (GMS)

TISSUE / HISTOPATHOLOGIC FINDINGS

<< MICROSCOPIC TISSUE OBSERVATIONS >>  
DISTRIBUTION (SEVERITY) / SPECIAL COMMENTS

PITUITARY GLAND ..... (PRESENT)  
-B- ADENOMA

EYES & OPTIC N. .... FOCAL (PRESENT)  
-METAPLASTIC BONE FORMATION AND/OR MINERALIZATION, SCLERA

## Appendix J (cont.): PATHOLOGY INDIVIDUAL ANIMAL DATA

LETTERMAN ARMY INSTITUTE OF RESEARCH  
 DIV OF RES SUPP, PATH SERV GP  
 SPECIES: RAT/FISCHER-344

INDIVIDUAL ANIMAL DATA REPORT  
 STUDY NUMBER: GLP83009  
 STUDY START DATE: 23-JAN-84

PRINTED: 21-NOV-89  
 PAGE: 317

ANIMAL NUMBER: 153/PRETEST= 153 SEX: MALE DOSE GROUP: 3 SACRIFICE STATUS: FINAL SACRIFICE  
 DATE OF DEATH: 27-JAN-86 STUDY DAY OF DEATH: 736 STUDY WEEK OF DEATH: 106 TERMINAL BODY WEIGHT: 355.00 (GMS)

STUDY TYPE: CHRONIC/2 YR CARCINOGENIC

<< GROSS ORGAN OBSERVATIONS >>  
 SEVERITY GROSS FREE-TEXT COMMENTS

ORGAN NAME  
 KEYWORDS / PHRASES

SPLEEN ENLARGED (SPLENOMEGALY) MILD 5 X 1CM  
 TESTES ENLARGED PRESENT BILATERAL, LEFT 3 X 1.75CM, RIGHT 2 X 1.5CM  
 TESTES GROWTH(S) / MASS(ES) PRESENT BILATERAL, YELLOW AND RED

<< MICROSCOPIC TISSUE OBSERVATIONS >>  
 DISTRIBUTION (SEVERITY) / SPECIAL COMMENTS

TISSUE / HISTOPATHOLOGIC FINDINGS

THYROID GLANDS  
 -B- PARA-FOLLICULAR CELL ADENOMA (PRESENT)

HEART  
 -CARDIOMYOPATHY NOT SPECIFIED(TRACE)  
 -MEDIAL HYPERTROPHY OF MUSCULAR ARTERIES NOT SPECIFIED(TRACE)

LUNGS  
 -MINERALIZATION OF PULMONARY ARTERIES NOT SPECIFIED(TRACE)  
 -INFARCTION, CHRONIC NOT SPECIFIED(MODERATE)

LIVER  
 -BILE DUCTULE EPITHELIAL HYPERPLASIA AND/OR CHOLANGIOFIBROSIS NOT SPECIFIED(MODERATE)  
 -HEPATOCTYIC VACUOLIZATION MULTI-FOCAL(TRACE)  
 -NECROSIS MULTI-FOCAL(TRACE)  
 -CYSTIC DEGENERATION NOT SPECIFIED (PRESENT)  
 -BENIGN HYPERPLASTIC NODULE(S) NOT SPECIFIED(TRACE)

KIDNEY  
 -PROGRESSIVE RENAL DISEASE NOT SPECIFIED(MODERATE)

PROSTATE

**Appendix J (cont.): PATHOLOGY INDIVIDUAL ANIMAL DATA**

LETTERMAN ARMY INSTITUTE OF RESEARCH  
 DIV OF RES SUPP, PATH SERV GP  
 SPECIES: RAT/FISCHER-344  
 STUDY START DATE: 23-JAN-84  
 STUDY NUMBER: GLP83009  
 PRINTED: 21-NOV-89  
 PAGE: 318  
 STUDY TYPE: CHRONIC/2 YR CARCINOGENIC  
 ANIMAL NUMBER: 153/PRETEST-153 SEX: MALE DOSE GROUP: 3 SACRIFICE STATUS: FINAL SACRIFICE  
 DATE OF DEATH: 27-JAN-86 STUDY DAY OF DEATH: 736 STUDY WEEK OF DEATH: 106 TERMINAL BODY WEIGHT: 355.00 (GMS)  
 TISSUE / HISTOPATHOLOGIC FINDINGS << MICROSCOPIC TISSUE OBSERVATIONS >>  
 DISTRIBUTION (SEVERITY) / SPECIAL COMMENTS

PROSTATE .....  
 -CHRONIC PROSTATITIS ..... NOT SPECIFIED(MILD)  
 -BENIGN HYPERPLASIA ..... NOT SPECIFIED(TRACE)

SEMINAL VESICLE .....  
 -GENERALIZED ATROPHY ..... NOT SPECIFIED (PRESENT)

TESTES .....  
 -B- INTERSTITIAL CELL ADENOMA ..... (PRESENT)

MAMMARY GLANDS .....  
 NO MAMMARY GLAND TISSUE COULD BE FOUND ASSOCIATED WITH SKIN SPECIMENS SUBMITTED. THE SMALL AMOUNTS OF MAMMARY TISSUE PRESENT IN CERVICAL SUBCUTANEOUS TISSUES ADJACENT TO SALIVARY GLANDS IN SECTION #4 ARE NORMAL.

NOSE/TURBINATES ..... INFILTRATE IS BILATERAL AND ADJACENT TO NASO-LACRIMAL DUCT.  
 -MIXED INFLAMMATORY CELL INFILTRATION, NASAL CAVITY, SINUSES, ..... NOT SPECIFIED(TRACE)  
 TURBINATES, NASO-LACRIMAL DUCTS

ADRENAL .....  
 -FOCUS OF CELLULAR ALTERATION, EOSINOPHILIC ..... NOT SPECIFIED(TRACE)  
 -FOCUS OF CELLULAR ALTERATION, VACUOLATED ..... NOT SPECIFIED(TRACE)

PITUITARY GLAND .....  
 -B- ADENOMA ..... (PRESENT)

EYES & OPTIC N. .... ALL OF THE LENS EXCEPT THE CAPSULE WAS LOST DURING PROCESSING.  
 -METAPLASTIC BONE FORMATION AND/OR MINERALIZATION, SCLERA ..... NOT SPECIFIED (PRESENT)



Appendix J (cont.): PATHOLOGY INDIVIDUAL ANIMAL DATA

LETTERMAN ARMY INSTITUTE OF RESEARCH  
 DIV OF RES SUPP, PATH SERV GP  
 SPECIES: RAT/FISCHER-344  
 STUDY START DATE: 23-JAN-84  
 ANIMAL NUMBER: 154/PRETEST-154  
 DATE OF DEATH: 27-JAN-86  
 SEX: MALE  
 STUDY DAY OF DEATH: 736  
 DOSE GROUP: 3  
 STUDY WEEK OF DEATH: 106  
 SACRIFICE STATUS: FINAL SACRIFICE  
 TERMINAL BODY WEIGHT: 360.00 (GMS)  
 STUDY TYPE: CHRONIC/2 YR CARCINOGENIC

INDIVIDUAL ANIMAL DATA REPORT  
 STUDY NUMBER: GLP83009  
 STUDY START DATE: 23-JAN-84

ORGAN NAME: << GROSS ORGAN OBSERVATIONS >>  
 KEYWORDS / PHRASES: SEVERITY GROSS FREE-TEXT COMMENTS  
 GROWTH(S) / MASS(ES): PRESENT YELLOW, MULTIPLE, VARIABLY SIZED, BILATERAL

TISSUE / HISTOPATHOLOGIC FINDINGS: << MICROSCOPIC TISSUE OBSERVATIONS >>  
 DISTRIBUTION (SEVERITY) / SPECIAL COMMENTS

TRACHEA ..... FOCAL(TRACE)  
 -SUPPURATIVE TRACHEITIS

HEART ..... NOT SPECIFIED(TRACE)  
 -CARDIOMYOPATHY ..... NOT SPECIFIED(TRACE)  
 -MEDIAL HYPERTROPHY OF MUSCULAR ARTERIES

LUNGS ..... NOT SPECIFIED(TRACE)  
 -PERIBRONCHIAL LYMPHOID HYPERPLASIA

LIVER ..... HEPATOCYTTIC VACUOLIZATION IS EXTENSIVE IN ONE LOBE (SLICE) OF LIVER BUT MINIMAL IN THE OTHER TWO.  
 -BILE DUCTULE EPITHELIAL HYPERPLASIA AND/OR CHOLANGIOFIBROSIS ..... NOT SPECIFIED(MILD)  
 -HEPATITIS ..... NOT SPECIFIED(TRACE)  
 -HEPATOCYTTIC VACUOLIZATION ..... NOT SPECIFIED(MILD)  
 -HEPATOCYTE COALESCING MICROVESICULAR (FATTY) CHANGE LEADING TO NECROSIS AND MINERALIZATION ..... MULTI-FOCAL(TRACE)

KIDNEY ..... NOT SPECIFIED(MILD)  
 -PROGRESSIVE RENAL DISEASE

PROSTATE ..... NOT SPECIFIED(TRACE)  
 -BENIGN HYPERPLASIA

TESTES ..... (PRESENT)  
 -8- INTERSTITIAL CELL ADENOMA

ADRENAL .....

Appendix J (cont.): PATHOLOGY INDIVIDUAL ANIMAL DATA

LETTERMAN ARMY INSTITUTE OF RESEARCH  
 DIV OF RES SUPP, PATH SERV GP  
 SPECIES: RAT/FISCHER-344

INDIVIDUAL ANIMAL DATA REPORT  
 STUDY NUMBER: GLP83009  
 STUDY START DATE: 23-JAN-84

PRINTED: 21-NOV-89  
 PAGE: 320  
 STUDY TYPE: CHRONIC/2 YR CARCINOGENIC

ANIMAL NUMBER: 154/PRETEST  
 DOSE GROUP: 3  
 SACRIFICE STATUS: FINAL SACRIFICE

DATE OF DEATH: 27-JAN-86  
 SEX: MALE  
 STUDY WEEK OF DEATH: 736  
 TERMINAL BODY WEIGHT: 360.00 (GMS)

TISSUE / HISTOPATHOLOGIC FINDINGS  
 << MICROSCOPIC TISSUE OBSERVATIONS >>  
 DISTRIBUTION (SEVERITY) / SPECIAL COMMENTS

ADRENAL ..... NOT SPECIFIED (TRACE)  
 - FOCUS OF CELLULAR ALTERATION, VACUOLATED

PITUITARY GLAND ..... (PRESENT)  
 - B- ADENOMA

EYES & OPTIC N. .... NOT SPECIFIED (PRESENT)  
 - METAPLASTIC BONE FORMATION AND/OR MINERALIZATION, SCLERA

Appendix J (cont.): PATHOLOGY INDIVIDUAL ANIMAL DATA

LETTERMAN ARMY INSTITUTE OF RESEARCH  
 DIV OF RES SUPP, PATH SERV GP  
 SPECIES: RAT/FISCHER-344  
 STUDY START DATE: 23-JAN-84  
 STUDY NUMBER: GLP83009  
 PRINTED: 21-NOV-89  
 PAGE: 32  
 STUDY TYPE: CHRONIC/2 YR CARCINOGENIC

ANIMAL NUMBER: 155/PRETEST#  
 DATE OF DEATH: 27-JAN-86  
 SEX: MALE  
 DOSE GROUP: 3  
 SACRIFICE STATUS: FINAL SACRIFICE  
 STUDY DAY OF DEATH: 736  
 STUDY WEEK OF DEATH: 106  
 TERMINAL BODY WEIGHT: 405.00 (GM)

<< GROSS ORGAN OBSERVATIONS >>  
 SEVERITY GROSS FREE-TEXT COMMENTS  
 KEYWORDS / PHRASES  
 ENLARGED  
 GROWTH(S) / MASS(ES)  
 PRESENT RIGHT, 2.5 X 1.5CM  
 PRESENT BILATERAL, MULTIPLE VARIABLY SIZED, YELLOW AND BLACK

<< MICROSCOPIC TISSUE OBSERVATIONS >>  
 DISTRIBUTION (SEVERITY) / SPECIAL COMMENTS

- THYROID GLANDS ..... (PRESENT)
- 8- PARA-FOLLICULAR CELL ADENOMA
- HEART ..... NOT SPECIFIED(MILD)
- CARDIOMYOPATHY ..... NOT SPECIFIED(TRACE)
- MEDIAL HYPERTROPHY OF MUSCULAR ARTERIES
- LUNGS ..... NOT SPECIFIED(TRACE)
- MINERALIZATION OF PULMONARY ARTERIES
- LIVER ..... NOT SPECIFIED(MILD)
- BILE DUCTULE EPITHELIAL HYPERPLASIA AND/OR CHOLANGIOFIBROSIS ..... NOT SPECIFIED(MILD)
- HEPATITIS ..... NOT SPECIFIED(TRACE)
- FOCUS OF CELLULAR ALTERATION - EOSINOPHILIC CELLS
- KIDNEY ..... NOT SPECIFIED(MARKED)
- PROGRESSIVE RENAL DISEASE
- PROSTATE ..... NOT SPECIFIED(TRACE)
- CHRONIC PROSTATITIS ..... NOT SPECIFIED(TRACE)
- BENIGN HYPERPLASIA
- SEMINAL VESICLE ..... NOT SPECIFIED (PRESENT)
- GENERALIZED ATROPHY
- PITUITARY GLAND .....

Appendix J (cont.): PATHOLOGY INDIVIDUAL ANIMAL DATA

LETTERMAN ARMY INSTITUTE OF RESEARCH  
DIV OF RES SUPP, PATH SERV GP  
SPECIES: RAT/FISCHER-344

INDIVIDUAL ANIMAL DATA REPORT  
STUDY NUMBER: GLP83009  
STUDY START DATE: 23-JAN-84

PRINTED: 21-NOV-89  
PAGE: 322

STUDY TYPE: CHRONIC/2 YR CARCINOGENIC

ANIMAL NUMBER: 155/PRETEST-  
DATE OF DEATH: 27-JAN-86 STUDY DAY OF DEATH: 736

DOSE GRPUP: 3 SACRIFICE STATUS: FINAL SACRIFICE  
STUDY WEEK OF DEATH: 106 TERMINAL BODY WEIGHT: 405.00 (GMS)

<< MICROSCOPIC TISSUE OBSERVATIONS >>  
TISSUE / HISTOPATHOLOGIC FINDINGS

DISTRIBUTION (SEVERITY) / SPECIAL COMMENTS

PITUITARY GLAND ..... (PRESENT)  
-B- ADENOMA

MEDIASTINUM ..... MISCELLANEOUS TISSUE  
-CHRONIC INFLAMMATION ..... NOT SPECIFIED(MILD)

**Appendix J (cont.): PATHOLOGY INDIVIDUAL ANIMAL DATA**

LETTERMAN ARMY INSTITUTE OF RESEARCH  
 DIV OF RES SUPP, PATH SERV GP  
 SPECIES: RAT/FISCHER-344

INDIVIDUAL ANIMAL DATA REPORT  
 STUDY NUMBER: GLP83009  
 STUDY START DATE: 23-JAN-84

156/PRETEST# 156 SEX: MALE DOSE GROUP: 3  
 STUDY DAY OF DEATH: 736 STUDY WEEK OF DEATH: 106 TERMINAL BODY WEIGHT: 337.00 (GMS)

PRINTED: 21-NOV-89  
 PAGE: 323  
 STUDY TYPE: CHRONIC/2 YR CARCINOGENIC

SACRIFICE STATUS: FINAL SACRIFICE  
 SEVERITY GROSS FREE-TEXT COMMENTS

ORGAN NAME	KEYWORDS / PHRASES	GROSS ORGAN OBSERVATIONS	SEVERITY	GROSS FREE-TEXT COMMENTS
MAMMARY GLAND	PROMINENT	YELLOW, AXILLARY AND INGUINAL AREA	PRESENT	
TESTES	ATROPHIC / SMALL, UNILATERALLY	1.5 X 1CM, RIGHT	PRESENT	
TESTES	GROWTH(S) / MASS(ES)	LEFT, YELLOW	PRESENT	
PAWS/FEET	GROWTH(S) / MASS(ES)	REAR, WART-LIKE, YELLOW, CRUSTY	PRESENT	
KIDNEY	DISCOLORATION	TAN, BILATERAL	PRESENT	
KIDNEY	GRANULAR SURFACE	BILATERAL	PRESENT	
ADRENAL	ENLARGED, UNILATERALLY	RIGHT, .7CM DIAMETER, MOTTLED RED AND BLACK	PRESENT	
PITUITARY GLAND	ENLARGED	.5CM DIAMETER, RED AND BLACK	PRESENT	

OBSEVATIONS >>>  
 OBSERVATIONS >>>  
 DISTRIBUTION (SEVERITY) / SPECIAL COMMENTS

HEART ..... NOT SPECIFIED(MILD)  
 -CARDIOMYOPATHY

THYMUS .....  
 THERE IS A SMALL ADENOMA IN THE THYMUS. HISTOLOGICALLY IT RESEMBLES A THYROID PARAFOLLICULAR CELL (C-CELL) ADENOMA OR AN ADENOMA OF THE PARATHYROID GLAND. CAROTID OR AORTIC BODY ORIGIN CANNOT BE RULED OUT.  
 (PRESENT)

-B- ADENOMA, ENDOCRINE ORIGIN, NOT OTHERWISE SPECIFIED

LIVER .....  
 -BILE DUCTULE EPITHELIAL HYPERPLASIA AND/OR CHOLANGIOFIBROSIS  
 -HEPATOCTYIC VACUOLIZATION  
 -CYSTIC DEGENERATION

KIDNEY .....  
 -PROGRESSIVE RENAL DISEASE

PROSTATE .....  
 -CHRONIC PROSTATITIS  
 -BENIGN HYPERPLASIA

Appendix J (cont.): PATHOLOGY INDIVIDUAL ANIMAL DATA

LETTERMAN ARMY INSTITUTE OF RESEARCH  
DIV OF RES SUPP, PATH SERV GP  
SPECIES: RAT/FISCHER-344

INDIVIDUAL ANIMAL DATA REPORT  
STUDY NUMBER: GLP83009

PRINTED: 21-NOV-89  
PAGE: 324

STUDY START DATE: 23-JAN-84  
STUDY TYPE: CHRONIC/2 YR CARCINOGENIC  
ANIMAL NUMBER: 156/PRETEST= 156 SEX: MALE DOSE GROUP: 3 SACRIFICE STATUS: FINAL SACRIFICE  
DATE OF DEATH: 27-JAN-86 STUDY DAY OF DEATH: 736 STUDY WEEK OF DEATH: 106 TERMINAL BODY WEIGHT: 337.00 (GMS)

<< MICROSCOPIC TISSUE OBSERVATIONS >>  
DISTRIBUTION (SEVERITY) / SPECIAL COMMENTS

TESTES ..... THE RIGHT (ATROPHIC) TESTIS CONTAINS NO INTERSTITIAL CELL  
ADENOMA. IT HAS SEVERE TUBULAR ATROPHY AND PERIARTERITIS.  
-TUBULAR ATROPHY (PRESENT)  
-B- INTERSTITIAL CELL ADENOMA (PRESENT)  
-PERIARTERITIS MODOSA NOT SPECIFIED (PRESENT)

PANCREAS ..... FOCAL(MODERATE)  
-CHRONIC INFLAMMATION

TONGUE ..... MULTI-FOCAL(MODERATE)  
-PERIARTERITIS

SKIN ..... LESION ON THE REAR FEET IS ACANTHOSIS AND HYPERKERATOSIS.  
-ACANTHOSIS NOT SPECIFIED(MODERATE)  
-HYPERKERATOSIS NOT SPECIFIED(MODERATE)

MAMMARY GLANDS ..... DIFFUSE(MARKED)  
-HYPERPLASIA AND/OR HYPERTROPHY OF THE ACIMAR TISSUE NOT SPECIFIED (PRESENT)  
-DILATATION (ECTASIA) OF DUCTS AND DUCTULES

BONE, FEMUR ..... NOT SPECIFIED (PRESENT)  
-MYELOFIBROSIS/OSTEOSCLEROSIS

ADRENAL ..... (PRESENT)  
-M- MEDULLARY CARCINOMA

PITUITARY GLAND ..... (PRESENT)  
-B- ADENOMA

EYES & OPTIC N. .... NOT SPECIFIED (PRESENT)  
-METAPLASTIC BONE FORMATION AND/OR MINERALIZATION, SCLERA

**Appendix J (cont.): PATHOLOGY INDIVIDUAL ANIMAL DATA**

LETTERMAN ARMY INSTITUTE OF RESEARCH  
 DIV OF RES SUPP, PATH SERV GP  
 SPECIES: RAT/FISCHER-344  
 STUDY START DATE: 23-JAN-84  
 STUDY NUMBER: GLP83009  
 PRINTED: 21-NOV-89  
 PAGE: 325  
 STUDY TYPE: CHRONIC/2 YR CARCINOGENIC

ANIMAL NUMBER: 157/PRETEST-157  
 DATE OF DEATH: 27-JAN-86  
 SEX: MALE  
 DOSE GROUP: 3  
 SACRIFICE STATUS: FINAL SACRIFICE  
 STUDY WEEK OF DEATH: 736  
 TERMINAL BODY WEIGHT: 358.00 (GMS)

<< GROSS ORGAN OBSERVATIONS >>  
 SEVERITY GROSS FREE-TEXT COMMENTS

KIDNEY PRESENT FOCAL, RIGHT, YELLOW, DEPRESSED, GRITTY  
 KIDNEY PRESENT  
 GRANULAR SURFACE PRESENT  
 TESTES ENLARGED  
 TESTES PRESENT BILATERAL, YELLOW AND BLACK

<< MICROSCOPIC TISSUE OBSERVATIONS >>  
 DISTRIBUTION (SEVERITY) / SPECIAL COMMENTS

HEART ..... NOT SPECIFIED(TRACE)

-CARDIOMYOPATHY

LUNGS ..... NOT SPECIFIED (PRESENT)

-VASCULAR CONGESTION

SPLEEN ..... FOCAL(TRACE)

-FIBROSIS CAPSULAR

LYMPH NODES ..... RBC'S, HEMOSIDERIN, AND REACTIVE HYPERPLASIA INVOLVE ONLY  
 CERVICAL NODES.  
 -RED BLOOD CELLS, HEMOSIDERIN AND/OR ERYTHROPHAGOCYTOSIS WITHIN  
 MEDULLARY SINUSES NOT SPECIFIED (PRESENT)  
 -REACTIVE HYPERPLASIA NOT SPECIFIED (PRESENT)

LIVER ..... NOT SPECIFIED(MILD)  
 -BILE DUCTULE EPITHELIAL HYPERPLASIA AND/OR CHOLANGIOFIBROSIS NOT SPECIFIED(TRACE)  
 -FOCUS OF CELLULAR ALTERATION - EOSINOPHILIC CELLS

KIDNEY ..... NOT SPECIFIED(MODERATE)  
 -PROGRESSIVE RENAL DISEASE NOT SPECIFIED (PRESENT)  
 -INFARCT, CHRONIC WITH FIBROSIS; WITH OR WITHOUT MINERALIZATION

SEMINAL VESICLE .....

Appendix J (cont.): PATHOLOGY INDIVIDUAL ANIMAL DATA

LETTERMAN ARMY INSTITUTE OF RESEARCH  
DIV OF RES SUPP, PATH SERV GP  
SPECIES: RAT/FISCHER-344

INDIVIDUAL ANIMAL DATA REPORT  
STUDY NUMBER: GLP83009

PRINTED: 21-NOV-89  
PAGE: 326

STUDY START DATE: 23-JAN-84

STUDY TYPE: CHRONIC/2 YR CARCINOGENIC

ANIMAL NUMBER: 157/PRETEST= 157 SEX: MALE DOSE GROUP: 3 SACRIFICE STATUS: FINAL SACRIFICE  
DATE OF DEATH: 27-JAN-86 STUDY DAY OF DEATH: 736 STUDY WEEK OF DEATH: 106 TERMINAL BODY WEIGHT: 358.00 (GMS)

TISSUE / HISTOPATHOLOGIC FINDINGS << MICROSCOPIC TISSUE OBSERVATIONS >>  
DISTRIBUTION (SEVERITY) / SPECIAL COMMENTS

SEMINAL VESICLE ..... NOT SPECIFIED (PRESENT)  
-GENERALIZED ATROPHY

TESTES ..... (PRESENT)  
-B- INTERSTITIAL CELL ADENOMA

ADRENAL ..... (PRESENT)  
-B- PHEOCHROMOCYTOMA

EYES & OPTIC N. ..... NOT SPECIFIED (PRESENT)  
-METAPLASTIC BONE FORMATION AND/OR MINERALIZATION, SCLERA

WHOLE BODY ..... NOT SPECIFIED (PRESENT)  
-INFLAMMATION OF BROWN FAT, (LOCATION SPECIFIED IN COMMENTS)  
DURING TRIMMING OF TISSUES, A MASS WAS DISCOVERED IN THE  
MESENTERY (DOCUMENTED ON LAIR FORM 52) AND EMBEDDED IN BLOCK  
#22. THIS LESION CONSISTS OF CHRONIC INFLAMMATION, FIBROSIS,  
AND MULTIFOCAL MINERALIZATION OF MESENTERIC FAT.



**Appendix J (cont.): PATHOLOGY INDIVIDUAL ANIMAL DATA**

LETTERMAN ARMY INSTITUTE OF RESEARCH  
 DIV OF RES SUPP, PATH SERV GP  
 SPECIES: RAT/FISCHER-344  
 ANIMAL NUMBER: 158/PRETEST#  
 DATE OF DEATH: 27-JAN-86  
 STUDY START DATE: 23-JAN-84  
 STUDY NUMBER: GLP83009  
 STUDY TYPE: CHRONIC/2 YR CARCINOGENIC  
 PRINTED: 21-NOV-89  
 PAGE: 327

INDIVIDUAL ANIMAL DATA REPORT  
 DOSE GROUP: 3  
 SACRIFICE STATUS: FINAL SACRIFICE  
 STUDY WEEK OF DEATH: 106  
 TERMINAL BODY WEIGHT: 377.00 (GMS)  
 SEX: MALE  
 GROSS ORGAN OBSERVATIONS  
 SEVERITY GROSS FREE-TEXT COMMENTS  
 PRESENT SMALL FOCAL ADHESION BETWEEN MEDIAL AND LEFT LATERAL LOBE  
 PRESENT RIGHT, 2.5 X 1.5CM  
 PRESENT BILATERAL, YELLOW AND BLACK

KEYWORDS / PHRASES  
 ADHESION(S)  
 ENLARGED  
 GROWTH(S) / MASS(ES)  
 OBSERVATIONS  
 DISTRIBUTION (SEVERITY) / SPECIAL COMMENTS

TISSUE / HISTOPATHOLOGIC FINDINGS  
 LACRIMAL GLAND  
 -INFLAMMATION, SUBACUTE TO CHRONIC

HEART  
 -CARDIOMYOPATHY  
 FOCAL(TRACE)

LUNGS  
 -MINERALIZATION OF PULMONARY ARTERIES  
 NOT SPECIFIED(MILD)

LYMPH NODES  
 -RED BLOOD CELLS, HEMOSIDERIN AND/OR ERYTHROPHAGOCYTOSIS WITHIN MEDULLARY SINUSES  
 NOT SPECIFIED(TRACE)

LIVER  
 -BILE DUCTULE EPITHELIAL HYPERPLASIA AND/OR CHOLANGIOFIBROSIS  
 -HEPATOCTYIC VACUOLIZATION  
 -FIBROSIS CAPSULAR NO COMPOUND  
 -CYSTIC DEGENERATION  
 RBC'S AND HEMOSIDERIN PRESENT IN CERVICAL AND MESENTERIC NODES.  
 NOT SPECIFIED (PRESENT)

KIDNEY  
 -PROGRESSIVE RENAL DISEASE  
 NOT SPECIFIED(MODERATE)

PROSTATE  
 -CHRONIC PROSTATITIS  
 -BENIGN HYPERPLASIA  
 NOT SPECIFIED(MILD)  
 NOT SPECIFIED(MILD)

TESTES

Appendix J (cont.): PATHOLOGY INDIVIDUAL ANIMAL DATA

LETTERMAN ARMY INSTITUTE OF RESEARCH  
DIV OF RES SUPP, PATH SERV GP  
SPECIES: RAT/FISCHER-344  
STUDY NUMBER: GLP83009  
STUDY START DATE: 23-JAN-84  
STUDY TYPE: CHRONIC/2 YR CARCINOGENIC

PRINTED: 21-NOV-89  
PAGE: 328

ANIMAL NUMBER: 158/PRETEST-158  
SEX: MALE  
DOSE GROUP: 3  
SACRIFICE STATUS: FINAL SACRIFICE  
DATE OF DEATH: 27-JAN-86  
STUDY DAY OF DEATH: 736  
STUDY WEEK OF DEATH: 106  
TERMINAL BODY WEIGHT: 377.00 (GMS)

<< MICROSCOPIC TISSUE OBSERVATIONS >>  
DISTRIBUTION (SEVERITY) / SPECIAL COMMENTS

TESTES ..... (PRESENT)  
-B- INTERSTITIAL CELL ADENOMA

PANCREAS .....  
-ACINAR (EXOCRINE) ATROPHY ..... MULTI-FOCAL(TRACE)

MAMMARY GLANDS .....  
-HYPERPLASIA AND/OR HYPERTROPHY OF THE ACINAR TISSUE ..... NOT SPECIFIED(TRACE)  
-DILATATION (ECTASIA) OF DUCTS AND DUCTULES ..... NOT SPECIFIED (PRESENT)

ADRENAL .....  
-FOCUS OF CELLULAR ALTERATION, EOSINOPHILIC ..... NOT SPECIFIED(TRACE)

PITUITARY GLAND .....  
-B- ADENOMA ..... (PRESENT)

EYES & OPTIC N. .... THE LENS OF BOSTH EYES WAS LOST DURING PROCESSING AND THEREFORE  
CANNOT BE EVALUATED.

-METAPLASTIC BONE FORMATION AND/OR MINERALIZATION, SCLERA  
NOT SPECIFIED (PRESENT)

Appendix J (cont.): PATHOLOGY INDIVIDUAL ANIMAL DATA

LETTERMAN ARMY INSTITUTE OF RESEARCH  
 DIV OF RES SUPP, PATH SERV GP  
 SPECIES: RAT/FISCHER-344

INDIVIDUAL ANIMAL DATA REPORT  
 STUDY NUMBER: GLP83009  
 STUDY START DATE: 23-JAN-84

ANIMAL NUMBER: 159/PRETEST# 159 SEX: MALE DOSE GROUP: 3 SACRIFICE STATUS: FINAL SACRIFICE  
 DATE OF DEATH: 27-JAN-86 STUDY DAY OF DEATH: 736 STUDY WEEK OF DEATH: 106 TERMINAL BODY WEIGHT: 404.00 (GMS)

STUDY TYPE: CHRONIC/2 YR CARCINOGENIC

PRINTED: 21-NOV-89  
 PAGE: 329

<< GROSS ORGAN OBSERVATIONS >>  
 SEVERITY GROSS FREE-TEXT COMMENTS  
 EYES & OPTIC N. LENS CATARACT PRESENT BILATERAL  
 TESTES ENLARGED PRESENT BILATERAL, 2.5 X 1.5CM  
 TESTES GROWTH(S) / MASS(ES) PRESENT BILATERAL, YELLOW AND BLACK

<< MICROSCOPIC TISSUE OBSERVATIONS >>  
 DISTRIBUTION (SEVERITY) / SPECIAL COMMENTS

THYROID GLANDS ..... NOT SPECIFIED (TRACE)  
 -PARA-FOLLICULAR CELL HYPERPLASIA ("C" CELL, LIGHT CELL)

LACRIMAL GLAND ..... MULTI-FOCAL (TRACE)  
 -INFLAMMATION, SUBCAPSULE TO CHRONIC

HEART ..... NOT SPECIFIED (MILD)  
 -CARDIOMYOPATHY NOT SPECIFIED (TRACE)  
 -MEDIAL HYPERTROPHY OF MUSCULAR ARTERIES

LIVER ..... NOT SPECIFIED (MILD)  
 -BILE DUCTULE EPITHELIAL HYPERPLASIA AND/OR CHOLANGIOFIBROSIS DIFFUSE (MILD)  
 -HEPATOCTYIC VACUOLIZATION NOT SPECIFIED (TRACE)  
 -BENIGN HYPERPLASTIC NODULE(S) MULTI-FOCAL (MILD)  
 -HEPATOCTYCE COALESCING MICROVESICULAR (FATTY) CHANGE LEADING TO NECROSIS AND MINERALIZATION

KIDNEY ..... NOT SPECIFIED (MILD)  
 -PROGRESSIVE RENAL DISEASE

PROSTATE ..... NOT SPECIFIED (MILD)  
 -CHRONIC PROSTATITIS NOT SPECIFIED (TRACE)  
 -BENIGN HYPERPLASIA

SEMINAL VESICLE .....

Appendix J (cont.): PATHOLOGY INDIVIDUAL ANIMAL DATA

LETTERMAN ARMY INSTITUTE OF RESEARCH  
 DIV OF RES SUPP, PATH SERV GP  
 SPECIES: RAT/FISCHER-344

INDIVIDUAL ANIMAL DATA REPORT  
 STUDY NUMBER: GLP83009

STUDY START DATE: 23-JAN-84

ANIMAL NUMBER: 159/PRETEST-159 SEX: MALE DOSE GROUP: 3 SACRIFICE STATUS: FINAL SACRIFICE  
 DATE OF DEATH: 27-JAN-86 STUDY DAY OF DEATH: 736 STUDY WEEK OF DEATH: 106 TERMINAL BODY WEIGHT: 404.00 (GMS)

STUDY TYPE: CHRONIC/2 YR CARCINOGENIC

TISSUE / HISTOPATHOLOGIC FINDINGS  
 << M I C R O S C O P I C T I S S U E O B S E R V A T I O N S >>  
 DISTRIBUTION (SEVERITY) / SPECIAL COMMENTS

PRINTED: 21-NOV-89  
PAGE: 330

SEMINAL VESICLE ..... NOT SPECIFIED (PRESENT)  
 -GENERALIZED ATROPHY

TESTES ..... (PRESENT)  
 -B- INTERSTITIAL CELL ADENOMA

NOSE/TURBINATES ..... INFILTRATE ADJACENT TO NASO-LACRIMAL DUCT.  
 -MIXED INFLAMMATORY CELL INFILTRATION, NASAL CAVITY, SINUSES, NOT SPECIFIED(TRACE)  
 TURBINATES, NASO-LACRIMAL DUCTS

ADRENAL ..... NOT SPECIFIED(TRACE)  
 -FOCUS OF CELLULAR ALTERATION, VACUOLATED

EYES & OPTIC N. .... THE RETINAL DEGENERATION, SCLERAL MINERALIZATION AND CATARACT  
 FORMATION ARE BILATERAL. CATARACT IS SUBCAPSULAR. CORNEAL  
 MINERALIZATION AND VASCULARIZATION AE UNILATERAL

-CORNEAL MINERALIZATION  
 -RETINAL ATROPHY AND/OR DEGENERATION, UNILATERAL OR BILATERAL  
 -CORNEAL VASCULARIZATION  
 -METAPLASTIC BONE FORMATION AND/OR MINERALIZATION, SCLERA  
 -LENTICULAR DEGENERATIVE CHANGES COMPATIBLE WITH CATARACT

FOCAL(TRACE)  
 DIFFUSE(MARKED)  
 FOCAL(TRACE)  
 NOT SPECIFIED (PRESENT)  
 NOT SPECIFIED (PRESENT)

Appendix J (cont.): **PATHOLOGIC INDIVIDUAL ANIMAL DATA**

LETTERMAN ARMY INSTITUTE OF RESEARCH  
 DIV OF RES SUPP, PATH SERV GP  
 SPECIES: RA1/FISCHER-344  
 STUDY NUMBER: GLP83009  
 STUDY START DATE: 23-JAN-84  
 STUDY TYPE: CHRONIC/2 YR CARCINOGENIC  
 PRINTED: 21-NOV-89  
 PAGE: 331

ANIMAL NUMBER: 160/PRETEST# 160 SEX: MALE DOSE GROUP: 3 SACRIFICE STATUS: FINAL SACRIFICE  
 DATE OF DEATH: 27-JAN-86 STUDY DAY OF DEATH: 736 STUDY WEEK OF DEATH: 106 TERMINAL BODY WEIGHT: 366.00 (GMS)

<< GROSS ORGAN OBSERVATIONS >>  
 SEVERITY GROSS FREE-TEXT COMMENTS  
 ADRENAL ENLARGED, UNILATERALLY PRESENT LEFT, .5CM DIAMETER  
 TESTES ATROPHIC / SMALL, UNILATERALLY PRESENT 1.5 X 1CM, LEFT  
 TESTES ENLARGED PRESENT RIGHT, 3 X 1.75CM  
 TESTES GROWTH(S) / MASS(ES) PRESENT LEFT HAS MULTIPLE VARIABLY SIZED YELLOW MASSES.  
 RIGHT INVOLVES ENTIRE TESTE, YELLOW AND BLACK

<< MICROSCOPIC TISSUE OBSERVATIONS >>  
 DISTRIBUTION (SEVERITY) / SPECIAL COMMENTS

TISSUE / HISTOPATHOLOGIC FINDINGS TISSUE IS MISSING

PARATHYROID  
 HEART  
 -CARDIOMYOPATHY  
 -MEDIAL HYPERTROPHY OF MUSCULAR ARTERIES  
 NOT SPECIFIED(TRACE)  
 NOT SPECIFIED(TRACE)

SPLEEN  
 -HISTIOCYTIC INFILTRATE, CAPSULE AND OMENTUM  
 NOT SPECIFIED (PRESENT)

LYMPH NODES  
 -RED BLOOD CELLS, HEMOSIDERIN AND/OR ERYTHROPHAGOCYTOSIS WITHIN MEDULLARY SINUSES  
 RBC'S AND HEMOSIDERIN LIMITED TO MEDIASTINAL NODES.  
 NOT SPECIFIED (PRESENT)

LIVER  
 -BILE DUCTULE EPITHELIAL HYPERPLASIA AND/OR CHOLANGIOFIBROSIS  
 -CYSTIC DEGENERATION  
 NOT SPECIFIED(MILD)  
 NOT SPECIFIED (PRESENT)

KIDNEY  
 -PROGRESSIVE RENAL DISEASE  
 NOT SPECIFIED(MODERATE)

PROSTATE  
 -CHRONIC PROSTATITIS  
 -BENIGN HYPERPLASIA  
 NOT SPECIFIED(MILD)  
 NOT SPECIFIED(TRACE)

SEMINAL VESICLE

Appendix J (cont.): PATHOLOGY INDIVIDUAL ANIMAL DATA

LETTERMAN ARMY INSTITUTE OF RESEARCH  
 DIV OF RES SUPP, PATH SERV GP  
 SPECIES: RAT/FISCHER-344  
 STUDY NUMBER: GLP83009  
 STUDY START DATE: 23-JAN-84  
 STUDY TYPE: CHRONIC/2 YR CARCINOGENIC  
 ANIMAL NUMBER: 160/PRETEST#  
 DATE OF DEATH: 27-JAN-86  
 SEX: MALE  
 DOSE GROUP: 3  
 SACRIFICE STATUS: FINAL SACRIFICE  
 STUDY WEEK OF DEATH: 106  
 TERMINAL BODY WEIGHT: 366.00 (GMS)  
 TISSUE << M I C R O S C O P I C T I S S U E O B S E R V A T I O N S >>  
 DISTRIBUTION (SEVERITY) / SPECIAL COMMENTS

PRINTED: 21-NOV-89  
PAGE: 332

SEMINAL VESICLE ..... NOT SPECIFIED (PRESENT)  
-GENERALIZED ATROPHY

TESTES ..... INTERSTITIAL CELL ADENOMAS ARE PRESENT IN BOTH TESTES. THE TUMOR IN THE LEFT TESTIS (DESCRIBED AS SMALL AND ATROPHIC GROSSLY) IS PROBABLY TOO SMALL TO BE DETECTED GROSSLY. (PRESENT)

-B- INTERSTITIAL CELL ADENOMA

PANCREAS ..... MULTI-FOCAL(MILD)  
-ACINAR (EXOCRINE) ATROPHY (PRESENT)  
-B- ISLET CELL ADENOMA

NOSE/TURBINATES ..... INFILTRATE IS BILATERAL, ADJACENT TO NASO-LACRIMAL DUCTS  
-MIXED INFLAMMATORY CELL INFILTRATION, NASAL CAVITY, SINUSES, NOT SPECIFIED(MILD)  
TURBINATES, NASO-LACRIMAL DUCTS

ADRENAL ..... (PRESENT)  
-B- CORTICAL ADENOMA

**Appendix J (cont.): PATHOLOGY INDIVIDUAL ANIMAL DATA**

LETTERMAN ARMY INSTITUTE OF RESEARCH  
 DIV OF RES SUPP, PATH SERV GP  
 SPECIES: RAT/FISCHER-344  
 STUDY START DATE: 23-JAN-84  
 STUDY NUMBER: GLP83059  
 STUDY TYPE: CHRONIC/2 YR CARCINOGENIC  
 PRINTED: 21-NOV-89  
 PAGE: 333  
 ANIMAL NUMBER: 161/PRETEST-161  
 SEX: MALE  
 DOSE GROUP: 3  
 SACRIFICE STATUS: FINAL SACRIFICE  
 DATE OF DEATH: 27-JAN-86  
 STUDY DAY OF DEATH: 736  
 STUDY WEEK OF DEATH: 106  
 TERMINAL BODY WEIGHT: 395.00 (GMS)  
 << GROSS ORGAN OBSERVATIONS >>  
 SEVERITY GROSS FREE-TEXT COMMENTS  
 KEYWORDS / PHRASES  
 LENS CATARACT LEFT  
 ENLARGED PRESENT BILATERAL, 3 X 2CM  
 GROWTH(S) / MASS(ES) PRESENT BILATERAL, YELLOW AND BLACK

TISSUE / HISTOPATHOLOGIC FINDINGS  
 << MICROSCOPIC TISSUE OBSERVATIONS >>  
 DISTRIBUTION (SEVERITY) / SPECIAL COMMENTS

- HEART ..... NOT SPECIFIED(MILD)
- CARDIOMYOPATHY ..... NOT SPECIFIED(TRACE)
- MEDIAL HYPERTROPHY OF MUSCULAR ARTERIES
- LYMPH NODES ..... RBC'S AND HEMOSIDERIN PRESENT ONLY IN MEDIASTINAL NODES.
- RED BLOOD CELLS, HEMOSIDERIN AND/OR ERYTHROPHAGOCYTOSIS WITHIN ..... NOT SPECIFIED (PRESENT)
- MEDULLARY SINUSES
- LIVER ..... NOT SPECIFIED(MODERATE)
- BILE DUCTULE EPITHELIAL HYPERPLASIA AND/OR CHOLANGIOFIBROSIS ..... NOT SPECIFIED (PRESENT)
- CYSTIC DEGENERATION
- KIDNEY ..... NOT SPECIFIED(MODERATE)
- PROGRESSIVE RENAL DISEASE
- PROSTATE ..... NOT SPECIFIED(TRACE)
- BENIGN HYPERPLASIA
- SEMINAL VESICLE ..... NOT SPECIFIED (PRESENT)
- GENERALIZED ATROPHY
- TESTES ..... (PRESENT)
- B- INTERSTITIAL CELL ADENOMA
- PANCREAS .....

Appendix J (cont.): PATHOLOGY INDIVIDUAL ANIMAL DATA

LETTERMAN ARMY INSTITUTE OF RESEARCH
DIV OF RES SUPP, PATH SERV GP
SPECIES: RAT/FISCHER-344
INDIVIDUAL ANIMAL DATA REPORT
STUDY NUMBER: GLP83009
STUDY START DATE: 23-JAN-84
STUDY TYPE: CHRONIC/2 YR CARCINOGENIC
PRINTED: 21-NOV-89
PAGE: 334

ANIMAL NUMBER: 161/PRETEST=
DATE OF DEATH: 27-JAN-86
STUDY DAY OF DEATH: 736
DOSE GROUP: 3
SACRIFICE STATUS: FINAL SACRIFICE
TERMINAL BODY WEIGHT: 395.00 (GMS)

<< MICROSCOPIC TISSUE OBSERVATIONS >>
DISTRIBUTION (SEVERITY) / SPECIAL COMMENTS

PANCREAS ..... MULTI-FOCAL(MILD)
-ACINAR (EXOCRINE) ATROPHY
MAMMARY GLANDS ..... NOT SPECIFIED (PRESENT)
-DILATATION (ECTASIA) OF DUCTS AND DUCTULES

EYES & OPTIC N. .... THE CATARACT IS SUBCAPSULAR AND UNILATERAL. THE RETINAL ATROPHY
AND DEGENERATION IS ALSO UNILATERAL AND INVOLVES THE SAME EYE
(LEFT) AS THE CATARACT.
-RETINAL ATROPHY AND/OR DEGENERATION, UNILATERAL OR BILATERAL
-METAPLASTIC BONE FORMATION AND/OR MINERALIZATION, SCLERA
-LENTICULAR DEGENERATIVE CHANGES COMPATIBLE WITH CATARACT

MEDIASTINUM ..... MISCELLANEOUS TISSUE
-REACTIVE HYPERPLASIA, LYMPH NODE NOT SPECIFIED (PRESENT)



Appendix J (cont.): PATHOLOGY INDIVIDUAL ANIMAL DATA

LETTERMAN ARMY INSTITUTE OF RESEARCH  
DIV OF RES SUPP, PATH SERV GP  
SPECIES: RAT/FISCHER-344

INDIVIDUAL ANIMAL DATA REPORT  
STUDY NUMBER: GLP83009

PRINTED: 21-NOV-89  
PAGE: 335

STUDY START DATE: 23-JAN-84

STUDY TYPE: CHRONIC/2 YR CARCINOGENIC

ANIMAL NUMBER: 162/PRETEST# 162 SEX: MALE DOSE GROUP: 3 SACRIFICE STATUS: FINAL SACRIFICE  
DATE OF DEATH: 29-JAN-86 STUDY DAY OF DEATH: 738 STUDY WEEK OF DEATH: 106 TERMINAL BODY WEIGHT: 321.00 (GMS)

<< GROSS ORGAN OBSERVATIONS >>

SEVERITY GROSS FREE-TEXT COMMENTS

ENLARGED PRESENT LEFT, 2.5 X 1.5CM

KEYWORDS / PHRASES PRESENT BILATERAL, MULTIPLE VARIABLY SIZED, YELLOW

GROWTH(S) / MASS(ES)

<< MICROSCOPIC TISSUE OBSERVATIONS >>  
DISTRIBUTION (SEVERITY) / SPECIAL COMMENTS

HEART ..... NOT SPECIFIED(TRACE)

LUNGS ..... NOT SPECIFIED(TRACE)

LIVER ..... NOT SPECIFIED(MODERATE)

KIDNEY ..... NOT SPECIFIED(MODERATE)

PROSTATE ..... FOCAL(TRACE)

TESTES ..... (PRESENT)

PANCREAS ..... MULTI-FOCAL(TRACE)

MAMMARY GLANDS ..... NOT SPECIFIED (PRESENT)

ADRENAL .....

Appendix J (cont.): PATHOLOGY INDIVIDUAL ANIMAL DATA

LETTERMAN ARMY INSTITUTE OF RESEARCH  
DIV OF RES SUPP, PATH SERV GP  
SPECIES: RAT/FISCHER-344

INDIVIDUAL ANIMAL DATA REPORT  
STUDY NUMBER: GLP83009  
STUDY START DATE: 23-JAN-84

PRINTED: 21-NOV-89  
PAGE: 336

STUDY TYPE: CHRONIC/2 YR CARCINOGENIC

ANIMAL NUMBER: 162/PRETEST# 162 SEX: MALE DOSE GROUP: 3 SACRIFICE STATUS: FINAL SACRIFICE  
DATE OF DEATH: 29-JAN-86 STUDY DAY OF DEATH: 738 STUDY WEEK OF DEATH: 106 TERMINAL BODY WEIGHT: 321.00 (GMS)

<< MICROSCOPIC TISSUE OBSERVATIONS >>  
TISSUE / HISTOPATHOLOGIC FINDINGS DISTRIBUTION (SEVERITY) / SPECIAL COMMENTS

ADRENAL .....  
- FOCUS OF CELLULAR ALTERATION, VACUOLATED ..... NOT SPECIFIED (TRACE)  
- CORTICAL MODULAR HYPERPLASIA ..... NOT SPECIFIED (PRESENT)

PITUITARY GLAND ..... TISSUE IS MISSING

EYES & OPTIC N. ....  
- METAPLASTIC BONE FORMATION AND/OR MINERALIZATION, SCLERA ..... NOT SPECIFIED (PRESENT)

Appendix J (cont.): PATHOLOGY INDIVIDUAL ANIMAL DATA

LETTERMAN ARMY INSTITUTE OF RESEARCH  
 DIV OF RES SUPP, PATH SERV GP  
 SPECIES: RAT/FISCHER-344  
 STUDY START DATE: 23-JAN-84  
 STUDY NUMBER: GLP83009  
 PRINTED: 21-NOV-89  
 PAGE: 337  
 STUDY TYPE: CHRONIC/2 YR CARCINOGENIC

ANIMAL NUMBER: 163/PRETEST-163 SEX: MALE DOSE GROUP: 3 SACRIFICE STATUS: FINAL SACRIFICE  
 DATE OF DEATH: 29-JAN-86 STUDY DAY OF DEATH: 736 STUDY WEEK OF DEATH: 106 TERMINAL BODY WEIGHT: 336.00 (GMS)

<< GROSS ORGAN OBSERVATIONS >>  
 SEVERITY GROSS FREE-TEXT COMMENTS

ORGAN NAME  
 KEYWORDS / PHRASES  
 ULCEERATION  
 ENLARGED  
 GROWTH(S) / MASS(ES)

TAIL  
 TESTES  
 TESTES  
 PRESENT VENTRAL BASE, .5CM DIAMETER  
 PRESENT LEFT, 4 X 2CM  
 PRESENT BILATERAL, MULTIPLE VARIABLY SIZED, YELLOW/BLACK

<< MICROSCOPIC TISSUE OBSERVATIONS >>  
 DISTRIBUTION (SEVERITY) / SPECIAL COMMENTS

THYROID GLANDS  
 -B- PARA-FOLLICULAR CELL ADENOMA (PRESENT)

HEART  
 -CARDIOMYOPATHY NOT SPECIFIED(MILD)

LIVER  
 -BILE DUCTULE EPITHELIAL HYPERPLASIA AND/OR CHOLANGIOFIBROSIS NOT SPECIFIED(MILD)  
 -HEPATITIS MULTI-FOCAL(TRACE)  
 -HEPATOCTYIC VACUOLIZATION MULTI-FOCAL(TRACE)

KIDNEY  
 -PROGRESSIVE RENAL DISEASE NOT SPECIFIED(MILD)

SEMINAL VESICLE  
 -GENERALIZED ATROPHY NOT SPECIFIED (PRESENT)

TESTES  
 -B- INTERSTITIAL CELL ADENOMA (PRESENT)

ADRENAL  
 -B- PHEOCHROMOCYTOMA (PRESENT)

PITUITARY GLAND

Appendix J (cont.): PATHOLOGY INDIVIDUAL ANIMAL DATA

LETTERMAN ARMY INSTITUTE OF RESEARCH  
DIV OF RES SUPP, PATH SERV GP  
SPECIES: RAT/FISCHER-344

INDIVIDUAL ANIMAL DATA REPORT  
STUDY NUMBER: GLP83009

PRINTED: 21-NOV-89  
PAGE: 338

STUDY START DATE: 23-JAN-84

STUDY TYPE: CHRONIC/2 YR CARCINOGENIC

ANIMAL NUMBER: 163/PRETEST-  
DATE OF DEATH: 29-JAN-86

163 SEX: MALE  
STUDY DAY OF DEATH: 738

DOSE GROUP: 3  
STUDY WEEK OF DEATH: 106

SACRIFICE STATUS: FINAL SACRIFICE  
TERMINAL BODY WEIGHT: 336.00 (GMS)

<< MICROSCOPIC FINDINGS

OBSERVATIONS  
>>

TISSUE / HISTOPATHOLOGIC FINDINGS  
DISTRIBUTION (SEVERITY) / SPECIAL COMMENTS

PITUITARY GLAND  
-B- ADENOMA (PRESENT)

EYES & OPTIC N.  
-METAPLASTIC BONE FORMATION AND/OR MINERALIZATION, SCLERA NOT SPECIFIED (PRESENT)

Appendix J (cont.): PATHOLOGY INDIVIDUAL ANIMAL DATA

LETTERMAN ARMY INSTITUTE OF RESEARCH INDIVIDUAL ANIMAL DATA REPORT PRINTED: 21-NOV-89  
 DIV OF RES SUPP, PATH SERV GP STUDY NUMBER: GLP83009 PAGE: 339  
 SPECIES: RAY/FISCHER-344 STUDY START DATE: 23-JAN-84 STUDY TYPE: CHRONIC/2 YR CARCINOGENIC

ANIMAL NUMBER: 164/PRETEST= 164 SEX: MALE DOSE GROUP: 3 SACRIFICE STATUS: FINAL SACRIFICE  
 DATE OF DEATH: 29-JAN-86 STUDY DAY OF DEATH: 738 STUDY WEEK OF DEATH: 106 TERMINAL BODY WEIGHT: 395.00 (GMS)

<< GROSS ORGAN OBSERVATIONS >>  
 KEYWORDS / PHRASES SEVERITY GROSS FREE-TEXT COMMENTS  
 ENLARGED PRESENT LEFT, 3.5 X 2CM  
 GROWTH(S) / MASS(ES) PRESENT BILATERAL, VARIABLY SIZED, YELLOW/BLACK  
 GRANULAR SURFACE TRACE

<< MICROSCOPIC TISSUE OBSERVATIONS >>  
 TISSUE / HISTOPATHOLOGIC FINDINGS DISTRIBUTION (SEVERITY) / SPECIAL COMMENTS

THYROID GLANDS ..... (PRESENT)  
 -B- PARA-FOLLICULAR CELL ADENOMA

HEART .....  
 -CARDIOMYOPATHY ..... NOT SPECIFIED(MILD)  
 -MEDIAL HYPERTROPHY OF MUSCULAR ARTERIES ..... NOT SPECIFIED(TRACE)

LIVER .....  
 -BILE DUCTULE EPITHELIAL HYPERPLASIA AND/OR CHOLANGIOFIBROSIS ..... NOT SPECIFIED(MODERATE)  
 -HEPATOCTYTIC VACUOLIZATION ..... MULTI-FOCAL(TRACE)  
 -NECROSIS ..... MULTI-FOCAL(TRACE)  
 -FOCUS OF CELLULAR ALTERATION - EOSINOPHILIC CELLS ..... NOT SPECIFIED(TRACE)

KIDNEY .....  
 -PROGRESSIVE RENAL DISEASE ..... NOT SPECIFIED(MODERATE)

PROSTATE .....  
 -CHRONIC PROSTATITIS ..... NOT SPECIFIED(MILD)  
 -BENIGN HYPERPLASIA ..... NOT SPECIFIED(TRACE)

TESTES ..... (PRESENT)  
 -B- INTERSTITIAL CELL ADENOMA

PANCREAS .....

Appendix J (cont.):  
LETTERMAN ARMY INSTITUTE OF RESEARCH  
DIV OF RES SUPP, PATH SERV GP  
SPECIES: RAT/FISCHER-344

PATHOLOGY INDIVIDUAL ANIMAL DATA

INDIVIDUAL ANIMAL DATA REPORT  
STUDY NUMBER: GLP83009  
PRINTED: 21-NOV-89  
PAGE: 340

STUDY START DATE: 23-JAN-84  
STUDY TYPE: CHRONIC/2 YR CARCINOGENIC

ANIMAL NUMBER: 164/PRETEST= 164 SEX: MALE DOSE GROUP: 3 SACRIFICE STATUS: FINAL SACRIFICE  
DATE OF DEATH: 29-JAN-86 STUDY DAY OF DEATH: 738 STUDY WEEK OF DEATH: 106 TERMINAL BODY WEIGHT: 395.00 (GMS)

TISSUE / HISTOPATHOLOGIC FINDINGS << MICROSCOPIC TISSUE OBSERVATIONS >>  
DISTRIBUTION (SEVERITY) / SPECIAL COMMENTS

PANCREAS ..... FOCAL(TRACE)  
-CHRONIC INFLAMMATION

MAMMARY GLANDS ..... NOT SPECIFIED(TRACE)  
-HYPERPLASIA AND/OR HYPERTROPHY OF THE ACINAR TISSUE

NOSE/TURBINATES ..... INFILTRATE IS BILATERAL, ADJACENT TO NASO-LACRIMAL DUCTS.  
-MIXED INFLAMMATORY CELL INFILTRATION, NASAL CAVITY, SINUSES, NOT SPECIFIED(MILD)  
TURBINATES, NASO-LACRIMAL DUCTS

ADRENAL ..... NOT SPECIFIED(TRACE)  
-FOCUS OF CELLULAR ALTERATION, EOSINOPHILIC  
-FOCUS OF CELLULAR ALTERATION, VACUOLATED

PITUITARY GLAND ..... (PRESENT)  
-8- ADENOMA

**Appendix J (cont.): PATHOLOGY INDIVIDUAL ANIMAL DATA**

LETTERMAN ARMY INSTITUTE OF RESEARCH  
 DIV OF RES SUPP, PATH SERV GP  
 SPECIES: RAT/FISCHER-344

INDIVIDUAL ANIMAL DATA REPORT  
 STUDY NUMBER: GLP83009

STUDY START DATE: 23-JAN-84

ANIMAL NUMBER: 165/PRETEST= 165 SEX: MALE DOSE GROUP: 3 SACRIFICE STATUS: FINAL SACRIFICE  
 DATE OF DEATH: 29-JAN-86 STUDY DAY OF DEATH: 738 STUDY WEEK OF DEATH: 106 TERMINAL BODY WEIGHT: 389.00 (GMS)

STUDY TYPE: CHRONIC/2 YR CARCINOGENIC

PRINTED: 21-NOV-89

PAGE: 341

<< GROSS ORGAN OBSERVATIONS >>

ORGAN NAME	KEYWORDS / PHRASES	SEVERITY	GROSS FREE-TEXT COMMENTS
TESTES	DISCOLORATION	PRESENT	LEFT, MOTTLED RED AND WHITE
TESTES	GROWTH(S) / MASS(ES)	PRESENT	BILATERAL, MULTIPLE VARIABLY SIZED,
TESTES	ENLARGED	PRESENT	LEFT, 3, X 2CM
LIVER	PROMINENT LOBULAR MARKINGS	PRESENT	

<< MICROSCOPIC TISSUE OBSERVATIONS >>

TISSUE / HISTOPATHOLOGIC FINDINGS

THYROID GLANDS  
 -PARA-FOLLICULAR CELL HYPERPLASIA ("C" CELL, LIGHT CELL) NOT SPECIFIED (TRACE)

EXORBITAL LACRIM TISSUE IS MISSING

HEART  
 -CARDIOMYOPATHY NOT SPECIFIED (MILD)  
 -MEDIAL HYPERTROPHY OF MUSCULAR ARTERIES NOT SPECIFIED (MILD)

LUNGS  
 -VASCULAR CONGESTION NOT SPECIFIED (PRESENT)  
 -MINERALIZATION OF PULMONARY ARTERIES NOT SPECIFIED (TRACE)

SPLEEN  
 -HISTIOCYTIC INFILTRATE, CAPSULE AND OMENTUM NOT SPECIFIED (PRESENT)

LIVER  
 -BILE DUCTULE EPITHELIAL HYPERPLASIA AND/OR CHOLANGIOFIBROSIS NOT SPECIFIED (MODERATE)  
 -CYSTIC DEGENERATION NOT SPECIFIED (PRESENT)

KIDNEY  
 -PROGRESSIVE RENAL DISEASE NOT SPECIFIED (MODERATE)

PROSTATE

Appendix J (cont.): PATHOLOGY INDIVIDUAL ANIMAL DATA

LETTERMAN ARMY INSTITUTE OF RESEARCH  
DIV OF RES SUPP, PATH SERV GP  
SPECIES: RAT/FISCHER-344

INDIVIDUAL ANIMAL DATA REPORT  
STUDY NUMBER: GLP83009  
STUDY START DATE: 23-JAN-84

PRINTED: 21-NOV-89  
PAGE: 342

STUDY TYPE: CHRONIC/2 YR CARCINOGENIC

ANIMAL NUMBER: 165/PRETEST# 165 SEX: MALE DOSE GROUP: 3 SACRIFICE STATUS: FINAL SACRIFICE  
DATE OF DEATH: 29-JAN-86 STUDY DAY OF DEATH: 738 STUDY WEEK OF DEATH: 106 TERMINAL BODY WEIGHT: 389.00 (GMS)

TISSUE / HISTOPATHOLOGIC FINDINGS << MICROSCOPIC TISSUE OBSERVATIONS >>  
DISTRIBUTION (SEVERITY) / SPECIAL COMMENTS

PROSTATE .....  
-ACUTE SUPPURATIVE PROSTATITIS ..... NOT SPECIFIED(TRACE)  
-BENIGN HYPERPLASIA ..... NOT SPECIFIED(TRACE)

SEMINAL VESICLE .....  
-GENERALIZED ATROPHY ..... NOT SPECIFIED (PRESENT)

TESTES .....  
-B- INTERSTITIAL CELL ADENOMA ..... (PRESENT)

PANCREAS .....  
-CHRONIC INFLAMMATION ..... NOT SPECIFIED(TRACE)

SKIN .....  
-CELLULITIS ..... DIFFUSE(MILD)

NOSE/TURBINATES ..... THE INFILTRATE IS PRIMARILY SUPPURATIVE AND LIES ADJACENT TO  
THE NASO-LACRIMAL DUCT.  
-MIXED INFLAMMATORY CELL INFILTRATION, NASAL CAVITY, SINUSES, NOT SPECIFIED(MODERATE)  
TURBINATES, NASO-LACRIMAL DUCTS

ADRENAL .....  
-FOCUS OF CELLULER ALTERATION, EOSINOPHILIC ..... NOT SPECIFIED(TRACE)

PITUITARY GLAND .....  
-B- ADENOMA ..... (PRESENT)

EYES & OPTIC N. .... NO EVIDENCE OF CONJUNCTIVITIS WAS OBSERVED IN THE LIMITED AMOUNT  
OF CONJUNCTIVA AVAILABLE. HARDERIAN GLANDS HAD A MARKED AMOUNT  
OF PIGMENTED SECRETORY PRODUCT WHICH MAY HAVE ACCOUNTED FOR THE  
GROSS IMPRESSION OF CONJUNCTIVITIS.



Appendix J (cont.): PATHOLOGY INDIVIDUAL ANIMAL DATA

LETTERMAN ARMY INSTITUTE OF RESEARCH  
DIV OF RES SUPP, PATH SERV GP  
SPECIES: RAT/FISCHER-344  
STUDY NUMBER: GLP83009  
STUDY START DATE: 23-JAN-84  
STUDY TYPE: CHRONIC/2 YR CARCINOGENIC  
PRINTED: 21-NOV-89  
PAGE: 343

ANIMAL NUMBER: 166/PRETEST= 166 SEX: MALE DOSE GROUP: 3 SACRIFICE STATUS: FINAL SACRIFICE  
DATE OF DEATH: 29-JAN-86 STUDY DAY OF DEATH: 738 STUDY WEEK OF DEATH: 106 TERMINAL BODY WEIGHT: 360.00 (GMS)

<< GROSS ORGAN OBSERVATIONS >>  
SEVERITY GROSS FREE-TEXT COMMENTS  
PITUITARY GLAND ENLARGED PRESENT DARK RED, .4CM DIAMETER  
SPLEEN MODULE PRESENT GRAY/WHITE, 1CM DIAMETER  
TESTES GROWTH(S) / MASS(ES) PRESENT BILATERAL, MULTIPLE VARIABLY SIZED, YELLOW/BLACK  
SKIN ABSCESS(ES) PRESENT RIGHT, NASOMAXILLARY, 2CM DIAMETER

<< MICROSCOPIC TISSUE OBSERVATIONS >>  
DISTRIBUTION (SEVERITY) / SPECIAL COMMENTS

BRAIN ..... SECONDARY NEOPLASM FROM ORGAN PITUITARY GLAND  
-I-PITUITARY TUMOR INVASION .....  
THYROID GLANDS ..... NOT SPECIFIED(TRACE)  
-PARA-FOLLICULAR CELL HYPERPLASIA ("C" CELL, LIGHT CELL) .....  
HEART ..... NOT SPECIFIED(MILD)  
-CARDIOMYOPATHY .....  
LUNGS ..... NOT SPECIFIED(TRACE)  
-MINERALIZATION OF PULMONARY ARTERIES .....  
-PERIBRONCHIAL LYMPHOID HYPERPLASIA .....  
SPLEEN ..... NOT SPECIFIED(MODERATE)  
-INFARCTION, CHRONIC .....  
-BENIGN HYPERTROPHIC NODULE .....  
LYMPH NODES ..... THE REACTIVE HYPERPLASIA INVOLVES THE CERVICAL LYMPH NODES.  
NUMEROUS PLASMA CELLS ARE IN THE CONNECTIVE TISSUES AT THE HYLUS  
OF THE NODE.  
NOT SPECIFIED (PRESENT)  
-REACTIVE HYPERPLASIA  
LIVER ..... NOT SPECIFIED(MILD)  
-BILE DUCTULE EPITHELIAL HYPERPLASIA AND/OR CHOLANGIOFIBROSIS

Appendix J (cont.): PATHOLOGY INDIVIDUAL ANIMAL DATA

LETTERMAN ARMY INSTITUTE OF RESEARCH  
 DIV OF RES SUPP, PATH SERV GP  
 SPECIES: RAT/FISCHER-344  
 STUDY NUMBER: GLP83009  
 STUDY START DATE: 23-JAN-64  
 STUDY TYPE: CHRONIC/2 YR CARCINOGENIC  
 ANIMAL NUMBER: 166/PRETEST= 166 SEX: MALE DOSE GROUP: 3 SACRIFICE STATUS: FINAL SACRIFICE  
 DATE OF DEATH: 29-JAN-86 STUDY DAY OF DEATH: 738 STUDY WEEK OF DEATH: 106 TERMINAL BODY WEIGHT: 360.00 (GMS)  
 << MICROSCOPIC TISSUE OBSERVATIONS >>  
 TISSUE / HISTOPATHOLOGIC FINDINGS DISTRIBUTION (SEVERITY) / SPECIAL COMMENTS

PRINTED: 21-NOV-89  
PAGE: 344

- LIVER .....  
 -HEPATOCTYIC VACUOLIZATION .....  
 -FOCUS OF CELLULAR ALTERATION - CLEAR CELLS .....  
 MULTI-FOCAL(TRACE)  
 NOT SPECIFIED(MILD)
- KIDNEY .....  
 -PROGRESSIVE RENAL DISEASE .....  
 NOT SPECIFIED(MARKED)
- PROSTATE .....  
 -CHRONIC PROSTATITIS .....  
 -BENIGN HYPERPLASIA .....  
 NOT SPECIFIED(MILD)  
 NOT SPECIFIED(MILD)
- SEMINAL VESICLE .....  
 -GENERALIZED ATROPHY .....  
 NOT SPECIFIED (PRESENT)
- TESTES .....  
 -B- INTERSTITIAL CELL ADENOMA .....  
 (PRESENT)
- SKIN .....  
 -B- KERATOACANTHOMA, ANATOMIC SITE TO BE SPECIFIED .....  
 THE LESION IN THE RIGHT NASOMAXILLARY AREA DIAGNOSED GROSSLY AS AN ABSCESS IS A LARGE KERATIN-FILLED CYSTIC CAVITY WITH A PROLIFERATIVE SQUAMOUS EPITHELIAL LINING COMPATIBLE WITH KERATOACANTHOMA. THE CYSTIC CAVITY CONTAINS NUMEROUS NEUTROPHILS IN ADDITION TO THE KERATIN.  
 (PRESENT)
- MAMMARY GLANDS .....  
 -HYPERPLASIA AND/OR HYPERTROPHY OF THE ACINAR TISSUE .....  
 -DILATATION (ECTASIA) OF DUCTS AND DUCTULES .....  
 NOT SPECIFIED(MODERATE)  
 NOT SPECIFIED (PRESENT)
- NOSE/TURBINATES .....  
 -MIXED INFLAMMATORY CELL INFILTRATION, NASAL CAVITY, SINUSES, TURBINATES, NASO-LACRIMAL DUCTS .....  
 INFILTRATE IS UNILATERAL AND INVOLVES THE NASO-LACRIMAL DUCT.  
 NOT SPECIFIED(MILD)
- PITUITARY GLAND .....  
 -M- ADENOCARCINOMA .....  
 (PRESENT)

Appendix J (cont.): PATHOLOGY INDIVIDUAL ANIMAL DATA

LETTERMAN ARMY INSTITUTE OF RESEARCH  
DIV OF RES SUPP, PATH SERV GP  
SPECIES: RAT/FISCHER-344

INDIVIDUAL ANIMAL DATA REPORT  
STUDY NUMBER: GLP83009

STUDY START DATE: 23-JAN-84

STUDY WEEK OF DEATH: 106

TERMINAL BODY WEIGHT: 389.00 (GMS)

STUDY TYPE: CHRONIC/2 YR CARCINOGENIC

DATE OF DEATH: 29-JAN-86

STUDY DAY OF DEATH: 730

ANIMAL NUMBER: 167/PRETEST=

SEX: MALE

DOSE GROUP: 3

SACRIFICE STATUS: FINAL SACRIFICE

SEVERITY: 3

SEVERITY: 3

SEVERITY: 3

SEVERITY: 3

ORGAN NAME

TESTES

KIDNEY

PITUITARY GLAND

ENLARGED

GROWTH(S) / MASS(ES)

GRANULAR SURFACE

ENLARGED

KEYWORDS / PHRASES

ENLARGED

GROWTH(S) / MASS(ES)

GRANULAR SURFACE

ENLARGED

ENLARGED

ENLARGED

ENLARGED

SEVERITY

PRESENT

PRESENT

PRESENT

PRESENT

PRESENT

PRESENT

PRESENT

GROSS OBSERVATIONS

RIGHT, 2.5 X 1.5CM

BILATERAL, MULTIPLE VARIABLY SIZED, YELLOW

DARK RED, .6CM DIAMETER

DARK RED, .6CM DIAMETER

DARK RED, .6CM DIAMETER

DARK RED, .6CM DIAMETER

DARK RED, .6CM DIAMETER

TISSUE OBSERVATIONS

TISSUE OBSERVATIONS

TISSUE OBSERVATIONS

TISSUE OBSERVATIONS

TISSUE OBSERVATIONS

TISSUE OBSERVATIONS

TISSUE OBSERVATIONS

TISSUE OBSERVATIONS

TRACHEA

HEART

LUNGS

LIVER

KIDNEY

TRACHEA

HEART

LUNGS

-SUPPURATIVE TRACHEITIS

-CARDIOMYOPATHY

-MINERALIZATION OF PULMONARY ARTERIES

-PERIBRONCHIAL LYMPHOID HYPERPLASIA

-BILE DUCTULE EPITHELIAL HYPERPLASIA AND/OR CHOLANGIOFIBROSIS

-HEPATOCTYIC VACUOLIZATION

-CYSTIC DEGENERATION

-HEPATOCTYIC DEGENERATIVE CHANGES (NON-NECROTIC)

-HEPATOCTYIC COALESCING MICROVESICULAR (FATTY) CHANGE LEADING TO NECROSIS AND MINERALIZATION

-PROGRESSIVE RENAL DISEASE

-PROGRESSIVE RENAL DISEASE

-PROGRESSIVE RENAL DISEASE

-PROGRESSIVE RENAL DISEASE

-PROGRESSIVE RENAL DISEASE

-PROGRESSIVE RENAL DISEASE

-PROGRESSIVE RENAL DISEASE

DISTRIBUTION (SEVERITY) / SPECIAL COMMENTS

DISTRIBUTION (SEVERITY) / SPECIAL COMMENTS

DISTRIBUTION (SEVERITY) / SPECIAL COMMENTS

DISTRIBUTION (SEVERITY) / SPECIAL COMMENTS

DISTRIBUTION (SEVERITY) / SPECIAL COMMENTS

DISTRIBUTION (SEVERITY) / SPECIAL COMMENTS

DISTRIBUTION (SEVERITY) / SPECIAL COMMENTS

DISTRIBUTION (SEVERITY) / SPECIAL COMMENTS

NOT SPECIFIED (TRACE)

NOT SPECIFIED (MILD)

NOT SPECIFIED (TRACE)

NOT SPECIFIED (TRACE)

NOT SPECIFIED (MILD)

NOT SPECIFIED (MILD)

NOT SPECIFIED (PRESENT)

NOT SPECIFIED (TRACE)

NOT SPECIFIED (TRACE)

NOT SPECIFIED (TRACE)

NOT SPECIFIED (TRACE)

NOT SPECIFIED (TRACE)

NOT SPECIFIED (TRACE)

NOT SPECIFIED (TRACE)

NOT SPECIFIED (TRACE)

NOT SPECIFIED (TRACE)

NOT SPECIFIED (MARKED)

NOT SPECIFIED (MARKED)

NOT SPECIFIED (MARKED)

NOT SPECIFIED (MARKED)

NOT SPECIFIED (MARKED)

NOT SPECIFIED (MARKED)

NOT SPECIFIED (MARKED)

NOT SPECIFIED (MARKED)

Appendix J (cont.): PATHOLOGY INDIVIDUAL ANIMAL DATA

LETTERMAN ARMY INSTITUTE OF RESEARCH  
 DIV OF RES SUPP, PATH SERV GP  
 SPECIES: RAT/FISCHER-344  
 STUDY START DATE: 23-JAN-84  
 ANIMAL NUMBER: 167/PRETEST-167 SEX: MALE DOSE GROUP: 3 SACRIFICE STATUS: FINAL SACRIFICE  
 DATE OF DEATH: 29-JAN-86 STUDY DAY OF DEATH: 738 STUDY WEEK OF DEATH: 106 TERMINAL BODY WEIGHT: 389.00 (GMS)  
 TISSUE / HISTOPATHOLOGIC FINDINGS  
 << MICROSCOPIC TISSUE OBSERVATIONS >>  
 DISTRIBUTION (SEVERITY) / SPECIAL COMMENTS

INDIVIDUAL ANIMAL DATA REPORT  
 STUDY NUMBER: GLP83009  
 STUDY TYPE: CHRONIC/2 YR CARCINOGENIC  
 PRINTED: 21-NOV-89  
 PAGE: 366

URINARY BLADDER ..... TISSUE IS MISSING

PROSTATE .....  
 -CHRONIC PROSTATITIS ..... NOT SPECIFIED(MODERATE)  
 -BENIGN HYPERPLASIA ..... NOT SPECIFIED(MODERATE)

TESTES ..... (PRESENT)  
 -B- INTERSTITIAL CELL ADENOMA ..... (PRESENT)

TONGUE .....  
 -MONONUCLEAR CELLULAR INFILTRATION ..... FOCAL(TRACE)

MAMMARY GLANDS .....  
 -HYPERPLASIA AND/OR HYPERTROPHY OF THE ACINAR TISSUE ..... NOT SPECIFIED(MARKED)  
 -DILATATION (ECTASIA) OF DUCTS AND DUCTULI ..... NOT SPECIFIED (PRESENT)

NOSE/TURBINATES ..... THE INFILTRATE IS PRIMARILY SUPPURATIVE AND INVOLVES NASO-  
 -MIXED INFLAMMATORY CELL INFILTRATION, NASAL CAVITY, SINUSES, LACRIMAL DUCTS BILATERALLY.  
 TURBINATES, NASO-LACRIMAL DUCTS ..... NOT SPECIFIED(MODERATE)

ADRENAL .....  
 -FOCUS OF CELLULAR ALTERATION, VACUOLATED ..... NOT SPECIFIED(TRACE)

PITUITARY GLAND .....  
 -B- ADENOMA ..... (PRESENT)

EYES & OPTIC N. ....  
 -METAPLASTIC BONE FORMATION AND/OR MINERALIZATION, SCLERA ..... NOT SPECIFIED (PRESENT)

Appendix J (cont.): PATHOLOGY INDIVIDUAL ANIMAL DATA

LETTERMAN ARMY INSTITUTE OF RESEARCH  
 DIV OF RES SUPP, PATH SERV GP  
 SPECIES: RAT/FISCHER-344  
 ANIMAL NUMBER: 168/PRETEST= 168 SEX: MALE  
 DATE OF DEATH: 29-JAN-86 STUDY DAY OF DEATH: 738  
 DOSE GROUP: 3 SACRIFICE STATUS: FINAL SACRIFICE  
 STUDY WEEK OF DEATH: 106 TERMINAL BODY WEIGHT: 392.00 (GMS)

INDIVIDUAL ANIMAL DATA REPORT  
 STUDY NUMBER: GLP83009  
 STUDY START DATE: 23-JAN-84  
 STUDY TYPE: CHRONIC/2 YR CARCINOGENIC  
 PRINTED: 21-NOV-89  
 PAGE: 347

ORGAN NAME SEVERITY GROSS FREE-TEXT COMMENTS  
 LIVER PRESENT MOTTLED RED AND YELLOW  
 SPLEEN ENLARGED (SPLENOMEGALY) MARKED 8.5 X 2.5CM  
 LUNGS PRESENT MULTIPLE, RED, .1CM DIAMETER  
 KIDNEY DISCOLORATION PRESENT BILATERAL, GREEN  
 TESTES GROWTH(S) / MASS(ES) PRESENT BILATERAL, MULTIPLE VARIABLY SIZED, YELLOW  
 PITUITARY GLAND DISCOLORATION PRESENT .2CM DIAMETER, RED

TISSUE / HISTOPATHOLOGIC FINDINGS  
 << MICROSCOPIC TISSUE OBSERVATIONS >>  
 DISTRIBUTION (SEVERITY) / SPECIAL COMMENTS

THYROID GLANDS (PRESENT)  
 -B- PARA-FOLLICULAR CELL ADENOMA (PRESENT)  
 HEART (PRESENT)  
 -MEDIAL HYPERTROPHY OF MUSCULAR ARTERIES MULTI-FOCAL(MILD)  
 LUNGS (PRESENT)  
 -PNEUMONIA, INTERSTITIAL, CHRONIC MULTI-FOCAL(MILD)  
 -N- LARGE GRANULAR LYMPHOCYTE LEUKEMIA, METASTATIC (PRESENT)  
 -ALVEOLAR HEMORRHAGE NOT SPECIFIED (PRESENT)  
 -PERIBRONCHIAL LYMPHOID HYPERPLASIA MULTI-FOCAL(MILD)  
 THYMUS (PRESENT)  
 -N- LARGE GRANULAR LYMPHOCYTE LEUKEMIA, METASTATIC (PRESENT)  
 SPLEEN (PRESENT)  
 -N- LARGE GRANULAR LYMPHOCYTE LEUKEMIA, METASTATIC (PRESENT)  
 LYMPH NODES (PRESENT)  
 -N- LARGE GRANULAR LYMPHOCYTE LEUKEMIA, METASTATIC (PRESENT)  
 LIVER (PRESENT)

Appendix J (cont.): PATHOLOGY INDIVIDUAL ANIMAL DATA

LETTERMAN ARMY INSTITUTE OF RESEARCH  
 DIV OF RES SUPP. PATH SERV GP  
 SPECIES: RAT/FISCHER-344

INDIVIDUAL ANIMAL DATA REPORT  
 STUDY NUMBER: GLP83009  
 STUDY START DATE: 23-JAN-84

PRINTED: 21-NOV-89  
 PAGE: 348  
 STUDY TYPE: CHRONIC/2 YR CARCINOGENIC

ANIMAL NUMBER: 168/PRETEST#  
 DATE OF DEATH: 29-JAN-86

168 SEX: MALE  
 DOSE GROUP: 3  
 SACRIFICE STATUS: FINAL SACRIFICE

STUDY DAY OF DEATH: 738  
 STUDY WEEK OF DEATH: 106  
 TERMINAL BODY WEIGHT: 392.00 (GMS)

<< M I C R O S C O P I C T I S S U E O B S E R V A T I O N S >>  
 TISSUE / HISTOPATHOLOGIC FINDINGS DISTRIBUTION (SEVERITY) / SPECIAL COMMENTS

LIVER .....  
 -BILE DUCTULE EPITHELIAL HYPERPLASIA AND/OR CHOLANGIOFIBROSIS ..... NOT SPECIFIED(MILD)  
 -NECROSIS ..... MULTI-FOCAL(MODERATE)  
 -HEPATOCTYIC DEGENERATIVE CHANGES (NON-NECROTIC) ..... DIFFUSE(MILD)  
 -M- LARGE GRANULAR LYMPHOCYTE LEUKEMIA, METASTATIC ..... (PRESENT)

KIDNEY .....  
 -PROGRESSIVE RENAL DISEASE ..... NOT SPECIFIED(MILD)

PROSTATE .....  
 -BENIGN HYPERPLASIA ..... NOT SPECIFIED(MILD)

SEMINAL VESICLE .....  
 -GENERALIZED ATROPHY ..... NOT SPECIFIED (PRESENT)

TESTES .....  
 -B- INTERSTITIAL CELL ADENOMA ..... (PRESENT)

PANCREAS .....  
 -B- ISLET CELL ADENOMA ..... (PRESENT)

MAMMARY GLANDS .....  
 -HYPERPLASIA AND/OR HYPERTROPHY OF THE ACINAR TISSUE ..... NOT SPECIFIED(MARKED)  
 -DILATATION (ECTASIA) OF DUCTS AND DUCTULES ..... NOT SPECIFIED (PRESENT)

NOSE/TURBINATES .....  
 -MIXED INFLAMMATORY CELL INFILTRATION, NASAL CAVITY, SINUSES, TURBINATES, MASO-LACRIMAL DUCTS ..... THE INFILTRATE IS PRIMARILY SUPPURATIVE AND INVOLVES MASO-LACRIMAL DUCTS BILATERALLY.  
 NOT SPECIFIED(MODERATE)

BONE, STERNUM .....  
 -MYELOID HISTIOCYTOSIS ..... NOT SPECIFIED (PRESENT)

BONE, FEMUR .....  
 NOT SPECIFIED (PRESENT)

Appendix J (cont.): PATHOLOGY INDIVIDUAL ANIMAL DATA

LETTERMAN ARMY INSTITUTE OF RESEARCH  
DIV OF RES SUPP, PATH SERV GP  
SPECIES: RAT/FISCHER-344

INDIVIDUAL ANIMAL DATA REPORT  
STUDY NUMBER: GLP83009

PRINTED: 21-NOV-89  
PAGE: 349

STUDY START DATE: 23-JAN-84

STUDY TYPE: CHRONIC/2 YR CARCINOGENIC

ANIMAL NUMBER: 168/PRETEST-168  
DATE OF DEATH: 29-JAN-86  
SEX: MALE  
STUDY DAY OF DEATH: 738

DOSE GROUP: 3  
STUDY WEEK OF DEATH: 106

SACRIFICE STATUS: FINAL SACRIFICE  
TERMINAL BODY WEIGHT: 392.00 (GMS)

<< MICROSCOPIC TISSUE OBSERVATIONS >>  
DISTRIBUTION (SEVERITY) / SPECIAL COMMENTS

BONE, FEMUR ..... NOT SPECIFIED (PRESENT)  
-MYELOID HISTIOCYTOSIS

BONE VERT ..... NOT SPECIFIED (PRESENT)  
-MYELOID HISTIOCYTOSIS

ADRENAL ..... NOT SPECIFIED (TRACE)  
-LIPIDOSIS  
-FOCUS OF CELLULAR ALTERATION, EOSINOPHILIC  
-FOCUS OF CELLULAR ALTERATION, VACUOLATED

PITUITARY GLAND ..... (PRESENT)  
-B- ADENOMA  
-HEMORRHAGE

EYES & OPTIC N. .... NOT SPECIFIED (PRESENT)  
-METAPLASTIC BONE FORMATION AND/OR MINERALIZATION, SCLERA

WHOLE BODY ..... (PRESENT)  
-W- LARGE GRANULAR LYMPHOCYTIC LEUKEMIA

**Appendix J (cont.): PATHOLOGY INDIVIDUAL ANIMAL DATA**

LETTERMAN ARMY INSTITUTE OF RESEARCH  
 DIV OF RES SUPP, PATH SERV GP  
 SPECIES: RAT/FISCHER-344

INDIVIDUAL ANIMAL DATA REPORT  
 STUDY NUMBER: GLP83009

STUDY START DATE: 23-JAN-84

PRINTED: 21-NOV-89  
 PAGE: 350

STUDY TYPE: CHRONIC/2 YR CARCINOGENIC

ANIMAL NUMBER: 169/PRETEST= 169 SEX: MALE DOSE GROUP: 3 SACRIFICE STATUS: FINAL SACRIFICE  
 DATE OF DEATH: 30-JAN-86 STUDY DAY OF DEATH: 739 STUDY WEEK OF DEATH: 106 TERMINAL BODY WEIGHT: 354.00 (GMS)

ORGAN NAME	KEYWORDS / PHRASES	GROSS ORGAN OBSERVATIONS	SEVERITY	GROSS FREE-TEXT COMMENTS
SPLEEN	MODULE	PRESENT	PRESENT	.5CM DIAMETER, DARK
TESTES	ENLARGED	PRESENT	PRESENT	LEFT, 2.75 X 1.75CM
TESTES	GROWTH(S) / MASS(ES)	PRESENT	PRESENT	BILATERAL, MULTIPLE VARIABLY SIZED, YELLOW/BLACK
ADRENAL	DISCOLORATION	PRESENT	PRESENT	FOCAL, DARK, .1CM DIAMETER

TISSUE / HISTOPATHOLOGIC FINDINGS  
 << MICROSCOPIC TISSUE OBSERVATIONS >>  
 DISTRIBUTION (SEVERITY) / SPECIAL COMMENTS

- TRACHEA ..... NOT SPECIFIED (TRACE)
- NON-SUPPURATIVE TRACHEITIS
- HEART ..... NOT SPECIFIED (TRACE)
- CARDIOMYOPATHY
- LUNGS ..... NOT SPECIFIED (TRACE)
- PERIBRONCHIAL LYMPHOID HYPERPLASIA
- SPLEEN ..... NOT SPECIFIED (PRESENT)
- BENIGN HYPERTROPHIC MODULE
- LIVER ..... NOT SPECIFIED (MILD)
- BILE DUCTULE EPITHELIAL HYPERPLASIA AND/OR CHOLANGIOFIBROSIS
- HEPATITIS
- HEPATOCTYIC VACUOLIZATION
- BENIGN HYPERPLASTIC MODULE(S)
- FOCUS OF CELLULAR ALTERATION - EOSINOPHILIC CELLS
- KIDNEY ..... NOT SPECIFIED (MODERATE)
- PROGRESSIVE RENAL DISEASE
- PROSTATE .....



Appendix J (cont.): PATHOLOGY INDIVIDUAL ANIMAL DATA

LETTERMAN ARMY INSTITUTE OF RESEARCH  
DIV OF RES SUPP, PATH SERV GP  
SPECIES: RAT/FISCHER-344

INDIVIDUAL ANIMAL DATA REPORT  
STUDY NUMBER: GLP83009

PRINTED: 21-NOV-89  
PAGE: 351

STUDY START DATE: 23-JAN-84

STUDY TYPE: CHRONIC/2 YR CARCINOGENIC

ANIMAL NUMBER: 169/PRETEST# 169 SEX: MALE DOSE GROUP: 3 SACRIFICE STATUS: FINAL SACRIFICE  
DATE OF DEATH: 30-JAN-86 STUDY DAY OF DEATH: 739 STUDY WEEK OF DEATH: 106 TERMINAL BODY WEIGHT: 354.00 (GMS)

<< MICROSCOPIC TISSUE OBSERVATIONS >>  
TISSUE / HISTOPATHOLOGIC FINDINGS DISTRIBUTION (SEVERITY) / SPECIAL COMMENTS

PROSTATE ..... NOT SPECIFIED(MODERATE)  
-CHRONIC PROSTATITIS ..... NOT SPECIFIED(MILD)  
-BENIGN HYPERPLASIA

SEMINAL VESICLE ..... NOT SPECIFIED (PRESENT)  
-GENERALIZED ATROPHY

TESTES ..... (PRESENT)  
-B- INTERSTITIAL CELL ADENOMA

MAMMARY GLANDS ..... NOT SPECIFIED (PRESENT)  
-GALACTOCELE(S) ..... NOT SPECIFIED (PRESENT)  
-DILATATION (ECTASIA) OF DUCTS AND DUCTULES

NOSE/TURBINATES ..... INFILTRATE INVOLVES VENTRAL ASPECT OF THE NASAL CAVITY.  
-MIXED INFLAMMATORY CELL INFILTRATION, NASAL CAVITY, SINUSES, NOT SPECIFIED(TRACE)  
TURBINATES, NASO-LACRIMAL DUCTS

ADRENAL ..... NOT SPECIFIED(MILD)  
-FOCUS OF CELLULER ALTERATION, EOSINOPHILIC

EYES & OPTIC N. .... NOT SPECIFIED (PRESENT)  
-METAPLASTIC BONE FORMATION AND/OR MINERALIZATION, SCLERA

Appendix J (cont.): PATHOLOGY INDIVIDUAL ANIMAL DATA

LETTERMAN ARMY INSTITUTE OF RESEARCH  
 DIV OF RES SUPP, PATH SERV GP  
 SPECIES: RAT/FISCHER-344  
 INDIVIDUAL ANIMAL DATA REPORT  
 STUDY NUMBER: GLP83009  
 STUDY START DATE: 23-JAN-84  
 PRINTED: 21-NOV-89  
 PAGE: 352  
 STUDY TYPE: CHRONIC/2 YR CARCINOGENIC

ANIMAL NUMBER: 170/PRETEST= 170 SEX: MALE DOSE GROUP: 3 SACRIFICE STATUS: FINAL SACRIFICE  
 DATE OF DEATH: 30-JAN-86 STUDY DAY OF DEATH: 739 STUDY WEEK OF DEATH: 106 TERMINAL BODY WEIGHT: 362.00 (GMS)  
 ORGAN NAME << GROSS ORGAN OBSERVATIONS >>  
 KEYWORDS / PHRASES SEVERITY GROSS FREE-TEXT COMMENTS  
 ENLARGED PRESENT LEFT, 3 X 1.75CM  
 GROWTH(S) / MASS(ES) PRESENT BILATERAL, MULTIPLE VARIABLY SIZED, YELLOW

<< MICROSCOPIC TISSUE OBSERVATIONS >>  
 TISSUE / HISTOPATHOLOGIC FINDINGS DISTRIBUTION (SEVERITY) / SPECIAL COMMENTS

PARATHYROID ..... TISSUE IS MISSING  
 HEART ..... NOT SPECIFIED(MODERATE)  
 -CARDIOMYOPATHY

LUNGS ..... (PRESENT)  
 -B- BRONCHIOLAR/ALVEOLAR ADENOMA  
 THYMUS ..... (PRESENT)  
 -B- THYOMA

LYMPH NODES ..... METASTASIS OF THE PULMONARY ALVEOLAR/BRONCHIOLAR CARCINOMA WAS  
 DETECTED ON A SINGLE LYMPH NODE IN THE MEDIASTINUM. THERE ARE  
 RBC'S, HEMOSIDERIN, AND REACTIVE HYPERPLASTIC CHANGES IN  
 ADJACENT MEDIASTINAL NODES. MESENTERIC NODES ARE NORMAL.  
 -RED BLOOD CELLS, HEMOSIDERIN AND/OR ERYTHROPHAGOCYTOSIS WITHIN  
 MEDULLARY SINUSES  
 -REACTIVE HYPERPLASIA  
 -N- PRESENCE OF METASTATIC NEOPLASM

LIVER ..... NOT SPECIFIED (PRESENT)  
 -BILE DUCTULE EPITHELIAL HYPERPLASIA AND/OR CHOLANGIOFIBROSIS  
 -CYSTIC DEGENERATION  
 SECONDARY NEOPLASM FROM ORGAN LUNGS

KIDNEY ..... NOT SPECIFIED(MODERATE)  
 -PROGRESSIVE RENAL DISEASE  
 SEMINAL VESICLE ..... NOT SPECIFIED(MODERATE)

Appendix J (cont.): PATHOLOGY INDIVIDUAL ANIMAL DATA

LETTERMAN ARMY INSTITUTE OF RESEARCH  
DIV OF RES SUPP, PATH SERV GP  
SPECIES: RAT/FISCHER-344

INDIVIDUAL ANIMAL DATA REPORT  
STUDY NUMBER: GLP83009

STUDY START DATE: 23-JAN-84

PRINTED: 21-NOV-89  
PAGE: 353

STUDY TYPE: CHRONIC/2 YR CARCINOGENIC

ANIMAL NUMBER: 170/PRETEST# DOSE GROUP: 3 SACRIFICE STATUS: FINAL SACRIFICE  
DATE OF DEATH: 30-JAN-86 STUDY DAY OF DEATH: 739 STUDY WEEK OF DEATH: 106 TERMINAL BODY WEIGHT: 362.00 (GMS)

<< MICROSCOPIC TISSUE OBSERVATIONS >>  
TISSUE / HISTOPATHOLOGIC FINDINGS DISTRIBUTION (SEVERITY) / SPECIAL COMMENTS

SEMINAL VESICLE ..... NOT SPECIFIED (PRESENT)  
-GENERALIZED ATROPHY

TESTES ..... (PRESENT)  
-B- INTERSTITIAL CELL ADENOMA

SKIN ..... TISSUE IS MISSING  
MAMMARY GLANDS ..... TISSUE IS MISSING

NOSE/TURBINATES ..... INFILTRATE NEAR NASO-LACRIMAL DUCT.  
-MIXED INFLAMMATORY CELL INFILTRATION, NASAL CAVITY, SINUSES, NOT SPECIFIED(MILD)  
TURBINATES, NASO-LACRIMAL DUCTS

ADRENAL ..... NOT SPECIFIED (PRESENT)  
-CORTICAL NODULAR HYPERPLASIA

PITUITARY GLAND ..... (PRESENT)  
-B- ADENOMA

EYES & OPTIC N. ..... NOT SPECIFIED (PRESENT)  
-METAPLASTIC BONE FORMATION AND/OR MINERALIZATION, SCLERA

MEDIASTINUM ..... MISCELLANEOUS TISSUE  
SEE DIAGNOSIS AND HISTOLOGIC COMMENT UNDER LUMPH NODE.

Appendix J (cont.): PATHOLOGY INDIVIDUAL ANIMAL DATA

LETTERMAN ARMY INSTITUTE OF RESEARCH  
DIV OF RES SUPP, PATH SERV GP  
SPECIES: RAT/FISCHER-344

INDIVIDUAL ANIMAL DATA REPORT  
STUDY NUMBER: GLP83009  
STUDY START DATE: 23-JAN-84

PRINTED: 21-NOV-89  
PAGE: 354

STUDY TYPE: CHRONIC/2 YR CARCINOGENIC

ANIMAL NUMBER: 171/PRETEST# 171 SEX: MALE DOSE GROUP: 3 SACRIFICE STATUS: SACRIFICED MORIBUND  
DATE OF DEATH: 14-JAN-86 STUDY DAY OF DEATH: 723 STUDY WEEK OF DEATH: 104 TERMINAL BODY WEIGHT: 385.00 (GMS)

ORGAN NAME << GROSS ORGAN OBSERVATIONS >>  
KEYWORDS / PHRASES SEVERITY GROSS FREE-TEXT COMMENTS

LIVER PRESENT MODERATELY PALE  
TESTES PRESENT RIGHT, TWO .2-.3CM, WHITE, OPAQUE

TISSUE / HISTOPATHOLOGIC FINDINGS << MICROSCOPIC TISSUE OBSERVATIONS >>  
DISTRIBUTION (SEVERITY) / SPECIAL COMMENTS

HEART ..... MURAL THROMBUS IS IN THE ATRIUM  
-CARDIOMYOPATHY ..... NOT SPECIFIED(MODERATE)  
-MURAL THROMBUS ..... NOT SPECIFIED (PRESENT)

LUNGS ..... NOT SPECIFIED(MILD)  
-MINERALIZATION OF PULMONARY ARTERIES

SPLEEN ..... NOT SPECIFIED(MILD)  
-INFARCTION, CHRONIC

LIVER ..... PERIACINAR NECROSIS IS PROBABLY SECONDARY TO CARDIAC FAILURE  
-BILE DUCTULE EPITHELIAL HYPERPLASIA AND/OR CHOLANGIOFIBROSIS DUE TO THE MURAL THROMBUS  
-CYSTIC DEGENERATION ..... NOT SPECIFIED(MODERATE)  
-BENIGN HYPERPLASTIC MODULE(S) MULTI-FOCAL (PRESENT)  
-NECROSIS, PERIACINAR ..... NOT SPECIFIED(TRACE)  
..... NOT SPECIFIED(MODERATE)

KIDNEY ..... NOT SPECIFIED(MILD)  
-PROGRESSIVE RENAL DISEASE

PROSTATE ..... NOT SPECIFIED(MODERATE)  
-CHRONIC PROSTATITIS ..... NOT SPECIFIED(MILD)  
-BENIGN HYPERPLASIA

SEMINAL VESICLE ..... NOT SPECIFIED (PRESENT)  
-GENERALIZED ATROPHY

TESTES .....

Appendix J (cont.): PATHOLOGY INDIVIDUAL ANIMAL DATA

LETTERMAN ARMY INSTITUTE OF RESEARCH  
DIV OF RES SUPP, PATH SERV GP  
SPECIES: RAY/FISCHER-344

INDIVIDUAL ANIMAL DATA REPORT  
STUDY NUMBER: GLP83009  
STUDY START DATE: 23-JAN-84

PRINTED: 21-NOV-89  
PAGE: 355  
STUDY TYPE: CHRONIC/2 YR CARCINOGENIC

ANIMAL NUMBER: 171/PRETEST# 171 SEX: MALE DOSE GROUP: 3 SACRIFICE STATUS: SACRIFICED MORIBUND  
DATE OF DEATH: 14-JAN-86 STUDY DAY OF DEATH: 723 STUDY WEEK OF DEATH: 104 TERMINAL BODY WEIGHT: 385.00 (GMS)

<< MICROSCOPIC TISSUE OBSERVATIONS >>  
TISSUE / HISTOPATHOLOGIC FINDINGS  
DISTRIBUTION (SEVERITY) / SPECIAL COMMENTS

TESTES ..... (PRESENT)  
-B- INTERSTITIAL CELL ADENOMA

ADRENAL ..... NOT SPECIFIED(MILD)  
-FOCUS OF CELLULAR ALTERATION, VACUOLATED

PITUITARY GLAND ..... (PRESENT)  
-B- ADENOMA

EYES & OPTIC N. .... NOT SPECIFIED (PRESENT)  
-METAPLASTIC BONE FORMATION AND/OR MINERALIZATION, SCLERA

Appendix J (cont.): PATHOLOGY INDIVIDUAL ANIMAL DATA

LETTERMAN ARMY INSTITUTE OF RESEARCH INDIVIDUAL ANIMAL DATA REPORT PRINTED: 21-NOV-89  
DIV OF RES SUPP, PATH SERV GP STUDY NUMBER: GLP83009 PAGE: 356  
SPECIES: RAT/FISCHER-344 STUDY START DATE: 23-JAN-84 STUDY TYPE: CHRONIC/2 YR CARCINOGENIC

ANIMAL NUMBER: 172/PRETEST= 172 SEX: MALE DOSE GROUP: 3 SACRIFICE STATUS: FINAL SACRIFICE  
DATE OF DEATH: 30-JAN-86 STUDY DAY OF DEATH: 739 STUDY WEEK OF DEATH: 106 TERMINAL BODY WEIGHT: 371.00 (GMS)

ORGAN NAME << GROSS ORGAN OBSERVATIONS >>  
KEYWORDS / PHRASES SEVERITY GROSS FREE-TEXT COMMENTS  
PITUITARY GLAND ENLARGED PRESENT 4 X 5MM, DARK RED  
MAMMARY GLAND PROMINENT PRESENT AXILLARY REGION, BILATERAL, YELLOW

TISSUE / HISTOPATHOLOGIC FINDINGS << MICROSCOPIC TISSUE OBSERVATIONS >>  
DISTRIBUTION (SEVERITY) / SPECIAL COMMENTS

EXORBITAL LACRIM ..... FOCAL(TRACE)  
-SUBACUTE INFLAMMATION

HEART ..... NOT SPECIFIED(MILD)  
-CARDIOMYOPATHY ..... NOT SPECIFIED(TRACE)  
-MEDIAL HYPERTROPHY OF MUSCULAR ARTERIES

LYMPH NODES ..... REACTIVE HYPERPLASIA LIMITED TO CERVICAL NODES.  
-REACTIVE HYPERPLASIA ..... NOT SPECIFIED (PRESENT)

LIVER ..... NOT SPECIFIED(MILD)  
-BILE DUCTULE EPITHELIAL HYPERPLASIA AND/OR CHOLANGIOFIBROSIS ..... MULTI-FOCAL(TRACE)  
-HEPATOCTYIC VACUOLIZATION ..... NOT SPECIFIED(TRACE)  
-FOCUS OF CELLULAR ALTERATION - CLEAR CELLS

KIDNEY ..... NOT SPECIFIED(MODERATE)  
-PROGRESSIVE RENAL DISEASE

PROSTATE ..... NOT SPECIFIED(MILD)  
-CHRONIC PROSTATITIS ..... NOT SPECIFIED(TRACE)  
-BENIGN HYPERPLASIA

TESTES ..... SMALL INTERSTITIAL CELL ADENOMAS WERE DETECTED MICROSCOPICALLY  
IN BOTH TESTES. THESE TUMORS ARE TOO SMALL TO BE EVIDENT  
ON GROSS EXAMINATION.  
-B- INTERSTITIAL CELL ADENOMA (PRESENT)

Appendix J (cont.): PATHOLOGY INDIVIDUAL ANIMAL DATA

LETTERMAN ARMY INSTITUTE OF RESEARCH  
DIV OF RES SUPP, PATH SERV GP  
SPECIES: RAT/FISCHER-344  
INDIVIDUAL ANIMAL DATA REPORT  
STUDY NUMBER: GLP83009  
STUDY START DATE: 23-JAN-84  
STUDY TYPE: CHRONIC/2 YR CARCINOGENIC

PRINTED: 21-NOV-89  
PAGE: 357

ANIMAL NUMBER: 172/PRETEST-  
DATE OF DEATH: 30-JAN-86  
DOSE GROUP: 3  
SEX: MALE  
STUDY DAY OF DEATH: 739  
STUDY WEEK OF DEATH: 106  
SACRIFICE STATUS: FINAL SACRIFICE  
TERMINAL BODY WEIGHT: 371.00 (GMS)

<< MICROSCOPIC TISSUE OBSERVATIONS >>  
TISSUE / HISTOPATHOLOGIC FINDINGS  
DISTRIBUTION (SEVERITY) / SPECIAL COMMENTS

MAMMARY GLANDS ..... THE PROMINENT MAMMARY TISSUE OBSERVED GROSSLY IS A GALACTOCELE.  
WITHIN THE CAVITY OF THIS LESION THERE ARE SMALL FOCI OF  
PROLIFERATING GRANULATION TISSUE, PROBABLY THE RESULT OF AN  
ORGANIZING HEMATOMA.  
NOT SPECIFIED (PRESENT)

- GALACTOCELE(S)  
NOSE/TURBINATES ..... INFILTRATE: BILATERAL NEAR NASO-LACRIMAL DUCTS  
NOT SPECIFIED(MILD)  
- MIXED INFLAMMATORY CELL INFILTRATION, NASAL CAVITY, SINUSES,  
TURBINATES, NASO-LACRIMAL DUCTS

ADRENAL ..... NOT SPECIFIED (TRACE)  
- FOCUS OF CELLULAR ALTERATION, VACUOLATED  
(PRESENT)  
PITUITARY GLAND .....  
- B- ADENOMA

EYES & OPTIC N. .... THE LENSES OF BOTH EYES HAVE CHANGES CONSISTENT WITH EARLY SUB-  
CAPSULAR CATARACT FORMATION. THESE MILD CHANGES MAY NOT HAVE  
BEEN EVIDENT ON GROSS EXAMINATION.  
NOT SPECIFIED (PRESENT)  
NOT SPECIFIED (PRESENT)

- METAPLASTIC BONE FORMATION AND/OR MINERALIZATION, SCLERA  
- LENTICULAR DEGENERATIVE CHANGES COMPATIBLE WITH CATARACT

Appendix J (cont.): PATHOLOGY INDIVIDUAL ANIMAL DATA

LETTERMAN ARMY INSTITUTE OF RESEARCH  
 DIV OF RES SUPP, PATH SERV GP  
 SPECIES: RAT/FISCHER-344  
 STUDY START DATE: 23-JAN-84  
 INDIVIDUAL ANIMAL DATA REPORT  
 STUDY NUMBER: GLP83009  
 PRINTED: 21-NOV-89  
 PAGE: 358  
 ANIMAL NUMBER: 173/PRETEST# 173 SEX: MALE DOSE GROUP: 3 SACRIFICE STATUS: SACRIFICED MORIBUND  
 DATE OF DEATH: 14-JAN-86 STUDY DAY OF DEATH: 723 STUDY WEEK OF DEATH: 104 TERMINAL BODY WEIGHT: 285.00 (GMS)  
 STUDY TYPE: CHRONIC/2 YR CARCINOGENIC  
 << GROSS ORGAN OBSERVATIONS >>  
 ORGAN NAME SEVERITY GROSS FREE-TEXT COMMENTS  
 KIDNEY DISCOLORATION PRESENT FOCAL, MINUTE, MULTIPLE, WHITE  
 TESTES GROWTH(S) / MASS(ES) PRESENT BILATERAL, MULTIPLE VARIABLY SIZED, WHITE  
 PITUITARY GLAND ENLARGED PRESENT .3-.4CM DIAMETER  
 LIVER PROMINENT LOBULAR MARKINGS PRESENT

TISSUE / HISTOPATHOLOGIC FINDINGS << MICROSCOPIC TISSUE OBSERVATIONS >>  
 DISTRIBUTION (SEVERITY) / SPECIAL COMMENTS

- THYROID GLANDS ..... (PRESENT)
- B- PARA-FOLLICULAR CELL ADENOMA
- PARATHYROID ..... TISSUE IS MISSING
- HEART ..... NOT SPECIFIED(MODERATE)
- CARDIOMYOPATHY
- LUNGS ..... NOT SPECIFIED(MODERATE)
- MINERALIZATION OF PULMONARY ARTERIES
- LIVER ..... NOT SPECIFIED(MILD)
- BILE DUCTULE EPITHELIAL HYPERPLASIA AND/OR CHOLANGIOFIBROSIS
- HEPATOCTYIC VACUOLIZATION
- CYSTIC DEGENERATION
- KIDNEY ..... NOT SPECIFIED(MARKED)
- PROGRESSIVE RENAL DISEASE
- PROSTATE ..... NOT SPECIFIED(MODERATE)
- CHRONIC PROSTATITIS
- BENIGN HYPERPLASIA
- TESTES .....



Appendix J (cont.): PATHOLOGY INDIVIDUAL ANIMAL DATA

LETTERMAN ARMY INSTITUTE OF RESEARCH  
DIV OF RES SUPP, PATH SERV GP  
SPECIES: RAT/FISCHER-344

INDIVIDUAL ANIMAL DATA REPORT  
STUDY NUMBER: GLP83009  
STUDY START DATE: 23-JAN-84

PRINTED: 21-NOV-89  
PAGE: 359  
STUDY TYPE: CHRONIC/2 YR CARCINOGENIC

ANIMAL NUMBER: 173/PRETEST-173 SEX: MALE DOSE GROUP: 3 SACRIFICE STATUS: SACRIFICED MORIBUND  
DATE OF DEATH: 14-JAN-86 STUDY DAY OF DEATH: 723 STUDY WEEK OF DEATH: 104 TERMINAL BODY WEIGHT: 285.00 (GMS)

<< MICROSCOPIC TISSUE OBSERVATIONS >>  
DISTRIBUTION (SEVERITY) / SPECIAL COMMENTS

TESTES ..... (PRESENT)  
-B- INTERSTITIAL CELL ADENOMA

RECTUM ..... TISSUE IS MISSING

MAMMARY GLANDS .....  
-HYPERPLASIA AND/OR HYPERTROPHY OF THE ACIMAR TISSUE ..... NOT SPECIFIED(MARKED)  
-DILATATION (ECTASIA) OF DUCTS AND DUCTULES ..... NOT SPECIFIED (PRESENT)

ADRENAL .....  
-FOCUS OF CELLULAR ALTERATION, VACUOLATED ..... NOT SPECIFIED(TRACE)

PITUITARY GLAND ..... (PRESENT)  
-B- ADENOMA

EYES & OPTIC N. ....  
-RETINAL ATROPHY AND/OR DEGENERATION, UNILATERAL OR BILATERAL ..... RETINAL DEGENERATION AND SUBCAPSULAR CATARACT IS UNILATERAL  
-LENTICULAR DEGENERATIVE CHANGES COMPATIBLE WITH CATARACT ..... DIFFUSE(MODERATE)  
NOT SPECIFIED (PRESENT)

Appendix J (cont.): PATHOLOGY INDIVIDUAL ANIMAL DATA

LETTERMAN ARMY INSTITUTE OF RESEARCH  
 DIV OF RES SUPP, PATH SERV GP  
 SPECIES: RAT/FISCHER-344  
 STUDY START DATE: 23-JAN-84  
 STUDY NUMBER: GLP83009  
 PRINTED: 21-NOV-89  
 PAGE: 360  
 STUDY TYPE: CHRONIC/2 YR CARCINOGENIC

ANIMAL NUMBER: 174/PRETEST-  
 DATE OF DEATH: 30-JAN-86  
 STUDY DAY OF DEATH: 739  
 DOSE GROUP: 3  
 STUDY WEEK OF DEATH: 106  
 SACRIFICE STATUS: FINAL SACRIFICE  
 TERMINAL BODY WEIGHT: 345.00 (GMS)

ORGAN NAME: << GROSS ORGAN OBSERVATIONS >>  
 KEYWORDS / PHRASES: SEVERITY GROSS FREE-TEXT COMMENTS  
 KIDNEY: PRESENT BILATERAL  
 LYMPH NODES: ENLARGED LEFT AXILLARY, .5CM DIAMETER, BLACK

TISSUE / HISTOPATHOLOGIC FINDINGS: << MICROSCOPIC TISSUE OBSERVATIONS >>  
 DISTRIBUTION (SEVERITY) / SPECIAL COMMENTS  
 SALIVARY GLAND: FOCAL (TRACE)  
 -ATROPHY AND LOSS OF ACINAR TISSUE

HEART: NOT SPECIFIED (MILD)  
 -CARDIOMYOPATHY: NOT SPECIFIED (TRACE)  
 -MEDIAL HYPERTROPHY OF MUSCULAR ARTERIES

LUNGS: FOCAL (PRESENT)  
 -ALVEOLAR HEMORRHAGE  
 LIVER: NOT SPECIFIED (MODERATE)  
 -BILE DUCTULE EPITHELIAL HYPERPLASIA AND/OR CHOLANGIOFIBROSIS  
 -HEPATOCTYIC VACUOLIZATION: MULTI-FOCAL (MILD)  
 -FOCUS OF CELLULAR ATTERATION - CLEAR CELLS: NOT SPECIFIED (TRACE)  
 -FOCUS OF CELLULAR ALTERATION - EOSINOPHILIC CELLS: NOT SPECIFIED (TRACE)

KIDNEY: NOT SPECIFIED (MARKED)  
 -PROGRESSIVE RENAL DISEASE  
 PROSTATE: NOT SPECIFIED (TRACE)  
 -BENIGN HYPERPLASIA  
 SEMINAL VESTICLE: NOT SPECIFIED (PRESENT)  
 -GENERALIZED ATROPHY  
 TESTES

## Appendix J (cont.): PATHOLOGY INDIVIDUAL ANIMAL DATA

LETTERMAN ARMY INSTITUTE OF RESEARCH  
 DIV OF RES SUPP, PATH SERV GP  
 SPECIES: RAT/FISCHER-344

INDIVIDUAL ANIMAL DATA REPORT  
 STUDY NUMBER: GLP83009  
 STUDY START DATE: 23-JAN-84

PRINTED: 21-NOV-89  
 PAGE: 361

STUDY TYPE: CHRONIC/2 YR CARCINOGENIC

ANIMAL NUMBER: 174/PRETEST= DOSE GROUP: 3 SACRIFICE STATUS: FINAL SACRIFICE  
 DATE OF DEATH: 30-JAN-86 STUDY DAY OF DEATH: 739 STUDY WEEK OF DEATH: 106 TERMINAL BODY WEIGHT: 345.00 (GMS)

<< MICROSCOPIC TISSUE OBSERVATIONS >>  
 TISSUE / HISTOPATHOLOGIC FINDINGS  
 DISTRIBUTION (SEVERITY) / SPECIAL COMMENTS

TESTES ..... (PRESENT)  
 -B- INTERSTITIAL CELL ADENOMA

PANCREAS ..... FOCAL(MILD)  
 -CHRONIC INFLAMMATION

MAMMARY GLANDS ..... THE ENLARGED LESION IN THE LEFT AXILLARY AREA THAT WAS THOUGHT  
 TO BE A LYMPH NODE ON GROSS EXAMINATION IS AN AREA OF MAMMARY  
 HYPERPLASIA AND A GALACTOCELE.

-HYPERPLASIA AND/OR HYPERTROPHY OF THE ACINAR TISSUE  
 -GALACTOCELE(S)  
 NOT SPECIFIED (PRESENT)

NOSE/TURBINATES ..... FOCAL(MILD)  
 -ACUTE INFLAMMATION

ADRENAL ..... NOT SPECIFIED (PRESENT)  
 -CORTICAL NODULAR HYPERPLASIA  
 -B- PNEOCHROMOCYTOMA

EYES & OPTIC N. .... THE CATARACT IS UNILATERAL.  
 -RETINAL ATROPHY AND/OR DEGENERATION, UNILATERAL OR BILATERAL  
 NOT SPECIFIED (MODERATE)  
 -METAPLASTIC BONE FORMATION AND/OR MINERALIZATION, SCLERA  
 NOT SPECIFIED (PRESENT)  
 -LENTICULAR DEGENERATIVE CHANGES COMPATIBLE WITH CATARACT  
 NOT SPECIFIED (PRESENT)

MEDIASTINUM ..... MISCELLANEOUS TISSUE  
 -REACTIVE HYPERPLASIA, LYMPH NODE  
 NOT SPECIFIED (PRESENT)

Appendix J (cont.): PATHOLOGY INDIVIDUAL ANIMAL DATA

LETTERMAN ARMY INSTITUTE OF RESEARCH  
DIV OF RES SUPP, PATH SERV GP  
SPECIES: RAT/FISCHER-344

INDIVIDUAL ANIMAL DATA REPORT  
STUDY NUMBER: GLP83009  
STUDY START DATE: 23-JAN-84

PRINTED: 21-NOV-89  
PAGE: 362  
STUDY TYPE: CHRONIC/2 YR CARCINOGENIC

ANIMAL NUMBER: 175/PRETEST# 175 SEX: MALE DOSE GROUP: 3 SACRIFICE STATUS: SACRIFICED MORIBUND  
DATE OF DEATH: 26-SEP-85 STUDY DAY OF DEATH: 613 STUDY WEEK OF DEATH: 88 TERMINAL BODY WEIGHT: 386.00 (GMS)

ORGAN NAME << GROSS ORGAN OBSERVATIONS >> SEVERITY GROSS FREE-TEXT COMMENTS  
KEYWORDS / PHRASES PRESENT BILATERAL  
CORNEAL OPACITY PRESENT  
ENLARGED (SPLENOHEGALY) PRESENT

TISSUE / HISTOPATHOLOGIC FINDINGS << MICROSCOPIC TISSUE OBSERVATIONS >> DISTRIBUTION (SEVERITY) / SPECIAL COMMENTS

PARATHYROID ..... TISSUE IS MISSING  
RECUITS OF BLOCK #3 FAILED TO DEMONSTRATE PARATHYROID GLAND.

LACRIMAL GLAND ..... NOT SPECIFIED (TRACE)  
-INFLAMMATION, SUBACUTE TO CHRONIC

EXORBITAL LACRIM ..... TISSUE IS MISSING  
HEART ..... NOT SPECIFIED (MILD)  
-CARDIOMYOPATHY

SPLEEN ..... THIS IS A CASE OF VERY EARLY LGLL. NEOPLASTIC CELLS ARE PRESENT  
BUT NOT IN THE LARGE NUMBERS USUALLY SEEN.  
-INFARCTION, CHRONIC  
-N- LARGE GRANULAR LYMPHOCYTE LEUKEMIA, METASTATIC  
-EXTRAMEDULLARY HEMATOPOIESIS

LYMPH NODES ..... NOT SPECIFIED (MILD)  
-LYMPHOID HYPERPLASIA  
-RED BLOOD CELLS, HEMOSIDERIN AND/OR ERYTHROPHAGOCYTOSIS WITHIN  
MEDULLARY SINUSES

LIVER ..... NOT SPECIFIED (MILD)  
-BILE DUCTULE EPITHELIAL HYPERPLASIA AND/OR CHOLANGIOFIBROSIS  
-HEPATITIS

KIDNEY ..... NOT SPECIFIED (TRACE)

Appendix J (cont.): PATHOLOGY INDIVIDUAL ANIMAL DATA

LETTERMAN ARMY INSTITUTE OF RESEARCH INDIVIDUAL ANIMAL DATA REPORT PRINTED: 21-NOV-89  
 DIV OF RES SUPP, PATH SERV GP STUDY NUMBER: GLP83009 PAGE: 363  
 SPECIES: RAT/FISCHER-344 STUDY START DATE: 23-JAN-84 STUDY TYPE: CHRONIC/2 YR CARCINOGENIC  
 ANIMAL NUMBER: 175/PRETEST= DOSE GROUP: 3 SACRIFICE STATUS: SACRIFICED MORIBUND  
 DATE OF DEATH: 26-SEP-85 STUDY DAY OF DEATH: 613 STUDY WEEK OF DEATH: 88 TERMINAL BODY WEIGHT: 386.00 (GMS)  
 << MICROSCOPIC TISSUE OBSERVATIONS >>  
 TISSUE / HISTOPATHOLOGIC FINDINGS DISTRIBUTION (SEVERITY) / SPECIAL COMMENTS

KIDNEY ..... NOT SPECIFIED(TRACE)  
 -PROGRESSIVE RENAL DISEASE .....  
 PROSTATE ..... THERE IS A SMALL MICROLITH IN THE PROSTATIC URETHRA.  
 -CHRONIC PROSTATITIS ..... NOT SPECIFIED(TRACE)  
 -BENIGN HYPERPLASIA ..... NOT SPECIFIED(MILD)  
 -MICROCALCULI, PROSTATIC URETHRA ..... NOT SPECIFIED (PRESENT)  
 SEMINAL VESICLE ..... NOT SPECIFIED (PRESENT)  
 -GENERALIZED ATROPHY .....  
 TESTES ..... (PRESENT)  
 -B- INTERSTITIAL CELL ADENOMA .....  
 BONE, STERNUM ..... NOT SPECIFIED (PRESENT)  
 -HYPERPLASIA, MYELOID .....  
 BONE, FEMUR ..... NOT SPECIFIED (PRESENT)  
 -HYPERPLASIA MYELOID .....  
 BONE VERT ..... NOT SPECIFIED (PRESENT)  
 -HYPERPLASIA, MYELOID .....  
 ADRENAL ..... ONLY ONE ADRENAL GLAND AVAILABLE FOR EXAMINATION  
 PITUITARY GLAND ..... (PRESENT)  
 -B- ADENOMA .....  
 EYES & OPTIC N. ..... CATARACT WAS SUBCAPSULAR AND UNILATERAL INVOLVING THE SAME  
 EYE AS THE RETINAL DEGENERATION  
 -RETINAL ATROPHY AND/OR DEGENERATION, UNILATERAL OR BILATERAL NOT SPECIFIED(MARKED)  
 -LENTICULAR DEGENERATIVE CHANGES COMPATIBLE WITH CATARACT NOT SPECIFIED (PRESENT)

Appendix J (cont.): PATHOLOGY INDIVIDUAL ANIMAL DATA

LETTERMAN ARMY INSTITUTE OF RESEARCH  
DIV OF RES SUPP, PATH SERV GP  
SPECIES: RAT/FISCHER-344

INDIVIDUAL ANIMAL DATA REPORT  
STUDY NUMBER: GLP83009  
STUDY START DATE: 23-JAN-84

PRINTED: 21-NOV-89  
PAGE: 364

STUDY TYPE: CHRONIC/2 YR CARCINOGENIC

ANIMAL NUMBER: 175/PRETEST= 175 SEX: MALE DOSE GROUP: 3 SACRIFICE STATUS: SACRIFICED MORIBUND  
DATE OF DEATH: 26-SEP-85 STUDY DAY OF DEATH: 613 STUDY WEEK OF DEATH: 88 TERMINAL BODY WEIGHT: 386.00 (GMS)

TISSUE / HISTOPATHOLOGIC FINDINGS << MICROSCOPIC TISSUE OBSERVATIONS >>  
DISTRIBUTION (SEVERITY) / SPECIAL COMMENTS

EAR ..... TISSUE IS MISSING

AD SEBACIOUS ..... TISSUE IS MISSING

WHOLE BODY ..... (PRESENT)  
-M- LARGE GRANULAR LYMPHOCYTTIC LEUKEMIA

Appendix J (cont.): **PATHOLOGY INDIVIDUAL ANIMAL DATA**

LETTERMAN ARMY INSTITUTE OF RESEARCH  
 DIV OF RES SUPP, PATH SERV GP  
 SPECIES: RAT/FISCHER-344  
 STUDY NUMBER: GLP83009  
 STUDY START DATE: 23-JAN-84  
 STUDY TYPE: CHRONIC/2 YR CARCINOGENIC

PRINTED: 21-NOV-89  
 PAGE: 365

ANIMAL NUMBER: 176/PRETEST= 176 SEX: MALE DOSE GROUP: 3 SACRIFICE STATUS: FINAL SACRIFICE  
 DATE OF DEATH: 30-JAN-86 STUDY DAY OF DEATH: 739 STUDY WEEK OF DEATH: 106 TERMINAL BODY WEIGHT: 327.00 (GMS)

ORGAN NAME KEYWORDS / PHRASES GROSS ORGAN OBSERVATIONS SEVERITY GROSS FREE-TEXT COMMENTS  
 TESTES GROWTH(S) / MASS(ES) PRESENT BILATERAL, MULTIPLE VARIABLY SIZED, YELLOW/RED  
 KIDNEY GRANULAR SURFACE PRESENT BILATERAL  
 PITUITARY GLAND DISCOLORATION PRESENT .2CM DIAMETER, BLACK FOCUS  
 THYROID GROWTH(S) / MASS(ES) PRESENT .8CM DIAMETER, DARK RED, SEMI-FIRM

TISSUE / HISTOPATHOLOGIC FINDINGS MICROSCOPIC TISSUE OBSERVATIONS DISTRIBUTION (SEVERITY) / SPECIAL COMMENTS  
 THYROID GLANDS (PRESENT)  
 -B- PARA-FOLLICULAR CELL ADENOMA

HEART  
 -CARDIOMYOPATHY NOT SPECIFIED(TRACE)  
 -MEDIAL HYPERTROPHY OF MUSCULAR ARTERIES NOT SPECIFIED(TRACE)

LUNGS  
 -MINERALIZATION OF PULMONARY ARTERIES NOT SPECIFIED(TRACE)

LIVER  
 -BILE DUCTULE EPITHELIAL HYPERPLASIA AND/OR CHOLANGIOFIBROSIS NOT SPECIFIED(MILD)  
 -HEPATITIS NOT SPECIFIED(TRACE)  
 -FOCUS OF CELLULAR ALTERATION - EOSINOPHILIC CELLS NOT SPECIFIED(TRACE)

KIDNEY  
 -PROGRESSIVE RENAL DISEASE NOT SPECIFIED(MODERATE)

PROSTATE  
 -CHRONIC PROSTATITIS NOT SPECIFIED(MILD)  
 -BENIGN HYPERPLASIA NOT SPECIFIED(MILD)

SEMINAL VESICLE

Appendix J (cont.): PATHOLOGY INDIVIDUAL ANIMAL DATA

LETTERMAN ARMY INSTITUTE OF RESEARCH  
 DIV OF RES SUPP, PATH SERV GP  
 SPECIES: RAT/FISCHER-344  
 STUDY START DATE: 23-JAN-84  
 STUDY NUMBER: GLP83009  
 PRINTED: 21-NOV-89  
 PAGE: 366  
 STUDY TYPE: CHRONIC/2 YR CARCINOGENIC

ANIMAL NUMBER: 176/PRETEST=  
 DATE OF DEATH: 30-JAN-86  
 STUDY DAY OF DEATH: 739  
 SEX: MALE  
 DOSE GROUP: 3  
 SACRIFICE STATUS: FINAL SACRIFICE  
 TERMINAL BODY WEIGHT: 327.00 (GMS)

TISSUE / HISTOPATHOLOGIC FINDINGS  
 << MICROSCOPIC TISSUE OBSERVATIONS >>  
 DISTRIBUTION (SEVERITY) / SPECIAL COMMENTS

SEMINAL VESICLE ..... NOT SPECIFIED (PRESENT)  
-GENERALIZED ATROPHY

TESTES ..... (PRESENT)  
-B- INTERSTITIAL CELL ADENOMA

PANCREAS ..... (PRESENT)  
-B- ISLET CELL ADENOMA

MAMMARY GLANDS ..... NOT SPECIFIED (MILD)  
-HYPERPLASIA AND/OR HYPERTROPHY OF THE ACINAR TISSUE  
-DILATATION (ECTASIA) OF DUCTS AND DUCTULES

ADRENAL ..... NOT SPECIFIED (PRESENT)  
-CORTICAL NODULAR HYPERPLASIA

PITUITARY GLAND ..... (PRESENT)  
-B- ADENOMA

EYES & OPTIC N. .... NOT SPECIFIED (PRESENT)  
-METAPLASTIC BONE FORMATION AND/OR MINERALIZATION, SCLERA



Appendix J (cont.): PATHOLOGY INDIVIDUAL ANIMAL DATA

LETTERMAN ARMY INSTITUTE OF RESEARCH INDIVIDUAL ANIMAL DATA REPORT PRINTED: 21-NOV-89  
DIV OF RES SUPP, PATH SERV GP STUDY NUMBER: GLP83009 PAGE: 367  
SPECIES: RAT/FISCHER-344 STUDY START DATE: 23-JAN-84 STUDY TYPE: CHRONIC/2 YR CARCINOGENIC

ANIMAL NUMBER: 177/PRETEST-177 SEX: MALE DOSE GROUP: 3 SACRIFICE STATUS: FINAL SACRIFICE  
DATE OF DEATH: 30-JAN-86 STUDY DAY OF DEATH: 739 STUDY WEEK OF DEATH: 106 TERMINAL BODY WEIGHT: 387.00 (GMS)

<< GROSS ORGAN OBSERVATIONS >>  
SEVERITY GROSS FREE-TEXT COMMENTS  
KEYWORDS / PHRASES  
ENLARGED PRESENT LEFT, 2.75 X 1.75CM  
GROWTH(S) / MASS(ES) PRESENT BILATERAL, MULTIPLE VARIABLY SIZED, YELLOW/BLACK  
CYST PRESENT .5CM DIAMETER, RIGHT ANTERIOR POLE

<< MICROSCOPIC TISSUE OBSERVATIONS >>  
DISTRIBUTION (SEVERITY) / SPECIAL COMMENTS

HEART ..... NOT SPECIFIED(TRACE)  
-CARDIOMYOPATHY ..... NOT SPECIFIED(TRACE)  
-MEDIAL HYPERTROPHY OF MUSCULAR ARTERIES

LUNGS ..... DIFFUSE (PRESENT)  
-VASCULAR CONGESTION

LYMPH NODES ..... ERYTHROPHAGOCYTOSIS AND HEMOSIDEROSIS ARE PRESENT IN CERVICAL  
-RED BLOOD CELLS, HEMOSIDERIN AND/OR ERYTHROPHAGOCYTOSIS WITHIN Lymph nodes.  
MEDULLARY SINUSES ..... NOT SPECIFIED (PRESENT)

LIVER ..... NOT SPECIFIED(MILD)  
-BILE DUCTULE EPITHELIAL HYPERPLASIA AND/OR CHOLANGIOFIBROSIS ..... MULTI-FOCAL(TRACE)  
-HEPATOCTYE COALESCING MICROVESICULAR (FATTY) CHANGE LEADING TO NECROSIS AND MINERALIZATION

KIDNEY ..... NOT SPECIFIED(MILD)  
-PROGRESSIVE RENAL DISEASE

PROSTATE ..... NOT SPECIFIED(MILD)  
-CHRONIC PROSTATITIS ..... NOT SPECIFIED(TRACE)  
-BENIGN HYPERPLASIA

SEMINAL VESICLE .....

Appendix J (cont.): PATHOLOGY INDIVIDUAL ANIMAL DATA

LETTERMAN ARMY INSTITUTE OF RESEARCH INDIVIDUAL ANIMAL DATA REPORT PRINTED: 21-NOV-89  
 DIV OF RES SUPP, PATH SERV GP STUDY NUMBER: GLP83009 PAGE: 368  
 SPECIES: RAY/FISCHER-344 STUDY START DATE: 23-JAN-84 STUDY TYPE: CHRONIC/2 YR CARCINOGENIC  
 ANIMAL NUMBER: 177/PRETEST-177 SEX: MALE DOSE GROUP: 3 SACRIFICE STATUS: FINAL SACRIFICE  
 DATE OF DEATH: 30-JAN-86 STUDY DAY OF DEATH: 739 STUDY WEEK OF DEATH: 106 TERMINAL BODY WEIGHT: 387.00 (GMS)  
 << MICROSCOPIC TISSUE OBSERVATIONS >>  
 TISSUE / HISTOPATHOLOGIC FINDINGS DISTRIBUTION (SEVERITY) / SPECIAL COMMENTS

SEMINAL VESICLE ..... NOT SPECIFIED (PRESENT)  
 -GENERALIZED ATROPHY .....  
 TESTES ..... (PRESENT)  
 -B- INTERSTITIAL CELL ADENOMA .....  
 MAMMARY GLANDS .....  
 -HYPERPLASIA AND/OR HYPERTROPHY OF THE ACINAR TISSUE ..... NOT SPECIFIED (TRACE)  
 -DILATATION (ECTASIA) OF DUCTS AND DUCTULES ..... NOT SPECIFIED (PRESENT)  
 NOSE/TURBINATES ..... INFILTRATE: SUPPURATIVE, BILATERAL NEAR NASO-LACRIMAL DUCTS.  
 -MIXED INFLAMMATORY CELL INFILTRATION, NASAL CAVITY, SINUSES, ..... NOT SPECIFIED (MODERATE)  
 TURBINATES, NASO-LACRIMAL DUCTS .....  
 ADRENAL .....  
 -FOCUS OF CELLULAR ALTERATION, EOSINOPHILIC ..... NOT SPECIFIED (TRACE)  
 PITUITARY GLAND ..... (PRESENT)  
 -B- ADENOMA .....  
 EYES & OPTIC N. ....  
 -METAPLASTIC BONE FORMATION AND/OR MINERALIZATION, SCLERA ..... NOT SPECIFIED (PRESENT)

Appendix J (cont.): PATHOLOGY INDIVIDUAL ANIMAL DATA

LETTERMAN ARMY INSTITUTE OF RESEARCH INDIVIDUAL ANIMAL DATA REPORT PRINTED: 21-NOV-89  
DIV OF RES SUPP, PATH SERV GP STUDY NUMBER: GLP83009 PAGE: 369  
SPECIES: RAT/FISCHER-344 STUDY START DATE: 23-JAN-84 STUDY TYPE: CHRONIC/2 YR CARCINOGENIC

ANIMAL NUMBER: 178/PRETEST= 178 SEX: MALE DOSE GROUP: 3 SACRIFICE STATUS: FINAL SACRIFICE  
DATE OF DEATH: 30-JAN-86 STUDY DAY OF DEATH: 739 STUDY WEEK OF DEATH: 106 TERMINAL BODY WEIGHT: 391.00 (GMS)

ORGAN NAME << GROSS ORGAN OBSERVATIONS >> SEVERITY GROSS FREE-TEXT COMMENTS  
KEYWORDS / PHRASES PRESENT BILATERAL, MULTIPLE VARIABLY SIZED, YELLOW  
GROWTH(S) / MASS(ES) PRESENT LEFT, 3 X 1.5CM  
ENLARGED

TISSUE << MICROSCOPIC TISSUE OBSERVATIONS >> DISTRIBUTION (SEVERITY) / SPECIAL COMMENTS  
HISTOPATHOLOGIC FINDINGS

LACRIMAL GLAND ..... MULTI-FOCAL(TRACE)  
-INFLAMMATION, SUBACUTE TO CHRONIC

HEART ..... NOT SPECIFIED(TRACE)  
-CARDIOMYOPATHY ..... NOT SPECIFIED(TRACE)  
-MEDIAL HYPERTROPHY OF MUSCULAR ARTERIES

LUNGS ..... NOT SPECIFIED(TRACE)  
-MINERALIZATION OF PULMONARY ARTERIES

LIVER ..... NOT SPECIFIED(MODERATE)  
-BILE DUCTULE EPITHELIAL HYPERPLASIA AND/OR CHOLANGIOFIBROSIS ..... NOT SPECIFIED(MILD)  
-HEPATITIS ..... MULTI-FOCAL(TRACE)  
-HEPATOCTYIC VACUOLIZATION ..... NOT SPECIFIED(TRACE)  
-FOCUS OF CELLULAR ALTERATION - CLEAR CELLS ..... MULTI-FOCAL (PRESENT)  
-CYSTIC DEGENERATION

KIDNEY ..... NOT SPECIFIED(MODERATE)  
-PROGRESSIVE RENAL DISEASE

PROSTATE ..... FOCAL(TRACE)  
-CHRONIC PROSTATITIS ..... NOT SPECIFIED(TRACE)  
-BENIGN HYPERPLASIA

SEMINAL VESICLE .....

Appendix J (cont.): PATHOLOGY INDIVIDUAL ANIMAL DATA

LETTERMAN ARMY INSTITUTE OF RESEARCH  
DIV OF RES SUPP, PATH SERV GP  
SPECIES: RAT/FISCHER-344

INDIVIDUAL ANIMAL DATA REPORT  
STUDY NUMBER: GLP63009  
STUDY START DATE: 23-JAN-84

PRINTED: 21-NOV-89  
PAGE: 370  
STUDY TYPE: CHRONIC/2 YR CARCINOGENIC

ANIMAL NUMBER: 178/PRETEST-178 SEX: MALE DOSE GROUP: 3 SACRIFICE STATUS: FINAL SACRIFICE  
DATE OF DEATH: 30-JAN-86 STUDY DAY OF DEATH: 739 STUDY WEEK OF DEATH: 106 TERMINAL BODY WEIGHT: 391.00 (GMS)

TISSUE / HISTOPATHOLOGIC FINDINGS << M I C R O S C O P I C T I S S U E O B S E R V A T I O N S >>  
DISTRIBUTION (SEVERITY) / SPECIAL COMMENTS

SEMINAL VESICLE ..... NOT SPECIFIED (PRESENT)  
-GENERALIZED ATROPHY

TESTES ..... (PRESENT)  
-B-MESOTHELIOMA (PRESENT)  
-B- INTERSTITIAL CELL ADENOMA (PRESENT)

MAMMARY GLANDS ..... NOT SPECIFIED (TRACE)  
-HYPERPLASIA AND/OR HYPERTROPHY OF THE ACINAR TISSUE

NOSE/TURBINATES ..... INFILTRATE: BILATERAL NEAR NASO-LACRIMAL DUCTS.  
-MIXED INFLAMMATORY CELL INFILTRATION, NASAL CAVITY, SINUSES, NOT SPECIFIED (MILD)  
TURBINATES, NASO-LACRIMAL DUCTS

ADRENAL ..... NOT SPECIFIED (TRACE)  
-FOCUS OF CELLULAR ALTERATION, VACUOLATED

PITUITARY GLAND ..... FOCAL (PRESENT)  
-CYST(S)

**Appendix J (cont.): PATHOLOGY INDIVIDUAL ANIMAL DATA**

LETTERMAN ARMY INSTITUTE OF RESEARCH  
 DIV OF RES SUPP, PATH SERV GP  
 SPECIES: RAT/FISCHER-344

INDIVIDUAL ANIMAL DATA REPORT  
 STUDY NUMBER: GLP83009

PRINTED: 21-NOV-89  
 PAGE: 371

STUDY START DATE: 23-JAN-84  
 STUDY TYPE: CHRONIC/2 YR CARCINOGENIC

ANIMAL NUMBER: 179/PREYEST= 179 SEX: MALE DOSE GROUP: 3 SACRIFICE STATUS: FINAL SACRIFICE  
 DATE OF DEATH: 03-FEB-86 STUDY DAY OF DEATH: 743 STUDY WEEK OF DEATH: 107 TERMINAL BODY WEIGHT: 409.00 (GMS)

<< GROSS ORGAN OBSERVATIONS >>  
 SEVERITY GROSS FREE-TEXT COMMENTS  
 KEYWORDS / PHRASES  
 DISCOLORATION PRESENT PALE  
 GROWTH(S) / MASS(ES) PRESENT BILATERAL, MULTIPLE VARIABLY SIZED, YELLOW  
 DISCOLORATION PRESENT FOCAL, BLACK, .2CM DIAMETER

TISSUE / HISTOPATHOLOGIC FINDINGS  
 << MICROSCOPIC TISSUE OBSERVATIONS >>  
 DISTRIBUTION (SEVERITY) / SPECIAL COMMENTS

PARATHYROID ..... TISSUE IS MISSING

HEART ..... NOT SPECIFIED(MILD)  
 -CARDIOMYOPATHY

LUNGS ..... NOT SPECIFIED(TRACE)  
 -MINERALIZATION OF PULMONARY ARTERIES

LYMPH NODES ..... REACTIVE HYPERPLASIA PRESENT IN BOTH CERVICAL AND MESENTERIC  
 LYMPH NODES.  
 NOT SPECIFIED (PRESENT)

-REACTIVE HYPERPLASIA

LIVER ..... NOT SPECIFIED(MILD)  
 -BILE DUCTULE EPITHELIAL HYPERPLASIA AND/OR CHOLANGIOFIBROSIS  
 -HEPATOCTYIC VACUOLIZATION MULTI-FOCAL(MILD)  
 -FOCUS OF CELLULAR ALTERATION - EOSINOPHILIC CELLS NOT SPECIFIED(MILD)

KIDNEY ..... NOT SPECIFIED(MODERATE)  
 -PROGRESSIVE RENAL DISEASE

PROSTATE ..... NOT SPECIFIED(TRACE)  
 -CHRONIC PROSTATITIS  
 -BENIGN HYPERPLASIA NOT SPECIFIED(MILD)

TESTES .....

Appendix J (cont.): PATHOLOGY INDIVIDUAL ANIMAL DATA

LETTERMAN ARMY INSTITUTE OF RESEARCH  
 DIV OF RES SUPP, PATH SERV GP  
 SPECIES: RAT/FISCHER-344

INDIVIDUAL ANIMAL DATA REPORT  
 STUDY NUMBER: GLP83009  
 STUDY START DATE: 23-JAN-84

PRINTED: 21-NOV-89  
 PAGE: 372

STUDY TYPE: CHRONIC/2 YR CARCINOGENIC

ANIMAL NUMBER: 179/PRETEST= 179 SEX: MALE DOSE GROUP: 3 SACRIFICE STATUS: FINAL SACRIFICE  
 DATE OF DEATH: 03-FEB-86 STUDY DAY OF DEATH: 743 STUDY WEEK OF DEATH: 107 TERMINAL BODY WEIGHT: 409.00 (GMS)

TISSUE / HISTOPATHOLOGIC FINDINGS << M I C R O S C O P I C T I S S U E O B S E R V A T I O N S >>  
 DISTRIBUTION (SEVERITY) / SPECIAL COMMENTS

TESTES ..... (PRESENT)

-B- INTERSTITIAL CELL ADENOMA

SKIN ..... TISSUE IS MISSING

MAMMARY GLANDS ..... TISSUE IS MISSING

NOSE/TURBINATES ..... SUBACUTE INFLAMMATION IS BILATERAL INVOLVING LATERAL ASPECTS OF THE VENTRAL NASAL MEATUS. NOT SPECIFIED(TRACE)

-SUBACUTE INFLAMMATION

ADRENAL ..... NOT SPECIFIED(MODERATE)

- FOCUS OF CELLULAR ALTERATION, VACUOLATED

PITUITARY GLAND ..... (PRESENT)

-B- ADENOMA

EYES & OPTIC N. .... NOT SPECIFIED (PRESENT)

-METAPLASTIC BONE FORMATION AND/OR MINERALIZATION, SCLERA

**Appendix J (cont.): PATHOLOGY INDIVIDUAL ANIMAL DATA**

LETTERMAN ARMY INSTITUTE OF RESEARCH  
 DIV OF RES SUPP, PATH SERV GP  
 SPECIES: RAT/FISCHER-344  
 ANIMAL NUMBER: 180/PRETEST-180 SEX: MALE DOSE GROUP: 3 SACRIFICE STATUS: FINAL SACRIFICE  
 DATE OF DEATH: 03-FEB-86 STUDY DAY OF DEATH: 743 STUDY WEEK OF DEATH: 107 TERMINAL BODY WEIGHT: 353.00 (GMS)  
 STUDY START DATE: 23-JAN-84 STUDY TYPE: CHRONIC/2 YR CARCINOGENIC

PRINTED: 21-NOV-89  
 PAGE: 373

ORGAN NAME << GROSS ORGAN OBSERVATIONS >>  
 SEVERITY GROSS FREE-TEXT COMMENTS  
 SKIN SUBCUTANEOUS MASS PRESENT OVOID .5 X .25CM, RED, INGUINAL AREA  
 TESTES ATROPHIC / SMALL, UNILATERALLY PRESENT LEFT, 1.75 X 1CM  
 TESTES GROWTH(S) / MASS(ES) PRESENT RIGHT, MULTIPLE VARIABLY SIZED, YELLOW

TISSUE / HISTOPATHOLOGIC FINDINGS << MICROSCOPIC TISSUE OBSERVATIONS >>  
 DISTRIBUTION (SEVERITY) / SPECIAL COMMENTS

HEART  
 -CARDIOMYOPATHY NOT SPECIFIED(MILD)  
 -MEDIAL HYPERTROPHY OF MUSCULAR ARTERIES NOT SPECIFIED(TRACE)

LUNGS  
 -MINERALIZATION OF PULMONARY ARTERIES NOT SPECIFIED(TRACE)

LIVER  
 -BILE DUCTULE EPITHELIAL HYPERPLASIA AND/OR CHOLANGIOFIBROSIS NOT SPECIFIED(MARKED)  
 -BENIGN HYPERPLASTIC MODULE(S) NOT SPECIFIED(TRACE)  
 -FOCUS OF CELLULAR ALTERATION - EOSINOPHILIC CELLS NOT SPECIFIED(TRACE)

KIDNEY  
 -PROGRESSIVE RENAL DISEASE NOT SPECIFIED(MARKED)

PROSTATE  
 -BENIGN HYPERPLASIA NOT SPECIFIED(MILD)

SEMINAL VESICLE  
 -GENERALIZED ATROPHY NOT SPECIFIED (PRESENT)

TESTES  
 -TUBULAR ATROPHY MILD TUBULAR ATROPHY AND INTERSTITIAL CELL HYPERPLASIA INVOLVE  
 -INTERSTITIAL CELL HYPERPLASIA THE SMALL TESTIS (LEFT) WHICH HAS NO INTERSTITIAL CELL TUMOR.  
 NOT SPECIFIED(TRACE)  
 NOT SPECIFIED(TRACE)

Appendix J (cont.): PATHOLOGY INDIVIDUAL ANIMAL DATA

LETTERMAN ARMY INSTITUTE OF RESEARCH  
DIV OF RES SUPP, PATH SERV GP  
SPECIES: RAT/FISCHER-344

INDIVIDUAL ANIMAL DATA REPORT  
STUDY NUMBER: GLP83009  
STUDY START DATE: 23-JAN-84

PRINTED: 21-NOV-89  
PAGE: 374

STUDY TYPE: CHRONIC/2 YR CARCINOGENIC

ANIMAL NUMBER: 180/PRETEST=  
DATE OF DEATH: 03-FEB-86 STUDY DAY OF DEATH: 743

DOSE GROUP: 3 SACRIFICE STATUS: FINAL SACRIFICE  
STUDY WEEK OF DEATH: 107 TERMINAL BODY WEIGHT: 353.00 (GMS)

TISSUE / HISTOPATHOLOGIC FINDINGS  
MICROSCOPIC TISSUE OBSERVATIONS  
DISTRIBUTION (SEVERITY) / SPECIAL COMMENTS

TESTES ..... (PRESENT)  
-B- INTERSTITIAL CELL ADENOMA

PANCREAS ..... NOT SPECIFIED(MODERATE)  
-ACINAR (EXOCRINE) ATROPHY

SKIN ..... THE SUBCUTANEOUS MASS IN THE INGUINAL AREA NOTED GROSSLY IS  
PROBABLY THE GALACTOCELE CODED UNDER MAMMARY GLAND.

MAMMARY GLANDS ..... THE GALACTOCELE PROBABLY CORRESPONDS TO THE SUBCUTANEOUS  
MASS NOTED GROSSLY IN THE INGUINAL AREA.  
-HYPERPLASIA AND/OR HYPERTROPHY OF THE ACINAR TISSUE  
-GALACTOCELE(S) NOT SPECIFIED (PRESENT)

NOSE/TURBINATES ..... INFILTRATE NEAR NASO-LACRIMAL DUCT.  
-MIXED INFLAMMATORY CELL INFILTRATION, NASAL CAVITY, SINUSES,  
TURBINATES, NASO-LACRIMAL DUCTS NOT SPECIFIED(MILD)

ADRENAL ..... NOT SPECIFIED(MILD)  
-FOCUS OF CELLULAR ALTERATION, VACUOLATED  
-CORTICAL NODULAR HYPERPLASIA NOT SPECIFIED (PRESENT)

PITUITARY GLAND ..... (PRESENT)  
-B- ADENOMA

EYES & OPTIC N. .... THE CATARACT IS SUBCAPSULAR AND UNILATERAL. IT IS CHARACTERIZED  
HISTOLOGICALLY BY THE PRESENCE OF LARGE NUCLEATED CELLS IN THE  
SUBCAPSULAR AREA. THIS IS AN EARLY CHANGE THAT MAY NOT HAVE  
BEEN DETECTED GROSSLY.  
-LENTICULAR DEGENERATIVE CHANGES COMPATIBLE WITH CATARACT NOT SPECIFIED (PRESENT)



Appendix J (cont.): PATHOLOGY INDIVIDUAL ANIMAL DATA

LETTERMAN ARMY INSTITUTE OF RESEARCH  
 DIV OF RES SUPP, PATH SERV GP  
 SPECIES: RAT/FISCHER-344

INDIVIDUAL ANIMAL DATA REPORT  
 STUDY NUMBER: GLP83009  
 STUDY START DATE: 23-JAN-84

PRINTED: 21-NOV-89  
 PAGE: 375  
 STUDY TYPE: CHRONIC/2 YR CARCINOGENIC

ANIMAL NUMBER: 181/PRETEST= 181 SEX: MALE DOSE GROUP: 3 SACRIFICE STATUS: FINAL SACRIFICE  
 DATE OF DEATH: 03-FEB-86 STUDY DAY OF DEATH: 743 STUDY WEEK OF DEATH: 107 TERMINAL BODY WEIGHT: 375.00 (GMS)

ORGAN NAME << GROSS ORGAN OBSERVATIONS >>  
 KEYWORDS / PHRASES SEVERITY GROSS FREE-TEXT COMMENTS

KIDNEY MILD  
 GRANULAR SURFACE  
 MAMMARY GLAND PROMINENT  
 PITUITARY GLAND ENLARGED  
 BILATERAL, AXILLARY REGION  
 .5CM DIAMETER, RED/BLACK

TISSUE / HISTOPATHOLOGIC FINDINGS << MICROSCOPIC TISSUE OBSERVATIONS >>  
 DISTRIBUTION (SEVERITY) / SPECIAL COMMENTS

HEART ..... NOT SPECIFIED(MILD)  
 -CARDIOMYOPATHY

LUNGS ..... NOT SPECIFIED (PRESENT)  
 -VASCULAR CONGESTION

LYMPH NODES ..... REACTIVE HYPERPLASIA LIMITED TO CERVICAL LYMPH NODES.  
 -REACTIVE HYPERPLASIA NOT SPECIFIED (PRESENT)

LIVER ..... NOT SPECIFIED(MILD)  
 -BILE DUCTULE EPITHELIAL HYPERPLASIA AND/OR CHOLANGIOFIBROSIS

KIDNEY ..... NOT SPECIFIED(MODERATE)  
 -PROGRESSIVE RENAL DISEASE

PROSTATE ..... NOT SPECIFIED(TRACE)  
 -BENIGN HYPERPLASIA

MAMMARY GLANDS ..... NOT SPECIFIED(MARKED)  
 -HYPERPLASIA AND/OR HYPERTROPHY OF THE ACINAR TISSUE  
 -DILATATION (ECTASIA) OF DUCTS AND DUCTULES NOT SPECIFIED (PRESENT)

NOSE/TURBINATES ..... INFILTRATE: UNILATERAL, NEAR NASO-LACRIMAL DUCT.  
 -MIXED INFLAMMATORY CELL INFILTRATION, NASAL CAVITY, SINUSES, NOT SPECIFIED(MODERATE)  
 TURBINATES, NASO-LACRIMAL DUCTS

ADRENAL .....

Appendix J (cont.): PATHOLOGY INDIVIDUAL ANIMAL DATA

LETTERMAN ARMY INSTITUTE OF RESEARCH  
DIV OF RES SUPP, PATH SERV GP  
SPECIES: RAT/FISCHER-344

INDIVIDUAL ANIMAL DATA REPORT  
STUDY NUMBER: GLP83009  
STUDY START DATE: 23-JAN-84

PRINTED: 21-NOV-89  
PAGE: 376

STUDY TYPE: CHRONIC/2 YR CARCINOGENIC

ANIMAL NUMBER: 181/PRETEST-  
DATE OF DEATH: 03-FEB-86 STUDY DAY OF DEATH: 743 181 SEX: MALE

DOSE GROUP: 3 SACRIFICE STATUS: FINAL SACRIFICE  
STUDY WEEK OF DEATH: 107 TERMINAL BODY WEIGHT: 375.00 (GMS)

TISSUE / HISTOPATHOLOGIC FINDINGS  
--<< MICROSCOPIC TISSUE OBSERVATIONS -->>  
DISTRIBUTION (SEVERITY) / SPECIAL COMMENTS

ADRENAL ..... NOT SPECIFIED(MODERATE)  
-FOCUS OF CELLULAR ALTERATION, VACUOLATED  
PITUITARY GLAND ..... (PRESENT)  
-B- ADENOMA  
EYES & OPTIC N. .... NOT SPECIFIED (PRESENT)  
-METAPLASTIC BONE FORMATION AND/OR MINERALIZATION, SCLERA

Appendix J (cont.): PATHOLOGY INDIVIDUAL ANIMAL DATA

LETTERMAN ARMY INSTITUTE OF RESEARCH  
 DIV OF RES SUPP, PATH SERV GP  
 SPECIES: RAT/FISCHER-344  
 ANIMAL NUMBER: 182/PRETEST= 182 SEX: MALE  
 DATE OF DEATH: 03-FEB-86 STUDY DAY OF DEATH: 743  
 DOSE GROUP: 3 SACRIFICE STATUS: FINAL SACRIFICE  
 STUDY WEEK OF DEATH: 107 TERMINAL BODY WEIGHT: 366.00 (GMS)  
 STUDY START DATE: 23-JAN-84  
 STUDY TYPE: CHRONIC/2 YR CARCINOGENIC  
 PRINTED: 21-NOV-89  
 PAGE: 377

ORGAN NAME << GROSS ORGAN OBSERVATIONS >>  
 SEVERITY GROSS FREE-TEXT COMMENTS

SKIN PRESENT DERMAL, ULCERATED, .5CM DIAMETER, NEAR PENIS  
 TESTES PRESENT RIGHT, 2.75 X 1.75CM  
 TESTES PRESENT BILATERAL, MULTIPLE VARIABLY SIZED, YELLOW  
 KIDNEY TRACE

<< MICROSCOPIC TISSUE OBSERVATIONS >>  
 DISTRIBUTION (SEVERITY) / SPECIAL COMMENTS

HEART ..... NOT SPECIFIED(MILD)  
 -CARDIOMYOPATHY ..... NOT SPECIFIED(TRACE)  
 -MEDIAL HYPERTROPHY OF MUSCULAR ARTERIES

LIVER ..... NOT SPECIFIED(MILD)  
 -BILE DUCTULE EPITHELIAL HYPERPLASIA AND/OR CHOLANGIOFIBROSIS ..... NOT SPECIFIED(MILD)  
 -FOCUS OF CELLULAR ALTERATION - CLEAR CELLS

KIDNEY ..... NOT SPECIFIED(MODERATE)  
 -PROGRESSIVE RENAL DISEASE

PROSTATE ..... NOT SPECIFIED(TRACE)  
 -CHRONIC PROSTATITIS ..... NOT SPECIFIED(TRACE)  
 -BENIGN HYPERPLASIA

SEMINAL VESICLE ..... NOT SPECIFIED (PRESENT)  
 -GENERALIZED ATROPHY

TESTES ..... (PRESENT)  
 -B- INTERSTITIAL CELL ADENOMA

PANCREAS ..... FOCAL(TRACE)  
 -CHRONIC INFLAMMATION

SKIN .....

Appendix J (cont.): PATHOLOGY INDIVIDUAL ANIMAL DATA

LETTERMAN ARMY INSTITUTE OF RESEARCH  
DIV OF RES SUPP, PATH SERV GP  
SPECIES: RAT/FISCHER-344

INDIVIDUAL ANIMAL DATA REPORT  
STUDY NUMBER: GLP83009  
STUDY START DATE: 23-JAN-84

PRINTED: 21-NOV-89  
PAGE: 378

STUDY TYPE: CHRONIC/2 YR CARCINOGENIC

ANIMAL NUMBER: 182/PRETEST-  
DATE OF DEATH: 03-FEB-86

182 SEX: MALE  
STUDY DAY OF DEATH: 743

DOSE GROUP: 3  
STUDY WEEK OF DEATH: 107

SACRIFICE STATUS: FINAL SACRIFICE  
TERMINAL BODY WEIGHT: 366.00 (GMS)

<< MICROSCOPIC TISSUE OBSERVATIONS >>  
TISSUE / HISTOPATHOLOGIC FINDINGS

DISTRIBUTION (SEVERITY) / SPECIAL COMMENTS

SKIN ..... (PRESENT)  
-B- PREPUTIAL GLAND ADENOMA ..... (PRESENT)  
PITUITARY GLAND ..... (PRESENT)  
-B- ADENOMA

Appendix J (cont.): PATHOLOGY INDIVIDUAL ANIMAL DATA

LETTERMAN ARMY INSTITUTE OF RESEARCH  
 DIV OF RES SUPP, PATH SERV GP  
 SPECIES: RAT/FISCHER-344  
 STUDY START DATE: 23-JAN-84  
 STUDY NUMBER: GLP83009  
 PRINTED: 21-NOV-89  
 PAGE: 379  
 STUDY TYPE: CHRONIC/2 YR CARCINOGENIC  
 ANIMAL NUMBER: 183/PRETEST= 183 SEX: MALE DOSE GROUP: 3 SACRIFICE STATUS: FINAL SACRIFICE  
 DATE OF DEATH: 03-FEB-86 STUDY DAY OF DEATH: 743 STUDY WEEK OF DEATH: 107 TERMINAL BODY WEIGHT: 387.00 (GMS)

ORGAN NAME << GROSS ORGAN OBSERVATIONS >>  
 KEYWORDS / PHRASES SEVERITY GROSS FREE-TEXT COMMENTS  
 TESTES GROUTM(S) / MASS(ES) PRESENT LEFT, MULTIPLE VARIABLY SIZED, YELLOW

TISSUE / HISTOPATHOLOGIC FINDINGS << MICROSCOPIC TISSUE OBSERVATIONS >>  
 DISTRIBUTION (SEVERITY) / SPECIAL COMMENTS

HEART  
 -CARDIOMYOPATHY NOT SPECIFIED(MILD)  
 -MEDIAL HYPERTROPHY OF MUSCULAR ARTERIES NOT SPECIFIED(TRACE)

LUNGS  
 -MINERALIZATION OF PULMONARY ARTERIES NOT SPECIFIED(TRACE)

LYMPH NODES  
 -RED BLOOD CELLS, HEMOSIDERIN AND/OR ERYTHROPHAGOCYTOSIS WITHIN MEDULLARY SINUSES ERYTHROPHAGOCYTOSIS AND HEMOSIDEROSIS WERE PRESENT IN THE CERVICAL LYMPH NODES.  
 NOT SPECIFIED (PRESENT)

LIVER  
 -BILE DUCTULE EPITHELIAL HYPERPLASIA AND/OR CHOLANGIOFIBROSIS NOT SPECIFIED(MILD)  
 -HEPATOCTIC VACUOLIZATION MULTI-FOCAL(TRACE)  
 -FOCUS OF CELLULAR ALTERATION - EOSINOPHILIC CELLS NOT SPECIFIED(TRACE)  
 -HEPATOCTE COALESCING MICROVESICULAR (FATTY) CHANGE LEADING TO NECROSIS AND MINERALIZATION MULTI-FOCAL(MILD)

KIDNEY  
 -PROGRESSIVE RENAL DISEASE NOT SPECIFIED(MILD)

PROSTATE  
 -CHRONIC PROSTATITIS  
 -BENIGN HYPERPLASIA MULTI-FOCAL(TRACE)  
 -MICROCALCULI, PROSTATIC URETHRA NOT SPECIFIED(TRACE)  
 NOT SPECIFIED (PRESENT)

Appendix J (cont.): PATHOLOGY INDIVIDUAL ANIMAL DATA

LETTERMAN ARMY INSTITUTE OF RESEARCH  
 DIV OF RES SUPP, PATH SERV GP  
 SPECIES: RAT/FISCHER-344

INDIVIDUAL ANIMAL DATA REPORT  
 STUDY NUMBER: GLP83009  
 STUDY START DATE: 23-JAN-84

PRINTED: 21-NOV-89  
 PAGE: 380  
 STUDY TYPE: CHRONIC/2 YR CARCINOGENIC

ANIMAL NUMBER: 183/PRETEST= 183 SEX: MALE DOSE GROUP: 3 SACRIFICE STATUS: FINAL SACRIFICE  
 DATE OF DEATH: 03-FEB-86 STUDY DAY OF DEATH: 743 STUDY WEEK OF DEATH: 107 TERMINAL BODY WEIGHT: 367.00 (GMS)

<< MICROSCOPIC TISSUE OBSERVATIONS >>  
 DISTRIBUTION (SEVERITY) / SPECIAL COMMENTS

COAG GL ..... TISSUE IS MISSING

SEMINAL VESICLE ..... NOT SPECIFIED (PRESENT)  
-GENERALIZED ATROPHY

TESTES ..... TUBULAR ATROPHY AND INTERSTITIAL HYPERPLASIA PRESENT IN RIGHT  
TESTIS WHICH CONTAINS NO TUMOR  
-TUBULAR ATROPHY  
-INTERSTITIAL CELL HYPERPLASIA  
-B- INTERSTITIAL CELL ADENOMA  
(PRESENT)

NOSE/TURBINATES ..... INFILTRATE BILATERAL NEAR NASO-LACRIMAL DUCTS.  
-MIXED INFLAMMATORY CELL INFILTRATION, NASAL CAVITY, SINUSES, NOT SPECIFIED(TRACE)  
TURBINATES, NASO-LACRIMAL DUCTS

ADRENAL ..... (PRESENT)  
-B- PHEOCHROMOCYTOMA

PITUITARY GLAND ..... (PRESENT)  
-B- ADENOMA

EYES & OPTIC N. ....  
-CORNEAL MINERALIZATION FOCAL(TRACE)  
-CORNEAL VASCULARIZATION FOCAL(TRACE)  
-METAPLASTIC BONE FORMATION AND/OR MINERALIZATION, SCLERA NOT SPECIFIED (PRESENT)

Appendix J (cont.): PATHOLOGY INDIVIDUAL ANIMAL DATA

LETTERMAN ARMY INSTITUTE OF RESEARCH
INDIVIDUAL ANIMAL DATA REPORT
DIV OF RES SUPP, PATH SERV GP
SPECIES: RAT/FISCHER-344
STUDY NUMBER: GLP83009
STUDY START DATE: 23-JAN-84
STUDY TYPE: CHRONIC/2 YR CARCINOGENIC
ANIMAL NUMBER: 184/PRETEST#
DOSE GROUP: 3
SACRIFICE STATUS: FINAL SACRIFICE
DATE OF DEATH: 03-FEB-86
STUDY DAY OF DEATH: 743
STUDY WEEK OF DEATH: 107
TERMINAL BODY WEIGHT: 380.00 (GMS)

ORGAN NAME OBSERVATIONS
KEYWORDS / PHRASES SEVERITY GROSS FREE-TEXT COMMENTS
GROWTH(S) / MASS(ES) PRESENT RIGHT UPPER LIP, FIRM, WHITE, .3CM DIAMETER
TESTES GROWTH(S) / MASS(ES) PRESENT BILATERAL, MULTIPLE VARIABLY SIZED, YELLOW

MICROSCOPIC TISSUE OBSERVATIONS
HISTOPATHOLOGIC FINDINGS DISTRIBUTION (SEVERITY) / SPECIAL COMMENTS

HEART NOT SPECIFIED (TRACE)
-CARDIOMYOPATHY

LIVER NOT SPECIFIED (TRACE)
-NEPATITIS MULTI-FOCAL (MILD)
-CYSTIC DEGENERATION NOT SPECIFIED (PRESENT)
-FOCUS OF CELLULAR ALTERATION - EOSINOPHILIC CELLS NOT SPECIFIED (TRACE)
-NEPATOCYTE COALESCING MICROVESICULAR (FATTY) CHANGE LEADING TO NECROSIS AND MINERALIZATION MULTI-FOCAL (TRACE)

KIDNEY NOT SPECIFIED (MILD)
-PROGRESSIVE RENAL DISEASE

PROSTATE NOT SPECIFIED (MILD)
-CHRONIC PROSTATITIS NOT SPECIFIED (TRACE)
-BENIGN HYPERPLASIA

TESTES (PRESENT)
-B INTERSTITIAL CELL ADENOMA

PANCREAS NOT SPECIFIED (MODERATE)
-ACINAR (EXOCRINE) ATROPHY

PRINTED: 21-NOV-89
PAGE: 381

Appendix J (cont.): PATHOLOGY INDIVIDUAL ANIMAL DATA

LETTERMAN ARMY INSTITUTE OF RESEARCH  
DIV OF RES SUPP, PATH SERV GP  
SPECIES: RAT/FISCHER-344

INDIVIDUAL ANIMAL DATA REPORT  
STUDY NUMBER: GLP83009  
STUDY START DATE: 23-JAN-84

PRINTED: 21-NOV-89  
PAGE: 382  
STUDY TYPE: CHRONIC/2 YR CARCINOGENIC

ANIMAL NUMBER: 184/PRETEST= 184 SEX: MALE DOSE GROUP: 3 SACRIFICE STATUS: FINAL SACRIFICE  
DATE OF DEATH: 03-FEB-86 STUDY DAY OF DEATH: 743 STUDY WEEK OF DEATH: 107 TERMINAL BODY WEIGHT: 380.00 (GMS)

TISSUE / HISTOPATHOLOGIC FINDINGS  
MICROSCOPIC TISSUE OBSERVATIONS >>  
DISTRIBUTION (SEVERITY) / SPECIAL COMMENTS

SKIN ..... THE MODULE ON THE LIP THAT WAS OBSERVED GROSSLY IS A BASAL CELL  
TUMOR. ULE ON THE LIP THAT WAS OBSERVED GROSSLY IS A BASAL CELL  
-CELLULITIS FOCAL (TRACE)  
-B- BASAL CELL TUMOR (PRESENT)

MAMMARY GLANDS .....  
-HYPERPLASIA AND/OR HYPERTROPHY OF THE ACINAR TISSUE NOT SPECIFIED (MILD)  
-DILATATION (ECTASIA) OF DUCTS AND DUCTULES NOT SPECIFIED (PRESENT)

NOSE/TURBINATES ..... INFILTRATE UNILATERAL NEAR MASO-LACRIMAL DUCTS.  
-MIXED INFLAMMATORY CELL INFILTRATION, NASAL CAVITY, SINUSES, NOT SPECIFIED (TRACE)  
TURBINATES, MASO-LACRIMAL DUCTS

PITUITARY GLAND .....  
-B- ADENOMA (PRESENT)

EYES & OPTIC N. ....  
-METAPLASTIC BONE FORMATION AND/OR MINERALIZATION, SCLERA NOT SPECIFIED (PRESENT)



Appendix J (cont.): PATHOLOGY INDIVIDUAL ANIMAL DATA

LETTERMAN ARMY INSTITUTE OF RESEARCH  
 DIV OF RES SUPP, PATH SERV GP  
 SPECIES: RAT/FISCHER-344  
 INDIVIDUAL ANIMAL DATA REPORT  
 STUDY NUMBER: GLP83009  
 STUDY START DATE: 23-JAN-84  
 PRINTED: 21-NOV-89  
 PAGE: 383  
 STUDY TYPE: CHRONIC/2 YR CARCINOGENIC  
 ANIMAL NUMBER: 185/PRETEST= 185 SEX: MALE DOSE GROUP: 3 SACRIFICE STATUS: FINAL SACRIFICE  
 DATE OF DEATH: 03-FEB-86 STUDY DAY OF DEATH: 743 STUDY WEEK OF DEATH: 107 TERMINAL BODY WEIGHT: 356.00 (GMS)

ORGAN NAME << GROSS ORGAN OBSERVATIONS >>  
 SEVERITY GROSS FREE-TEXT COMMENTS  
 TESTES ENLARGED PRESENT RIGHT, 3 X 2CM  
 TESTES GROWTH(S) / MASS(ES) PRESENT BILATERAL, MULTIPLE VARIABLY SIZED, YELLOW

TISSUE / HISTOPATHOLOGIC FINDINGS << MICROSCOPIC TISSUE OBSERVATIONS >>  
 DISTRIBUTION (SEVERITY) / SPECIAL COMMENTS

THYROID GLANDS  
 -PARA-FOLLICULAR CELL HYPERPLASIA ("C" CELL, LIGHT CELL) NOT SPECIFIED(TRACE)

HEART  
 -CARDIOMYOPATHY NOT SPECIFIED(TRACE)

LUNGS  
 -MINERALIZATION OF PULMONARY ARTERIES NOT SPECIFIED(TRACE)

LIVER  
 -BILE DUCTULE EPITHELIAL HYPERPLASIA AND/OR CHOLANGIOFIBROSIS NOT SPECIFIED(MILD)  
 -FOCUS OF CELLULAR ALTERATION - CLEAR CELLS NOT SPECIFIED(TRACE)  
 -CYSTIC DEGENERATION NOT SPECIFIED (PRESENT)  
 -FOCUS OF CELLULAR ALTERATION - EOSINOPHILIC CELLS NOT SPECIFIED(TRACE)  
 -HEPATOCYTE COALESCING MICROVESICULAR (FATTY) CHANGE LEADING TO MULTI-FOCAL(TRACE)  
 NECROSIS AND MINERALIZATION

KIDNEY  
 -PROGRESSIVE RENAL DISEASE NOT SPECIFIED(MILD)

PROSTATE  
 THERE IS CHRONIC INFLAMMATION OF THE URETHRA AT THE LEVEL OF THE PROSTATE. THE URETHRA CONTAINS INSPISSATED EOSINOPHILIC MATERIAL.  
 -CHRONIC PROSTATITIS NOT SPECIFIED(TRACE)  
 -BENIGN HYPERPLASIA NOT SPECIFIED(TRACE)

SEMINAL VESICLE

Appendix J (cont.): PATHOLOGY INDIVIDUAL ANIMAL DATA

LETTERMAN ARMY INSTITUTE OF RESEARCH  
 DIV OF RES SUPP, PATH SERV GP  
 SPECIES: RAT/FISCHER-344

INDIVIDUAL ANIMAL DATA REPORT  
 STUDY NUMBER: GLP83009

STUDY START DATE: 23-JAN-84

PRINTED: 21-NOV-89  
 PAGE: 364

ANIMAL NUMBER: 185/PRETEST#  
 DOSE GROUP: 3  
 SACRIFICE STATUS: FINAL SACRIFICE

DATE OF DEATH: 03-FEB-86  
 STUDY DAY OF DEATH: 743  
 STUDY WEEK OF DEATH: 107  
 TERMINAL BODY WEIGHT: 356.00 (GMS)

STUDY TYPE: CHRONIC/2 YR CARCINOGENIC

TISSUE / HISTOPATHOLOGIC FINDINGS  
 << MICROSCOPIC TISSUE OBSERVATIONS >>  
 DISTRIBUTION (SEVERITY) / SPECIAL COMMENTS

SEMINAL VESICLE ..... NOT SPECIFIED (PRESENT)  
 -GENERALIZED ATROPHY

TESTES ..... (PRESENT)  
 -B- INTERSTITIAL CELL ADENOMA

MAMMARY GLANDS ..... NOT SPECIFIED(MODERATE)  
 -HYPERPLASIA AND/OR HYPERTROPHY OF THE ACINAR TISSUE

NOSE/TURBINATES ..... INFILTRATE BILATERAL NEAR NASO-LACRIMAL DUCTS.  
 -MIXED INFLAMMATORY CELL INFILTRATION, NASAL CAVITY, SINUSES, NOT SPECIFIED(TRACE)  
 TURBINATES, NASO-LACRIMAL DUCTS

EYES & OPTIC N. .... NOT SPECIFIED (PRESENT)  
 -METAPLASTIC BONE FORMATION AND/OR MINERALIZATION, SCLERA

Appendix J (cont.): PATHOLOGY INDIVIDUAL ANIMAL DATA

LETTERMAN ARMY INSTITUTE OF RESEARCH  
 DIV OF RES SUPP, PATH SERV GP  
 SPECIES: RAT/FISCHER-344  
 INDIVIDUAL ANIMAL DATA REPORT  
 STUDY NUMBER: GLP83009  
 STUDY START DATE: 23-JAN-84  
 PRINTED: 21-NOV-89  
 PAGE: 385  
 STUDY TYPE: CHRONIC/2 YR CARCINOGENIC

ANIMAL NUMBER: 186/PRETEST= 186 SEX: MALE DOSE GROUP: 3 SACRIFICE STATUS: FINAL SACRIFICE  
 DATE OF DEATH: 03-FEB-86 STUDY DAY OF DEATH: 743 STUDY WEEK OF DEATH: 107 TERMINAL BODY WEIGHT: 391.00 (GMS)

ORGAN NAME << GROSS ORGAN OBSERVATIONS >> SEVERITY GROSS FREE-TEXT COMMENTS  
 KEYWORDS / PHRASES

TESTES GROWTH(S) / MASS(ES) PRESENT BILATERAL, MULTIPLE VARIABLY SIZED, YELLOW  
 PITUITARY GLAND ENLARGED PRESENT DARK RED, .5CM DIAMETER

TISSUE << MICROSCOPIC TISSUE OBSERVATIONS >> DISTRIBUTION (SEVERITY) / SPECIAL COMMENTS  
 FINDINGS

THYROID GLANDS (PRESENT)  
 -B- PARA-FOLLICULAR CELL ADENOMA

HEART (PRESENT)  
 -CARDIOMYOPATHY NOT SPECIFIED(MODERATE)

LUNGS NOT SPECIFIED(TRACE)  
 -PERIBRONCHIAL LYMPHOID HYPERPLASIA

SPLEEN THERE ARE NO CHANGES IN THE SPLEEN MICROSCOPICALLY WHICH WOULD ACCOUNT FOR THE "INTRA-ABDOMINAL SPLENIC MASS" DETECTED CLINICALLY. THE SIZE OF THE SPLEEN ON SECTION IS WITHIN NORMAL LIMITS.

LIVER NOT SPECIFIED(WILD)  
 -BILE DUCTULE EPITHELIAL HYPERPLASIA AND/OR CHOLANGIOFIBROSIS MULTI-FOCAL(TRACE)  
 -HEPATOCTYIC VACUOLIZATION NOT SPECIFIED (PRESENT)  
 -CYSTIC DEGENERATION

KIDNEY NOT SPECIFIED(MARKED)  
 -PROGRESSIVE RENAL DISEASE

PROSTATE NOT SPECIFIED(MODERATE)  
 -CHRONIC PROSTATITIS NOT SPECIFIED(TRACE)  
 -BENIGN HYPERPLASIA

TESTES

Appendix J (cont.): PATHOLOGY INDIVIDUAL ANIMAL DATA

LETTERMAN ARMY INSTITUTE OF RESEARCH  
DIV OF RES SUPP, PATH SERV GP  
SPECIES: RAT/FISCHER-344

INDIVIDUAL ANIMAL DATA REPORT  
STUDY NUMBER: GLP83009

PRINTED: 21-NOV-89  
PAGE: 386

STUDY START DATE: 23-JAN-84

STUDY TYPE: CHRONIC/2 YR CARCINOGENIC

ANIMAL NUMBER: 186/PRETEST-186 SEX: MALE DOSE GROUP: 3 SACRIFICE STATUS: FINAL SACRIFICE

DATE OF DEATH: 03-FEB-86 STUDY DAY OF DEATH: 743 STUDY WEEK OF DEATH: 107 TERMINAL BODY WEIGHT: 391.00 (GMS)

TISSUE / HISTOPATHOLOGIC FINDINGS << M I C R O S C O P I C T I S S U E O B S E R V A T I O N S >>  
DISTRIBUTION (SEVERITY) / SPECIAL COMMENTS

TESTES ..... (PRESENT)  
-B- INTERSTITIAL CELL ADENOMA

PANCREAS ..... (PRESENT)  
-B- ISLET CELL ADENOMA

TONGUE ..... MULTI-FOCAL (TRACE)  
-MONONUCLEAR CELLULAR INFILTRATION

MAMMARY GLANDS ..... NOT SPECIFIED (MILD)  
-HYPERPLASIA AND/OR HYPERTROPHY OF THE ACINAR TISSUE  
-DILATATION (ECTASIA) OF DUCTS AND DUCTULES NOT SPECIFIED (PRESENT)

PITUITARY GLAND ..... (PRESENT)  
-B- ADENOMA

EYES & OPTIC N. .... NOT SPECIFIED (PRESENT)  
-METAPLASTIC BONE FORMATION AND/OR MINERALIZATION, SCLERA

**Appendix J (cont.): PATHOLOGY INDIVIDUAL ANIMAL DATA**

LETTERMAN ARMY INSTITUTE OF RESEARCH  
 DIV OF RES SUPP, PATH SERV GP  
 SPECIES: RAT/FISCHER-344  
 STUDY START DATE: 23-JAN-84  
 STUDY NUMBER: GLP83009  
 PRINTED: 21-NOV-89  
 PAGE: 387

ANIMAL NUMBER: 167/PRETEST#  
 DATE OF DEATH: 08-NOV-85  
 STUDY DAY OF DEATH: 656  
 DOSE GROUP: 3  
 STUDY WEEK OF DEATH: 94  
 SACRIFICE STATUS: SACRIFICED MORIBUND  
 TERMINAL BODY WEIGHT: 380.00 (GMS)  
 STUDY TYPE: CHRONIC/2 YR CARCINOGENIC

ORGAN NAME: << GROSS ORGAN OBSERVATIONS >>  
 KEYWORDS / PHRASES: SEVERITY GROSS FREE-TEXT COMMENTS  
 TESTES: DISCOLORATION PRESENT MOTTLED RED, WHITE AND GRAY. GELATINOUS CONSISTENCY.  
 KIDNEY: FIRM WHITE MASS PRESENT IRREGULAR, 1.2 X 1.4CM, EXTENDS INTO THE SUBCAPSULAR CORTEX  
 LIVER: DISCOLORATION PRESENT ONE FOCAL, WHITE, .5 X .3CM, LEFT LATERAL LOBE VISCERAL SURFACE  
 EYES & OPTIC N.: CRUSTY MATERIAL, PERIORBITAL PRESENT RED

<< MICROSCOPIC TISSUE OBSERVATIONS >>  
 DISTRIBUTION (SEVERITY) / SPECIAL COMMENTS

BRAIN ..... (PRESENT)  
 -B- ASTROCYTOMA  
 THYROID GLANDS .....  
 -PARA-FOLLICULAR CELL HYPERPLASIA (\*CM CELL, LIGHT CELL) FOCAL(TRACE)  
 HEART .....  
 -CARDIOMYOPATHY NOT SPECIFIED(MILD)  
 LUNGS .....  
 -MINERALIZATION OF PULMONARY ARTERIES NOT SPECIFIED(TRACE)  
 LIVER .....  
 -BILE DUCTULE EPITHELIAL HYPERPLASIA AND/OR CHOLANGIOFIBROSIS NOT SPECIFIED(MODERATE)  
 -BENIGN HYPERPLASTIC NODULE(S) NOT SPECIFIED(MILD)  
 KIDNEY .....  
 -PROGRESSIVE RENAL DISEASE NOT SPECIFIED(MODERATE)  
 -M- SARCOMA NOT OTHERWISE SPECIFIED (PRESENT)  
 PROSTATE .....  
 -CHRONIC PROSTATITIS FOCAL(TRACE)

Appendix J (cont.): PATHOLOGY INDIVIDUAL ANIMAL DATA

LETTERMAN ARMY INSTITUTE OF RESEARCH  
DIV OF RES SUPP, PATH SERV GP  
SPECIES: RAT/FISCHER-344

INDIVIDUAL ANIMAL DATA REPORT  
STUDY NUMBER: GLP83009  
STUDY START DATE: 23-JAN-84

PRINTED: 21-NOV-89  
PAGE: 388

STUDY TYPE: CHRONIC/2 YR CARCINOGENIC

ANIMAL NUMBER: 187/PRETEST-187 SEX: MALE DOSE GROUP: 3 SACRIFICE STATUS: SACRIFICED MORIBUND  
DATE OF DEATH: 08-NOV-85 STUDY DAY OF DEATH: 656 STUDY WEEK OF DEATH: 94 TERMINAL BODY WEIGHT: 380.00 (GMS)

TISSUE / HISTOPATHOLOGIC FINDINGS << M I C R O S C O P I C T I S S U E O B S E R V A T I O N S >>  
DISTRIBUTION (SEVERITY) / SPECIAL COMMENTS

PROSTATE ..... NOT SPECIFIED(MODERATE)  
-BENIGN HYPERPLASIA

SEMINAL VESICLE ..... NOT SPECIFIED (PRESENT)  
-GENERALIZED ATROPHY

TESTES ..... (PRESENT)  
-B- INTERSTITIAL CELL ADENOMA

PANCREAS ..... FOCAL(TRACE)  
-ACINAR (EXOCRINE) ATROPHY

NOSE/TURBINATES ..... INFILTRATE BILATERAL NEAR NASO-LACRIMAL DUCTS.  
-MIXED INFLAMMATORY CELL INFILTRATION, NASAL CAVITY, SINUSES,  
TURBINATES, NASO-LACRIMAL DUCTS NOT SPECIFIED(MILD)

PITUITARY GLAND ..... (PRESENT)  
-B- ADENOMA

Appendix J (cont.): PATHOLOGY INDIVIDUAL ANIMAL DATA

LETTERMAN ARMY INSTITUTE OF RESEARCH  
DIV OF RES SUPP, PATH SERV GP  
SPECIES: RAT/FISCHER-344  
STUDY NUMBER: GLP83009  
STUDY START DATE: 23-JAN-84  
STUDY TYPE: CHRONIC/2 YR CARCINOGENIC

ANIMAL NUMBER: 188/PRETEST#  
DATE OF DEATH: 17-OCT-85  
SEX: MALE  
DOSE GROUP: 3  
SACRIFICE STATUS: SACRIFICED MORIBUND  
STUDY WEEK OF DEATH: 91  
TERMINAL BODY WEIGHT: 400.00 (GMS)

ORGAN NAME: << GROSS ORGAN OBSERVATIONS >>  
KEYWORDS / PHRASES: SEVERITY GROSS FREE-TEXT COMMENTS  
SUBCUTANEOUS MASS: PRESENT FIRM, PINK, 4 X 3 X 1.5CM, RIGHT ABDOMINAL REGION

TISSUE / HISTOPATHOLOGIC FINDINGS: << MICROSCOPIC TISSUE OBSERVATIONS >>  
DISTRIBUTION (SEVERITY) / SPECIAL COMMENTS

PARATHYROID: TISSUE IS MISSING

LUNGS: MINERALIZATION OF PULMONARY ARTERIES NOT SPECIFIED (TRACE)

LYMPH NODES: RED BLOOD CELLS, HEMOSIDERIN AND/OR ERYTHROPHAGOCYTOSIS WITHIN MEDULLARY SINUSES NOT SPECIFIED (PRESENT)

LIVER: BILE DUCTULE EPITHELIAL HYPERPLASIA AND/OR CHOLANGIOFIBROSIS NOT SPECIFIED (MODERATE)  
-HEPATOCTYE COALESCING MICROVESICULAR (FATTY) CHANGE LEADING TO MULTI-FOCAL (MILD) NECROSIS AND MINERALIZATION

KIDNEY: PROGRESSIVE RENAL DISEASE NOT SPECIFIED (TRACE)

PROSTATE: BENIGN HYPERPLASIA NOT SPECIFIED (TRACE)

SEMINAL VESICLE: GENERALIZED ATROPHY NOT SPECIFIED (PRESENT)

SKIN: THE FIBROMA WAS IN THE SUBCUTIS ON THE RIGHT SIDE OF THE ABDOMEN. THERE WAS NO SKIN SPECIMEN SUBMITTED FOR SECTION #15. (PRESENT)

-B- FIBROMA

PRINTED: 21-NOV-89  
PAGE: 389

Appendix J (cont.): PATHOLOGY INDIVIDUAL ANIMAL DATA

LETTERMAN ARMY INSTITUTE OF RESEARCH  
DIV OF RES SUPP, PATH SERV GP  
SPECIES: RAT/FISCHER-344

INDIVIDUAL ANIMAL DATA REPORT  
STUDY NUMBER: GLP83009

PRINTED: 21-NOV-89  
PAGE: 390

STUDY START DATE: 23-JAN-84

STUDY TYPE: CHRONIC/2 YR CARCINOGENIC

ANIMAL NUMBER: 188/PRETEST= 188 SEX: MALE  
DATE OF DEATH: 17-OCT-85 STUDY DAY OF DEATH: 634

DOSE GROUP: 3 SACRIFICE STATUS: SACRIFICED MORIBUND  
STUDY WEEK OF DEATH: 91 TERMINAL BODY WEIGHT: 400.00 (GMS)

<< MICROSCOPIC TISSUE OBSERVATIONS >>  
TISSUE / HISTOPATHOLOGIC FINDINGS

DISTRIBUTION (SEVERITY) / SPECIAL COMMENTS

MAMMARY GLANDS ..... TISSUE IS MISSING

ADRENAL ..... NOT SPECIFIED(TRACE)  
-FOCUS OF CELLULAR ALTERATION, VACUOLATED

PITUITARY GLAND ..... TISSUE IS MISSING  
RECUTS OF BLOCK #18 FAILED TO DEMONSTRATE PITUITARY GLAND.

EYES & OPTIC N. .... NOT SPECIFIED(TRACE)  
-CORNEAL MINERALIZATION  
-RETINAL ATROPHY AND/OR DEGENERATION, UNILATERAL OR BILATERAL



## Appendix J (cont.): PATHOLOGY INDIVIDUAL ANIMAL DATA

LETTERMAN ARMY INSTITUTE OF RESEARCH  
 DIV OF RES SUPP, PATH SERV GP  
 SPECIES: RAT/FISCHER-344  
 STUDY START DATE: 23-JAN-84  
 STUDY NUMBER: GLP83009  
 PRINTED: 21-NOV-89  
 PAGE: 391  
 STUDY TYPE: CHRONIC/2 YR CARCINOGENIC

ANIMAL NUMBER: 189/PRETEST-  
 DATE OF DEATH: 23-APR-85  
 STUDY DAY OF DEATH: 457  
 DOSE GROUP: 3  
 STUDY WEEK OF DEATH: 66  
 SACRIFICE STATUS: SACRIFICED MORIBUND  
 TERMINAL BODY WEIGHT: 410.00 (GMS)

<< GROSS ORGAN OBSERVATIONS >>  
 SEVERITY GROSS FREE-TEXT COMMENTS  
 KEYWORDS / PHRASES  
 ALOPECIA  
 PRESENT 4 X 2CM ON DORSAL THORAX, MULTIPLE 1MM YELLOW CRUSTY FOCI IN  
 AREA OF HAIR LOSS.  
 ATROPHIC / SMALL, UNILATERALLY PRESENT  
 GROWTH(S) / MASS(ES) PRESENT RIGHT, MULTIPLE, ANTERIOR POLE, YELLOW, .2-.4CM DIAMETER

<< MICROSCOPIC TISSUE OBSERVATIONS >>  
 DISTRIBUTION (SEVERITY) / SPECIAL COMMENTS

HEART ..... NOT SPECIFIED(MODERATE)  
 -CARDIOMYOPATHY

LUNGS ..... NOT SPECIFIED(TRACE)  
 -MINERALIZATION OF PULMONARY ARTERIES

LIVER ..... NOT SPECIFIED(MILD)  
 -BILE DUCTULE EPITHELIAL HYPERPLASIA AND/OR CHOLANGIOFIBROSIS

KIDNEY ..... NOT SPECIFIED(TRACE)  
 -PROGRESSIVE RENAL DISEASE

PROSTATE ..... NOT SPECIFIED(MILD)  
 -BENIGN HYPERPLASIA

SEMINAL VESICLE ..... NOT SPECIFIED (PRESENT)  
 -GENERALIZED ATROPHY

TESTES ..... (PRESENT)  
 -B- INTERSTITIAL CELL ADENOMA

PANCREAS ..... NOT SPECIFIED(TRACE)  
 -ACINAR (EXOCRINE) ATROPHY

Appendix J (cont.): PATHOLOGY INDIVIDUAL ANIMAL DATA

LETTERMAN ARMY INSTITUTE OF RESEARCH  
DIV OF RES SUPP, PATH SERV GP  
SPECIES: RAT/FISCHER-344

INDIVIDUAL ANIMAL DATA REPORT  
STUDY NUMBER: GLP83009  
STUDY START DATE: 23-JAN-84

PRINTED: 21-NOV-89  
PAGE: 392

STUDY TYPE: CHRONIC/2 YR CARCINOGENIC

ANIMAL NUMBER: 189/PRETEST-189 SEX: MALE DOSE GROUP: 3 SACRIFICE STATUS: SACRIFICED MORIBUND  
DATE OF DEATH: 23-APR-85 STUDY DAY OF DEATH: 457 STUDY WEEK OF DEATH: 66 TERMINAL BODY WEIGHT: 410.00 (GMS)

TISSUE / HISTOPATHOLOGIC FINDINGS << MICROSCOPIC TISSUE OBSERVATIONS >>  
DISTRIBUTION (SEVERITY) / SPECIAL COMMENTS

SKIN ..... SUBACUTE  
-CELLULITIS ..... DIFFUSE(MILD)

MAMMARY GLANDS ..... NOT SPECIFIED (PRESENT)  
-GALACTOCELE(S) .....

EYES & OPTIC N. .... FOCAL(TRACE)  
-CORNEAL MINERALIZATION .....

**Appendix J (cont.): PATHOLOGY INDIVIDUAL ANIMAL DATA**

LETTERMAN ARMY INSTITUTE OF RESEARCH  
 DIV OF RES SUPP, PATH SERV GP  
 SPECIES: RAT/FISCHER-344  
 STUDY START DATE: 23-JAN-84  
 STUDY NUMBER: GLP83009  
 PRINTED: 21-NOV-89  
 PAGE: 393  
 ANIMAL NUMBER: 190/PRETEST-190  
 SEX: MALE  
 DOSE GROUP: 3  
 SACRIFICE STATUS: FINAL SACRIFICE  
 DATE OF DEATH: 05-FEB-86  
 STUDY DAY OF DEATH: 745  
 STUDY WEEK OF DEATH: 107  
 TERMINAL BODY WEIGHT: 421.00 (GMS)  
 STUDY TYPE: CHRONIC/2 YR CARCINOGENIC

ORGAN NAME ..... GROSS ORGAN OBSERVATIONS >>  
 SEVERITY GROSS FREE-TEXT COMMENTS  
 EYES & OPTIC N. .... LENS CATARACT ..... PRESENT LEFT  
 SKIN ..... SUBCUTANEOUS MASS ..... PRESENT SEMI-FIRM, WHITE, RIGHT THORACIC REGION, 2.5 X 2 X 1CM  
 TESTES ..... ENLARGED ..... PRESENT RIGHT, 2.75 X 1.75  
 TESTES ..... GROWTH(S) / MASSES) ..... PRESENT BILATERAL, MULTIPLE VARIABLY SIZED, YELLOW/BLACK  
 KIDNEY ..... GRANULAR SURFACE ..... PRESENT

TISSUE / HISTOPATHOLOGIC FINDINGS ..... MICROSCOPIC TISSUE OBSERVATIONS >>  
 DISTRIBUTION (SEVERITY) / SPECIAL COMMENTS

LACRIMAL GLAND ..... INFLAMMATION, SUBACUTE TO CHRONIC ..... MULTI-FOCAL(TRACE)  
 HEART ..... CARDIOMYOPATHY ..... NOT SPECIFIED(TRACE)  
 LUNGS ..... MINERALIZATION OF PULMONARY ARTERIES ..... MULTI-FOCAL(TRACE)  
 LYMPH NODES ..... RED BLOOD CELLS, HEMOSIDERIN AND/OR ERYTHROPHAGOCYTOSIS WITHIN MEDULLARY SINUSES ..... RBC'S AND HEMOSIDEROSIS ARE PRESENT IN CERVICAL NODES ONLY  
 -REACTIVE HYPERPLASIA ..... NOT SPECIFIED (PRESENT)  
 LIVER ..... BILE DUCTULE EPITHELIAL HYPERPLASIA AND/OR CHOLANGIOFIBROSIS ..... NOT SPECIFIED(MILD)  
 -FOCUS OF CELLULAR ALTERATION - BASOPHILIC ..... FOCAL(TRACE)  
 -HEPATOCTYIC VACUOLIZATION ..... MULTI-FOCAL(TRACE)  
 -BENIGN HYPERPLASTIC NODULE(S) ..... FOCAL(TRACE)  
 KIDNEY ..... PROGRESSIVE RENAL DISEASE ..... NOT SPECIFIED(MODERATE)  
 -CYST(S) CORTICAL ..... MULTI-FOCAL (PRESENT)  
 PROSTATE

**Appendix J (cont.): PATHOLOGY INDIVIDUAL ANIMAL DATA**

LETTERMAN ARMY INSTITUTE OF RESEARCH  
 DIV OF RES SUPP, PATH SERV GP  
 SPECIES: RAT/FISCHER-344  
 STUDY START DATE: 23-JAN-84  
 ANIMAL NUMBER: 190/PRETEST-  
 DATE OF DEATH: 05-FEB-86  
 STUDY DAY OF DEATH: 745  
 190 SEX: MALE  
 DOSE GROUP: 3  
 SACRIFICE STATUS: FINAL SACRIFICE  
 STUDY WEEK OF DEATH: 107  
 TERMINAL BODY WEIGHT: 421.00 (GMS)  
 STUDY TYPE: CHRONIC/2 YR CARCINOGENIC  
 PRINTED: 21-NOV-89  
 PAGE: 394

INDIVIDUAL ANIMAL DATA REPORT  
 STUDY NUMBER: GLP83009  
 STUDY START DATE: 23-JAN-84  
 DOSE GROUP: 3  
 SACRIFICE STATUS: FINAL SACRIFICE  
 STUDY WEEK OF DEATH: 107  
 TERMINAL BODY WEIGHT: 421.00 (GMS)  
 STUDY TYPE: CHRONIC/2 YR CARCINOGENIC  
 PRINTED: 21-NOV-89  
 PAGE: 394

PROSTATE .....  
 -ACUTE SUPPURATIVE PROSTATITIS .....  
 -BENIGN HYPERPLASIA .....  
 NOT SPECIFIED(MILD)  
 FOCAL(TRACE)

TESTES .....  
 -B- INTERSTITIAL CELL ADENOMA .....  
 (PRESENT)

PANCREAS .....  
 -ACINAR (EXOCRINE) ATROPHY .....  
 -ACINAR HYPERPLASIA .....  
 MULTI-FOCAL(TRACE)  
 FOCAL(TRACE)

SKIN .....  
 -B- FIBROMA .....  
 THE SUBCUTANEOUS MASS IN THE RIGHT THORACIC REGION IS A FIBROMA  
 PROBABLY OF MAMMARY ORIGIN.  
 (PRESENT)

MAMMARY GLANDS .....  
 TISSUE IS MISSING  
 NO MAMMARY TISSUE PRESENT. THE FIBROMA LISTED UNDER SKIN IS  
 PROBABLY OF MAMMARY ORIGIN.

NOSE/TURBINATES .....  
 -MIXED INFLAMMATORY CELL INFILTRATION, NASAL CAVITY, SINUSES,  
 TURBINATES, NASO-LACRIMAL DUCTS .....  
 INFILTRATE INVOLVES NASO-LACRIMAL DUCTS.  
 NOT SPECIFIED(TRACE)

ADRENAL .....  
 -FOCUS OF CELLULAR ALTERATION, VACUOLATED .....  
 NOT SPECIFIED(TRACE)

PITUITARY GLAND .....  
 -B- ADENOMA .....  
 (PRESENT)

EYES & OPTIC N. ....  
 -RETINAL ATROPHY AND/OR DEGENERATION, UNILATERAL OR BILATERAL .....  
 -CHRONIC KERATITIS .....  
 -METAPLASTIC BONE FORMATION AND/OR MINERALIZATION, SCLERA .....  
 -LENTICULAR DEGENERATIVE CHANGES COMPATIBLE WITH CATARACT .....  
 THE LENS OF ONE EYE WAS LOST IN PROCESSING.  
 NOT SPECIFIED(MODERATE)  
 NOT SPECIFIED(TRACE)  
 NOT SPECIFIED (PRESENT)  
 NOT SPECIFIED (PRESENT)

**Appendix J (cont.): PATHOLOGY INDIVIDUAL ANIMAL DATA**

LETTERMAN ARMY INSTITUTE OF RESEARCH  
 DIV OF RES SUPP, PATH SERV GP  
 SPECIES: RAT/FISCHER-344  
 STUDY START DATE: 23-JAN-84  
 STUDY NUMBER: GLP83009  
 INDIVIDUAL ANIMAL DATA REPORT  
 PRINTED: 21-NOV-89  
 PAGE: 395

ANIMAL NUMBER: 191/PRETEST-  
 DATE OF DEATH: 05-FEB-86  
 SEX: MALE  
 DOSE GROUP: 3  
 STUDY WEEK OF DEATH: 107  
 SACRIFICE STATUS: FINAL SACRIFICE  
 TERMINAL BODY WEIGHT: 428.00 (GMS)

ORGAN NAME: << GROSS ORGAN OBSERVATIONS >>  
 KEYWORDS / PHRASES: SEVERITY GROSS FREE-TEXT COMMENTS  
 TESTES: GROWTH(S) / MASS(ES) PRESENT BILATERAL, MULTIPLE VARIABLY SIZED, YELLOW/BLACK

TISSUE / HISTOPATHOLOGIC FINDINGS: << MICROSCOPIC TISSUE OBSERVATIONS >>  
 DISTRIBUTION (SEVERITY) / SPECIAL COMMENTS

THYROID GLANDS: (PRESENT)

-B- PARA-FOLLICULAR CELL ADENOMA

PARATHYROID: TISSUE IS MISSING

HEART: NOT SPECIFIED(MILD)

-CARDIOMYOPATHY

LIVER: NOT SPECIFIED(MODERATE)  
 -BILE DUCTULE EPITHELIAL HYPERPLASIA AND/OR CHOLANGIOFIBROSIS  
 -FOCUS OF CELLULAR ALTERATION - CLEAR CELLS  
 -HEPATOCYTE COALESCING MICROVESICULAR (FATTY) CHANGE LEADING TO  
 NECROSIS AND MINERALIZATION  
 MULTI-FOCAL(TRACE)

KIDNEY: NOT SPECIFIED(MODERATE)  
 -PROGRESSIVE RENAL DISEASE

PROSTATE: NOT SPECIFIED(MILD)  
 -CHRONIC PROSTATITIS  
 -BENIGN HYPERPLASIA  
 NOT SPECIFIED(TRACE)

TESTES: (PRESENT)  
 -B- INTERSTITIAL CELL ADENOMA

PANCREAS: FOCAL(TRACE)  
 -CHRONIC INFLAMMATION

Appendix J (cont.): PATHOLOGY INDIVIDUAL ANIMAL DATA

LETTERMAN ARMY INSTITUTE OF RESEARCH  
DIV OF RES SUPP, PATN SERV GP  
SPECIES: RAT/FISCHER-344

INDIVIDUAL ANIMAL DATA REPORT  
STUDY NUMBER: GLP83009  
STUDY START DATE: 23-JAN-84

PRINTED: 21-NOV-89  
PAGE: 396  
STUDY TYPE: CHRONIC/2 YR CARCINOGENIC

ANIMAL NUMBER: 191/PRETEST-      191 SEX: MALE      DOSE GROUP: 3      SACRIFICE STATUS: FINAL SACRIFICE  
DATE OF DEATH: 05-FEB-86      STUDY DAY OF DEATH: 745      STUDY WEEK OF DEATH: 107      TERMINAL BODY WEIGHT: 428.00 (GMS)

<< MICROSCOPIC TISSUE OBSERVATIONS >>  
TISSUE / HISTOPATHOLOGIC FINDINGS ..... DISTRIBUTION (SEVERITY) / SPECIAL COMMENTS .....

NOSE/TURBINATES ..... INFILTRATE LIMITED TO VENTRAL NASAL CAVITY.  
-MIXED INFLAMMATORY CELL INFILTRATION, NASAL CAVITY, SINUSES, ..... NOT SPECIFIED (TRACE)  
TURBINATES, NASO-LACRIMAL DUCTS

ADRENAL ..... NOT SPECIFIED (TRACE)  
-FOCUS OF CELLULAR ALTERATION, EOSINOPHILIC ..... NOT SPECIFIED (PRESENT)  
-CORTICAL MODULAR HYPERPLASIA

EYES & OPTIC N. .... NOT SPECIFIED (TRACE)  
-RETINAL ATROPHY AND/OR DEGENERATION, UNILATERAL OR BILATERAL

Appendix J (cont.): PATHOLOGY INDIVIDUAL ANIMAL DATA

LETTERMAN ARMY INSTITUTE OF RESEARCH  
 DIV OF RES SUPP, PATH SERV GP  
 SPECIES: RAT/FISCHER-344

INDIVIDUAL ANIMAL DATA REPORT  
 STUDY NUMBER: GLP83009

STUDY START DATE: 23-JAN-84

ANIMAL NUMBER: 192/PRETEST= 192 SEX: MALE DOSE GROUP: 3 SACRIFICE STATUS: FINAL SACRIFICE  
 DATE OF DEATH: 05-FEB-86 STUDY DAY OF DEATH: 745 STUDY WEEK OF DEATH: 107 TERMINAL BODY WEIGHT: 432.00 (GMS)

STUDY TYPE: CHRONIC/2 YR CARCINOGENIC

ORGAN NAME << GROSS ORGAN OBSERVATIONS >>  
 SEVERITY GROSS FREE-TEXT COMMENTS

SKIN GROWTH(S) / MASS(ES) PRESENT PAPILLARY, UPPER LIP, .2CM DIAMETER  
 TESTES ENLARGED PRESENT RIGHT, 2.5 X 1.5CM  
 TESTES GROWTH(S) / MASS(ES) PRESENT BILATERAL, MULTIPLE VARIABLY SIZED, YELLOW

TISSUE / HISTOPATHOLOGIC FINDINGS << MICROSCOPIC TISSUE OBSERVATIONS >>  
 DISTRIBUTION (SEVERITY) / SPECIAL COMMENTS

THYROID GLANDS ..... NOT SPECIFIED (TRACE)  
 -PARA-FOLLICULAR CELL HYPERPLASIA (\*C\* CELL, LIGHT CELL)

HEART ..... NOT SPECIFIED (TRACE)  
 -CARDIOMYOPATHY

LUNGS ..... NOT SPECIFIED (TRACE)  
 -MINERALIZATION OF PULMONARY ARTERIES

LIVER ..... NOT SPECIFIED (MODERATE)  
 -BILE DUCTULE EPITHELIAL HYPERPLASIA AND/OR CHOLANGIOFIBROSIS  
 -FOCUS OF CELLULAR ALTERATION - EOSINOPHILIC CELLS  
 -HEPATOCTYE COALESCING MICROVESICULAR (FATTY) CHANGE LEADING TO  
 NECROSIS AND MINERALIZATION

KIDNEY ..... NOT SPECIFIED (MODERATE)  
 -PROGRESSIVE RENAL DISEASE

PROSTATE ..... NOT SPECIFIED (MILD)  
 -CHRONIC PROSTATITIS  
 -MICROCALCULI, PROSTATIC URETHRA

TESTES ..... (PRESENT)  
 -B- INTERSTITIAL CELL ADENOMA

PANCREAS .....

PRINTED: 21-NOV-89  
 PAGE: 397

Appendix J (cont.): PATHOLOGY INDIVIDUAL ANIMAL DATA

LETTERMAN ARMY INSTITUTE OF RESEARCH  
DIV OF RES SUPP, PATH SERV GP  
SPECIES: RAT/FISCHER-344

INDIVIDUAL ANIMAL DATA REPORT  
STUDY NUMBER: GLP83009

PRINTED: 21-NOV-89  
PAGE: 398

STUDY START DATE: 23-JAN-84

STUDY TYPE: CHRONIC/2 YR CARCINOGENIC

ANIMAL NUMBER: 192/PRETEST-192 SEX: MALE DOSE GROUP: 3 SACRIFICE STATUS: FINAL SACRIFICE  
DATE OF DEATH: 05-FEB-86 STUDY DAY OF DEATH: 745 STUDY WEEK OF DEATH: 107 TERMINAL BODY WEIGHT: 432.00 (GMS)

TISSUE / HISTOPATHOLOGIC FINDINGS << MICROSCOPIC TISSUE OBSERVATIONS >>  
DISTRIBUTION (SEVERITY) / SPECIAL COMMENTS

PANCREAS ..... NOT SPECIFIED(MILD)  
-ACINAR (EXOCRINE) ATROPHY

SKIN ..... THIS SQUAMOUS PAPILLOMA WAS LOCATED ON THE UPPER LIP.  
-B- SQUAMOUS PAPILLOMA (PRESENT)

NOSE/TURBINATES ..... INFILTRATE INVOLVES NASO-LACRIMAL DUCTS AND VENTRAL NASAL CAVITY  
-MIXED INFLAMMATORY CELL INFILTRATION, NASAL CAVITY, SINUSES, NOT SPECIFIED(TRACE)  
TURBINATES, NASO-LACRIMAL DUCTS

ADRENAL ..... NOT SPECIFIED(TRACE)  
-FOCUS OF CELLULAR ALTERATION, EOSINOPHILIC NOT SPECIFIED(TRACE)  
-FOCUS OF CELLULAR ALTERATION, VACUOLATED NOT SPECIFIED (PRESENT)  
-CORTICAL MODULAR HYPERPLASIA

EYES & OPTIC N. .... NOT SPECIFIED (PRESENT)  
-METAPLASTIC BONE FORMATION AND/OR MINERALIZATION, SCLERA



Appendix J (cont.): PATHOLOGY INDIVIDUAL ANIMAL DATA

LETTERMAN ARMY INSTITUTE OF RESEARCH  
 DIV OF RES SUPP, PATH SERV GP  
 SPECIES: RAT/FISCHER-344

INDIVIDUAL ANIMAL DATA REPORT  
 STUDY NUMBER: GLP83009  
 STUDY START DATE: 23-JAN-84

PRINTED: 21-NOV-89  
 PAGE: 399  
 STUDY TYPE: CHRONIC/2 YR CARCINOGENIC

ANIMAL NUMBER: 193/PRETEST-  
 DATE OF DEATH: 29-JAN-86  
 SEX: MALE  
 DOSE GROUP: 3  
 SACRIFICE STATUS: SACRIFICED MORIBUND  
 STUDY DAY OF DEATH: 738  
 STUDY WEEK OF DEATH: 106  
 TERMINAL BODY WEIGHT: 340.00 (GMS)

ORGAN NAME                   <<   GROSS   ORGAN   OBSERVATIONS   >>  
 -----                   <----->  
 STOMACH                    PRESENT   -2CM DIAMETER, GRAY  
 LIVER                      PRESENT   PALE, IRREGULAR, 1.5CM DIAMETER, FOCAL  
 PITUITARY GLAND            PRESENT   DARK RED, .5CM DIAMETER  
 KIDNEY                     PRESENT   BILATERAL  
 TESTES                     PRESENT   LEFT, ONE .25CM DIAMETER, YELLOW

SEVERITY   GROSS FREE-TEXT COMMENTS  
 -----   ----->  
 <<   MICROSCOPIC   TISSUE   OBSERVATIONS   >>  
 -----   ----->  
 TISSUE / HISTOPATHOLOGIC FINDINGS   DISTRIBUTION (SEVERITY) / SPECIAL COMMENTS  
 -----   ----->

TRACHEA                    FOCAL(TRACE)  
 -NON-SUPPURATIVE TRACHEITIS

LACRIMAL GLAND             NOT SPECIFIED(TRACE)  
 -INFLAMMATION, SUBACUTE TO CHRONIC

EXORBITAL LACRIM           TISSUE IS MISSING  
                           RECUTS OF BLOCK #4 FAILED TO DEMONSTRATE EXORBITAL LACRIMAL  
                           GLAND.

HEART                      NOT SPECIFIED(MILD)  
 -CARDIOMYOPATHY

LIVER                      NOT SPECIFIED(MILD)  
 -BILE DUCTULE EPITHELIAL HYPERPLASIA AND/OR CHOLANGIOFIBROSIS  
 -HEPATOCTYIC VACUOLIZATION  
 -CYSTIC DEGENERATION

KIDNEY                     NOT SPECIFIED(MARKED)  
 -PROGRESSIVE RENAL DISEASE

PROSTATE                   NOT SPECIFIED(MARKED)

Appendix J (cont.): PATHOLOGY INDIVIDUAL ANIMAL DATA

LETTERMAN ARMY INSTITUTE OF RESEARCH  
 DIV OF RES SUPP, PATH SERV GP  
 SPECIES: RAT/FISCHER-344  
 STUDY NUMBER: GLP83009  
 STUDY START DATE: 23-JAN-84  
 PRINTED: 21-NOV-89  
 PAGE: 400  
 STUDY TYPE: CHRONIC/2 YR CARCINOGENIC

ANIMAL NUMBER: 193/PRETEST-  
 DATE OF DEATH: 29-JAN-86  
 SEX: MALE  
 DOSE GROUP: 3  
 SACRIFICE STATUS: SACRIFICED MORIBUND  
 STUDY WEEK OF DEATH: 738  
 TERMINAL BODY WEIGHT: 340.00 (GMS)

TISSUE / HISTOPATHOLOGIC FINDINGS  
 << MICROSCOPIC TISSUE OBSERVATIONS >>  
 DISTRIBUTION (SEVERITY) / SPECIAL COMMENTS

- PROSTATE ..... NOT SPECIFIED(MODERATE)
- CHRONIC PROSTATITIS
- SEMINAL VESICLE ..... NOT SPECIFIED (PRESENT)
- GENERALIZED ATROPHY
- TESTES ..... (PRESENT)
- B- INTERSTITIAL CELL ADENOMA
- PERIARTERITIS XANTHOSA
- STOMACH ..... NOT SPECIFIED (PRESENT)
- ULCERATION, NON-GLANDULAR AREA
- TONGUE ..... TISSUE IS MISSING
- MAMMARY GLANDS ..... NOT SPECIFIED(MILD)
- HYPERPLASIA AND/OR HYPERTROPHY OF THE ACINAR TISSUE
- DILATATION (ECTASIA) OF DUCTS AND DUCTULES
- NOSE/TURBINATES ..... INFILTRATE: SUPPURATIVE, BILATERAL, ADJACENT NASO-LACRIMAL DUCTS.
- MIXED INFLAMMATORY CELL INFILTRATION, NASAL CAVITY, SINUSES, TURBINATES, NASO-LACRIMAL DUCTS
- ADRENAL ..... NOT SPECIFIED(MARKED)
- FOCUS OF CELLULAR ALTERATION, VACUOLATED
- PITUITARY GLAND ..... (PRESENT)
- B- ADENOMA
- EYES & OPTIC N. .... NOT SPECIFIED(TRACE)
- RETINAL ATROPHY AND/OR DEGENERATION, UNILATERAL OR BILATERAL
- METAPLASTIC BONE FORMATION AND/OR MINERALIZATION, SCLERA

Appendix J (cont.): PATHOLOGY INDIVIDUAL ANIMAL DATA

LETTERMAN ARMY INSTITUTE OF RESEARCH DIV OF RES SUPP, PATH SERV GP STUDY NUMBER: GLP83009 PRINTED: 21-NOV-89

PAGE: 401

STUDY START DATE: 23-JAN-84

STUDY TYPE: CHRONIC/2 YR CARCINOGENIC

ANIMAL NUMBER: 194/PRETEST= 194 SEX: MALE DOSE GROUP: 3 SACRIFICE STATUS: FINAL SACRIFICE DATE OF DEATH: 05-FEB-86 STUDY DAY OF DEATH: 745 STUDY WEEK OF DEATH: 107 TERMINAL BODY WEIGHT: 425.00 (GMS)

ORGAN NAME KEYWORDS / PHRASES ORGAN OBSERVATIONS SEVERITY GROSS FREE-TEXT COMMENTS

MAMMARY GLAND PROMINENT PRESENT RIGHT CERVICAL REGION PITUITARY GLAND ENLARGED PRESENT DARK RED, .4CM DIAMETER

TISSUE / HISTOPATHOLOGIC FINDINGS MICROSCOPIC TISSUE OBSERVATIONS DISTRIBUTION (SEVERITY) / SPECIAL COMMENTS

THYROID GLANDS -PARA-FOLLICULAR CELL HYPERPLASIA (MC CELL, LIGHT CELL) NOT SPECIFIED(TRACE)

HEART -CARDIOMYOPATHY NOT SPECIFIED(MILD)

LUNGS -MINERALIZATION OF PULMONARY ARTERIES NOT SPECIFIED(TRACE)

LYMPH NODES -RED BLOOD CELLS, HEMOSIDERIN AND/OR ERYTHROPHAGOCYTOSIS WITHIN MEDULLARY SINUSES RBC'S AND HEMOSIDERIN PRESENT IN CERVICAL NODES ONLY. NOT SPECIFIED (PRESENT)

LIVER -BILE DUCTULE EPITHELIAL HYPERPLASIA AND/OR CHOLANGIOFIBROSIS -HEPATITIS -CYSTIC DEGENERATION NOT SPECIFIED(MILD) MULTI-FOCAL(TRACE) MULTI-FOCAL (PRESENT)

KIDNEY -PROGRESSIVE RENAL DISEASE NOT SPECIFIED(MODERATE)

PROSTATE -CHRONIC PROSTATITIS NOT SPECIFIED(TRACE)

MAMMARY GLANDS -HYPERPLASIA AND/OR HYPERTROPHY OF THE ACINAR TISSUE NOT SPECIFIED(MILD)

Appendix J (cont.): PATHOLOGY INDIVIDUAL ANIMAL DATA

LETTERMAN ARMY INSTITUTE OF RESEARCH  
DIV OF RES SUPP, PATH SERV GP  
SPECIES: RAT/FISCHER-344

INDIVIDUAL ANIMAL DATA REPORT  
STUDY NUMBER: GLP83009

PRINTED: 21-NOV-89  
PAGE: 402

STUDY START DATE: 23-JAN-84

STUDY TYPE: CHRONIC/2 YR CARCINOGENIC

ANIMAL NUMBER: 194/PRETEST-194 SEX: MALE DOSE GROUP: 3 SACRIFICE STATUS: FINAL SACRIFICE  
DATE OF DEATH: 05-FEB-86 STUDY DAY OF DEATH: 745 STUDY WEEK OF DEATH: 107 TERMINAL BODY WEIGHT: 425.00 (GMS)

TISSUE / HISTOPATHOLOGIC FINDINGS << MICROSCOPIC TISSUE OBSERVATIONS >>  
DISTRIBUTION (SEVERITY) / SPECIAL COMMENTS

MAMMARY GLANDS ..... NOT SPECIFIED (PRESENT)  
-DILATATION (ECTASIA) OF DUCTS AND DUCTULES

NOSE/TURBINATES ..... INFILTRATE INVOLVES NASO-LACRIMAL DUCTS.  
-MIXED INFLAMMATORY CELL INFILTRATION, NASAL CAVITY, SINUSES, ..... NOT SPECIFIED(MILD)  
TURBINATES, NASO-LACRIMAL DUCTS

ADRENAL ..... DIFFUSE(TRACE)  
-LIPIDOSIS

PITUITARY GLAND ..... (PRESENT)  
-8- ADENOMA

EYES & OPTIC N. .... THERE IS NO HISTOLGIC EVIDENCE OF CONJUNCTIVITIS WHICH WAS NOTED  
GROSSLY. THE GROSS APPEARANCE MAY HAVE BEEN DUE TO  
HYPERSECRETION OF THE HARDERIAN GLAND WHICH CONTAINS AN  
ABUNDANCE OF SECRETORY PRODUCT IN THIS ANIMAL.

**Appendix J (cont.): PATHOLOGY INDIVIDUAL ANIMAL DATA**

LETTERMAN ARMY INSTITUTE OF RESEARCH  
 DIV OF RES SUPP, PATH SERV GP  
 SPECIES: RAT/FISCHER-344  
 INDIVIDUAL ANIMAL DATA REPORT  
 STUDY NUMBER: GLP83009  
 STUDY START DATE: 23-JAN-84  
 PRINTED: 21-NOV-89  
 PAGE: 403  
 STUDY TYPE: CHRONIC/2 YR CARCINOGENIC

ANIMAL NUMBER: 195/PRETEST# 195 SEX: MALE DOSE GROUP: 3 SACRIFICE STATUS: FINAL SACRIFICE  
 DATE OF DEATH: 05-FEB-86 STUDY DAY OF DEATH: 745 STUDY WEEK OF DEATH: 107 TERMINAL BODY WEIGHT: 412.00 (GMS)

<< GROSS ORGAN OBSERVATIONS >>  
 SEVERITY GROSS FREE-TEXT COMMENTS  
 KEYWORDS / PHRASES  
 GROWTH(S) / MASS(ES) PRESENT RIGHT, MULTIPLE VARIABLY SIZED, YELLOW

<< MICROSCOPIC TISSUE OBSERVATIONS >>  
 DISTRIBUTION (SEVERITY) / SPECIAL COMMENTS

PARATHYROID ..... TISSUE IS MISSING

SALIVARY GLAND ..... THE ATROPHY PRIMARILY INVOLVES ONE LOBULE OF THE PAROTID GLAND. THE ACINAR TISSUE IN THIS LOBULE IS ALMOST COMPLETELY REPLACED BY FIBROUS CONNECTIVE TISSUE. Milder atrophic changes are present in several adjacent lobules. The submandibular and sublingual glands are normal. NOT SPECIFIED(MILD)

-ATROPHY AND LOSS OF ACINAR TISSUE ..... NOT SPECIFIED(TRACE)

HEART ..... NOT SPECIFIED(TRACE)

-CARDIOMYOPATHY ..... NOT SPECIFIED(TRACE)

LIVER ..... NOT SPECIFIED(MILD)

-BILE DUCTULE EPITHELIAL HYPERPLASIA AND/OR CHOLANGIOFIBROSIS ..... NOT SPECIFIED(MODERATE)

KIDNEY ..... NOT SPECIFIED(MODERATE)

-PROGRESSIVE RENAL DISEASE ..... NOT SPECIFIED(MODERATE)

TESTES ..... THE RIGHT TESTIS CONTAINS THE INTERSTITIAL CELL ADENOMA. THERE ARE MULTIFOCAL AREAS OF INTERSTITIAL CELL HYPERPLASIA IN THE LEFT TESTIS. MULTI-FOCAL(TRACE) (PRESENT)

-INTERSTITIAL CELL HYPERPLASIA

-B- INTERSTITIAL CELL ADENOMA

MAMMARY GLANDS ..... NOT SPECIFIED(TRACE)

-HYPERPLASIA AND/OR HYPERTROPHY OF THE ACINAR TISSUE

-DILATATION (ECTASIA) OF DUCTS AND DUCTULES ..... NOT SPECIFIED (PRESENT)

Appendix J (cont.): PATHOLOGY INDIVIDUAL ANIMAL DATA

LETTERMAN ARMY INSTITUTE OF RESEARCH  
DIV OF RES SUPP. PATH SERV GP  
SPECIES: RAT/FISCHER-344

INDIVIDUAL ANIMAL DATA REPORT  
STUDY NUMBER: GLP83009  
STUDY START DATE: 23-JAN-84

PRINTED: 21-NOV-89  
PAGE: 404

STUDY TYPE: CHRONIC/2 YR CARCINOGENIC

ANIMAL NUMBER: 195/PRETEST= 195 SEX: MALE DOSE GROUP: 3 SACRIFICE STATUS: FINAL SACRIFICE  
DATE OF DEATH: 05-FEB-86 STUDY DAY OF DEATH: 745 STUDY WEEK OF DEATH: 107 TERMINAL BODY WEIGHT: 412.00 (GMS)

TISSUE / HISTOPATHOLOGIC FINDINGS << MICROSCOPIC TISSUE OBSERVATIONS >>  
DISTRIBUTION (SEVERITY) / SPECIAL COMMENTS

NOSE/TURBINATES ..... INFILTRATE: BILATERAL ADJACENT NASO-LACRIMAL DUCTS.  
-MIXED INFLAMMATORY CELL INFILTRATION, NASAL CAVITY, SINUSES, NOT SPECIFIED(TRACE)  
TURBINATES, NASO-LACRIMAL DUCTS

ADRENAL ..... NOT SPECIFIED(MILD)  
-FOCUS OF CELLULAR ALTERATION, VACUOLATED

PITUITARY GLAND ..... (PRESENT)  
-8- ADENOMA

EYES & OPTIC N. .... NOT SPECIFIED(TRACE)  
-RETINAL ATROPHY AND/OR DEGENERATION, UNILATERAL OR BILATERAL NOT SPECIFIED (PRESENT)  
-METAPLASTIC BONE FORMATION AND/OR MINERALIZATION, SCLERA

## Appendix J (cont.): PATHOLOGY INDIVIDUAL ANIMAL DATA

LETTERMAN ARMY INSTITUTE OF RESEARCH  
 DIV OF RES SUPP, PATH SERV GP  
 SPECIES: RAT/FISCHER-344

INDIVIDUAL ANIMAL DATA REPORT  
 STUDY NUMBER: GLP83009  
 STUDY START DATE: 23-JAN-84

PRINTED: 21-NOV-89  
 PAGE: 405  
 STUDY TYPE: CHRONIC/2 YR CARCINOGENIC

ANIMAL NUMBER: 196/PRETEST= 196 SEX: MALE DOSE GROUP: 3 SACRIFICE STATUS: FINAL SACRIFICE  
 DATE OF DEATH: 05-FEB-86 STUDY DAY OF DEATH: 745 STUDY WEEK OF DEATH: 107 TERMINAL BODY WEIGHT: 430.00 (GMS)

<< GROSS ORGAN OBSERVATIONS >>  
 SEVERITY GROSS FREE-TEXT COMMENTS  
 GROWTH(S) / MASS(ES) PRESENT BILATERAL, MULTIPLE VARIABLY SIZED, YELLOW/BLACK

<< MICROSCOPIC TISSUE OBSERVATIONS >>  
 DISTRIBUTION (SEVERITY) / SPECIAL COMMENTS

TISSUE / HISTOPATHOLOGIC FINDINGS

HEART  
 -CARDIOMYOPATHY NOT SPECIFIED(TRACE)

LIVER  
 -BILE DUCTULE EPITHELIAL HYPERPLASIA AND/OR CHOLANGIOFIBROSIS NOT SPECIFIED(MILD)  
 -HEPATOCTYIC VACUOLIZATION MULTI-FOCAL(TRACE)  
 -CYSTIC DEGENERATION NOT SPECIFIED (PRESENT)  
 -HEPATOCTYIC COALESCING MICROVESICULAR (FATTY) CHANGE LEADING TO NECROSIS AND MINERALIZATION NOT SPECIFIED(TRACE)

KIDNEY  
 -PROGRESSIVE RENAL DISEASE NOT SPECIFIED(MODERATE)

PROSTATE  
 -CHRONIC PROSTATITIS NOT SPECIFIED(TRACE)  
 -BENIGN HYPERPLASIA NOT SPECIFIED(TRACE)

SEMINAL VESICLE  
 -GENERALIZED ATROPHY NOT SPECIFIED (PRESENT)

TESTES  
 -B- INTERSTITIAL CELL ADENOMA (PRESENT)

PANCREAS  
 -ACINAR (EXOCRINE) ATROPHY MULTI-FOCAL(MODERATE)

MAMMARY GLANDS

Appendix J (cont.): PATHOLOGY INDIVIDUAL ANIMAL DATA

LETTERMAN ARMY INSTITUTE OF RESEARCH  
DIV OF RES SUPP, PATH SERV GP  
SPECIES: RAT/FISCHER-344

INDIVIDUAL ANIMAL DATA REPORT  
STUDY NUMBER: GLP83009  
STUDY START DATE: 23-JAN-84

PRINTED: 21-NOV-89  
PAGE: 406

STUDY TYPE: CHRONIC/2 YR CARCINOGENIC

ANIMAL NUMBER: 196/PRETEST-196 SEX: MALE DOSE GROUP: 3 SACRIFICE STATUS: FINAL SACRIFICE  
DATE OF DEATH: 05-FEB-86 STUDY DAY OF DEATH: 745 STUDY WEEK OF DEATH: 107 TERMINAL BODY WEIGHT: 430.00 (GMS)

<< MICROSCOPIC TISSUE OBSERVATIONS >>  
DISTRIBUTION (SEVERITY) / SPECIAL COMMENTS

MAMMARY GLANDS ..... NOT SPECIFIED (MILD)  
-HYPERPLASIA AND/OR HYPERTROPHY OF THE ACINAR TISSUE

PITUITARY GLAND ..... (PRESENT)  
-B- ADENOMA

EYES & OPTIC N. .... NOT SPECIFIED (PRESENT)  
-METAPLASTIC BONE FORMATION AND/OR MINERALIZATION, SCLERA



Appendix J (cont.): PATHOLOGY INDIVIDUAL ANIMAL DATA

LETTERMAN ARMY INSTITUTE OF RESEARCH  
DIV OF RES SUPP, PATH SERV GP  
SPECIES: RAT/FISCHER-344  
INDIVIDUAL ANIMAL DATA REPORT  
STUDY NUMBER: GLP83009  
STUDY START DATE: 23-JAN-84  
STUDY TYPE: CHRONIC/2 YR CARCINOGENIC  
PRINTED: 21-NOV-89  
PAGE: 407

ANIMAL NUMBER: 197/PRETEST#  
DATE OF DEATH: 05-FEB-86  
SEX: MALE  
DOSE GROUP: 3  
SACRIFICE STATUS: FINAL SACRIFICE  
STUDY WEEK OF DEATH: 107  
TERMINAL BODY WEIGHT: 364.00 (GMS)

ORGAN NAME: << GROSS ORGAN OBSERVATIONS >>  
KEYWORDS / PHRASES: SEVERITY GROSS FREE-TEXT COMMENTS  
ATROPHIC / SMALL, UNILATERALLY PRESENT LEFT, 1.5 X 1CM  
GROWTH(S) / MASS(ES) PRESENT RIGHT, MULTIPLE VARIABLY SIZED, YELLOW

TISSUE / HISTOPATHOLOGIC FINDINGS: << MICROSCOPIC TISSUE OBSERVATIONS >>  
DISTRIBUTION (SEVERITY) / SPECIAL COMMENTS

HEART: -CARDIOMYOPATHY NOT SPECIFIED(TRACE)  
-MEDIAL HYPERTROPHY OF MUSCULAR ARTERIES NOT SPECIFIED(TRACE)

LUNGS: -MINERALIZATION OF PULMONARY ARTERIES NOT SPECIFIED(TRACE)

LYMPH NODES: -REACTIVE HYPERPLASIA NOT SPECIFIED (PRESENT)

LIVER: -BILE DUCTULE EPITHELIAL HYPERPLASIA AND/OR CHOLANGIOFIBROSIS NOT SPECIFIED(MODERATE)  
-HEPATITIS NOT SPECIFIED(TRACE)  
-HEPATOCTYIC VACUOLIZATION MULTI-FOCAL(TRACE)

KIDNEY: -PROGRESSIVE RENAL DISEASE NOT SPECIFIED(MILD)

PROSTATE: -CHRONIC PROSTATITIS NOT SPECIFIED(MILD)  
-BENIGN HYPERPLASIA NOT SPECIFIED(TRACE)

TESTES: -TUBULAR ATROPHY NOT SPECIFIED(MARKED)  
-B- INTERSTITIAL CELL ADENOMA (PRESENT)

Appendix J (cont.): PATHOLOGY INDIVIDUAL ANIMAL DATA

LETTERMAN ARMY INSTITUTE OF RESEARCH  
DIV OF RES SUPP, PATH SERV GP  
SPECIES: RAY/FISCHER-344

PRINTED: 21-NOV-89  
PAGE: 408

INDIVIDUAL ANIMAL DATA REPORT  
STUDY NUMBER: GLP83009  
STUDY START DATE: 23-JAN-84

ANIMAL NUMBER: 197/PRETEST-197 SEX: MALE DOSE GROUP: 3 SACRIFICE STATUS: FINAL SACRIFICE  
DATE OF DEATH: 05-FEB-86 STUDY DAY OF DEATH: 745 STUDY WEEK OF DEATH: 107 TERMINAL BODY WEIGHT: 364.00 (GMS)  
STUDY TYPE: CHRONIC/2 YR CARCINOGENIC

TISSUE / HISTOPATHOLOGIC FINDINGS << MICROSCOPIC TISSUE OBSERVATIONS >>  
DISTRIBUTION (SEVERITY) / SPECIAL COMMENTS

NOSE/TURBINATES ..... INFILTRATE ADJACENT NASO-LACRIMAL DUCTS.  
-MIXED INFLAMMATORY CELL INFILTRATION, NASAL CAVITY, SINUSES, NOT SPECIFIED(TRACE)  
TURBINATES, NASO-LACRIMAL DUCTS

PITUITARY GLAND ..... (PRESENT)  
-B- ADENOMA

EYES & OPTIC N. .... NOT SPECIFIED (PRESENT)  
-METAPLASTIC BONE FORMATION AND/OR MINERALIZATION, SCLERA

Appendix J (cont.): PATHOLOGY INDIVIDUAL ANIMAL DATA

LETTERMAN ARMY INSTITUTE OF RESEARCH  
 DIV OF RES SUPP, PATH SERV GP  
 SPECIES: RAT/FISCHER-344  
 INDIVIDUAL ANIMAL DATA REPORT  
 STUDY NUMBER: GLP83009  
 STUDY START DATE: 23-JAN-84  
 STUDY TYPE: CHRONIC/2 YR CARCINOGENIC  
 ANIMAL NUMBER: 198/PRETEST= 198 SEX: MALE DOSE GROUP: 3 SACRIFICE STATUS: SACRIFICED MORIBUND  
 DATE OF DEATH: 16-JAN-86 STUDY DAY OF DEATH: 725 STUDY WEEK OF DEATH: 104 TERMINAL BODY WEIGHT: 406.00 (GMS)  
 << GROSS ORGAN OBSERVATIONS >>  
 SEVERITY GROSS FREE-TEXT COMMENTS  
 SPLEEN ENLARGED (SPLENOMEGALY) MARKED 11 X 3.2 X 1.5CM  
 TESTES ATROPHIC / SMALL, UNILATERALLY PRESENT LEFT, 1 X .9CM  
 TESTES ENLARGED PRESENT RIGHT, 4 X 2CM  
 TESTES GROWTH(S) / MASS(ES) PRESENT BILATERAL, MULTIPLE VARIABLY SIZED, RED/WHITE/BLACK  
 ADRENAL ENLARGED, UNILATERALLY PRESENT LEFT, 1 X .4CM  
 LUNGS DISCOLORATION PRESENT FOCAL, BLACK, .1CM DIAMETER, RIGHT LOBE  
 LIVER MODULE(S) PRESENT FOCAL, RAISED, YELLOW, .2-.3CM DIAMETER, NUMBERING 6-7

TISSUE / HISTOPATHOLOGIC FINDINGS << MICROSCOPIC TISSUE OBSERVATIONS >>  
 DISTRIBUTION (SEVERITY) / SPECIAL COMMENTS

HEART ..... NOT SPECIFIED(MILD)  
 -CARDIOMYOPATHY .....  
 LUNGS ..... FOCAL(TRACE)  
 -PNEUMONIA, INTERSTITIAL, CHRONIC ..... MULTI-FOCAL (PRESENT)  
 -PERIVASCULAR LYMPHOID AGGREGATIONS (CUFFING) (PRESENT)  
 -M- LARGE GRANULAR LYMPHOCYTE LEUKEMIA, METASTATIC  
 THYMUS ..... (PRESENT)  
 -M- LARGE GRANULAR LYMPHOCYTE LEUKEMIA, METASTATIC (PRESENT)  
 SPLEEN ..... (PRESENT)  
 -M- LARGE GRANULAR LYMPHOCYTE LEUKEMIA, METASTATIC (PRESENT)  
 LYMPH NODES ..... (PRESENT)  
 -M- LARGE GRANULAR LYMPHOCYTE LEUKEMIA, METASTATIC (PRESENT)  
 LIVER ..... NOT SPECIFIED(MILD)  
 -BILE DUCTULE EPITHELIAL HYPERPLASIA AND/OR CHOLANGIOFIBROSIS NOT SPECIFIED(TRACE)  
 -BENIGN HYPERPLASTIC NODULE(S)

**Appendix J (cont.): PATHOLOGY INDIVIDUAL ANIMAL DATA**

LETTERMAN ARMY INSTITUTE OF RESEARCH  
 DIV OF RES SUPP. PATH SERV GP  
 SPECIES: RAT/FISCHER-344

INDIVIDUAL ANIMAL DATA REPORT  
 STUDY NUMBER: GLP63009

STUDY START DATE: 23-JAN-84

198/PRETEST= 198 SEX: MALE DOSE GROUP: 3 SACRIFICE STATUS: SACRIFICED MORIBUND  
 DATE OF DEATH: 16-JAN-86 STUDY DAY OF DEATH: 725 STUDY WEEK OF DEATH: 104 TERMINAL BODY WEIGHT: 406.00 (GMS)

<< M I C R O S C O P I C T I S S U E O B S E R V A T I O N S >>  
 TISSUE / HISTOPATHOLOGIC FINDINGS DISTRIBUTION (SEVERITY) / SPECIAL COMMENTS

PRINTED: 21-NOV-89  
 PAGE: 410  
 STUDY TYPE: CHRONIC/2 YR CARCINOGENIC

- LIVER ..... (PRESENT)
- N- LARGE GRANULAR LYMPHOCYTE LEUKEMIA, METASTATIC
- KIDNEY ..... NOT SPECIFIED(MILD)
- PROGRESSIVE RENAL DISEASE
- PROSTATE ..... NOT SPECIFIED(MODERATE)
- BENIGN HYPERPLASIA
- SEMINAL VESICLE ..... NOT SPECIFIED (PRESENT)
- GENERALIZED ATROPHY
- TESTES ..... (PRESENT)
- B- INTERSTITIAL CELL ADENOMA
- ILEUM ..... (PRESENT)
- N- LARGE GRANULAR LYMPHOCYTE LEUKEMIA, METASTATIC
- BONE, STERNUM ..... NOT SPECIFIED (PRESENT)
- HYPERPLASIA, MYELOID
- BONE, FEMUR ..... NOT SPECIFIED (PRESENT)
- HYPERPLASIA MYELOID
- BONE VERT ..... NOT SPECIFIED (PRESENT)
- HYPERPLASIA, MYELOID
- ADRENAL ..... ONLY ONE ADRENAL AVAILABLE FOR EXAMINATION
- PITUITARY GLAND ..... TISSUE IS MISSING
- EYES & OPTIC N. .... NOT SPECIFIED (PRESENT)
- METAPLASTIC BONE FORMATION AND/OR MINERALIZATION, SCLERA
- WHOLE BODY .....

Appendix J (cont.): PATHOLOGY INDIVIDUAL ANIMAL DATA

LETTERMAN ARMY INSTITUTE OF RESEARCH  
 DIV OF RES SUPP, PATH SERV GP  
 SPECIES: RAT/FISCHER-344

INDIVIDUAL ANIMAL DATA REPORT  
 STUDY NUMBER: GLP83009  
 STUDY START DATE: 23-JAN-84

198/PRETEST= 198 SEX: MALE DOSE GROUP: 3 SACRIFICE STATUS: SACRIFICED MORIBUND  
 DATE OF DEATH: 16-JAN-86 STUDY DAY OF DEATH: 725 STUDY WEEK OF DEATH: 104 TERMINAL BODY WEIGHT: 406.00 (GMS)

<< MICROSCOPIC TISSUE OBSERVATIONS >>  
 TISSUE / HISTOPATHOLOGIC FINDINGS DISTRIBUTION (SEVERITY) / SPECIAL COMMENTS

PRINTED: 21-NOV-89  
PAGE: 411

STUDY TYPE: CHRONIC/2 YR CARCINOGENIC

WHOLE BODY ..... (PRESENT)  
-M- LARGE GRANULAR LYMPHOCYTTIC LEUKEMIA

Appendix J (cont.): PATHOLOGY INDIVIDUAL ANIMAL DATA

LETTERMAN ARMY INSTITUTE OF RESEARCH  
 DIV OF RES SUPP, PATH SERV GP  
 SPECIES: RAT/FISCHER-344  
 INDIVIDUAL ANIMAL DATA REPORT  
 STUDY NUMBER: GLP83009  
 STUDY START DATE: 23-JAN-84  
 PRINTED: 21-NOV-89  
 PAGE: 412  
 STUDY TYPE: CHRONIC/2 YR CARCINOGENIC

ANIMAL NUMBER: 199/PRETEST\*  
 DATE OF DEATH: 24-DEC-85  
 DOSE GROUP: 3  
 STUDY WEEK OF DEATH: 101  
 SACRIFICE STATUS: SACRIFICED MORIBUND  
 TERMINAL BODY WEIGHT: 412.00 (GMS)

ORGAN NAME: << GROSS ORGAN OBSERVATIONS >>  
 KEYWORDS / PHRASES SEVERITY GROSS FREE-TEXT COMMENTS  
 TESTES ATROPHIC / SMALL, UNILATERALLY PRESENT LEFT  
 TESTES DISCOLORATION PRESENT FOCAL, YELLOW .3 X .5CM  
 KIDNEY DISCOLORATION PRESENT CORTEX, MULTIPLE, MINUTE, WHITE  
 PITUITARY GLAND ENLARGED TRACE

TISSUE / HISTOPATHOLOGIC FINDINGS << MICROSCOPIC TISSUE OBSERVATIONS >>  
 DISTRIBUTION (SEVERITY) / SPECIAL COMMENTS

THYROID GLANDS  
 -PARA-FOLLICULAR CELL HYPERPLASIA (\*C<sup>+</sup> CELL, LIGHT CELL) NOT SPECIFIED(TRACE)

HEART  
 -CARDIOMYOPATHY NOT SPECIFIED(TRACE)  
 -MEDIAL HYPERTROPHY OF MUSCULAR ARTERIES MULTI-FOCAL(MILD)

LUNGS  
 -MINERALIZATION OF PULMONARY ARTERIES NOT SPECIFIED(TRACE)

LIVER  
 -BILE DUCTULE EPITHELIAL HYPERPLASIA AND/OR CHOLANGIOFIBROSIS NOT SPECIFIED(MILD)  
 -CYSTIC DEGENERATION NOT SPECIFIED (PRESENT)

KIDNEY  
 -PROGRESSIVE RENAL DISEASE NOT SPECIFIED(MODERATE)

PROSTATE  
 -CHRONIC PROSTATITIS NOT SPECIFIED(MILD)  
 -BENIGN HYPERPLASIA NOT SPECIFIED(MILD)

SEMINAL VESICLE  
 -GENERALIZED ATROPHY NOT SPECIFIED (PRESENT)

TESTES

**Appendix J (cont.): PATHOLOGY INDIVIDUAL ANIMAL DATA**

LETTERMAN ARMY INSTITUTE OF RESEARCH  
 DIV OF RES SUPP, PATH SERV GP  
 SPECIES: RAT/FISCHER-344  
 INDIVIDUAL ANIMAL DATA REPORT  
 STUDY NUMBER: GLP83009  
 STUDY START DATE: 23-JAN-84  
 PRINTED: 21-NOV-89  
 PAGE: 413  
 STUDY TYPE: CHRONIC/2 YR CARCINOGENIC

ANIMAL NUMBER: 199/PRETEST= 199 SEX: MALE DOSE GROUP: 3 SACRIFICE STATUS: SACRIFICED MORIBUND  
 DATE OF DEATH: 24-DEC-85 STUDY DAY OF DEATH: 702 STUDY WEEK OF DEATH: 101 TERMINAL BODY WEIGHT: 412.00 (GMS)

<< MICROSCOPIC TISSUE OBSERVATIONS >>  
 TISSUE / HISTOPATHOLOGIC FINDINGS DISTRIBUTION (SEVERITY) / SPECIAL COMMENTS

TESTES ..... (PRESENT)  
 -B- INTERSTITIAL CELL ADENOMA ..... NOT SPECIFIED (PRESENT)  
 -PERIARTERITIS NODOSA .....  
 PANCREAS ..... NOT SPECIFIED (PRESENT)  
 -PERIARTERITIS NODOSA .....  
 MAMMARY GLANDS .....  
 -HYPERPLASIA AND/OR HYPERTROPHY OF THE ACINAR TISSUE ..... NOT SPECIFIED (TRACE)  
 -DILATATION (ECTASIA) OF DUCTS AND DUCTULES ..... NOT SPECIFIED (PRESENT)

NOSE/TURBINATES ..... INFILTRATE ADJACENT NASO-LACRIMAL DUCT.  
 -MIXED INFLAMMATORY CELL INFILTRATION, NASAL CAVITY, SINUSES, ..... NOT SPECIFIED (TRACE)  
 TURBINATES, NASO-LACRIMAL DUCTS

ADRENAL ..... NOT SPECIFIED (MILD)  
 -LIPIDOSIS ..... (PRESENT)  
 -B- PHEOCHROMOCYTOMA ..... (PRESENT)

PITUITARY GLAND .....  
 -B- ADENOMA ..... (PRESENT)

EYES & OPTIC N. .... NOT SPECIFIED (PRESENT)  
 -METAPLASTIC BONE FORMATION AND/OR MINERALIZATION, SCLERA

Appendix J (cont.): PATHOLOGY INDIVIDUAL ANIMAL DATA

LETTERMAN ARMY INSTITUTE OF RESEARCH
INDIVIDUAL ANIMAL DATA REPORT
DIV OF RES SUPP, PATM SERV GP
SPECIES: RAT/FISCHER-344
STUDY NUMBER: GLP83009
STUDY START DATE: 23-JAN-84
STUDY TYPE: CHRONIC/2 YR CARCINOGENIC
ANIMAL NUMBER: 200/PRETEST=
DOSE GROUP: 3
SACRIFICE STATUS: FINAL SACRIFICE
DATE OF DEATH: 05-FEB-86
STUDY DAY OF DEATH: 745
STUDY WEEK OF DEATH: 107
TERMINAL BODY WEIGHT: 360.00 (GMS)

PRINTED: 21-NOV-89
PAGE: 414

<< GROSS ORGAN OBSERVATIONS >>
SEVERITY GROSS FREE-TEXT COMMENTS
KEYWORDS / PHRASES
GROWTH(S) / MASS(ES)
PRESENT LEFT, MULTIPLE VARIABLY SIZED, YELLOW
PITUITARY GLAND ENLARGED
PRESENT DARK RED, .5CM DIAMETER
MAMMARY GLAND PROMINENT
PRESENT AXILLARY AND INGUINAL REGIONS, BILATERAL

TISSUE / HISTOPATHOLOGIC FINDINGS
<< MICROSCOPIC TISSUE OBSERVATIONS >>
DISTRIBUTION (SEVERITY) / SPECIAL COMMENTS

- HEART
-CARDIOMYOPATHY
NOT SPECIFIED(MODERATE)
LIVER
-BILE DUCTULE EPITHELIAL HYPERPLASIA AND/OR CHOLANGIOFIBROSIS
NOT SPECIFIED(MODERATE)
-HEPATITIS
NOT SPECIFIED(TRACE)
-FOCUS OF CELLULAR ALTERATION - BASOPHILIC
NOT SPECIFIED(MILD)
KIDNEY
-PROGRESSIVE RENAL DISEASE
NOT SPECIFIED(MODERATE)
PROSTATE
-BENIGN HYPERPLASIA
NOT SPECIFIED(TRACE)
TESTES
-B- INTERSTITIAL CELL ADENOMA
(PRESENT)
PANCREAS
-CHRONIC INFLAMMATION
FOCAL(TRACE)
MAMMARY GLANDS
-HYPERPLASIA AND/OR HYPERTROPHY OF THE ACINAR TISSUE
NOT SPECIFIED(MILD)
NOSE/TURBINATES
INFILTRATE: BILATERAL ADJACENT NASO-LACRIMAL DUCTS.



Appendix J (cont.): PATHOLOGY INDIVIDUAL ANIMAL DATA

LETTERMAN ARMY INSTITUTE OF RESEARCH  
DIV OF RES SUPP, PATH SERV GP  
SPECIES: RAT/FISCHER-344

INDIVIDUAL ANIMAL DATA REPORT  
STUDY NUMBER: GLP83009  
STUDY START DATE: 23-JAN-84

PRINTED: 21-NOV-89  
PAGE: 415

STUDY TYPE: CHRONIC/2 YR CARCINOGENIC

ANIMAL NUMBER: 200/PRETEST= 200 SEX: MALE DOSE GROUP: 3 SACRIFICE STATUS: FINAL SACRIFICE  
DATE OF DEATH: 05-FEB-86 STUDY DAY OF DEATH: 745 STUDY WEEK OF DEATH: 107 TERMINAL BODY WEIGHT: 368.00 (GMS)

<< MICROSCOPIC TISSUE OBSERVATIONS >>  
TISSUE / HISTOPATHOLOGIC FINDINGS DISTRIBUTION (SEVERITY) / SPECIAL COMMENTS

NOSE/TURBINATES .....  
-MIXED INFLAMMATORY CELL INFILTRATION, NASAL CAVITY, SINUSES, ..... NOT SPECIFIED(MILD)  
TURBINATES, NASO-LACRIMAL DUCTS

ADRENAL .....  
-FOCUS OF CELLULAR ALTERATION, VACUOLATED ..... NOT SPECIFIED(MILD)

PITUITARY GLAND .....  
-B- ADENOMA ..... (PRESENT)

Appendix J (cont.): PATHOLOGY INDIVIDUAL ANIMAL DATA

LETTERMAN ARMY INSTITUTE OF RESEARCH
DIV OF RES SUPP, PATH SERV GP
SPECIES: RAT/FISCHER-344
INDIVIDUAL ANIMAL DATA REPORT
STUDY NUMBER: GLP83009
PRINTED: 21-NOV-89
PAGE: 416
STUDY START DATE: 23-JAN-84
STUDY TYPE: CHRONIC/2 YR CARCINOGENIC
ANIMAL NUMBER: 201/PRETEST=
DOSE GROUP: 3
SACRIFICE STATUS: FINAL SACRIFICE
DATE OF DEATH: 05-FEB-86
STUDY DAY OF DEATH: 745
STUDY WEEK OF DEATH: 107
TERMINAL BODY WEIGHT: 315.00 (GMS)
ORGAN NAME
GROSS ORGAN OBSERVATIONS
KEYWORDS / PHRASES
SEVERITY GROSS FREE-TEXT COMMENTS
TESTES
GROWTH(S) / MASS(ES)
PRESENT BILATERAL, MULTIPLE VARIABLELY SIZED, YELLOW/BLACK

TISSUE / HISTOPATHOLOGIC FINDINGS
MICROSCOPIC TISSUE OBSERVATIONS
DISTRIBUTION (SEVERITY) / SPECIAL COMMENTS

HEART
-CARDIOMYOPATHY
NOT SPECIFIED(MILD)
LYMPH NODES
-RED BLOOD CELLS, HEMOSIDERIN AND/OR ERYTHROPHAGOCYTOSIS WITHIN
RBC'S AND HEMOSIDERIN PRESENT IN MEDIASTINAL NODES ONLY.
MEDULLARY SINUSES
NOT SPECIFIED (PRESENT)
LIVER
-BILE DUCTULE EPITHELIAL HYPERPLASIA AND/OR CHOLANGIOFIBROSIS
NOT SPECIFIED(MILD)
-FOCUS OF CELLULAR ALTERATION - CLEAR CELLS
NOT SPECIFIED(TRACE)
-FOCUS OF CELLULAR ALTERATION - EOSINOPHILIC CELLS
NOT SPECIFIED(TRACE)
KIDNEY
-PROGRESSIVE RENAL DISEASE
NOT SPECIFIED(MARKED)
PROSTATE
-CHRONIC PROSTATITIS
NOT SPECIFIED(MILD)
-BENIGN HYPERPLASIA
NOT SPECIFIED(TRACE)
-MICROCALCULI, PROSTATIC URETHRA
NOT SPECIFIED (PRESENT)
SEMINAL VESICLE
-GENERALIZED ATROPHY
NOT SPECIFIED (PRESENT)
TESTES
-B INTERSTITIAL CELL ADENOMA
(PRESENT)
PANCREAS

Appendix J (cont.): PATHOLOGY INDIVIDUAL ANIMAL DATA

LETTERMAN ARMY INSTITUTE OF RESEARCH  
 DIV OF RES SUPP, PATH SERV GP  
 SPECIES: RAT/FISCHER-344

INDIVIDUAL ANIMAL DATA REPORT  
 STUDY NUMBER: GLP83009

STUDY START DATE: 23-JAN-84

STUDY TYPE: CHRONIC/2 YR CARCINOGENIC

ANIMAL NUMBER: 201/PRETEST= 201 SEX: MALE DOSE GROUP: 3 SACRIFICE STATUS: FINAL SACRIFICE  
 DATE OF DEATH: 05-FEB-86 STUDY DAY OF DEATH: 745 STUDY WEEK OF DEATH: 107 TERMINAL BODY WEIGHT: 315.00 (GMS)

<< M I C R O S C O P I C T I S S U E O B S E R V A T I O N S >>  
 TISSUE / HISTOPATHOLOGIC FINDINGS

PRINTED: 21-NOV-89  
PAGE: 417

- PANCREAS ..... NOT SPECIFIED(MILD)
- ACINAR (EXOCRINE) ATROPHY
- NOSE/TURBINATES ..... INFILTRATE: BILATERAL ADJACENT NASO-LACRIMAL DUCTS.
- MIXED INFLAMMATORY CELL INFILTRATION, NASAL CAVITY, SINUSES, ..... NOT SPECIFIED(MILD)
- TURBINATES, NASO-LACRIMAL DUCTS
- ADRENAL ..... NOT SPECIFIED(TRACE)
- FOCUS OF CELLULAR ALTERATION, VACUOLATED ..... NOT SPECIFIED (PRESENT)
- CORTICAL MODULAR HYPERPLASIA (PRESENT)
- B - PHECCHROMOCYTOMA
- EYES & OPTIC N. .... NOT SPECIFIED (PRESENT)
- METAPLASTIC BONE FORMATION AND/OR MINERALIZATION, SCLERA

Appendix J (cont.): PATHOLOGY INDIVIDUAL ANIMAL DATA

LETTERMAN ARMY INSTITUTE OF RESEARCH  
DIV OF RES SUPP, PATH SERV GP  
SPECIES: RAT/FISCHER-344

INDIVIDUAL ANIMAL DATA REPORT  
STUDY NUMBER: GLP83009

PRINTED: 21-NOV-89  
PAGE: 418

STUDY START DATE: 23-JAN-84  
STUDY TYPE: CHRONIC/2 YR CARCINOGENIC

ANIMAL NUMBER: 202/PRETEST- 202 SEX: MALE DOSE GROUP: 3 SACRIFICE STATUS: FINAL SACRIFICE  
DATE OF DEATH: 05-FEB-86 STUDY DAY OF DEATH: 745 STUDY WEEK OF DEATH: 107 TERMINAL BODY WEIGHT: 353.00 (GMS)

ORGAN NAME << GROSS ORGAN OBSERVATIONS >>  
SEVERITY GROSS FREE-TEXT COMMENTS

LIVER GRANULAR SURFACE PRESENT  
LIVER PROMINENT LOBULAR MARKINGS PRESENT  
SPLEEN ENLARGED (SPLENOHEGALY) MODERATE 6 X 1.5CM  
SPLEEN STRICTURE PRESENT  
TESTES GROWTH(S) / MASS(ES) PRESENT BILATERAL, MULTIPLE VARIABLY SIZED, YELLOW/BLACK

TISSUE / HISTOPATHOLOGIC FINDINGS << MICROSCOPIC TISSUE OBSERVATIONS >>  
DISTRIBUTION (SEVERITY) / SPECIAL COMMENTS

THYROID GLANDS  
-PARA-FOLLICULAR CELL HYPERPLASIA ("C" CELL, LIGHT CELL) FOCAL(TRACE)

HEART  
-CARDIOMYOPATHY  
-MEDIAL HYPERTROPHY OF MUSCULAR ARTERIES NOT SPECIFIED(MILD)  
NOT SPECIFIED(TRACE)

LUNGS  
-W- LARGE GRANULAR LYMPHOCYTE LEUKEMIA, METASTATIC (PRESENT)

SPLEEN  
-INFARCTION, CHRONIC THE STRUCTURE OBSERVED GROSSLY WAS DUE TO CHRONIC INFARCTION  
AND SUBSEQUENT FIBROSIS AND SMOOTH MUSCLE HYPERTROPHY. THESE  
CHANGES ARE PROBABLY SECONDARY TO THE LGLL.  
-W- LARGE GRANULAR LYMPHOCYTE LEUKEMIA, METASTATIC NOT SPECIFIED(MODERATE)  
-SMOOTH MUSCLE HYPERTROPHY, CAPSULE AND TRABECULAE NOT SPECIFIED (PRESENT)

LIVER  
-BILE DUCTULE EPITHELIAL HYPERPLASIA AND/OR CHOLANGIOFIBROSIS NOT SPECIFIED(MILD)  
-CYSTIC DEGENERATION NOT SPECIFIED (PRESENT)  
-HEPATOCTYTIC DEGENERATIVE CHANGES (NON-NECROTIC) DIFFUSE(MODERATE)  
-NECROSIS, PERIACINAR MULTI-FOCAL(TRACE)  
-W- LARGE GRANULAR LYMPHOCYTE LEUKEMIA, METASTATIC (PRESENT)

KIDNEY

Appendix J (cont.): PATHOLOGY INDIVIDUAL ANIMAL DATA

LETTERMAN ARMY INSTITUTE OF RESEARCH  
DIV OF RES SUPP, PATH SERV GP  
SPECIES: RAT/FISCHER-344

INDIVIDUAL ANIMAL DATA REPORT  
STUDY NUMBER: GLP83009  
STUDY START DATE: 23-JAN-84

ANIMAL NUMBER: 202/PRETEST  
DATE OF DEATH: 05-FEB-86

202 SEX. MALE  
STUDY DAY OF DEATH: 745

DOSE GROUP: 3  
STUDY WEEK OF DEATH: 107

SACRIFICE STATUS: FINAL SACRIFICE  
TERMINAL BODY WEIGHT: 353.00 (GMS)

STUDY TYPE: CHRONIC/2 YR CARCINOGENIC

STUDY START DATE: 23-JAN-84

DOSE GROUP: 3  
STUDY WEEK OF DEATH: 107

202 SEX. MALE  
STUDY DAY OF DEATH: 745

DOSE GROUP: 3  
STUDY WEEK OF DEATH: 107

SACRIFICE STATUS: FINAL SACRIFICE  
TERMINAL BODY WEIGHT: 353.00 (GMS)

<< MICROSCOPIC TISSUE OBSERVATIONS >>  
DISTRIBUTION (SEVERITY) / SPECIAL COMMENTS

KIDNEY ..... NOT SPECIFIED(MODERATE)

-PROGRESSIVE RENAL DISEASE

PROSTATE ..... NOT SPECIFIED(MILD)

-CHRONIC PROSTATITIS  
-BENIGN HYPERPLASIA

SEMINAL VESICLE ..... NOT SPECIFIED (PRESENT)

-GENERALIZED ATROPHY

TESTES ..... (PRESENT)

-B- INTERSTITIAL CELL ADENOMA

PANCREAS ..... DIFFUSE(MARKED)

-ACINAR (EXOCRINE) ATROPHY  
-B- ISLET CELL ADENOMA

MAMMARY GLANDS ..... NOT SPECIFIED(MILD)

-HYPERPLASIA AND/OR HYPERTROPHY OF THE ACINAR TISSUE  
-DILATATION (ECTASIA) OF DUCTS AND DUCTULES

NOSE/TURBINATES ..... INFILTRATE INVOLVES NASO-LACRIMAL DUCT.  
-MIXED INFLAMMATORY CELL INFILTRATION, NASAL CAVITY, SINUSES,  
TURBINATES, NASO-LACRIMAL DUCTS

BONE, STERNUM ..... NOT SPECIFIED (PRESENT)

-MYELOFIBROSIS/OSTEOSCLEROSIS

BONE, FEMUR ..... NOT SPECIFIED (PRESENT)

-MYELOFIBROSIS/OSTEOSCLEROSIS

BONE VERT ..... NOT SPECIFIED (PRESENT)

-MYELOFIBROSIS/OSTEOSCLEROSIS

ADRENAL .....

PRINTED: 21-NOV-89  
PAGE: 419

Appendix J (cont.): PATHOLOGY INDIVIDUAL ANIMAL DATA

LETTERMAN ARMY INSTITUTE OF RESEARCH  
 DIV OF RES SUPP, PATH SERV GP  
 SPECIES: RAT/FISCHER-344  
 ANIMAL NUMBER: 202/PRETEST-  
 DATE OF DEATH: 05-FEB-86  
 TISSUE / HISTOPATHOLOGIC FINDINGS

INDIVIDUAL ANIMAL DATA REPORT  
 STUDY NUMBER: GLP83009  
 STUDY START DATE: 23-JAN-84  
 DOSE GROUP: 3  
 SEX: MALE  
 STUDY DAY OF DEATH: 745  
 SACRIFICE STATUS: FINAL SACRIFICE  
 STUDY WEEK OF DEATH: 107  
 TERMINAL BODY WEIGHT: 353.00 (GMS)

PRINTED: 21-NOV-89  
 PAGE: 420  
 STUDY TYPE: CHRONIC/2 YR CARCINOGENIC

<< MICROSCOPIC TISSUE OBSERVATIONS >>  
 DISTRIBUTION (SEVERITY) / SPECIAL COMMENTS

ADRENAL .....  
 - FOCUS OF CELLULAR ALTERATION, EOSINOPHILIC  
 - M- LARGE GRANULE LYMPHOCYTE LEUKEMIA, METASTATIC  
 NOT SPECIFIED (MODERATE)  
 (PRESENT)

PITUITARY GLAND .....  
 - B- ADENOMA  
 - M- LARGE GRANULE LYMPHOCYTE LEUKEMIA, METASTATIC  
 (PRESENT)  
 (PRESENT)

WHOLE BODY .....  
 - M- LARGE GRANULAR LYMPHOCYTTIC LEUKEMIA  
 (PRESENT)

Appendix J (cont.): PATHOLOGY INDIVIDUAL ANIMAL DATA

LETTERMAN ARMY INSTITUTE OF RESEARCH
INDIVIDUAL ANIMAL DATA REPORT
DIV OF RES SUPP, PATH SERV GP
SPECIES: RAT/FISCHER-344
STUDY NUMBER: GLP83009
STUDY START DATE: 23-JAN-84
STUDY TYPE: CHRONIC/2 YR CARCINOGENIC
ANIMAL NUMBER: 203/PRETEST=
203 SEX: MALE DOSE GROUP: 3 SACRIFICE STATUS: FINAL SACRIFICE
DATE OF DEATH: 05-FEB-86 STUDY DAY OF DEATH: 745 STUDY WEEK OF DEATH: 107 TERMINAL BODY WEIGHT: 368.00 (GMS)

ORGAN NAME
KEYWORDS / PHRASES
SEVERITY GROSS FREE-TEXT COMMENTS
ATROPHIC / SMALL, UNILATERALLY PRESENT RIGHT, 1 X .75CM
TESTES GROWTH(S) / MASS(ES) PRESENT LEFT, MULTIPLE VARIABLY SIZED, YELLOW/BLACK

GROSS ORGAN OBSERVATIONS
SEVERITY GROSS FREE-TEXT COMMENTS
ATROPHIC / SMALL, UNILATERALLY PRESENT RIGHT, 1 X .75CM
TESTES GROWTH(S) / MASS(ES) PRESENT LEFT, MULTIPLE VARIABLY SIZED, YELLOW/BLACK

TISSUE / HISTOPATHOLOGIC FINDINGS
MICROSCOPIC TISSUE OBSERVATIONS
DISTRIBUTION (SEVERITY) / SPECIAL COMMENTS

THYROID GLANDS
-PARA-FOLLICULAR CELL HYPERPLASIA ("CM" CELL, LIGHT CELL) NOT SPECIFIED(TRACE)
HEART
-CARDIOMYOPATHY NOT SPECIFIED(TRACE)

LIVER
-BILE DUCTULE EPITHELIAL HYPERPLASIA AND/OR CHOLANGIOFIBROSIS NOT SPECIFIED(MODERATE)
-FOCUS OF CELLULAR ALTERATION - CLEAR CELLS NOT SPECIFIED(TRACE)

KIDNEY
-PROGRESSIVE RENAL DISEASE NOT SPECIFIED(MODERATE)

PROSTATE
-CHRONIC PROSTATITIS NOT SPECIFIED(TRACE)
-BENIGN HYPERPLASIA NOT SPECIFIED(TRACE)

TESTES
-TUBULAR ATROPHY THE SMALL (RIGHT) TESTIS HAS NO INTERSTITIAL CELL TUMOR. THE
-B- INTERSTITIAL CELL ADENOMA MARKED TUBULAR ATROPHY AND PERIARTERITIS INVOLVES THIS TESTIS.
-PERIARTERITIS NODOSA (PRESENT)
NOT SPECIFIED (PRESENT)

PANCREAS
-ACINAR (EXOCRINE) ATROPHY FOCAL(TRACE)

Appendix J (cont.): PATHOLOGY INDIVIDUAL ANIMAL DATA

LETTERMAN ARMY INSTITUTE OF RESEARCH  
DIV OF RES SUPP, PATH SERV GP  
SPECIES: RAT/FISCHER-344

INDIVIDUAL ANIMAL DATA REPORT  
STUDY NUMBER: GLP83009  
STUDY START DATE: 23-JAN-84

PRINTED: 21-NOV-89  
PAGE: 422  
STUDY TYPE: CHRONIC/2 YR CARCINOGENIC

ANIMAL NUMBER: 203/PRETEST= 203 SEX: MALE DOSE GROUP: 3 SACRIFICE STATUS: FINAL SACRIFICE  
DATE OF DEATH: 05-FEB-86 STUDY DAY OF DEATH: 745 STUDY WEEK OF DEATH: 107 TERMINAL BODY WEIGHT: 368.00 (GMS)

<< M I C R O S C O P I C T I S S U E O B S E R V A T I O N S >>  
TISSUE / HISTOPATHOLOGIC FINDINGS  
DISTRIBUTION (SEVERITY) / SPECIAL COMMENTS

CECUM ..... TISSUE IS AUTOLYTIC

MAMMARY GLANDS .....  
-HYPERPLASIA AND/OR HYPERTROPHY OF THE ACINAR TISSUE ..... NOT SPECIFIED (TRACE)  
-DILATATION (ECTASIA) OF DUCTS AND DUCTULES ..... NOT SPECIFIED (PRESENT)

NOSE/TURBINATES ..... INFILTRATE ADJACENT NASO-LACRIMAL DUCT.  
-MIXED INFLAMMATORY CELL INFILTRATION, NASAL CAVITY, SINUSES, ..... NOT SPECIFIED (MILD)  
TURBINATES, NASO-LACRIMAL DUCTS

ADRENAL .....  
-CORTICAL MODULAR HYPERPLASIA ..... NOT SPECIFIED (PRESENT)

EYES & OPTIC N. ....  
-METAPLASTIC BONE FORMATION AND/OR MINERALIZATION, SCLERA ..... NOT SPECIFIED (PRESENT)

MEDIASTINUM ..... MISCELLANEOUS TISSUE  
-REACTIVE HYPERPLASIA, LYMPH NODE ..... NOT SPECIFIED (PRESENT)



**Appendix J (cont.): PATHOLOGY INDIVIDUAL ANIMAL DATA**

LETTERMAN ARMY INSTITUTE OF RESEARCH  
 DIV OF RES SUPP, PATH SERV GP  
 SPECIES: RAT/FISCHER-344

INDIVIDUAL ANIMAL DATA REPORT  
 STUDY NUMBER: GLP83009

ANIMAL NUMBER: 204/PREST= 204 SEX: MALE DOSE GROUP: 3 SACRIFICE STATUS: FINAL SACRIFICE  
 DATE OF DEATH: 05-FEB-86 STUDY DAY OF DEATH: 745 STUDY WEEK OF DEATH: 107 TERMINAL BODY WEIGHT: 404.00 (GMS)

STUDY START DATE: 23-JAN-84 STUDY TYPE: CHRONIC/2 YR CARCINOGENIC

<< GROSS ORGAN OBSERVATIONS >>  
 KEYWORDS / PHRASES SEVERITY GROSS FREE-TEXT COMMENTS  
 GROWTH(S) / MASS(ES) PRESENT BILATERAL, MULTIPLE VARIABLY SIZED, YELLOW

<< MICROSCOPIC TISSUE OBSERVATIONS >>  
 TISSUE / HISTOPATHOLOGIC FINDINGS DISTRIBUTION (SEVERITY) / SPECIAL COMMENTS

HEART  
 -CARDIOMYOPATHY NOT SPECIFIED(MILD)  
 -MEDIAL HYPERTROPHY OF MUSCULAR ARTERIES NOT SPECIFIED(TRACE)

LUNGS  
 -MINERALIZATION OF PULMONARY ARTERIES NOT SPECIFIED(TRACE)  
 -PERIVASCULAR LYMPHOID AGGREGATIONS (CUFFING) NOT SPECIFIED (PRESENT)  
 -ALVEOLAR HEORRHAGE NOT SPECIFIED (PRESENT)

SPLEEN  
 -HEMOSIDERIN PIGMENTATION (RED PULP) NOT SPECIFIED (PRESENT)

LIVER  
 -BILE DUCTULE EPITHELIAL HYPERPLASIA AND/OR CHOLANGIOFIBROSIS NOT SPECIFIED(MODERATE)  
 -HEPATOCTYE COALESCING MICROVESICULAR (FATTY) CHANGE LEADING TO MULTI-FOCAL(TRACE)  
 NECROSIS AND MINERALIZATION

KIDNEY  
 -PROGRESSIVE RENAL DISEASE NOT SPECIFIED(MILD)

PROSTATE  
 -CHRONIC PROSTATITIS NOT SPECIFIED(TRACE)  
 -BENIGN HYPERPLASIA NOT SPECIFIED(TRACE)

SEMINAL VESICLE  
 -GENERALIZED ATROPHY NOT SPECIFIED (PRESENT)

TESTES

PRINTED: 21-NOV-89  
 PAGE: 423

Appendix J (cont.): PATHOLOGY INDIVIDUAL ANIMAL DATA

LETTERMAN ARMY INSTITUTE OF RESEARCH  
DIV OF RES SUPP, PATH SERV GP  
SPECIES: RAT/FISCHER-344

PRINTED: 21-NOV-89  
PAGE: 424

INDIVIDUAL ANIMAL DATA REPORT  
STUDY NUMBER: GLP83009  
STUDY START DATE: 23-JAN-84

STUDY TYPE: CHRONIC/2 YR CARCINOGENIC

ANIMAL NUMBER: 204/PRETEST# 204 SEX: MALE DOSE GROUP: 3 SACRIFICE STATUS: FINAL SACRIFICE  
DATE OF DEATH: 05-FEB-86 STUDY DAY OF DEATH: 745 STUDY WEEK OF DEATH: 107 TERMINAL BODY WEIGHT: 404.00 (GMS)

TISSUE / HISTOPATHOLOGIC FINDINGS << MICROSCOPIC TISSUE OBSERVATIONS >>  
DISTRIBUTION (SEVERITY) / SPECIAL COMMENTS

- TESTES ..... (PRESENT)
- B- INTERSTITIAL CELL ADENOMA
- ADRENAL ..... NOT SPECIFIED (TRACE)
- FOCUS OF CELLULAR ALTERATION, EOSINOPHILIC
- PITUITARY GLAND ..... (PRESENT)
- B- ADENOMA
- EYES & OPTIC N. .... NOT SPECIFIED (PRESENT)
- METAPLASTIC BONE FORMATION AND/OR MINERALIZATION, SCLERA

Appendix J (cont.): PATHOLOGY INDIVIDUAL ANIMAL DATA

LETTERMAN ARMY INSTITUTE OF RESEARCH  
DIV OF RES SUPP, PATH SERV GP  
SPECIES: RAT/FISCHER-344

INDIVIDUAL ANIMAL DATA REPORT  
STUDY NUMBER: GLP03009  
STUDY START DATE: 23-JAN-84

PRINTED: 21-NOV-89  
PAGE: 439  
STUDY TYPE: CHRONIC/2 YR CARCINOGENIC

ANIMAL NUMBER: 218/PRETEST-      218 SEX: FEMALE      DOSE GROUP: 1      SACRIFICE STATUS: FINAL SACRIFICE  
DATE OF DEATH: 07-FEB-86      STUDY DAY OF DEATH: 747      STUDY WEEK OF DEATH: 107      TERMINAL BODY WEIGHT: 259.00 (GMS)

<<    G R O S S    O R G A N    O B S E R V A T I O N S    >>  
KEYWORDS / PHRASES      SEVERITY    GROSS FREE-TEXT COMMENTS  
ADHESION(S)              PRESENT    DIAPHRAGM, VENTRAL ABDOMINAL WALL, INTESTINES.

<<    M I C R O S C O P I C    T I S S U E    O B S E R V A T I O N S    >>  
TISSUE / HISTOPATHOLOGIC FINDINGS      DISTRIBUTION (SEVERITY) / SPECIAL COMMENTS

THYROID GLANDS .....  
-B- PARA-FOLLICULAR CELL ADENOMA ..... (PRESENT)

HEART .....  
-CORONARYOPATHY ..... NOT SPECIFIED(MILD)

LUNGS .....  
-MINERALIZATION OF PULMONARY ARTERIES ..... NOT SPECIFIED(TRACE)

SPLEEN .....  
-FIBROSIS CAPSULAR ..... FOCAL(TRACE)

LYMPH NODES .....  
-REACTIVE HYPERPLASIA ..... REACTIVE HYPERPLASIA NOTED IN CERVICAL NODES.  
NOT SPECIFIED (PRESENT)

LIVER .....  
-COMPOUND RELATED INFLAMMATORY REACTION ..... NOT SPECIFIED (PRESENT)  
-BILE DUCTULE EPITHELIAL HYPERPLASIA AND/OR CHOLANGIOFIBROSIS ..... NOT SPECIFIED(TRACE)  
-HEPATITIS ..... MULTI-FOCAL(TRACE)  
-HEPATOCYTE VACUOLIZATION ..... MULTI-FOCAL(TRACE)  
-HEPATOCYTE COALESCING MICROVESICULAR (FATTY) CHANGE LEADING TO ..... MULTI-FOCAL(MODERATE)  
NECROSIS AND MINERALIZATION

KIDNEY .....  
-PROGRESSIVE RENAL DISEASE ..... NOT SPECIFIED(MILD)

STOMACH .....

Appendix J (cont.): PATHOLOGY INDIVIDUAL ANIMAL DATA

LETTERMAN ARMY INSTITUTE OF RESEARCH  
DIV OF RES SUPP, PATH SERV GP  
SPECIES: RAT/FISCHER-344

INDIVIDUAL ANIMAL DATA REPORT  
STUDY NUMBER: GLP83009  
STUDY START DATE: 23-JAN-84

PRINTED: 21-NOV-89  
PAGE: 440  
STUDY TYPE: CHRONIC/2 YR CARCINOGENIC

ANIMAL NUMBER: 218/PRETEST-218 SEX: FEMALE DOSE GROUP: 1 SACRIFICE STATUS: FINAL SACRIFICE  
DATE OF DEATH: 07-FEB-86 STUDY DAY OF DEATH: 747 STUDY WEEK OF DEATH: 107 TERMINAL BODY WEIGHT: 259.00 (GMS)

<< MICROSCOPIC TISSUE OBSERVATIONS >>  
DISTRIBUTION (SEVERITY) / SPECIAL COMMENTS

- STOMACH ..... NOT SPECIFIED (PRESENT)
- COMPOUND RELATED INFLAMMATORY REACTION
- MAMMARY GLANDS ..... NOT SPECIFIED(MILD)
- HYPERPLASIA AND/OR HYPERTROPHY OF THE ACIMAR TISSUE
- DILATATION (ECTASIA) OF DUCTS AND DUCTULES ..... NOT SPECIFIED (PRESENT)
- NOSE/TURBINATES ..... CELLULAR INFILTRATE IS ADJACENT TO NASO-LACRIMAL DUCT.
- MIXED INFLAMMATORY CELL INFILTRATION, NASAL CAVITY, SINUSES, ..... NOT SPECIFIED(MILD)
- TURBINATES, NASO-LACRIMAL DUCTS
- BONE, FEMUR ..... NOT SPECIFIED (PRESENT)
- HYPERPLASIA MYELOID
- PITUITARY GLAND ..... (PRESENT)
- B- ADENOMA
- DIAPHRAGM ..... MISCELLANEOUS TISSUE
- COMPOUND RELATED INFLAMMATORY REACTION ..... NOT SPECIFIED (PRESENT)

Appendix J (cont.): **PATHOLOGY INDIVIDUAL ANIMAL DATA**

LETTERMAN ARMY INSTITUTE OF RESEARCH  
 DIV OF RES SUPP, PATH SERV GP  
 SPECIES: RAT/FISCHER-344  
 STUDY START DATE: 23-JAN-84  
 STUDY NUMBER: GLP83009  
 PRINTED: 21-NOV-89  
 PAGE: 441  
 STUDY TYPE: CHRONIC/2 YR CARCINOGENIC

ANIMAL NUMBER: 219/PRETEST-  
 DATE OF DEATH: 18-NOV-85  
 SEX: FEMALE  
 DOSE GROUP: 1  
 SACRIFICE STATUS: SACRIFICED MORIBUND  
 STUDY DAY OF DEATH: 666  
 STUDY WEEK OF DEATH: 96  
 TERMINAL BODY WEIGHT: 259.00 (GMS)

<< GROSS ORGAN OBSERVATIONS >>  
 SEVERITY GROSS FREE-TEXT COMMENTS

SPLEEN ENLARGED (SPLEOMEGALY) MARKED 6.5 X 2 X 1.5CM  
 LIVER ADHESION(S) PRESENT DIAPHRAGM, VENTRAL ABDOMINAL WALL  
 PERITONEAL CAV. ADHESION(S) PRESENT 10CM LOOP OF SMALL INTESTINE ADHERED TOGETHER 20CM FROM STOMACH.

TISSUE / HISTOPATHOLOGIC FINDINGS << MICROSCOPIC TISSUE OBSERVATIONS >>  
 DISTRIBUTION (SEVERITY) / SPECIAL COMMENTS

THYROID GLANDS  
 -PARA-FOLLICULAR CELL HYPERPLASIA ("M" CELL, LIGHT CELL) NOT SPECIFIED(TRACE)

HEART  
 -CARDIOMYOPATHY NOT SPECIFIED(TRACE)

LUNGS  
 -MINERALIZATION OF PULMONARY ARTERIES NOT SPECIFIED(TRACE)  
 -M- LARGE GRANULAR LYMPHOCYTE LEUKEMIA, METASTATIC (PRESENT)

SPLEEN  
 -M- LARGE GRANULAR LYMPHOCYTE LEUKEMIA, METASTATIC (PRESENT)

LYMPH NODES  
 -M- LARGE GRANULAR LYMPHOCYTE LEUKEMIA, METASTATIC (PRESENT)

LIVER  
 -COMPOUND RELATED INFLAMMATORY REACTION NOT SPECIFIED (PRESENT)  
 -BILE DUCTULE EPITHELIAL HYPERPLASIA AND/OR CHOLANGIOFIBROSIS NOT SPECIFIED(MILD)  
 -HEPATOCTYTIC VACUOLIZATION MULTI-FOCAL(MILD)  
 -HEPATOCTYTIC DEGENERATIVE CHANGES (NON-NECROTIC) NOT SPECIFIED(MILD)  
 -NECROSIS, PERIACINAR MULTI-FOCAL(MILD)  
 -M- LARGE GRANULAR LYMPHOCYTE LEUKEMIA, METASTATIC (PRESENT)

JEJUNUM

Appendix J (cont.): PATHOLOGY INDIVIDUAL ANIMAL DATA

LETTERMAN ARMY INSTITUTE OF RESEARCH  
 DIV OF RES SUPP, PATH SERV GP  
 SPECIES: RAT/FISCHER-344  
 STUDY START DATE: 23-JAN-84  
 STUDY NUMBER: GLP83009  
 PRINTED: 21-NOV-89  
 PAGE: 442

ANIMAL NUMBER: 219/PRETEST= 219 SEX: FEMALE DOSE GROUP: 1 SACRIFICE STATUS: SACRIFICED MORIBUND  
 DATE OF DEATH: 18-NOV-85 STUDY DAY OF DEATH: 666 STUDY WEEK OF DEATH: 96 TERMINAL BODY WEIGHT: 259.00 (GMS)  
 STUDY TYPE: CHRONIC/2 YR CARCINOGENIC

TISSUE / HISTOPATHOLOGIC FINDINGS  
 << MICROSCOPIC TISSUE OBSERVATIONS >>  
 DISTRIBUTION (SEVERITY) / SPECIAL COMMENTS

JEJUNUM ..... NOT SPECIFIED (PRESENT)

ILEUM ..... NOT SPECIFIED (PRESENT)

MAMMARY GLANDS ..... DIFFUSE(SEVERE)  
 -HYPERPLASIA AND/OR HYPERTROPHY OF THE ACINAR TISSUE NOT SPECIFIED (PRESENT)  
 -DILATATION (ECTASIA) OF DUCTS AND DUCTULES

EYES & OPTIC N. .... OCULAR LESIONS ARE ALL UNILATERAL.  
 -RETINAL ATROPHY AND/OR DEGENERATION, UNILATERAL OR BILATERAL NOT SPECIFIED(MARKED)  
 -IRIDOCYLITIS NOT SPECIFIED(MILD)  
 -METAPLASTIC BONE FORMATION AND/OR MINERALIZATION, SCLERA NOT SPECIFIED (PRESENT)  
 -LENTICULAR DEGENERATIVE CHANGES COMPATIBLE WITH CATARACT NOT SPECIFIED (PRESENT)

WHOLE BODY ..... (PRESENT)  
 -M- LARGE GRANULAR LYMPHOCYTTIC LEUKEMIA

DIAPHRAGM ..... MISCELLANEOUS TISSUE  
 -COMPOUND RELATED INFLAMMATORY REACTION NOT SPECIFIED (PRESENT)

**Appendix J (cont.): PATHOLOGY INDIVIDUAL ANIMAL DATA**

LETTERMAN ARMY INSTITUTE OF RESEARCH  
 DIV OF RES SUPP, PATH SERV GP  
 SPECIES: RAT/FISCHER-344  
 STUDY START DATE: 23-JAN-84  
 STUDY TYPE: CHRONIC/2 YR CARCINOGENIC  
 ANIMAL NUMBER: 220/PRETEST= 220 SEX: FEMALE DOSE GROUP: 1 SACRIFICE STATUS: SACRIFICED MORIBUND  
 DATE OF DEATH: 14-JUN-85 STUDY DAY OF DEATH: 509 STUDY WEEK OF DEATH: 73 TERMINAL BODY WEIGHT: 301.00 (GMS)

PRINTED: 21-NOV-89  
 PAGE: 443

ORGAN NAME  
 EYES & OPTIC N.  
 DUODENUM  
 LIVER  
 GROSS ORGAN OBSERVATIONS  
 SEVERITY GROSS FREE-TEXT COMMENTS  
 PRESENT  
 PRESENT  
 PRESENT  
 ALSO ADHERED TO RIGHT PERITONEAL WALL  
 FIRM, WHITE, 3CM DIAMETER, INFILTRATING DIAPHRAGM AND  
 THORACIC WALL.

TISSUE / HISTOPATHOLOGIC FINDINGS  
 << MICROSCOPIC TISSUE OBSERVATIONS >>  
 DISTRIBUTION (SEVERITY) / SPECIAL COMMENTS

THYROID GLANDS  
 -PARA-FOLLICULAR CELL HYPERPLASIA ("C" CELL, LIGHT CELL) NOT SPECIFIED(TRACE)

HEART  
 -CARDIOMYOPATHY NOT SPECIFIED(TRACE)  
 -MEDIAL HYPERTROPHY OF MUSCULAR ARTERIES NOT SPECIFIED(TRACE)

LYMPH NODES  
 -RED BLOOD CELLS, HEMOSIDERIN AND/OR ERYTHROPHAGOCYTOSIS WITHIN RBC'S AND PIGMENT PRESENT IN CERVICAL AND MEDIASTINAL NODES.  
 MEDULLARY SINUSES NOT SPECIFIED (PRESENT)

LIVER  
 -COMPOUND RELATED INFLAMMATORY REACTION NOT SPECIFIED (PRESENT)  
 -HEPATITIS MULTI-FOCAL(MILD)  
 -FOCUS OF CELLULAR ALTERATION - BASOPHILIC NOT SPECIFIED(TRACE)  
 -W- PRESENCE OF METASTATIC SARCOMA SECONDARY NEOPLASM FROM ORGAN ABDOMINAL CAVITY

KIDNEY  
 -PROGRESSIVE RENAL DISEASE NOT SPECIFIED(MILD)

DUODENUM  
 -COMPOUND RELATED INFLAMMATORY REACTION NOT SPECIFIED (PRESENT)

PANCREAS

Appendix J (cont.): PATHOLOGY INDIVIDUAL ANIMAL DATA

LETTERMAN ARMY INSTITUTE OF RESEARCH  
DIV OF RES SUPP, PATH SERV GP  
SPECIES: RAT/FISCHER-344

INDIVIDUAL ANIMAL DATA REPORT  
STUDY NUMBER: GLP83009  
STUDY START DATE: 23-JAN-84

PRINTED: 21-NOV-89  
PAGE: 444  
STUDY TYPE: CHRONIC/2 YR CARCINOGENIC

ANIMAL NUMBER: 220/PRETEST= 220 SEX: FEMALE DOSE GROUP: 1 SACRIFICE STATUS: SACRIFICED MORIBUND  
DATE OF DEATH: 14-JUN-85 STUDY DAY OF DEATH: 509 STUDY WEEK OF DEATH: 73 TERMINAL BODY WEIGHT: 301.00 (GMS)

TISSUE / HISTOPATHOLOGIC FINDINGS << MICROSCOPIC TISSUE OBSERVATIONS >>  
DISTRIBUTION (SEVERITY) / SPECIAL COMMENTS

PANCREAS ..... FOCAL(MILD)  
-ACINAR (EXOCRINE) ATROPHY

MAMMARY GLANDS ..... NOT SPECIFIED(MILD)  
-HYPERPLASIA AND/OR HYPERTROPHY OF THE ACINAR TISSUE  
-DILATATION (ECTASIA) OF DUCTS AND DUCTULES NOT SPECIFIED (PRESENT)

NOSE/TURBINATES ..... CELLULAR INFILTRATE INVOLVES NASO LACRIMAL DUCT.  
-MIXED INFLAMMATORY CELL INFILTRATION, NASAL CAVITY, SINUSES, NOT SPECIFIED(MODERATE)  
TURBINATES, NASO-LACRIMAL DUCTS

EYES & OPTIC N. .... NOT SPECIFIED (PRESENT)  
-METAPLASTIC BONE FORMATION AND/OR MINERALIZATION, SCLERA

ABDOMINAL CAVITY ..... MISCELLANEOUS TISSUE  
THE SARCOMA INVOLVES PRIMARILY LIVER AND DIAPHRAGM. TUMOR CELL  
DIFFERENTIATION AND ARRANGEMENT IN MOST AREAS ARE TYPICAL OF  
FIBROSARCOMA. HOWEVER, THERE IS A LARGE AREA CONSISTING OF WELL  
DIFFERENTIATED CARTILAGINOUS MATRIX AND CHONDROCYTES. IN ALL  
AREAS, THERE IS A GREAT AMOUNT OF MITOTIC ACTIVITY AND MANY OF  
THE MITOTIC FIGURES ARE LARGE AND BIZARRE.  
(PRESENT)

-M- SARCOMA, CELLULAR DIFFERENTIATION UNSPECIFIED  
DIAPHRAGM ..... MISCELLANEOUS TISSUE  
-M- PRESENCE OF METASTATIC SARCOMA SECONDARY MEOPLASM FROM ORGAN  
-COMPOUND RELATED INFLAMMATORY REACTION NOT SPECIFIED (PRESENT)



Appendix J (cont.): PATHOLOGY INDIVIDUAL ANIMAL DATA

LETTERMAN ARMY INSTITUTE OF RESEARCH  
 DIV OF RES SUPP, PATH SERV GP  
 SPECIES: RAT/FISCHER-344

INDIVIDUAL ANIMAL DATA REPORT  
 STUDY NUMBER: GLP83009  
 STUDY START DATE: 23-JAN-84

ANIMAL NUMBER: 223/PRETEST- 223 SEX: FEMALE DOSE GROUP: 1 SACRIFICE STATUS: SACRIFICED MORIBUND  
 DATE OF DEATH: 02-AUG-85 STUDY DAY OF DEATH: 558 STUDY WEEK OF DEATH: 80 TERMINAL BODY WEIGHT: 237.00 (GMS)

STUDY TYPE: CHRONIC/2 YR CARCINOGENIC

ORGAN NAME      << GROSS ORGAN OBSERVATIONS >>  
 KEYWORDS / PHRASES      SEVERITY GROSS FREE-TEXT COMMENTS

VAGINA      MUCOID DISCHARGE      PRESENT      DARK RED, HEMORRHAGIC  
 UTERUS      GROWTH(S)/MASS(S)      PRESENT      CENTER OF LEFT HORN ENLARGED 2.5 X 1.5CM, GRAY/BLACK. MASS IS FIRM AND LOBULAR, 1.5CM DIAMETER, RED/BLACK.

LIVER      ADHESION(S)      PRESENT      LEFT LATERAL LOBE TO DIAPHRAGM  
 LIVER      PROMINENT LOBULAR MARKINGS      MODERATE      LEFT LATERAL LOBE  
 LIVER      GROWTH(S) / MASS(ES)      PRESENT      MEDIAL LOBE, FIRM, WHITE, 2.5 X 1.5CM  
 LIVER      DISCOLORATION      PRESENT      RIGHT LATERAL LOBES, LIGHT BROWN.  
 KIDNEY      DISCOLORATION      PRESENT      DIFFUSELY BROWN

TISSUE / HISTOPATHOLOGIC FINDINGS      << MICROSCOPIC TISSUE OBSERVATIONS >>  
 DISTRIBUTION (SEVERITY) / SPECIAL COMMENTS

THYROID GLANDS  
 -PARA-FOLLICULAR CELL HYPERPLASIA (MC CELL, LIGHT CELL)      NOT SPECIFIED(TRACE)

PARATHYROID      TISSUE IS MISSING

EXORBITAL LACRIM      FOCAL(TRACE)  
 -ACINAR ATROPHY

HEART      NOT SPECIFIED(TRACE)  
 -CARDIOMYOPATHY

SPLEEN      NOT SPECIFIED (PRESENT)  
 -EXTRAMEDULLARY HEMATOPOIESIS

LYMPH NODES      REACTIVE HYPERPLASIA AND RBC'S ARE PRESENT IN MEDIASTINAL NODES.  
 -RED BLOOD CELLS, HEMOSIDERIN AND/OR ERYTHROPHAGOCYTOSIS WITHIN A FEW RBC'S ARE NOTED IN MESENTERIC NODES.  
 MEDULLARY SINUSES      NOT SPECIFIED (PRESENT)  
 -REACTIVE HYPERPLASIA      NOT SPECIFIED (PRESENT)

LIVER

PRINTED: 21-NOV-89  
 PAGE: 447

Appendix J (cont.): **PATHOLOGY INDIVIDUAL ANIMAL DATA**

LETTERMAN ARMY INSTITUTE OF RESEARCH  
DIV OF RES SUPP, PATH SERV GP  
SPECIES: RAT/FISCHER-344  
INDIVIDUAL ANIMAL DATA REPORT  
STUDY NUMBER: GLP83009  
STUDY START DATE: 23-JAN-84  
PRINTED: 21-NOV-89  
PAGE: 448  
STUDY TYPE: CHRONIC/2 YR CARCINOGENIC

ANIMAL NUMBER: 223/PRETEST# 223 SEX: FEMALE DOSE GROUP: 1 SACRIFICE STATUS: SACRIFICED MORIBUND  
DATE OF DEATH: 02-AUG-85 STUDY DAY OF DEATH: 558 STUDY WEEK OF DEATH: 80 TERMINAL BODY WEIGHT: 237.00 (GMS)

<< M I C R O S C O P I C T I S S U E O B S E R V A T I O N S >>  
TISSUE / HISTOPATHOLOGIC FINDINGS  
DISTRIBUTION (SEVERITY) / SPECIAL COMMENTS

LIVER  
-COMPOUND RELATED INFLAMMATORY REACTION NOT SPECIFIED (PRESENT)  
-BILE DUCTULE EPITHELIAL HYPERPLASIA AND/OR CHOLANGIOFIBROSIS NOT SPECIFIED (TRACE)  
-NECROSIS, PERIACINAR NOT SPECIFIED (MODERATE)  
-M- PRESENCE OF METASTATIC SARCOMA SECONDARY NEOPLASM FROM ORGAN ABDOMINAL CAVITY

UTERUS  
-ENDOMETRIAL STROMAL POLYP NOT SPECIFIED (PRESENT)

MAMMARY GLANDS  
-HYPERPLASIA AND/OR HYPERTROPHY OF THE ACINAR TISSUE NOT SPECIFIED (MILD)

PITUITARY GLAND  
-CYST(S) NOT SPECIFIED (PRESENT)

EYES & OPTIC N.  
-METAPLASTIC BONE FORMATION AND/OR MINERALIZATION, SCLERA NOT SPECIFIED (PRESENT)

ABDOMINAL CAVITY  
-M- SARCOMA, CELLULAR DIFFERENTIATION UNSPECIFIED  
MISCELLANEOUS TISSUE  
THE SARCOMA INVOLVES PRIMARILY THE LIVER AND DIAPHRAGM. TUMOR CELL DIFFERENTIATION AND ARRANGEMENT ARE TYPICAL OF FIBROSARCOMA ALTHOUGH THERE ARE HIGHLY ANAPLASTIC CELLS IN SOME AREAS.  
(PRESENT)

DIAPHRAGM  
-M- PRESENCE OF METASTATIC SARCOMA  
-COMPOUND RELATED INFLAMMATORY REACTION  
MISCELLANEOUS TISSUE  
SECONDARY NEOPLASM FROM ORGAN  
NOT SPECIFIED (PRESENT)

Appendix J (cont.): PATHOLOGY INDIVIDUAL ANIMAL DATA

LETTERMAN ARMY INSTITUTE OF RESEARCH  
 DIV OF RES SUPP, PATH SERV GP  
 SPECIES: RAT/FISCHER-344  
 INDIVIDUAL ANIMAL DATA REPORT  
 STUDY NUMBER: GLP83009  
 STUDY START DATE: 23-JAN-84  
 PRINTED: 21-NOV-89  
 PAGE: 449  
 STUDY TYPE: CHRONIC/2 YR CARCINOGENIC

ANIMAL NUMBER: 224/PRETEST-  
 DATE OF DEATH: 15-MAR-85  
 DOSE GROUP: 1  
 SEX: FEMALE  
 STUDY WEEK OF DEATH: 60  
 SACRIFICE STATUS: SACRIFICED MORIBUND  
 TERMINAL BODY WEIGHT: 211.00 (GMS)

<< GROSS ORGAN OBSERVATIONS >>  
 SEVERITY GROSS FREE-TEXT COMMENTS  
 LIVER  
 GROWTH(S) / PHRASES PRESENT  
 GROWTH(S) / MASS(ES)  
 PLEURAL CAVITY GROWTH(S) / MASS(ES) PRESENT  
 ILEUM ADHESION(S) PRESENT  
 FIRM, WHITE, 5CM DIAMETER, EXTENDS THROUGH DIAPHRAGM, PLEURA,  
 THORACIC WALL INTO SUBCUTANEOUS TISSUE ON LEFT SIDE.  
 MULTIPLE, FIRM, WHITE, DISTRIBUTED ON PLEURAL SURFACES AND  
 MEDIASTINUM.  
 TO MASS 60CM FROM STOMACH.

TISSUE / HISTOPATHOLOGIC FINDINGS  
 << MICROSCOPIC TISSUE OBSERVATIONS >>  
 DISTRIBUTION (SEVERITY) / SPECIAL COMMENTS

HEART  
 -CARDIOMYOPATHY NOT SPECIFIED(TRACE)

LUNGS  
 -N- PRESENCE OF METASTATIC SARCOMA SECONDARY NEOPLASM FROM ORGAN ABDOMINAL CAVITY

LYMPH NODES  
 -RED BLOOD CELLS, MEMOSIDERIN AND/OR ERYTHROPHAGOCYTOSIS WITHIN METASTATIC SARCOMA, REACTIVE HYPERPLASIA, RBC'S AND PIGMENT ARE  
 MEDULLARY SINUSES PRESENT IN MEDIASTINAL LYMPH NODES. REACTIVE HYPERPLASIA AND  
 -REACTIVE HYPERPLASIA RBC'S ALSO NOTED IN MESENTERIC NODE.  
 -N- PRESENCE OF METASTATIC SARCOMA NOT SPECIFIED (PRESENT)

LIVER  
 -COMPOUND RELATED INFLAMMATORY REACTION NOT SPECIFIED (PRESENT)  
 -NEPATOCTYIC VACUOLIZATION DIFFUSE(MILD)  
 -NECROSIS FOCAL(MODERATE)  
 -N- PRESENCE OF METASTATIC SARCOMA SECONDARY NEOPLASM FROM ORGAN ABDOMINAL CAVITY

KIDNEY  
 -PROGRESSIVE RENAL DISEASE NOT SPECIFIED(TRACE)

OVARIES

Appendix J (cont.): PATHOLOGY INDIVIDUAL ANIMAL DATA

LETTERMAN ARMY INSTITUTE OF RESEARCH  
 DIV OF RES SUPP, PATH SERV GP  
 SPECIES: RAT/FISCHER-344  
 STUDY NUMBER: GLP03009  
 STUDY START DATE: 23-JAN-84  
 STUDY TYPE: CHRONIC/2 YR CARCINOGENIC  
 PRINTED: 21-NOV-89  
 PAGE: 450

ANIMAL NUMBER: 224/PRETEST= 224 SEX: FEMALE DOSE GROUP: 1 SACRIFICE STATUS: SACRIFICED MORIBUND  
 DATE OF DEATH: 15-MAR-85 STUDY DAY OF DEATH: 418 STUDY WEEK OF DEATH: 60 TERMINAL BODY WEIGHT: 211.00 (GMS)

← MICROSCOPIC TISSUE OBSERVATIONS →  
 DISTRIBUTION (SEVERITY) / SPECIAL COMMENTS

- TISSUE / HISTOPATHOLOGIC FINDINGS
- OVARIES ..... NOT SPECIFIED (PRESENT)
- FOLLICULAR CYST(S)
- ILEUM ..... SECONDARY NEOPLASM FROM ORGAN ABDOMINAL CAVITY
- N- PRESENCE OF METASTATIC SARCOMA
- MAMMARY GLANDS ..... NOT SPECIFIED (TRACE)
- HYPERPLASIA AND/OR HYPERTROPHY OF THE ACINAR TISSUE
- NOSE/TURBINATES ..... CELLULAR INFILTRATE ASSOCIATED WITH NASO-LACRIMAL DUCTS  
 BILATERALLY.  
 NOT SPECIFIED (MILD)
- MIXED INFLAMMATORY CELL INFILTRATION, NASAL CAVITY, SINUSES,  
 TURBINATES, NASO-LACRIMAL DUCTS
- EYES & OPTIC N. .... TISSUE IS MISSING  
 NUMEROUS PROCESSING ARTIFACTS PRECLUDE DETAILED HISTOLOGIC  
 EVALUATION OF THE EYES.
- THORAX ..... MISCELLANEOUS TISSUE
- N- PRESENCE OF METASTATIC SARCOMA IN THORACIC WALL. .... SECONDARY NEOPLASM FROM ORGAN ABDOMINAL CAVITY
- MEDIASTINUM ..... MISCELLANEOUS TISSUE
- REACTIVE HYPERPLASIA, LYMPH NODE ..... NOT SPECIFIED (PRESENT)
- N- PRESENCE OF METASTATIC SARCOMA ..... SECONDARY NEOPLASM FROM ORGAN ABDOMINAL CAVITY
- ABDOMINAL CAVITY ..... MISCELLANEOUS TISSUE

Appendix J (cont.): PATHOLOGY INDIVIDUAL ANIMAL DATA

LETTERMAN ARMY INSTITUTE OF RESEARCH  
DIV OF RES SUPP, PATH SERV GP  
SPECIES: RAT/FISCHER-344

INDIVIDUAL ANIMAL DATA REPORT  
STUDY NUMBER: GLP83009  
STUDY START DATE: 23-JAN-84

PRINTED: 21-NOV-89  
PAGE: 451  
STUDY TYPE: CHRONIC/2 YR CARCINOGENIC

ANIMAL NUMBER: 224/PRETEST= 224 SEX: FEMALE DOSE GROUP: 1 SACRIFICE STATUS: SACRIFICED MORIBUND  
DATE OF DEATH: 15-MAR-85 STUDY DAY OF DEATH: 418 STUDY WEEK OF DEATH: 60 TERMINAL BODY WEIGHT: 211.00 (GMS)

<< M I C R O S C O P I C T I S S U E O B S E R V A T I O N S >>  
TISSUE / HISTOPATHOLOGIC FINDINGS DISTRIBUTION (SEVERITY) / SPECIAL COMMENTS

ABDOMINAL CAVITY ..... THE SARCOMA IS PRIMARILY ASSOCIATED WITH LIVER AND DIAPHRAGM. IT EXTENDED THROUGH THE DIAPHRAGM TO INVOLVE MEDIASTINUM, LUNG, THORACIC WALL, AND IN THE ABDOMEN IT INVADED THROUGH THE WALL OF THE SMALL INTESTINE. CELLULAR DIFFERENTIATION AND ARRANGEMENT RESEMBLES FIBROSARCOMA, AND IN FACT, ABUNDANT COLLAGEN IS BEING PRODUCED BY NEOPLASTIC CELLS AS DEMONSTRATED IN SECTION STAINED WITH MASSON'S TRICHOME. THERE ARE NUMEROUS POORLY DIFFERENTIATED TUMOR CELLS IN SOME AREAS THAT RESEMBLE MUSCLE CELLS. ATTEMPTS TO DEMONSTRATE CROSS-STRIATIONS IN THESE CELLS WITH THE PTAH STAINS WERE UNSUCCESSFUL.  
-M- SARCOMA, CELLULAR DIFFERENTIATION UNSPECIFIED (PRESENT)

DIAPHRAGM ..... MISCELLANEOUS TISSUE  
-M- PRESENCE OF METASTATIC SARCOMA SECONDARY NEOPLASM FROM ORGAN ABDOMINAL CAVITY  
-COMPOUND RELATED INFLAMMATORY REACTION NOT SPECIFIED (PRESENT)

Appendix J (cont.): **PATHELOGY INDIVIDUAL ANIMAL DATA**

LETTERMAN ARMY INSTITUTE OF RESEARCH  
 DIV OF RES SUPP, PATH SERV GP  
 SPECIES: RAT/FISCHER-344  
 INDIVIDUAL ANIMAL DATA REPORT  
 STUDY NUMBER: GLP83009  
 STUDY START DATE: 23-JAN-84  
 PRINTED: 21-NOV-89  
 PAGE: 452  
 STUDY TYPE: CHRONIC/2 YR CARCINOGENIC

ANIMAL NUMBER: 225/PRETEST= 225 SEX: FEMALE DOSE GROUP: 1 SACRIFICE STATUS: SACRIFICED MORIBUND  
 DATE OF DEATH: 03-FEB-86 STUDY DAY OF DEATH: 743 STUDY WEEK OF DEATH: 107 TERMINAL BODY WEIGHT: 229.00 (GMS)

<< GROSS ORGAN OBSERVATIONS >>  
 SEVERITY GROSS FREE-TEXT COMMENTS  
 -----  
 SPLEEN ENLARGED (SPLENOHEGALY) MARKED 7 X 1.75CM  
 LIVER ADHESION(S) PRESENT SMALL INTESTINES, STOMACH, VENTRAL ABDOMINAL WALL, DIAPHRAGM  
 LIVER PROMINENT LOBULAR MARKINGS PRESENT  
 LIVER GRANULAR SURFACE PRESENT  
 LYMPH NODES DISCOLORATION PRESENT RED, MESENTERIC  
 WHOLE BODY FAT GENERALLY YELLOW PRESENT  
 UTERUS GROWTH(S)/MASS(S) PRESENT .2 X .5CM, INTRAUTERINE, BODY, BLOOD FILLED  
 WHOLE BODY THIN WATERY BLOOD PRESENT  
 SKIN ABSCESS(ES) PRESENT LUMBAR REGION, 2CM DIAMETER, ULCERATED, PUSS FILLED

TISSUE / HISTOPATHOLOGIC FINDINGS  
 << MICROSCOPIC TISSUE OBSERVATIONS >>  
 DISTRIBUTION (SEVERITY) / SPECIAL COMMENTS  
 -----

- HEART ..... NOT SPECIFIED (TRACE)
- CARDIOMYOPATHY
- SPLEEN ..... NOT SPECIFIED (TRACE)
- INFARCTION, CHRONIC
- N- LARGE GRANULAR LYMPHOCYTE LEUKEMIA, METASTATIC (PRESENT)
- LYMPH NODES ..... (PRESENT)
- N- LARGE GRANULAR LYMPHOCYTE LEUKEMIA, METASTATIC
- LIVER ..... NOT SPECIFIED (PRESENT)
- COMPOUND RELATED INFLAMMATORY REACTION
- BILE DUCTULE EPITHELIAL HYPERPLASIA AND/OR CHOLANGIOFIBROSIS
- HEPATOCTYIC DEGENERATIVE CHANGES (NON-NECROTIC)
- NECROSIS, PERIACINAR
- N- LARGE GRANULAR LYMPHOCYTE LEUKEMIA, METASTATIC (PRESENT)
- KIDNEY .....

**Appendix J (cont.): PATHOLOGY INDIVIDUAL ANIMAL DATA**

LETTERMAN ARMY INSTITUTE OF RESEARCH  
 DIV OF RES SUPP, PATH SERV GP  
 SPECIES: RAT/FISCHER-344

INDIVIDUAL ANIMAL DATA REPORT  
 STUDY NUMBER: GLP83009  
 STUDY START DATE: 23-JAN-84

ANIMAL NUMBER: 225/PRETEST= 225 SEX: FEMALE DOSE GROUP: 1 SACRIFICE STATUS: SACRIFICED MORIBUND  
 DATE OF DEATH: 03-FEB-86 STUDY DAY OF DEATH: 743 STUDY WEEK OF DEATH: 107 TERMINAL BODY WEIGHT: 229.00 (GMS)

STUDY TYPE: CHRONIC/2 YR CARCINOGENIC  
 << MICROSCOPIC TISSUE OBSERVATIONS >>  
 DISTRIBUTION (SEVERITY) / SPECIAL COMMENTS

PRINTED: 21-NOV-89  
 PAGE: 453

KIDNEY ..... NOT SPECIFIED(MILD)  
 -PROGRESSIVE RENAL DISEASE

UTERUS ..... DIFFUSE(MILD)  
 -ENDOMETRITIS, SUBACUTE

JEJUNUM ..... NOT SPECIFIED (PRESENT)  
 -COMPOUND RELATED INFLAMMATORY REACTION

SKIN ..... (PRESENT)  
 -B- KERATOACANTHOMA, ANATOMIC SITE TO BE SPECIFIED

MAMMARY GLANDS ..... NOT SPECIFIED(MODERATE)  
 -HYPERPLASIA AND/OR HYPERTROPHY OF THE ACINAR TISSUE  
 -DILATATION (ECTASIA) OF DUCTS AND DUCTULES

NOSE/TURBINATES ..... CELLULAR INFILTRATE INVOLVES NASO-LACRIMAL DUCTS.  
 -MIXED INFLAMMATORY CELL INFILTRATION, NASAL CAVITY, SINUSES,  
 TURBINATES, NASO-LACRIMAL DUCTS  
 NOT SPECIFIED(MILD)

BONE, STERNUM ..... NOT SPECIFIED (PRESENT)  
 -HYPERPLASIA, MYELOID

BONE, FEMUR ..... NOT SPECIFIED (PRESENT)  
 -HYPERPLASIA MYELOID

BONE VERT ..... NOT SPECIFIED (PRESENT)  
 -HYPERPLASIA, MYELOID

ADRENAL ..... NOT SPECIFIED(TRACE)  
 -FOCUS OF CELLULAR ALTERATION, VACUOLATED

PITUITARY GLAND .....

Appendix J (cont.): PATHOLOGY INDIVIDUAL ANIMAL DATA

LETTERMAN ARMY INSTITUTE OF RESEARCH  
 DIV OF RES SUPP, PATH SERV GP  
 SPECIES: RAT/FISCHER-344  
 ANIMAL NUMBER: 225/PRETEST= 225 SEX: FEMALE DOSE GROUP: 1  
 DATE OF DEATH: 03-FEB-86 STUDY DAY OF DEATH: 743 STUDY WEEK OF DEATH: 107 SACRIFICE STATUS: SACRIFICED MORIBUND  
 TISSUE / HISTOPATHOLOGIC FINDINGS << MICROSCOPIC TISSUE OBSERVATIONS >>  
 PITUITARY GLAND ..... (PRESENT)  
 -B- ADENOMA .....  
 EYES & OPTIC N. .... NOT SPECIFIED (TRACE)  
 -RETINAL ATROPHY AND/OR DEGENERATION, UNILATERAL OR BILATERAL ..... NOT SPECIFIED (PRESENT)  
 -LENTICULAR DEGENERATIVE CHANGES COMPATIBLE WITH CATARACT .....  
 DIAPHRAGM ..... MISCELLANEOUS TISSUE  
 -COMPOUND RELATED INFLAMMATORY REACTION ..... NOT SPECIFIED (PRESENT)

INDIVIDUAL ANIMAL DATA REPORT  
 STUDY NUMBER: GLP83009  
 STUDY START DATE: 23-JAN-84  
 STUDY TYPE: CHRONIC/2 YR CARCINOGENIC  
 PRINTED: 21-NOV-89  
 PAGE: 454  
 TERMINAL BODY WEIGHT: 229.00 (GMS)



Appendix J (cont.): PATHOLOGY INDIVIDUAL ANIMAL DATA

LETTERMAN ARMY INSTITUTE OF RESEARCH  
 DIV OF RES SUPP, PATH SERV GP  
 SPECIES: RAT/FISCHER-344  
 STUDY NUMBER: GLP83009  
 STUDY START DATE: 23-JAN-84  
 STUDY TYPE: CHRONIC/2 YR CARCINOGENIC  
 PRINTED: 21-NOV-89  
 PAGE: 456

ANIMAL NUMBER: 227/PRETEST= 227 SEX: FEMALE DOSE GROUP: 1 SACRIFICE STATUS: FINAL SACRIFICE  
 DATE OF DEATH: 07-FEB-86 STUDY DAY OF DEATH: 747 STUDY WEEK OF DEATH: 107 TERMINAL BODY WEIGHT: 275.00 (GMS)

ORGAN NAME << GROSS ORGAN OBSERVATIONS >>  
 SEVERITY GROSS FREE-TEXT COMMENTS  
 LIVER ADHESION(S) PRESENT DIAPHRAGM, ABDOMINAL WALL, STOMACH.  
 KIDNEY GRANULAR SURFACE PRESENT  
 PITUITARY GLAND ENLARGED PRESENT  
 UTERUS POLYP PRESENT .6CM DIAMETER, DARK RED.  
 LEFT, INTRAUTERINE.

TISSUE / HISTOPATHOLOGIC FINDINGS << MICROSCOPIC TISSUE OBSERVATIONS >>  
 DISTRIBUTION (SEVERITY) / SPECIAL COMMENTS

THYROID GLANDS ..... (PRESENT)  
 -B- PARA-FOLLICULAR CELL ADENOMA

HEART ..... NOT SPECIFIED (TRACE)  
 -CARDIOMYOPATHY

LYMPH NODES ..... REACTIVE HYPERPLASIA NOTED IN CERVICAL AND MEDIASTINAL NODES.  
 -REACTIVE HYPERPLASIA NOT SPECIFIED (PRESENT)

LIVER ..... NOT SPECIFIED (PRESENT)  
 -COMPOUND RELATED INFLAMMATORY REACTION NOT SPECIFIED (PRESENT)  
 -BILE DUCTULE EPITHELIAL HYPERPLASIA AND/OR CHOLANGIOFIBROSIS MULTI-FOCAL (MILD)  
 -HEPATITIS MULTI-FOCAL (MILD)  
 -HEPATOCTYIC VACUOLIZATION FOCAL (PRESENT)  
 -FIBROSIS CAPSULAR NO COMPOUND FOCAL (PRESENT)  
 -FOCUS OF CELLULAR ALTERATION - CLEAR CELLS FOCAL (MILD)

KIDNEY ..... NOT SPECIFIED (MODERATE)  
 -PROGRESSIVE RENAL DISEASE

UTERUS ..... NOT SPECIFIED (PRESENT)  
 -ENDOMETRIAL STROMAL POLYP

OVARIES .....

Appendix J (cont.): PATHOLOGY INDIVIDUAL ANIMAL DATA

LETTERMAN ARMY INSTITUTE OF RESEARCH INDIVIDUAL ANIMAL DATA REPORT PRINTED: 21-NOV-89  
DIV OF RES SUPP, PATH SERV GP STUDY NUMBER: GLP83009 PAGE: 457  
SPECIES: RAT/FISCHER-344 STUDY START DATE: 23-JAN-84 STUDY TYPE: CHRONIC/2 YR CARCINOGENIC

ANIMAL NUMBER: 227/PRETEST= 227 SEX: FEMALE DOSE GROUP: 1 SACRIFICE STATUS: FINAL SACRIFICE  
DATE OF DEATH: 07-FEB-86 STUDY DAY OF DEATH: 747 STUDY WEEK OF DEATH: 107 TERMINAL BODY WEIGHT: 275.00 (GMS)

TISSUE / HISTOPATHOLOGIC FINDINGS MICROSCOPIC TISSUE OBSERVATIONS >>  
DISTRIBUTION (SEVERITY) / SPECIAL COMMENTS

OVARIES ..... NOT SPECIFIED (PRESENT)  
-CYSTIC CORPORA LUTEA

PANCREAS ..... NOT SPECIFIED (MILD)  
-ACINAR (EXOCRINE) ATROPHY

STOMACH ..... NOT SPECIFIED (PRESENT)  
-COMPOUND RELATED INFLAMMATORY REACTION

MAMMARY GLANDS ..... NOT SPECIFIED (MILD)  
-HYPERPLASIA AND/OR HYPERTROPHY OF THE ACINAR TISSUE  
-DILATATION (ECTASIA) OF DUCTS AND DUCTULES

NOSE/TURBINATES ..... CELLULAR INFILTRATE INVOLVES MUCO-LACRIMAL DUCT.  
-MIXED INFLAMMATORY CELL INFILTRATION, NASAL CAVITY, SINUSES, NOT SPECIFIED (MILD)  
TURBINATES, MUCO-LACRIMAL DUCTS

ADRENAL ..... NOT SPECIFIED (MILD)  
-FOCUS OF CELLULAR ALTERATION, VACUOLATED

PITUITARY GLAND ..... (PRESENT)  
-B- ADENOMA

EYES & OPTIC N. .... NOT SPECIFIED (MODERATE)  
-RETINAL ATROPHY AND/OR DEGENERATION, UNILATERAL OR BILATERAL  
-CORNEAL VASCULARIZATION

DIAPHRAGM ..... MISCELLANEOUS TISSUE  
-COMPOUND RELATED INFLAMMATORY REACTION

**Appendix J (cont.): PATHOLOGY INDIVIDUAL ANIMAL DATA**

LETTERMAN ARMY INSTITUTE OF RESEARCH  
 DIV OF RES SUPP, PATH SERV GP  
 SPECIES: RAT/FISCHER-344

PRINTED: 21-NOV-99  
 PAGE: 458

INDIVIDUAL ANIMAL DATA REPORT  
 STUDY NUMBER: GLP83009

STUDY TYPE: CHRONIC/2 YR CARCINOGENIC

ANIMAL NUMBER: 228/PRETEST= 228 SEX: FEMALE DOSE GROUP: 1 SACRIFICE STATUS: FINAL SACRIFICE  
 DATE OF DEATH: 10-FEB-86 STUDY DAY OF DEATH: 750 STUDY WEEK OF DEATH: 108 TERMINAL BODY WEIGHT: 257.00 (GHS)

ORGAN NAME: << GROSS ORGAN OBSERVATIONS >>  
 SEVERITY GROSS FREE-TEXT COMMENTS  
 LIVER PRESENT DIAPHRAGM, VENTRAL ABDOMINAL WALL, DUODENUM  
 PITUITARY GLAND PRESENT BLACK, .3CM DIAMETER  
 VAGINA PRESENT

TISSUE / HISTOPATHOLOGIC FINDINGS << MICROSCOPIC TISSUE OBSERVATIONS >>  
 DISTRIBUTION (SEVERITY) / SPECIAL COMMENTS

- THYROID GLANDS ..... TISSUE IS MISSING
- PARATHYROID ..... TISSUE IS MISSING
- LACRIMAL GLAND ..... NOT SPECIFIED(TRACE)
- ATROPHY AND/OR LOSS OF ACINAR TISSUE ..... MULTI-FOCAL(MILD)
- EXORBITAL LACRIM ..... NOT SPECIFIED(TRACE)
- ACINAR ATROPHY ..... NOT SPECIFIED(MODERATE)
- HEART ..... REACTIVE HYPERPLASIA PRESENT IN CERVICAL NODES.
- CARDIOMYOPATHY ..... HISTIOCYTIC INFILTRATION AND PIGMENT NOTED IN MEDIASTINAL NODES.
- LUNGS ..... NOT SPECIFIED (PRESENT)
- PULMONARY EDEMA ..... NOT SPECIFIED (PRESENT)
- LYMPH NODES ..... NOT SPECIFIED (PRESENT)
- RED BLOOD CELLS, HEMOSIDERIN AND/OR ERYTHROPHAGOCYTOSIS WITHIN MEDULLARY SINUSES ..... NOT SPECIFIED (PRESENT)
- HISTIOCYTIC INFILTRATION, SUBCAPSULAR AND MEDULLARY SINUSES ..... NOT SPECIFIED (PRESENT)
- REACTIVE HYPERPLASIA ..... NOT SPECIFIED (PRESENT)
- LIVER ..... NOT SPECIFIED (PRESENT)
- COMPOUND RELATED INFLAMMATORY REACTION

Appendix J (cont.): PATHOLOGY INDIVIDUAL ANIMAL DATA

LETTERMAN ARMY INSTITUTE OF RESEARCH  
 DIV OF RES SUPP, PATH SERV GP  
 SPECIES: RAT/FISCHER-344

INDIVIDUAL ANIMAL DATA REPORT  
 STUDY NUMBER: GLP3009

STUDY START DATE: 23-JAN-84

PRINTED: 21-NOV-89  
 PAGE: 459

STUDY TYPE: CHRONIC/2 YR CARCINOGENIC

ANIMAL NUMBER: 228/PRETEST=  
 DATE OF DEATH: 10-FEB-86

228 SEX: FEMALE DOSE GROUP: 1 SACRIFICE STATUS: FINAL SACRIFICE  
 STUDY DAY OF DEATH: 750 STUDY WEEK OF DEATH: 108 TERMINAL BODY WEIGHT: 257.00 (GMS)

TISSUE / HISTOPATHOLOGIC FINDINGS << MICROSCOPIC TISSUE OBSERVATIONS >>  
 DISTRIBUTION (SEVERITY) / SPECIAL COMMENTS

LIVER .....  
 -BILE DUCTULE EPITHELIAL HYPERPLASIA AND/OR CHOLANGIOFIBROSIS ..... NOT SPECIFIED(TRACE)  
 -HEPATITIS ..... MULTI-FOCAL(TRACE)  
 -FOCUS OF CELLULAR ALTERATION - BASOPHILIC ..... MULTI-FOCAL(MILD)  
 -HEPATOCTYIC VACUOLIZATION ..... MULTI-FOCAL(MILD)  
 -HEPATOCTYIC COALESCING MICROVESICULAR (FATTY) CHANGE LEADING TO ..... NOT SPECIFIED(MARKED)  
 NECROSIS AND MINERALIZATION

KIDNEY .....  
 -PROGRESSIVE RENAL DISEASE ..... NOT SPECIFIED(TRACE)

DUODENUM .....  
 -COMPOUND RELATED INFLAMMATORY REACTION ..... NOT SPECIFIED (PRESENT)

SKIN .....  
 A VAGINAL ABSCESS IS DESCRIBED GROSSLY. A THOROUGH SEARCH OF  
 WET TISSUE REVEALED NO TISSUE SPECIMEN CORRESPONDING TO THIS  
 LESION.

MAMMARY GLANDS .....  
 -HYPERPLASIA AND/OR HYPERTROPHY OF THE ACINAR TISSUE ..... NOT SPECIFIED(MILD)  
 -DILATATION (ECTASIA) OF DUCTS AND DUCTULES ..... NOT SPECIFIED (PRESENT)

NOSE/TURBINATES .....  
 -MIXED INFLAMMATORY CELL INFILTRATION, NASAL CAVITY, SINUSES, ..... CELLULAR INFILTRATE INVOLVES NASO-LACRIMAL DUCT.  
 TURBINATES, NASO-LACRIMAL DUCTS ..... NOT SPECIFIED(MILD)

ADRENAL .....  
 -FOCUS OF CELLULAR ALTERATION, VACUOLATED ..... NOT SPECIFIED(MILD)

PITUITARY GLAND .....  
 -B- ADENOMA ..... (PRESENT)

EYES & OPTIC N. ....  
 -METAPLASTIC BONE FORMATION AND/OR MINERALIZATION, SCLERA ..... NOT SPECIFIED (PRESENT)

Appendix J (cont.): PATHOLOGY INDIVIDUAL ANIMAL DATA

LETTERNAN ARMY INSTITUTE OF RESEARCH  
DIV OF RES SUPP, PATH SERV GP  
SPECIES: RAT/FISCHER-344  
INDIVIDUAL ANIMAL DATA REPORT  
STUDY NUMBER: GLP83009  
STUDY START DATE: 23-JAN-84  
PRINTED: 21-NOV-89  
PAGE: 460  
STUDY TYPE: CHRONIC/2 YR CARCINOGENIC

ANIMAL NUMBER: 228/PRETEST=  
DATE OF DEATH: 10-FEB-86  
SEX: FEMALE  
DOSE GROUP: 1  
SACRIFICE STATUS: FINAL SACRIFICE  
STUDY DAY OF DEATH: 750  
STUDY WEEK OF DEATH: 108  
TERMINAL BODY WEIGHT: 257.00 (GMS)

<< MICROSCOPIC TISSUE OBSERVATIONS >>  
DISTRIBUTION (SEVERITY) / SPECIAL COMMENTS

AD SEBACIOUS ..... TISSUE IS MISSING  
DIAPHRAGM ..... MISCELLANEOUS TISSUE  
-COMPOUND RELATED INFLAMMATORY REACTION NOT SPECIFIED (PRESENT)

**Appendix J (cont.): PATHOLOGY INDIVIDUAL ANIMAL DATA**

LETTERMAN ARMY INSTITUTE OF RESEARCH  
 DIV OF RES SUPP, PATH SERV GP  
 SPECIES: RAT/FISCHER-344

INDIVIDUAL ANIMAL DATA REPORT  
 STUDY NUMBER: GLP63009  
 STUDY START DATE: 23-JAN-84

PRINTED: 21-NOV-89  
 PAGE: 461  
 STUDY TYPE: CHRONIC/2 YR CARCINOGENIC

ANIMAL NUMBER: 229/PRETEST# 229 SEX: FEMALE DOSE GROUP: 1 SACRIFICE STATUS: FINAL SACRIFICE  
 DATE OF DEATH: 10-FEB-86 STUDY DAY OF DEATH: 750 STUDY WEEK OF DEATH: 108 TERMINAL BODY WEIGHT: 254.00 (GMS)

<< GROSS ORGAN OBSERVATIONS >>  
 SEVERITY GROSS FREE-TEXT COMMENTS

ORGAN NAME  
 LIVER PRESENT STOMACH, INTESTINES, DIAPHRAGM, VENTRAL ABDOMINAL WALL  
 SKIN PRESENT RIGHT FLANK, 5CM DIAMETER  
 PITUITARY GLAND PRESENT BLACK, .1CM DIAMETER

<< MICROSCOPIC TISSUE OBSERVATIONS >>  
 DISTRIBUTION (SEVERITY) / SPECIAL COMMENTS

HEART ..... NOT SPECIFIED(TRACE)  
 -CARDIOMYOPATHY

LUNGS ..... FOCAL(TRACE)  
 -PNEUMONIA, INTERSTITIAL, CHRONIC

LYMPH NODES ..... A FEW RBC'S AND MODERATE AMOUNTS OF PIGMENT ARE NOTED IN  
 -RED BLOOD CELLS, HEMOSIDERIN AND/OR ERYTHROPHAGOCYTOSIS WITHIN  
 MEDULLARY SINUSES NOT SPECIFIED (PRESENT)

LIVER ..... NOT SPECIFIED (PRESENT)  
 -COMPOUND RELATED INFLAMMATORY REACTION NOT SPECIFIED(TRACE)  
 -BILE DUCTULE EPITHELIAL HYPERPLASIA AND/OR CHOLANGIOFIBROSIS

KIDNEY ..... NOT SPECIFIED(MILD)  
 -PROGRESSIVE RENAL DISEASE

UTERUS ..... NOT SPECIFIED (PRESENT)  
 -CYSTIC DILATATION OF THE ENDOMETRIAL GLANDS

JEJUNUM ..... NOT SPECIFIED (PRESENT)  
 -COMPOUND RELATED INFLAMMATORY REACTION

STOMACH .....

Appendix J (cont.): PATHOLOGY INDIVIDUAL ANIMAL DATA

LETTERMAN ARMY INSTITUTE OF RESEARCH  
 DIV OF RES SUPP, PATH SERV GP  
 SPECIES: RAT/FISCHER-344  
 INDIVIDUAL ANIMAL DATA REPORT  
 STUDY NUMBER: GLP63009  
 STUDY START DATE: 23-JAN-84  
 PRINTED: 21-NOV-89  
 PAGE: 462  
 STUDY TYPE: CHRONIC/2 YR CARCINOGENIC  
 ANIMAL NUMBER: 229/PRETEST= 229 SEX: FEMALE DOSE GROUP: 1 SACRIFICE STATUS: FINAL SACRIFICE  
 DATE OF DEATH: 10-FEB-86 STUDY DAY OF DEATH: 750 STUDY WEEK OF DEATH: 108 TERMINAL BODY WEIGHT: 254.00 (GMS)  
 << MICROSCOPIC TISSUE OBSERVATIONS >>  
 TISSUE / HISTOPATHOLOGIC FINDINGS DISTRIBUTION (SEVERITY) / SPECIAL COMMENTS

STOMACH ..... NOT SPECIFIED (PRESENT)  
 -COMPOUND RELATED INFLAMMATORY REACTION  
 TONGUE ..... FOCAL (TRACE)  
 -MONONUCLEAR CELLULAR INFILTRATION  
 MAMMARY GLANDS ..... THE SUBCUTANEOUS MASS IN THE RIGHT FLANK IS A MAMMARY FIBROADENOMA.  
 -HYPERPLASIA AND/OR HYPERTROPHY OF THE ACINAR TISSUE NOT SPECIFIED (MILD)  
 -B- FIBROADENOMA (PRESENT)  
 -DILATATION (ECTASIA) OF DUCTS AND DUCTULES NOT SPECIFIED (PRESENT)  
 NOSE/TURBINATES ..... CELLULAR INFILTRATE IS ADJACENT NASO-LACRIMAL DUCTS.  
 -MIXED INFLAMMATORY CELL INFILTRATION, NASAL CAVITY, SINUSES, NOT SPECIFIED (TRACE)  
 TURBINATES, NASO-LACRIMAL DUCTS  
 ADRENAL ..... NOT SPECIFIED (TRACE)  
 -FOCUS OF CELLULAR ALTERATION, VACUOLATED  
 PITUITARY GLAND ..... NOT SPECIFIED (PRESENT)  
 -CYST(S) FOCAL (PRESENT)  
 -HEMORRHAGE  
 EYES & OPTIC N. .... NOT SPECIFIED (TRACE)  
 -CORNEAL MINERALIZATION NOT SPECIFIED (MILD)  
 -CORNEAL VASCULARIZATION NOT SPECIFIED (PRESENT)  
 -METAPLASTIC BONE FORMATION AND/OR MINERALIZATION, SCLERA  
 DIAPHRAGM ..... MISCELLANEOUS TISSUE  
 -COMPOUND RELATED INFLAMMATORY REACTION NOT SPECIFIED (PRESENT)

Appendix J (cont.): PATHOLOGY INDIVIDUAL ANIMAL DATA

LETTERMAN ARMY INSTITUTE OF RESEARCH  
DIV OF RES SUPP. PATH SERV GP  
SPECIES: RAT/FISCHER-344

INDIVIDUAL ANIMAL DATA REPORT  
STUDY NUMBER: GLP83009

PRINTED: 21-NOV-89  
PAGE: 463

STUDY START DATE: 23-JAN-84

STUDY TYPE: CHRONIC/2 YR CARCINOGENIC

ANIMAL NUMBER: 230/PRETEST-230 SEX: FEMALE DOSE GROUP: 1 SACRIFICE STATUS: FINAL SACRIFICE  
DATE OF DEATH: 10-FEB-86 STUDY DAY OF DEATH: 750 STUDY WEEK OF DEATH: 108 TERMINAL BODY WEIGHT: 274.00 (GMS)

ORGAN NAME << GROSS ORGAN OBSERVATIONS >>  
KEYWORDS / PHRASES SEVERITY GROSS FREE-TEXT COMMENTS  
LIVER ADENOM(S) PRESENT DIAPHRAGM, VENTRAL ABDOMINAL WALL  
KIDNEY GRANULAR SURFACE PRESENT  
PITUITARY GLAND DISCOLORATION PRESENT RED

TISSUE / HISTOPATHOLOGIC FINDINGS << MICROSCOPIC TISSUE OBSERVATIONS >>  
DISTRIBUTION (SEVERITY) / SPECIAL COMMENTS

THYROID GLANDS  
-8- PARA-FOLLICULAR CELL ADENOMA (PRESENT)

HEART  
-CARDIOMYOPATHY NOT SPECIFIED(TRACE)

LUNGS  
-PNEUMONIA, INTERSTITIAL, CHRONIC FOCAL(TRACE)

LYMPH NODES  
-RED BLOOD CELLS, MEMOSIDERIN AND/OR ERYTHROPHAGOCYTOSIS WITHIN  
MEDULLARY SINUSES REACTIVE HYPERPLASIA PRESENT IN CERVICAL NODES.  
RBC'S AND PIGMENT PRESENT IN MEDIASTINAL NODE.  
-REACTIVE HYPERPLASIA NOT SPECIFIED (PRESENT)

LIVER  
-COMPOUND RELATED INFLAMMATORY REACTION NOT SPECIFIED (PRESENT)  
-HEPATITIS MULTI-FOCAL(MILD)  
-HEPATOCTYIC VACUOLIZATION MULTI-FOCAL(TRACE)  
-HEPATOCTYIC COALESCING MICROVESICULAR (FATTY) CHANGE LEADING TO  
NECROSIS AND MINERALIZATION MULTI-FOCAL(MILD)

KIDNEY  
-PROGRESSIVE RENAL DISEASE NOT SPECIFIED(MODERATE)

PANCREAS



Appendix J (cont.): PATHOLOGY INDIVIDUAL ANIMAL DATA

LETTERMAN ARMY INSTITUTE OF RESEARCH INDIVIDUAL ANIMAL DATA REPORT PRINTED: 21-NOV-89  
DIV OF RES SUPP, PATH SERV GP STUDY NUMBER: GLP83009 PAGE: 464  
SPECIES: RAT/FISCHER-344 STUDY START DATE: 23-JAN-84 STUDY TYPE: CHRONIC/2 YR CARCINOGENIC

ANIMAL NUMBER: 230/PRETEST= 230 SEX: FEMALE DOSE GROUP: 1 SACRIFICE STATUS: FINAL SACRIFICE  
DATE OF DEATH: 10-FEB-86 STUDY DAY OF DEATH: 750 STUDY WEEK OF DEATH: 108 TERMINAL BODY WEIGHT: 274.00 (GMS)

<< MICROSCOPIC TISSUE OBSERVATIONS >>  
TISSUE / HISTOPATHOLOGIC FINDINGS DISTRIBUTION (SEVERITY) / SPECIAL COMMENTS

- PANCREAS ..... NOT SPECIFIED (TRACE)
- ACINAR (EXOCRINE) ATROPHY
- COLON ..... TISSUE IS MISSING
- STOMACH ..... NOT SPECIFIED (PRESENT)
- COMPOUND RELATED INFLAMMATORY REACTION
- MAMMARY GLANDS ..... NOT SPECIFIED (TRACE)
- HYPERPLASIA AND/OR HYPERTROPHY OF THE ACINAR TISSUE
- DILATATION (ECTASIA) OF DUCTS AND DUCTULES ..... NOT SPECIFIED (PRESENT)
- ADRENAL ..... NOT SPECIFIED (MILD)
- FOCUS OF CELLULAR ALTERATION, VACUOLATED
- PITUITARY GLAND ..... (PRESENT)
- B- ADENOMA
- DIAPHRAGM ..... MISCELLANEOUS TISSUE
- COMPOUND RELATED INFLAMMATORY REACTION ..... NOT SPECIFIED (PRESENT)

Appendix J (cont.): PATHOLOGY INDIVIDUAL ANIMAL DATA

LETTERMAN ARMY INSTITUTE OF RESEARCH INDIVIDUAL ANIMAL DATA REPORT PRINTED: 21-NOV-89
DIV OF RES SUPP, PATH SERV GP STUDY NUMBER: GLP83009 PAGE: 466
SPECIES: RAT/FISCHER-344 STUDY START DATE: 23-JAN-84 STUDY TYPE: CHRONIC/2 YR CARCINOGENIC
ANIMAL NUMBER: 232/PRETEST-232 SEX: FEMALE DOSE GROUP: 1 SACRIFICE STATUS: SACRIFICED MORIBUND
DATE OF DEATH: 15-NOV-85 STUDY DAY OF DEATH: 663 STUDY WEEK OF DEATH: 95 TERMINAL BODY WEIGHT: 270.00 (GMS)

ORGAN NAME KEYWORDS / PHRASES ORGAN OBSERVATIONS SEVERITY GROSS FREE-TEXT COMMENTS
LIVER ADHESION(S) PRESENT DIAPHRAGM, VENTRAL ABDOMINAL WALL
LIVER GROWTH(S) / MASS(ES) PRESENT FIRM, WHITE, 5 X 4 X 3CM
SM INTESTINE ADHERED TO MASS PRESENT
COLON ADHERED TO PERITONEAL WALL PRESENT
PERITONEAL CAV. GROWTH(S) / MASS(ES) PRESENT NUMEROUS, FIRM, WHITE, .1-.4CM DIAMETER, DISSEMINATED IN MESENTERY.
PITUITARY GLAND ENLARGED PRESENT 4MM DIAMETER
PITUITARY GLAND DISCOLORATION PRESENT RED, FOCAL

TISSUE / HISTOPATHOLOGIC FINDINGS MICROSCOPIC TISSUE OBSERVATIONS DISTRIBUTION (SEVERITY) / SPECIAL COMMENTS
EXORBITAL LACRIM FOCAL (TRACE)
ACINAR ATROPHY
HEART NOT SPECIFIED (TRACE)
CARDIOMYOPATHY
LUNGS SECONDARY NEOPLASM FROM ORGAN LIVER
METASTATIC NEOPLASM

SPLEEN NOT SPECIFIED (PRESENT)
EXTRAMEDULLARY HEMATOPOIESIS
LYMPH NODES METASTATIC HEPATOCELLULAR CARCINOMA WITH RBC'S AND PIGMENT ARE PRESENT IN MEDIASTINAL AND MESENTERIC LYMPH NODES.
RED BLOOD CELLS, HEMOSIDERIN AND/OR ERYTHROPHAGOCYTOSIS WITHIN MEDULLARY SINUSES NOT SPECIFIED (PRESENT)
PRESENCE OF METASTATIC NEOPLASM SECONDARY NEOPLASM FROM ORGAN LIVER
PRESENCE OF METASTATIC NEOPLASM

LIVER COMPOUND RELATED INFLAMMATORY REACTION NOT SPECIFIED (PRESENT)

Appendix J (cont.): PATHOLOGY INDIVIDUAL ANIMAL DATA

LETTERMAN ARMY INSTITUTE OF RESEARCH  
 DIV OF RES SUPP, PATH SERV GP  
 SPECIES: RAT/FISCHER-344  
 ANIMAL NUMBER: 232/PRETEST= 232 SEX: FEMALE DOSE GROUP: 1 SACRIFICE STATUS: SACRIFICED MORIBUND  
 DATE OF DEATH: 15-NOV-85 STUDY DAY OF DEATH: 663 STUDY WEEK OF DEATH: 95 TERMINAL BODY WEIGHT: 270.00 (GMS)  
 TISSUE / HISTOPATHOLOGIC FINDINGS << M I C R O S C O P I C T I S S U E O B S E R V A T I O N S >>  
 STUDY START DATE: 23-JAN-84 STUDY TYPE: CHRONIC/2 YR CARCINOGENIC  
 INDIVIDUAL ANIMAL DATA REPORT  
 STUDY NUMBER: GLP83009  
 PRINTED: 21-NOV-89  
 PAGE: 467

LIVER .....  
 -HEPATOCYTTIC VACUOLIZATION .....  
 -NECROSIS .....  
 -M- HEPATOCELLULAR CARCINOMA .....  
 KIDNEY .....  
 -PROGRESSIVE RENAL DISEASE .....  
 -M- PRESENCE OF METASTATIC NEOPLASM .....  
 UTERUS .....  
 DUODENUM .....  
 -M- PRESENCE OF METASTATIC NEOPLASM .....  
 JEJUNUM .....  
 -MUCOSAL EROSION/ULCERATION .....  
 -M- PRESENCE OF METASTATIC NEOPLASM .....  
 PANCREAS .....  
 -M- PRESENCE OF METASTATIC NEOPLASM .....  
 STOMACH .....  
 -ULCERATION, NON-GLANDULAR AREA .....  
 -MUCOSAL AND/OR SUBMUCOSAL EDEMA .....  
 MAMMARY GLANDS .....  
 -HYPERPLASIA AND/OR HYPERTROPHY OF THE ACINAR TISSUE .....  
 -DILATATION (ECTASIA) OF DUCTS AND DUCTULES .....  
 NOSE/TURBINATES .....  
 -MIXED INFLAMMATORY CELL INFILTRATION, NASAL CAVITY, SINUSES, .....  
 TURBINATES, NASO-LACRIMAL DUCTS .....  
 ADRENAL .....  
 DIFFUSE(MARKED)  
 MULTI-FOCAL(MILD)  
 (PRESENT)  
 NOT SPECIFIED(TRACE)  
 SECONDARY NEOPLASM FROM ORGAN LIVER  
 NO HISTOLOGIC LESION WAS FOUND THAT CORRESPONDED TO THE MASS DESCRIBED GROSSLY. A THOROUGH SEARCH OF FORMALIN-FIXED TISSUE FOR THIS LESION WAS UNSUCCESSFUL.  
 SECONDARY NEOPLASM FROM ORGAN LIVER  
 NOT SPECIFIED (PRESENT)  
 SECONDARY NEOPLASM FROM ORGAN LIVER  
 SECONDARY NEOPLASM FROM ORGAN LIVER  
 NOT SPECIFIED (PRESENT)  
 NOT SPECIFIED (PRESENT)  
 NOT SPECIFIED(MARKED)  
 NOT SPECIFIED (PRESENT)  
 CELLULAR INFILTRATE IS ADJACENT NASO-LACRIMAL DUCT.  
 NOT SPECIFIED(MILD)

Appendix J (cont.): PATHOLOGY INDIVIDUAL ANIMAL DATA

LETTERMAN ARMY INSTITUTE OF RESEARCH  
DIV OF RES SUPP, PATH SERV GP  
SPECIES: RAT/FISCHER-344

INDIVIDUAL ANIMAL DATA REPORT  
STUDY NUMBER: GLP83009  
STUDY START DATE: 23-JAN-84

PRINTED: 21-NOV-89  
PAGE: 468  
STUDY TYPE: CHRONIC/2 YR CARCINOGENIC

ANIMAL NUMBER: 232/PRETEST= 232 SEX: FEMALE DOSE GROUP: 1 SACRIFICE STATUS: SACRIFICED MORIBUND  
DATE OF DEATH: 15-NOV-85 STUDY DAY OF DEATH: 663 STUDY WEEK OF DEATH: 95 TERMINAL BODY WEIGHT: 270.00 (GMS)

<< M I C R O S C O P I C T I S S U E O B S E R V A T I O N S >>  
TISSUE / HISTOPATHOLOGIC FINDINGS ..... DISTRIBUTION (SEVERITY) / SPECIAL COMMENTS .....

ADRENAL ..... NOT SPECIFIED (PRESENT)  
-CORTICAL MODULAR HYPERPLASIA ..... NOT SPECIFIED (PRESENT)  
-EXTRAMEDULLARY HEMATOPOIESIS

DIAPHRAGM ..... MISCELLANEOUS TISSUE  
-COMPOUND RELATED INFLAMMATORY REACTION ..... NOT SPECIFIED (PRESENT)  
-M- PRESENCE OF METASTATIC NEOPLASM ..... SECONDARY NEOPLASM FROM ORGAN LIVER

**Appendix J (cont.): PATHOLOGY INDIVIDUAL ANIMAL DATA**

LETTERMAN ARMY INSTITUTE OF RESEARCH  
 DIV OF RES SUPP, PATH SERV GP  
 SPECIES: RAT/FISCHER-344  
 STUDY START DATE: 23-JAN-84  
 STUDY NUMBER: GLP83009  
 PRINTED: 21-NOV-89  
 PAGE: 469  
 STUDY TYPE: CHRONIC/2 YR CARCINOGENIC  
 ANIMAL NUMBER: 233/PRETEST-233 SEX: FEMALE DOSE GROUP: 1 SACRIFICE STATUS: FINAL SACRIFICE  
 DATE OF DEATH: 10-FEB-86 STUDY DAY OF DEATH: 750 STUDY WEEK OF DEATH: 108 TERMINAL BODY WEIGHT: 258.00 (GMS)

<< GROSS ORGAN OBSERVATIONS >>  
 SEVERITY GROSS FREE-TEXT COMMENTS  
 LIVER ADHESION(S) PRESENT DIAPHRAGM, VENTRAL ABDOMINAL WALL  
 UTERUS CYST(S) PRESENT DISTAL LEFT HORN, .4CM DIAMETER

<< MICROSCOPIC TISSUE OBSERVATIONS >>  
 DISTRIBUTION (SEVERITY) / SPECIAL COMMENTS

HEART  
 -CARDIOMYOPATHY NOT SPECIFIED (TRACE)

SPLEEN  
 -MEMOSIDERIN PIGMENTATION (RED PULP) NOT SPECIFIED (PRESENT)

LYMPH NODES  
 -RED BLOOD CELLS, MEMOSIDERIN AND/OR ERYTHROPHAGOCYTOSIS WITHIN MEDULLARY SINUSES RBC'S PRESENT IN CERVICAL AND MEDIASTINAL NODES.  
 NOT SPECIFIED (PRESENT)

LIVER  
 -COMPOUND RELATED INFLAMMATORY REACTION NOT SPECIFIED (PRESENT)  
 -BILE DUCTULE EPITHELIAL HYPERPLASIA AND/OR CHOLANGIOFIBROSIS NOT SPECIFIED (MILD)  
 -HEPATITIS MULTI-FOCAL (TRACE)  
 -FOCUS OF CELLULAR ALTERATION - BASOPHILIC MULTI-FOCAL (MILD)  
 -HEPATOCTYIC VACUOLIZATION MULTI-FOCAL (TRACE)  
 -CYSTIC DEGENERATION NOT SPECIFIED (PRESENT)  
 -HEPATOCTYIC COALESCING MICROVESICULAR (FATTY) CHANGE LEADING TO NECROSIS AND MINERALIZATION MULTI-FOCAL (MILD)

KIDNEY  
 -PROGRESSIVE RENAL DISEASE NOT SPECIFIED (TRACE)

UTERUS  
 -CYSTIC DILATATION OF THE ENDOMETRIAL GLANDS FOCAL (PRESENT)

MAMMARY GLANDS

Appendix J (cont.): PATHOLOGY INDIVIDUAL ANIMAL DATA

LETTERMAN ARMY INSTITUTE OF RESEARCH  
DIV OF RES SUPP, PATH SERV GP  
SPECIES: RAT/FISCHER-344

INDIVIDUAL ANIMAL DATA REPORT  
STUDY NUMBER: GLP83009

PRINTED: 21-NOV-89  
PAGE: 470

STUDY START DATE: 23-JAN-84

STUDY TYPE: CHRONIC/2 YR CARCINOGENIC

ANIMAL NUMBER: 233/PRETEST- 233 SEX: FEMALE DOSE GROUP: 1 SACRIFICE STATUS: FINAL SACRIFICE  
DATE OF DEATH: 10-FEB-86 STUDY DAY OF DEATH: 750 STUDY WEEK OF DEATH: 108 TERMINAL BODY WEIGHT: 258.00 (GMS)

<< M I C R O S C O P I C T I S S U E O B S E R V A T I O N S >>  
TISSUE / HISTOPATHOLOGIC FINDINGS DISTRIBUTION (SEVERITY) / SPECIAL COMMENTS

- MAMMARY GLANDS ..... NOT SPECIFIED(MILD)
- HYPERPLASIA AND/OR HYPERTROPHY OF THE ACINAR TISSUE ..... NOT SPECIFIED (PRESENT)
- DILATATION (ECTASIA) OF DUCTS AND DUCTULES ..... NOT SPECIFIED (PRESENT)
- ADRENAL ..... NOT SPECIFIED(TRACE)
- FOCUS OF CELLULAR ALTERATION, VACUOLATED
- EYES & OPTIC N. ....
- RETINAL ATROPHY AND/OR DEGENERATION, UNILATERAL OR BILATERAL ..... NOT SPECIFIED(TRACE)
- CORNEAL VASCULARIZATION ..... NOT SPECIFIED(TRACE)
- DIAPHRAGM ..... MISCELLANEOUS TISSUE
- COMPOUND RELATED INFLAMMATORY REACTION ..... NOT SPECIFIED (PRESENT)

**Appendix J (cont.): PATHOLOGY INDIVIDUAL ANIMAL DATA**

LETTERMAN ARMY INSTITUTE OF RESEARCH  
 DIV OF RES SUPP, PATH SERV GP  
 SPECIES: RAT/FISCHER-344

PRINTED: 21-NOV-89  
 PAGE: 471

INDIVIDUAL ANIMAL DATA REPORT  
 STUDY NUMBER: GLP83009  
 STUDY START DATE: 23-JAN-84  
 STUDY TYPE: CHRONIC/2 YR CARCINOGENIC

ANIMAL NUMBER: 234/PRETEST-234 SEX: FEMALE DOSE GROUP: 1 SACRIFICE STATUS: SACRIFICED MORIBUND  
 DATE OF DEATH: 30-AUG-85 STUDY DAY OF DEATH: 586 STUDY WEEK OF DEATH: 84 TERMINAL BODY WEIGHT: 265.00 (GMS)

ORGAN NAME << GROSS ORGAN OBSERVATIONS >>  
 SEVERITY GROSS FREE-TEXT COMMENTS

LIVER ADHESION(S) PRESENT DIAPHRAGM, VENTRAL ABDOMINAL WALL, STOMACH  
 LIVER GROWTH(S) / MASS(ES) PRESENT IRREGULAR, SEMI-FIRM, WHITE, 5 X 4 X 4CM  
 KIDNEY DISCOLORATION PRESENT DIFFUSELY BROWN

TISSUE / HISTOPATHOLOGIC FINDINGS << MICROSCOPIC TISSUE OBSERVATIONS >>  
 DISTRIBUTION (SEVERITY) / SPECIAL COMMENTS

HEART  
 -CARDIOMYOPATHY  
 -MEDIAL HYPERTROPHY OF MUSCULAR ARTERIES

LYMPH NODES  
 -RED BLOOD CELLS, HEMOSIDERIN AND/OR ERYTHROPHAGOCYTOSIS WITHIN MEDULLARY SINUSES

LIVER  
 -COMPOUND RELATED INFLAMMATORY REACTION  
 -HEPATITIS  
 -FOCUS OF CELLULAR ALTERATION - BASOPHILIC  
 -N- PRESENCE OF METASTATIC SARCOMA

OVARIES  
 -CYSTIC CORPORA LUTEA

DUODENUM  
 -COMPOUND RELATED INFLAMMATORY REACTION

STOMACH  
 -N- PRESENCE OF METASTATIC SARCOMA

MAMMARY GLANDS  
 -HYPERPLASIA AND/OR HYPERTROPHY OF THE ACINAR TISSUE

NOT SPECIFIED(TRACE)  
 NOT SPECIFIED(TRACE)  
 RBC'S AND PIGMENT PRESENT IN MEDIASTINAL NODE.  
 NOT SPECIFIED (PRESENT)  
 MULTI-FOCAL(MILD)  
 NOT SPECIFIED(MILD)  
 SECONDARY NEOPLASM FROM ORGAN ABDOMINAL CAVITY  
 NOT SPECIFIED (PRESENT)  
 NOT SPECIFIED (PRESENT)  
 (PRESENT)  
 NOT SPECIFIED(MILD)

Appendix J (cont.): PATHOLOGY INDIVIDUAL ANIMAL DATA

LETTERMAN ARMY INSTITUTE OF RESEARCH  
DIV OF RES SUPP, PATM SERV GP  
SPECIES: RAT/FISCHER-344

INDIVIDUAL ANIMAL DATA REPORT  
STUDY NUMBER: GLP83009  
STUDY START DATE: 23-JAN-84

PRINTED: 21-NOV-89  
PAGE: 472

ANIMAL NUMBER: 234/PRETEST= 234 SEX: FEMALE DOSE GROUP: 1 SACRIFICE STATUS: SACRIFICED MORIBUND  
DATE OF DEATH: 30-AUG-85 STUDY DAY OF DEATH: 586 STUDY WEEK OF DEATH: 84 TERMINAL BODY WEIGHT: 265.00 (GMS)  
STUDY TYPE: CHRONIC/2 YR CARCINOGENIC

<< MICROSCOPIC TISSUE OBSERVATIONS >>  
DISTRIBUTION (SEVERITY) / SPECIAL COMMENTS

MAMMARY GLANDS ..... NOT SPECIFIED (PRESENT)  
-DILATATION (ECTASIA) OF DUCTS AND DUCTULES

NOSE/TURBINATES .....  
-MIXED INFLAMMATORY CELL INFILTRATION, NASAL CAVITY, SINUSES, ..... CELLULAR INFILTRATE INVOLVES NASO-LACRIMAL DUCT.  
TURBINATES, NASO-LACRIMAL DUCTS ..... NOT SPECIFIED(MILD)

ADRENAL .....  
-FOCUS OF CELLULAR ALTERATION, VACUOLATED ..... NOT SPECIFIED(TRACE)

PITUITARY GLAND .....  
-B- ADENOMA ..... (PRESENT)

EYES & OPTIC N. ....  
-CORNEAL MINERALIZATION ..... NOT SPECIFIED(TRACE)

ABDOMINAL CAVITY ..... MISCELLANEOUS TISSUE  
THE SARCOMA INVOLVES PRIMARILY LIVER AND STOMACH. THERE ARE  
MANY LARGE AREAS IN WHICH NEOPLASTIC CELLS HAVE MORPHOLOGY  
TYPICAL OF OSTEOBLASTS AND ARE PRODUCING ABUNDANT OSTEOID.  
OSTEOID IS MINERALIZED IN SOME AREAS. IN OTHER AREAS, CELLS ARE  
ANAPLASTIC AND HAVE A HIGH MITOTIC RATE. FOCAL AREAS OF  
NECROSIS ARE PRESENT IN THESE AREAS.  
-M- SARCOMA, CELLULAR DIFFERENTIATION UNSPECIFIED (PRESENT)

DIAPHRAGM ..... MISCELLANEOUS TISSUE  
-COMPOUND RELATED INFLAMMATORY REACTION ..... NOT SPECIFIED (PRESENT)



**Appendix J (cont.): PATHOLOGY INDIVIDUAL ANIMAL DATA**

LETTERMAN ARMY INSTITUTE OF RESEARCH  
 DIV OF RES SUPP, PATH SERV GP  
 SPECIES: RAT/FISCHER-344

INDIVIDUAL ANIMAL DATA REPORT  
 STUDY NUMBER: GLP83009  
 STUDY START DATE: 23-JAN-84

PRINTED: 21-NOV-89  
 PAGE: 474  
 STUDY TYPE: CHRONIC/2 YR CARCINOGENIC

ANIMAL NUMBER: 236/PRETEST-  
 DATE OF DEATH: 30-AUG-85

DOSE GROUP: 1  
 STUDY WEEK OF DEATH: 84

SACRIFICE STATUS: SACRIFICED MORIBUND  
 TERMINAL BODY WEIGHT: 294.00 (GMS)

SEX: FEMALE  
 STUDY DAY OF DEATH: 586

ORGAN OBSERVATIONS  
 SEVERITY GROSS FREE-TEXT COMMENTS

KEYWORDS / PHRASES

SUBCUTANEOUS MASS  
 PARA-OVARIAN CYST(S)  
 GROWTH(S) / MASSES  
 PROMINENT LOBULAR MARKINGS  
 CORNEAL OPACITY  
 ENLARGED

LEFT INGUINAL AREA, 3.5CM DIAMETER  
 LEFT, 3 X 2CM, CLEAR YELLOW FLUID FILLED  
 FIRM, WHITE, LOBULAR, 3 X 3 X 2CM  
 PALE WHITE  
 MULTIPLE, FOCAL, PINPOINT  
 HEMORRHAGIC

TISSUE / HISTOPATHOLOGIC FINDINGS

MICROSCOPIC TISSUE OBSERVATIONS  
 DISTRIBUTION (SEVERITY) / SPECIAL COMMENTS

EXORBITAL LACRIM ..... FOCAL(TRACE)  
 -ACINAR ATROPHY .....  
 HEART ..... NOT SPECIFIED(TRACE)  
 -CARDIOMYOPATHY .....  
 LYMPH NODES ..... RBC'S AND PIGMENT ARE PRESENT IN MEDIASTINAL AND MESENTERIC  
 -RED BLOOD CELLS, HEMOSIDERIN AND/OR ERYTHROPHAGOCYTOSIS WITHIN  
 MEDULLARY SINUSES ..... NOT SPECIFIED (PRESENT)  
 LIVER ..... NOT SPECIFIED (PRESENT)  
 -COMPOUND RELATED INFLAMMATORY REACTION ..... MULTI-FOCAL(TRACE)  
 -HEPATITIS ..... MULTI-FOCAL(MILD)  
 -HEPATOCTIC VACUOLIZATION ..... NOT SPECIFIED(MILD)  
 -HEPATOCTIC DEGENERATIVE CHANGES (NON-NECROTIC) ..... NOT SPECIFIED(MODERATE)  
 -NECROSIS, PERIACINAR ..... SECONDARY NEOPLASM FROM ORGAN  
 -N- PRESENCE OF METASTATIC SARCOMA

KIDNEY ..... NOT SPECIFIED(TRACE)  
 -PROGRESSIVE RENAL DISEASE .....

**Appendix J (cont.): PATHOLOGY INDIVIDUAL ANIMAL DATA**

LETTERMAN ARMY INSTITUTE OF RESEARCH  
 DIV OF RES SUPP, PATH SERV GP  
 SPECIES: RAT/FISCHER-344

INDIVIDUAL ANIMAL DATA REPORT  
 STUDY NUMBER: GLP83009  
 STUDY START DATE: 23-JAN-84

PRINTED: 21-NOV-89  
 PAGE: 475  
 STUDY TYPE: CHRONIC/2 YR CARCINOGENIC

ANIMAL NUMBER: 236/PRETEST-  
 DATE OF DEATH: 30-AUG-85  
 DOSE GROUP: 1  
 SEX: FEMALE  
 STUDY WEEK OF DEATH: 84  
 SACRIFICE STATUS: SACRIFICED MORIBUND  
 TERMINAL BODY WEIGHT: 294.00 (GMS)

<< MICROSCOPIC TISSUE OBSERVATIONS >>  
 DISTRIBUTION (SEVERITY) / SPECIAL COMMENTS

OVARIES ..... THE WALL OF THE PAROVARIAN CYST IS ON SECTIONS #10 AND #24.  
 SECTION #11 (OVARIES) HAS NO LESION.  
 NOT SPECIFIED (PRESENT)

- PARA-OVARIAN CYST(S) .....  
 MAMMARY GLANDS ..... THE SUBCUTANEOUS MASS IN THE INGUINAL AREA IS A MAMMARY  
 FIBROADENOMA.  
 - HYPERPLASIA AND/OR HYPERTROPHY OF THE ACINAR TISSUE  
 - B- FIBROADENOMA NOT SPECIFIED(MODERATE)  
 - DILATATION (ECTASIA) OF DUCTS AND DUCTULES NOT SPECIFIED (PRESENT)

PITUITARY GLAND ..... (PRESENT)  
 - B- ADENOMA

EYES & OPTIC N. .... NOT SPECIFIED(MILD)  
 - CORNEAL MINERALIZATION NOT SPECIFIED(MILD)  
 - CORNEAL VASCULARIZATION

ABDOMINAL CAVITY ..... MISCELLANEOUS TISSUE  
 THE SARCOMA INVOLVES PRIMARILY LIVER AND DIAPHRAGM. NEOPLASTIC  
 CELLS ARE POORLY DIFFERENTIATED AND ANAPLASTIC IN MOST AREAS.  
 - M- SARCOMA, CELLULAR DIFFERENTIATION UNSPECIFIED (PRESENT)

DIAPHRAGM ..... MISCELLANEOUS TISSUE  
 - M- PRESENCE OF METASTATIC SARCOMA SECONDARY NEOPLASM FROM ORGAN ABDOMINAL CAVITY

Appendix J (cont.): PATHOLOGY INDIVIDUAL ANIMAL DATA

LETTERMAN ARMY INSTITUTE OF RESEARCH  
 DIV OF RES SUPP, PATH SERV GP  
 SPECIES: RAT/FISCHER-344  
 ANIMAL NUMBER: 237/PRETEST= 237 SEX: FEMALE DOSE GROUP: 1 SACRIFICE STATUS: SACRIFICED MORIBUND  
 DATE OF DEATH: 19-NOV-85 STUDY DAY OF DEATH: 667 STUDY WEEK OF DEATH: 96 TERMINAL BODY WEIGHT: 290.00 (GMS)  
 STUDY START DATE: 23-JAN-84 STUDY TYPE: CHRONIC/2 YR CARCINOGENIC  
 PRINTED: 21-NOV-89  
 PAGE: 476

<< GROSS ORGAN OBSERVATIONS >>  
 SEVERITY GROSS FREE-TEXT COMMENTS  
 LIVER ADHESION(S) PRESENT DIAPHRAGM, VENTRAL ABDOMINAL WALL  
 LIVER PROMINENT LOBULAR MARKINGS PRESENT  
 LIVER GRANULAR SURFACE PRESENT  
 SPLEEN ENLARGED (SPLENOMEGALY) MARKED 7 X 2.5 X 1CM  
 PERITONEAL CAV. FLUID-FILLED PRESENT 3ML RED FLUID  
 JEJUNUM ENLARGED PRESENT 2 X 2 X 1.5CM, 12CM FROM STOMACH

<< MICROSCOPIC TISSUE OBSERVATIONS >>  
 DISTRIBUTION (SEVERITY) / SPECIAL COMMENTS

THYROID GLANDS ..... NOT SPECIFIED (TRACE)  
 -PARA-FOLLICULAR CELL HYPERPLASIA ("C" CELL, LIGHT CELL)  
 EXORBITAL LACRIM ..... FOCAL (TRACE)  
 -ACINAR ATROPHY .....  
 HEART ..... NOT SPECIFIED (MILD)  
 -CARDIOMYOPATHY .....  
 SPLEEN ..... FOCAL (TRACE)  
 -FIBROSIS CAPSULAR ..... NOT SPECIFIED (PRESENT)  
 -EXTRAMEDULLARY HEMATOPOIESIS .....  
 LYMPH NODES ..... REACTIVE HYPERPLASIA NOTED IN CERVICAL NODES.  
 -REACTIVE HYPERPLASIA ..... NOT SPECIFIED (PRESENT)  
 LIVER ..... NOT SPECIFIED (PRESENT)  
 -COMPOUND RELATED INFLAMMATORY REACTION ..... MULTI-FOCAL (MILD)  
 -HEPATITIS ..... FOCAL (TRACE)  
 -FOCUS OF CELLULAR ALTERATION - BASOPHILIC  
 KIDNEY .....

Appendix J (cont.): PATHOLOGY INDIVIDUAL ANIMAL DATA

LETTERMAN ARMY INSTITUTE OF RESEARCH
INDIVIDUAL ANIMAL DATA REPORT
DIV OF RES SUPP, PATH SERV GP
STUDY NUMBER: GLP83009
SPECIES: RAT/FISCHER-344
STUDY START DATE: 23-JAN-84
PRINTED: 21-NOV-89
PAGE: 477
STUDY TYPE: CHRONIC/2 YR CARCINOGENIC
ANIMAL NUMBER: 237/PRETEST=
DOSE GROUP: 1
SACRIFICE STATUS: SACRIFICED MORIBUND
DATE OF DEATH: 19-NOV-85
STUDY DAY OF DEATH: 667
STUDY WEEK OF DEATH: 96
TERMINAL BODY WEIGHT: 290.00 (GMS)
TISSUE / HISTOPATHOLOGIC FINDINGS
<< M I C R O S C O P I C T I S S U E O B S E R V A T I O N S >>
DISTRIBUTION (SEVERITY) / SPECIAL COMMENTS

KIDNEY
-PROGRESSIVE RENAL DISEASE
NOT SPECIFIED(TRACE)

JEJUNUM
LESIONS CODED FOR JEJUNUM ARE FROM THE FOCAL AREA DESCRIBED AS AN "ENLARGED" AREA 12 CM FROM THE CECUM. THESE LESIONS ARE ON SECTION #21. SECTION OF JEJUNUM ON SLIDE #12 IS ESSENTIALLY NORMAL.

- COMPOUND RELATED INFLAMMATORY REACTION
-ENTERITIS, SUBACUTE
-MUCOSAL EROSION/ULCERATION
-PRESENCE OF MUCOSAL EPITHELIAL CELLS WITHIN INTESTINAL WALL AND ADJACENT FIBROUS/GRANULOMATOUS INFLAMMATORY REACTION
-FIBROVASCULAR ADHESION, SEROSA
NOT SPECIFIED (PRESENT)
NOT SPECIFIED (MODERATE)
NOT SPECIFIED (PRESENT)
NOT SPECIFIED (PRESENT)
NOT SPECIFIED (PRESENT)

PANCREAS
PANCREATIC LESIONS NOTED ADJACENT TO "ENLARGED" AREA OF SMALL INTESTINE WHICH CONSISTS OF COMPOUND-RELATED INFLAMMATORY REACTION AND ADHESIONS.
DIFFUSE(MILD)
NOT SPECIFIED (PRESENT)

- MAMMARY GLANDS
-HYPERPLASIA AND/OR HYPERTROPHY OF THE ACINAR TISSUE
-DILATATION (ECTASIA) OF DUCTS AND DUCTULES
NOT SPECIFIED (MILD)
NOT SPECIFIED (PRESENT)

BONE, FEMUR
-HYPERPLASIA MYELOID
NOT SPECIFIED (PRESENT)

BONE VERT
-HYPERPLASIA, MYELOID
NOT SPECIFIED (PRESENT)

PITUITARY GLAND
-B- ADENOMA
(PRESENT)

EYES & OPTIC N.

Appendix J (cont.): PATHOLOGY INDIVIDUAL ANIMAL DATA

LETTERMAN ARMY INSTITUTE OF RESEARCH  
DIV OF RES SUPP, PATH SERV GP  
SPECIES: RAT/FISCHER-344

INDIVIDUAL ANIMAL DATA REPORT  
STUDY NUMBER: GLP83009  
STUDY START DATE: 23-JAN-84

PRINTED: 21-NOV-89  
PAGE: 478

STUDY TYPE: CHRONIC/2 YR CARCINOGENIC

ANIMAL NUMBER: 237/PRETEST-237 SEX: FEMALE DOSE GROUP: 1 SACRIFICE STATUS: SACRIFICED MORIBUND  
DATE OF DEATH: 19-NOV-85 STUDY DAY OF DEATH: 667 STUDY WEEK OF DEATH: 96 TERMINAL BODY WEIGHT: 290.00 (GMS)

<< MICROSCOPIC TISSUE OBSERVATIONS >>  
DISTRIBUTION (SEVERITY) / SPECIAL COMMENTS

EYES & OPTIC N. .... NOT SPECIFIED (TRACE)  
-CORNEAL MINERALIZATION NOT SPECIFIED (TRACE)  
-CORNEAL VASCULARIZATION

DIAPHRAGM ..... MISCELLANEOUS TISSUE  
-COMPOUND RELATED INFLAMMATORY REACTION NOT SPECIFIED (PRESENT)

Appendix J (cont.): PATHOLOGY INDIVIDUAL ANIMAL DATA

LETTERMAN ARMY INSTITUTE OF RESEARCH  
DIV OF RES SUPP, PATH SERV GP  
SPECIES: RAY/FISCHER-344  
STUDY NUMBER: GLP83009  
STUDY START DATE: 23-JAN-84  
STUDY TYPE: CHRONIC/2 YR CARCINOGENIC  
PRINTED: 21-NOV-89  
PAGE: 480

ANIMAL NUMBER: 239/PRETEST= 239 SEX: FEMALE DOSE GROUP: 1 SACRIFICE STATUS: FINAL SACRIFICE  
DATE OF DEATH: 12-FEB-86 STUDY DAY OF DEATH: 752 STUDY WEEK OF DEATH: 108 TERMINAL BODY WEIGHT: 306.00 (GMS)

ORGAN NAME << GROSS ORGAN OBSERVATIONS >>  
SEVERITY GROSS FREE-TEXT COMMENTS  
LIVER PRESENT DIAPHRAGM, VENTRAL ABDOMINAL WALL  
ADHESION(S) PRESENT INTESTINES ADHERED TO THEMSELVES AND ABDOMINAL WALL  
PERITONEAL CAV. PRESENT MULTIPLE, RAISED, FOCAL, LEFT  
EYES & OPTIC N. PRESENT CORNEAL OPACITY RIGHT, CLEAR  
OVARIES PRESENT CYST(S) WITHIN OVARY  
PITUITARY GLAND PRESENT FOCAL, BLACK, .2CM DIAMETER DISCOLORATION

TISSUE / HISTOPATHOLOGIC FINDINGS << MICROSCOPIC TISSUE OBSERVATIONS >>  
DISTRIBUTION (SEVERITY) / SPECIAL COMMENTS

THYROID GLANDS ..... (PRESENT)  
-B- PARA-FOLLICULAR CELL ADENOMA

EXORBITAL LACRIM ..... FOCAL(TRACE)  
-ACINAR ATROPHY

HEART ..... NOT SPECIFIED(MILD)  
-CARDIOMYOPATHY

LUNGS ..... NOT SPECIFIED(TRACE)  
-MINERALIZATION OF PULMONARY ARTERIES

LYMPH NODES ..... REACTIVE HYPERPLASIA NOTED IN CERVICAL NODE.  
-REACTIVE HYPERPLASIA

LIVER ..... NOT SPECIFIED (PRESENT)  
-COMPOUND RELATED INFLAMMATORY REACTION NOT SPECIFIED(TRACE)  
-BILE DUCTULE EPITHELIAL HYPERPLASIA AND/OR CHOLANGIOFIBROSIS MULTI-FOCAL(MILD)  
-HEPATITIS MULTI-FOCAL(MILD)  
-FOCUS OF CELLULAR ALTERATION - BASOPHILIC MULTI-FOCAL(TRACE)  
-BENIGN HYPERPLASTIC MODULE(S) MULTI-FOCAL(MILD)  
-HEPATOCTYE COALESCING MICROVESICULAR (FATTY) CHANGE LEADING TO NECROSIS AND MINERALIZATION

KIDNEY .....

Appendix J (cont.): PATHOLOGY INDIVIDUAL ANIMAL DATA

LETTERMAN ARMY INSTITUTE OF RESEARCH  
 D'V OF RES SUPP, PATH SERV GP  
 SPECIES: RAT/FISCHER-344  
 STUDY START DATE: 23-JAN-84  
 STUDY NUMBER: GLP03009  
 PRINTED: 21-NOV-89  
 PAGE: 481  
 STUDY TYPE: CHRONIC/2 YR CARCINOGENIC  
 ANIMAL NUMBER: 239/PRETEST= 239 SEX: FEMALE DOSE GROUP: 1 SACRIFICE STATUS: FINAL SACRIFICE  
 DATE OF DEATH: 12-FEB-86 STUDY DAY OF DEATH: 752 STUDY WEEK OF DEATH: 108 TERMINAL BODY WEIGHT: 306.00 (GMS)  
 TISSUE / HISTOPATHOLOGIC FINDINGS << M I C R O S C O P I C T I S S U E O B S E R V A T I O N S >>  
 DISTRIBUTION (SEVERITY) / SPECIAL COMMENTS

- KIDNEY ..... NOT SPECIFIED (TRACE)
- PROGRESSIVE RENAL DISEASE
- OVARIES ..... NOT SPECIFIED (PRESENT)
- PARA-OVARIAN CYST(S)
- JEJUNUM ..... NOT SPECIFIED (PRESENT)
- COMPOUND RELATED INFLAMMATORY REACTION
- PRESENCE OF MUCOSAL EPITHELIAL CELLS WITHIN INTESTINAL WALL AND ADJACENT FIBROUS/GRANULOMATOUS INFLAMMATORY REACTION
- ILEUM ..... NOT SPECIFIED (PRESENT)
- COMPOUND RELATED INFLAMMATORY REACTION
- PANCREAS ..... MULTI-FOCAL (MILD)
- ACINAR (EXOCRINE) ATROPHY
- STOMACH ..... NOT SPECIFIED (PRESENT)
- COMPOUND RELATED INFLAMMATORY REACTION
- MAMMARY GLANDS ..... NOT SPECIFIED (MILD)
- HYPERPLASIA AND/OR HYPERTROPHY OF THE ACINAR TISSUE
- DILATATION (ECTASIA) OF DUCTS AND DUCTULES
- ADRENAL ..... MULTI-FOCAL (MILD)
- LIPIDOSIS
- PITUITARY GLAND ..... NOT SPECIFIED (PRESENT)
- CYST(S)
- HEMORRHAGE
- EYES & OPTIC N. .... NOT SPECIFIED (PRESENT)

Appendix J (cont.): PATHOLOGY INDIVIDUAL ANIMAL DATA

LETTERMAN ARMY INSTITUTE OF RESEARCH  
DIV OF RES SUPP, PATH SERV GP  
SPECIES: RAT/FISCHER-344

INDIVIDUAL ANIMAL DATA REPORT  
STUDY NUMBER: GLP83009  
STUDY START DATE: 23-JAN-84

PRINTED: 21-NOV-89  
PAGE: 482

STUDY TYPE: CHRONIC/2 YR CARCINOGENIC

ANIMAL NUMBER: 239/PRETEST-  
DATE OF DEATH: 12-FEB-86  
STUDY DAY OF DEATH: 752  
SEX: FEMALE  
DOSE GROUP: 1  
STUDY WEEK OF DEATH: 108  
SACRIFICE STATUS: FINAL SACRIFICE  
TERMINAL BODY WEIGHT: 306.00 (GMS)

<< MICROSCOPIC TISSUE OBSERVATIONS >>  
TISSUE / HISTOPATHOLOGIC FINDINGS DISTRIBUTION (SEVERITY) / SPECIAL COMMENTS

- EYES & OPTIC N. ....
- CORNEAL MINERALIZATION .....
- RETINAL ATROPHY AND/OR DEGENERATION, UNILATERAL OR BILATERAL .....
- CORNEAL VASCULARIZATION .....
- LENTICULAR DEGENERATIVE CHANGES COMPATIBLE WITH CATARACT .....
- DIAPHRAGM .....
- COMPOUND RELATED INFLAMMATORY REACTION .....
- FOCAL(TRACE) .....
- NOT SPECIFIED(MILD) .....
- NOT SPECIFIED(MILD) .....
- NOT SPECIFIED (PRESENT) .....
- MISCELLANEOUS TISSUE .....
- NOT SPECIFIED (PRESENT) .....



Appendix J (cont.): PATHOLOGY INDIVIDUAL ANIMAL DATA

LETTERMAN ARMY INSTITUTE OF RESEARCH  
 DIV OF RES SUPP, PATH SERV GP  
 SPECIES: RAT/FISCHER-344

PRINTED: 21-NOV-89  
 PAGE: 483

INDIVIDUAL ANIMAL DATA REPORT  
 STUDY NUMBER: GLP83009  
 STUDY START DATE: 23-JAN-84

ANIMAL NUMBER: 240/PRETEST-240 SEX: FEMALE DOSE GROUP: 1 SACRIFICE STATUS: FINAL SACRIFICE  
 DATE OF DEATH: 12-FEB-86 STUDY DAY OF DEATH: 752 STUDY WEEK OF DEATH: 108 TERMINAL BODY WEIGHT: 241.00 (GMS)

ORGAN NAME: << GROSS ORGAN OBSERVATIONS >>  
 KEYWORDS / PHRASES: SEVERITY GROSS FREE-TEXT COMMENTS  
 LIVER: PRESENT STOMACH, INTESTINES, DIAPHRAGM, VENTRAL ABDOMINAL WALL

TISSUE / HISTOPATHOLOGIC FINDINGS: << MICROSCOPIC TISSUE OBSERVATIONS >>  
 DISTRIBUTION (SEVERITY) / SPECIAL COMMENTS

HEART ..... NOT SPECIFIED (MILD)  
 -CARDIOMYOPATHY

LUNGS ..... NOT SPECIFIED (MILD)  
 -PNEUMONIA, INTERSTITIAL, CHRONIC

SPLEEN ..... NOT SPECIFIED (PRESENT)  
 -EXTRAMEDULLARY HEMATOPOIESIS

LYMPH NODES ..... RBC'S AND PIGMENT NOTED IN MEDIASTINAL NODE.  
 -RED BLOOD CELLS, HEMOSIDERIN AND/OR ERYTHROPHAGOCYTOSIS WITHIN  
 MEDULLARY SINUSES

LIVER ..... NOT SPECIFIED (PRESENT)  
 -COMPOUND RELATED INFLAMMATORY REACTION  
 -FOCUS OF CELLULAR ALTERATION - EOSINOPHILIC CELLS  
 -HEPATOCTYE COALESCING MICROVESICULAR (FATTY) CHANGE LEADING TO  
 NECROSIS AND MINERALIZATION

KIDNEY ..... NOT SPECIFIED (TRACE)  
 -PROGRESSIVE RENAL DISEASE

JEJUNUM ..... NOT SPECIFIED (PRESENT)  
 -COMPOUND RELATED INFLAMMATORY REACTION

NOSE/TURBINATES ..... CELLULAR INFILTRATE INVOLVES NASO-LACRIMAL DUCT.  
 -MIXED INFLAMMATORY CELL INFILTRATION, NASAL CAVITY, SINUSES,  
 TURBINATES, NASO-LACRIMAL DUCTS

EYES & OPTIC N. .... NOT SPECIFIED (TRACE)

Appendix J (cont.): PATHOLOGY INDIVIDUAL ANIMAL DATA

LETTERMAN ARMY INSTITUTE OF RESEARCH  
 DIV OF RES SUPP, PATH SERV GP  
 SPECIES: RAT/FISCHER-344  
 STUDY START DATE: 23-JAN-84  
 STUDY NUMBER: GLP83009  
 PRINTED: 21-NOV-89  
 PAGE: 484

ANIMAL NUMBER: 240/PRETEST-  
 DATE OF DEATH: 12-FEB-86  
 STUDY DAY OF DEATH: 752  
 SEX: FEMALE  
 DOSE GROUP: 1  
 SACRIFICE STATUS: FINAL SACRIFICE  
 STUDY WEEK OF DEATH: 108  
 TERMINAL BODY WEIGHT: 241.00 (GMS)

<< MICROSCOPIC TISSUE OBSERVATIONS >>  
 DISTRIBUTION (SEVERITY) / SPECIAL COMMENTS

EYES & OPTIC N. .... NOT SPECIFIED(TRACE)  
 -CORNEAL VASCULARIZATION

DIAPHRAGM ..... MISCELLANEOUS TISSUE  
 -COMPOUND RELATED INFLAMMATORY REACTION ..... NOT SPECIFIED (PRESENT)

Appendix J (cont.): PATHOLOGY INDIVIDUAL ANIMAL DATA

LETTERMAN ARMY INSTITUTE OF RESEARCH  
 DIV OF RES SUPP, PATH SERV GP  
 SPECIES: RAT/FISCHER-344  
 STUDY START DATE: 23-JAN-84  
 STUDY NUMBER: GLP83009  
 PRINTED: 21-NOV-89  
 PAGE: 485  
 STUDY TYPE: CHRONIC/2 YR CARCINOGENIC

ANIMAL NUMBER: 241/PRETEST= 241 SEX: FEMALE DOSE GROUP: 1 SACRIFICE STATUS: FINAL SACRIFICE  
 DATE OF DEATH: 12-FEB-86 STUDY DAY OF DEATH: 752 STUDY WEEK OF DEATH: 108 TERMINAL BODY WEIGHT: 265.00 (GMS)

<< GROSS ORGAN OBSERVATIONS >>  
 SEVERITY GROSS FREE-TEXT COMMENTS  
 PRESENT STOMACH, INTESTINES, DIAPHRAGM, VENTRAL ABDOMINAL WALL

<< MICROSCOPIC TISSUE OBSERVATIONS >>  
 DISTRIBUTION (SEVERITY) / SPECIAL COMMENTS

- EXORBITAL LACRIM ..... MULTI-FOCAL(MILD)
- ACINAR ATROPHY .....
- LYMPH NODES .....
- RED BLOOD CELLS, HEMOSIDERIN AND/OR ERYTHROPHAGOCYTOSIS WITHIN  
 MEDULLARY SINUSES  
 -REACTIVE HYPERPLASIA .....
- LIVER .....
- COMPOUND RELATED INFLAMMATORY REACTION .....
- BILE DUCTULE EPITHELIAL HYPERPLASIA AND/OR CHOLANGIOFIBROSIS .....
- HEPATITIS .....
- HEPATOCYTE COALESCING MICROVESICULAR (FATTY) CHANGE LEADING TO  
 NECROSIS AND MINERALIZATION .....
- KIDNEY .....
- PROGRESSIVE RENAL DISEASE .....
- UTERUS .....
- CYSTIC DILATATION OF THE ENDOMETRIAL GLANDS .....
- DUODENUM .....
- COMPOUND RELATED INFLAMMATORY REACTION .....
- JEJUNUM .....
- COMPOUND RELATED INFLAMMATORY REACTION .....
- PANCREAS .....

REACTIVE HYPERPLASIA NOTED IN CERVICAL NODES.  
 RBC'S AND PIGMENT NOTED IN MEDIASTINAL NODE.  
 NOT SPECIFIED (PRESENT)  
 NOT SPECIFIED (PRESENT)  
 NOT SPECIFIED (PRESENT)  
 NOT SPECIFIED (MILD)  
 MULTI-FOCAL(MILD)  
 MULTI-FOCAL(MODERATE)  
 NOT SPECIFIED(TRACE)  
 NOT SPECIFIED (PRESENT)  
 NOT SPECIFIED (PRESENT)  
 NOT SPECIFIED (PRESENT)  
 NOT SPECIFIED (PRESENT)

Appendix J (cont.): PATHOLOGY INDIVIDUAL ANIMAL DATA

LETTERMAN ARMY INSTITUTE OF RESEARCH  
DIV OF RES SUPP, PATH SERV GP  
SPECIES: RAT/FISCHER-344

INDIVIDUAL ANIMAL DATA REPORT  
STUDY NUMBER: GLP83009  
STUDY START DATE: 23-JAN-84

PRINTED: 21-NOV-89  
PAGE: 486

STUDY TYPE: CHRONIC/2 YR CARCINOGENIC

ANIMAL NUMBER: 241/PRETEST- 241 SEX: FEMALE DOSE GROUP: 1 SACRIFICE STATUS: FINAL SACRIFICE  
DATE OF DEATH: 12-FEB-86 STUDY DAY OF DEATH: 752 STUDY WEEK OF DEATH: 108 TERMINAL BODY WEIGHT: 265.00 (GMS)

<< M I C R O S C O P I C T I S S U E O B S E R V A T I O N S >>  
TISSUE / HISTOPATHOLOGIC FINDINGS DISTRIBUTION (SEVERITY) / SPECIAL COMMENTS

PANCREAS ..... FOCAL (TRACE)  
-ACINAR (EXOCRINE) ATROPHY

STOMACH ..... NOT SPECIFIED (PRESENT)  
-COMPOUND RELATED INFLAMMATORY REACTION

MAMMARY GLANDS ..... NOT SPECIFIED (MILD)  
-HYPERPLASIA AND/OR HYPERTROPHY OF THE ACINAR TISSUE

NOSE/TURBINATES ..... CELLULAR INFILTRATE INVOLVES NASO-LACRIMAL DUCTS BILATERALLY.  
-MIXED INFLAMMATORY CELL INFILTRATION, NASAL CAVITY, SINUSES, NOT SPECIFIED (MILD)  
TURBINATES, NASO-LACRIMAL DUCTS

EYES & OPTIC N. .... NOT SPECIFIED (PRESENT)  
-METAPLASTIC BONE FORMATION AND/OR MINERALIZATION, SCLERA

DIAPHRAGM ..... MISCELLANEOUS TISSUE  
-COMPOUND RELATED INFLAMMATORY REACTION NOT SPECIFIED (PRESENT)

Appendix J (cont.): PATHOLOGY INDIVIDUAL ANIMAL DATA

LETTERMAN ARMY INSTITUTE OF RESEARCH  
 DIV OF RES SUPP, PATH SERV GP  
 SPECIES: RAT/FISCHER-344

INDIVIDUAL ANIMAL DATA REPORT  
 STUDY NUMBER: GLP83009  
 STUDY START DATE: 23-JAN-84

PRINTED: 21-NOV-89  
 PAGE: 487  
 STUDY TYPE: CHRONIC/2 YR CARCINOGENIC

ANIMAL NUMBER: 242/PRETEST= 242 SEX: FEMALE DOSE GROUP: 1 SACRIFICE STATUS: SACRIFICED MORIBUND  
 DATE OF DEATH: 17-JAN-86 STUDY DAY OF DEATH: 726 STUDY WEEK OF DEATH: 104 TERMINAL BODY WEIGHT: 222.00 (GMS)

<< GROSS ORGAN OBSERVATIONS >>  
 SEVERITY GROSS FREE-TEXT COMMENTS

ORGAN NAME KEYWORDS / PHRASES PRESENT RED  
 EYES & OPTIC N. CRUSTY MATERIAL, PERIORBITAL PRESENT FOCAL, MULTIPLE, .1-.2CM DIAMETER, YELLOW, SUBCAPSULAR  
 LIVER DISCOLORATION

<< MICROSCOPIC TISSUE OBSERVATIONS >>  
 DISTRIBUTION (SEVERITY) / SPECIAL COMMENTS

TISSUE / HISTOPATHOLOGIC FINDINGS

PARATHYROID ..... TISSUE IS MISSING

HEART .....  
 -CARDIOMYOPATHY ..... NOT SPECIFIED(MILD)  
 -MEDIAL HYPERTROPHY OF MUSCULAR ARTERIES ..... NOT SPECIFIED(TRACE)

LYMPH NODES ..... REACTIVE HYPERPLASIA PRESENT IN CERVICAL AND MESENTERIC NODES.  
 -REACTIVE HYPERPLASIA ..... NOT SPECIFIED (PRESENT)

LIVER .....  
 -COMPOUND RELATED INFLAMMATORY REACTION ..... NOT SPECIFIED (PRESENT)  
 -BILE DUCTULE EPITHELIAL HYPERPLASIA AND/OR CHOLANGIOFIBROSIS ..... MULTI-FOCAL(TRACE)  
 -HEPATITIS ..... NOT SPECIFIED(TRACE)  
 -FOCUS OF CELLULAR ALTERATION - BASOPHILIC ..... MULTI-FOCAL(TRACE)  
 -HEPATOCTYIC VACUOLIZATION

KIDNEY .....  
 -PROGRESSIVE RENAL DISEASE ..... NOT SPECIFIED(MILD)

MAMMARY GLANDS .....  
 -HYPERPLASIA AND/OR HYPERTROPHY OF THE ACIMAR TISSUE ..... NOT SPECIFIED(MARKED)  
 -DILATATION (ECTASIA) OF DUCTS AND DUCTULES ..... NOT SPECIFIED (PRESENT)

ADRENAL .....  
 - FOCUS OF CELLULAR ALTERATION, VACUOLATED ..... NOT SPECIFIED(TRACE)  
 -CORTICAL MODULAR HYPERPLASIA ..... NOT SPECIFIED (PRESENT)

EYES & OPTIC N. ....

Appendix J (cont.): PATHOLOGY INDIVIDUAL ANIMAL DATA

LETTERMAN ARMY INSTITUTE OF RESEARCH  
DIV OF RES SUPP, PATH SERV GP  
SPECIES: RAT/FISCHER-344

INDIVIDUAL ANIMAL DATA REPORT  
STUDY NUMBER: GLP83009  
STUDY START DATE: 23-JAN-84

PRINTED: 21-NOV-89  
PAGE: 488

STUDY TYPE: CHRONIC/2 YR CARCINOGENIC

ANIMAL NUMBER: 242/PRETEST=  
DATE OF DEATH: 17-JAN-86

242 SEX: FEMALE  
STUDY DAY OF DEATH: 726

DOSE GROUP: 1  
STUDY WEEK OF DEATH: 104

SACRIFICE STATUS: SACRIFICED MORIBUND  
TERMINAL BODY WEIGHT: 222.00 (GMS)

TISSUE / HISTOPATHOLOGIC FINDINGS

<< MICROSCOPIC TISSUE OBSERVATIONS >>  
DISTRIBUTION (SEVERITY) / SPECIAL COMMENTS

EYES & OPTIC N.

- CORNEAL VASCULARIZATION
- METAPLASTIC BONE FORMATION AND/OR MINERALIZATION, SCLERA

- NOT SPECIFIED (TRACE)
- NOT SPECIFIED (PRESENT)

DIAPHRAGM

- COMPOUND RELATED INFLAMMATORY REACTION

- MISCELLANEOUS TISSUE
- NOT SPECIFIED (PRESENT)

**Appendix J (cont.): PATHOLOGY INDIVIDUAL ANIMAL DATA**

LETTERMAN ARMY INSTITUTE OF RESEARCH  
 DIV OF RES SUPP, PATH SERV GP  
 SPECIES: RAT/FISCHER-344

INDIVIDUAL ANIMAL DATA REPORT  
 STUDY NUMBER: GLP83009  
 STUDY START DATE: 23-JAN-84

PRINTED: 21-NOV-89  
 PAGE: 489

STUDY TYPE: CHRONIC/2 YR CARCINOGENIC

ANIMAL NUMBER: 243/PRETEST= 243 SEX: FEMALE DOSE GROUP: 1 SACRIFICE STATUS: FINAL SACRIFICE  
 DATE OF DEATH: 12-FEB-86 STUDY DAY OF DEATH: 752 STUDY WEEK OF DEATH: 108 TERMINAL BODY WEIGHT: 228.00 (GMS)

<< GROSS ORGAN OBSERVATIONS >>

ORGAN NAME SEVERITY GROSS FREE-TEXT COMMENTS

LIVER ADMESION(S) PRESENT DIAPHRAGM, STOMACH, VENTRAL ABDOMINAL WALL  
 SPLEEN ADHERED TO PERITONEAL WALL PRESENT  
 UTERUS POLYP PRESENT  
 PITUITARY GLAND DISCOLORATION PRESENT

<< MICROSCOPIC TISSUE OBSERVATIONS >>

TISSUE / HISTOPATHOLOGIC FINDINGS DISTRIBUTION (SEVERITY) / SPECIAL COMMENTS

THYROID GLANDS ..... (PRESENT)  
 -B- PARA-FOLLICULAR CELL ADENOMA .....  
 HEART ..... NOT SPECIFIED(TRACE)  
 -CARDIOMYOPATHY .....  
 SPLEEN ..... FOCAL(TRACE)  
 -FIBROSIS CAPSULAR .....  
 LYMPH NODES ..... RBC'S AND PIGMENT PRESENT IN MEDIASTINAL NODES.  
 -RED BLOOD CELLS, HEMOSIDERIN AND/OR ERYTHROPHAGOCYTOSIS WITHIN ..... NOT SPECIFIED (PRESENT)  
 MEDULLARY SINUSES .....  
 LIVER .....  
 -COMPOUND RELATED INFLAMMATORY REACTION .....  
 -HEPATITIS ..... NOT SPECIFIED (PRESENT)  
 -FOCUS OF CELLULAR ALTERATION - BASOPHILIC ..... MULTI-FOCAL(MODERATE)  
 -HEPATOCYTE COALESCING MICROVESICULAR (FATTY) CHANGE LEADING TO ..... MULTI-FOCAL(MILD)  
 NECROSIS AND MINERALIZATION ..... MULTI-FOCAL(MILD)  
 KIDNEY ..... NOT SPECIFIED(MILD)  
 -PROGRESSIVE RENAL DISEASE .....

**Appendix J (cont.): PATHOLOGY INDIVIDUAL ANIMAL DATA**

LETTERMAN ARMY INSTITUTE OF RESEARCH  
 DIV OF RES SUPP, PATH SERV GP  
 SPECIES: RAT/FISCHER-344

INDIVIDUAL ANIMAL DATA REPORT  
 STUDY NUMBER: GLP83009  
 STUDY START DATE: 23-JAN-84

ANIMAL NUMBER: 243/PRETEST#  
 DOSE GROUP: 1  
 SACRIFICE STATUS: FINAL SACRIFICE  
 DATE OF DEATH: 12-FEB-86  
 STUDY DAY OF DEATH: 752  
 STUDY WEEK OF DEATH: 108  
 TERMINAL BODY WEIGHT: 228.00 (GMS)

STUDY TYPE: CHRONIC/2 YR CARCINOGENIC

<< MICROSCOPIC TISSUE OBSERVATIONS >>  
 DISTRIBUTION (SEVERITY) / SPECIAL COMMENTS

UTERUS ..... A LARGE STROMAL POLYP IS PRESENT IN THE UTERUS. WITHIN THIS LESION IS A SMALL FOCAL AREA COMPRISED OF SPINDELOID CELLS ARRANGED IN EITHER PARALLEL BUNDLES OR WHORLS. FEW MITOTIC FIGURES ARE PRESENT. THE LESION IS WELL-DEMARCATED BUT NOT ENCAPSULATED. IT IS VERY IRREGULAR IN SHAPE AND APPEARS TO BE INFILTRATING THE STROMA. THE PERIPHERAL ENDOMETRIUM IS INFILTRATED WITH MIXED INFLAMMATORY CELLS.  
 -ENDOMETRIAL STROMAL POLYP  
 -ENDOMETRITIS, SUBACUTE  
 -N- LEIOMYOSARCOMA

STOMACH ..... NOT SPECIFIED (PRESENT)  
 -COMPOUND RELATED INFLAMMATORY REACTION

MAMMARY GLANDS ..... NOT SPECIFIED (MILD)  
 -HYPERPLASIA AND/OR HYPERTROPHY OF THE ACINAR TISSUE  
 -DILATATION (ECTASIA) OF DUCTS AND DUCTULES

NOSE/TURBINATES ..... CELLULAR INFILTRATE INVOLVES THE NASO-LACRIMAL DUCTS.  
 -MIXED INFLAMMATORY CELL INFILTRATION, NASAL CAVITY, SINUSES,  
 TURBINATES, NASO-LACRIMAL DUCTS

BONE, STERNUM ..... NOT SPECIFIED (PRESENT)  
 -HYPERPLASIA, MYELOID

BONE, FEMUR ..... NOT SPECIFIED (PRESENT)  
 -HYPERPLASIA MYELOID

BONE VERT ..... NOT SPECIFIED (PRESENT)  
 -HYPERPLASIA, MYELOID

ADRENAL ..... NOT SPECIFIED (MILD)  
 -FOCUS OF CELLULAR ALTERATION, VACUOLATED

PITUITARY GLAND ..... NOT SPECIFIED (MILD)

PRINTED: 21-NOV-89  
 PAGE: 490



Appendix J (cont.): PATHOLOGY INDIVIDUAL ANIMAL DATA

LETTERMAN ARMY INSTITUTE OF RESEARCH  
DIV OF RES SUPP, PATH SERV GP  
SPECIES: RAT/FISCHER-344

INDIVIDUAL ANIMAL DATA REPORT  
STUDY NUMBER: GLP83009

PRINTED: 21-NOV-89  
PAGE: 491

STUDY START DATE: 23-JAN-84

STUDY TYPE: CHRONIC/2 YR CARCINOGENIC

ANIMAL NUMBER: 243/PRETEST= 243 SEX: FEMALE DOSE GROUP: 1 SACRIFICE STATUS: FINAL SACRIFICE  
DATE OF DEATH: 12-FEB-86 STUDY DAY OF DEATH: 752 STUDY WEEK OF DEATH: 108 TERMINAL BODY WEIGHT: 228.00 (GMS)

<< MICROSCOPIC TISSUE OBSERVATIONS >>  
TISSUE / HISTOPATHOLOGIC FINDINGS DISTRIBUTION (SEVERITY) / SPECIAL COMMENTS

PITUITARY GLAND ..... (PRESENT)  
-B- ADENOMA

EYES & OPTIC N. .... NOT SPECIFIED (PRESENT)  
-METAPLASTIC BONE FORMATION AND/OR MINERALIZATION, SCLERA

DIAPHRAGM ..... MISCELLANEOUS TISSUE  
-COMPOUND RELATED INFLAMMATORY REACTION NOT SPECIFIED (PRESENT)

**Appendix J (cont.): PATHOLOGY INDIVIDUAL ANIMAL DATA**

LETTERMAN ARMY INSTITUTE OF RESEARCH  
 DIV OF RES SUPP, PATH SERV GP  
 SPECIES: RAT/FISCHER-344  
 STUDY START DATE: 23-JAN-84  
 STUDY NUMBER: GLP83009  
 PRINTED: 21-NOV-89  
 PAGE: 492

ANIMAL NUMBER: 244/PRETEST# 244 SEX: FEMALE DOSE GROUP: 1 SACRIFICE STATUS: SACRIFICED MORIBUND  
 DATE OF DEATH: 19-NOV-85 STUDY DAY OF DEATH: 667 STUDY WEEK OF DEATH: 96 TERMINAL BODY WEIGHT: 270.00 (GMS)  
 STUDY TYPE: CHRONIC/2 YR CARCINOGENIC

<< GROSS ORGAN OBSERVATIONS >>  
 KEYWORDS / PHRASES SEVERITY GROSS FREE-TEXT COMMENTS  
 UTERUS GROWTH(S)/MASS(S) PRESENT UTERINE BODY, 3CM DIAMETER, FIRM  
 LIVER ADHESION(S) PRESENT VENTRAL ABDOMINAL WALL  
 SPLEEN ENLARGED (SPLENOHEGALY) PRESENT  
 EYES & OPTIC N. OCULAR DISCHARGE PRESENT RED, BILATERAL

TISSUE / HISTOPATHOLOGIC FINDINGS << MICROSCOPIC TISSUE OBSERVATIONS >>  
 DISTRIBUTION (SEVERITY) / SPECIAL COMMENTS

- THYROID GLANDS ..... (PRESENT)
- B- PARA-FOLLICULAR CELL ADENOMA
- EXORBITAL LACRIM
- ACINAR ATROPHY FOCAL(TRACE)
- SUBACUTE INFLAMMATION FOCAL(TRACE)
- HEART
- CARDIOMYOPATHY NOT SPECIFIED(TRACE)
- LUNGS
- MINERALIZATION OF PULMONARY ARTERIES NOT SPECIFIED(TRACE)
- SPLEEN
- EXTRAMEDULLARY HEMATOPOIESIS NOT SPECIFIED (PRESENT)
- LYMPH NODES
- RED BLOOD CELLS, HEMOSIDERIN AND/OR ERYTHROPHAGOCYTOSIS WITHIN MEDULLARY SINUSES REACTIVE HYPERPLASIA PRESENT IN MEDIASTINAL AND MESENTERIC NODES. PIGMENT NOTED IN MEDIASTINAL NODES.
- REACTIVE HYPERPLASIA NOT SPECIFIED (PRESENT)
- LIVER
- COMPOUND RELATED INFLAMMATORY REACTION NOT SPECIFIED (PRESENT)

**Appendix J (cont.): PATHOLOGY INDIVIDUAL ANIMAL DATA**

LETTERMAN ARMY INSTITUTE OF RESEARCH  
 DIV OF RES SUPP, PATH SERV GP  
 SPECIES: RAT/FISCHER-344  
 STUDY START DATE: 23-JAN-84  
 STUDY NUMBER: GLP83009  
 PRINTED: 21-NOV-89  
 PAGE: 493  
 STUDY TYPE: CHRONIC/2 YR CARCINOGENIC

ANIMAL NUMBER: 244/PRETEST-  
 DATE OF DEATH: 19-NOV-85  
 STUDY DAY OF DEATH: 667  
 SEX: FEMALE  
 DOSE GROUP: 1  
 SACRIFICE STATUS: SACRIFICED MORIBUND  
 TERMINAL BODY WEIGHT: 270.00 (GMS)

<< MICROSCOPIC TISSUE OBSERVATIONS >>  
 DISTRIBUTION (SEVERITY) / SPECIAL COMMENTS

LIVER ..... MULTI-FOCAL(TRACE)  
 -HEPATITIS ..... MULTI-FOCAL(TRACE)  
 -HEPATOCTYIC VACUOLIZATION

KIDNEY ..... NOT SPECIFIED(TRACE)  
 -PROGRESSIVE RENAL DISEASE

UTERUS ..... (PRESENT)  
 -M- ENDOMETRIAL SARCOMA

JEJUNUM .....  
 -COMPOUND RELATED INFLAMMATORY REACTION  
 INTISTINE ADHERED TO LIVER. COMPOUND INDUCED INFLMMATORY REACTION PRESENT IN AREA OF ADHESION. NOT SPECIFIED (PRESENT)

NOSE/TURBINATES .....  
 -MIXED INFLAMMATORY CELL INFILTRATION, NASAL CAVITY, SINUSES, CELLULAR INFILTRATE INVOLVES MASO-LACRIMAL DUCT. NOT SPECIFIED(MILD)  
 TURBINATES, MASO-LACRIMAL DUCTS

BONE, STERNUM ..... NOT SPECIFIED (PRESENT)  
 -HYPERPLASIA, MYELOID

BONE, FEMUR ..... NOT SPECIFIED (PRESENT)  
 -HYPERPLASIA MYELOID

BONE VERT ..... NOT SPECIFIED (PRESENT)  
 -HYPERPLASIA, MYELOID

PITUITARY GLAND .....  
 -B- ADENOMA (PRESENT)

DIAPHRAGM ..... MISCELLANEOUS TISSUE  
 -COMPOUND RELATED INFLAMMATORY REACTION NOT SPECIFIED (PRESENT)

Appendix J (cont.): PATHOLOGY INDIVIDUAL ANIMAL DATA

PRINTED: 21-NOV-89  
PAGE: 496

INDIVIDUAL ANIMAL DATA REPORT  
STUDY NUMBER: GLP63009

LETTERMAN ARMY INSTITUTE OF RESEARCH  
DIV OF RES SUPP, PATH SERV GP

STUDY START DATE: 23-JAN-84  
STUDY TYPE: CHRONIC/2 YR CARCINOGENIC

SPECIES: RAT/FISCHER-344  
ANIMAL NUMBER: 247/PRETEST  
DATE OF DEATH: 12-FEB-86

DOSE GROUP: 1  
SEX: FEMALE  
STUDY WEEK OF DEATH: 108  
TERMINAL BODY WEIGHT: 243.00 (GMS)

SACRIFICE STATUS: FINAL SACRIFICE  
STUDY WEEK OF DEATH: 108  
TERMINAL BODY WEIGHT: 243.00 (GMS)

ORGAN NAME  
LIVER  
LIVER  
PITUITARY GLAND

GROSS ORGAN OBSERVATIONS >>  
SEVERITY GROSS FREE-TEXT COMMENTS  
STOMACH, INTESTINES, DIAPHRAGM, VENTRAL ABDOMINAL WALL  
DARK RED, .5CM DIAMETER

KEYWORDS / PHRASES  
ADHESION(S)  
PROMINENT LOBULAR MARKINGS  
ENLARGED

TISSUE / HISTOPATHOLOGIC FINDINGS  
<< MICROSCOPIC TISSUE OBSERVATIONS >>  
DISTRIBUTION (SEVERITY) / SPECIAL COMMENTS

EXORBITAL LACRIM ..... FOCAL (TRACE)  
-ACINAR ATROPHY .....  
HEART ..... NOT SPECIFIED (MILD)  
-CARDIOMYOPATHY .....

LUNGS ..... MULTI-FOCAL (TRACE)  
-PNEUMONIA, INTERSTITIAL, CHRONIC .....

SPLEEN ..... (PRESENT)  
-N- LARGE GRANULAR LYMPHOCYTE LEUKEMIA, METASTATIC  
REACTIVE HYPERPLASIA AND RBC'S PRESENT IN MEDIASTINAL NODES.  
DILATED SINUSOIDS PRESENT IN MESENTERIC NODES.  
NOT SPECIFIED (PRESENT)

LYMPH NODES .....  
-RED BLOOD CELLS, HEMOSIDERIN AND/OR ERYTHROPHAGOCYTOSIS WITHIN  
MEDULLARY SINUSES  
-REACTIVE HYPERPLASIA  
-DILATED AND/OR CYSTIC MEDULLARY SINUSES

LIVER ..... NOT SPECIFIED (PRESENT)  
-COMPOUND RELATED INFLAMMATORY REACTION  
MULTI-FOCAL (TRACE)  
-HEPATOCTIC VACUOLIZATION  
NOT SPECIFIED (MILD)  
-HEPATOCTIC DEGENERATIVE CHANGES (NON-NECROTIC)  
-N- LARGE GRANULAR LYMPHOCYTE LEUKEMIA, METASTATIC  
(PRESENT)

Appendix J (cont.): PATHOLOGY INDIVIDUAL ANIMAL DATA

LETTERMAN ARMY INSTITUTE OF RESEARCH INDIVIDUAL ANIMAL DATA REPORT PRINTED: 21-NOV-89  
DIV OF RES SUPP, PATH SERV GP STUDY NUMBER: GLP83009 PAGE: 497  
SPECIES: RAT/FISCHER-344 STUDY START DATE: 23-JAN-84 STUDY TYPE: CHRONIC/2 YR CARCINOGENIC

ANIMAL NUMBER: 247/PRETEST= 247 SEX: FEMALE DOSE GROUP: 1 SACRIFICE STATUS: FINAL SACRIFICE  
DATE OF DEATH: 12-FEB-86 STUDY DAY OF DEATH: 752 STUDY WEEK OF DEATH: 108 TERMINAL BODY WEIGHT: 243.00 (GMS)

TISSUE / HISTOPATHOLOGIC FINDINGS << MICROSCOPIC TISSUE OBSERVATIONS >>  
DISTRIBUTION (SEVERITY) / SPECIAL COMMENTS

LIVER .....  
-HEPATOCYTE COALESCING MICROVESICULAR (FATTY) CHANGE LEADING TO NOT SPECIFIED(TRACE)  
NECROSIS AND MINERALIZATION

KIDNEY .....  
-PROGRESSIVE RENAL DISEASE ..... NOT SPECIFIED(MILD)

OVARIES .....  
-FOLLICULAR CYST(S) ..... NOT SPECIFIED (PRESENT)

JEJUNUM .....  
-COMPOUND RELATED INFLAMMATORY REACTION ..... NOT SPECIFIED (PRESENT)

PANCREAS .....  
-ACINAR (EXOCRINE) ATROPHY ..... NOT SPECIFIED(MILD)

STOMACH .....  
-COMPOUND RELATED INFLAMMATORY REACTION ..... NOT SPECIFIED (PRESENT)

MAMMARY GLANDS .....  
-HYPERPLASIA AND/OR HYPERTROPHY OF THE ACINAR TISSUE ..... NOT SPECIFIED(MILD)  
-DILATATION (ECTASIA) OF DUCTS AND DUCTULES ..... NOT SPECIFIED (PRESENT)

NOSE/TURBINATES .....  
-MIXED INFLAMMATORY CELL INFILTRATION, NASAL CAVITY, SINUSES, ..... CELLULAR INFILTRATE IS ADJACENT TO THE NASO-LACRIMAL DUCT.  
TURBINATES, NASO-LACRIMAL DUCTS ..... NOT SPECIFIED(MILD)

ADRENAL .....  
-FOCUS OF CELLULAR ALTERATION, VACUOLATED ..... NOT SPECIFIED(MILD)

PITUITARY GLAND .....  
-B- ADENOMA ..... (PRESENT)

WHOLE BODY .....

Appendix J (cont.): PATHOLOGY INDIVIDUAL ANIMAL DATA

LETTERMAN ARMY INSTITUTE OF RESEARCH  
DIV OF RES SUPP, PATH SERV GP  
SPECIES: RAT/FISCHER-344

INDIVIDUAL ANIMAL DATA REPORT  
STUDY NUMBER: GLP83009  
STUDY START DATE: 23-JAN-84

PRINTED: 21-NOV-89  
PAGE: 498  
STUDY TYPE: CHRONIC/2 YR CARCINOGENIC

ANIMAL NUMBER: 247/PRETEST#  
DATE OF DEATH: 12-FEB-86

SEX: FEMALE  
DOSE GROUP: 1  
STUDY WEEK OF DEATH: 108

SACRIFICE STATUS: FINAL SACRIFICE  
TERMINAL BODY WEIGHT: 243.00 (GMS)

TISSUE / HISTOPATHOLOGIC FINDINGS

<< MICROSCOPIC TISSUE OBSERVATIONS >>  
DISTRIBUTION (SEVERITY) / SPECIAL COMMENTS

WHOLE BODY ..... (PRESENT)  
-M- LARGE GRANULAR LYMPHOCYTTIC LEUKEMIA

DIAPHRAGM ..... MISCELLANEOUS TISSUE NOT SPECIFIED (PRESENT)  
-COMPOUND RELATED INFLAMMATORY REACTION

Appendix J (cont.): PATHOLOGY INDIVIDUAL ANIMAL DATA

LETTERMAN ARMY INSTITUTE OF RESEARCH  
 DIV OF RES SUPP, PATH SERV GP  
 SPECIES: RAT/FISCHER-344  
 STUDY START DATE: 23-JAN-84  
 ANIMAL NUMBER: 248/PRETEST-248 SEX: FEMALE DOSE GROUP: 1 SACRIFICE STATUS: FOUND DEAD  
 DATE OF DEATH: 13-FEB-85 STUDY DAY OF DEATH: 388 STUDY WEEK OF DEATH: 56 TERMINAL BODY WEIGHT: 229.00 (GMS)  
 STUDY TYPE: CHRONIC/2 YR CARCINOGENIC

PRINTED: 21-NOV-89  
 PAGE: 499

<< GROSS ORGAN OBSERVATIONS >>  
 SEVERITY GROSS FREE-TEXT COMMENTS  
 LIVER PRESENT DIAPHRAGM, VENTRAL ABDOMINAL WALL, CECUM  
 ADHESION(S) PRESENT TWO LOOPS OF SMALL INTESTINE ADHERED TO RIGHT ABDOMINAL WALL.  
 PITUITARY GLAND MEMORRHAGIC PRESENT SURROUNDED BY BLOOD CLOT

<< MICROSCOPIC TISSUE OBSERVATIONS >>  
 DISTRIBUTION (SEVERITY) / SPECIAL COMMENTS

EXORBITAL LACRIM ..... TISSUE IS MISSING  
 THYRUS ..... TISSUE IS MISSING  
 LIVER ..... NOT SPECIFIED (PRESENT)  
 -COMPOUND RELATED INFLAMMATORY REACTION ..... NOT SPECIFIED (TRACE)  
 -HEPATITIS .....  
 KIDNEY ..... NOT SPECIFIED (TRACE)  
 -PROGRESSIVE RENAL DISEASE .....  
 JEJUNUM ..... NOT SPECIFIED (PRESENT)  
 -COMPOUND RELATED INFLAMMATORY REACTION .....  
 CECUM ..... NOT SPECIFIED (PRESENT)  
 -COMPOUND RELATED INFLAMMATORY REACTION ..... TISSUE IS MISSING  
 RECTUM ..... TISSUE IS MISSING  
 COLON ..... NOT SPECIFIED (PRESENT)  
 -COMPOUND RELATED INFLAMMATORY REACTION .....  
 MAMMARY GLANDS ..... NOT SPECIFIED (MILD)  
 -HYPERPLASIA AND/OR HYPERTROPHY OF THE ACINAR TISSUE .....

Appendix J (cont.): PATHOLOGY INDIVIDUAL ANIMAL DATA

LETTERMAN ARMY INSTITUTE OF RESEARCH  
DIV OF RES SUPP, PATH SERV GP  
SPECIES: RAT/FISCHER-344

INDIVIDUAL ANIMAL DATA REPORT  
STUDY NUMBER: GLP83009  
STUDY START DATE: 23-JAN-84

PRINTED: 21-NOV-89  
PAGE: 500  
STUDY TYPE: CHRON C/2 YR CARCINOGENIC

ANIMAL NUMBER: 248/PRETEST# 248 SEX: FEMALE DOSE GROUP: 1 SACRIFICE STATUS: FOUND DEAD  
DATE OF DEATH: 13-FEB-85 STUDY DAY OF DEATH: 388 STUDY WEEK OF DEATH: 56 TERMINAL BODY WEIGHT: 229.00 (GMS)

<< MICROSCOPIC TISSUE OBSERVATIONS >>  
DISTRIBUTION (SEVERITY) / SPECIAL COMMENTS

MAMMARY GLANDS ..... NOT SPECIFIED (PRESENT)  
-DILATATION (ECTASIA) OF DUCTS AND DUCTULES

PITUITARY GLAND ..... (PRESENT)  
-B- ADENOMA ..... NOT SPECIFIED (PRESENT)  
-HEMORRHAGE

EYES & OPTIC N. .... NOT SPECIFIED (PRESENT)  
-METAPLASTIC BONE FORMATION AND/OR MINERALIZATION, SCLERA

DIAPHRAGM ..... MISCELLANEOUS TISSUE  
-COMPOUND RELATED INFLAMMATORY REACTION ..... NOT SPECIFIED (PRESENT)



Appendix J (cont.): PATHOLOGY INDIVIDUAL ANIMAL DATA

LETTERMAN ARMY INSTITUTE OF RESEARCH  
 DIV OF RES SUPP, PATH SERV GP  
 SPECIES: RAT/FISCHER-344  
 ANIMAL NUMBER: 253/PRETEST-  
 DATE OF DEATH: 23-JAN-86  
 STUDY DAY OF DEATH: 732  
 DOSE GROUP: 1  
 STUDY WEEK OF DEATH: 105  
 SACRIFICE STATUS: SACRIFICED MORIBUND  
 TERMINAL BODY WEIGHT: 238.00 (GMS)  
 STUDY START DATE: 23-JAN-84  
 STUDY TYPE: CHRONIC/2 YR CARCINOGENIC  
 PRINTED: 21-NOV-89  
 PAGE: 505

INDIVIDUAL ANIMAL DATA REPORT  
 STUDY NUMBER: GLP83009

ORGAN NAME << GROSS ORGAN OBSERVATIONS >>  
 KEYWORDS / PHRASES SEVERITY GROSS FREE-TEXT COMMENTS  
 LIVER ADHESION(S) PRESENT DIAPHRAGM  
 PITUITARY GLAND ENLARGED PRESENT DARK RED, .9CM DIAMETER

<< MICROSCOPIC TISSUE OBSERVATIONS >>  
 TISSUE / HISTOPATHOLOGIC FINDINGS DISTRIBUTION (SEVERITY) / SPECIAL COMMENTS

BRAIN (PRESENT)  
 -I-PITUITARY TUMOR INVASION TISSUE IS MISSING

PARATHYROID  
 LACRIMAL GLAND  
 -INFLAMMATION, SUBACUTE TO CHRONIC MULTI-FOCAL(TRACE)  
 -ATROPHY AND/OR LOSS OF ACINAR TISSUE NOT SPECIFIED(MILD)

EXORBITAL LACRIM FOCAL(TRACE)  
 -ACINAR ATROPHY

HEART NOT SPECIFIED(TRACE)  
 -CARDIOMYOPATHY

SPLEEN NOT SPECIFIED(MILD)  
 -FIBROSIS CAPSULAR

LYMPH NODES REACTIVE HYPERPLASIA, RBC'S AND PIGMENT ARE PRESENT IN CERVICAL  
 AND MESENTERIC LYMPH NODES.  
 -RED BLOOD CELLS, MEMOSIDERIN AND/OR ERYTHROPHAGOCYTOSIS WITHIN NOT SPECIFIED (PRESENT)  
 MEDULLARY SINUSES  
 -REACTIVE HYPERPLASIA NOT SPECIFIED (PRESENT)

LIVER NOT SPECIFIED (PRESENT)  
 -COMPOUND RELATED INFLAMMATORY REACTION

Appendix J (cont.): PATHOLOGY INDIVIDUAL ANIMAL DATA

LETTERMAN ARMY INSTITUTE OF RESEARCH  
DIV OF RES SUPP, PATH SERV GP  
SPECIES: RAT/FISCHER-344

INDIVIDUAL ANIMAL DATA REPORT  
STUDY NUMBER: GLP83009  
STUDY START DATE: 23-JAN-84

PRINTED: 21-NOV-89  
PAGE: 506

STUDY TYPE: CHRONIC/2 YR CARCINOGENIC

ANIMAL NUMBER: 253/PRETEST-      DOSE GROUP: 1      SACRIFICE STATUS: SACRIFICED MORIBUND  
DATE OF DEATH: 23-JAN-86      STUDY DAY OF DEATH: 732      STUDY WEEK OF DEATH: 105      TERMINAL BODY WEIGHT: 238.00 (GMS)

TISSUE / HISTOPATHOLOGIC FINDINGS      <<      M I C R O S C O P I C      T I S S U E      O B S E R V A T I O N S      >>  
DISTRIBUTION (SEVERITY) / SPECIAL COMMENTS

LIVER .....  
-BILE DUCTULE EPITHELIAL HYPERPLASIA AND/OR CHOLANGIOFIBROSIS ..... NOT SPECIFIED(MILD)  
-HEPATOCTYIC VACUOLIZATION ..... MULTI-FOCAL(TRACE)

KIDNEY .....  
-PROGRESSIVE RENAL DISEASE ..... NOT SPECIFIED(MILD)

OVARIES .....  
-PARA-OVARIAN CYST(S) ..... NOT SPECIFIED (PRESENT)

STOMACH .....  
-COMPOUND RELATED INFLAMMATORY REACTION ..... NOT SPECIFIED (PRESENT)

MAMMARY GLANDS .....  
-HYPERPLASIA AND/OR HYPERTROPHY OF THE ACINAR TISSUE ..... NOT SPECIFIED(MODERATE)  
-DILATATION (ECTASIA) OF DUCTS AND DUCTULES ..... NOT SPECIFIED (PRESENT)

NOSE/TURBINATES .....  
-MIXED INFLAMMATORY CELL INFILTRATION, NASAL CAVITY, SINUSES, ..... CELLULAR INFILTRATE IS NEAR NASO-LACRIMAL DUCT.  
TURBINATES, NASO-LACRIMAL DUCTS ..... NOT SPECIFIED(MODERATE)

PITUITARY GLAND .....  
-B- ADENOMA ..... (PRESENT)

DIAPHRAGM .....  
-COMPOUND RELATED INFLAMMATORY REACTION ..... MISCELLANEOUS TISSUE  
NOT SPECIFIED (PRESENT)

**Appendix J (cont.): PATHOLOGY INDIVIDUAL ANIMAL DATA**

LETTERMAN ARMY INSTITUTE OF RESEARCH  
 DIV OF RES SUPP, PATH SERV GP  
 SPECIES: RAT/FISCHER-344

INDIVIDUAL ANIMAL DATA REPORT  
 STUDY NUMBER: GLP83009  
 STUDY START DATE: 23-JAN-84

PRINTED: 21-NOV-89  
 PAGE: 507

ANIMAL NUMBER: 254/PRETEST-  
 DATE OF DEATH: 14-FEB-86 STUDY DAY OF DEATH: 754 SEX: FEMALE DOSE GROUP: 1 SACRIFICE STATUS: FINAL SACRIFICE  
 STUDY TYPE: CHRONIC/2 YR CARCINOGENIC  
 STUDY WEEK OF DEATH: 108 TERMINAL BODY WEIGHT: 255.00 (GMS)

ORGAN NAME	KEYWORDS / PHRASES	ORGAN OBSERVATIONS	SEVERITY	GROSS FREE-TEXT COMMENTS
LIVER	ADHESION(S)	PRESENT	DIAPHRAGM	
DUODENUM	ADHERED TO LIVER	PRESENT	ONE LOOP	
PITUITARY GLAND	DISCOLORATION	PRESENT	FOCAL, RED, .2CM DIAMETER	
MAMMARY GLAND	PROMINENT	PRESENT	RIGHT AXILLARY	

TISSUE / HISTOPATHOLOGIC FINDINGS  
 << MICROSCOPIC TISSUE OBSERVATIONS >>  
 DISTRIBUTION (SEVERITY) / SPECIAL COMMENTS

THYROID GLANDS  
 -B- PARA-FOLLICULAR CELL ADENOMA (PRESENT)

HEART  
 -CARDIOMYOPATHY NOT SPECIFIED(MILD)

SPLEEN  
 -HEMOSIDERIN PIGMENTATION (RED PULP) NOT SPECIFIED (PRESENT)

LYMPH NODES  
 -RED BLOOD CELLS, HEMOSIDERIN AND/OR ERYTHROPHAGOCYTOSIS WITHIN RBC'S AND REACTIVE HYPERPLASIA PRESENT IN CERVICAL NODES.  
 MEDULLARY SINUSES NOT SPECIFIED (PRESENT)  
 -REACTIVE HYPERPLASIA NOT SPECIFIED (PRESENT)

LIVER  
 -COMPOUND RELATED INFLAMMATORY REACTION  
 -BILE DUCTULE EPITHELIAL HYPERPLASIA AND/OR CHOLANGIOFIBROSIS NOT SPECIFIED (PRESENT)  
 -HEPATITIS MULTI-FOCAL(MILD)  
 -FOCUS OF CELLULAR ALTERATION - BASOPHILIC NOT SPECIFIED(TRACE)  
 -NECROSIS, HEPATOCTIC, INDIVIDUAL CELLS MULTI-FOCAL(TRACE)  
 -HEPATOCTE COALESCING MICROVESICULAR (FATTY) CHANGE LEADING TO NOT SPECIFIED(MODERATE)  
 NECROSIS AND MINERALIZATION

KIDNEY

Appendix J (cont.): PATHOLOGY INDIVIDUAL ANIMAL DATA

LETTERMAN ARMY INSTITUTE OF RESEARCH  
 DIV OF RES SUPP, PATH SERV GP  
 SPECIES: RAT/FISCHER-344  
 STUDY NUMBER: GLP83009  
 STUDY START DATE: 23-JAN-84  
 STUDY TYPE: CHRONIC/2 YR CARCINOGENIC  
 ANIMAL NUMBER: 254/PRETEST# 254 SEX: FEMALE DOSE GROUP: 1 SACRIFICE STATUS: FINAL SACRIFICE  
 DATE OF DEATH: 14-FEB-86 STUDY DAY OF DEATH: 754 STUDY WEEK OF DEATH: 108 TERMINAL BODY WEIGHT: 255.00 (GMS)  
 << MICROSCOPIC TISSUE OBSERVATIONS >>  
 TISSUE / HISTOPATHOLOGIC FINDINGS DISTRIBUTION (SEVERITY) / SPECIAL COMMENTS

PRINTED: 21-NOV-89  
PAGE: 508

- KIDNEY ..... NOT SPECIFIED(MILD)
- PROGRESSIVE RENAL DISEASE
- PANCREAS ..... FOCAL(TRACE)
- ACINAR (EXOCRINE) ATROPHY
- MAMMARY GLANDS ..... PROMINENT MAMMARY TISSUE IN RIGHT AXILLARY AREA IS A MAMMARY  
FIBROADENOMA.
- HYPERPLASIA AND/OR HYPERTROPHY OF THE ACINAR TISSUE NOT SPECIFIED(MILD)
- B- FIBROADENOMA (PRESENT)
- DILATATION (ECTASIA) OF DUCTS AND DUCTULES NOT SPECIFIED (PRESENT)
- NOSE/TURBINATES ..... BILATERAL CELLULAR INFILTRATE INVOLVES NASO-LACRIMAL DUCTS.
- MIXED INFLAMMATORY CELL INFILTRATION, NASAL CAVITY, SINUSES, NOT SPECIFIED(TRACE)
- TURBINATES, NASO-LACRIMAL DUCTS
- ADRENAL ..... MULTI-FOCAL(TRACE)
- FOCUS OF CELLULAR ALTERATION, VACUOLATED (PRESENT)
- PITUITARY GLAND ..... (PRESENT)
- B- ADENOMA
- EYES & OPTIC N. .... NOT SPECIFIED(TRACE)
- RETINAL ATROPHY AND/OR DEGENERATION, UNILATERAL OR BILATERAL FOCAL(TRACE)
- CORNEAL VASCULARIZATION
- DIAPHRAGM ..... MISCELLANEOUS TISSUE
- COMPOUND RELATED INFLAMMATORY REACTION NOT SPECIFIED (PRESENT)

Appendix J (cont.): PATHOLOGY INDIVIDUAL ANIMAL DATA

LETTERMAN ARMY INSTITUTE OF RESEARCH  
DIV OF RES SUPP, PATH SERV GP  
SPECIES: RAT/FISCHER-344

INDIVIDUAL ANIMAL DATA REPORT  
STUDY NUMBER: GLP83009

STUDY START DATE: 23-JAN-84

STUDY DAY OF DEATH: 754

STUDY WEEK OF DEATH: 108

STUDY TYPE: CHRONIC/2 YR CARCINOGENIC

PRINTED: 21-NOV-89  
PAGE: 509

ANIMAL NUMBER: 255/PRETEST=  
DATE OF DEATH: 14-FEB-86

255 SEX: FEMALE DOSE GROUP: 1  
SACRIFICE STATUS: FINAL SACRIFICE

TERMINAL BODY WEIGHT: 250.00 (GMS)

SEVERITY GROSS FREE-TEXT COMMENTS

ORGAN OBSERVATIONS

KEYWORDS / PHRASES

ADHESION(S)

ADHERED TO LIVER

PITUITARY GLAND ENLARGED

DIAPHRAGM, STOMACH, VENTRAL ABDOMINAL WALL

DARK, .5CM DIAMETER

PRESENT

PRESENT

PRESENT

PRESENT

PRESENT

PRESENT

TISSUE / HISTOPATHOLOGIC FINDINGS

TISSUE IS MISSING

NOT SPECIFIED(MILD)

NOT SPECIFIED(MILD)

NOT SPECIFIED(TRACE)

REACTIVE HYPERPLASIA NOTED IN CERVICAL NODES

NOT SPECIFIED (PRESENT)

NOT SPECIFIED (PRESENT)

NOT SPECIFIED (TRACE)

NOT SPECIFIED (PRESENT)

MULTI-FOCAL(TRACE)

MULTI-FOCAL(TRACE)

MULTI-FOCAL(TRACE)

MULTI-FOCAL(TRACE)

MULTI-FOCAL(TRACE)

MULTI-FOCAL(TRACE)

NOT SPECIFIED(MODERATE)

NOT SPECIFIED(MODERATE)

NOT SPECIFIED(MODERATE)

NOT SPECIFIED(MODERATE)

NOT SPECIFIED(MODERATE)

NOT SPECIFIED(MODERATE)

NOT SPECIFIED(MODERATE)

NOT SPECIFIED(MODERATE)

NOT SPECIFIED(MODERATE)

NOT SPECIFIED(MODERATE)

NOT SPECIFIED(MODERATE)

NOT SPECIFIED(MODERATE)

NOT SPECIFIED(MODERATE)

NOT SPECIFIED(MODERATE)

NOT SPECIFIED(MODERATE)

NOT SPECIFIED(MODERATE)

NOT SPECIFIED(MODERATE)

NOT SPECIFIED(MODERATE)

NOT SPECIFIED(MODERATE)

NOT SPECIFIED(MODERATE)

NOT SPECIFIED(MODERATE)

NOT SPECIFIED(MODERATE)

NOT SPECIFIED(MODERATE)

NOT SPECIFIED(MODERATE)

NOT SPECIFIED(MODERATE)

NOT SPECIFIED(MODERATE)

NOT SPECIFIED(MODERATE)

NOT SPECIFIED(MODERATE)

NOT SPECIFIED(MODERATE)

NOT SPECIFIED(MODERATE)

NOT SPECIFIED(MODERATE)

NOT SPECIFIED(MODERATE)

NOT SPECIFIED(MODERATE)

NOT SPECIFIED(MODERATE)

NOT SPECIFIED(MODERATE)

NOT SPECIFIED(MODERATE)

NOT SPECIFIED(MODERATE)

NOT SPECIFIED(MODERATE)

NOT SPECIFIED(MODERATE)

NOT SPECIFIED(MODERATE)

NOT SPECIFIED(MODERATE)

NOT SPECIFIED(MODERATE)

NOT SPECIFIED(MODERATE)

NOT SPECIFIED(MODERATE)

NOT SPECIFIED(MODERATE)

NOT SPECIFIED(MODERATE)

NOT SPECIFIED(MODERATE)

NOT SPECIFIED(MODERATE)

NOT SPECIFIED(MODERATE)

NOT SPECIFIED(MODERATE)

NOT SPECIFIED(MODERATE)

NOT SPECIFIED(MODERATE)

NOT SPECIFIED(MODERATE)

NOT SPECIFIED(MODERATE)

NOT SPECIFIED(MODERATE)

NOT SPECIFIED(MODERATE)

NOT SPECIFIED(MODERATE)

NOT SPECIFIED(MODERATE)

NOT SPECIFIED(MODERATE)

NOT SPECIFIED(MODERATE)

NOT SPECIFIED(MODERATE)

NOT SPECIFIED(MODERATE)

NOT SPECIFIED(MODERATE)

NOT SPECIFIED(MODERATE)

NOT SPECIFIED(MODERATE)

NOT SPECIFIED(MODERATE)

NOT SPECIFIED(MODERATE)

NOT SPECIFIED(MODERATE)

NOT SPECIFIED(MODERATE)

NOT SPECIFIED(MODERATE)

NOT SPECIFIED(MODERATE)

NOT SPECIFIED(MODERATE)

NOT SPECIFIED(MODERATE)

NOT SPECIFIED(MODERATE)

NOT SPECIFIED(MODERATE)

NOT SPECIFIED(MODERATE)

NOT SPECIFIED(MODERATE)

NOT SPECIFIED(MODERATE)

NOT SPECIFIED(MODERATE)

NOT SPECIFIED(MODERATE)

NOT SPECIFIED(MODERATE)

NOT SPECIFIED(MODERATE)

NOT SPECIFIED(MODERATE)

NOT SPECIFIED(MODERATE)

NOT SPECIFIED(MODERATE)

NOT SPECIFIED(MODERATE)

NOT SPECIFIED(MODERATE)

NOT SPECIFIED(MODERATE)

Appendix J (cont.): PATHOLOGY INDIVIDUAL ANIMAL DATA

LETTERMAN ARMY INSTITUTE OF RESEARCH  
 DIV OF RES SUPP, PATH SERV GP  
 SPECIES: RAT/FISCHER-344

INDIVIDUAL ANIMAL DATA REPORT  
 STUDY NUMBER: GLP83009  
 STUDY START DATE: 23-JAN-84

PRINTED: 21-NOV-89  
 PAGE: 510  
 STUDY TYPE: CHRONIC/2 YR CARCINOGENIC

ANIMAL NUMBER: 255/PRETEST# 255 SEX: FEMALE DOSE GROUP: 1 SACRIFICE STATUS: FINAL SACRIFICE  
 DATE OF DEATH: 14-FEB-86 STUDY DAY OF DEATH: 754 STUDY WEEK OF DEATH: 108 TERMINAL BODY WEIGHT: 250.00 (GMS)

<< MICROSCOPIC TISSUE OBSERVATIONS >>  
 TISSUE / HISTOPATHOLOGIC FINDINGS  
 DISTRIBUTION (SEVERITY) / SPECIAL COMMENTS

MAMMARY GLANDS ..... NOT SPECIFIED(MILD)  
 -HYPERPLASIA AND/OR HYPERTROPHY OF THE ACINAR TISSUE

PITUITARY GLAND ..... (PRESENT)  
 -B- ADENOMA

DIAPHRAGM ..... MISCELLANEOUS TISSUE  
 -COMPOUND RELATED INFLAMMATORY REACTION ..... NOT SPECIFIED (PRESENT)

**Appendix J (cont.): PATHOLOGY INDIVIDUAL ANIMAL DATA**

LETTERMAN ARMY INSTITUTE OF RESEARCH  
 DIV OF RES SUPP, PATH SERV GP  
 SPECIES: RAT/FISCHER-344  
 STUDY START DATE: 23-JAN-84  
 STUDY NUMBER: GLP83009  
 PRINTED: 21-NOV-89  
 PAGE: 511  
 STUDY TYPE: CHRONIC/2 YR CARCINOGENIC  
 ANIMAL NUMBER: 256/PRETEST-256 SEX: FEMALE DOSE GROUP: 1 SACRIFICE STATUS: FINAL SACRIFICE  
 DATE OF DEATH: 14-FEB-86 STUDY DAY OF DEATH: 754 STUDY WEEK OF DEATH: 108 TERMINAL BODY WEIGHT: 260.00 (GMS)

ORGAN NAME	KEYWORDS / PHRASES	SEVERITY	GROSS FREE-TEXT COMMENTS
JEJUNUM	ADHERED TO LIVER	PRESENT	3CM LENGHT
MAMMARY GLAND	PROMINENT	PRESENT	LEFT INGUINAL, 5 X 3.5CM
SPLEEN	ENLARGED (SPLENOMEGALY)	PRESENT	8 X 1.5 X 1CM
DUODENUM	ADHERED TO LIVER	PRESENT	
DUODENUM	THICKENED	PRESENT	ENLARGED TO 1CM DIAMETER
LIVER	ADHESION(S)	PRESENT	DIAPHRAGM
LIVER	GROWTH(S) / MASS(ES)	PRESENT	FIRM, WHITE, 1.5CM DIAMETER, MEDIAL LOBE
LIVER	PROMINENT LOBULAR MARKINGS	PRESENT	
LIVER	DISCOLORATION	PRESENT	RIGHT ACCESSORY LOBE, GREEN/YELLOW, MARGIN.
THYROID	ENLARGED	PRESENT	LEFT .3CM DIAMETER.
UTERUS	POLYP	PRESENT	RIGHT MEDIAL.2CM.

TISSUE OBSERVATIONS  
 TISSUE OBSERVATIONS / SPECIAL COMMENTS

THYROID GLANDS  
 -B- PARA-FOLLICULAR CELL ADENOMA (PRESENT)

HEART  
 -CARDIOMYOPATHY NOT SPECIFIED (TRACE)

LUNGS  
 -M- LARGE GRANULAR LYMPHOCYTE LEUKEMIA, METASTATIC (PRESENT)

SPLEEN  
 -INFARCTION, CHRONIC NOT SPECIFIED (MODERATE)  
 -M- LARGE GRANULAR LYMPHOCYTE LEUKEMIA, METASTATIC (PRESENT)

LYMPH NODES  
 -RED BLOOD CELLS, MEMOSIDERIN AND/OR ERYTHROPHAGOCYTOSIS WITHIN MEDULLARY SINUSES  
 REACTIVE HYPERPLASIA PRESENT IN CERVICAL AND MEDIASTINAL NODES.  
 PIGMENT PRESENT IN MEDIASTINAL NODES.  
 NOT SPECIFIED (PRESENT)

**Appendix J (cont.): PATHOLOGY INDIVIDUAL ANIMAL DATA**

LETTERMAN ARMY INSTITUTE OF RESEARCH  
 DIV OF RES SUPP, PATH SERV GP  
 SPECIES: RAT/FISCHER-344  
 STUDY START DATE: 23-JAN-84  
 ANIMAL NUMBER: 256/PRETEST= 256 SEX: FEMALE DOSE GROUP: 1 SACRIFICE STATUS: FINAL SACRIFICE  
 DATE OF DEATH: 14-FEB-86 STUDY DAY OF DEATH: 754 STUDY WEEK OF DEATH: 108 TERMINAL BODY WEIGHT: 260.00 (GMS)  
 STUDY TYPE: CHRONIC/2 YR CARCINOGENIC  
 PRINTED: 21-NOV-89  
 PAGE: 512  
 TISSUE / HISTOPATHOLOGIC FINDINGS << MICROSCOPIC TISSUE OBSERVATIONS >>  
 DISTRIBUTION (SEVERITY) / SPECIAL COMMENTS

- LYMPH NODES ..... NOT SPECIFIED (PRESENT)
- REACTIVE HYPERPLASIA
- LIVER ..... NOT SPECIFIED (PRESENT)
- COMPOUND RELATED INFLAMMATORY REACTION
- BILE DUCTULE EPITHELIAL HYPERPLASIA AND/OR CHOLANGIOFIBROSIS
- NECROSIS
- CYSTIC DEGENERATION
- HEPATOCYTTIC DEGENERATIVE CHANGES (NON-NECROTIC)
- N- LARGE GRANULAR LYMPHOCYTE LEUKEMIA, METASTATIC
- N- PRESENCE OF METASTATIC SARCOMA
- KIDNEY ..... NOT SPECIFIED(TRACE)
- PROGRESSIVE RENAL DISEASE
- UTERUS ..... NOT SPECIFIED (PRESENT)
- ENDOMETRIAL STROMAL POLYP
- OVARIES ..... NOT SPECIFIED (PRESENT)
- CYSTIC CORPORA LUTEA
- DUODENUM ..... SECONDARY NEOPLASM FROM ORGAN
- N- PRESENCE OF METASTATIC SARCOMA
- MUCOSAL EROSION/ULCERATION
- PRESENCE OF MUCOSAL EPITHELIAL CELLS WITHIN INTESTINAL WALL AND ADJACENT FIBROUS/GRANULOMATOUS INFLAMMATORY REACTION
- JEJUNUM ..... SECONDARY NEOPLASM FROM ORGAN
- N- PRESENCE OF METASTATIC SARCOMA
- PANCREAS ..... NOT SPECIFIED(MILD)
- CHRONIC INFLAMMATION



Appendix J (cont.): PATHOLOGY INDIVIDUAL ANIMAL DATA

LETTERMAN ARMY INSTITUTE OF RESEARCH  
 DIV OF RES SUPP, PATH SERV GP  
 SPECIES: RAT/FISCHER-344

INDIVIDUAL ANIMAL DATA REPORT  
 STUDY NUMBER: GLP83009

STUDY START DATE: 23-JAN-84

STUDY TYPE: CHRONIC/2 YR CARCINOGENIC

ANIMAL NUMBER: 256/PRETEST= 256 SEX: FEMALE DOSE GROUP: 1 SACRIFICE STATUS: FINAL SACRIFICE  
 DATE OF DEATH: 14-FEB-86 STUDY DAY OF DEATH: 754 STUDY WEEK OF DEATH: 108 TERMINAL BODY WEIGHT: 260.00 (GMS)

<< MICROSCOPIC TISSUE OBSERVATIONS >>  
 DISTRIBUTION (SEVERITY) / SPECIAL COMMENTS

PRINTED: 21-NOV-89  
PAGE: 513

PANCREAS ..... SECONDARY NEOPLASM FROM ORGAN  
 -N- PRESENCE OF METASTATIC SARCOMA .....  
 MAMMARY GLANDS ..... THE MASS IN THE LEFT INGUINAL AREA A MAMMARY ADENOCARCINOMA.  
 -HYPERPLASIA AND/OR HYPERTROPHY OF THE ACINAR TISSUE ..... NOT SPECIFIED(MODERATE)  
 -DILATATION (ECTASIA) OF DUCTS AND DUCTULES ..... NOT SPECIFIED (PRESENT)  
 -N- MAMMARY ADENOCARCINOMA (PRESENT)

NOSE/TURBINATES ..... CELLULAR INFILTRATE IS ADJACENT TO MASO-LACRIMAL DUCT.  
 -MIXED INFLAMMATORY CELL INFILTRATION, NASAL CAVITY, SINUSES, ..... NOT SPECIFIED(MILD)  
 TURBINATES, MASO-LACRIMAL DUCTS

ADRENAL ..... MULTI-FOCAL(MILD)  
 -FOCUS OF CELLULAR ALTERATION, VACUOLATED

EYES & OPTIC N. .... NOT SPECIFIED(MODERATE)  
 -RETINAL ATROPHY AND/OR DEGENERATION, UNILATERAL OR BILATERAL ..... NOT SPECIFIED (PRESENT)  
 -METAPLASTIC BONE FORMATION AND/OR MINERALIZATION, SCLERA ..... NOT SPECIFIED (PRESENT)  
 -LENTICULAR DEGENERATIVE CHANGES COMPATIBLE WITH CATARACT

WHOLE BODY ..... (PRESENT)  
 -N- LARGE GRANULAR LYMPHOCTIC LEUKEMIA

ABDOMINAL CAVITY ..... MISCELLANEOUS TISSUE  
 THE SARCOMA INVOLVES PRIMARILY LIVER, INTESTINE AND PANCREAS.  
 IN MANY AREAS THE NEOPLASTIC CELLS ARE LARGE, BIZARRE AND HIGHLY  
 ANAPLASTIC. IN SOME AREAS THERE APPEARS TO BE ABUNDANT COLLAGEN  
 PRODUCTION AND IN OTHER AREAS THERE IS MATERIAL RESEMBLING  
 OSTEOID. THERE IS ENTRAPMENT OF ESSENTIALLY NORMAL  
 HEPATOCYTES, BILE DUCT EPITHELIUM, PANCREATIC ACINAR CELLS AND  
 INTESTINAL EPITHELIUM IN AREAS WHERE THE SARCOMA HAS INVADED  
 LIVER, PANCREAS AND INTESTINE.  
 (PRESENT)

-N- SARCOMA, CELLULAR DIFFERENTIATION UNSPECIFIED

DIAPHRAGM ..... MISCELLANEOUS TISSUE

Appendix J (cont.): PATHOLOGY INDIVIDUAL ANIMAL DATA

LETTERMAN ARMY INSTITUTE OF RESEARCH  
DIV OF RES SUPP, PATH SERV GP  
SPECIES: RAT/FISCHER-344  
INDIVIDUAL ANIMAL DATA REPORT  
STUDY NUMBER: GLP83009  
STUDY START DATE: 23-JAN-84  
PRINTED: 21-NOV-89  
PAGE: 514  
STUDY TYPE: CHRONIC/2 YR CARCINOGENIC

ANIMAL NUMBER: 256/PRETEST-  
DATE OF DEATH: 14-FEB-86  
SEX: FEMALE  
DOSE GROUP: 1  
SACRIFICE STATUS: FINAL SACRIFICE  
STUDY WEEK OF DEATH: 108  
TERMINAL BODY WEIGHT: 260.00 (GMS)

TISSUE / HISTOPATHOLOGIC FINDINGS  
MICROSCOPIC TISSUE OBSERVATIONS >>  
DISTRIBUTION (SEVERITY) / SPECIAL COMMENTS

DIAPHRAGH ..... MISCELLANEOUS TISSUE  
-N- PRESENCE OF METASTATIC SARCOMA  
-COMPOUND RELATED INFLAMMATORY REACTION  
SECONDARY NEOPLASM FROM ORGAN ABDOMINAL CAVITY  
NOT SPECIFIED (PRESENT)

**Appendix J (cont.): PATHOLOGY INDIVIDUAL ANIMAL DATA**

LETTERMAN ARMY INSTITUTE OF RESEARCH  
 DIV OF RES SUPP, PATH SERV GP  
 SPECIES: RAT/FISCHER-344  
 ANIMAL NUMBER: 257/PRETEST-  
 DATE OF DEATH: 14-FEB-86  
 STUDY START DATE: 23-JAN-84  
 STUDY WEEK OF DEATH: 108  
 DOSE GROUP: 1  
 SEX: FEMALE  
 SACRIFICE STATUS: FINAL SACRIFICE  
 TERMINAL BODY WEIGHT: 293.00 (GMS)  
 STUDY TYPE: CHRONIC/2 YR CARCINOGENIC

PRINTED: 21-NOV-89  
 PAGE: 515

<< GROSS ORGAN OBSERVATIONS >>  
 SEVERITY GROSS FREE-TEXT COMMENTS  
 LIVER GROWTH(S) / MASS(ES) PRESENT 2.5CM, WHITE, FIRM, ENCAPSULATED, LOBULATED.  
 PITUITARY GLAND ENLARGED PRESENT .25CM.

<< MICROSCOPIC TISSUE OBSERVATIONS >>  
 DISTRIBUTION (SEVERITY) / SPECIAL COMMENTS

- THYROID GLANDS ..... NOT SPECIFIED(MILD)
- PARA-FOLLICULAR CELL HYPERPLASIA ("C" CELL, LIGHT CELL)
- EXORBITAL LACRIM ..... FOCAL(TRACE)
- ACINAR ATROPHY
- HEART ..... NOT SPECIFIED(MILD)
- CARDIOMYOPATHY
- LUNGS ..... NOT SPECIFIED(TRACE)
- MINERALIZATION OF PULMONARY ARTERIES
- SPLEEN ..... NOT SPECIFIED (PRESENT)
- EXTRAMEDULLARY HEMATOPOIESIS ..... NOT SPECIFIED (PRESENT)
- COMPOUND RELATED INFLAMMATORY REACTION
- LYMPH NODES ..... REACTIVE HYPERPLASIA NOTED IN CERVICAL NODE.
- REACTIVE HYPERPLASIA ..... NOT SPECIFIED (PRESENT)
- LIVER ..... NOT SPECIFIED (PRESENT)
- COMPOUND RELATED INFLAMMATORY REACTION ..... NOT SPECIFIED(TRACE)
- HEPATITIS ..... NOT SPECIFIED(TRACE)
- FOCUS OF CELLULAR ALTERATION - BASOPHILIC ..... MULTI-FOCAL(MILD)
- HEPATOCTIC VACUOLIZATION

Appendix J (cont.): PATHOLOGY INDIVIDUAL ANIMAL DATA

LETTERMAN ARMY INSTITUTE OF RESEARCH  
 DIV OF RES SUPP, PATM SERV GP  
 SPECIES: RAT/FISCHER-344  
 STUDY START DATE: 23-JAN-84  
 INDIVIDUAL ANIMAL DATA REPORT  
 STUDY NUMBER: GLP83009  
 PRINTED: 21-NOV-89  
 PAGE: 516  
 STUDY TYPE: CHRONIC/2 YR CARCINOGENIC

ANIMAL NUMBER: 257/PRETEST-  
 DATE OF DEATH: 14-FEB-86  
 SEX: FEMALE  
 DOSE GROUP: 1  
 SACRIFICE STATUS: FINAL SACRIFICE  
 STUDY WEEK OF DEATH: 754  
 TERMINAL BODY WEIGHT: 293.00 (GMS)

TISSUE / HISTOPATHOLOGIC FINDINGS  
 << M I C R O S C O P I C T I S S U E O B S E R V A T I O N S >>  
 DISTRIBUTION (SEVERITY) / SPECIAL COMMENTS

LIVER  
 -HEPATOCYTE COALESCING MICROVESICULAR (FATTY) CHANGE LEADING TO MULTI-FOCAL(MODERATE)  
 NECROSIS AND MINERALIZATION  
 -N- PRESENCE OF METASTATIC SARCOMA  
 SECONDARY NEOPLASM FROM ORGAN ABDOMINAL CAVITY

KIDNEY  
 -PROGRESSIVE RENAL DISEASE  
 NOT SPECIFIED(TRACE)

UTERUS  
 -ENDOMETRIAL STROMAL POLYP  
 NOT SPECIFIED (PRESENT)

PANCREAS  
 -ACINAR (EXOCRINE) ATROPHY  
 FOCAL(TRACE)

STOMACH  
 -COMPOUND RELATED INFLAMMATORY REACTION  
 -N- PRESENCE OF METASTATIC SARCOMA  
 NOT SPECIFIED (PRESENT)  
 SECONDARY NEOPLASM FROM ORGAN

SKELETAL MUSCLE  
 A FRAGMENT OF THE ANAPLASTIC SARCOMA IS PRESENT ON SLIDE #14 WITH THE SKELETAL MUSCLE AND SCIATIC NERVE. THE TUMOR DOES NOT INVOLVE MUSCLE OR NERVE TISSUE. IT IS AN EXTRANEUS FRAGMENT PROBABLY PICKED UP ON THE WATER BATH DURING HISTOLOGIC PREPARATION.

MAMMARY GLANDS  
 -HYPERPLASIA AND/OR HYPERTROPHY OF THE ACINAR TISSUE  
 -DILATATION (ECTASIA) OF DUCTS AND DUCTULES  
 NOT SPECIFIED(MODERATE)  
 NOT SPECIFIED (PRESENT)

NOSE/TURBINATES  
 -MIXED INFLAMMATORY CELL INFILTRATION, NASAL CAVITY, SINUSES, TURBINATES, NASO-LACRIMAL DUCTS  
 BILATERAL CELLULAR INFILTRATE INVOLVES NASO-LACRIMAL DUCTS.  
 NOT SPECIFIED(MILD)

PITUITARY GLAND  
 -B- ADENOMA  
 (PRESENT)

EYES & OPTIC N.

Appendix J (cont.): PATHOLOGY INDIVIDUAL ANIMAL DATA

LETTERMAN ARMY INSTITUTE OF RESEARCH  
DIV OF RES SUPP, PATH SERV GP  
SPECIES: RAT/FISCHER-344

INDIVIDUAL ANIMAL DATA REPORT  
STUDY NUMBER: GLP83009  
STUDY START DATE: 23-JAN-84

PRINTED: 21-NOV-89  
PAGE: 517

STUDY TYPE: CHRONIC/2 YR CARCINOGENIC

ANIMAL NUMBER: 257/PRETEST- 257 SEX: FEMALE DOSE GROUP: 1 SACRIFICE STATUS: FINAL SACRIFICE  
DATE OF DEATH: 14-FEB-86 STUDY DAY OF DEATH: 754 STUDY WEEK OF DEATH: 108 TERMINAL BODY WEIGHT: 293.00 (GMS)

TISSUE / HISTOPATHOLOGIC FINDINGS << MICROSCOPIC TISSUE OBSERVATIONS >>  
DISTRIBUTION (SEVERITY) / SPECIAL COMMENTS

EYES & OPTIC N. ....  
-CORNEAL MINERALIZATION  
-CORNEAL VASCULARIZATION  
-LENTICULAR DEGENERATIVE CHANGES COMPATIBLE WITH CATARACT

AD SEBACIOUS ..... TISSUE IS MISSING

ABDOMINAL CAVITY ..... MISCELLANEOUS TISSUE  
THE SARCOMA INVOLVES PRIMARILY THE LIVER AND DIAPHRAGM WITH  
FOCAL INFILTRATION INTO THE WALL OF THE STOMACH, THE NEOPLASTIC  
CELLS ARE HIGHLY ANAPLASTIC WITH NUMEROUS NEOPLASTIC GIANT CELLS  
AND LARGE BIZARRE MITOTIC FIGURES.  
(PRESENT)

-N- SARCOMA, CELLULAR DIFFERENTIATION UNSPECIFIED  
DIAPHRAGM ..... MISCELLANEOUS TISSUE  
-N- PRESENCE OF METASTATIC SARCOMA  
-COMPOUND RELATED INFLAMMATORY REACTION  
SECONDARY NEOPLASM FROM ORGAN ABDOMINAL CAVITY  
NOT SPECIFIED (PRESENT)

Appendix J (cont.): PATHOLOGY INDIVIDUAL ANIMAL DATA

LETTERMAN ARMY INSTITUTE OF RESEARCH INDIVIDUAL ANIMAL DATA REPORT PRINTED: 21-NOV-69  
DIV OF RES SUPP, PATH SERV GP STUDY NUMBER: GLP83009 PAGE: 518  
SPECIES: RAT/FISCHER-344 STUDY START DATE: 23-JAN-84 STUDY TYPE: CHRONIC/2 YR CARCINOGENIC

ANIMAL NUMBER: 258/PRETEST= 258 SEX: FEMALE DOSE GROUP: 1 SACRIFICE STATUS: FINAL SACRIFICE  
DATE OF DEATH: 14-FEB-86 STUDY DAY OF DEATH: 754 STUDY WEEK OF DEATH: 108 TERMINAL BODY WEIGHT: 247.00 (GMS)

ORGAN NAME SEVERITY GROSS OBSERVATIONS FREE-TEXT COMMENTS  
SPLEEN DISCOLORATION PRESENT 5 X 1 X .5CM  
SPLEEN ENLARGED (SPLEHOMEGALY) PRESENT RIGHT PERITONEAL WALL,DIAPHRAGM.  
LIVER ADMESION(S) PRESENT FIRM, WHITE, 1.5CM DIAMETER, RIGHT LATERAL LOBE  
LIVER GROWTH(S) / MASS(ES) PRESENT  
LIVER ROUNDED EDGES PRESENT  
DUODENUM ADHERED TO LIVER PRESENT ONE LOOP  
UTERUS POLYP PRESENT LEFT HORN, 1CM LONG.

TISSUE / HISTOPATHOLOGIC FINDINGS MICROSCOPIC TISSUE OBSERVATIONS DISTRIBUTION (SEVERITY) / SPECIAL COMMENTS

THYROID GLANDS  
-PARA-FOLLICULAR CELL HYPERPLASIA ("C" CELL, LIGHT CELL) NOT SPECIFIED(TRACE)  
-COLLOID CYST(S) NOT SPECIFIED (PRESENT)

EXORBITAL LACRIM  
-ACINAR ATROPHY MULTI-FOCAL(MODERATE)  
HEART  
-CARDIOMYOPATHY NOT SPECIFIED(MILD)

LUNGS  
-MINERALIZATION OF PULMONARY ARTERIES  
-W- LARGE GRANULAR LYMPHOCYTE LEUKEMIA, METASTATIC NOT SPECIFIED(TRACE)  
(PRESENT)

SPLEEN  
-W- LARGE GRANULAR LYMPHOCYTE LEUKEMIA, METASTATIC (PRESENT)

LYMPH NODES  
-RED BLOOD CELLS, MEMOSIDERIN AND/OR ERYTHROPHAGOCYTOSIS WITHIN ABUNDANT PIGMENT. PRESENT IN MEDIASTINAL NODES.  
MEDULLARY SINUSES NOT SPECIFIED (PRESENT)

LIVER

**Appendix J (cont.): PATHOLOGY INDIVIDUAL ANIMAL DATA**

LETTERMAN ARMY INSTITUTE OF RESEARCH  
 DIV OF RES SUPP, PATH SERV GP  
 SPECIES: RAT/FISCHER-344

INDIVIDUAL ANIMAL DATA REPORT  
 STUDY NUMBER: GLP83009  
 STUDY START DATE: 23-JAN-84

PRINTED: 21-NOV-89  
 PAGE: 519  
 STUDY TYPE: CHRONIC/2 YR CARCINOGENIC

ANIMAL NUMBER: 258/PRETEST= 258 SEX: FEMALE DOSE GROUP: 1 SACRIFICE STATUS: FINAL SACRIFICE  
 DATE OF DEATH: 14-FEB-86 STUDY DAY OF DEATH: 754 STUDY WEEK OF DEATH: 108 TERMINAL BODY WEIGHT: 247.00 (GMS)

<< MICROSCOPIC TISSUE OBSERVATIONS >>  
 DISTRIBUTION (SEVERITY) / SPECIAL COMMENTS

TISSUE / HISTOPATHOLOGIC FINDINGS	OBSERVATIONS
LIVER	NOT SPECIFIED (PRESENT)
-COMPOUND RELATED INFLAMMATORY REACTION	NOT SPECIFIED (TRACE)
-BILE DUCTULE EPITHELIAL HYPERPLASIA AND/OR CHOLANGIOFIBROSIS	NOT SPECIFIED (TRACE)
-FOCUS OF CELLULAR ALTERATION - BASOPHILIC	NOT SPECIFIED (MILD)
-HEPATOCTYIC DEGENERATIVE CHANGES (NON-NECROTIC)	MULTI-FOCAL (TRACE)
-NECROSIS, HEPATOCTYIC, INDIVIDUAL CELLS	(PRESENT)
-N- LARGE GRANULAR LYMPHOCYTE LEUKEMIA, METASTATIC	NOT SPECIFIED (TRACE)
-HEPATOCTYIC COALESCING MICROVESICULAR (FATTY) CHANGE LEADING TO NECROSIS AND MINERALIZATION	SECONDARY NEOPLASM FROM ORGAN ABDOMINAL CAVITY
-N- PRESENCE OF METASTATIC SARCOMA	
KIDNEY	NOT SPECIFIED (MILD)
-PROGRESSIVE RENAL DISEASE	
UTERUS	NOT SPECIFIED (PRESENT)
-ENDOMETRIAL STROMAL POLYP	NOT SPECIFIED (PRESENT)
-CYSTIC DILATATION OF THE ENDOMETRIAL GLANDS	
DUODENUM	NOT SPECIFIED (PRESENT)
-COMPOUND RELATED INFLAMMATORY REACTION	
PANCREAS	NOT SPECIFIED (TRACE)
-CHRONIC INFLAMMATION	
MAMMARY GLANDS	NOT SPECIFIED (TRACE)
-HYPERPLASIA AND/OR HYPERTROPHY OF THE ACINAR TISSUE	NOT SPECIFIED (PRESENT)
-DILATATION (ECTASIA) OF DUCTS AND DUCTULES	
ADRENAL	NOT SPECIFIED (MILD)
-FOCUS OF CELLULAR ALTERATION, VACUOLATED	
PITUITARY GLAND	

Appendix J (cont.): PATHOLOGY INDIVIDUAL ANIMAL DATA

LETTERMAN ARMY INSTITUTE OF RESEARCH  
 DIV OF RES SUPP, PATH SERV GP  
 SPECIES: RAT/FISCHER-344  
 ANIMAL NUMBER: 258/PRETEST-  
 DATE OF DEATH: 14-FEB-86  
 TISSUE / HISTOPATHOLOGIC FINDINGS

INDIVIDUAL ANIMAL DATA REPORT  
 STUDY NUMBER: GLP83009  
 STUDY START DATE: 23-JAN-84  
 DOSE GROUP: 1  
 SEX: FEMALE  
 STUDY WEEK OF DEATH: 754  
 SACRIFICE STATUS: FINAL SACRIFICE  
 TERMINAL BODY WEIGHT: 247.00 (GMS)

STUDY TYPE: CHRONIC/2 YR CARCINOGENIC  
 OBSERVATIONS  
 DISTRIBUTION (SEVERITY) / SPECIAL COMMENTS

PRINTED: 21-NOV-89  
 PAGE: 520

PITUITARY GLAND ..... (PRESENT)  
 -B- ADENOMA

EYES & OPTIC N. ....  
 -CORNEAL VASCULARIZATION ..... FOCAL (TRACE)  
 -METAPLASTIC PONE FORMATION AND/OR MINERALIZATION, SCLERA ..... NOT SPECIFIED (PRESENT)

WHOLE BODY ..... (PRESENT)  
 -M- LARGE GRANULAR LYMPHOCYTTIC LEUKEMIA

ABDOMINAL CAVITY ..... MISCELLANEOUS TISSUE  
 THE SARCOMA INVOLVES PRIMARILY LIVER AND DIAPHRAGM. NEOPLASTIC  
 CELLS ARE PRODUCING LARGE AMOUNTS OF EITHER COLLAGEN OR  
 OSTEOID MATRIX.  
 (PRESENT)

-M- SARCOMA, CELLULAR DIFFERENTIATION UNSPECIFIED

DIAPHRAGM ..... MISCELLANEOUS TISSUE  
 -M- PRESENCE OF METASTATIC SARCOMA ..... SECONDARY NEOPLASM FROM ORGAN ABDOMINAL CAVITY  
 -COMPOUND RELATED INFLAMMATORY REACTION ..... NOT SPECIFIED (PRESENT)



**Appendix J (cont.): PATHOLOGY INDIVIDUAL ANIMAL DATA**

LETTERMAN ARMY INSTITUTE OF RESEARCH  
 DIV OF RES SUPP, PATH SERV GP  
 SPECIES: RAT/FISCHER-344  
 INDIVIDUAL ANIMAL DATA REPORT  
 STUDY NUMBER: GLP83009  
 PRINTED: 21-NOV-89  
 PAGE: 523

ANIMAL NUMBER: 261/PRETEST-261  
 DATE OF DEATH: 14-FEB-86  
 STUDY DAY OF DEATH: 754  
 SEX: FEMALE  
 DOSE GROUP: 1  
 SACRIFICE STATUS: FINAL SACRIFICE  
 STUDY WEEK OF DEATH: 108  
 TERMINAL BODY WEIGHT: 271.00 (GMS)  
 STUDY START DATE: 23-JAN-84  
 STUDY TYPE: CHRONIC/2 YR CARCINOGENIC

ORGAN NAME: << GROSS ORGAN OBSERVATIONS >>  
 KEYWORDS / PHRASES: SEVERITY GROSS FREE-TEXT COMMENTS  
 SKIN: SUBCUTANEOUS MASS PRESENT LEFT THORAX, 3 X 3 X 2CM.  
 LIVER: ADHESION(S) PRESENT DIAPHRAGM, VENTRAL ABDOMINAL WALL, INTESTINE.  
 SKIN: GROWTH(S) / MASS(ES) PRESENT CLITORAL GLAND, 2 X 1CM.

TISSUE / HISTOPATHOLOGIC FINDINGS: << MICROSCOPIC TISSUE OBSERVATIONS >>  
 DISTRIBUTION (SEVERITY) / SPECIAL COMMENTS

PARATHYROID ..... TISSUE IS MISSING  
 HEART ..... NOT SPECIFIED(TRACE)  
 -CARDIOMYOPATHY  
 LUNGS ..... NOT SPECIFIED(TRACE)  
 -MINERALIZATION OF PULMONARY ARTERIES  
 LYMPH NODES ..... RBC'S AND PIGMENT NOTED IN CERVICAL NODES.  
 -RED BLOOD CELLS, MEMOSIDERIN AND/OR ERYTHROPHAGOCYTOSIS WITHIN RBC'S, PIGMENT AND REACTIVE HYPERPLASIA PRESENT IN MEDIASTINAL  
 MEDULLARY SINUSES  
 -REACTIVE HYPERPLASIA  
 NOT SPECIFIED (PRESENT)  
 LIVER ..... NOT SPECIFIED (PRESENT)  
 -COMPOUND RELATED INFLAMMATORY REACTION  
 -BILE DUCTULE EPITHELIAL HYPERPLASIA AND/OR CHOLANGIOFIBROSIS  
 -HEPATITIS  
 -FOCUS OF CELLULAR ALTERATION - BASOPHILIC  
 -HEPATOCTYCE COALESCING MICROVESICULAR (FATTY) CHANGE LEADING TO  
 NECROSIS AND MINERALIZATION  
 NOT SPECIFIED (TRACE)  
 NOT SPECIFIED (MILD)  
 NOT SPECIFIED (MILD)  
 KIDNEY ..... NOT SPECIFIED(MILD)  
 -PROGRESSIVE RENAL DISEASE  
 DUODENUM .....

**Appendix J (cont.): PATHOLOGY INDIVIDUAL ANIMAL DATA**

LETTERMAN ARMY INSTITUTE OF RESEARCH  
 DIV OF RES SUPP, PATH SERV GP  
 SPECIES: RAT/FISCHER-344  
 STUDY START DATE: 23-JAN-84  
 STUDY TYPE: CHRONIC/2 YR CARCINOGENIC  
 ANIMAL NUMBER: 261/PRETEST-261  
 SEX: FEMALE  
 DOSE GROUP: 1  
 SACRIFICE STATUS: FINAL SACRIFICE  
 DATE OF DEATH: 14-FEB-86  
 STUDY DAY OF DEATH: 754  
 STUDY WEEK OF DEATH: 108  
 TERMINAL BODY WEIGHT: 271.00 (GMS)  
 TISSUE / HISTOPATHOLOGIC FINDINGS  
 << MICROSCOPIC TISSUE OBSERVATIONS >>  
 DISTRIBUTION (SEVERITY) / SPECIAL COMMENTS

PRINTED: 21-NOV-89  
 PAGE: 524

DUODENUM ..... NOT SPECIFIED (PRESENT)  
 -COMPOUND RELATED INFLAMMATORY REACTION .....  
 JEJUNUM ..... NOT SPECIFIED (PRESENT)  
 -COMPOUND RELATED INFLAMMATORY REACTION .....  
 SKIN ..... (PRESENT)  
 -B- KERATOACANTHOMA, ANATOMIC SITE TO BE SPECIFIED .....  
 MAMMARY GLANDS ..... THE SUBCUTANEOUS MASS ON THE LEFT THORAX IS A MAMMARY  
 FIBROADENOMA.  
 -HYPERPLASIA AND/OR HYPERTROPHY OF THE ACIMAR TISSUE ..... NOT SPECIFIED(MODERATE)  
 -B- FIBROADENOMA ..... (PRESENT)  
 -DILATATION (ECTASIA) OF DUCTS AND DUCTULES ..... NOT SPECIFIED (PRESENT)  
 NOSE/TURBINATES ..... CELLULAR INFILTRATE INVOLVES NASO-LACRIMAL DUCT.  
 -MIXED INFLAMMATORY CELL INFILTRATION, NASAL CAVITY, SINUSES, ..... NOT SPECIFIED(MILD)  
 TURBINATES, NASO-LACRIMAL DUCTS .....  
 ADRENAL ..... NOT SPECIFIED(MILD)  
 -FOCUS OF CELLULAR ALTERATION, VACUOLATED .....  
 PITUITARY GLAND ..... NOT SPECIFIED (PRESENT)  
 -CYST(S) .....  
 EYES & OPTIC N. .... NOT SPECIFIED (PRESENT)  
 -METAPLASTIC BONE FORMATION AND/OR MINERALIZATION, SCLERA .....  
 THORAX ..... MISCELLANEOUS TISSUE  
 THE SUBCUTANEOUS MASS ON THE LEFT THORAX IS A MAMMARY  
 FIBROADENOMA. THIS DIAGNOSIS IS CODED UNDER MAMMARY GLAND.  
 DIAPHRAGM ..... MISCELLANEOUS TISSUE  
 -COMPOUND RELATED INFLAMMATORY REACTION ..... NOT SPECIFIED (PRESENT)

**Appendix J (cont.): PATHOLOGY INDIVIDUAL ANIMAL DATA**

LETTERMAN ARMY INSTITUTE OF RESEARCH  
 DIV OF RES SUPP, PATH SERV GP  
 SPECIES: RAT/FISCHER-344  
 ANIMAL NUMBER: 262/PRETEST-  
 DATE OF DEATH: 21-JAN-86  
 DOSE GROUP: 1  
 SEX: FEMALE  
 STUDY DAY OF DEATH: 730  
 SACRIFICE STATUS: FOUND DEAD  
 STUDY WEEK OF DEATH: 105  
 TERMINAL BODY WEIGHT: 251.00 (GMS)

INDIVIDUAL ANIMAL DATA REPORT  
 STUDY NUMBER: GLP83009  
 STUDY START DATE: 23-JAN-84  
 STUDY TYPE: CHRONIC/2 YR CARCINOGENIC

PRINTED: 03-JAN-90  
 PAGE: 1

<< GROSS ORGAN OBSERVATIONS >>  
 SEVERITY GROSS FREE-TEXT COMMENTS  
 EYES & OPTIC N. PRESENT LEFT, RED  
 FLUID-FILLED PRESENT 53ML, RED  
 PERITONEAL CAV. PRESENT FOUR .2-.3CM DIAMETER, WHITE, WITHIN MESENTERY  
 PERITONEAL CAV. PRESENT EXTREMELY PALE  
 LIVER PRESENT FIRM, WHITE, IRREGULARLY SHAPED  
 LIVER PRESENT 1CM DIAMETER, YELLOW FLUID FILLED, LEFT  
 OVARIES PRESENT FOCAL, RED, .2CM DIAMETER  
 URINARY BLADDER PRESENT  
 PITUITARY GLAND PRESENT

<< MICROSCOPIC TISSUE OBSERVATIONS >>  
 DISTRIBUTION (SEVERITY) / SPECIAL COMMENTS

THYROID GLANDS ..... TISSUE IS AUTOLYTIC  
 PARATHYROID ..... TISSUE IS AUTOLYTIC  
 HEART ..... NOT SPECIFIED(MILD)  
 -CARDIOMYOPATHY .....  
 SPLEEN ..... NOT SPECIFIED (PRESENT)  
 -EXTRAMEDULLARY HEMATOPOIESIS .....  
 LYMPH NODES ..... METASTATIC OSTEOSARCOMA PRESENT IN MESENTERIC LYMPH NODES.  
 -N- PRESENCE OF METASTATIC SARCOMA ..... SECONDARY NEOPLASM FROM ORGAN  
 LIVER ..... NOT SPECIFIED (PRESENT)  
 -COMPOUND RELATED INFLAMMATORY REACTION ..... NOT SPECIFIED(MODERATE)  
 -NECROSIS, PERIACINAR ..... SECONDARY NEOPLASM FROM ORGAN ABDOMINAL CAVITY  
 -N- PRESENCE OF METASTATIC SARCOMA .....  
 OVARIES ..... NOT SPECIFIED (PRESENT)  
 -PARA-OVARIAN CYST(S) .....

Appendix J (cont.): PATHOLOGY INDIVIDUAL ANIMAL DATA

LETTERMAN ARMY INSTITUTE OF RESEARCH  
 DIV OF RES SUPP, PATH SERV GP  
 SPECIES: RAT/FISCHER-344

INDIVIDUAL ANIMAL DATA REPORT  
 STUDY NUMBER: GLP83009  
 STUDY START DATE: 23-JAN-84

PRINTED: 03-JAN-90  
 PAGE: 2  
 STUDY TYPE: CHRONIC/2 YR CARCINOGENIC

ANIMAL NUMBER: 262/PRETEST-  
 DATE OF DEATH: 21-JAN-86

262 SEX: FEMALE  
 DOSE GROUP: 1  
 SACRIFICE STATUS: FOUND DEAD  
 STUDY DAY OF DEATH: 730  
 STUDY WEEK OF DEATH: 105  
 TERMINAL BODY WEIGHT: 251.00 (GMS)

<< MICROSCOPIC TISSUE OBSERVATIONS >>  
 TISSUE / HISTOPATHOLOGIC FINDINGS  
 DISTRIBUTION (SEVERITY) / SPECIAL COMMENTS

- SCIATIC NERVE ..... TISSUE IS MISSING
- MAMMARY GLANDS .....  
 -HYPERPLASIA AND/OR HYPERTROPHY OF THE ACINAR TISSUE ..... NOT SPECIFIED (TRACE)  
 -DILATATION (ECTASIA) OF DUCTS AND DUCTULES ..... NOT SPECIFIED (PRESENT)
- PITUITARY GLAND .....  
 -B- ADENOMA ..... (PRESENT)
- EYES & OPTIC N. ....  
 BECAUSE OF AUTOLYTIC CHANGES, THE RETINA CANNOT BE EVALUATED HISTOLOGICALLY.
- CORNEAL MINERALIZATION ..... NOT SPECIFIED (TRACE)  
 -CORNEAL VASCULARIZATION ..... NOT SPECIFIED (TRACE)  
 -LENTICULAR DEGENERATIVE CHANGES COMPATIBLE WITH CATARACT ..... NOT SPECIFIED (PRESENT)
- ABDOMINAL CAVITY ..... MISCELLANEOUS TISSUE  
 THE SARCOMA INVOLVES PRIMARILY LIVER. THERE IS ABUNDANT OSTEOID PRODUCTION AND MUCH OF THE OSTEOID IS MINERALIZED. CELLULAR DIFFERENTIATION IS PRIMARILY THAT OF OSTEOSARCOMA.  
 (PRESENT)
- M- SARCOMA, CELLULAR DIFFERENTIATION UNSPECIFIED
- DIAPHRAGM ..... MISCELLANEOUS TISSUE  
 -COMPOUND RELATED INFLAMMATORY REACTION ..... NOT SPECIFIED (PRESENT)

**Appendix J (cont.): PATHOLOGY INDIVIDUAL ANIMAL DATA**

LETTERMAN ARMY INSTITUTE OF RESEARCH  
 DIV OF RES SUPP, PATH SERV GP  
 SPECIES: RAT/FISCHER-344  
 STUDY START DATE: 23-JAN-84  
 ANIMAL NUMBER: 263/PRETEST#  
 DATE OF DEATH: 16-JAN-86  
 SEX: FEMALE  
 DOSE GROUP: 1  
 SACRIFICE STATUS: SACRIFICED MORIBUND  
 STUDY WEEK OF DEATH: 104  
 TERMINAL BODY WEIGHT: 248.00 (GMS)  
 STUDY TYPE: CHRONIC/2 YR CARCINOGENIC

PRINTED: 21-NOV-89  
 PAGE: 527

ORGAN NAME	KEYWORDS / PHRASES	SEVERITY	GROSS OBSERVATIONS	DISTRIBUTION (SEVERITY) / SPECIAL COMMENTS
SKIN	SUBCUTANEOUS MASS	PRESENT	FIRM, WHITE, 2.5 X 2CM, NEAR ANUS	
LIVER	ADHESION(S)	PRESENT	DIAPHRAGM, VENTRAL ABDOMINAL WALL	
PITUITARY GLAND	ENLARGED	PRESENT	.3CM DIAMETER	

<< MICROSCOPIC TISSUE OBSERVATIONS >>  
 TISSUE / HISTOPATHOLOGIC FINDINGS

THYROID GLANDS  
 -PARAFOLLICULAR CELL HYPERPLASIA ("C" CELL, LIGHT CELL) NOT SPECIFIED(TRACE)

HEART  
 -CARDIOMYOPATHY NOT SPECIFIED(MODERATE)

SPLEEN  
 -INFARCTION, CHRONIC NOT SPECIFIED(MODERATE)

LYMPH NODES  
 -RED BLOOD CELLS, HEMOSIDERIN AND/OR ERYTHROPHAGOCYTOSIS WITHIN MEDULLARY SINUSES RBC'S AND HEMOSIDERIN PRESENT IN MEDIASTINAL NODE ONLY.  
 NOT SPECIFIED (PRESENT)

LIVER  
 -COMPOUND RELATED INFLAMMATORY REACTION NOT SPECIFIED (PRESENT)  
 -BILE DUCTULE EPITHELIAL HYPERPLASIA AND/OR CHOLANGIOFIBROSIS MULTI-FOCAL(TRACE)  
 -FOCUS OF CELLULAR ALTERATION - BASOPHILIC MULTI-FOCAL(MODERATE)  
 -BENIGN HYPERPLASTIC NODULE(S) FOCAL(TRACE)

KIDNEY  
 -PROGRESSIVE RENAL DISEASE NOT SPECIFIED(MODERATE)

ILEUM  
 -COMPOUND RELATED INFLAMMATORY REACTION NOT SPECIFIED (PRESENT)  
 -MUCOSAL EROSION/ULCERATION NOT SPECIFIED (PRESENT)

PANCREAS

Appendix J (cont.): PATHOLOGY INDIVIDUAL ANIMAL DATA

LETTERMAN ARMY INSTITUTE OF RESEARCH  
 DIV OF RES SUPP, PATH SERV GP  
 SPECIES: RAT/FISCHER-344

INDIVIDUAL ANIMAL DATA REPORT  
 STUDY NUMBER: GLP83009

STUDY START DATE: 23-JAN-64

STUDY TYPE: CHRONIC/2 YR CARCINOGENIC

ANIMAL NUMBER: 263/PRETEST-  
 DATE OF DEATH: 16-JAN-66

STUDY DAY OF DEATH: 725

DOSE GROUP: 1

SACRIFICE STATUS: SACRIFICED MORIBUND

TERMINAL BODY WEIGHT: 248.00 (GMS)

STUDY WEEK OF DEATH: 104

OBSE R V A T I O N S >>

<< M I C R O S C O P I C T I S S U E D I S T R I B U T I O N ( S E V E R I T Y ) / S P E C I A L C O M M E N T S <<

PRINTED: 21-NOV-89  
PAGE: 528

PANCREAS ..... FOCAL(TRACE)  
 -CHRONIC INFLAMMATION

RECTUM ..... (PRESENT)  
 -I- FIBROSARCOMA, LOCALLY INVASIVE

SKIN ..... THE INGUINAL SUBCUTANEOUS TISSUE IS THE PROBABLE PRIMARY SITE OF THIS SARCOMA. NO TEST COMPOUND WAS OBSERVED IN HISTOLOGIC SECTIONS OF THIS LESION. THE HISTOLOGIC DIFFERENTIATION OF THIS NEOPLASM IS FIBROSARCOMA. (PRESENT)

-M- FIBROSARCOMA

MAMMARY GLANDS ..... NOT SPECIFIED(MILD)  
 -HYPERTROPHY AND/OR HYPERTROPHY OF THE ACINAR TISSUE  
 -DILATATION (ECTASIA) OF DUCTS AND DUCTULES NOT SPECIFIED (PRESENT)

NOSE/TURBINATES ..... CELLULAR INFILTRATE IS LOCATED IN THE VENTRO-LATERAL ASPECT OF THE NASAL CAVITY. NOT SPECIFIED(TRACE)

-MIXED INFLAMMATORY CELL INFILTRATION, NASAL CAVITY, SINUSES, TURBINATES, NASO-LACRIMAL DUCTS

ADRENAL ..... NOT SPECIFIED(MILD)  
 -FOCUS OF CELLULAR ALTERATION, VACUOLATED

PITUITARY GLAND ..... (PRESENT)  
 -B- ADENOMA

EYES & OPTIC N. .... NUMEROUS PROCESSING ARTIFACTS MAKE DETAILED HISTOLOGIC EVALUATION IMPOSSIBLE. IF ACTS MAKE DETAILED HISTOLOGIC NOT SPECIFIED(TRACE)  
 -CORNEAL MINERALIZATION  
 -CORNEAL VASCULARIZATION NOT SPECIFIED(TRACE)

DIAPHRAGM ..... MISCELLANEOUS TISSUE  
 -COMPOUND RELATED INFLAMMATORY REACTION NOT SPECIFIED (PRESENT)

**Appendix J (cont.): PATHOLOGY INDIVIDUAL ANIMAL DATA**

LETTERMAN ARMY INSTITUTE OF RESEARCH  
 DIV OF RES SUPP, PATH SERV GP  
 SPECIES: RAT/FISCHER-344  
 STUDY NUMBER: GLP83009  
 STUDY START DATE: 23-JAN-84  
 PRINTED: 21-NOV-89  
 PAGE: 529

ANIMAL NUMBER: 264/PRETEST-264 SEX: FEMALE DOSE GROUP: 1 SACRIFICE STATUS: SACRIFICED MORIBUND  
 DATE OF DEATH: 05-NOV-85 STUDY DAY OF DEATH: 653 STUDY WEEK OF DEATH: 94 TERMINAL BODY WEIGHT: 230.00 (GMS)  
 STUDY TYPE: CHRONIC/2 YR CARCINOGENIC

ORGAN NAME << GROSS ORGAN OBSERVATIONS >>  
 SEVERITY GROSS FREE-TEXT COMMENTS  
 UTERUS POLYP PRESENT RIGHT HORN, 2 X 1CM  
 LIVER ADHESION(S) PRESENT DIAPHRAGM, VENTRAL ABDOMINAL WALL, INTESTINES, STOMACH  
 LIVER GROWTH(S) / MASS(ES) PRESENT FIRM, WHITE, INVOLVES 3/4 OF THE LIVER

TISSUE / HISTOPATHOLOGIC FINDINGS << MICROSCOPIC TISSUE OBSERVATIONS >>  
 DISTRIBUTION (SEVERITY) / SPECIAL COMMENTS

- HEART ..... NOT SPECIFIED(MILD)
- CARDIOMYOPATHY
- LUNGS ..... NOT SPECIFIED(TRACE)
- MINERALIZATION OF PULMONARY ARTERIES
- SPLEEN ..... NOT SPECIFIED (PRESENT)
- HEMOSIDERIN PIGMENTATION (RED PULP)
- LYMPH NODES ..... REACTIVE HYPERPLASIA, RBC'S AND PIGMENT PRESENT IN MESENTERIC NODES.  
 NOT SPECIFIED (PRESENT)
- RED BLOOD CELLS, HEMOSIDERIN AND/OR ERYTHROPHAGOCYTOSIS WITHIN MEDULLARY SINUSES  
 NOT SPECIFIED (PRESENT)
- REACTIVE HYPERPLASIA  
 NOT SPECIFIED (PRESENT)
- LIVER ..... NOT SPECIFIED (PRESENT)  
 -COMPOUND RELATED INFLAMMATORY REACTION  
 -HEPATITIS  
 -NECROSIS, PERIACINAR  
 -N- PRESENCE OF METASTATIC SARCOMA  
 SECONDARY NEOPLASM FROM ORGAN ABDOMINAL CAVITY
- UTERUS ..... NOT SPECIFIED (PRESENT)
- ENDOMETRIAL STROMAL POLYP
- JEJUNUM .....

**Appendix J (cont.): PATHOLOGY INDIVIDUAL ANIMAL DATA**

LETTERMAN ARMY INSTITUTE OF RESEARCH  
 DIV OF RES SUPP, PATH SERV GP  
 SPECIES: RAT/FISCHER-344  
 STUDY START DATE: 23-JAN-84  
 ANIMAL NUMBER: 264/PRETEST-264 SEX: FEMALE DOSE GROUP: 1 SACRIFICE STATUS: SACRIFICED MORIBUND  
 DATE OF DEATH: 05-NOV-85 STUDY DAY OF DEATH: 653 STUDY WEEK OF DEATH: 94 TERMINAL BODY WEIGHT: 230.00 (GMS)  
 TISSUE / HISTOPATHOLOGIC FINDINGS << M I C R O S C O P I C T I S S U E O B S E R V A T I O N S >>  
 DISTRIBUTION (SEVERITY) / SPECIAL COMMENTS

PRINTED: 21-NOV-89  
 PAGE: 530  
 STUDY TYPE: CHRONIC/2 YR CARCINOGENIC

- JEJUNUM ..... SECONDARY NEOPLASM FROM ORGAN
- N- PRESENCE OF METASTATIC SARCOMA
- RECTUM ..... TISSUE IS MISSING
- BONE, STERNUM ..... TISSUE IS MISSING
- ADRENAL ..... NOT SPECIFIED (TRACE)
- FOCUS OF CELLULAR ALTERATION, VACUOLATED
- EYES & OPTIC N. .... TISSUE IS MISSING
- NUMEROUS ARTIFACTS INDUCED DURING PROCESSING MAKE HISTOLOGIC EVALUATION OF EYES IMPOSSIBLE.
- MEDIASTINUM ..... MISCELLANEOUS TISSUE
- N- PRESENCE OF METASTATIC SARCOMA ..... SECONDARY NEOPLASM FROM ORGAN ABDOMINAL CAVITY
- ABDOMINAL CAVITY ..... MISCELLANEOUS TISSUE
- THE SARCOMA INVOLVES PRIMARILY LIVER, DIAPHRAGM AND SMALL INTESTINE. CELLULAR ARRANGEMENT AND MORPHOLOGY ARE TYPICAL OF FIBROSARCOMA. (PRESENT)
- M- SARCOMA, CELLULAR DIFFERENTIATION UNSPECIFIED
- DIAPHRAGM ..... MISCELLANEOUS TISSUE
- N- PRESENCE OF METASTATIC SARCOMA ..... SECONDARY NEOPLASM FROM ORGAN ABDOMINAL CAVITY
- COMPOUND RELATED INFLAMMATORY REACTION ..... NOT SPECIFIED (PRESENT)



Appendix J (cont.): PATHOLOGY INDIVIDUAL ANIMAL DATA

LETTERMAN ARMY INSTITUTE OF RESEARCH  
 DIV OF RES SUPP, PATH SERV GP  
 SPECIES: RAT/FISCHER-344

INDIVIDUAL ANIMAL DATA REPORT  
 STUDY NUMBER: GLP83009  
 STUDY START DATE: 23-JAN-84

ANIMAL NUMBER: 265/PRETEST-  
 DATE OF DEATH: 14-FEB-86

STUDY TYPE: CHRONIC/2 YR CARCINOGENIC  
 DOSE GROUP: 1  
 SACRIFICE STATUS: FINAL SACRIFICE  
 STUDY WEEK OF DEATH: 108  
 TERMINAL BODY WEIGHT: 258.00 (GMS)

ORGAN NAME << GROSS ORGAN OBSERVATIONS >>  
 SEVERITY GROSS FREE-TEXT COMMENTS

LIVER ADMETION(S)  
 PITUITARY GLAND ENLARGED

PRESENT SMALL INTESTINE, VENTRAL ABDOMINAL WALL, DIAPHRAGM.  
 PRESENT .5CM DIAMETER.  
 6.. DARK RED

TISSUE / HISTOPATHOLOGIC FINDINGS << MICROSCOPIC TISSUE OBSERVATIONS >>  
 DISTRIBUTION (SEVERITY) / SPECIAL COMMENTS

HEART  
 -CARDIOMYOPATHY

NOT SPECIFIED(MILD)

LUNGS  
 -MINERALIZATION OF PULMONARY ARTERIES  
 -PNEUMONIA, INTERSTITIAL, CHRONIC

NOT SPECIFIED(TRACE)  
 FOCAL(TRACE)

SPLEEN  
 -INFARCTION, CHRONIC  
 -HEMOSIDERIN PIGMENTATION (RED PULP)

MULTI-FOCAL(MILD)  
 NOT SPECIFIED (PRESENT)

LYMPH NODES

RBC'S AND REACTIVE HYPERPLASIA NOTED IN CERVICAL NODE.  
 PIGMENT PRESENT IN MEDIASTINAL NODE AND DILATED SINUSOIDS NOTED  
 IN MESENTERIC NODE.  
 NOT SPECIFIED (PRESENT)

-RED BLOOD CELLS, HEMOSIDERIN AND/OR ERYTHROPHAGOCYTOSIS WITHIN  
 MEDULLARY SINUSES  
 -REACTIVE HYPERPLASIA  
 -DILATED AND/OR CYSTIC MEDULLARY SINUSES

NOT SPECIFIED (PRESENT)  
 NOT SPECIFIED (PRESENT)

LIVER  
 -COMPOUND RELATED INFLAMMATORY REACTION  
 -BILE DUCTULE EPITHELIAL HYPERPLASIA AND/OR CHOLANGIOFIBROSIS  
 -HEPATITIS  
 -FOCUS OF CELLULAR ALTERATION - BASOPHILIC  
 -HEPATOCTYIC VACUOLIZATION

NOT SPECIFIED (PRESENT)  
 NOT SPECIFIED(TRACE)  
 MULTI-FOCAL(MILD)  
 NOT SPECIFIED(MILD)  
 NOT SPECIFIED(TRACE)

Appendix J (cont.): PATHOLOGY INDIVIDUAL ANIMAL DATA

LETTERMAN ARMY INSTITUTE OF RESEARCH  
DIV OF RES SUPP, PATH SERV GP  
SPECIES: RAT/FISCHER-344

INDIVIDUAL ANIMAL DATA REPORT  
STUDY NUMBER: GLP83009

PRINTED: 21-NOV-89  
PAGE: 532

STUDY START DATE: 23-JAN-84

STUDY TYPE: CHRONIC/2 YR CARCINOGENIC

ANIMAL NUMBER: 265/PRETEST= 265 SEX: FEMALE DOSE GROUP: 1 SACRIFICE STATUS: FINAL SACRIFICE  
DATE OF DEATH: 14-FEB-86 STUDY DAY OF DEATH: 754 STUDY WEEK OF DEATH: 106 TERMINAL BODY WEIGHT: 258.00 (GMS)

<< MICROSCOPIC TISSUE OBSERVATIONS >>  
DISTRIBUTION (SEVERITY) / SPECIAL COMMENTS

- LIVER ..... MULTI-FOCAL(TRACE)
- NECROSIS, HEPATOCTYIC, INDIVIDUAL CELLS
- KIDNEY ..... NOT SPECIFIED(MILD)
- PROGRESSIVE RENAL DISEASE
- UTERUS ..... NOT SPECIFIED (PRESENT)
- CYSTIC DILATATION OF THE ENDOMETRIAL GLANDS
- JEJUNUM ..... NOT SPECIFIED (PRESENT)
- COMPOUND RELATED INFLAMMATORY REACTION
- ENTERITIS, SUBACUTE
- MUCOSAL EROSION/ULCERATION
- COLON ..... NOT SPECIFIED (PRESENT)
- COMPOUND RELATED INFLAMMATORY REACTION
- MAMMARY GLANDS ..... NOT SPECIFIED(MODERATE)
- HYPERPLASIA AND/OR HYPERTROPHY OF THE ACINAR TISSUE
- DILATATION (ECTASIA) OF DUCTS AND DUCTULES
- PITUITARY GLAND ..... (PRESENT)
- B- ADENOMA
- DIAPHRAGM ..... MISCELLANEOUS TISSUE
- COMPOUND RELATED INFLAMMATORY REACTION

**Appendix J (cont.): PATHOLOGY INDIVIDUAL ANIMAL DATA**

LETTERMAN ARMY INSTITUTE OF RESEARCH  
 DIV OF RES SUPP, PATH SERV GP  
 SPECIES: RAT/FISCHER-344

INDIVIDUAL ANIMAL DATA REPORT  
 STUDY NUMBER: GLP83009  
 STUDY START DATE: 23-JAN-84

PRINTED: 21-NOV-89  
 PAGE: 533  
 STUDY TYPE: CHRONIC/2 YR CARCINOGENIC

ANIMAL NUMBER: 266/PRETEST= 266 SEX: FEMALE DOSE GROUP: 1 SACRIFICE STATUS: FINAL SACRIFICE  
 DATE OF DEATH: 14-FEB-86 STUDY DAY OF DEATH: 754 STUDY WEEK OF DEATH: 108 TERMINAL BODY WEIGHT: 268.00 (GMS)

<< GROSS ORGAN OBSERVATIONS >>  
 SEVERITY GROSS FREE-TEXT COMMENTS  
 LIVER PRESENT STOMACH, DIAPHRAGM, LEFT PERITONEAL WALL.  
 JEJUNUM PRESENT SEVERAL LOOPS.  
 PITUITARY GLAND ENLARGED DARK, .3CM DIAMETER

<< MICROSCOPIC TISSUE OBSERVATIONS >>  
 DISTRIBUTION (SEVERITY) / SPECIAL COMMENTS

HEART  
 -CARDIOMYOPATHY NOT SPECIFIED(MILD)  
 -MEDIAL HYPERTROPHY OF MUSCULAR ARTERIES NOT SPECIFIED(TRACE)

SPLEEN  
 -FIBROSIS CAPSULAR FOCAL(TRACE)

LYMPH NODES  
 -RED BLOOD CELLS, HEMOSIDERIN AND/OR ERYTHROPHAGOCYTOSIS WITHIN RBC'S AND REACTIVE HYPERPLASIA NOTED IN CERVICAL NODES.  
 -REACTIVE HYPERPLASIA RBC'S AND PIGMENT PRESENT IN MEDIASTINAL NODE.  
 NOT SPECIFIED (PRESENT)

LIVER  
 -COMPOUND RELATED INFLAMMATORY REACTION NOT SPECIFIED (PRESENT)  
 -BILE DUCTULE EPITHELIAL HYPERPLASIA AND/OR CHOLANGIOFIBROSIS NOT SPECIFIED(TRACE)  
 -HEPATITIS MULTI-FOCAL(TRACE)  
 -HEPATOCTYCE COALESCING MICROVESICULAR (FATTY) CHANGE LEADING TO NOT SPECIFIED(MODERATE)  
 NECROSIS AND MINERALIZATION

KIDNEY  
 -PROGRESSIVE RENAL DISEASE NOT SPECIFIED(MODERATE)

JEJUNUM  
 -COMPOUND RELATED INFLAMMATORY REACTION NOT SPECIFIED (PRESENT)

PANCREAS

Appendix J (cont.): PATHOLOGY INDIVIDUAL ANIMAL DATA

LETTERMAN ARMY INSTITUTE OF RESEARCH  
 DIV OF RES SUPP, PATH SERV GP  
 SPECIES: RAT/FISCHER-344

INDIVIDUAL ANIMAL DATA REPORT  
 STUDY NUMBER: GLP83009

STUDY START DATE: 23-JAN-84

PRINTED: 21-NOV-89  
 PAGE: 534

STUDY TYPE: CHRONIC/2 YR CARCINOGENIC

ANIMAL NUMBER: 266/PRETEST= 266 SEX: FEMALE DOSE GROUP: 1 SACRIFICE STATUS: FINAL SACRIFICE  
 DATE OF DEATH: 14-FEB-86 STUDY DAY OF DEATH: 754 STUDY WEEK OF DEATH: 108 TERMINAL BODY WEIGHT: 268.00 (GMS)

TISSUE / HISTOPATHOLOGIC FINDINGS << MICROSCOPIC TISSUE OBSERVATIONS >>  
 DISTRIBUTION (SEVERITY) / SPECIAL COMMENTS

PANCREAS ..... FOCAL (TRACE)  
 -ACINAR (EXOCRINE) ATROPHY

STOMACH ..... NOT SPECIFIED (PRESENT)  
 -COMPOUND RELATED INFLAMMATORY REACTION

SKIN ..... TISSUE IS MISSING

MAMMARY GLANDS ..... MAMMARY DYSPLASIA TAKEN FROM SLIDE #4. NO SKIN OR MAMMARY TISSUE  
 -HYPERPLASIA AND/OR HYPERTROPHY OF THE ACINAR TISSUE  
 WAS SUBMITTED FOR BLOCK #15.  
 NOT SPECIFIED (TRACE)

BONE, FEMUR ..... NOT SPECIFIED (PRESENT)  
 -HYPERPLASIA MYELOID

ADRENAL ..... FOCAL (TRACE)  
 -FOCUS OF CELLULAR ALTERATION, EOSINOPHILIC  
 -FOCUS OF CELLULAR ALTERATION, VACUOLATED  
 MULTI-FOCAL (TRACE)

PITUITARY GLAND ..... (PRESENT)  
 -B- ADENOMA

EYES & OPTIC N. ..... NOT SPECIFIED (TRACE)  
 -CORNEAL VASCULARIZATION

DIAPHRAGM ..... MISCELLANEOUS TISSUE  
 -COMPOUND RELATED INFLAMMATORY REACTION  
 NOT SPECIFIED (PRESENT)

Appendix J (cont.): PATHOLOGY INDIVIDUAL ANIMAL DATA

LETTERMAN ARMY INSTITUTE OF RESEARCH  
 DIV OF RES SUPP, PATH SERV GP  
 SPECIES: RAT/FISCHER-344

INDIVIDUAL ANIMAL DATA REPORT  
 STUDY NUMBER: GLP83009

PRINTED: 21-NOV-89  
 PAGE: 535

STUDY START DATE: 23-JAN-84

STUDY TYPE: CHRONIC/2 YR CARCINOGENIC

ANIMAL NUMBER: 267/PRETEST-

267 SEX: FEMALE

DOSE GROUP: 1

SACRIFICE STATUS: SACRIFICED MORIBUND

DATE OF DEATH: 10-MAY-85

STUDY DAY OF DEATH: 474

STUDY WEEK OF DEATH: 68

TERMINAL BODY WEIGHT: 243.00 (GMS)

ORGAN NAME

<< GROSS ORGAN OBSERVATIONS >>

SEVERITY GROSS FREE-TEXT COMMENTS

SPLEEN ENLARGED (SPLENOmegaly)

MODERATE 6 X 1.5 X 1CM

PRESENT

OVARIES PARA-OVARIAN CYST(S)

GROWTH(S) / MASS(ES)

PRESENT

PRESENT THREE FIRM WHITE ROUND MODULES ATTACHED TO CAPSULE, FILLED WITH CLEAR YELLOL FLUID, 1CM DIAMETER

SM INTESTINE ADHERED TO MASS

PRESENT

PRESENT FIRM, WHITE, MULTIMODULAR, 4CM DIAMETER.

STOMACH ADHERED TO MASS

PRESENT

TISSUE / HISTOPATHOLOGIC FINDINGS

<< MICROSCOPIC TISSUE OBSERVATIONS >>

DISTRIBUTION (SEVERITY) / SPECIAL COMMENTS

HEART -CARDIOMYOPATHY

NOT SPECIFIED(TRACE)

LUNGS

-N- LARGE GRANULAR LYMPHOCYTE LEUKEMIA, METASTATIC

(PRESENT)

SPLEEN

-N- LARGE GRANULAR LYMPHOCYTE LEUKEMIA, METASTATIC

(PRESENT)

SECONDARY NEOPLASM FROM ORGAN ABDOMINAL CAVITY

LYMPH NODES

-RED BLOOD CELLS, HEMOSIDERIN AND/OR ERYTHROPHAGOCYTOSIS WITHIN MEDULLARY SINUSES

RBC'S AND REACTIVE HYPERPLASIA NOTED IN MEDIASTINAL NODES. NOT SPECIFIED (PRESENT)

LIVER

-N- LARGE GRANULAR LYMPHOCYTE LEUKEMIA, METASTATIC

(PRESENT)

NOT SPECIFIED (PRESENT)

COMPOUND RELATED INFLAMMATORY REACTION

-BILE DUCTULE EPITHELIAL HYPERPLASIA AND/OR CHOLANGIOFIBROSIS

NOT SPECIFIED (PRESENT)

HEPATOCTYIC DEGENERATIVE CHANGES (NON-NECROTIC)

-N- LARGE GRANULAR LYMPHOCYTE LEUKEMIA, METASTATIC

NOT SPECIFIED(TRACE)

HEPATOCTYIC DEGENERATIVE CHANGES (NON-NECROTIC)

-N- LARGE GRANULAR LYMPHOCYTE LEUKEMIA, METASTATIC

NOT SPECIFIED(MILD)

(PRESENT)

**Appendix J (cont.): PATHOLOGY INDIVIDUAL ANIMAL DATA**

LETTERMAN ARMY INSTITUTE OF RESEARCH  
 DIV OF RES SUPP, PATH SERV GP  
 SPECIES: RAT/FISCHER-344  
 PRINTED: 21-NOV-89  
 PAGE: 536  
 STUDY NUMBER: GLP83009  
 STUDY START DATE: 23-JAN-84  
 STUDY TYPE: CHRONIC/2 YR CARCINOGENIC  
 ANIMAL NUMBER: 267/PRETEST# 267 SEX: FEMALE DOSE GROUP: 1 SACRIFICE STATUS: SACRIFICED MORIBUND  
 DATE OF DEATH: 10-MAY-85 STUDY DAY OF DEATH: 474 STUDY WEEK OF DEATH: 68 TERMINAL BODY WEIGHT: 243.00 (GMS)  
 << MICROSCOPIC TISSUE OBSERVATIONS >>  
 TISSUE / HISTOPATHOLOGIC FINDINGS DISTRIBUTION (SEVERITY) / SPECIAL COMMENTS

LIVER ..... SECONDARY NEOPLASM FROM ORGAN ABDOMINAL CAVITY  
 -M- PRESENCE OF METASTATIC SARCOMA  
 KIDNEY ..... NOT SPECIFIED(TRACE)  
 -PROGRESSIVE RENAL DISEASE  
 URINARY BLADDER ..... (PRESENT)  
 -B- TRANSITIONAL CELL PAPILLOMA  
 OVARIES ..... NOT SPECIFIED (PRESENT)  
 -PARA-OVARIAN CYST(S)  
 STOMACH ..... NOT SPECIFIED (PRESENT)  
 -COMPOUND RELATED INFLAMMATORY REACTION  
 SKIN ..... (PRESENT)  
 -B- CLITORAL GLAND ADENOMA  
 MAMMARY GLANDS ..... NOT SPECIFIED(MILD)  
 -HYPERPLASIA AND/OR HYPERTROPHY OF THE ACINAR TISSUE NOT SPECIFIED (PRESENT)  
 -DILATATION (ECTASIA) OF DUCTS AND DUCTULES  
 NOSE/TURBINATES ..... THE INFLAMMATORY CELL INFILTRATE INVOLVES MASO-LACRIMAL DUCTS  
 -MIXED INFLAMMATORY CELL INFILTRATION, NASAL CAVITY, SINUSES, BILATERALLY.  
 TURBINATES, MASO-LACRIMAL DUCTS NOT SPECIFIED(MILD)  
 BONE, FEMUR ..... NOT SPECIFIED (PRESENT)  
 -HYPERPLASIA MYELOID  
 ADRENAL ..... (PRESENT)  
 -M- LARGE GRANULE LYMPHOCYTE LEUKEMIA, METASTATIC

Appendix J (cont.): PATHOLOGY INDIVIDUAL ANIMAL DATA

LETTERMAN ARMY INSTITUTE OF RESEARCH  
DIV OF RES SUPP, PATH SERV GP  
SPECIES: RAT/FISCHER-344

INDIVIDUAL ANIMAL DATA REPORT

STUDY NUMBER: GLP83009

STUDY START DATE: 23-JAN-84

PRINTED: 21-NOV-89

PAGE: 537

STUDY TYPE: CHRONIC/2 YR CARCINOGENIC

ANIMAL NUMBER: 267/PRETEST-267 SEX: FEMALE DOSE GROUP: 1 SACRIFICE STATUS: SACRIFICED MORIBUND  
DATE OF DEATH: 10-MAY-85 STUDY DAY OF DEATH: 474 STUDY WEEK OF DEATH: 68 TERMINAL BODY WEIGHT: 243.00 (GMS)

TISSUE / HISTOPATHOLOGIC FINDINGS << MICROSCOPIC TISSUE OBSERVATIONS >>  
DISTRIBUTION (SEVERITY) / SPECIAL COMMENTS

EYES & OPTIC N. .... TISSUE IS MISSING  
EYES CANNOT BE EVALUATED HISTOLOGICALLY BECAUSE OF PROCESSING  
ARTIFACTS.

WHOLE BODY ..... (PRESENT)  
-M- LARGE GRANULAR LYMPHOCYTTIC LEUKEMIA

ABDOMINAL CAVITY ..... MISCELLANEOUS TISSUE  
THE SARCOMA INVOLVES PRIMARILY LIVER AND DIAPHRAGM WITH FOCAL  
AREAS OF IMPLANTATION ON THE CAPSULAR SURFACE OF THE SPLEEN.  
THE CELLULAR DIFFERENTIATION AND ARRANGEMENT TO THE NEOPLASTIC  
CELLS IS CONSISTENT WITH FIBROSARCOMA. SOME CELLS ARE FAIRLY  
ANAPLASTIC IN APPEARANCE AND HAVE LARGE HYPERCHROMATIC NUCLEI.  
LARGE IRREGULAR AREAS OF NECROSIS ARE RANDOMLY SITUATED  
THROUGHOUT THE NEOPLASTIC MASS.  
(PRESENT)

-M- SARCOMA, CELLULAR DIFFERENTIATION UNSPECIFIED  
DIAPHRAGM ..... MISCELLANEOUS TISSUE  
SECONDARY NEOPLASM FROM ORGAN ABDOMINAL CAVITY  
NOT SPECIFIED (PRESENT)

-M- PRESENCE OF METASTATIC SARCOMA  
-COMPOUND RELATED INFLAMMATORY REACTION

Appendix J (cont.): PATHOLOGY INDIVIDUAL ANIMAL DATA

LETTERMAN ARMY INSTITUTE OF RESEARCH  
DIV OF RES SUPP, PATH SERV GP  
SPECIES: RAT/FISCHER-344

INDIVIDUAL ANIMAL DATA REPORT  
STUDY NUMBER: GLP83009

PRINTED: 21-NOV-89  
PAGE: 538

STUDY START DATE: 23-JAN-84

STUDY TYPE: CHRONIC/2 YR CARCINOGENIC

ANIMAL NUMBER: 268/PRETEST= 268 SEX: FEMALE DOSE GROUP: 1 SACRIFICE STATUS: SACRIFICED MORIBUND

DATE OF DEATH: 25-OCT-85 STUDY DAY OF DEATH: 642 STUDY WEEK OF DEATH: 92 TERMINAL BODY WEIGHT: 221.00 (GMS)

<< GROSS ORGAN OBSERVATIONS >>

SEVERITY GROSS FREE-TEXT COMMENTS

LIVER ..... ADHESION(S) PRESENT DIAPHRAGM PRESENT RED/BLACK  
PITUITARY GLAND ..... ENLARGED

<< MICROSCOPIC TISSUE OBSERVATIONS >>

TISSUE / HISTOPATHOLOGIC FINDINGS ..... DISTRIBUTION (SEVERITY) / SPECIAL COMMENTS

THYROID GLANDS .....  
-PARA-FOLLICULAR CELL HYPERPLASIA (\*C) CELL, LIGHT CELL) ..... NOT SPECIFIED(MILD)

HEART .....  
-CARDIOMYOPATHY ..... NOT SPECIFIED(TRACE)

LUNGS .....  
-MINERALIZATION OF PULMONARY ARTERIES ..... NOT SPECIFIED(TRACE)

SPLEEN .....  
-FIBROSIS CAPSULAR ..... NOT SPECIFIED(TRACE)

LYMPH NODES .....  
-RED BLOOD CELLS, HEMOSIDERIN AND/OR ERYTHROPHAGOCYTOSIS WITHIN MEDIASTINAL NODES ..... REACTIVE HYPERPLASIA, RBC'S AND PIGMENT PRESENT IN CERVICAL AND  
MEDULLARY SINUSES ..... NOT SPECIFIED (PRESENT)  
-REACTIVE HYPERPLASIA ..... NOT SPECIFIED (PRESENT)

LIVER .....  
-COMPOUND RELATED INFLAMMATORY REACTION ..... NOT SPECIFIED (PRESENT)  
-BILE DUCTULE EPITHELIAL HYPERPLASIA AND/OR CHOLANGIOFIBROSIS ..... NOT SPECIFIED(MILD)  
-HEPATITIS ..... MULTI-FOCAL(TRACE)  
-PERIPORTAL MONONUCLEAR CELLULAR INFILTRATION ..... NOT SPECIFIED(TRACE)

KIDNEY .....  
-PROGRESSIVE RENAL DISEASE ..... NOT SPECIFIED(MILD)



Appendix J (cont.): PATHOLOGY INDIVIDUAL ANIMAL DATA

LETTERMAN ARMY INSTITUTE OF RESEARCH  
 DIV OF RES SUPP, PATH SERV GP  
 SPECIES: RAT/FISCHER-344  
 INDIVIDUAL ANIMAL DATA REPORT  
 STUDY NUMBER: GLP83009  
 STUDY START DATE: 23-JAN-84  
 STUDY TYPE: CHRONIC/2 YR CARCINOGENIC  
 ANIMAL NUMBER: 268/PRETEST# 268 SEX: FEMALE DOSE GROUP: 1 SACRIFICE STATUS: SACRIFICED MORIBUND  
 DATE OF DEATH: 25-OCT-85 STUDY DAY OF DEATH: 642 STUDY WEEK OF DEATH: 92 TERMINAL BODY WEIGHT: 221.00 (GMS)  
 TISSUE / HISTOPATHOLOGIC FINDINGS  
 << MICROSCOPIC TISSUE OBSERVATIONS >>  
 DISTRIBUTION (SEVERITY) / SPECIAL COMMENTS

PRINTED: 21-NOV-89  
 PAGE: 539

MAMMARY GLANDS ..... MAMMARY TISSUE NOT PRESENT IN SECTION #15. DIAGNOSES WERE  
 BASED ON OBSERVATIONS OF MAMMARY TISSUE ADJACENT TO THE RECTUM  
 IN SECTION #13.  
 -HYPERPLASIA AND/OR HYPERTROPHY OF THE ACINAR TISSUE NOT SPECIFIED(MODERATE)  
 -DILATATION (ECTASIA) OF DUCTS AND DUCTULES NOT SPECIFIED (PRESENT)

PITUITARY GLAND ..... (PRESENT)  
 -B- ADENOMA

EYES & OPTIC N. .... NOT SPECIFIED(MILD)  
 -RETINAL ATROPHY AND/OR DEGENERATION, UNILATERAL OR BILATERAL NOT SPECIFIED(TRACE)  
 -CORNEAL VASCULARIZATION NOT SPECIFIED(MILD)  
 -CHRONIC KERATITIS

DIAPHRAGM ..... MISCELLANEOUS TISSUE  
 -COMPOUND RELATED INFLAMMATORY REACTION NOT SPECIFIED (PRESENT)

Appendix J (cont.): PATHOLOGY INDIVIDUAL ANIMAL DATA

LETTERMAN ARMY INSTITUTE OF RESEARCH  
DIV OF RES SUPP, PATH SERV GP  
SPECIES: RAT/FISCHER-344  
STUDY NUMBER: GLP83009  
STUDY START DATE: 23-JAN-84  
STUDY TYPE: CHRONIC/2 YR CARCINOGENIC  
PRINTED: 21-NOV-89  
PAGE: 540

ANIMAL NUMBER: 269/PRETEST-269  
DATE OF DEATH: 09-JUL-85  
SEX: FEMALE  
DOSE GROUP: 1  
SACRIFICE STATUS: FOUND DEAD  
STUDY WEEK OF DEATH: 77  
TERMINAL BODY WEIGHT: 227.00 (GMS)

ORGAN NAME  
EYES & OPTIC N.  
LIVER  
LIVER  
PLEURAL CAVITY  
SPLEEN  
WHOLE BODY  
WHOLE BODY  
GROSS ORGAN OBSERVATIONS  
KEYWORDS / PHRASES  
STAINED HAIR  
ADHESION(S)  
GROWTH(S) / MASS(ES)  
HEMOTHROAX  
ENLARGED (SPLENOMEGALY)  
POST MORTEM AUTOLYSIS.  
POSSIBLE MECHANICAL INJURY  
SEVERITY GROSS FREE-TEXT COMMENTS  
PRESENT RED PIGMENT  
PRESENT DIAPHRAGM  
PRESENT FIRM, WHITE, 5 X 4CM, EXTENDS INTO THORAX, MULTIPLE FIBROUS MODULES.  
PRESENT 1/3 FULL  
MILD 3 X .7CM  
MARKED  
PRESENT

TISSUE / HISTOPATHOLOGIC FINDINGS  
MICROSCOPIC TISSUE OBSERVATIONS  
DISTRIBUTION (SEVERITY) / SPECIAL COMMENTS

PARATHYROID  
SALIVARY GLAND  
EXORBITAL LACRIM  
HEART  
-CARDIOMYOPATHY  
SPLEEN  
-EXTRAMEDULLARY HEMATOPOIESIS  
LYMPH NODES  
-RED BLOOD CELLS, MEMOSIDERIN AND/OR ERYTHROPHAGOCYTOSIS WITHIN MEDULLARY SINUSES  
-REACTIVE HYPERPLASIA  
LIVER  
-COMPOUND RELATED INFLAMMATORY REACTION  
TISSUE IS MISSING  
TISSUE IS MISSING  
TISSUE IS MISSING  
NOT SPECIFIED (TRACE)  
NOT SPECIFIED (PRESENT)  
NOT SPECIFIED (PRESENT)  
REACTIVE HYPERPLASIA PRESENT IN MESENTERIC NODES. RBC'S AND PIGMENT PRESENT IN MEDIASTINAL NODE.  
NOT SPECIFIED (PRESENT)  
NOT SPECIFIED (PRESENT)  
NOT SPECIFIED (PRESENT)

Appendix J (cont.): PATHOLOGY INDIVIDUAL ANIMAL DATA

LETTERMAN ARMY INSTITUTE OF RESEARCH  
 DIV OF RES SUPP, PATH SERV GP  
 SPECIES: RAT/FISCHER-344  
 STUDY NUMBER: GLP83009  
 STUDY START DATE: 23-JAN-84  
 STUDY TYPE: CHRONIC/2 YR CARCINOGENIC

ANIMAL NUMBER: 269/PRETEST#  
 DOSE GROUP: 1  
 SACRIFICE STATUS: FOUND DEAD  
 DATE OF DEATH: 09-JUL-85  
 STUDY DAY OF DEATH: 534  
 STUDY WEEK OF DEATH: 77  
 TERMINAL BODY WEIGHT: 227.00 (GMS)

<< M I C R O S C O P I C T I S S U E O B S E R V A T I O N S >>  
 TISSUE / HISTOPATHOLOGIC FINDINGS  
 DISTRIBUTION (SEVERITY) / SPECIAL COMMENTS

LIVER .....  
 -NECROSIS, PERIACINAR .....  
 -M- PRESENCE OF METASTATIC SARCOMA ..... MULTI-FOCAL(TRACE)  
 ..... SECONDARY NEOPLASM FROM ORGAN ABDOMINAL CAVITY

KIDNEY .....  
 -PROGRESSIVE RENAL DISEASE ..... NOT SPECIFIED(TRACE)

URINARY BLADDER .....  
 ..... TISSUE IS MISSING

RECTUM .....  
 ..... TISSUE IS MISSING

BONE, STERNUM .....  
 ..... TISSUE IS MISSING

EYES & OPTIC N. ....  
 -METAPLASTIC BONE FORMATION AND/OR MINERALIZATION, SCLERA ..... NOT SPECIFIED (PRESENT)

ABDOMINAL CAVITY .....  
 MISCELLANEOUS TISSUE  
 THE SARCOMA INVOLVES PRIMARILY LIVER AND DIAPHRAGM. CELLULAR  
 MORPHOLOGY AND ARRANGEMENT ARE TYPICAL OF FIBROSARCOMA. THERE  
 ARE NUMEROUS MITOTIC FIGURES, SOME OF WHICH ARE LARGE AND  
 BIZARRE. THERE ARE ALSO NUMEROUS INDIVIDUAL NEOPLASTIC CELLS  
 UNDERGOING NECROSIS.  
 (PRESENT)

-M- SARCOMA, CELLULAR DIFFERENTIATION UNSPECIFIED  
 DIAPHRAGM ..... MISCELLANEOUS TISSUE  
 -N- PRESENCE OF METASTATIC SARCOMA ..... SECONDARY NEOPLASM FROM ORGAN ABDOMINAL CAVITY

Appendix J (cont.): PATHOLOGY INDIVIDUAL ANIMAL DATA

LETTERMAN ARMY INSTITUTE OF RESEARCH  
 DIV OF RES SUPP, PATH SERV GP  
 SPECIES: RAT/FISCHER-344  
 STUDY START DATE: 23-JAN-84  
 STUDY NUMBER: GLP03009  
 PRINTED: 21-NOV-89  
 PAGE: 542  
 STUDY TYPE: CHRONIC/2 YR CARCINOGENIC

ANIMAL NUMBER: 270/PRETEST= 270 SEX: FEMALE DOSE GROUP: 1 SACRIFICE STATUS: SACRIFICED MORIBUND  
 DATE OF DEATH: 08-JUL-85 STUDY DAY OF DEATH: 533 STUDY WEEK OF DEATH: 77 TERMINAL BODY WEIGHT: 241.00 (GMS)

<< GROSS ORGAN OBSERVATIONS >>  
 SEVERITY GROSS FREE-TEXT COMMENTS

ORGAN NAME	KEYWORDS / PHRASES	DISCOLORATION	ADHESION(S)	ADHESION(S)	MODULE(S)
KIDNEY		PRESENT	CHOCOLATE BROWN		
ILEUM		PRESENT	ABDOMINAL WALL		
LIVER		PRESENT	DIAPHRAGM, VENTRAL ABDOMINAL WALL, STOMACH, INTESTINES		
LIVER		PRESENT	MULTIPLE, FIRM, RED AND WHITE, .5-1CM DIAMETER		

<< MICROSCOPIC TISSUE OBSERVATIONS >>  
 DISTRIBUTION (SEVERITY) / SPECIAL COMMENTS

HEART ..... NOT SPECIFIED (TRACE)  
 -CARDIOMYOPATHY

LUNGS ..... NOT SPECIFIED (MILD)  
 -PNEUMONIA, INTERSTITIAL, CHRONIC

THYRUS ..... TISSUE IS MISSING

SPLEEN ..... LGLL IS IN ITS INITIAL STAGES AND IS CONFINED TO THE MARGINAL ZONE AT THE PERIPHERY OF SPLENIC CORPUSCLES. EXTENSIVE EXTRAMEDULLARY HEMATOPOIESIS IS PRESENT IN RED PULP AREAS.  
 -M- LARGE GRANULAR LYMPHOCYTE LEUKEMIA, METASTATIC (PRESENT)  
 -EXTRAMEDULLARY HEMATOPOIESIS NOT SPECIFIED (PRESENT)

LYMPH NODES ..... REACTIVE HYPERPLASIA IS MARKED IN CERVICAL AND MESENTERIC NODES.  
 -REACTIVE HYPERPLASIA NOT SPECIFIED (PRESENT)

LIVER ..... NOT SPECIFIED (PRESENT)  
 -COMPOUND RELATED INFLAMMATORY REACTION NOT SPECIFIED (MILD)  
 -BILE DUCTULE EPITHELIAL HYPERPLASIA AND/OR CHOLANGIOFIBROSIS NOT SPECIFIED (MILD)  
 -HEPATOCTYIC VACUOLIZATION NOT SPECIFIED (MILD)  
 -BENIGN HYPERPLASTIC NODULE(S) NOT SPECIFIED (TRACE)  
 -M- HEPATOCELLULAR CARCINOMA (PRESENT)

ILEUM .....

Appendix J (cont.): PATHOLOGY INDIVIDUAL ANIMAL DATA

LETTERMAN ARMY INSTITUTE OF RESEARCH  
 DIV OF RES SUPP, PATH SERV GP  
 SPECIES: RAT/FISCNER-344  
 STUDY START DATE: 23-JAN-84  
 INDIVIDUAL ANIMAL DATA REPORT  
 STUDY NUMBER: GLP83009  
 PRINTED: 21-NOV-89  
 PAGE: 543  
 STUDY TYPE: CHRONIC/2 YR CARCINOGENIC

ANIMAL NUMBER: 270/PRETEST= 270 SEX: FEMALE DOSE GROUP: 1 SACRIFICE STATUS: SACRIFICED MORIBUND  
 DATE OF DEATH: 08-JUL-85 STUDY DAY OF DEATH: 533 STUDY WEEK OF DEATH: 77 TERMINAL BODY WEIGHT: 241.00 (GMS)

<< M I C R O S C O P I C T I S S U E O B S E R V A T I O N S >>  
 TISSUE / HISTOPATHOLOGIC FINDINGS  
 DISTRIBUTION (SEVERITY) / SPECIAL COMMENTS

ILEUM ..... NOT SPECIFIED (PRESENT)  
 -COMPOUND RELATED INFLAMMATORY REACTION  
 -N- PRESENCE OF METASTATIC NEOPLASM  
 MAMMARY GLANDS ..... NOT SPECIFIED (PRESENT)  
 -DILATATION (ECTASIA) OF DUCTS AND DUCTULES  
 NOSE/TURBINATES ..... CELLULAR INFILTRATE INVOLVES MASO-LACRIMAL DUCT.  
 -MIXED INFLAMMATORY CELL INFILTRATION, NASAL CAVITY, SINUSES, NOT SPECIFIED (TRACE)  
 TURBINATES, MASO-LACRIMAL DUCTS  
 WHOLE BODY ..... THE LARGE GRANULE LYMPHOCYTE LEUKEMIA (LGLL) IN THIS ANIMAL IS  
 IN ITS INITIAL STAGES AND IS CONFINED TO THE SPLEEN.  
 -M- LARGE GRANULAR LYMPHOCYTTIC LEUKEMIA (PRESENT)  
 DIAPHRAGM ..... MISCELLANEOUS TISSUE  
 -COMPOUND RELATED INFLAMMATORY REACTION NOT SPECIFIED (PRESENT)  
 -N- PRESENCE OF METASTATIC NEOPLASM  
 SECONDARY NEOPLASM FROM ORGAN LIVER

**Appendix J (cont.): PATHOLOGY INDIVIDUAL ANIMAL DATA**

LETTERMAN ARMY INSTITUTE OF RESEARCH  
 DIV OF RES SUPP, PATH SERV GP  
 SPECIES: RAT/FISCHER-344

INDIVIDUAL ANIMAL DATA REPORT  
 STUDY NUMBER: GLP83009  
 STUDY START DATE: 23-JAN-84

PRINTED: 21-NOV-89  
 PAGE: 544

STUDY TYPE: CHRONIC/2 YR CARCINOGENIC

ANIMAL NUMBER: 271/PRETEST= 271 SEX: FEMALE DOSE GROUP: 1 SACRIFICE STATUS: FOUND DEAD  
 DATE OF DEATH: 23-JAN-86 STUDY DAY OF DEATH: 732 STUDY WEEK OF DEATH: 105 TERMINAL BODY WEIGHT: 234.00 (GMS)

ORGAN NAME << GROSS ORGAN OBSERVATIONS >>  
 KEYWORDS / PHRASES SEVERITY GROSS FREE-TEXT COMMENTS  
 ADHESION(S) PRESENT DIAPHRAGM  
 CONGESTED / RED PRESENT

<< MICROSCOPIC TISSUE OBSERVATIONS >>  
 TISSUE / HISTOPATHOLOGIC FINDINGS DISTRIBUTION (SEVERITY) / SPECIAL COMMENTS

- THYROID GLANDS ..... TISSUE IS AUTOLYTIC
- PARATHYROID ..... TISSUE IS MISSING
- HEART ..... NOT SPECIFIED(MILD)
- CARDIOMYOPATHY
- LUNGS ..... NOT SPECIFIED (PRESENT)
- VASCULAR CONGESTION
- ALVEOLAR HEMORRHAGE
- LYMPH NODES ..... RBC'S AND PIGMENT PRESENT IN CERVICAL AND MEDIASTINAL NODES.
- RED BLOOD CELLS, HEMOSIDERIN AND/OR ERYTHROPHAGOCYTOSIS WITHIN NOT SPECIFIED (PRESENT)
- MEGALYMPHATIC SINUSES
- LIVER ..... NOT SPECIFIED (PRESENT)
- COMPOUND RELATED INFLAMMATORY REACTION
- BILE DUCTULE EPITHELIAL HYPERPLASIA AND/OR CHOLANGIOFIBROSIS
- KIDNEY ..... NOT SPECIFIED(TRACE)
- PROGRESSIVE RENAL DISEASE
- MAMMARY GLANDS ..... NOT SPECIFIED(MILD)
- HYPERPLASIA AND/OR HYPERTROPHY OF THE ACINAR TISSUE
- DILATATION (ECTASIA) OF DUCTS AND DUCTULES

Appendix J (cont.): PATHOLOGY INDIVIDUAL ANIMAL DATA

LETTERMAN ARMY INSTITUTE OF RESEARCH  
DIV OF RES SUPP, PATH SERV GP  
SPECIES: RAT/FISCHER-344

INDIVIDUAL ANIMAL DATA REPORT  
STUDY NUMBER: GLP83009  
STUDY START DATE: 23-JAN-84

PRINTED: 21-NOV-89  
PAGE: 545

STUDY TYPE: CHRONIC/2 YR CARCINOGENIC

ANIMAL NUMBER: 271/PRETEST# 271 SEX: FEMALE DOSE GROUP: 1 SACRIFICE STATUS: FOUND DEAD  
DATE OF DEATH: 23-JAN-86 STUDY DAY OF DEATH: 732 STUDY WEEK OF DEATH: 105 TERMINAL BODY WEIGHT: 234.00 (GMS)

TISSUE / HISTOPATHOLOGIC FINDINGS << MICROSCOPIC TISSUE OBSERVATIONS >>  
DISTRIBUTION (SEVERITY) / SPECIAL COMMENTS

NOSE/TURBINATES ..... CELLULAR INFILTRATE INVOLVES NASO-LACRIMAL DUCTS.  
-MIXED INFLAMMATORY CELL INFILTRATION, NASAL CAVITY, SINUSES, NOT SPECIFIED(MODERATE)  
TURBINATES, NASO-LACRIMAL DUCTS  
ADRENAL ..... ONLY ONE ADRENAL AVAILABLE FOR HISTOLOGIC EXAMINATION.  
DIAPHRAGM ..... MISCELLANEOUS TISSUE  
-COMPOUND RELATED INFLAMMATORY REACTION NOT SPECIFIED (PRESENT)

Appendix J (cont.): PATHOLOGY INDIVIDUAL ANIMAL DATA

LETTERMAN ARMY INSTITUTE OF RESEARCH  
DIV OF RES SUPP, PATH SERV GP  
SPECIES: RAT/FISCHER-344

INDIVIDUAL ANIMAL DATA REPORT  
STUDY NUMBER: GLP83009

PRINTED: 21-NOV-89  
PAGE: 558

STUDY START DATE: 23-JAN-84

STUDY TYPE: CHRONIC/2 YR CARCINOGENIC

ANIMAL NUMBER: 284/PRETEST-284 SEX: FEMALE DOSE GROUP: 2 SACRIFICE STATUS: SACRIFICED MORIBUND  
DATE OF DEATH: 13-JAN-86 STUDY DAY OF DEATH: 722 STUDY WEEK OF DEATH: 104 TERMINAL BODY WEIGHT: 310.00 (GMS)

ORGAN NAME: SKIN  
SUBCUTANEOUS MASS  
ENLARGED (SPLENOHEGALY)  
KEYWORDS / PHRASES: SUBCUTANEOUS MASS  
ENLARGED (SPLENOHEGALY)  
SEVERITY: MILD  
GROSS ORGAN OBSERVATIONS: PRESENT FIRM, WHITE, 5 X 4.5 X 4CM  
GROSS ORGAN OBSERVATIONS: MILD 4CM LONG  
SEVERITY: MILD  
GROSS ORGAN OBSERVATIONS: PRESENT FIRM, WHITE, 5 X 4.5 X 4CM  
SEVERITY: MILD  
GROSS ORGAN OBSERVATIONS: MILD 4CM LONG

TISSUE / HISTOPATHOLOGIC FINDINGS: << MICROSCOPIC TISSUE OBSERVATIONS >>  
DISTRIBUTION (SEVERITY) / SPECIAL COMMENTS

THYROID GLANDS: TISSUE IS MISSING

PARATHYROID: TISSUE IS MISSING

HEART: NOT SPECIFIED(MODERATE)

LUNGS: NOT SPECIFIED(TRACE)

SPLEEN: (PRESENT)

LYMPH NODES: REACTIVE HYPERPLASIA NOTED IN CERVICAL NODES.  
RBC'S AND PIGMENT NOTED IN MEDIASTINAL NODES AND IN SEVERAL  
SMALL MESENTERIC NODES ADJACENT TO THE PANCREAS IN SECTION #12.  
NOT SPECIFIED (PRESENT)

-RED BLOOD CELLS, HEMOSIDERIN AND/OR ERYTHROPHAGOCYTOSIS WITHIN  
MEDULLARY SINUSES  
NOT SPECIFIED (PRESENT)

LIVER: FOCAL(TRACE)  
-FOCUS OF CELLULAR ALTERATION - BASOPHILIC  
-FIBROSIS CAPSULAR NO COMPOUND  
NOT SPECIFIED (PRESENT)

-N- LARGE GRANULAR LYMPHOCYTE LEUKEMIA, METASTATIC  
KIDNEY



Appendix J (cont.): PATHOLOGY INDIVIDUAL ANIMAL DATA

LETTERMAN ARMY INSTITUTE OF RESEARCH  
DIV OF RES SUPP, PATH SERV GP  
SPECIES: RAT/FISCHER-344

INDIVIDUAL ANIMAL DATA REPORT  
STUDY NUMBER: GLP83009  
STUDY START DATE: 23-JAN-84

PRINTED: 21-NOV-89  
PAGE: 559

STUDY TYPE: CHRONIC/2 YR CARCINOGENIC

ANIMAL NUMBER: 284/PRETEST= 284 SEX: FEMALE DOSE GROUP: 2 SACRIFICE STATUS: SACRIFICED MORIBUND  
DATE OF DEATH: 13-JAN-86 STUDY DAY OF DEATH: 722 STUDY WEEK OF DEATH: 104 TERMINAL BODY WEIGHT: 310.00 (GMS)

<< MICROSCOPIC TISSUE OBSERVATIONS >>  
TISSUE / HISTOPATHOLOGIC FINDINGS DISTRIBUTION (SEVERITY) / SPECIAL COMMENTS

KIDNEY ..... NOT SPECIFIED(TRACE)  
-PROGRESSIVE RENAL DISEASE

SKIN .....  
THERE IS A LARGE ANAPLASTIC FIBROSARCOMA IN THE LEFT AXILLARY AREA. THERE IS NO SARCOMA IN THE ABDOMINAL CAVITY OF THIS RAT. NO TEST MATERIAL WAS OBSERVED IN THE AREA OF THE NEOPLASM. ALL INDICATIONS ARE THAT THE PRIMARY SITE TO THIS LESION IS THE SUBCUTIS OF THE LEFT AXILLARY AREA.  
-M- FIBROSARCOMA (PRESENT)

MAMMARY GLANDS ..... TISSUE IS MISSING

EYES & OPTIC N. .... ONE EYE CANNOT BE EVALUATED BECAUSE OF SEVERE ARTIFACT.

WHOLE BODY .....  
-M- LARGE GRANULAR LYMPHOCYTTIC LEUKEMIA (PRESENT)

**Appendix J (cont.): PATHOLOGY INDIVIDUAL ANIMAL DATA**

LETTERMAN ARMY INSTITUTE OF RESEARCH  
 DIV OF RES SUPP, PATH SERV 6P  
 SPECIES: RAT/FISCHER-344  
 STUDY START DATE: 23-JAN-84  
 STUDY NUMBER: GLP83009  
 PRINTED: 21-NOV-89  
 PAGE: 560

ANIMAL NUMBER: 285/PREST-285  
 DATE OF DEATH: 25-SEP-85  
 SEX: FEMALE  
 DOSE GROUP: 2  
 SACRIFICE STATUS: SACRIFICED MORIBUND  
 STUDY DAY OF DEATH: 612  
 STUDY WEEK OF DEATH: 88  
 TERMINAL BODY WEIGHT: 201.00 (GMS)  
 STUDY TYPE: CHRONIC/2 YR CARCINOGENIC

<< GROSS ORGAN OBSERVATIONS >>  
 SEVERITY GROSS FREE-TEXT COMMENTS  
 KEYWORDS / PHRASES  
 ADHESION(S)  
 BLOOD WITHIN LUMEN  
 GROWTH(S) / MASS(ES)  
 MINIMAL BODY FAT  
 PRESENT DIAPHRAGM  
 FILLED WITH RED FLUID AND DARK RED CLOTTED MATERIAL  
 FIRM, WHITE, 3 X 2.5CM, INGUINAL REGION, INCORPORATES THE  
 DESCENDING COLON, RECTUM AND URINARY BLADDER.  
 PRESENT

<< MICROSCOPIC TISSUE OBSERVATIONS >>  
 DISTRIBUTION (SEVERITY) / SPECIAL COMMENTS

- THYROID GLANDS
- PARA-FOLLICULAR CELL HYPERPLASIA (MC CELL, LIGHT CELL) NOT SPECIFIED(TRACE)
- EXORBITAL LACRIM TISSUE IS MISSING
- HEART NOT SPECIFIED(TRACE)
- CARDIOMYOPATHY
- LYMPH NODES RBC'S PRESENT IN MEDIASTINAL NODE. ONLY A SMALL AMOUNT OF MESENTERIC LYMPH NODE TISSUE IS PRESENT. NOT SPECIFIED (PRESENT)
- RED BLOOD CELLS, HEMOSIDERIN AND/OR ERYTHROPHAGOCYTOSIS WITHIN MEDULLARY SINUSES
- LIVER NOT SPECIFIED (PRESENT)
- COMPOUND RELATED INFLAMMATORY REACTION NOT SPECIFIED(TRACE)
- BILE DUCTULE EPITHELIAL HYPERPLASIA AND/OR CHOLANGIOFIBROSIS MULTI-FOCAL(TRACE)
- HEPATITIS MULTI-FOCAL(MILD)
- FOCUS OF CELLULAR ALTERATION - BASOPHILIC
- KIDNEY NOT SPECIFIED(TRACE)
- PROGRESSIVE RENAL DISEASE
- RECTUM THE SARCOMA IS PRESENT ONLY IN PERI-RECTAL MUSCLE. (PRESENT)
- I- FIBROSARCOMA, LOCALLY INVASIVE

Appendix J (cont.): PATHOLOGY INDIVIDUAL ANIMAL DATA

LETTERMAN ARMY INSTITUTE OF RESEARCH  
 DIV OF RES SUPP, PATH SERV GP  
 SPECIES: RAT/FISCHER-344  
 ANIMAL NUMBER: 285/PRETEST-  
 DATE OF DEATH: 25-SEP-85  
 STUDY DAY OF DEATH: 612  
 SEX: FEMALE  
 DOSE GROUP: 2  
 STUDY WEEK OF DEATH: 88  
 TERMINAL BODY WEIGHT: 201.00 (GMS)  
 STUDY START DATE: 23-JAN-84  
 STUDY TYPE: CHRONIC/2 YR CARCINOGENIC  
 SACRIFICE STATUS: SACRIFICED MORIBUND

PRINTED: 21-NOV-89  
 PAGE: 561

<< MICROSCOPIC TISSUE OBSERVATIONS >>  
 DISTRIBUTION (SEVERITY) / SPECIAL COMMENTS

SKIN ..... THE MASS LOCATED IN THE INGUINAL REGION AND EXTENDING INTO THE  
 ABDOMINAL CAVITY AROUND THE RECTUM AND URINARY BLADDER IS A  
 FIBROSARCOMA.  
 (PRESENT)

-M- FIBROSARCOMA  
 MAMMARY GLANDS ..... NOT SPECIFIED (PRESENT)  
 -DILATATION (ECTASIA) OF DUCTS AND DUCTULES

ADRENAL .....  
 -LIPIDOSIS ..... DIFFUSE(MILD)

DIAPHRAGM ..... MISCELLANEOUS TISSUE  
 -COMPOUND RELATED INFLAMMATORY REACTION ..... NOT SPECIFIED (PRESENT)

Appendix J (cont.): PATHOLOGY INDIVIDUAL ANIMAL DATA

LETTERMAN ARMY INSTITUTE OF RESEARCH  
 DIV OF RES SUPP, PATH SERV GP  
 SPECIES: RAT/FISCHER-344

INDIVIDUAL ANIMAL DATA REPORT  
 STUDY NUMBER: GLP83009  
 STUDY START DATE: 23-JAN-84

PRINTED: 21-NOV-89  
 PAGE: 562  
 STUDY TYPE: CHRONIC/2 YR CARCINOGENIC

ANIMAL NUMBER: 286/PRETEST#  
 DATE OF DEATH: 07-FEB-86

286 SEX: FEMALE  
 STUDY DAY OF DEATH: 747

DOSE GROUP: 2  
 STUDY WEEK OF DEATH: 107

SACRIFICE STATUS: FINAL SACRIFICE  
 TERMINAL BODY WEIGHT: 293.00 (GMS)

ORGAN NAME << GROSS ORGAN OBSERVATIONS >>  
 KEYWORDS / PHRASES SEVERITY GROSS FREE-TEXT COMMENTS

LIVER ADHESION(S) PRESENT VENTRAL ABDOMINAL WALL  
 LIVER DISCOLORATION PRESENT FOCAL, MULTIPLE, .1-.2CM DIAMETER, WHITE  
 PITUITARY GLAND DISCOLORATION PRESENT FOCAL, RED, .2CM DIAMETER

TISSUE / HISTOPATHOLOGIC FINDINGS << MICROSCOPIC TISSUE OBSERVATIONS >>  
 DISTRIBUTION (SEVERITY) / SPECIAL COMMENTS

HEART ..... NOT SPECIFIED(MILD)  
 -CARDIOMYOPATHY

LUNGS ..... NOT SPECIFIED(TRACE)  
 -MINERALIZATION OF PULMONARY ARTERIES

LYMPH NODES ..... REACTIVE HYPERPLASIA NOTED IN CERVICAL AND MEDIASTINAL NODES.  
 -REACTIVE HYPERPLASIA

LIVER ..... MULTI-FOCAL(MODERATE)  
 -HEPATITIS NOT SPECIFIED(TRACE)  
 -FOCUS OF CELLULAR ALTERATION - BASOPHILIC MULTI-FOCAL(MILD)  
 -NECROSIS NOT SPECIFIED(MODERATE)  
 -HEPATOCTYTE COALESCING MICROVESICULAR (FATTY) CHANGE LEADING TO  
 NECROSIS AND MINERALIZATION

KIDNEY ..... NOT SPECIFIED(MILD)  
 -PROGRESSIVE RENAL DISEASE

PANCREAS ..... MULTI-FOCAL(MILD)  
 -ACINAR (EXOCRINE) ATROPHY

MAMMARY GLANDS ..... NOT SPECIFIED(MILD)  
 -HYPERPLASIA AND/OR HYPERTROPHY OF THE ACINAR TISSUE  
 -DILATATION (ECTASIA) OF DUCTS AND DUCTULES NOT SPECIFIED (PRESENT)

Appendix J (cont.): PATHOLOGY INDIVIDUAL ANIMAL DATA

LETTERMAN ARMY INSTITUTE OF RESEARCH  
DIV OF RES SUPP, PATH SERV GP  
SPECIES: RAY/FISCHER-344  
INDIVIDUAL ANIMAL DATA REPORT  
STUDY NUMBER: GLP83009  
STUDY START DATE: 23-JAN-84  
PRINTED: 21-NOV-89  
PAGE: 563  
STUDY TYPE: CHRONIC/2 YR CARCINOGENIC

ANIMAL NUMBER: 286/PRETEST#  
DATE OF DEATH: 07-FEB-86  
SEX: FEMALE  
DOSE GROUP: 2  
SACRIFICE STATUS: FINAL SACRIFICE  
STUDY DAY OF DEATH: 747  
STUDY WEEK OF DEATH: 107  
TERMINAL BODY WEIGHT: 293.00 (GMS)

TISSUE / HISTOPATHOLOGIC FINDINGS  
MICROSCOPIC TISSUE OBSERVATIONS  
DISTRIBUTION (SEVERITY) / SPECIAL COMMENTS

NOSE/TURBINATES ..... CELLULAR INFILTRATE IS ON THE VENTRAL LATERAL ASPECT OF THE NASAL CAVITY.  
-MIXED INFLAMMATORY CELL INFILTRATION, NASAL CAVITY, SINUSES, NOT SPECIFIED(TRACE)  
TURBINATES, NASO-LACRIMAL DUCTS

PITUITARY GLAND ..... NOT SPECIFIED (PRESENT)  
-CYST(S)

EYES & OPTIC N. .... NOT SPECIFIED(TRACE)  
-RETINAL ATROPHY AND/OR DEGENERATION, UNILATERAL OR BILATERAL

Appendix J (cont.): PATHOLOGY INDIVIDUAL ANIMAL DATA

LETTERMAN ARMY INSTITUTE OF RESEARCH  
DIV OF RES SUPP, PATH SERV GP  
SPECIES: RAT/FISCHER-344

INDIVIDUAL ANIMAL DATA REPORT  
STUDY NUMBER: GLP03009

PRINTED: 21-NOV-89  
PAGE: 564

STUDY START DATE: 23-JAN-84

STUDY TYPE: CHRONIC/2 YR CARCINOGENIC

ANIMAL NUMBER: 287/PRETEST= 287 SEX: FEMALE DOSE GROUP: 2 SACRIFICE STATUS: FINAL SACRIFICE  
DATE OF DEATH: 07-FEB-86 STUDY DAY OF DEATH: 747 STUDY WEEK OF DEATH: 107 TERMINAL BODY WEIGHT: 267.00 (GMS)

ORGAN NAME << GROSS ORGAN OBSERVATIONS >>  
KEYWORDS / PHRASES SEVERITY GROSS FREE-TEXT COMMENTS  
LIVER ADHESION(S) PRESENT DIAPHRAGM, ABDOMINAL WALL.  
PITUITARY GLAND DISCOLORATION PRESENT DARK RED.  
EYES & OPTIC N. LENS CATARACT PRESENT LEFT.

TISSUE / HISTOPATHOLOGIC FINDINGS << MICROSCOPIC TISSUE OBSERVATIONS >>  
DISTRIBUTION (SEVERITY) / SPECIAL COMMENTS

- THYROID GLANDS ..... (PRESENT)
- B- PARA-FOLLICULAR CELL ADENOMA
- EXORBITAL LACRIM ..... NOT SPECIFIED(TRACE)
- ACINAR ATROPHY
- HEART ..... NOT SPECIFIED(TRACE)
- CARDIOMYOPATHY
- LYMPH NODES ..... REACTIVE HYPERPLASIA NOTED IN CERVICAL AND MESENTERIC NODES.
- REACTIVE HYPERPLASIA ..... NOT SPECIFIED (PRESENT)
- LIVER ..... NOT SPECIFIED (PRESENT)
- COMPOUND RELATED INFLAMMATORY REACTION ..... NOT SPECIFIED(TRACE)
- BILE DUCTULE EPITHELIAL HYPERPLASIA AND/OR CHOLANGIOFIBROSIS ..... MULTI-FOCAL(TRACE)
- HEPATITIS ..... NOT SPECIFIED(TRACE)
- BENIGN HYPERPLASTIC NODULE(S) ..... MULTI-FOCAL(MILD)
- HEPATOCTYE COALESCING MICROVESICULAR (FATTY) CHANGE LEADING TO NECROSIS AND MINERALIZATION
- KIDNEY ..... NOT SPECIFIED(TRACE)
- PROGRESSIVE RENAL DISEASE
- UTERUS ..... NOT SPECIFIED (PRESENT)
- ENDOMETRIAL STROMAL POLYP

Appendix J (cont.): PATHOLOGY INDIVIDUAL ANIMAL DATA

LETTERMAN ARMY INSTITUTE OF RESEARCH INDIVIDUAL ANIMAL DATA REPORT PRINTED: 21-NOV-89  
DIV OF RES SUPP, PATH SERV GP STUDY NUMBER: GLP83009 PAGE: 565  
SPECIES: RAT/FISCHER-344 STUDY START DATE: 23-JAN-84 STUDY TYPE: CHRONIC/2 YR CARCINOGENIC

ANIMAL NUMBER: 287/PRETEST# 287 SEX: FEMALE DOSE GROUP: 2 SACRIFICE STATUS: FINAL SACRIFICE  
DATE OF DEATH: 07-FEB-86 STUDY DAY OF DEATH: 747 STUDY WEEK OF DEATH: 107 TERMINAL BODY WEIGHT: 267.00 (GMS)

TISSUE / HISTOPATHOLOGIC FINDINGS << M I C R O S C O P I C T I S S U E O B S E R V A T I O N S >>  
DISTRIBUTION (SEVERITY) / SPECIAL COMMENTS

UTERUS ..... NOT SPECIFIED (PRESENT)  
-CYSTIC DILATATION OF THE ENDOMETRIAL GLANDS

OVARIES ..... NOT SPECIFIED (PRESENT)  
-FOLLICULAR CYST(S)

PANCREAS ..... NOT SPECIFIED(MILD)  
-ACINAR (EXOCRINE) ATROPHY

SKELETAL MUSCLE ..... TISSUE IS MISSING

SCIATIC NERVE ..... TISSUE IS MISSING

MAMMARY GLANDS ..... NOT SPECIFIED(MILD)  
-HYPERPLASIA AND/OR HYPERTROPHY OF THE ACINAR TISSUE  
-DILATATION (ECTASIA) OF DUCTS AND DUCTULES

NOSE/TURBINATES ..... CELLULAR INFILTRATE NOTED ADJACENT TO MASO-LACRIMAL DUCTS.  
-MIXED INFLAMMATORY CELL INFILTRATION, NASAL CAVITY, SINUSES, NOT SPECIFIED(TRACE)  
TURBINATES, MASO-LACRIMAL DUCTS

ADRENAL ..... FOCAL(TRACE)  
-FOCUS OF CELLULAR ALTERATION, BASOPHILIC

PITUITARY GLAND ..... TISSUE IS MISSING

Appendix J (cont.): PATHOLOGY INDIVIDUAL ANIMAL DATA

LETTERMAN ARMY INSTITUTE OF RESEARCH  
 DIV OF RES SUPP, PATH SERV GP  
 SPECIES: RAT/FISCHER-344  
 ANIMAL NUMBER: 288/PRETEST-288  
 DATE OF DEATH: 20-AUG-85  
 STUDY START DATE: 23-JAN-84  
 STUDY NUMBER: GLP83009  
 DOSE GROUP: 2  
 STUDY WEEK OF DEATH: 83  
 SACRIFICE STATUS: SACRIFICED MORIBUND  
 TERMINAL BODY WEIGHT: 234.00 (GMS)  
 STUDY TYPE: CHRONIC/2 YR CARCINOGENIC

PRINTED: 21-NOV-89  
 PAGE: 566

ORGAN NAME	KEYWORDS / PHRASES	SEVERITY	GROSS OBSERVATIONS	GROSS FREE-TEXT COMMENTS
EYES & OPTIC N.	CRUSTY MATERIAL, PERIORBITAL	PRESENT	RED AND BLACK	
WHOLE BODY	THIN WATERY BLOOD	PRESENT	LITTLE CLOTTING	
SPLEEN	ENLARGED (SPLENOMEGALY)	MARKED	7 X 2 X 1.5CM	
LIVER	PROMINENT LOBULAR MARKINGS	MILD		
LIVER	ADHESION(S)	PRESENT		VENTRAL ABDOMINAL WALL ADJACENT TO DIAPHRAGM
PERITONEAL CAV.	GROWTH(S) / MASS(ES)	PRESENT		FIRM, RED/BLACK, .6 X .5CM, LOOSELY ADHERED TO LUMBAR SPINE
KIDNEY	DISCOLORATION	PRESENT		BETWEEN ADRENALS.
LUNGS	DISCOLORATION	PRESENT		DIFFUSELY BROWN
PITUITARY GLAND	DISCOLORATION	PRESENT		DIFFUSE, BROWN, SLIGHTLY DEPRESSED, .5-1CM DIAMETER
		PRESENT		RED, .1CM DIAMETER, LEFT DORSAL SURFACE

TISSUE / HISTOPATHOLOGIC FINDINGS  
 << MICROSCOPIC TISSUE OBSERVATIONS >>  
 DISTRIBUTION (SEVERITY) / SPECIAL COMMENTS

THYROID GLANDS  
 -COLLOID CYST(S) ..... NOT SPECIFIED (PRESENT)

PARATHYROID ..... TISSUE IS MISSING

SALIVARY GLAND ..... NOT SPECIFIED (MODERATE)

-ATROPHY AND LOSS OF ACINAR TISSUE

HEART ..... NOT SPECIFIED (MILD)

-CARDIOMYOPATHY



Appendix J (cont.): PATHOLOGY INDIVIDUAL ANIMAL DATA

LETTERMAN ARMY INSTITUTE OF RESEARCH  
 DIV OF RES SUPP, PATH SERV GP  
 SPECIES: RAT/FISCHER-344

INDIVIDUAL ANIMAL DATA REPORT  
 STUDY NUMBER: GLP83009

STUDY START DATE: 23-JAN-34

PRINTED: 21-NOV-89  
 PAGE: 567

STUDY TYPE: CHRONIC/2 YR CARCINOGENIC

ANIMAL NUMBER: 288/PRETEST= 288 SEX: FEMALE DOSE GROUP: 2 SACRIFICE STATUS: SACRIFICED MORIBUND  
 DATE OF DEATH: 20-AUG-85 STUDY DAY OF DEATH: 576 STUDY WEEK OF DEATH: 83 TERMINAL BODY WEIGHT: 234.00 (GMS)

<< M I C R O S C O P I C T I S S U E O B S E R V A T I O N S >>  
 TISSUE / HISTOPATHOLOGIC FINDINGS DISTRIBUTION (SEVERITY) / SPECIAL COMMENTS

LUNGS ..... EXTENSIVE PNEUMONIC LESIONS ARE PRESENT. THE DISTRIBUTION IS PATCHY BUT DEFINITE AIRWAY ORIENTATION IS NOTED. THE LESION IS CHARACTERIZED PRIMARILY BY INFILTRATION OF MACROPHAGES AND FEWER INFLAMMATORY CELLS OF OTHER TYPES AND A MARKED PROLIFERATION OF TYPE 2 ALVEOLAR EPITHELIUM. GOODPASTURE, PAS, GMS, AND AFB STAINS FAILED TO DEMONSTRATE AN ETIOLOGIC AGENT DEFINITELY ALTHOUGH MANY OF THE MACROPHAGES CONTAIN ROUND OR COCCOID STRUCTURES WHICH MAY BE BACTERIA. THE STAINING CHARACTERISTICS OF THESE PARTICLES VARY. THEY ARE NEITHER GRAM + NOR GRAM -. ARE NOT ACID FAST, AND DO NOT STAIN WITH GMS. MANY MACROPHAGES ARE FILLED WITH PAS + MATERIAL WHICH IS PROBABLY SECRETORY PRODUCT AND/OR CELLULAR DEBRIS. MULTI-FOCAL(MARKED)

-PNEUMONIA, INTERSTITIAL, CHRONIC

SPLEEN ..... (PRESENT)  
 -N- LARGE GRANULAR LYMPHOCYTE LEUKEMIA, METASTATIC

LYMPH NODES ..... REACTIVE HYPERPLASIA IS PRESENT IN CERVICAL, MEDIASTINAL AND MESENTERIC NODES. RBC ARE ALSO PRESENT IN MESENTERIC NODES. LGLL IS NOTED IN A NODE ADJACENT TO THE PANCREAS IN SLIDE #12. THE LESION NOTED GROSSLY ADJACENT TO THE LUMBAR SPINE BETWEEN THE ADRENAL GLANDS IS A LYMPH NODE HEAVILY INFILTRATED BY NEOPLASTIC LYMPHOCYTES AND NUMEROUS RBC'S FILLING GREATLY DILATED SINUSOIDS.  
 NOT SPECIFIED (PRESENT)

-RED BLOOD CELLS, HEMOSIDERIN AND/OR ERYTHROPHAGOCYTOSIS WITHIN MEDULLARY SINUSES (PRESENT)  
 -N- LARGE GRANULAR LYMPHOCYTE LEUKEMIA, METASTATIC NOT SPECIFIED (PRESENT)  
 -REACTIVE HYPERPLASIA NOT SPECIFIED (PRESENT)

LIVER .....  
 -COMPOUND RELATED INFLAMMATORY REACTION  
 -BILE DUCTULE EPITHELIAL HYPERPLASIA AND/OR CHOLANGIOFIBROSIS  
 -NECROSIS, PERIACINAR

**Appendix J (cont.): PATHOLOGY INDIVIDUAL ANIMAL DATA**

LETTERMAN ARMY INSTITUTE OF RESEARCH  
 DIV OF RES SUPP, PATH SERV GP  
 SPECIES: RAT/FISCHER-344  
 STUDY START DATE: 23-JAN-84  
 STUDY NUMBER: GLP83009  
 PRINTED: 21-NOV-89  
 PAGE: 568

ANIMAL NUMBER: 288/PRETEST# 288 SEX: FEMALE DOSE GROUP: 2 SACRIFICE STATUS: SACRIFICED MORIBUND  
 DATE OF DEATH: 20-AUG-85 STUDY DAY OF DEATH: 576 STUDY WEEK OF DEATH: 83 TERMINAL BODY WEIGHT: 234.00 (GMS)

TISSUE / HISTOPATHOLOGIC FINDINGS << M I C R O S C O P I C T I S S U E O B S E R V A T I O N S >>  
 DISTRIBUTION (SEVERITY) / SPECIAL COMMENTS

- LIVER ..... (PRESENT)
- M- LARGE GRANULAR LYMPHOCYTE LEUKEMIA, METASTATIC
- KIDNEY ..... NOT SPECIFIED (TRACE)
- PROGRESSIVE RENAL DISEASE
- PANCREAS ..... DIFFUSE(MILD)
- ACINAR (EXOCRINE) ATROPHY ..... DIFFUSE(MILD)
- CHRONIC INFLAMMATION ..... (PRESENT)
- M- LARGE GRANULAR LYMPHOCYTE LEUKEMIA, METASTATIC
- STOMACH ..... NOT SPECIFIED (PRESENT)
- MUCOSAL AND/OR SUBMUCOSAL EDEMA
- MAMMARY GLANDS ..... NOT SPECIFIED (MODERATE)
- HYPERPLASIA AND/OR HYPERTROPHY OF THE ACINAR TISSUE ..... NOT SPECIFIED (PRESENT)
- DILATATION (ECTASIA) OF DUCTS AND DUCTULES
- NOSE/TURBINATES ..... CELLULAR INFILTRATE IS BILATERAL AND INVOLVES NASO-LACRIMAL DUCTS. NOT SPECIFIED (MODERATE)
- MIXED INFLAMMATORY CELL INFILTRATION, NASAL CAVITY, SINUSES, TURBINATES, NASO-LACRIMAL DUCTS
- ADRENAL ..... (PRESENT)
- M- LARGE GRANULE LYMPHOCYTE LEUKEMIA, METASTATIC
- PITUITARY GLAND ..... (PRESENT)
- B- ADENOMA ..... NOT SPECIFIED (PRESENT)
- CYST(S)
- EYES & OPTIC N. .... ONLY ONE EYE SECTION IS AVAILABLE FOR EXAMINATION.
- WHOLE BODY ..... (PRESENT)
- M- LARGE GRANULAR LYMPHOCYTIC LEUKEMIA

Appendix J (cont.): PATHOLOGY INDIVIDUAL ANIMAL DATA

LETTERMAN ARMY INSTITUTE OF RESEARCH  
DIV OF RES SUPP, PATH SERV GP  
SPECIES: RAT/FISCHER-344

INDIVIDUAL ANIMAL DATA REPORT  
STUDY NUMBER: GLP83009  
STUDY START DATE: 23-JAN-84

PRINTED: 21-NOV-89  
PAGE: 569  
STUDY TYPE: CHRONIC/2 YR CARCINOGENIC

ANIMAL NUMBER: 285/PRETEST# 288 SEX: FEMALE DOSE GROUP: 2 SACRIFICE STATUS: SACRIFICED MORIBUND  
DATE OF DEATH: 20-AUG-85 STUDY DAY OF DEATH: 576 STUDY WEEK OF DEATH: 83 TERMINAL BODY WEIGHT: 234.00 (GMS)

<< MICROSCOPIC TISSUE OBSERVATIONS >>  
TISSUE / HISTOPATHOLOGIC FINDINGS  
DISTRIBUTION (SEVERITY) / SPECIAL COMMENTS

ABDOMINAL CAVITY ..... MISCELLANEOUS TISSUE  
THE LESION NOTED GROSSLY AS A 6MM X 5MM MASS BETWEEN THE ADRENAL  
GLANDS IS A LYMPH NODE WITH METASTATIC LGLL. SEE COMMENT UNDER  
LYMPH NODE. THIS LESION IS IN SECTION #21.

Appendix J (cont.): **PATHOLOGY INDIVIDUAL ANIMAL DATA**

LETTERMAN ARMY INSTITUTE OF RESEARCH  
 DIV OF RES SUPP, PATH SERV GP  
 SPECIES: RAT/FISCHER-344  
 INDIVIDUAL ANIMAL DATA REPORT  
 STUDY NUMBER: GLP83009  
 STUDY START DATE: 23-JAN-84  
 PRINTED: 21-NOV-89  
 PAGE: 570

ANIMAL NUMBER: 289/PRETEST# 289 SEX: FEMALE DOSE GROUP: 2 SACRIFICE STATUS: FINAL SACRIFICE  
 DATE OF DEATH: 07-FEB-86 STUDY DAY OF DEATH: 747 STUDY WEEK OF DEATH: 107 TERMINAL BODY WEIGHT: 246.00 (GMS)  
 STUDY TYPE: CHRONIC/2 YR CARCINOGENIC

<< GROSS ORGAN OBSERVATIONS >>  
 SEVERITY GROSS FREE-TEXT COMMENTS  
 KEYWORDS / PHRASES  
 SUBCUTANEOUS MASS PRESENT FIRM, WHITE, 1 X 2CM, RIGHT THORACIC REGION  
 ENLARGED PRESENT 1CM DIAMETER, DARK RED  
 HYDROMETRA PRESENT  
 ADHESION(S) PRESENT  
 GROWTH(S)/MASS(S) PRESENT DIAPHRAGM, VENTRAL ABDOMINAL WALL.  
 DARK RED, LOBULATED, SOFT, 4 X 2CM IN BODY

<< MICROSCOPIC TISSUE OBSERVATIONS >>  
 DISTRIBUTION (SEVERITY) / SPECIAL COMMENTS

PARATHYROID ..... TISSUE IS MISSING

SALIVARY GLAND ..... SUBLINGUAL AND SUBMANDIBULAR GLANDS ARE MISSING. PAROTID IS PRESENT AND NO LESIONS ARE RECOGNIZED.

HEART ..... NOT SPECIFIED (TRACE)  
 -CARDIOMYOPATHY ..... TISSUE IS MISSING

THYMUS ..... TISSUE IS MISSING

LIVER ..... NOT SPECIFIED (PRESENT)  
 -COMPOUND RELATED INFLAMMATORY REACTION ..... NOT SPECIFIED (TRACE)  
 -BILE DUCTULE EPITHELIAL HYPERPLASIA AND/OR CHOLANGIOFIBROSIS ..... MULTI-FOCAL (TRACE)  
 -HEPATOCTYE COALESCING MICROVESICULAR (FATTY) CHANGE LEADING TO NECROSIS AND MINERALIZATION

KIDNEY ..... NOT SPECIFIED (MILD)  
 -PROGRESSIVE RENAL DISEASE ..... TISSUE IS MISSING

URINARY BLADDER ..... NOT SPECIFIED (PRESENT)

UTERUS ..... NOT SPECIFIED (PRESENT)  
 -ENDOMETRIAL STROMAL POLYP

LETTERMAN ARMY INSTITUTE OF RESEARCH  
 DIV OF RES SUPP, PATH SERV GP  
 SPECIES: RAT/FISCHER-344

**Appendix J (cont.): PATHOLOGY INDIVIDUAL ANIMAL DATA**

INDIVIDUAL ANIMAL DATA REPORT  
 STUDY NUMBER: GLP83009  
 STUDY START DATE: 23-JAN-84

PRINTED: 21-NOV-89  
 PAGE: 571

ANIMAL NUMBER: 289/PRETEST-  
 DATE OF DEATH: 07-FEB-86  
 STUDY DAY OF DEATH: 747  
 SEX: FEMALE  
 DOSE GROUP: 2  
 SACRIFICE STATUS: FINAL SACRIFICE  
 STUDY WEEK OF DEATH: 107  
 TERMINAL BODY WEIGHT: 246.00 (GMS)

STUDY TYPE: CHRONIC/2 YR CARCINOGENIC

<< M I C R O S C O P I C T I S S U E O B S E R V A T I O N S >>

TISSUE / HISTOPATHOLOGIC FINDINGS ..... DISTRIBUTION (SEVERITY) / SPECIAL COMMENTS

UTERUS .....  
 -CYSTIC DILATATION OF THE ENDOMETRIAL GLANDS ..... NOT SPECIFIED (PRESENT)  
 -ENDOMETRITIS, SUBACUTE ..... NOT SPECIFIED(TRACE)

OVARIES ..... TISSUE IS MISSING

SCIATIC NERVE ..... TISSUE IS MISSING

MAMMARY GLANDS ..... THE SUBCUTANEOUS MASS IN THE RIGHT THORACIC REGION IS A  
 -B- FIBROADENOMA ..... MAMMARY FIBROADENOMA.  
 (PRESENT)

ADRENAL ..... FOCAL(TRACE)  
 -FOCUS OF CELLULAR ALTERATION, VACUOLATED

PITUITARY GLAND .....  
 -B- ADENOMA ..... (PRESENT)

EYES & OPTIC N. ....  
 -RETINAL ATROPHY AND/OR DEGENERATION, UNILATERAL OR BILATERAL ..... NOT SPECIFIED(MILD)

Appendix J (cont.): **PATHOLOGY INDIVIDUAL ANIMAL DATA**

LETTERMAN ARMY INSTITUTE OF RESEARCH  
DIV OF RES SUPP, PATH SERV GP  
SPECIES: RAT/FISCHER-344  
STUDY NUMBER: GLP83009  
STUDY START DATE: 23-JAN-84  
STUDY TYPE: CHRONIC/2 YR CARCINOGENIC

PRINTED: 21-NOV-89  
PAGE: 572

ANIMAL NUMBER: 290/PRETEST=  
DATE OF DEATH: 07-FEB-86  
SEX: FEMALE  
DOSE GROUP: 2  
STUDY WEEK OF DEATH: 107  
SACRIFICE STATUS: FINAL SACRIFICE  
TERMINAL BODY WEIGHT: 262.00 (GMS)

ORGAN NAME: LIVER  
KEYWORDS / PHRASES: ENLARGED  
ADHESION(S)  
GROSS ORGAN OBSERVATIONS: VENTRAL ABDOMINAL WALL, DARK RED, .6CM DIAMETER.  
SEVERITY: PRESENT  
GROSS FREE-TEXT COMMENTS: PRESENT

TISSUE / HISTOPATHOLOGIC FINDINGS: TISSUE OBSERVATIONS: FOCAL(WILD)  
DISTRIBUTION (SEVERITY) / SPECIAL COMMENTS: NOT SPECIFIED(MILD)

HEART: -CARDIOMYOPATHY  
NOT SPECIFIED(MILD)

LUNGS: -FOCAL HYPERPLASTIC PROLIFERATION OF TYPE 2 ALVEOLAR EPITHELIAL CELLS WITH OR WITHOUT INFLAMMATORY CELL INFILTRATION  
FOCAL(WILD)

LIVER: -COMPOUND RELATED INFLAMMATORY REACTION  
-BILE DUCTULE EPITHELIAL HYPERPLASIA AND/OR CHOLANGIOFIBROSIS  
-HEPATITIS  
-HEPATOCYTTIC VACUOLIZATION  
NOT SPECIFIED (PRESENT)  
NOT SPECIFIED(TRACE)  
MULTI-FOCAL(TRACE)  
MULTI-FOCAL(MILD)

KIDNEY: -PROGRESSIVE RENAL DISEASE  
NOT SPECIFIED(MODERATE)

UTERUS: -ENDOMETRIAL STROMAL POLYP  
NOT SPECIFIED (PRESENT)

SKELETAL MUSCLE: TISSUE IS MISSING

SCIATIC NERVE: TISSUE IS MISSING

MAMMARY GLANDS: -HYPERPLASIA AND/OR HYPERTROPHY OF THE ACINAR TISSUE  
NOT SPECIFIED(MILD)

Appendix J (cont.): PATHOLOGY INDIVIDUAL ANIMAL DATA

LETTERMAN ARMY INSTITUTE OF RESEARCH  
DIV OF RES SUPP, PATH SERV GP  
SPECIES: RAT/FISCHER-344

INDIVIDUAL ANIMAL DATA REPORT  
STUDY NUMBER: GLP83009  
STUDY START DATE: 23-JAN-84

PRINTED: 21-NOV-89  
PAGE: 573

STUDY TYPE: CHRONIC/2 YR CARCINOGENIC

ANIMAL NUMBER: 290/PRETEST#      DOSE GROUP: 2      SACRIFICE STATUS: FINAL SACRIFICE  
DATE OF DEATH: 07-FEB-86      STUDY DAY OF DEATH: 747      STUDY WEEK OF DEATH: 107      TERMINAL BODY WEIGHT: 262.00 (GMS)

<< MICROSCOPIC TISSUE OBSERVATIONS >>  
TISSUE / HISTOPATHOLOGIC FINDINGS      DISTRIBUTION (SEVERITY) / SPECIAL COMMENTS

MAMMARY GLANDS ..... NOT SPECIFIED (PRESENT)  
-DILATATION (ECTASIA) OF DUCTS AND DUCTULES  
MOSE/TURBINATES ..... CELLULAR INFILTRATE IS ADJACENT NASO-LACRIMAL DUCTS.  
-MIXED INFLAMMATORY CELL INFILTRATION, NASAL CAVITY, SINUSES,      NOT SPECIFIED(MILD)  
TURBINATES, NASO-LACRIMAL DUCTS  
PITUITARY GLAND ..... (PRESENT)  
-B- ADENOMA

Appendix J (cont.): PATHOLOGY INDIVIDUAL ANIMAL DATA

LETTERMAN ARMY INSTITUTE OF RESEARCH INDIVIDUAL ANIMAL DATA REPORT PRINTED: 21-NOV-89  
DIV OF RES SUPP, PATH SERV GP STUDY NUMBER: GLP83009 PAGE: 574  
SPECIES: RAT/FISCHER-344 STUDY START DATE: 23-JAN-84 STUDY TYPE: CHRONIC/2 YR CARCINOGENIC

ANIMAL NUMBER: 291/PRETEST# 291 SEX: FEMALE DOSE GROUP: 2 SACRIFICE STATUS: FINAL SACRIFICE  
DATE OF DEATH: 07-FEB-86 STUDY DAY OF DEATH: 747 STUDY WEEK OF DEATH: 107 TERMINAL BODY WEIGHT: 270.00 (GMS)

<< GROSS ORGAN OBSERVATIONS >>  
SEVERITY GROSS FREE-TEXT COMMENTS  
ORGAN NAME KEYWORDS / PHRASES  
LIVER ADHESION(S) PRESENT DIAPHRAGM.  
UTERUS POLYP PRESENT LEFT UTERINE HORN  
LYMPH NODES ENLARGED PRESENT CERVICAL, .5CM IN DIAMETER.

<< MICROSCOPIC TISSUE OBSERVATIONS >>  
DISTRIBUTION (SEVERITY) / SPECIAL COMMENTS  
TISSUE / HISTOPATHOLOGIC FINDINGS

THYROID GLANDS ..... (PRESENT)  
-9- PARA-FOLLICULAR CELL ADENOMA

LUNGS ..... NOT SPECIFIED(TRACE)  
-MINERALIZATION OF PULMONARY ARTERIES

LYMPH NODES ..... RBC'S AND PIGMENT PRESENT IN MEDIASTINAL NODE.  
-RED BLOOD CELLS, HEMOSIDERIN AND/OR ERYTHROPHAGOCYTOSIS WITHIN NOT SPECIFIED (PRESENT)  
MEDULLARY SINUSES

LIVER ..... NOT SPECIFIED (PRESENT)  
-COMPOUND RELATED INFLAMMATORY REACTION NOT SPECIFIED(TRACE)  
-BILE DUCTULE EPITHELIAL HYPERPLASIA AND/OR CHOLANGIOFIBROSIS MULTI-FOCAL(TRACE)  
-HEPATITIS MULTI-FOCAL(MILD)  
-HEPATOCTYE COALESCING MICROVESICULAR (FATTY) CHANGE LEADING TO NECROSIS AND MINERALIZATION

KIDNEY ..... NOT SPECIFIED(TRACE)  
-PROGRESSIVE RENAL DISEASE

UTERUS ..... EXAMINATION OF MULTIPLE SECTIONS OF THE UTERUS FAILED TO DEMONSTRATE THE UTERINE POLYP DESCRIBED GROSSLY.

MAMMARY GLANDS ..... NOT SPECIFIED(TRACE)  
-HYPERPLASIA AND/OR HYPERTROPHY OF THE ACINAR TISSUE NOT SPECIFIED (PRESENT)  
-DILATATION (ECTASIA) OF DUCTS AND DUCTULES



Appendix J (cont.): PATHOLOGY INDIVIDUAL ANIMAL DATA

LETTERMAN ARMY INSTITUTE OF RESEARCH  
 DIV OF RES SUPP, PATH SERV GP  
 SPECIES: RAT/FISCHER-344

INDIVIDUAL ANIMAL DATA REPORT  
 STUDY NUMBER: GLP83009  
 STUDY START DATE: 23-JAN-84

PRINTED: 21-NOV-89  
 PAGE: 575  
 STUDY TYPE: CHRONIC/2 YR CARCINOGENIC

ANIMAL NUMBER: 291/PRETEST#  
 DOSE GROUP: 2  
 SACRIFICE STATUS: FINAL SACRIFICE

DATE OF DEATH: 07-FEB-86  
 STUDY DAY OF DEATH: 747  
 STUDY WEEK OF DEATH: 107  
 TERMINAL BODY WEIGHT: 270.00 (GMS)

<< MICROSCOPIC TISSUE OBSERVATIONS >>  
 DISTRIBUTION (SEVERITY) / SPECIAL COMMENTS

TISSUE / HISTOPATHOLOGIC FINDINGS

NOSE/TURBINATES ..... CELLULAR INFILTRATE INVOLVES MASO-LACRIMAL DUCTS.  
 -MIXED INFLAMMATORY CELL INFILTRATION, NASAL CAVITY, SINUSES, NOT SPECIFIED(MARKED)  
 TURBINATES, MASO-LACRIMAL DUCTS

ADRENAL ..... NOT SPECIFIED(TRACE)  
 -FOCUS OF CELLULAR ALTERATION, VACUOLATED

PITUITARY GLAND ..... (PRESENT)  
 -B- ADENOMA

EYES & OPTIC N. ....  
 -RETINAL ATROPHY AND/OR DEGENERATION, UNILATERAL OR BILATERAL NOT SPECIFIED(SEVERE)  
 -IRIDOCYCLITIS NOT SPECIFIED(MODERATE)  
 -LENTICULAR DEGENERATIVE CHANGES COMPATIBLE WITH CATARACT NOT SPECIFIED (PRESENT)

DIAPHRAGM ..... MISCELLANEOUS TISSUE  
 -COMPOUND RELATED INFLAMMATORY REACTION NOT SPECIFIED (PRESENT)

Appendix J (cont.): PATHOLOGY INDIVIDUAL ANIMAL DATA

LETTERMAN ARMY INSTITUTE OF RESEARCH  
DIV OF RES SUPP, PATH SERV GP  
SPECIES: RAT/FISCHER-344  
STUDY NUMBER: GLP83009  
STUDY START DATE: 23-JAN-84  
STUDY TYPE: CHRONIC/2 YR CARCINOGENIC

PRINTED: 21-NOV-89  
PAGE: 576

ANIMAL NUMBER: 292/PRETEST-  
DATE OF DEATH: 11-JAN-86  
SEX: FEMALE  
DOSE GROUP: 2  
SACRIFICE STATUS: FOUND DEAD  
STUDY WEEK OF DEATH: 103  
TERMINAL BODY WEIGHT: NOT TAKEN

ORGAN NAME: << GROSS ORGAN OBSERVATIONS >>  
KEYWORDS / PHRASES: SEVERITY GROSS FREE-TEXT COMMENTS  
LIVER: ADHESION(S) PRESENT DIAPHRAGM AND ABDOMINAL WALL, 1.5CM DIAMETER AREA  
PITUITARY GLAND: ENLARGED MILD PRESENT  
PITUITARY GLAND: DISCOLORATION PRESENT FOCAL, DARK RED, 2MM DIAMETER

TISSUE / HISTOPATHOLOGIC FINDINGS: << MICROSCOPIC TISSUE OBSERVATIONS >>  
DISTRIBUTION (SEVERITY) / SPECIAL COMMENTS

- HEART ..... NOT SPECIFIED (TRACE)
- CARDIOMYOPATHY
- THYMUS ..... TISSUE IS MISSING
- LIVER ..... NOT SPECIFIED (PRESENT)
- COMPOUND RELATED INFLAMMATORY REACTION
- BILE DUCTULE EPITHELIAL HYPERPLASIA AND/OR CHOLANGIOFIBROSIS
- HEPATITIS
- FOCUS OF CELLULAR ALTERATION . BASOPHILIC
- HEPATOCTYIC VACUOLIZATION
- KIDNEY ..... NOT SPECIFIED (TRACE)
- PROGRESSIVE RENAL DISEASE
- URINARY BLADDER ..... TISSUE IS MISSING
- CECUM ..... TISSUE IS AUTOLYTIC
- MAMMARY GLANDS ..... NOT SPECIFIED (MILD)
- HYPERPLASIA AND/OR HYPERTROPHY OF THE ACINAR TISSUE
- DILATATION (ECTASIA) OF DUCTS AND DUCTULES
- ADRENAL .....

Appendix J (cont.): PATHOLOGY INDIVIDUAL ANIMAL DATA

LETTERMAN ARMY INSTITUTE OF RESEARCH  
 DIV OF RES SUPP, PATH SERV GP  
 SPECIES: RAT/FISCHER-344  
 ANIMAL NUMBER: 292/PRETEST-  
 DATE OF DEATH: 11-JAN-86  
 STUDY START DATE: 23-JAN-84  
 STUDY NUMBER: GLP83009  
 STUDY TYPE: CHRONIC/2 YR CARCINOGENIC  
 DOSE GROUP: 2  
 SACRIFICE STATUS: FOUND DEAD  
 STUDY WEEK OF DEATH: 103  
 TERMINAL BODY WEIGHT: NOT TAKEN  
 << MICROSCOPIC TISSUE OBSERVATIONS >>  
 TISSUE / HISTOPATHOLOGIC FINDINGS  
 DISTRIBUTION (SEVERITY) / SPECIAL COMMENTS

PRINTED: 21-NOV-89  
PAGE: 577

- ADRENAL ..... NOT SPECIFIED (TRACE)
- FOCUS OF CELLULAR ALTERATION, VACUOLATED
- PITUITARY GLAND ..... (PRESENT)
- B- ADENOMA
- EYES & OPTIC N. .... THE RETINA HAS UNDERGONE AUTOLYTIC CHANGE AND CANNOT BE EVALUATED.
- METAPLASTIC BONE FORMATION AND/OR MINERALIZATION, SCLERA NOT SPECIFIED (PRESENT)
- DIAPHRAGM ..... MISCELLANEOUS TISSUE
- COMPOUND RELATED INFLAMMATORY REACTION NOT SPECIFIED (PRESENT)

Appendix J (cont.): PATHOLOGY INDIVIDUAL ANIMAL DATA

LETTERMAN ARMY INSTITUTE OF RESEARCH  
DIV OF RES SUPP, PATH SERV GP  
SPECIES: RAT/FISCHER-344

INDIVIDUAL ANIMAL DATA REPORT  
STUDY NUMBER: GLP83009  
STUDY START DATE: 23-JAN-84

PRINTED: 21-NOV-89  
PAGE: 578

STUDY TYPE: CHRONIC/2 YR CARCINOGENIC

ANIMAL NUMBER: 293/PRETEST- 293 SEX: FEMALE DOSE GROUP: 2 SACRIFICE STATUS: FINAL SACRIFICE  
DATE OF DEATH: 07-FEB-86 STUDY DAY OF DEATH: 747 STUDY WEEK OF DEATH: 107 TERMINAL BODY WEIGHT: 299.00 (GMS)

ORGAN NAME << GROSS ORGAN OBSERVATIONS >>  
KEYWORDS / PHRASES SEVERITY GROSS FREE-TEXT COMMENTS  
ADHESION(S) PRESENT DIAPHRAGM

TISSUE / HISTOPATHOLOGIC FINDINGS << MICROSCOPIC TISSUE OBSERVATIONS >>  
DISTRIBUTION (SEVERITY) / SPECIAL COMMENTS

PARATHYROID ..... TISSUE IS MISSING

HEART .....  
-CARDIOMYOPATHY ..... NOT SPECIFIED(TRACE)

LYMPH NODES .....  
-REACTIVE HYPERPLASIA ..... REACTIVE HYPERPLASIA IS PRESENT IN CERVICAL AND MEDIASTINAL  
NOT SPECIFIED (PRESENT) ..... NODES. MESENTERIC NODES ARE MISSING. RVICAL AND MEDIASTINAL  
NOT SPECIFIED (PRESENT)

LIVER .....  
-COMPOUND RELATED INFLAMMATORY REACTION ..... NOT SPECIFIED (PRESENT)  
-BILE DUCTULE EPITHELIAL HYPERPLASIA AND/OR CHOLANGIOFIBROSIS ..... NOT SPECIFIED(MILD)  
-HEPATITIS ..... MULTI-FOCAL(TRACE)  
-FOCUS OF CELLULAR ALTERATION - BASOPHILIC ..... MULTI-FOCAL(MILD)  
-HEPATOCTYIC VACUOLIZATION ..... NOT SPECIFIED(MODERATE)  
-HEPATOCTYCE COALESCING MICROVESICULAR (FATTY) CHANGE LEADING TO ..... MULTI-FOCAL(MILD)  
NECROSIS AND MINERALIZATION

KIDNEY .....  
-PROGRESSIVE RENAL DISEASE ..... NOT SPECIFIED(TRACE)

MAMMARY GLANDS .....  
-HYPERPLASIA AND/OR HYPERTROPHY OF THE ACINAR TISSUE ..... NOT SPECIFIED(MILD)  
-DILATATION (ECTASIA) OF DUCTS AND DUCTULES ..... NOT SPECIFIED (PRESENT)

NOSE/TURBINATES .....  
-MIXED INFLAMMATORY CELL INFILTRATION, NASAL CAVITY, SINUSES, ..... CELLULAR INFILTRATE IS ADJACENT NASO-LACRIMAL DUCTS.  
TURBINATES, NASO-LACRIMAL DUCTS ..... NOT SPECIFIED(MILD)

Appendix J (cont.): PATHOLOGY INDIVIDUAL ANIMAL DATA

LETTERMAN ARMY INSTITUTE OF RESEARCH  
 DIV OF RES SUPP. PATH SERV GP  
 SPECIES: RAT/FISCHER-344  
 STUDY START DATE: 23-JAN-84  
 STUDY NUMBER: GLP83009  
 PRINTED: 21-NOV-89  
 PAGE: 579  
 STUDY TYPE: CHRONIC/2 YR CARCINOGENIC

ANIMAL NUMBER: 293/PRETEST-  
 DATE OF DEATH: 07-FEB-86  
 STUDY DAY OF DEATH: 747  
 SEX: FEMALE  
 DOSE GROUP: 2  
 SACRIFICE STATUS: FINAL SACRIFICE  
 TERMINAL BODY WEIGHT: 299.00 (GMS)

<< M I C R O S C O P I C T I S S U E O B S E R V A T I O N S >>  
 TISSUE / HISTOPATHOLOGIC FINDINGS  
 DISTRIBUTION (SEVERITY) / SPECIAL COMMENTS

ADRENAL ..... TISSUE IS MISSING

PITUITARY GLAND ..... TISSUE IS MISSING

EYES & OPTIC N. .... FOCAL (TRACE)

-CORNEAL MINERALIZATION

WHOLE BODY ..... CHRONIC INFLAMMATION OF BROWN FAT IS NOTED ADJACENT TO THE  
 TRACHEA AT THE LEVEL OF THE THYROID GLANDS AND ADJACENT TO THE  
 THYMUS IN THE MEDIASTINUM. E THYROID GLANDS AND ADJACENT TO THE  
 NOT SPECIFIED (PRESENT)

-INFLAMMATION OF BROWN FAT, (LOCATION SPECIFIED IN COMMENTS)

DIAPHRAGM ..... MISCELLANEOUS TISSUE  
 -COMPOUND RELATED INFLAMMATORY REACTION NOT SPECIFIED (PRESENT)

Appendix J (cont.): PATHOLOGY INDIVIDUAL ANIMAL DATA

LETTERMAN ARMY INSTITUTE OF RESEARCH  
 DIV OF RES SUPP, PATH SERV GP  
 SPECIES: RAT/FISCHER-344  
 ANIMAL NUMBER: 294/PRETEST=  
 DATE OF DEATH: 07-FEB-86  
 STUDY START DATE: 23-JAN-84  
 STUDY DAY OF DEATH: 747  
 294 SEX: FEMALE  
 DOSE GROUP: 2  
 STUDY WEEK OF DEATH: 107  
 SACRIFICE STATUS: FINAL SACRIFICE  
 TERMINAL BODY WEIGHT: 260.00 (GMS)  
 STUDY TYPE: CHRONIC/2 YR CARCINOGENIC  
 PRINTED: 21-NOV-89  
 PAGE: 580

<< GROSS ORGAN OBSERVATIONS >>  
 SEVERITY GROSS FREE-TEXT COMMENTS  
 KEYWORDS / PHRASES  
 ADHESION(S)  
 CORNEAL OPACITY  
 PRESENT DIAPHRAGM  
 PRESENT RIGHT.

<< MICROSCOPIC TISSUE OBSERVATIONS >>  
 DISTRIBUTION (SEVERITY) / SPECIAL COMMENTS

- THYROID GLANDS ..... NOT SPECIFIED (TRACE)
- PARA-FOLLICULAR CELL HYPERPLASIA (% CELL, LIGHT CELL)
- LUNGS ..... NOT SPECIFIED (TRACE)
- MINERALIZATION OF PULMONARY ARTERIES
- LIVER ..... NOT SPECIFIED (PRESENT)
- COMPOUND RELATED INFLAMMATORY REACTION
- BILE DUCTULE EPITHELIAL HYPERPLASIA AND/OR CHOLANGIOFIBROSIS
- HEPATITIS
- FOCUS OF CELLULAR ALTERATION - BASOPHILIC
- KIDNEY ..... NOT SPECIFIED (TRACE)
- PROGRESSIVE RENAL DISEASE
- URINARY BLADDER ..... TISSUE IS MISSING
- MAMMARY GLANDS ..... NOT SPECIFIED (TRACE)
- HYPERPLASIA AND/OR HYPERTROPHY OF THE ACINAR TISSUE
- DILATATION (ECTASIA) OF DUCTS AND DUCTULES
- NOSE/TURBINATES ..... CELLULAR INFILTRATE IS ADJACENT THE NASO-LACRIMAL DUCTS.
- MIXED INFLAMMATORY CELL INFILTRATION, NASAL CAVITY, SINUSES, NOT SPECIFIED (MILD)
- TURBINATES, NASO-LACRIMAL DUCTS

Appendix J (cont.): PATHOLOGY INDIVIDUAL ANIMAL DATA

LETTERMAN ARMY INSTITUTE OF RESEARCH  
DIV OF RES SUPP, PATH SERV GP  
SPECIES: RAT/FISCHER-344

INDIVIDUAL ANIMAL DATA REPORT  
STUDY NUMBER: GLP83009  
STUDY START DATE: 23-JAN-84

PRINTED: 21-NOV-89  
PAGE: 581  
STUDY TYPE: CHRONIC/2 YR CARCINOGENIC

ANIMAL NUMBER: 294/PRETEST= 294 SEX: FEMALE DOSE GROUP: 2 SACRIFICE STATUS: FINAL SACRIFICE  
DATE OF DEATH: 07-FEB-86 STUDY DAY OF DEATH: 747 STUDY WEEK OF DEATH: 107 TERMINAL BODY WEIGHT: 260.00 (GMS)

<< MICROSCOPIC TISSUE OBSERVATIONS >>  
TISSUE / HISTOPATHOLOGIC FINDINGS  
DISTRIBUTION (SEVERITY) / SPECIAL COMMENTS

BONE, FEMUR ..... TISSUE IS MISSING

PITUITARY GLAND ..... NOT SPECIFIED (PRESENT)  
-CYST(S)

EYES & OPTIC N. ....  
-CORNEAL MINERALIZATION ..... NOT SPECIFIED (TRACE)  
-RETINAL ATROPHY AND/OR DEGENERATION, UNILATERAL OR BILATERAL ..... NOT SPECIFIED (MODERATE)  
-LENTICULAR DEGENERATIVE CHANGES COMPATIBLE WITH CATARACT ..... NOT SPECIFIED (PRESENT)

DIAPHRAGM ..... MISCELLANEOUS TISSUE  
-COMPOUND RELATED INFLAMMATORY REACTION ..... NOT SPECIFIED (PRESENT)

Appendix J (cont.): PATHOLOGY INDIVIDUAL ANIMAL DATA

LETTERMAN ARMY INSTITUTE OF RESEARCH DIV OF RES SUPP, PATH SERV GP SPECIES: RAT/FISCHER-344 STUDY START DATE: 23-JAN-84 STUDY NUMBER: GLP83009 PRINTED: 21-NOV-89 PAGE: 582

ANIMAL NUMBER: 295/PRETEST= 295 SEX: FEMALE DOSE GROUP: 2 SACRIFICE STATUS: FINAL SACRIFICE DATE OF DEATH: 07-FEB-86 STUDY DAY OF DEATH: 747 STUDY WEEK OF DEATH: 107 TERMINAL BODY WEIGHT: 224.00 (GMS) STUDY TYPE: CHRONIC/2 YR CARCINOGENIC

ORGAN NAME SEVERITY GROSS ORGAN OBSERVATIONS GROSS FREE-TEXT COMMENTS LIVER PRESENT VENTRAL ABDOMINAL WALL. UTERUS PRESENT RIGHT HORN, PROXIMAL TO OVARY, 1.5 X .6CM, DISTAL TO OVARY, .5 X .3 CM. LEFT HORN, PROXIMAL TO OVARY, 1 X .7CM. OVARIES PRESENT LEFT. 1CM DIAMETER. PARA-OVARIAN CYST(S)

TISSUE / HISTOPATHOLOGIC FINDINGS << MICROSCOPIC TISSUE OBSERVATIONS >> DISTRIBUTION (SEVERITY) / SPECIAL COMMENTS

LACRIMAL GLAND -INFLAMMATION, SUBACUTE TO CHRONIC MULTI-FOCAL(MILD)

LUNGS -MINERALIZATION OF PULMONARY ARTERIES NOT SPECIFIED(TRACE)

LYMPH NODES RBC'S. PIGMENT, REACTIVE HYPERPLASIA AND DILATED SINUSES ARE NOTED IN MEDIASTINAL NODES. NOT SPECIFIED (PRESENT)

-RED BLOOD CELLS, HEMOSIDERIN AND/OR ERYTHROPHAGOCYTOSIS WITHIN MEDULLARY SINUSES NOT SPECIFIED (PRESENT) -REACTIVE HYPERPLASIA NOT SPECIFIED (PRESENT) -DILATED AND/OR CYSTIC MEDULLARY SINUSES

LIVER -COMPOUND RELATED INFLAMMATORY REACTION NOT SPECIFIED (PRESENT) -BILE DUCTULE EPITHELIAL HYPERPLASIA AND/OR CHOLANGIOFIBROSIS NOT SPECIFIED(TRACE) -HEPATITIS MULTI-FOCAL(MILD) -FOCUS OF CELLULAR ALTERATION - BASOPHILIC MULTI-FOCAL(MODERATE) -HEPATOCTYIC VACUOLIZATION

KIDNEY -PROGRESSIVE RENAL DISEASE NOT SPECIFIED(MILD)

UTERUS



Appendix J (cont.): PATHOLOGY INDIVIDUAL ANIMAL DATA

LETTERMAN ARMY INSTITUTE OF RESEARCH  
DIV OF RES SUPP, PATH SERV GP  
SPECIES: RAT/FISCHER-344

INDIVIDUAL ANIMAL DATA REPORT  
STUDY NUMBER: GLP83009  
STUDY START DATE: 23-JAN-84

PRINTED: 21-NOV-89  
PAGE: 583

STUDY TYPE: CHRONIC/2 YR CARCINOGENIC

ANIMAL NUMBER: 295/PRETEST#      DOSE GROUP: 2      SACRIFICE STATUS: FINAL SACRIFICE  
DATE OF DEATH: 07-FEB-86      STUDY DAY OF DEATH: 747      STUDY WEEK OF DEATH: 107      TERMINAL BODY WEIGHT: 224.00 (GMS)

<< M I C R O S C O P I C      T I S S U E      O B S E R V A T I O N S      >>  
TISSUE / HISTOPATHOLOGIC FINDINGS      DISTRIBUTION (SEVERITY) / SPECIAL COMMENTS

UTERUS .....  
-ENDOMETRIAL STROMAL POLYP ..... NOT SPECIFIED (PRESENT)  
-CYSTIC DILATATION OF THE ENDOMETRIAL GLANDS ..... NOT SPECIFIED (PRESENT)

OVARIES .....  
-PARA-OVARIAN CYST(S) ..... NOT SPECIFIED (PRESENT)

MAMMARY GLANDS .....  
-HYPERPLASIA AND/OR HYPERTROPHY OF THE ACIMAR TISSUE ..... NOT SPECIFIED (MILD)  
-DILATATION (ECTASIA) OF DUCTS AND DUCTULES ..... NOT SPECIFIED (PRESENT)

NOSE/TURBINATES .....  
-MIXED INFLAMMATORY CELL INFILTRATION, NASAL CAVITY, SINUSES, ..... CELLULAR INFILTRATE IS NOTED ADJACENT TO NASO-LACRIMAL DUCT.  
TURBINATES, NASO-LACRIMAL DUCTS ..... NOT SPECIFIED (MILD)

ADRENAL .....  
-FOCUS OF CELLULAR ALTERATION, VACUOLATED ..... NOT SPECIFIED (TRACE)

PITUITARY GLAND .....  
-CYST(S) ..... NOT SPECIFIED (PRESENT)

WHOLE BODY .....  
-INFLAMMATION OF BROWN FAT, (LOCATION SPECIFIED IN COMMENTS) ..... INFLAMMATION OF BROWN FAT NOTED ADJACENT TO THE THYROID GLANDS.  
-INFLAMMATION OF BROWN FAT, (LOCATION SPECIFIED IN COMMENTS) ..... NOT SPECIFIED (PRESENT)

**Appendix J (cont.): PATHOLOGY INDIVIDUAL ANIMAL DATA**

LETTERMAN ARMY INSTITUTE OF RESEARCH  
 DIV OF RES SUPP, PATH SERV GP  
 SPECIES: RAT/FISCHER-344

INDIVIDUAL ANIMAL DATA REPORT  
 STUDY NUMBER: GLP83009  
 STUDY START DATE: 23-JAN-84

PRINTED: 21-NOV-89  
 PAGE: 584

STUDY TYPE: CHRONIC/2 YR CARCINOGENIC

ANIMAL NUMBER: 296/PRETEST-296 SEX: FEMALE DOSE GROUP: 2 SACRIFICE STATUS: FINAL SACRIFICE  
 DATE OF DEATH: 07-FEB-86 STUDY DAY OF DEATH: 747 STUDY WEEK OF DEATH: 107 TERMINAL BODY WEIGHT: 247.00 (GMS)

ORGAN NAME << GROSS ORGAN OBSERVATIONS >>  
 SEVERITY GROSS FREE-TEXT COMMENTS  
 LIVER PRESENT DIAPHRAGM  
 PITUITARY GLAND PRESENT FOCAL, BLACK, .3CM DIAMETER

TISSUE / HISTOPATHOLOGIC FINDINGS << MICROSCOPIC TISSUE OBSERVATIONS >>  
 DISTRIBUTION (SEVERITY) / SPECIAL COMMENTS

- THYROID GLANDS ..... NOT SPECIFIED (TRACE)
- PARA-FOLLICULAR CELL HYPERPLASIA ("C" CELL, LIGHT CELL) .....
- HEART ..... NOT SPECIFIED (TRACE)
- CARDIOMYOPATHY .....
- LUNGS ..... NOT SPECIFIED (TRACE)
- MINERALIZATION OF PULMONARY ARTERIES .....
- LYMPH NODES ..... REACTIVE HYPERPLASIA NOTED IN CERVICAL NODES.  
 REACTIVE HYPERPLASIA, PIGMENT AND RBC'S NOTED IN MEDIASTINAL  
 NODES.  
 NOT SPECIFIED (PRESENT)
- RED BLOOD CELLS, HEMOSIDERIN AND/OR ERYTHROPHAGOCYTOSIS WITHIN  
 MEDULLARY SINUSES  
 -REACTIVE HYPERPLASIA  
 NOT SPECIFIED (PRESENT)
- LIVER ..... NOT SPECIFIED (TRACE)  
 -BILE DUCTULE EPITHELIAL HYPERPLASIA AND/OR CHOLANGIOFIBROSIS  
 -HEPATITIS  
 -FOCUS OF CELLULAR ALTERATION - BASOPHILIC  
 -FIBROSIS CAPSULAR NO COMPOUND  
 -CYSTIC DEGENERATION  
 FOCAL (PRESENT)
- KIDNEY ..... NOT SPECIFIED (MODERATE)  
 -PROGRESSIVE RENAL DISEASE .....
- PANCREAS .....

**Appendix J (cont.): PATHOLOGY INDIVIDUAL ANIMAL DATA**

LETTERMAN ARMY INSTITUTE OF RESEARCH  
 DIV OF RES SUPP, PATH SERV GP  
 SPECIES: RAT/FISCHER-344  
 STUDY START DATE: 23-JAN-84  
 STUDY NUMBER: GLP83009  
 PRINTED: 21-NOV-89  
 PAGE: 585

ANIMAL NUMBER: 296/PRETEST= 296 SEX: FEMALE DOSE GROUP: 2 SACRIFICE STATUS: FINAL SACRIFICE  
 DATE OF DEATH: 07-FEB-86 STUDY DAY OF DEATH: 747 STUDY WEEK OF DEATH: 107 TERMINAL BODY WEIGHT: 247.00 (GMS)  
 STUDY TYPE: CHRONIC/2 YR CARCINOGENIC

TISSUE / HISTOPATHOLOGIC FINDINGS  
 << MICROSCOPIC TISSUE OBSERVATIONS >>  
 DISTRIBUTION (SEVERITY) / SPECIAL COMMENTS

PANCREAS ..... FOCAL(TRACE)  
 -ACINAR (EXOCRINE) ATROPHY .....  
 SKELETAL MUSCLE ..... TISSUE IS MISSING  
 SCIATIC NERVE ..... TISSUE IS MISSING  
 MAMMARY GLANDS .....  
 -HYPERPLASIA AND/OR HYPERTROPHY OF THE ACINAR TISSUE ..... NOT SPECIFIED(MILD)  
 -DILATATION (ECTASIA) OF DUCTS AND DUCTULES ..... NOT SPECIFIED (PRESENT)  
 NOSE/TURBINATES ..... CELLULAR INFILTRATE IS ADJACENT NASO-LACRIMAL DUCTS.  
 -MIXED INFLAMMATORY CELL INFILTRATION, NASAL CAVITY, SINUSES, ..... NOT SPECIFIED(MILD)  
 TURBINATES, NASO-LACRIMAL DUCTS .....  
 PITUITARY GLAND ..... (PRESENT)  
 -B- ADENOMA .....  
 EYES & OPTIC N. ....  
 -RETINAL ATROPHY AND/OR DEGENERATION, UNILATERAL OR BILATERAL ..... NOT SPECIFIED(TRACE)  
 -CHRONIC KERATITIS ..... FOCAL(TRACE)  
 DIAPHRAGM ..... MISCELLANEOUS TISSUE  
 -COMPOUND RELATED INFLAMMATORY REACTION ..... NOT SPECIFIED (PRESENT)

Appendix J (cont.): PATHOLOGY INDIVIDUAL ANIMAL DATA

LETTERMAN ARMY INSTITUTE OF RESEARCH  
DIV OF RES SUPP, PATH SERV 6P  
SPECIES: RAT/FISCHER-344

INDIVIDUAL ANIMAL DATA REPORT  
STUDY NUMBER: GLP83009  
STUDY START DATE: 23-JAN-84

PRINTED: 21-NOV-89  
PAGE: 506

STUDY TYPE: CHRONIC/2 YR CARCINOGENIC

ANIMAL NUMBER: 297/PRETEST= 297 SEX: FEMALE DOSE GROUP: 2 SACRIFICE STATUS: FINAL SACRIFICE  
DATE OF DEATH: 07-FEB-86 STUDY DAY OF DEATH: 747 STUDY WEEK OF DEATH: 107 TERMINAL BODY WEIGHT: 289.00 (GMS)

<< GROSS ORGAN OBSERVATIONS >>  
SEVERITY GROSS FREE-TEXT COMMENTS  
ADHESION(S) PRESENT VENTRAL ABDOMINAL WALL, DIAPHRAGM.

<< MICROSCOPIC TISSUE OBSERVATIONS >>  
TISSUE / HISTOPATHOLOGIC FINDINGS DISTRIBUTION (SEVERITY) / SPECIAL COMMENTS

THYROID GLANDS ..... (PRESENT)  
-B- PARA-FOLLICULAR CELL ADENOMA

HEART ..... NOT SPECIFIED(TRACE)  
-CARDIOMYOPATHY

LYMPH NODES ..... RBC'S AND PIGMENT NOTED IN MEDIASTINAL NODE.  
-RED BLOOD CELLS, HEMOSIDERIN AND/OR ERYTHROPHAGOCYTOSIS WITHIN MEDULLARY SINUSES NOT SPECIFIED (PRESENT)

LIVER ..... NOT SPECIFIED (PRESENT)  
-COMPOUND RELATED INFLAMMATORY REACTION NOT SPECIFIED (MILD)  
-BILE DUCTULE EPITHELIAL HYPERPLASIA AND/OR CHOLANGIOFIBROSIS MULTI-FOCAL(TRACE)  
-HEPATITIS MULTI-FOCAL(MILD)  
-HEPATOCTYE COALESCING MICROVESICULAR (FATTY) CHANGE LEADING TO NECROSIS AND MINERALIZATION

KIDNEY ..... NOT SPECIFIED(MILD)  
-PROGRESSIVE RENAL DISEASE

MAMMARY GLANDS ..... NOT SPECIFIED(MILD)  
-HYPERPLASIA AND/OR HYPERTROPHY OF THE ACINAR TISSUE NOT SPECIFIED (PRESENT)  
-DILATATION (ECTASIA) OF DUCTS AND DUCTULES

ADRENAL ..... NOT SPECIFIED(TRACE)  
-FOCUS OF CELLULAR ALTERATION, VACUOLATED

EYES & OPTIC N. ....

Appendix J (cont.): PATHOLOGY INDIVIDUAL ANIMAL DATA

LETTERMAN ARMY INSTITUTE OF RESEARCH  
DIV OF RES SUPP, PATH SERV GP  
SPECIES: RAT/FISCHER-344

PRINTED: 21-NOV-89  
PAGE: 567

INDIVIDUAL ANIMAL DATA REPORT  
STUDY NUMBER: GLP83009

STUDY START DATE: 23-JAN-84  
STUDY TYPE: CHRONIC/2 YR CARCINOGENIC  
ANIMAL NUMBER: 297/PRETEST=  
DOSE GROUP: 2  
SACRIFICE STATUS: FINAL SACRIFICE

DATE OF DEATH: 07-FEB-86  
STUDY DAY OF DEATH: 747  
STUDY WEEK OF DEATH: 107  
TERMINAL BODY WEIGHT: 289.00 (GMS)

TISSUE / HISTOPATHOLOGIC FINDINGS  
MICROSCOPIC TISSUE OBSERVATIONS >>  
DISTRIBUTION (SEVERITY) / SPECIAL COMMENTS

EYES & OPTIC N. ....  
-RETINAL ATROPHY AND/OR DEGENERATION, UNILATERAL OR BILATERAL NOT SPECIFIED (TRACE)  
-METAPLASTIC BONE FORMATION AND/OR MINERALIZATION, SCLERA NOT SPECIFIED (PRESENT)

DIAPHRAGM ..... MISCELLANEOUS TISSUE  
-COMPOUND RELATED INFLAMMATORY REACTION NOT SPECIFIED (PRESENT)

Appendix J (cont.): PATHOLOGY INDIVIDUAL ANIMAL DATA

LETTERMAN ARMY INSTITUTE OF RESEARCH  
DIV OF RES SUPP, PATH SERV GP  
SPECIES: RAT/FISCHER-344

INDIVIDUAL ANIMAL DATA REPORT  
STUDY NUMBER: GLP83009

PRINTED: 21-NOV-89  
PAGE: 588

STUDY START DATE: 23-JAN-84

STUDY TYPE: CHRONIC/2 YR CARCINOGENIC

ANIMAL NUMBER: 298/PRETEST=

298 SEX: FEMALE

DOSE GROUP: 2

SACRIFICE STATUS: FINAL SACRIFICE

DATE OF DEATH: 07-FEB-86

STUDY DAY OF DEATH: 747

STUDY WEEK OF DEATH: 107

TERMINAL BODY WEIGHT: 259.00 (GMS)

ORGAN NAME  
KEYWORDS / PHRASES

SEVERITY OBSERVATIONS >>>

GROSS ORGAN OBSERVATIONS >>>

LIVER  
ADHESION(S)  
DISCOLORATION  
UTERUS  
POLYP

PRESENT  
PRESENT  
PRESENT  
DIAPHRAGM, ABDOMINAL WALL.  
MULTIPLE, MINUTE, TAN FOCI, BILATERAL.  
LEFT HORN, DISTAL TO OVARY, 1 X .5CM.

TISSUE / HISTOPATHOLOGIC FINDINGS

TISSUE OBSERVATIONS >>>

DISTRIBUTION (SEVERITY) / SPECIAL COMMENTS

THYROID GLANDS

-PARAFOLLICULAR CELL HYPERPLASIA (MC CELL, LIGHT CELL)

NOT SPECIFIED(TRACE)

PARATHYROID

TISSUE IS MISSING

HEART

-CARDIOMYOPATHY

NOT SPECIFIED(MILD)

LIVER

-COMPOUND RELATED INFLAMMATORY REACTION  
-BILE DUCTULE EPITHELIAL HYPERPLASIA AND/OR CHOLANGIOFIBROSIS  
-HEPATITIS  
-FOCUS OF CELLULAR ALTERATION - BASOPHILIC  
-HEPATOCTYIC VACUOLIZATION  
-HEPATOCTYIC COALESCING MICROVESICULAR (FATTY) CHANGE LEADING TO  
NECROSIS AND MINERALIZATION

NOT SPECIFIED (PRESENT)  
NOT SPECIFIED(MILD)  
MULTI-FOCAL(TRACE)  
FOCAL(TRACE)  
MULTI-FOCAL(TRACE)  
MULTI-FOCAL(MILD)

KIDNEY

-PROGRESSIVE RENAL DISEASE

NOT SPECIFIED(MILD)

UTERUS

-ENDOMETRIAL STROMAL POLYP  
-CYSTIC DILATATION OF THE ENDOMETRIAL GLANDS

NOT SPECIFIED (PRESENT)  
NOT SPECIFIED (PRESENT)

MAMMARY GLANDS

Appendix J (cont.): PATHOLOGY INDIVIDUAL ANIMAL DATA

LETTERMAN ARMY INSTITUTE OF RESEARCH  
DIV OF RES SUPP, PATH SERV GP  
SPECIES: RAT/FISCHER-344

INDIVIDUAL ANIMAL DATA REPORT  
STUDY NUMBER: GLP83009  
STUDY START DATE: 23-JAN-84

PRINTED: 21-NOV-89  
PAGE: 589

STUDY TYPE: CHRONIC/2 YR CARCINOGENIC

ANIMAL NUMBER: 298/PRETEST= 298 SEX: FEMALE DOSE GROUP: 2 SACRIFICE STATUS: FINAL SACRIFICE  
DATE OF DEATH: 07-FEB-86 STUDY DAY OF DEATH: 747 STUDY WEEK OF DEATH: 107 TERMINAL BODY WEIGHT: 259.00 (GMS)

TISSUE / HISTOPATHOLOGIC FINDINGS << M I C R O S C O P I C T I S S U E O B S E R V A T I O N S >>  
DISTRIBUTION (SEVERITY) / SPECIAL COMMENTS

MAMMARY GLANDS ..... NOT SPECIFIED (PRESENT)  
-DILATATION (ECTASIA) OF DUCTS AND DUCTULES

NOSE/TURBINATES ..... CELLULAR INFILTRATE NOTED ADJACENT NASO-LACRIMAL DUCTS.  
-MIXED INFLAMMATORY CELL INFILTRATION, NASAL CAVITY, SINUSES, NOT SPECIFIED(MILD)  
TURBINATES, NASO-LACRIMAL DUCTS

**Appendix J (cont.): PATHOLOGY INDIVIDUAL ANIMAL DATA**

LETTERMAN ARMY INSTITUTE OF RESEARCH  
 DIV OF RES SUPP, PATH SERV GP  
 SPECIES: RAT/FISCHER-344

INDIVIDUAL ANIMAL DATA REPORT  
 STUDY NUMBER: GLP03009

PRINTED: 21-NOV-69  
 PAGE: 590

STUDY START DATE: 23-JAN-84

STUDY TYPE: CHRONIC/2 YR CARCINOGENIC

ANIMAL NUMBER: 299/PRETEST= 299 SEX: FEMALE DOSE GROUP: 2 SACRIFICE STATUS: FINAL SACRIFICE  
 DATE OF DEATH: 07-FEB-86 STUDY DAY OF DEATH: 747 STUDY WEEK OF DEATH: 107 TERMINAL BODY WEIGHT: 269.00 (GMS)

ORGAN NAME << G R O S S O R G A N O B S E R V A T I O N S >>  
 KEYWORDS / PHRASES SEVERITY GROSS FREE-TEXT COMMENTS  
 LIVER PRESENT VENTRAL ABDOMINAL WALL.  
 UTERUS PRESENT UTERINE HORNS, BILATERAL.  
 PITUITARY GLAND ENLARGED .5CM, DARK RED.

TISSUE / HISTOPATHOLOGIC FINDINGS << M I C R O S C O P I C T I S S U E O B S E R V A T I O N S >>  
 DISTRIBUTION (SEVERITY) / SPECIAL COMMENTS

- HEART ..... NOT SPECIFIED(MILD)
- CARDIOMYOPATHY .....
- LUNGS ..... FOCAL(MILD)
- PNEUMONIA, INTERSTITIAL, CHRONIC .....
- LYMPH NODES ..... REACTIVE HYPERPLASIA NOTED IN CERVICAL NODES.  
 REACTIVE HYPERPLASIA AND DILATED SINUSES ARE NOTED IN  
 MEDIASTINAL NODES.  
 NOT SPECIFIED (PRESENT)  
 NOT SPECIFIED (PRESENT)
- REACTIVE HYPERPLASIA .....
- DILATED AND/OR CYSTIC MEDULLAR. SINUSES .....
- LIVER ..... NOT SPECIFIED (PRESENT)  
 -COMPOUND RELATED INFLAMMATORY REACTION .....
- BILE DUCTULE EPITHELIAL HYPERPLASIA AND/OR CHOLANGIOFIBROSIS .....
- HEPATITIS .....
- HEPATOCTYTIC VACUOLIZATION .....
- FOCUS OF CELLULAR ALTERATION - EOSINOPHILIC CELLS .....
- HEPATOCTYTE COALESCING MICROVESICULAR (FATTY) CHANGE LEADING TO  
 NECROSIS AND MINERALIZATION .....
- KIDNEY ..... NOT SPECIFIED(MILD)
- PROGRESSIVE RENAL DISEASE .....
- UTERUS ..... NOT SPECIFIED(MILD)



Appendix J (cont.): PATHOLOGY INDIVIDUAL ANIMAL DATA

LETTERMAN ARMY INSTITUTE OF RESEARCH  
 DIV OF RES SUPP, PATH SERV GP  
 SPECIES: RAT/FISCHER-344  
 ANIMAL NUMBER: 299/PRETEST-  
 DATE OF DEATH: 07-FEB-86  
 STUDY DAY OF DEATH: 747  
 299 SEX: FEMALE  
 DOSE GROUP: 2  
 SACRIFICE STATUS: FINAL SACRIFICE  
 STUDY WEEK OF DEATH: 107  
 TERMINAL BODY WEIGHT: 289.00 (GMS)

INDIVIDUAL ANIMAL DATA REPORT  
 STUDY NUMBER: GLP83009  
 STUDY START DATE: 23-JAN-84  
 STUDY TYPE: CHRONIC/2 YR CARCINOGENIC

PRINTED: 21-NOV-89  
 PAGE: 591

<< M I C R O S C O P I C T I S S U E O B S E R V A T I O N S >>  
 TISSUE / HISTOPATHOLOGIC FINDINGS  
 DISTRIBUTION (SEVERITY) / SPECIAL COMMENTS

UTERUS  
 -DILATATION OF THE UTERINE LUMEN (HYDROMETRA)  
 -CYSTIC DILATATION OF THE ENDOMETRIAL GLANDS  
 NOT SPECIFIED (PRESENT)  
 NOT SPECIFIED (PRESENT)

OVARIES  
 -FOLLICULAR CYST(S)  
 NOT SPECIFIED (PRESENT)

MAMMARY GLANDS  
 -HYPERPLASIA AND/OR HYPERTROPHY OF THE ACINAR TISSUE  
 -DILATATION (ECTASIA) OF DUCTS AND DUCTULES  
 NOT SPECIFIED (MODERATE)  
 NOT SPECIFIED (PRESENT)

PITUITARY GLAND  
 -B- ADENOMA  
 (PRESENT)

Appendix J (cont.): PATHOLOGY INDIVIDUAL ANIMAL DATA

LETTERMAN ARMY INSTITUTE OF RESEARCH INDIVIDUAL ANIMAL DATA REPORT PRINTED: 21-NOV-89  
DIV OF RES SUPP, PATH SERV GP STUDY NUMBER: GLP83009 PAGE: 592  
SPECIES: RAT/FISCHER-344 STUDY START DATE: 23-JAN-84 STUDY TYPE: CHRONIC/2 YR CARCINOGENIC

ANIMAL NUMBER: 300/PRETEST-300 SEX: FEMALE DOSE GROUP: 2 SACRIFICE STATUS: FINAL SACRIFICE  
DATE OF DEATH: 07-FEB-86 STUDY DAY OF DEATH: 747 STUDY WEEK OF DEATH: 107 TERMINAL BODY WEIGHT: 270.00 (GMS)

<< GROSS ORGAN OBSERVATIONS >>  
SEVERITY GROSS FREE-TEXT COMMENTS  
ORGAN NAME  
LIVER PRESENT DIAPHRAGM, VENTRAL ABDOMINAL WALL  
ADHESION(S) PRESENT FOCAL, RED, .5CM DIAMETER  
PITUITARY GLAND PRESENT ONE BLACK FOCAL AREA, .1CM DIAMETER, BILATERAL.  
ADRENAL PRESENT RIGHT HORN, 1.5 X .5CM, PROXIMAL TO OVARY.  
UTERUS PRESENT LEFT HORN, 1.2 X .4CM, PROXIMAL TO OVARY. 1.4 X .5CM PROXIMAL TO UTERUS.

<< MICROSCOPIC TISSUE OBSERVATIONS >>  
DISTRIBUTION (SEVERITY) / SPECIAL COMMENTS

HEART ..... NOT SPECIFIED(TRACE)  
-CARDIOMYOPATHY .....  
SPLEEN ..... FOCAL(TRACE)  
-FIBROSIS CAPSULAR .....  
LIVER ..... NOT SPECIFIED (PRESENT)  
-COMPOUND RELATED INFLAMMATORY REACTION ..... MULTI-FOCAL(TRACE)  
-HEPATITIS ..... MULTI-FOCAL(MILD)  
-HEPATOCTYTE COALESCING MICROVESICULAR (FATTY) CHANGE LEADING TO NECROSIS AND MINERALIZATION .....  
KIDNEY ..... NOT SPECIFIED(TRACE)  
-PROGRESSIVE RENAL DISEASE .....  
UTERUS ..... THE UTERINE LUMEN IS DILATED BUT NO HISTOLOGIC EVIDENCE OF A POLYP IS PRESENT.  
-DILATATION OF THE UTERINE LUMEN (HYDROMETRA) ..... NOT SPECIFIED (PRESENT)  
CECUM ..... TISSUE IS MISSING  
MAMMARY GLANDS .....

Appendix J (cont.): PATHOLOGY INDIVIDUAL ANIMAL DATA

LETTERMAN ARMY INSTITUTE OF RESEARCH  
DIV OF RES SUPP, PATH SERV GP  
SPECIES: RAT/FISCHER-344

INDIVIDUAL ANIMAL DATA REPORT  
STUDY NUMBER: GLP83009  
STUDY START DATE: 23-JAN-84

PRINTED: 21-NOV-89  
PAGE: 593

STUDY TYPE: CHRONIC/2 YR CARCINOGENIC

ANIMAL NUMBER: 300/PRETEST=  
DATE OF DEATH: 07-FEB-86

300 SEX: FEMALE  
STUDY DAY OF DEATH: 747

DOSE GROUP: 2  
STUDY WEEK OF DEATH: 107

SACRIFICE STATUS: FINAL SACRIFICE  
TERMINAL BODY WEIGHT: 270.00 (GMS)

TISSUE / HISTOPATHOLOGIC FINDINGS

<< M I C R O S C O P I C T I S S U E O B S E R V A T I O N S >>

DISTRIBUTION (SEVERITY) / SPECIAL COMMENTS

MAMMARY GLANDS

-HYPERPLASIA AND/OR HYPERTROPHY OF THE ACINAR TISSUE  
-DILATATION (ECTASIA) OF DUCTS AND DUCTULES

NOT SPECIFIED(MILD)  
NOT SPECIFIED (PRESENT)

NOSE/TURBINATES

-MIXED INFLAMMATORY CELL INFILTRATION, NASAL CAVITY, SINUSES,  
TURBINATES, NASO-LACRIMAL DUCTS

CELLULAR INFILTRATE NOTED ADJACENT NASO-LACRIMAL DUCT.  
NOT SPECIFIED(MILD)

PITUITARY GLAND

-B- ADENOMA  
-CYST(S)

(PRESENT)  
NOT SPECIFIED (PRESENT)

DIAPHRAGM

-COMPOUND RELATED INFLAMMATORY REACTION

MISCELLANEOUS TISSUE  
NOT SPECIFIED (PRESENT)

Appendix J (cont.): PATHOLOGY INDIVIDUAL ANIMAL DATA

LETTERMAN ARMY INSTITUTE OF RESEARCH  
 DIV OF RES SUPP, PATH SERV GP  
 SPECIES: RAT/FISCHER-344  
 STUDY NUMBER: GLP83009  
 STUDY START DATE: 23-JAN-84  
 PRINTED: 21-NOV-89  
 PAGE: 594  
 STUDY TYPE: CHRONIC/2 YR CARCINOGENIC

ANIMAL NUMBER: 301/PRETEST= 301 SEX: FEMALE DOSE GROUP: 2 SACRIFICE STATUS: FINAL SACRIFICE  
 DATE OF DEATH: 07-FEB-86 STUDY DAY OF DEATH: 747 STUDY WEEK OF DEATH: 107 TERMINAL BODY WEIGHT: 267.00 (GMS)

ORGAN NAME << GROSS ORGAN OBSERVATIONS >>  
 SEVERITY GROSS FREE-TEXT COMMENTS  
 PANCREAS GROWTH(S) / PHRASES PRESENT .5CM, FOCAL  
 PITUITARY GLAND ENLARGED PRESENT .25CM, DARK RED.

TISSUE / HISTOPATHOLOGIC FINDINGS << MICROSCOPIC TISSUE OBSERVATIONS >>  
 DISTRIBUTION (SEVERITY) / SPECIAL COMMENTS

PARATHYROID ..... TISSUE IS MISSING

HEART .....  
 -CARDIOMYOPATHY ..... NOT SPECIFIED(TRACE)  
 -MEDIAL HYPERTROPHY OF MUSCULAR ARTERIES ..... NOT SPECIFIED(TRACE)

LUNGS .....  
 -MINERALIZATION OF PULMONARY ARTERIES ..... NOT SPECIFIED(TRACE)

LYMPH NODES .....  
 -RED BLOOD CELLS, HEOSIDERIN AND/OR ERYTHROPHAGOCYTOSIS WITHIN MEDULLARY SINUSES ..... REACTIVE HYPERPLASIA NOTED IN CERVICAL NODE. RBC'S AND PIGMENT NOTED IN MEDIASTINAL NODE.  
 -REACTIVE HYPERPLASIA ..... NOT SPECIFIED (PRESENT)

LIVER .....  
 -COMPOUND RELATED INFLAMMATORY REACTION ..... NOT SPECIFIED (PRESENT)  
 -BILE DUCTULE EPITHELIAL HYPERPLASIA AND/OR CHOLANGIOFIBROSIS ..... NOT SPECIFIED(MILD)  
 -HEPATITIS ..... MULTI-FOCAL(MILD)  
 -HEPATOCTYCE COALESCING MICROVESICULAR (FATTY) CHANGE LEADING TO NECROSIS AND MINERALIZATION ..... MULTI-FOCAL(MILD)

KIDNEY .....  
 -PROGRESSIVE RENAL DISEASE ..... NOT SPECIFIED(TRACE)  
 PANCREAS ..... NOT SPECIFIED(TRACE)

Appendix J (cont.): PATHOLOGY INDIVIDUAL ANIMAL DATA

LETTERMAN ARMY INSTITUTE OF RESEARCH  
 DIV OF RES SUPP, PATH SERV GP  
 SPECIES: RAT/FISCHER-344

INDIVIDUAL ANIMAL DATA REPORT  
 STUDY NUMBER: GLP83009

STUDY START DATE: 23-JAN-84

PRINTED: 21-NOV-89  
 PAGE: 595

STUDY TYPE: CHRONIC/2 YR CARCINOGENIC

ANIMAL NUMBER: 301/PRETEST# 301 SEX: FEMALE DOSE GROUP: 2 SACRIFICE STATUS: FINAL SACRIFICE  
 DATE OF DEATH: 07-FEB-86 STUDY DAY OF DEATH: 747 STUDY WEEK OF DEATH: 107 TERMINAL BODY WEIGHT: 267.00 (GMS)

←← MICROSCOPIC TISSUE OBSERVATIONS →→

TISSUE / HISTOPATHOLOGIC FINDINGS  
 DISTRIBUTION (SEVERITY) / SPECIAL COMMENTS

PANCREAS ..... (PRESENT)  
 -B- ISLET CELL ADENOMA

RECTUM ..... TISSUE IS MISSING

MAMMARY GLANDS ..... NOT SPECIFIED(MILD)  
 -HYPERPLASIA AND/OR HYPERTROPHY OF THE ACINAR TISSUE

ADRENAL ..... NOT SPECIFIED(TRACE)  
 - FOCUS OF CELLULAR ALTERATION, VACUOLATED

PITUITARY GLAND ..... (PRESENT)  
 -B- ADENOMA

EYES & OPTIC N. .... NOT SPECIFIED(TRACE)  
 -RETINAL ATROPHY AND/OR DEGENERATION, UNILATERAL OR BILATERAL

DIAPHRAGM ..... MISCELLANEOUS TISSUE  
 -COMPOUND RELATED INFLAMMATORY REACTION ..... NOT SPECIFIED (PRESENT)

Appendix J (cont.): PATHOLOGY INDIVIDUAL ANIMAL DATA

LETTERMAN ARMY INSTITUTE OF RESEARCH  
DIV OF RES SUPP, PATH SERV GP  
SPECIES: RAT/FISCHER-344

INDIVIDUAL ANIMAL DATA REPORT  
STUDY NUMBER: GLP63009

PRINTED: 21-NOV-89  
PAGE: 596

STUDY START DATE: 23-JAN-84

STUDY TYPE: CHRONIC/2 YR CARCINOGENIC

ANIMAL NUMBER: 302/PRETEST=  
DATE OF DEATH: 07-FEB-86

302 SEX: FEMALE  
STUDY DAY OF DEATH: 747

DOSE GROUP: 2  
STUDY WEEK OF DEATH: 107

SACRIFICE STATUS: FINAL SACRIFICE  
TERMINAL BODY WEIGHT: 255.00 (GMS)

ORGAN NAME  
KEYWORDS / PHRASES  
GRANULAR SURFACE  
ADHESION(S)  
ENLARGED  
PITUITARY GLAND

SEVERITY  
GROSS FREE-TEXT COMMENTS  
PRESENT BILATERAL.  
PRESENT DIAPHRAGM  
PRESENT .9 X .4CM, DARK RED.

<< MICROSCOPIC TISSUE  
DISTRIBUTION (SEVERITY) / SPECIAL COMMENTS

>>  
>>

BRAIN  
-I-PITUITARY TUMOR INVASION

(PRESENT)

THYROID GLANDS  
-PARA-FOLLICULAR CELL HYPERPLASIA ("C" CELL, LIGHT CELL)

NOT SPECIFIED(TRACE)

HEART  
-CARDIOMYOPATHY

NOT SPECIFIED(MILD)

LUNGS  
-MINERALIZATION OF PULMONARY ARTERIES

NOT SPECIFIED(TRACE)

LYMPH NODES

REACTIVE HYPERPLASIA NOTED IN CERVICAL NODES.  
REACTIVE HYPERPLASIA AND DILATED MEDULLARY SINUSES ARE PRESENT  
IN MESENTERIC NODES.

NOT SPECIFIED (PRESENT)

NOT SPECIFIED (PRESENT)

-REACTIVE HYPERPLASIA

-DILATED AND/OR CYSTIC MEDULLARY SINUSES

LIVER

-COMPOUND RELATED INFLAMMATORY REACTION

-FOCUS OF CELLULAR ALTERATION - BASOPHILIC

-HEPATOCTYIC VACUOLIZATION

-TELANGIECTASIS

NOT SPECIFIED (PRESENT)

MULTI-FOCAL(MILD)

MULTI-FOCAL(TRACE)

FOCAL(TRACE)

KIDNEY

Appendix J (cont.): PATHOLOGY INDIVIDUAL ANIMAL DATA

LETTERMAN ARMY INSTITUTE OF RESEARCH  
 DIV OF RES SUPP, PATH SERV GP  
 SPECIES: RAT/FISCHER-344  
 ANIMAL NUMBER: 302/PRETEST-  
 DATE OF DEATH: 07-FEB-86  
 TISSUE / HISTOPATHOLOGIC FINDINGS

INDIVIDUAL ANIMAL DATA REPORT  
 STUDY NUMBER: GLP83009  
 STUDY START DATE: 23-JAN-84  
 302 SEX: FEMALE DOSE GROUP: 2  
 STUDY DAY OF DEATH: 747  
 SACRIFICE STATUS: FINAL SACRIFICE  
 STUDY WEEK OF DEATH: 107  
 TERMINAL BODY WEIGHT: 255.00 (GMS)

<< M I C R O S C O P I C T I S S U E O B S E R V A T I O N S >>  
 DISTRIBUTION (SEVERITY) / SPECIAL COMMENTS

PRINTED: 21-NOV-89  
PAGE: 597

STUDY TYPE: CHRONIC/2 YR CARCINOGENIC

KIDNEY ..... NOT SPECIFIED(MODERATE)  
 -PROGRESSIVE RENAL DISEASE

UTERUS ..... NOT SPECIFIED(TRACE)  
 -LYMPHOCYtic INFILTRATE

CECUM ..... TISSUE IS MISSING

MAMMARY GLANDS .....  
 -HYPERPLASIA AND/OR HYPERTROPHY OF THE ACIMAR TISSUE  
 -DILATATION (ECTASIA) OF DUCTS AND DUCTULES

NOSE/TURBINATES ..... CELLULAR INFILTRATE IS ADJACENT TO NASO-LACRIMAL DUCT.  
 -MIXED INFLAMMATORY CELL INFILTRATION, NASAL CAVITY, SINUSES,  
 TURBINATES, NASO-LACRIMAL DUCTS

PITUITARY GLAND ..... (PRESENT)  
 -B- ADENOMA

EYES & OPTIC N. .... NOT SPECIFIED(TRACE)  
 -CORNEAL VASCULARIZATION

DIAPHRAGM ..... MISCELLANEOUS TISSUE  
 -COMPOUND RELATED INFLAMMATORY REACTION

Appendix J (cont.): PATHOLOGY INDIVIDUAL ANIMAL DATA

LETTERMAN ARMY INSTITUTE OF RESEARCH  
DIV OF RES SUPP, PATH SERV GP  
SPECIES: RAT/FISCHER-344

INDIVIDUAL ANIMAL DATA REPORT  
STUDY NUMBER: GLP83009

PRINTED: 21-NOV-89  
PAGE: 598

STUDY START DATE: 23-JAN-84

STUDY TYPE: CHRONIC/2 YR CARCINOGENIC

ANIMAL NUMBER: 303/PRETEST= 303 SEX: FEMALE DOSE GROUP: 2 SACRIFICE STATUS: FINAL SACRIFICE

DATE OF DEATH: 10-FEB-86 STUDY DAY OF DEATH: 750 STUDY WEEK OF DEATH: 108 TERMINAL BODY WEIGHT: 256.00 (GMS)

ORGAN NAME << GROSS ORGAN OBSERVATIONS >> SEVERITY GROSS FREE-TEXT COMMENTS

LIVER KEYWORDS / PHRASES PRESENT VENTRAL ABDOMINAL WALL

PITUITARY GLAND ADHESION(S) PRESENT BLACK, .1CM DIAMETER

DISCOLORATION DISCOLORATION

TISSUE / HISTOPATHOLOGIC FINDINGS << MICROSCOPIC TISSUE OBSERVATIONS >> DISTRIBUTION (SEVERITY) / SPECIAL COMMENTS

THYROID GLANDS NOT SPECIFIED (TRACE)

-PARA-FOLLICULAR CELL HYPERPLASIA ("C" CELL, LIGHT CELL) NOT SPECIFIED (MODERATE)

LACRIMAL GLAND NOT SPECIFIED (MILD)

-ATROPHY AND/OR LOSS OF ACINAR TISSUE NOT SPECIFIED (TRACE)

HEART NOT SPECIFIED (MILD)

-CARDIOMYOPATHY NOT SPECIFIED (TRACE)

-MEDIAL HYPERTROPHY OF MUSCULAR ARTERIES

LYMPH NODES REACTIVE HYPERPLASIA NOTED IN CERVICAL NODES.

-RED BLOOD CELLS, HEMOSIDERIN AND/OR ERYTHROPHAGOCYTOSIS WITHIN

REACTIVE HYPERPLASIA, RBC'S AND PIGMENT NOTED IN MEDIASTINAL

REACTIVE HYPERPLASIA, RBC'S, PIGMENT AND DILATED

REACTIVE HYPERPLASIA

-DILATED AND/OR CYSTIC MEDULLARY SINUSES

REACTIVE HYPERPLASIA

REACTIVE HYPERPLASIA

REACTIVE HYPERPLASIA

REACTIVE HYPERPLASIA

REACTIVE HYPERPLASIA

REACTIVE HYPERPLASIA

REACTIVE HYPERPLASIA

REACTIVE HYPERPLASIA

REACTIVE HYPERPLASIA

REACTIVE HYPERPLASIA

REACTIVE HYPERPLASIA

REACTIVE HYPERPLASIA

REACTIVE HYPERPLASIA

REACTIVE HYPERPLASIA

REACTIVE HYPERPLASIA

REACTIVE HYPERPLASIA

REACTIVE HYPERPLASIA

REACTIVE HYPERPLASIA

REACTIVE HYPERPLASIA

REACTIVE HYPERPLASIA

REACTIVE HYPERPLASIA

REACTIVE HYPERPLASIA

REACTIVE HYPERPLASIA



Appendix J (cont.): PATHOLOGY INDIVIDUAL ANIMAL DATA

LETTERMAN ARMY INSTITUTE OF RESEARCH  
DIV OF RES SUPP, PATH SERV GP  
SPECIES: RAT/FISCHER-344

INDIVIDUAL ANIMAL DATA REPORT  
STUDY NUMBER: GLP83009

PRINTED: 21-NOV-89  
PAGE: 599

STUDY START DATE: 23-JAN-84

STUDY TYPE: CHRONIC/2 YR CARCINOGENIC

ANIMAL NUMBER: 303/PRETEST-  
DATE OF DEATH: 10-FEB-86

303 SEX: FEMALE  
STUDY DAY OF DEATH: 750

DOSE GROUP: 2  
STUDY WEEK OF DEATH: 108

SACRIFICE STATUS: FINAL SACRIFICE  
TERMINAL BODY WEIGHT: 256.00 (GMS)

<< MICROSCOPIC TISSUE  
DISTRIBUTION (SEVERITY) / SPECIAL COMMENTS

OBSERVATIONS >>

KIDNEY

-PROGRESSIVE RENAL DISEASE

NOT SPECIFIED (TRACE)

UTERUS

-CYSTIC DILATATION OF THE ENDOMETRIAL GLANDS

NOT SPECIFIED (PRESENT)

SCIATIC NERVE

TISSUE IS MISSING

MAMMARY GLANDS

NO MAMMARY TISSUE IS PRESENT ON SLIDE #15. DIAGNOSIS OF MAMMARY ACINAR HYPERPLASIA AND DILATED DUCTS WAS MADE ON MAMMARY TISSUE IN SECTIONS 4 AND 13.

-HYPERPLASIA AND/OR HYPERTROPHY OF THE ACINAR TISSUE  
-DILATATION (ECTASIA) OF DUCTS AND DUCTULES

NOT SPECIFIED (MILD)  
NOT SPECIFIED (PRESENT)

EYES & OPTIC N.

-METAPLASTIC BONE FORMATION AND/OR MINERALIZATION, SCLERA

NOT SPECIFIED (PRESENT)

Appendix J (cont.): PATHOLOGY INDIVIDUAL ANIMAL DATA

LETTERMAN ARMY INSTITUTE OF RESEARCH
DIV OF RES SUPP, PATH SERV GP
SPECIES: RAT/FISCHER-344
ANIMAL NUMBER: 304/PRETEST=
DATE OF DEATH: 10-FEB-86
STUDY START DATE: 23-JAN-84
STUDY NUMBER: GLP83009
STUDY TYPE: CHRONIC/2 YR CARCINOGENIC
INDIVIDUAL ANIMAL DATA REPORT
DOSE GROUP: 2
SACRIFICE STATUS: FINAL SACRIFICE
DOSE SEX: FEMALE
STUDY WEEK OF DEATH: 108
TERMINAL BODY WEIGHT: 261.00 (GMS)

ORGAN NAME
LIVER
KIDNEY
SPLEEN
PITUITARY GLAND
GROSS ORGAN OBSERVATIONS
KEYWORDS / PHRASES
ADHESION(S)
DISCOLORATION
ENLARGED (SPLENOMEGALY)
ENLARGED
PRESENT DIAPHRAGM
PRESENT GREEN/BROWN
MARKED 6.5 X 1.75CM
PRESENT DARK RED, .4CM DIAMETER
SEVERITY GROSS FREE-TEXT COMMENTS

TISSUE / HISTOPATHOLOGIC FINDINGS
MICROSCOPIC TISSUE OBSERVATIONS
DISTRIBUTION (SEVERITY) / SPECIAL COMMENTS

HEART
-CARDIOMYOPATHY
NOT SPECIFIED(MILD)

LUNGS
-MINERALIZATION OF PULMONARY ARTERIES
-N- LARGE GRANULAR LYMPHOCYTE LEUKEMIA, METASTATIC
-ALVEOLAR HEMORRHAGE
NOT SPECIFIED(TRACE)
(PRESENT)
NOT SPECIFIED (PRESENT)

SPLEEN
-N- LARGE GRANULAR LYMPHOCYTE LEUKEMIA, METASTATIC
(PRESENT)

LYMPH NODES
-N- LARGE GRANULAR LYMPHOCYTE LEUKEMIA, METASTATIC
LGLL IS PRESENT IN CERVICAL, MEDIASTINAL AND MESENTERIC NODES.
(PRESENT)

LIVER
-COMPOUND RELATED INFLAMMATORY REACTION
-BILE DUCTULE EPITHELIAL HYPERPLASIA AND/OR CHOLANGIOFIBROSIS
-FOCUS OF CELLULAR ALTERATION - BASOPHILIC
-NECROSIS
-N- LARGE GRANULAR LYMPHOCYTE LEUKEMIA, METASTATIC
NOT SPECIFIED (PRESENT)
NOT SPECIFIED(MILD)
MULTI-FOCAL(TRACE)
NOT SPECIFIED(MILD)
(PRESENT)

KIDNEY
-PROGRESSIVE RENAL DISEASE
NOT SPECIFIED(TRACE)

PANCREAS

Appendix J (cont.): PATHOLOGY INDIVIDUAL ANIMAL DATA

LETTERMAN ARMY INSTITUTE OF RESEARCH  
 DIV OF RES SUPP, PATH SERV GP  
 SPECIES: RAT/FISCHER-344  
 STUDY START DATE: 23-JAN-84  
 ANIMAL NUMBER: 304/PRETEST# 304 SEX: FEMALE DOSE GROUP: 2 SACRIFICE STATUS: FINAL SACRIFICE  
 DATE OF DEATH: 10-FEB-86 STUDY DAY OF DEATH: 750 STUDY WEEK OF DEATH: 108 TERMINAL BODY WEIGHT: 261.00 (GMS)  
 STUDY TYPE: CHRONIC/2 YR CARCINOGENIC  
 TISSUE / HISTOPATHOLOGIC FINDINGS << MICROSCOPIC TISSUE OBSERVATIONS >>  
 DISTRIBUTION (SEVERITY) / SPECIAL COMMENTS

PRINTED: 21-NOV-89  
 PAGE: 601

PANCREAS ..... MULTI-FOCAL(TRACE)  
 -ACINAR (EXOCRINE) ATROPHY (PRESENT)  
 -B- ISLET CELL ADENOMA  
 MAMMARY GLANDS ..... NOT SPECIFIED(MILD)  
 -HYPERPLASIA AND/OR HYPERTROPHY OF THE ACINAR TISSUE  
 NOSE/TURBINATES ..... ACUTE AND SUBACUTE INFLAMMATION INVOLVES PRIMARILY THE  
 -ACUTE INFLAMMATION NASO-LACRIMAL DUCT.  
 -SUBACUTE INFLAMMATION NOT SPECIFIED(MILD)  
 NOT SPECIFIED(MILD)  
 PITUITARY GLAND ..... (PRESENT)  
 -B- ADENOMA  
 EYES & OPTIC N. .... NOT SPECIFIED(MILD)  
 -CHRONIC CONJUNCTIVITIS  
 WHOLE BODY ..... (PRESENT)  
 -M- LARGE GRANULAR LYMPHOCTIC LEUKEMIA  
 DIAPHRAGM ..... MISCELLANEOUS TISSUE  
 -COMPOUND RELATED INFLAMMATORY REACTION NOT SPECIFIED (PRESENT)

Appendix J (cont.): PATHOLOGY INDIVIDUAL ANIMAL DATA

LETTERMAN ARMY INSTITUTE OF RESEARCH  
DIV OF RES SUPP, PATH SERV GP  
SPECIES: RAT/FISCHER-344  
STUDY NUMBER: GLP83009  
STUDY START DATE: 23-JAN-84  
PRINTED: 21-NOV-89  
PAGE: 602  
STUDY TYPE: CHRONIC/2 YR CARCINOGENIC

ANIMAL NUMBER: 305/PRETEST= 305 SEX: FEMALE DOSE GROUP: 2 SACRIFICE STATUS: FINAL SACRIFICE  
DATE OF DEATH: 10-FEB-86 STUDY DAY OF DEATH: 750 STUDY WEEK OF DEATH: 108 TERMINAL BODY WEIGHT: 253.00 (GMS)

ORGAN NAME << GROSS ORGAN OBSERVATIONS >>  
KEYWORDS / PHRASES SEVERITY GROSS FREE-TEXT COMMENTS  
ADHESION(S) PRESENT VENTRAL ABDOMINAL WALL

TISSUE / HISTOPATHOLOGIC FINDINGS << MICROSCOPIC TISSUE OBSERVATIONS >>  
DISTRIBUTION (SEVERITY) / SPECIAL COMMENTS

THYROID GLANDS  
-PARA-FOLLICULAR CELL HYPERPLASIA (MC CELL, LIGHT CELL) NOT SPECIFIED (TRACE)

HEART  
-CARDIOMYOPATHY NOT SPECIFIED (TRACE)

SPLEEN  
-INFARCTION, CHRONIC NOT SPECIFIED (MILD)

LIVER  
-COMPOUND RELATED INFLAMMATORY REACTION NOT SPECIFIED (PRESENT)  
-BILE DUCTULE EPITHELIAL HYPERPLASIA AND/OR CHOLANGIOFIBROSIS NOT SPECIFIED (TRACE)  
-HEPATITIS MULTI-FOCAL (MILD)  
-HEPATOCYTE COALESCING MICROVESICULAR (FATTY) CHANGE LEADING TO MULTI-FOCAL (MILD)  
NECROSIS AND MINERALIZATION

KIDNEY  
-PROGRESSIVE RENAL DISEASE NOT SPECIFIED (MILD)

PANCREAS  
-ACINAR (EXOCRINE) ATROPHY NOT SPECIFIED (MODERATE)

MAMMARY GLANDS  
-HYPERPLASIA AND/OR HYPERTROPHY OF THE ACINAR TISSUE NOT SPECIFIED (MODERATE)  
-DILATATION (ECTASIA) OF DUCTS AND DUCTULES NOT SPECIFIED (PRESENT)

Appendix J (cont.): PATHOLOGY INDIVIDUAL ANIMAL DATA

LETTERMAN ARMY INSTITUTE OF RESEARCH  
DIV OF RES SUPP, PATH SERV GP  
SPECIES: RAT/FISCHER-344

INDIVIDUAL ANIMAL DATA REPORT  
STUDY NUMBER: GLP83009

PRINTED: 21-NOV-89  
PAGE: 603

STUDY START DATE: 23-JAN-84

STUDY TYPE: CHRONIC/2 YR CARCINOGENIC

ANIMAL NUMBER: 305/PRETEST

305 SEX: FEMALE

DOSE GROUP: 2

SACRIFICE STATUS: FINAL SACRIFICE

DATE OF DEATH: 10-FEB-86

STUDY DAY OF DEATH: 750

STUDY WEEK OF DEATH: 108

TERMINAL BODY WEIGHT: 253.00 (GMS)

<< M I C R O S C O P I C T I S S U E O B S E R V A T I O N S >>  
TISSUE / HISTOPATHOLOGIC FINDINGS

DISTRIBUTION (SEVERITY) / SPECIAL COMMENTS

MOSE/TURBINATES ..... CELLULAR INFILTRATE NOTED ADJACENT TO NASO-LACRIMAL DUCTS.  
-MIXED INFLAMMATORY CELL INFILTRATION, NASAL CAVITY, SINUSES, NOT SPECIFIED(MILD)  
TURBINATES, NASO-LACRIMAL DUCTS

PITUITARY GLAND ..... NOT SPECIFIED (PRESENT)  
-CYST(S)

Appendix J (cont.): PATHOLOGY INDIVIDUAL ANIMAL DATA

LETTERMAN ARMY INSTITUTE OF RESEARCH  
DIV OF RES SUPP, PATH SERV GP  
SPECIES: RAT/FISCHER-344

INDIVIDUAL ANIMAL DATA REPORT  
STUDY NUMBER: GLP83009  
STUDY START DATE: 23-JAN-84

PRINTED: 21-NOV-89  
PAGE: 604

STUDY TYPE: CHRONIC/2 YR CARCINOGENIC

ANIMAL NUMBER: 306/PRETEST= 306 SEX: FEMALE DOSE GROUP: 2 SACRIFICE STATUS: FINAL SACRIFICE  
DATE OF DEATH: 10-FEB-86 STUDY DAY OF DEATH: 751 STUDY WEEK OF DEATH: 108 TERMINAL BODY WEIGHT: 300.00 (GMS)

ORGAN NAME << GROSS ORGAN OBSERVATIONS >>  
KEYWORDS / PHRASES SEVERITY GROSS FREE-TEXT COMMENTS  
ADHESION(S) PRESENT DIAPHRAGM

TISSUE / HISTOPATHOLOGIC FINDINGS << MICROSCOPIC TISSUE OBSERVATIONS >>  
DISTRIBUTION (SEVERITY) / SPECIAL COMMENTS

SALIVARY GLAND ..... THERE IS A SMALL ADENOMA, PROBABLY OF MAMMARY ORIGIN, IN THE  
ADIPOSE CONNECTIVE TISSUE ADJACENT TO THE PAROTID GLAND. SEE  
MAMMARY GLAND FOR DIAGNOSIS AND COMMENT.

HEART ..... NOT SPECIFIED(TRACE)  
-CARDIOMYOPATHY

LYMPH NODES ..... RBC'S AND PIGMENT PRESENT IN MEDIASTINAL NODES.  
-RED BLOOD CELLS, MEMOSIDERIN AND/OR ERYTHROPHAGOCYTOSIS WITHIN  
MEDULLARY SINUSES NOT SPECIFIED (PRESENT)

LIVER ..... NOT SPECIFIED (PRESENT)  
-COMPOUND RELATED INFLAMMATORY REACTION NOT SPECIFIED(TRACE)  
-BILE DUCTULE EPITHELIAL HYPERPLASIA AND/OR CHOLANGIOFIBROSIS MULTI-FOCAL(TRACE)  
-HEPATITIS FOCAL(TRACE)  
-NECROSIS NOT SPECIFIED(MILD)  
-HEPATOCTYCE COALESCING MICROVESICULAR (FATTY) CHANGE LEADING TO  
NECROSIS AND MINERALIZATION

KIDNEY ..... NOT SPECIFIED(TRACE)  
-PROGRESSIVE RENAL DISEASE

UTERUS ..... NOT SPECIFIED (PRESENT)  
-ENDOMETRIAL STROMAL POLYP

OVARIES ..... NOT SPECIFIED (PRESENT)  
-FOLLICULAR CYST(S)

PANCREAS

Appendix J (cont.): PATHOLOGY INDIVIDUAL ANIMAL DATA

LETTERMAN ARMY INSTITUTE OF RESEARCH  
DIV OF RES SUPP, PATH SERV GP  
SPECIES: RAT/FISCHER-344

INDIVIDUAL ANIMAL DATA REPORT  
STUDY NUMBER: GLP83009  
STUDY START DATE: 23-JAN-84

PRINTED: 21-NOV-89  
PAGE: 605  
STUDY TYPE: CHRONIC/2 YR CARCINOGENIC

ANIMAL NUMBER: 306/PRETEST# 306 SEX: FEMALE DOSE GROUP: 2 SACRIFICE STATUS: FINAL SACRIFICE  
DATE OF DEATH: 10-FEB-86 STUDY DAY OF DEATH: 750 STUDY WEEK OF DEATH: 108 TERMINAL BODY WEIGHT: 300.00 (GMS)

<< MICROSCOPIC TISSUE OBSERVATIONS >>  
TISSUE / HISTOPATHOLOGIC FINDINGS

PANCREAS ..... NOT SPECIFIED (TRACE)  
-ACINAR (EXOCRINE) ATROPHY .....  
MAMMARY GLANDS ..... A SMALL ADENOMA, PROBABLY OF MAMMARY ORIGIN, IS SITUATED IN THE  
ADIPOSE CONNECTIVE TISSUE ADJACENT THE PAROTID GLAND IN SECTION #4.  
-HYPERPLASIA AND/OR HYPERTROPHY OF THE ACINAR TISSUE ..... NOT SPECIFIED (MILD)  
-B- FIBROADENOMA ..... (PRESENT)  
-DILATATION (ECTASIA) OF DUCTS AND DUCTULES ..... NOT SPECIFIED (PRESENT)  
NOSE/TURBINATES ..... CELLULAR INFILTRATE IS ADJACENT NASO-LACRIMAL DUCT.  
-MIXED INFLAMMATORY CELL INFILTRATION, NASAL CAVITY, SINUSES, ..... NOT SPECIFIED (MILD)  
TURBINATES, NASO-LACRIMAL DUCTS .....  
ADRENAL ..... NOT SPECIFIED (PRESENT)  
-CORTICAL MODULAR HYPERPLASIA .....  
PITUITARY GLAND ..... NOT SPECIFIED (PRESENT)  
-CYST(S) .....

Appendix J (cont.): PATHOLOGY INDIVIDUAL ANIMAL DATA

LETTERMAN ARMY INSTITUTE OF RESEARCH  
DIV OF RES SUPP, PATH SERV GP  
SPECIES: RAT/FISCHER-344

INDIVIDUAL ANIMAL DATA REPORT  
STUDY NUMBER: GLP83009

PRINTED: 21-NOV-89  
PAGE: 606

STUDY START DATE: 23-JAN-84

STUDY TYPE: CHRONIC/2 YR CARCINOGENIC

ANIMAL NUMBER: 307/PRETEST= 307 SEX: FEMALE DOSE GROUP: 2 SACRIFICE STATUS: FOUND DEAD  
DATE OF DEATH: 23-NOV-85 STUDY DAY OF DEATH: 671 STUDY WEEK OF DEATH: 96 TERMINAL BODY WEIGHT: 268.00 (GMS)

ORGAN NAME SEVERITY GROSS FREE-TEXT COMMENTS  
KEYWORDS / PHRASES OBSERVATIONS

WHOLE BODY POST MORTEM AUTOLYSIS. MODERATE  
SPLEEN ENLARGED (SPLENOHEGALY) MARKED  
LIVER ENLARGED PRESENT  
EYES & OPTIC N. CORNEAL OPACITY PRESENT  
6 X 2 X 1.5CM

TISSUE / HISTOPATHOLOGIC FINDINGS  
<< MICROSCOPIC TISSUE OBSERVATIONS >>  
DISTRIBUTION (SEVERITY) / SPECIAL COMMENTS

THYROID GLANDS TISSUE IS MISSING

PARATHYROID TISSUE IS MISSING

HEART NOT SPECIFIED (TRACE)  
-CARDIOMYOPATHY

LUNGS (PRESENT)  
-N- LARGE GRANULAR LYMPHOCYTE LEUKEMIA, METASTATIC

SPLEEN (PRESENT)  
-N- LARGE GRANULAR LYMPHOCYTE LEUKEMIA, METASTATIC

LYMPH NODES REACTIVE HYPERPLASIA PRESENT IN CERVICAL NODE.  
LGLL IS PRESENT IN A MEDIASTINAL NODE IN SECTION #8 ADJACENT TO  
THE LUNG AND IN MESENTERIC NODES ON SECTION #7.  
(PRESENT)  
NOT SPECIFIED (PRESENT)

LIVER NOT SPECIFIED (PRESENT)  
-COMPOUND RELATED INFLAMMATORY REACTION NOT SPECIFIED (TRACE)  
-BILE DUCTULE EPITHELIAL HYPERPLASIA AND/OR CHOLANGIOFIBROSIS  
-FOCUS OF CELLULAR ALTERATION - BASOPHILIC MULTI-FOCAL (MILD)  
-HEPATOCTYIC DEGENERATIVE CHANGES (NON-NECROTIC) NOT SPECIFIED (MILD)



Appendix J (cont.): PATHOLOGY INDIVIDUAL ANIMAL DATA

LETTERMAN ARMY INSTITUTE OF RESEARCH  
 DIV OF RES SUPP, PATH SERV GP  
 SPECIES: RAT/FISCHER-344  
 STUDY START DATE: 23-JAN-84  
 STUDY NUMBER: GLP83009  
 STUDY TYPE: CHRONIC/2 YR CARCINOGENIC  
 ANIMAL NUMBER: 307/PRETEST-  
 DATE OF DEATH: 23-NOV-85  
 SEX: FEMALE  
 DOSE GROUP: 2  
 SACRIFICE STATUS: FOUND DEAD  
 STUDY WEEK OF DEATH: 671  
 TERMINAL BODY WEIGHT: 268.00 (GMS)  
 << MICROSCOPIC TISSUE OBSERVATIONS >>  
 TISSUE / HISTOPATHOLOGIC FINDINGS  
 DISTRIBUTION (SEVERITY) / SPECIAL COMMENTS

PRINTED: 21-NOV-89  
 PAGE: 607

LIVER .....  
 -M- LARGE GRANULAR LYMPHOCYTE LEUKEMIA, METASTATIC ..... (PRESENT)  
 KIDNEY .....  
 -PROGRESSIVE RENAL DISEASE ..... NOT SPECIFIED(TRACE)  
 UTERUS .....  
 -M- LARGE GRANULE LYMPHOCYTE LEUKEMIA, METASTATIC ..... (PRESENT)  
 OVARIES .....  
 -M- LARGE GRANULE LYMPHOCYTE LEUKEMIA, METASTATIC ..... (PRESENT)  
 DUODENUM ..... TISSUE IS AUTOLYTIC  
 JEJUNUM ..... TISSUE IS AUTOLYTIC  
 ILEUM ..... TISSUE IS AUTOLYTIC  
 CECUM ..... TISSUE IS AUTOLYTIC  
 RECTUM ..... TISSUE IS AUTOLYTIC  
 COLON ..... TISSUE IS AUTOLYTIC  
 MAMMARY GLANDS .....  
 -HYPERPLASIA AND/OR HYPERTROPHY OF THE ACINAR TISSUE ..... NOT SPECIFIED(MILD)  
 -DILATATION (ECTASIA) OF DUCTS AND DUCTULES ..... NOT SPECIFIED (PRESENT)  
 BONE, STERNUM ..... TISSUE IS MISSING  
 EYES & OPTIC N. .... IT IS NOT POSSIBLE TO EVALUATE THE RETINA OR OTHER INTRAOCULAR  
 STRUCTURES OTHER THAN THE LENS BECAUSE OF AUTOLYTIC CHANGE.  
 -CORNEAL MINERALIZATION ..... NOT SPECIFIED(TRACE)

Appendix J (cont.): PATHOLOGY INDIVIDUAL ANIMAL DATA

LETTERMAN ARMY INSTITUTE OF RESEARCH  
DIV OF RES SUPP, PATH SERV GP  
SPECIES: RAT/FISCHER-344

PRINTED: 21-NOV-89  
PAGE: 608

INDIVIDUAL ANIMAL DATA REPORT  
STUDY NUMBER: GLP83009  
STUDY START DATE: 23-JAN-84

STUDY TYPE: CHRONIC/2 YR CARCINOGENIC

ANIMAL NUMBER: 307/PRETEST= 307 SEX: FEMALE DOSE GROUP: 2 SACRIFICE STATUS: FOUND DEAD  
DATE OF DEATH: 23-NOV-85 STUDY DAY OF DEATH: 671 STUDY WEEK OF DEATH: 96 TERMINAL BODY WEIGHT: 268.00 (GMS)

<< MICROSCOPIC TISSUE OBSERVATIONS >>  
TISSUE / HISTOPATHOLOGIC FINDINGS ..... DISTRIBUTION (SEVERITY) / SPECIAL COMMENTS .....

EYES & OPTIC N. .... NOT SPECIFIED (PRESENT)  
-LENTICULAR DEGENERATIVE CHANGES COMPATIBLE WITH CATARACT .....

WHOLE BODY .....  
-W- LARGE GRANULAR LYMPHOCYTTIC LEUKEMIA ..... (PRESENT)

DIAPHRAGM ..... MISCELLANEOUS TISSUE  
-COMPOUND RELATED INFLAMMATORY REACTION ..... NOT SPECIFIED (PRESENT)

Appendix J (cont.): PATHOLOGY INDIVIDUAL ANIMAL DATA

LETTERMAN ARMY INSTITUTE OF RESEARCH  
 DIV OF RES SUPP, PATH SERV GP  
 SPECIES: RAT/FISCHER-344  
 INDIVIDUAL ANIMAL DATA REPORT  
 STUDY NUMBER: GLP83009  
 STUDY START DATE: 23-JAN-84  
 PRINTED: 21-NOV-89  
 PAGE: 609  
 STUDY TYPE: CHRONIC/2 YR CARCINOGENIC

ANIMAL NUMBER: 308/PRETEST= 308 SEX: FEMALE DOSE GROUP: 2 SACRIFICE STATUS: FINAL SACRIFICE  
 DATE OF DEATH: 10-FEB-86 STUDY DAY OF DEATH: 750 STUDY WEEK OF DEATH: 108 TERMINAL BODY WEIGHT: 267.00 (GMS)

<< GROSS ORGAN OBSERVATIONS >>  
 SEVERITY GROSS FREE-TEXT COMMENTS  
 PRESENT DIAPHRAGM, VENTRAL ABDOMINAL WALL  
 PRESENT BLACK, .1CM DIAMETER, FOCAL  
 ADHESION(S)  
 DISCOLORATION

<< MICROSCOPIC TISSUE OBSERVATIONS >>  
 DISTRIBUTION (SEVERITY) / SPECIAL COMMENTS

THYROID GLANDS ..... (PRESENT)  
 -8- PARA-FOLLICULAR CELL ADENOMA

PARATHYROID ..... TISSUE IS MISSING

EXORBITAL LACRIM ..... FOCAL(TRACE)  
 -ACIHAR ATROPHY

HEART ..... NOT SPECIFIED(MILD)  
 -CARDIOMYOPATHY

LUNGS ..... NOT SPECIFIED(TRACE)  
 -MINERALIZATION OF PULMONARY ARTERIES

THYMUS ..... TISSUE IS MISSING

LYMPH NODES ..... RBC'S AND PIGMENT NOTED IN MEDIASTINAL NODE. THE MESENTERIC  
 NODE IS MISSING.

-RED BLOOD CELLS, HEMOSIDERIN AND/OR ERYTHROPHAGOCYTOSIS WITHIN  
 MEDULLARY SINUSES NOT SPECIFIED (PRESENT)

LIVER ..... NOT SPECIFIED (PRESENT)  
 -COMPOUND RELATED INFLAMMATORY REACTION  
 -HEPATITIS MULTI-FOCAL(MODERATE)  
 -FOCUS OF CELLULAR ALTERATION - BASOPHILIC NOT SPECIFIED(TRACE)  
 -HEPATOCTYIC VACUOLIZATION MULTI-FOCAL(TRACE)

Appendix J (cont.): PATHOLOGY INDIVIDUAL ANIMAL DATA

LETTERMAN ARMY INSTITUTE OF RESEARCH  
DIV OF RES SUPP, PATH SERV GP  
SPECIES: RAT/FISCHER-344

INDIVIDUAL ANIMAL DATA REPORT  
STUDY NUMBER: GLP83009

PRINTED: 21-NOV-89  
PAGE: 610

STUDY START DATE: 23-JAN-84

STUDY TYPE: CHRONIC/2 YR CARCINOGENIC

ANIMAL NUMBER: 308/PRETEST=  
DATE OF DEATH: 10-FEB-86

308 SEX: FEMALE  
STUDY DAY OF DEATH: 750

DOSE GROUP: 2  
STUDY WEEK OF DEATH: 108

SACRIFICE STATUS: FINAL SACRIFICE  
TERMINAL BODY WEIGHT: 267.00 (GMS)

<< MICROSCOPIC TISSUE  
TISSUE / HISTOPATHOLOGIC FINDINGS

OBSERVATIONS  
DISTRIBUTION (SEVERITY) / SPECIAL COMMENTS

LIVER .....  
-HEPATOCTYCLE COALESCING MICROVESICULAR (FATTY) CHANGE LEADING TO NOT SPECIFIED(MILD)  
NECROSIS AND MINERALIZATION

KIDNEY .....  
-PROGRESSIVE RENAL DISEASE NOT SPECIFIED(TRACE)

URINARY BLADDER .....  
-CHRONIC INFLAMMATORY CELL INFILTRATION FOCAL(TRACE)

MAMMARY GLANDS .....  
-HYPERPLASIA AND/OR HYPERTROPHY OF THE ACINAR TISSUE NOT SPECIFIED(MILD)

NOSE/TURBINATES .....  
-MIXED INFLAMMATORY CELL INFILTRATION, NASAL CAVITY, SINUSES, CELLULAR INFILTRATE IS ADJACENT TO THE NASO-LACRIMAL DUCT.  
TURBINATES, NASO-LACRIMAL DUCTS NOT SPECIFIED(MILD)

ADRENAL .....  
-CORTICAL NODULAR HYPERPLASIA NOT SPECIFIED (PRESENT)

PITUITARY GLAND .....  
-CYST(S) NOT SPECIFIED (PRESENT)

DIAPHRAGM .....  
-COMPOUND RELATED INFLAMMATORY REACTION MISCELLANEOUS TISSUE  
NOT SPECIFIED (PRESENT)

Appendix J (cont.): PATHOLOGY INDIVIDUAL ANIMAL DATA

LETTERMAN ARMY INSTITUTE OF RESEARCH  
DIV OF RES SUPP, PATH SERV 6P  
SPECIES: RAT/FISCHER-344

INDIVIDUAL ANIMAL DATA REPORT  
STUDY NUMBER: GLP03009

PRINTED: 21-NOV-89  
PAGE: 611

STUDY START DATE: 23-JAN-84

STUDY TYPE: CHRONIC/2 YR CARCINOGENIC

ANIMAL NUMBER: 309/PRETEST#  
DATE OF DEATH: 01-JUL-85  
SEX: FEMALE  
DOSE GROUP: 2  
SACRIFICE STATUS: FOUND DEAD  
STUDY WEEK OF DEATH: 76  
TERMINAL BODY WEIGHT: 218.00 (GMS)

ORGAN NAME: << GROSS ORGAN OBSERVATIONS >>  
KEYWORDS / PHRASES SEVERITY GROSS FREE-TEXT COMMENTS

WHOLE BODY: POST MORTEM AUTOLYSIS. MARKED  
PERITONEAL CAV.: FLUID-FILLED PRESENT  
LIVER: ADHESION(S) PRESENT  
PERITONEAL CAV.: GROWTH(S) / MASS(ES) PRESENT  
10-15ML CLEAR PALE YELLOW ASCITIC FLUID  
DIAPHRAGM, 1CM AREA  
WHITE, NUMEROUS, RAISED, RANDOMLY DISTRIBUTED THROUGHOUT  
PERITONEAL CAVITY.

TISSUE / HISTOPATHOLOGIC FINDINGS << MICROSCOPIC TISSUE OBSERVATIONS >>  
DISTRIBUTION (SEVERITY) / SPECIAL COMMENTS

THYROID GLANDS: TISSUE IS AUTOLYTIC

HEART: NOT SPECIFIED(TRACE)  
-CARDIOMYOPATHY SECONDARY NEOPLASM FROM ORGAN ABDOMINAL CAVITY  
-N- PRESENCE OF METASTATIC NEOPLASM

LUNGS: MULTI-FOCAL(TRACE)  
-PNEUMONIA, INTERSTITIAL, CHRONIC SECONDARY NEOPLASM FROM ORGAN ABDOMINAL CAVITY  
-N- PRESENCE OF METASTATIC NEOPLASM

SPLEEN: SECONDARY NEOPLASM FROM ORGAN ABDOMINAL CAVITY  
-N- PRESENCE OF METASTATIC NEOPLASM TISSUE IS AUTOLYTIC

LYMPH NODES: TISSUE IS AUTOLYTIC

LIVER: NOT SPECIFIED(MILD)  
-BILE DUCTULE EPITHELIAL HYPERPLASIA AND/OR CHOLANGIOFIBROSIS NOT SPECIFIED (PRESENT)  
-FIBROSIS CAPSULAR NO COMPOUND SECONDARY NEOPLASM FROM ORGAN ABDOMINAL CAVITY  
-N- PRESENCE OF METASTATIC NEOPLASM

Appendix J (cont.): PATHOLOGY INDIVIDUAL ANIMAL DATA

LETTERMAN ARMY INSTITUTE OF RESEARCH  
DIV OF RES SUPP, PATH SERV GP  
SPECIES: RAT/FISCHER-344

INDIVIDUAL ANIMAL DATA REPORT  
STUDY NUMBER: GLP83009  
STUDY START DATE: 23-JAN-84

PRINTED: 21-NOV-89  
PAGE: 612  
STUDY TYPE: CHRONIC/2 YR CARCINOGENIC

ANIMAL NUMBER: 309/PRETEST= 309 SEX: FEMALE DOSE GROUP: 2 SACRIFICE STATUS: FOUND DEAD  
DATE OF DEATH: 01-JUL-85 STUDY DAY OF DEATH: 526 STUDY WEEK OF DEATH: 76 TERMINAL BODY WEIGHT: 218.00 (GMS)

TISSUE / HISTOPATHOLOGIC FINDINGS << MICROSCOPIC TISSUE OBSERVATIONS >>  
DISTRIBUTION (SEVERITY) / SPECIAL COMMENTS

- KIDNEY ..... TISSUE IS AUTOLYTIC
- URINARY BLADDER ..... TISSUE IS AUTOLYTIC
- UTERUS ..... TISSUE IS AUTOLYTIC
- OVARIES ..... SECONDARY NEOPLASM FROM ORGAN ABDOMINAL CAVITY
- W- PRESENCE OF METASTATIC NEOPLASM
- DUODENUM ..... TISSUE IS AUTOLYTIC
- JEJUNUM ..... TISSUE IS AUTOLYTIC
- ILEUM ..... TISSUE IS AUTOLYTIC
- PANCREAS ..... TISSUE IS AUTOLYTIC
- CECUM ..... TISSUE IS AUTOLYTIC
- RECTUM ..... TISSUE IS AUTOLYTIC
- COLON ..... TISSUE IS AUTOLYTIC
- STOMACH ..... TISSUE IS AUTOLYTIC
- ADRENAL ..... TISSUE IS MISSING
- PITUITARY GLAND ..... TISSUE IS AUTOLYTIC
- EYES & OPTIC N. .... TISSUE IS AUTOLYTIC
- MEDIASTINUM ..... MISCELLANEOUS TISSUE

Appendix J (cont.): PATHOLOGY INDIVIDUAL ANIMAL DATA

LETTERMAN ARMY INSTITUTE OF RESEARCH  
DIV OF RES SUPP, PATH SERV GP  
SPECIES: RAT/FISCHER-344

INDIVIDUAL ANIMAL DATA REPORT  
STUDY NUMBER: GLP83009  
STUDY START DATE: 23-JAN-84

PRINTED: 21-NOV-89  
PAGE: 613  
STUDY TYPE: CHRONIC/2 YR CARCINOGENIC

ANIMAL NUMBER: 309/PRETEST= 309 SEX: FEMALE DOSE GROUP: 2 SACRIFICE STATUS: FOUND DEAD  
DATE OF DEATH: 01-JUL-85 STUDY DAY OF DEATH: 526 STUDY WEEK OF DEATH: 76 TERMINAL BODY WEIGHT: 218.00 (GMS)  
TISSEU OBSERVATIONS >>  
<< MICROSCOPIC TISSUE DISTRIBUTION (SEVERITY) / SPECIAL COMMENTS

MEDIASTINUM ..... MISCELLANEOUS TISSUE  
-M- PRESENCE OF METASTATIC NEOPLASM ..... SECONDARY NEOPLASM FROM ORGAN ABDOMINAL CAVITY  
ABDOMINAL CAVITY ..... MISCELLANEOUS TISSUE  
-M- MESOTHELIOMA ..... (PRESENT)

Appendix J (cont.): PATHOLOGY INDIVIDUAL ANIMAL DATA

LETTERMAN ARMY INSTITUTE OF RESEARCH  
 DIV OF RES SUPP, PATH SERV GP  
 SPECIES: RAT/FISCHER-344  
 PRINTED: 21-NOV-89  
 PAGE: 614  
 STUDY NUMBER: GLP83009  
 STUDY START DATE: 23-JAN-84  
 STUDY TYPE: CHRONIC/2 YR CARCINOGENIC

ANIMAL NUMBER: 310/PRETEST=  
 DATE OF DEATH: 03-JAN-86  
 SEX: FEMALE  
 DOSE GROUP: 2  
 SACRIFICE STATUS: SACRIFICED MORIBUND  
 STUDY DAY OF DEATH: 712  
 STUDY WEEK OF DEATH: 102  
 TERMINAL BODY WEIGHT: 226.00 (GMS)

ORGAN NAME	KEYWORDS / PHRASES	SEVERITY	GROSS OBSERVATIONS	GROSS FREE-TEXT COMMENTS
SPLEEN	ENLARGED (SPLEOMEGALY)	MODERATE	5 X 2 X 1CM	
PERITONEAL CAV.	FLUID-FILLED	PRESENT	CLEAR RED, APPROXIMATELY 3ML	
LIVER	GRANULAR SURFACE	PRESENT	MOTTLED PINK	
LIVER	PROMINENT LOBULAR MARKINGS	PRESENT		
LIVER	DISCOLORATION	PRESENT	FOCAL, YELLOW, .5-.3CM DIAMETER	
KIDNEY	DISCOLORATION	PRESENT	GREEN/BROWN	
LUNGS	DISCOLORATION	PRESENT	MULTIPLE, RED, FOCAL.	
VAGINA	PURULENT DISCHARGE	PRESENT	YELLOW/GREEN	

TISSUE / HISTOPATHOLOGIC FINDINGS  
 << MICROSCOPIC TISSUE OBSERVATIONS >>  
 DISTRIBUTION (SEVERITY) / SPECIAL COMMENTS

PARATHYROID ..... TISSUE IS MISSING

HEART ..... NOT SPECIFIED(MODERATE)  
 -CARDIOMYOPATHY

LUNGS ..... (PRESENT)  
 -N- LARGE GRANULAR LYMPHOCYTE LEUKEMIA, METASTATIC  
 -ALVEOLAR HEMORRHAGE MULTI-FOCAL (PRESENT)

THYRUS ..... TISSUE IS MISSING

SPLEEN ..... NOT SPECIFIED(MILD)  
 -INFARCTION, CHRONIC (PRESENT)  
 -N- LARGE GRANULAR LYMPHOCYTE LEUKEMIA, METASTATIC (PRESENT)

LYMPH NODES ..... (PRESENT)  
 -N- LARGE GRANULAR LYMPHOCYTE LEUKEMIA, METASTATIC (PRESENT)  
 -DILATED AND/OR CYSTIC MEDULLARY SINUSES NOT SPECIFIED (PRESENT)

LIVER .....



**Appendix J (cont.): PATHOLOGY INDIVIDUAL ANIMAL DATA**

LETTERMAN ARMY INSTITUTE OF RESEARCH  
 DIV OF RES SUPP, PATH SERV GP  
 SPECIES: RAT/FISCHER-344  
 STUDY START DATE: 23-JAN-84  
 STUDY NUMBER: GLP83009  
 PRINTED: 21-NOV-89  
 PAGE: 615  
 STUDY TYPE: CHRONIC/2 YR CARCINOGENIC

ANIMAL NUMBER: 310/PRETEST# 310 SEX: FEMALE DOSE GROUP: 2 SACRIFICE STATUS: SACRIFICED MORIBUND  
 DATE OF DEATH: 03-JAN-86 STUDY DAY OF DEATH: 712 STUDY WEEK OF DEATH: 102 TERMINAL BODY WEIGHT: 226.00 (GMS)

<< M I C R O S C O P I C T I S S U E O B S E R V A T I O N S >>  
 TISSUE / HISTOPATHOLOGIC FINDINGS DISTRIBUTION (SEVERITY) / SPECIAL COMMENTS

- LIVER ..... NOT SPECIFIED (TRACE)
- BILE DUCTULE EPITHELIAL HYPERPLASIA AND/OR CHOLANGIOFIBROSIS ..... MULTI-FOCAL (SEVERE)
- HEPATITIS ..... MULTI-FOCAL (MODERATE)
- NECROSIS ..... (PRESENT)
- N- LARGE GRANULAR LYMPHOCYTE LEUKEMIA, METASTATIC
- KIDNEY ..... NOT SPECIFIED (MILD)
- PROGRESSIVE RENAL DISEASE
- PANCREAS ..... A SMALL GRANULOMA IS PRESENT IN THE PANCREAS. IN AN ADJACENT AREA THERE ARE AREAS OF GRANULOMATOUS INFLAMMATION ACCOMPANIED BY PROLIFERATION OF MESOTHELIAL CELLS WITHIN AND ON THE SURFACE OF THE MESENTERY. FOCAL (TRACE)
- CHRONIC INFLAMMATION
- SKELETAL MUSCLE ..... NOT SPECIFIED (PRESENT)
- CHRONIC INFLAMMATION RESTRICTED TO FASCIA
- SCIATIC NERVE ..... TISSUE IS MISSING
- SKIN ..... NOT SPECIFIED (MILD)
- CELLULITIS
- MAMMARY GLANDS ..... NOT SPECIFIED (MILD)
- HYPERPLASIA AND/OR HYPERTROPHY OF THE ACINAR TISSUE ..... NOT SPECIFIED (PRESENT)
- DILATATION (ECTASIA) OF DUCTS AND DUCTULES
- NOSE/TURBINATES ..... CELLULAR INFILTRATE INVOLVES NASO-LACRIMAL DUCTS.
- MIXED INFLAMMATORY CELL INFILTRATION, NASAL CAVITY, SINUSES, ..... NOT SPECIFIED (MODERATE)
- TURBINATES, NASO-LACRIMAL DUCTS
- ADRENAL ..... (PRESENT)
- B- CORTICAL ADENOMA ..... NOT SPECIFIED (TRACE)
- FOCUS OF CELLULAR ALTERATION, VACUOLATED

Appendix J (cont.): PATHOLOGY INDIVIDUAL ANIMAL DATA

LETTERMAN ARMY INSTITUTE OF RESEARCH  
DIV OF RES SUPP, PATH SERV GP  
SPECIES: RAT/FISCHER-344

INDIVIDUAL ANIMAL DATA REPORT  
STUDY NUMBER: GLP83009  
STUDY START DATE: 23-JAN-84

PRINTED: 21-NOV-89  
PAGE: 616

ANIMAL NUMBER: 310/PRETEST-  
DATE OF DEATH: 03-JAN-86 STUDY DAY OF DEATH: 712 SEX: FEMALE DOSE GROUP: 2 SACRIFICE STATUS: SACRIFICED MORIBUND  
STUDY WEEK OF DEATH: 102 TERMINAL BODY WEIGHT: 226.00 (GMS)

TISSUE / HISTOPATHOLOGIC FINDINGS  
MICROSCOPIC TISSUE OBSERVATIONS >>  
DISTRIBUTION (SEVERITY) / SPECIAL COMMENTS

PITUITARY GLAND ..... TISSUE IS MISSING  
WHOLE BODY .....  
-M- LARGE GRANULAR LYMPHOCYTTIC LEUKEMIA (PRESENT)  
MEDIASTINUM ..... MISCELLANEOUS TISSUE  
-CHRONIC INFLAMMATION MULTI-FOCAL(MILD)

**Appendix J (cont.): PATHOLOGY INDIVIDUAL ANIMAL DATA**

LETTERMAN ARMY INSTITUTE OF RESEARCH  
 DIV OF RES SUPP, PATN SERV GP  
 SPECIES: RAT/FISCHER-344

INDIVIDUAL ANIMAL DATA REPORT  
 STUDY NUMBER: GLP83009

PRINTED: 21-NOV-89  
 PAGE: 617

STUDY START DATE: 23-JAN-84      STUDY TYPE: CHRONIC/2 YR CARCINOGENIC

ANIMAL NUMBER: 311/PRETEST-      311 SEX: FEMALE      DOSE GROUP: 2      SACRIFICE STATUS: FINAL SACRIFICE  
 DATE OF DEATH: 10-FEB-86      STUDY DAY OF DEATH: 750      STUDY WEEK OF DEATH: 108      TERMINAL BODY WEIGHT: 287.00 (GMS)

ORGAN NAME      <<      G R O S S      O R G A N      O B S E R V A T I O N S      >>  
 KEYWORDS / PHRASES      SEVERITY      GROSS FREE-TEXT COMMENTS  
 LIVER      ADHESION(S)      PRESENT      DIAPHRAGM  
 OVARIES      PARA-OVARIAN CYST(S)      PRESENT      LEFT, 1CM DIAMETER, CLEAR FLUID FILLED

TISSUE / HISTOPATHOLOGIC FINDINGS      <<      M I C R O S C O P I C      T I S S U E      O B S E R V A T I O N S      >>  
 DISTRIBUTION (SEVERITY) / SPECIAL COMMENTS

THYROID GLANDS  
 -PARA-FOLLICULAR CELL HYPERPLASIA ("M" CELL, LIGHT CELL)      NOT SPECIFIED(TRACE)

HEART  
 -CARDIOMYOPATHY      NOT SPECIFIED(MILD)

LUNGS  
 -MINERALIZATION OF PULMONARY ARTERIES      NOT SPECIFIED(TRACE)

LIVER  
 -COMPOUND RELATED INFLAMMATORY REACTION      NOT SPECIFIED (PRESENT)  
 -BILE DUCTULE EPITHELIAL HYPERPLASIA AND/OR CHOLANGIOFIBROSIS      NOT SPECIFIED(MILD)  
 -HEPATITIS      MULTI-FOCAL(MILD)  
 -HEPATOCYTE COALESCING MICROVESICULAR (FATTY) CHANGE LEADING TO      NOT SPECIFIED(MODERATE)  
 NECROSIS AND MINERALIZATION

KIDNEY  
 -PROGRESSIVE RENAL DISEASE      NOT SPECIFIED(TRACE)

OVARIES  
 -PARA-OVARIAN CYST(S)      NOT SPECIFIED (PRESENT)

MAMMARY GLANDS  
 -HYPERPLASIA AND/OR HYPERTROPHY OF THE ACINAR TISSUE      NOT SPECIFIED(TRACE)  
 -DILATATION (ECTASIA) OF DUCTS AND DUCTULES      NOT SPECIFIED (PRESENT)

ADRENAL

Appendix J (cont.): PATHOLOGY INDIVIDUAL ANIMAL DATA

LETTERMAN ARMY INSTITUTE OF RESEARCH  
DIV OF RES SUPP, PATH SERV GP  
SPECIES: RAT/FISCHER-344

INDIVIDUAL ANIMAL DATA REPORT  
STUDY NUMBER: GLP83009  
STUDY START DATE: 23-JAN-84

PRINTED: 21-NOV-89  
PAGE: 618  
STUDY TYPE: CHRONIC/2 YR CARCINOGENIC

ANIMAL NUMBER: 311/PRETEST=  
DATE OF DEATH: 10-FEB-86 STUDY DAY OF DEATH: 750

SEX: FEMALE DOSE GROUP: 2  
STUDY WEEK OF DEATH: 108

SACRIFICE STATUS: FINAL SACRIFICE  
TERMINAL BODY WEIGHT: 287.00 (GMS)

<< MICROSCOPIC TISSUE OBSERVATIONS >>  
TISSUE / HISTOPATHOLOGIC FINDINGS

DISTRIBUTION (SEVERITY) / SPECIAL COMMENTS

ADRENAL ..... NOT SPECIFIED(MILD)  
-FOCUS OF CELLULAR ALTERATION, BASOPHILIC

DIAPHRAGM ..... MISCELLANEOUS TISSUE  
-COMPOUND RELATED INFLAMMATORY REACTION NOT SPECIFIED (PRESENT)

Appendix J (cont.): PATHOLOGY INDIVIDUAL ANIMAL DATA

LETTERMAN ARMY INSTITUTE OF RESEARCH  
DIV OF RES SUPP, PATH SERV GP  
SPECIES: RAT/FISCHER-344

PRINTED: 21-NOV-89  
PAGE: 619  
STUDY NUMBER: GLP83009  
STUDY START DATE: 23-JAN-84

ANIMAL NUMBER: 312/PRETEST-      312 SEX: FEMALE      DOSE GROUP: 2      SACRIFICE STATUS: FINAL SACRIFICE  
DATE OF DEATH: 10-FEB-86      STUDY DAY OF DEATH: 750      STUDY WEEK OF DEATH: 108      TERMINAL BODY WEIGHT: 278.00 (GMS)

ORGAN NAME      <<      G R O S S      O R G A N      O B S E R V A T I O N S      >>  
KEYWORDS / PHRASES      SEVERITY      GROSS FREE-TEXT COMMENTS  
LIVER      ADHESION(S)      PRESENT      DIAPHRAGM, VENTRAL ABDOMINAL WALL  
PITUITARY GLAND      ENLARGED      PRESENT      BLACK, .4CM DIAMETER

TISSUE / HISTOPATHOLOGIC FINDINGS      <<      M I C R O S C O P I C      T I S S U E      O B S E R V A T I O N S      >>  
DISTRIBUTION (SEVERITY) / SPECIAL COMMENTS

- HEART ..... NOT SPECIFIED(TRACE)
- CARDIOMYOPATHY
- LYMPH NODES ..... REACTIVE HYPERPLASIA NOTED IN CERVICAL NODE.
- REACTIVE HYPERPLASIA
- LIVER ..... NOT SPECIFIED (PRESENT)
- COMPOUND RELATED INFLAMMATORY REACTION
- KIDNEY ..... NOT SPECIFIED(MODERATE)
- PROGRESSIVE RENAL DISEASE
- UTERUS ..... NOT SPECIFIED (PRESENT)
- ENDOMETRIAL STROMAL POLYP
- MAMMARY GLANDS ..... NOT SPECIFIED(MILD)
- HYPERPLASIA AND/OR HYPERTROPHY OF THE ACINAR TISSUE
- DILATATION (ECTASIA) OF DUCTS AND DUCTULES
- NOSE/TURBINATES ..... CELLULAR INFILTRATE NOTED ADJACENT NASO-LACRIMAL DUCTS.
- MIXED INFLAMMATORY CELL INFILTRATION, NASAL CAVITY, SINUSES,      NOT SPECIFIED(MILD)
- TURBINATES, NASO-LACRIMAL DUCTS
- PITUITARY GLAND ..... (PRESENT)
- B- ADENOMA
- EYES & OPTIC N. ....

Appendix J (cont.): PATHOLOGY INDIVIDUAL ANIMAL DATA

LETTERMAN ARMY INSTITUTE OF RESEARCH  
DIV OF RES SUPP, PATH SERV GP  
SPECIES: RAT/FISCHER-344

INDIVIDUAL ANIMAL DATA REPORT  
STUDY NUMBER: GLP83009  
STUDY START DATE: 23-JAN-84

PRINTED: 21-NOV-89  
PAGE: 620

STUDY TYPE: CHRONIC/2 YR CARCINOGENIC

ANIMAL NUMBER: 312/PRETEST-      312 SEX: FEMALE      DOSE GROUP: 2      SACRIFICE STATUS: FINAL SACRIFICE  
DATE OF DEATH: 10-FEB-86      STUDY DAY OF DEATH: 750      STUDY WEEK OF DEATH: 108      TERMINAL BODY WEIGHT: 278.00 (GMS)

<<      M I C R O S C O P I C      T I S S U E      O B S E R V A T I O N S      >>  
TISSUE / HISTOPATHOLOGIC FINDINGS      DISTRIBUTION (SEVERITY) / SPECIAL COMMENTS

EYES & OPTIC N. .... NOT SPECIFIED (PRESENT)  
-METAPLASTIC BONE FORMATION AND/OR MINERALIZATION, SCLERA  
DIAPHRAGM ..... MISCELLANEOUS TISSUE  
-COMPOUND RELATED INFLAMMATORY REACTION ..... NOT SPECIFIED (PRESENT)

## Appendix J (cont.): PATHOLOGY INDIVIDUAL ANIMAL DATA

LETTERMAN ARMY INSTITUTE OF RESEARCH  
 DIV OF RES SUPP, PATH SERV GP  
 SPECIES: RAT/FISCHER-344

INDIVIDUAL ANIMAL DATA REPORT  
 STUDY NUMBER: GLP83009  
 STUDY START DATE: 23-JAN-84

PRINTED: 21-NOV-89  
 PAGE: 621  
 STUDY TYPE: CHRONIC/2 YR CARCINOGENIC

ANIMAL NUMBER: 313/PRETEST= 313 SEX: FEMALE DOSE GROUP: 2 SACRIFICE STATUS: FINAL SACRIFICE  
 DATE OF DEATH: 10-FEB-86 STUDY DAY OF DEATH: 750 STUDY WEEK OF DEATH: 108 TERMINAL BODY WEIGHT: 235.00 (GMS)

<< GROSS ORGAN OBSERVATIONS >>  
 SEVERITY GROSS FREE-TEXT COMMENTS  
 -----  
 LIVER ADMESION(S) PRESENT DIAPHRAGM, VENTRAL ABDOMINAL WALL  
 LIVER DISCOLORATION PRESENT BLACK, FOCAL, .2CM DIAMETER, LEFT LATERAL LOBE  
 UTERUS CYST(S) PRESENT MEDIAL LEFT HORN, .3CM DIAMETER  
 UTERUS POLYP PRESENT DIATAL RIGHT HORN, .3CM DIAMETER  
 PITUITARY GLAND ENLARGED PRESENT DARK RED, .4CM DIAMETER

TISSUE / HISTOPATHOLOGIC FINDINGS << MICROSCOPIC TISSUE OBSERVATIONS >>  
 -----  
 EXORBITAL LACRIM ..... NOT SPECIFIED(TRACE)  
 -ACINAR ATROPHY .....  
 HEART ..... NOT SPECIFIED(MILD)  
 -CARDIOMYOPATHY .....  
 LUNGS ..... NOT SPECIFIED(TRACE)  
 -MINERALIZATION OF PULMONARY ARTERIES .....  
 THYMUS ..... TISSUE IS MISSING  
 LYMPH NODES ..... REACTIVE HYPERPLASIA NOTED IN CERVICAL NODES.  
 -REACTIVE HYPERPLASIA ..... MESENTERIC AND MEDIASTINAL NODES ARE MISSING.  
 NOT SPECIFIED (PRESENT)  
 LIVER ..... NOT SPECIFIED (PRESENT)  
 -COMPOUND RELATED INFLAMMATORY REACTION ..... NOT SPECIFIED (MILD)  
 -HEPATOCTYE COALESCING MICROVESICULAR (FATTY) CHANGE LEADING TO .....  
 NECROSIS AND MINERALIZATION .....  
 KIDNEY ..... NOT SPECIFIED(MILD)  
 -PROGRESSIVE RENAL DISEASE .....

Appendix J (cont.): PATHOLOGY INDIVIDUAL ANIMAL DATA

LETTERMAN ARMY INSTITUTE OF RESEARCH  
 DIV OF RES SUPP, PATH SERV GP  
 SPECIES: RAT/FISCHER-344

INDIVIDUAL ANIMAL DATA REPORT  
 STUDY NUMBER: GLP83009

STUDY START DATE: 23-JAN-84

STUDY TYPE: CHRONIC/2 YR CARCINOGENIC

ANIMAL NUMBER: 313/PRETEST= 313 SEX: FEMALE DOSE GROUP: 2 SACRIFICE STATUS: FINAL SACRIFICE  
 DATE OF DEATH: 10-FEB-86 STUDY DAY OF DEATH: 750 STUDY WEEK OF DEATH: 108 TERMINAL BODY WEIGHT: 235.00 (GMS)

<< M I C R O S C O P I C T I S S U E O B S E R V A T I O N S >>  
 TISSUE / HISTOPATHOLOGIC FINDINGS DISTRIBUTION (SEVERITY) / SPECIAL COMMENTS

PRINTED: 21-NOV-89  
PAGE: 622

UTERUS ..... NO POLYP WAS OBSERVED MICROSCOPICALLY IN THE UTERUS. THERE IS  
 LARGE CYSTIC DILATATION OF SEVERAL UTERINE GLANDS PRESENT.  
 -CYSTIC DILATATION OF THE ENDOMETRIAL GLANDS NOT SPECIFIED (PRESENT)

PANCREAS ..... NOT SPECIFIED (MODERATE)  
 -ACINAR (EXOCRINE) ATROPHY (PRESENT)  
 -B- ISLET CELL ADENOMA

MAMMARY GLANDS ..... NOT SPECIFIED (TRACE)  
 -HYPERPLASIA AND/OR HYPERTROPHY OF THE ACINAR TISSUE NOT SPECIFIED (PRESENT)  
 -DILATATION (ECTASIA) OF DUCTS AND DUCTULES

NOSE/TURBINATES ..... CELLULAR INFILTRATE IS ADJACENT NASO-LACRIMAL DUCTS.  
 -MIXED INFLAMMATORY CELL INFILTRATION, NASAL CAVITY, SINUSES, NOT SPECIFIED (TRACE)  
 TURBINATES, NASO-LACRIMAL DUCTS

PITUITARY GLAND ..... (PRESENT)  
 -B- ADENOMA

EYES & OPTIC N. .... NOT SPECIFIED (PRESENT)  
 -METAPLASTIC BONE FORMATION AND/OR MINERALIZATION, SCLERA

DIAPHRAGM ..... MISCELLANEOUS TISSUE  
 -COMPOUND RELATED INFLAMMATORY REACTION NOT SPECIFIED (PRESENT)



Appendix J (cont.): PATHOLOGY INDIVIDUAL ANIMAL DATA

LETTERMAN ARMY INSTITUTE OF RESEARCH  
 DIV OF RES SUPP, PATH SERV GP  
 SPECIES: RAT/FISCHER-344

INDIVIDUAL ANIMAL DATA REPORT  
 STUDY NUMBER: GLP83009

ANIMAL NUMBER: 314/PRETEST-314  
 DATE OF DEATH: 10-FEB-86  
 STUDY DAY OF DEATH: 750  
 SEX: FEMALE  
 DOSE GROUP: 2  
 SACRIFICE STATUS: FINAL SACRIFICE

STUDY START DATE: 23-JAN-84  
 STUDY TYPE: CHRONIC/2 YR CARCINOGENIC

TERMINAL BODY WEIGHT: 288.00 (GMS)

ORGAN NAME      <<    G R O S S    O R G A N    O B S E R V A T I O N S    >>  
 KEYWORDS / PHRASES      SEVERITY    GROSS FREE-TEXT COMMENTS

PITUITARY GLAND      ENLARGED      PRESENT      DARK RED, LEFT SIDE, .4CM DIAMETER  
 LIVER                    ADHESION(S)      PRESENT      VENTRAL ABDOMINAL WALL  
 UTERUS                    HYDROMETRA      PRESENT      BILATERAL  
 SKIN                      ABSCESS(ES)      PRESENT      .5CM DIAMETER, SUBCUTANEOUS AT CLITORAL GLAND

TISSUE / HISTOPATHOLOGIC FINDINGS      <<    M I C R O S C O P I C    T I S S U E    O B S E R V A T I O N S    >>  
 DISTRIBUTION (SEVERITY) / SPECIAL COMMENTS

- HEART ..... NOT SPECIFIED(TRACE)
- CARDIOMYOPATHY
- LIVER ..... NOT SPECIFIED (PRESENT)
- COMPOUND RELATED INFLAMMATORY REACTION
- HEPATITIS      MULTI-FOCAL(TRACE)
- HEPATOCYTE COALESCING MICROVESICULAR (FATTY) CHANGE LEADING TO      MULTI-FOCAL(MILD)
- NECROSIS AND MINERALIZATION
- KIDNEY ..... NOT SPECIFIED(MILD)
- PROGRESSIVE RENAL DISEASE
- UTERUS ..... MULTI-FOCAL(TRACE)
- LYMPHOCYTTIC INFILTRATE
- PANCREAS ..... MULTI-FOCAL(MODERATE)
- ACINAR (EXOCRINE) ATROPHY      NOT SPECIFIED (PRESENT)
- CYSTIC DUCT

PRINTED: 21-NOV-89  
PAGE: 623

Appendix J (cont.): PATHOLOGY INDIVIDUAL ANIMAL DATA

LETTERMAN ARMY INSTITUTE OF RESEARCH  
DIV OF RES SUPP, PATH SERV GP  
SPECIES: RAT/FISCHER-344

INDIVIDUAL ANIMAL DATA REPORT  
STUDY NUMBER: GLP83009

PRINTED: 21-NOV-89  
PAGE: 624

STUDY START DATE: 23-JAN-84

STUDY TYPE: CHRONIC/2 YR CARCINOGENIC

ANIMAL NUMBER: 314/PRETEST=

314 SEX: FEMALE

DOSE GROUP: 2

SACRIFICE STATUS: FINAL SACRIFICE

DATE OF DEATH: 10-FEB-86

STUDY DAY OF DEATH: 750

STUDY WEEK OF DEATH: 108

TERMINAL BODY WEIGHT: 286.00 (GMS)

TISSUE / HISTOPATHOLOGIC FINDINGS

<< M I C R O S C O P I C T I S S U E

O B S E R V A T I O N S >>

DISTRIBUTION (SEVERITY) / SPECIAL COMMENTS

SKIN

MICROSCOPIC EXAMINATION OF THE LESION DESCRIBED AS AN ABSCESS  
IN THE SUBCUTANEOUS TISSUE NEAR THE CLITORAL GLAND DEMONSTRATED  
A SMALL CYSTIC CAVITY LINED BY A PROLIFERATIVE SQUAMOUS  
EPITHELIAL WALL AND FILLED WITH KERATIN. THIS LESION IS  
COMPATIBLE WITH A KERATOACANTHOMA.  
(PRESENT)

-B- KERATOACANTHOMA, ANATOMIC SITE TO BE SPECIFIED

MAMMARY GLANDS

-HYPERPLASIA AND/OR HYPERTROPHY OF THE ACINAR TISSUE

-DILATATION (ECTASIA) OF DUCTS AND DUCTULES

NOT SPECIFIED(MODERATE)

NOT SPECIFIED (PRESENT)

NOSE/TURBINATES

-MIXED INFLAMMATORY CELL INFILTRATION, NASAL CAVITY, SINUSES,

TURBINATES, MASO-LACRIMAL DUCTS

CELLULAR INFILTRATE IS ADJACENT TO MASO-LACRIMAL DUCT.

NOT SPECIFIED(TRACE)

PITUITARY GLAND

-B- ADENOMA

(PRESENT)

EYES & OPTIC N.

EYE SECTION 19A IS EMBEDDED IN AN INCORRECT ORIENTATION. PLANE  
OF SECTION DOES NOT INCLUDE CORNEA.

AD SEBACIOUS

TISSUE IS MISSING

Appendix J (cont.): PATHOLOGY INDIVIDUAL ANIMAL DATA

LETTERMAN ARMY INSTITUTE OF RESEARCH  
DIV OF RES SUPP, PATH SERV GP  
SPECIES: RAY/FISCHER-344  
STUDY NUMBER: GLP83009  
STUDY START DATE: 23-JAN-84  
PRINTED: 21-NOV-89  
PAGE: 625  
STUDY TYPE: CHRONIC/2 YR CARCINOGENIC

ANIMAL NUMBER: 315/PRETEST=  
DATE OF DEATH: 10-FEB-86  
STUDY DAY OF DEATH: 750  
SEX: FEMALE  
DOSE GROUP: 2  
SACRIFICE STATUS: FINAL SACRIFICE  
TERMINAL BODY WEIGHT: 255.00 (GMS)

ORGAN NAME: << GROSS ORGAN OBSERVATIONS >>  
KEYWORDS / PHRASES: SEVERITY GROSS FREE-TEXT COMMENTS  
ADHESION(S): PRESENT DIAPHRAGM

TISSUE / HISTOPATHOLOGIC FINDINGS: << MICROSCOPIC TISSUE OBSERVATIONS >>  
DISTRIBUTION (SEVERITY) / SPECIAL COMMENTS

THYROID GLANDS: << MICROSCOPIC TISSUE OBSERVATIONS >>  
-PARA-FOLLICULAR CELL HYPERPLASIA (\*M\* CELL, LIGHT CELL) NOT SPECIFIED(TRACE)

EXORBITAL LACRIM: << MICROSCOPIC TISSUE OBSERVATIONS >>  
-ACINAR ATROPHY NOT SPECIFIED(TRACE)

HEART: << MICROSCOPIC TISSUE OBSERVATIONS >>  
-CARDIOMYOPATHY NOT SPECIFIED(TRACE)  
-MEDIAL HYPERTROPHY OF MUSCULAR ARTERIES NOT SPECIFIED(TRACE)

LYMPH NODES: << MICROSCOPIC TISSUE OBSERVATIONS >>  
-REACTIVE HYPERPLASIA REACTIVE HYPERPLASIA IS NOTED IN CERVICAL, MEDIASTINAL AND MESENTERIC NODES. NOT SPECIFIED (PRESENT)

LIVER: << MICROSCOPIC TISSUE OBSERVATIONS >>  
-COMPOUND RELATED INFLAMMATORY REACTION NOT SPECIFIED (PRESENT)  
-BILE DUCTULE EPITHELIAL HYPERPLASIA AND/OR CHOLANGIOFIBROSIS NOT SPECIFIED(TRACE)  
-PERIPORTAL MONONUCLEAR CELLULAR INFILTRATION MULTI-FOCAL(TRACE)  
-HEPATOCYTE COALESCING MICROVESICULAR (FATTY) CHANGE LEADING TO NECROSIS AND MINERALIZATION MULTI-FOCAL(TRACE)

KIDNEY: << MICROSCOPIC TISSUE OBSERVATIONS >>  
-PROGRESSIVE RENAL DISEASE NOT SPECIFIED(TRACE)

MAMMARY GLANDS: << MICROSCOPIC TISSUE OBSERVATIONS >>  
-HYPERPLASIA AND/OR HYPERTROPHY OF THE ACINAR TISSUE NOT SPECIFIED(MILD)  
-DILATATION (ECTASIA) OF DUCTS AND DUCTULES NOT SPECIFIED (PRESENT)

Appendix J (cont.): PATHOLOGY INDIVIDUAL ANIMAL DATA

LETTERMAN ARMY INSTITUTE OF RESEARCH  
DIV OF RES SUPP, PATH SERV GP  
SPECIES: RAT/FISCHER-344

INDIVIDUAL ANIMAL DATA REPORT  
STUDY NUMBER: GLP83009

PRINTED: 21-NOV-89  
PAGE: 626

STUDY START DATE: 23-JAN-84

STUDY TYPE: CHRONIC/2 YR CARCINOGENIC

ANIMAL NUMBER: 315/PRETEST= 315 SEX: FEMALE DOSE GROUP: 2 SACRIFICE STATUS: FINAL SACRIFICE  
DATE OF DEATH: 10-FEB-86 STUDY DAY OF DEATH: 750 STUDY WEEK OF DEATH: 108 TERMINAL BODY WEIGHT: 255.00 (GMS)

TISSUE / HISTOPATHOLOGIC FINDINGS << MICROSCOPIC TISSUE OBSERVATIONS >>  
DISTRIBUTION (SEVERITY) / SPECIAL COMMENTS

NOSE/TURBINATES ..... CELLULAR INFILTRATE IS ADJACENT NASO-LACRIMAL DUCTS.  
-MIXED INFLAMMATORY CELL INFILTRATION, NASAL CAVITY, SINUSES, NOT SPECIFIED(MILD)  
TURBINATES, NASO-LACRIMAL DUCTS

PITUITARY GLAND ..... NOT SPECIFIED (PRESENT)  
-CYST(S)

EYES & OPTIC N. .... CHRONIC CONJUNCTIVITIS IS PRESENT IN SECTIONS ATTACHED TO THE  
LACRIMAL GLAND IN SLIDE #4, NO CONJUNCTIVAL MEMBRANE IS PRESENT  
ON SLIDES OF THE EYES THEMSELVES. JUNCTIVAL MEMBRANE IS PRESENT  
-CORNEAL MINERALIZATION NOT SPECIFIED(TRACE)  
-CORNEAL VASCULARIZATION NOT SPECIFIED(TRACE)  
-CHRONIC CONJUNCTIVITIS NOT SPECIFIED(MODERATE)

**Appendix J (cont.): PATHOLOGY INDIVIDUAL ANIMAL DATA**

LETTERMAN ARMY INSTITUTE OF RESEARCH  
 DIV OF RES SUPP, PATH SERV GP  
 SPECIES: RAT/FISCHER-344

INDIVIDUAL ANIMAL DATA REPORT  
 STUDY NUMBER: GLP83009

STUDY START DATE: 23-JAN-84

ANIMAL NUMBER: 316/PRETEST=  
 DATE OF DEATH: 10-FEB-86

PRINTED: 21-NOV-89  
 PAGE: 627  
 STUDY TYPE: CHRONIC/2 YR CARCINOGENIC

316 SEX: FEMALE DOSE GROUP: 2 SACRIFICE STATUS: FINAL SACRIFICE  
 STUDY DAY OF DEATH: 750 STUDY WEEK OF DEATH: 108 TERMINAL BODY WEIGHT: 275.00 (GMS)

<< GROSS ORGAN OBSERVATIONS >>  
 SEVERITY GROSS FREE-TEXT COMMENTS  
 KEYWORDS / PHRASES  
 ADHESION(S) PRESENT DIAPHRAGM, VENTRAL ABDOMINAL WALL  
 PITUITARY GLAND DISCOLORATION PRESENT DARK RED, .2CM DIAMETER  
 OVARIES PARA-OVARIAN CYST(S) PRESENT RIGHT, 1.25CM DIAMETER, CLEAR FLUID FILLED

<< MICROSCOPIC TISSUE OBSERVATIONS >>  
 DISTRIBUTION (SEVERITY) / SPECIAL COMMENTS

HEART ..... NOT SPECIFIED(TRACE)  
 -CARDIOMYOPATHY ..... NOT SPECIFIED(TRACE)  
 -MEDIAL HYPERTROPHY OF MUSCULAR ARTERIES .....  
 LUNGS ..... NOT SPECIFIED(TRACE)  
 -MINERALIZATION OF PULMONARY ARTERIES .....  
 LYMPH NODES ..... REACTIVE HYPERPLASIA NOTED IN CERVICAL NODE.  
 -REACTIVE HYPERPLASIA ..... NOT SPECIFIED (PRESENT)  
 LIVER .....  
 -COMPOUND RELATED INFLAMMATORY REACTION ..... NOT SPECIFIED (PRESENT)  
 -FOCUS OF CELLULAR ALTERATION - BASOPHILIC ..... NOT SPECIFIED(TRACE)  
 -HEPATOCYTE COALESCING MICROVESICULAR (FATTY) CHANGE LEADING TO ..... NOT SPECIFIED(TRACE)  
 NECROSIS AND MINERALIZATION .....  
 KIDNEY .....  
 -PROGRESSIVE RENAL DISEASE ..... NOT SPECIFIED(MILD)  
 OVARIES .....  
 -PARA-OVARIAN CYST(S) ..... NOT SPECIFIED (PRESENT)  
 MAMMARY GLANDS .....  
 -HYPERPLASIA AND/OR HYPERTROPHY OF THE ACINAR TISSUE ..... NOT SPECIFIED(MILD)

Appendix J (cont.): PATHOLOGY INDIVIDUAL ANIMAL DATA

LETTERMAN ARMY INSTITUTE OF RESEARCH  
 DIV OF RES SUPP, PATN SERV GP  
 SPECIES: RAT/FISCHER-344  
 STUDY START DATE: 23-JAN-84  
 STUDY NUMBER: GLP83009  
 PRINTED: 21-NOV-89  
 PAGE: 628  
 STUDY TYPE: CHRONIC/2 YR CARCINOGENIC

ANIMAL NUMBER: 316/PRETEST#  
 DOSE GROUP: 2  
 SACRIFICE STATUS: FINAL SACRIFICE  
 DATE OF DEATH: 10-FEB-86  
 STUDY DAY OF DEATH: 750  
 STUDY WEEK OF DEATH: 108  
 TERMINAL BODY WEIGHT: 275.00 (GMS)

<< M I C R O S C O P I C T I S S U E O B S E R V A T I O N S >>  
 TISSUE / HISTOPATHOLOGIC FINDINGS  
 DISTRIBUTION (SEVERITY) / SPECIAL COMMENTS

NOSE/TURBINATES ..... CELLULAR INFILTRATE IS ADJACENT THE NASO-LACRIMAL DUCT.  
 -MIXED INFLAMMATORY CELL INFILTRATION, NASAL CAVITY, SINUSES, NOT SPECIFIED(MILD)  
 TURBINATES, NASO-LACRIMAL DUCTS

ADRENAL .....  
 -FOCUS OF CELLULAR ALTERATION, VACUOLATED NOT SPECIFIED(TRACE)  
 -CORTICAL NODULAR HYPERPLASIA NOT SPECIFIED (PRESENT)

PITUITARY GLAND .....  
 -B- ADENOMA (PRESENT)  
 -CYST(S) NOT SPECIFIED (PRESENT)

EYES & OPTIC N. ....  
 -RETINAL ATROPHY AND/OR DEGENERATION, UNILATERAL OR BILATERAL NOT SPECIFIED(MILD)

DIAPHRAGM ..... MISCELLANEOUS TISSUE  
 -COMPOUND RELATED INFLAMMATORY REACTION NOT SPECIFIED (PRESENT)

Appendix J (cont.): PATHOLOGY INDIVIDUAL ANIMAL DATA

LETTERMAN ARMY INSTITUTE OF RESEARCH  
 DIV OF RES SUPP, PATH SERV GP  
 SPECIES: RAT/FISCHER-344  
 STUDY START DATE: 23-JAN-84  
 STUDY NUMBER: GLP83009  
 PRINTED: 21-NOV-89  
 PAGE: 630  
 STUDY TYPE: CHRONIC/2 YR CARCINOGENIC

ANIMAL NUMBER: 318/PRETEST= 318 SEX: FEMALE DOSE GROUP: 2 SACRIFICE STATUS: SACRIFICED MORIBUND  
 DATE OF DEATH: 13-JAN-86 STUDY DAY OF DEATH: 722 STUDY WEEK OF DEATH: 104 TERMINAL BODY WEIGHT: 208.00 (GMS)

<< GROSS ORGAN OBSERVATIONS >>  
 SEVERITY GROSS FREE-TEXT COMMENTS  
 KEYWORDS / PHRASES  
 ADHESION(S)  
 PITUITARY GLAND ENLARGED  
 PRESENT DIAPHRAGM AND VENTRAL ABDOMINAL WALL  
 PRESENT .8CH DIAMETER, RED/BLACK

<< MICROSCOPIC TISSUE OBSERVATIONS >>  
 DISTRIBUTION (SEVERITY) / SPECIAL COMMENTS

BRAIN  
 -I-PITUITARY TUMOR INVASION (PRESENT)

THYROID GLANDS  
 -PARA-FOLLICULAR CELL HYPERPLASIA ("M" CELL, LIGHT CELL) NOT SPECIFIED(TRACE)

HEART  
 -CARDIOMYOPATHY NOT SPECIFIED(MILD)

LIVER  
 -COMPOUND RELATED INFLAMMATORY REACTION NOT SPECIFIED (PRESENT)  
 -HEPATITIS MULTI-FOCAL(TRACE)  
 -FOCUS OF CELLULAR ALTERATION - BASOPHILIC MULTI-FOCAL(MILD)

KIDNEY  
 -PROGRESSIVE RENAL DISEASE NOT SPECIFIED(MODERATE)

MAMMARY GLANDS  
 -HYPERPLASIA AND/OR HYPERTROPHY OF THE ACINAR TISSUE NOT SPECIFIED(MODERATE)  
 -DILATATION (ECTASIA) OF DUCTS AND DUCTULES NOT SPECIFIED (PRESENT)

PITUITARY GLAND  
 -B- ADENOMA (PRESENT)

EYES & OPTIC N. (PRESENT)

Appendix J (cont.): PATHOLOGY INDIVIDUAL ANIMAL DATA

LETTERMAN ARMY INSTITUTE OF RESEARCH  
DIV OF RES SUPP, PATH SERV GP  
SPECIES: RAT/FISCHER-344

INDIVIDUAL ANIMAL DATA REPORT  
STUDY NUMBER: GLP63009  
STUDY START DATE: 23-JAN-84

PRINTED: 21-NOV-89  
PAGE: 631

STUDY TYPE: CHRONIC/2 YR CARCINOGENIC

ANIMAL NUMBER: 318/PRETEST=  
DATE OF DEATH: 13-JAN-86

318 SEX: FEMALE  
STUDY DAY OF DEATH: 722

DOSE GROUP: 2  
STUDY WEEK OF DEATH: 104

SACRIFICE STATUS: SACRIFICED MORIBUND  
TERMINAL BODY WEIGHT: 208.00 (GMS)

<< MICROSCOPIC TISSUE OBSERVATIONS >>  
DISTRIBUTION (SEVERITY) / SPECIAL COMMENTS

EYES & OPTIC N. .... NOT SPECIFIED (PRESENT)  
-METAPLASTIC BONE FORMATION AND/OR MINERALIZATION, SCLERA



**Appendix J (cont.): PATHOLOGY INDIVIDUAL ANIMAL DATA**

LETTERMAN ARMY INSTITUTE OF RESEARCH  
 DIV OF RES SUPP, PATH SERV GP  
 SPECIES: RAT/FISCHER-344

INDIVIDUAL ANIMAL DATA REPORT  
 STUDY NUMBER: GLP83009  
 STUDY START DATE: 23-JAN-84

PRINTED: 21-NOV-89  
 PAGE: 632  
 STUDY TYPE: CHRONIC/2 YR CARCINOGENIC

ANIMAL NUMBER: 319/PRETEST= 319 SEX: FEMALE DOSE GROUP: 2 SACRIFICE STATUS: SACRIFICED MORIBUND  
 DATE OF DEATH: 21-JAN-86 STUDY DAY OF DEATH: 730 STUDY WEEK OF DEATH: 105 TERMINAL BODY WEIGHT: 197.00 (GMS)

ORGAN NAME SEVERITY GROSS OBSERVATIONS  
 EYES & OPTIC N. PRESENT RED  
 OVARIES CRUSTY MATERIAL, PERIORBITAL  
 LIVER PARA-OVARIAN CYST(S)  
 PITUITARY GLAND ADHESION(S)  
 ENLARGED

TISSUE / HISTOPATHOLOGIC FINDINGS  
 TISSUE OBSERVATIONS / SPECIAL COMMENTS

BRAIN  
 -I-PITUITARY TUMOR INVASION (PRESENT)

THYROID GLANDS  
 -PARA-FOLLICULAR CELL HYPERPLASIA ("C" CELL, LIGHT CELL) NOT SPECIFIED(TRACE)

PARATHYROID  
 TISSUE IS MISSING

SALIVARY GLAND  
 -INFLAMMATION, SUBACUTE NOT SPECIFIED(MODERATE)

HEART  
 -CARDIOMYOPATHY NOT SPECIFIED(TRACE)

LYMPH NODES  
 -REACTIVE HYPERPLASIA REACTIVE HYPERPLASIA NOTED IN CERVICAL LYMPH NODE.  
 NOT SPECIFIED (PRESENT)

LIVER  
 -COMPOUND RELATED INFLAMMATORY REACTION NOT SPECIFIED (PRESENT)

KIDNEY  
 -PROGRESSIVE RENAL DISEASE NOT SPECIFIED(TRACE)

OVARIES

Appendix J (cont.): PATHOLOGY INDIVIDUAL ANIMAL DATA

LETTERMAN ARMY INSTITUTE OF RESEARCH  
DIV OF RES SUPP, PATH SERV GP  
SPECIES: RAT/FISCHER-344

INDIVIDUAL ANIMAL DATA REPORT  
STUDY NUMBER: GLP83009  
STUDY START DATE: 23-JAN-84

PRINTED: 21-NOV-89  
PAGE: 633

STUDY TYPE: CHRONIC/2 YR CARCINOGENIC

ANIMAL NUMBER: 319/PRETEST# 319 SEX: FEMALE DOSE GROUP: 2 SACRIFICE STATUS: SACRIFICED MORIBUND  
DATE OF DEATH: 21-JAN-86 STUDY DAY OF DEATH: 730 STUDY WEEK OF DEATH: 105 TERMINAL BODY WEIGHT: 197.00 (GMS)

TISSUE / HISTOPATHOLOGIC FINDINGS << MICROSCOPIC TISSUE OBSERVATIONS >> DISTRIBUTION (SEVERITY) / SPECIAL COMMENTS

OVARIES ..... NOT SPECIFIED (PRESENT)  
-PARA-OVARIAN CYST(S)

MAMMARY GLANDS ..... NOT SPECIFIED (MILD)  
-HYPERPLASIA AND/OR HYPERTROPHY OF THE ACINAR TISSUE  
-DILATATION (ECTASIA) OF DUCTS AND DUCTULES

PITUITARY GLAND ..... (PRESENT)  
-B- ADENOMA

DIAPHRAGM ..... MISCELLANEOUS TISSUE  
THERE IS A SMALL GRANULOMATOUS ADHESION CONTAINING THE TEST  
MATERIAL ADHERING TO THE LIVER CAPSULE. NO TISSUE FROM THE  
DIAPHRAGM IS INCLUDED IN THIS PLANE OF SECTION ALTHOUGH A  
DIAPHRAGMATIC ADHESION WAS OBSERVED AND RECORDED ON GROSS EXAM.

Appendix J (cont.): PATHOLOGY INDIVIDUAL ANIMAL DATA

LETTERMAN ARMY INSTITUTE OF RESEARCH  
 DIV OF RES SUPP, PATH SERV GP  
 SPECIES: RAT/FISCHER-344

PRINTED: 21-NOV-89  
 PAGE: 635

INDIVIDUAL ANIMAL DATA REPORT  
 STUDY NUMBER: GLP83009

STUDY TYPE: CHRONIC/2 YR CARCINOGENIC

STUDY START DATE: 23-JAN-84

ANIMAL NUMBER: 321/PRETEST\*  
 DATE OF DEATH: 12-FEB-86  
 SEX: FEMALE  
 DOSE GROUP: 2  
 SACRIFICE STATUS: FINAL SACRIFICE

STUDY WEEK OF DEATH: 108  
 TERMINAL BODY WEIGHT: 271.00 (GMS)

ORGAN NAME: << GROSS ORGAN OBSERVATIONS >>  
 SEVERITY GROSS FREE-TEXT COMMENTS  
 LIVER ADHESION(S) PRESENT LEFT VENTRAL ABDOMINAL WALL  
 LIVER NODULE(S) PRESENT .6CM DIAMETER, MEDIAL LOBE  
 PITUITARY GLAND ENLARGED PRESENT .4CM DIAMETER, FOCAL BLACK DISCOLORATION, .1CM DIAMETER

TISSUE / HISTOPATHOLOGIC FINDINGS << MICROSCOPIC TISSUE OBSERVATIONS >>  
 DISTRIBUTION (SEVERITY) / SPECIAL COMMENTS

SALIVARY GLAND  
 -ATROPHY AND LOSS OF ACINAR TISSUE FOCAL(TRACE)  
 -INFLAMMATION, SUBACUTE FOCAL(TRACE)

EXORBITAL LACRIM  
 -SUBACUTE INFLAMMATION MULTI-FOCAL(TRACE)

HEART  
 -CARDIOMYOPATHY NOT SPECIFIED(MILD)

LYMPH NODES  
 -REACTIVE HYPERPLASIA REACTIVE HYPERPLASIA NOTED IN CERVICAL AND MESENTERIC NODES.  
 NOT SPECIFIED (PRESENT)

LIVER  
 -COMPOUND RELATED INFLAMMATORY REACTION NOT SPECIFIED (PRESENT)  
 -HEPATITIS MULTI-FOCAL(TRACE)  
 -FOCUS OF CELLULAR ALTERATION - BASOPHILIC NOT SPECIFIED(TRACE)  
 -HEPATOCTYIC VACUOLIZATION MULTI-FOCAL(TRACE)  
 -BENIGN HYPERPLASTIC NODULE(S) NOT SPECIFIED(TRACE)  
 -HEPATOCTYCE COALESCING MICROVESICULAR (FATTY) CHANGE LEADING TO NECROSIS AND MINERALIZATION MULTI-FOCAL(TRACE)

KIDNEY  
 -PROGRESSIVE RENAL DISEASE NOT SPECIFIED(MILD)

MAMMARY GLANDS

Appendix J (cont.): PATHOLOGY INDIVIDUAL ANIMAL DATA

LETTERMAN ARMY INSTITUTE OF RESEARCH  
DIV OF RES SUPP, PATH SERV GP  
SPECIES: RAT/FISCHER-344

INDIVIDUAL ANIMAL DATA REPORT  
STUDY NUMBER: GLP83009  
STUDY START DATE: 23-JAN-84

PRINTED: 21-NOV-89  
PAGE: 636

STUDY TYPE: CHRONIC/2 YR CARCINOGENIC

ANIMAL NUMBER: 321/PRETEST-321 SEX: FEMALE DOSE GROUP: 2 SACRIFICE STATUS: FINAL SACRIFICE  
DATE OF DEATH: 12-FEB-86 STUDY DAY OF DEATH: 752 STUDY WEEK OF DEATH: 108 TERMINAL BODY WEIGHT: 271.00 (GMS)

<< MICROSCOPIC TISSUE OBSERVATIONS >>  
DISTRIBUTION (SEVERITY) / SPECIAL COMMENTS

MAMMARY GLANDS ..... NOT SPECIFIED(MILD)  
-HYPERPLASIA AND/OR HYPERTROPHY OF THE ACINAR TISSUE ..... NOT SPECIFIED (PRESENT)  
-DILATATION (ECTASIA) OF DUCTS AND DUCTULES .....  
NOSE/TURBINATES ..... CELLULAR INFILTRATE INVOLVES VENTRAL TURBINATE AREA BILATERALLY.  
-MIXED INFLAMMATORY CELL INFILTRATION, NASAL CAVITY, SINUSES, ..... NOT SPECIFIED(MILD)  
TURBINATES, NASO-LACRIMAL DUCTS .....  
ADRENAL ..... NOT SPECIFIED(TRACE)  
-FOCUS OF CELLULAR ALTERATION, VACUOLATED .....  
PITUITARY GLAND ..... (PRESENT)  
-B- ADENOMA .....  
DIAPHRAGM ..... MISCELLANEOUS TISSUE  
-COMPOUND RELATED INFLAMMATORY REACTION ..... NOT SPECIFIED (PRESENT)

Appendix J (cont.): PATHOLOGY INDIVIDUAL ANIMAL DATA

LETTERMAN ARMY INSTITUTE OF RESEARCH  
 DIV OF RES SUPP, PATH SERV GP  
 SPECIES: RAT/FISCHER-344

INDIVIDUAL ANIMAL DATA REPORT  
 STUDY NUMBER: GLP83009

PRINTED: 21-NOV-89  
 PAGE: 637

STUDY START DATE: 23-JAN-84

STUDY TYPE: CHRONIC/2 YR CARCINOGENIC

ANIMAL NUMBER: 322/PRETEST= 322 SEX: FEMALE DOSE GROUP: 2 SACRIFICE STATUS: SACRIFICED MORIBUND  
 DATE OF DEATH: 29-JAN-86 STUDY DAY OF DEATH: 738 STUDY WEEK OF DEATH: 106 TERMINAL BODY WEIGHT: 233.00 (GMS)

ORGAN NAME	KEYWORDS / PHRASES	SEVERITY	GROSS OBSERVATIONS	GROSS FREE-TEXT COMMENTS
LIVER	ADHESION(S)	PRESENT	VENTRAL ABDOMINAL WALL	
KIDNEY	GRANULAR SURFACE	PRESENT	DARK	
PITUITARY GLAND	ENLARGED	PRESENT	.7CM DIAMETER, DARK RED	

TISSUE / HISTOPATHOLOGIC FINDINGS

TISSUE	MICROSCOPIC TISSUE	OBSERVATIONS	DISTRIBUTION (SEVERITY) / SPECIAL COMMENTS
BRAIN			MILD HYDROCEPHALUS IS NOTED. THERE IS LIQUIFACTION NECROSIS ADJACENT TO DILATED LATERAL VENTRICLES. NOT SPECIFIED (PRESENT) NOT SPECIFIED(MILD)
THYROID GLANDS			THIS SECTION IS VERY THICK AND HAS MANY ARTIFACTS. NO LESION IS RECOGNIZED. TO RECUT THIS BLOCK WOULD PROBABLY EXHAUST THE TISSUE AND WOULD PROBABLY NOT RESULT IN ANY USEFUL DATA.
HEART			NOT SPECIFIED(TRACE)
LUNGS			NOT SPECIFIED(TRACE) FOCAL (PRESENT)
LYMPH NODES			NOT SPECIFIED (PRESENT)
LIVER			NOT SPECIFIED (PRESENT) NOT SPECIFIED(TRACE) FOCAL(TRACE) NOT SPECIFIED (PRESENT)
KIDNEY			

TISSUE / HISTOPATHOLOGIC FINDINGS

<< MICROSCOPIC TISSUE OBSERVATIONS >>

BRAIN

-HYDROCEPHALUS

-LIQUIFACTION NECROSIS

THYROID GLANDS

HEART

-CARDIOMYOPATHY

LUNGS

-MINERALIZATION OF PULMONARY ARTERIES

-ALVEOLAR HEMORRHAGE

LYMPH NODES

-DILATED AND/OR CYSTIC MEDULLARY SINUSES

LIVER

-COMPOUND RELATED INFLAMMATORY REACTION

-BILE DUCTULE EPITHELIAL HYPERPLASIA AND/OR CHOLANGIOFIBROSIS

-HEPATOCTYTIC VACUOLIZATION

-TELANGIECTASIS

-FIBROSIS CAPSULAR NO COMPOUND

KIDNEY

Appendix J (cont.): PATHOLOGY INDIVIDUAL ANIMAL DATA

LETTERMAN ARMY INSTITUTE OF RESEARCH  
DIV OF RES SUPP, PATH SERV GP  
SPECIES: RAT/FISCHER-344

INDIVIDUAL ANIMAL DATA REPORT  
STUDY NUMBER: GLP83009

PRINTED: 21-NOV-89  
PAGE: 638

STUDY START DATE: 23-JAN-84

STUDY TYPE: CHRONIC/2 YR CARCINOGENIC

ANIMAL NUMBER: 322/PRETEST=

322 SEX: FEMALE

DOSE GROUP: 2

SACRIFICE STATUS: SACRIFICED MORIBUND

DATE OF DEATH: 29-JAN-86

STUDY DAY OF DEATH: 738

STUDY WEEK OF DEATH: 106

TERMINAL BODY WEIGHT: 233.00 (GMS)

TISSUE / HISTOPATHOLOGIC FINDINGS

<< MICROSCOPIC TISSUE OBSERVATIONS >>  
DISTRIBUTION (SEVERITY) / SPECIAL COMMENTS

- KIDNEY ..... NOT SPECIFIED(MODERATE)
- PROGRESSIVE RENAL DISEASE
- PANCREAS ..... FOCAL(TRACE)
- ACINAR (EXOCRINE) ATROPHY
- SCIATIC NERVE ..... TISSUE IS MISSING
- MAMMARY GLANDS ..... NOT SPECIFIED(MARKED)
- HYPERPLASIA AND/OR HYPERTROPHY OF THE ACINAR TISSUE
- ADRENAL ..... MULTI-FOCAL(MILD)
- FOCUS OF CELLULAR ALTERATION, VACUOLATED
- PITUITARY GLAND ..... (PRESENT)
- B- ADENOMA

Appendix J (cont.): PATHOLOGY INDIVIDUAL ANIMAL DATA

LETTERMAN ARMY INSTITUTE OF RESEARCH  
 DIV OF RES SUPP, PATH SERV GP  
 SPECIES: RAT/FISCHER-344

INDIVIDUAL ANIMAL DATA REPORT  
 STUDY NUMBER: GLP83009  
 STUDY START DATE: 23-JAN-84

PRINTED: 21-NOV-89  
 PAGE: 639  
 STUDY TYPE: CHRONIC/2 YR CARCINOGENIC

ANIMAL NUMBER: 323/PRETEST= 323 SEX: FEMALE DOSE GROUP: 2 SACRIFICE STATUS: SACRIFICED MORIBUND  
 DATE OF DEATH: 13-SEP-85 STUDY DAY OF DEATH: 600 STUDY WEEK OF DEATH: 86 TERMINAL BODY WEIGHT: 223.00 (GMS)

<<	GROSS	ORGAN	OBSERVATIONS	>>
	KEYWORDS / PHRASES		SEVERITY	GROSS FREE-TEXT COMMENTS
SKIN	SUBCUTANEOUS MASS		PRESENT	LEFT VENTRAL SHOULDER AREA, FIRM, WHITE, 1CM DIAMETER
THYROID	DISCOLORATION		PRESENT	RIGHT, RED, FOCAL, .2CM DIAMETER
ADRENAL	ENLARGED, UNILATERALLY		MARKED	LEFT, 1.6CM
LIVER	ADHESION(S)		PRESENT	DIAPHRAGM
KIDNEY	DISCOLORATION		PRESENT	LIGHT BROWN WITH MULTIPLE PINPOINT RED FOCI.

<< MICROSCOPIC TISSUE OBSERVATIONS >>  
 DISTRIBUTION (SEVERITY) / SPECIAL COMMENTS

THYROID GLANDS ..... (PRESENT)  
 -8- PARA-FOLLICULAR CELL ADENOMA

EXORBITAL LACRIM ..... NOT SPECIFIED(TRACE)  
 -ACINAR ATROPHY

HEART ..... NOT SPECIFIED(MILD)  
 -CARDIOMYOPATHY ..... NOT SPECIFIED(TRACE)  
 -MEDIAL HYPERTROPHY OF MUSCULAR ARTERIES

LUNGS ..... MULTI-FOCAL(MILD)  
 -PNEUMONIA, INTERSTITIAL, CHRONIC

LYMPH NODES ..... RBC'S AND PIGMENT PRESENT IN MEDIASTINAL NODE.  
 -RED BLOOD CELLS, HEMOSIDERIN AND/OR ERYTHROPHAGOCYTOSIS WITHIN ..... NOT SPECIFIED (PRESENT)  
 MEDULLARY SINUSES

LIVER ..... NOT SPECIFIED (PRESENT)  
 -COMPOUND RELATED INFLAMMATORY REACTION ..... NOT SPECIFIED(MILD)  
 -BILE DUCTULE EPITHELIAL HYPERPLASIA AND/OR CHOLANGIOFIBROSIS ..... MULTI-FOCAL(MODERATE)  
 -NECROSIS, PERIACINAR

KIDNEY .....

Appendix J (cont.): PATHOLOGY INDIVIDUAL ANIMAL DATA

LETTERMAN ARMY INSTITUTE OF RESEARCH  
DIV OF RES SUPP, PATH SERV GP  
SPECIES: RAT/FISCHER-344

INDIVIDUAL ANIMAL DATA REPORT  
STUDY NUMBER: GLP83009

PRINTED: 21-NOV-89  
PAGE: 640

STUDY START DATE: 23-JAN-84

STUDY TYPE: CHRONIC/2 YR CARCINOGENIC

ANIMAL NUMBER: 323/PRETEST-  
DATE OF DEATH: 13-SEP-85

DOSE GROUP: 2  
SEX: FEMALE  
SACRIFICE STATUS: SACRIFICED MORIBUND

STUDY WEEK OF DEATH: 86  
TERMINAL BODY WEIGHT: 223.00 (GMS)

TISSUE / HISTOPATHOLOGIC FINDINGS

<< M I C R O S C O P I C T I S S U E O B S E R V A T I O N S >>  
DISTRIBUTION (SEVERITY) / SPECIAL COMMENTS

KIDNEY ..... NOT SPECIFIED(MILD)  
-PROGRESSIVE RENAL DISEASE

URINARY BLADDER .....  
-CHRONIC INFLAMMATORY CELL INFILTRATION

SCIATIC NERVE ..... TISSUE IS MISSING  
DIFFUSE(TRACE)

MAMMARY GLANDS ..... THE SUBCUTANEOUS MASS IN THE LEFT SHOULDER AREA IS A MAMMARY  
ADENOCARCINOMA. IT WAS CODED UNDER MAMMARY GLAND.  
-HYPERPLASIA AND/OR HYPERTROPHY OF THE ACINAR TISSUE  
-DILATATION (ECTASIA) OF DUCTS AND DUCTULES  
-M- MAMMARY ADENOCARCINOMA

ADRENAL ..... NOT SPECIFIED(MILD)  
-FOCUS OF CELLULAR ALTERATION, VACUOLATED  
-B- PHEOCHROMOCYTOMA

EYES & OPTIC N. .... THE LENS IS MISSING FROM BOTH EYE SECTIONS.

THORAX ..... MISCELLANEOUS TISSUE  
MASS ON THE LEFT VENTRAL SHOULDER AREA IS A MAMMARY ADENOCA.  
IT WAS CODED UNDER MAMMARY GLAND.

DIAPHRAGM ..... MISCELLANEOUS TISSUE  
-COMPOUND RELATED INFLAMMATORY REACTION  
NOT SPECIFIED (PRESENT)



Appendix J (cont.): PATHOLOGY INDIVIDUAL ANIMAL DATA

LETTERMAN ARMY INSTITUTE OF RESEARCH  
 DIV OF RES SUPP, PATH SERV GP  
 SPECIES: RAT/FISCHER-344

INDIVIDUAL ANIMAL DATA REPORT  
 STUDY NUMBER: GLP83009  
 STUDY START DATE: 23-JAN-84

PRINTED: 21-NOV-89  
 PAGE: 642  
 STUDY TYPE: CHRONIC/2 YR CARCINOGENIC

ANIMAL NUMBER: 325/PRETEST= 325 SEX: FEMALE DOSE GROUP: 2 SACRIFICE STATUS: FINAL SACRIFICE  
 DATE OF DEATH: 12-FEB-86 STUDY DAY OF DEATH: 752 STUDY WEEK OF DEATH: 108 TERMINAL BODY WEIGHT: 246.00 (GMS)

<< GROSS ORGAN OBSERVATIONS >>  
 SEVERITY GROSS FREE-TEXT COMMENTS  
 KEYWORD / PHRASES  
 ADHESION(S)  
 PITUITARY GLAND DISCOLORATION  
 PRESENT DIAPHRAGM, VENTRAL ABDOMINAL WALL  
 PRESENT FOCAL, BLACK, .2CM DIAMETER

<< MICROSCOPIC TISSUE OBSERVATIONS >>  
 DISTRIBUTION (SEVERITY) / SPECIAL COMMENTS

HEART ..... NOT SPECIFIED(MILD)  
 -CARDIOMYOPATHY

LUNGS ..... NOT SPECIFIED(TRACE)  
 -MINERALIZATION OF PULMONARY ARTERIES

LYMPH NODES ..... REACTIVE HYPERPLASIA NOTED IN CERVICAL NODES.  
 -REACTIVE HYPERPLASIA

LIVER ..... NOT SPECIFIED (PRESENT)  
 -COMPOUND RELATED INFLAMMATORY REACTION  
 -BILE DUCTULE EPITHELIAL HYPERPLASIA AND/OR CHOLANGIOFIBROSIS  
 -HEPATITIS  
 -FOCUS OF CELLULAR ALTERATION - BASOPHILIC  
 -HEPATOCTYE COALESCING MICROVESICULAR (PATTY) CHANGE LEADING TO  
 NECROSIS AND MINERALIZATION

KIDNEY ..... NOT SPECIFIED(TRACE)  
 -PROGRESSIVE RENAL DISEASE

MAMMARY GLANDS ..... SECTION #15 CONTAINS NO MAMMARY TISSUE. DIAGNOSIS OF ACINAR  
 HYPERPLASIA IS BASED ON MAMMARY TISSUE PRESENT IN SECTION #4.  
 NOT SPECIFIED(MILD)

-HYPERPLASIA AND/OR HYPERTROPHY OF THE ACINAR TISSUE  
 NOSE/TURBINATES ..... CELLULAR INFILTRATE IS ADJACENT NASO-LACRIMAL DUCT.  
 -MIXED INFLAMMATORY CELL INFILTRATION, NASAL CAVITY, SINUSES, NOT SPECIFIED(MILD)  
 TURBINATES, NASO-LACRIMAL DUCTS

ADRENAL .....

Appendix J (cont.): PATHOLOGY INDIVIDUAL ANIMAL DATA

LETTERMAN ARMY INSTITUTE OF RESEARCH  
 DIV OF RES SUPP, PATH SERV GP  
 SPECIES: RAT/FISCHER-344  
 STUDY START DATE: 23-JAN-84  
 INDIVIDUAL ANIMAL DATA REPORT  
 STUDY NUMBER: GLP83009  
 PRINTED: 21-NOV-89  
 PAGE: 643

ANIMAL NUMBER: 325/PRETEST= 325 SEX: FEMALE DOSE GROUP: 2 SACRIFICE STATUS: FINAL SACRIFICE  
 DATE OF DEATH: 12-FEB-86 STUDY DAY OF DEATH: 752 STUDY WEEK OF DEATH: 108 TERMINAL BODY WEIGHT: 246.00 (GMS)  
 STUDY TYPE: CHRONIC/2 YR CARCINOGENIC

<< MICROSCOPIC TISSUE OBSERVATIONS >>  
 DISTRIBUTION (SEVERITY) / SPECIAL COMMENTS

ADRENAL ..... NOT SPECIFIED (TRACE)  
 -FOCUS OF CELLULAR ALTERATION, VACUOLATED

EYES & OPTIC N. .... THE LENS IS MISSING FROM SECTION #19A.  
 -RETINAL ATROPHY AND/OR DEGENERATION, UNILATERAL OR BILATERAL ..... NOT SPECIFIED (MODERATE)

DIAPHRAGM ..... MISCELLANEOUS TISSUE  
 -COMPOUND RELATED INFLAMMATORY REACTION ..... NOT SPECIFIED (PRESENT)

Appendix J (cont.): PATHOLOGY INDIVIDUAL ANIMAL DATA

LETTERMAN ARMY INSTITUTE OF RESEARCH  
 DIV OF RES SUPP, PATH SERV GP  
 SPECIES: RAT/FISCHER-344  
 INDIVIDUAL ANIMAL DATA REPORT  
 STUDY NUMBER: GLP83009  
 STUDY START DATE: 23-JAN-84  
 PRINTED: 21-NOV-89  
 PAGE: 644  
 STUDY TYPE: CHRONIC/2 YR CARCINOGENIC

ANIMAL NUMBER: 326/PRETEST# 326 SEX: FEMALE DOSE GROUP: 2 SACRIFICE STATUS: FINAL SACRIFICE  
 DATE OF DEATH: 12-FEB-86 STUDY DAY OF DEATH: 752 STUDY WEEK OF DEATH: 108 TERMINAL BODY WEIGHT: 238.00 (GMS)

ORGAN NAME << GROSS ORGAN OBSERVATIONS >>  
 KEYWORDS / PHRASES SEVERITY GROSS FREE-TEXT COMMENTS

OVARIES PRESENT BILATERAL, LEFT 1.5CM DIAMETER, RIGHT 1CM DIAMETER  
 LIVER PRESENT DIAPHRAGM, VENTRAL ABDOMINAL WALL

TISSUE / HISTOPATHOLOGIC FINDINGS << MICROSCOPIC TISSUE OBSERVATIONS >>  
 DISTRIBUTION (SEVERITY) / SPECIAL COMMENTS

PARATHYROID ..... TISSUE IS MISSING  
 LACRIMAL GLAND ..... MULTI-FOCAL(TRACE)  
 -INFLAMMATION, SUBACUTE TO CHRONIC

HEART ..... NOT SPECIFIED(MILD)  
 -CARDIOMYOPATHY

LUNGS ..... NOT SPECIFIED(TRACE)  
 -MINERALIZATION OF PULMONARY ARTERIES  
 -ALVEOLAR HEMORRHAGE MULTI-FOCAL (PRESENT)

LYMPH NODES ..... REACTIVE HYPERPLASIA NOTED IN CERVICAL NODES. PIGMENT IS  
 -RED BLOOD CELLS, HEMOSIDERIN AND/OR ERYTHROPHAGOCYTOSIS WITHIN PRESENT IN MEDIASTINAL NODE.  
 MEDULLARY SINUSES NOT SPECIFIED (PRESENT)  
 -REACTIVE HYPERPLASIA NOT SPECIFIED (PRESENT)

LIVER ..... NOT SPECIFIED (PRESENT)  
 -COMPOUND RELATED INFLAMMATORY REACTION NOT SPECIFIED(TRACE)  
 -BILE DUCTULE EPITHELIAL HYPERPLASIA AND/OR CHOLANGIOFIBROSIS MULTI-FOCAL(MILD)  
 -HEPATITIS MULTI-FOCAL(MODERATE)  
 -HEPATOCTYCE COALESCING MICROVESICULAR (FATTY) CHANGE LEADING TO  
 NECROSIS AND MINERALIZATION

KIDNEY .....

Appendix J (cont.): PATHOLOGY INDIVIDUAL ANIMAL DATA

LETTERMAN ARMY INSTITUTE OF RESEARCH  
 DIV OF RES SUPP, PATH SERV GP  
 SPECIES: RAT/FISCHER-344  
 STUDY START DATE: 23-JAN-84  
 STUDY NUMBER: GLP83009  
 PRINTED: 21-NOV-89  
 PAGE: 645

ANIMAL NUMBER: 326/PRETEST=  
 DATE OF DEATH: 12-FEB-86  
 STUDY DAY OF DEATH: 752  
 SEX: FEMALE  
 DOSE GROUP: 2  
 SACRIFICE STATUS: FINAL SACRIFICE  
 STUDY WEEK OF DEATH: 108  
 TERMINAL BODY WEIGHT: 238.00 (GMS)

STUDY TYPE: CHRONIC/2 YR CARCINOGENIC

TISSUE / HISTOPATHOLOGIC FINDINGS  
 << MICROSCOPIC TISSUE OBSERVATIONS >>  
 DISTRIBUTION (SEVERITY) / SPECIAL COMMENTS

- KIDNEY ..... NOT SPECIFIED (TRACE)
- PROGRESSIVE RENAL DISEASE
- OVARIES ..... NOT SPECIFIED (PRESENT)
- PARA-OVARIAN CYST(S)
- MAMMARY GLANDS ..... NOT SPECIFIED (TRACE)
- HYPERPLASIA AND/OR HYPERTROPHY OF THE ACINAR TISSUE
- DILATATION (ECTASIA) OF DUCTS AND DUCTULES
- NOSE/TURBINATES ..... CELLULAR INFILTRATE IS ADJACENT TO NASO-LACRIMAL DUCT.
- MIXED INFLAMMATORY CELL INFILTRATION, NASAL CAVITY, SINUSES,  
 TURBINATES, NASO-LACRIMAL DUCTS
- ADRENAL ..... NOT SPECIFIED (PRESENT)
- CORTICAL NODULAR HYPERPLASIA
- EYES & OPTIC N. .... CONJUNCTIVITIS IS PRESENT IN TISSUE ATTACHED TO THE LACRIMAL  
 GLAND IN SECTION #3. NO CONJUNCTIVAL TISSUE IS PRESENT IN  
 SECTIONS OF EYES. THE LENS IS NOT PRESENT IN SECTION #19A.
- METAPLASTIC BONE FORMATION AND/OR MINERALIZATION, SCLERA
- CHRONIC CONJUNCTIVITIS

Appendix J (cont.): PATHOLOGY INDIVIDUAL ANIMAL DATA

LETTERMAN ARMY INSTITUTE OF RESEARCH  
 DIV OF RES SUPP, PATH SERV GP  
 SPECIES: RAT/FISCHER-344  
 ANIMAL NUMBER: 327/PRETEST= 327 SEX: FEMALE DOSE GROUP: 2 SACRIFICE STATUS: FINAL SACRIFICE  
 DATE OF DEATH: 12-FEB-86 STUDY DAY OF DEATH: 752 STUDY WEEK OF DEATH: 108 TERMINAL BODY WEIGHT: 269.00 (GMS)  
 STUDY START DATE: 23-JAN-84 STUDY TYPE: CHRONIC/2 YR CARCINOGENIC  
 INDIVIDUAL ANIMAL DATA REPORT  
 STUDY NUMBER: GLP83009  
 PRINTED: 21-NOV-89  
 PAGE: 646

<< GROSS ORGAN OBSERVATIONS >>  
 SEVERITY GROSS FREE-TEXT COMMENTS  
 KEYWORDS / PHRASES PRESENT DIAPHRAGM  
 ADHESION(S)

<< MICROSCOPIC TISSUE OBSERVATIONS >>  
 DISTRIBUTION (SEVERITY) / SPECIAL COMMENTS

EXORBITAL LACRIM ..... MULTI-FOCAL(MILD)  
 -ACINAR ATROPHY

HEART ..... NOT SPECIFIED(MILD)  
 -CARDIOMYOPATHY

LUNGS ..... NOT SPECIFIED(TRACE)  
 -MINERALIZATION OF PULMONARY ARTERIES

LIVER ..... NOT SPECIFIED (PRESENT)  
 -COMPOUND RELATED INFLAMMATORY REACTION  
 -BILE DUCTULE EPITHELIAL HYPERPLASIA AND/OR CHOLANGIOFIBROSIS  
 -HEPATOCYTE COALESCING MICROVESICULAR (FATTY) CHANGE LEADING TO  
 NECROSIS AND MINERALIZATION

KIDNEY ..... NOT SPECIFIED(MILD)  
 -PROGRESSIVE RENAL DISEASE

UTERUS ..... FOCAL(TRACE)  
 -LYMPHOCYTTIC INFILTRATE

PANCREAS ..... MULTI-FOCAL(TRACE)  
 -ACINAR (EXOCRINE) ATROPHY

MAMMARY GLANDS ..... NOT SPECIFIED(MILD)  
 -HYPERPLASIA AND/OR HYPERTROPHY OF THE ACINAR TISSUE

Appendix J (cont.): PATHOLOGY INDIVIDUAL ANIMAL DATA

LETTERMAN ARMY INSTITUTE OF RESEARCH  
DIV OF RES SUPP. PATH SERV GP  
SPECIES: RAT/FISCHER-344

INDIVIDUAL ANIMAL DATA REPORT  
STUDY NUMBER: GLP83009  
STUDY START DATE: 23-JAN-84

PRINTED: 21-NOV-89  
PAGE: 647

STUDY TYPE: CHRONIC/2 YR CARCINOGENIC

ANIMAL NUMBER: 327/PRETEST= 327 SEX: FEMALE DOSE GROUP: 2 SACRIFICE STATUS: FINAL SACRIFICE  
DATE OF DEATH: 12-FEB-86 STUDY DAY OF DEATH: 752 STUDY WEEK OF DEATH: 108 TERMINAL BODY WEIGHT: 269.00 (GMS)

TISSUE / HISTOPATHOLOGIC FINDINGS << MICROSCOPIC TISSUE OBSERVATIONS >>  
DISTRIBUTION (SEVERITY) / SPECIAL COMMENTS

MAMMARY GLANDS ..... NOT SPECIFIED (PRESENT)  
-DILATATION (ECTASIA) OF DUCTS AND DUCTULES

ADRENAL ..... NOT SPECIFIED (PRESENT)  
-CORTICAL NODULAR HYPERPLASIA

Appendix J (cont.): PATHOLOGY INDIVIDUAL ANIMAL DATA

LETTERMAN ARMY INSTITUTE OF RESEARCH  
 DIV OF RES SUPP, PATH SERV GP  
 SPECIES: RAT/FISCHER-344  
 ANIMAL NUMBER: 328/PRETEST= 328 SEX: FEMALE DOSE GROUP: 2 SACRIFICE STATUS: FINAL SACRIFICE  
 DATE OF DEATH: 12-FEB-86 STUDY DAY OF DEATH: 752 STUDY WEEK OF DEATH: 108 TERMINAL BODY WEIGHT: 228.00 (GMS)  
 STUDY START DATE: 23-JAN-84 STUDY TYPE: CHRONIC/2 YR CARCINOGENIC

PRINTED: 21-NOV-89  
 PAGE: 648

<< GROSS ORGAN OBSERVATIONS >>  
 SEVERITY GROSS FREE-TEXT COMMENTS  
 KEYWORDS / PHRASES PRESENT VENTRAL ABDOMINAL WALL  
 ADHESION(S) PRESENT BILATERAL  
 HYDROMETRA

<< MICROSCOPIC TISSUE OBSERVATIONS >>  
 DISTRIBUTION (SEVERITY) / SPECIAL COMMENTS

THYROID GLANDS ..... TISSUE IS MISSING  
 PARATHYROID ..... TISSUE IS MISSING  
 HEART ..... NOT SPECIFIED(MODERATE)  
 -CARDIOMYOPATHY  
 LUNGS ..... NOT SPECIFIED(TRACE)  
 -MINERALIZATION OF PULMONARY ARTERIES  
 LYMPH NODES ..... REACTIVE HYPERPLASIA NOTED IN CERVICAL NODES.  
 -REACTIVE HYPERPLASIA  
 LIVER ..... NOT SPECIFIED (PRESENT)  
 -COMPOUND RELATED INFLAMMATORY REACTION NOT SPECIFIED(TRACE)  
 -BILE DUCTULE EPITHELIAL HYPERPLASIA AND/OR CHOLANGIOFIBROSIS MULTI-FOCAL(MILD)  
 -HEPATITIS MULTI-FOCAL(MILD)  
 -HEPATOCYTE COALESCING MICROVESICULAR (FATTY) CHANGE LEADING TO NECROSIS AND MINERALIZATION  
 KIDNEY ..... NOT SPECIFIED(MODERATE)  
 -PROGRESSIVE RENAL DISEASE  
 UTERUS ..... NOT SPECIFIED (PRESENT)  
 -DILATATION OF THE UTERINE LUMEN (HYDROMETRA)  
 -CYSTIC DILATATION OF THE ENDOMETRIAL GLANDS  
 MAMMARY GLANDS .....

Appendix J (cont.): PATHOLOGY INDIVIDUAL ANIMAL DATA

LETTERMAN ARMY INSTITUTE OF RESEARCH  
DIV OF RES SUPP, PATH SERV GP  
SPECIES: RAT/FISCHER-344

INDIVIDUAL ANIMAL DATA REPORT  
STUDY NUMBER: GLP83009  
STUDY START DATE: 23-JAN-84

PRINTED: 21-NOV-89  
PAGE: 649  
STUDY TYPE: CHRONIC/2 YR CARCINOGENIC

ANIMAL NUMBER: 328/PRETEST= 328 SEX: FEMALE DOSE GROUP: 2 SACRIFICE STATUS: FINAL SACRIFICE  
DATE OF DEATH: 12-FEB-86 STUDY DAY OF DEATH: 752 STUDY WEEK OF DEATH: 108 TERMINAL BODY WEIGHT: 228.00 (GMS)

TISSUE / HISTOPATHOLOGIC FINDINGS << MICROSCOPIC TISSUE OBSERVATIONS >>  
DISTRIBUTION (SEVERITY) / SPECIAL COMMENTS

MAMMARY GLANDS .....  
-HYPERPLASIA AND/OR HYPERTROPHY OF THE ACINAR TISSUE ..... NOT SPECIFIED(MILD)  
-DILATATION (ECTASIA) OF DUCTS AND DUCTULES ..... NOT SPECIFIED (PRESENT)

BONE, FEMUR .....  
-HYPERPLASIA MYELOID ..... NOT SPECIFIED (PRESENT)

ADRENAL .....  
-FOCUS OF CELLULAR ALTERATION, VACUOLATED ..... NOT SPECIFIED(TRACE)



Appendix J (cont.): PATHOLOGY INDIVIDUAL ANIMAL DATA

LETTERMAN ARMY INSTITUTE OF RESEARCH  
 DIV OF RES SUPP, PATH SERV GP  
 SPECIES: RAT/FISCHER-344

INDIVIDUAL ANIMAL DATA REPORT  
 STUDY NUMBER: GLP83009  
 STUDY START DATE: 23-JAN-84

PRINTED: 21-NOV-89  
 PAGE: 650  
 STUDY TYPE: CHRONIC/2 YR CARCINOGENIC

ANIMAL NUMBER: 329/PRETEST= 329 SEX: FEMALE DOSE GROUP: 2 SACRIFICE STATUS: SACRIFICED MORIBUND  
 DATE OF DEATH: 03-DEC-85 STUDY DAY OF DEATH: 681 STUDY WEEK OF DEATH: 98 TERMINAL BODY WEIGHT: 201.00 (GMS)

<< GROSS ORGAN OBSERVATIONS >>  
 SEVERITY GROSS FREE-TEXT COMMENTS  
 -----  
 SPLEEN ENLARGED (SPLENOHEGALY) MARKED 6 X 1.5 X 1CM  
 LIVER ADHESION(S) PRESENT DIAPHRAGM, VENTRAL ABDOMINAL WALL  
 LIVER GRANULAR SURFACE PRESENT  
 UTERUS DISTENDED PRESENT DISTAL END OF RIGHT HORN, SEGMENTAL, 8MM DIAMETER

<< MICROSCOPIC TISSUE OBSERVATIONS >>  
 DISTRIBUTION (SEVERITY) / SPECIAL COMMENTS  
 -----

THYROID GLANDS ..... NOT SPECIFIED (TRACE)  
 -PARA-FOLLICULAR CELL HYPERPLASIA ("C" CELL, LIGHT CELL)

PARATHYROID ..... TISSUE IS MISSING

HEART .....  
 -CARDIOMYOPATHY ..... NOT SPECIFIED (TRACE)  
 -N- LARGE GRANULAR LYMPHOCYTE LEUKEMIA, METASTATIC (PRESENT)

LUNGS ..... (PRESENT)  
 -N- LARGE GRANULAR LYMPHOCYTE LEUKEMIA, METASTATIC (PRESENT)

THYMUS ..... (PRESENT)  
 -N- LARGE GRANULAR LYMPHOCYTE LEUKEMIA, METASTATIC (PRESENT)

SPLEEN .....  
 -INFARCTION, CHRONIC ..... NOT SPECIFIED (MILD)  
 -N- LARGE GRANULAR LYMPHOCYTE LEUKEMIA, METASTATIC (PRESENT)

LYMPH NODES ..... METASTATIC LGLL NOTED IN MEDIASTINAL AND MESENTERIC NODES.  
 -RED BLOOD CELLS, HEMOSIDERIN AND/OR ERYTHROPHAGOCYTOSIS WITHIN BROWN GRANULAR PIGMENT IS PRESENT IN MEDIASTINAL NODES.  
 MEDULLARY SINUSES NOT SPECIFIED (PRESENT)

-N- LARGE GRANULAR LYMPHOCYTE LEUKEMIA, METASTATIC (PRESENT)

LIVER .....

Appendix J (cont.): PATHOLOGY INDIVIDUAL ANIMAL DATA

LETTERMAN ARMY INSTITUTE OF RESEARCH INDIVIDUAL ANIMAL DATA REPORT PRINTED: 21-NOV-89  
DIV OF RES SUPP, PATH SERV GP STUDY NUMBER: GLP63009 PAGE: 651  
SPECIES: RAT/FISCHER-344 STUDY START DATE: 23-JAN-84 STUDY TYPE: CHRONIC/2 YR CARCINOGENIC

ANIMAL NUMBER: 329/PRETEST-2 DOSE GROUP: 2 SACRIFICE STATUS: SACRIFICED MORIBUND  
DATE OF DEATH: 03-DEC-85 STUDY DAY OF DEATH: 681 STUDY WEEK OF DEATH: 98 TERMINAL BODY WEIGHT: 201.00 (GMS)

<< MICROSCOPIC TISSUE OBSERVATIONS >>  
TISSUE / HISTOPATHOLOGIC FINDINGS DISTRIBUTION (SEVERITY) / SPECIAL COMMENTS

LIVER ..... NOT SPECIFIED (PRESENT)  
-COMPOUND RELATED INFLAMMATORY REACTION ..... NOT SPECIFIED (TRACE)  
-BILE DUCTULE EPITHELIAL HYPERPLASIA AND/OR CHOLANGIOFIBROSIS ..... NOT SPECIFIED (TRACE)  
-NECROSIS, PERIACINAR ..... MULTI-FOCAL(MILD)  
-N- LARGE GRANULAR LYMPHOCYTE LEUKEMIA, METASTATIC ..... (PRESENT)

KIDNEY ..... NOT SPECIFIED (TRACE)  
-PROGRESSIVE RENAL DISEASE

UTERUS ..... NOT SPECIFIED (PRESENT)  
-ENDOMETRIAL STROMAL POLYP ..... (PRESENT)  
-N- LARGE GRANULE LYMPHOCYTE LEUKEMIA, METASTATIC

OVARIES ..... (PRESENT)  
-N- LARGE GRANULE LYMPHOCYTE LEUKEMIA, METASTATIC

PANCREAS ..... (PRESENT)  
-N- LARGE GRANULAR LYMPHOCYTE LEUKEMIA, METASTATIC

MAMMARY GLANDS ..... NOT SPECIFIED (MILD)  
-HYPERPLASIA AND/OR HYPERTROPHY OF THE ACINAR TISSUE ..... NOT SPECIFIED (PRESENT)  
-DILATATION (ECTASIA) OF DUCTS AND DUCTULES

NOSE/TURBINATES ..... CELLULAR INFILTRATE IS ADJACENT TO NASO-LACRIMAL DUCTS.  
-MIXED INFLAMMATORY CELL INFILTRATION, NASAL CAVITY, SINUSES, ..... NOT SPECIFIED (MILD)  
TURBINATES, NASO-LACRIMAL DUCTS

BONE, STERNUM ..... (PRESENT)  
-N- LARGE GRANULE LYMPHOCYTE LEUKEMIA, METASTATIC

BONE, FEMUR ..... (PRESENT)  
-N- LARGE GRANULE LYMPHOCYTE LEUKEMIA, METASTATIC

BONE VERT ..... (PRESENT)

Appendix J (cont.): PATHOLOGY INDIVIDUAL ANIMAL DATA

LETTERMAN ARMY INSTITUTE OF RESEARCH  
DIV OF RES SUPP, PATH SERV GP  
SPECIES: RAT/FISCHER-344

INDIVIDUAL ANIMAL DATA REPORT  
STUDY NUMBER: GLP83009

PRINTED: 21-NOV-89  
PAGE: 652

STUDY START DATE: 23-JAN-84

STUDY TYPE: CHRONIC/2 YR CARCINOGENIC

ANIMAL NUMBER: 329/PRETEST=

329 SEX: FEMALE DOSE GROUP: 2

SACRIFICE STATUS: SACRIFICED MORIBUND

DATE OF DEATH: 03-DEC-85

STUDY DAY OF DEATH: 681

STUDY WEEK OF DEATH: 98

TERMINAL BODY WEIGHT: 201.00 (GMS)

TISSUE / HISTOPATHOLOGIC FINDINGS

<< MICROSCOPIC TISSUE OBSERVATIONS >>  
DISTRIBUTION (SEVERITY) / SPECIAL COMMENTS

- BONE VERT ..... (PRESENT)
- M- LARGE GRANULE LYMPHOCYTE LEUKEMIA, METASTATIC
- ADRENAL ..... (PRESENT)
- M- LARGE GRANULE LYMPHOCYTE LEUKEMIA, METASTATIC
- WHOLE BODY ..... (PRESENT)
- M- LARGE GRANULAR LYMPHOCYTTIC LEUKEMIA

Appendix J (cont.): PATHOLOGY INDIVIDUAL ANIMAL DATA

LETTERMAN ARMY INSTITUTE OF RESEARCH  
 DIV OF RES SUPP, PATH SERV GP  
 SPECIES: RAT/FISCHER-344  
 STUDY NUMBER: GLP83009  
 STUDY START DATE: 23-JAN-84  
 STUDY TYPE: CHRONIC/2 YR CARCINOGENIC  
 ANIMAL NUMBER: 330/PRETEST= 330 SEX: FEMALE DOSE GROUP: 2 SACRIFICE STATUS: SACRIFICED MORIBUND  
 DATE OF DEATH: 29-DEC-85 STUDY DAY OF DEATH: 707 STUDY WEEK OF DEATH: 101 TERMINAL BODY WEIGHT: 213.00 (GMS)

PRINTED: 21-NOV-89  
 PAGE: 653

ORGAN NAME << GROSS ORGAN OBSERVATIONS >>  
 SEVERITY GROSS FREE-TEXT COMMENTS  
 LIVER ADHESION(S) PRESENT DIAPHRAGM AND ABDOMINAL WALL  
 SPLEEN ENLARGED (SPLENOHEGALY) MILD  
 KIDNEY DISCOLORATION PRESENT FOCAL .2CM DIAMETER, WHITE, CAPSULAR  
 PITUITARY GLAND ENLARGED PRESENT .5CM DIAMETER, BLACK/RED  
 UTERUS GROWTH(S)/MASS(S) PRESENT RIGHT HORN, BROWN, .8 X .2CM

TISSUE / HISTOPATHOLOGIC FINDINGS << MICROSCOPIC TISSUE OBSERVATIONS >>  
 DISTRIBUTION (SEVERITY) / SPECIAL COMMENTS

THYROID GLANDS ..... TISSUE IS MISSING  
 PARATHYROID ..... TISSUE IS MISSING  
 HEART ..... NOT SPECIFIED(TRACE)  
 -CARDIOMYOPATHY ..... NOT SPECIFIED(TRACE)  
 -MEDIAL HYPERTROPHY OF MUSCULAR ARTERIES .....  
 LUNGS ..... NOT SPECIFIED(TRACE)  
 -MINERALIZATION OF PULMONARY ARTERIES ..... (PRESENT)  
 -N- LARGE GRANULAR LYMPHOCYTE LEUKEMIA, METASTATIC ..... TISSUE IS MISSING  
 THYMUS ..... TISSUE IS MISSING  
 SPLEEN ..... (PRESENT)  
 -N- LARGE GRANULAR LYMPHOCYTE LEUKEMIA, METASTATIC .....  
 LYMPH NODES ..... REACTIVE HYPERPLASIA NOTED IN CERVICAL NODES.  
 -REACTIVE HYPERPLASIA ..... NOT SPECIFIED (PRESENT)  
 LIVER ..... DIFFUSE(MARKED)  
 -HEPATOCTYIC VACUOLIZATION ..... NOT SPECIFIED(MILD)  
 -HEPATOCTYIC DEGENERATIVE CHANGES (NON-NECROTIC) .....

**Appendix J (cont.): PATHOLOGY INDIVIDUAL ANIMAL DATA**

LETTERMAN ARMY INSTITUTE OF RESEARCH  
 DIV OF RES SUPP, PATH SERV GP  
 SPECIES: RAT/FISCHER-344  
 STUDY START DATE: 23-JAN-84  
 INDIVIDUAL ANIMAL DATA REPORT  
 STUDY NUMBER: GLP83009  
 PRINTED: 21-NOV-89  
 PAGE: 654  
 STUDY TYPE: CHRONIC/2 YR CARCINOGENIC

ANIMAL NUMBER: 330/PRETEST\*  
 DOSE GROUP: 2  
 SACRIFICE STATUS: SACRIFICED MORIBUND  
 DATE OF DEATH: 29-DEC-85  
 STUDY DAY OF DEATH: 707  
 STUDY WEEK OF DEATH: 101  
 TERMINAL BODY WEIGHT: 213.00 (GMS)

TISSUE / HISTOPATHOLOGIC FINDINGS  
 << M I C R O S C O P I C T I S S U E O B S E R V A T I O N S >>  
 DISTRIBUTION (SEVERITY) / SPECIAL COMMENTS

LIVER ..... NOT SPECIFIED(MODERATE)  
 -NECROSIS, PERIACINAR (PRESENT)  
 -W- LARGE GRANULAR LYMPHOCYTE LEUKEMIA, METASTATIC

KIDNEY ..... NOT SPECIFIED(MILD)  
 -PROGRESSIVE RENAL DISEASE

UTERUS ..... NOT SPECIFIED (PRESENT)  
 -ENDOMETRIAL STROMAL POLYP

STOMACH ..... NOT SPECIFIED (PRESENT)  
 -ULCERATION, NON-GLANDULAR AREA  
 -MUCOSAL AND/OR SUBMUCOSAL EDEMA

MAMMARY GLANDS ..... NOT SPECIFIED(MARKED)  
 -HYPERPLASIA AND/OR HYPERTROPHY OF THE ACINAR TISSUE

NOSE/TURBINATES ..... CELLULAR INFILTRATE IS ADJACENT NASO-LACRIMAL DUCTS.  
 -MIXED INFLAMMATORY CELL INFILTRATION, NASAL CAVITY, SINUSES, NOT SPECIFIED(MILD)  
 TURBINATES, NASO-LACRIMAL DUCTS

ADRENAL ..... NOT SPECIFIED(MILD)  
 -FOCUS OF CELLULAR ALTERATION, VACUOLATED FOCAL(MILD)  
 -NECROSIS (PRESENT)

PITUITARY GLAND ..... NOT SPECIFIED(TRACE)  
 -B- ADENOMA NOT SPECIFIED (PRESENT)

EYES & OPTIC N. ..... NOT SPECIFIED(TRACE)  
 -CORNEAL MINERALIZATION NOT SPECIFIED(TRACE)  
 -CORNEAL VASCULARIZATION NOT SPECIFIED (PRESENT)  
 -METAPLASTIC BONE FORMATION AND/OR MINERALIZATION, SCLERA

WHOLE BODY .....

Appendix J (cont.): PATHOLOGY INDIVIDUAL ANIMAL DATA

LETTERMAN ARMY INSTITUTE OF RESEARCH  
DIV OF RES SUPP, PATH SERV GP  
SPECIES: RAT/FISCHER-344

INDIVIDUAL ANIMAL DATA REPORT  
STUDY NUMBER: GLP83009

PRINTED: 21-NOV-89  
PAGE: 655

STUDY START DATE: 23-JAN-84

STUDY TYPE: CHRONIC/2 YR CARCINOGENIC

ANIMAL NUMBER: 330/PRETEST=  
DATE OF DEATH: 29-DEC-85

SEX: FEMALE  
STUDY DAY OF DEATH: 707

DOSE GROUP: 2  
STUDY WEEK OF DEATH: 101

SACRIFICE STATUS: SACRIFICED MORIBUND  
TERMINAL BODY WEIGHT: 213.0g (GMS)

<< MICROSCOPIC TISSUE OBSERVATIONS >>  
DISTRIBUTION (SEVERITY) / SPECIAL COMMENTS

WHOLE BODY ..... (PRESENT)  
-M- LARGE GRANULAR LYMPHOCYTTIC LEUKEMIA

Appendix J (cont.): PATHOLOGY INDIVIDUAL ANIMAL DATA

LETTERMAN ARMY INSTITUTE OF RESEARCH  
 DIV OF RES SUPP, PATH SERV GP  
 SPECIES: RAT/FISCHER-344  
 STUDY START DATE: 23-JAN-84  
 STUDY NUMBER: GLP83009  
 PRINTED: 21-NOV-89  
 PAGE: 656  
 STUDY TYPE: CHRONIC/2 YR CARCINOGENIC  
 ANIMAL NUMBER: 321/PRETEST= 331 SEX: FEMALE DOSE GROUP: 2 SACRIFICE STATUS: FINAL SACRIFICE  
 DATE OF DEATH: 14-FEB-86 STUDY DAY OF DEATH: 754 STUDY WEEK OF DEATH: 108 TERMINAL BODY WEIGHT: 263.00 (GMS)  
 ORGAN NAME << GROSS ORGAN OBSERVATIONS >>  
 KEYWORDS / PHRASES SEVERITY GROSS FREE-TEXT COMMENTS  
 LIVER ADHESION(S) PRESENT DIAPHRAGM, VENTRAL ABDOMINAL WALL

TISSUE OBSERVATIONS >>  
 TISSUE / HISTOPATHOLOGIC FINDINGS DISTRIBUTION (SEVERITY) / SPECIAL COMMENTS

- THYROID GLANDS ..... NOT SPECIFIED(TRACE)
- PARA-FOLLICULAR CELL HYPERPLASIA (MC) CELL, LIGHT CELL
- HEART ..... NOT SPECIFIED(MILD)
- CARDIOMYOPATHY
- LUNGS ..... NOT SPECIFIED(MILD)
- MINERALIZATION OF PULMONARY ARTERIES
- LIVER ..... NOT SPECIFIED (PRESENT)
- COMPOUND RELATED INFLAMMATORY REACTION MULTI-FOCAL(MILD)
- HEPATITIS MULTI-FOCAL(MODERATE)
- HEPATOCTYE COALESCING MICROVESICULAR (FATTY) CHANGE LEADING TO NECROSIS AND MINERALIZATION
- KIDNEY ..... NOT SPECIFIED(TRACE)
- PROGRESSIVE RENAL DISEASE
- PANCREAS ..... MULTI-FOCAL(TRACE)
- ACINAR (EXOCRINE) ATROPHY
- MAMMARY GLANDS ..... NOT SPECIFIED(TRACE)
- HYPERPLASIA AND/OR HYPERTROPHY OF THE ACINAR TISSUE NOT SPECIFIED (PRESENT)
- DILATATION (ECTASIA) OF DUCTS AND DUCTULES
- NOSE/TURBINATES ..... CELLULAR INFILTRATE IS ADJACENT NASO-LACRIMAL DUCTS

Appendix J (cont.): PATHOLOGY INDIVIDUAL ANIMAL DATA

LETTERMAN ARMY INSTITUTE OF RESEARCH  
DIV OF RES SUPP, PATH SERV GP  
SPECIES: RAT/FISCHER-344

INDIVIDUAL ANIMAL DATA REPORT  
STUDY NUMBER: GLP83009

PRINTED: 21-NOV-89  
PAGE: 657

STUDY START DATE: 23-JAN-84

STUDY TYPE: CHRONIC/2 YR CARCINOGENIC

ANIMAL NUMBER: 331/PRETEST#  
DATE OF DEATH: 14-FEB-86

331 SEX: FEMALE  
STUDY DAY OF DEATH: 754

DOSE GROUP: 2  
STUDY WEEK OF DEATH: 108

SACRIFICE STATUS: FINAL SACRIFICE  
TERMINAL BODY WEIGHT: 263.00 (GMS)

<< MICROSCOPIC TISSUE OBSERVATIONS >>  
DISTRIBUTION (SEVERITY) / SPECIAL COMMENTS

NOSE/TURBINATES .....  
-MIXED INFLAMMATORY CELL INFILTRATION, NASAL CAVITY, SINUSES, NOT SPECIFIED(MILD)  
TURBINATES, NASO-LACRIMAL DUCTS

ADRENAL .....  
-FOCUS OF CELLULAR ALTERATION, VACUOLATED FOCAL(TRACE)

EYES & OPTIC N. ....  
-CORNEAL MINERALIZATION NOT SPECIFIED(TRACE)  
-CORNEAL VASCULARIZATION NOT SPECIFIED(TRACE)

DIAPHRAGM .....  
-COMPOUND RELATED INFLAMMATORY REACTION MISCELLANEOUS TISSUE NOT SPECIFIED (PRESENT)



Appendix J (cont.): PATHOLOGY INDIVIDUAL ANIMAL DATA

LETTERMAN ARMY INSTITUTE OF RESEARCH  
 DIV OF RES SUPP, PATH SERV GP  
 SPECIES: RAT/FISCHER-344  
 STUDY START DATE: 23-JAN-84  
 STUDY TYPE: CHRONIC/2 YR CARCINOGENIC  
 PRINTED: 21-NOV-89  
 PAGE: 658

INDIVIDUAL ANIMAL DATA REPORT  
 STUDY NUMBER: GLP83009

ANIMAL NUMBER: 332/PRETEST#  
 DATE OF DEATH: 16-AUG-85  
 SEX: FEMALE  
 DOSE GROUP: 2  
 SACRIFICE STATUS: SACRIFICED MORIBUND  
 STUDY DAY OF DEATH: 572  
 STUDY WEEK OF DEATH: 82  
 TERMINAL BODY WEIGHT: 311.00 (GMS)

ORGAN NAME: SKIN  
 LIVER  
 GROSS ORGAN OBSERVATIONS  
 SEVERITY GROSS FREE-TEXT COMMENTS  
 PRESENT LEFT AXILLARY REGION, SERIFIRM 4 x 2.5 x 2.5CM  
 PRESENT VENTRAL ABDOMINAL WALL, 1CM AREA

TISSUE / HISTOPATHOLOGIC FINDINGS  
 << MICROSCOPIC TISSUE OBSERVATIONS >>  
 DISTRIBUTION (SEVERITY) / SPECIAL COMMENTS

THYROID GLANDS  
 -PARA-FOLLICULAR CELL HYPERPLASIA (\*CM CELL, LIGHT CELL) NOT SPECIFIED(TRACE)

HEART  
 -CARDIOMYOPATHY NOT SPECIFIED(TRACE)

LYMPH NODES  
 -REACTIVE HYPERPLASIA REACTIVE HYPERPLASIA PRESENT IN CERVICAL NODES.  
 NOT SPECIFIED (PRESENT)

LIVER  
 -COMPOUND RELATED INFLAMMATORY REACTION NOT SPECIFIED (PRESENT)  
 -HEPATITIS MULTI-FOCAL(TRACE)  
 -FOCUS OF CELLULAR ALTERATION - BASOPHILIC MULTI-FOCAL(MILD)

KIDNEY  
 -PROGRESSIVE RENAL DISEASE NOT SPECIFIED(TRACE)

MAMMARY GLANDS  
 -HYPERPLASIA AND/OR HYPERTROPHY OF THE ACINAR TISSUE THE SUBCUTANEOUS MASS IN THE LEFT AXILLARY AREA IS A MAMMARY  
 -DILATATION (ECTASIA) OF DUCTS AND DUCTULES ADENOCARCINOMA.  
 -M- MAMMARY ADENOCARCINOMA NOT SPECIFIED(MILD)  
 NOT SPECIFIED (PRESENT)  
 (PRESENT)

BONE, FEMUR  
 -HYPERPLASIA MYELOID NOT SPECIFIED (PRESENT)

PITUITARY GLAND

Appendix J (cont.): PATHOLOGY INDIVIDUAL ANIMAL DATA

LETTERMAN ARMY INSTITUTE OF RESEARCH  
DIV OF RES SUPP, PATH SERV GP  
SPECIES: RAT/FISCHER-344

INDIVIDUAL ANIMAL DATA REPORT  
STUDY NUMBER: GLP83009

PRINTED: 21-NOV-89  
PAGE: 659

STUDY START DATE: 23-JAN-84

STUDY TYPE: CHRONIC/2 YR CARCINOGENIC

ANIMAL NUMBER: 332/PRETEST#  
DATE OF DEATH: 16-AUG-85

SEX: FEMALE  
STUDY DAY OF DEATH: 572

DOSE GROUP: 2  
SACRIFICE STATUS: SACRIFICED MORIBUND

TERMINAL BODY WEIGHT: 311.00 (GMS)

<< MICROSCOPIC TISSUE  
TISSUE / HISTOPATHOLOGIC FINDINGS

OBSERVATIONS >>  
DISTRIBUTION (SEVERITY) / SPECIAL COMMENTS

PITUITARY GLAND ..... NOT SPECIFIED (PRESENT)  
-CYST(S)

THORAX .....

MISCELLANEOUS TISSUE

THE SUBCUTANEOUS MASS IN THE LEFT AXILLARY AREA IS A MAMMARY  
ADENOCARCINOMA. IT WAS CODED UNDER MAMMARY GLAND.

DIAPHRAGM .....

MISCELLANEOUS TISSUE

-COMPOUND RELATED INFLAMMATORY REACTION

NOT SPECIFIED (PRESENT)

Appendix J (cont.): PATHOLOGY INDIVIDUAL ANIMAL DATA

LETTERMAN ARMY INSTITUTE OF RESEARCH  
 DIV OF RES SUPP, PATH SERV GP  
 SPECIES: RAT/FISCHER-344  
 STUDY START DATE: 23-JAN-84  
 INDIVIDUAL ANIMAL DATA REPORT  
 STUDY NUMBER: GLP83009  
 PRINTED: 21-NOV-89  
 PAGE: 660  
 STUDY TYPE: CHRONIC/2 YR CARCINOGENIC

ANIMAL NUMBER: 333/PRETEST-333 SEX: FEMALE DOSE GROUP: 2 SACRIFICE STATUS: SACRIFICED MORIBUND  
 DATE OF DEATH: 17-JUL-85 STUDY DAY OF DEATH: 542 STUDY WEEK OF DEATH: 78 TERMINAL BODY WEIGHT: 219.00 (GMS)

<< GROSS ORGAN OBSERVATIONS >>  
 SEVERITY GROSS FREE-TEXT COMMENTS  
 KEYWORDS / PHRASES  
 ENLARGED (SPLENOHEGALY) MARKED 7 X 2CM  
 DISCOLORATION PRESENT FIVE WHITE FOCI ALONG THE MARGINS OF THE SPLEEN, .4 X .2CM  
 PITUITARY GLAND DISCOLORATION PRESENT RED, FOCAL, ANTERIOR PORTION, .2CM AREA

<< MICROSCOPIC TISSUE OBSERVATIONS >>  
 DISTRIBUTION (SEVERITY) / SPECIAL COMMENTS

SALIVARY GLAND ..... TISSUE IS MISSING

EXORBITAL LACRIM ..... NOT SPECIFIED(TRACE)

-ACINAR ATROPHY ..... NOT SPECIFIED(TRACE)

HEART ..... TISSUE IS MISSING

CARDIOMYOPATHY ..... TISSUE IS MISSING

LUNGS ..... (PRESENT)

-M- LARGE GRANULAR LYMPHOCYTE LEUKEMIA, METASTATIC

THYRUS ..... TISSUE IS MISSING

SPLEEN ..... NOT SPECIFIED(MODERATE)

-INFARCTION, CHRONIC ..... (PRESENT)

-M- LARGE GRANULAR LYMPHOCYTE LEUKEMIA, METASTATIC

LYMPH NODES ..... LGLL NOTED IN MESENTERIC NODE. CERVICAL AND MEDIASTINAL NODES  
 ARE NOT AVAILABLE FOR EXAMINATION.

-M- LARGE GRANULAR LYMPHOCYTE LEUKEMIA, METASTATIC ..... (PRESENT)

LIVER ..... NOT SPECIFIED(MILD)

-BILE DUCTULE EPITHELIAL HYPERPLASIA AND/OR CHOLANGIOFIBROSIS ..... NOT SPECIFIED(TRACE)

-NECROSIS, PERIACINAR ..... (PRESENT)

-M- LARGE GRANULAR LYMPHOCYTE LEUKEMIA, METASTATIC

KIDNEY .....

Appendix J (cont.): PATHOLOGY INDIVIDUAL ANIMAL DATA

LETTERMAN ARMY INSTITUTE OF RESEARCH  
 DIV OF RES SUPP, PATH SERV GP  
 SPECIES: RAT/FISCHER-344  
 STUDY START DATE: 23-JAN-84  
 STUDY NUMBER: GLP83009  
 PRINTED: 21-NOV-89  
 PAGE: 661  
 STUDY TYPE: CHRONIC/2 YR CARCINOGENIC

ANIMAL NUMBER: 333/PRETEST= 333 SEX: FEMALE DOSE GROUP: 2 SACRIFICE STATUS: SACRIFICED MORIBUND  
 DATE OF DEATH: 17-JUL-87 STUDY DAY OF DEATH: 542 STUDY WEEK OF DEATH: 78 TERMINAL BODY WEIGHT: 219.00 (GMS)

<< M I C R O S C O P I C T I S S U E O B S E R V A T I O N S >>  
 TISSUE / HISTOPATHOLOGIC FINDINGS  
 DISTRIBUTION (SEVERITY) / SPECIAL COMMENTS

KIDNEY ..... NOT SPECIFIED (TRACE)  
 -PROGRESSIVE RENAL DISEASE ..... TISSUE IS MISSING  
 RECTUM ..... NOT SPECIFIED (MILD)  
 MAMMARY GLANDS ..... NOT SPECIFIED (PRESENT)  
 -HYPERPLASIA AND/OR HYPERTROPHY OF THE ACINAR TISSUE .....  
 -DILATATION (ECTASIA) OF DUCTS AND DUCTULES .....  
 PITUITARY GLAND ..... (PRESENT)  
 -B- ADENOMA .....  
 WHOLE BODY ..... (PRESENT)  
 -M- LARGE GRANULAR LYMPHOCYTTIC LEUKEMIA .....

Appendix J (cont.): PATHOLOGY INDIVIDUAL ANIMAL DATA

LETTERMAN ARMY INSTITUTE OF RESEARCH  
DIV OF RES SUPP, PATH SERV GP  
SPECIES: RAT/FISCHER-344

ANIMAL NUMBER: 334/PRETEST  
DATE OF DEATH: 17-JAN-86  
STUDY DAY OF DEATH: 726  
SEX: FEMALE  
DOSE GROUP: 2  
STUDY WEEK OF DEATH: 104  
SACRIFICE STATUS: SACRIFICED MORIBUND  
TERMINAL BODY WEIGHT: 253.00 (GMS)

STUDY START DATE: 23-JAN-84  
STUDY TYPE: CHRONIC/2 YR CARCINOGENIC

ORGAN NAME  
PERITONEAL CAV.  
LUNGS  
LIVER  
SPLEEN  
PITUITARY GLAND

KEYWORDS / PHRASES  
FLUID-FILLED  
DISCOLORATION  
ADHESION(S)  
PROMINENT LOBULAR MARKINGS  
ENLARGED (SPLENOHEGALY)  
DISCOLORATION

GROSS ORGAN OBSERVATIONS  
SEVERITY GROSS FREE-TEXT COMMENTS  
PRESENT 3-4ML, RED  
PRESENT FOCAL, MULTIPLE, .1-.2CM DIAMETER, RED  
PRESENT DIAPHRAGM, VENTRAL ABDOMINAL WALL  
MARKED 7 X 2 X 1CM  
PRESENT FOCAL, RED, .1CM DIAMETER

TISSUE / HISTOPATHOLOGIC FINDINGS  
MICROSCOPIC TISSUE OBSERVATIONS  
DISTRIBUTION (SEVERITY) / SPECIAL COMMENTS

THYROID GLANDS  
-PARA-FOLLICULAR CELL HYPERPLASIA ("C" CELL, LIGHT CELL) NOT SPECIFIED(TRACE)

HEART  
-CARDIOMYOPATHY NOT SPECIFIED(TRACE)  
-MEDIAL HYPERTROPHY OF MUSCULAR ARTERIES NOT SPECIFIED(TRACE)

LUNGS  
-PNEUMONIA, INTERSTITIAL, CHRONIC MULTI-FOCAL(TRACE)  
-M- LARGE GRANULAR LYMPHOCYTE LEUKEMIA, METASTATIC (PRESENT)  
-ALVEOLAR HEMORRHAGE MULTI-FOCAL (PRESENT)

SPLEEN  
-M- LARGE GRANULAR LYMPHOCYTE LEUKEMIA, METASTATIC (PRESENT)

LYMPH NODES  
-RED BLOOD CELLS, HEMOSIDERIN AND/OR ERYTHROPHAGOCYTOSIS WITHIN RBC'S AND PIGMENT PRESENT IN MEDIASTINAL NODE. THIS NODE ALSO  
MEDULLARY SINUSES CONTAINS NUMEROUS NEOPLASTIC LYMPHOCYTES.  
-M- LARGE GRANULAR LYMPHOCYTE LEUKEMIA, METASTATIC NOT SPECIFIED (PRESENT)  
(PRESENT)

LIVER  
(PRESENT)

PRINTED: 21-NOV-89  
PAGE: 662

Appendix J (cont.): PATHOLOGY INDIVIDUAL ANIMAL DATA

LETTERMAN ARMY INSTITUTE OF RESEARCH  
 DIV OF RES SUPP, PATH SERV GP  
 SPECIES: RAT/FISCHER-344

INDIVIDUAL ANIMAL DATA REPORT  
 STUDY NUMBER: GLP83009  
 STUDY START DATE: 23-JAN-84

PRINTED: 21-NOV-89  
 PAGE: 663  
 STUDY TYPE: CHRONIC/2 YR CARCINOGENIC

ANIMAL NUMBER: 334/PRETEST= 334 SEX: FEMALE DOSE GROUP: 2 SACRIFICE STATUS: SACRIFICED MORIBUND  
 DATE OF DEATH: 17-JAN-86 STUDY DAY OF DEATH: 726 STUDY WEEK OF DEATH: 104 TERMINAL BODY WEIGHT: 253.00 (GMS)

<< MICROSCOPIC TISSUE OBSERVATIONS >>  
 DISTRIBUTION (SEVERITY) / SPECIAL COMMENTS

- TISSUE / HISTOPATHOLOGIC FINDINGS
- LIVER
    - COMPOUND RELATED INFLAMMATORY REACTION
    - BILE DUCTULE EPITHELIAL HYPERPLASIA AND/OR CHOLANGIOFIBROSIS
    - HEPATOCTYIC DEGENERATIVE CHANGES (NON-NECROTIC)
    - NECROSIS, PERIACINAR
    - M- LARGE GRANULAR LYMPHOCYTE LEUKEMIA, METASTATIC
  - KIDNEY
    - PROGRESSIVE RENAL DISEASE
  - MAMMARY GLANDS
    - HYPERPLASIA AND/OR HYPERTROPHY OF THE ACINAR TISSUE
  - ADRENAL
    - FOCUS OF CELLULAR ALTERATION, VACUOLATED
  - EYES & OPTIC N.
    - CORNEAL MINERALIZATION
  - WHOLE BODY
    - M- LARGE GRANULAR LYMPHOCYTIC LEUKEMIA
- NOT SPECIFIED (PRESENT)  
 NOT SPECIFIED (MILD)  
 NOT SPECIFIED (MILD)  
 MULTI-FOCAL (TRACE)  
 (PRESENT)  
 NOT SPECIFIED (TRACE)  
 MULTI-FOCAL (TRACE)  
 NOT SPECIFIED (TRACE)  
 (PRESENT)

Appendix J (cont.): PATHOLOGY INDIVIDUAL ANIMAL DATA

LETTERMAN ARMY INSTITUTE OF RESEARCH  
 DIV OF RES SUPP, PATH SERV GP  
 SPECIES: RAT/FISCHER-344

INDIVIDUAL ANIMAL DATA REPORT  
 STUDY NUMBER: GLP83/09  
 STUDY START DATE: 23-JAN-84

PRINTED: 21-NOV-89  
 PAGE: 665  
 STUDY TYPE: CHRONIC/2 YR CARCINOGENIC

ANIMAL NUMBER: 336/PRETEST-336 SEX: FEMALE DOSE GROUP: 2 SACRIFICE STATUS: SACRIFICED MORIBUND  
 DATE OF DEATH: 07-MAY-85 STUDY DAY OF DEATH: 471 STUDY WEEK OF DEATH: 68 TERMINAL BODY WEIGHT: 181.00 (GMS)

ORGAN NAME	SEVERITY	GROSS OBSERVATIONS	GROSS FREE-TEXT COMMENTS
EYES & OPTIC N.	PRESENT	DARK RED, BILATERAL	
LIVER	PRESENT	DIAPHRAGM	
ADRENAL	PRESENT	LEFT, BLACK, DEMARCATED, .1CM DIAMETER, CORTICAL SURFACE	
PITUITARY GLAND	PRESENT	.5CM DIAMETER, DARK RED	

TISSUE / HISTOPATHOLOGIC FINDINGS  
 << MICROSCOPIC TISSUE OBSERVATIONS >>  
 DISTRIBUTION (SEVERITY) / SPECIAL COMMENTS

- BRAIN ..... (PRESENT)
- I-PITUITARY TUMOR INVASION
- THYROID GLANDS ..... NOT SPECIFIED (TRACE)
- PARA-FOLLICULAR CELL HYPERPLASIA ("C" CELL, LIGHT CELL)
- HEART ..... NOT SPECIFIED (TRACE)
- CARDIOMYOPATHY
- LYMPH NODES ..... RBC'S, PIGMENT AND REACTIVE HYPERPLASIA PRESENT IN CERVICAL AND MEDIASTINAL NODES. REACTIVE HYPERPLASIA ALSO PRESENT IN MESENTERIC NODE.
- RED BLOOD CELLS, HEMOSIDERIN AND/OR ERYTHROPHAGOCYTOSIS WITHIN MEDULLARY SINUSES NOT SPECIFIED (PRESENT)
- REACTIVE HYPERPLASIA NOT SPECIFIED (PRESENT)
- LIVER ..... NOT SPECIFIED (PRESENT)
- COMPOUND RELATED INFLAMMATORY REACTION NOT SPECIFIED (TRACE)
- HEPATITIS
- KIDNEY ..... NOT SPECIFIED (MILD)
- PROGRESSIVE RENAL DISEASE
- MAMMARY GLANDS .....

Appendix J (cont.): PATHOLOGY INDIVIDUAL ANIMAL DATA

LETTERMAN ARMY INSTITUTE OF RESEARCH  
DIV OF RES SUPP, PATH SERV GP  
SPECIES: RAT/FISCHER-344

INDIVIDUAL ANIMAL DATA REPORT  
STUDY NUMBER: GLP83009

PRINTED: 21-NOV-89  
PAGE: 666

STUDY START DATE: 23-JAN-84

STUDY TYPE: CHRONIC/2 YR CARCINOGENIC

ANIMAL NUMBER: 336/PRETEST=  
DATE OF DEATH: 07-MAY-85

336 SEX: FEMALE  
STUDY DAY OF DEATH: 471

DOSE GROUP: 2  
STUDY WEEK OF DEATH: 68

SACRIFICE STATUS: SACRIFICED MORIBUND  
TERMINAL BODY WEIGHT: 181.00 (GMS)

<< MICROSCOPIC TISSUE OBSERVATIONS >>  
TISSUE / HISTOPATHOLOGIC FINDINGS

DISTRIBUTION (SEVERITY) / SPECIAL COMMENTS

MAMMARY GLANDS .....  
-HYPERPLASIA AND/OR HYPERTROPHY OF THE ACINAR TISSUE  
-DILATATION (ECTASIA) OF DUCTS AND DUCTULES

NOT SPECIFIED(MODER/TE)  
NOT SPECIFIED (PRESENT)

NOSE/TURBINATES .....  
-MIXED INFLAMMATORY CELL INFILTRATION, NASAL CAVITY, SINUSES,  
TURBINATES, NASO-LACRIMAL DUCTS

CELLULAR INFILTRATE INVOLVES NASO-LACRIMAL DUCTS.  
NOT SPECIFIED(MILD)

PITUITARY GLAND .....  
-B- ADENOMA

(PRESENT)

EYES & OPTIC N. ....  
-METAPLASTIC BONE FORMATION AND/OR MINERALIZATION, SCLERA  
-CHRONIC CONJUNCTIVITIS

CHRONIC CONJUNCTIVITIS NOTED IN A FAIRLY LARGE SEGMENT OF THE  
CONJUNCTIVA THAT IS ATTACHED TO THE LACRIMAL GLAND IN SECTION  
#4. NO CONJUNCTIVA WAS INCLUDED WITH EITHER EYE SECTION.  
NOT SPECIFIED (PRESENT)  
NOT SPECIFIED(MILD)

EAR .....  
DIAPHRAGM .....  
-COMPOUND RELATED INFLAMMATORY REACTION

THERE ARE NO LESIONS IN ANY OF THE STRUCTURES OF THE EAR.  
HOWEVER, THERE IS HEMORRHAGE, CELLULAR INFILTRATION AND FIBROUS  
CONNECTIVE TISSUE PROLIFERATION IN THE MENINGES COVERING THE  
VENTRAL ASPECT OF THE CRANIAL CAVITY. THIS LESION IS A PART OF  
THE LARGE PITUITARY TUMOR REPRESENTED IN SECTICK #18 AND WHICH  
EXTENDS INTO THE BRAIN IN SECTION #2.

MISCELLANEOUS TISSUE  
NOT SPECIFIED (PRESENT)



Appendix J (cont.): PATHOLOGY INDIVIDUAL ANIMAL DATA

LETTERMAN ARMY INSTITUTE OF RESEARCH  
 DIV OF RES SUPP, PATH SERV GP  
 SPECIES: RAT/FISCHER-344  
 STUDY START DATE: 23-JAN-84  
 STUDY NUMBER: GLP83009  
 STUDY TYPE: CHRONIC/2 YR CARCINOGENIC  
 PRINTED: 21-NOV-89  
 PAGE: 667  
 ANIMAL NUMBER: 337/PRETEST= 337 SEX: FEMALE DOSE GROUP: 2 SACRIFICE STATUS: SACRIFICED MORIBUND  
 DATE OF DEATH: 17-JAN-86 STUDY DAY OF DEATH: 726 STUDY WEEK OF DEATH: 104 TERMINAL BODY WEIGHT: 241.00 (GMS)

ORGAN NAME << GROSS ORGAN OBSERVATIONS >>  
 KEYWORDS / PHRASES SEVERITY GROSS FREE-TEXT COMMENTS  
 KIDNEY DISCOLORATION PRESENT GREEN/BROWN  
 KIDNEY GRANULAR SURFACE PRESENT  
 LIVER ADHESION(S) PRESENT DIAPHRAGM  
 LIVER PROMINENT LOBULAR MARKINGS PRESENT SLIGHTLY ENLARGED  
 LIVER DISCOLORATION PRESENT FOCAL, WHITE, VARIABLY SIZED, NUMBERING 16  
 THYROID ENLARGED PRESENT .5CM DIAMETER, MOTTLED RED AND WHITE

TISSUE / HISTOPATHOLOGIC FINDINGS << MICROSCOPIC TISSUE OBSERVATIONS >>  
 DISTRIBUTION (SEVERITY) / SPECIAL COMMENTS

THYROID GLANDS ..... (PRESENT)  
 -M- PARA-FOLLICULAR CELL ADENOCARCINOMA .....  
 PARATHYROID ..... TISSUE IS MISSING  
 SALIVARY GLAND ..... TISSUE IS MISSING  
 EXORBITAL LACRIM ..... TISSUE IS MISSING  
 HEART ..... NOT SPECIFIED(TRACE)  
 -CARDIOMYOPATHY .....  
 LUNGS ..... NOT SPECIFIED(TRACE)  
 -MINERALIZATION OF PULMONARY ARTERIES .....  
 LYMPH NODES ..... RBC'S AND PIGMENT PRESENT IN MEDIASTINAL NODE.  
 -RED BLOOD CELLS, HEMOSIDERIN AND/OR ERYTHROPHAGOCYTOSIS WITHIN ..... NOT SPECIFIED (PRESENT)  
 MEDULLARY SINUSES .....  
 LIVER ..... NOT SPECIFIED (PRESENT)  
 -COMPOUND RELATED INFLAMMATORY REACTION .....  
 -FOCUS OF CELLULAR ALTERATION - BASOPHILIC FOCAL(TRACE)

Appendix J (cont.): PATHOLOGY INDIVIDUAL ANIMAL DATA

LETTERMAN ARMY INSTITUTE OF RESEARCH  
DIV OF RES SUPP, PATH SERV GP  
SPECIES: RAT/FISCHER-344

INDIVIDUAL ANIMAL DATA REPORT  
STUDY NUMBER: GLP83009  
STUDY START DATE: 23-JAN-84

PRINTED: 21-NOV-89  
PAGE: 668

STUDY TYPE: CHRONIC/2 YR CARCINOGENIC

ANIMAL NUMBER: 337/PRETEST-  
DATE OF DEATH: 17-JAN-86  
STUDY DAY OF DEATH: 726  
SEX: FEMALE  
DOSE GROUP: 2  
SACRIFICE STATUS: SACRIFICED MORIBUND  
TERMINAL BODY WEIGHT: 241.00 (GMS)

TISSUE / HISTOPATHOLOGIC FINDINGS  
MICROSCOPIC TISSUE OBSERVATIONS  
DISTRIBUTION (SEVERITY) / SPECIAL COMMENTS

LIVER .....  
 -HEPATOCTYIC VACUOLIZATION .....  
 -HEPATOCTYCE COALESCING MICROVESICULAR (FATTY) CHANGE LEADING TO  
 NECROSIS AND MINERALIZATION .....  
 KIDNEY .....  
 -PROGRESSIVE RENAL DISEASE .....  
 NOSE/TURBINATES .....  
 -MIXED INFLAMMATORY CELL INFILTRATION, NASAL CAVITY, SINUSES,  
 TURBINATES, NASO-LACRIMAL DUCTS .....  
 ADRENAL .....  
 -LIPIDOSIS .....  
 PITUITARY GLAND .....  
 DIAPHRAGM .....  
 -COMPOUND RELATED INFLAMMATORY REACTION .....

DIFFUSE(MARKED)  
 DIFFUSE(MODERATE)  
 NOT SPECIFIED(MODERATE)  
 CELLULAR INFILTRATE INVOLVES NASO-LACRIMAL DUCTS.  
 NOT SPECIFIED(MILO)  
 DIFFUSE(MODERATE)  
 TISSUE IS MISSING  
 MISCELLANEOUS TISSUE  
 NOT SPECIFIED (PRESENT)

**Appendix J (cont.): PATHOLOGY INDIVIDUAL ANIMAL DATA**

LETTERMAN ARMY INSTITUTE OF RESEARCH  
 DIV OF RES SUPP, PATH SERV GP  
 SPECIES: RAT/FISCHER-344

INDIVIDUAL ANIMAL DATA REPORT  
 STUDY NUMBER: GLP83009

PRINTED: 21-NOV-89  
 PAGE: 669

STUDY START DATE: 23-JAN-84

STUDY TYPE: CHRONIC/2 YR CARCINOGENIC

ANIMAL NUMBER: 338/PRETEST# 338 SEX: FEMALE DOSE GROUP: 2 SACRIFICE STATUS: SACRIFICED MORIBUND  
 DATE OF DEATH: 28-AUG-85 STUDY DAY OF DEATH: 584 STUDY WEEK OF DEATH: 84 TERMINAL BODY WEIGHT: 207.00 (GMS)

ORGAN NAME	KEYWORDS / PHRASES	ORGAN OBSERVATIONS	SEVERITY	GROSS FREE-TEXT COMMENTS
WHOLE BODY	JAUNDICED			
LIVER	ADHESION(S)		PRESENT	SUBCUTANEOUS AND BODY FAT
LIVER	PROMINENT LOBULAR MARKINGS		PRESENT	DIAPHRAGM, VENTRAL ABDOMINAL WALL
KIDNEY	DISCOLORATION		PRESENT	GREEN/BROWN
SPLEEN	ENLARGED (SPLENOMEGALY)		MODERATE	4.5 X 1.5 X .5CM
PITUITARY GLAND	DISCOLORATION		PRESENT	BLACK, FOCAL, .2CM DIAMETER

TISSUE / HISTOPATHOLOGIC FINDINGS

<< MICROSCOPIC TISSUE OBSERVATIONS >>

DISTRIBUTION (SEVERITY) / SPECIAL COMMENTS

HEART

- CARDIOMYOPATHY ..... NOT SPECIFIED(TRACE)

LUNGS

- MINERALIZATION OF PULMONARY ARTERIES ..... NOT SPECIFIED(TRACE)
- N- LARGE GRANULAR LYMPHOCYTE LEUKEMIA, METASTATIC (PRESENT)

THYMUS

- N- LARGE GRANULAR LYMPHOCYTE LEUKEMIA, METASTATIC (PRESENT)

SPLEEN

- N- LARGE GRANULAR LYMPHOCYTE LEUKEMIA, METASTATIC (PRESENT)

LYMPH NODES

- N- LARGE GRANULAR LYMPHOCYTE LEUKEMIA, METASTATIC (PRESENT)

LIVER

- COMPOUND RELATED INFLAMMATORY REACTION ..... NOT SPECIFIED (PRESENT)
- BILE DUCTULE EPITHELIAL HYPERPLASIA AND/OR CHOLANGIOFIBROSIS ..... NOT SPECIFIED(TRACE)
- HEPATOCTYIC DEGENERATIVE CHANGES (NON-NECROTIC) ..... DIFFUSE(MODERATE)

LGLL INVOLVES CERVICAL, MEDIASTINAL AND MESENTERIC NODES AND IN MANY CASES IS PRESENT IN PERINODAL FAT IN ALL THESE LOCATIONS.  
 (PRESENT)

DD  
 10  
 0  
 2  
 5  
 10  
 15  
 20  
 25  
 30  
 35  
 40  
 45  
 50  
 55  
 60  
 65  
 70  
 75  
 80  
 85  
 90  
 95

**Appendix J (cont.): PATHOLOGY INDIVIDUAL ANIMAL DATA**

LETTERMAN ARMY INSTITUTE OF RESEARCH  
 DIV OF RES SUPP, PATH SERV GP  
 SPECIES: RAT/FISCHER-344  
 STUDY START DATE: 23-JAN-84  
 STUDY NUMBER: GLP83009  
 PRINTED: 21-NOV-89  
 PAGE: 670

ANIMAL NUMBER: 338/PRETEST= 338 SEX: FEMALE DOSE GROUP: 2 SACRIFICE STATUS: SACRIFICED MORIBUND  
 DATE OF DEATH: 28-AUG-85 STUDY DAY OF DEATH: 584 STUDY WEEK OF DEATH: 84 TERMINAL BODY WEIGHT: 207.00 (GMS)  
 STUDY TYPE: CHRONIC/2 YR CARCINOGENIC

TISSUE / HISTOPATHOLOGIC FINDINGS << MICROSCOPIC TISSUE OBSERVATIONS >>  
 DISTRIBUTION (SEVERITY) / SPECIAL COMMENTS

- LIVER ..... (PRESENT)
  - N- LARGE GRANULAR LYMPHOCYTE LEUKEMIA, METASTATIC
- KIDNEY ..... (PRESENT)
  - PROGRESSIVE RENAL DISEASE
- URINARY BLADDER ..... NOT SPECIFIED(TRACE)
  - CHRONIC INFLAMMATORY CELL INFILTRATION
- UTERUS ..... NOT SPECIFIED(MILD)
  - ENDOMETRITIS, SUBACUTE
- OVARIES ..... NOT SPECIFIED(TRACE)
  - INFLAMMATORY CELL INFILTRATION
- MAMMARY GLANDS ..... NOT SPECIFIED (MILD)
  - DILATATION (ECTASIA) OF DUCTS AND ACINI
- NOSE/TURBINATES ..... NOT SPECIFIED (PRESENT)
  - MIXED INFLAMMATORY CELL INFILTRATION, NASAL CAVITY, SINUSES,  
 TURBINATES, NASO-LACRIMAL DUCTS
- PITUITARY GLAND ..... CELLULAR INFILTRATE INVOLVES NASO-LACRIMAL DUCTS.  
 -B- ADENOMA ..... NOT SPECIFIED(MILD)  
 -CYST(S) ..... NOT SPECIFIED (PRESENT)
- WHOLE BODY ..... (PRESENT)
  - M- LARGE GRANULAR LYMPHOCYTTIC LEUKEMIA

**Appendix J (cont.): PATHOLOGY INDIVIDUAL ANIMAL DATA**

LETTERMAN ARMY INSTITUTE OF RESEARCH  
 DIV OF RES SUPP, PATH SERV GP  
 SPECIES: RAT/FISCHER-344

PRINTED: 21-NOV-89  
 PAGE: 671

INDIVIDUAL ANIMAL DATA REPORT  
 STUDY NUMBER: GLP83009

STUDY START DATE: 23-JAN-84

STUDY TYPE: CHRONIC/2 YR CARCINOGENIC

ANIMAL NUMBER: 339/PRETEST= 339 SEX: FEMALE DOSE GROUP: 2 SACRIFICE STATUS: FINAL SACRIFICE  
 DATE OF DEATH: 14-FEB-86 STUDY DAY OF DEATH: 754 STUDY WEEK OF DEATH: 108 TERMINAL BODY WEIGHT: 263.00 (GMS)

<< G R O S S O R G A N O B S E R V A T I O N S >>  
 SEVERITY GROSS FREE-TEXT COMMENTS

LIVER	ADHESION(S)	PRESENT	STOMACH, VENTRAL ABDOMINAL WALL.
DUODENUM	ADHERED TO LIVER	PRESENT	ONE LOOP.
SPLEEN	ENLARGED (SPLENOEGALY)	PRESENT	5 X 1.5 X 1CM.
PITUITARY GLAND	ENLARGED	PRESENT	.5CM DIAMETER.
PITUITARY GLAND	DISCOLORATION	PRESENT	FOCAL, RED/BROWN, .2CM DIAMETER

<< M I C R O S C O P I C T I S S U E O B S E R V A T I O N S >>  
 DISTRIBUTION (SEVERITY) / SPECIAL COMMENTS

THYROID GLANDS  
 -PARA-FOLLICULAR CELL HYPERPLASIA ("C" CELL, LIGHT CELL) NOT SPECIFIED(MILD)

EXORBITAL LACRIM  
 -ACINAR ATROPHY NOT SPECIFIED(TRACE)

HEART  
 -CARDIOMYOPATHY NOT SPECIFIED(MILD)  
 -MEDIAL HYPERTROPHY OF MUSCULAR ARTERIES NOT SPECIFIED(MILD)

LUNGS  
 -MINERALIZATION OF PULMONARY ARTERIES NOT SPECIFIED(TRACE)

SPLEEN  
 -M- LARGE GRANULAR LYMPHOCYTE LEUKEMIA, METASTATIC (PRESENT)

LYMPH NODES  
 -M- LARGE GRANULAR LYMPHOCYTE LEUKEMIA, METASTATIC LGLL NOTED IN MEDIASTINAL AND MESENTERIC NODES.  
 (PRESENT)

LIVER  
 -COMPOUND RELATED INFLAMMATORY REACTION NOT SPECIFIED (PRESENT)  
 -BILE DUCTULE EPITHELIAL HYPERPLASIA AND/OR CHOLANGIOFIBROSIS NOT SPECIFIED(TRACE)  
 -FOCUS OF CELLULAR ALTERATION - BASOPHILIC NOT SPECIFIED(TRACE)

W  
 0  
 3  
 0  
 1  
 1  
 1  
 1

**Appendix J (cont.): PATHOLOGY INDIVIDUAL ANIMAL DATA**

LETTERMAN ARMY INSTITUTE OF RESEARCH  
 DIV OF RES SUPP, PATH SERV GP  
 SPECIES: RAT/FISCHER-344  
 STUDY START DATE: 23-JAN-84  
 STUDY NUMBER: GLP83009  
 PRINTED: 21-NOV-89  
 PAGE: 672  
 STUDY TYPE: CHRONIC/2 YR CARCINOGENIC  
 ANIMAL NUMBER: 339/PRETEST= 339 SEX: FEMALE DOSE GROUP: 2 SACRIFICE STATUS: FINAL SACRIFICE  
 DATE OF DEATH: 14-FEB-86 STUDY DAY OF DEATH: 754 STUDY WEEK OF DEATH: 108 TERMINAL BODY WEIGHT: 263.00 (GMS)  
 << M I C R O S C O P I C T I S S U E O B S E R V A T I O N S >>  
 TISSUE / HISTOPATHOLOGIC FINDINGS ..... DISTRIBUTION (SEVERITY) / SPECIAL COMMENTS .....

- LIVER ..... (PRESENT)
- M- LARGE GRANULAR LYMPHOCYTE LEUKEMIA, METASTATIC (PRESENT)
- HEPATOCTE COALESCING MICROVESICULAR (FATTY) CHANGE LEADING TO MULTI-FOCAL(MODERATE) NECROSIS AND MINERALIZATION
- KIDNEY ..... NOT SPECIFIED(TRACE)
- PROGRESSIVE RENAL DISEASE
- UTERUS ..... NOT SPECIFIED (PRESENT)
- DILATATION OF THE UTERINE LUMEN (HYDROMETRA) NOT SPECIFIED (PRESENT)
- CYSTIC DILATATION OF THE ENDOMETRIAL GLANDS
- MAMMARY GLANDS ..... NOT SPECIFIED(MILD)
- HYPERPLASIA AND/OR HYPERTROPHY OF THE ACINAR TISSUE
- NOSE/TURBINATES ..... CELLULAR INFILTRATE IS ADJACENT TO THE NASO-LACRIMAL DUCT.
- MIXED INFLAMMATORY CELL INFILTRATION, NASAL CAVITY, SINUSES, NOT SPECIFIED(MILD)
- TURBINATES, NASO-LACRIMAL DUCTS
- ADRENAL ..... NOT SPECIFIED (PRESENT)
- CORTICAL MODULAR HYPERPLASIA (PRESENT)
- M- LARGE GRANULE LYMPHOCYTE LEUKEMIA, METASTATIC
- PITUITARY GLAND ..... NOT SPECIFIED (PRESENT)
- CYST(S)
- EYES & OPTIC N. .... NOT SPECIFIED (PRESENT)
- METAPLASTIC BONE FORMATION AND/OR MINERALIZATION, SCLERA
- WHOLE BODY ..... (PRESENT)
- M- LARGE GRANULAR LYMPHOCYTIC LEUKEMIA
- DIAPHRAGM ..... MISCELLANEOUS TISSUE

Appendix J (cont.): PATHOLOGY INDIVIDUAL ANIMAL DATA

LETTERMAN ARMY INSTITUTE OF RESEARCH  
DIV OF RES SUPP, PATH SERV GP  
SPECIES: RAT/FISCHER-344

INDIVIDUAL ANIMAL DATA REPORT  
STUDY NUMBER: GLP83009  
STUDY START DATE: 23-JAN-84

PRINTED: 21-NOV-89  
PAGE: 673

STUDY TYPE: CHRONIC/2 YR CARCINOGENIC

ANIMAL NUMBER: 339/PRETEST=

339 SEX: FEMALE

DOSE GROUP: 2

SACRIFICE STATUS: FINAL SACRIFICE

DATE OF DEATH: 14-FEB-86

STUDY DAY OF DEATH: 754

STUDY WEEK OF DEATH: 108

TERMINAL BODY WEIGHT: 263.00 (GMS)

<< MICROSCOPIC TISSUE OBSERVATIONS >>  
DISTRIBUTION (SEVERITY) / SPECIAL COMMENTS

DIAPHRAGM ..... MISCELLANEOUS TISSUE  
-COMPOUND RELATED INFLAMMATORY REACTION NOT SPECIFIED (PRESENT)

Appendix J (cont.): PATHOLOGY INDIVIDUAL ANIMAL DATA

LETTERMAN ARMY INSTITUTE OF RESEARCH DIV OF RES SUPP, PATH SERV GP SPECIES: RAT/FISCHER-344

INDIVIDUAL ANIMAL DATA REPORT STUDY NUMBER: GLP83009 STUDY START DATE: 23-JAN-84 PRINTED: 21-NOV-89 PAGE: 689 STUDY TYPE: CHRONIC/2 YR CARCINOGENIC

ANIMAL NUMBER: 355/PRETEST= 355 SEX: FEMALE DOSE GROUP: 3 SACRIFICE STATUS: SACRIFICED MORIBUND DATE OF DEATH: 03-OCT-85 STUDY DAY OF DEATH: 620 STUDY WEEK OF DEATH: 89 TERMINAL BODY WEIGHT: 283.00 (GMS)

ORGAN NAME: SALIVARY GLAND GROSS ORGAN OBSERVATIONS SEVERITY GROSS FREE-TEXT COMMENTS KEYWORDS / PHRASES PRESENT 3.5 X 3.5 X 2CM, MODULAR, RED/BLACK/TAN, INCORPORATES SUBMANDIBULAR SALIVARY GLANDS.

TISSUE / HISTOPATHOLOGIC FINDINGS: << MICROSCOPIC TISSUE OBSERVATIONS >> DISTRIBUTION (SEVERITY) / SPECIAL COMMENTS

THYROID GLANDS: -PARA-FOLLICULAR CELL HYPERPLASIA (\*CM CELL, LIGHT CELL) -B- PARA-FOLLICULAR CELL ADENOMA NOT SPECIFIED(TRACE) (PRESENT)

SALIVARY GLAND: -M- ADENOCARCINOMA (PRESENT)

HEART: -CARDIOMYOPATHY NOT SPECIFIED(MILD)

THYMUS: TISSUE IS MISSING RECUTS OF BLOCK #7 WHICH SHOULD CONTAIN THYMUS FAILED TO DEMONSTRATE THIS ORGAN. ATTEMPTS TO DEMONSTRATE THYMUS BY EMBEDDING AND CUTTING ADDITIONAL WET TISSUES WERE LIKEWISE UNSUCCESSFUL.

LYMPH NODES: -RED BLOOD CELLS, HEMOSIDERIN AND/OR ERYTHROPHAGOCYTOSIS WITHIN MEDULLARY SINUSES NOT SPECIFIED (PRESENT)

LIVER: -BILE DUCTULE EPITHELIAL HYPERPLASIA AND/OR CHOLANGIOFIBROSIS -HEPATITIS NOT SPECIFIED(TRACE) NOT SPECIFIED(TRACE)

NOSE/TURBINATES: MINIMAL INFILTRATE IS BILATERAL ADJACENT NASO-LACRIMAL DUCTS.



Appendix J (cont.): PATHOLOGY INDIVIDUAL ANIMAL DATA

LETTERMAN ARMY INSTITUTE OF RESEARCH  
DIV OF RES SUPP, PATH SERV GP  
SPECIES: RAT/FISCHER-344

INDIVIDUAL ANIMAL DATA REPORT  
STUDY NUMBER: GLP83009  
STUDY START DATE: 23-JAN-84

PRINTED: 21-NOV-89  
PAGE: 690

STUDY TYPE: CHRONIC/2 YR CARCINOGENIC

ANIMAL NUMBER: 355/PRETEST# 355 SEX: FEMALE DOSE GROUP: 3 SACRIFICE STATUS: SACRIFICED MORIBUND  
DATE OF DEATH: 03-OCT-85 STUDY DAY OF DEATH: 621 STUDY WEEK OF DEATH: 89 TERMINAL BODY WEIGHT: 283.00 (GMS)

<< M I C R O S C O P I C T I S S U E O B S E R V A T I O N S >>  
DISTRIBUTION (SEVERITY) / SPECIAL COMMENTS

NOSE/TURBINATES .....  
-MIXED INFLAMMATORY CELL INFILTRATION, NASAL CAVITY, SINUSES, ..... NOT SPECIFIED(TRACE)  
TURBINATES, NASO-LACRIMAL DUCTS

EYES & OPTIC N. ....  
-METAPLASTIC BONE FORMATION AND/OR MINERALIZATION, SCLERA ..... NOT SPECIFIED (PRESENT)

**Appendix J (cont.): PATHOLOGY INDIVIDUAL ANIMAL DATA**

LETTERMAN ARMY INSTITUTE OF RESEARCH  
 DIV OF RES SUPP, PATH SERV GP  
 SPECIES: RAT/FISCHER-344

INDIVIDUAL ANIMAL DATA REPORT  
 STUDY NUMBER: GLP83009

STUDY START DATE: 23-JAN-84

ANIMAL NUMBER: 356/PRETEST= 356 SEX: FEMALE OOSE GROUP: 3 SACRIFICE STATUS: FINAL SACRIFICE  
 DATE OF DEATH: 07-FEB-86 STUDY DAY OF DEATH: 747 STUDY WEEK OF DEATH: 107 TERMINAL BODY WEIGHT: 258.00 (GMS)

ORGAN NAME << GROSS ORGAN OBSERVATIONS >>  
 SEVERITY GROSS FREE-TEXT COMMENTS  
 LIVER PRESENT 2MM DIAMETER, WHITE

TISSUE / HISTOPATHOLOGIC FINDINGS << MICROSCOPIC TISSUE OBSERVATIONS >>  
 DISTRIBUTION (SEVERITY) / SPECIAL COMMENTS

HEART ..... NOT SPECIFIED (TRACE)  
 -CARDIOMYOPATHY

LYMPH NODES ..... A SMALL MESENTERIC LYMPH NODE ADJACENT TO THE PANCREAS IN SLIDE #12 HAS A REACTIVE CHANGE. MACROPHAGES IN THIS NODE CONTAIN ABUNDANT GREEN AND BROWN CRYSTALLINE PIGMENT.  
 NOT SPECIFIED (PRESENT)

-REACTIVE HYPERPLASIA  
 LIVER ..... MULTI-FOCAL (TRACE)  
 -HEPATOCTYIC VACUOLIZATION NOT SPECIFIED (TRACE)  
 -FOCUS OF CELLULAR ALTERATION - CLEAR CELLS FOCAL (TRACE)  
 -BENIGN HYPERPLASTIC MODULE(S) MULTI-FOCAL (MILD)  
 -HEPATOCTYIC COALESCING MICROVESICULAR (FATTY) CHANGE LEADING TO NECROSIS AND MINERALIZATION

KIDNEY ..... NOT SPECIFIED (MILD)  
 -PROGRESSIVE RENAL DISEASE

UTERUS ..... NOT SPECIFIED (PRESENT)  
 -CYSTIC DILATATION OF THE ENDOMETRIAL GLANDS

SKIN ..... THERE IS AN EPIDERMAL INCLUSION CYST IN THE CONNECTIVE TISSUE ADJACENT TO THE THYROID GLAND.  
 NOT SPECIFIED (PRESENT)  
 -EPIDERMAL INCLUSION CYST(S)

MAMMARY GLANDS ..... NOT SPECIFIED (MODERATE)  
 -HYPERPLASIA AND/OR HYPERTROPHY OF THE ACINAR TISSUE NOT SPECIFIED (PRESENT)  
 -DILATATION (ECTASIA) OF DUCTS AND DUCTULES

ADRENAL .....

Appendix J (cont.): PATHOLOGY INDIVIDUAL ANIMAL DATA

LETTERMAN ARMY INSTITUTE OF RESEARCH  
DIV OF RES SUPP, PATH SERV GP  
SPECIES: RAT/FISCHER-344

INDIVIDUAL ANIMAL DATA REPORT  
STUDY NUMBER: GLP83009  
STUDY START DATE: 23-JAN-84

PRINTED: 21-0V-89  
PAGE: 692

STUDY TYPE: CHRONIC/2 YR CARCINOGENIC

ANIMAL NUMBER: 356/PRETEST= 356 SEX: FEMALE DOSE GROUP: 3 SACRIFICE STATUS: FINAL SACRIFICE  
DATE OF DEATH: 07-FEB-86 STUDY DAY OF DEATH: 747 STUDY WEEK OF DEATH: 107 TERMINAL BODY WEIGHT: 258.00 (GHS)

TISSUE / HISTOPATHOLOGIC FINDINGS << MICROSCOPIC TISSUE OBSERVATIONS >>  
DISTRIBUTION (SEVERITY) / SPECIAL COMMENTS

ADRENAL ..... NOT SPECIFIED (TRACE)  
-FOCUS OF CELLULAR ALTERATION, VACUOLATED

Appendix J (cont.): PATHOLOGY INDIVIDUAL ANIMAL DATA

LETTERMAN ARMY INSTITUTE OF RESEARCH  
 DIV OF RES SUPP, PATH SERV GP  
 SPECIES: RAT/FISCHER-344

INDIVIDUAL ANIMAL DATA REPORT  
 STUDY NUMBER: GLP83009  
 STUDY START DATE: 23-JAN-84

PRINTED: 21-NOV-89  
 PAGE: 693  
 STUDY TYPE: CHRONIC/2 YR CARCINOGENIC

ANIMAL NUMBER: 357/PRETEST# 357 SEX: FEMALE DOSE GROUP: 3 SACRIFICE STATUS: FINAL SACRIFICE  
 DATE OF DEATH: 07-FEB-86 STUDY DAY OF DEATH: 747 STUDY WEEK OF DEATH: 107 TERMINAL BODY WEIGHT: 220.00 (GMS)

ORGAN NAME << GROSS ORGAN OBSERVATIONS >>  
 KEYWORDS / PHRASES SEVERITY GROSS FREE-TEXT COMMENTS  
 SKIN SUBCUTANEOUS MASS PRESENT RIGHT AXILLARY, 2.5X1.5 CM, YELLOW

<< MICROSCOPIC TISSUE OBSERVATIONS >>  
 DISTRIBUTION (SEVERITY) / SPECIAL COMMENTS

TISSUE / HISTOPATHOLOGIC FINDINGS

PARATHYROID ..... TISSUE IS MISSING

EXORBITAL LACRIM .....  
 -ACINAR ATROPHY ..... MULTI-FOCAL (TRACE)

HEART ..... NOT SPECIFIED (TRACE)  
 -CARDIOMYOPATHY .....

SPLEEN ..... NOT SPECIFIED (PRESENT)  
 -EXTRAMEDULLARY HEMATOPOIESIS ..... NOT SPECIFIED (PRESENT)  
 -HEMOSIDERIN PIGMENTATION (RED PULP) .....

LYMPH NODES ..... RBC'S, HEMOSIDERIN AND REACTIVE HYPERPLASTIC CHANGES ARE  
 PRESENT IN BOTH MEDIASTINAL AND CERVICAL NODES.  
 -RED BLOOD CELLS, HEMOSIDERIN AND/OR ERYTHROPHAGOCYTOSIS WITHIN  
 MEDULLARY SINUSES ..... NOT SPECIFIED (PRESENT)  
 -REACTIVE HYPERPLASIA ..... NOT SPECIFIED (PRESENT)

LIVER ..... MULTI-FOCAL (MILD)  
 -HEPATOCYTE COALESCING MICROVESICULAR (FATTY) CHANGE LEADING TO  
 NECROSIS AND MINERALIZATION .....

KIDNEY ..... NOT SPECIFIED (MILD)  
 -PROGRESSIVE RENAL DISEASE .....

MAMMARY GLANDS ..... THE SUBCUTANEOUS MASS NOTED GROSSLY IN THE AXILLARY AREA IS  
 A MAMMARY FIBROADENOMA.  
 -HYPERPLASIA AND/OR HYPERTROPHY OF THE ACINAR TISSUE ..... NOT SPECIFIED (MILD)

## Appendix J (cont.): PATHOLOGY INDIVIDUAL ANIMAL DATA

LETTERMAN ARMY INSTITUTE OF RESEARCH  
DIV OF RES SUPP, PATH SERV GP  
SPECIES: RAT/FISCHER-344

INDIVIDUAL ANIMAL DATA REPORT  
STUDY NUMBER: GLP83009  
STUDY START DATE: 23-JAN-84

PRINTED: 21-NOV-89  
PAGE: 694  
STUDY TYPE: CHRONIC/2 YR CARCINOGENIC

ANIMAL NUMBER: 357/PRETEST= 357 SEX: FEMALE DOSE GROUP: 3 SACRIFICE STATUS: FINAL SACRIFICE  
DATE OF DEATH: 07-FEB-86 STUDY DAY OF DEATH: 747 STUDY WEEK OF DEATH: 107 TERMINAL BODY WEIGHT: 220.00 (GMS)

TISSUE / HISTOPATHOLOGIC FINDINGS << MICROSCOPIC TISSUE OBSERVATIONS >>  
DISTRIBUTION (SEVERITY) / SPECIAL COMMENTS

MAMMARY GLANDS ..... (PRESENT)  
-B- FIBROADENOMA ..... NOT SPECIFIED (PRESENT)  
-DILATATION (ECTASIA) OF DUCTS AND DUCTULES

NOSE/TURBINATES ..... INFILTRATE: BILATERAL ADJACENT NASO-LACRIMAL DUCTS.  
-MIXED INFLAMMATORY CELL INFILTRATION, NASAL CAVITY, SINUSES, ..... NOT SPECIFIED(MODERATE)  
TURBINATES, NASO-LACRIMAL DUCTS

BONE, STERNUM ..... TISSUE IS MISSING

ADRENAL ..... NOT SPECIFIED(MILD)  
-FOCUS OF CELLULAR ALTERATION, VACUOLATED

PITUITARY GLAND ..... NOT SPECIFIED (PRESENT)  
-CYST(S)

EYES & OPTIC N. .... NOT SPECIFIED(TRACE)  
-CORNEAL VASCULARIZATION ..... NOT SPECIFIED (PRESENT)  
-METAPLASTIC BONE FORMATION AND/OR MINERALIZATION, SCLERA ..... NOT SPECIFIED (PRESENT)  
-LENTICULAR DEGENERATIVE CHANGES COMPATIBLE WITH CATARACT

THORAX ..... MISCELLANEOUS TISSUE  
THE SUBCUTANEOUS MASS NOTED GROSSLY IN THE AXILLARY AREA IS  
A MAMMARY FIBROADENOMA THAT WAS CODED UNDER MAMMARY GLAND.

WHOLE BODY ..... THERE IS INFLAMMATION OF BROWN FAT IN MANY LOCATIONS THROUGHOUT  
THE BODY SUCH AS CERVICAL SUBCUTANEOUS AREA, THE MEDIASTINUM  
AND THE PERI-RENAL AREA.  
NOT SPECIFIED (PRESENT)

-INFLAMMATION OF BROWN FAT, (LOCATION SPECIFIED IN COMMENTS)

MEDIASTINUM ..... MISCELLANEOUS TISSUE  
INFLAMMATION INVOLVES BROWN FAT.  
MULTI-FOCAL(MILD)

-CHRONIC INFLAMMATION

Appendix J (cont.): PATHOLOGY INDIVIDUAL ANIMAL DATA

LETTERMAN ARMY INSTITUTE OF RESEARCH  
 DIV OF RES SUPP, PATH SERV GP  
 SPECIES: RAT/FISCHER-344  
 STUDY START DATE: 23-JAN-84  
 STUDY NUMBER: GLP83009  
 PRINTED: 21-NOV-89  
 PAGE: 695

ANIMAL NUMBER: 358/PRETEST= 358 SEX: FEMALE DOSE GROUP: 3 SACRIFICE STATUS: SACRIFICED MORIBUND  
 DATE OF DEATH: 17-OCT-85 STUDY DAY OF DEATH: 634 STUDY WEEK OF DEATH: 91 TERMINAL BODY WEIGHT: 290.00 (GMS)  
 STUDY TYPE: CHRONIC/2 YR CARCINOGENIC

ORGAN NAME << GROSS ORGAN OBSERVATIONS >>  
 KEYWORDS / PHRASES SEVERITY GROSS FREE-TEXT COMMENTS  
 SUBCUTANEOUS MASS PRESENT SEMIFIRM, WHITE AND RED, 4 X 3.5 X 2CM, ADJACENT TO RIGHT HUMERUS

TISSUE / HISTOPATHOLOGIC FINDINGS << MICROSCOPIC TISSUE OBSERVATIONS >>  
 DISTRIBUTION (SEVERITY) / SPECIAL COMMENTS

- LUNGS ..... FOCAL(MILD)  
 -PNEUMONIA, INTERSTITIAL, CHRONIC
- LIVER ..... NOT SPECIFIED(MILD)  
 -BILE DUCTULE EPITHELIAL HYPERPLASIA AND/OR CHOLANGIOFIBROSIS  
 -HEPATOCYTE COALESCING MICROVESICULAR (FATTY) CHANGE LEADING TO MULTI-FOCAL(TRACE)  
 NECROSIS AND MINERALIZATION
- MAMMARY GLANDS ..... THE MASS ADJACENT TO THE RIGHT NUMEROUS IS A MAMMARY FIBROADENOMA.  
 -HYPERPLASIA AND/OR HYPERTROPHY OF THE ACINAR TISSUE (PRESENT)  
 -B- FIBROADENOMA NOT SPECIFIED (TRACE)  
 -DILATATION (ECTASIA) OF DUCTS AND DUCTULES NOT SPECIFIED (PRESENT)
- EYES & OPTIC N. .... TISSUE IS MISSING  
 MANY ARTIFACTS OF TISSUE PREPARATION MAKE EVALUATION OF EYES IMPOSSIBLE. NO LESIONS ARE RECOGNIZED IN TISSUES AVAILABLE.

**Appendix J (cont.): PATHOLOGY INDIVIDUAL ANIMAL DATA**

LETTERMAN ARMY INSTITUTE OF RESEARCH  
 DIV OF RES SUPP, PATH SERV GP  
 SPECIES: RAT/FISCHER-344  
 STUDY NUMBER: GLP83009  
 STUDY START DATE: 23-JAN-84  
 PRINTED: 21-NOV-89  
 PAGE: 696  
 STUDY TYPE: CHRONIC/2 YR CARCINOGENIC

ANIMAL NUMBER: 359/PRETEST= 359 SEX: FEMALE DOSE GROUP: 3 SACRIFICE STATUS: SACRIFICED MORIBUND  
 DATE OF DEATH: 17-JAN-86 STUDY DAY OF DEATH: 726 STUDY WEEK OF DEATH: 104 TERMINAL BODY WEIGHT: 260.00 (GMS)

ORGAN NAME	KEYWORDS / PHRASES	SEVERITY	GROSS	ORGAN	OBSERVATIONS	GROSS FREE-TEXT COMMENTS
LUNGS	DISCOLORATION	PRESENT			FOCAL, DIFFUSE, VARIABLY SIZED, RED	
KIDNEY	DISCOLORATION	PRESENT			GREEN/BROWN	
KIDNEY	GRANULAR SURFACE	PRESENT			PITTED SURFACE	
LIVER	ENLARGED	PRESENT				
SPLEEN	ENLARGED (SPLENOMEGALY)	MARKED			8 X 3 X 1CM, IRREGULAR SHAPED MARGIN	
PITUITARY GLAND	ENLARGED	PRESENT			.6CM DIAMETER, DARK RED	

TISSUE / HISTOPATHOLOGIC FINDINGS  
 << MICROSCOPIC TISSUE OBSERVATIONS >>  
 DISTRIBUTION (SEVERITY) / SPECIAL COMMENTS

THYROID GLANDS  
 -PARA-FOLLICULAR CELL HYPERPLASIA (4CM CELL, LIGHT CELL) FOCAL(TRACE)

HEART  
 -CARDIOMYOPATHY NOT SPECIFIED(TRACE)  
 -MEDIAL HYPERTROPHY OF MUSCULAR ARTERIES NOT SPECIFIED(MILD)

LUNGS  
 -PNEUMONIA, INTERSTITIAL, CHRONIC MULTI-FOCAL(MILD)  
 -N- LARGE GRANULAR LYMPHOCYTE LEUKEMIA, METASTATIC (PRESENT)

SPLEEN  
 -N- LARGE GRANULAR LYMPHOCYTE LEUKEMIA, METASTATIC (PRESENT)  
 -HEMOSIDERIN PIGMENTATION (RED PULP) NOT SPECIFIED (PRESENT)  
 -SMOOTH MUSCLE HYPERTROPHY, CAPSULE AND TRABECULAE NOT SPECIFIED (PRESENT)

LYMPH NODES  
 -N- LARGE GRANULAR LYMPHOCYTE LEUKEMIA, METASTATIC (PRESENT)

LIVER  
 -BILE DUCTULE EPITHELIAL HYPERPLASIA AND/OR CHOLANGIOFIBROSIS NOT SPECIFIED(MODERATE)

Appendix J (cont.): PATHOLOGY INDIVIDUAL ANIMAL DATA

LETTERMAN ARMY INSTITUTE OF RESEARCH  
 DIV OF RES SUPP, PATH SERV GP  
 SPECIES: RAY/FISCHER-344  
 ANIMAL NUMBER: 359/PRETEST= 359 SEX: FEMALE DOSE GROUP: 3 SACRIFICE STATUS: SACRIFICED MORIBUND  
 DATE OF DEATH: 17-JAN-86 STUDY DAY OF DEATH: 726 STUDY WEEK OF DEATH: 104 TERMINAL BODY WEIGHT: 260.00 (GMS)  
 TISSUE / HISTOPATHOLOGIC FINDINGS << MICROSCOPIC TISSUE OBSERVATIONS >>  
 DISTRIBUTION (SEVERITY) / SPECIAL COMMENTS

INDIVIDUAL ANIMAL DATA REPORT  
 STUDY NUMBER: GLP83009  
 STUDY START DATE: 23-JAN-84  
 PRINTED: 21-NOV-89  
 PAGE: 697  
 STUDY TYPE: CHRONIC/2 YR CARCINOGENIC

- LIVER ..... NOT SPECIFIED(MODERATE)
- HEPATOCTIC DEGENERATIVE CHANGES (NON-NECROTIC) (PRESENT)
- M- LARGE GRANULAR LYMPHOCYTE LEUKEMIA, METASTATIC
- KIDNEY ..... NOT SPECIFIED(MODERATE)
- PROGRESSIVE RENAL DISEASE
- UTERUS ..... MASSON'S TRICHROME STAIN DID NOT REVEAL THE PRESENCE OF MUSCLE TISSUE IN THE TUMOR MASS (PRESENT)
- M- ENDOMETRIAL SARCOMA
- MAMMARY GLANDS ..... NOT SPECIFIED(TRACE)
- HYPERPLASIA AND/OR HYPERTROPHY OF THE ACINAR TISSUE NOT SPECIFIED (PRESENT)
- DILATATION (ECTASIA) OF DUCTS AND DUCTULES
- ADRENAL ..... NOT SPECIFIED(MILD)
- FOCUS OF CELLULAR ALTERATION, VACUOLATED (PRESENT)
- PITUITARY GLAND ..... NOT SPECIFIED (PRESENT)
- B- ADENOMA
- EYES & OPTIC N. .... NOT SPECIFIED (PRESENT)
- METAPLASTIC BONE FORMATION AND/OR MINERALIZATION, SCLERA
- WHOLE BODY ..... NOT SPECIFIED (PRESENT)
- M- LARGE GRANULAR LYMPHOCYTIC LEUKEMIA



Appendix J (cont.): PATHOLOGY INDIVIDUAL ANIMAL DATA

LETTERMAN ARMY INSTITUTE OF RESEARCH INDIVIDUAL ANIMAL DATA REPORT PRINTED: 21-NOV-89  
 DIV OF RES SUPP, PATH SERV GP STUDY NUMBER: GLP83009 PAGE: 698  
 SPECIES: RAT/FISCHER-344 STUDY START DATE: 23-JAN-84 STUDY TYPE: CHRONIC/2 YR CARCINOGENIC

ANIMAL NUMBER: 360/PRETEST= 360 SEX: FEMALE DOSE GROUP: 3 SACRIFICE STATUS: FINAL SACRIFICE  
 DATE OF DEATH: 07-FEB-86 STUDY DAY OF DEATH: 747 STUDY WEEK OF DEATH: 107 TERMINAL BODY WEIGHT: 249.00 (GMS)

<< GROSS ORGAN OBSERVATIONS >>  
 SEVERITY GROSS FREE-TEXT COMMENTS  
 UTERUS POLYP PRESENT ENDOMETRIAL, DISTAL LEFT HORN, 1 X.3CM, YELLOW.  
 LIVER PROMINENT LOBULAR MARKINGS TRACE  
 SPLEEN ENLARGED (SPLENOHEGALY) PRESENT 5.5X1.5X1CM.

<< MICROSCOPIC TISSUE OBSERVATIONS >>  
 DISTRIBUTION (SEVERITY) / SPECIAL COMMENTS

HEART ..... NOT SPECIFIED(MILD)  
 -CARDIOMYOPATHY ..... NOT SPECIFIED(TRACE)  
 -MEDIAL HYPERTROPHY OF MUSCULAR ARTERIES

LUNGS ..... (PRESENT)  
 -N- LARGE GRANULAR LYMPHOCYTE LEUKEMIA, METASTATIC

SPLEEN ..... (PRESENT)  
 -N- LARGE GRANULAR LYMPHOCYTE LEUKEMIA, METASTATIC

LIVER ..... (PRESENT)  
 -N- LARGE GRANULAR LYMPHOCYTE LEUKEMIA, METASTATIC

KIDNEY ..... NOT SPECIFIED(TRACE)  
 -PROGRESSIVE RENAL DISEASE

UTERUS ..... NOT SPECIFIED (PRESENT)  
 -ENDOMETRIAL STROMAL POLYP

MAMMARY GLANDS ..... NOT SPECIFIED(MILD)  
 -HYPERPLASIA AND/OR HYPERTROPHY OF THE ACINAR TISSUE

ADRENAL ..... NOT SPECIFIED(TRACE)  
 -FOCUS OF CELLULAR ALTERATION, VACUOLATED

Appendix J (cont.): PATHOLOGY INDIVIDUAL ANIMAL DATA

LETTERMAN ARMY INSTITUTE OF RESEARCH  
DIV OF RES SUPP, PATH SERV GP  
SPECIES: RAT/FISCHER-344

INDIVIDUAL ANIMAL DATA REPORT  
STUDY NUMBER: GLP83009  
STUDY START DATE: 23-JAN-84

PRINTED: 21-NOV-89  
PAGE: 699

STUDY TYPE: CHRONIC/2 YR CARCINOGENIC

ANIMAL NUMBER: 360/PRETEST= 360 SEX: FEMALE DOSE GROUP: 3 SACRIFICE STATUS: FINAL SACRIFICE  
DATE OF DEATH: 07-FEB-86 STUDY DAY OF DEATH: 747 STUDY WEEK OF DEATH: 107 TERMINAL BODY WEIGHT: 249.00 (GMS)

<< MICROSCOPIC TISSUE OBSERVATIONS >>  
TISSUE / HISTOPATHOLOGIC FINDINGS ..... DISTRIBUTION (SEVERITY) / SPECIAL COMMENTS .....

EYES & OPTIC N. .... CATARACT AND CORNEAL LESIONS ARE UNILATERAL.  
-CORNEAL MINERALIZATION ..... NOT SPECIFIED(TRACE)  
-RETINAL ATROPHY AND/OR DEGENERATION, UNILATERAL OR BILATERAL ..... NOT SPECIFIED(MILD)  
-CORNEAL VASCULARIZATION ..... NOT SPECIFIED(TRACE)  
-LENTICULAR DEGENERATIVE CHANGES COMPATIBLE WITH CATARACT ..... NOT SPECIFIED (PRESENT)

WHOLE BODY .....  
-M- LARGE GRANULAR LYMPHOCYTIC LEUKEMIA ..... (PRESENT)

Appendix J (cont.): PATHOLOGY INDIVIDUAL ANIMAL DATA

LETTERMAN ARMY INSTITUTE OF RESEARCH  
DIV OF RES SUPP, PATH SERV GP  
SPECIES: RAT/FISCHER-344

INDIVIDUAL ANIMAL DATA REPORT  
STUDY NUMBER: GLP83009  
STUDY START DATE: 23-JAN-84

PRINTED: 21-NOV-89  
PAGE: 700  
STUDY TYPE: CHRONIC/2 YR CARCINOGENIC

ANIMAL NUMBER: 361/PRETEST= 361 SEX: FEMALE DOSE GROUP: 3 SACRIFICE STATUS: SACRIFICED MORIBUND  
DATE OF DEATH: 09-SEP-85 STUDY DAY OF DEATH: 596 STUDY WEEK OF DEATH: 86 TERMINAL BODY WEIGHT: 170.00 (GMS)

<< GROSS ORGAN OBSERVATIONS >>  
SEVERITY GROSS FREE-TEXT COMMENTS  
KEYWORDS / PHRASES PRESENT RAISED, GRAY/OPAQUE, MULTIFOCAL, .1-.2CM DIAMETER, DISSEMINATED  
DISCOLORATION IN PARENCHYMA.

<< MICROSCOPIC TISSUE OBSERVATIONS >>  
TISSUE / HISTOPATHOLOGIC FINDINGS DISTRIBUTION (SEVERITY) / SPECIAL COMMENTS

TRACHEA THE TRACHEAL WALL IS INVADDED BY THE THYROID PARAFOLLICULAR CELL  
ADENOCARCINOMA.  
-M- PRESENCE OF METASTATIC NEOPLASM SECONDARY NEOPLASM FROM ORGAN THYROID GLANDS

THYROID GLANDS  
-M- PARA-FOLLICULAR CELL ADENOCARCINOMA (PRESENT)

PARATHYROID TISSUE IS MISSING  
THE ENTIRE THYROID AREA IS OCCUPIED BY A MALIGNANT THYROID  
NEOPLASM. PARATHYROID GLANDS WERE NOT FOUND.

LUNGS  
-MINERALIZATION OF PULMONARY ARTERIES  
-M- PRESENCE OF METASTATIC NEOPLASM NOT SPECIFIED(TRACE)  
SECONDARY NEOPLASM FROM ORGAN THYROID GLANDS

LYMPH NODES  
-HISTIOCYTIC INFILTRATION, SUBCAPSULAR AND MEDULLARY SINUSES NOT SPECIFIED (PRESENT)

KIDNEY THERE IS INFLAMMATION OF PERIRENAL BROWN FAT. LESION IS CODED  
UNDER "WHOLE BODY"  
TISSUE IS MISSING

MAMMARY GLANDS  
PITUITARY GLAND  
-CYST(S) NOT SPECIFIED (PRESENT)

Appendix J (cont.): PATHOLOGY INDIVIDUAL ANIMAL DATA

LETTERMAN ARMY INSTITUTE OF RESEARCH  
DIV OF RES SUPP, PATH SERV GP  
SPECIES: RAT/FISCHER-344

INDIVIDUAL ANIMAL DATA REPORT  
STUDY NUMBER: GLP83009  
STUDY START DATE: 23-JAN-84

PRINTED: 21-NOV-89  
PAGE: 701  
STUDY TYPE: CHRONIC/2 YR CARCINOGENIC

ANIMAL NUMBER: 361/PRETEST= 361 SEX: FEMALE DOSE GROUP: 3 SACRIFICE STATUS: SACRIFICED MORIBUND  
DATE OF DEATH: 09-SEP-85 STUDY DAY OF DEATH: 596 STUDY WEEK OF DEATH: 86 TERMINAL BODY WEIGHT: 170.00 (GMS)

TISSUE / HISTOPATHOLOGIC FINDINGS << M I C R O S C O P I C T I S S U E O B S E R V A T I O N S >>  
DISTRIBUTION (SEVERITY) / SPECIAL COMMENTS

WHOLE BODY ..... THERE IS INFLAMMATION OF BROWN FAT ADJACENT TO SALIVARY GLANDS  
AND ADJACENT TO KIDNEYS  
-INFLAMMATION OF BROWN FAT, (LOCATION SPECIFIED IN COMMENTS) NOT SPECIFIED (PRESENT)

**Appendix J (cont.): PATHOLOGY INDIVIDUAL ANIMAL DATA**

LETTERMAN ARMY INSTITUTE OF RESEARCH  
 DIV OF RES SUPP, PATH SERV GP  
 SPECIES: RAT/FISCHER-344  
 STUDY START DATE: 23-JAN-84  
 STUDY NUMBER: GLP83009  
 PRINTED: 21-NOV-89  
 PAGE: 702

ANIMAL NUMBER: 362/PRETEST-  
 DATE OF DEATH: 26-NOV-85  
 STUDY DAY OF DEATH: 674  
 SEX: FEMALE  
 DOSE GROUP: 3  
 SACRIFICE STATUS: SACRIFICED MORIBUND  
 STUDY WEEK OF DEATH: 97  
 TERMINAL BODY WEIGHT: 235.00 (GMS)

STUDY TYPE: CHRONIC/2 YR CARCINOGENIC

ORGAN NAME SEVERITY GROSS FREE-TEXT COMMENTS  
 -----  
 SPLEEN ENLARGED (SPLENOMEGALY) PRESENT 6 X 1.5 X 1CM  
 LIVER PROMINENT LOBULAR MARKINGS MODERATE  
 KIDNEY DISCOLORATION PRESENT  
 PITUITARY GLAND DISCOLORATION PRESENT  
 PITUITARY GLAND ENLARGED PRESENT

TISSUE / HISTOPATHOLOGIC FINDINGS  
 -----  
 << MICROSCOPIC TISSUE OBSERVATIONS >>  
 DISTRIBUTION (SEVERITY) / SPECIAL COMMENTS  
 -----

THYROID GLANDS ..... (PRESENT)  
 -B- PARA-FOLLICULAR CELL ADENOMA

SALIVARY GLAND ..... THERE IS MAMMARY HYPERPLASIA IN THE ADIPOSE TISSUE ADJACENT TO THE SALIVARY GLAND

HEART ..... NOT SPECIFIED(MODERATE)  
 -CARDIOMYOPATHY

LUNGS ..... (PRESENT)  
 -N- LARGE GRANULAR LYMPHOCYTE LEUKEMIA, METASTATIC

THYMUS ..... (PRESENT)  
 -N- LARGE GRANULAR LYMPHOCYTE LEUKEMIA, METASTATIC

SPLEEN ..... (PRESENT)  
 -N- LARGE GRANULAR LYMPHOCYTE LEUKEMIA, METASTATIC

LIVER ..... MULTIFOCAL NECROSIS AND HEPATOCYTTIC DEGENERATIVE CHANGES ARE SECONDARY TO LGLL  
 -BILE DUCTULE EPITHELIAL HYPERPLASIA AND/OR CHOLANGIOFIBROSIS NOT SPECIFIED(MILD)  
 -HEPATOCYTTIC DEGENERATIVE CHANGES (NON-NECROTIC) DIFFUSE(MODERATE)  
 -NECROSIS, HEPATOCYTTIC, INDIVIDUAL CELLS DIFFUSE(MILD)  
 -N- LARGE GRANULAR LYMPHOCYTE LEUKEMIA, METASTATIC (PRESENT)

KIDNEY .....

Appendix J (cont.): PATHOLOGY INDIVIDUAL ANIMAL DATA

LETTERMAN ARMY INSTITUTE OF RESEARCH  
 DIV OF RES SUPP, PATH SERV GP  
 SPECIES: RAT/FISCHER-344

INDIVIDUAL ANIMAL DATA REPORT  
 STUDY NUMBER: GLP85009  
 STUDY START DATE: 23-JAN-84

ANIMAL NUMBER: 362/PRETEST=  
 DATE OF DEATH: 26-NOV-85  
 STUDY DAY OF DEATH: 674  
 SEX: FEMALE  
 DOSE GROUP: 3  
 SACRIFICE STATUS: SACRIFICED MORIBUND  
 TERMINAL BODY WEIGHT: 235.00 (GMS)

STUDY TYPE: CHRONIC/2 YR CARCINOGENIC

TISSUE / HISTOPATHOLOGIC FINDINGS  
 << I C R O S C O P I C T I S S U E O B S E R V A T I O N S >>  
 DISTRIBUTION (SEVERITY) / SPECIAL COMMENTS

PRINTED: 21-NOV-89  
PAGE: 703

- KIDNEY ..... NOT SPECIFIED (TRACE)
- PROGRESSIVE RENAL DISEASE
- ILEUM ..... (PRESENT)
- N- LARGE GRANULAR LYMPHOCYTE LEUKEMIA, METASTATIC
- PANCREAS ..... NOT SPECIFIED (MILD)
- ACINAR (EXOCRINE) ATROPHY
- MAMMARY GLANDS ..... NOT SPECIFIED (MILD)
- HYPERPLASIA AND/OR HYPERTROPHY OF THE ACINAR TISSUE
- DILATATION (ECTASIA) OF DUCTS AND DUCTULES
- NOSE/TURBINATES ..... CELLULITIS INVOLVES NASO-LACRIMAL DUCT REGION
- MIXED INFLAMMATORY CELL INFILTRATION, NASAL CAVITY, SINUSES,  
 TURBINATES, NASO-LACRIMAL DUCTS
- ADRENAL ..... NOT SPECIFIED (MILD)
- FOCUS OF CELLULAR ALTERATION, VACUOLATED
- PITUITARY GLAND ..... (PRESENT)
- B- ADENOMA
- EYES & OPTIC N. .... NOT SPECIFIED (MILD)
- RETINAL ATROPHY AND/OR DEGENERATION, UNILATERAL OR BILATERAL
- METAPLASTIC BONE FORMATION AND/OR MINERALIZATION, SCLERA
- WHOLE BODY ..... (PRESENT)
- M- LARGE GRANULAR LYMPHOCYTTIC LEUKEMIA

Appendix J (cont.): PATHOLOGY INDIVIDUAL ANIMAL DATA

LETTERMAN ARMY INSTITUTE OF RESEARCH  
 DIV OF RES SUPP, PATH SERV GP  
 SPECIES: RAT/FISCHER-344

INDIVIDUAL ANIMAL DATA REPORT  
 STUDY NUMBER: GLP83009  
 STUDY START DATE: 23-JAN-84

PRINTED: 21-NOV-89  
 PAGE: 704

STUDY TYPE: CHRONIC/2 YR CARCINOGENIC

ANIMAL NUMBER: 363/PRETEST= 363 SEX: FEMALE DOSE GROUP: 3 SACRIFICE STATUS: FINAL SACRIFICE  
 DATE OF DEATH: 07-FEB-86 STUDY DAY OF DEATH: 747 STUDY WEEK OF DEATH: 107 TERMINAL BODY WEIGHT: 279.00 (GMS)

<< GROSS ORGAN OBSERVATIONS >>  
 SEVERITY GROSS FREE-TEXT COMMENTS  
 KEYWORDS / PHRASES  
 PARA-OVARIAN CYST(S) PRESENT LEFT, 1.5CM DIAMETER.

<< MICROSCOPIC TISSUE OBSERVATIONS >>  
 DISTRIBUTION (SEVERITY) / SPECIAL COMMENTS

TISSUE / HISTOPATHOLOGIC FINDINGS

EXORBITAL LACRIM ..... FOCAL(TRACE)  
 -ACINAR ATROPHY

HEART ..... NOT SPECIFIED(TRACE)  
 -CARDIOMYOPATHY

LUNGS ..... NOT SPECIFIED(TRACE)  
 -MINERALIZATION OF PULMONARY ARTERIES

LYMPH NODES ..... REACTIVE HYPERPLASIA IS LIMITED TO ONE MEDIASTINAL LYMPH NODE.  
 -REACTIVE HYPERPLASIA NOT SPECIFIED (PRESENT)

LIVER ..... MULTI-FOCAL(TRACE)  
 -HEPATITIS FOCAL(TRACE)  
 -FOCUS OF CELLULAR ALTERATION - BASOPHILIC MULTI-FOCAL(MILD)  
 -HEPATOCTYE COALESCING MICROVESICULAR (FATTY) CHANGE LEADING TO NECROSIS AND MINERALIZATION

KIDNEY ..... NOT SPECIFIED(TRACE)  
 -PROGRESSIVE RENAL DISEASE

OVARIES ..... A PAROVARIAN CYST WAS REPORTED ON GROSS EXAMINATION. THERE WERE  
 NO MICROSCOPIC CHANGES CORRESPONDING TO THIS LESION IN SECTIONS  
 SUBMITTED FOR HISTOLOGIC EXAMINATION.

MAMMARY GLANDS ..... NOT SPECIFIED(TRACE)  
 -HYPERPLASIA AND/OR HYPERTROPHY OF THE ACINAR TISSUE  
 -DILATATION (ECTASIA) OF DUCTS AND DUCTULES NOT SPECIFIED (PRESENT)

ADRENAL .....

Appendix J (cont.): PATHOLOGY INDIVIDUAL ANIMAL DATA

LETTERMAN ARMY INSTITUTE OF RESEARCH  
DIV OF RES SUPP, PATH SERV GP  
SPECIES: RAT/FISCHER-344

INDIVIDUAL ANIMAL DATA REPORT  
STUDY NUMBER: GLP83009  
STUDY START DATE: 23-JAN-84

PRINTED: 21-NOV-89  
PAGE: 705

STUDY TYPE: CHRONIC/2 YR CARCINOGENIC

ANIMAL NUMBER: 363/PRETEST= 363 SEX: FEMALE DOSE GROUP: 3 SACRIFICE STATUS: FINAL SACRIFICE  
DATE OF DEATH: 07-FEB-86 STUDY DAY OF DEATH: 747 STUDY WEEK OF DEATH: 107 TERMINAL BODY WEIGHT: 279.00 (GMS)

<< M I C R O S C O P I C T I S S U E O B S E R V A T I O N S >>  
TISSUE / HISTOPATHOLOGIC FINDINGS DISTRIBUTION (SEVERITY) / SPECIAL COMMENTS

ADRENAL ..... NOT SPECIFIED (TRACE)  
- FOCUS OF CELLULAR ALTERATION, VACUOLATED

EYES & OPTIC N. .... THE CATARACT IS SUBCAPSULAR, UNILATERAL AND VERY SLIGHT.  
- METAPLASTIC BONE FORMATION AND/OR MINERALIZATION, SCLERA NOT SPECIFIED (PRESENT)  
- LENTICULAR DEGENERATIVE CHANGES COMPATIBLE WITH CATARACT NOT SPECIFIED (PRESENT)



Appendix J (cont.): PATHOLOGY INDIVIDUAL ANIMAL DATA

LETTERMAN ARMY INSTITUTE OF RESEARCH INDIVIDUAL ANIMAL DATA REPORT PRINTED: 21-NOV-89  
DIV OF RES SUPP, PATH SERV GP STUDY NUMBER: GLP83009 PAGE: 706  
SPECIES: RAT/FISCHER-344 STUDY START DATE: 23-JAN-84 STUDY TYPE: CHRONIC/2 YR CARCINOGENIC

ANIMAL NUMBER: 364/PRETEST# 364 SEX: FEMALE DOSE GROUP: 3 SACRIFICE STATUS: FINAL SACRIFICE  
DATE OF DEATH: 07-FEB-86 STUDY DAY OF DEATH: 747 STUDY WEEK OF DEATH: 107 TERMINAL BODY WEIGHT: 210.00 (GMS)

ORGAN NAME << GROSS ORGAN OBSERVATIONS >> SEVERITY GROSS FREE-TEXT COMMENTS  
KEYWORDS / PHRASES  
PITUITARY GLAND ENLARGED PRESENT .25CM DIAMETER.  
LIVER ADHESION(S) PRESENT DIAPHRAGM.  
MAMMARY GLAND PROMINENT PRESENT CYSTIC.

TISSUE / HISTOPATHOLOGIC FINDINGS << MICROSCOPIC TISSUE OBSERVATIONS >> DISTRIBUTION (SEVERITY) / SPECIAL COMMENTS

LACRIMAL GLAND .....  
-INFLAMMATION, SUBACUTE TO CHRONIC  
-ATROPHY AND/OR LOSS OF ACINAR TISSUE

HEART .....  
-CARDIOMYOPATHY

LUNGS .....  
-MINERALIZATION OF PULMONARY ARTERIES

THYMUS .....  
TISSUE IS MISSING  
NO THYMIC TISSUE WAS PRESENT IN ORIGINAL SECTIONS OR RE CUTS OF BLOCK #7.

LYMPH NODES .....  
MESENTERIC LYMPH NODES ARE HYPERPLASTIC PROBABLY AS A RESULT OF THE STEATITIS IN MESENTERIC FAT. THIS LESION IS CODED UNDER "WHOLE BODY".  
NOT SPECIFIED (PRESENT)

-REACTIVE HYPERPLASIA

Appendix J (cont.): PATHOLOGY INDIVIDUAL ANIMAL DATA

LETTERMAN ARMY INSTITUTE OF RESEARCH  
DIV OF RES SUPP, PATH SERV GP  
SPECIES: RAT/FISCHER-344

INDIVIDUAL ANIMAL DATA REPORT  
STUDY NUMBER: GLP83009

PRINTED: 21-NOV-89  
PAGE: 707

STUDY START DATE: 23-JAN-84

STUDY TYPE: CHRONIC/2 YR CARCINOGENIC

ANIMAL NUMBER: 364/PRETEST=

364 SEX: FEMALE

DOSE GROUP: 3

SACRIFICE STATUS: FINAL SACRIFICE

DATE OF DEATH: 07-FEB-86

STUDY DAY OF DEATH: 747

STUDY WEEK OF DEATH: 107

TERMINAL BODY WEIGHT: 210.00 (GMS)

<< MICROSCOPIC TISSUE

OBSERVATIONS >>

DISTRIBUTION (SEVERITY) / SPECIAL COMMENTS

LIVER

SECTION #21 WAS INCLUDED WITHOUT EXPLANATION FROM GROSS NECROPSY OR TISSUE TRIMMING LAB. THIS IS A SMALL FRAGMENT OF LIVER WHICH WAS ABUNDANT TEST MATERIAL AND TYPICAL ATTENDANT REACTION ON THE CAPSULAR SURFACE. DETAILED MICROSCOPIC EXAMINATION OF ALL TISSUES AND AN EXHAUSTIVE SEARCH OF WET TISSUES WITH ADDITIONAL MICROSCOPIC EXAMINATION (SECTION #22) FAILED TO DEMONSTRATE TEST MATERIAL OR REACTION TO IT. SMALL, VERY FINE ADHESIONS BETWEEN LIVER AND DIAPHRAGM ARE PRESENT IN SECTION #22 CORRESPONDING TO GROSS FINDINGS. CONCLUSION: TISSUE IN BLOCK #21 DOES NOT BELONG TO THIS ANIMAL AND WERE PLACED WITH THIS RAT'S TISSUES IN ERROR. ALL OTHER INDICATIONS ARE THAT THIS IS A CONTROL ANIMAL THAT WAS NOT EXPOSED TO THE TEST MATERIAL.

-BILE DUCTULE EPITHELIAL HYPERPLASIA AND/OR CHOLANGIOFIBROSIS  
-HEPATITIS  
-HEPATOCYTE COALESCING MICROVESICULAR (FATTY) CHANGE LEADING TO NECROSIS AND MINERALIZATION

KIDNEY  
-PROGRESSIVE RENAL DISEASE

UTERUS  
-ENDOMETRIAL STROMAL POLYP  
-CYSTIC DILATATION OF THE ENDOMETRIAL GLANDS

TONGUE  
-PERIARTERITIS

MAMMARY GLANDS  
-HYPERPLASIA AND/OR HYPERTROPHY OF THE ACINAR TISSUE  
-DILATATION (ECTASIA) OF DUCTS AND DUCTULES

ADRENAL

NOT SPECIFIED(MILD)

NOT SPECIFIED (PRESENT)  
NOT SPECIFIED (PRESENT)

FOCAL(TRACE)

NOT SPECIFIED(MARKED)  
NOT SPECIFIED (PRESENT)

Appendix J (cont.): PATHOLOGY INDIVIDUAL ANIMAL DATA

LETTERMAN ARMY INSTITUTE OF RESEARCH  
DIV OF RES SUPP, PATH SERV GP  
SPECIES: RAT/FISCHER-344

INDIVIDUAL ANIMAL DATA REPORT  
STUDY NUMBER: GLP83009  
STUDY START DATE: 23-JAN-84

PRINTED: 21-NOV-89  
PAGE: 708

STUDY TYPE: CHRONIC/2 YR CARCINOGENIC

ANIMAL NUMBER: 364/PRETEST= 364 SEX: FEMALE DOSE GROUP: 3 SACRIFICE STATUS: FINAL SACRIFICE  
DATE OF DEATH: 07-FEB-86 STUDY DAY OF DEATH: 747 STUDY WEEK OF DEATH: 107 TERMINAL BODY WEIGHT: 210.00 (GMS)

TISSUE / HISTOPATHOLOGIC FINDINGS << M I C R O S C O P I C T I S S U E O B S E R V A T I O N S >>  
DISTRIBUTION (SEVERITY) / SPECIAL COMMENTS

ADRENAL ..... FOCAL(TRACE)  
- FOCUS OF CELLULAR ALTERATION, VACUOLATED

PITUITARY GLAND .....  
- B - ADENOMA (PRESENT)

WHOLE BODY ..... INFLAMMATION OF MESENTERIC FAT WAS NOTED IN SECTION #7 ADJACENT  
TO MESENTERIC LYMPH NODES.  
- INFLAMMATION OF BROWN FAT, (LOCATION SPECIFIED IN COMMENTS) NOT SPECIFIED (PRESENT)

Appendix J (cont.): PATHOLOGY INDIVIDUAL ANIMAL DATA

LETTERMAN ARMY INSTITUTE OF RESEARCH  
 DIV OF RES SUPP, PATH SERV GP  
 SPECIES: RAT/FISCHER-344  
 STUDY START DATE: 23-JAN-84  
 STUDY NUMBER: GLP83009  
 PRINTED: 21-NOV-89  
 PAGE: 709

ANIMAL NUMBER: 365/PRETEST= 365 SEX: FEMALE DOSE GROUP: 3 SACRIFICE STATUS: SACRIFICED MORIBUND  
 DATE OF DEATH: 01-AUG-85 STUDY DAY OF DEATH: 557 STUDY WEEK OF DEATH: 80 TERMINAL BODY WEIGHT: 183.00 (GMS)

ORGAN NAME << GROSS ORGAN OBSERVATIONS >>  
 KEYWORDS / PHRASES SEVERITY GROSS FREE-TEXT COMMENTS  
 EYES & OPTIC N. CORNEAL OPACITY PRESENT RIGHT

TISSUE / HISTOPATHOLOGIC FINDINGS << MICROSCOPIC TISSUE OBSERVATIONS >>  
 DISTRIBUTION (SEVERITY) / SPECIAL COMMENTS

LUNGS ..... NOT SPECIFIED (TRACE)  
 -MINERALIZATION OF PULMONARY ARTERIES .....  
 LIVER .....  
 -HEPATITIS .....  
 -FOCUS OF CELLULAR ALTERATION - EOSINOPHILIC CELLS ..... MULTI-FOCAL (TRACE)  
 ..... MULTI-FOCAL (TRACE)  
 KIDNEY ..... ACUTE HEMORRHAGE IS PROBABLY A TERMINAL LESION  
 -HEMORRHAGE, ACUTE, ..... NOT SPECIFIED (PRESENT)  
 NOSE/TURBINATES ..... THE INFLAMMATION IS PYOGRAMULOMATOUS AND IS LOCATED ON AND NEAR  
 ..... THE NASAL SEPTUM AND NEAR THE MASO-LACRIMAL DUCT BILATERALLY.  
 ..... FOREIGN BODY (PLANT MATERIAL) IS PRESENT.  
 ..... NOT SPECIFIED (MARKED)

-SUBACUTE INFLAMMATION ..... SECTION OF STERNUM IS MISSING

BONE, STERNUM ..... NOT SPECIFIED (PRESENT)

ADRENAL ..... TISSUE IS MISSING  
 -CORTICAL MODULAR HYPERPLASIA

PITUITARY GLAND ..... CATARACT IS UNILATERAL AND SUBCAPSULAR. IT INVOLVES THE EYE  
 EYES & OPTIC N. ..... AFFECTED BY THE RETINAL DEGENERATION.  
 -RETINAL ATROPHY AND/OR DEGENERATION, UNILATERAL OR BILATERAL  
 -LENTICULAR DEGENERATIVE CHANGES COMPATIBLE WITH CATARACT NOT SPECIFIED (MODERATE)  
 NOT SPECIFIED (PRESENT)

**Appendix J (cont.): PATHOLOGY INDIVIDUAL ANIMAL DATA**

LETTERMAN ARMY INSTITUTE OF RESEARCH  
 DIV OF RES SUPP, PATH SERV GP  
 STUDY NUMBER: GLP83009  
 STUDY START DATE: 23-JAN-84  
 STUDY TYPE: CHRONIC/2 YR CARCINOGENIC  
 ANIMAL NUMBER: 366/PRETEST= 366 SEX: FEMALE DOSE GROUP: 3 SACRIFICE STATUS: FINAL SACRIFICE  
 DATE OF DEATH: 07-FEB-86 STUDY DAY OF DEATH: 747 STUDY WEEK OF DEATH: 107 TERMINAL BODY WEIGHT: 284.00 (GMS)  
 << GROSS ORGAN OBSERVATIONS >>  
 SEVERITY GROSS FREE-TEXT COMMENTS  
 PRESENT LEFT LATERAL, .3 X .4CM.

PRINTED: 21-NOV-89  
 PAGE: 710

TISSUE / HISTOPATHOLOGIC FINDINGS << MICROSCOPIC TISSUE OBSERVATIONS >>  
 DISTRIBUTION (SEVERITY) / SPECIAL COMMENTS

THYROID GLANDS  
 -M- PARA-FOLLICULAR CELL ADENOCARCINOMA (PRESENT)

LACRIMAL GLAND  
 -INFLAMMATION, SUBACUTE TO CHRONIC MULTI-FOCAL(TRACE)

EXORBITAL LACRIM  
 -ACINAR ATROPHY NOT SPECIFIED(TRACE)

HEART  
 -CARDIOMYOPATHY NOT SPECIFIED(MILD)  
 -MEDIAL HYPERTROPHY OF MUSCULAR ARTERIES NOT SPECIFIED(TRACE)

LYMPH NODES  
 -RED BLOOD CELLS, HEMOSIDERIN AND/OR ERYTHROPHAGOCYTOSIS WITHIN  
 MEDULLARY SINUSES  
 -HISTIOCYTIC INFILTRATION, SUBCAPSULAR AND MEDULLARY SINUSES  
 -M- PRESENCE OF METASTATIC NEOPLASM  
 A SMALL LYMPH NODE ADJACENT TO THE THYROID CONTAINS METASTASIS OF THE PARAFOLLICULAR CELL ADENOCARCINOMA. A MEDIASTINAL NODE NEAR THE THYROID CONTAINS ERYTHROPHAGOCYTOSIS AND HEMOSIDERIN. THE HISTIOCYTIC INFILTRATION INVOLVES MESENTERIC NODES.  
 NOT SPECIFIED (PRESENT)

LIVER  
 -HEPATITIS  
 -PERIPORTAL MONONUCLEAR CELLULAR INFILTRATION  
 -BENIGN HYPERPLASTIC NODULE(S)  
 NOT SPECIFIED (PRESENT)  
 SECONDARY NEOPLASM FROM ORGAN THYROID GLANDS

THE LIVER NODULE NOTED GROSSLY WAS EXAMINED HISTOLOGICALLY. ESSENTIALLY, IT CONSISTS OF LIVER TISSUE WITH THE CHANGES CODED. THERE ARE NO HYPERPLASTIC CELLULAR CHANGES IN THE NODULE.  
 MULTI-FOCAL(TRACE)  
 MULTI-FOCAL(TRACE)  
 NOT SPECIFIED(MILD)

Appendix J (cont.): PATHOLOGY INDIVIDUAL ANIMAL DATA

LETTERMAN ARMY INSTITUTE OF RESEARCH  
DIV OF RES SUPP, PATH SERV GP  
SPECIES: RAT/FISCHER-344

INDIVIDUAL ANIMAL DATA REPORT  
STUDY NUMBER: GLP83009

PRINTED: 21-NOV-89  
PAGE: 711

STUDY START DATE: 23-JAN-84

STUDY TYPE: CHRONIC/2 YR CARCINOGENIC

ANIMAL NUMBER: 366/PRETEST-366 SEX: FEMALE DOSE GROUP: 3 SACRIFICE STATUS: FINAL SACRIFICE  
DATE OF DEATH: 07-FEB-86 STUDY DAY OF DEATH: 747 STUDY WEEK OF DEATH: 107 TERMINAL BODY WEIGHT: 284.00 (GMS)

<< MICROSCOPIC TISSUE OBSERVATIONS >>  
DISTRIBUTION (SEVERITY) / SPECIAL COMMENTS

LIVER

-HEPATOCYTE COALESCING MICROVESICULAR (FATTY) CHANGE LEADING TO MULTI-FOCAL(MILD)  
NECROSIS AND MINERALIZATION

KIDNEY

-PROGRESSIVE RENAL DISEASE NOT SPECIFIED(TRACE)

MAMMARY GLANDS

MAMMARY HYPERPLASIA IS MINIMAL IN SECTION #15. HOWEVER THERE IS SIGNIFICANT MAMMARY TISSUE IN THE SUBCUTIS OF THE CERVICAL REGION ADJACENT TO SALIVARY GLANDS IN SECTION #4.  
NOT SPECIFIED(MILD)

-HYPERPLASIA AND/OR HYPERTROPHY OF THE ACINAR TISSUE

NOSE/TURBINATES

-MIXED INFLAMMATORY CELL INFILTRATION, NASAL CAVITY, SINUSES, INFILTRATE IS BILATERAL ADJACENT NASO-LACRIMAL DUCTS.  
TURBINATES, NASO-LACRIMAL DUCTS NOT SPECIFIED(MILD)

ADRENAL

-FOCUS OF CELLULAR ALTERATION, VACUOLATED NOT SPECIFIED(TRACE)

PITUITARY GLAND

-B- ADENOMA THE ADENOMA IS PERIPHERALLY LOCATED AND QUITE SMALL.  
(PRESENT)

EYES & OPTIC N.

-METAPLASTIC BONE FORMATION AND/OR MINERALIZATION, SCLERA NOT SPECIFIED (PRESENT)

Appendix J (cont.): PATHOLOGY INDIVIDUAL ANIMAL DATA

LETTERMAN ARMY INSTITUTE OF RESEARCH  
 DIV OF RES SUPP, PATH SERV GP  
 SPECIES: RAT/FISCHER-344  
 STUDY START DATE: 23-JAN-84  
 STUDY NUMBER: GLP83009  
 PRINTED: 21-NOV-89  
 PAGE: 712  
 STUDY TYPE: CHRONIC/2 YR CARCINOGENIC  
 ANIMAL NUMBER: 367/PRETEST-  
 DATE OF DEATH: 07-FEB-86  
 SEX: FEMALE  
 DOSE GROUP: 3  
 SACRIFICE STATUS: FINAL SACRIFICE  
 STUDY DAY OF DEATH: 747  
 STUDY WEEK OF DEATH: 107  
 TERMINAL BODY WEIGHT: 241.00 (GMS)  
 << GROSS ORGAN OBSERVATIONS >>  
 KEYWORDS / PHRASES SEVERITY GROSS FREE-TEXT COMMENTS  
 NO GROSS LESIONS RECOGNIZED PRESENT

<< MICROSCOPIC TISSUE OBSERVATIONS >>  
 DISTRIBUTION (SEVERITY) / SPECIAL COMMENTS

THYROID GLANDS  
 -PARA-FOLLICULAR CELL HYPERPLASIA (\*C\* CELL, LIGHT CELL) NOT SPECIFIED(TRACE)

EXORBITAL LACRIM  
 -SUBACUTE INFLAMMATION FOCAL(TRACE)

HEART  
 -CARDIOMYOPATHY NOT SPECIFIED(MILD)  
 -MEDIAL HYPERTROPHY OF MUSCULAR ARTERIES NOT SPECIFIED(TRACE)

LUNGS  
 -PNEUMONIA, GRANULOMATOUS MULTI-FOCAL(MILD)

LYMPH NODES  
 -RED BLOOD CELLS, HEMOSIDERIN AND/OR ERYTHROPHAGOCYTOSIS WITHIN RBC'S AND HEMOSIDERIN PRESENT IN MESENTERIC NODES ONLY.  
 MEDULLARY SINUSES NOT SPECIFIED (PRESENT)

LIVER  
 -BILE DUCTULE EPITHELIAL HYPERPLASIA AND/OR CHOLANGIOFIBROSIS NOT SPECIFIED(MILD)  
 -HEPATITIS NOT SPECIFIED(TRACE)  
 -FOCUS OF CELLULAR ALTERATION - CLEAR CELLS NOT SPECIFIED(TRACE)  
 -HEPATOCTYCE COALESCING MICROVESICULAR (FATTY) CHANGE LEADING TO NECROSIS AND MINERALIZATION NOT SPECIFIED(MILD)

KIDNEY  
 -PROGRESSIVE RENAL DISEASE NOT SPECIFIED(MILD)

PANCREAS

Appendix J (cont.):

PATHOLOGY INDIVIDUAL ANIMAL DATA

LETTERMAN ARMY INSTITUTE OF RESEARCH  
DIV OF RES SUPP, PATH SERV GP  
SPECIES: RAT/FISCHER-344

INDIVIDUAL ANIMAL DATA REPORT  
STUDY NUMBER: GLP83009  
STUDY START DATE: 23-JAN-84

PRINTED: 21-NOV-89  
PAGE: 713

STUDY TYPE: CHRONIC/2 YR CARCINOGENIC

ANIMAL NUMBER: 367/PRETEST= 367 SEX: FEMALE DOSE GROUP: 3 SACRIFICE STATUS: FINAL SACRIFICE  
DATE OF DEATH: 07-FEB-86 STUDY DAY OF DEATH: 747 STUDY WEEK OF DEATH: 107 TERMINAL BODY WEIGHT: 241.00 (GMS)

TISSUE / HISTOPATHOLOGIC FINDINGS << MICROSCOPIC TISSUE OBSERVATIONS >>  
DISTRIBUTION (SEVERITY) / SPECIAL COMMENTS

PANCREAS ..... FOCAL(TRACE)  
-ACINAR (EXOCRINE) ATROPHY

MAMMARY GLANDS ..... NOT SPECIFIED(TRACE)  
-HYPERPLASIA AND/OR HYPERTROPHY OF THE ACINAR TISSUE  
-DILATATION (ECTASIA) OF DUCTS AND DUCTULES NOT SPECIFIED (PRESENT)

ADRENAL ..... NOT SPECIFIED(MILD)  
-FOCUS OF CELLULAR ALTERATION, VACUOLATED



Appendix J (cont.): PATHOLOGY INDIVIDUAL ANIMAL DATA

LETTERMAN ARMY INSTITUTE OF RESEARCH  
 DIV OF RES SUPP, PATH SERV GP  
 SPECIES: RAT/FISCHER-344  
 STUDY START DATE: 23-JAN-84  
 STUDY NUMBER: GLP83009  
 PRINTED: 21-NOV-89  
 PAGE: 714  
 STUDY TYPE: CHRONIC/2 YR CARCINOGENIC

ANIMAL NUMBER: 368/PRETEST= 368 SEX: FEMALE DOSE GROUP: 3 SACRIFICE STATUS: FINAL SACRIFICE  
 DATE OF DEATH: 10-FEB-86 STUDY DAY OF DEATH: 750 STUDY WEEK OF DEATH: 108 TERMINAL BODY WEIGHT: 278.00 (GMS)

<< GROSS ORGAN OBSERVATIONS >>  
 SEVERITY GROSS FREE-TEXT COMMENTS  
 KEYWORDS / PHRASES PRESENT  
 GRANULAR SURFACE PRESENT  
 PITUITARY GLAND ENLARGED .5CM DIAMETER, RED

<< MICROSCOPIC TISSUE OBSERVATIONS >>  
 DISTRIBUTION (SEVERITY) / SPECIAL COMMENTS

EXORBITAL LACRIM ..... MULTI-FOCAL(TRACE)  
 -ACINAR ATROPHY .....

HEART .....  
 -CARDIOMYOPATHY ..... NOT SPECIFIED(MILD)  
 -MEDIAL HYPERTROPHY OF MUSCULAR ARTERIES ..... NOT SPECIFIED(TRACE)

LYMPH NODES ..... RBC'S AND MEMOSIDERIN LIMITED TO MEDIASTINAL NODES.  
 -RED BLOOD CELLS, MEMOSIDERIN AND/OR ERYTHROPHAGOCYTOSIS WITHIN ..... NOT SPECIFIED (PRESENT)  
 MEDULLARY SINUSES .....

LIVER .....  
 -HEPATITIS ..... FOCAL(TRACE)  
 -HEPATOCTYIC VACUOLIZATION ..... MULTI-FOCAL(TRACE)

KIDNEY .....  
 -PROGRESSIVE RENAL DISEASE ..... NOT SPECIFIED(MARKED)

UTERUS .....  
 -ENDOMETRIAL STROMAL POLYP ..... NOT SPECIFIED (PRESENT)

MAMMARY GLANDS .....  
 -HYPERPLASIA AND/OR HYPERTROPHY OF THE ACINAR TISSUE ..... NOT SPECIFIED(TRACE)  
 -DILATATION (ECTASIA) OF DUCTS AND DUCTULES ..... NOT SPECIFIED (PRESENT)

NOSE/TURBINATES ..... INFILTRATE INVOLVES NASO-LACRIMAL DUCT.

Appendix J (cont.): PATHOLOGY INDIVIDUAL ANIMAL DATA

LETTERMAN ARMY INSTITUTE OF RESEARCH  
DIV OF RES SUPP, PATH SERV GP  
SPECIES: RAT/FISCHER-344

INDIVIDUAL ANIMAL DATA REPORT  
STUDY NUMBER: GLP83009  
STUDY START DATE: 23-JAN-84

PRINTED: 21-NOV-89  
PAGE: 715

STUDY TYPE: CHRONIC/2 YR CARCINOGENIC

ANIMAL NUMBER: 368/PRETEST-368 SEX: FEMALE DOSE GROUP: 3 SACRIFICE STATUS: FINAL SACRIFICE  
DATE OF DEATH: 10-FEB-86 STUDY DAY OF DEATH: 750 STUDY WEEK OF DEATH: 108 TERMINAL BODY WEIGHT: 278.00 (GMS)

TISSUE / HISTOPATHOLOGIC FINDINGS << MICROSCOPIC TISSUE OBSERVATIONS >>  
DISTRIBUTION (SEVERITY) / SPECIAL COMMENTS

NOSE/TURBINATES .....  
-MIXED INFLAMMATORY CELL INFILTRATION, NASAL CAVITY, SINUSES, ..... NOT SPECIFIED(MILD)  
TURBINATES, NASO-LACRIMAL DUCTS

ADRENAL .....  
-FOCUS OF CELLULAR ALTERATION, VACUOLATED ..... NOT SPECIFIED(TRACE)

PITUITARY GLAND .....  
-B- ADENOMA ..... (PRESENT)

EYES & OPTIC N. ....  
-RETINAL ATROPHY AND/OR DEGENERATION, UNILATERAL OR BILATERAL ..... NOT SPECIFIED(TRACE)

Appendix J (cont.): PATHOLOGY INDIVIDUAL ANIMAL DATA

LETTERMAN ARMY INSTITUTE OF RESEARCH
INDIVIDUAL ANIMAL DATA REPORT
DIV OF RES SUPP, PATH SERV GP
SPECIES: RAT/FISCHER-344
STUDY NUMBER: GLP83009
STUDY START DATE: 23-JAN-84
STUDY TYPE: CHRONIC/2 YR CARCINOGENIC
ANIMAL NUMBER: 369/PRETEST
DOSE GROUP: 3
SACRIFICE STATUS: FINAL SACRIFICE
DATE OF DEATH: 10-FEB-86
STUDY DAY OF DEATH: 750
STUDY WEEK OF DEATH: 108
TERMINAL BODY WEIGHT: 327.00 (GMS)

ORGAN NAME
KEYWORDS / PHRASES
OBSERVATIONS
SEVERITY
GROSS FREE-TEXT COMMENTS
SKIN
ABSCESSES
LIVER
PROMINENT LOBULAR MARKINGS
SPLEEN
ENLARGED (SPLENOEGALY)
UTERUS
HYPOPLASIA
PRESENT
TRACE
PRESENT
.3CM DIAMETER, CLITORAL GLAND
4 X 1.25CM
ENTIRE RIGHT HORN

MICROSCOPIC TISSUE OBSERVATIONS
TISSUE / HISTOPATHOLOGIC FINDINGS DISTRIBUTION (SEVERITY) / SPECIAL COMMENTS

THYROID GLANDS
-PARA-FOLLICULAR CELL HYPERPLASIA (MC CELL, LIGHT CELL) FOCAL(MILD)
EXORBITAL LACRIM
-ACINAR ATROPHY NOT SPECIFIED(TRACE)
HEART
-CARDIOMYOPATHY NOT SPECIFIED(MILD)
SPLEEN
-N- LARGE GRANULAR LYMPHOCYTE LEUKEMIA, METASTATIC (PRESENT)
LYMPH NODES
-THERE IS MODERATE REACTIVE HYPERPLASIA IN CERVICAL LYMPH NODES
IN SLIDE #4 ADJACENT TO SALIVARY GLAND. MESENTERIC LYMPH NODES
ARE ESSENTIALLY NORMAL.
NOT SPECIFIED (PRESENT)
-REACTIVE HYPERPLASIA

Appendix J (cont.): PATHOLOGY INDIVIDUAL ANIMAL DATA

LETTERMAN ARMY INSTITUTE OF RESEARCH  
 DIV OF RES SUPP, PATH SERV GP  
 SPECIES: RAT/FISCHER-344  
 STUDY START DATE: 23-JAN-84  
 STUDY NUMBER: GLP83009  
 PRINTED: 21-NOV-89  
 PAGE: 717

ANIMAL NUMBER: 369/PRETEST= 369 SEX: FEMALE DOSE GROUP: 3 SACRIFICE STATUS: FINAL SACRIFICE  
 DATE OF DEATH: 10-FEB-86 STUDY DAY OF DEATH: 750 STUDY WEEK OF DEATH: 108 TERMINAL BODY WEIGHT: 327.00 (GMS)  
 STUDY TYPE: CHRONIC/2 YR CARCINOGENIC

TISSUE / HISTOPATHOLOGIC FINDINGS << MICROSCOPIC TISSUE OBSERVATIONS >>  
 DISTRIBUTION (SEVERITY) / SPECIAL COMMENTS

LIVER ..... FROZEN LIVER SECTIONS STAINED WITH OIL-RED-O AND SUDAN BLACK REVEALED THE PRESENCE OF FAT IN VACUOLATED HEPATOCYTES NEAR DILATED SUNUSOIDS. NUMEROUS COLORLESS CYRSTALS ARE PRESENT IN THESE AREAS CORRESPONDING TO SPICULES ON H&E STAINS. SECTIONS STAINED WITH VON KOSSA AND ALIZARIN RED-S STAINS DEMONSTRATE BOTH PHOSPHATE AND CALCIUM RESPECTIVELY. PAS STAINS ARE NON-CONTRIBUTORY. INTERPRETATION: FATTY DEGENERATIVE CHANGES IN HEPATOCYTES LEADING TO NECROSIS AND SUBSEQUENT SAPONIFICATION OF ACCUMULATED LIPID. THESE HISTOCHEMICAL FINDINGS ARE THE BASIS FOR DIAGNOSIS #240, "HEPATOCYTE COALESCING MICROVESICULAR (FATTY) CHANGE LEADING TO NECROSIS AND MINERALIZATION".

-HEPATOCYIC DEGENERATIVE CHANGES (NON-NECROTIC)  
 -FOCUS OF CELLULAR ALTERATION - EOSINOPHILIC CELLS  
 -M- LARGE GRANULAR LYMPHOCYTE LEUKEMIA, METASTATIC  
 -HEPATOCYTE COALESCING MICROVESICULAR (FATTY) CHANGE LEADING TO NECROSIS AND MINERALIZATION

KIDNEY ..... NOT SPECIFIED(MODERATE)  
 -PROGRESSIVE RENAL DISEASE

MAMMARY GLANDS ..... NOT SPECIFIED(MILD)  
 -HYPERPLASIA AND/OR HYPERTROPHY OF THE ACINAR TISSUE  
 -DILATATION (ECTASIA) OF DUCTS AND DUCTULES

NOSE/TURBINATES ..... INFILTRATE ADJACENT NASO-LACRIMAL DUCT.  
 -MIXED INFLAMMATORY CELL INFILTRATION, NASAL CAVITY, SINUSES, TURBINATES, NASO-LACRIMAL DUCTS  
 NOT SPECIFIED(MILD)

ADRENAL ..... NOT SPECIFIED(MILD)  
 -FOCUS OF CELLULAR ALTERATION, VACUOLATED

PITUITARY GLAND ..... (PRESENT)  
 -B- ADENOMA

WHOLE BODY .....

Appendix J (cont.): PATHOLOGY INDIVIDUAL ANIMAL DATA

LETTERMAN ARMY INSTITUTE OF RESEARCH  
 DIV OF RES SUPP, PATH SERV GP  
 SPECIES: RAT/FISCHER-344  
 STUDY START DATE: 23-JAN-84  
 ANIMAL NUMBER: 369/PRETEST= 369 SEX: FEMALE DOSE GROUP: 3 SACRIFICE STATUS: FINAL SACRIFICE  
 DATE OF DEATH: 10-FEB-86 STUDY DAY OF DEATH: 750 STUDY WEEK OF DEATH: 108 TERMINAL BODY WEIGHT: 327.00 (GMS)  
 << MICROSCOPIC TISSUE OBSERVATIONS >>  
 TISSUE / HISTOPATHOLOGIC FINDINGS  
 DISTRIBUTION (SEVERITY) / SPECIAL COMMENTS

PRINTED: 21-NOV-89  
PAGE: 718

WHOLE BODY ..... (PRESENT)  
-M- LARGE GRANULAR LYMPHOCYTTIC LEUKEMIA

Appendix J (cont.): PATHOLOGY INDIVIDUAL ANIMAL DATA

LETTERMAN ARMY INSTITUTE OF RESEARCH  
 DIV OF RES SUPP, PATH SERV GP  
 SPECIES: RAT/FISCHER-344  
 STUDY NUMBER: GLP83009  
 STUDY START DATE: 23-JAN-84  
 STUDY TYPE: CHRONIC/2 YR CARCINOGENIC  
 PRINTED: 21-NOV-89  
 PAGE: 719

ANIMAL NUMBER: 370/PRETEST-  
 DATE OF DEATH: 13-JAN-86  
 STUDY DAY OF DEATH: 722  
 SEX: FEMALE  
 DOSE GROUP: 3  
 STUDY WEEK OF DEATH: 104  
 SACRIFICE STATUS: SACRIFICED MORIBUND  
 TERMINAL BODY WEIGHT: 214.00 (GMS)

ORGAN NAME      << GROSS ORGAN OBSERVATIONS >>  
 KEYWORDS / PHRASES      SEVERITY GROSS FREE-TEXT COMMENTS  
 KIDNEY      PRESENT      ALSO PITTED, BILATERAL  
 KIDNEY      PRESENT      MOTTLED RED/BROWN, BILATERAL  
 PITUITARY GLAND      ENLARGED      .5CM DIAMETER, DARK RED/BLACK

TISSUE / HISTOPATHOLOGIC FINDINGS      << MICROSCOPIC TISSUE OBSERVATIONS >>  
 DISTRIBUTION (SEVERITY) / SPECIAL COMMENTS

BRAIN      NOT SPECIFIED (PRESENT)  
 -HYDROCEPHALUS

THYROID GLANDS      NOT SPECIFIED (TRACE)  
 -PARA-FOLLICULAR CELL HYPERPLASIA ("C" CELL, LIGHT CELL)

LIVER      NOT SPECIFIED (TRACE)  
 -BILE DUCTULE EPITHELIAL HYPERPLASIA AND/OR CHOLANGIOFIBROSIS  
 -HEPATITIS      NOT SPECIFIED (MILD)  
 -FOCUS OF CELLULAR ALTERATION - BASOPHILIC FOCAL (TRACE)  
 -HEPATOCTYIC VACUOLIZATION      NOT SPECIFIED (MILD)

KIDNEY      NOT SPECIFIED (MODERATE)  
 -PROGRESSIVE RENAL DISEASE

DUODENUM      TISSUE IS MISSING

MAMMARY GLANDS      NOT SPECIFIED (TRACE)  
 -HYPERPLASIA AND/OR HYPERTROPHY OF THE ACINAR TISSUE  
 -DILATATION (ECTASIA) OF DUCTS AND DUCTULES

ADRENAL      NOT SPECIFIED (MILD)  
 -FOCUS OF CELLULAR ALTERATION, VACUOLATED

PITUITARY GLAND

Appendix J (cont.): PATHOLOGY INDIVIDUAL ANIMAL DATA

LETTERMAN ARMY INSTITUTE OF RESEARCH  
DIV OF RES SUPP, PATH SERV GP  
SPECIES: RAT/FISCHER-344

INDIVIDUAL ANIMAL DATA REPORT  
STUDY NUMBER: GLP83009

PRINTED: 21-NOV-89  
PAGE: 720

STUDY START DATE: 23-JAN-84

STUDY TYPE: CHRONIC/2 YR CARCINOGENIC

ANIMAL NUMBER: 370/PRETEST= 370 SEX: FEMALE DOSE GROUP: 3 SACRIFICE STATUS: SACRIFICED MORIBUND  
DATE OF DEATH: 13-JAN-86 STUDY DAY OF DEATH: 722 STUDY WEEK OF DEATH: 104 TERMINAL BODY WEIGHT: 214.00 (GMS)

TISSUE / HISTOPATHOLOGIC FINDINGS  
<< M I C R O S C O P I C T I S S U E O B S E R V A T I O N S >>  
DISTRIBUTION (SEVERITY) / SPECIAL COMMENTS

PITUITARY GLAND ..... (PRESENT)  
-B- ADENOMA

EYES & OPTIC N. .... NOT SPECIFIED (TRACE)  
-RETINAL ATROPHY AND/OR DEGENERATION, UNILATERAL OR BILATERAL  
-METAPLASTIC BONE FORMATION AND/OR MINERALIZATION, SCLERA

Appendix J (cont.): PATHOLOGY INDIVIDUAL ANIMAL DATA

LETTERMAN ARMY INSTITUTE OF RESEARCH  
DIV OF RES SUPP, PATH SERV GP  
SPECIES: RAT/FISCHER-344

INDIVIDUAL ANIMAL DATA REPORT  
STUDY NUMBER: GLP83009  
STUDY START DATE: 23-JAN-84

PRINTED: 21-NOV-89  
PAGE: 721

ANIMAL NUMBER: 371/PRETEST# 371 SEX: FEMALE DOSE GROUP: 3 SACRIFICE STATUS: FINAL SACRIFICE  
DATE OF DEATH: 10-FEB-86 STUDY DAY OF DEATH: 750 STUDY WEEK OF DEATH: 108 TERMINAL BODY WEIGHT: 272.00 (GMS)  
STUDY TYPE: CHRONIC/2 YR CARCINOGENIC

ORGAN NAME << GROSS ORGAN OBSERVATIONS >>  
KEYWORDS / PHRASES SEVERITY GROSS FREE-TEXT COMMENTS

LIVER MODULE(S) PRESENT .5 X.6CM, ASSOCIATED WITH DIAPHRAGMATIC HERNIA  
DIAPHRAGM HERNIA PRESENT ASSOCIATED WITH LIVER MODULE  
PITUITARY GLAND ENLARGED DARK RED, .5CM DIAMETER

TISSUE / HISTOPATHOLOGIC FINDINGS << MICROSCOPIC TISSUE OBSERVATIONS >>  
DISTRIBUTION (SEVERITY) / SPECIAL COMMENTS

PARATHYROID ..... TISSUE IS MISSING

EXORBITAL LACRIM .....  
-ACINAR ATROPHY ..... FOCAL(TRACE)

HEART .....  
-CARDIOMYOPATHY ..... NOT SPECIFIED(MILD)

SPLEEN .....  
-EXTRAMEDULLARY HEMATOPOIESIS ..... NOT SPECIFIED (PRESENT)  
-HEMOSIDERIN PIGMENTATION (RED PULP) ..... NOT SPECIFIED (PRESENT)

LYMPH NODES .....  
-RED BLOOD CELLS, HEMOSIDERIN AND/OR ERYTHROPHAGOCYTOSIS WITHIN ..... RBC'S AND HEMOSIDERIN PRESENT ONLY IN MEDIASTINAL NODES.  
MEDULLARY SINUSES ..... NOT SPECIFIED (PRESENT)

LIVER .....  
-HEPATITIS ..... THE HYPERTROPHIC NODULE HAS NO HYPERPLASTIC CELLULAR CHANGES.  
-FOCUS OF CELLULAR ALTERATION - BASOPHILIC THIS IS THE LESION OBSERVED GROSSLY IN ASSOCIATION WITH THE  
-BENIGN HYPERPLASTIC NODULE(S) DIAPHRAGMATIC HERNIA.  
-HEPATOCYTE COALESCING MICROVESICULAR (FATTY) CHANGE LEADING TO FOCAL(TRACE)  
NECROSIS AND MINERALIZATION MULTI-FOCAL(TRACE)  
MULTI-FOCAL(MILD)

KIDNEY .....



**Appendix J (cont.): PATHOLOGY INDIVIDUAL ANIMAL DATA**

LETTERMAN ARMY INSTITUTE OF RESEARCH  
 DIV OF RES SUPP, PATH SERV GP  
 SPECIES: RAT/FISCHER-344  
 STUDY START DATE: 23-JAN-84  
 INDIVIDUAL ANIMAL DATA REPORT  
 STUDY NUMBER: GLP83009  
 PRINTED: 21-NOV-89  
 PAGE: 722  
 ANIMAL NUMBER: 371/PRETEST# 371 SEX: FEMALE DOSE GROUP: 3 SACRIFICE STATUS: FINAL SACRIFICE  
 DATE OF DEATH: 10-FEB-86 STUDY DAY OF DEATH: 750 STUDY WEEK OF DEATH: 108 TERMINAL BODY WEIGHT: 272.00 (GMS)  
 STUDY TYPE: CHRONIC/2 YR CARCINOGENIC  
 TISSUE / HISTOPATHOLOGIC FINDINGS  
 << MICROSCOPIC TISSUE OBSERVATIONS >>  
 DISTRIBUTION (SEVERITY) / SPECIAL COMMENTS

- KIDNEY ..... NOT SPECIFIED(MODERATE)
- PROGRESSIVE RENAL DISEASE
- PANCREAS ..... MULTI-FOCAL(TRACE)
- ACINAR (EXOCRINE) ATROPHY
- MAMMARY GLANDS ..... NOT SPECIFIED(MILD)
- HYPERPLASIA AND/OR HYPERTROPHY OF THE ACINAR TISSUE
- DILATATION (ECTASIA) OF DUCTS AND DUCTULES ..... NOT SPECIFIED (PRESENT)
- ADRENAL ..... (PRESENT)
- B- CORTICAL ADENOMA
- PITUITARY GLAND ..... (PRESENT)
- B- ADENOMA

**Appendix J (cont.): PATHOLOGY INDIVIDUAL ANIMAL DATA**

LETTERMAN ARMY INSTITUTE OF RESEARCH  
 DIV OF RES SUPP, PATH SERV GP  
 SPECIES: RAT/FISCHER-344  
 STUDY START DATE: 23-JAN-84  
 STUDY NUMBER: GLP83009  
 PRINTED: 21-NOV-89  
 PAGE: 723  
 STUDY TYPE: CHRONIC/2 YR CARCINOGENIC

ANIMAL NUMBER: 372/PRETEST# 372 SEX: FEMALE DOSE GROUP: 3 SACRIFICE STATUS: SACRIFICED MORIBUND  
 DATE OF DEATH: 07-FEB-86 STUDY DAY OF DEATH: 747 STUDY WEEK OF DEATH: 107 TERMINAL BODY WEIGHT: 232.00 (GMS)

<< GROSS ORGAN OBSERVATIONS >>  
 SEVERITY GROSS FREE-TEXT COMMENTS

ORGAN NAME	KEYWORDS / PHRASES	SEVERITY	GROSS FREE-TEXT COMMENTS
LIVER	GRANULAR SURFACE	PRESENT	
KIDNEY	GRANULAR SURFACE	PRESENT	
SPLEEN	ENLARGED (SPLENOHEGALY)	PRESENT	5.5 X 1.6 X 1CM.
PITUITARY GLAND	ENLARGED	PRESENT	
PITUITARY GLAND	DISCOLORATION	PRESENT	
WHOLE BODY	JAUNDICED	PRESENT	TWO FOCI ONE RED, ONE BLACK.

<< MICROSCOPIC TISSUE OBSERVATIONS >>  
 DISTRIBUTION (SEVERITY) / SPECIAL COMMENTS

THYROID GLANDS  
 -PARA-FOLLICULAR CELL HYPERPLASIA (MC CELL, LIGHT CELL) NOT SPECIFIED(TRACE)

HEART  
 -CARDIOMYOPATHY NOT SPECIFIED(TRACE)

LUNGS  
 -PNEUMONIA, INTERSTITIAL, CHRONIC  
 -N- LARGE GRANULAR LYMPHOCYTE LEUKEMIA, METASTATIC MULTI-FOCAL(TRACE)  
 (PRESENT)

SPLEEN  
 -N- LARGE GRANULAR LYMPHOCYTE LEUKEMIA, METASTATIC (PRESENT)

LYMPH NODES  
 -N- LARGE GRANULAR LYMPHOCYTE LEUKEMIA, METASTATIC (PRESENT)

LIVER  
 -BILE DUCTULE EPITHELIAL HYPERPLASIA AND/OR CHOLANGIOFIBROSIS NOT SPECIFIED(MILD)  
 -HEPATOCTYTIC VACUOLIZATION NOT SPECIFIED(MILD)  
 -HEPATOCTYTIC DEGENERATIVE CHANGES (NON-NECROTIC) NOT SPECIFIED(MILD)  
 -NECROSIS, PERIACINAR NOT SPECIFIED(MILD)

Appendix J (cont.): **PATHOLOGY INDIVIDUAL ANIMAL DATA**

LETTERMAN ARMY INSTITUTE OF RESEARCH  
DIV OF RES SUPP, PATH SERV 6P  
SPECIES: RAT/FISCHER-344

INDIVIDUAL ANIMAL DATA REPORT  
STUDY NUMBER: GLP83009  
STUDY START DATE: 23-JAN-84

PRINTED: 21-NOV-89  
PAGE: 724

STUDY TYPE: CHRONIC/2 YR CARCINOGENIC

ANIMAL NUMBER: 372/PRETEST- 372 SEX: FEMALE DOSE GROUP: 3 SACRIFICE STATUS: SACRIFICED MORIBUND  
DATE OF DEATH: 07-FEB-86 STUDY DAY OF DEATH: 747 STUDY WEEK OF DEATH: 107 TERMINAL BODY WEIGHT: 232.00 (GMS)

TISSUE / HISTOPATHOLOGIC FINDINGS << M I C R O S C O P I C T I S S U E O B S E R V A T I O N S >>  
DISTRIBUTION (SEVERITY) / SPECIAL COMMENTS

LIVER .....  
-M- LARGE GRANULAR LYMPHOCYTE LEUKEMIA, METASTATIC ..... (PRESENT)

KIDNEY .....  
-PROGRESSIVE RENAL DISEASE ..... NOT SPECIFIED(MILD)

OVARIES .....  
-CYSTIC CORPORA LUTEA ..... NOT SPECIFIED (PRESENT)

MAMMARY GLANDS .....  
-HYPERPLASIA AND/OR HYPERTROPHY OF THE ACINAR TISSUE ..... NOT SPECIFIED(MILD)  
-DILATATION (ECTASIA) OF DUCTS AND DUCTULES ..... NOT SPECIFIED (PRESENT)

NOSE/TURBINATES ..... INFILTRATE: BILATERAL ADJACENT NASO-LACRIMAL DUCTS.  
-MIXED INFLAMMATORY CELL INFILTRATION, NASAL CAVITY, SINUSES, ..... NOT SPECIFIED(MODERATE)  
TURBINATES, NASO-LACRIMAL DUCTS

PITUITARY GLAND .....  
-B- ADENOMA ..... (PRESENT)

EYES & OPTIC N. ..... CORNEAL VASCULARIZATION IS BILATERAL  
-CORNEAL VASCULARIZATION ..... NOT SPECIFIED(MILD)

WHOLE BODY .....  
-M- LARGE GRANULAR LYMPHOCYTIC LEUKEMIA ..... (PRESENT)

**Appendix J (cont.): PATHOLOGY INDIVIDUAL ANIMAL DATA**

LETTERMAN ARMY INSTITUTE OF RESEARCH  
 DIV OF RES SUPP, PATH SERV GP  
 SPECIES: RAT/FISCHER-344

PRINTED: 21-NOV-89  
 PAGE: 725

INDIVIDUAL ANIMAL DATA REPORT  
 STUDY NUMBER: GLP83009

STUDY START DATE: 23-JAN-84  
 STUDY TYPE: CHRONIC/2 YR CARCINOGENIC

ANIMAL NUMBER: 373/PRETEST-  
 DATE OF DEATH: 07-FEB-86  
 SEX: FEMALE  
 DOSE GROUP: 3  
 SACRIFICE STATUS: SACRIFICED MORIBUND  
 STUDY WEEK OF DEATH: 107  
 TERMINAL BODY WEIGHT: 241.00 (GMS)

ORGAN NAME  
 KEYWORDS / PHRASES  
 GROSS ORGAN OBSERVATIONS  
 SEVERITY GROSS FREE-TEXT COMMENTS

LIVER PROMINENT LOBULAR MARKINGS PRESENT ABDOMINAL WALL.  
 LIVER ADHESION(S) PRESENT 8 X 2 X 1.5CM.  
 SPLEEN ENLARGED (SPLENOHEGALY) PRESENT 2 WHITE DEPRESSED, FOCAL, .2CM AND .5CM DIAMETER.  
 SPLEEN DISCOLORATION PRESENT BILATERAL, MOTTLED RED.  
 ADRENAL DISCOLORATION PRESENT FOCAL, MULTIPLE.  
 EYES & OPTIC N. CORNEAL OPACITY PRESENT DARK RED .4CM.  
 PITUITARY GLAND ENLARGED PRESENT PALE DEPRESSED AREAS, BILATERAL.  
 LUNGS DISCOLORATION PRESENT

TISSUE / HISTOPATHOLOGIC FINDINGS  
 MICROSCOPIC TISSUE OBSERVATIONS  
 DISTRIBUTION (SEVERITY) / SPECIAL COMMENTS

THYROID GLANDS  
 -PARA-FOLLICULAR CELL HYPERPLASIA (MC CELL, LIGHT CELL) NOT SPECIFIED(MILD)

HEART  
 -CARDIOMYOPATHY NOT SPECIFIED(TRACE)

LUNGS  
 -PNEUMONIA, INTERSTITIAL, CHRONIC NOT SPECIFIED(MODERATE)  
 -W- LARGE GRANULAR LYMPHOCYTE LEUKEMIA, METASTATIC (PRESENT)

SPLEEN  
 -W- LARGE GRANULAR LYMPHOCYTE LEUKEMIA, METASTATIC (PRESENT)

LYMPH NODES  
 -W- LARGE GRANULAR LYMPHOCYTE LEUKEMIA, METASTATIC (PRESENT)

LIVER  
 -BILE DUCTULE EPITHELIAL HYPERPLASIA AND/OR CHOLANGIOFIBROSIS NOT SPECIFIED(TRACE)  
 -BENIGN HYPERPLASTIC NODULE(S) NOT SPECIFIED(TRACE)

**Appendix J (cont.): PATHOLOGY INDIVIDUAL ANIMAL DATA**

LETTERMAN ARMY INSTITUTE OF RESEARCH  
 DIV OF RES SUPP, PATH SERV GP  
 SPECIES: RAT/FISCHER-344  
 STUDY START DATE: 23-JAN-84  
 STUDY NUMBER: GLP83009  
 PRINTED: 21-NOV-89  
 PAGE: 726  
 STUDY TYPE: CHRONIC/2 YR CARCINOGENIC

ANIMAL NUMBER: 373/PRETEST#  
 DATE OF DEATH: 07-FEB-86  
 STUDY DAY OF DEATH: 747  
 SEX: FEMALE  
 DOSE GROUP: 3  
 SACRIFICE STATUS: SACRIFICED MORIBUND  
 TERMINAL BODY WEIGHT: 241.00 (GMS)

TISSUE / HISTOPATHOLOGIC FINDINGS  
 << M I C R O S C O P I C T I S S U E O B S E R V A T I O N S >>  
 DISTRIBUTION (SEVERITY) / SPECIAL COMMENTS

- LIVER .....  
 -N- LARGE GRANULAR LYMPHOCYTE LEUKEMIA, METASTATIC ..... (PRESENT)
- KIDNEY .....  
 -PROGRESSIVE RENAL DISEASE ..... NOT SPECIFIED (TRACE)
- UTERUS .....  
 -LYMPHOCYTIC INFILTRATE ..... NOT SPECIFIED (TRACE)
- MAMMARY GLANDS .....  
 -HYPERPLASIA AND/OR HYPERTROPHY OF THE ACINAR TISSUE ..... NOT SPECIFIED (MODERATE)  
 -DILATATION (ECTASIA) OF DUCTS AND DUCTULES ..... NOT SPECIFIED (PRESENT)
- ADRENAL .....  
 -FIBROSIS, CAPSULE ..... FOCAL (MILD)
- PITUITARY GLAND .....  
 -B- ADENOMA ..... (PRESENT)
- EYES & OPTIC N. ....  
 -CORNEAL MINERALIZATION ..... NOT SPECIFIED (TRACE)  
 -RETINAL ATROPHY AND/OR DEGENERATION, UNILATERAL OR BILATERAL ..... DIFFUSE (MODERATE)
- WHOLE BODY .....  
 -N- LARGE GRANULAR LYMPHOCYTIC LEUKEMIA ..... (PRESENT)

Appendix J (cont.): PATHOLOGY INDIVIDUAL ANIMAL DATA

LETTERMAN ARMY INSTITUTE OF RESEARCH  
DIV OF RES SUPP, PATH SERV GP  
SPECIES: RAT/FISCHER-344

INDIVIDUAL ANIMAL DATA REPORT  
STUDY NUMBER: GLP83009

PRINTED: 21-NOV-89  
PAGE: 727

STUDY START DATE: 23-JAN-84

STUDY TYPE: CHRONIC/2 YR CARCINOGENIC

ANIMAL NUMBER: 374/PRETEST= 374 SEX: FEMALE DOSE GROUP: 3 SACRIFICE STATUS: SACRIFICED MORIBUND  
DATE OF DEATH: 03-DEC-85 STUDY DAY OF DEATH: 681 STUDY WEEK OF DEATH: 98 TERMINAL BODY WEIGHT: 206.00 (GMS)

<< GROSS ORGAN OBSERVATIONS >>  
SEVERITY GROSS FREE-TEXT COMMENTS  
ORGAN NAME  
LIVER DISCOLORATION PRESENT LIGHT BROWN  
LIVER GRANULAR SURFACE PRESENT  
UTERUS DISTENDED MILD  
SPLEEN ENLARGED (SPLENOMEGALY) MILD  
PITUITARY GLAND DISCOLORATION PRESENT TWO, FOCAL, RED, .1-.2CM DIAMETER

<< MICROSCOPIC TISSUE OBSERVATIONS >>  
DISTRIBUTION (SEVERITY) / SPECIAL COMMENTS

LUNGS  
-MINERALIZATION OF PULMONARY ARTERIES NOT SPECIFIED (TRACE)  
SPLEEN  
-N- LARGE GRANULAR LYMPHOCYTE LEUKEMIA, METASTATIC (PRESENT)  
-EXTRAMEDULLARY HEMATOPOIESIS NOT SPECIFIED (PRESENT)  
LIVER  
-BILE DUCTULE EPITHELIAL HYPERPLASIA AND/OR CHOLANGIOFIBROSIS PERIACINAR NECROSIS IS PROBABLY SECONDARY TO ANEMIA. A LARGE AMOUNT OF IRON-POSITIVE PIGMENT IS PRESENT IN THE LIVER.  
-HEPATOCTYIC VACUOLIZATION NOT SPECIFIED (TRACE)  
-NECROSIS, PERIACINAR NOT SPECIFIED (MILD)  
-N- LARGE GRANULAR LYMPHOCYTE LEUKEMIA, METASTATIC NOT SPECIFIED (MILD) (PRESENT)  
KIDNEY  
-HEMOSIDEROSIS (BROWN GRANULAR PIGMENT) IN TUBULAR EPITHELIAL CELLS NOT SPECIFIED (PRESENT)  
UTERUS  
-DILATATION OF THE UTERINE LUMEN (HYDROMETRA) NOT SPECIFIED (PRESENT)  
CECUM  
-PERIARITERITIS NODOSA, ARTERIES IN CECAL WALL OR MESENTERY NOT SPECIFIED (PRESENT)  
MAMMARY GLANDS

Appendix J (cont.): PATHOLOGY INDIVIDUAL ANIMAL DATA

LETTERMAN ARMY INSTITUTE OF RESEARCH  
 DIV OF RES SUPP, PATH SERV GP  
 SPECIES: RAT/FISCHER-344  
 STUDY START DATE: 23-JAN-84  
 STUDY NUMBER: GLP83009  
 PRINTED: 21-NOV-89  
 PAGE: 728

ANIMAL NUMBER: 374/PRETEST-  
 DATE OF DEATH: 03-DEC-85  
 STUDY DAY OF DEATH: 681  
 SEX: FEMALE  
 DOSE GROUP: 3  
 SACRIFICE STATUS: SACRIFICED MORIBUND  
 STUDY WEEK OF DEATH: 98  
 TERMINAL BODY WEIGHT: 206.00 (GMS)

STUDY TYPE: CHRONIC/2 YR CARCINOGENIC

TISSUE OBSERVATIONS >>  
 << MICROSCOPIC TISSUE OBSERVATIONS >>  
 DISTRIBUTION (SEVERITY) / SPECIAL COMMENTS

MAMMARY GLANDS .....  
 -HYPERPLASIA AND/OR HYPERTROPHY OF THE ACINAR TISSUE ..... NOT SPECIFIED(MARKED)  
 -DILATATION (ECTASIA) OF DUCTS AND DUCTULES ..... NOT SPECIFIED (PRESENT)

NOSE/TURBINATES ..... INFILTRATE: SUPPURATIVE, BILATERAL, ADJACENT NASO-LACRIMAL DUCT  
 -MIXED INFLAMMATORY CELL INFILTRATION, NASAL CAVITY, SINUSES, ..... NOT SPECIFIED(MODERATE)  
 TURBINATES, NASO-LACRIMAL DUCTS

ADRENAL .....  
 -FOCUS OF CELLULAR ALTERATION, VACUOLATED ..... NOT SPECIFIED(MILD)

PITUITARY GLAND .....  
 -B- ADENOMA ..... (PRESENT)

WHOLE BODY .....  
 -M- LARGE GRANULAR LYMPHOCYTTIC LEUKEMIA ..... (PRESENT)

Appendix J (cont.): PATHOLOGY INDIVIDUAL ANIMAL DATA

LETTERMAN ARMY INSTITUTE OF RESEARCH  
 DIV OF RES SUPP, PATH SERV GP  
 SPECIES: RAT/FISCHER-344

INDIVIDUAL ANIMAL DATA REPORT  
 STUDY NUMBER: GLP83009  
 STUDY START DATE: 23-JAN-84

PRINTED: 21-NOV-89  
 PAGE: 729  
 STUDY TYPE: CHRONIC/2 YR CARCINOGENIC

ANIMAL NUMBER: 375/PRETEST= 375 SEX: FEMALE DOSE GROUP: 3 SACRIFICE STATUS: FINAL SACRIFICE  
 DATE OF DEATH: 10-FEB-86 STUDY DAY OF DEATH: 750 STUDY WEEK OF DEATH: 108 TERMINAL BODY WEIGHT: 267.00 (GMS)

ORGAN NAME << GROSS ORGAN OBSERVATIONS >>  
 KEYWORDS / PHRASES SEVERITY GROSS FREE-TEXT COMMENTS

PITUITARY GLAND DISCOLORATION PRESENT BLACK, FOCAL, .2CM DIAMETER

TISSUE / HISTOPATHOLOGIC FINDINGS << MICROSCOPIC TISSUE OBSERVATIONS >>  
 DISTRIBUTION (SEVERITY) / SPECIAL COMMENTS

THYROID GLANDS  
 -PARA-FOLLICULAR CELL HYPERPLASIA ("M" CELL, LIGHT CELL) MULTI-FOCAL(TRACE)

HEART  
 -CARDIOMYOPATHY NOT SPECIFIED(TRACE)

LUNGS  
 -MINERALIZATION OF PULMONARY ARTERIES NOT SPECIFIED(TRACE)

LYMPH NODES  
 -RED BLOOD CELLS, HEOSIDERIN AND/OR ERYTHROPHAGOCYTOSIS WITHIN LESION INVOLVES ONLY MEDIASTINAL NODES.  
 MEDULLARY SINUSES NOT SPECIFIED (PRESENT)

LIVER  
 -HEPATITIS MULTI-FOCAL(MILD)  
 -FOCUS OF CELLULAR ALTERATION - BASOPHILIC MULTI-FOCAL(MARKED)  
 -CYSTIC DEGENERATION NOT SPECIFIED (PRESENT)  
 -HEPATOCTYE COALESCING MICROVESICULAR (FATTY) CHANGE LEADING TO MULTI-FOCAL(MILD)  
 NECROSIS AND MINERALIZATION

KIDNEY  
 -PROGRESSIVE RENAL DISEASE NOT SPECIFIED(TRACE)

UTERUS  
 -ENDOMETRIAL STROMAL POLYP NOT SPECIFIED (PRESENT)  
 -CYSTIC DILATATION OF THE ENDOMETRIAL GLANDS NOT SPECIFIED (PRESENT)

PANCREAS



Appendix J (cont.): PATHOLOGY INDIVIDUAL ANIMAL DATA

LETTERMAN ARMY INSTITUTE OF RESEARCH  
DIV OF RES SUPP, PATH SERV GP  
SPECIES: RAT/FISCHER-344

INDIVIDUAL ANIMAL DATA REPORT  
STUDY NUMBER: CLP87009  
STUDY START DATE: 23-JAN-84

PRINTED: 21-NOV-89  
PAGE: 730

STUDY TYPE: CHRONIC/2 YR CARCINOGENIC

ANIMAL NUMBER: 375/PRETEST# 375 SEX: FEMALE DOSE GROUP: 3 SACRIFICE STATUS: FINAL SACRIFICE  
DATE OF DEATH: 10-FEB-86 STUDY DAY OF DEATH: 750 STUDY WEEK OF DEATH: 10 TERMINAL BODY WEIGHT: 267.00 (GMS)

<< MICROSCOPIC TISSUE OBSERVATION >>  
TISSUE / HISTOPATHOLOGIC FINDINGS DISTRIBUTION (SEVERITY) / SPECIAL COMMENTS

- PANCREAS ..... FOCAL (TRACE)
- ACINAR (EXOCRINE) ATROPHY
- MAMMARY GLANDS ..... NOT SPECIFIED (TRACE)
- HYPERPLASIA AND/OR HYPERTROPHY OF THE ACINAR TISSUE
- DILATATION (ECTASIA) OF DUCTS AND DUCTULES ..... NOT SPECIFIED (PRESENT)
- NOSE/TURBINATES ..... INFILTRATE: BILATERAL ADJACENT ASO-LA RIMAL UCT.
- MIXED INFLAMMATORY CELL INFILTRATION, NASAL CAVITY, SINUSES, ..... NOT SPECIFIED (MILD)
- TURBINATES, NASO-LACRIMAL DUCTS
- PITUITARY GLAND ..... (PRESENT)
- B- ADENOMA
- EYES & OPTIC N. .... NOT SPECIFIED (PRESENT)
- METAPLASTIC BONE FORMATION AND/OR MINERALIZATION, SCLERA

Appendix J (cont.): PATHOLOGY INDIVIDUAL ANIMAL DATA

LETTERMAN ARMY INSTITUTE OF RESEARCH  
 DIV OF RES SUPP, PATH SERV GP  
 SPECIES: RAT/FISCHER-344  
 ANIMAL NUMBER: 376/PRETEST-  
 DATE OF DEATH: 10-FEB-86  
 STUDY DAY OF DEATH: 750  
 376 SEX: FEMALE  
 DOSE GROUP: 3  
 SACRIFICE STATUS: FINAL SACRIFICE  
 STUDY WEEK OF DEATH: 108  
 TERMINAL BODY WEIGHT: 275.00 (GMS)

INDIVIDUAL ANIMAL DATA REPORT  
 STUDY NUMBER: GLP83009  
 STUDY START DATE: 23-JAN-84  
 STUDY TYPE: CHRONIC/2 YR CARCINOGENIC

<< GROSS ORGAN OBSERVATIONS >>  
 SEVERITY GROSS FREE-TEXT COMMENTS  
 SKIN PRESENT LEFT INGUINAL AREA, 4CM DIAMETER, SEMI-FIRM, PUSS FILLED  
 EYES & OPTIC N. PRESENT FOCAL, MULTIPLE, MINUTE, BILATERAL  
 OVARIES PRESENT BILATERAL, LEFT 2.5 X 1.5CM, RIGHT 1.5 X 1CM, CLEAR FLUID FILLED  
 KIDNEY PRESENT GRANULAR SURFACE  
 PITUITARY GLAND PRESENT ENLARGED DARK RED, 1CM DIAMETER

<< MICROSCOPIC TISSUE OBSERVATIONS >>  
 TISSUE / HISTOPATHOLOGIC FINDINGS DISTRIBUTION (SEVERITY) / SPECIAL COMMENTS

THYROID GLANDS ..... (PRESENT)  
 -B- PARA-FOLLICULAR CELL ADENOMA

HEART .....  
 -CARDIOMYOPATHY ..... NOT SPECIFIED(TRACE)  
 -MEDIAL HYPERTROPHY OF MUSCULAR ARTERIES ..... NOT SPECIFIED(TRACE)

LYMPH NODES ..... REACTIVE HYPERPLASIA IS LIMITED TO CERVICAL LYMPH NODES.  
 -REACTIVE HYPERPLASIA ..... NOT SPECIFIED (PRESENT)

LIVER .....  
 -HEPATITIS ..... MULTI-FOCAL(TRACE)  
 -NEPATOCYTTIC VACUOLIZATION ..... MULTI-FOCAL(TRACE)

KIDNEY .....  
 -PROGRESSIVE RENAL DISEASE ..... NOT SPECIFIED(MODERATE)

URINARY BLADDER ..... TISSUE IS MISSING

OVARIES .....  
 -PARA-OVARIAN CYST(S) ..... NOT SPECIFIED (PRESENT)

PANCREAS .....

**Appendix J (cont.): PATHOLOGY INDIVIDUAL ANIMAL DATA**

LETTERMAN ARMY INSTITUTE OF RESEARCH  
 DIV OF RES SUPP, PATH SERV GP  
 SPECIES: RAT/FISCHER-344  
 INDIVIDUAL ANIMAL DATA REPORT  
 STUDY NUMBER: GLP83009  
 STUDY START DATE: 23-JAN-84  
 PRINTED: 21-NOV-89  
 PAGE: 732  
 STUDY TYPE: CHRONIC/2 YR CARCINOGENIC

ANIMAL NUMBER: 376/PRETEST= 376 SEX: FEMALE DOSE GROUP: 3 SACRIFICE STATUS: FINAL SACRIFICE  
 DATE OF DEATH: 10-FEB-86 STUDY DAY OF DEATH: 750 STUDY WEEK OF DEATH: 108 TERMINAL BODY WEIGHT: 275.00 (GHS)

<< MICROSCOPIC TISSUE OBSERVATIONS >>  
 TISSUE / HISTOPATHOLOGIC FINDINGS  
 DISTRIBUTION (SEVERITY) / SPECIAL COMMENTS

- PANCREAS ..... FOCAL (TRACE)
- ACINAR (EXOCRINE) ATROPHY
- MAMMARY GLANDS ..... MAMMARY ADENOCARCINOMA IS LOCATED IN THE INGUINAL SUBCUTANEOUS TISSUE.
- HYPERPLASIA AND/OR HYPERTROPHY OF THE ACINAR TISSUE NOT SPECIFIED (MILD)
- GALACTOCELE(S) NOT SPECIFIED (PRESENT)
- B- FIBROADENOMA (PRESENT)
- DILATATION (ECTASIA) OF DUCTS AND DUCTULES NOT SPECIFIED (PRESENT)
- M- MAMMARY ADENOCARCINOMA (PRESENT)
- ADRENAL ..... NOT SPECIFIED (TRACE)
- FOCUS OF CELLULAR ALTERATION, VACUOLATED
- PITUITARY GLAND ..... (PRESENT)
- B- ADEMOMA
- EYES & OPTIC N. .... MILD HISTOLOGIC CHANGES CONSISTENT WITH SUBCAPSULAR CATARACT ARE PRESENT IN BOTH EYES.
- LENTICULAR DEGENERATIVE CHANGES COMPATIBLE WITH CATARACT NOT SPECIFIED (PRESENT)

Appendix J (cont.): PATHOLOGY INDIVIDUAL ANIMAL DATA

LETTERMAN ARMY INSTITUTE OF RESEARCH  
 DIV OF RES SUPP, PATH SERV GP  
 SPECIES: RAT/FISCHER-344

INDIVIDUAL ANIMAL DATA REPORT  
 STUDY NUMBER: GLP83009  
 STUDY START DATE: 23-JAN-84

ANIMAL NUMBER: 377/PRETEST# 377 SEX: FEMALE DOSE GROUP: 3 SACRIFICE STATUS: FINAL SACRIFICE  
 DATE OF DEATH: 12-FEB-86 STUDY DAY OF DEATH: 752 STUDY WEEK OF DEATH: 108 TERMINAL BODY WEIGHT: 221.00 (GMS)

STUDY TYPE: CHRONIC/2 YR CARCINOGENIC

ORGAN NAME      GROSS ORGAN OBSERVATIONS      SEVERITY GROSS FREE-TEXT COMMENTS  
 KEYWORDS / PHRASES

PITUITARY GLAND      ENLARGED      PRESENT      DARK RED, .4CM DIAMETER  
 OVARIES      CYST(S) WITHIN OVARY      PRESENT      RIGHT, 1CM DIAMETER, AMBER FLUID FILLED  
 UTERUS      GROWTH(S)/MASS(S)      PRESENT      DISTAL RIGHT HORN, INTRALUMINAL, .5CM DIAMETER  
 KIDNEY      GRANULAR SURFACE      PRESENT

TISSUE / HISTOPATHOLOGIC FINDINGS      OBSERVATIONS      DISTRIBUTION (SEVERITY) / SPECIAL COMMENTS

    << MICROSCOPIC TISSUE      OBSERVATIONS      >>

LACRIMAL GLAND      .....

-INFLAMMATION, SUBACUTE TO CHRONIC      .....

    MULTI-FOCAL(TRACE)

HEART      .....

-CARDIOMYOPATHY      .....

-MEDIAL HYPERTROPHY OF MUSCULAR ARTERIES      .....

    NOT SPECIFIED(MILD)  
 NOT SPECIFIED(TRACE)

SPLEEN      .....

-M- LARGE GRANULAR LYMPHOCYTE LEUKEMIA, METASTATIC      .....

    (PRESENT)

LYMPH NODES      .....

-REACTIVE HYPERPLASIA      .....

    REACTIVE HYPERPLASIA PRESENT ONLY IN CERVICAL NODES ADJACENT TO SALIVARY GLANDS.  
 NOT SPECIFIED (PRESENT)

LIVER      .....

-BILE DUCTULE EPITHELIAL HYPERPLASIA AND/OR CHOLANGIOFIBROSIS      .....

-HEPATITIS      .....

-FOCUS OF CELLULAR ALTERATION - BASOPHILIC      .....

-HEPATOCTYIC VACUOLIZATION      .....

-HEPATOCTYIC DEGENERATIVE CHANGES (NON-NECROTIC)      .....

-M- LARGE GRANULAR LYMPHOCYTE LEUKEMIA, METASTATIC      .....

    NOT SPECIFIED(TRACE)  
 MULTI-FOCAL(TRACE)  
 MULTI-FOCAL(TRACE)  
 MULTI-FOCAL(TRACE)  
 DIFFUSE(TRACE)  
 (PRESENT)

KIDNEY      .....

-PROGRESSIVE RENAL DISEASE      .....

    NOT SPECIFIED(MARKED)

Appendix J (cont.): PATHOLOGY INDIVIDUAL ANIMAL DATA

LETTERMAN ARMY INSTITUTE OF RESEARCH  
 DIV OF RES SUPP, PATH SERV GP  
 SPECIES: RAT/FISCHER-344  
 INDIVIDUAL ANIMAL DATA REPORT  
 STUDY NUMBER: GLP83009  
 STUDY START DATE: 23-JAN-84  
 STUDY TYPE: CHRONIC/2 YR CARCINOGENIC  
 ANIMAL NUMBER: 377/PRETEST# 377 SEX: FEMALE DOSE GROUP: 3 SACRIFICE STATUS: FINAL SACRIFICE  
 DATE OF DEATH: 12-FEB-86 STUDY DAY OF DEATH: 752 STUDY WEEK OF DEATH: 108 TERMINAL BODY WEIGHT: 221.00 (GMS)  
 TISSUE / HISTOPATHOLOGIC FINDINGS << MICROSCOPIC TISSUE OBSERVATIONS >>  
 DISTRIBUTION (SEVERITY) / SPECIAL COMMENTS

PRINTED: 21-NOV-89  
 PAGE: 734

UTERUS ..... SPECIAL STAINS (PAS, MUCICARHINE, AND ALCIAN BLUE) WERE APPLIED IN ATTEMPTS TO CHARACTERIZE CONTENT OF LARGE FOAMY MACROPHAGES. IN SOME CELLS, THIS MATERIAL APPEARS TO BE EITHER MUCIN OR OTHER GLYCOPROTEIN. PROBABLY THIS SECTION WAS TAKEN NEAR THE CERVIX AND THE MATERIAL IS A SECRETORY PRODUCT OF CERVICAL EPITHELIUM.  
 -CYSTIC DILATATION OF THE ENDOMETRIAL GLANDS NOT SPECIFIED (PRESENT)  
 -DEGENERATION, NECROSIS AND CHRONIC INFLAMMATION OF UTERINE STROMA NOT SPECIFIED (PRESENT)

OVARIES ..... NOT SPECIFIED (PRESENT)  
 -PARA-OVARIAN CYST(S)  
 MAMMARY GLANDS ..... NOT SPECIFIED(MILD)  
 -HYPERPLASIA AND/OR HYPERTROPHY OF THE ACINAR TISSUE NOT SPECIFIED (PRESENT)  
 -DILATATION (ECTASIA) OF DUCTS AND DUCTULES

ADRENAL ..... NOT SPECIFIED(MILD)  
 -FOCUS OF CELLULAR ALTERATION, EOSINOPHILIC NOT SPECIFIED(MILD)  
 -FOCUS OF CELLULAR ALTERATION, VACUOLATED

PITUITARY GLAND ..... (PRESENT)  
 -B- ADENOMA

EYES & OPTIC N. .... EYE SECTION #19 B IS EMBEDDED IN THE WRONG PLANE OF SECTION. IT IS NOT POSSIBLE TO EVALUATE RETINA OR CORNEA IN THIS SECTION. OTHER THAN THE METAPLASTIC BONE IN THE SCLERA, THERE ARE NO LESIONS IN SECTION #19A.  
 -METAPLASTIC BONE FORMATION AND/OR MINERALIZATION, SCLERA NOT SPECIFIED (PRESENT)

WHOLE BODY ..... (PRESENT)  
 -M- LARGE GRANULAR LYMPHOCYTTIC LEUKEMIA

Appendix J (cont.): PATHOLOGY INDIVIDUAL ANIMAL DATA

LETTERMAN ARMY INSTITUTE OF RESEARCH
DIV OF RES SUPP, PATH SERV GP
SPECIES: RAT/FISCHER-344
INDIVIDUAL ANIMAL DATA REPORT
STUDY NUMBER: GLP83009
STUDY START DATE: 23-JAN-84
STUDY TYPE: CHRONIC/2 YR CARCINOGENIC
ANIMAL NUMBER: 378/PRETEST=
378 SEX: FEMALE DOSE GROUP: 3 SACRIFICE STATUS: FINAL SACRIFICE
DATE OF DEATH: 12-FEB-86 STUDY DAY OF DEATH: 752 STUDY WEEK OF DEATH: 108 TERMINAL BODY WEIGHT: 235.00 (GMS)

ORGAN NAME
KEYWORDS / PHRASES
GROSS ORGAN OBSERVATIONS
SEVERITY GROSS FREE-TEXT COMMENTS
UTERUS POLYP
LIVER DISCOLORATION
PRESENT RIGHT DISTAL HORN, .8CM DIAMETER, INTRALUMINAL
PRESENT LEFT LATERAL LOBE, RAISED, PALE, .7CM DIAMETER

TISSUE / HISTOPATHOLOGIC FINDINGS
MICROSCOPIC TISSUE OBSERVATIONS
DISTRIBUTION (SEVERITY) / SPECIAL COMMENTS

THYROID GLANDS
-B- PARA-FOLLICULAR CELL ADENOMA (PRESENT)

HEART
-CARDIOMYOPATHY NOT SPECIFIED(MILD)

LUNGS
-IMMERIALIZATION OF PULMONARY ARTERIES NOT SPECIFIED(TRACE)
-PERIBRONCHIAL LYMPHOID HYPERPLASIA NOT SPECIFIED(TRACE)

LIVER
HEPATOCTYIC DEGENERATIVE CHANGES AND HEPATOCTYIC NECROSIS IS LIMITED TO ONE LOBE, PRESUMABLY THE LOBE THAT WAS ABNORMAL GROSSLY. NO APPARENT REASON FOR THIS LESION WAS DETECTED MICROSCOPICALLY.
MULTI-FOCAL(TRACE)
NOT SPECIFIED(TRACE)
DIFFUSE(MILD)
MULTI-FOCAL(MILD)

KIDNEY
-PROGRESSIVE RENAL DISEASE NOT SPECIFIED(TRACE)

UTERUS
-ENDOMETRIAL STROMAL POLYP NOT SPECIFIED (PRESENT)

MAMMARY GLANDS

PRINTED: 21-NOV-89
PAGE: 735

Appendix J (cont.): PATHOLOGY INDIVIDUAL ANIMAL DATA

LETTERMAN ARMY INSTITUTE OF RESEARCH  
DIV OF RES SUPP, PATH SERV GP  
SPECIES: RAT/FISCHER-344

INDIVIDUAL ANIMAL DATA REPORT  
STUDY NUMBER: GLP83009  
STUDY START DATE: 23-JAN-84

PRINTED: 21-NOV-89  
PAGE: 736

STUDY TYPE: CHRONIC/2 YR CARCINOGENIC

ANIMAL NUMBER: 378/PRETEST#  
DATE OF DEATH: 12-FEB-86

378 SEX: FEMALE  
STUDY DAY OF DEATH: 752

DOSE GROUP: 3  
STUDY WEEK OF DEATH: 108

SACRIFICE STATUS: FINAL SACRIFICE  
TERMINAL BODY WEIGHT: 235.00 (GMS)

< MICROSCOPIC TISSUE OBSERVATIONS >>  
TISSUE / HISTOPATHOLOGIC FINDINGS

DISTRIBUTION (SEVERITY) / SPECIAL COMMENTS

MAMMARY GLANDS

-HYPERPLASIA AND/OR HYPERTROPHY OF THE ACINAR TISSUE  
-DILATATION (ECTASIA) OF DUCTS AND DUCTULES

NOT SPECIFIED(MILD)  
NOT SPECIFIED (PRESENT)

ADRENAL

-FOCUS OF CELLULAR ALTERATION, VACUOLATED

NOT SPECIFIED(MODERATE)

PITUITARY GLAND

-CYST(S)

NOT SPECIFIED (PRESENT)

Appendix J (cont.): PATHOLOGY INDIVIDUAL ANIMAL DATA

LETTERMAN ARMY INSTITUTE OF RESEARCH  
DIV OF RES SUPP, PATH SERV GP  
SPECIES: RAT/FISCHER-344

INDIVIDUAL ANIMAL DATA REPORT  
STUDY NUMBER: GLP83009

PRINTED: 21-NOV-89  
PAGE: 737

STUDY START DATE: 23-JAN-84

STUDY TYPE: CHRONIC/2 YR CARCINOGENIC

ANIMAL NUMBER: 379/PRETEST= 379 SEX: FEMALE DOSE GROUP: 3 SACRIFICE STATUS: FINAL SACRIFICE  
DATE OF DEATH: 12-FEB-86 STUDY DAY OF DEATH: 752 STUDY WEEK OF DEATH: 108 TERMINAL BODY WEIGHT: 276.00 (GMS)

ORGAN NAME << GROSS ORGAN OBSERVATIONS >>  
KEYWORDS / PHRASES SEVERITY GROSS FREE-TEXT COMMENTS  
PITUITARY GLAND DISCOLORATION PRESENT RED, FOCAL, .1CM DIAMETER

TISSUE / HISTOPATHOLOGIC FINDINGS << MICROSCOPIC TISSUE OBSERVATIONS >>  
DISTRIBUTION (SEVERITY) / SPECIAL COMMENTS

LACRIMAL GLAND ..... FOCAL (TRACE)  
-INFLAMMATION, SUBACUTE TO CHRONIC

HEART ..... NOT SPECIFIED (TRACE)  
-CARDIOMYOPATHY

LUNGS ..... NOT SPECIFIED (TRACE)  
-MINERALIZATION OF PULMONARY ARTERIES

LYMPH NODES ..... RBC'S AND HEMOSIDERIN ARE PRESENT ONLY IN A MEDIASTINAL NODE.  
-RED BLOOD CELLS, HEMOSIDERIN AND/OR ERYTHROPHAGOCYTOSIS WITHIN NOT SPECIFIED (PRESENT)  
MEDULLARY SINUSES

LIVER ..... MULTI-FOCAL (TRACE)  
-HEPATITIS MULTI-FOCAL (MODERATE)  
NECROSIS AND MINERALIZATION

KIDNEY ..... NOT SPECIFIED (TRACE)  
-PROGRESSIVE RENAL DISEASE

MAMMARY GLANDS ..... NOT SPECIFIED (TRACE)  
-HYPERPLASIA AND/OR HYPERTROPHY OF THE ACINAR TISSUE

NOSE/TURBINATES ..... INFILTRATE: UNILATERAL ADJACENT NASO-LACRIMAL DUCT.  
-MIXED INFLAMMATORY CELL INFILTRATION, NASAL CAVITY, SINUSES, NOT SPECIFIED (MILD)  
TURBINATES, NASO-LACRIMAL DUCTS

BONE, STERNUM .....



Appendix J (cont.): PATHOLOGY INDIVIDUAL ANIMAL DATA

LETTERMAN ARMY INSTITUTE OF RESEARCH  
DIV OF RES SUPP, PATH SERV GP  
SPECIES: RAT/FISCHER-344

INDIVIDUAL ANIMAL DATA REPORT  
STUDY NUMBER: GLP83009  
STUDY START DATE: 23-JAN-84

PRINTED: 21-NOV-89  
PAGE: 738

STUDY TYPE: CHRONIC/2 YR CARCINOGENIC

ANIMAL NUMBER: 379/PRETEST-      379 SEX: FEMALE      DOSE GROUP: 3      SACRIFICE STATUS: FINAL SACRIFICE  
DATE OF DEATH: 12-FEB-86      STUDY DAY OF DEATH: 752      STUDY WEEK OF DEATH: 108      TERMINAL BODY WEIGHT: 276.00 (GMS)

<<      M I C R O S C O P I C      T I S S U E      O B S E R V A T I O N S      >>  
TISSUE / HISTOPATHOLOGIC FINDINGS      DISTRIBUTION (SEVERITY) / SPECIAL COMMENTS

BONE, STERNUM .....  
-HYPERPLASIA, MYELOID ..... MULTI-FOCAL (PRESENT)

BONE, FEMUR .....  
-HYPERPLASIA MYELOID ..... MULTI-FOCAL (PRESENT)

PITUITARY GLAND .....  
THERE IS NO HISTOLOGIC CORRELATE TO THE GROSS OBSERVATION (A  
1 MM RED FOCAL DISCOLORATION). BECAUSE OF THE SMALL SIZE OF  
LESION IT PROBABLY WAS NOT INCLUDED IN TO PLANE OF SECTION.  
THE MOST LIKELY CAUSE FOR SUCH A CHANGE IS A BLOOD-FILLED CYST.

EYES & OPTIC N. ....  
-METAPLASTIC BONE FORMATION AND/OR MINERALIZATION, SCLERA ..... NOT SPECIFIED (PRESENT)

**Appendix J (cont.): PATHOLOGY INDIVIDUAL ANIMAL DATA**

LETTERMAN ARMY INSTITUTE OF RESEARCH  
 DIV OF RES SUPP, PATH SERV GP  
 SPECIES: RAT/FISCHER-344

INDIVIDUAL ANIMAL DATA REPORT  
 STUDY NUMBER: GLP83009  
 STUDY START DATE: 23-JAN-84

PRINTED: 21-NOV-89  
 PAGE: 739

ANIMAL NUMBER: 380/PRETEST-380 SEX: FEMALE DOSE GROUP: 3 SACRIFICE STATUS: FINAL SACRIFICE  
 DATE OF DEATH: 12-FEB-86 STUDY DAY OF DEATH: 752 STUDY WEEK OF DEATH: 108 TERMINAL BODY WEIGHT: 248.00 (GMS)

STUDY TYPE: CHRONIC/2 YR CARCINOGENIC

<< GROSS ORGAN OBSERVATIONS >>  
 KEYWORDS / PHRASES SEVERITY GROSS FREE-TEXT COMMENTS  
 SUBCUTANEOUS MASS PRESENT LEFT MEDIAL THIGH, SEMI-FIRM, WHITE, 4CM DIAMETER  
 ENLARGED (SPLENOHEGALY) TRACE 4.5CH LONG

<< MICROSCOPIC TISSUE OBSERVATIONS >>  
 TISSUE / HISTOPATHOLOGIC FINDINGS DISTRIBUTION (SEVERITY) / SPECIAL COMMENTS

SALIVARY GLAND ..... ONE SUBLINGUAL GLAND IS DIFFUSELY ATROPHIC.  
 -ATROPHY AND LOSS OF ACINAR TISSUE ..... DIFFUSE(MILD)

HEART .....  
 -CARDIOMYOPATHY ..... NOT SPECIFIED(MILD)  
 -MEDIAL HYPERTROPHY OF MUSCULAR ARTERIES ..... NOT SPECIFIED(MILD)

SPLEEN ..... (PRESENT)  
 -N- LARGE GRANULAR LYMPHOCYTE LEUKEMIA, METASTATIC

LYMPH NODES ..... THE MESENTERIC NODES ARE EXTENSIVELY INFILTRATED BY NEOPLASTIC LYMPHOCYTES. THERE IS MINIMAL INVOLVEMENT IN OTHER NODES EXAMINED. (PRESENT)  
 -N- LARGE GRANULAR LYMPHOCYTE LEUKEMIA, METASTATIC

LIVER .....  
 -N- LARGE GRANULAR LYMPHOCYTE LEUKEMIA, METASTATIC (PRESENT)  
 -HEPATOCTYCE COALESCING MICROVESICULAR (FATTY) CHANGE LEADING TO NECROSIS AND MINERALIZATION MULTI-FOCAL(TRACE)

KIDNEY ..... NOT SPECIFIED(TRACE)  
 -PROGRESSIVE RENAL DISEASE

UTERUS ..... NOT SPECIFIED (PRESENT)  
 -DILATATION OF THE UTERINE LUMEN (HYDROMETRA)

PANCREAS .....

Appendix J (cont.): PATHOLOGY INDIVIDUAL ANIMAL DATA

LETTERMAN ARMY INSTITUTE OF RESEARCH  
DIV OF RES SUPP, PATH SERV GP  
SPECIES: RAT/FISCHER-344

INDIVIDUAL ANIMAL DATA REPORT  
STUDY NUMBER: GLP83009

PRINTED: 21-NOV-89  
PAGE: 740

STUDY START DATE: 23-JAN-84

STUDY TYPE: CHRONIC/2 YR CARCINOGENIC

ANIMAL NUMBER: 380/PRETEST=

380 SEX: FEMALE

DOSE GROUP: 3

SACRIFICE STATUS: FINAL SACRIFICE

DATE OF DEATH: 12-FEB-86

STUDY DAY OF DEATH: 752

STUDY WEEK OF DEATH: 108

TERMINAL BODY WEIGHT: 248.00 (GMS)

TISSUE / HISTOPATHOLOGIC FINDINGS

<< MICROSCOPIC TISSUE OBSERVATIONS >>

DISTRIBUTION (SEVERITY) / SPECIAL COMMENTS

PANCREAS .....  
-ACINAR (EXOCRINE) ATROPHY

FOCAL(TRACE)

SKIN .....  
-B- FIBROMA

THE MASS IN THE SUBCUTIS OF THE LEFT THIGH IS A FIBROMA.  
(PRESENT)

MAMMARY GLANDS .....  
-HYPERPLASIA AND/OR HYPERTROPHY OF THE ACINAR TISSUE

NOT SPECIFIED(MILD)

PITUITARY GLAND .....  
-B- ADENOMA

(PRESENT)

EYES & OPTIC N. ....

SLIGHT CHANGES CONSISTENT WITH SUBCAPSULAR CATARACT ARE PRESENT  
IN ONE EYE (SECTION #198)

-LENTICULAR DEGENERATIVE CHANGES COMPATIBLE WITH CATARACT

NOT SPECIFIED (PRESENT)

WHOLE BODY .....

-M- LARGE GRANULAR LYMPHOCYTTIC LEUKEMIA

(PRESENT)

Appendix J (cont.): PATHOLOGY INDIVIDUAL ANIMAL DATA

LETTERMAN ARMY INSTITUTE OF RESEARCH  
DIV OF RES SUPP, PATH SERV 6P  
SPECIES: RAT/FISCHER-344

PRINTED: 21-NOV-89  
PAGE: 741

INDIVIDUAL ANIMAL DATA REPORT  
STUDY NUMBER: GLP83009

STUDY START DATE: 23-JAN-84

STUDY TYPE: CHRONIC/2 YR CARCINOGENIC

ANIMAL NUMBER: 381/PRETEST-

381 SEX: FEMALE

DOSE GROUP: 3

SACRIFICE STATUS: FINAL SACRIFICE

TERMINAL BODY WEIGHT: 288.00 (GMS)

DATE OF DEATH: 12-FEB-86

STUDY DAY OF DEATH: 752

STUDY WEEK OF DEATH: 108

STUDY TYPE: CHRONIC/2 YR CARCINOGENIC

ORGAN NAME

<< GROSS ORGAN OBSERVATIONS >>

SEVERITY GROSS FREE-TEXT COMMENTS

KEYWORDS / PHRASES

ENLARGED

PRESENT

PITUITARY GLAND

ENLARGED

PRESENT

ENLARGED

ENLARGED

PRESENT

ENLARGED

ENLARGED

PRESENT

ENLARGED

ENLARGED

PRESENT

ENLARGED

ENLARGED

PRESENT

ENLARGED

ENLARGED

PRESENT

ENLARGED

ENLARGED

PRESENT

ENLARGED

ENLARGED

PRESENT

ENLARGED

ENLARGED

PRESENT

ENLARGED

ENLARGED

PRESENT

ENLARGED

ENLARGED

PRESENT

ENLARGED

ENLARGED

PRESENT

ENLARGED

ENLARGED

PRESENT

ENLARGED

ENLARGED

PRESENT

ENLARGED

ENLARGED

PRESENT

ENLARGED

ENLARGED

PRESENT

ENLARGED

ENLARGED

PRESENT

ENLARGED

ENLARGED

PRESENT

ENLARGED

ENLARGED

PRESENT

ENLARGED

ENLARGED

PRESENT

ENLARGED

ENLARGED

PRESENT

ENLARGED

ENLARGED

PRESENT

ENLARGED

ENLARGED

PRESENT

ENLARGED

ENLARGED

PRESENT

ENLARGED

ENLARGED

PRESENT

ENLARGED

ENLARGED

PRESENT

ENLARGED

ENLARGED

PRESENT

ENLARGED

ENLARGED

PRESENT

ENLARGED

ENLARGED

PRESENT

ENLARGED

ENLARGED

PRESENT

ENLARGED

ENLARGED

PRESENT

ENLARGED

ENLARGED

PRESENT

ENLARGED

ENLARGED

PRESENT

ENLARGED

ENLARGED

PRESENT

ENLARGED

ENLARGED

PRESENT

ENLARGED

ENLARGED

PRESENT

ENLARGED

ENLARGED

PRESENT

ENLARGED

ENLARGED

PRESENT

ENLARGED

ENLARGED

PRESENT

ENLARGED

ENLARGED

PRESENT

ENLARGED

ENLARGED

PRESENT

ENLARGED

ENLARGED

PRESENT

ENLARGED

ENLARGED

PRESENT

ENLARGED

ENLARGED

PRESENT

ENLARGED

ENLARGED

PRESENT

ENLARGED

ENLARGED

PRESENT

ENLARGED

ENLARGED

PRESENT

ENLARGED

ENLARGED

PRESENT

ENLARGED

ENLARGED

PRESENT

ENLARGED

ENLARGED

PRESENT

ENLARGED

ENLARGED

PRESENT

Appendix J (cont.): PATHOLOGY INDIVIDUAL ANIMAL DATA

LETTERMAN ARMY INSTITUTE OF RESEARCH  
DIV OF RES SUPP, PATH SERV GP  
SPECIES: RAT/FISCHER-344

INDIVIDUAL ANIMAL DATA REPORT  
STUDY NUMBER: GLP83009  
STUDY START DATE: 23-JAN-84

PRINTED: 21-NOV-89  
PAGE: 742  
STUDY TYPE: CHRONIC/2 YR CARCINOGENIC

ANIMAL NUMBER: 381/PRETEST-  
DATE OF DEATH: 12-FEB-86

381 SEX: FEMALE DOSE GROUP: 3  
STUDY DAY OF DEATH: 752 STUDY WEEK OF DEATH: 108

SACRIFICE STATUS: FINAL SACRIFICE  
TERMINAL BODY WEIGHT: 288.00 (GMS)

<< MICROSCOPIC TISSUE OBSERVATIONS >>  
TISSUE / HISTOPATHOLOGIC FINDINGS

DISTRIBUTION (SEVERITY) / SPECIAL COMMENTS

PITUITARY GLAND ..... (PRESENT)  
-B- ADENOMA

EYES & OPTIC N. .... NOT SPECIFIED (PRESENT)  
-METAPLASTIC BONE FORMATION AND/OR MINERALIZATION, SCLERA

Appendix J (cont.): PATHOLOGY INDIVIDUAL ANIMAL DATA

LETTERMAN ARMY INSTITUTE OF RESEARCH  
 DIV OF RES SUPP, PATH SERV GP  
 SPECIES: RAT/FISCHER-344  
 STUDY START DATE: 23-JAN-84  
 STUDY NUMBER: GLP83009  
 PRINTED: 21-NOV-89  
 PAGE: 743  
 STUDY TYPE: CHRONIC/2 YR CARCINOGENIC

ANIMAL NUMBER: 362/PRETEST#  
 DATE OF DEATH: 23-DEC-85  
 SEX: FEMALE  
 DOSE GROUP: 3  
 SACRIFICE STATUS: FOUND DEAD  
 STUDY DAY OF DEATH: 701  
 STUDY WEEK OF DEATH: 101  
 TERMINAL BODY WEIGHT: 262.00 (GMS)

<< GROSS ORGAN OBSERVATIONS >>  
 SEVERITY GROSS FREE-TEXT COMMENTS  
 ORG NAME KEYWORDS / PHRASES  
 LIVER ADHESION(S) PRESENT MULTIPLE, SEROSAL  
 JEJUNUM MEMORRHAGE(S) PRESENT MULTIPLE, 2-3MM DIAMETER SEEN THROUGH SEROSA  
 ILEUM MEMORRHAGE(S) PRESENT MULTIPLE, 2-3MM DIAMETER SEEN THROUGH SEROSA  
 EYES & OPTIC N. CORNEAL VASCULARIZATION PRESENT BILATERAL  
 PITUITARY GLAND ENLARGED PRESENT .5CM DIAMETER, RED/BLACK

<< MICROSCOPIC TISSUE OBSERVATIONS >>  
 DISTRIBUTION (SEVERITY) / SPECIAL COMMENTS

EXORBITAL LACRIM ..... TISSUE IS MISSING

HEART ..... NOT SPECIFIED(MILD)  
 -CARDIOMYOPATHY

THYMUS ..... TISSUE IS MISSING

LIVER ..... MULTI-FOCAL(TRACE)  
 -HEPATITIS FOCAL (PRESENT)  
 -FIBROSIS CAPSULAR NO COMPOUND FOCAL(TRACE)  
 -BENIGN HYPERPLASTIC MODULE(S)

KIDNEY ..... NOT SPECIFIED(TRACE)  
 -PROGRESSIVE RENAL DISEASE

UTERUS ..... UNILATERAL HYDROMETRA  
 -DILATATION OF THE UTERINE LUMEN (HYDROMETRA) NOT SPECIFIED (PRESENT)

JEJUNUM ..... TISSUE IS AUTOLYTIC

ILEUM ..... TISSUE IS AUTOLYTIC

MAMMARY GLANDS .....

Appendix J (cont.): PATHOLOGY INDIVIDUAL ANIMAL DATA

LETTERMAN ARMY INSTITUTE OF RESEARCH  
DIV OF RES SUPP, PATH SERV GF  
SPECIES: RAT/FISCHER-344

INDIVIDUAL ANIMAL DATA REPORT  
STUDY NUMBER: GLP83009

PRINTED: 21-NOV-89  
PAGE: 744

STUDY START DATE: 23-JAN-84

STUDY TYPE: CHRONIC/2 YR CARCINOGENIC

ANIMAL NUMBER: 382/PRETEST=

382 SEX: FEMALE

DOSE GROUP: 3

SACRIFICE STATUS: FOUND DEAD

DATE OF DEATH: 23-DEC-85

STUDY DAY OF DEATH: 701

STUDY WEEK OF DEATH: 101

TERMINAL BODY WEIGHT: 262.00 (GMS)

<< MICROSCOPIC TISSUE OBSERVATIONS >>  
DISTRIBUTION (SEVERITY) / SPECIAL COMMENTS

MAMMARY GLANDS .....  
-HYPERPLASIA AND/OR HYPERTROPHY OF THE ACINAR TISSUE ..... NOT SPECIFIED(MODERATE)  
-DILATATION (ECTASIA) OF DUCTS AND DUCTULES ..... NOT SPECIFIED (PRESENT)

ADRENAL .....  
-FOCUS OF CELLULAR ALTERATION, VACUOLATED ..... FOCAL(TRACE)

PITUITARY GLAND .....  
-B- ADENOMA ..... (PRESENT)

EYES & OPTIC N. ....

-CORNEAL VASCULARIZATION ..... CATARACT IS SUBCAPSULAR AND BILATERAL  
-LENTICULAR DEGENERATIVE CHANGES COMPATIBLE WITH CATARACT ..... CORNEAL VASCULARIZATION IS BILATERAL  
NOT SPECIFIED(TRACE)  
NOT SPECIFIED (PRESENT)

**Appendix J (cont.): PATHOLOGY INDIVIDUAL ANIMAL DATA**

LETTERMAN ARMY INSTITUTE OF RESEARCH  
 DIV OF RES SUPP, PATH SERV GP  
 SPECIES: RAT/FISCHER-344  
 STUDY NUMBER: GLP83009  
 STUDY START DATE: 23-JAN-84  
 PRINTED: 21-NOV-89  
 PAGE: 746

ANIMAL NUMBER: 384/PRETEST-  
 DATE OF DEATH: 12-FEB-86  
 SEX: FEMALE  
 DOSE GROUP: 3  
 STUDY WEEK OF DEATH: 108  
 SACRIFICE STATUS: FINAL SACRIFICE  
 TERMINAL BODY WEIGHT: 247.00 (GMS)

STUDY TYPE: CHRONIC/2 YR CARCINOGENIC

ORGAN NAME      <<    G R O S S    O R G A N    O B S E R V A T I O N S    >>  
 KEYWORDS / PHRASES      SEVERITY    GROSS FREE-TEXT COMMENTS

PERINEAL      MASS(S)/GROWTH(S)      PRESENT      FIRM, WHITE, 2.5 X 2CM  
 KIDNEY      GRANULAR SURFACE      PRESENT      BILATERAL  
 PITUITARY GLAND      ENLARGED      PRESENT      .5CM DIAMETER, DARK RED

TISSUE / HISTOPATHOLOGIC FINDINGS      <<    M I C R O S C O P I C    T I S S U E    O B S E R V A T I O N S    >>  
 DISTRIBUTION (SEVERITY) / SPECIAL COMMENTS

EXORBITAL LACRIM      .....      FOCAL (TRACE)  
 -ACINAR ATROPHY

HEART      .....      NOT SPECIFIED (MILD)  
 -CARDIOMYOPATHY

LIVER      .....      NOT SPECIFIED (TRACE)  
 -BILE DUCTULE EPITHELIAL HYPERPLASIA AND/OR CHOLANGIOFIBROSIS      MULTI-FOCAL (TRACE)  
 -HEPATITIS      MULTI-FOCAL (TRACE)  
 -HEPATOCYTE COALESCING MICROVESICULAR (FATTY) CHANGE LEADING TO      MULTI-FOCAL (TRACE)  
 NECROSIS AND MINERALIZATION

KIDNEY      .....      NOT SPECIFIED (MODERATE)  
 -PROGRESSIVE RENAL DISEASE

UTERUS      .....      NOT SPECIFIED (PRESENT)  
 -ENDOMETRIAL STROMAL POLYP      NOT SPECIFIED (PRESENT)  
 -CYSTIC DILATATION OF THE ENDOMETRIAL GLANDS

PANCREAS      .....      MULTI-FOCAL (MARKED)  
 -ACINAR (EXOCRINE) ATROPHY

RECTUM      .....      (PRESENT)  
 -I- FIBROSARCOMA, LOCALLY INVASIVE



Appendix J (cont.): PATHOLOGY INDIVIDUAL ANIMAL DATA

LETTERMAN ARMY INSTITUTE OF RESEARCH  
DIV OF RES SUPP, PATH SERV GP  
SPECIES: RAT/FISCHER-344

INDIVIDUAL ANIMAL DATA REPORT  
STUDY NUMBER: GLP83009

PRINTED: 21-NOV-89  
PAGE: 747

STUDY START DATE: 23-JAN-84

STUDY TYPE: CHRONIC/2 YR CARCINOGENIC

ANIMAL NUMBER: 384/PRETEST#

384 SEX: F MALE

DOSE GROUP: 3

SACRIFICE STATUS: FINAL SACRIFICE

DATE OF DEATH: 12-FEB-86

STUDY DAY OF DEATH: 752

STUDY WEEK OF DEATH: 108

TERMINAL BODY WEIGHT: 247.00 (GMS)

TISSUE / HISTOPATHOLOGIC FINDINGS

OBSE RVATI ONS >>  
DISTRIBUTION (SEVERITY) / SPECIAL COMMENTS

SKIN ..... THE MASS IN THE PERINEAL AREA IS A FIBROSARCOMA. MASSON'S TRICHROME STAIN APPLIED TO SECTIONS OF THIS NEOPLASM DEMONSTRATED ABUNDANT COLLAGEN BEING PRODUCED BY THE NEOPLASTIC CELLS. THE HISTOMORPHOLOGY OF THE TUMOR CELLS AND THE PRESENCE OF COLLAGEN IS THE BASIS FOR THE DIAGNOSIS OF FIBROSARCOMA. (PRESENT)

-N- FIBROSARCOMA

MAMMARY GLANDS .....  
-HYPERPLASIA AND/OR HYPERTROPHY OF THE ACINAR TISSUE ..... NOT SPECIFIED(MODERATE)  
-DILATATION (ECTASIA) OF DUCTS AND DUCTULES ..... NOT SPECIFIED (PRESENT)

NOSE/TURBINATES ..... INFILTRATE INVOLVES MASO-LACRIMAL DUCT.  
-MIXED INFLAMMATORY CELL INFILTRATION, NASAL CAVITY, SINUSES, ..... NOT SPECIFIED(MILD)  
TURBINATES, MASO-LACRIMAL DUCTS

ADRENAL ..... NOT SPECIFIED(TRACE)  
-FOCUS OF CELLULAR ALTERATION, VACUOLATED ..... (PRESENT)

PITUITARY GLAND .....  
-B- ADENOMA ..... (PRESENT)

EYES & OPTIC N. ....  
-RETINAL ATROPHY AND/OR DEGENERATION, UNILATERAL OR BILATERAL ..... NOT SPECIFIED(TRACE)  
-LENTICULAR DEGENERATIVE CHANGES COMPATIBLE WITH CATARACT ..... NOT SPECIFIED (PRESENT)

Appendix J (cont.): PATHOLOGY INDIVIDUAL ANIMAL DATA

LETTERMAN ARMY INSTITUTE OF RESEARCH  
 DIV OF RES SUPP, PATH SERV GP  
 SPECIES: RAT/FISCHER-344

INDIVIDUAL ANIMAL DATA REPORT

PRINTED: 21-NOV-89

STUDY NUMBER: GLP83009

PAGE: 748

STUDY START DATE: 23-JAN-84

STUDY TYPE: CHRONIC/2 YR CARCINOGENIC

ANIMAL NUMBER: 385/PRETEST= 385 SEX: FEMALE DOSE GROUP: 3 SACRIFICE STATUS: FOUND DEAD  
 DATE OF DEATH: 23-NOV-85 STUDY DAY OF DEATH: 671 STUDY WEEK OF DEATH: 96 TERMINAL BODY WEIGHT: 228.00 (GMS)

ORGAN NAME << GROSS ORGAN OBSERVATIONS >>  
 KEYWORDS / PHRASES SEVERITY GROSS FREE-TEXT COMMENTS

WHOLE BODY POST MORTEM AUTOLYSIS. PRESENT  
 SPLEEN ENLARGED (SPLENOHEGALY) PRESENT

TISSUE / HISTOPATHOLOGIC FINDINGS << MICROSCOPIC TISSUE OBSERVATIONS >>  
 DISTRIBUTION (SEVERITY) / SPECIAL COMMENTS

TRACHEA ..... TISSUE IS AUTOLYTIC

THYROID GLANDS ..... TISSUE IS AUTOLYTIC

PARATHYROID ..... TISSUE IS AUTOLYTIC

ESOPHAGUS ..... TISSUE IS AUTOLYTIC

HEART ..... NOT SPECIFIED(MILD)  
 -CARDIOMYOPATHY

LUNGS ..... NOT SPECIFIED(TRACE)  
 -MINERALIZATION OF PULMONARY ARTERIES (PRESENT)  
 -N- LARGE GRANULAR LYMPHOCYTE LEUKEMIA, METASTATIC

SPLEEN ..... (PRESENT)  
 -N- LARGE GRANULAR LYMPHOCYTE LEUKEMIA, METASTATIC

LIVER ..... FOCAL(TRACE)  
 -FOCUS OF CELLULAR ALTERATION - BASOPHILIC DIFFUSE(MILD)  
 -HEPATOCTYIC DEGENERATIVE CHANGES (NON-NECROTIC) (PRESENT)  
 -N- LARGE GRANULAR LYMPHOCYTE LEUKEMIA, METASTATIC

KIDNEY ..... AUTOLYTIC CHANGE IS PRESENT, HOWEVER IT IS POSSIBLE TO DETECT  
 -PROGRESSIVE RENAL DISEASE PROGRESSIVE RENAL DISEASE, GRADE 1.  
 NOT SPECIFIED(TRACE)

UTERUS .....

Appendix J (cont.): PATHOLOGY INDIVIDUAL ANIMAL DATA

LETTERMAN ARMY INSTITUTE OF RESEARCH  
 DIV OF RES SUPP, PATH SERV GP  
 SPECIES: RAT/FISCHER-344

INDIVIDUAL ANIMAL DATA REPORT  
 STUDY NUMBER: GLP83009

STUDY START DATE: 23-JAN-84

STUDY TYPE: CHRONIC/2 YR CARCINOGENIC

ANIMAL NUMBER: 385/PRETEST= 385 SEX: FEMALE DOSE GROUP: 3 SACRIFICE STATUS: FOUND DEAD  
 DATE OF DEATH: 23-NOV-85 STUDY DAY OF DEATH: 671 STUDY WEEK OF DEATH: 96 TERMINAL BODY WEIGHT: 228.00 (GMS)

<< MICROSCOPIC TISSUE OBSERVATIONS >>  
 TISSUE / HISTOPATHOLOGIC FINDINGS DISTRIBUTION (SEVERITY) / SPECIAL COMMENTS

UTERUS ..... NOT SPECIFIED (PRESENT)  
 -ENDOMETRIAL STROMAL POLYP

DUODENUM ..... TISSUE IS AUTOLYTIC

JEJUNUM ..... TISSUE IS AUTOLYTIC

ILEUM ..... TISSUE IS AUTOLYTIC

PANCREAS ..... TISSUE IS AUTOLYTIC

CECUM ..... TISSUE IS AUTOLYTIC

RECTUM ..... TISSUE IS AUTOLYTIC

COLON ..... TISSUE IS AUTOLYTIC

STOMACH ..... TISSUE IS AUTOLYTIC

WHOLE BODY ..... (PRESENT)  
 -M- LARGE GRANULAR LYMPHOCYtic LEUKEMIA

Appendix J (cont.): PATHOLOGY INDIVIDUAL ANIMAL DATA

LETTERMAN ARMY INSTITUTE OF RESEARCH  
DIV OF RES SUPP, PATH SERV GP  
SPECIES: RAT/FISCHER-344

INDIVIDUAL ANIMAL DATA REPORT  
STUDY NUMBER: GLP83009

PRINTED: 21-NOV-89  
PAGE: 750

STUDY START DATE: 23-JAN-84

STUDY TYPE: CHRONIC/2 YR CARCINOGENIC

ANIMAL NUMBER: 386/PRETEST= 386 SEX: FEMALE  
DATE OF DEATH: 08-OCT-85 STUDY DAY OF DEATH: 625

DOSE GROUP: 3 SACRIFICE STATUS: SACRIFICED MORIBUND

STUDY WEEK OF DEATH: 90 TERMINAL BODY WEIGHT: 215.00 (GMS)

ORGAN NAME                      << G R O S S O R G A N O B S E R V A T I O N S >>  
KEYWORDS / PHRASES                      SEVERITY GROSS FREE-TEXT COMMENTS

RECTUM                      MUCOID DISCHARGE                      PRESENT  
LIVER                      DISCOLORATION                      PRESENT  
CECUM                      MASS(ES)                      PRESENT  
UTERUS                      GROWTH(S)/MASS(S)                      PRESENT

YELLOW, POSTERIOR END COVERED WITH BLACK HARDENED MATERIAL.  
GENERALLY PALE  
CECUM DISTENDED, CONTAINS A 4 X 2.5 X 2CM PEDUNCULATED MASS,  
KOLLOID, CLEAR FLUID FILLED  
BROWN/RED, SEMI-FIRM, 2.5 X 1.5 X 1.5CM, DISTAL END OF LEFT  
HORN WHICH IS ENLARGED, INTRALUMINAL.

TISSUE / HISTOPATHOLOGIC FINDINGS                      << M I C R O S C O P I C T I S S U E O B S E R V A T I O N S >>  
DISTRIBUTION (SEVERITY) / SPECIAL COMMENTS

THYROID GLANDS                      NOT SPECIFIED(TRACE)  
-PARA-FOLLICULAR CELL HYPERPLASIA ("C" CELL, LIGHT CELL)

EXORBITAL LACRIM                      MULTI-FOCAL(TRACE)  
-ACINAR ATROPHY

HEART                      NOT SPECIFIED(MILD)  
-MEDIAL HYPERTROPHY OF MUSCULAR ARTERIES

SPLEEN                      NOT SPECIFIED (PRESENT)  
-EXTRAMEDULLARY HEMATOPOIESIS

LYMPH NODES                      NOT SPECIFIED (PRESENT)  
-HISTIOCYTIC INFILTRATION, SUBCAPSULAR AND MEDULLARY SINUSES

LIVER                      MULTI-FOCAL(MILD)  
-FOCUS OF CELLULAR ALTERATION - CLEAR CELLS  
-BENIGN HYPERPLASTIC NODULE(S)

KIDNEY                      NOT SPECIFIED(TRACE)  
-PROGRESSIVE RENAL DISEASE

Appendix J (cont.): PATHOLOGY INDIVIDUAL ANIMAL DATA

LETTERMAN ARMY INSTITUTE OF RESEARCH  
D'V OF RES SUPP, PATH SERV GP  
SPECIES: RAT/FISCHER-344

INDIVIDUAL ANIMAL DATA REPORT  
STUDY NUMBER: GLP83009  
STUDY START DATE: 23-JAN-84

PRINTED: 21-NOV-89  
PAGE: 751

STUDY TYPE: CHRONIC/2 YR CARCINOGENIC

ANIMAL NUMBER: 386/PRETEST= 386 SEX: FEMALE DOSE GROUP: 3 SACRIFICE STATUS: SACRIFICED MORIBUND  
DATE OF DEATH: 08-OCT-85 STUDY DAY OF DEATH: 625 STUDY WEEK OF DEATH: 90 TERMINAL BODY WEIGHT: 215.00 (GMS)

<< MICROSCOPIC TISSUE OBSERVATIONS >>  
TISSUE / HISTOPATHOLOGIC FINDINGS ..... DISTRIBUTION (SEVERITY) / SPECIAL COMMENTS .....

UTERUS ..... MUCH OF THE STROMAL SARCOMA IS INFARCTED AND NECROTIC. THERE IS FOCAL DECIDUAL CELL PROLIFERATION IN SOME AREAS OF THE TUMOR.  
-M- ENDOMETRIAL SARCOMA (PRESENT)

CECUM .....  
-B- ADENOMATOUS POLYP (PRESENT)

COLON .....  
-CHRONIC COLITIS WITH MUCOUS GLAND HYPERPLASIA AND HYPERSECRETION DIFFUSE(MILD)

MAMMARY GLANDS ..... NOT SPECIFIED(TRACE)  
-HYPERPLASIA AND/OR HYPERTROPHY OF THE ACINAR TISSUE

ADRENAL ..... NOT SPECIFIED(TRACE)  
-FOCUS OF CELLULAR ALTERATION, VACUOLATED

Appendix J (cont.): PATHOLOGY INDIVIDUAL ANIMAL DATA

LETTERMAN ARMY INSTITUTE OF RESEARCH  
 DIV OF RES SUPP, PATH SERV GP  
 SPECIES: RAT/FISCHER-344  
 STUDY START DATE: 23-JAN-84  
 STUDY NUMBER: GLP83009  
 PRINTED: 21-NOV-89  
 PAGE: 752  
 STUDY TYPE: CHRONIC/2 YR CARCINOGENIC

ANIMAL NUMBER: 387/PRETEST= 387 SEX: FEMALE DOSE GROUP: 3 SACRIFICE STATUS: FINAL SACRIFICE  
 DATE OF DEATH: 12-FEB-86 STUDY DAY OF DEATH: 752 STUDY WEEK OF DEATH: 108 TERMINAL BODY WEIGHT: 203.00 (GMS)

ORGAN NAME << GROSS ORGAN OBSERVATIONS >>  
 KEYWORDS / PHRASES SEVERITY GROSS FREE-TEXT COMMENTS  
 PITUITARY GLAND POLYP PRESENT PROXIMAL RIGHT HORN, INTRALUMINAL  
 CYST(S) PRESENT .1CM DIAMETER

TISSUE / HISTOPATHOLOGIC FINDINGS << MICROSCOPIC TISSUE OBSERVATIONS >>  
 DISTRIBUTION (SEVERITY) / SPECIAL COMMENTS

LUNGS  
 -MINERALIZATION OF PULMONARY ARTERIES NOT SPECIFIED(TRACE)

SPLEEN  
 -SMOOTH MUSCLE HYPERTROPHY, CAPSULE AND TRABECULAE NOT SPECIFIED (PRESENT)

LIVER  
 -BILE DUCTULE EPITHELIAL HYPERPLASIA AND/OR CHOLANGIOFIBROSIS FOCAL(TRACE)  
 -HEPATITIS MULTI-FOCAL(TRACE)  
 -HEPATOCTYE COALESCING MICROVESICULAR (FATTY) CHANGE LEADING TO MULTI-FOCAL(TRACE)  
 NECROSIS AND MINERALIZATION

KIDNEY  
 -PROGRESSIVE RENAL DISEASE NOT SPECIFIED(TRACE)

UTERUS  
 -ENDOMETRIAL STROMAL POLYP NOT SPECIFIED (PRESENT)  
 -CYSTIC DILATATION OF THE ENDOMETRIAL GLANDS NOT SPECIFIED (PRESENT)

NOSE/TURBINATES  
 -MIXED INFLAMMATORY CELL INFILTRATION, NASAL CAVITY, SINUSES, INFILTRATE ADJACENT NASO-LACRIMAL DUCT.  
 TURBINATES, NASO-LACRIMAL DUCTS NOT SPECIFIED(MILD)

ADRENAL  
 -FOCUS OF CELLULAR ALTERATION, VACUOLATED NOT SPECIFIED(TRACE)

PITUITARY GLAND

Appendix J (cont.): PATHOLOGY INDIVIDUAL ANIMAL DATA

LETTERMAN ARMY INSTITUTE OF RESEARCH  
 DIV OF RES SUPP, PATH SERV GP  
 SPECIES: RAT/FISCHER-344  
 STUDY START DATE: 23-JAN-84  
 STUDY NUMBER: GLP83009  
 PRINTED: 21-NOV-89  
 PAGE: 753  
 STUDY TYPE: CHRONIC/2 YR CARCINOGENIC

ANIMAL NUMBER: 387/PRETEST= 387 SEX: FEMALE DOSE GROUP: 3 SACRIFICE STATUS: FINAL SACRIFICE  
 DATE OF DEATH: 12-FEB-86 STUDY DAY OF DEATH: 752 STUDY WEEK OF DEATH: 108 TERMINAL BODY WEIGHT: 203.00 (GMS)

<< MICROSCOPIC TISSUE OBSERVATIONS >>  
 DISTRIBUTION (SEVERITY) / SPECIAL COMMENTS

PITUITARY GLAND ..... NOT SPECIFIED (PRESENT)  
 -CYST(S)

Appendix J (cont.): PATHOLOGY INDIVIDUAL ANIMAL DATA

LETSMAN ARMY INSTITUTE OF RESEARCH INDIVIDUAL ANIMAL DATA REPORT PRINTED: 21-NOV-89  
DIV OF RES SUPP, PATH SERV GP STUDY NUMBER: GLP83009 PAGE: 754  
SPECIES: RAT/FISCHER-344 STUDY START DATE: 23-JAN-84 STUDY TYPE: CHRONIC/2 YR CARCINOGENIC

ANIMAL NUMBER: 388/PRETEST= 388 SEX: FEMALE DOSE GROUP: 3 SACRIFICE STATUS: FINAL SACRIFICE  
DATE OF DEATH: 12-FEB-86 STUDY DAY OF DEATH: 752 STUDY WEEK OF DEATH: 108 TERMINAL BODY WEIGHT: 262.00 (GMS)

ORGAN NAME << GROSS ORGAN OBSERVATIONS >>  
KEYWORDS / PHRASES SEVERITY GROSS FREE-TEXT COMMENTS  
PITUITARY GLAND ENLARGED PRESENT DARK RED, .5CM DIAMETER

TISSUE / HISTOPATHOLOGIC FINDINGS << MICROSCOPIC TISSUE OBSERVATIONS >>  
DISTRIBUTION (SEVERITY) / SPECIAL COMMENTS

THYROID GLANDS  
-PARA-FOLLICULAR CELL HYPERPLASIA (MC) CELL, LIGHT CELL) FOCAL(TRACE)

HEART  
-CARDIOMYOPATHY NOT SPECIFIED(TRACE)

SPLEEN  
-EXTRAMEDULLARY HEMATOPOIESIS NOT SPECIFIED (PRESENT)

LYMPH NODES  
-RED BLOOD CELLS, HEMOSIDERIN AND/OR ERYTHROPHAGOCYTOSIS WITHIN MEDULLARY SINUSES RBC'S AND HEMOSIDERIN LIMITED TO A MEDIASTIANL NODE.  
NOT SPECIFIED (PRESENT)

LIVER  
-FOCUS OF CELLULAR ALTERATION - BASOPHILIC MULTI-FOCAL(MILD)  
-HEPATOCTYIC VACUOLIZATION NOT SPECIFIED(TRACE)  
-HEPATOCTYIC COALESCING MICROVESICULAR (FATTY) CHANGE LEADING TO MULTI-FOCAL(MILD)  
NECROSIS AND MINERALIZATION

KIDNEY  
-PROGRESSIVE RENAL DISEASE NOT SPECIFIED(MODERATE)

UTERUS  
-CYSTIC DILATATION OF THE ENDOMETRIAL GLANDS NOT SPECIFIED (PRESENT)



Appendix J (cont.): PATHOLOGY INDIVIDUAL ANIMAL DATA

LETTERMAN ARMY INSTITUTE OF RESEARCH  
DIV OF RES SUPP. PATH SERV GP  
SPECIES: RAT/FISCHER-344

INDIVIDUAL ANIMAL DATA REPORT  
STUDY NUMBER: GLP83009  
STUDY START DATE: 23-JAN-84

PRINTED: 21-NOV-89  
PAGE: 755

STUDY TYPE: CHRONIC/2 YR CARCINOGENIC

ANIMAL NUMBER: 388/PRETEST# 388 SEX: FEMALE DOSE GROUP: 3 SACRIFICE STATUS: FINAL SACRIFICE  
DATE OF DEATH: 12-FEB-86 STUDY DAY OF DEATH: 752 STUDY WEEK OF DEATH: 108 TERMINAL BODY WEIGHT: 262.00 (GMS)

TISSUE / HISTOPATHOLOGIC FINDINGS << MICROSCOPIC TISSUE OBSERVATIONS >>  
DISTRIBUTION (SEVERITY) / SPECIAL COMMENTS

MAMMARY GLANDS ..... SECTION #21 HAS A SECTION OF SKIN WITH ADJACENT HYPERPLASTIC  
MAMMARY TISSUE SIMILAR TO THAT IN SECTION #15. THERE IS NO  
NOTATION AS TO THE LOCATION OF THIS TISSUE.  
-HYPERPLASIA AND/OR HYPERTROPHY OF THE ACINAR TISSUE  
-DILATATION (ECTASIA) OF DUCTS AND DUCTULES NOT SPECIFIED (PRESENT)

NOSE/TURBINATES ..... INFILTRATE ADJACENT NASO-LACRIMAL DUCT.  
-MIXED INFLAMMATORY CELL INFILTRATION, NASAL CAVITY, SINUSES, NOT SPECIFIED(MILD)  
TURBINATES, NASO-LACRIMAL DUCTS

ADRENAL ..... MULTI-FOCAL(TRACE)  
-FOCUS OF CELLULAR ALTERATION, VACUOLATED (PRESENT)

PITUITARY GLAND .....  
-B- ADENOMA (PRESENT)

EYES & OPTIC N. .... NOT SPECIFIED (PRESENT)  
-METAPLASTIC BONE FORMATION AND/OR MINERALIZATION, SCLERA

WHOLE BODY ..... THERE IS INFLAMMATION OF BROWN FAT IN SEVERAL LOCATIONS :THE  
MEDIASTINUM NEAR THE THYMUS, THE PERIRENAL FAT, AND IN THE  
MESENTERY. IN SECTION #21 THERE IS A FOCAL AREA OF NECROTIC  
FAT.  
-INFLAMMATION OF BROWN FAT, (LOCATION SPECIFIED IN COMMENTS) NOT SPECIFIED (PRESENT)

Appendix J (cont.): PATHOLOGY INDIVIDUAL ANIMAL DATA

LETTERMAN ARMY INSTITUTE OF RESEARCH  
DIV OF RES SUPP, PATH SERV GP  
SPECIES: RAT/FISCHER-344

INDIVIDUAL ANIMAL DATA REPORT  
STUDY NUMBER: GLP83009  
STUDY START DATE: 23-JAN-84

PRINTED: 21-NOV-89  
PAGE: 757

STUDY TYPE: CHRONIC/2 YR CARCINOGENIC

ANIMAL NUMBER: 390/PRETEST= 390 SEX: FEMALE DOSE GROUP: 3 SACRIFICE STATUS: FINAL SACRIFICE  
DATE OF DEATH: 12-FEB-86 STUDY DAY OF DEATH: 752 STUDY WEEK OF DEATH: 108 TERMINAL BODY WEIGHT: 246.00 (GMS)

ORGAN NAME << GROSS ORGAN OBSERVATIONS >>  
KEYWORDS / PHRASES SEVERITY GROSS FREE-TEXT COMMENTS  
LIVER PRESENT THREE .3-.4CM DIAMETER  
LIVER PROMINENT LOBULAR MARKINGS PRESENT  
PITUITARY GLAND PRESENT .2CM DIAMETER

TISSUE / HISTOPATHOLOGIC FINDINGS << MICROSCOPIC TISSUE OBSERVATIONS >>  
DISTRIBUTION (SEVERITY) / SPECIAL COMMENTS

PARATHYROID ..... TISSUE IS MISSING

HEART ..... NOT SPECIFIED(MILD)  
-CARDIOMYOPATHY

LYMPH NODES ..... RBC'S AND HEMOSIDERIN ARE PRESENT ONLY IN A MEDIASTINAL NODE.  
-RED BLOOD CELLS, HEMOSIDERIN AND/OR ERYTHROPHAGOCYTOSIS WITHIN HISTIOCYTIC INFILTRATION INVOLVES ONLY THE MESENTERIC NODES.  
MEDULLARY SINUSES NOT SPECIFIED (PRESENT)

-HISTIOCYTIC INFILTRATION, SUBCAPSULAR AND MEDULLARY SINUSES NOT SPECIFIED (PRESENT)

LIVER ..... NOT SPECIFIED(MILD)  
-BILE DUCTULE EPITHELIAL HYPERPLASIA AND/OR CHOLANGIOFIBROSIS NOT SPECIFIED(TRACE)  
-HEPATITIS MULTI-FOCAL(MILD)  
-NECROSIS, HEPATOCTIC, INDIVIDUAL CELLS MULTI-FOCAL(MILD)  
-BENIGN HYPERPLASTIC MODULE(S) FOCAL(MARKED)  
-FIBROSIS, PARENCHYMAL (SCARRING) MULTI-FOCAL(MODERATE)  
-HEPATOCTE COALESCING MICROVESICULAR (FATTY) CHANGE LEADING TO NECROSIS AND MINERALIZATION

PANCREAS ..... (PRESENT)  
-B ISLET CELL ADENOMA

MAMMARY GLANDS ..... NOT SPECIFIED(MILD)  
-HYPERPLASIA AND/OR HYPERTROPHY OF THE ACINAR TISSUE

ADRENAL .....

Appendix J (cont.): PATHOLOGY INDIVIDUAL ANIMAL DATA

LETTERMAN ARMY INSTITUTE OF RESEARCH  
DIV OF RES SUPP, PATH SERV GP  
SPECIES: RAT/FISCHER-344

INDIVIDUAL ANIMAL DATA REPORT  
STUDY NUMBER: GLP83009  
STUDY START DATE: 23-JAN-84

PRINTED: 21-NOV-89  
PAGE: 758

STUDY TYPE: CHRONIC/2 YR CARCINOGENIC

ANIMAL NUMBER: 390/PRETEST# 390 SEX: FEMALE DOSE GROUP: 3 SACRIFICE STATUS: FINAL SACRIFICE  
DATE OF DEATH: 12-FEB-86 STUDY DAY OF DEATH: 752 STUDY WEEK OF DEATH: 108 TERMINAL BODY WEIGHT: 246.00 (GMS)

<< M I C R O S C O P I C T I S S U E O B S E R V A T I O N S >>  
TISSUE / HISTOPATHOLOGIC FINDINGS DISTRIBUTION (SEVERITY) / SPECIAL COMMENTS

ADRENAL ..... NOT SPECIFIED(MILD)  
-FOCUS OF CELLULAR ALTERATION, VACUOLATED  
EYES & OPTIC N. .... THE LENS OF ONE EYE WAS LOST DURING PROCESSING.

**Appendix J (cont.): PATHOLOGY INDIVIDUAL ANIMAL DATA**

LETTERMAN ARMY INSTITUTE OF RESEARCH  
 DIV OF RES SUPP, PATH SERV GP  
 SPECIES: RAT/FISCHER-344  
 STUDY START DATE: 23-JAN-84  
 STUDY NUMBER: GLP83009  
 PRINTED: 21-NOV-89  
 PAGE: 759

ANIMAL NUMBER: 391/PRETEST= 391 SEX: FEMALE DOSE GROUP: 3 SACRIFICE STATUS: FINAL SACRIFICE  
 DATE OF DEATH: 12-FEB-86 STUDY DAY OF DEATH: 752 STUDY WEEK OF DEATH: 108 TERMINAL BODY WEIGHT: 285.00 (GMS)  
 STUDY TYPE: CHRONIC/2 YR CARCINOGENIC

<< GROSS ORGAN OBSERVATIONS >>  
 SEVERITY GROSS FREE-TEXT COMMENTS  
 OVARIES PARA-OVARIAN CYST(S) PRESENT 1CM DIAMETER LEFT  
 UTERUS HYDROMETRA PRESENT BILATERAL  
 PITUITARY GLAND ENLARGED PRESENT .4CM DIAMETER, FOCAL DISCOLORATION, DARK RED, .3CM DIAMETER

<< MICROSCOPIC TISSUE OBSERVATIONS >>  
 TISSUE / HISTOPATHOLOGIC FINDINGS DISTRIBUTION (SEVERITY) / SPECIAL COMMENTS

EXORBITAL LACRIM ..... FOCAL(TRACE)  
 -ACINAR ATROPHY .....  
 HEART ..... NOT SPECIFIED(MILD)  
 -CARDIOMYOPATHY .....  
 LUNGS ..... FOCAL(TRACE)  
 -MINERALIZATION OF PULMONARY ARTERIES .....  
 LYMPH NODES ..... RBC'S AND HEMOSIDERIN LIMITED TO A MEDIASTIANL NODE.  
 -RED BLOOD CELLS, HEMOSIDERIN AND/OR ERYTHROPHAGOCYTOSIS WITHIN ..... NOT SPECIFIED (PRESENT)  
 MEDULLARY SINUSES .....  
 LIVER .....  
 -FOCUS OF CELLULAR ALTERATION - BASOPHILIC .....  
 -NECROSIS ..... MULTI-FOCAL(MILD)  
 -HEPATOCYTE COALESCING MICROVESICULAR (FATTY) CHANGE LEADING TO FOCAL(TRACE)  
 NECROSIS AND MINERALIZATION ..... MULTI-FOCAL(MODERATE)

KIDNEY ..... NOT SPECIFIED(MILD)  
 -PROGRESSIVE RENAL DISEASE .....  
 UTERUS ..... NOT SPECIFIED (PRESENT)  
 -DILATATION OF THE UTERINE LUMEN (HYDROMETRA) .....

Appendix J (cont.): PATHOLOGY INDIVIDUAL ANIMAL DATA

LETTERMAN ARMY INSTITUTE OF RESEARCH  
DIV OF RES SUPP, PATH SERV GP  
SPECIES: RAT/FISCHER-344

INDIVIDUAL ANIMAL DATA REPORT  
STUDY NUMBER: GLP83009

PRINTED: 21-NOV-89  
PAGE: 760

STUDY START DATE: 23-JAN-84

STUDY TYPE: CHRONIC/2 YR CARCINOGENIC

ANIMAL NUMBER: 391/PRETEST= 391 SEX: FEMALE DOSE GROUP: 3 SACRIFICE STATUS: FINAL SACRIFICE  
DATE OF DEATH: 12-FEB-86 STUDY DAY OF DEATH: 752 STUDY WEEK OF DEATH: 108 TERMINAL BODY WEIGHT: 285.00 (GMS)

TISSUE / HISTOPATHOLOGIC FINDINGS << MICROSCOPIC TISSUE OBSERVATIONS >>  
DISTRIBUTION (SEVERITY) / SPECIAL COMMENTS

UTERUS ..... NOT SPECIFIED (PRESENT)  
-CYSTIC DILATATION OF THE ENDOMETRIAL GLANDS

OVARIES ..... NOT SPECIFIED (PRESENT)  
-PARA-OVARIAN CYST(S)

SKELETAL MUSCLE ..... MULTI-FOCAL(MILD)  
-CHRONIC MYOSITIS

MAMMARY GLANDS ..... NOT SPECIFIED (TRACE)  
-HYPERPLASIA AND/OR HYPERTROPHY OF THE ACINAR TISSUE  
-DILATATION (ECTASIA) OF DUCTS AND DUCTULES

PITUITARY GLAND ..... (PRESENT)  
-B- ADENOMA

Appendix J (cont.): PATHOLOGY INDIVIDUAL ANIMAL DATA

LETTERMAN ARMY INSTITUTE OF RESEARCH  
DIV OF RES SUPP, PATH SERV GP  
SPECIES: RAT/FISCHER-344

INDIVIDUAL ANIMAL DATA REPORT  
STUDY NUMBER: GLP83009

PRINTED: 21-NOV-89  
PAGE: 761

STUDY START DATE: 23-JAN-84

STUDY TYPE: CHRONIC/2 YR CARCINOGENIC

ANIMAL NUMBER: 392/PRETEST=

392 SEX: FEMALE

DOSE GROUP: 3

SACRIFICE STATUS: SACRIFICED MORIBUND

DATE OF DEATH: 31-MAY-85

STUDY DAY OF DEATH: 495

STUDY WEEK OF DEATH: 71

TERMINAL BODY WEIGHT: 237.00 (GMS)

ORGAN NAME

<< GROSS ORGAN OBSERVATIONS >>

KEYWORDS / PHRASES SEVERITY GROSS FREE-TEXT COMMENTS

SKIN

PRESENT

MULTIPLE, .1-.3CM DIAMETER, FOCAL, COVERED WITH RED/BLACK CRUSTY EXUDATE, LOCATED BEHIND EARS AND OVER RIGHT SCAPULA

<< MICROSCOPIC TISSUE OBSERVATIONS >>  
TISSUE / HISTOPATHOLOGIC FINDINGS

DISTRIBUTION (SEVERITY) / SPECIAL COMMENTS

LIVER

MULTI-FOCAL(MILD)

KIDNEY

NOT SPECIFIED(MILD)

-PROGRESSIVE RENAL DISEASE

OVARIES

NOT SPECIFIED (PRESENT)

-CYSTIC CORPORA LUTEA

RECTUM

TISSUE IS MISSING

SKIN

MULTI-FOCAL (PRESENT)

-EROSION/ULCERATION OF THE SKIN SURFACE

MAMMARY GLANDS

TISSUE IS MISSING

BONE, STERNUM

MYELOID HISTIOCYTOSIS IS A PROVISIONAL DIAGNOSIS. THE LESION IN THIS ANIMAL IS VERY SIMILAR TO THAT IN ANIMAL #84D00030, (XYBION #148). IN ANIMAL #392, THE LESION IS PRESENT IN THE MARROW OF THE STERNUM, FEMUR, AND VERTEBRAE. IT CONSISTS OF NUMEROUS LARGE HISTIOCYTIC CELLS. NO ORGANISMS WERE DETECTED IN SECTIONS STAINED WITH GIEMSA, BROWN & BREN, GOODPASTURE, PAS-OR GMS STAINS. MANY OF THE HISTIOCYTIC CELLS CONTAINED PAS-POSITIVE MATERIAL. SEE ANIMAL #148 FOR ADDITIONAL COMMENTS. NOT SPECIFIED (PRESENT)

-MYELOID HISTIOCYTOSIS

BONE, FEMUR

Appendix J (cont.): PATHOLOGY INDIVIDUAL ANIMAL DATA

LETTERMAN ARMY INSTITUTE OF RESEARCH  
DIV OF RES SUPP, PATH SERV GP  
SPECIES: RAT/FISCHER-344

INDIVIDUAL ANIMAL DATA REPORT  
STUDY NUMBER: GLP83009  
STUDY START DATE: 23-JAN-84

PRINTED: 21-NOV-89  
PAGE: 762  
STUDY TYPE: CHRONIC/2 YR CARCINOGENIC

ANIMAL NUMBER: 392/PRETEST= 392 SEX: FEMALE DOSE GROUP: 3 SACRIFICE STATUS: SACRIFICED MORIBUND  
DATE OF DEATH: 31-MAY-85 STUDY DAY OF DEATH: 495 STUDY WEEK OF DEATH: 71 TERMINAL BODY WEIGHT: 237.00 (GMS)

<< MICROSCOPIC TISSUE OBSERVATIONS >>  
TISSUE / HISTOPATHOLOGIC FINDINGS ..... DISTRIBUTION (SEVERITY) / SPECIAL COMMENTS .....

BONE, FEMUR ..... NOT SPECIFIED (PRESENT)  
-MYELOID HISTIOCYTOSIS

BONE VERT ..... NOT SPECIFIED (PRESENT)  
-MYELOID HISTIOCYTOSIS

ADRENAL ..... NOT SPECIFIED(MILD)  
-FOCUS OF CELLULAR ALTERATION, VACUOLATED

Appendix J (cont.): PATHOLOGY INDIVIDUAL ANIMAL DATA

LETTERMAN ARMY INSTITUTE OF RESEARCH  
DIV OF RES SUPP, PATH SERV GP  
SPECIES: RAT/FISCHER-344

INDIVIDUAL ANIMAL DATA REPORT  
STUDY NUMBER: GLP83009  
STUDY START DATE: 23-JAN-84

PRINTED: 21-NOV-89  
PAGE: 763

STUDY TYPE: CHRONIC/2 YR CARCINOGENIC

ANIMAL NUMBER: 393/PRETEST= 393 SEX: FEMALE DOSE GROUP: 3 SACRIFICE STATUS: FINAL SACRIFICE  
DATE OF DEATH: 14-FEB-86 STUDY DAY OF DEATH: 754 STUDY WEEK OF DEATH: 108 TERMINAL BODY WEIGHT: 244.00 (GMS)

ORGAN NAME << GROSS ORGAN OBSERVATIONS >>  
KEYWORDS / PHRASES SEVERITY GROSS FREE-TEXT COMMENTS

PITUITARY GLAND DISCOLORATION PRESENT DARK, RAISED, .1CM DIAMETER  
HEART GROWTH(S)/MASS(S) PRESENT .2CM, WHITE, LEFT VENTRICLE.  
UTERUS ABSCESS(ES) PRESENT .3CM ENDOMETRIAL RIGHT HORN, PALE.  
SKIN PRESENT INGUINAL, 2CM.

TISSUE / HISTOPATHOLOGIC FINDINGS << MICROSCOPIC TISSUE OBSERVATIONS >>  
DISTRIBUTION (SEVERITY) / SPECIAL COMMENTS

TRACHEA ..... NOT SPECIFIED(TRACE)  
-NON-SUPPURATIVE TRACHEITIS

HEART ..... THE "MODULE" NOTED GROSSLY CONSISTS OF A WELL-DEMARCATED AREA  
OF MATURE FIBROUS CONNECTIVE TISSUE WITH A FEW ENTRAPPED  
ATROPHIC MYOCARDIAL FIBERS. THIS LESION MAY BE A HEALED  
INFARCT OR A RATHER UNUSUAL MANIFESTATION OF THE CARDIOMYOPATHY  
COMMON IN THIS STRAIN OF RAT.  
NOT SPECIFIED(MARKED)

LUNGS ..... NOT SPECIFIED(TRACE)  
-MINERALIZATION OF PULMONARY ARTERIES

LIVER ..... NOT SPECIFIED(TRACE)  
-BILE DUCTULE EPITHELIAL HYPERPLASIA AND/OR CHOLANGIOFIBROSIS  
-HEPATITIS NOT SPECIFIED(MILD)  
-FOCUS OF CELLULAR ALTERATION - BASOPHILIC NOT SPECIFIED(MILD)  
-HEPATOCTYTE COALESCING MICROVESICULAR (FATTY) CHANGE LEADING TO MULTI-FOCAL(MILD)  
NECROSIS AND MINERALIZATION

KIDNEY ..... NOT SPECIFIED(TRACE)  
-PROGRESSIVE RENAL DISEASE

UTERUS ..... NOT SPECIFIED(TRACE)



Appendix J (cont.): PATHOLOGY INDIVIDUAL ANIMAL DATA

LETTERMAN ARMY INSTITUTE OF RESEARCH  
DIV OF RES SUPP, PATH SERV GP  
SPECIES: RAT/FISCHER-344

INDIVIDUAL ANIMAL DATA REPORT  
STUDY NUMBER: GLP83009  
STUDY START DATE: 23-JAN-84

PRINTED: 21-NOV-89  
PAGE: 764

STUDY TYPE: CHRONIC/2 YR CARCINOGENIC

ANIMAL NUMBER: 393/PRETEST# 393 SEX: FEMALE DOSE GROUP: 3 SACRIFICE STATUS: FINAL SACRIFICE  
DATE OF DEATH: 14-FEB-86 STUDY DAY OF DEATH: 754 STUDY WEEK OF DEATH: 108 TERMINAL BODY WEIGHT: 244.00 (GMS)

TISSUE / HISTOPATHOLOGIC FINDINGS  
MICROSCOPIC TISSUE OBSERVATIONS >>  
DISTRIBUTION (SEVERITY) / SPECIAL COMMENTS

UTERUS ..... NOT SPECIFIED (PRESENT)  
-ENDOMETRIAL STROMAL POLYP

SKIN .....  
-B- CLITORAL GLAND ADENOMA (PRESENT)

MAMMARY GLANDS ..... A MAMMARY FIBROADENOMA IS PRESENT IN SLIDE #21 IMMEDIATELY  
ADJACENT TO THE CLITORAL GLAND ADENOMA.  
-HYPERPLASIA AND/OR HYPERTROPHY OF THE ACINAR TISSUE NOT SPECIFIED (TRACE)  
-B- FIBROADENOMA (PRESENT)  
-DILATATION (ECTASIA) OF DUCTS AND DUCTULES NOT SPECIFIED (PRESENT)

ADRENAL ..... NOT SPECIFIED (TRACE)  
-FOCUS OF CELLULAR ALTERATION, VACUOLATED

PITUITARY GLAND ..... (PRESENT)  
-B- ADENOMA

EYES & OPTIC N. .... NOT SPECIFIED (TRACE)  
-RETINAL ATROPHY AND/OR DEGENERATION, UNILATERAL OR BILATERAL  
-METAPLASTIC BONE FORMATION AND/OR MINERALIZATION, SCLERA NOT SPECIFIED (PRESENT)

AD SEBACIOUS ..... TISSUE IS MISSING

Appendix J (cont.): PATHOLOGY INDIVIDUAL ANIMAL DATA

LETTERMAN ARMY INSTITUTE OF RESEARCH  
 DIV OF RES SUPP, PATH SERV GP  
 SPECIES: RAT/FISCHER-344  
 ANIMAL NUMBER: 394/PRETEST-  
 DATE OF DEATH: 02-AUG-85  
 STUDY START DATE: 23-JAN-84  
 STUDY NUMBER: GLP83009  
 STUDY TYPE: CHRONIC/2 YR CARCINOGENIC  
 PRINTED: 21-NOV-89  
 PAGE: 765

INDIVIDUAL ANIMAL DATA REPORT  
 STUDY NUMBER: GLP83009  
 STUDY START DATE: 23-JAN-84  
 DOSE GROUP: 3  
 SACRIFICE STATUS: FOUND DEAD  
 SEX: FEMALE  
 STUDY DAY OF DEATH: 558  
 STUDY WEEK OF DEATH: 80  
 TERMINAL BODY WEIGHT: 248.00 (GMS)

<< GROSS ORGAN OBSERVATIONS >>  
 SEVERITY GROSS FREE-TEXT COMMENTS  
 KEYWORDS / PHRASES  
 PERITONEAL CAV. FLUID-FILLED PRESENT 2.5ML, SEROSANGUINOUS  
 SPLEEN ENLARGED (SPLENOMEGALY) MARKED 7 X 2.2 X .5CM  
 LIVER PROMINENT LOBULAR MARKINGS PRESENT  
 LIVER GRANULAR SURFACE PRESENT  
 KIDNEY DISCOLORATION PRESENT  
 KIDNEY CYST PRESENT

DIFFUSELY BROWN, BILATERAL  
 2MM DIAMETER AT JUNCTION OF CORTEX AND RENAL PELVIS

<< MICROSCOPIC TISSUE OBSERVATIONS >>  
 DISTRIBUTION (SEVERITY) / SPECIAL COMMENTS

TISSUE / HISTOPATHOLOGIC FINDINGS

THYROID GLANDS  
 -B- PARA-FOLLICULAR CELL ADENOMA (PRESENT)  
 PARATHYROID TISSUE IS MISSING  
 ANIMAL HAS A LARGE THYROID ADENOMA. RECUTS OF SECTION FAILED TO DETECT PARATHYROID GLANDS.

LUNGS  
 -N- LARGE GRANULAR LYMPHOCYTE LEUKEMIA, METASTATIC (PRESENT)

THYMUS  
 -N- LARGE GRANULAR LYMPHOCYTE LEUKEMIA, METASTATIC (PRESENT)

SPLEEN  
 -N- LARGE GRANULAR LYMPHOCYTE LEUKEMIA, METASTATIC (PRESENT)

LYMPH NODES  
 -N- LARGE GRANULAR LYMPHOCYTE LEUKEMIA, METASTATIC (PRESENT)

LIVER  
 -B- BILE DUCTULE EPITHELIAL HYPERPLASIA AND/OR CHOLANGIOFIBROSIS NOT SPECIFIED(MILD)

Appendix J (cont.): PATHOLOGY INDIVIDUAL ANIMAL DATA

LETTERMAN ARMY INSTITUTE OF RESEARCH  
 DIV OF RES SUPP, PATH SERV GP  
 SPECIES: RAT/FISCHER-344  
 STUDY START DATE: 23-JAN-84  
 STUDY NUMBER: GLP83009  
 PRINTED: 21-NOV-89  
 PAGE: 766  
 STUDY TYPE: CHRONIC/2 YR CARCINOGENIC

ANIMAL NUMBER: 394/PRETEST#  
 DATE OF DEATH: 02-AUG-85  
 SEX: FEMALE  
 DOSE GROUP: 3  
 SACRIFICE STATUS: FOUND DEAD  
 STUDY DAY OF DEATH: 558  
 STUDY WEEK OF DEATH: 80  
 TERMINAL BODY WEIGHT: 248.00 (GMS)

<< MICROSCOPIC TISSUE OBSERVATIONS >>  
 DISTRIBUTION (SEVERITY) / SPECIAL COMMENTS

- LIVER .....  
 -NECROSIS, PERIACINAR .....  
 -M- LARGE GRANULAR LYMPHOCYTE LEUKEMIA, METASTATIC ..... MULTI-FOCAL(TRACE)  
 (PRESENT)
- KIDNEY .....  
 -PROGRESSIVE RENAL DISEASE ..... NOT SPECIFIED(TRACE)  
 -CYST(S) CORTICAL ..... FOCAL (PRESENT)
- OVARIES .....  
 -FOLLICULAR CYST(S) ..... NOT SPECIFIED (PRESENT)  
 -CYSTIC CORPORA LUTEA ..... NOT SPECIFIED (PRESENT)
- MAMMARY GLANDS .....  
 -HYPERPLASIA AND/OR HYPERTROPHY OF THE ACINAR TISSUE ..... NOT SPECIFIED(TRACE)  
 -DILATATION (ECTASIA) OF DUCTS AND DUCTULES ..... NOT SPECIFIED (PRESENT)
- NOSE/TURBINATES .....  
 -MIXED INFLAMMATORY CELL INFILTRATION, NASAL CAVITY, SINUSES, ..... INFILTRATE: BILATERAL ADJACENT NASO-LACRIMAL DUCTS.  
 TURBINATES, NASO-LACRIMAL DUCTS ..... NOT SPECIFIED(TRACE)
- PITUITARY GLAND .....  
 -B- ADENOMA ..... (PRESENT)
- WHOLE BODY .....  
 -M- LARGE GRANULAR LYMPHOCYTIC LEUKEMIA ..... (PRESENT)

**Appendix J (cont.): PATHOLOGY INDIVIDUAL ANIMAL DATA**

LETTERMAN ARMY INSTITUTE OF RESEARCH  
 DIV OF RES SUPP, PATH SERV GP  
 SPECIES: RAT/FISCHER-344  
 STUDY START DATE: 23-JAN-84  
 STUDY NUMBER: GLP83009  
 PRINTED: 21-NOV-89  
 PAGE: 767  
 STUDY TYPE: CHRONIC/2 YR CARCINOGENIC

ANIMAL NUMBER: 395/PRETEST= 395 SEX: FEMALE DOSE GROUP: 3 SACRIFICE STATUS: SACRIFICED MORIBUND  
 DATE OF DEATH: 13-SEP-85 STUDY DAY OF DEATH: 600 STUDY WEEK OF DEATH: 86 TERMINAL BODY WEIGHT: 205.00 (GMS)

<< GROSS ORGAN OBSERVATIONS >>  
 SEVERITY GROSS FREE-TEXT COMMENTS  
 KEYWORDS / PHRASES  
 NO GROSS LESIONS RECOGNIZED PRESENT

<< MICROSCOPIC TISSUE OBSERVATIONS >>  
 DISTRIBUTION (SEVERITY) / SPECIAL COMMENTS

TRACHEA  
 -NON-SUPPURATIVE TRACHEITIS FOCAL(TRACE)

EXORBITAL LACRIM TISSUE IS MISSING

LUNGS  
 -PNEUMONIA, GRANULOMATOUS MULTI-FOCAL(MILD)

PANCREAS  
 -CHRONIC INFLAMMATION MULTI-FOCAL(TRACE)

MAMMARY GLANDS  
 -HYPERPLASIA AND/OR HYPERTROPHY OF THE ACINAR TISSUE NOT SPECIFIED(TRACE)  
 -DILATATION (ECTASIA) OF DUCTS AND DUCTULES NOT SPECIFIED (PRESENT)

NOSE/TURBINATES  
 -MIXED INFLAMMATORY CELL INFILTRATION, NASAL CAVITY, SINUSES, INFILTRATE: INILATERAL ADJACENT NASO-LACRIMAL DUCT.  
 TURBINATES, NASO-LACRIMAL DUCTS FOCAL(TRACE)

EAR  
 -OTITIS MEDIA, SUPPURATIVE OR NON-SUPPURATIVE NOT SPECIFIED(MODERATE)

## Appendix J (cont.): PATHOLOGY INDIVIDUAL ANIMAL DATA

LETTERMAN ARMY INSTITUTE OF RESEARCH  
 DIV OF RES SUPP, PATH SERV GP  
 SPECIES: RAT/FISCHER-344  
 ANIMAL NUMBER: 396/PRETEST= 396 SEX: FEMALE DOSE GROUP: 3 SACRIFICE STATUS: SACRIFICED MORIBUND  
 DATE OF DEATH: 15-NOV-85 STUDY DAY OF DEATH: 663 STUDY WEEK OF DEATH: 95 TERMINAL BODY WEIGHT: 218.00 (GMS)  
 PRINTED: 21-NOV-89  
 PAGE: 768  
 STUDY NUMBER: GLP83009  
 STUDY START DATE: 23-JAN-84  
 STUDY TYPE: CHRONIC/2 YR CARCINOGENIC

<< GROSS ORGAN OBSERVATIONS >>  
 SEVERITY GROSS FREE-TEXT COMMENTS

ORGAN NAME	KEYWORDS / PHRASES	OBSERVATIONS	DISTRIBUTION (SEVERITY) / SPECIAL COMMENTS
LIVER	GRANULAR SURFACE	PRESENT	
LIVER	PROMINENT LOBULAR MARKINGS	PRESENT	
SPLEEN	ENLARGED (SPLENOHEGALY)	PRESENT	6 X 2 X 2CM
KIDNEY	DISCOLORATION	PRESENT	YELLOW
SKIN	DISCOLORATION	PRESENT	YELLOW, SUBCUTANEOUS
PITUITARY GLAND	DISCOLORATION	PRESENT	FOCAL, .3CM DIAMETER, RED/BLACK
PITUITARY GLAND	ENLARGED	MILD	

<< MICROSCOPIC TISSUE OBSERVATIONS >>  
 TISSUE / HISTOPATHOLOGIC FINDINGS

THYROID GLANDS  
 -PARA-FOLLICULAR CELL HYPERPLASIA ("C" CELL, LIGHT CELL) FOCAL (TRACE)

LUNGS  
 -N- LARGE GRANULAR LYMPHOCYTE LEUKEMIA, METASTATIC (PRESENT)

SPLEEN  
 -FIBROSIS CAPSULAR FOCAL (TRACE)  
 -N- LARGE GRANULAR LYMPHOCYTE LEUKEMIA, METASTATIC (PRESENT)

LYMPH NODES  
 -N- LARGE GRANULAR LYMPHOCYTE LEUKEMIA, METASTATIC (PRESENT)

LIVER  
 -CYSTIC DEGENERATION NOT SPECIFIED (PRESENT)  
 -HEPATOCTYIC DEGENERATIVE CHANGES (NON-NECROTIC) NOT SPECIFIED (TRACE)  
 -N- LARGE GRANULAR LYMPHOCYTE LEUKEMIA, METASTATIC (PRESENT)

KIDNEY  
 -PROGRESSIVE RENAL DISEASE NOT SPECIFIED (TRACE)

Appendix J (cont.): PATHOLOGY INDIVIDUAL ANIMAL DATA

LETTERMAN ARMY INSTITUTE OF RESEARCH  
 DIV OF RES SUPP, PATH SERV GP  
 SPECIES: RAT/FISCHER-344

INDIVIDUAL ANIMAL DATA REPORT  
 STUDY NUMBER: GLP83009

STUDY START DATE: 23-JAN-84

PRINTED: 21-NOV-89  
 PAGE: 769

ANIMAL NUMBER: 396/PRETEST-  
 DATE OF DEATH: 15-NOV-85

SEX: FEMALE  
 DOSE GROUP: 3  
 SACRIFICE STATUS: SACRIFICED MORIBUND

STUDY DAY OF DEATH: 663  
 STUDY WEEK OF DEATH: 95  
 TERMINAL BODY WEIGHT: 218.00 (GMS)

STUDY TYPE: CHRONIC/2 YR CARCINOGENIC

TISSUE / HISTOPATHOLOGIC FINDINGS  
 << M I C R O S C O P I C T I S S U E O B S E R V A T I O N S >>  
 DISTRIBUTION (SEVERITY) / SPECIAL COMMENTS

URINARY BLADDER ..... TISSUE IS MISSING

UTERUS ..... NOT SPECIFIED (PRESENT)

-ENDOMETRIAL STROMAL POLYP

PANCREAS ..... THE MULTIFOCAL PERITONITIS IS CHRONIC AND IS SITUATED IN THE  
 OMENTAL FAT ADJACENT TO THE PANCREAS. SEVERAL HAIR SHAFTS ARE  
 PRESENT IN AREAS OF CHRONIC INFLAMMATION. THESE MAY HAVE BEEN  
 INTRODUCED TO THIS LOCATION DURING THE SURGERY.  
 MULTI-FOCAL(TRACE)

-CHRONIC INFLAMMATION

MAMMARY GLANDS ..... NOT SPECIFIED (MILD)

-HYPERPLASIA AND/OR HYPERTROPHY OF THE ACINAR TISSUE  
 -DILATATION (ECTASIA) OF DUCTS AND DUCTULES  
 NOT SPECIFIED (PRESENT)

ADRENAL ..... NOT SPECIFIED(TRACE)

-FOCUS OF CELLULAR ALTERATION, VACUOLATED

PITUITARY GLAND ..... (PRESENT)

-B- ADEMOMA

EYES & OPTIC N. .... NOT SPECIFIED (PRESENT)

-METAPLASTIC BONE FORMATION AND/OR MINERALIZATION, SCLERA

WHOLE BODY ..... (PRESENT)

-M- LARGE GRANULAR LYMPHOCYTTIC LEUKEMIA

Appendix J (cont.): PATHOLOGY INDIVIDUAL ANIMAL DATA

LETTERMAN ARMY INSTITUTE OF RESEARCH  
 DIV OF RES SUPP, PATH SERV GP  
 SPECIES: RAT/FISCHER-344  
 STUDY START DATE: 23-JAN-84  
 STUDY TYPE: CHRONIC/2 YR CARCINOGENIC  
 PRINTED: 21-NOV-89  
 PAGE: 770

INDIVIDUAL ANIMAL DATA REPORT  
 STUDY NUMBER: GLP83009  
 ANIMAL NUMBER: 397/PRETEST-397 SEX: FEMALE DOSE GROUP: 3 SACRIFICE STATUS: FINAL SACRIFICE  
 DATE OF DEATH: 14-FEB-86 STUDY DAY OF DEATH: 754 STUDY WEEK OF DEATH: 108 TERMINAL BODY WEIGHT: 248.00 (GMS)

<< GROSS ORGAN OBSERVATIONS >>  
 SEVERITY GROSS FREE-TEXT COMMENTS  
 ORGANS / PHRASES  
 LIVER DISCOLORATION PRESENT MULTIFOCAL, RED, .3-.6CM DIAMETER  
 KIDNEY DISCOLORATION PRESENT PALE  
 PITUITARY GLAND ENLARGED PRESENT .6CM DIAMETER.  
 KIDNEY GRANULAR SURFACE PRESENT BILATERAL

<< MICROSCOPIC TISSUE OBSERVATIONS >>  
 DISTRIBUTION (SEVERITY) / SPECIAL COMMENTS

THYROID GLANDS  
 -PARA-FOLLICULAR CELL HYPERPLASIA ("C" CELL, LIGHT CELL) FOCAL(TRACE)

EXORBITAL LACRIM  
 -ACINAR ATROPHY FOCAL(TRACE)

LUNGS  
 -MINERALIZATION OF PULMONARY ARTERIES THE MINIMAL ALVEOLAR HEMORRHAGE IS PROBABLY DUE TO AGONAL  
 -ALVEOLAR HEMORRHAGE ASPIRATION OF BLOOD.  
 FOCAL(TRACE)  
 FOCAL (PRESENT)

LIVER  
 -HEPATITIS MULTI-FOCAL(TRACE)  
 -NECROSIS MULTI-FOCAL(MILD)  
 -HEPATOCTYTE COALESCING MICROVESICULAR (FATTY) CHANGE LEADING TO MULTI-FOCAL(MILD)  
 NECROSIS AND MINERALIZATION

KIDNEY  
 -PROGRESSIVE RENAL DISEASE NOT SPECIFIED(MODERATE)

OVARIES  
 -PARA-OVARIAN CYST(S) NOT SPECIFIED (PRESENT)

MAMMARY GLANDS

Appendix J (cont.): PATHOLOGY INDIVIDUAL ANIMAL DATA

LETTERMAN ARMY INSTITUTE OF RESEARCH  
DIV OF RES SUPP, PATH SERV GP  
SPECIES: RAT/FISCHER-344

INDIVIDUAL ANIMAL DATA REPORT  
STUDY NUMBER: GLP83009

PRINTED: 21-NOV-89  
PAGE: 771

STUDY START DATE: 23-JAN-84

STUDY TYPE: CHRONIC/2 YR CARCINOGENIC

ANIMAL NUMBER: 397/PRETEST#

397 SEX: FEMALE

DOSE GROUP: 3

SACRIFICE STATUS: FINAL SACRIFICE

DATE OF DEATH: 14-FEB-86

STUDY DAY OF DEATH: 754

STUDY WEEK OF DEATH: 108

TERMINAL BODY WEIGHT: 248.00 (GMS)

TISSUE / HISTOPATHOLOGIC FINDINGS

<< M I C R O S C O P I C T I S S U E O B S E R V A T I O N S >>  
DISTRIBUTION (SEVERITY) / SPECIAL COMMENTS

MAMMARY GLANDS

-HYPERPLASIA AND/OR HYPERTROPHY OF THE ACINAR TISSUE  
-DILATATION (ECTASIA) OF DUCTS AND DUCTULES

NOT SPECIFIED(MODERATE)  
NOT SPECIFIED (PRESENT)

ADRENAL

-FOCUS OF CELLULAR ALTERATION, VACUOLATED  
-B- PNECROCYTOMA

NOT SPECIFIED(TRACE)  
(PRESENT)

PITUITARY GLAND

-B- ADENOMA

(PRESENT)

EYES & OPTIC N.

-CORNEAL VASCULARIZATION

NOT SPECIFIED(TRACE)



**Appendix J (cont.): PATHOLOGY INDIVIDUAL ANIMAL DATA**

LETTERMAN ARMY INSTITUTE OF RESEARCH  
 DIV OF RES SUPP, PATH SERV GP  
 SPECIES: RAT/FISCHER-344

PRINTED: 21-NOV-89  
 PAGE: 772

INDIVIDUAL ANIMAL DATA REPORT

STUDY NUMBER: GLP83009

STUDY START DATE: 23-JAN-84

STUDY TYPE: CHRONIC/2 YR CARCINOGENIC

ANIMAL NUMBER: 398/PRETEST= 398 SEX: FEMALE DOSE GROUP: 3 SACRIFICE STATUS: FINAL SACRIFICE  
 DATE OF DEATH: 14-FEB-86 STUDY DAY OF DEATH: 754 STUDY WEEK OF DEATH: 108 TERMINAL BODY WEIGHT: 284.00 (GMS)

ORGAN NAME << GROSS ORGAN OBSERVATIONS >>  
 KEYWORDS / PHRASES SEVERITY GROSS FREE-TEXT COMMENTS  
 OVARIES PARA-OVARIAN CYST(S) PRESENT LEFT, 1.5CM DIAMETER.

TISSUE / HISTOPATHOLOGIC FINDINGS << MICROSCOPIC TISSUE OBSERVATIONS >>  
 DISTRIBUTION (SEVERITY) / SPECIAL COMMENTS

THYROID GLANDS  
 -PARA-FOLLICULAR CELL HYPERPLASIA ("C" CELL, LIGHT CELL) NOT SPECIFIED(TRACE)

SALIVARY GLAND  
 -ATROPHY AND LOSS OF ACINAR TISSUE FOCAL(TRACE)

EXORBITAL LACRIM  
 -ACINAR ATROPHY MULTI-FOCAL(MILD)

HEART  
 -CARDIOMYOPATHY NOT SPECIFIED(TRACE)

SPLEEN  
 -INFARCTION, CHRONIC FOCAL(TRACE)

LIVER  
 -FOCUS OF CELLULAR ALTERATION - BASOPHILIC NOT SPECIFIED(TRACE)  
 -HEPATOCYTE COALESCING MICROVESICULAR (FATTY) CHANGE LEADING TO MULTI-FOCAL(MILD)  
 NECROSIS AND MINERALIZATION

KIDNEY  
 -PROGRESSIVE RENAL DISEASE NOT SPECIFIED(MODERATE)

UTERUS  
 -CYSTIC DILATATION OF THE ENDOMETRIAL GLANDS NOT SPECIFIED (PRESENT)

OVARIES

**Appendix J (cont.): PATHOLOGY INDIVIDUAL ANIMAL DATA**

LETTERMAN ARMY INSTITUTE OF RESEARCH  
 DIV OF RES SUPP, PATH SERV GP  
 SPECIES: RAT/FISCHER-344  
 ANIMAL NUMBER: 398/PRETEST= 398 SEX: FEMALE DOSE GROUP: 3 SACRIFICE STATUS: FINAL SACRIFICE  
 DATE OF DEATH: 14-FEB-86 STUDY DAY OF DEATH: 754 STUDY WEEK OF DEATH: 108 TERMINAL BODY WEIGHT: 286.00 (GMS)  
 TISSUE / HISTOPATHOLOGIC FINDINGS << MICROSCOPIC TISSUE OBSERVATIONS >>  
 .....  
 OVARIES ..... NOT SPECIFIED (PRESENT)  
 -PARA-OVARIAN CYST(S) .....  
 PANCREAS ..... FOCAL (TRACE)  
 -ACINAR (EXOCRINE) ATROPHY .....  
 MAMMARY GLANDS ..... NOT SPECIFIED (MODERATE)  
 -HYPERPLASIA AND/OR HYPERTROPHY OF THE ACINAR TISSUE .....  
 ADRENAL ..... NOT SPECIFIED (TRACE)  
 -FOCUS OF CELLULAR ALTERATION, VACUOLATED .....  
 -CORTICAL NODULAR HYPERPLASIA ..... NOT SPECIFIED (PRESENT)  
 PITUITARY GLAND ..... (PRESENT)  
 -B- ADENOMA .....  
 EYES & OPTIC N. ....  
 -CORNEAL MINERALIZATION ..... FOCAL (TRACE)  
 -LENTICULAR DEGENERATIVE CHANGES COMPATIBLE WITH CATARACT ..... NOT SPECIFIED (PRESENT)

PRINTED: 21-NOV-89  
 PAGE: 773

STUDY START DATE: 23-JAN-84  
 STUDY TYPE: CHRONIC/2 YR CARCINOGENIC

**Appendix J (cont.): PATHOLOGY INDIVIDUAL ANIMAL DATA**

LETTERMAN ARMY INSTITUTE OF RESEARCH  
 DIV OF RES SUPP, PATH SERV GP  
 SPECIES: RAY/FLSCHER-344

INDIVIDUAL ANIMAL DATA REPORT  
 STUDY NUMBER: GLP83009  
 STUDY START DATE: 23-JAN-84

PRINTED: 21-NOV-89  
 PAGE: 774  
 STUDY TYPE: CHRONIC/2 YR CARCINOGENIC

ANIMAL NUMBER: 399/PRETEST# 399 SEX: FEMALE DOSE GROUP: 3 SACRIFICE STATUS: SACRIFICED MORIBUND  
 DATE OF DEATH: 17-JAN-86 STUDY DAY OF DEATH: 726 STUDY WEEK OF DEATH: 104 TERMINAL BODY WEIGHT: 259.00 (GMS)

<< G R O S S O R G A N O B S E R V A T I O N S >>  
 SEVERITY GROSS FREE-TEXT COMMENTS  
 ENLARGED (SPLENOMEGALY) MARKED 7 X 2.5 X 1.5CM, LOBULAR MARGINS  
 ENLARGED ENLARGED PRESENT  
 ENLARGED ENLARGED PRESENT .5CM DIAMETER, DARK RED

<< M I C R O S C O P I C T I S S U E O B S E R V A T I O N S >>  
 DISTRIBUTION (SEVERITY) / SPECIAL COMMENTS

- THYROID GLANDS ..... NOT SPECIFIED(TRACE)
- PARA-FOLLICULAR CELL HYPERPLASIA ("C" CELL, LIGHT CELL)
- LACRIMAL GLAND ..... NOT SPECIFIED(MILD)
- INFLAMMATION, SUBACUTE TO CHRONIC
- HEART ..... MULTI-FOCAL(MILD)
- MEDIAL HYPERTROPHY OF MUSCULAR ARTERIES
- LUNGS ..... (PRESENT)
- M- LARGE GRANULAR LYMPHOCYTE LEUKEMIA, METASTATIC
- SPLEEN ..... NOT SPECIFIED(TRACE)
- INFARCTION, CHRONIC
- M- LARGE GRANULAR LYMPHOCYTE LEUKEMIA, METASTATIC
- LYMPH NODES ..... (PRESENT)
- M- LARGE GRANULAR LYMPHOCYTE LEUKEMIA, METASTATIC
- LIVER ..... FOCAL(MILD)
- NECROSIS ..... DIFFUSE(MILD)
- HEPATOCTYIC DEGENERATIVE CHANGES (NON-NECROTIC)
- M- LARGE GRANULAR LYMPHOCYTE LEUKEMIA, METASTATIC
- KIDNEY .....

Appendix J (cont.): PATHOLOGY INDIVIDUAL ANIMAL DATA

LETTERMAN ARMY INSTITUTE OF RESEARCH  
DIV OF RES SUPP, PATH SERV GP  
SPECIES: RAT/FISCHER-344

INDIVIDUAL ANIMAL DATA REPORT  
STUDY NUMBER: GLP83009

PRINTED: 21-NOV-89  
PAGE: 775

STUDY START DATE: 23-JAN-84

STUDY TYPE: CHRONIC/2 YR CARCINOGENIC

ANIMAL NUMBER: 399/PRETEST#

399 SEX: FEMALE

DOSE GROUP: 3

SACRIFICE STATUS: SACRIFICED MORIBUND

DATE OF DEATH: 17-JAN-86

STUDY DAY OF DEATH: 726

STUDY WEEK OF DEATH: 104

TERMINAL BODY WEIGHT: 259.00 (GMS)

<< MICROSCOPIC TISSUE OBSERVATIONS >>  
DISTRIBUTION (SEVERITY) / SPECIAL COMMENTS

KIDNEY ..... NOT SPECIFIED(MILD)  
-PROGRESSIVE RENAL DISEASE

MAMMARY GLANDS .....  
-HYPERPLASIA AND/OR HYPERTROPHY OF THE ACINAR TISSUE ..... NOT SPECIFIED(MILD)  
-DILATATION (ECTASIA) OF DUCTS AND DUCTULES ..... NOT SPECIFIED (PRESENT)

ADRENAL ..... NOT SPECIFIED(MILD)  
-FOCUS OF CELLULAR ALTERATION, VACUOLATED

PITUITARY GLAND ..... (PRESENT)  
-B- ADENOMA

EYES & OPTIC N. .... NOT SPECIFIED(TRACE)  
-RETINAL ATROPHY AND/OR DEGENERATION, UNILATERAL OR BILATERAL

WHOLE BODY ..... (PRESENT)  
-M- LARGE GRANULAR LYMPHOCYTTIC LEUKEMIA

**Appendix J (cont.): PATHOLOGY INDIVIDUAL ANIMAL DATA**

LETTERMAN ARMY INSTITUTE OF RESEARCH  
 DIV OF RES SUPP, PATH SERV GP  
 SPECIES: RAT/FISCHER-344

INDIVIDUAL ANIMAL DATA REPORT  
 STUDY NUMBER: GLP83009  
 STUDY START DATE: 23-JAN-84

PRINTED: 21-NOV-89  
 PAGE: 776  
 STUDY TYPE: CHRON.C/2 YR CARCINOGENIC

ANIMAL NUMBER: 400/PRETEST= 400 SEX: FEMALE DOSE GROUP: 3 SACRIFICE STATUS: SACRIFICED MORIBUND  
 DATE OF DEATH: 10-FEB-86 STUDY DAY OF DEATH: 750 STUDY WEEK OF DEATH: 108 TERMINAL BODY WEIGHT: 209.00 (GMS)

<< GROSS ORGAN OBSERVATIONS >>  
 SEVERITY GROSS FREE-TEXT COMMENTS

LIVER	PROMINENT LOBULAR MARKINGS	PRESENT
PITUITARY GLAND	ENLARGED	PRESENT
LIVER	MODULE(S)	PRESENT
	DARK RED, .9 X .6CM	
	MULTIPLE, RAISED, LESS THAN 1CM	

<< MICROSCOPIC TISSUE OBSERVATIONS >>  
 DISTRIBUTION (SEVERITY) / SPECIAL COMMENTS

TISSUE / HISTOPATHOLOGIC FINDINGS

LACRIMAL GLAND ..... MULTI-FOCAL(TRACE)  
 -INFLAMMATION, SUBACUTE TO CHRONIC

HEART ..... NOT SPECIFIED(TRACE)  
 -CARDIOMYOPATHY

LIVER ..... MULTI-FOCAL(MILD)  
 -HEPATITIS ..... FOCAL(TRACE)  
 -FOCUS OF CELLULAR ALTERATION - BASOPHILIC ..... FOCAL(TRACE)  
 -BENIGN HYPERPLASTIC MODULE(S)

KIDNEY ..... NOT SPECIFIED(MILD)  
 -PROGRESSIVE RENAL DISEASE

UTERUS ..... NOT SPECIFIED (PRESENT)  
 -CYSTIC DILATATION OF THE ENDOMETRIAL GLANDS

NOSE/TURBINATES ..... INFILTRATE BILATERAL ADJACENT NASO-LACRIMAL DUCTS.  
 -MIXED INFLAMMATORY CELL INFILTRATION, NASAL CAVITY, SINUSES, ..... NOT SPECIFIED(MILD)  
 TURBINATES, NASO-LACRIMAL DUCTS

ADRENAL ..... ONE ADRENAL GLAND IS MISSING  
 -FOCUS OF CELLULAR ALTERATION, VACUOLATED ..... NOT SPECIFIED(TRACE)

PITUITARY GLAND ..... (PRESENT)  
 -B- ADENOMA

Appendix J (cont.): PATHOLOGY INDIVIDUAL ANIMAL DATA

LETTERMAN ARMY INSTITUTE OF RESEARCH  
DIV OF RES SUPP, PATH SERV GP  
SPECIES: RAT/FISCHER-344

INDIVIDUAL ANIMAL DATA REPORT  
STUDY NUMBER: GLP83009

PRINTED: 21-NOV-89  
PAGE: 777

STUDY START DATE: 23-JAN-84

STUDY TYPE: CHRONIC/2 YR CARCINOGENIC

ANIMAL NUMBER: 401/PRETEST= 401 SEX: FEMALE DOSE GROUP: 3 SACRIFICE STATUS: FOUND DEAD  
DATE OF DEATH: 23-SEP-85 STUDY DAY OF DEATH: 610 STUDY WEEK OF DEATH: 88 TERMINAL BODY WEIGHT: 238.00 (GMS)

ORGAN NAME << GROSS ORGAN OBSERVATIONS >>  
KEYWORDS / PHRASES SEVERITY GROSS FREE-TEXT COMMENTS

MAMMARY GLAND DISCOLORATION PRESENT BLACK PIGMENTED, LOWER LEFT ABDOMINAL REGION.  
LUNGS CONGESTED / RED PRESENT  
UTERUS BLACK DISCOLORATION PRESENT ENTIRE UTERUS AND HORNS  
PITUITARY GLAND ENLARGED PRESENT RED/BLACK  
WHOLE BODY POST MORTEM AUTOLYSIS. MODERATE

TISSUE / HISTOPATHOLOGIC FINDINGS << MICROSCOPIC TISSUE OBSERVATIONS >>  
DISTRIBUTION (SEVERITY) / SPECIAL COMMENTS

BRAIN ..... LIQUIFACTION NECROSIS ..... FOCAL(MODERATE)

LUNGS ..... SECTIONS OF LUNG WERE STAINED WITH PERIODIC ACID-SCHIFF, ACID FAST AND GOMORI'S METHENAMINE SILVER PROCEDURES. EXAMINATION OF THESE SPECIAL STAINS FAILED TO REVEAL THE CAUSE OF THE GRANULOMATOUS PNEUMONIA. DIFFUSE (PRESENT) MULTI-FOCAL(MILD)

SPLEEN ..... NOT SPECIFIED (PRESENT)

LIVER ..... NOT SPECIFIED(TRACE)  
-BILE DUCTULE EPITHELIAL HYPERPLASIA AND/OR CHOLANGIOFIBROSIS  
-BENIGN HYPERPLASTIC NODULE(S) MULTI-FOCAL(TRACE)

KIDNEY ..... NOT SPECIFIED(TRACE)  
-PROGRESSIVE RENAL DISEASE

**Appendix J (cont.): PATHOLOGY INDIVIDUAL ANIMAL DATA**

LETTERMAN ARMY INSTITUTE OF RESEARCH  
 DIV OF RES SUPP, PATH SERV GP  
 SPECIES: RAY/FISCHER-344

INDIVIDUAL ANIMAL DATA REPORT  
 STUDY NUMBER: GLP83009

PRINTED: 21-NOV-89  
 PAGE: 778

STUDY START DATE: 23-JAN-84

STUDY TYPE: CHRONIC/2 YR CARCINOGENIC

ANIMAL NUMBER: 401/PRETEST-401 SEX: FEMALE DOSE GROUP: 3 SACRIFICE STATUS: FOUND DEAD  
 DATE OF DEATH: 23-SEP-85 STUDY DAY OF DEATH: 610 STUDY WEEK OF DEATH: 88 TERMINAL BODY WEIGHT: 238.00 (GMS)

TISSUE / HISTOPATHOLOGIC FINDINGS << MICROSCOPIC TISSUE OBSERVATIONS >>  
 DISTRIBUTION (SEVERITY) / SPECIAL COMMENTS

UTERUS ..... THE BLACK DISCOLORATION NOTED GROSSLY IS PROBABLY DUE TO POST-MORTEM HYPOSTATIC CONGESTION AND EARLY AUTOLYTIC CHANGE. THERE ARE NO OTHER FINDINGS IN THE THREE SECTIONS OF UTERUS EXAMINED MICROSCOPICALLY.

JEJUNUM ..... TISSUE IS AUTOLYTIC

ILEUM ..... TISSUE IS AUTOLYTIC

CECUM ..... TISSUE IS AUTOLYTIC

MAMMARY GLANDS ..... DISCOLORATION OF THE MAMMARY TISSUE NOTED GROSSLY IS PROBABLY DUE TO POST-MORTEM HYPOSTATIC CONGESTION AND EARLY AUTOLYTIC CHANGE. MODERATE HYPERPLASIA OF MAMMARY TISSUE IS ALSO PRESENT. -HYPERPLASIA AND/OR HYPERTROPHY OF THE ACINAR TISSUE -DILATATION (ECTASIA) OF DUCTS AND DUCTULES

NOSE/TURBINATES ..... INFILTRATE: SUPPURATIVE, BILATERAL ADJACENT NASO-LACRIMAL DUCTS  
 -MIXED INFLAMMATORY CELL INFILTRATION, NASAL CAVITY, SINUSES, NOT SPECIFIED(MODERATE)  
 TURBINATES, NASO-LACRIMAL DUCTS

ADRENAL ..... ONLY ONE ADRENAL GLAND IS AVAILABLE FOR EXAMINATION.

PITUITARY GLAND ..... (PRESENT)  
 -B- ADENOMA NOT SPECIFIED (PRESENT)  
 -HEMORRHAGE

EYES & OPTIC N. .... TISSUE IS AUTOLYTIC

WHOLE BODY ..... AUTOLYTIC CHANGE VARYING FROM MILD TO SEVERE IS PRESENT IN MOST TISSUES. THIS PRECLUDED EVALUATION OF SEVERAL TISSUES FROM THE GASTRO-INTESTINAL TRACT AND THE EYES. WHERE AUTOLYSIS WAS SEVERE ENOUGH TO INTERFERE WITH HISTOLOGIC EVALUATION, TISSUES WERE CODED AS AUTOLYTIC AND NO OTHER FINDINGS WERE RECORDED.

Appendix J (cont.): PATHOLOGY INDIVIDUAL ANIMAL DATA

LETTERMAN ARMY INSTITUTE OF RESEARCH DIV OF RES SUPP, PATH SERV 6P SPECIES: RAT/FISCHER-344

INDIVIDUAL ANIMAL DATA REPORT STUDY NUMBER: GLP83009 STUDY START DATE: 23-JAN-84

PRINTED: 21-NOV-89 PAGE: 779 STUDY TYPE: CHRONIC/2 YR CARCINOGENIC

ANIMAL NUMBER: 402/PRETEST= 402 SEX: FEMALE DOSE GROUP: 3 SACRIFICE STATUS: FINAL SACRIFICE DATE OF DEATH: 14-FEB-86 STUDY DAY OF DEATH: 754 STUDY WEEK OF DEATH: 108 TERMINAL BODY WEIGHT: 247.00 (GMS)

ORGAN NAME KEYWORDS / PHRASES SEVERITY GROSS FREE-TEXT COMMENTS PITUITARY GLAND DISCOLORATION PRESENT FOCAL, RED, .1CM DIAMETER OVARIES PARA-OVARIAN CYST(S) PRESENT LEFT, 1.5CM DIAMETER UTERUS POLYP PRESENT RIGHT HORN, DISTAL, 1CM LONG

ORGAN NAME OBSERVATIONS OBSERVATIONS OBSERVATIONS OBSERVATIONS OBSERVATIONS OBSERVATIONS OBSERVATIONS OBSERVATIONS OBSERVATIONS OBSERVATIONS

TISSUE / HISTOPATHOLOGIC FINDINGS OBSERVATIONS OBSERVATIONS OBSERVATIONS OBSERVATIONS OBSERVATIONS OBSERVATIONS OBSERVATIONS OBSERVATIONS OBSERVATIONS

EXORBITAL LACRIM ACINAR ATROPHY MULTI-FOCAL(TRACE)

HEART CARDIOMYOPATHY NOT SPECIFIED(TRACE)

LUNGS MINERALIZATION OF PULMONARY ARTERIES NOT SPECIFIED(TRACE)

LYMPH NODES RED BLOOD CELLS, HEMOSIDERIN AND/OR ERYTHROPHAGOCYTOSIS WITHIN MEDULLARY SINUSES RBC'S AND HEMOSIDERIN PRESENT ONLY IN A CERVICAL NODE. NOT SPECIFIED (PRESENT)

LIVER FOCUS OF CELLULAR ALTERATION - BASOPHILIC HEPATOCYTE COALESCING MICROVESICULAR (FATTY) CHANGE LEADING TO NECROSIS AND MINERALIZATION MULTI-FOCAL(MARKED) MULTI-FOCAL(TRACE)

KIDNEY PROGRESSIVE RENAL DISEASE NOT SPECIFIED(MILD)

UTERUS ENDOMETRIAL STROMAL POLYP NOT SPECIFIED (PRESENT)

OVARIES NOT SPECIFIED (PRESENT)



**Appendix J (cont.): PATHOLOGY INDIVIDUAL ANIMAL DATA**

LETTERMAN ARMY INSTITUTE OF RESEARCH  
 DIV OF RES SUPP, PATH SERV GP  
 SPECIES: RAT/FISCHER-344  
 INDIVIDUAL ANIMAL DATA REPORT  
 STUDY NUMBER: GLP83009  
 STUDY START DATE: 23-JAN-84  
 PRINTED: 21-NOV-89  
 PAGE: 780  
 STUDY TYPE: CHRONIC/2 YR CARCINOGENIC

ANIMAL NUMBER: 402/PRETEST= 402 SEX: FEMALE DOSE GROUP: 3 SACRIFICE STATUS: FINAL SACRIFICE  
 DATE OF DEATH: 14-FEB-86 STUDY DAY OF DEATH: 754 STUDY WEEK OF DEATH: 108 TERMINAL BODY WEIGHT: 247.00 (GMS)

←← MICROSCOPIC TISSUE OBSERVATIONS →→  
 TISSUE / HISTOPATHOLOGIC FINDINGS  
 DISTRIBUTION (SEVERITY) / SPECIAL COMMENTS

- OVARIES ..... NOT SPECIFIED (PRESENT)
- PARA-OVARIAN CYST(S) .....
- MAMMARY GLANDS .....
- HYPERPLASIA AND/OR HYPERTROPHY OF THE ACINAR TISSUE .....
- DILATATION (ECTASIA) OF DUCTS AND DUCTULES .....
- NOSE/TURBINATES .....
- MIXED INFLAMMATORY CELL INFILTRATION, NASAL CAVITY, SINUSES, .....
- TURBINATES, NASO-LACRIMAL DUCTS .....
- ADRENAL .....
- FOCUS OF CELLULAR ALTERATION, VACUOLATED .....
- PITUITARY GLAND .....
- B- ADENOMA ..... (PRESENT)
- EYES & OPTIC N. ....
- CORNEAL VASCULARIZATION .....
- METAPLASTIC BONE FORMATION AND/OR MINERALIZATION, SCLERA .....
- LENTICULAR DEGENERATIVE CHANGES COMPATIBLE WITH CATARACT .....

FOCAL (TRACE)  
 NOT SPECIFIED (PRESENT)  
 FOCAL (PRESENT)

INFILTRATE IS BILATERAL ADJACENT NASO-LACRIMAL DUCTS.  
 NOT SPECIFIED (MILD)

Appendix J (cont.): PATHOLOGY INDIVIDUAL ANIMAL DATA

LETTERMAN ARMY INSTITUTE OF RESEARCH  
 DIV OF RES SUPP, PATH SERV GP  
 SPECIES: RAT/FISCHER-344  
 STUDY START DATE: 23-JAN-84  
 STUDY NUMBER: GLP83009  
 PRINTED: 21-NOV-89  
 PAGE: 781  
 STUDY TYPE: CHRONIC/2 YR CARCINOGENIC

ANIMAL NUMBER: 403/PRETEST= 403 SEX: FEMALE DOSE GROUP: 3 SACRIFICE STATUS: FINAL SACRIFICE  
 DATE OF DEATH: 14-FEB-86 STUDY DAY OF DEATH: 754 STUDY WEEK OF DEATH: 108 TERMINAL BODY WEIGHT: 252.00 (GMS)

<< GROSS ORGAN OBSERVATIONS >>  
 SEVERITY GROSS FREE-TEXT COMMENTS  
 KEYWORDS / PHRASES  
 DISCOLORATION CERVICAL  
 ENLARGED DARK, .5CM DIAMETER  
 MODULE(S) MEDIAL LOBE, .5CM DIAMETER.

<< MICROSCOPIC TISSUE OBSERVATIONS >>  
 DISTRIBUTION (SEVERITY) / SPECIAL COMMENTS

- HEART ..... NOT SPECIFIED (TRACE)
- CARDIOMYOPATHY
- LUNGS ..... NOT SPECIFIED (TRACE)
- MINERALIZATION OF PULMONARY ARTERIES
- SPLEEN ..... NOT SPECIFIED (PRESENT)
- HEMOSIDERIN PIGMENTATION (RED PULP)
- LYMPH NODES ..... RBC'S AND HEMOSIDERIN PIGMENT ARE FAIRLY EXTENSIVE IN BOTH CERVICAL AND MEDIASTINAL NODES AND PROBABLY ACCOUNTED FOR THE DISCOLORATION NOTED GROSSLY.  
 NOT SPECIFIED (PRESENT)
- RED BLOOD CELLS, HEMOSIDERIN AND/OR ERYTHROPHAGOCYTOSIS WITHIN MEDULLARY SINUSES
- LIVER ..... MULTI-FOCAL (TRACE)
- HEPATITIS FOCAL (TRACE)
- FOCUS OF CELLULAR ALTERATION - BASOPHILIC NOT SPECIFIED (TRACE)
- BENIGN HYPERPLASTIC NODULE(S)
- KIDNEY ..... NOT SPECIFIED (MILD)
- PROGRESSIVE RENAL DISEASE
- MAMMARY GLANDS ..... NOT SPECIFIED (MILD)
- HYPERPLASIA AND/OR HYPERTROPHY OF THE ACINAR TISSUE

Appendix J (cont.): PATHOLOGY INDIVIDUAL ANIMAL DATA

LETTERMAN ARMY INSTITUTE OF RESEARCH  
DIV OF RES SUPP, PATH SERV GP  
SPECIES: RAT/FISCHER-344  
INDIVIDUAL ANIMAL DATA REPORT  
STUDY NUMBER: GLP83009  
STUDY START DATE: 23-JAN-84

PRINTED: 21-NOV-89  
PAGE: 782

STUDY TYPE: CHRONIC/2 YR CARCINOGENIC

ANIMAL NUMBER: 403/PRETEST-403 SEX: FEMALE DOSE GROUP: 3 SACRIFICE STATUS: FINAL SACRIFICE  
DATE OF DEATH: 14-FEB-86 STUDY DAY OF DEATH: 754 STUDY WEEK OF DEATH: 108 TERMINAL BODY WEIGHT: 252.00 (GMS)

<< MICROSCOPIC TISSUE OBSERVATIONS >>  
TISSUE / HISTOPATHOLOGIC FINDINGS ..... DISTRIBUTION (SEVERITY) / SPECIAL COMMENTS .....

MAMMARY GLANDS ..... NOT SPECIFIED (PRESENT)  
-DILATATION (ECTASIA) OF DUCTS AND DUCTULES .....

PITUITARY GLAND ..... (PRESENT)  
-B- ADENOMA .....

EYES & OPTIC N. .... NOT SPECIFIED (PRESENT)  
-METAPLASTIC BONE FORMATION AND/OR MINERALIZATION, SCLERA ..... NOT SPECIFIED (PRESENT)  
-LENTICULAR DEGENERATIVE CHANGES COMPATIBLE WITH CATARACT ..... NOT SPECIFIED (PRESENT)

**Appendix J (cont.): PATHOLOGY INDIVIDUAL ANIMAL DATA**

LETTERMAN ARMY INSTITUTE OF RESEARCH  
 DIV OF RES SUPP, PATH SERV GP  
 SPECIES: RAT/FISCHER-344  
 STUDY START DATE: 23-JAN-84  
 ANIMAL NUMBER: 404/PRETEST= 404 SEX: FEMALE DOSE GROUP: 3 SACRIFICE STATUS: SACRIFICED MORIBUND  
 DATE OF DEATH: 19-NOV-85 STUDY DAY OF DEATH: 667 STUDY WEEK OF DEATH: 96 TERMINAL BODY WEIGHT: 313.00 (GMS)  
 ORGAN NAME << GROSS ORGAN OBSERVATIONS >>  
 KEYWORDS / PHRASES SEVERITY GROSS FREE-TEXT COMMENTS  
 OVARIES PARA-OVARIAN CYST(S) PRESENT LEFT

INDIVIDUAL ANIMAL DATA REPORT  
 STUDY NUMBER: GLP83009  
 PRINTED: 21-NOV-89  
 PAGE: 783  
 STUDY TYPE: CHRONIC/2 YR CARCINOGENIC

<< MICROSCOPIC TISSUE OBSERVATIONS >>  
 DISTRIBUTION (SEVERITY) / SPECIAL COMMENTS

LACRIMAL GLAND ..... NOT SPECIFIED(MILD)  
 -INFLAMMATION, SUBACUTE TO CHRONIC

HEART ..... NOT SPECIFIED(MILD)  
 -CARDIOMYOPATHY

LIVER ..... NOT SPECIFIED(MILD)  
 -FOCUS OF CELLULAR ALTERATION / EOSINOPHILIC CELLS

KIDNEY ..... NOT SPECIFIED(TRACE)  
 -PROGRESSIVE RENAL DISEASE

OVARIES ..... PAROVARIAN CYST IS COLLAPSED AND FILLED WITH HEMOSIDERIN-  
 LADEN MACROPHAGES.  
 -FOLLICULAR CYST(S) NOT SPECIFIED (PRESENT)  
 -PARA-OVARIAN CYST(S) NOT SPECIFIED (PRESENT)

MAHMARY GLANDS ..... THE ANATOMIC SITE OF THIS MAHMARY FIBROADENOMA WAS NOT RECORDED  
 AT NECROPSY.  
 -HYPERPLASIA AND/OR HYPERTROPHY OF THE ACINAR TISSUE NOT SPECIFIED(MILD)  
 -B- FIBROADENOMA (PRESENT)  
 -DILATATION (ECTASIA) OF DUCTS AND DUCTULES NOT SPECIFIED (PRESENT)

PITUITARY GLAND ..... NOT SPECIFIED (PRESENT)  
 -CYST(S)

**Appendix J (cont.): PATHOLOGY INDIVIDUAL ANIMAL DATA**

LETTERMAN ARMY INSTITUTE OF RESEARCH  
 DIV OF RES SUPP, PATH SERV GP  
 SPECIES: RAT/FISCHER-344  
 STUDY START DATE: 23-JAN-84  
 STUDY NUMBER: GLP83009  
 PRINTED: 21-NOV-89  
 PAGE: 784  
 STUDY TYPE: CHRONIC/2 YR CARCINOGENIC  
 ANIMAL NUMBER: 405/PRETEST= 405 SEX: FEMALE DOSE GROUP: 3 SACRIFICE STATUS: FINAL SACRIFICE  
 DATE OF DEATH: 14-FEB-86 STUDY DAY OF DEATH: 754 STUDY WEEK OF DEATH: 108 TERMINAL BODY WEIGHT: 272.00 (GMS)  
 ORGAN NAME << GROSS ORGAN OBSERVATIONS >>  
 KEYWORDS / PHRASES SEVERITY GROSS FREE-TEXT COMMENTS  
 SPLEEN ENLARGED (SPLENOHEGALY) TRACE  
 LIVER ROUNDED EDGES TRACE

TISSUE / HISTOPATHOLOGIC FINDINGS << MICROSCOPIC TISSUE OBSERVATIONS >>  
 DISTRIBUTION (SEVERITY) / SPECIAL COMMENTS

HEART ..... NOT SPECIFIED(MILD)  
 -CARDIOMYOPATHY

LUNGS ..... NOT SPECIFIED(TRACE)  
 -MINERALIZATION OF PULMONARY ARTERIES (PRESENT)  
 -N- LARGE GRANULAR LYMPHOCYTE LEUKEMIA, METASTATIC

SPLEEN ..... FOCAL(MILD)  
 -INFARCTION, CHRONIC (PRESENT)  
 -N- LARGE GRANULAR LYMPHOCYTE LEUKEMIA, METASTATIC

LIVER ..... MULTI-FOCAL(TRACE)  
 -FOCUS OF CELLULAR ALTERATION - BASOPHILIC FOCAL(TRACE)  
 -NECROSIS NOT SPECIFIED (PRESENT)  
 -CYSTIC DEGENERATION (PRESENT)  
 -N- LARGE GRANULAR LYMPHOCYTE LEUKEMIA, METASTATIC  
 -HEPATOCTE COALESCING MICROVESICULAR (FATTY) CHANGE LEADING TO MULTI-FOCAL(MILD)  
 NECROSIS AND MINERALIZATION

KIDNEY ..... NOT SPECIFIED(TRACE)  
 -PROGRESSIVE RENAL DISEASE

UTERUS ..... MULTI-FOCAL (PRESENT)  
 -CYSTIC DILATATION OF THE ENDOMETRIAL GLANDS

MAMMARY GLANDS .....

Appendix J (cont.): PATHOLOGY INDIVIDUAL ANIMAL DATA

LETTERMAN ARMY INSTITUTE OF RESEARCH  
 DIV OF RES SUPP, PATH SERV GP  
 SPECIES: RAT/FISCHER-344  
 ANIMAL NUMBER: 405/PRETEST=  
 DATE OF DEATH: 14-FEB-86  
 TISSUE / HISTOPATHOLOGIC FINDINGS  
 << MICROSCOPIC TISSUE OBSERVATIONS >>  
 DISTRIBUTION (SEVERITY) / SPECIAL COMMENTS

INDIVIDUAL ANIMAL DATA REPORT  
 STUDY NUMBER: GLP83009  
 STUDY START DATE: 23-JAN-84  
 DOSE GROUP: 3  
 SACRIFICE STATUS: FINAL SACRIFICE  
 STUDY WEEK OF DEATH: 108  
 TERMINAL BODY WEIGHT: 272.00 (GMS)

STUDY TYPE: CHRONIC/2 YR CARCINOGENIC  
 PRINTED: 21-NOV-89  
 PAGE: 785

MAMMARY GLANDS  
 -HYPERPLASIA AND/OR HYPERTROPHY OF THE ACINAR TISSUE  
 -DILATATION (ECTASIA) OF DUCTS AND DUCTULES  
 NOT SPECIFIED (TRACE)  
 NOT SPECIFIED (PRESENT)

NOSE/TURBINATES  
 -MIXED INFLAMMATORY CELL INFILTRATION, NASAL CAVITY, SINUSES,  
 TURBINATES, MASO-LACRIMAL DUCTS  
 INFILTRATE IS BILATERAL ADJACENT MASO-LACRIMAL DUCTS.  
 NOT SPECIFIED (MILD)

PITUITARY GLAND  
 -CYST(S)  
 NOT SPECIFIED (PRESENT)

EYES & OPTIC N.  
 -CORNEAL VASCULARIZATION  
 FOCAL (TRACE)

WHOLE BODY  
 -M- LARGE GRANULAR LYMPHOCYTTIC LEUKEMIA  
 (PRESENT)

**Appendix J (cont.): PATHOLOGY INDIVIDUAL ANIMAL DATA**

LETTERMAN ARMY INSTITUTE OF RESEARCH  
 DIV OF RES SUPP, PATH SERV GP  
 SPECIES: RAT/FISCHER-344

INDIVIDUAL ANIMAL DATA REPORT  
 STUDY NUMBER: GLP83009  
 STUDY START DATE: 23-JAN-84

PRINTED: 21-NOV-89  
 PAGE: 786  
 STUDY TYPE: CHRONIC/2 YR CARCINOGENIC

ANIMAL NUMBER: 406/PRETEST  
 DATE OF DEATH: 14-FEB-86  
 SEX: FEMALE  
 DOSE GROUP: 3  
 SACRIFICE STATUS: FINAL SACRIFICE  
 STUDY WEEK OF DEATH: 754  
 TERMINAL BODY WEIGHT: 225.00 (GMS)

<< GROSS ORGAN OBSERVATIONS >>  
 KEYWORDS / PHRASES SEVERITY GROSS FREE-TEXT COMMENTS  
 SUBCUTANEOUS MASS PRESENT CLITORAL GLAND, 2.5 X 2CM  
 DISCOLORATION PRESENT FOCAL, RED, .1CM DIAMETER

<< MICROSCOPIC TISSUE OBSERVATIONS >>  
 TISSUE / HISTOPATHOLOGIC FINDINGS DISTRIBUTION (SEVERITY) / SPECIAL COMMENTS

THYROID GLANDS ..... (PRESENT)  
 -B- PARA-FOLLICULAR CELL ADENOMA

HEART ..... NOT SPECIFIED (TRACE)  
 -CARDIOMYOPATHY

SPLEEN ..... NOT SPECIFIED (PRESENT)  
 -EXTRAMEDULLARY HEMATOPOIESIS

LYMPH NODES ..... RBC'S AND HEMOSIDERIN ARE LIMITED TO CERVICAL NODES.  
 -RED BLOOD CELLS, HEMOSIDERIN AND/OR ERYTHROPHAGOCYTOSIS WITHIN MEDULLARY SINUSES NOT SPECIFIED (PRESENT)

LIVER ..... NOT SPECIFIED (MILD)  
 -BILE DUCTULE EPITHELIAL HYPERPLASIA AND/OR CHOLANGIOFIBROSIS MULTI-FOCAL (MILD)  
 -HEPATITIS MULTI-FOCAL (MILD)  
 -HEPATOCTYCE COALESCING MICROVESICULAR (FATTY) CHANGE LEADING TO NECROSIS AND MINERALIZATION

KIDNEY ..... NOT SPECIFIED (MILD)  
 -PROGRESSIVE RENAL DISEASE

SKIN ..... (PRESENT)  
 -B- CLITORAL GLAND ADENOMA

MAMMARY GLANDS .....

Appendix J (cont.): PATHOLOGY INDIVIDUAL ANIMAL DATA

LETTERMAN ARMY INSTITUTE OF RESEARCH  
 DIV OF RES SUPP, PATH SERV GP  
 SPECIES: RAT/FISCHER-344  
 INDIVIDUAL ANIMAL DATA REPORT  
 STUDY NUMBER: GLP83009  
 STUDY START DATE: 23-JAN-84  
 PRINTED: 21-NOV-89  
 PAGE: 787

ANIMAL NUMBER: 406/PRETEST-  
 DATE OF DEATH: 14-FEB-86  
 STUDY DAY OF DEATH: 754  
 SEX: FEMALE  
 DOSE GROUP: 3  
 SACRIFICE STATUS: FINAL SACRIFICE  
 STUDY WEEK OF DEATH: 108  
 TERMINAL BODY WEIGHT: 225.00 (GMS)

<< MICROSCOPIC TISSUE OBSERVATIONS >>  
 TISSUE / HISTOPATHOLOGIC FINDINGS DISTRIBUTION (SEVERITY) / SPECIAL COMMENTS

MAMMARY GLANDS  
 -HYPERPLASIA AND/OR HYPERTROPHY OF THE ACINAR TISSUE  
 -DILATATION (ECTASIA) OF DUCTS AND DUCTULES

ADRENAL  
 -FOCUS OF CELLULAR ALTERATION, VACUOLATED

PITUITARY GLAND  
 -CYST(S)

EYES & OPTIC N.  
 -LENTICULAR DEGENERATIVE CHANGES COMPATIBLE WITH CATARACT

NOT SPECIFIED (MILD)  
 NOT SPECIFIED (PRESENT)  
 FOCAL (TRACE)  
 NOT SPECIFIED (PRESENT)  
 NOT SPECIFIED (PRESENT)  
 THE SUBCAPSULAR CHANGES IN THE LENS ARE EARLY, SUBTLE, MINIMAL AND INVOLVE ONLY ONE EYE (SECTION #19 B). THESE MINIMAL CHANGES WERE PROBABLY NOT EVIDENT ON GROSS EXAMINATION.  
 NOT SPECIFIED (PRESENT)



Appendix J (cont.): PATHOLOGY INDIVIDUAL ANIMAL DATA

LETTERMAN ARMY INSTITUTE OF RESEARCH  
 DIV OF RES SUPP, PATH SERV GP  
 SPECIES: RAT/FISCHER-344

INDIVIDUAL ANIMAL DATA REPORT  
 STUDY NUMBER: GLP83009  
 STUDY START DATE: 23-JAN-84

PRINTED: 21-NOV-89  
 PAGE: 788  
 STUDY TYPE: CHRONIC/2 YR CARCINOGENIC

ANIMAL NUMBER: 407/PRETEST# 407 SEX: FEMALE DOSE GROUP: 3 SACRIFICE STATUS: SACRIFICED MORIBUND  
 DATE OF DEATH: 23-APR-85 STUDY DAY OF DEATH: 457 STUDY WEEK OF DEATH: 66 TERMINAL BODY WEIGHT: 216.00 (GMS)

ORGAN NAME << GROSS ORGAN OBSERVATIONS >>  
 KEYWORDS / PHRASES SEVERITY GROSS FREE-TEXT COMMENTS  
 SKIN ULCER(S) / EROSION(S) PRESENT 3 X 4MM COVERED BY BLACK DRY CRUSTY MATERIAL ON VENTRAL MIDLINE 1CM ANTERIOR TO VAGINA

TISSUE / HISTOPATHOLOGIC FINDINGS << MICROSCOPIC TISSUE OBSERVATIONS >>  
 DISTRIBUTION (SEVERITY) / SPECIAL COMMENTS

- LACRIMAL GLAND ..... NOT SPECIFIED(MILD)
- INFLAMMATION, SUBACUTE TO CHRONIC
- HEART ..... NOT SPECIFIED(MILD)
- CARDIOMYOPATHY
- LUNGS ..... ALVEOLAR HEMORRHAGE IS PROBABLY DUE TO ASPIRATION OF BLOOD AT TERMINALLY
- ALVEOLAR HEMORRHAGE NOT SPECIFIED (PRESENT)
- KIDNEY ..... NOT SPECIFIED(TRACE)
- PROGRESSIVE RENAL DISEASE
- SKIN ..... KERATOACANTHOMA INVOLVES THE CLITORAL GLAND.
- B- KERATOACANTHOMA, ANATOMIC SITE TO BE SPECIFIED (PRESENT)
- NOSE/TURBINATES ..... INFILTRATE: BILATERAL, SUPPURATIVE, ADJACENT NASO-LACRIMAL DUCTS.
- MIXED INFLAMMATORY CELL INFILTRATION, NASAL CAVITY, SINUSES, NOT SPECIFIED(MODERATE)
- TURBINATES, NASO-LACRIMAL DUCTS
- ADRENAL ..... NOT SPECIFIED (PRESENT)
- CORTICAL MODULAR HYPERPLASIA
- EYES & OPTIC N. .... TISSUE IS MISSING
- NUMEROUS ARTIFACTS INDUCED DURING EMBEDDING AND SECTIONING MAKE HISTOLOGIC EVALUATION IMPOSSIBLE.

OFFICIAL DISTRIBUTION LIST

Commander  
US Army Medical Research  
& Development Command  
ATTN: SGRD-RMS/Mrs. Madigan  
Fort Detrick, MD 21701-5012

Defense Technical Information Center  
ATTN: DTIC/DDAB (2 copies)  
Cameron Station  
Alexandria, VA 22304-6145

Office of Under Secretary of Defense  
Research and Engineering  
ATTN: R&AT (E&LS), Room 3D129  
The Pentagon  
Washington, DC 20301-3080

DASG-AAFJML  
Army/Air Force Joint Medical Library  
Offices of the Surgeons General  
5109 Leesburg Pike, Room 670  
Falls Church, VA 22041-3258

HQ DA (DASG-ZXA)  
WASH DC 20310-2300

Commandant  
Academy of Health Sciences  
US Army  
ATTN: HSHA-CDM  
Fort Sam Houston, TX 78234-6100

Uniformed Services University of  
Health Sciences  
Office of Grants Management  
4301 Jones Bridge Road  
Bethesda, MD 20814-4799

US Army Research Office  
ATTN: Chemical and Biological  
Sciences Division  
PO Box 12211  
Research Triangle Park, NC 27709-2211

Director  
Walter Reed Army Institute of Research  
ATTN: SGRD-UWZ-L  
Washington, DC. 20307-5100

Commander  
US Army Medical Research Institute  
of Infectious Diseases  
ATTN: SGRD-ULZ-A  
Fort Detrick, MD 21701-5011

Commander  
US Army Medical Materiel Development  
Activity  
Fort Detrick, Bldg T622  
Frederick, MD 21701-5009

Commander  
US Army Biomedical Research and  
Development Laboratory  
ATTN: Library  
Fort Detrick, Bldg 568  
Frederick, MD 21701-5010

Commander  
US Army Research Institute of  
Environmental Medicine  
ATTN: SGRD-UE-RSA  
Kansas Street  
Natick, MA 01760-5007

Commander  
US Army Institute of Surgical Research  
Fort Sam Houston, TX 78234-6200

Commander  
US Army Medical Research Institute of  
Chemical Defense  
ATTN: SGRD-UV-AJ  
Aberdeen Proving Ground, MD 21010-5425

Commander  
US Army Aeromedical Research  
Laboratory  
Fort Rucker, AL 36362-5000

AIR FORCE Office of Scientific  
Research (NL)  
Building 410, Room A217  
Bolling Air Force Base, DC 20332-6448

USAF School of Aerospace Medicine  
Document Section  
USAFSAM/TSKD  
Brooks Air Force Base, TX 78235-5301

Head, Biological Sciences Division  
OFFICE OF NAVAL RESEARCH  
800 North Quincy Street  
Arlington, VA 22217-5000