

AD-A203 562

***Plasmodium berghei*-Hamster Cheek Pouch Model for the study of Severe Malaria**

David R. Franz, Wallace B. Baze, G. David Young, and George E. Lewis Jr.

Malaria Research Group, U. S. Army Medical Research Unit, Institute for Medical Research, Kuala Lumpur, Malaysia; Pathophysiology Division, U. S. Army Medical Research Institute of Infectious Diseases, Fort Detrick, MD; Division of Veterinary Pathology, U.S. Army Medical Component, Armed Forces Research Institute of Medical Sciences, Bangkok, Thailand; and Division of Pathology, Walter Reed Army Institute of Research, Washington, DC.

This research was supported by grant DAMD 17-85-G-5011 from the U.S. Army Medical Research and Development Command, Fort Detrick, Frederick, Maryland

Running Head: Hamster cheek pouch malaria model

4 Figures / 23 References

Send reprint requests and all correspondence to: David R. Franz
Pathophysiology Division
U.S. Army Medical Research
Institute of Infectious Diseases
Fort Detrick, MD 21701
(301) 663-6197

DTIC
ELECTE
S JAN 13 1989 D
a
H

DISTRIBUTION STATEMENT A
Approved for public release;
Distribution Unlimited

89 1 13 099

REPORT DOCUMENTATION PAGE

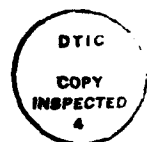Form Approved
OMB No. 0704-0188

1a. REPORT SECURITY CLASSIFICATION Unclassified		1b. RESTRICTIVE MARKINGS	
2a. SECURITY CLASSIFICATION AUTHORITY		3. DISTRIBUTION / AVAILABILITY OF REPORT Distribution unlimited - approved for public release	
2b. DECLASSIFICATION / DOWNGRADING SCHEDULE			
4. PERFORMING ORGANIZATION REPORT NUMBER(S)		5. MONITORING ORGANIZATION REPORT NUMBER(S)	
6a. NAME OF PERFORMING ORGANIZATION U.S. Army Medical Research Institute of Infectious Diseases	6b. OFFICE SYMBOL (if applicable) SGRD-UIS-F	7a. NAME OF MONITORING ORGANIZATION U.S. Army Medical Research and Development Command	
6c. ADDRESS (City, State, and ZIP Code) Fort Detrick, Frederick, MD 21701-5011		7b. ADDRESS (City, State, and ZIP Code) Fort Detrick, Frederick, MD 21701-5012	
8a. NAME OF FUNDING / SPONSORING ORGANIZATION	8b. OFFICE SYMBOL (if applicable) SGRD-UIS-F	9. PROCUREMENT INSTRUMENT IDENTIFICATION NUMBER	
8c. ADDRESS (City, State, and ZIP Code)		10. SOURCE OF FUNDING NUMBERS	
		PROGRAM ELEMENT NO.	PROJECT NO.
		TASK NO.	WORK UNIT ACCESSION NO.
11. TITLE (Include Security Classification) Plasmodium bergehei-Hamster Cheek Pouch Model for the Study of Severe Malaria			
12. PERSONAL AUTHOR(S) David R. Franz, Wallace B. Baze, G. David Young, and George E. Lewis, Jr.			
13a. TYPE OF REPORT Interim	13b. TIME COVERED FROM _____ TO _____	14. DATE OF REPORT (Year, Month, Day) 21 November 1988	15. PAGE COUNT 11
16. SUPPLEMENTARY NOTATION			
17. COSATI CODES		18. SUBJECT TERMS (Continue on reverse if necessary and identify by block number)	
FIELD	GROUP	Hamster cheek pouch, <u>Plasmodium berghei</u> , severe malaria	
	SUB-GROUP		
19. ABSTRACT (Continue on reverse if necessary and identify by block number) Severe malaria in man, caused by <i>Plasmodium falciparum</i> , is typically characterized by drowsiness, disorientation, incoherence, and severe headache. Untreated, coma and death often follow; mortality may be as high as 25% to 50%. The syndrome is often called cerebral malaria because of its most common clinical signs and typical postmortem cerebral lesions; however, it involves multiple organ systems, and results in far-ranging pathologic change. Systemic changes include an adult respiratory distress-like syndrome, acute renal tubular necrosis, hypoglycemia, thrombocytopenia, dyserythropoiesis and hemolysis, gastrointestinal abnormalities, and liver damage. Simple invasion of erythrocytes (RBCs) by protozoa cannot explain all of the lesions described. Several hypotheses have been advanced to try to explain the observed lesions--increased permeability of the blood brain barrier, disseminated intravascular coagulation, immunologically mediated disease, and systemic toxemia--yet, the pathogenesis of severe malaria remains unknown. Yoeli, noting that the human vascular lesion can only be observed on postmortem, challenged			
20. DISTRIBUTION / AVAILABILITY OF ABSTRACT <input type="checkbox"/> UNCLASSIFIED/UNLIMITED <input type="checkbox"/> SAME AS RPT <input type="checkbox"/> DTIC USERS		21. ABSTRACT SECURITY CLASSIFICATION	
22a. NAME OF RESPONSIBLE INDIVIDUAL		22b. TELEPHONE (Include Area Code)	22c. OFFICE SYMBOL

↓
 Severe malaria in man, caused by *Plasmodium falciparum*, is typically characterized by drowsiness, disorientation, incoherence, and severe headache. Untreated, coma and death often follow; mortality may be as high as 25% to 50%. The syndrome is often called cerebral malaria because of its most common clinical signs and typical postmortem cerebral lesions; however, it involves multiple organ systems, and results in far-ranging pathologic change. Systemic changes include an adult respiratory distress-like syndrome, acute renal tubular necrosis, hypoglycemia, thrombocytopenia, dyserythropoiesis and hemolysis, gastro-intestinal abnormalities, and liver damage. Simple invasion of erythrocytes (RBCs) by protozoa cannot explain all of the lesions described. Several hypotheses have been advanced to try to explain the observed lesions — increased permeability of the blood brain barrier, disseminated intravascular coagulation, immunologically mediated disease, and systemic toxemia — yet, the pathogenesis of severe malaria remains unknown. Yoeli, noting that the human vascular lesion can only be observed on postmortem, challenged malariologists to develop an *in-vivo* model in which one might observe and record the changes in the microcirculation during active infection,

ANIMAL MODEL

The classical hamster cheek-pouch model^{12,13} has now been combined with a previously described *Plasmodium berghei*-infected golden hamster model. The vascular lesions observed in the cheek pouch of the living anesthetized hamster (Figures 1-3) and in the post-mortem cheek pouch (Figure 4) are similar, in degree of severity and time of onset, to those occurring in the hamster brain.¹⁵ Golden hamsters (*Mesocricetus auratus*) of either sex are infected at 4-6 weeks of age with 1.5×10^7 *P. berghei*-parasitized (ANKA strain) hamster red blood cells injected intraperitoneally. Infected animals typically live for 12-15 days, during which time one can observe, *in vivo*, mononuclear cells containing



For	
AI	<input checked="" type="checkbox"/>
ed	<input type="checkbox"/>
ion	<input type="checkbox"/>
on/	
ity Codes	
and/or	
Dist	Special
A-1	

intracytoplasmic malarial pigment, margined with adherent RBCs, in submucosal blood vessels; malarial parasitized RBCs; and progressive failure of capillary beds. Using the cheek pouch model, one can observe and manipulate the dynamic relationships between formed blood elements and the endothelium in severe malaria.

COMPARISON WITH HUMAN DISEASE

Postmortem brain lesions in man include petechia in the white matter; congestion of capillaries and venules; aggregates of parasitized RBCs, macrophages, and mononuclear leucocytes containing malarial pigment and interwoven by fibrin; perivascular hemorrhages; glial granulomata; ischemic changes in nerve cells; and sometimes edema.¹⁶ All these lesions (with the exception of glial granulomata) can be observed in the hamster brain post-mortem, only the relative frequency of occurrence being different. Congestion of RBCs in cerebral capillaries, normally noted as the most striking postmortem histologic sequela of severe malaria in humans, was infrequently seen in our studies or those described by Rest and Wright.¹⁷ Mononuclear cells containing malarial pigment are commonly seen along the walls of venules within the cheek pouch and brain; these cells are occasionally observed in the brains of cerebral malaria patients¹⁶ and alveolar capillaries of *P.-falciparum* malaria patients who die with acute pulmonary insufficiency.¹⁸ Like its human counterpart, the *P. berghei* infection in hamsters is a lethal systemic disease involving vascular beds other than those of the brain; we have also demonstrated mononuclear/RBC aggregates in the vascular beds of the lung, liver, spleen, and kidney in hamsters.¹⁵

USEFULNESS OF THE MODEL

This model allows simultaneous observation of morphology and function in a large vascular bed; pathologic change may be recorded by photo- or videomicroscopy. Lesions in small capillaries are generally observed in the pouch *in vivo* before they can be seen by histologic techniques. The broad perspective gained facilitates focus of effort for subsequent histopathology or pharmacology. Compounds that might alter the vascular lesions can now be screened quickly while observing their *in-vivo* effects. Individual cells or vascular regions may be collected for further study. This model is ideally suited to study the role of the monocyte in severe malaria, as this cell type is sequestered in greater numbers in hamster vessels than in the vessels of the brains of humans. There has recently evolved a general acceptance of the importance of monokines in *Plasmodium* infection. Antibody directed against recombinant tumor necrosis factor (TNF)¹⁹ or pretreatment with dexamethasone²⁰ can prevent the development of the described lesions in rodents, while recombinant TNF given to mice with low *P. vinckei* parasitemia leads to clinical signs like those seen in high parasitemia.²¹ Lastly, the finding of elevated serum levels of TNF in 7 of 10 malarial patients²² and the growing body of evidence suggesting a significant role for cell-mediated immunity in the pathogenesis of human malaria²³ make this model of severe human malaria even more attractive and useful.

REFERENCES

1. Jelliffe DB: Diseases of Children in the Subtropics and Tropics. 1972, Edward Arnold Ltd., London, 1972, pp 774-818
2. Warrell DA: Pathophysiology of severe falciparum malaria in man. *Parasitology* 1987, 94:S53-S67
3. Fein IA, Rackow EC, Shapiro L: Acute pulmonary edema in *Plasmodium falciparum* malaria. *Am Rev Respir Dis* 1987, 118:425-429
4. Stone WJ, Hanchett EJ, Knepshield JH: Acute renal insufficiency due to falciparum malaria. *Arch Intern Med* 1972, 129:620-628
5. White NJ, Warrell DA, Chanthavanich P, Looareesuwan S, Warrell MJ, Krishna S, Williamson DH, Turner RC: Severe hypoglycemia and hyperinsulinemia in falciparum malaria. *N Engl J Med* 1983, 309: 61-66
6. Skudowitz RB, Katz J, Lurie A, Levin J, Metz J: Mechanisms of thrombocytopenia in malignant tertian malaria. *Br Med J* 1973, 2: 515-518
7. Abdalla S, Weatherall DJ, Wickramasinghe SN, Hughes M: The anaemia of *P. falciparum* malaria. *Br J Haematol* 1980, 46: 171-183
8. Karney WW, Tong MJ: Malabsorption in *Plasmodium falciparum* malaria. *Am J Trop Med Hyg* 1972, 21: 1-5
9. McMahon AE Jr, Kelsey JE, Derauf DE: Hepatitis of malarial origin; clinical and pathologic study of 54 Korean veterans 1954, 25: 379-386

10. Phillips RE, Warrell DA: The pathophysiology of severe falciparum malaria. *Parasitol Today* 1986, 2:271-282
11. Yoeli, M: Cerebral malaria—the quest for suitable experimental models in parasitic diseases of man. *Trans Roy Soc Trop Med Hyg* 1976, 70:24-35
12. Fulton GP, Jackson RG: Cinephotomicroscopy of normal blood circulation in the cheek pouch of the hamster. *Science* 1947, 105:361-362
13. Duling BR: The preparation and use of the hamster cheek pouch for studies of the microcirculation. *Microvasc Res* 1973, 5: 423-429
14. Wright DH, Masembe RM, Basira ER: The effect of antithymocyte serum on golden hamsters and rats infected with *Plasmodium berghei*. *Br J Exp Path*, 1971, 52:465-477
15. Franz DR, Lee M, Lim TS, Young GD, Baze WB, Lewis GE Jr: Peripheral vascular pathophysiology of *Plasmodium berghei* infection: A comparative study in the cheek pouch and brain of the golden hamster. *Am J Trop Med Hyg*, 1987, 36:474-480
16. Boonpucknavig V, Srichaikul T, Punyagupta S: Antimalarial Drugs I: Biological background, experimental methods, and drug resistance. Edited by W Peters and WHG Richards. Springer-Verlag, Berlin, 1984, pp 127-176
17. Rest JR, Wright DH: Electron microscopy of cerebral malaria in the golden hamsters (*Mesocricetus auratus*) infected with *Plasmodium berghei*. *J Pathol*, 1979, 127:115-120
18. Punyagupta S, Srichaikul T, Nitiyanant SP, Petchclai B: Acute pulmonary insufficiency in falciparum malaria: summary of 12 cases with evidence of disseminated intravascular coagulation. *Am J Trop Med Hyg*, 1974, 23: 551-559

19. Grau GE, Fajardo LF, Piguet P-F, Allet B, Lambert P-H, Vassalli P: Tumor necrosis factor (cachectin) as an essential mediator in murine cerebral malaria. *Science* 1987, 237:1210-1212
20. Franz DR, Lim TS, Baze WB, Arimbalam S, Lee M, Lewis, GE Jr: Pathologic activity of *Plasmodium berghei* prevented but not reversed by dexamethasone. *Am J Trop Med Hyg* 1988, 38: 249-254
21. Clark IA, Cowden WB, Butcher GA, Hunt NH: Possible roles of tumor necrosis factor in the pathology of malaria. *Am J Path* 1987, 129:192-199
22. Scuderi P, Sterling KE, Lam KS, Finley PR, Ryan KJ, Ray CG, Petersen E, Shymen DJ, Salmon SE: Raised serum levels of tumour necrosis factor in parasitic infections. *Lancet* 1986, 2:1364-1365
23. Clark IA: Monokines and lymphokines in malarial pathology. *Ann Trop Med Parasitol* 1987, 81:577-585

LEGENDS FOR FIGURES

Figure 1. Mononuclear cell (at arrow), containing malarial pigment, adherent to the endothelium of a 30- μm vessel within the cheek pouch of a living hamster infected with *P. berghei*. When noted, such cells remain attached in one position and blood flow continues around them throughout the entire period of observation, typically 15-60 min. Several RBCs appear to be adhering to the larger mononuclear cell. In the background are skeletal muscle fibers, normally seen in the pouch preparation.

Figure 2. A venule of 40- μm diameter within the cheek pouch of a living hamster 6 days after challenge with *P. berghei*. RBCs are commonly seen adhered to the walls of venules and small veins, although the walls of capillaries and arterial vessels are universally free of cells. Such RBCs are sometimes seen in the vessels of noninfected animals, but the venular and venous walls of infected animals' pouches are typically densely covered with cells, especially between 5-7 days post-challenge, resulting in a cobblestone appearance. Some of the spherical cells tumble slowly along the vessel walls, propelled by flowing blood. Tumbling cells move at different rates as if some adhere more tenaciously than others.

Figure 3. Venous (v) and arterial (a) vessels within the pouch of a living hamster 12 days after *P. berghei* challenge. Note the typical aggregate of cells, probably pigment-laden mononuclear cell(s) with numerous RBCs adherent (at bracket), apparently attached to venous endothelium. Formed elements can be seen as blurred eddy currents passing around the lesion. One can observe *in vivo* as additional RBCs leave the flowing blood to adhere momentarily or permanently to the surface of the "growing" lesion.

Figure 4. Photomicrograph of azure II methylene blue 1- μm section from the cheek pouch of a *P. berghei*-infected hamster killed 12 days post-challenge. Note endothelial walls (e)

of a vessel containing parasitized (p) and nonparasitized (np) RBCs with marginated mononuclear cells (m), possible mediators of endothelial cell damage, near disrupted endothelium on the lower margin. RBCs, primarily nonparasitized, can be seen outside the vessel representing hemorrhage. The lesion is similar to the "ring hemorrhages" described in the brains of humans after death due to *P. falciparum* infection. Such hemorrhages are typically not seen in the cheek pouch *in-vivo* preparation. x630.

NOTE: Figures used with permission from Franz, et al., 1987 ¹⁵




Fig 1



Fig 2




Fig 3

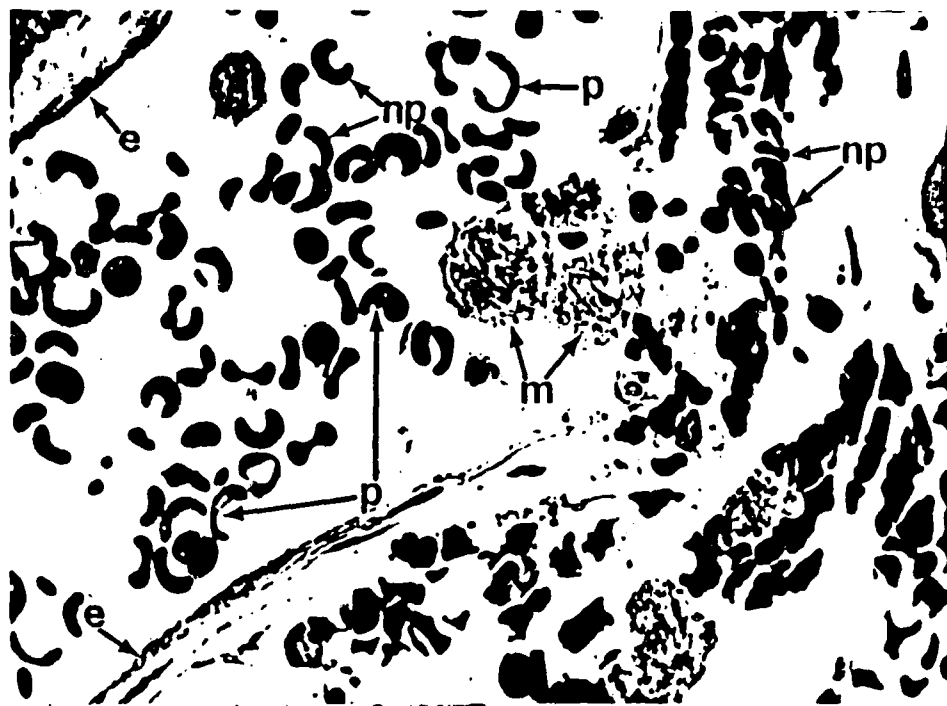


Fig 4