

1a. REPORT SECURITY CLASSIFICATION
Unclassified1b. RESTRICTIVE MARKING
Unlimited

2a. SECURITY CLASSIFICATION AUTHORITY

3. DISTRIBUTION/AVAILABILITY OF REPORT
Approved for public release
Distribution unlimited

2b. DECLASSIFICATION/DOWNGRADING SCHEDULE

4. PERFORMING ORGANIZATION REPORT NUMBER(S)

5. MONITORING ORGANIZATION REPORT NUMBER(S)

6a. NAME OF PERFORMING ORGANIZATION
U.S. Army Research Institute of
Environmental Medicine6b. OFFICE SYMBOL
(if applicable)
SGRD-UE-CR7a. NAME OF MONITORING ORGANIZATION
U.S. Army Medical Research and Development
Command

6c. ADDRESS (City, State, and ZIP Code)

Kansas Street
Natick, MA 01760-5007

7b. ADDRESS (City, State, and ZIP Code)

Ft. Detrick
Maryland 21701-50128a. NAME OF FUNDING/SPONSORING
ORGANIZATION8b. OFFICE SYMBOL
(if applicable)

9. PROCUREMENT INSTRUMENT IDENTIFICATION NUMBER

8c. ADDRESS (City, State, and ZIP Code)

10. SOURCE OF FUNDING NUMBERS

PROGRAM
ELEMENT NO.
611102PROJECT
NO.
3M161102BS15TASK
NO.
CAWORK UNIT
ACCESSION NO.
DA305215

11. TITLE (Include Security Classification)

An Evaluation of the Ability of the Peripheral Vasodilator Buflomedil to Improve Vascular
Patency After Acute Frostbite

12. PERSONAL AUTHOR(S)

Patricia S. Daum, Wilbert D. Bowers, Jr., Jorge Tejada, David Morehouse and Murray P. Haral

13a. TYPE OF REPORT
Final

13b. TIME COVERED

FROM _____ TO _____

14. DATE OF REPORT (Year, Month, Day)

1988 June 21

15. PAGE COUNT
16

16. SUPPLEMENTARY NOTATION

17. COSATI CODES

FIELD GROUP SUB-GROUP

18. SUBJECT TERMS (Continue on reverse if necessary and identify by block number)

Frostbite, Vascular microcorrosion casts, Scanning electron
microscopy, Buflomedil, Capillaries

19. ABSTRACT (Continue on reverse if necessary and identify by block number)

The extent of microvascular damage from frostbite can be accurately demonstrated by vascular microcorrosion casting techniques (Daum et al. *Cryobiology* 24, 65-73, 1987). In the present investigation, the peripheral vasodilator buflomedil was evaluated for its ability to ameliorate microcirculatory damage from acute experimentally induced freeze injury. This drug has been reported to decrease tissue loss in human frostbite patients when given intravenously during thawing (Poray et al. *Ann. Hop. Paris* 56, 490-497, 1980). In seven groups of anesthetized rats, left hindpaws were cooled (to heat of fusion; cooling continued until the temperature in the footpads fell to -15°C. Prior to cooling, group one received a tail vein injection of 1ml saline/kg while group two received 10mg buflomedil/kg. Immediately following cooling, group three received an injection of 10mg buflomedil/kg. Hindpaws were rapidly rewarmed in a 40°C bath. During rewarm, left hindpaws from group four were immersed in deionized water, from group five in 24mg buflomedil in deionized water, from group six in 30% dimethyl sulfoxide (Me₂SO) and from

20. DISTRIBUTION/AVAILABILITY OF ABSTRACT

☒ UNCLASSIFIED/UNLIMITED ☐ SAME AS RPT. ☐ DTIC USERS

21. ABSTRACT SECURITY CLASSIFICATION

Unclassified

22a. NAME OF RESPONSIBLE INDIVIDUAL

Patricia S. Daum

22b. TELEPHONE (Include Area Code)

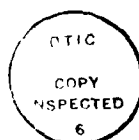(617) 651-4862

22c. OFFICE SYMBOL

SGRD-UE-CR

group seven in 24mg buflomedil in 30% Me₂SO. Right hindpaws served as controls. Vascular microcorrosion casts were made from left and right hindpaws of all groups. There was no significant difference in mean cast weights when frozen hindpaws of the seven groups were compared, although treatment with buflomedil increased the mean cast weight of control hindpaws from groups three and seven. It therefore appears that, in this acute model for frostbite, buflomedil does not improve vascular patency.

Accession For	
NTIS GRA&I	<input checked="checked" type="checkbox"/>
DTIC TAB	<input type="checkbox"/>
Unannounced	<input type="checkbox"/>
Justification	
By	
Distribution/	
Availability Codes	
Avail and/or	
Dist. Special	
A-1	



An Evaluation of the Ability of the Peripheral Vasodilator Buflomedil
to Improve Vascular Patency After Acute Frostbite

PATRICIA S. DAUM, WILBERT D. BOWERS, JR., JORGE TEJADA,
DAVID MOREHOUSE AND MURRAY P. HAMLEY

U.S. Army Research Institute of Environmental Medicine,
Natick, MA 01760-5007

Short Title: Effect of buflomedil on vascular patency

Send Correspondence To:

Ms. Patricia S. Daum

Experimental Pathology Branch, CRD

U.S. Army Research Institute of Environmental Medicine

Kansas Street

Natick, MA 01760-5007

ABSTRACT

The extent of microvascular damage from frostbite can be accurately demonstrated by vascular microcorrosion casting techniques (Daum et al. *Cryobiology* 24, 65-73, 1987). In the present investigation, the peripheral vasodilator buflomedil was evaluated for its ability to ameliorate microcirculatory damage from acute experimentally induced freeze injury. This drug has been reported to decrease tissue loss in human frostbite patients when given intravenously during thawing (Foray et al. *Sem. Hop. Paris* 56, 490-497, 1980). In seven groups of anesthetized rats, left hindpaws were cooled to heat of fusion; cooling continued until the temperature in the footpads fell to -15°C . Prior to cooling, group one received a tail vein injection of 1ml saline/kg while group two received 10mg buflomedil/kg. Immediately following cooling, group three received an injection of 10mg buflomedil/kg. Hindpaws were rapidly rewarmed in a 40°C bath. During rewarm, left hindpaws from group four were immersed in deionized water, from group five in 24mg buflomedil in deionized water, from group six in 30% dimethyl sulfoxide (Me_2SO) and from group seven in 24mg buflomedil in 30% Me_2SO . Right hindpaws served as controls. Vascular microcorrosion casts were made from left and right hindpaws of all groups. There was no significant difference in mean cast weights when frozen hindpaws of the seven groups were compared, although treatment with buflomedil increased the mean cast weight of control hindpaws from groups three and seven. It therefore appears that, in this acute model for frostbite, buflomedil does not improve vascular patency.

Current approaches to frostbite therapy in humans treat symptoms by the application of a wide variety of remedies which are used in conjunction with rapid rewarming of the injured area. These complex therapeutic regimens have included heparin (11), vasodilators (4), dextran (3), sympathetic neural blockade (22, 24), anti-inflammatory agents (7), and inhibitors of the arachidonic acid cascade (14). Vasodilators have been used clinically as a treatment for frostbite injury since their application in patient trials during the Korean War (20). Although administration of these drugs did not result in any observable benefits, treatment protocols for frostbite continue to advise that there is the potential for a decrease in tissue loss when a vasodilator is included in the therapy (2, 4, 18). However, the efficacy of vasodilators in preventing tissue loss continues to be equivocal. Mills found that vasodilators, administered in the early stage of the injury, were not particularly effective in the treatment of frostbite (19), while other clinicians have reported that the drugs do have value in the management of severe cold injuries (4). To date, no particular vasodilator has gained wide acceptance as a treatment for frostbite, although the diversity of opinions on this subject could be due, in part, to ethical considerations which prevent the establishment of adequate controls.

Recently, the peripheral vasodilator buflomedil [4-(1-pyrrolidinyl)-1-(2,4,6-trimethoxyphenyl)-1-butanone hydrochloride] was reported to have decreased tissue loss in human frostbite patients (11). According to Foray et al. (11), when given intravenously during rewarming, the drug appeared to prevent the anticipated amputation of frostbitten limbs. Since recent work in this laboratory has demonstrated the remarkable capacity of vascular microcorrosion casting techniques for evaluating vascular integrity in the frozen hindpaw of the rat (8), these techniques were utilized, in this

investigation, to quantitatively evaluate the ability of buflomedil to ameliorate microcirculatory damage from acute experimentally induced frostbite.

MATERIALS AND METHODS

Male CD strain rats (Charles River Laboratories, Wilmington, MA) were housed in wire bottom rat cages with food and water available ad libitum. Seventy-one animals, weighing 351-415g, were used in this experiment. All animals were randomly placed in seven groups and anesthetized prior to experimentation with an intraperitoneal injection of sodium pentobarbital (70mg/kg body weight); if necessary, an additional dose of one-third the initial dose was administered. Group one contained 10 animals, group two contained 11 animals and groups three through seven contained 10 animals each. In all animals, a 23-gauge copper-constantan needle thermocouple was inserted 1 cm below the knee under the gastrocnemius muscles of the right and left hindlimbs and a 29-gauge copper-constantan needle thermocouple was inserted into the left and right hindfootpads. The thermocouples were read on a Leeds and Northrup Speedomax Recorder. Core temperatures were monitored with a rectal probe and maintained within normal limits throughout the experiments by circulating 37°C water through tubing coiled around the animals. The left hindlimbs of all animals were enclosed in finger cots and immersed in an alcohol bath to the distal end of the femurs. The limbs were cooled at an average rate of 1.0°C per minute, by an external gravity fed mixture of alcohol and dry ice, until freezing occurred in the footpads, as indicated by heat of fusion; cooling continued until the temperature in the footpads fell to -15°C (Fig. 1). The limbs were then withdrawn from the cooling bath and rapidly

rewarmed in a 40°C bath until the temperature under the gastrocnemius muscles reached 37°C. The right hindlimbs served as uninjured controls and were neither cooled nor rewarmed.

In the first part of this study, animals in groups one, two and three received intravenous injections of either saline or buflomedil (supplied by Abbott Laboratories) through cannulas placed in the tail veins. Control rats in group one received 1ml saline/kg immediately prior to cooling (Saline Prefreeze). Buflomedil (10mg/ml), in a dose of 10mg/kg, was administered to the rats in group two, also immediately prior to cooling (Buflomedil Prefreeze). Rats in group three received 10mg buflomedil/kg, at the end of the freeze, when cooling was complete (Buflomedil Postfreeze). In the second part of the study, 4.8ml of liquid solution were added to the sheaths surrounding the left hindlimbs of animals in groups four through seven, immediately after they were removed from the cooling bath, prior to rapid rewarming. Hindlimbs from group four were immersed in deionized water (Deionized Water), those from group five in 24mg buflomedil in deionized water (Buflomedil in Deionized Water), those from group six in 30% dimethyl sulfoxide (Me₂SO) and those from group seven in 24mg buflomedil in 30% Me₂SO (Buflomedil in Me₂SO).

Following rewarming, the left hindlimbs were removed from the 40°C bath. Vascular microcorrosion casts were then prepared as previously reported by Daum et al. (8). When the casting process was complete, the casts were weighed, mounted on stubs and sputter coated with gold-palladium prior to examination in a scanning electron microscope (SEM). The mean cast weights of the frozen hindpaws from all groups and the mean cast weights of the control hindpaws from all groups were analyzed for statistical significance using analysis of variance and the mean cast weights of the control and frozen hindpaws from each group were analyzed for statistical significance using paired-t test.

RESULTS

The mean weights of the casts from the control hindpaws of groups one (Saline Prefreeze), five (Buflomedil in Deionized Water) and six (Me₂SO) were significantly different from the mean weights of the casts from the frozen hindpaws of each respective group ($p < 0.05$), as were those of the casts from the control hindpaws of groups three (Buflomedil Postfreeze) and seven (Buflomedil in Me₂SO) when compared to the mean weights of the casts from the frozen hindpaws of their respective groups ($p < 0.005$) (Table 1). However, the mean weights of the casts from the control and frozen hindpaws of groups two (Buflomedil Prefreeze) and four (Deionized Water) were not significantly different from each other. Since the mean weights of the casts from the frozen hindpaws of these latter two groups are not different from those of groups one, three, five, six and seven and the mean weights of the casts from the control hindpaws of the two groups are the lowest for their mode of treatment, the lack of difference between the control and frozen hindpaws is probably due to variability resulting in decreased mean weight of the casts from the control hindpaws rather than to improved patency in the frozen hindpaws.

There was no significant difference when the mean weights of the casts from the frozen hindpaws of the seven groups were compared with each other. In the first part of the study a single intravenous dose of buflomedil, administered either prophylactically (Buflomedil Prefreeze) or therapeutically (Buflomedil Postfreeze), did not increase the amount of microvascular architecture retained after frostbite injury. Similarly, in the second part of the study, there was no statistically significant difference to indicate increased retention of the microvasculature in the frozen hindpaws that received the soak treatment (Table 1). However, the mean cast weight of the

control hindpaws from group seven (Buflomedil in Me₂SO) was significantly different from the mean cast weights of the control hindpaws from groups four (Deionized Water), five (Deionized Water in Buflomedil) and six (Me₂SO) ($p < 0.05$) (Table 1).

Scanning electron microscopic examination, as well as visual observation, of the vascular microcorrosion casts from all groups confirmed what was determined by the statistical analysis of their weights. A range of normal vascular tone was demonstrated by casts from the hindpaws of the seven control groups. Those from groups three (Buflomedil Postfreeze) and seven (Buflomedil in Me₂SO) replicated the vasodilatation which was pharmacologically induced by the buflomedil (Fig. 2) and SEM examination of them showed the complex patterns of the microvascular architecture (Fig. 3). Casts prepared from the frozen hindpaws of all groups showed the loss of the vast majority of the vascular network, especially vessels on the plantar surface and from the toes, that is characteristic of the injury, as represented in this model (Fig. 4), while SEM examination of the casts from these groups revealed a lack of continuity in the remaining microvasculature (Fig. 5).

DISCUSSION

The mode of action of buflomedil is not fully known; however, its major pharmacological action appears to be a non-specific inhibition of alpha-adrenergic action on vascular smooth muscle (9, 25). Recent studies indicate that it possesses antiplatelet aggregation activity and improves red cell deformability as well (5, 21). Buflomedil is distributed throughout the body fluid compartments and tissues where the pharmacological action of the drug

begins almost immediately after administration. The plasma half-life is approximately 2-3 hours (13). The recommended intravenous dosage of the drug is up to 200mg/day by infusion (9). It is generally well tolerated by patients, producing only minimal side effects which may include dizziness, nausea, headache, palpitation, tachycardia and rash (1, 9, 23). In human studies of vasculopathic patients, buflomedil pharmacologically increased perfusion of the microcirculation (5, 9, 10); arterial blood flow was also increased, with minimal effects on central hemodynamics. Patients with Raynaud's syndrome have also responded favorably to treatment with buflomedil (6, 17).

Foray et al. (11) reported a decrease in loss of tissue in human frostbite patients treated according to a protocol in which 50mg of buflomedil were slowly injected intravenously, immediately upon arrival in the hospital emergency room, prior to routine treatment which included a 38°C antiseptic bath, dextran perfusion, heparin therapy and antibiotics (11). Sixty-six per cent of the 12 patients treated in that protocol showed an improvement greater than that seen in 8 patients treated under a second protocol in which the initial infusion of buflomedil was administered after an examination and the routine treatment described above. Patients in both protocols received additional daily infusions of buflomedil throughout their hospitalization period, which varied according to the severity of the patient's condition.

The objective of our study was to utilize vascular microcorrosion casting as a direct method for quantitatively evaluating the potential of buflomedil as a therapeutic agent in an animal model for acute experimental frostbite. In the first portion of the study, when the mode of treatment was the intravenous administration of buflomedil either prophylactically or therapeutically, there was no improvement in the amount of microvasculature retained after freezing

injury. However, the mean weight of the casts from the control hindpaws of group three (Buflomedil Postfreeze) was considerably higher than, although not significantly different from, those of groups one and two. This increase in mean cast weight suggests that the vasodilator, administered following freeze, was given in a dose sufficient to dilate the vessels in the control hindpaw. The lack of increase in mean cast weight of the control hindpaws from group two (Buflomedil Prefreeze) may have been due to the timing of the administration of the vasodilator. In group three the drug was administered closer to the fixation and casting procedures than in group two, resulting in a more immediate effect on the vasculature of the uninjured tissue. Although the half-life of buflomedil is reported to be considerably longer than the time from injection of the drug to the initiation of fixation in group two (13), it may have been cleared early in those animals.

Cold induced vasospasm could override the ability of the drug to dilate the frozen paw, making it difficult for postfreeze administration to reverse the condition. In that case, the vasodilator would have had only limited access to the previously frozen tissue. Therefore, an alternate mode of treatment was chosen for delivery of buflomedil to the site of injury. In the second portion of this study, buflomedil was administered to the frozen hindpaws in a soak with Me₂SO during the rewarming period. The immersion of the injured hindpaws in buflomedil, in solution with Me₂SO which is reported to increase membrane permeability (16), resulted in the systemic distribution of the vasodilator as shown by the significant increase in the mean cast weight of group seven (Buflomedil in Me₂SO). Since another of the reported properties of Me₂SO is that of vasodilatory activity (15), it may have contributed to the significant increase in mean weight of the casts from those control hindpaws. Immersion in buflomedil in solution with deionized water did not produce a

similar result, indicating that it was not possible to deliver the drug in this manner without Me₂SO. Although the purpose for using Me₂SO was to deliver the vasodilator systemically, it has been previously used, alone, for the treatment of experimental frostbite (12, 26). The Me₂SO successfully delivered the buflomedil systemically, as indicated by the significant increase in the mean cast weight from the control hindpaws of group seven, however, there was no increase in the microvascular architecture retained in the frozen hindpaws after frostbite.

This acute study was undertaken with the expectation that the administration of the vasodilator buflomedil either immediately prior to or as close to the end of the freeze as possible, in a model utilizing rapid rewarming, would have the best possible chance for decreasing tissue loss. However, there was no significant improvement in the vascular patency of the frozen hindpaws when a single concentration of the drug was used in either the intravenous or the soak portion of this study. Therefore, in this acute model, the delivery of this peripheral vasodilator by either intravenous administration or systemic distribution in a soak with Me₂SO did not significantly increase the amount of microvasculature retained at the site of freeze injury. Ultimately, a chronic study might provide more comparable circumstances for further investigation, since the reported successful treatment of human frostbite patients was achieved after multiple infusions of buflomedil over time.

ACKNOWLEDGEMENTS

The investigators adhered to the "Guide for Laboratory Animal Facilities and Care" as promulgated by the Committee on the Guide for Laboratory Animal Facilities and Care of the Institute of Laboratory Animal Resources, National Academy of Sciences, National Research Council. The opinions or assertions contained herein are the private views of the authors and are not to be construed as official or as reflecting the views of the Department of the Army or the Department of Defense.

References

1. Balas, P., and Pagratis, N. Experience with buflomedil in peripheral arterial occlusive disease. *Angiology* 32, 679-685 (1981).
2. Bangs, C.C., and Hamlet, M.P. Hypothermia and cold injuries. In "Management of Wilderness and Environmental Emergencies" (P.S.Auerbach and E.C. Geehr, Eds.), pp. 27-63. Macmillan, New York, NY, 1983.
3. Bangs, C.C., Boswick, J.A., Hamlet, M.P., Sumner, D.S., and Weatherley-White, R.C.A. When your patient suffers frostbite. *Patient Care* 11, 132-157 (1977).
4. Barat, A.K., Puri, H.C., and Ray, N. Cold injuries in Kashmir, December 1971. *Ann. R. Coll. Surg. Engl.* 60, 332-335 (1978).
5. Battaglia, L., Valgiusti, D., and Di Paola, F.M. Our experience with the use of buflomedil chlorhydrate in a mixed population of vasculopathic patients. *J. Int. Med. Res.* 12, 63-72 (1984).
6. Courbier, R., Bergeron, P., and Fouque, R. Double-blind capillaroscopic study of the activity of buflomedil in Raynaud's syndrome: A report on 80 cases. *Angiology* 32, 676-678 (1981).
7. Cummings, R., and Lykke, A.W.J. The effects of anti-inflammatory drugs on vascular exudation evoked by cold injury. *Pathology* 5, 117-122 (1973).
8. Daum, P.S., Bowers, W.D., Jr., Tejada, J., and Hamlet, M.P. Vascular casts demonstrate microcirculatory insufficiency in acute frostbite. *Cryobiology* 24, 65-73 (1987).
9. Dubourg, A., and Scamuffa, R.F. An experimental overview of a new vasoactive drug: buflomedil HCL. *Angiology* 32, 663-675 (1981).

10. Fagrell, V.B. and Hermansson, I.L. Wirkung von buflomedil auf die mikro-zirkulation der haut bei akralgangran. Fortschr. Med. 103, 23-27 (1985).
11. Foray, J., Baisse, P.E., Mont, J.P., and Cahen, Cl. Le traitement des gelures de montagne. Sem. Hop. Paris 56, 490-497 (1980).
12. Gadarowski, J.J., Jr., and Esce, J.D. Therapeutic and prophylactic effect of dimethyl sulfoxide (Me₂SO) on frostbite injury in rabbits. Curr. Ther. Res. 34, 332-340 (1983).
13. Gundert-Remy, U., Weber, E., Lam, G., Chiou, W.L., Mann, W., and Aynilian, G.H. The clinical pharmacokinetics of buflomedil in normal subjects after intravenous and oral administration. Eur. J. Clin. Pharmacol. 20, 459-463 (1981).
14. Heggers, J.P., Robson, M.C., Manavalen, K., Weingarten, M.D., Carethers, J.M., Boertman, J.A., Smith, D.J., Jr., and Sachs, R.J. Experimental and clinical observations on frostbite. Annal. Emerg. Med. 16, 191-197 (1987).
15. Jackson, C.V., Karow, A.M., and Carrier, G.O. Influence of dimethyl sulfoxide (Me₂SO) on vascular smooth muscle. Arch. Int. Pharmacodyn. 237, 4-15 (1979).
16. Jacob, S.W., Bischel, M., and Herschler, R.J. Dimethyl sulfoxide: effects on the permeability of biologic membranes (preliminary report). Curr. Ther. Res. 6, 193-198 (1964).
17. Jacobs, M.J.H.M., and Lemmens, H.A.J. Microcirculatory changes in patients with primary Raynaud's phenomenon after treatment with buflomedil. Int. J. Microcirc.: Clin. Exp. 4, 63-68 (1985).

18. Kappes, B.M., and Mills, W.J. Thermal biofeedback training with frostbite patients. In "Proceedings of the Sixth International Symposium on Circumpolar Health", pp. 83-84 (1984).
19. Mills, W.J., Jr., Whaley, R., and Fish, W. Frostbite: Experience with rapid rewarming and ultrasonic therapy. Alaska Med. 3, 28-36 (1961).
20. Orr, K.D., and Fainer, D.C. Cold injuries in Korea during winter of 1950-51. U.S. Army Medical Research Laboratory, Fort Knox, Kentucky (1951).
21. Pacheco e Silva, A., and Landi de Almeida, S.M. Double blind comparative study of cinnarizine and buflomedil in patients suffering from cerebrovascular insufficiency. Angiology 32, 728-732 (1981).
22. Porter, J.M., Wesche, D.H., Rosch, J., and Baur, G.M. Intra-arterial sympathetic blockade in the treatment of clinical frostbite. Am. J. Surg. 132, 625-630 (1976).
23. Rosas, G., Cerdeyra, C., Lucas, M.A., Parano, J.R., and Villa, J.J. Comparison of safety and efficacy of buflomedil and naftidrofuryl in the treatment of intermittent claudication. Angiology 32, 291-297 (1981).
24. Shumacker, H.B., Jr., and Kilman, J.W. Sympathectomy in the treatment of frostbite. Arch. Surg. 89, 575-584 (1964).
25. Vanhoutte, P.M. Cardiovascular pharmacology of buflomedil. Bibl. Cardiol. 38, 209-221 (1984).
26. Wood, D.C., Weber, F.S., Larsen, J.B., and Smith J.C., II. Some experimental studies with dimethyl sulfoxide (DMSO) in cold injury. Curr. Ther. Res. 12, 97-110 (1970).

TABLE 1

Comparison of the Mean Weight of Casts from the Control and Frozen Hindpaws
(in mg \pm S.E.M.) of Groups One through Seven

Mode of Treatment		Cast Weights	
Intravenous		Control	Frozen
Group 1	Saline Prefreeze	80.80 \pm 10.18	45.25 \pm 10.75
Group 2	Buflomedil Prefreeze	75.52 \pm 12.51	48.99 \pm 8.84
Group 3	Buflomedil Postfreeze	101.84 \pm 6.95	31.16 \pm 7.49
Soak Postfreeze			
Group 4	Deionized Water	53.39 \pm 12.60	32.00 \pm 8.71
Group 5	Buflomedil in Deionized Water	59.61 \pm 11.92	30.43 \pm 8.84
Group 6	Me ₂ SO	76.71 \pm 13.16	31.50 \pm 7.84
Group 7	Buflomedil in Me ₂ SO	123.13 \pm 8.39	47.10 \pm 10.82

FIGURES

- Figure 1 The average temperature is shown under the left gastrocnemius muscles and in the left hindfootpads of groups one through seven. The characteristic change associated with heat of fusion is also shown.
- Figure 2 Photograph of a vascular microcorrosion cast from a control hindpaw from group seven (Buflomedil in Me₂SO).
- Figure 3 Scanning electron micrograph of a portion of a vascular microcorrosion cast from a control hindpaw from group seven.
Bar = 30um.
- Figure 4 Photograph of a vascular microcorrosion cast from a frozen hindpaw from group one (Saline Prefreeze).
- Figure 5 Scanning electron micrograph of a portion of a vascular microcorrosion cast from a frozen hindpaw from group one.
Bar = 30um.

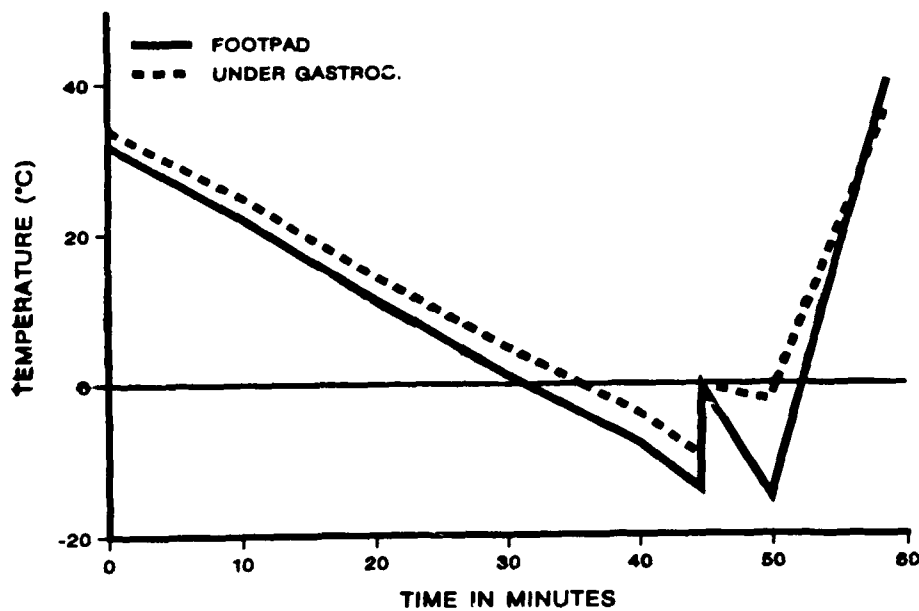


Figure 1

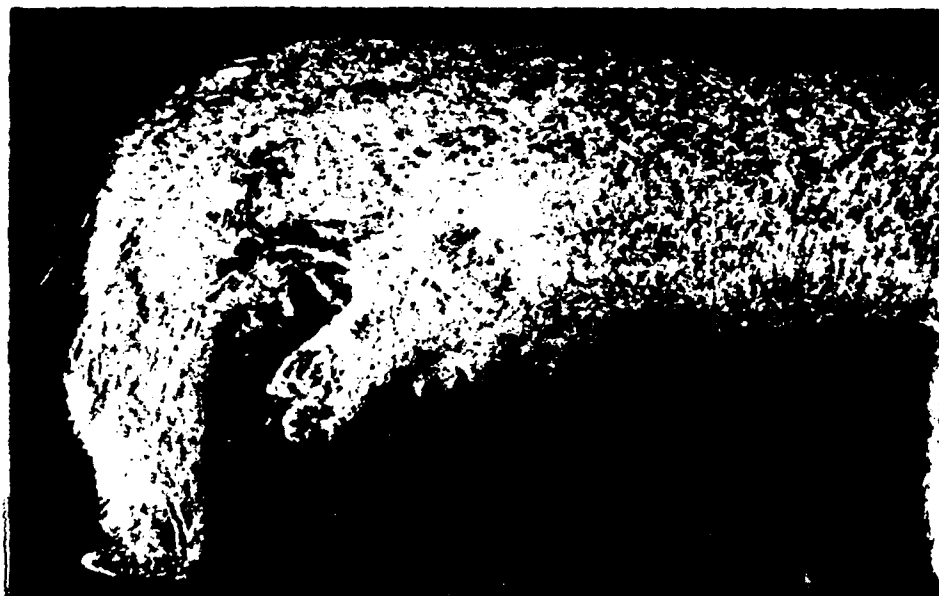

Figure 2




Figure 3



Figure 4

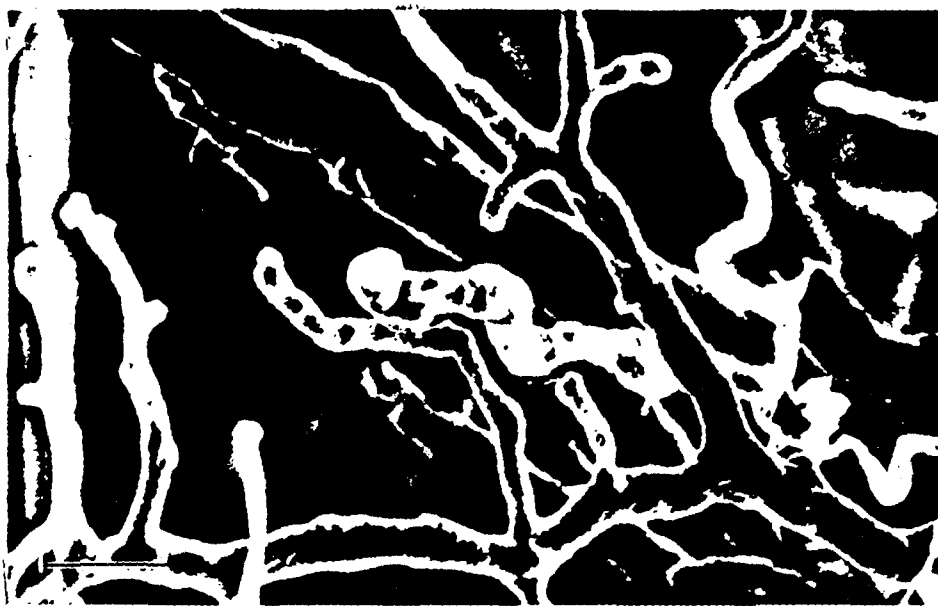


Figure 5