

(2)

Experimental Inhalation Injury in the Goat

HARREL L. WALKER, M.S., CHARLES G. McLEOD, JR., D.V.M., LTC, VC, AND
WILLIAM F. McMANUS, M.D., F.A.C.S.

ADA 112844

Inhalation injuries are usually produced by inhalation of gaseous or particulate products of incomplete combustion and are rarely due to heat per se unless steam is inhaled. The clinical and anatomic characteristics of an appropriate animal model should mimic the disease encountered clinically. A model of inhalation injury has been produced in anesthetized goats through the use of a modified bee smoker. The smoke is delivered at a low temperature and contains byproducts of incomplete combustion.

This reproducible injury produces necrotic tracheobronchitis and bronchiolitis with pseudomembrane and cast formation in association with mild multifocal atelectasis and bronchopneumonia. These lesions spontaneously resolve within 3 weeks without supportive therapy. The upper trachea, protected from smoke injury by the inflated cuff of the endotracheal tube, showed no evidence of injury. This nonlethal injury is proposed as an appropriate model for evaluation of the pathophysiology and treatment of inhalation injury.

DTIC
SELECTED
MAR 30 1982
S H

The incidence of inhalation injury in patients admitted to burn centers has been estimated to be from 15 to more than 30% (1). In a study of 100 patients admitted to the University of Wisconsin Burn Center and the Duke University Burn Service, 33 showed bronchoscopic evidence of inhalation injury (5). In spite of the remarkable recovery capacity of the respiratory system, the mortality rate in such cases is estimated to be from 48 to 86% (3). In patients with extensive burns, the mortality rate of those with inhalation injury exceeds that expected for patients without such injury (2).

Inhalation injuries commonly take the form of an inflammatory tracheobronchitis due to inhalation of gaseous or particulate products of incomplete combustion and are rarely due to heat alone unless steam has been inhaled (4). These toxic substances include acetic acid, acetic anhydride, oxides of nitrogen, acrolein, sulphur dioxide, formaldehyde, and cyanide.

As a result of improved techniques of early resuscitation, burned patients rarely succumb to shock or renal failure, which in the past were major causes of early

death. The impact of inhalation injury has thus become more prominent and emphasizes the need for an animal model of the injury independent of any complications caused by cutaneous burns.

This paper describes a model of inhalation injury in the goat in which reproducible nonlethal inhalation injury accompanies histologic changes which occur in a predictable manner. The clinical and anatomic characteristics of this model compare favorably with those of inhalation injury in man.

MATERIALS AND METHODS

Construction and Adaptation of Bee Smoker for Producing Inhalation Injury. Inhalation injury was produced in anesthetized goats using a modified bee smoker. A standard-sized bee smoker (model number N-3) manufactured by A. I. Root Company (San Antonio, TX) was adapted for attachment to an endotracheal tube. The nozzle of the smoker was removed from the can or body of the smoker and a brass adapter soldered to the opening of the nozzle. This brass adapter (3/4" long, 1" OD with a 5/16" ID) served to connect the endotracheal tube to the smoker nozzle. To prevent leakage of smoke, one of two brass rings (OD 5 3/4" and ID 4 1/4") was soldered to the base of the nozzle and the other to the top of the can or body of bee smoker (Fig. 1). A 5" neoprene (chloroprene rubber) ring was placed between the two brass rings and the rings were held firmly together and the nozzle secured to the can with two #10 paper clips (Fig. 2).

From the United States Army Institute of Surgical Research, Fort Sam Houston, Texas.

In conducting the research described in this report, the investigators adhered to the *Guide for Laboratory Animal Facilities and Care*, as promulgated by the Committee on the Guide for Laboratory Animal Facilities and Care of the Institute of Laboratory Animal Resources, National Academy of Sciences National Research Council.

The opinions or assertions contained herein are the private views of the authors and are not to be construed as official or as reflecting the views of the Department of the Army or the Department of Defense.

Address for reprints: Library, US Army Institute of Surgical Research, Fort Sam Houston, TX 78234.

DTIC FILE COPY

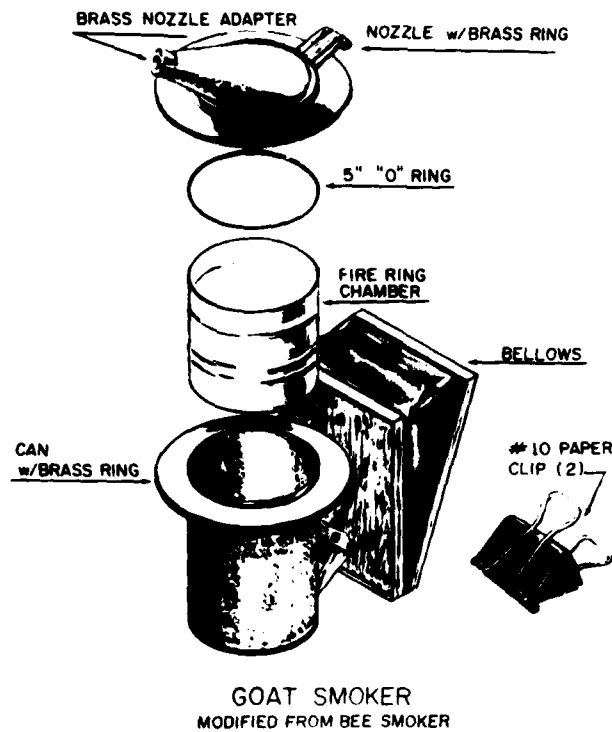


FIG. 1. Goat smoker, modified from bee smoker.



FIG. 2. Smoker with endotracheal tube attached.

Method of Inhalation Injury (Nonlethal). Twenty-two goats ranging in weight from 18 to 44 kg were used in this study. Food was withheld 24 hours before any study. Each animal was anesthetized with intravenous methohexital sodium, 10 to 15 mg/kg, placed in ventral recumbency on a flat surface, and intubated with a cuffed endotracheal tube of appropriate size.

The fire chamber of the bee smoker was half filled with dyed cotton towel waste, a fuel which resulted in uniform pulmonary injury. After ignition of the fuel, the smoker was connected to the endotracheal tube and

smoke delivered to the lungs by pushing the bellows 15 times. This procedure was repeated a total of four times, checking each time for adequate smoke production by the ignited waste, with a time lapse between each repetition of 1½ to 2 minutes.

Method of Temperature Monitoring. All temperature measurements were taken with a Tele-Thermometer (YSI Model 43SC, Yellow Springs Instrument Co.). The sensor end of the Tele-Thermometer probe was placed in the distal end of the endotracheal tube for measuring temperatures of the animal's trachea, the smoke produced by the smoking device, and the ambient air of the working area.

The temperature of the ambient air at the distal end of the endotracheal tube before intubation of the animal was found to be 26.5°C. After intubation of the animal, the temperature of the air rose to 37°C at the distal end of the endotracheal tube.

The temperature of the smoke produced by the device was measured and found to be 46°C at the distal end of the endotracheal tube before the animal was intubated. With the animal intubated, the temperature of the smoke delivered to the distal end of the endotracheal tube dropped to 39°C.

Pathology. For gross and microscopic studies of the lungs and tracheobronchial tree the animals were sacrificed on days 1, 2, 3, 5, 6, 7, 8, 9, 10, 14, and 15. Tissue samples were processed routinely for light microscopy.

RESULTS

No animals died from this procedure. They were eating and drinking normally within 24 hours after injury. Smoke exposure regularly produced necrotic tracheobronchitis and bronchiolitis with pseudomembrane and cast formation (Fig. 3). Sloughing casts composed of



FIG. 3. Trachea with sloughing necrotic mucosa. Darkened subpleural foci (arrow) represent atelectasis and mild pneumonia.




FIG. 4. Necrotic cellular casts (arrows) in bronchi of sections cut through right cranial lobe. Darkened areas represent atelectasis and mild acute bronchopneumonia.

necrotic respiratory epithelium (Fig. 4) occurred and were associated with a mild multifocal atelectasis and bronchopneumonia. These lesions resolved within 3 weeks without supportive therapy. In each goat, the upper segment of the trachea, which was protected from smoke injury by the inflated cuff on the endotracheal tube, showed no evidence of injury. Intubated control animals which were not insufflated with smoke showed no major lesions.

DISCUSSION

Moritz and his colleagues (4) observed in dogs that only when the temperature of heated air alone was high enough to produce instantaneous burning of the skin and upper respiratory mucosa was there sufficient residual heat in the air reaching the lungs to cause pulmonary injury. The same investigators experimented with inhaled steam; the resultant pulmonary injury was severe, and the animals survived only for 10 hours. Hot air, flame blast, and steam were used to produce inhalation injury in animals by these investigators and smoke was not included as part of their studies.

A murine model of inhalation injury has been described by Zawacki et al. (6). In this model, burned and unburned

mice exhibited reproducible responses and mortality following controlled exposures to smoke. However, burned mice receiving a 4-minute dose of 85°C smoke failed to develop major histologic changes in the trachea or lungs even though they lived several days before death occurred.

In earlier prototype studies a lethal inhalation injury in the goat was produced using a 70-cm endotracheal tube. The tip of the endotracheal tube extended to the carina of the trachea in an animal of the size used. The described smoking procedure using such an endotracheal tube resulted in a severe injury causing death of the animals in 12 to 18 hours. The rapid demise of such animals made study difficult and bore little resemblance to the clinically encountered disease. The experimental model of inhalation injury here described reliably and consistently produces histologic changes in the tracheo-bronchial tree resembling those seen in patients. The nonlethal inhalation injury as described will permit useful assessment of the pathophysiology and treatment of such injury. Infliction of both inhalation injury and cutaneous burn injury in the study animal may even allow one to study the interaction between such injuries.

Acknowledgment

The authors acknowledge the technical assistance of Harmut Arnhold for modifying a standard bee smoker to inflict inhalation injury, and John M. Powers for his artistic design of Figure 1.

REFERENCES

1. Achauer, B. M., Allyn, P. A., Furnas, D. W., et al.: Pulmonary complications of burns: The major threat to the burn patient. *Ann. Surg.*, 177: 311-319, 1973.
2. Agee, R. N., Long, J. M., III, Hunt, J. L., et al.: Use of ¹³³Xenon in early diagnosis of inhalation injury. *J. Trauma*, 16: 218-224, 1976.
3. Levine, B. A., Petroff, P. A., Slade, C. L., et al.: Prospective trials of dexamethasone and aerosolized gentamicin in the treatment of inhalation injury in the burned patient. *J. Trauma*, 18: 188-193, 1978.
4. Moritz, A. R., Henriques, F. C., Jr., McLean, R.: The effects of inhaled heat on the air passages and lungs: An experimental investigation. *Am. J. Pathol.*, 21: 311-325, 1945.
5. Moylan, J. A., Chan, C. K.: Inhalation injury—An increasing problem. *Ann. Surg.*, 188: 34-37, 1978.
6. Zawacki, B. E., Jung, R. C., Joyce, J., et al.: Smoke, burns, and the natural history of inhalation injury in fire victims: A correlation of experimental and clinical data. *Ann. Surg.*, 185: 100-110, 1977.

| | | | |
|--------------------|--------------------------|--------------------------|--------------------------|
| Accession For | <input type="checkbox"/> | <input type="checkbox"/> | <input type="checkbox"/> |
| STATE CLAIM | | | |
| ERIC T-D | | | |
| Unreproducible | | | |
| Justification | | | |
| By | | | |
| Distribution/ | | | |
| Availability Codes | | | |
| and/or | | | |
| Special | | | |
| | | | A 20 |

