

AD-A074 147


ARMY INST OF DENTAL RESEARCH WASHINGTON D C  
SCANNING ELECTRON MICROSCOPY OF TEETH IN AUTOSOMAL DOMINANT OST--ETC(U)  
AUG 79 J M BRADY, L S LEVIN, M MELNICK

F/6 6/5


UNCLASSIFIED

NL

| OF |  
ADA  
074147



END  
DATE  
FILMED  
10-79  
DDC



MICROCOPY RESOLUTION TEST CHART

NATIONAL BUREAU OF STANDARDS-1963-A

6

SECURITY CLASSIFICATION OF THIS PAGE (When Data Entered)

REPORT DOCUMENTATION PAGE

READ INSTRUCTIONS BEFORE COMPLETING FORM

1. REPORT NUMBER	2. GOVT ACCESSION NO.	3. RECIPIENT'S CATALOG NUMBER
------------------	-----------------------	-------------------------------

9/ Rept. for

TITLE (and Subtitle)	5. TYPE OF REPORT & PERIOD COVERED
----------------------	------------------------------------

Scanning Electron Microscopy of Teeth in Autosomal Dominant Osteogenesis Imperfecta: Support for Genetic Heterogeneity.

Manuscript for Publication  
1 Jul 78- 1 Aug 79

7. AUTHOR(s)	8. CONTRACT OR GRANT NUMBER(s)
--------------	--------------------------------

John M./Brady, L. Stefan/Levin, Michael Melnick

16

17/00

9. PERFORMING ORGANIZATION NAME AND ADDRESS	10. PROGRAM ELEMENT PROJECT, TASK AREA & WORK UNIT NUMBER
---	---

U. S. Army Institute of Dental Research  
Walter Reed Army Medical Center  
Washington, DC 20012

62775A, 3S762775A825  
00, 006

11. CONTROLLING OFFICE NAME AND ADDRESS	12. REPORT DATE
---	-----------------

U. S. Army Medical Research & Development Command  
HQDA-IS  
Fort Detrick, Maryland 21701

10 Aug 1979

14. MONITORING AGENCY NAME & ADDRESS (if different from Controlling Office)	13. NUMBER OF PAGES	15. SECURITY CLASS. (of this report)
---	---------------------	--------------------------------------

15

UNCLASSIFIED

15a. DECLASSIFICATION/DOWNGRADING SCHEDULE

**LEVEL**

16. DISTRIBUTION STATEMENT (of this Report)
---

This document has been approved for public release and sale; its distribution is unlimited.

12 23p

17. DISTRIBUTION STATEMENT (of the abstract entered in Block 20, if different from Report)
--

DDC  
RECEIVED  
SEP 24 1979  
E

18. SUPPLEMENTARY NOTES
-------------------------

None

19. KEY WORDS (Continue on reverse side if necessary and identify by block number)
--

038670 Lu

20. ABSTRACT (Continue on reverse side if necessary and identify by block number)
---

SEM studies were performed on 25 deciduous and permanent teeth from members of seven kindreds with autosomal dominant osteogenesis imperfecta (O.I.). Two families had normal teeth on clinical and radiological examination; five families had blue or brown opalescent teeth with specific radiologic findings. Enamel surfaces and prism organization were normal on all teeth. On fractured surfaces, the dentin tubules of normal teeth from patients with O.I. were evenly distributed and coursed regularly to the dentin-enamel junction. Opalescent teeth had few tubules; those tubules present were narrow, short, and tortuous.

AD A 0 7 4 1 4 7 6  
DDC FILE COPY

UNCLASSIFIED

SECURITY CLASSIFICATION OF THIS PAGE(When Data Entered)

20. Continued:

Dentin calcification fronts of normal teeth were composed of many mushroom shaped nodules, with regularly spaced openings on their surfaces. Calcification fronts of opalescent teeth were composed of irregularly spaced, small nodules, which varied greatly in size one from another; the nodules lacked tubule openings on their surfaces.

The results of this study support the concept that two autosomal dominant O.I. syndromes exist, one in which all individuals with O.I. have normal teeth, and the other in which all with O.I. have blue or brown opalescent teeth.

Accession For	
NTIS GRA&I	<input checked="" type="checkbox"/>
DDC TAB	<input type="checkbox"/>
Unannounced	<input type="checkbox"/>
Justification	
By _____	
Distribution/	
Availability Codes	
Dist	Availand/or special
A	



SCANNING ELECTRON MICROSCOPY OF TEETH  
IN AUTOSOMAL DOMINANT OSTEOGENESIS IMPERFECTA:  
SUPPORT FOR GENETIC HETEROGENEITY

John M. Brady\*  
L. Stefan Levin†  
Michael Melnick§

\*Division of Oral Biology  
United States Army Institute of Dental Research  
Walter Reed Army Medical Center  
Washington, DC 20012

†Johns Hopkins Hospital  
Baltimore, Maryland

§Laboratory for Developmental Biology  
University of Southern California  
Los Angeles, California

ABSTRACT

Scanning electron microscopic studies were performed on 25 deciduous and permanent teeth from members of seven kindreds with autosomal dominant osteogenesis imperfecta (O.I.). Two families had normal teeth on clinical and radiological examination; five families had blue or brown opalescent teeth with specific radiologic findings. Enamel surfaces and prism organization were normal on all teeth. On fractured surfaces, the dentin tubules of normal teeth from patients with O.I. were evenly distributed and coursed regularly to the dentin-enamel junction. Opalescent teeth had few tubules; those tubules present were narrow, short and tortuous. Dentin calcification fronts of normal teeth were composed of many mushroom shaped nodules, with regularly spaced openings on their surfaces. Calcification fronts of opalescent teeth were composed of irregularly spaced, small nodules, which varied greatly in size one from another; the nodules lacked tubule openings on their surfaces.

The results of this study support the concept that two autosomal dominant O.I. syndromes exist, one in which all individuals with O.I. have normal teeth, and the other in which all with O.I. have blue or brown opalescent teeth.

## INTRODUCTION

Osteogenesis imperfecta (O.I.) is a group of heritable disorders of connective tissue characterized, in general, by bone fragility, blue sclerae, hearing impairment, dental anomalies, ligamentous laxity and cardiovascular abnormalities (1). Considerable interfamilial phenotypic variation has been noted, suggesting that several O.I. syndromes exist. Several clinical classifications have been proposed (2-9), but none is definitive, primarily because the biochemical defects are unknown.

Abnormalities of the dentition, although well known features of some types of O.I., have usually been neglected when formulating a clinical classification. The teeth in some patients with O.I. are blue or brown and opalescent. They have particular radiologic abnormalities including bulbous crowns, constricted coronal-radicular junctions, and partially or completely obliterated pulp chambers and root canals (10). Levin et al. (11) described consistent dental findings in families with autosomal dominant O.I.: in one group of families, all patients with O.I. had opalescent teeth; in another group of families, all patients with O.I. had normal teeth. These investigators suggested that at least two different autosomal dominant osteogenesis imperfecta syndromes exist, based on the presence or absence of specific dental abnormalities.

In order to test this hypothesis more accurately, scanning electron microscopy (S.E.M.) was performed on teeth from each group. These studies allowed for a more refined definition of the dental portion of the phenotype.

## MATERIALS AND METHODS

Twenty-five exfoliated or extracted deciduous and per-



manent teeth were collected from 16 members of 7 kindreds with autosomal dominant O.I. Nine of the 25 teeth were from two families whose members with O.I. had normal teeth on clinical and radiologic examination. The remaining 16 teeth were from 5 families with O.I. whose affected members had opalescent teeth. All except four of the patients who donated teeth had previously been examined by one of us (L.S.L.). History obtained on the four unexamined individuals was sufficient to confirm the diagnosis of O.I.

Teeth were radiographed to locate the pulp chambers and root canals. The teeth were fractured longitudinally through their pulpal spaces where possible, deproteinized using 5% sodium hypochlorite, dehydrated through a graded ethanol series, mounted on aluminum stubs, sputterer-coated\* with a 100-200 Å thick layer of gold-palladium, and examined using a AMR scanning electron microscope.\*\* Teeth without radiographic evidence of pulp chambers or root canals were fractured as closely as possible to where a pulp chamber and root canal would have been expected to be.

Nine opalescent teeth (five deciduous and four permanent) and four normal teeth (two deciduous and two permanent) from patients with O.I. were decalcified in 4.13% ethylenediamine-tetraacetic acid (12), dehydrated through a graded ethanol series, infiltrated with amyl acetate and critical point dried in liquid carbon dioxide.\*\*\* The specimens were then mounted

\*Hummer I Sputterer Coater, Technics, Inc., Alexandria, Virginia.

\*\*AMR 1000 Scanning Electron Microscope. AMR Corp., Bedford, Massachusetts.

\*\*\*Samdri PVT-3 Critical Point Drying Apparatus, Tousimis Research Corporation, Rockville, Maryland.

on aluminum stubs, sputterer-coated and examined using S.E.M. for the purpose of evaluating the morphology of the dentin-enamel junctions. Deciduous and permanent teeth from 12 individuals who did not have O.I. served as controls; these teeth had either exfoliated normally or had been removed for orthodontic or periodontic reasons.

## RESULTS

No differences were found on S.E.M. between the enamel surfaces of opalescent and nonopalescent teeth from patients with O.I., and teeth from controls, nor were abnormalities of prism organization seen on fracture planes.

The fractured dentin surfaces of deciduous and permanent teeth from patients with O.I. whose teeth were clinically and radiologically normal were similar (Fig. 1). The dentin tubules were evenly distributed, parallel to one another, and coursed regularly from the dentin-enamel and dentin-cementum junctions toward the dentin-predentin interface. In contrast, the number of dentin tubules seen on fractured dentin surfaces of deciduous and permanent teeth from patients with O.I. whose teeth were opalescent was markedly reduced (Fig. 2). In some opalescent teeth, remnants of dentin tubules were difficult to find. Tubules were narrow, short, tortuous, and scattered haphazardly throughout the dentin surface. No normal mantle dentin was found.

Calcification fronts of deciduous and permanent teeth from patients with O.I. and normal dentitions were composed of many mushroom-shaped nodules with regularly spaced tubule openings evenly distributed on their surfaces (Fig. 3). Calcification



front morphology was similar to control teeth. The calcification fronts of opalescent teeth, on the other hand, were composed of irregularly spaced smaller nodules markedly dissimilar in size from one another, and lacking openings for odontoblastic processes (Fig. 4). The calcification fronts of carious control teeth were similar to those in opalescent teeth; however in control teeth, only the portion of the front adjacent to the carious lesion was irregular (Fig. 5).

The fractured dentin surface of a fully developed, impacted maxillary second premolar from a patient with O.I. and opalescent teeth had abnormal and sparse tubules, similar to those found in erupted teeth of other patients with opalescent dentin (Fig. 6). However, the calcification front was similar to that found in normal teeth (Fig. 7). On radiographs, the pulp chamber was obliterated but the root canal was patent. All three of the other teeth from this patient examined as well as one deciduous tooth from a relative had the previously described scanning electron microscopic findings of opalescent dentin. No other impacted teeth from patients with opalescent dentin were available for study.

The predominant feature of the dentin-enamel junctions after decalcification with EDTA was an array of interconnected, elevated ridges or scallops (Fig. 8). The scalloped structures were confined to the middle and incisal dentin surfaces and were absent from the gingival region. These ridges were more prominent in the permanent than in the deciduous teeth (Fig. 9). There were no differences in the size or number of scalloped structures

between control and opalescent teeth (Fig. 9).

#### DISCUSSION

The scanning electron microscopic findings on teeth from patients with O.I. support the clinical observations of Levin et al. (11) that two autosomal dominant O.I. syndromes exist, based on the presence or absence of opalescent teeth. That is, clinically and radiologically normal teeth from families with O.I. are normal on S.E.M., while opalescent teeth have few dentin tubules on longitudinal section, and have morphologic abnormalities on their calcification fronts. Whether these two O.I. syndromes are determined by mutations at different loci, or are allelic disorders is unknown. Linkage studies and determination of the basic biochemical defect(s) will aid in resolving this question.

Scanning electron microscopic findings on one tooth from a patient with O.I. and opalescent teeth have previously been reported (13). Reduction in size and number of dentin tubules was noted. Since the calcification front was not described in that report, and the mode of inheritance was unknown, further comparisons with our findings are not possible.

The calcification front of one impacted opalescent tooth studied was indistinguishable from controls. However, its fractured dentin surface resembled that seen in erupted opalescent teeth. These findings were interpreted to mean that normal numbers of odontoblasts function during development of opalescent teeth and that the dentin tubules are occluded subsequent to primary dentin production which is initially morpholog-

ically normal. Our observations also indicate that obliteration of the pulp chamber prior to eruption is not dependent on eruption or post-eruptive forces. However, since only one impacted tooth was evaluated, further studies are necessary.

Reparative dentin under carious lesions may resemble the calcification front in opalescent teeth, so findings in this region may be difficult to interpret. On the other hand, fractured dentin surfaces of opalescent teeth are distinctive regardless of caries or eruption status, and therefore are the more definitive for diagnostic purposes.

Opalescent deciduous teeth in patients with autosomal dominant O.I. wear more easily than normal (14-16). Levin et al. (17) examined 13 children with O.I. and opalescent primary teeth and noted that 12 had abnormal occlusal wear at least on deciduous incisors. The one child without unusual wear was one year of age and had four erupted deciduous incisors only. Of the seven children with O.I. examined who had clinically and radiologically normal teeth, none had abnormal wear. Attrition has also been described in teeth of individuals with dentinogenesis imperfecta (D.I.) without O.I. (10,18,19). The clinical and radiographic features of the dentition in D.I. are similar to those found in O.I. although the disorders are genetically different (10). On light microscopy, teeth from patients with D.I. are said to have reduced or abnormal scalloping at the dentin-enamel interface (20). The presumed lack of scalloping is believed to result in loss of mechanical retention of the enamel. Consequently, the enamel fractures easily and leaves the dentin exposed to chewing forces (21,22). Rapid and excessive wear then occur.



Since a similar mechanism could be responsible for the wear found in opalescent teeth in patients with O.I. (23), dentin-enamel junctions of opalescent teeth were examined. No differences in the scalloped dentin surfaces were noted between opalescent and normal teeth from patients with O.I. and controls. Our findings in teeth from normal individuals confirm those reported by Whittaker (24). Therefore, enamel loss from opalescent teeth in O.I. is not likely initiated by fracture between the enamel and dentin since no morphologic abnormalities were found at the dentin-enamel junction. Fracture elsewhere, either within the abnormal dentin as proposed by others (25), or through the enamel which, although normal on SEM, may have a molecular defect, are alternative hypotheses.

Witkop and Rao (10) have reported that opalescent teeth in patients with O.I. which develop early in life are more severely affected than those which develop later. Using S.E.M., we were unable to confirm their observations and found all opalescent teeth examined to be similar.

ACKNOWLEDGMENTS

This project was supported, in part, by a National Institutes of Health Research Career Development Award KO4 DE00021 (Dr. Levin).

The authors thank SP4 Juan Morales, Mr. Walter Gray, Ms. Susan Piniecki and Ms. Patricia Rocks for their technical assistance, as well as the patients who participated in the study.

MILITARY DISCLAIMER

The opinions or assertions contained herein are the private views of the authors and are not to be construed as reflecting the view of the Department of the Army or the Department of Defense.

HUMAN USE STATEMENT

Teeth specimens were from a collection at the Johns-Hopkins Hospital. Electronmicroscopy was performed at the United States Army Institute of Dental Research. The investigation was approved by the Committee on Investigations at the Johns-Hopkins Hospital. All patients signed a human-use consent form.



REFERENCES

1. McKusick VA: "Heritable Disorders of Connective Tissue."  
St. Louis: The C.V. Mosby Co., 1972, pp. 390-454.
2. Bauze RJ, Smith R, Francis MJO: A new look at osteogenesis imperfecta. A clinical, radiological and biochemical study of forty-two patients. J Bone Jt Surg 57B: 2-12, 1975.
3. Smith R, Francis MJO, Bauze RJ: Osteogenesis imperfecta. A clinical and biochemical study of a generalized connective tissue disorder. Quart J Med 44:555-573, 1975.
4. Ibsen KH: Heterogeneity in osteogenesis imperfecta. Birth Def: Orig Art Ser 5:140-144, 1969.
5. Francis MJO, Bauze RJ, Smith R: Osteogenesis imperfecta: a new classification. Birth Def:Orig Art Ser 11:99-102, 1975.
6. Sillence DO, Rimoin DL: The classification of osteogenesis imperfecta. Lancet i:1041-1042, 1978.
7. Falvo KA, Root L, Bullough PG: Osteogenesis imperfecta: clinical evaluations and management. J Bone Jt Surg 56A: 783-793, 1974.
8. Sillence DO, Rimoin DL, Danks DM: Clinical variability in osteogenesis imperfecta-variable expression or genetic heterogeneity. Birth Def:Orig Art Ser 1979 (in press).
9. Sillence DO, Senn A, Danks SM: Genetic heterogeneity in osteogenesis imperfecta. J Med Gen 16:101-116, 1979.

10. Witkop CJ Jr, Rao S: Inherited defects in tooth structure. Birth Def:Orig Art Ser 7(7):153-184, 1971.
11. Levin LS, Salinas CF, Jorgenson RJ: Classification of osteogenesis imperfecta by dental characteristics. Lancet i:332-333, 1978.
12. Warshawsky H, Moore G: A technique for the fixation and decalcification of rat incisors for electron microscopy. J Histochem Cytochem 15:542-549, 1976.
13. Skinner HCW, Bartz Z, Ladenbauer-Bellis I, Pooley A, Albright JA: Scanning electron microscopy of osteogenesis imperfecta and normal deciduous human dentin. J Dent Res 57:418-419, 1978.
14. Bergman G: Studies on mineralized dental tissues. XIV. The incremental pattern of the dentine in a case of osteogenesis imperfecta. Oral Surg 13:70-75, 1960.
15. Velley J: Étude clinique et génétique de la dentinogénèse imparfaite héréditaire. Actual Odontostomatol (Paris) 28:519-532, 1974.
16. Hayes FM, Blattner RJ, Robinson HBG: Osteogenesis imperfecta and odontogenesis imperfecta: clinical and genetic aspects in eighteen families. J Ped 56:234-245, 1960.
17. Levin LS, Salinas CF, Jorgenson RJ: Unpublished observations, 1978.

18. Bixler D, Conneally PM, Christen AG: Dentinogenesis imperfecta: genetic variations in a six-generation family. J Dent Res 48:1196-1199, 1969.
19. Mars M, Farrant S, Roberts GT: Dentinogenesis imperfecta. Report of a 5-generation family. Brit Dent J 140:206-209, 1976.
20. Witkop CJ, Jr: Hereditary defects of dentin. Dent Clin NA 19:25-45, 1975.
21. Alley TR, Burkett LW: Hereditary opalescent dentine. Oral Surg 6:328-334, 1953.
22. Hodge HC, Finn SB, Robinson HBG, Manley RS, Manly M LeF, Van Huysen G, Bale WF: Hereditary opalescent dentin. III. Histological, chemical and physical studies. J Dent Res 19:521-536, 1940.
23. Gorlin RJ: Oral Syndromes. Chapter 26, In Tiecke RW (ed); "Oral Pathology," New York: McGraw-Hill Book Company 1965, pp. 657.
24. Whittaker DK: The enamel-dentine junction of human and Macaca irus teeth: a light and electron microscopic study. J Anat 125:323-335, 1978.
25. Bergman G, Engfeldt B: Studies on mineralized dental tissues. IV. Biophysical studies on teeth and tooth-germs in osteogenesis imperfecta. Acta Path Microbiol Scand 35:537-548, 1954.



-14-  
FIGURES

- Fig. 1. Scanning electron micrograph (SEM) of the fractured dentin surface of a mandibular permanent first molar from a patient with O.I. and normal teeth. Dentin tubules are parallel and evenly distributed. Original magnification 1600X.
- Fig. 2. SEM of the fractured dentin surface of a primary central incisor from a patient with O.I. and opalescent teeth. Dentin tubules are narrow, short, tortuous and few in number. Original magnification 1600X.
- Fig. 3. SEM of the calcification front of the dentin of a permanent molar from a patient with O.I. and normal teeth. Nodules of calcification are hemispherical. Patent tubules are evenly distributed on their surfaces. Original magnification 1500X.
- Fig. 4. SEM of the calcification front of the dentin of a maxillary permanent central incisor in a patient with O.I. and opalescent teeth. Calcification nodules are irregular and smaller than normal. No patent tubules are observed. Original magnification 1400X.
- Fig. 5. SEM of calcification front of a carious tooth, immediately beneath carious lesion. There are scattered patent tubule openings. Original magnification 1440X.
- Fig. 6. SEM of the fractured dentin surface of an impacted maxillary second premolar from a patient with O.I. and opalescent teeth. There are few dentin tubules;

numerous atubular spaces are present in the inter-tubular dentin. Original magnification 1600X.

Fig. 7. SEM of the calcification front of the tooth seen in Fig. 5. The front is similar to the front in normal teeth (see Fig. 3). Original magification 1400X.

Fig. 8. SEM of the coronal surface of a normal permanent maxillary molar after decalcification with EDTA. Scalloping is the predominant feature of the middle and occlusal regions of the dentino-enamel junctions. Original magnification 30X.

Fig. 9. SEM's of the middle third of the buccal surfaces of teeth after decalcification with EDTA.

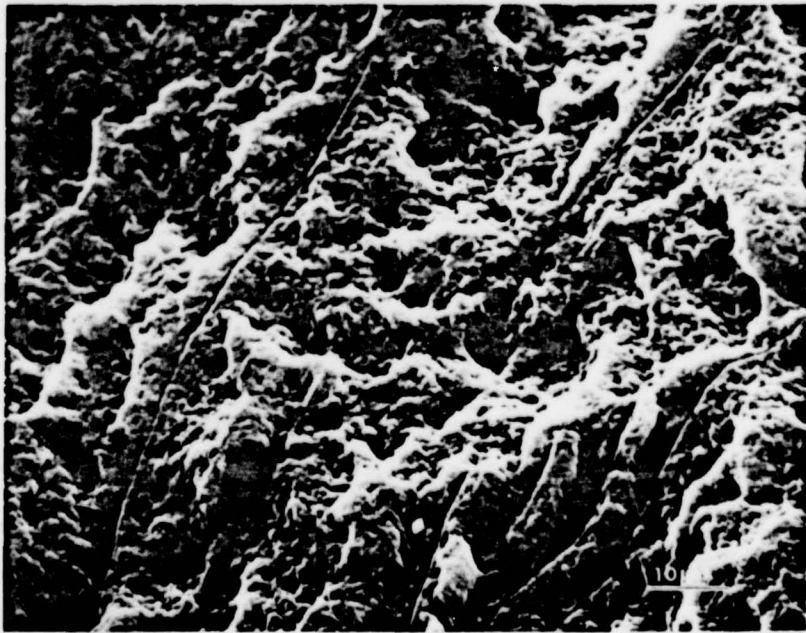
- a. Normal permanent maxillary molar
- b. Normal deciduous molar
- c. Permanent mandibular molar from a patient with O.I. and opalescent teeth
- d. Deciduous incisor from a patient with O.I. and opalescent teeth.

There is less scalloping of the dentin-enamel junction in deciduous than in permanent teeth. Opalescent teeth are no different from normal in the appearance of the scalloping. Original magnifications 750X.

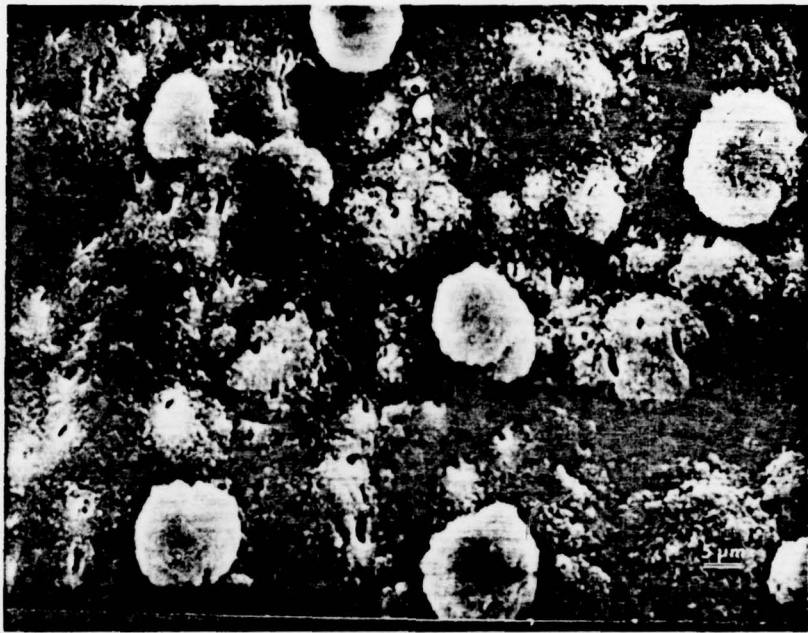




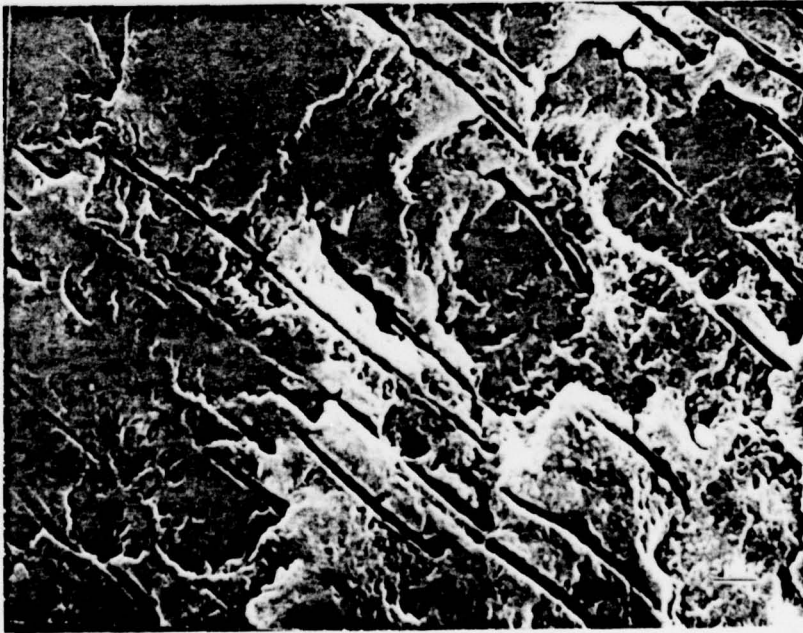
1



2



5




6



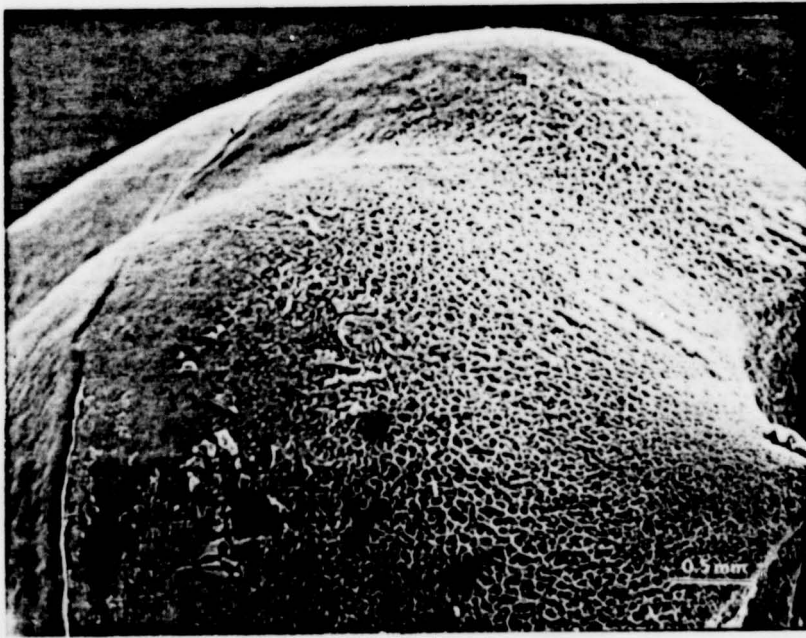
3



4

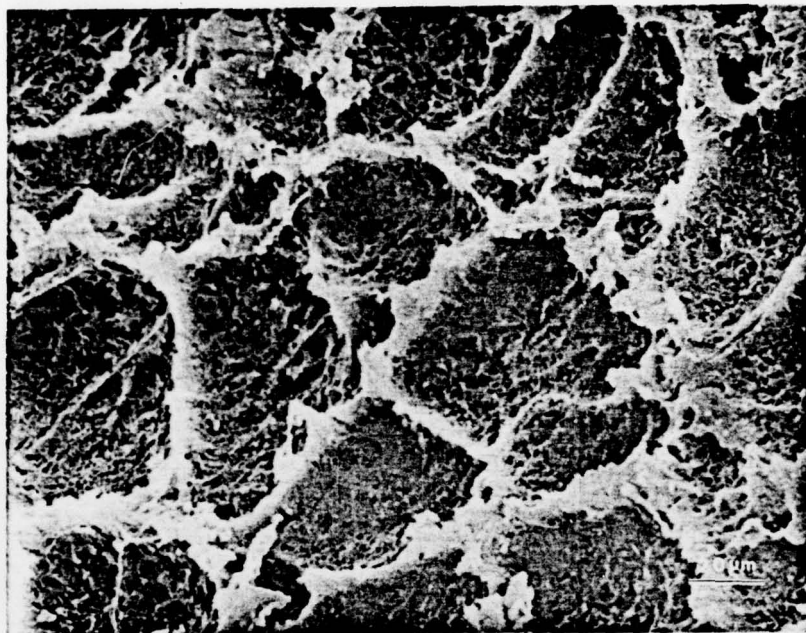


-7

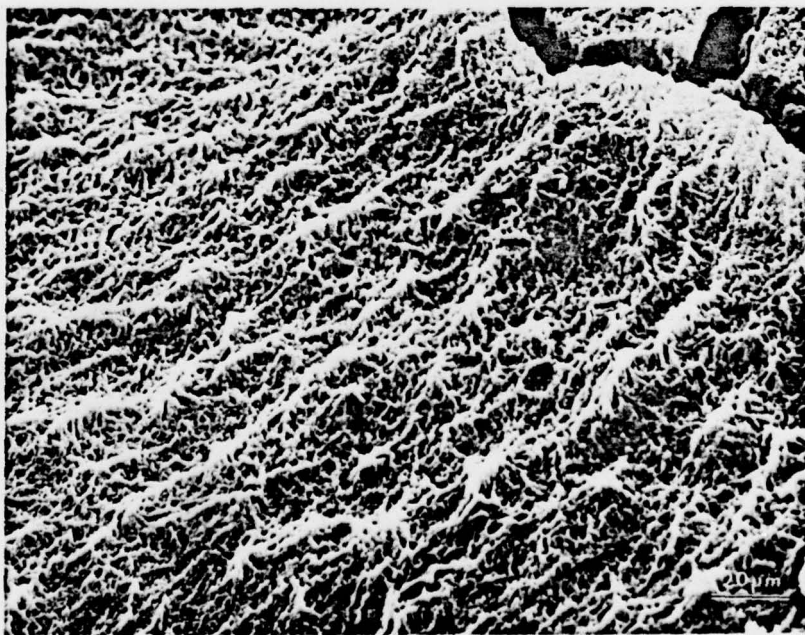


8



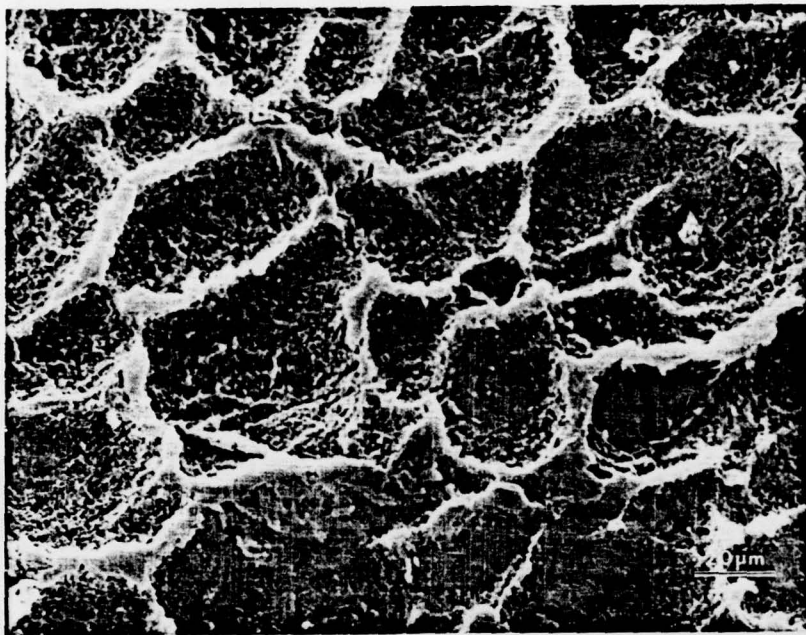


9a




9b





9c



9d

