

AD-A067 630

TUFTS UNIV BOSTON MASS SCHOOL OF DENTAL MEDICINE  
RESORBABLE CERAMICS FOR AUGMENTATION OF ATROPHIC RESIDUAL RIDGE--ETC(U)  
NOV 78 L J STANWICH, N J SHEPHERD, H C DOKU DADA17-73-C-3105

F/G 6/5

UNCLASSIFIED

NL

| OF |

AD  
A067630



## REPORT DOCUMENTATION PAGE

**LEVEL II****(13)**READ INSTRUCTIONS  
BEFORE COMPLETING FORM

1. REPORT NUMBER <b>DADA 17-73-C-3105</b>	2. GOVT N	3. REPORT NUMBER N
4. TITLE (and Subtitle) <b>RESORBABLE CERAMICS FOR AUGMENTATION OF ATROPHIC RESIDUAL RIDGES</b>		5. TYPE OF REPORT & PERIOD COVERED <b>FINAL COMPREHENSIVE REPORT</b>
		6. PERFORMING ORG. REPORT NUMBER
7. AUTHOR(s) <b>Lawrence J. Stanwich, D.D.S. Norman J. Shepherd, D.M.D. H. Chris Doku, D.M.D., M.S.D. Edmund F. Cataldo, Jr., D.D.S., M.S.</b>	8. CONTRACT OR GRANT NUMBER(s) <b>DADA-17-72-C2094 DADA-17-73-C-3105</b>	
9. PERFORMING ORGANIZATION NAME AND ADDRESS <b>TUFTS UNIVERSITY SCHOOL OF DENTAL MEDICINE ONE KNEELAND STREET BOSTON, MASSACHUSETTS 02111 354 750</b>		10. PROGRAM ELEMENT, PROJECT, TASK AREA & WORK UNIT NUMBERS <b>62110A 3A162110A835.00.004</b>
11. CONTROLLING OFFICE NAME AND ADDRESS <b>U.S. ARMY MEDICAL RESEARCH AND DEVELOPMENT COMMAND Frederick, MARYLAND 21701</b>		12. REPORT DATE <b>NOVEMBER 1978</b>
14. MONITORING AGENCY NAME & ADDRESS (if different from Controlling Office)		13. NUMBER OF PAGES <b>29</b>
		15. SECURITY CLASS. (of this report) <b>UNCLASSIFIED</b>
		15a. DECLASSIFICATION/DOWNGRADING SCHEDULE
16. DISTRIBUTION STATEMENT (of this Report) <b>APPROVED FOR PUBLICATION: DISTRIBUTION UNLIMITED</b>		
17. DISTRIBUTION STATEMENT (of the abstract entered in Block 20, if different from Report)		
18. SUPPLEMENTARY NOTES		
19. KEY WORDS (Continue on reverse side if necessary and identify by block number) <b>RIDGE AUGMENTATION TRICALCIUM PHOSPHATE BONE IMPLANT CERAMIC IMPLANT</b>		
20. ABSTRACT (Continue on reverse side if necessary and identify by block number) <b>The purpose of the study that we have carried on since March of 1972 has been to evaluate biodegradable ceramic as an augmentation material to atrophic mandibles. We wished to investigate the effectiveness and predictability of using either tricalcium phosphate ceramic or calcium aluminate to repair skeletal defects. In particular, we attempted to increase the height of atrophic mandibular ridges such that remedial prosthetic appliances could be constructed more easily and worn more successfully.</b>		

**DDC****RECEIVED**  
**APR 19 1979**  
**REGULATED**  
**D**DDC FILE COPY  
AD A067630

## 20. Abstract (continued)

In order to construct new higher mandibular ridges, a series of experimental steps were necessary. We started comparing small pieces of ceramic in small animals and progressed to larger pieces in larger animals. Each phase consisted of preparing the receptor sites, inserting ceramic implants and evaluating the acceptance of the implants over specific lengths of time. Our results show that: (1) in the mandible tricalcium phosphate is a better material to use than calcium aluminate; (2) it is possible to grow new bone higher than surrounding cortex when using small ceramic implants; (3) it is possible to augment large sections of mandible by inserting the ceramic beneath raised osteoplastic flaps.

Our conclusions are that tricalcium phosphate can be used to augment mandibular ridges if the material is placed in such a way that: (a) a good blood supply is available; (b) the implant is surrounded by viable bone as much as possible and (c) the implant is protected during healing period. We feel that the techniques we used on dogs can be refined in monkeys because of their human-like jaw structure and ultimately can be used in humans to aid in atrophic mandibular ridge augmentation.

CLASSIFICATION		
1.1	White Section	<input checked="" type="checkbox"/>
1.2	Ref Section	<input type="checkbox"/>
ANNOUNCED		<input type="checkbox"/>
CLASSIFICATION		
DISTRIBUTION/AVAILABILITY CODES		
1.1	AVAIL. and/or SPECIAL	
A		

FINAL REPORT

⑥ RESORBABLE CERAMICS FOR AUGMENTATION OF ATROPHIC  
RESIDUAL RIDGES.

FINAL COMPREHENSIVE REPORT

⑩ LAWRENCE J. STANWICH, D.D.S.  
NORMAN J. SHEPHERD, D.M.D.  
H. CRIS DOKU, D.M.D., M.S.D.  
EDMUND F. CATALDO, JR., D.D.S., M.S.

⑪ NOVEMBER 1978

SUPPORTED BY: U.S. ARMY MEDICAL RESEARCH  
AND DEVELOPMENT COMMAND  
FORT DETRICK, FREDERICK  
MARYLAND 21701

⑫ 29 p.

⑮ CONTRACT NOS. DADA17-73-C-3105, &  
DADA17-72-C-2094

⑨ Final rept.

TUFTS UNIVERSITY SCHOOL OF DENTAL MEDICINE  
ONE KNEELAND STREET  
BOSTON, MASSACHUSETTS 02111

APPROVED FOR PUBLIC RELEASE: DISTRIBUTION UNLIMITED

THE FINDINGS OF THIS REPORT ARE NOT TO BE  
CONSTRUED AS AN OFFICIAL DEPARTMENT OF  
THE ARMY POSITION UNLESS SO DESIGNATED BY  
OTHER AUTHORIZED DOCUMENTS.

⑬ 3A16211/A835

⑭ 00

DDC  
RECEIVED  
APR 19 1979  
D

69 04 10 025  
354 750

elt



## TABLE OF CONTENTS

Summary	Page 1
Forward	Page 2
Body of Report: Statement of Problem	Page 2
Background	Page 3
Approach, Methods and Materials	Page 4
Theory	Page 4
Phase I	Page 5
Phase II	Page 6
Phase II - Results	Page 6
Phase III	Page 8
Phase III (a)	Page 8
Phase III (b)	Page 9
Phase IV	Page 10
Phase V	Page 11
Results of Phase V	Page 12
Conclusions	Page 13
Recommendations	Page 13
Bibliography	Page 14
Appendix: Illustrations	
1. Preoperative View of Edentulous Body of Mandible.	
2. Augmented Section of Mandible 40 Weeks after Surgery.	
3. Preoperative Radiograph of Receptor Site in Edentulous Mandible.	
4. Radiograph of Tricalcium Phosphate Covered with Host Cortex One Month Post Insertion.	
5. Radiograph of Receptor Site 6 Months Post-Operatively.	
6. Cross Section of Mandible with Triangular-Shaped Ceramic Implant Mounted Superior to Neurovascular Bundle.	
7. Higher Power View of Illustration No. 6.	
8. Cross Section of 22 Week Specimen.	
9. Cross Section of 40 Week Specimen.	

SUMMARY

The purpose of the study that we have carried on since March of 1972 has been to evaluate biodegradable ceramic as an augmentation material to atrophic mandibles. We wished to investigate the effectiveness and predictability of using either tricalcium phosphate ceramic or calcium aluminate to repair skeletal defects. In particular, we attempted to increase the height of atrophic mandibular ridges such that remedial prosthetic appliances could be constructed more easily and worn more successfully.

In order to construct new higher mandibular ridges, a series of experimental steps were necessary. We started comparing small pieces of ceramic in small animals and progressed to larger pieces in larger animals. Each phase consisted of preparing the receptor sites, inserting ceramic implants and evaluating the acceptance of the implants over specific lengths of time. Our results show that: (1) in the mandible tricalcium phosphate is a better material to use than calcium aluminate; (2) it is possible to grow new bone higher than surrounding cortex when using small ceramic implants; (3) it is possible to augment large sections of mandible by inserting the ceramic beneath raised osteoplastic flaps.

Our conclusions are that tricalcium phosphate can be used to augment mandibular ridges if the material is placed in such a way that: (a) a good blood supply is available; (b) the implant is surrounded by viable bone as much as possible and (c) the implant is protected during the healing period. We feel that the techniques we used on dogs can be refined in monkeys because of their human-like jaw structure and ultimately can be used in humans to aid in atrophic mandibular ridge augmentation.

## FORWARD

In conducting the research described in this report, the investigators adhered to the "Guide for Laboratory Animal Facilities and Care", as promulgated by the Committee on the Guide for Laboratory Animal Resources, National Academy of Sciences-National Research Council.

## BODY OF REPORT

### STATEMENT OF PROBLEM

The elimination of osseous defects and skeletal augmentation is of universal concern common both to dentistry and medicine. The enormity and complexity of the problems related to a solution for bony defects and augmentation can be assessed when one reviews the intensive, exhaustive literature and research devoted to the subject of skeletal defects.

The paramount objective of the dentist is the restoration of an edentulous mouth with a prosthesis that will be therapeutic, remedial and restorative, and will conform to the requirements of stability, retention, esthetics, phonetics, comfort and masticatory efficiency.

These objectives for a complete denture, however, are not as easily realized or attained, where the ridge is atrophic, concave, undercut, diseased or surgically lost.

The surgical procedures utilized for extending the depth of the alveolar sulcus or augmenting the alveolar height or insertion of implants for the support of a prosthesis, have specific limitations which often render them impractical for universal application.

The current desire and search to provide some form of fixation to bone has given rise to the development of various porous materials for additional retention and stabilization.

A significant and promising development has been the formulation of resorbable ceramics for bone graft implants, which will stimulate bone induction and mineralization; for the replacement of lost or diseased bone with the hosts own osteoid tissue.

From the results of previous investigators and our own studies, it is anticipated that the ceramic implants will be accepted by the soft and hard tissues of the host. It is also expected that the ceramic will be resorbed by the body fluids with ingrowth of new osseous tissue into the ever increasing pores. Eventually the ceramic will lose its structural identity and be replaced by host's own bone.



The development of a more readily available, ideal bone graft material for skeletal defects would provide for a more effective and comprehensive solution for diseases, fractures, and skeletal defects, etc. In severe cases where bone segments must be removed or are destroyed, biodegradable ceramic could solve the problem by providing a compatible platform on which collagen fibers and osteoblastic cells can grow and provide mechanical strength to carry the load. Restoration of skeletal defects would become less traumatic, difficult procedures simplified and it would reduce the time necessary for the rehabilitative process.

This research has particular significance to the military in at least two important areas. First, in combat injuries with avulsion of hard and soft tissues it will be very beneficial in the necessary reconstructive surgery. Avulsion wounds frequently destroy large segments of bone and associated teeth. Bone grafting can replace the bone but teeth must be replaced by prosthetic appliances. A satisfactory ridge is essential to a successful prosthesis and this method of ridge augmentation, if successful, will be of great assistance in providing a successful prosthesis. Second, when military personnel in the older age group lose their teeth, there is frequently an inadequate ridge upon which to construct a prosthesis. This method would restore the ridges sufficiently to enable the individual to wear the prosthesis comfortably. It will also provide greater stability to the prosthesis and increase masticatory efficiency. Since this type of individual is in the older age group and usually assigned to a position of responsibility and authority, the value of providing an efficient functional prosthesis is obvious.

#### BACKGROUND

Previous studies by our group utilizing calcium aluminate ceramics have shown the material to be unsuitable for utilization in the augmentation of residual ridges. Our studies show that the calcium aluminate ceramic after six weeks and longer periods of implantation in animals undergoes little or no biodegradation; also inflammation, fibrous encapsulation and foreign body cells were present. These results prompted us to curtail our activities in the augmentation of ridges with the calcium aluminate ceramics. Limited studies (necessitated by supply) of tricalcium phosphate for the purpose of augmentation of residual ridges has shown great potential.

The results of our study indicate that tricalcium phosphate ceramic does not cause any inflammatory or immunologic response by the tissues. It is biodegradable and supports osseous proliferation, all of which are consistent with Bashker et al, with the same material. The material degrades in the mandible of rabbits at a rate such that at two weeks 10% is gone, 40% in four weeks, 70% in six weeks and 98% in twenty-four weeks.



Whereas, in the femur of the rabbit the ceramic was completely dissolved in twelve weeks. This is possibly due to the greater degree of vascularity in that area. These studies also show that after 167 days approximately 5% of the ceramic remains with formation of dense cortical bone and the surface of this cortical plate elevates gradually to the original ceramic height of 1.0mm. The preliminary studies have demonstrated the ability of tricalcium phosphate ceramic to augment a deficient bony area.

The purpose of this investigation will be to determine the capabilities of tricalcium phosphate compositions to function as bone grafts for the partial or total replacement of structurally deficient residual ridges. An evaluation will be made as to the effectiveness and predictability of tricalcium phosphate ceramic to the solution of the problem of skeletal defects.

#### APPROACH, METHODS AND MATERIALS

To this date no techniques have been developed to successfully augment the height or width of a bony structure. Bone grafts have been used in some instances, but are successful only in areas that have no stress upon them; stress results in either graft resorption or rejection in a matter of months. The long range aim of this project is to develop a technique which will create a substantial increase in the height of an edentulous ridge. This ridge will be capable of withstanding masticatory forces, will last indefinitely, and will form rapidly enough to be clinically feasible.

The technique involves implanting a biodegradable ceramic into an edentulous ridge with a portion of the ceramic extending above it in the shape of the desired ridge. Several types of ceramic were used: tricalcium phosphate which is completely resorbable, and calcium aluminate with phosphate which is partially resorbable. The preliminary experiments were performed to determine the ability of these materials to augment a deficient bony area.

#### THEORY

The primary factors preventing new bone growth are: (1) a lack of matrix on which collagen fibers and osteoblastic cells (precursors of bone) can grow; (2) a lack of calcium and phosphate ions in sufficient concentration to initiate crystal nucleation.

These ceramics have the potential of resolving both problems. They are very porous and extremely strong. The extracellular fluids and collagen fibers surround the implant and infiltrate the most superficial pores. The soluble phase of the ceramic then dissolves slowly, releasing free calcium and phosphate into

the immediate area. This not only increases the concentration of these ions but also slowly enlarges the pores so that there is more area for extracellular fluids. This sets up conditions suitable for the initiation of epitaxial growth of hydroxyapatite crystals supported by the remaining matrix.

A mineralized osteoid will begin to organize from the collagen and phosphate ions present in the pores. It will then redissolve and will be redeposited as a reactive crystalline precipitate. Further structural transformation will finally result in a stable crystalline form of hydroxyapatite (McLean, F.C., BONE, University of Chicago Press, 1968). As the matrix becomes more porous, its strength decreases, but by the time it is too weak to resist the forces upon it, there will be enough bone produced to take over this capacity. In the case of the partially resorbable ceramics, a residual aluminate matrix will never be dissolved. This may or may not produce better results. Other workers have successfully used this type of material for defects in long bone with success. The influence of the ceramic on the rate of new bone growth has been shown by Herstrich et al (Journal of Biomedical Materials, Research, Volume 5, 1971). They demonstrated that there was substantially more mineralization around such a resorbable ceramic than around a ceramic that did not release calcium and phosphate into the immediate area.

It would seem then, that in an area where healthy periosteum is present, as well as an implant material capable of supplying the conditions described above, more rapid bone ossification and enhanced induction are theoretically feasible. With these materials now available, techniques should be developed and utilized for the replacement of diseased or lost bone.

#### Phase I

The inferior border of the anterior mandible of rabbits was the site first chosen, mainly due to its easy access. Four walled defects were created with a high speed drill approximately 3mm x 2mm with a depth of 2mm. In each of six rabbits a piece of tricalcium phosphate was fitted into the defect with an elevation of 1-2mm above the surface of the bone. Two of these were sacrificed at 42 days for histologic studies. The rest either died or were unuseable. Grossly, the area of the implant was white and elevated about one mm. Upon histologic preparation of these with hematoxylin and eosin staining both showed that the pieces of tricalcium phosphate were surrounded with a fibrous connective tissue capsule as well as areas of connective tissue infiltration about 3-4mm into the material indicating biodegradation resulting in increased pore size. Also in both cases a foreign body reaction was going on throughout the capsule. However, one of the samples showed some new bone formation on the periphery of the implant and on the inner surface of the capsule.

From this phase an effective means of anesthesia has been worked out after losing 40% of the rabbits during operation. 20mg/kg thorazine IM is given, then twenty minutes later 20mg/kg pentobarbital IV and lidocaine in the area of the operation are given, this gives excellent results. It is possible that the thick capsule greatly hinders the blood flow and resorption of the material.

## Phase II

Rabbits were used again for the Phase II with a more refined operative technique. To combat the formation of the fibrous capsule, the tricalcium phosphate was soaked in hydrocortisone, or a small piece of millipore filter was placed between the implant and the periosteum. This time the defects were made on the inferior border of the angle of the mandible. Previous workers in this field found their best results when placing the implants in the femur possibly due to a better blood supply to that area. Three of the six rabbits used for this phase also had implants put into the femur.

## Phase II - Results

At fifteen days the implant was completely saturated with tissue fluid and cellular material. The pores were increasingly large towards the periphery of the implant with the larger holes having more cellular contact. Both fibrous connective tissue and bone were forming around the entire edge of the implant that was in contact with the bone, with some proliferation into the pores, approximately 100m. None of the osseous tissue was above the original bone surface however. There appeared to be active osteogenic cells on the surface of the new bone spicules as well as a few multi-nucleated giant cells of indistinct function. The radiographic analysis showed an indistinguishable change in the overall density of the implant but the radiolucent margin had become wider and more dense eliminating a defined border of the implant. At day thirty-two the implant was smaller and the overall porosity had increased leaving approximately 60% of the original ceramic intact. Osseous tissue had proliferated 25m into the material some of which extended up to the original surface level. The bone had completely occluded the pores that it was in and little connective tissue was remaining. There was no change in the radiographic appearance. At day 46 both a mandibular and a femoral implant were evaluated. Both appeared similar grossly, being firm, elevated and a whiter color than the surrounding bone. At this time the mandibular implant demonstrated long spicules throughout, even extending 1mm above the original cortical level. In some of the larger spicules, spaces appeared with a marrow-like cellular content. Approximately 30% of the ceramic material remained. The implant from the femur demonstrated the same basic characteristics but the bone was more extensive and only 15% of the ceramic remained.



The next rabbit sacrificed was 76 days old, and once again the firm, white, elevated area was found, but the histological results were quite different. There was a thick capsule surrounding it with giant cells present. Throughout the remaining tricalcium phosphate there was islands of cellular material, but it was neither bone nor osteoid. It appeared hyalinized and fibrous, similar to scar tissue with many inflammatory cells surrounding each island. It is questionable what this meant. These could have been bone spicules at one time and were now being resorbed, or the area could have become infected (there were now what appeared to be bacterial colonies on the periphery).

Another rabbit was sacrificed at 86 days. This one had the millipore covering the implant. This was also used as a test of tetracycline marking that enables the new bone to be differentiated from bone that was present before the tetracycline was injected. When a ground section of the two defects was exposed to the ultra-violet light the entire implant glowed markedly, indicating that the tetracycline had been absorbed into that area. The histological study of the same sections showed purple tinge in the bone that exactly corresponded to the area of fluorescence under the ultra-violet light. This was on the inner and outer periphery of the bone and in the area of the implant, all of the areas of the expected bone growth. Approximately 80% of the material had been resorbed and most of the space contained spicules of bone similar to those seen in earlier slides. However, these spicules were surrounded by inflammatory cells, and there were some islands of fibrous tissue. This could indicate that the previously formed spicules were beginning to degenerate as seen in the 76 day specimen. But there were no indications of bacterial colonies which might speed up the degenerative process.

The last sacrifice was made at day 167. Approximately 5% of the ceramic still remained and there were interconnecting bone spicules throughout with extensive marrow spaces between them. These spicules were more numerous and thicker than those at 86 days. A more dense cortical plate formed along the outer surface of the implant with branches of osseous tissue extending towards the center of the implant. The surface of this cortical plate elevated gradually to the original ceramic height of 1.0mm., it was covered by a thin layer of fibrous connective tissue containing some inflammatory cells but no osteoclasts or foreign body giant cells were present in the sections.

The results of this study indicate that tricalcium phosphate ceramic does not cause any inflammatory or immunologic response by the tissues. It is biodegradable and supports osseous proliferation all of which are consistent with studies by Bashker et al, with the same material. The material degrades in the mandible of rabbits at a rate such that at two weeks 10% is gone, 40% in 4 weeks, 70% at 6 weeks and 98% in 24 weeks. Whereas in the femur of the rabbit the ceramic was completely



dissolved at 12 weeks. This is possibly due to the greater degree of vascularity in that area, but this has not been determined. It appears that collagen fibers precede the bone formation at the initial stages and areas of mineralization form within the fibers which then proliferate the spicules; this supports Robinson's mechanism of bone proliferation. After 2 weeks bone is forming at the periphery in close contact with the original bone and it is not until 4 weeks that structurally normal spicules have formed independently in the more interior aspects of the implant. In the later stages the bone spicules seem to increase in size relative to the size of the constantly enlarging pores. That the actual relationship between these two was not determined. Whether or not a more rapidly dissolving ceramic would cause faster spicule formation is a question that should be looked into. In fact the actual cause of the effects that resorbable ceramic implants have on bone has not been answered and has not been attempted here.

### Phase III

The goal of Phase III remained that of our entire project. Namely; to be able to increase bone height such that atrophied mandibles could be augmented or bone defects filled without using autogenous grafts. We decided to utilize both rabbits and dogs in this phase, to avoid wasting laboratory time and personnel. It must be explained that to simulate human clinical experience, it was necessary to extract the teeth of the animals, do a radical alveolectomy and then wait a sufficient period of time for proper healing. Other experiments have waited only 4-6 weeks which is quite sufficient for soft tissue healing, but not for bone healing. By this I mean formation of a cortex over the extraction sites. To place a ceramic implant or onlay over the cortex is one thing and over fresh medullary bone is quite another. We preferred to wait three to six months on the dogs. The rabbits, therefore, which have a much faster healing rate, were used during the waiting period.

### Phase III (a)

The posterior teeth of 5 rabbits were extracted under IV pentobarbital anesthesia. This proved to be a technically difficult surgical feat and required some practice rabbits and some special surgical instruments. Finally a technique was developed and the five rabbits were allowed to heal for four weeks. At this time we had run out of the tricalcium phosphate that had been sent from Batelle Laboratories in Ohio and were told that we would have to wait until more was available. There were further delays with no fixed date for replenishing our supply. Once again, rather than run-up animal storage fees and lab charges, we elected to utilize a biodegradable ceramic, namely,  $\text{CaO}_3 \text{ Al}_2\text{O}_3; \text{P}_2\text{O}_5$ , made by G. A. Graves at the University of Dayton.

Via submandibular approach the edentulous ridge was exposed and trapezoid bony defects cut with a high speed drill under saline irrigation. These defects were approximately 5mm at the base and 3mm deep. A piece of ceramic of similar dimensions was cut and inserted into the defect. Approximately 3mm of ceramic was allowed to extend above the cortical bone. The surgical site was closed. The mandible was x-rayed and the rabbit was injected with tetracycline to establish new bone growth. Intraoral inspection was carried out to be sure there had been no mucosal perforations and that the ceramic bulges were smooth.

Two rabbits were sacrificed in 3 weeks time and we found that little biodegradation had occurred. There was some inflammation present clinically and histologically. No mucosal ulceration had occurred but the tissues were red and swollen. At six weeks there was no sign of inflammation but encapsulation had occurred around the defects and we elected to terminate the experiment.

#### Phase III (b)

In this portion of the study we planned to study the use of ceramic to fill the undercuts of the mandibular alveolar process in dogs. There were to be 3 subgroupings of the 9 dogs used for this phase. The groups were divided by method of implant placement as follows:

- (a) Onlay-ceramic to cortex  
The shaped sterile ceramic implant was inserted into position and the incision was closed in a two layer fashion.
- (b) Onlay-ceramic to perforated cortex  
Using a retractor to hold the periosteum away from the bone, with a #6 round bur in a high speed handpiece the buccal alveolar cortex was perforated randomly. The implant then was inserted and the incision was closed as above.
- (c) Inlay/Onlay-ceramic to medullary bone  
Again after appropriate retraction of the periosteum, an area approximately 4 x 6 mm of buccal cortex was removed with a high speed bur and the ceramic implant was inserted. The wound was closed as described in (a).

Unfortunately, Phase III (b) began before we realized the results of Phase III (a), and therefore the Graves material, calcium aluminate was used as the ceramic.

The corners of all the inlays which were left above the cortical surface, were carefully smoothed and the tissues were

approximated such that the suture line as no closer than 1cm to the inlay site. Closure was accomplished and the dogs were allowed to heal. They were given a soft diet and any maxillary teeth that impinged upon the surgical site were removed. Sacrifices were made at 6 weeks, 8 weeks, and 8 months. The results of the biopsies were very similar to those of the rabbits in Phase III (a). Namely slight degradation had taken place even after 8 months and that a fibrous capsule had formed in each case. Our feelings concerning both Phase III (a) and Phase III (b) was that the Graves material, calcium aluminate, simply did not degrade at a quick enough rate to stimulate osteogenesis into the pores and that a fibrous capsule once formed prevented further ingrowth of bone tissue. Once again the experiment was terminated.

#### Phase IV

At this time a new supply of tricalcium phosphate was made available to us from Battelle Laboratories and a new more ambitious project was started.

Once again, 9 dogs were made edentulous in the posterior mandible region either unilaterally or bilaterally. The mandibular ridge was smoothed with rongeurs and high speed drill in certain indicated cases simulating a somewhat atrophied mandibular ridge. Primary closure was done and the dogs were then allowed to heal for a period of two months. Tricalcium phosphate implants of approximately 20mm in height were placed on the ridge in retention defects or held by circummandibular wires. Once again the ridges were cut down quite vigorously to simulate atrophied mandibles and allowed to heal at a minimum of two months. The surgical incisions were made intraorally, but far out on the buccal mucosa. Blunt dissection was used to undermine the mucosa towards the mandibular ridge. The flap was pedicled towards the lingual, and the cortex of the mandibular ridge was removed allowing healthy bleeding bone to be exposed. The implants were trimmed to match the retentive defect and approximately 5 to 7mm of ceramic was allowed to extend above the cortex. The tissues were closed with a double layer closure using dexton suture.

The animals once again were placed on a soft diet and in several cases Victorian collars were placed upon the dogs in hopes of preventing the dogs from damaging the surgical site with their paws. There was extreme difficulty in keeping the implants in place, namely due to cage trauma in which the animals gnaw on the cage wire. In every case but one the implants were either displaced or lost completely, or the mucosa was damaged and ulcerated such that the implants had to be removed.

In one animal, however, this did not happen. In this particular animal, after the defect was made into the mandible, the cortical plate, which had been removed was placed on top of the ceramic implant in such a way that the implant was sandwiched between bone below and bone above. Circummandibular chromic



sutures were used to hold this "sandwich" together. Soft tissues were once again closed in a double layer closure. The implant remained in position in the following weeks and at 29 weeks the sacrifice revealed that although no implant was remaining there was a 4mm increase in ridge height. We felt that this result was impressive enough to pursue in a specific study by itself. In this dog the cortical bone, which was placed superior to the implant, was done almost as an afterthought and it was decided that with proper planning we could be consistent in our surgical technique. With this in mind, Phase V was begun.

#### Phase V

The excellent results we got from the one dog in the previous phase indicated that the bone resting on top of the implant had a lot to do with both the infiltration of osteoid tissue into the tricalcium phosphate and also aided in protection during the initial healing period. A technique was then devised in which the bone would be elevated via an osteoplastic flap such that the mucoperiosteum would not be reflected from the piece of bone that was to be elevated. The entire mucosa-periosteum-cortical bone would be flapped towards the lingual. Since hinging would take place at the lingual wall of the mandible, as we elevated the flap we produced a somewhat pie-shaped defect. The flap would then be held in its elevated position with the intra-osseous tricalcium implant. The implant would be cut as a wedge such that the greatest height would be at the buccal aspect and the wedge would taper to a point at the lingual edge.

Six dogs were used in this study and once again they were made edentulous similar to the dogs in the previous phases. The surgical approach was made extraorally along the inferior border of the mandible. This was done to further protect the wound and prevent contamination from cage trauma and diet. The tissues of the dog are loose enough such that the crest of the ridge can be reached from an inferior approach. Also sterility is much more easily maintained from an extraoral approach. Our feeling was that since we had already proven that it would work intraorally, going extraorally would be purely a precaution.

Routine surgical exposure was done through an incision approximately 5cm in length. Sharp dissection was carried down to the periosteum. Periosteum was incised and elevated up to the level of the mental foramen. Next, a tunneling of the mucoperiosteum between these two tunnels (a distance of approximately 20cm) firmly attached to the bone. A highspeed drill was then used to cut horizontally through the cortex of the mandible and in the area of the tunnels two vertical cuts were made over the crest of the ridge. This was done very carefully to prevent perforation into the mouth. Next, a spear point drill was used to go through the buccal cortical cut all the way to the lingual cortex. A series of holes were made through the lingual cortex, but not through the periosteum.



A wide osteotome was then placed into the horizontal cut and by a combination of malleting and prying the osteoplastic flap was raised. This flap was attached to the mucoperiosteum and the lingual tissues. In each case as we elevated the cortex, the mandibular canal with its neurovascular bundle could be seen undamaged, lying as a bed onto which the tricalcium phosphate implant would be placed.

The implants were cut in a wedge shaped fashion such that the point was inserted all the way to the lingual soft tissues and the wide portion of the wedge rested adjacent to the buccal cortical plate. The wide portion of the implant was approximately 5 to 7mm in height, 20mm in length and the width was determined by the width of the mandible, which in this case ranged from 8 to 10mm.

A thin wire was then placed in a circummandibular fashion around the entire mandible in such a way that the osteoplastic flap was held securely down against the tricalcium phosphate implant. The area was irrigated well with saline and a layered closure was accomplished.

All six dogs had mucosal tissues unperforated. Distinct elevations could be determined and intraoral measurements with a Boly gauge were done pre-surgery, immediate post surgery and on a weekly basis. X-rays were taken pre-surgery, post surgery and on a monthly basis. All surgical wounds held with no difficulty. There was no perforation of the mucosa throughout the entire experiment. The dogs ate well and the tissues remained firm and pink over the elevated cortex. Detailed examination was planned at sacrifice intervals of 4, 14, 22, 26, 30, 36, 40 and 44 weeks.

#### Results of Phase V

<u>Dog #</u>	<u>Pre-op mand. ht.</u>	<u>Post-op mand. ht. initial</u>	<u>Post-op mand. ht. final</u>	<u>% of ceramic left</u>	<u>Sacrificed by week</u>
1	15.3	19.2	19.0	30	23*
2	21.7	26.4	24.2	0	40
3	14.9	20.0	19.6	30	14
4	16.7	20.5	20.0	90	4
5	19.2	23.1	21	0	44
6	14.3	18.5	17.2	20	22
7	19.7	24.3	22.1	10	30
8	20.2	24.7	Displaced Graft		
9	15.6	19.8	17.6	0	36

\* Originally planned for week 26.

Although the radiographs were difficult to use in estimating the amount of ceramic left they were accurate in determining the height of the alveolar crest. Histologically the specimens were very similar to what we found in Phase II. Bone spicules could be seen penetrating into the implant by the 4th week. Later sections showed that the bone spicules increased in size as the porosity of the implant got larger. Very little connective tissue could be found between the bone spicules and the ceramic implant. As the ceramic disappeared cortical bone formed in continuity with the original cortex and it later became impossible to determine which was new bone and which was old bone. In this series we saw no evidence of inflammatory cells near the implants, however, it must be mentioned that the first sacrifice was at 4 weeks and when we had seen inflammatory cells present during earlier experiments, they usually disappeared by the 3rd or 4th week. While ceramic was present, cells with multiple nuclei could be seen adjacent to the ceramic.

Photographic illustrations of selected surgical sites are shown in the Appendix.

### Conclusions

The most important conclusion we arrived at after 3 years of working with biodegradable ceramic was that it is indeed possible to increase the height of atrophied mandibles. This was our goal and this was achieved. By means of several intermediate steps using different materials, different animals and different techniques, we found that tricalcium phosphate can be used to augment mandibular ridges if placed in such a way as to assure good bone contact and retain good vascularity to the area. It is also essential, at least in animals, to be sure the implant can be well protected during the healing period. The technique that we developed to meet these criteria was that of an osteoplastic flap that is elevated by inserting a wedge-shaped implant of tricalcium phosphate beneath it. The advantages of this technique are that the implant is almost completely surrounded by viable bone and that the implant is protected by the cortex and attached to the mucoperiosteum. Although not yet tested with the loading force of a denture, we feel that the fact a denture would be resting on natural mucosa and bone would be very advantageous.

### Recommendations

The fact that we are able to increase bone height and maintain it for almost a year means we have developed a technique that merits further investigation. The next logical step would be to investigate how well this implant holds up under the loading stress of a denture. Unfortunately, the mandibles of dogs do not lend themselves well to dentures because of anatomical configurations. We would recommend the procedure be done on monkeys next with dentures placed on the new ridges. We have also worked out a theory whereby a two stage procedure would allow a rectangular implant rather than a wedge-shaped implant.

Finally, we feel that there is enough data and experience to warrant considering placement of the ceramic implant under an osteoplastic flap in humans.

#### Bibliography

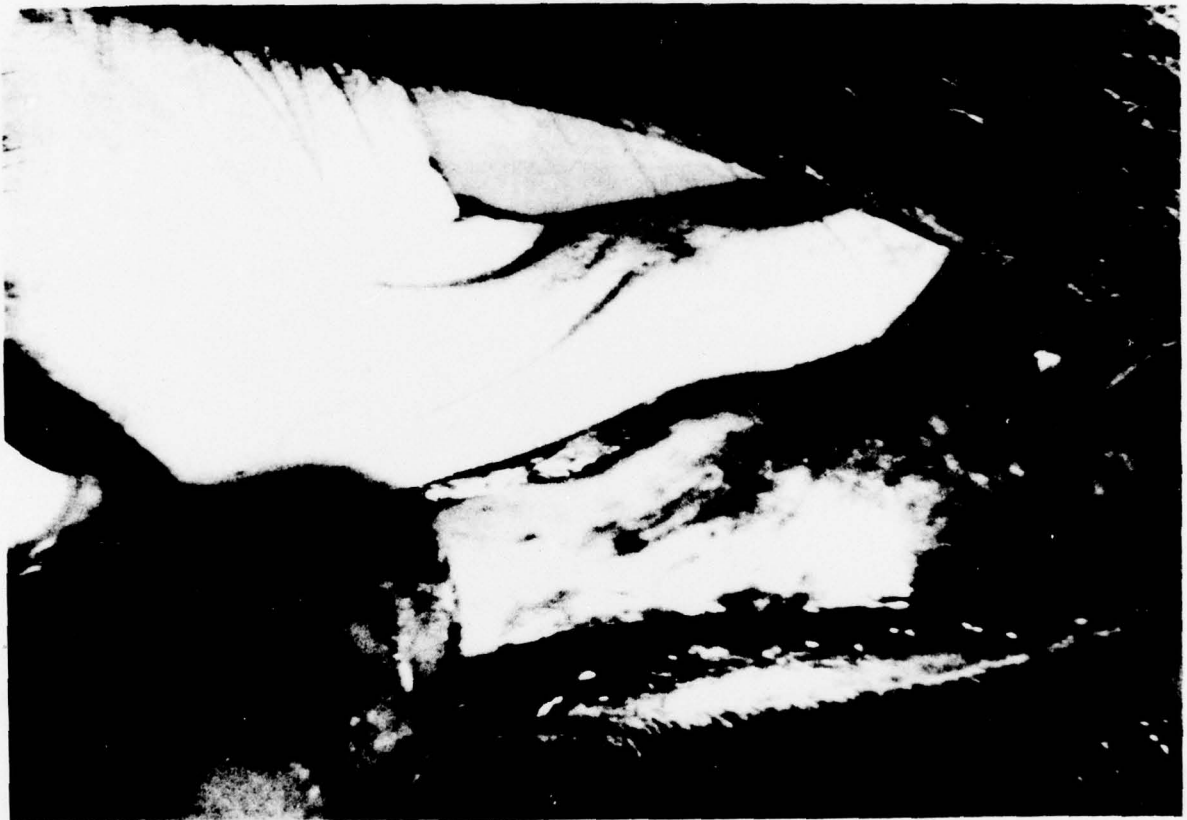- (1) Klawitter, J.J., Hulbert, S.F., Talbert, C.D. and Fitts, C.T. The Use of Ceramics in Surgical Implants; Artificial Bones, Hulbert, S.F., and Young, F.A. (editors), New York, 1969, Gordon & Breach, Science Publishers.
- (2) Hulbert, S.F., Young, F.A., Mathews, R.S., Klawitter, J.J., Talbert, C.D., and Stelling, F.H. "Potential of Ceramic Materials as Permanently Implantable Skeletal Prosthesis", J. Biomed. Mat. Res. 4:443-456, 1970.
- (3) Hentrich, R.L., Graves, G.A., Stern, H.G., and Bajpa, P.K.: "An Evaluation of Inert and Resorbable Ceramics for Future Clinical Orthopedic Applications", J. Biomed. Mat. Res. 5:25-52, 1971.
- (5) Smith, L. "Ceramic-Plastic Materials as a Bone Substitute", Arch. Surg. 87:653, 1963.
- (6) Steling, W.J., Bhasker, S.N. "Structural Strength of the Interface Between Bone and Nondegradable Porous Ceramic Implants", J. Dent. Res. 52:91-94, 1973.
- (7) Newman, W.F., Newman, M.W. "The Chemical Dynamics of Bone Mineral", U. of Chicago Press, Chicago, Ill. 1958.
- (8) Urist, M.R., and McLean, C.F. J. Bone and Joint Surg. 34A:443, 1952.

APPENDIX I

ILLUSTRATIONS



THIS PAGE IS BEST QUALITY PRACTICABLE  
FROM COPY FURNISHED TO DDC



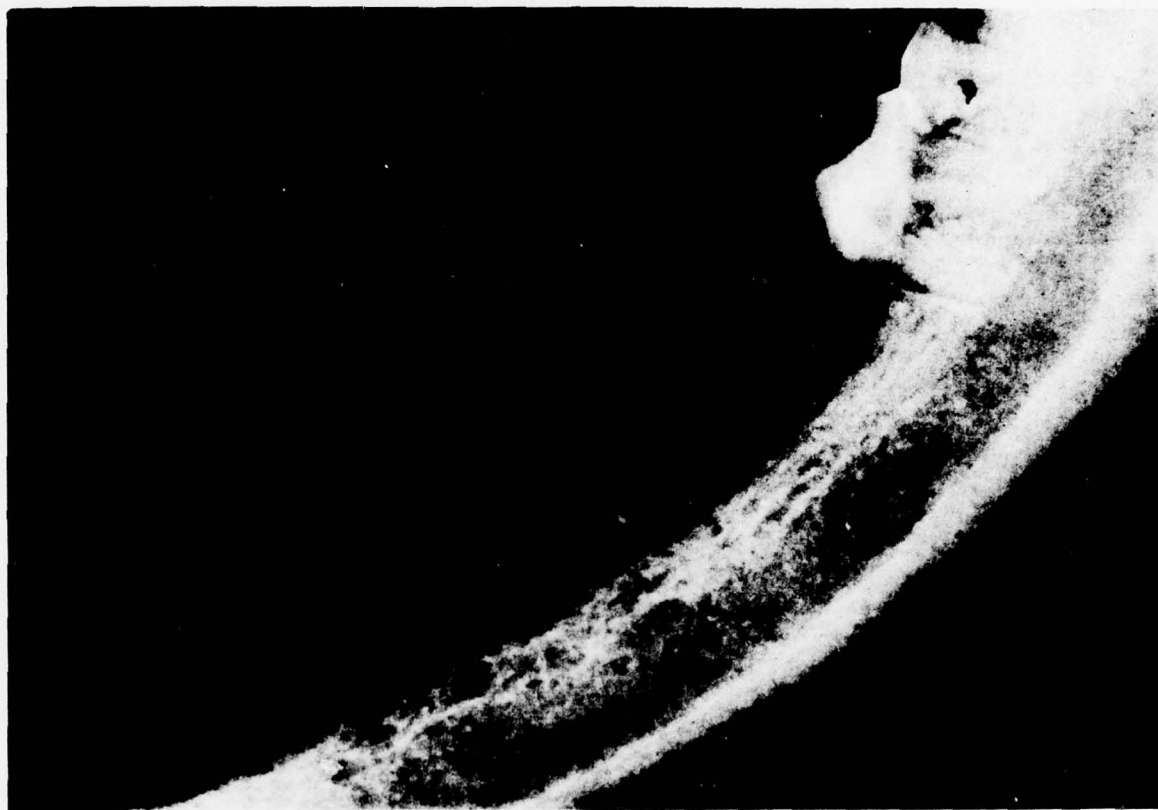
1. Preoperative view of edentulous body of mandible.

THIS PAGE IS BEST QUALITY PRACTICABLE  
FROM COPY FURNISHED TO DDC



2. Augmented section of mandible 40 weeks after surgery.

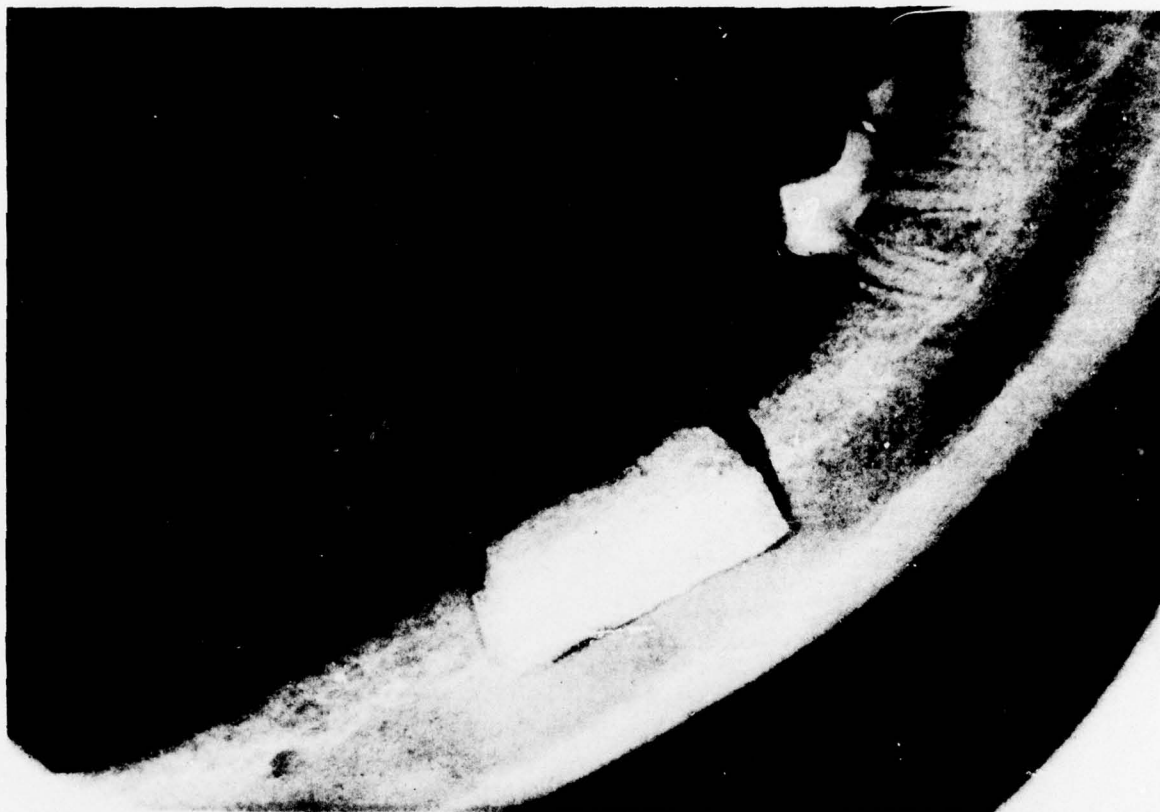THIS PAGE IS BEST QUALITY PRACTICABLE  
FROM COPY FURNISHED TO DDC



3. Preoperative radiograph of receptor site in edentulous mandible.

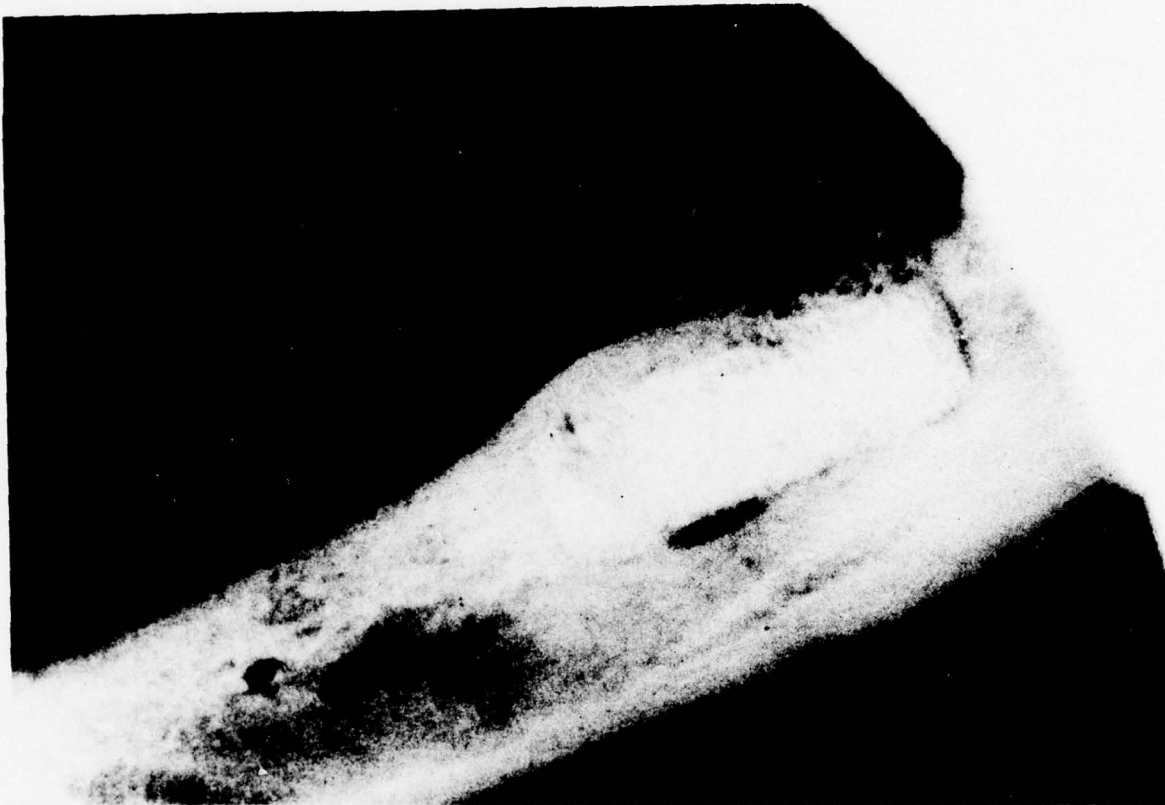


THIS PAGE IS BEST QUALITY PRACTICABLE  
FROM COPY FURNISHED TO DDC



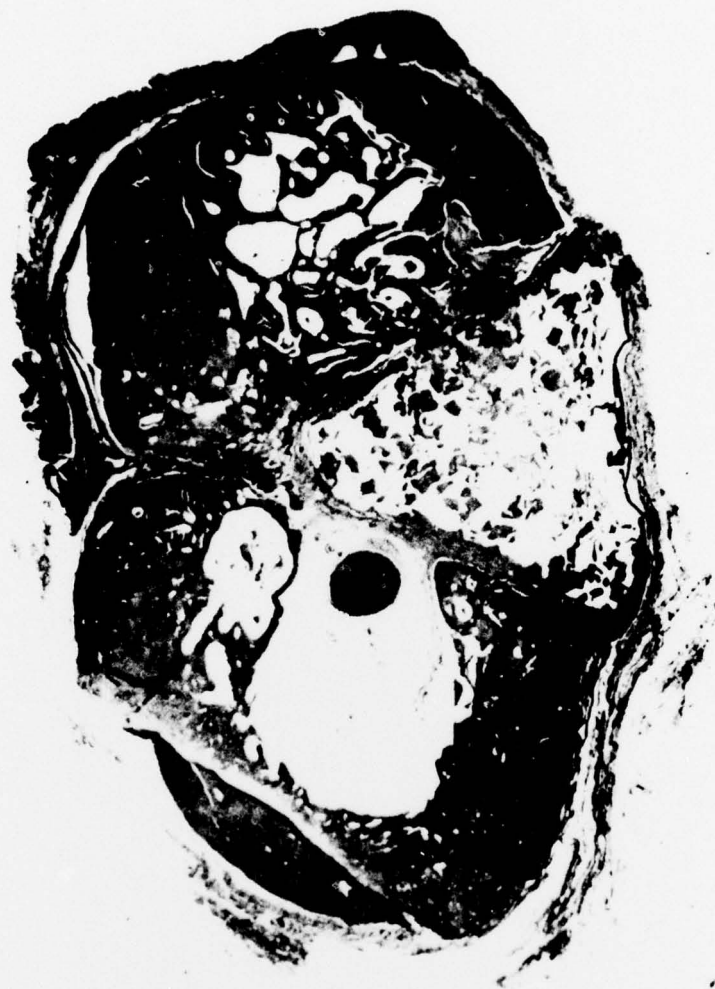4. Radiograph of tricalcium phosphate covered with host cortex one month post insertion.

THIS PAGE IS BEST QUALITY PRACTICABLE  
FROM COPY FURNISHED TO DDC



5. Radiograph of receptor site 6 months post operative.

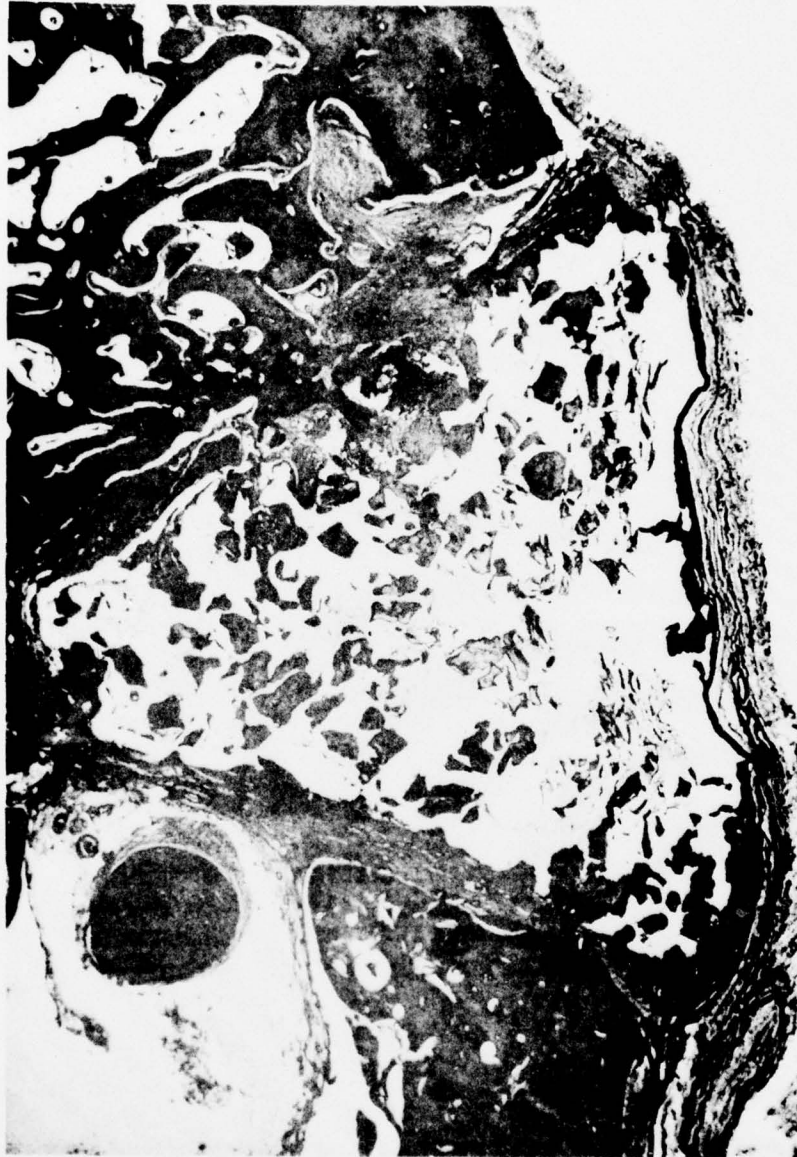THIS PAGE IS BEST QUALITY PRACTICABLE  
FROM COPY FURNISHED TO DDC



6. Cross section of mandible with triangular-shaped ceramic implant inserted just superior to neurovascular bundle. Host cortex has been hinged superiorly 14 weeks post insertion.

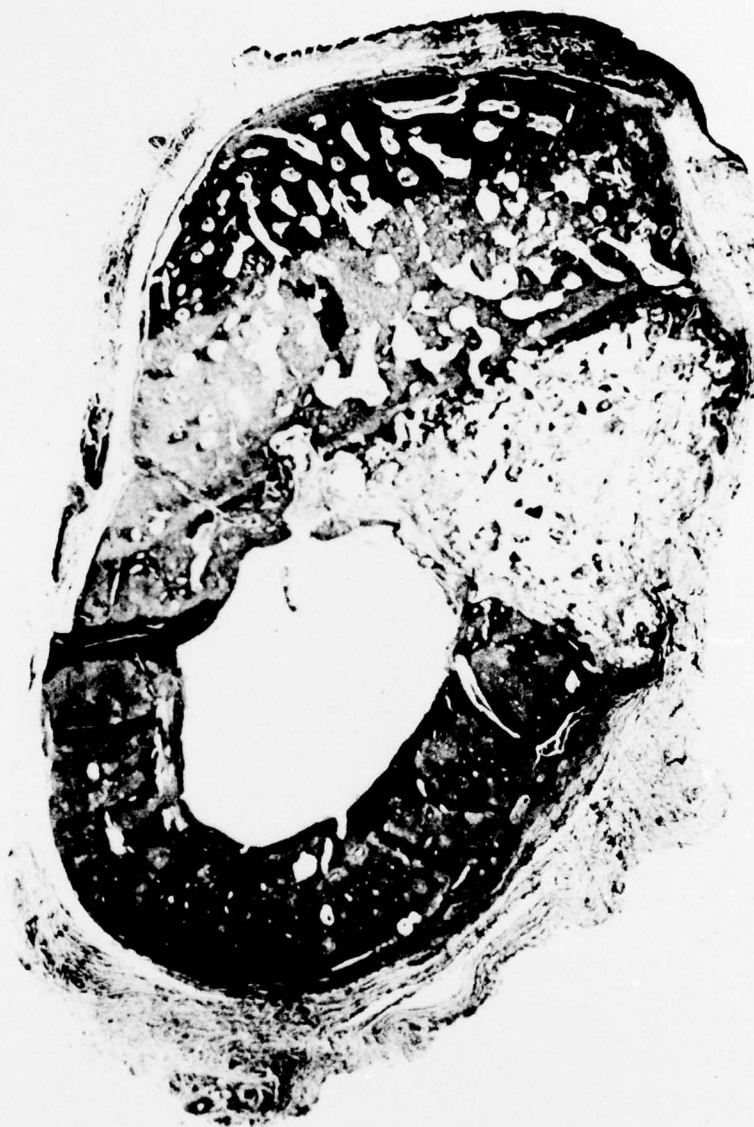

THIS PAGE IS BEST QUALITY PRACTICABLE  
FROM COPY FURNISHED TO DDC

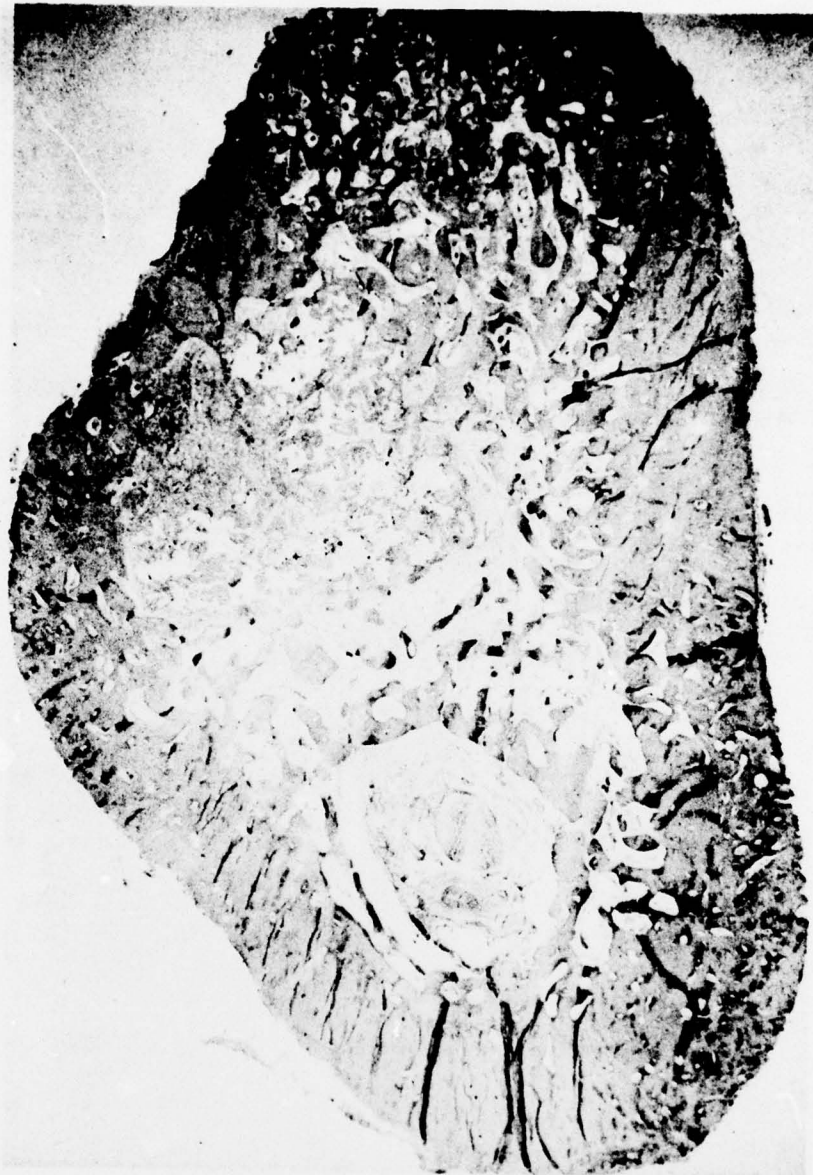

7. Higher power view of previous section showing new bone growth into the ceramic implant. The clear portion in the triangular section represents the remaining tricalcium phosphate.

THIS PAGE IS BEST QUALITY PRACTICABLE  
FROM COPY FURNISHED TO DDC



8. Cross section of 22 week specimen. Original triangular shape can still be seen, but very little ceramic is left.



9. Cross section of 40 week specimen. Bone has now completely infiltrated the ceramic implant and is maturing.



DISTRIBUTION LIST

4 copies

HQDA (SGRD-SI)  
Fort Detrick  
Frederick, MD. 21701

12 copies

Defense Documentation Center (DDC)  
ATTN: DDC-DCA  
Cameron Station  
Alexandria, Virginia 22314

1 copy

Dean  
School of Medicine  
Uniformed Services University of the  
Health Sciences  
4301 Jones Bridge Road  
Bethesda, Maryland 20014

1 copy

Superintendent  
Academy of Health Sciences, US Army  
ATTN: AHS-COM  
Fort Sam Houston, Texas 78234