

REPORT DOCUMENTATION PAGE					Form Approved OMB No. 0704-0188	
<p>The public reporting burden for this collection of information is estimated to average 1 hour per response, including the time for reviewing instructions, searching existing data sources, gathering and maintaining the data needed, and completing and reviewing the collection of information. Send comments regarding this burden estimate or any other aspect of this collection of information, including suggestions for reducing the burden, to the Department of Defense, Executive Service Directorate (0704-0188). Respondents should be aware that notwithstanding any other provision of law, no person shall be subject to any penalty for failing to comply with a collection of information if it does not display a currently valid OMB control number.</p> <p>PLEASE DO NOT RETURN YOUR FORM TO THE ABOVE ORGANIZATION.</p>						
1. REPORT DATE (DD-MM-YYYY) 06/04/2018		2. REPORT TYPE poster		3. DATES COVERED (From - To) 04/06/2018		
4. TITLE AND SUBTITLE Longitudinally Extensive Spinal Arachnoid Cyst Secondary to Chronic Coccidioides immitis Meningitis				5a. CONTRACT NUMBER		
				5b. GRANT NUMBER		
				5c. PROGRAM ELEMENT NUMBER		
6. AUTHOR(S) Koehn, Tyler R., Capt				5d. PROJECT NUMBER		
				5e. TASK NUMBER		
				5f. WORK UNIT NUMBER		
7. PERFORMING ORGANIZATION NAME(S) AND ADDRESS(ES) 59th Clinical Research Division 1100 Willford Hall Loop, Bldg 4430 JBASA-Lackland, TX 78236-9908 210-292-7141				8. PERFORMING ORGANIZATION REPORT NUMBER 17739		
9. SPONSORING/MONITORING AGENCY NAME(S) AND ADDRESS(ES) 59th Clinical Research Division 1100 Willford Hall Loop, Bldg 4430 JBASA-Lackland, TX 78236-9908 210-292-7141				10. SPONSOR/MONITOR'S ACRONYM(S)		
				11. SPONSOR/MONITOR'S REPORT NUMBER(S)		
12. DISTRIBUTION/AVAILABILITY STATEMENT Approved for public release. Distribution is unlimited.						
13. SUPPLEMENTARY NOTES American Academy of Neurology 70th Annual Meeting, Los Angeles, CA, April 6, 2018						
14. ABSTRACT						
15. SUBJECT TERMS						
16. SECURITY CLASSIFICATION OF:			17. LIMITATION OF ABSTRACT	18. NUMBER OF PAGES	19a. NAME OF RESPONSIBLE PERSON	
a. REPORT	b. ABSTRACT	c. THIS PAGE			Clarice Longoria	
					19b. TELEPHONE NUMBER (Include area code) 210-292-7141	



Longitudinally Extensive Spinal Arachnoid Cyst Secondary to

Chronic *Coccidioides immitis* Meningitis

Tyler R. Koehn, MD, Jeffrey C. McClean, MD, Anthony R. Fratalone, MD

Department of Neurology, San Antonio Military Medical Center, Fort Sam Houston, Texas



Introduction

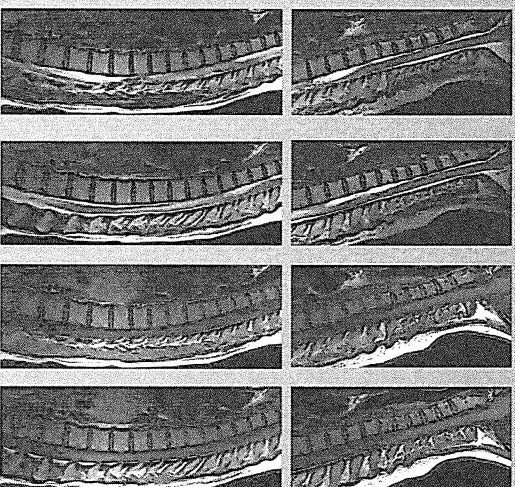
Spinal arachnoid cysts are intraspinal, extramedullary fluid collections. They may be congenital or acquired, with secondary cysts arising from trauma, inflammation, hemorrhage, or spinal procedures. These fluid collections can remain asymptomatic or produce signs and symptoms of myelopathy and/or radiculopathy.^{1,2}

Coccidioides immitis disseminated to the central nervous system (CNS) may manifest as meningitis, hydrocephalus, vasculitis infarction, spinal arachnoiditis, or rarely cerebral or spinal abscesses.³⁻⁵ Spinal arachnoid cyst as a consequence of chronic *Coccidioides* meningitis has not been previously described in the literature.

Case

A 35 year old woman with a history of *Coccidioides* meningitis and systemic lupus erythematosus presented with 3 months of progressive left leg numbness, urinary retention, gait impairment, left leg myoclonus, and lower extremity dysesthesias. Her neurologic exam was notable for hyperreflexia and spasticity in both lower extremities along with bilateral Babinski signs. She was admitted for expedited MRI of the spinal cord, which showed a non-enhancing, T2 hyper-intense, extra-axial fluid collection extending from C5 to T4. This fluid collection resulted in significant mass effect on the spinal cord and subsequent extensive cord edema from T4-T10 with cord expansion.

Imaging



Top row: MRI C-spine. From left to right: Left parasagittal T2, Sagittal T2, Left para-sagittal T1, Sagittal T1.

Bottom row: MRI T-spine. From left to right: Right parasagittal T2, Sagittal T2, Right parasagittal T1, Sagittal T1.

T1 post-contrast images did not show any clear enhancement. The images were degraded by motion artifact, therefore they have not been included in the poster.

Case Continued

The patient underwent a T2-T4 laminectomy for cyst fenestration. Intra-operatively, the cyst was observed to be thickened and densely adherent to the cord circumferentially. CSF analysis was performed, and there were no signs of this being an infectious fluid collection. The fluid was otherwise consistent with a CSF sample obtained from her previously placed VP shunt. After the surgery, her gait and associated symptoms improved.

Conclusions

Chronic *Coccidioides* of the central nervous system generates a persistent inflammatory state involving the meninges of not only the brain but also the spinal cord. As a result, this arachnoiditis predisposes to arachnoid cyst formation, which may range from asymptomatic to symptoms of myelopathy and/or radiculopathy. While *Coccidioides immitis* is known to result in various other CNS manifestations, to our knowledge this is the first case in the literature to describe this specific complication of *coccidioides* disseminated to the CNS.

References

1. Moreno, Carolina Ospina, et al. "Radiological Diagnosis of Spinal Arachnoid Cysts: A Pictorial Essay." *Journal of Medical Imaging and Radiation Oncology*, vol. 60, no. 5, 2016, pp. 632-638.
2. Cho, Ho-yeon, et al. "Symptomatic Large Spinal Extramedullary Arachnoid Cyst: A Case Report." *Korean Journal of Spine*, vol. 12, no. 3, 2015, p. 217.
3. Goldstein, Elie J. C., et al. "Coccidioides Meningitis." *Clinical Infectious Diseases*, vol. 42, no. 1, 2006, pp. 103-107.
4. Bannet, A. F., et al. "Central Nervous System Abscesses Due to *Coccidioides* Species." *Clinical Infectious Diseases*, vol. 22, no. 2, 1996, pp. 240-250.
5. Kakkila, Udaya K., et al. "Surgical Management of *Coccidioides* of the Spine." *Journal of Neurosurgery: Spine*, vol. 15, no. 4, 2011, pp. 441-446.