

REPORT DOCUMENTATION PAGE				Form Approved OMB No. 0704-0188	
<p>The public reporting burden for this collection of information is estimated to average 1 hour per response, including the time for reviewing instructions, searching existing data sources, gathering and maintaining the data needed, and completing and reviewing the collection of information. Send comments regarding this burden estimate or any other aspect of this collection of information, including suggestions for reducing the burden, to the Department of Defense, Executive Service Directorate (0704-0188). Respondents should be aware that notwithstanding any other provision of law, no person shall be subject to any penalty for failing to comply with a collection of information if it does not display a currently valid OMB control number.</p> <p>PLEASE DO NOT RETURN YOUR FORM TO THE ABOVE ORGANIZATION.</p>					
1. REPORT DATE (DD-MM-YYYY) 22/03/2019		2. REPORT TYPE Journal		3. DATES COVERED (From - To) 03/22/2019	
4. TITLE AND SUBTITLE Cytomegalovirus Colitis Masquerading as Apple-Core Lesion after Systemic Chemotherapy in a Patient with Relapsed Acute Myeloid Leukemia				5a. CONTRACT NUMBER	
				5b. GRANT NUMBER	
				5c. PROGRAM ELEMENT NUMBER	
6. AUTHOR(S) An, Jong W, Maj				5d. PROJECT NUMBER	
				5e. TASK NUMBER	
				5f. WORK UNIT NUMBER	
7. PERFORMING ORGANIZATION NAME(S) AND ADDRESS(ES) 59th Clinical Research Division 1100 Willford Hall Loop, Bldg 4430 JBSA-Lackland, TX 78236-9908 210-292-7141				8. PERFORMING ORGANIZATION REPORT NUMBER 17678	
9. SPONSORING/MONITORING AGENCY NAME(S) AND ADDRESS(ES) 59th Clinical Research Division 1100 Willford Hall Loop, Bldg 4430 JBSA-Lackland, TX 78236-9908 210-292-7141				10. SPONSOR/MONITOR'S ACRONYM(S)	
				11. SPONSOR/MONITOR'S REPORT NUMBER(S)	
12. DISTRIBUTION/AVAILABILITY STATEMENT Approved for public release. Distribution is unlimited.					
13. SUPPLEMENTARY NOTES Case Reports in Oncological Medicine					
14. ABSTRACT Abstract We report the case of a 71-year old male with relapsed acute myeloid leukemia who developed cytomegalovirus (CMV) colitis presenting as an apple core lesion during induction chemotherapy. CMV infection occurs rarely during induction chemotherapy for acute myeloid leukemia. CMV infection is usually observed in patients with Acquired Immune Deficiency Syndrome (AIDS) and in those on immunosuppressive agents following bone marrow transplant. Although rare, CMV colitis should be considered in patients who are critically ill after systemic chemotherapy as it can cause significant morbidity and mortality.					
15. SUBJECT TERMS					
16. SECURITY CLASSIFICATION OF:			17. LIMITATION OF ABSTRACT UU	18. NUMBER OF PAGES	19a. NAME OF RESPONSIBLE PERSON Clarice Longoria
a. REPORT	b. ABSTRACT	c. THIS PAGE			19b. TELEPHONE NUMBER (Include area code) 210-268-2201

Cytomegalovirus colitis masquerading as apple-core lesion after systemic chemotherapy in a patient with relapsed acute myeloid leukemia

Jong An¹, Jason Brownell², Darrell Barker³, Theresa Stockinger⁴, Baur Russell¹, Robert Brady⁴, Katherine Cebe⁴

¹Department of Hematology and Oncology Service, San Antonio Military Medical Center, Fort Sam Houston, TX 78234, USA

²Department of Internal Medicine, San Antonio Military Medical Center, Fort Sam Houston, TX, USA

³Department of Gastroenterology, San Antonio Military Medical Center, Fort Sam Houston, TX, USA

⁴Department of Pathology, San Antonio Military Medical Center, Fort Sam Houston, TX, USA

Correspondence should be addressed to Jong An; jong.w.an.mil@mail.mil

*The views expressed are those of the authors and do not reflect the official views or policy of the Department of Defense or its Components.

Abstract We report the case of a 71-year old male with relapsed acute myeloid leukemia who developed cytomegalovirus (CMV) colitis presenting as an apple core lesion during induction chemotherapy. CMV infection occurs rarely during induction chemotherapy for acute myeloid leukemia. CMV infection is usually observed in patients with Acquired Immune Deficiency Syndrome (AIDS) and in those on immunosuppressive agents following bone marrow transplant. Although rare, CMV colitis should be considered in patients who are critically ill after systemic chemotherapy as it can cause significant morbidity and mortality.

Introduction

CMV colitis typically occurs in severely immunocompromised patients with AIDS and in those on immunosuppressive agents after allogeneic stem cell transplant or solid organ transplant. Infection in immunocompetent patients is generally asymptomatic or may presents as transient symptoms consisting of fever, myalgias and cervical lymphadenopathy. In recent years, however, there have been a rising number of cases of severe CMV infections in immunocompromised elderly patients with malignancies (1). Given that CMV seroprevalence rates rise with age, there is a higher risk of reactivation in the setting of chemotherapy among elderly patients leading to significant morbidity and mortality. This report documents an incidental finding of CMV colitis presenting as an apple-core lesion after chemotherapy in a patient with acute myeloid leukemia.

Case Presentation

A 71-year-old man, with a past medical history significant for acute myeloid leukemia, underwent induction with cytarabine and idarubicin followed by consolidation with three cycles of high dose cytarabine. After one year of achieving remission, he was found to have relapsed leukemia during workup for anemia. He was admitted to the hospital for salvage chemotherapy with cytarabine and

mitoxantrone. Ten days after salvage chemotherapy he developed a neutropenic fever, diarrhea, abdominal pain and elevated total bilirubin. Abdominal ultrasound showed no signs of biliary obstruction. CT scan of the abdomen and pelvis showed pericecal inflammatory stranding without pneumatosis concerning for cecal typhlitis as well as an “apple core mass” of the ascending colon near the hepatic flexure concerning for colon cancer (Fig 1).

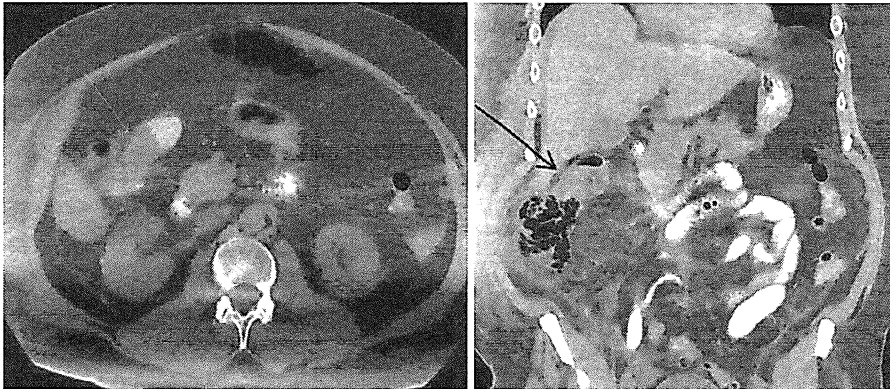


Figure 1 Abdominal computed tomography (CT) demonstrating apple core mass of the ascending colon.

Colonoscopy was deferred because he was critically ill with neutropenic enterocolitis. Despite initiation of broad spectrum antibiotics consisting of vancomycin and piperacillin-tazobactam, his clinical condition deteriorated. He was transferred to the medical intensive care unit with acute respiratory failure requiring assisted ventilation for several days. Blood cultures revealed *Granulicatella adjacens* and transthoracic echocardiogram revealed an aortic valve vegetation consistent with endocarditis requiring 6 weeks treatment with intravenous vancomycin. Additionally, he was noted to have hyperbilirubinemia secondary to hepatic veno-occlusive disease for which he completed a course of defibrotide with eventual normalization of liver enzymes. The patient improved clinically and subsequent bone marrow biopsy obtained 7 weeks after induction chemotherapy showed no evidence of leukemia. After six weeks of inpatient treatment and subsequent clinical improvement, a colonoscopy was performed to rule out colon cancer given the suspicious apple core lesion noted on the CT at the hepatic flexure. It revealed diffuse friable changes of the colonic wall extending from the cecum to hepatic flexure and transverse colon (Fig 2). Biopsies of the ascending colon, cecum, hepatic flexure and transverse colon were taken. He was discharged to acute rehabilitation due to deconditioning and a 55 pound weight loss after 7 weeks of inpatient hospitalization.

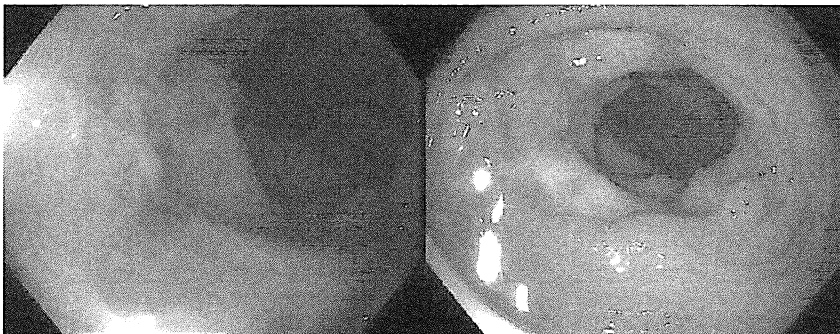


Figure 2 Colonoscopy showing a mass in the proximal transverse colon. Mucosa presents with nodularity, loss of vascular pattern, and diffuse exudates.

Final pathology from the cecal biopsy specimens showed chronic active colitis with cryptitis, ulceration and architectural distortion (Fig 3). CMV immunohistochemical staining was positive for CMV type inclusions compatible with CMV colitis (Fig 4). The biopsies were negative for dysplasia and malignancy. The ascending colon, hepatic flexure mass and transverse colon mass were negative for CMV inclusions on immunohistochemical stains but showed features consistent with chronic active colitis with cryptitis and architectural distortion.

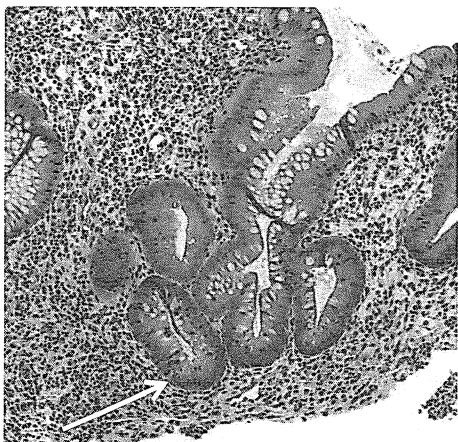


Figure 3: H&E, 126x magnification, showing changes of chronic, active colitis including crypt architectural distortion (branching) and focal active cryptitis (white arrow).

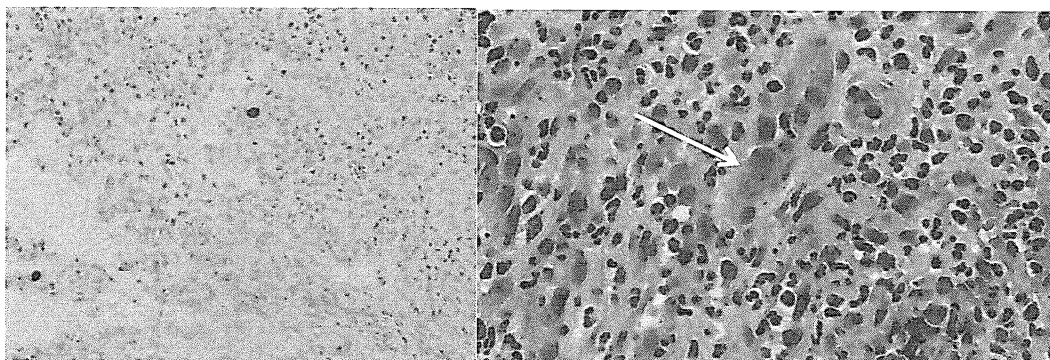


Figure 4: Left panel: CMV Immunohistochemical stain, 200x magnification, highlighting both nuclear and cytoplasmic staining (brown chromogen) within the ulcerated granulation tissue. Right panel: H&E stain, 400x magnification, showing a CMV infected endothelial cell with dot-like cytoplasmic inclusions (white arrow).

Our patient remained asymptomatic, without recurrence of diarrhea, fever or abdominal pain.

Discussion

We describe a rare case of CMV colitis in 71-year-old male treated with salvage chemotherapy consisting of cytarabine and mitoxantrone for relapsed acute myeloid leukemia.

CMV remains latent within the host after initial infection and can reactivate later in life. Clinically significant CMV disease is typically seen in profound immunocompromised state such as in AIDS and bone marrow transplant patients. Although CMV status among AIDS and transplant patients is closely monitored with the subsequent initiation of pre-emptive treatment using antiviral therapy if needed, similar monitoring and treatment plans are not routinely implemented for cancer patients receiving standard chemotherapy. Generally, conventional chemotherapy does not lead to significant alterations in lymphocyte function which is thought to be considered a high risk for the development of CMV disease. However, this paradigm may be changing.

There is increasing incidence of CMV reactivation in patients undergoing conventional chemotherapy. In our literature review, the earliest reported case of CMV colitis after standard chemotherapy was in a patient receiving azacitidine, published in 2011 (2). A recent study involving 15 cancer patients with 11 head and neck cancers, two lung cancers, one lymphoma, and one rectal cancer showed that all but one patient experienced CMV reactivation during the course of chemotherapy (3). Ten of the 15 participants had no detectable viral DNA before starting chemotherapy, but the viral load increased in 14 of 15 patients after chemotherapy. The highest CMV viral loads were >100 000 copies/mL in two patients who died. As viral loads increased, patients experienced an increase in symptoms as well as abnormal liver function tests. Another study showed that CMV viremia predicts high mortality rate in cancer patients. The retrospective analysis of cancer patients with CMV viremia showed overall mortality rate of 56% (60/107). This study recommended pre-emptive antiviral therapy for cancer patients with positive serum CMV PCR results, especially those requiring mechanical ventilation (4). It is not known in our case whether infection with CMV was present prior to or after the initiation of chemotherapy, as we did not obtain CMV serology.

Because CMV infections commonly occur after allogeneic stem cell transplant these serologic tests are used pre-transplant to establish the serostatus which predicts the risk of developing disease, and guides the use of pre-emptive antiviral therapy. The exact mechanism of the reactivation of CMV is not well established. However, disturbance of the host's immune defenses are thought to play an importance role. Male sex, lower body mass index, lymphopenia, hematological malignancy, steroid use and red blood cell transfusion within one month prior to CMV disease were risk factors for the development of CMV gastrointestinal infection in adult patients with cancer (5). Our patient possessed several risk factors to include male sex, lymphopenia, and hematological malignancy.

An apple core lesion of the colon is most frequently associated with obstruction of the colon lumen by colorectal carcinoma but can also be seen in setting of lymphomas, Crohn's disease, ulcerative colitis, ischemic colitis, chlamydia infection, colonic tuberculosis, helminthoma, colonic amoebiasis, villous adenoma, and colonic cytomegalovirus (6). Thus, tissue biopsy remains the keystone in obtaining the definitive diagnosis.

The gold standard for diagnosing CMV tissue invasive disease is the identification of CMV inclusion or positive CMV immunohistochemistry staining on histopathology (7). CMV gastrointestinal disease cannot be excluded based on negative blood tests. In a retrospective study of 81 solid organ transplant recipients 20 cases of biopsy-proven gastrointestinal disease were identified. The sensitivity of PCR for diagnosing

CMV gastrointestinal disease was only 85 percent (8). Plasma CMV DNA was undetectable in three patients with biopsy-proven CMV gastrointestinal disease. Also, gastrointestinal disease may be focal, as seen in this patient. Therefore, multiple biopsies may be needed to confirm the diagnosis of CMV colitis.

Individuals suspected to have CMV colitis should have plasma or whole blood PCR testing since PCR results are often available prior to biopsy results and may influence the decision to initiate antiviral therapy. Furthermore, the early PCR detection can prompt earlier treatment when "gold standard" testing is not available as colonoscopy is relatively contraindicated in the presence of neutropenia. Our patient's CMV infection resolved without the use of antivirals, which we attribute to recovery of the immune system. However it is possible that the use of early antiviral treatment could have led to shorter hospitalization and reduced complications.

Given the high morbidity and mortality associated with reactivated CMV disease, physicians may consider CMV testing, monitoring and pre-emptive treatment in leukemic patients with high risk features who are undergoing chemotherapy. A high index of suspicion for CMV disease may be beneficial in those cancer patients who clinically deteriorate and may benefit from early antiviral therapy to improve prognosis.

References

1. Jacob S, Zayyani N. Cytomegalovirus colitis masquerading as rectal malignancy in an immunocompetent patient. *Indian J of Pathol Microbiol.* 2015 Jan-Mar;58(1):80-82.
2. Khan R, Rudkin P, Grewal K, Leonard J, Hamodat M, Hutchinson J, et al. Cytomegalovirus colitis following azacitidine therapy. *Can J Infect Dis Med Microbiol.* 2011; 22(3):e21-e23.
3. Kuo CP, Wu CL, Ho HT, Chen CG, Liu SI, Lu YT. Detection of cytomegalovirus reactivation in cancer patients receiving chemotherapy. *Clin Microbiol Infect.* 2008; 14(3):221-227.
4. Wang Y, Wang N, Lin J, Perng C, Yeh K, Yang Y, et al. Risk factors and outcomes of cytomegalovirus viremia in cancer patients: a study from a medical center in northern Taiwan. *J of Microbiol Immunol Infect.* 2011 Dec; 44(6):442-448.
5. Ko JH, Peck KR, Lee WJ, Huh K, Yoo JR, Kim K, et al. Risk Factors for cytomegalovirus gastrointestinal disease in adult patients with cancer. *Eur J Clin Microbiol Infect Dis.* 2014 Oct; 33(10):1847-1853.
6. Paolantonio P, Dromain C. Imaging of Small Bowel, Colon and Rectum. 2014;1:15.
7. Ljungman P, Boeckh M, Hirsche HH, Josephson F, Lundgren J, Nichols G, et al. Definitions of Cytomegalovirus Infection and Disease in Transplant Patients for Use in Clinical Trials. *Clin Infect Dis.* 2017 Jan 1; 64(1):87-91.
8. Durand CM, Marr KA, Arnold CA, Tang L, Durand DJ, Avery RK, et al. Detection of cytomegalovirus DNA in plasma as an adjunct diagnostic for gastrointestinal tract disease in kidney and liver transplant recipients. *Clin Infect Dis.* 2013 Dec; 57(11):1550-1559.