

REPORT DOCUMENTATION PAGE				Form Approved OMB No. 0704-0188	
<p>The public reporting burden for this collection of information is estimated to average 1 hour per response, including the time for reviewing instructions, searching existing data sources, gathering and maintaining the data needed, and completing and reviewing the collection of information. Send comments regarding this burden estimate or any other aspect of this collection of information, including suggestions for reducing the burden, to the Department of Defense, Executive Service Directorate (0704-0188). Respondents should be aware that notwithstanding any other provision of law, no person shall be subject to any penalty for failing to comply with a collection of information if it does not display a currently valid OMB control number.</p> <p>PLEASE DO NOT RETURN YOUR FORM TO THE ABOVE ORGANIZATION.</p>					
1. REPORT DATE (DD-MM-YYYY) 10/26/2017		2. REPORT TYPE Poster		3. DATES COVERED (From - To) 10/29/2017	
4. TITLE AND SUBTITLE Late onset Presentation of Hori's Nevus in and Elderly Caucasian Female				5a. CONTRACT NUMBER	
				5b. GRANT NUMBER	
				5c. PROGRAM ELEMENT NUMBER	
6. AUTHOR(S) Cpt Jonathan Jeter				5d. PROJECT NUMBER	
				5e. TASK NUMBER	
				5f. WORK UNIT NUMBER	
7. PERFORMING ORGANIZATION NAME(S) AND ADDRESS(ES) 59th Clinical Research Division 1100 Willford Hall Loop, Bldg 4430 JBSA-Lackland, TX 78236-9908 210-292-7141				8. PERFORMING ORGANIZATION REPORT NUMBER 17418	
9. SPONSORING/MONITORING AGENCY NAME(S) AND ADDRESS(ES) 59th Clinical Research Division 1100 Willford Hall Loop, Bldg 4430 JBSA-Lackland, TX 78236-9908 210-292-7141				10. SPONSOR/MONITOR'S ACRONYM(S)	
				11. SPONSOR/MONITOR'S REPORT NUMBER(S)	
12. DISTRIBUTION/AVAILABILITY STATEMENT Approved for public release. Distribution is unlimited.					
13. SUPPLEMENTARY NOTES					
14. ABSTRACT Acquired Bilateral Nevus of Ota-like Macules (Hori's Nevus) are characterized clinically by bilateral blue-gray to gray-brown macules or patches most commonly over the zygomatic area and histopathologically by pigmented, elongated dendritic melanocytes within the dermis. Like other dermal melanocytoses this condition is more common in Asians and is usually congenital or appears during childhood or adolescence.					
15. SUBJECT TERMS					
16. SECURITY CLASSIFICATION OF:			17. LIMITATION OF ABSTRACT UU	18. NUMBER OF PAGES	19a. NAME OF RESPONSIBLE PERSON Clarice Longoria
a. REPORT	b. ABSTRACT	c. THIS PAGE			19b. TELEPHONE NUMBER (Include area code) 210-292-7141

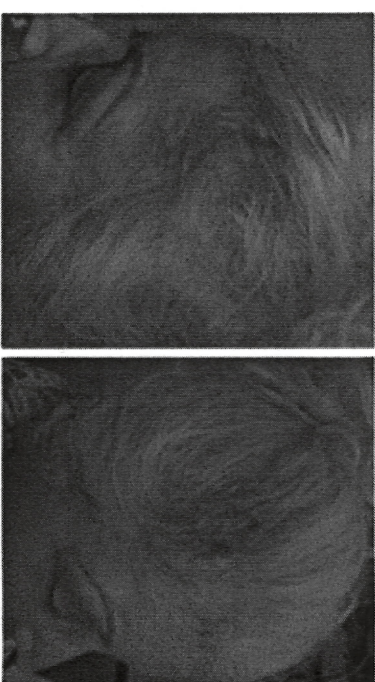
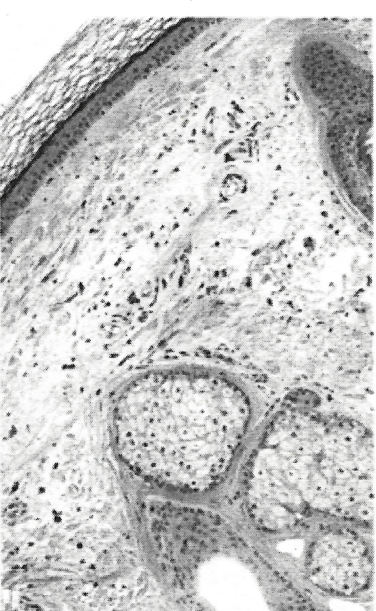Authors: CPT Jonathan Jeter, MD¹, CPT Ashley Burris, DO¹, MAJ Kevin Krauland, MD¹, Col Stephanie McLeish, MD¹

Acquired Bilateral Nevus of Ota-like Macules (Hori's Nevus) are characterized clinically by bilateral blue-gray to gray-brown macules or patches most commonly over the zygomatic area and histopathologically by pigmented, elongated dendritic melanocytes within the dermis¹. Like other dermal melanocytoses this condition is more common in Asians and is usually congenital or appears during childhood or adolescence^{2,3}.

Hori's nevus are usually congenital and have a poorly understood pathogenesis. Lesions consist of blue-grey macules distributed on the forehead, temples, eyelids, cheeks and nose while sparing the eye and oral mucosa. They persist for life with variable extension and color intensity. There is a female preponderance and they are more common in Asians with rare onset after the age of twenty years. Incidence for Caucasians is very low, particularly in the elderly. It is important to be aware of this possibility however rare so it can be differentiated from other more concerning acquired lesions.

Our patient is an 81 year old female with a rare presentation of Acquired Bilateral Temporal Hor's Nevus. She presented with an approximately two year history of asymptomatic bilateral temporal brown to gray pigmented patches. Punch biopsies were consistent with dermal melanocytoses and follow up full body skin exam and ophthalmology evaluation did not reveal any associated neoplasms or glaucoma.

On histology, there are deeply pigmented dendritic melanocytes and melanophages, highlighted by S-100 in figure C, that dissect through bundles of dermal collagen within the reticular dermis.



Awareness of this entity as a possibility for elderly Caucasians has two-fold importance. First, a new onset melanocytic lesion in an elderly Fitzpatrick I or II individual raises the spectre of the more prognostically concerning primary or even metastatic melanoma. Secondly, while generally a very safe lesion it does have associated risks, including glaucoma and very rarely melanoma. In other words when this condition does occur atypically in an elderly female, Caucasian or otherwise, it is important to differentiate it from more concerning lesions and to implement appropriate screening for possible associated diagnoses.

1. Bologna, Jean, Joseph L. Jorizzo, and Julie V. Schaffer. *Dermatology*. Edinburgh: Elsevier/Saunders, 2012. Print.
2. Maliax, Javier, Norberto Lopez, Rosario Haro, Elena Gonzalez, Jorge Angulo, and Luis Requena. "Late-onset Ito's Nevus: An Uncommon Acquired Dermal Melanocytosis." *Journal of Cutaneous Pathology* 34.8 (2007): 640-43. Web.
3. Resende, C., C. Araujo, A. P. Vieira, and C. Brito. "Late Onset Ito's Nevus." *Case Reports* 2013.May30 1 (2013): n. pag. Web.