



DEPARTMENT OF THE AIR FORCE
59TH MEDICAL WING (AETC)
JOINT BASE SAN ANTONIO - LACKLAND TEXAS

2 FEB 2017

MEMORANDUM FOR SGCEE

ATTN: CAPT TIMOTHY A. SOEKEN

FROM: 59 MDW/SGVU

SUBJECT: Professional Presentation Approval

1. Your paper, entitled Sealing of Corneal Lacerations Using Photo-Activated Rose Bengal Dye and Amniotic Membrane presented at/published to Sun and Science, Galveston, TX 22 April 2017 in accordance with MDWI 41-108, has been approved and assigned local file #17040.
2. Pertinent biographic information (name of author(s), title, etc.) has been entered into our computer file. Please advise us (by phone or mail) that your presentation was given. At that time, we will need the date (month, day and year) along with the location of your presentation. It is important to update this information so that we can provide quality support for you, your department, and the Medical Center commander. This information is used to document the scholarly activities of our professional staff and students, which is an essential component of Wilford Hall Ambulatory Surgical Center (WHASC) internship and residency programs.
3. Please know that if you are a Graduate Health Sciences Education student and your department has told you they cannot fund your publication, the 59th Clinical Research Division may pay for your basic journal publishing charges (to include costs for tables and black and white photos). We cannot pay for reprints. If you are 59 MDW staff member, we can forward your request for funds to the designated wing POC.
4. Congratulations, and thank you for your efforts and time. Your contributions are vital to the medical mission. We look forward to assisting you in your future publication/presentation efforts.

Linda Steel-Goodwin

LINDA STEEL-GOODWIN, Col, USAF, BSC
Director, Clinical Investigations & Research Support

PROCESSING OF PROFESSIONAL MEDICAL RESEARCH/TECHNICAL PUBLICATIONS/PRESENTATIONS

INSTRUCTIONS

USE ONLY THE MOST CURRENT 59 MDW FORM 3039 LOCATED ON AF E-PUBLISHING

1. The author must complete page two of this form:
 - a. In Section 2, add the funding source for your study [e.g., 59 MDW CRD Graduate Health Sciences Education (GHSE) (SG5 O&M); SG5 R&D; Tri-Service Nursing Research Program (TSNRP); Defense Medical Research & Development Program (DMRDP); NIH; Congressionally Directed Medical Research Program (CDMRP) ; Grants; etc.]
 - b. In Section 2, there may be funding available for journal costs, if your department is not paying for figures, tables or photographs for your publication. Please state "YES" or "NO" in Section 2 of the form, if you need publication funding support.
2. Print your name, rank/grade, sign and date the form in the author's signature block or use an electronic signature.
3. Attach a copy of the 59 MDW IRB or IACUC approval letter for the research related study. If this is a technical publication/presentation, state the type (e.g. case report, QA/QI study, program evaluation study, informational report/briefing, etc.) in the "Protocol Title" box.
4. Attach a copy of your abstract, paper, poster and other supporting documentation.
5. Save and forward, via email, the processing form and all supporting documentation to your unit commander, program director or immediate supervisor for review/approval.
6. On page 2, have either your unit commander, program director or immediate supervisor:
 - a. Print their name, rank/grade, title; sign and date the form in the approving authority's signature block or use an electronic signature.
7. Submit your completed form and all supporting documentation to the CRD for processing (59crdpubspres@us.af.mil). **This should be accomplished no later than 30 days before final clearance is required to publish/present your materials.** If you have any questions or concerns, please contact the 59 CRD/Publications and Presentations Section at 292-7141 for assistance.
8. The 59 CRD/Publications and Presentations Section will route the request form to clinical investigations, 502 ISG/JAC (Ethics Review) and Public Affairs (59 MDW/PA) for review and then forward you a final letter of approval or disapproval.
9. Once your manuscript, poster or presentation has been approved for a one-time public release, you may proceed with your publication or presentation submission activities, as stated on this form. **Note:** For each new release of medical research or technical information as a publication/presentation, a new 59 MDW Form 3039 must be submitted for review and approval.
10. If your manuscript is accepted for scientific publication, please contact the 59 CRD/Publications and Presentations Section at 292-7141. This information is reported to the 59 MDW/CC. All medical research or technical information publications/presentations must be reported to the Defense Technical Information Center (DITC). See 59 MDWI 41-108, *Presentation and Publication of Medical and Technical Papers*, for additional information.
11. The Joint Ethics Regulation (JER) DoD 5500.07-R, *Standards of Conduct*, provides standards of ethical conduct for all DoD personnel and their interactions with other non-DoD entities, organizations, societies, conferences, etc. Part of the Form 3039 review and approval process includes a legal ethics review to address any potential conflicts related to DoD personnel participating in non-DoD sponsored conferences, professional meetings, publication/presentation disclosures to domestic and foreign audiences, DoD personnel accepting non-DoD contributions, awards, honoraria, gifts, etc. The specific circumstances for your presentation will determine whether a legal review is necessary. **If you (as the author) or your supervisor check "NO" in block 17 of the Form 3039, your research or technical documents will not be forwarded to the 502 ISG/JAC legal office for an ethics review.** To assist you in making this decision about whether to request a legal review, the following examples are provided as a guideline:

For presentations before professional societies and like organizations, the 59 MDW Public Affairs Office (PAO) will provide the needed review to ensure proper disclaimers are included and the subject matter of the presentation does not create any cause for DoD concern.

If the sponsor of a conference or meeting is a DoD entity, an ethics review of your presentation is not required, since the DoD entity is responsible to obtain all approvals for the event.

If the sponsor of a conference or meeting is a non-DoD commercial entity or an entity seeking to do business with the government, then your presentation should have an ethics review.

If your travel is being paid for (in whole or in part) by a non-Federal entity (someone other than the government), a legal ethics review is needed. These requests for legal review should come through the 59 MDW Gifts and Grants Office to 502 ISG/JAC.

If you are receiving an honorarium or payment for speaking, a legal ethics review is required.

If you (as the author) or your supervisor check "YES" in block 17 of the Form 3039, your research or technical documents will be forwarded simultaneously to the 502 ISG/JAC legal office and PAO for review to help reduce turn-around time. If you have any questions regarding legal reviews, please contact the legal office at (210) 671-5795/3365, DSN 473.

NOTE: All abstracts, papers, posters, etc., should contain the following disclaimer statement:

"The views expressed are those of the [author(s)] [presenter(s)] and do not reflect the official views or policy of the Department of Defense or its Components"

NOTE: All abstracts, papers, posters, etc., should contain the following disclaimer statement for research involving humans:

"The voluntary, fully informed consent of the subjects used in this research was obtained as required by 32 CFR 219 and DODI 3216.02_AFI 40-402."

NOTE: All abstracts, papers, posters, etc., should contain the following disclaimer statement for research involving animals, as required by AFMAN 40-401_IP :

"The experiments reported herein were conducted according to the principles set forth in the National Institute of Health Publication No. 80-23, Guide for the Care and Use of Laboratory Animals and the Animal Welfare Act of 1966, as amended."

PROCESSING OF PROFESSIONAL MEDICAL RESEARCH/TECHNICAL PUBLICATIONS/PRESENTATIONS			
1. TO: CLINICAL RESEARCH	2. FROM: (Author's Name, Rank, Grade, Office Symbol) Timothy A. Soeken, Capt, O-3, SGCEE	3. GME/GHSE STUDENT: <input checked="" type="checkbox"/> YES <input type="checkbox"/> NO	4. PROTOCOL NUMBER: A-2009-03
5. PROTOCOL TITLE: (NOTE: For each new release of medical research or technical information as a publication/presentation, a new 59 MDW Form 3039 must be submitted for review and approval.) Sealing of Corneal Lacerations Using Photo-Activated Rose Bengal Dye and Amniotic Membrane			
6. TITLE OF MATERIAL TO BE PUBLISHED OR PRESENTED: Sealing of Corneal Lacerations Using Photo-Activated Rose Bengal Dye and Amniotic Membrane			
7. FUNDING RECEIVED FOR THIS STUDY? <input checked="" type="checkbox"/> YES <input type="checkbox"/> NO FUNDING SOURCE: US Department of Defense contracts W81XWH-09-2-0050 and			
8. DO YOU NEED FUNDING SUPPORT FOR PUBLICATION PURPOSES: <input type="checkbox"/> YES <input checked="" type="checkbox"/> NO			
9. IS THIS MATERIAL CLASSIFIED? <input type="checkbox"/> YES <input checked="" type="checkbox"/> NO			
10. IS THIS MATERIAL SUBJECT TO ANY LEGAL RESTRICTIONS FOR PUBLICATION OR PRESENTATION THROUGH A COLLABORATIVE RESEARCH AND DEVELOPMENT AGREEMENT (CRADA), MATERIAL TRANSFER AGREEMENT (MTA), INTELLECTUAL PROPERTY RIGHTS AGREEMENT ETC.? <input type="checkbox"/> YES <input checked="" type="checkbox"/> NO NOTE: If the answer is YES then attach a copy of the Agreement to the Publications/Presentations Request Form.			
11. MATERIAL IS FOR: <input checked="" type="checkbox"/> DOMESTIC RELEASE <input type="checkbox"/> FOREIGN RELEASE CHECK APPROPRIATE BOX OR BOXES FOR APPROVAL WITH THIS REQUEST. ATTACH COPY OF MATERIAL TO BE PUBLISHED/PRESENTED.			
<input type="checkbox"/> 11a. PUBLICATION/JOURNAL (List intended publication/journal.)			
<input type="checkbox"/> 11b. PUBLISHED ABSTRACT (List intended journal.)			
<input checked="" type="checkbox"/> 11c. POSTER (To be demonstrated at meeting: name of meeting, city, state, and date of meeting.) Sun and Science, Galveston, Texas, April 22, 2017			
<input checked="" type="checkbox"/> 11d. PLATFORM PRESENTATION (At civilian institutions: name of meeting, state, and date of meeting.) Sun and Science, Galveston, Texas, April 22, 2017			
<input type="checkbox"/> 11e. OTHER (Describe: name of meeting, city, state, and date of meeting.)			
12. HAVE YOUR ATTACHED RESEARCH/TECHNICAL MATERIALS BEEN PREVIOUSLY APPROVED TO BE PUBLISHED/PRESENTED? <input type="checkbox"/> YES <input checked="" type="checkbox"/> NO ASSIGNED FILE # _____ DATE _____			
13. EXPECTED DATE WHEN YOU WILL NEED THE CRD TO SUBMIT YOUR CLEARED PRESENTATION/PUBLICATION TO DTIC NOTE: All publications/presentations are required to be placed in the Defense Technical Information Center (DTIC).			
DATE December 16, 2016			
14. 59 MDW PRIMARY POINT OF CONTACT (Last Name, First Name, M.I., email) Timothy A. Soeken, timothy.a.soeken.mil@mail.mil			15. DUTY PHONE/PAGER NUMBER 594-1364
16. AUTHORSHIP AND CO-AUTHOR(S) List in the order they will appear in the manuscript.			
LAST NAME, FIRST NAME AND M.I.	GRADE/RANK	SQUADRON/GROUP/OFFICE SYMBOL	INSTITUTION (If not 59 MDW)
a. Primary/Corresponding Author Timothy A. Soeken	O-3	59TRS/59MDSG/SGCEE	
b. Hong Zhu	n/a	n/a	Massachusetts General Hosp
c. Brett W. Davies	O-4	59SGC/59MDOG/SGCEE	
d. Irene E. Kochevar	n/a	n/a	Massachusetts General Hosp
e. Anthony J. Johnson	retired O-6	Army	BAMC, Ophthalmology
17. IS A 502 ISG/JAC ETHICS REVIEW REQUIRED (JER DOD 5500.07-R)? <input type="checkbox"/> YES <input type="checkbox"/> NO			
I CERTIFY ANY HUMAN OR ANIMAL RESEARCH RELATED STUDIES WERE APPROVED AND PERFORMED IN STRICT ACCORDANCE WITH 32 CFR 219, AFMAN 40-401_IP, AND 59 MDWI 41-108. I HAVE READ THE FINAL VERSION OF THE ATTACHED MATERIAL AND CERTIFY THAT IT IS AN ACCURATE MANUSCRIPT FOR PUBLICATION AND/OR PRESENTATION.			
18. AUTHOR'S PRINTED NAME, RANK, GRADE Timothy A. Soeken/Capt/O-3	19. AUTHOR'S SIGNATURE SOEKEN.TIMOTHY.ADM.1266509428		20. DATE December 05, 2016
21. APPROVING AUTHORITY'S PRINTED NAME, RANK, TITLE Walter A. Steigleman, MD/CDR/Program Director	22. APPROVING AUTHORITY'S SIGNATURE STEIGLEMAN.WALTER.A.1185930137		23. DATE December 07, 2016

PROCESSING OF PROFESSIONAL MEDICAL RESEARCH/TECHNICAL PUBLICATIONS/PRESENTATIONS		
1st ENDORSEMENT (59 MDW/SGVU Use Only)		
TO: Clinical Research Division 59 MDW/CRD Contact 292-7141 for email instructions.	24. DATE RECEIVED January 24, 2017	25. ASSIGNED PROCESSING REQUEST FILE NUMBER 17040
26. DATE REVIEWED	27. DATE FORWARDED TO 502 ISG/JAC	
28. AUTHOR CONTACTED FOR RECOMMENDED OR NECESSARY CHANGES: <input checked="" type="checkbox"/> NO <input type="checkbox"/> YES If yes, give date. _____ <input type="checkbox"/> N/A		
29. COMMENTS <input checked="" type="checkbox"/> APPROVED <input type="checkbox"/> DISAPPROVED		
30. PRINTED NAME, RANK/GRADE, TITLE OF REVIEWER Linda D Harris, GS-14, Chief, Ops Branch	31. REVIEWER SIGNATURE HARRIS LINDA DAWN 113189058 <small>Digitally signed by HARRIS LINDA DAWN 113189058 DN: cn=Linda D. Harris, o=59 MDW, ou=CRD, email=harris.linda@59mdw.mil, c=US Date: 2017.01.24 10:37:15 -0500</small>	32. DATE January 30, 2017
2nd ENDORSEMENT (502 ISG/JAC Use Only)		
33. DATE RECEIVED	34. DATE FORWARDED TO 59 MDW/PA	
35. COMMENTS <input type="checkbox"/> APPROVED (In compliance with security and policy review directives.) <input type="checkbox"/> DISAPPROVED		
36. PRINTED NAME, RANK/GRADE, TITLE OF REVIEWER	37. REVIEWER SIGNATURE	38. DATE
3rd ENDORSEMENT (59 MDW/PA Use Only)		
39. DATE RECEIVED January 30, 2017	40. DATE FORWARDED TO 59 MDW/SGVU January 30, 2017	
41. COMMENTS <input checked="" type="checkbox"/> APPROVED (In compliance with security and policy review directives.) <input type="checkbox"/> DISAPPROVED		
42. PRINTED NAME, RANK/GRADE, TITLE OF REVIEWER Kevin Iinuma, SSgt/E-5, 59 MDW Public Affairs	43. REVIEWER SIGNATURE IINUMA KEVIN MITSUGU 1296227 <small>Digitally signed by IINUMA KEVIN MITSUGU 1296227 DN: cn=Kevin M. Iinuma, o=59 MDW, ou=Public Affairs, email=iinuma.kevin@59mdw.mil, c=US Date: 2017.01.30 10:11:51 -0500</small>	44. DATE January 30, 2017
4th ENDORSEMENT (59 MDW/SGVU Use Only)		
45. DATE RECEIVED	46. SENIOR AUTHOR NOTIFIED BY PHONE OF APPROVAL OR DISAPPROVAL <input type="checkbox"/> YES <input type="checkbox"/> NO <input type="checkbox"/> COULD NOT BE REACHED <input type="checkbox"/> LEFT MESSAGE	
47. COMMENTS <input type="checkbox"/> APPROVED <input type="checkbox"/> DISAPPROVED		
48. PRINTED NAME, RANK/GRADE, TITLE OF REVIEWER	49. REVIEWER SIGNATURE	50. DATE



DEPARTMENT OF THE AIR FORCE
59TH MEDICAL WING (AETC)
JOINT BASE SAN ANTONIO - LACKLAND TEXAS

8 DEC 2016

MEMORANDUM FOR SGCEE

ATTN: CAPT TIMOTHY A SOEKEN

FROM: 59 MDW/SGVU

SUBJECT: Professional Presentation Approval

1. Your paper, entitled Sealing of Corneal Lacerations Using Photo-Activated Rose Bengal Dye and Amniotic Membrane presented at/published to Military Refractive Surgery Safety and Standards Symposium, 10-12 January 2017 in accordance with MDWI 41-108, has been approved and assigned local file #17011.
2. Pertinent biographic information (name of author(s), title, etc.) has been entered into our computer file. Please advise us (by phone or mail) that your presentation was given. At that time, we will need the date (month, day and year) along with the location of your presentation. It is important to update this information so that we can provide quality support for you, your department, and the Medical Center commander. This information is used to document the scholarly activities of our professional staff and students, which is an essential component of Wilford Hall Ambulatory Surgical Center (WHASC) internship and residency programs.
3. Please know that if you are a Graduate Health Sciences Education student and your department has told you they cannot fund your publication, the 59th Clinical Research Division may pay for your basic journal publishing charges (to include costs for tables and black and white photos). We cannot pay for reprints. If you are 59 MDW staff member, we can forward your request for funds to the designated wing POC.
4. Congratulations, and thank you for your efforts and time. Your contributions are vital to the medical mission. We look forward to assisting you in your future publication/presentation efforts.

PAUL T. BARNICOTT, GS-15-DAF
Deputy Director, Clinical Research Division

PROCESSING OF PROFESSIONAL MEDICAL RESEARCH/TECHNICAL PUBLICATIONS/PRESENTATIONS

INSTRUCTIONS

1. The author must complete page two of the 59 MDW Form 3039 (this form).
 - a) In Section 2, add the funding source for your study [e.g., 59 MDW CRD Graduate Health Sciences Education (GHSC) [SG5 O&M]; SG5 R&D; Tri-Service Nursing Research Program (TSNRP); Defense Medical Research & Development Program (DMRDP); NIH; Congressionally Directed Medical Research Program (CDMRP); Grants; etc.]
2. Print your name, rank/grade, sign and date the form in the author's signature block or use electronic signature.
3. Attach a copy of the 59th MDW IRB or IACUC approval letter for the research related study. If this is a technical publication/presentation, state the type (e.g., case report, QA/QI study, program evaluation study, informational report/briefing, etc.) in the "Protocol Title" box of the 59 MDW Form 3039.
4. Attach a copy of your abstract, paper, poster and other supporting documentation.
5. Save and forward, via email, the processing form and all supporting documentation to your Unit Commander, Program Director or immediate supervisor for review/approval.
6. On page 2, have either your Unit Commander, Program Director or immediate supervisor:
 - a) Print their name, rank/grade/title, sign and date the form in the approving authority's signature block or use electronic signature.
7. Contact the 59th CRD/Publications and Presentations Section at (292-7141) for instructions for submitting the request form.
8. The 59th CRD/Publications and Presentations Section will route the request form to clinical investigations and public affairs and forward you a final letter of approval or disapproval.
9. Once your manuscript, poster or presentation has been approved for a one-time public release, you may proceed with your publication or presentation submission activities, as stated on the 59 MDW Form 3039. **[NOTE: For each new release of medical research or technical information as a publication/presentation, a new 59 MDW Form 3039 must be submitted for review and approval.]**
10. If your manuscript is accepted for scientific publication, please contact the 59th CRD/Publications and Presentations Section (292-7141). This information is reported to the 59 MDW/CC. All medical research or technical information publications/presentations must be reported to the Defense Technical Information Center (DTIC). See 59 MDWI 41-108, *Presentation and Publication of Medical and Technical Papers* for additional information.

NOTE: All abstracts, papers, posters, etc., should contain the following disclaimer statement:

"The views expressed are those of the [author(s)] [presenter(s)] and do not reflect the official views or policy of the Department of Defense or its Components."

NOTE: All abstracts, papers, posters, etc., should contain the following disclaimer statement for research involving humans:

"The voluntary, fully informed consent of the subjects used in this research was obtained as required by 32 CFR 219 and DoDI 3216.02_AFI 40-402, Protection of Human Subjects in Biomedical and Behavioral Research."

NOTE: All abstracts, papers, posters, etc., should contain the following disclaimer statement for research involving animals, as required by AFMAN 40-401_IP, *The Care and Use of Laboratory Animals in DoD Programs*:

"The experiments reported herein were conducted according to the principles set forth in the National Institute of Health Publication No. 80-23, Guide for the Care and Use of Laboratory Animals and the Animal Welfare Act of 1966, as amended."

PROCESSING OF PROFESSIONAL MEDICAL RESEARCH/TECHNICAL PUBLICATIONS/PRESENTATIONS			
TO: Clinical Research Division/SGVU (59 MDW/SGVU)	FROM: Author's Name, Rank, Grade, Office Symbol Timothy A. Soeken, Capt, O-3, Ophthalmology	PROTOCOL NUMBER: A-2009-03	
PROTOCOL TITLE - [NOTE: For each new release of medical research or technical information as a publication/presentation, a new 59 MDW Form 3039 must be submitted for review and approval.] Sealing of Corneal Lacerations Using Photo-Activated Rose Bengal Dye and Amniotic Membrane			
1. TITLE OF MATERIAL TO BE PUBLISHED OR PRESENTED Sealing of Corneal Lacerations Using Photo-Activated Rose Bengal Dye and Amniotic Membrane			
2. FUNDING RECEIVED FOR THIS STUDY? <input checked="" type="checkbox"/> YES <input type="checkbox"/> NO FUNDING SOURCE: US Department of Defense contracts W81XWH-09-2-004			
3. IS THIS MATERIAL CLASSIFIED? <input type="checkbox"/> YES <input checked="" type="checkbox"/> NO			
4. IS THIS MATERIAL SUBJECT TO ANY LEGAL RESTRICTIONS FOR PUBLICATION OR PRESENTATION THROUGH A COLLABORATIVE RESEARCH AND DEVELOPMENT AGREEMENT (CRADA), MATERIAL TRANSFER AGREEMENT (MTA), INTELLECTUAL PROPERTY RIGHTS AGREEMENT ETC.? <input type="checkbox"/> YES <input checked="" type="checkbox"/> NO <small>NOTE: If the answer is "YES" then attach a copy to the Agreement to the Publications/Presentations Request Form.</small>			
5. MATERIAL IS FOR (Check appropriate box or boxes for approval with this request.) <input checked="" type="checkbox"/> DOMESTIC RELEASE <input type="checkbox"/> FOREIGN RELEASE (ATTACH COPY OF MATERIAL TO BE PUBLISHED/PRESENTED)			
<input type="checkbox"/> PUBLICATION/JOURNAL (List intended publication/journal)			
<input type="checkbox"/> PUBLICATION ABSTRACT (List intended journal.)			
<input type="checkbox"/> POSTER (To be demonstrated at meeting/Name of Meeting, City, State, and Date of Meeting)			
<input checked="" type="checkbox"/> PLATFORM PRESENTATION (At civilian institutions/Name of Meeting, State, Date of Meeting) Military Refractive Surgery Safety and Standards Symposium, January 10-12, 2017			
<input type="checkbox"/> OTHER (Describe: Name of Meeting, City, State, and Date of Meeting)			
6. WHAT IS THE EXPECTED DATE YOUR PRESENTATION/PUBLICATION WILL BE SUBMITTED TO THE DEFENSE TECHNICAL INFORMATION CENTER (DTIC)?			
POINT OF CONTACT			
7. WHO IS THE PRIMARY 59 MDW POINT OF CONTACT? (Last, First, MI.) (Include email) Soeken, Timothy A timothy.a.soeken.mil@mail.mil			DUTY PHONE/PAGER No. 210-594-1364
AUTHORSHIP AND CO-AUTHOR(S) (List in the order they will appear in the manuscript)			
LAST NAME, FIRST NAME AND MI.	GRADE/RANK	SQUADRON/GROUP/OFFICE SYM	INSTITUTION (If not 59 MDW)
a. Primary/corresponding author Timothy A. Soeken	O-3	59TRS/59MDSG/SGCEE	59MDW
b. Hong Zhu	n/a	n/a	Massachusetts General Hospital
c. Shen DeMartelaere	O-6	Army	BAMC, Ophthalmology
d. Brett W. Davies	O-4	59SGC/59MDOG/SGCEE	59MDW
e. Rose Grimm	O-4	Army	USA ISR
f. Irene E. Kochevar	n/a	n/a	Massachusetts General Hospital
g. Anthony J. Johnson	retired O-6	Army	BAMC, Ophthalmology
I CERTIFY ANY HUMAN OR ANIMAL RESEARCH RELATED STUDIES WERE APPROVED AND PERFORMED IN STRICT ACCORDANCE WITH 32 CFR 219, AFMAN 40-401_IP AND 59 MDWI 41-108. I HAVE READ THE FINAL VERSION OF THE ATTACHED MATERIAL AND CERTIFY THAT IT IS AN ACCURATE MANUSCRIPT FOR PUBLICATION AND/OR PRESENTATION.			
AUTHOR'S PRINTED NAME/RANK/GRADE Timothy A. Soeken/Capt/O-3	AUTHOR'S SIGNATURE SOEKEN.TIMOTHY.ADAM.1266509 428		DATE Nov 8, 2016
APPROVING AUTHORITY'S PRINTED NAME, RANK, TITLE Walter A. Steigleman, MD/CDR/Program Director	APPROVING AUTHORITY'S SIGNATURE STEIGLEMAN.WALTER.A.11859301 37		DATE Nov 15, 2016

PROCESSING OF PROFESSIONAL MEDICAL RESEARCH/TECHNICAL PUBLICATIONS/PRESENTATIONS

1st INDORSEMENT (SGVU Use Only)

TO: Clinical Research Division
(59 MDW/SGVU)
(Contact 292-7141 for email instructions)

1. DATE RECEIVED
Nov 15, 2016

2. ASSIGNED PROCESSING REQUEST FILE NUMBER
17011

3. DATE REVIEWED

4. DATE FORWARDED TO PA

5. AUTHOR CONTACTED FOR RECOMMENDED OR NECESSARY CHANGES

☐ NO ☒ YES If yes give date: 15 Nov 16 ☐ N/A

6. COMMENTS

☒ APPROVED ☐ DISAPPROVED

PRINTED NAME, RANK/GRADE, TITLE OF REVIEWER

Linda D Harris, GS 14, Chief, Ops Br

DATE

17 Nov 16

SIGNATURE OF REVIEWER

HARRIS.LINDA.DAWN.113189058
0

2nd INDORSEMENT (PA Use Only)

TO: 59 MDW OFFICE OF PUBLIC AFFAIRS
(PA)

1. DATE RECEIVED

Dec 6, 2016

2. DATE FORWARDED TO 59 MDW/SGVU

Dec 8, 2016

6. COMMENTS ☒ APPROVED (In compliance with security and policy review directives.) ☐ DISAPPROVED

PRINTED NAME, RANK/GRADE, TITLE OF REVIEWER

Kevin Iinuma, SSgt/E-5, 59 MDW Public Affairs

DATE

Dec 8, 2016

SIGNATURE OF REVIEWER

IINUMA.KEVIN.MITSUGU.1
296227613

3rd INDORSEMENT (SGVU Use Only)

TO: 59 MDW/SGVU

1. DATE RECEIVED

2. SENIOR AUTHOR NOTIFIED BY PHONE OF APPROVAL OR DISAPPROVAL: ☐ YES ☐ NO ☐ Could not be reached ☐ Left message

3. DATE WRITTEN NOTICE OF APPROVAL AND CLEARANCE MAILED TO AUTHOR:

4. COMMENTS ☐ APPROVED ☐ DISAPPROVED

PRINTED NAME, RANK/GRADE, TITLE OF REVIEWER

SIGNATURE OF REVIEWER

DATE

Sealing of Corneal Lacerations Using Photo-Activated Rose Bengal Dye and Amniotic Membrane

Timothy A Soeken¹, Hong Zhu², Sheri DeMartelaere³, Brett W. Davies¹, Rose Grimm⁴, Irene E Kochevar², Anthony J Johnson^{1,4}

1 San Antonio Uniformed Services Health Education Consortium, San Antonio, TX

2. Wellman Center for Photomedicine, Massachusetts General Hospital, Boston, MA

3. Landstuhl Regional Medical Center, Landstuhl, Rhineland-Palatinate, Deutschland

4. United States Army Institute of Surgical Research, Fort Sam Houston, TX

Corresponding Author:

Timothy A. Soeken MD

3551 Roger Brooke Drive, ATTN: Ophthalmology, JBSA Ft Sam Houston, TX 78234

(210) 916-4519

Conflict of Interest: None of the authors have a conflict of interest to declare.

Keywords: Amniotic Membrane, Photo-Activated Rose Bengal Dye, Corneal Laceration

Funding Organizations: US Department of Defense contracts W81XWH-09-2-0050 and FA9550-10-1-0537

Purpose: Watertight closure of perforating corneoscleral lacerations is necessary to prevent epithelial ingrowth, infection, and potential loss of the eye. Complex lacerations can be difficult to treat, and repair with sutures alone is often inadequate. In this study we evaluated a sutureless technology for sealing complex corneal and scleral lacerations that bonds amniotic membrane (AM) to the wound using only green light and the dye, rose bengal (RB).

Methods: AM was impregnated with RB, then sealed over lacerations using green light to bond the AM to the de-epithelialized cornea surface. This process was compared to suture repair of three laceration configurations in New Zealand White (NZW) rabbits in three arms of the study. A fourth study arm assessed the side effect profile including viability of cells in the iris, damage to the blood-retinal barrier, the retinal photoreceptors, retinal pigment epithelium (RPE) and choriocapillaris in Dutch Belted (DB) rabbits.

Results: Analyses of the first three arms revealed no significant difference between the groups regarding induced edema to the corneal stroma, induced stroma thickening, endothelial necrosis, and inflammation. In the fourth arm, iris cells appeared unaffected and no evidence of breakdown of the blood retina barrier was detected. Retina from greenlight laser treated eyes showed normal RPE, intact outer segments and normal outer nuclear layer (ONL) thickness.

Conclusions: The results of these studies established that a light-activated method to crosslink AM to the cornea can be used for sealing complex penetrating wounds in the cornea and sclera with minimal inflammation, or secondary effects.

The views expressed are those of the authors and do not reflect the official views or policy of the Department of Defense or its Components.

43 *The experiments reported herein were conducted according to the principles set forth in the*
44 *National Institute of Health Publication No. 80-23, Guide for the Care and Use of Laboratory*
45 *Animals and the Welfare Act of 1966, as amended.*

46

47 **Introduction**

48 Penetrating injury to the eye is a frequent ophthalmic emergency at trauma centers worldwide.

49 From the standpoint of the military ophthalmologist, fragments and debris propelled at high
50 velocity by improvised explosive devices (IEDs) have increased the incidence of penetrating eye
51 injuries compared to conflicts prior to the development of IEDs. At the height of the recent
52 conflict in Iraq, 29% of all evacuations from Iraq were due to ocular injuries (Joint Theater
53 Trauma Report, 2012)

54 When an eye sustains a penetrating or perforating injury, rapid closure with the formation of a
55 water-tight seal is critical to preventing infection and preventing surface epithelium from gaining
56 entry into the eye. This stabilizes the eye until further reconstructive surgery can occur. Despite
57 the small surface area of the eye, repair of complex injuries can be labor and time intensive.
58 Effective repair of these injuries requires the use of specialized instruments and advanced
59 surgical training.

60 In complex lacerations in which flat objects are propelled through the cornea, the lamella of the
61 cornea can shred, making closure by suture impossible. In these cases surgical adjuncts are used
62 to close the wound, none of which are currently approved by the FDA for this purpose.

63 Cyanoacrylate glue is the most commonly used adjunct, effectively binding to the cornea and
64 sealing the wound. While effective, there are a number of disadvantages to the use of this glue.
65 These include difficulty in removal, adhesion to the sutures, and the opacity it creates. Thus, the
66 overall goal of this research was to find a more efficient method of sealing complex corneal
67 lacerations.

68 To achieve this goal, we utilized a light-activated technology in which amniotic membrane (AM)

69 impregnated with rose bengal (RB) dye is cross-linked to the surface of the cornea. RB is a
70 common FDA-approved photoactive vital dye used as a diagnostic tool for staining ocular
71 surface abnormalities. Since it uses currently FDA approved materials/devices (clinical laser,
72 RB, AM) this method may be integrated rapidly to the modern civilian and deployed
73 environment with materials already in the ophthalmic surgical set.

74

Methods

This study utilized two separate groups of rabbits. For the treatment arms, 98 New Zealand White (NZW) rabbits were acquired. These rabbits were used to perform the surgical procedures and to record the clinical and histopathological data, all of which were completed at the United States Army Institute of Surgical Research (USAISR), San Antonio, TX. To evaluate the side effect profile of the procedure, 17 young female Dutch Belted (DB) rabbits were acquired. These rabbits were supplied by Millbrook Labs (Amherst, MA), and all procedures were performed at Massachusetts General Hospital, Boston, MA. All experiments were humanely performed in accordance with the ARVO statement for the Use of Animals in Ophthalmic and Vision Research. The study protocols were approved by the USAISR Institutional Animal Care and Use Committee (IACUC) and the Subcommittee on Research Animal Care at Massachusetts General Hospital.

Methods, Treatment Arms

A summary of the methods can be found in Table 1. The 98 NZW rabbits of the treatment arms were separated into three treatment arms. For every animal, only the right eye was operated on in accordance with IACUC guidelines. Each treatment arm was separated into two groups—one control group treated with sutures only and one study group treated with the AM technique. In the first arm, a 4 mm linear central corneal laceration in the visual axis was made. In the second arm, a V shaped laceration in the central cornea with two 3 mm legs in an equatorial triangle fashion was made. In the third arm, a 4 mm corneal-scleral laceration centered in the limbus was made. The RB and the human AM used in this study were prepared and attained as previously described (Verter et al, 2011). A prototype light delivery system was constructed to deliver diffuse retina-safe light levels while providing sufficient energy for sealing corneal wounds

(Verter et al, 2011). All studies employed a clinical laser that emits green light at 532 nm. The laser instrument is an IRIDEX OcLightTX Ophthalmic 532 nm Laser Diode. The set power was 400 mW, and the beam diameter was 13 mm with a beam area of 1.33 cm². Due to losses in the delivery system, the measured power was 360 mW. The irradiance at 2 cm from the exit point of the lens was 271 mW/cm². Laser power was measured with a Scientech model 365, SN: 6277 (head model 380101).

The first arm included a total of 40 live NZW rabbits. The right eye of all rabbits received a simple 4 mm linear central corneal laceration. The rabbit was placed under anesthesia, then prepped and draped in the normal sterile fashion for eye surgery. A lid speculum was placed in the eye and centered under the operating microscope. A surgical ruler was used to measure the central 4 mm of the cornea and 2 dots were placed. A diamond knife was then used to make a central laceration between the dots, which resulted in a gaping wound and collapse of the anterior chamber. In the 19 rabbits that served as the control group, repair of their corneal wound was completed with interrupted 10-0 nylon sutures. In the 17 rabbits of the treatment group the epithelium in the center of the cornea was debrided, and viscoelastic was injected into the wound to protect the lens and deepen the chamber. One central 10-0 nylon suture was placed. Pre-prepared AM impregnated with RB was then centered on the wound. The amnion was gently stroked with a 27 gauge cannula until it dried sufficiently to adhere to the cornea. The microscope was moved, the laser hand piece was centered over the wound and the AM was irradiated. The laser was set to a 13 mm beam diameter and 271 mW/cm² was delivered to the AM surface for 250 seconds for a total fluence of 68 J/cm². Afterwards the wound was tested for water-tightness with fluorescein staining, and a tonopen was used to ensure the eye was at physiologic pressure.

121 The second arm of the study included a total of 30 NZW rabbits. For this arm, a complex V-
122 shaped laceration was made in the center of each cornea. Each leg of the "V" was approximately
123 3 mm in length. The control group consisted of 15 rabbits, each of which received closure of
124 their corneal wound with 5 interrupted 10-0 nylon sutures. The treatment group also consisted of
125 15 rabbits. After the epithelium was debrided, a single 10-0 nylon suture was placed at the
126 wound apex. The AM was then applied and irradiated as previously described. All wounds were
127 tested for water-tightness with fluorescein staining, and a tonopen was used to ensure the eye
128 was at physiologic pressure.

129 The third arm of the study included 28 NZW rabbits. For this arm, a 3 clock hour peritomy was
130 placed from 10 o'clock until 1 o'clock. A 4mm laceration centered on the limbus in the 11:30
131 meridian was made. The control group consisted of 15 rabbits, each of which received closure of
132 their corneoscleral laceration with four interrupted nylon sutures (10-0 on the cornea, 9-0 at the
133 limbus, and 8-0 on the sclera). The treatment group consisted of 13 rabbits. After the epithelium
134 was debrided, a single 10-0 nylon suture was placed at the limbus. The AM was then applied
135 and irradiated as previously described. All wounds were tested for water-tightness with
136 fluorescein staining, and a tonopen was used to ensure the eye was at physiologic pressure.

137 In the post-operative period, each animal in all treatment groups was further subdivided into
138 necropsy times of 3, 7 and 28 days. This allowed for clinical and histopathologic evaluation at
139 various postoperative stages. Following euthanasia, the treated globes were isolated and the AM
140 was removed. The globes were fixed in Modified Davidson's solution for 24-48 hours and then
141 transferred to 10% buffered neutral formalin. After fixation, each globe was transected sagittally,
142 embedded in paraffin, sectioned at 5 μ m, and stained with hematoxylin and eosin (H&E).
143 Corneal sections were analyzed for mononuclear and polymorphonuclear inflammation.

vascularization of the stroma, stromal edema, endothelial necrosis, and regeneration of the corneal epithelium.

Histopathological analysis was performed using a five point grading system (0-4) for each of the above variables. A score of zero was assigned for no observable characteristics, one was scored for minimal observable characteristics, two for mild, three for moderate, and four for severe characteristics. Inflammation was quantified by counting inflammatory cells per high powered field.

The results were then analyzed utilizing a repeated measures mixed model ANOVA for time dependent analysis. If the effect of time or the time-treatment interaction were not significant, the data was pooled together and a one-way ANOVA or Wilcoxon's Test were performed. All p-values < 0.05 were deemed statistically significant. All statistical analysis was performed using JMP v10.0.

Methods Side Effect Arm

The fourth arm of the study included 17 DB rabbits. The right eye of each rabbit was subjected to a simple 3 mm linear central corneal laceration. The epithelium was mechanically scratched after adding 30% ethanol for 15 sec on the cornea, and then a 3 mm-long linear incision was made in the central cornea. Human AM in diameter previously stained with RB was then placed over the incision as previously described (Verter et al, 2011). The cornea was then exposed to green light at an irradiance of 0.25 W/cm^2 for a total of 6.6 min (100 J/cm^2). Half way through the 6.6 min, an additional 30 sec addition of RB was re-applied, then irradiated for the second half of the 6.6 min. This is done because the first 3.3 min bleaches the pink color of the dye and sufficient dye present to absorb the green light for crosslinking.

166 A LaserScope Aura StarPulse Laser (San Jose, CA) with a 600- μ m optical fiber in diameter was
167 used for eye safety evaluation. The power was measured with a power meter (NOVA; Ophir
168 Optonics Ltd., North Andover, MA) before each use. An optical system was designed and built
169 to focus a 12 mm laser beam on the cornea then expand the beam to impinge on a larger area of
170 the retina to minimize potential light-initiated damage as previously described (Zhu et al, 2016).
171 The cornea surface temperature was recorded during treatment using a non-contact precision
172 infrared thermometer (Fluke 572, Fluke Corporation, Everett, WA). The left eye of each rabbit
173 served as a control; it was also de-epithelialized but received no further treatment. For the change
174 in temperature, the measurements were made on each treated eye. The temperature at the
175 beginning of the irradiation ($\sim 32^{\circ}\text{C}$) was compared to the mean temperature between 60 and 360
176 minutes irradiation.

177 The lactate dehydrogenase-nitro blue tetrazolium (LDH-NBT) staining method was used to
178 assess the activity of the thermally sensitive enzyme, LDH as an indication of iris cell viability
179 using a previously described method (Zhu et al, 2016). A blue formazan product indicates cell
180 viability. No statistical analysis of the iris damage was done. The response was qualitative,
181 either blue formazan was observed or not.

182 The rabbits were sacrificed on day 1 or 28. Prior to euthanasia, fundus fluorescein angiography
183 (FFA) was performed on day 28 after treatment of DB rabbits ($n = 4$ / day). After anesthesia the
184 pupil was dilated with 2 drops of 1% tropicamide hydrochloride eye solution. A scanning laser
185 ophthalmoscope (SLO) (HRA2, Heidelberg Engineering, Heidelberg) was used. One milliliter of
186 10% fluorescein sterile solution (Alcon Inc., Fort Worth, TX) was injected into the marginal ear
187 vein, and images were recorded immediately after injection. No statistical analysis of the FFA
188 was done. The vessels were observed for breakdown or leakage from the blood vessels.

189 Following necropsy, the cornea, iris and retina were separated and fixed in 10% formalin for 24
190 hours at room temperature, then embedded in paraffin. Five-micron vertical cut sections were
191 stained with H&E and scanned using a digital slide scanner (NanoZoomer Digital Pathology
192 System, Hamamatsu, Photonics, Japan). The morphology of the corneas was observed by light
193 microscopy. Retina H&E sections were used for outer nuclear layer thickness measurements.
194 The thickness of the outer nuclear layer (ONL) from the optic disc was measured at 10 points
195 with 200- μ m intervals in each section to obtain the average for each retina. ONL thickness data
196 were tested by a two-tailed unpaired Student t test.
197 Each histologic evaluation was carried out in a masked fashion.

Results, Treatment Arms

For the first, second and third arms of this study, there was no statistically significant difference between the treatment groups and control groups in terms of induced edema to the corneal stroma, induced stroma thickening, endothelial necrosis, and inflammation. This held true for all post-operative periods. Even after pooling the time points together, differences between these histology values remained non-significant. Figure 1 shows the pooled mean plot demonstrating there is no significant difference comparing crosslinking and suture closure for induced edema to the corneal stroma, induced stroma thickening, endothelial necrosis, nor inflammation (Wilcoxon p-values were 0.11, 0.45, 0.30, and 0.59, respectively).

In order to understand the healing response to the performed interventions, a 2-way repeated measures mixed model ANOVA was utilized to evaluate the effects of using laser versus suture at all the various time points. Additional analysis between laser closure and suture closure demonstrated no difference in neovascularization, endothelial necrosis, inflammation, edema or stromal thickening between the laser and suture techniques.

Between suture repair and laser crosslinking repair for the same time points there were no statistical differences in any of the categories except epithelial hyperplasia. On day 3 there was more epithelial hyperplasia in the control group, but the changes were not persistent as time progressed and none of the animals scored over 1 on the 0-4 scale ($p=0.05$).

On slit lamp evaluations, the sutured corneas remained clearer than the cross-linked corneas at the 3 and 7 day time points. At 28 days there were no significant differences. Of note, by 7 days all the corneas were sufficiently clear to see iris detail, sufficient to allow reconstructive surgery to be performed.

Results, Side Effects Arm

221 In the fourth arm, the temperature on the surface of cornea during the procedure at 0.25 W/cm^2
222 in DB rabbits was measured. As shown in Figure 2, the temperature increased 8 degrees.
223 In order to assess damage to iris cells during the procedure, the LDH-NBT assay was used which
224 shows deposition of a blue formazan product if cells are viable. The positive control was
225 untreated DB rabbit iris, which showed blue deposits in cells near melanin (Figure 3). Iris tissue
226 harvested 1 and 28 days after treatment showed similar deposits of blue formazan product in the
227 cells adjacent to melanin granules as found in the positive control.
228 FA images of the retina around the optic disc were examined for signs of leakage indicating
229 breakdown of the blood retina barrier, which may result from laser-induced RPE or endothelial
230 cell damage. FFA was performed on Day 28 after treatment in DB rabbit corneas (100 J/cm^2 ; $n =$
231 $4 / \text{group}$). Retinal vessels in the region of the optic disc were visible including small diameter
232 vessels (Figure 4). On Day 28 after treatment, diffuse fluorescein fluorescence in the avascular
233 regions of the fundus was not detected nor was there any appearance of fluorescein leakage from
234 the retinal vessels (Figure 4 B).
235 Irreversible damage to the photoreceptors could be assessed by measuring the ONL thickness,
236 which decreases after photoreceptor cell death. No significant difference was found in ONL
237 thickness between retinæ from treated and untreated eyes on either day 1 or day 28 ($n = 6 /$
238 group , $p > 0.05$, Figure 4C).
239

Discussion

On the basis of prior studies, our team designed this study to compare the sealing of a central cornea laceration and a corneoscleral laceration sealed with crosslinked RB impregnated AM to traditional suture closure. Specifically, RB, without the AM, activated with neodymium:YAG laser light at 532 nm has been shown to seal a simple corneal laceration and provide a long duration seal (Proano et al, Invest 2004; Proano et al, J Cataract 2004). Later, it was demonstrated that the technique used in this study sealed incisions in *ex vivo* rabbit eyes to withstand an intraocular pressure of 350 mm Hg, more than 10 times normal pressure (Verter et al, 2011).

To determine the appropriate laser parameters for sealing the AM to the surface of the eye, we carried out pilot *ex vivo* studies. Over 1000 seconds exceeded the calculated safety threshold. Successful cross-linking the AM was attained at 400 seconds, and at 250 seconds there was about 90% strength. Thus, we selected 250 seconds in this protocol, which correlated to a total fluence of 68 J/cm² when the laser was set to a 13mm beam diameter and 271 mW/cm². The combination of the 1000 second upper limit and the 250 second treatment would allow up to four tries if the AM did not adhere to the ocular surface satisfactorily.

In the model development stage for this study, we determined that due to gaping of the central lacerations and the larger V shaped laceration, and brisk aqueous outflow, a direct closure with AM was near impossible. This also put the patient at risk because the scar required to fill the gap would decrease visual function, the AM over the gap would tectonically be too weak, and the brisk outflow would also prevent adhesion of the AM to the cornea prior to crosslinking. This was not evident in the abattoir eyes used in pilot studies and the previous study (Verter, 2011) because there was no aqueous outflow and the low pressure did not cause wound gap. Thus the

technique was modified to place one suture in the wound to approximate the corneal stromal surfaces. This accomplished three things. It minimized the scar size, tectonically strengthened the cornea and allowed air or viscoelastic to block the outflow of aqueous sufficient to crosslink AM to the cornea.

Previous studies indicate that RB demonstrated potential toxicity to cultured epithelial cells and that the use of AM in albino rabbits is associated with granulomatous inflammation (Tabery, 1998; Barton et al, 2001). As demonstrated in Figure 1, crosslinking AM to the cornea surface was no more damaging than suturing. This study also demonstrates histopathologically that the AM patched corneas did not cause any adverse reactions in the rabbits. The only statistically significant difference in the histopathological analysis of the three surgical arms was the epithelial hyperplasia noted on day 3. The authors hypothesize that this reflects the healing of the surface after scraping and neovascularization. None of the animals scored over one on the zero to four scale. The neovascularization noted was related to anterior chamber and iris changes that the rabbit developed while the anterior chamber was flat.

On two rabbits the iris was stuck to the underside of the cornea on slit lamp evaluation. This is not an uncommon response and likewise occurs in humans when the iris comes in contact with cornea for a period of time and the iris is irritated or inflamed. This could contribute to gradual loss of endothelial cells, and could prompt a return to the operating room in the future to remove the iris if the adhesion was significant or evidence of endothelial failure was present. There appeared to be no neovascularization responses to the cross-linking procedure in the wounds. To evaluate potential deleterious effects of laser crosslinking, we analyzed the cornea surface temperature, iris cellular damage, and retinal blood-retinal barrier and outer nuclear layer. None of these measures indicated damage to these ocular structures resulting from the treatment.

Since photothermal damage on the cornea might occur due to absorption of the laser light, we measured the temperature on the surface of cornea during the procedure. As shown in Figure 2, the temperature increased less than 42°C, a temperature at which thermal damage is not expected (Landry and Marceau, 1978). In addition to the cornea, we also evaluated the thermal effects on the iris. High irradiances and fluences may heat the melanin particles in the iris and damage adjacent iris cells. Using the LDH-NBT staining method, an accepted method for detecting thermal damage in tissues (Sherwood and Flotte, 2007), our results indicated that iris cells near the melanin particles were still viable (Figure 3). These results demonstrate that the iris cells are not thermally damaged during treatment.

We used two methods to assess potential side effects on the retinas of DB rabbits, namely, FFA and ONL thickness. Fluorescence images of the retina around the optic disc were examined for signs of fluorescein leakage indicating breakdown of the blood retina barrier resulting from laser-induced RPE or endothelial cell damage. FFA performed on Day 28 after treatment showed retinal vessels, including small diameter vessels, without diffuse fluorescein fluorescence in the avascular regions of the fundus or any appearance of fluorescein leakage from the retinal vessels (Figure 4B). These results suggest that the retinal radiant exposure was not sufficient to initiate thermal damage to either the RPE cells or to retinal vessels.

Irreversible damage to the photoreceptors was assessed by measuring the outer nuclear layer thickness, which decreases after photoreceptor cell death. No significant difference was found in outer nuclear layer thickness between retinae from treated and untreated eyes either on Day 1 and Day 28 (Figure 4 C).

In conclusion, the results of these studies established that a light-activated method to crosslink AM to the cornea can be used for sealing complex penetrating wounds in the cornea, and the

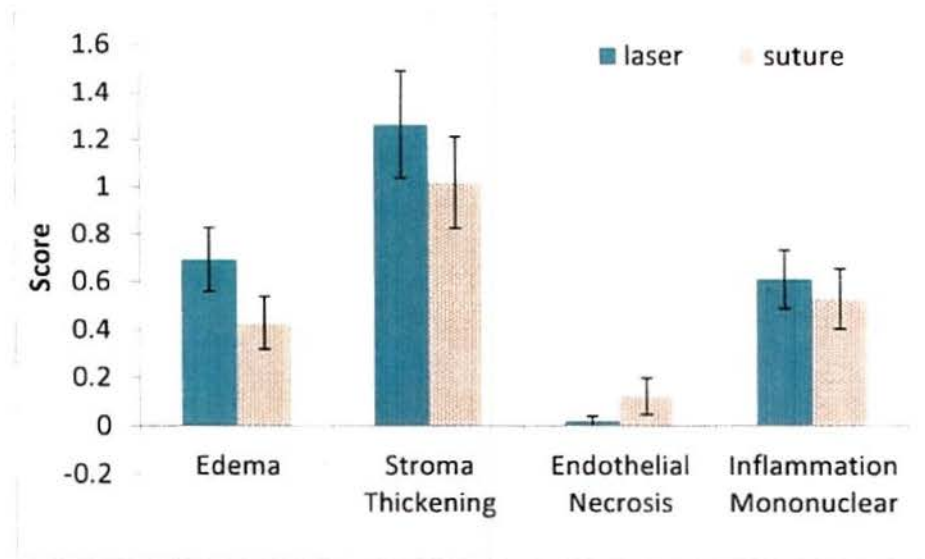
309 sclera, with minimal inflammation, or secondary effects. We did not identify problems or
310 obstacles that will inhibit the translation of this light-activated repair technique to clinical use.
311 This treatment involves off-label use of three FDA-allowed materials/devices (clinical laser, RB,
312 human AM), which may facilitate translation to the clinic. Rose bengal is approved as
313 diagnostic agent but not as a treatment agent; thus further safety documentation would be
314 beneficial. In all applications a strong seal was produced immediately. The best method for
315 sealing corneal and scleral wounds is to bond AM over the wound using a dye and green laser
316 light, after any significant gaps in the stroma have been reduced with sutures. Thus, for these
317 experiments this technology appears to be best employed as an adjunct to only suturing to reduce
318 operative time or when edges cannot be approximated in cases with brisk aqueous outflow, as
319 occurs in simple lacerations.

	Treatment Arms			Side Effect Arm
Location of Experimental Procedure	USAISR, San Antonio, TX			MGH, Boston, MA
Rabbit Type	New Zealand White			Dutch Belted Pigmented
Study Arm	1	2	3	4
Number of Rabbits	40	30	28	17
Experimental Wound	4mm linear central cornea laceration	"V" shaped central cornea laceration	4mm linear corneoscleral laceration	3mm linear central cornea laceration
Number of Experimental Eyes	21	15	13	17
Repair Method	A single central 10-0 nylon suture, and Rose Bengal impregnated amniotic	A single 10-0 nylon suture at the "V" apex, and Rose Bengal impregnated amniotic	A single 10-0 nylon suture at the limbus, and Rose Bengal impregnated amniotic membrane irradiated for	Rose Bengal impregnated amniotic membrane irradiated for 400 seconds of a 12mm diameter 400mW laser

	membrane irradiated for 250 seconds of a 13mm diameter 400mW laser	membrane irradiated for 250 seconds of a 13mm diameter 400mW laser	250 seconds of a 13mm diameter 400mW laser	
Number of Control Eyes	19	15	15	-
Repair Method	interrupte d 10-0 nylon sutures	interrupted 10-0 nylon sutures	interrupted nylon sutures: 10-0 on cornea, 9-0 on limbus, 8-0 on sclera	-

320

321 Table 1. Summary of Methods.



322

323 Figure 1. Comparison of histopathological results after sealing amniotic membrane over cornea
 324 lacerations using laser crosslinking or sutures. The data are the mean values \pm SD of the values
 325 measured at three time points (3, 7 and 28 days).

326

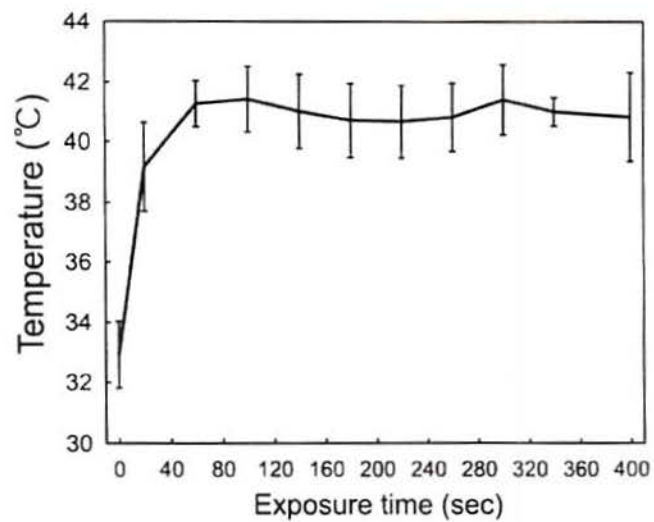


Figure 2. Temperature of the cornea surface during irradiation of RB-impregnated amniotic membrane over a central cornea laceration using 0.25 W/cm^2 at 532 nm. ($n = 6$ / group).

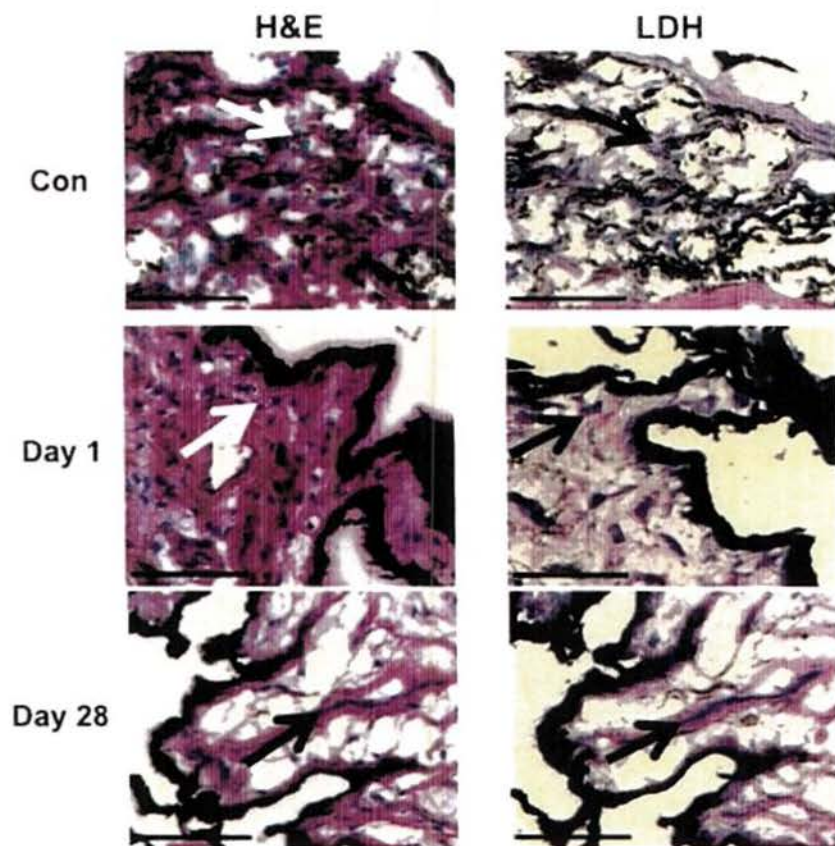


Figure 3. Evaluation of cell viability in iris tissue after sealing amniotic membrane over central cornea lacerations using laser crosslinking. Iris tissue sections were stained with H&E or for LDH activity indicating cell viability by formation of a blue formazan product. Arrows showing the areas of blue formazan.

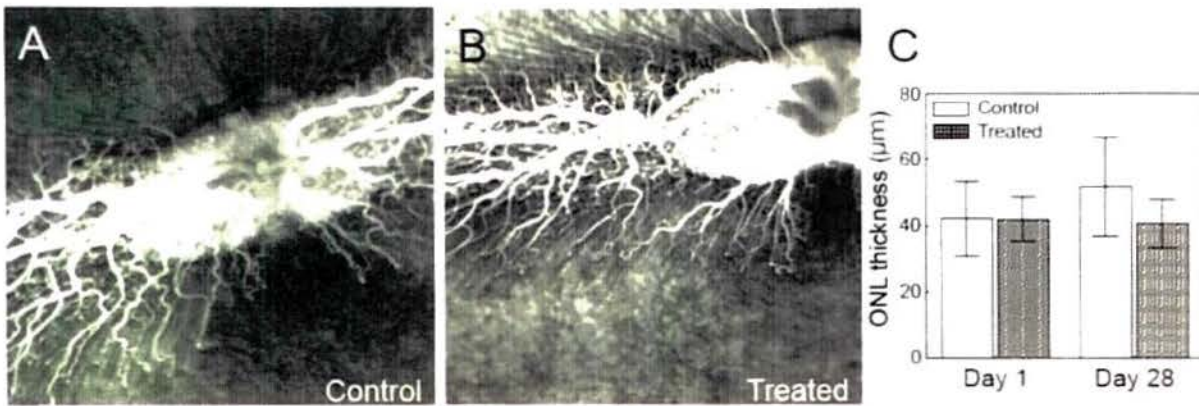


Figure 4. FFA and ONL thickness measurement of retinas from control eyes and from eyes treated with laser crosslinking to seal amniotic membrane over central cornea lacerations (third arm of study). Images were taken on Day 28 post treatment of (A) control and (B) treated eyes. (C) ONL thickness measured on H&E sections of retinas in control and treated eyes on Day 1 and Day 28. (n = 6 / group).

344 REFERENCES

- 345 Joint Theater Trauma Report, provided by Robert Mazzoli, Evacuation incidents 2002-2012.
- 346 Verter EE, Gisel TE, Yang P, et al. Light-Initiated Bonding of Amniotic Membrane to Cornea,
347 *IOVS* 2011;52(13):9470-9477.
- 348 Irene Kochevar, Final Report: Sealing Penetrating Eye injuries with Photoactivated bonding,
349 September 2013.
- 350 Delori F, Webb R, Sliney D. Maximum permissible exposures for ocular safety (ANSI 2000),
351 with emphasis on ophthalmic devices. *J Opt Soc Am A Opt Image Sci Vis* 2007;24:1250-1265.
- 352 Barton K, Budenz DL, Khaw PT, et al. Glaucoma Filtration Surgery using Amniotic Membrane
353 Transplantation. *IOVS* 2001;42(8):1762-1768.
- 354 Tabery HM. Toxic effect of rose bengal dye on the living human corneal epithelium, *Acta*
355 *Ophthalmol Scand* 1998;76(2):142-145.
- 356 Yang P, Yao M, DeMartelaere SL, et al. Light-activated sutureless closure of wounds in thin
357 skin, *Lasers Surg Med* 2012;44(2):163-167.
- 358 Tsao S, Yao M, Tsao H. Light-activated tissue bonding for excisional wound closure: a split-
359 lesion clinical trial, *Br J Dermatol* 2012;166:555-63.
- 360 Proano CE, Azar DT, Mocan MC. Photochemical keratodesmos as an adjunct to sutures for
361 bonding penetrating keratoplasty corneal incisions, *J Cataract Refract Surg* 2004;30:2420-2424.
- 362 Proano CE, Mulroy L, Jones E, et al. Photochemical keratodesmos for bonding corneal incisions,
363 *Invest Ophthalmol Vis Sci* 2004;45:2177-2181.
- 364 Zhu H, Alt C, Webb RH, et al. Corneal Crosslinking With Rose Bengal and Green Light:
365 Efficacy and Safety Evaluation, *Cornea* 2016;35(9):1234-1241.

366 Sherwood ME, Flotte TJ. Improved staining method for determining the extent of thermal
367 damage to cells, *Lasers Surg Med* 2007;39:128-131.
368 Landry J and Marceau N. Rate-Limiting Events in Hyperthermic Cell Killing, *Radiation*
369 *Research* 1978;75(3):573-585