

AD-751 352

CASE FOR DIAGNOSIS

Frank A. Voelker, et al

Armed Forces Institute of Pathology  
Washington, D. C.

1972

DISTRIBUTED BY:

**NTIS**

National Technical Information Service  
U. S. DEPARTMENT OF COMMERCE  
5285 Port Royal Road, Springfield Va. 22151

## Case for Diagnosis\*

**A** 13 YEAR old male Barbary ape (*Macaca sylvana*) from the National Zoological Park, Washington, D.C., died after a one-day illness characterized by lethargy and prostration. Although two other Barbary apes had died of an apparently similar cause within several weeks of this time, there were no clinical signs in 23 other nonhuman primates housed in the same colony.

\* Prepared by CPT Frank A. Voelker, USAF, VC and COL F. M. Garner, VC, USA, Veterinary Pathology Division, Armed Forces Institute of Pathology 29305. The assistance of the staff at the National Zoological Park is gratefully acknowledged.

Supported in part by PHS Grant RR00301-07, Division of Research Resources, USHEW, under the auspices of Universities Associated for Research and Education in Pathology, Inc.




Fig. 1. Photomicrograph of liver containing focal areas of necrosis and marked individualization of hepatocytes. H&E, x40.

At necropsy this animal was icteric, and there were widespread petechiae and ecchymoses of visceral organs. The liver was enlarged, friable, and bled freely when incised. Focal disseminated areas of necrosis and a conspicuous individualization of hepatocytes could be observed microscopically in the liver (Fig. 1). In the kidney there was extensive and diffuse nephritis (Fig. 2). Large number of lymphocytes, monocytes, and neutrophils were present both in the interstitium and within tubular lumina of this organ. In addition, vascular congestion was widespread and prominent.

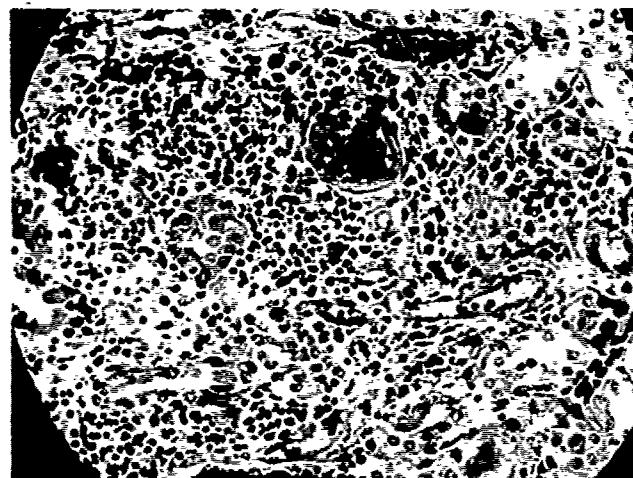



Fig. 2. Interstitially in the kidney there is extensive interstitial cellular exudation, mainly of a mononuclear nature. Hemorrhage is observed within tubular lumina. H&E, x220.

Details of illustrations in  
this document may be better  
studied on microfiche

Reproduced by  
**NATIONAL TECHNICAL  
INFORMATION SERVICE**  
U S Department of Commerce  
Springfield VA 22151



## Case for Diagnosis (Solution)

Diagnosis and discussion of case illustrated on page 358.

**SPIROCHETES** could be demonstrated with Warthin-Starry silver stain in both kidney (Fig. 3) and liver tissue. The organisms were darkly stained and appeared in a filamentous spiral form. Although leptospire were not isolated from the tissue because of freezing prior to processing, they were isolated from the liver and kidneys of the other two Barbary apes that died, by direct culture and by inoculation of hamsters. By utilizing cross-agglutination reactions it was found that the isolates cross-reacted with antisera for serotype *icterohaemorrhagiae*.

The local environment and the sequence of morbidity in the colony of apes seemed to favor an exogenous source of infection, most likely wild rodents known to be in the area. Since the colony was housed out of doors and fed and watered on the floor of the cage, contamination of food and water by urine of carrier rodents could easily have occurred. Although no clinical signs were noted in any of the cage mates nor in other nonhuman primates harbored at the National Zoological Park, it is possible that subclinical infections may have existed. From serologic tests it was obvious that infections did occur in at least two other Barbary apes.

It is known that nonhuman primates are relatively resistant to overt clinical leptospirosis, and consequently there are few reports of the naturally occurring disease. As evidenced by antibody formation, however, several Old World (Eastern Hemisphere) primates are known to be susceptible to experimental and natural infection.<sup>1</sup> Serologically it is reported that *Leptospira icterohaemorrhagiae* is the most com-

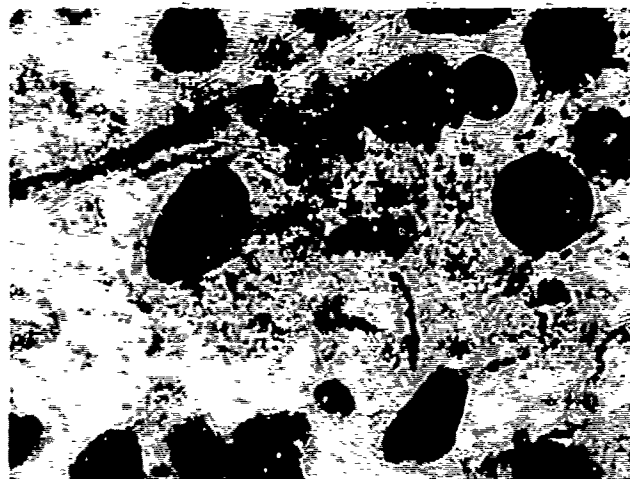


Fig. 3. Photomicrograph of a renal tubular cell containing leptospiral organisms. Warthin-Starry, x2,160.

mon serotype involved. Among New World primates that have been tested, there is little evidence of infection.

### References

- <sup>1</sup> Minette, H. P.: Leptospirosis in primates other than man. *Amer. J. Trop. Med.*, 15:190-198, 1966.
- <sup>2</sup> Shive, R. J., Green, S. S., Evans, L. B. and Garner, F. M.: Leptospirosis in Barbary apes (*Macaca*). *J. Amer. Vet. Med. Ass.*, 155:1175-1178, 1959.

2

