

AD 712988

AD

**EDGEWOOD ARSENAL
TECHNICAL REPORT**

EATR 4431

**ATLAS OF GOAT ANATOMY.
PART I: OSTEOLOGY**

by

Clarence E. Hopkins, Sr.

Thomas E. Hamm, Jr., CPT, VC


Gary L. Leppart

September 1970



Reproduced by the
CLEARINGHOUSE
for Federal Scientific & Technical
Information Springfield Va. 22151

**DEPARTMENT OF THE ARMY
EDGEWOOD ARSENAL
Research Laboratories
Biophysics Laboratory
Edgewood Arsenal, Maryland 21010**



60

ACCESSION for	
CPSTI	WHITE SECTION <input checked="" type="checkbox"/>
DDC	BUFF SECTION <input type="checkbox"/>
UNANNOUNCED	<input type="checkbox"/>
JUSTIFICATION	
.....	
BY	
DISTRIBUTION/AVAILABILITY CODES	
DIST.	AVAIL. and/or SPECIAL
1	

Distribution Statement

This document has been approved for public release and sale; its distribution is unlimited.

Disclaimer

The findings in this report are not to be construed as an official Department of the Army position unless so designated by other authorized documents.

Disposition

Destroy this report when no longer needed. Do not return it to the originator.

EDGEWOOD ARSENAL TECHNICAL REPORT

EATR 4431

ATLAS OF GOAT ANATOMY. PART I: OSTFOLOGY

by

Clarence E. Hopkins, Sr.
Thomas E. Hamm, Jr., CPT, VC
Gary L. Leppart

Biomedical Department

September 1970

This document has been approved for public release and sale; its distribution is unlimited.

Project 1T062110A027

DEPARTMENT OF THE ARMY
EDGEWOOD ARSENAL
Research Laboratories
Biophysics Laboratory
Edgewood Arsenal, Maryland 21010

FOREWORD

The work described in this report was authorized under Project 1T062110A027, Wound Ballistics (U). This work was started in September 1968 and completed in March 1970.

In conducting the research described in this report, the investigators adhered to the "Guide for Laboratory Animal Facilities and Care," as promulgated by the Committee on the Guide for Laboratory Animal Resources, National Academy of Sciences-National Research Council.

Acknowledgments

The authors wish to acknowledge the technical assistance of William J. Kelly, John J. Holter, Bernard Meyers, Joseph B. Scott, and Garnet E. Affleck, Jr., in performing the photographic procedures.

DIGEST

The purpose of this investigation was to establish a reference source for the anatomy of the angora goat (*Capra hircus*). This report, the first in a series, presents the skeletal anatomy of this animal.

CONTENTS

	Page
I. INTRODUCTION	7
II. MATERIALS AND METHODS	7
III. SKELETAL ANATOMY	8
SELECTED REFERENCES	55
APPENDIX	57
DISTRIBUTION LIST	61

LIST OF FIGURES

Figure		
1	Articulated Skeleton, Lateral Aspect	8
2	Skull, Dorsal Aspect	9
3	Skull, Dorsolateral Aspect	10
4	Skull, Left Lateral Aspect	11
5	Skull, Caudal Aspect	12
6	Skull, Ventral Aspect	13
7	Mandible, Dorsal Aspect	14
8	Right Mandible, Lateral Aspect	15
9	Right Mandible, Medial Aspect	16
10	Bones of the Middle Ear (11 X)	17
11	Hyoid Bones	18
12	Third Cervical, Axis, and Atlas Vertebrae, Dorsal Aspect	19
13	Third Cervical, Axis, and Atlas Vertebrae, Ventral Aspect	20
14	Axis Vertebra, Right Lateral Aspect	21
15	Axis Vertebra, Caudal Aspect	22
16	Third Cervical Vertebra, Right Lateral Aspect	23
17	Ribs and Sternum, Right Lateral Aspect	24
18	Second and Eighth Thoracic Vertebrae, Caudal and Left Lateral Aspects	25
19	First Right Rib, Medial and Lateral Aspects	26
20	Sixth Right Rib, Medial and Lateral Aspects	27
21	Sternum, Dorsal Aspect	28
22	Sternum, Ventral Aspect	29
23	Right Scapula, Medial Aspect	30
24	Right Scapula, Lateral Aspect	31
25	Right Radius and Ulna, Cranial and Lateral Aspects	32
26	Right Radius and Ulna, Medial and Caudal Aspects	33
27	Right Humerus, Lateral and Cranial Aspects	34

LIST OF FIGURES—Continued

Figure		Page
28	Right Humerus, Medial and Caudal Aspects	35
29	Left Pectoral Foot, Cranial Aspect	36
30	Left Pectoral Foot, Caudal Aspect	37
31	Left Pectoral Foot, Lateral Aspect	38
32	Left Pectoral Foot, Medial Aspect	39
33	Lumbar Vertebrae, Dorsal Aspect	40
34	Lumbar Vertebrae, Ventral Aspect	41
35	Sixth Lumbar Vertebra, Ventral and Cranial Aspects	42
36	Pelvis With Sacral and Caudal Vertebrae Attached, Dorsal Aspect	43
37	Pelvis With Sacral and Caudal Vertebrae Attached, Left Lateral Aspect	44
38	Pelvis With Sacral and Caudal Vertebrae Attached, Ventral Aspect	45
39	Left Femur, Cranial and Lateral Aspects	46
40	Left Femur, Caudal and Medial Aspects	47
41	Left Tibia, Cranial and Caudal Aspects	48
42	Left Tibia, Lateral and Medial Aspects	49
43	Left Pelvic Foot, Cranial Aspect	50
44	Left Pelvic Foot, Caudal Aspect	51
45	Left Pelvic Foot, Lateral Aspect	52
46	Left Pelvic Foot, Medial Aspect	53

ATLAS OF GOAT ANATOMY. PART I: OSTEOLOGY

I. INTRODUCTION.

The angora goat (*Capra hircus*) has been the main experimental animal used by the Biophysics Laboratory, Edgewood Arsenal, Maryland, for many years. Knowledge of goat anatomy is important during both the planning and experimental stages of projects. Because no readily usable information on goat anatomy is available, this report has been written to provide a reference source for this information. This report, the first in a series, presents the skeletal anatomy of the angora goat. Part II: Serial Cross Sections, which is near completion, presents serial 1-inch cross sections of the entire goat.

II. MATERIALS AND METHODS.

The goats used in the Biophysics Laboratory are all castrated males, are generally over 3 years old, and weigh from 30 to 50 kg. The divisions and average number of the bones of the goat are shown in the table. The intact skeleton (figure 1) was prepared in the fall of 1954 from one goat that weighed approximately 50 kg. The individual bones (figures 2 through 46) were selected from over 2000 autopsies and are typical of the average angora goat.

Beginning in 1968, these bones (already prepared by the methods described in the appendix) were photographed, drawn, and labeled. The first *Nomina Anatomica Veterinaria* (NAV)* was published in October 1968, too late to be used for planning this report. The authors have reviewed all figures, however, and attempted to bring them into agreement with the NAV. Future sections of this atlas will be in the correct Latin nomenclature in agreement with the NAV.

Table. Skeletal Divisions and Average Number of Bones

Division	Number
Axial skeleton:	
Vertebral column ^a	42
Skull ^b and hyoids	35
Ribs and sternum	27
Appendicular skeleton:	
Pectoral limbs	26
Pelvic limbs	37
Total	167

^aThe vertebral formula is $C_7 T_{13} L_6 S_4 Cy_{10}$ to Cy_{12} . Variation is common except in the cervical region (T_{12} to T_{14} , L_5 to L_6).

^bThe permanent dental formula is $2(1 \frac{0}{4} C \frac{0}{0} P \frac{3}{3} M \frac{3}{3}) = 32$.

**Nomina Anatomica Veterinaria*. Department of Anatomy, New York State Veterinary College, Ithaca, New York, 1968.

III. SKELETAL ANATOMY.

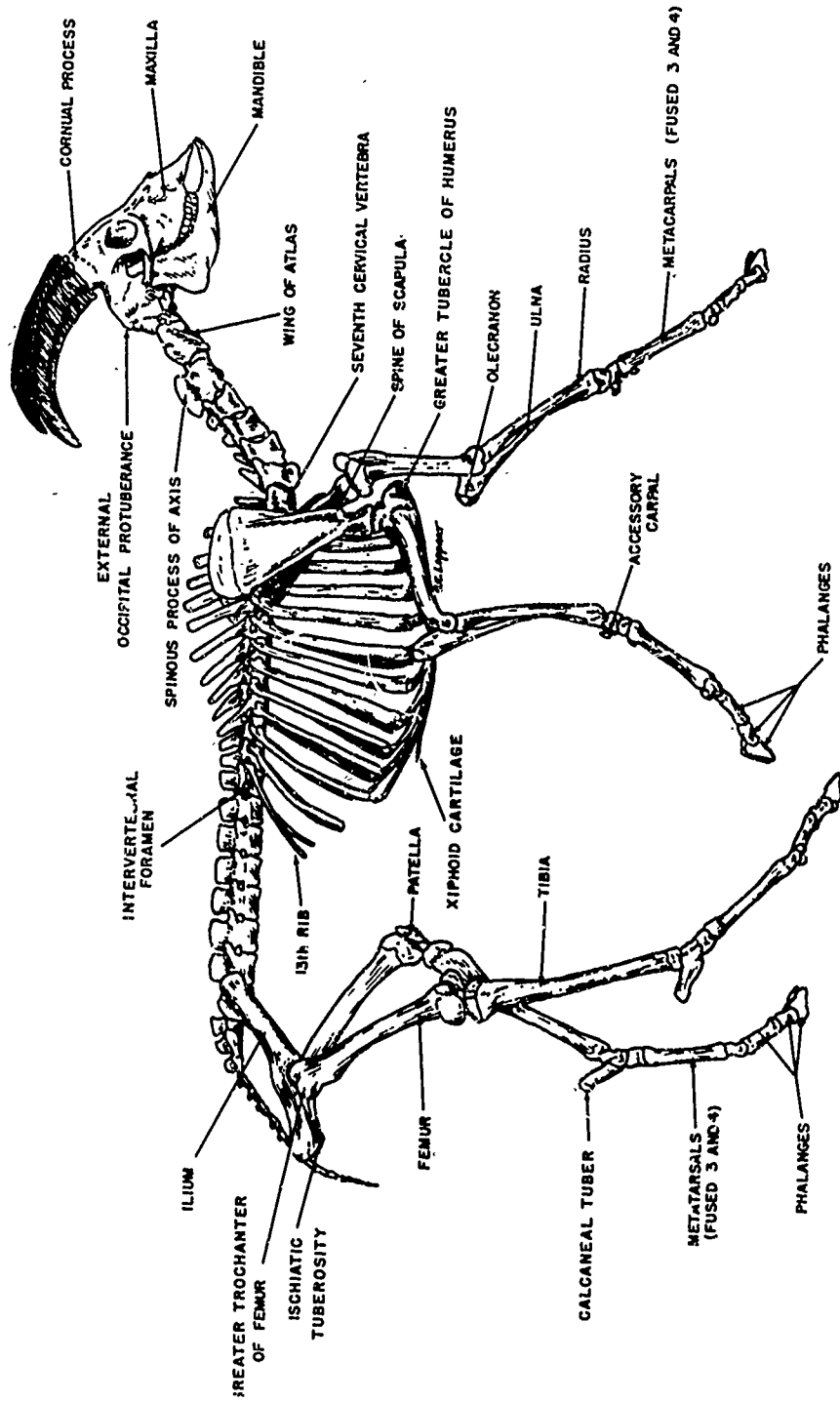


Figure 1: Articulated Skeleton, Lateral Aspect

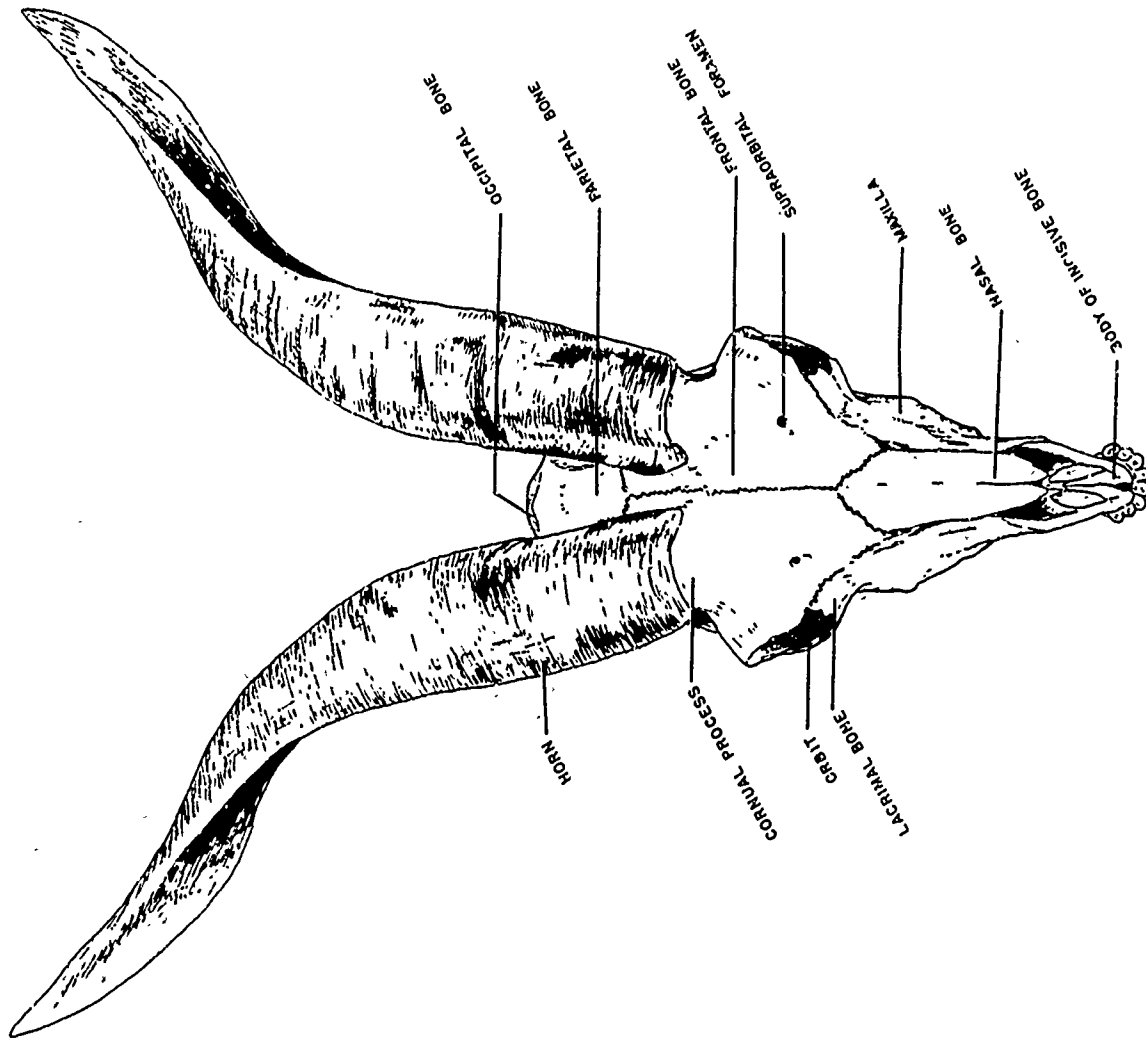


Figure 2. Skull, Dorsal Aspect

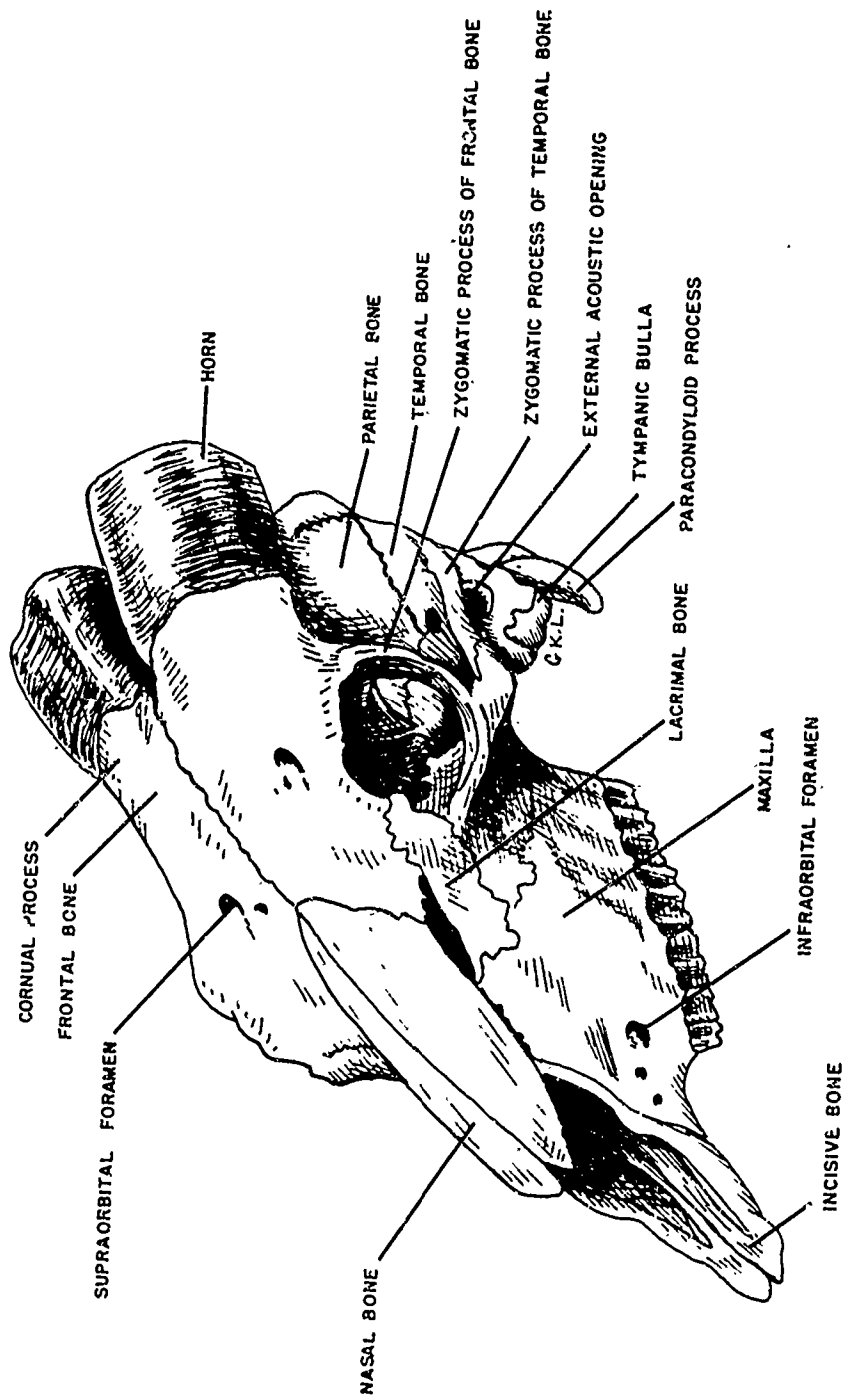


Figure 3. Skull, Dorsolateral Aspect

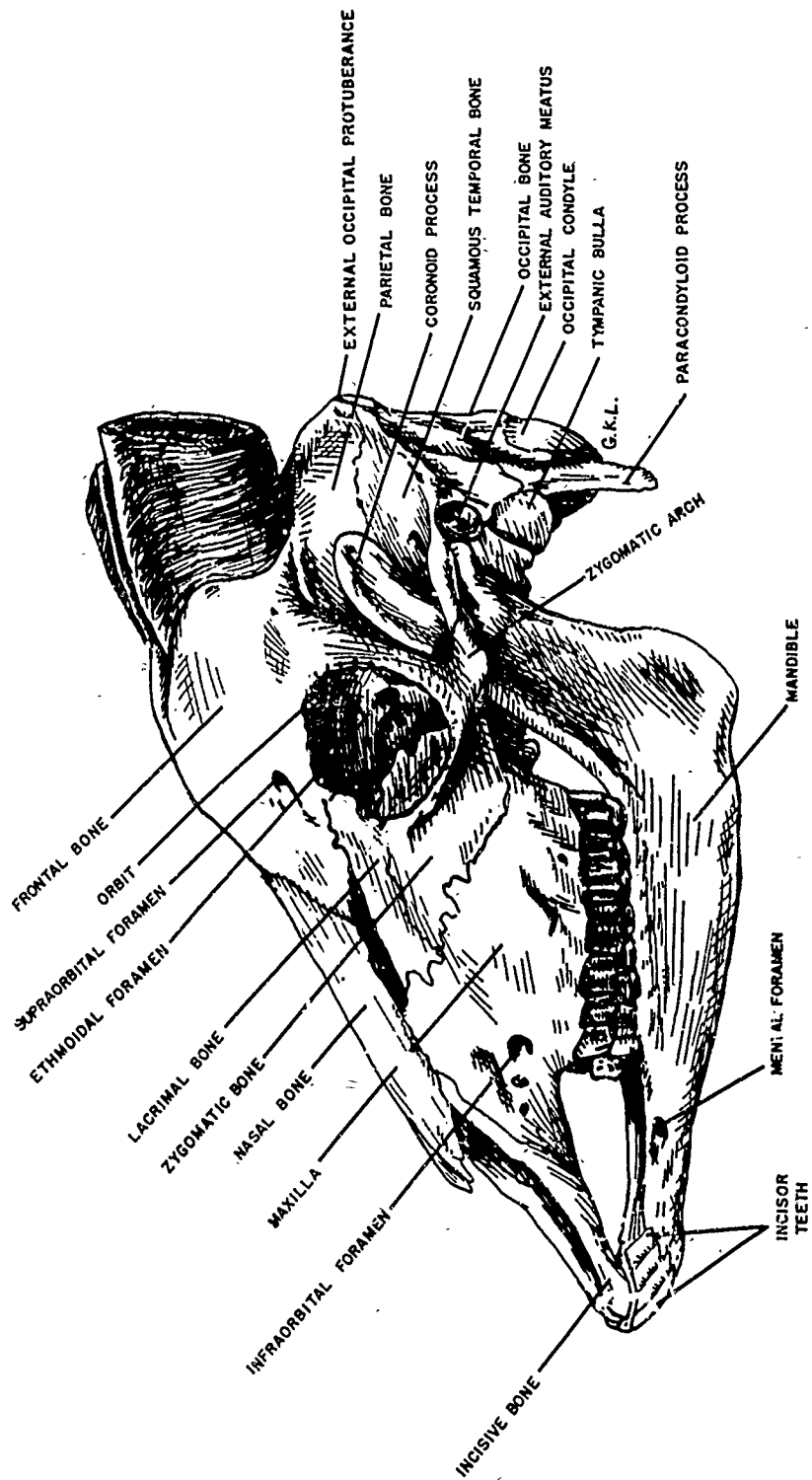


Figure 4. Skull, Left Lateral Aspect

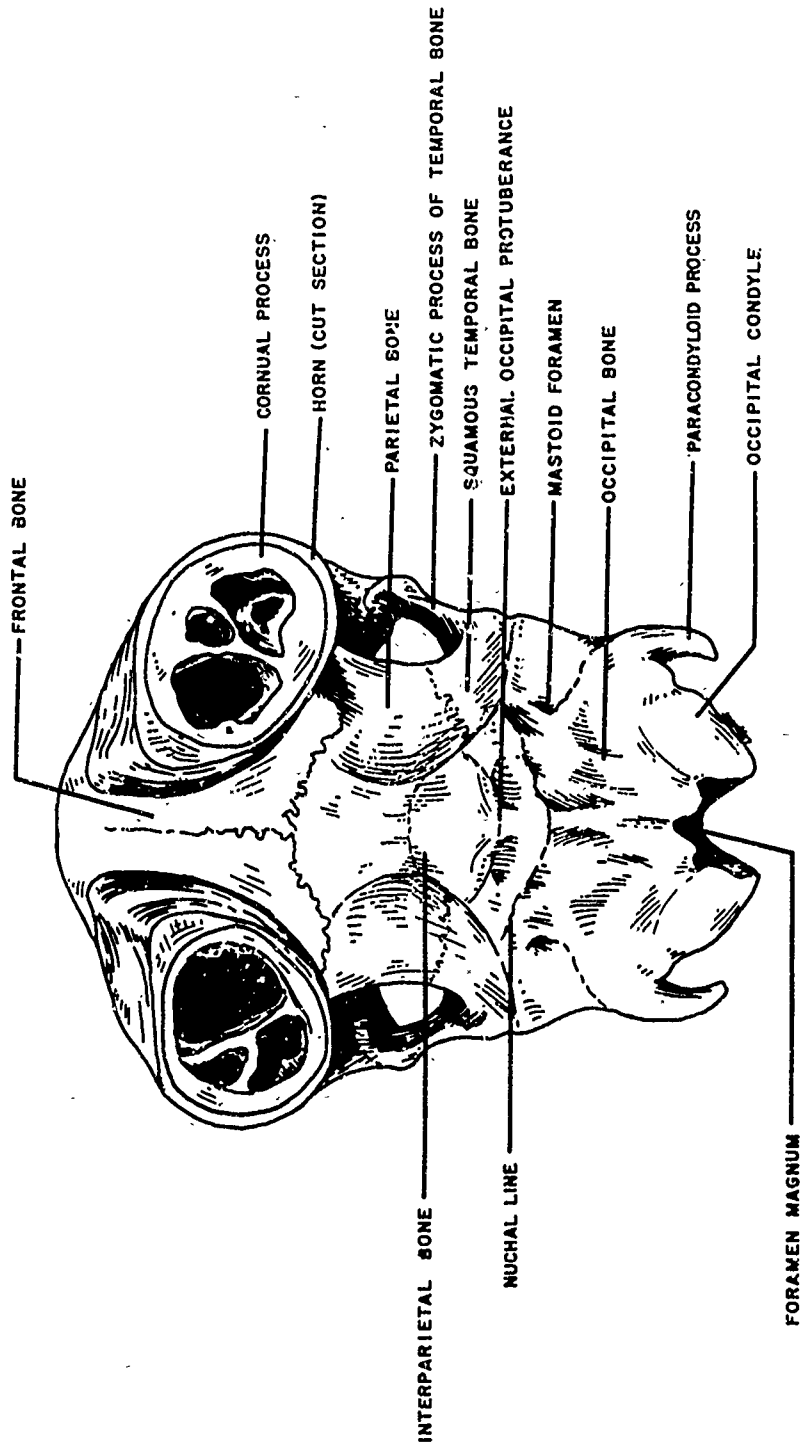


Figure 5. Skuii, Caudal Aspect

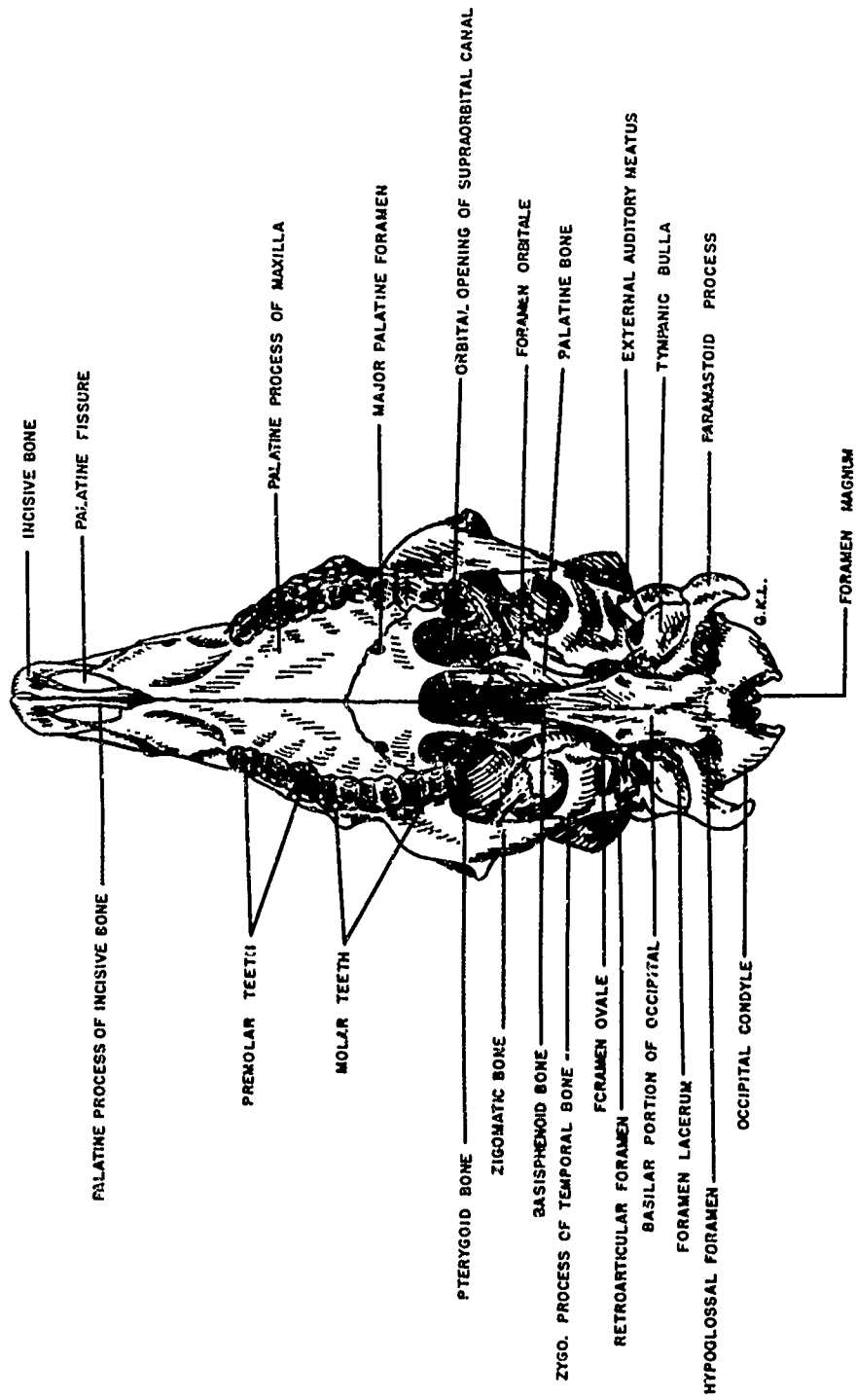


Figure 6. Skull, Ventral Aspect

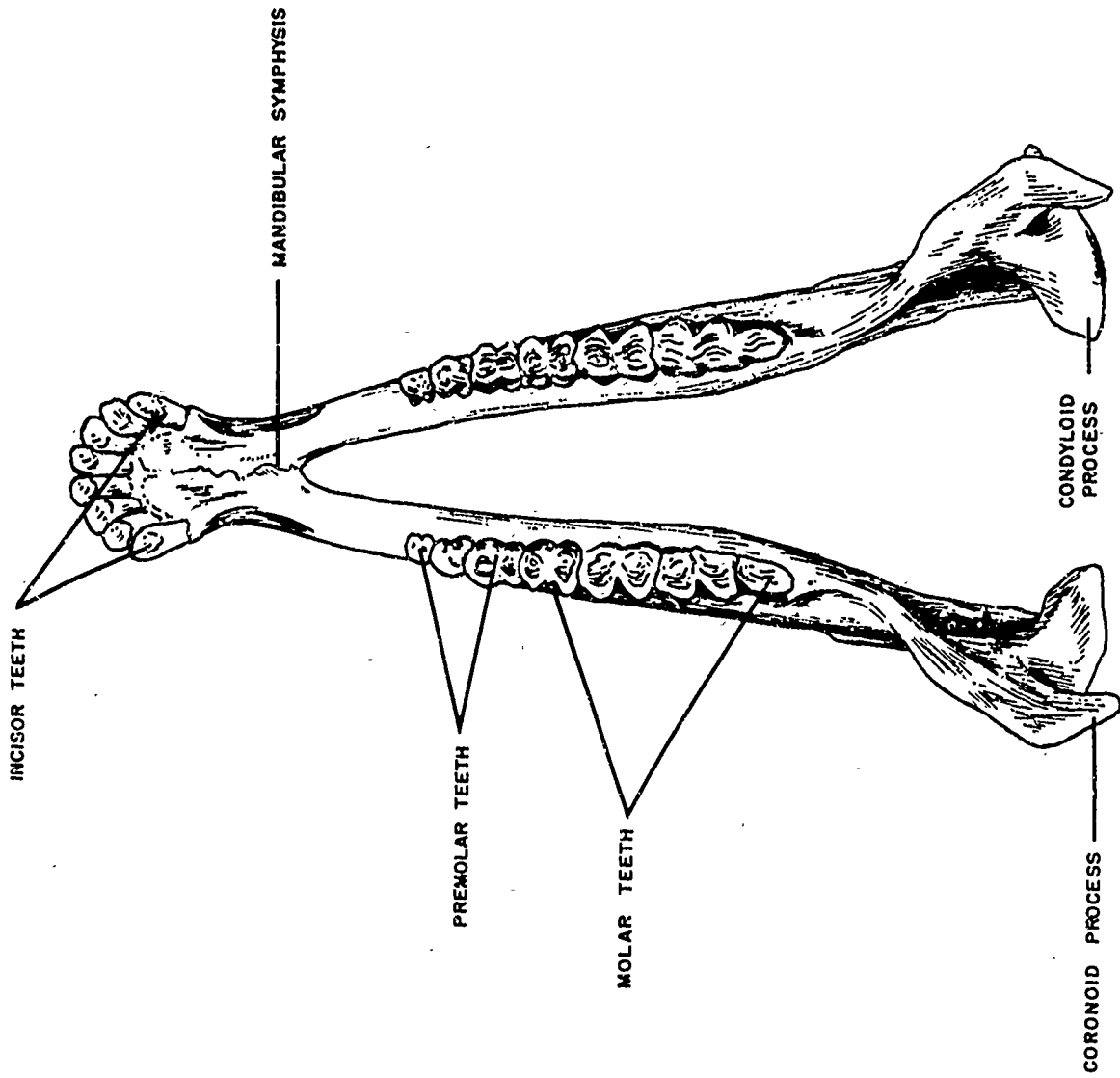


Figure 7. Mandible, Dorsal Aspect

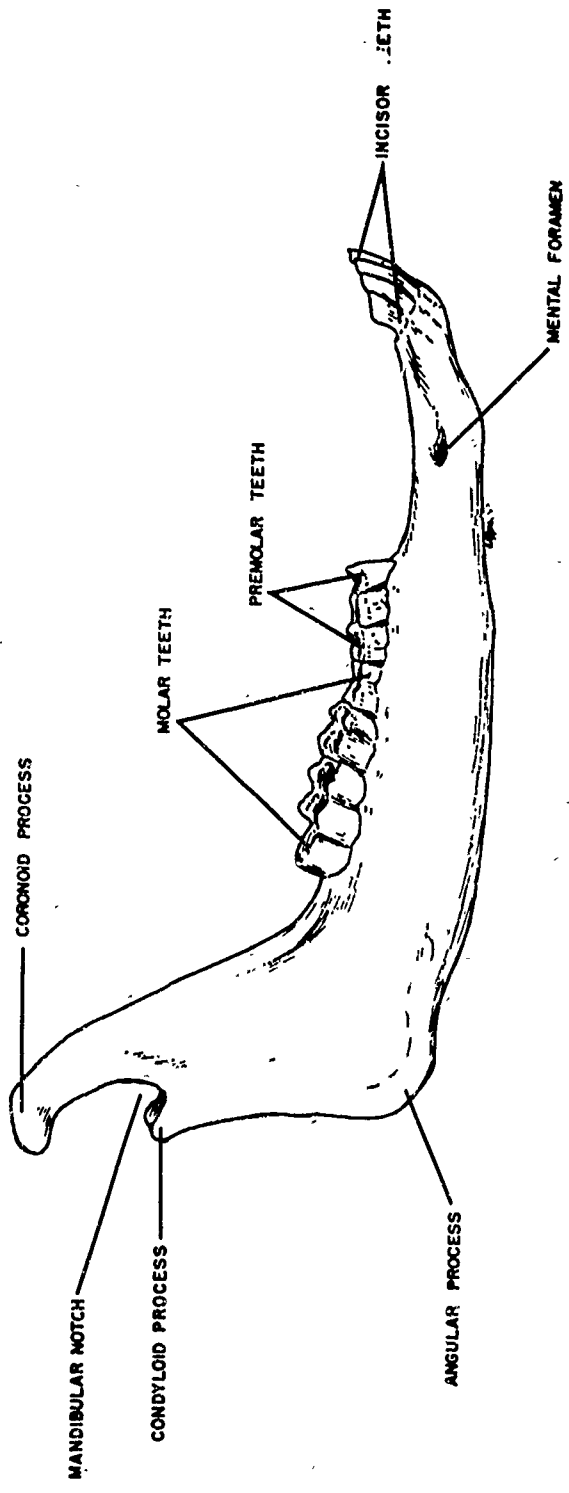


Figure 8. Right Mandible, Lateral Aspect

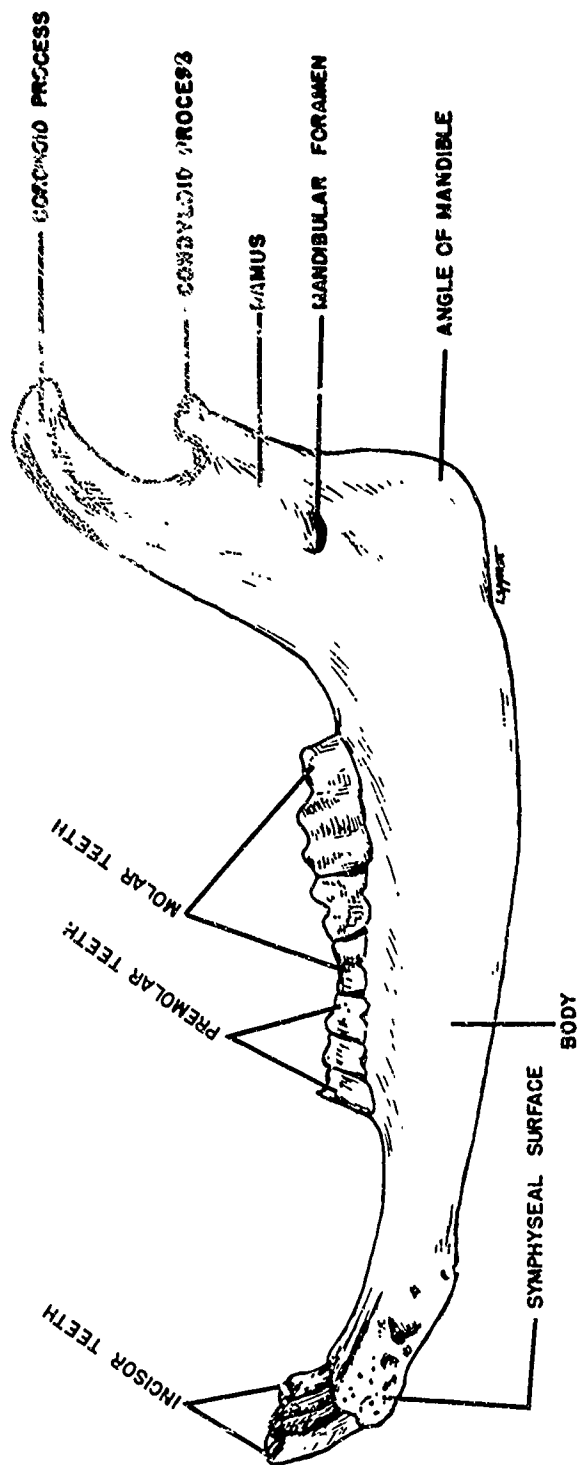


Figure 9. Right Mandible, Medial Aspect

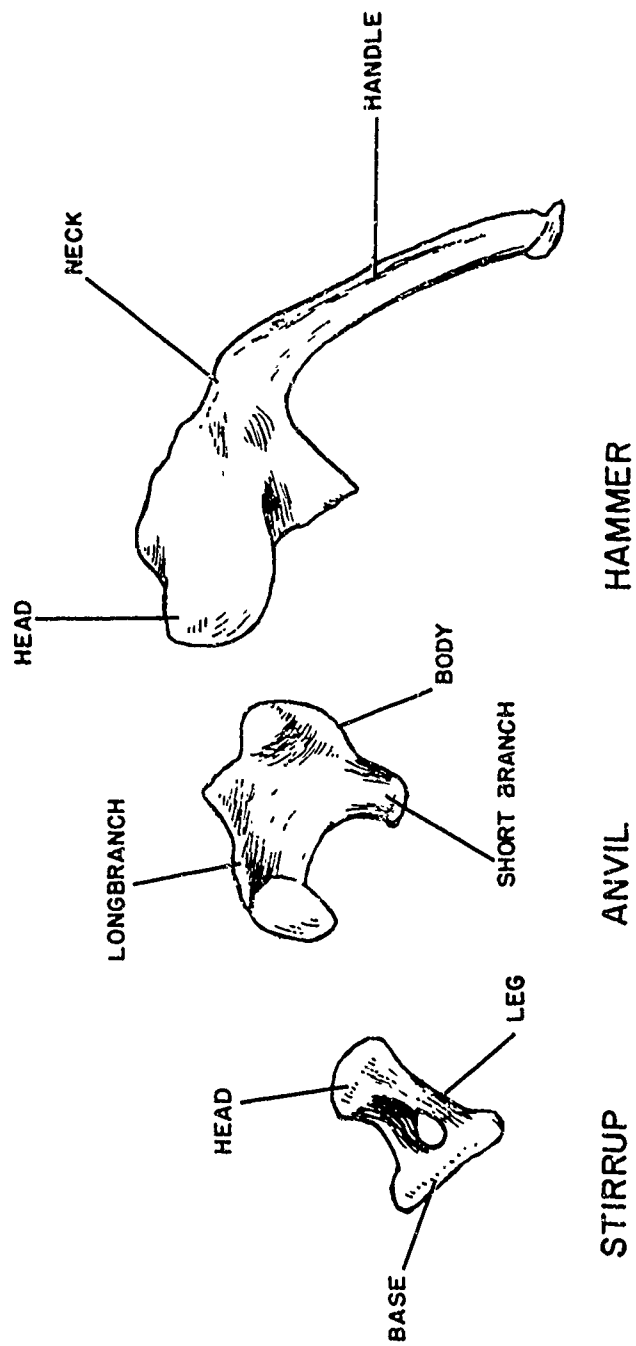


Figure 10. Bones of the Middle Ear (11 X)

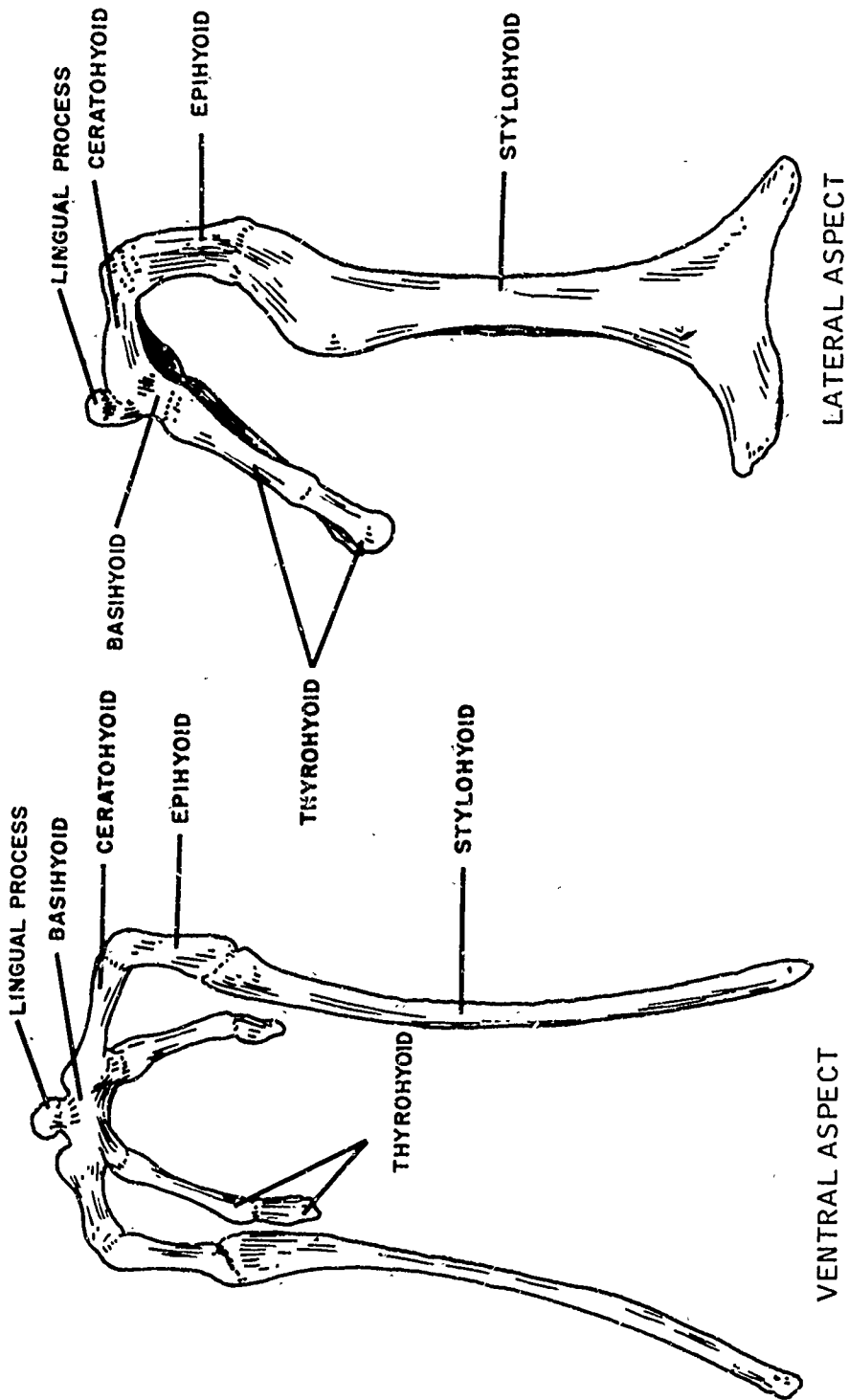


Figure 11. Hyoid Bones

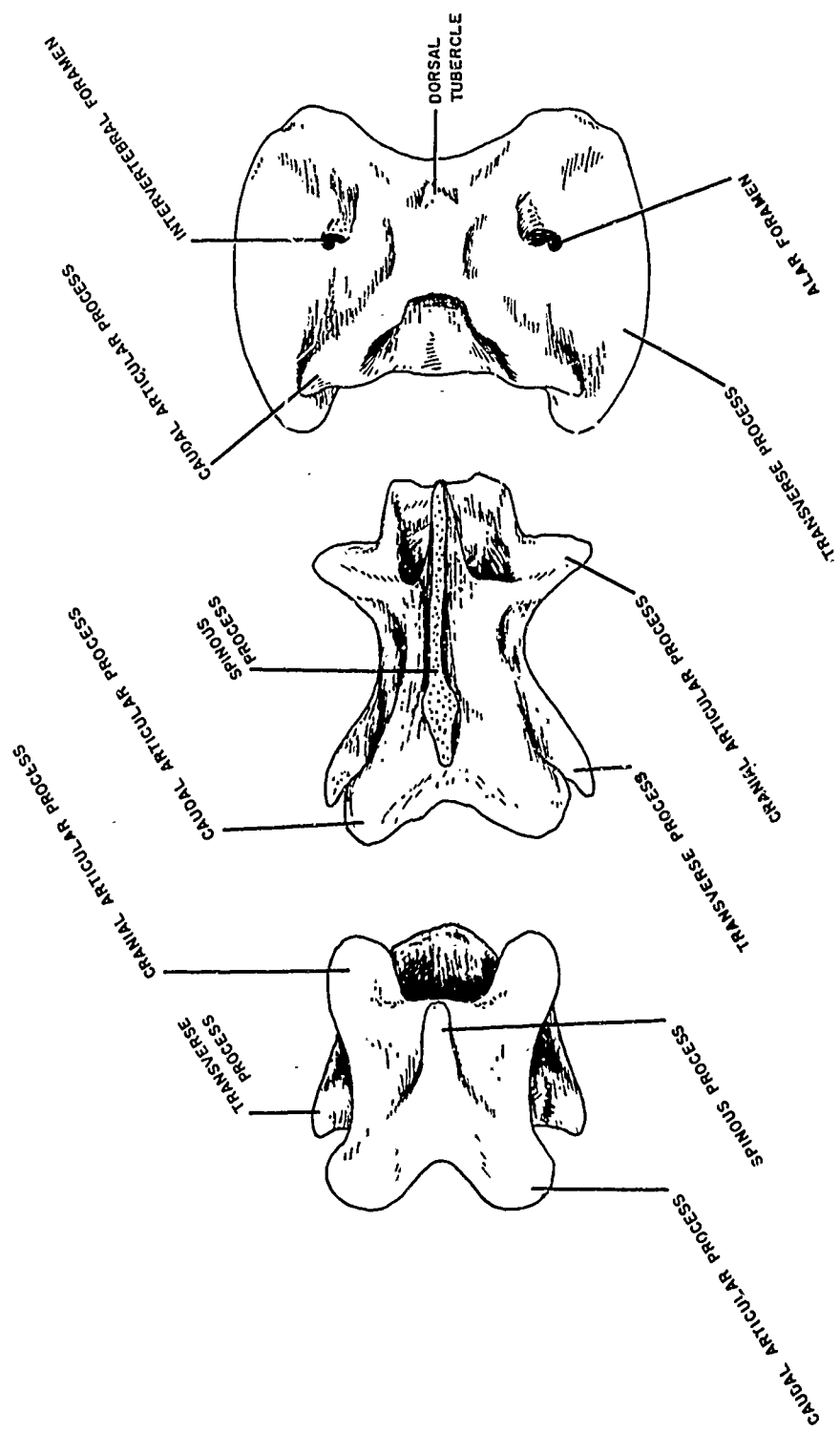


Figure 12. Third Cervical, Axis, and Atlas Vertebrae, Dorsal Aspect

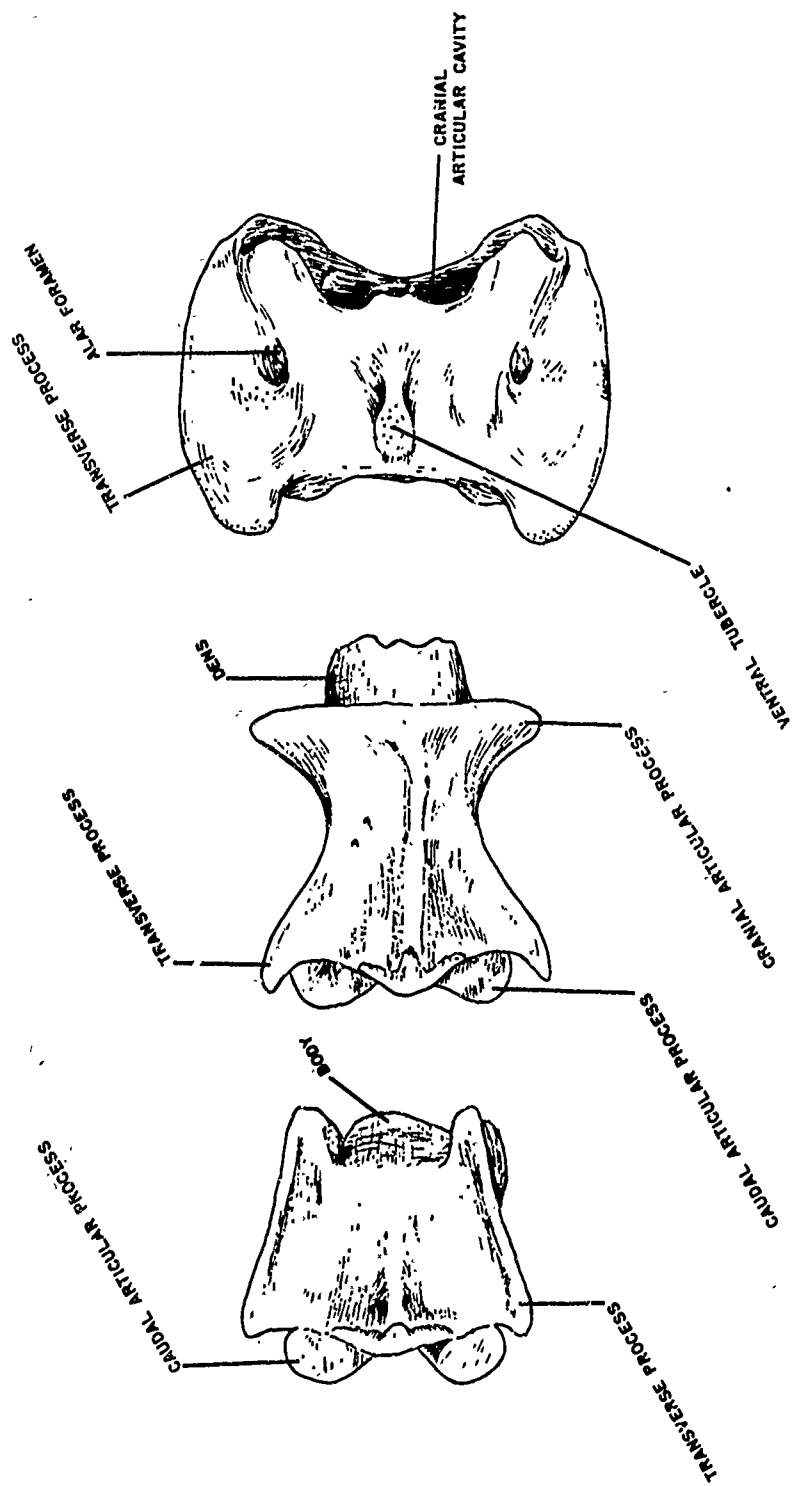


Figure 13. Third Cervical, Axis, and Atlas Vertebrae, Ventral Aspect

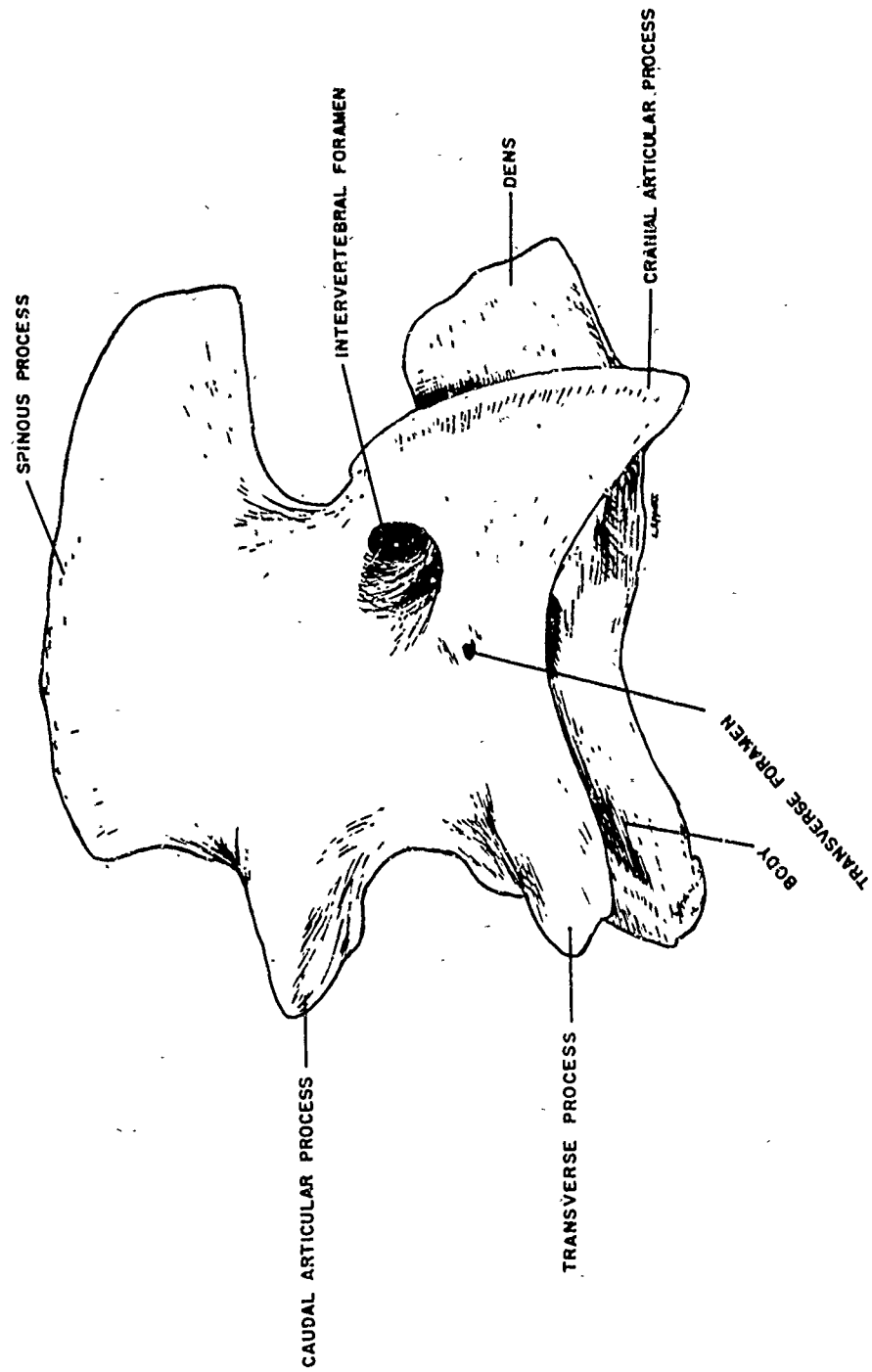


Figure 14. Axis Vertebra, Right Lateral Aspect

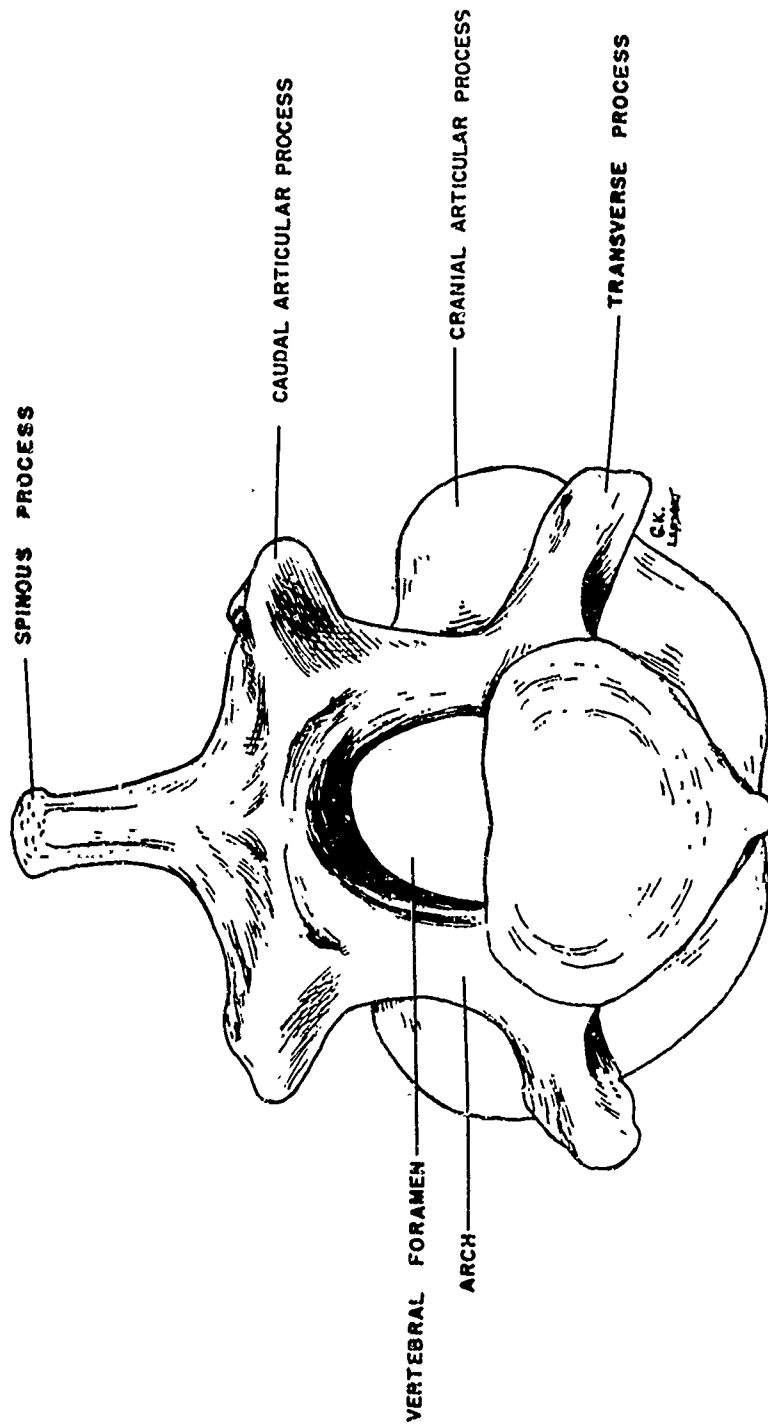


Figure 15. Axis Vertebra, Caudal Aspect

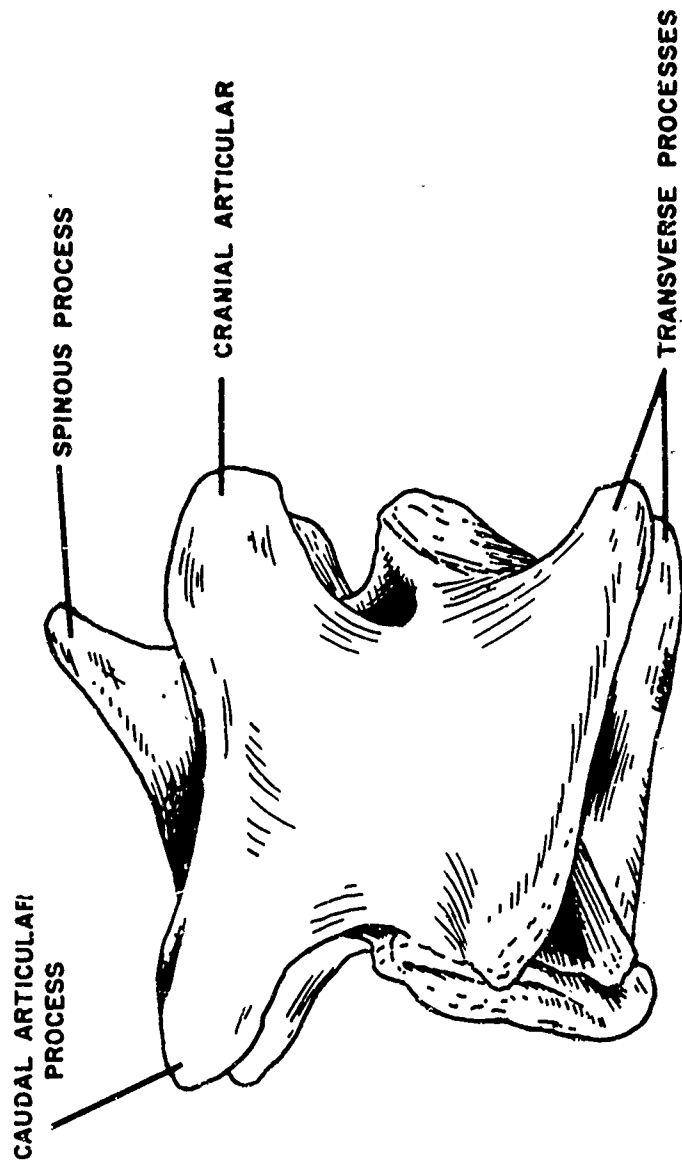


Figure 16. Third Cervical Vertebra, Right Lateral Aspect

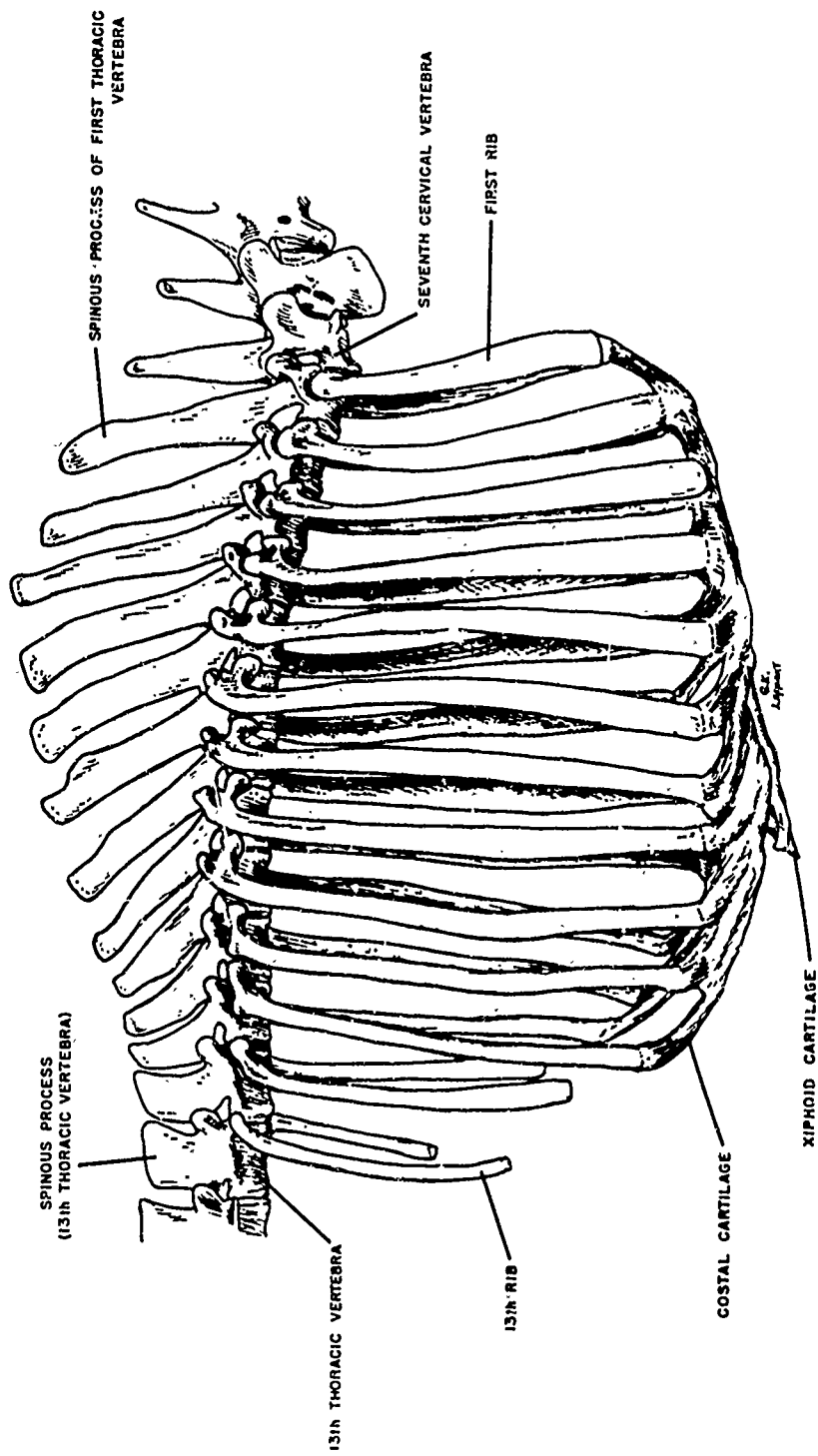
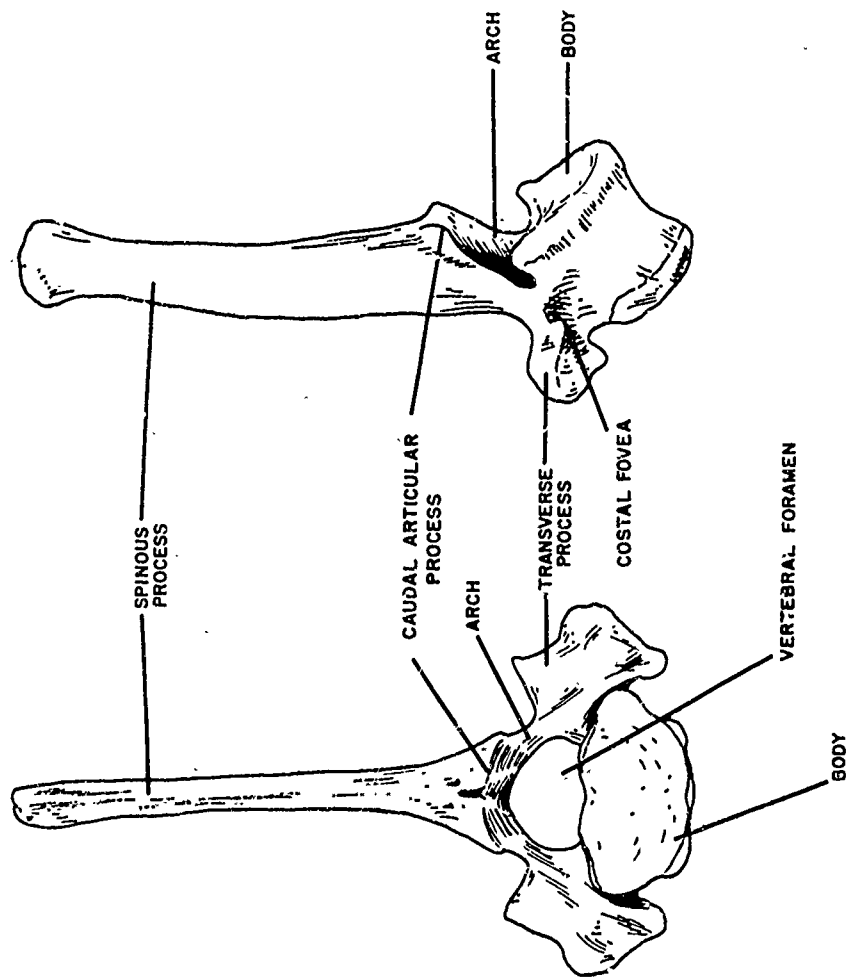


Figure 17. Ribs and Sternum, Right Lateral Aspect



CAUDAL ASPECT

LEFT LATERAL ASPECT

Figure 18. Second and Eighth Thoracic Vertebrae, Caudal and Left Lateral Aspects

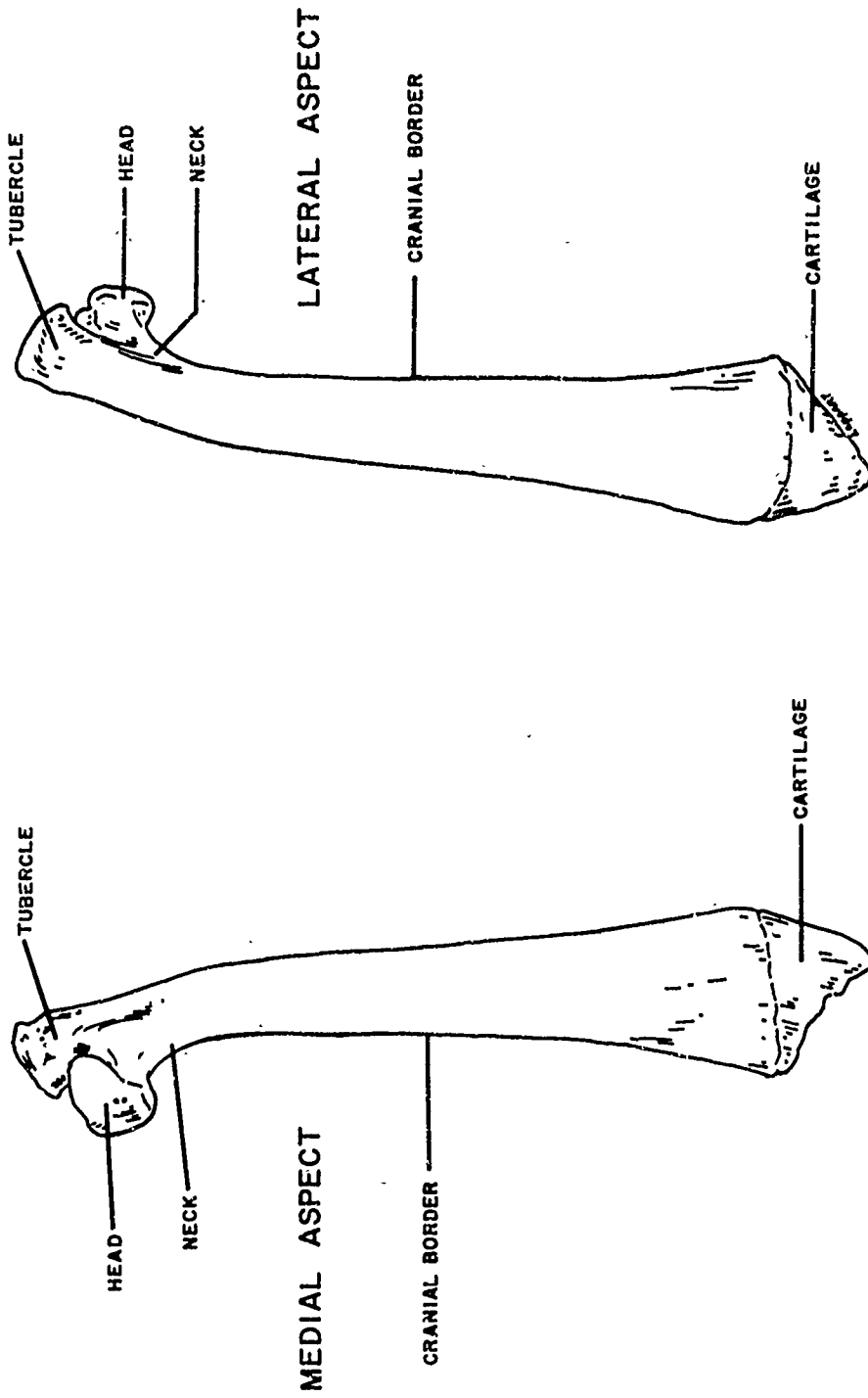


Figure 19. First Right Rib, Medial and Lateral Aspects

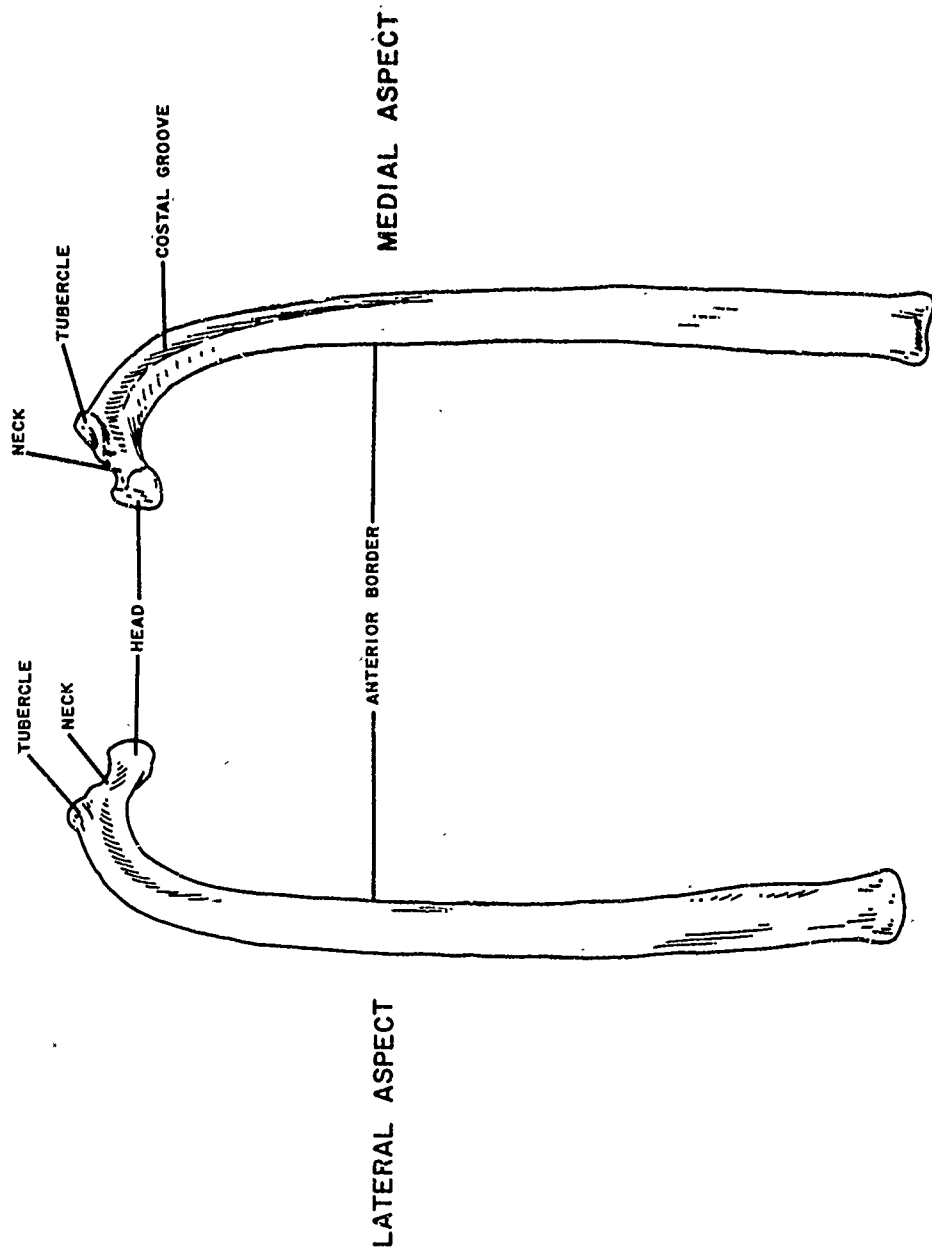


Figure 20. Sixth Right Rib, Medial and Lateral Aspects

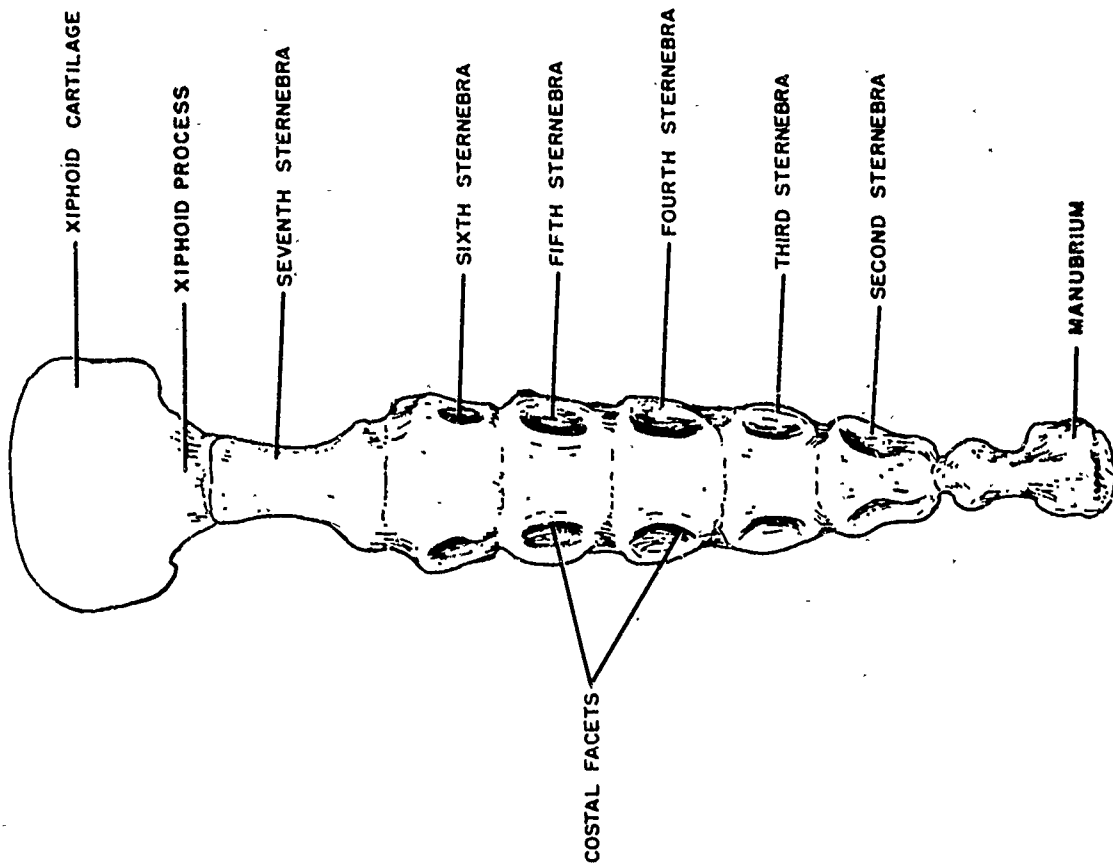


Figure 21. Sternum, Dorsal Aspect

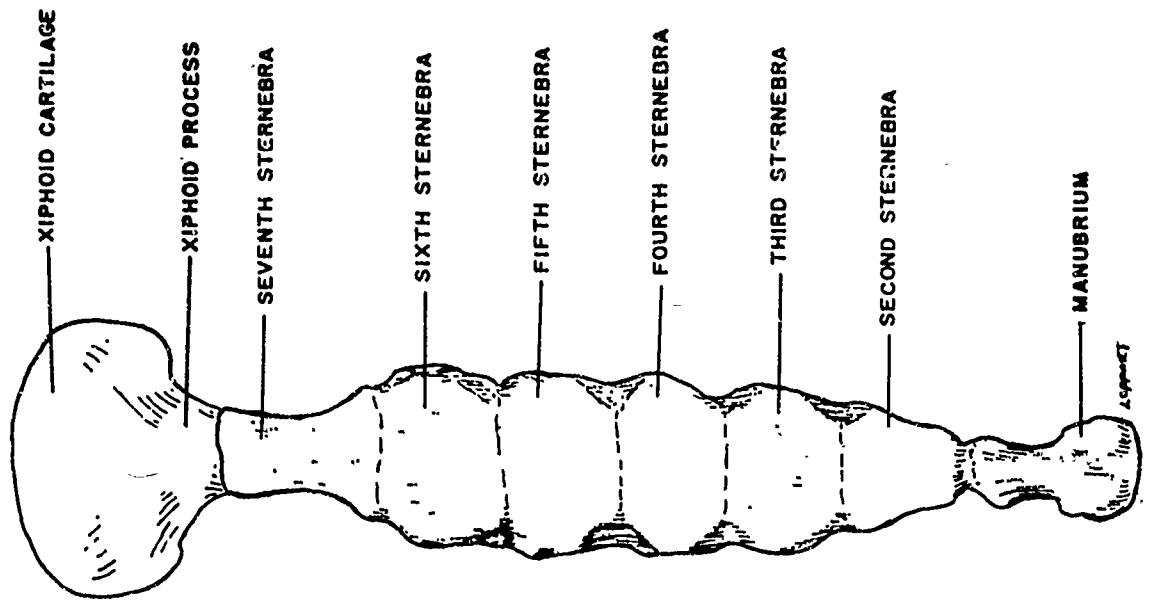


Figure 22. Sternum, Ventral Aspect

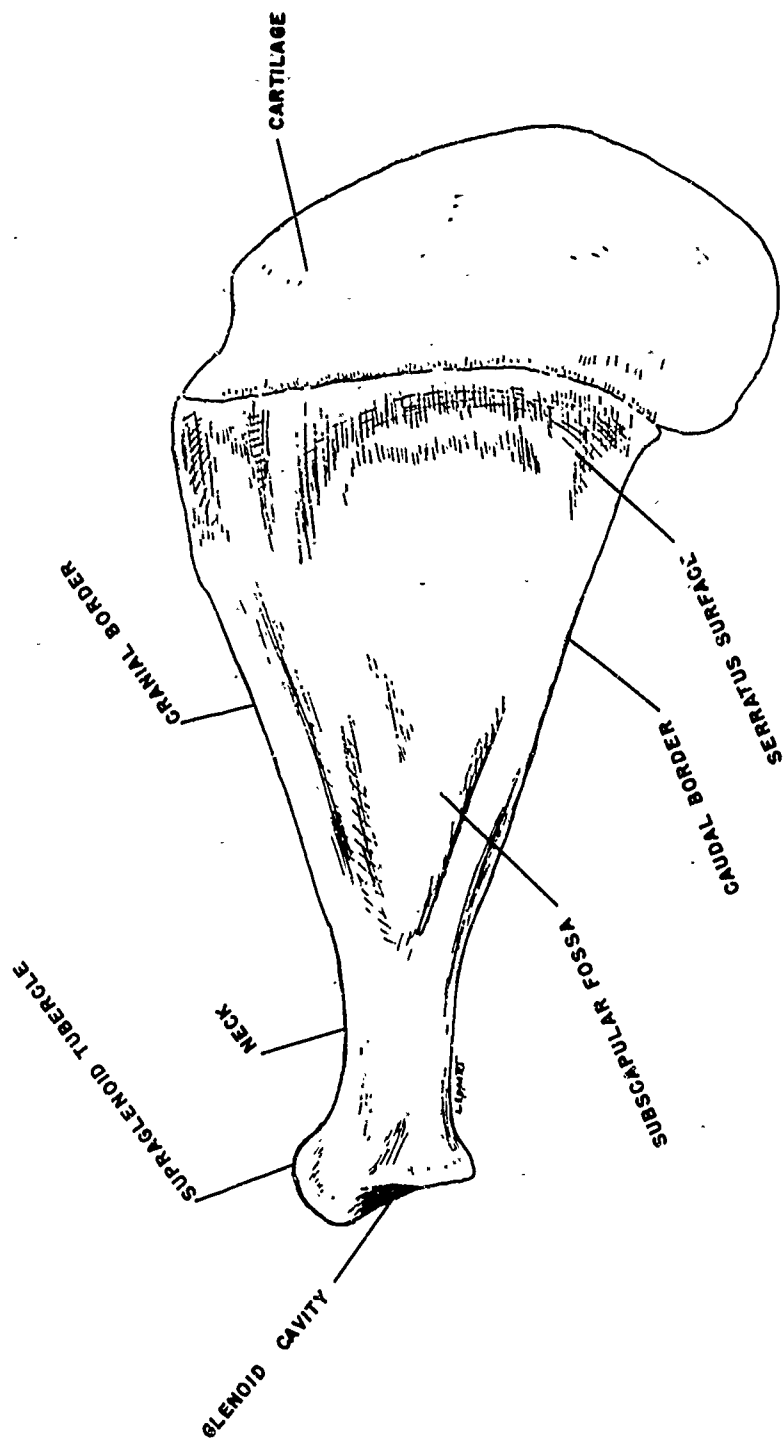


Figure 23. Right Scapula, Medial Aspect

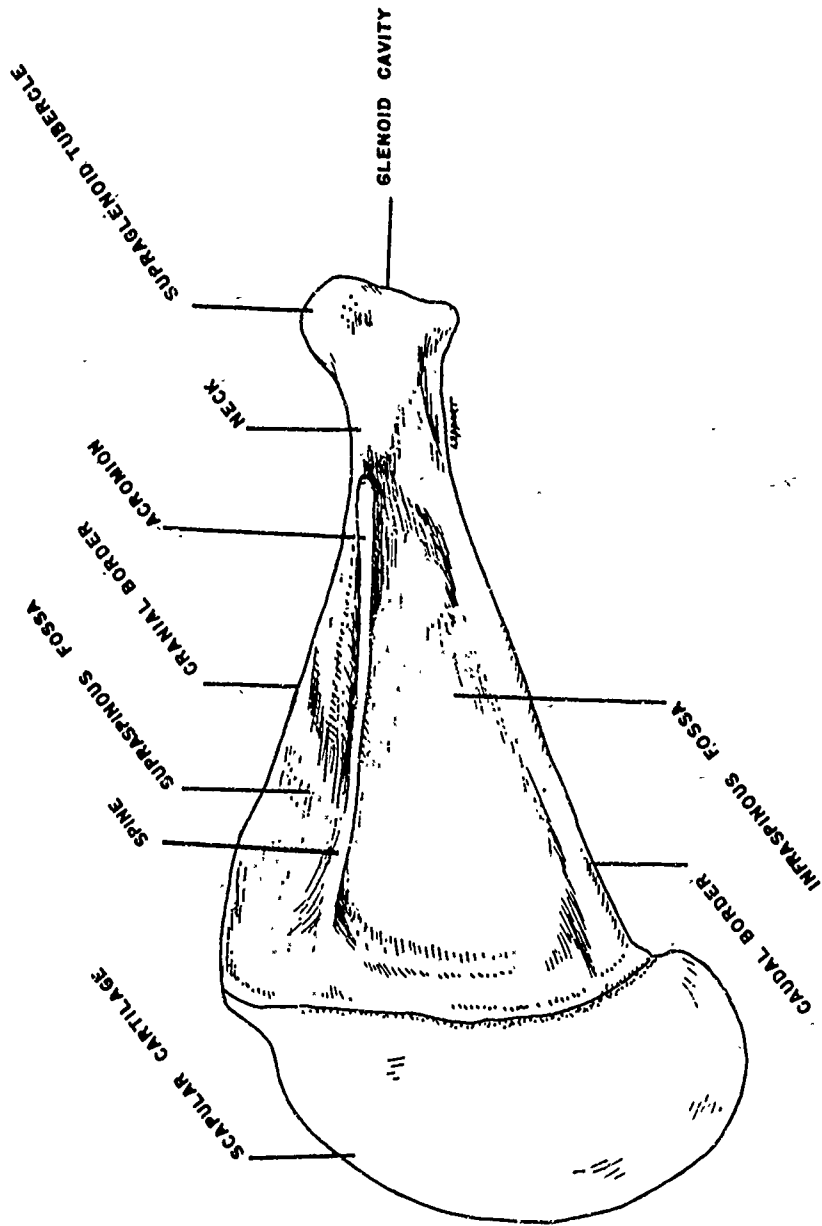


Figure 24. Right Scapula, Lateral Aspect

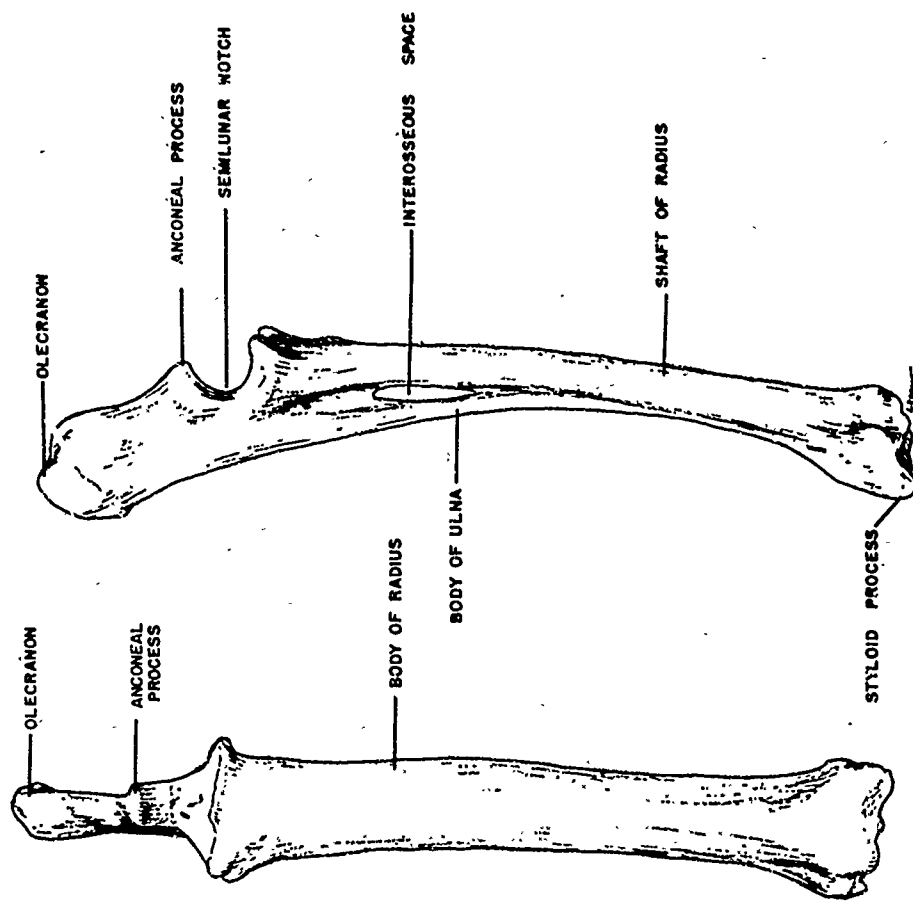


Figure 25. Right Radius and Ulna, Cranial and Lateral Aspects

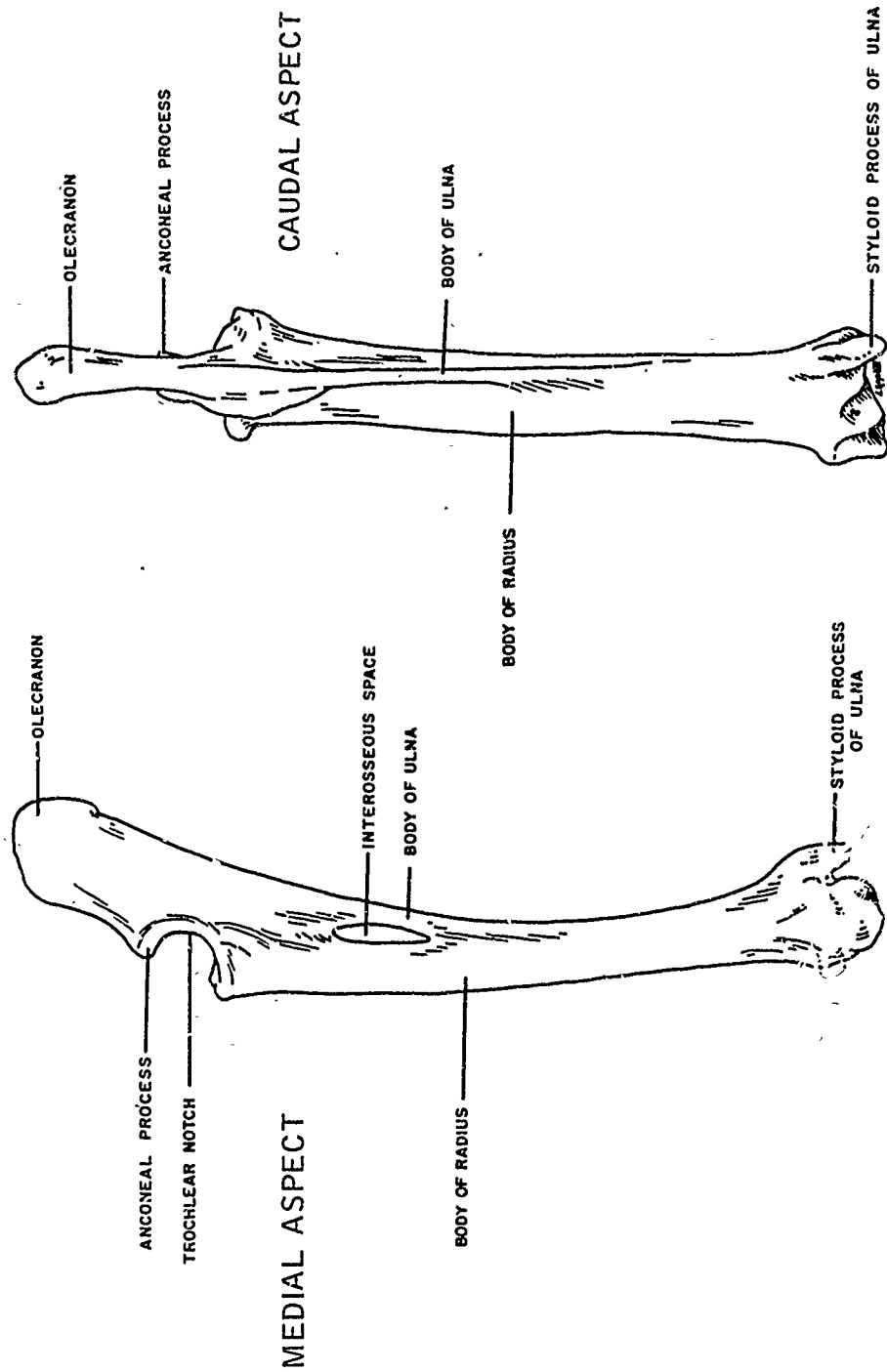


Figure 26. Right Radius and Ulna, Medial and Caudal Aspects

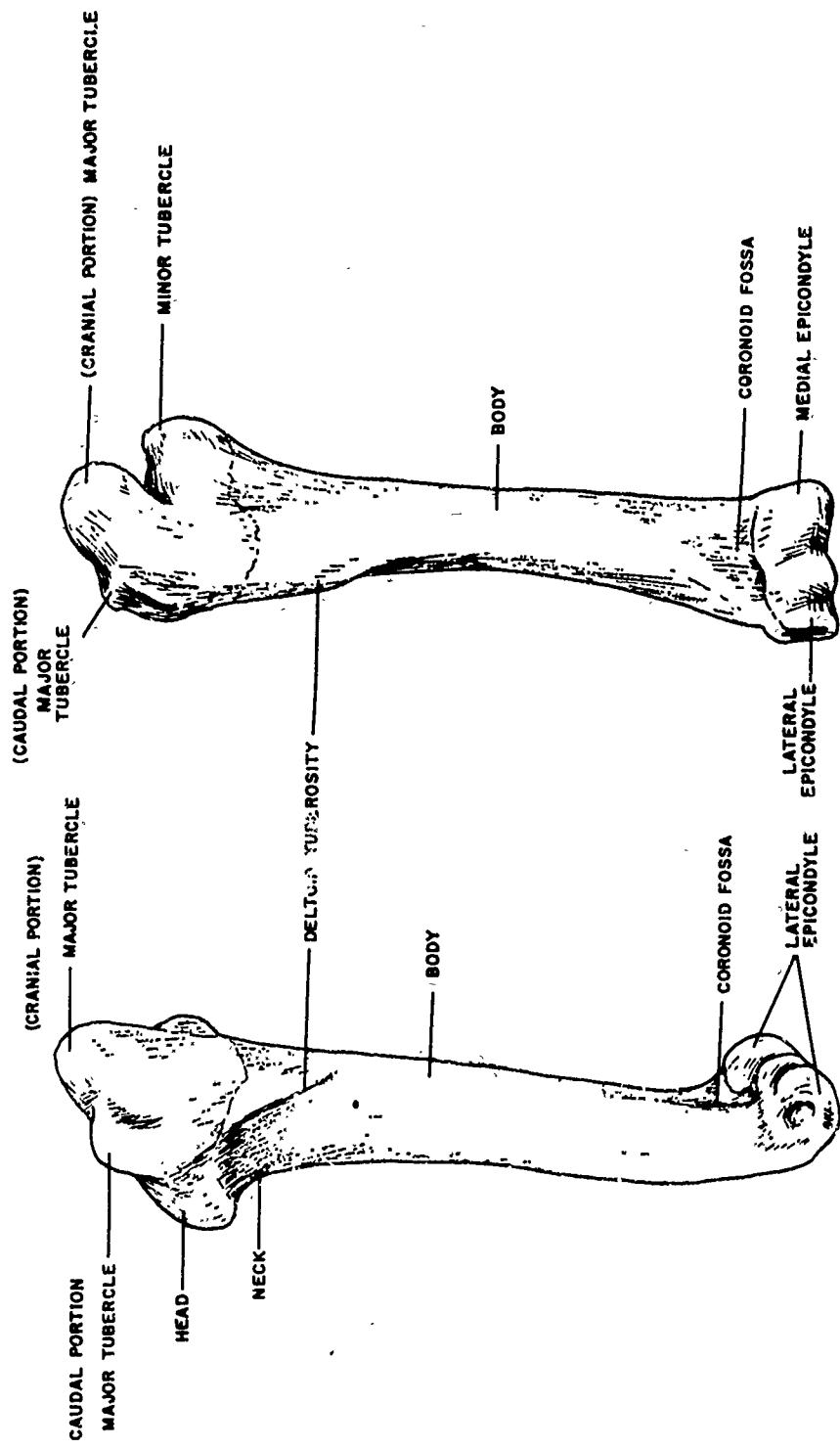


Figure 27. Right Humerus, Lateral and Cranial Aspects

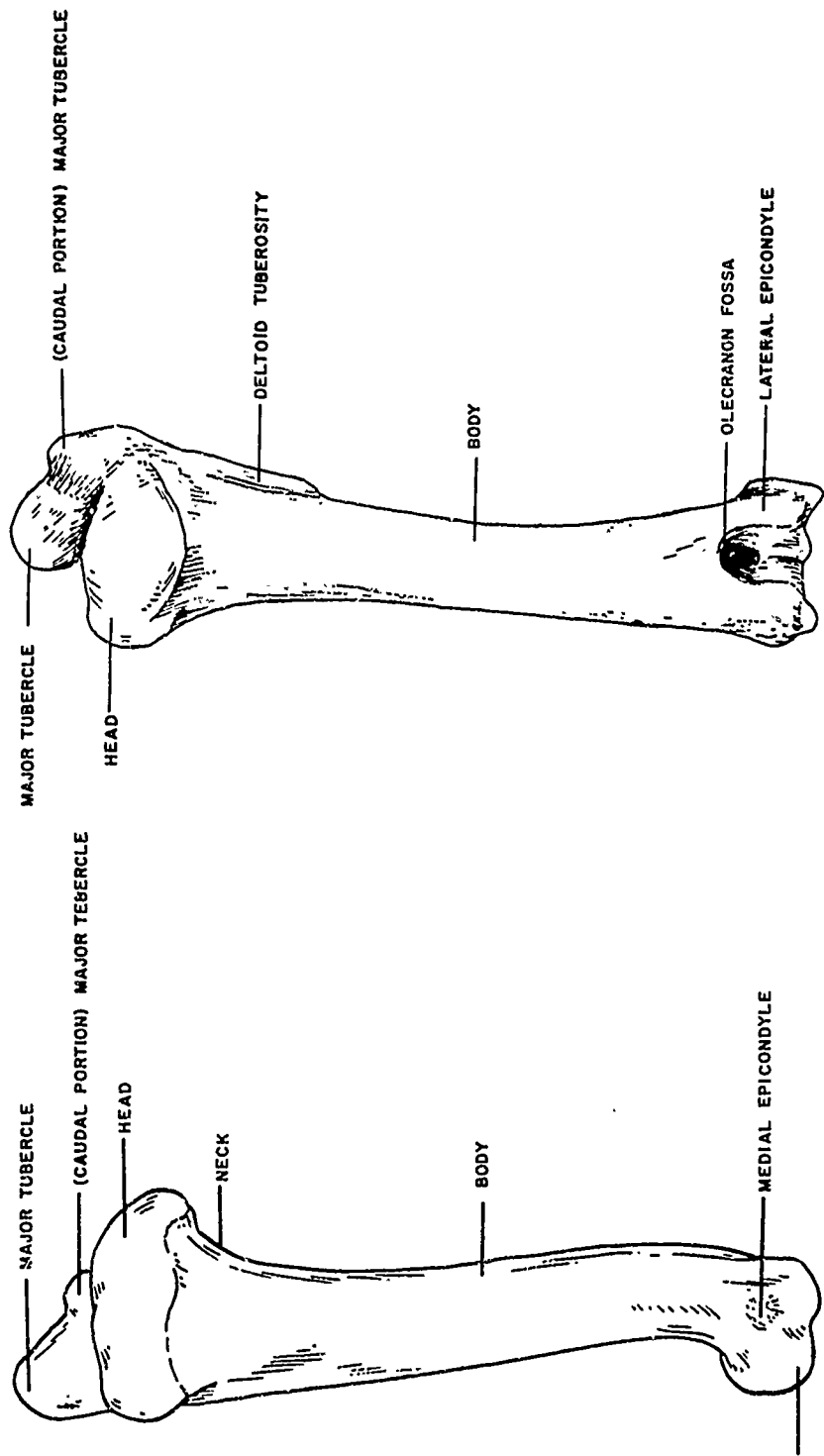


Figure 28. Right Humerus, Medial and Caudal Aspects

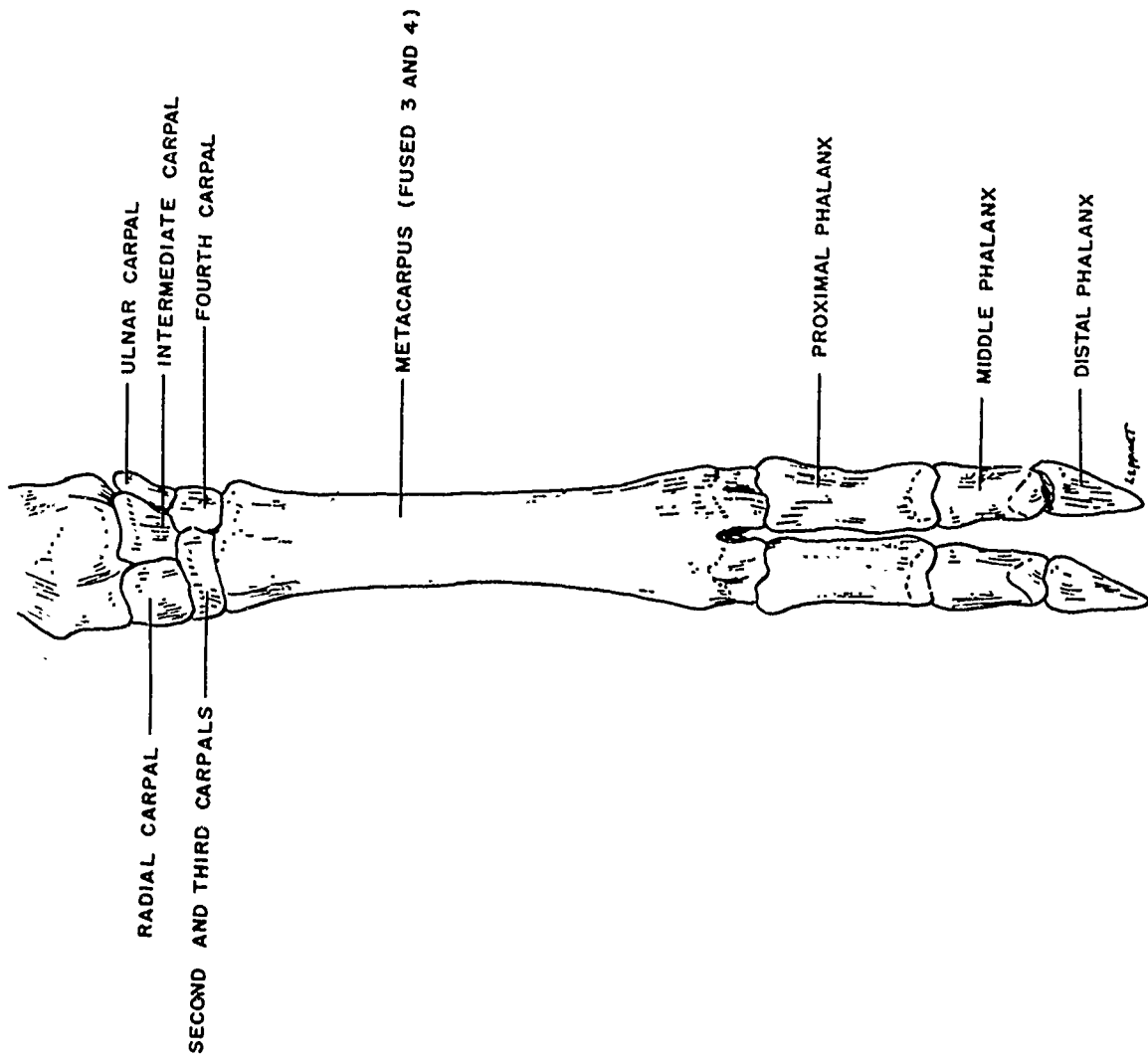


Figure 29. Left Pectoral Foot, Cranial Aspect

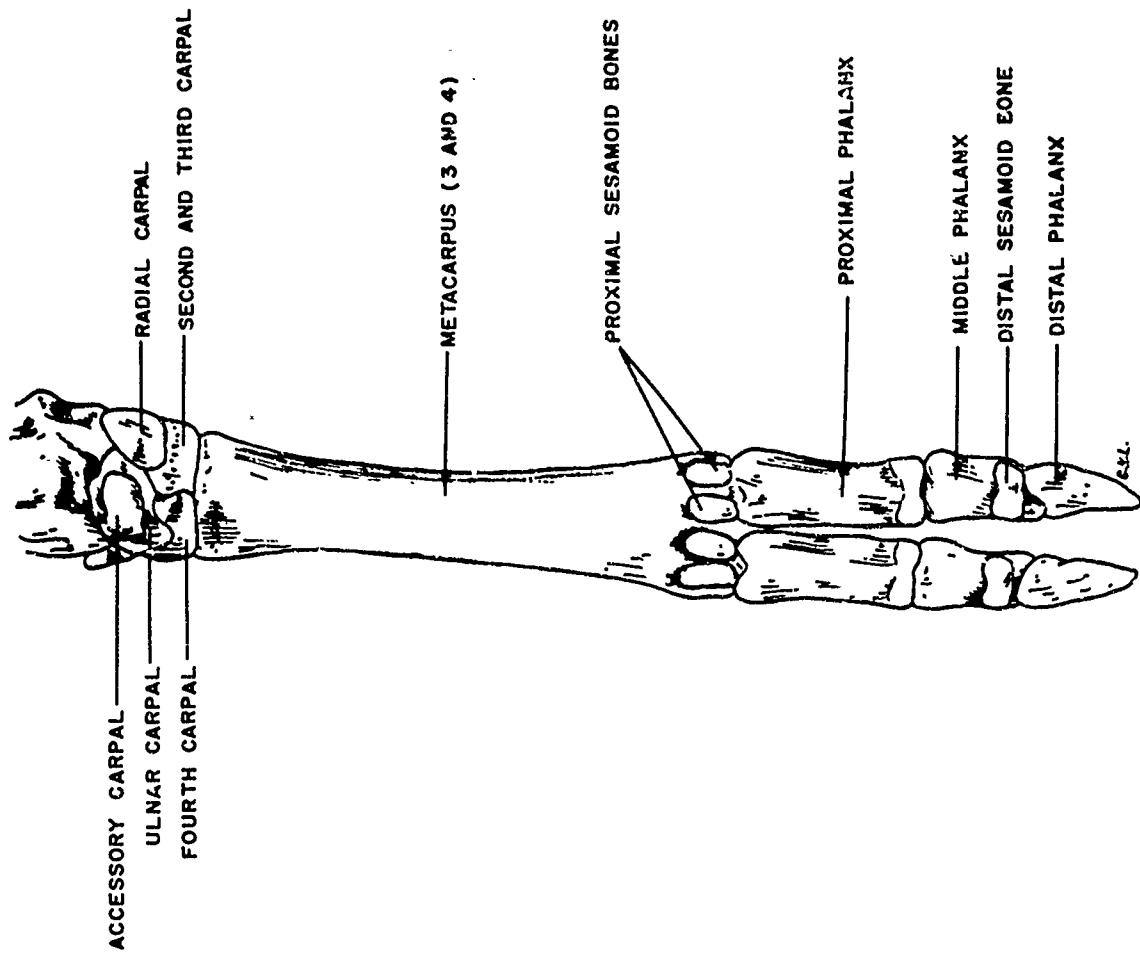


Figure 30. Left Pectoral Foot, Caudal Aspect

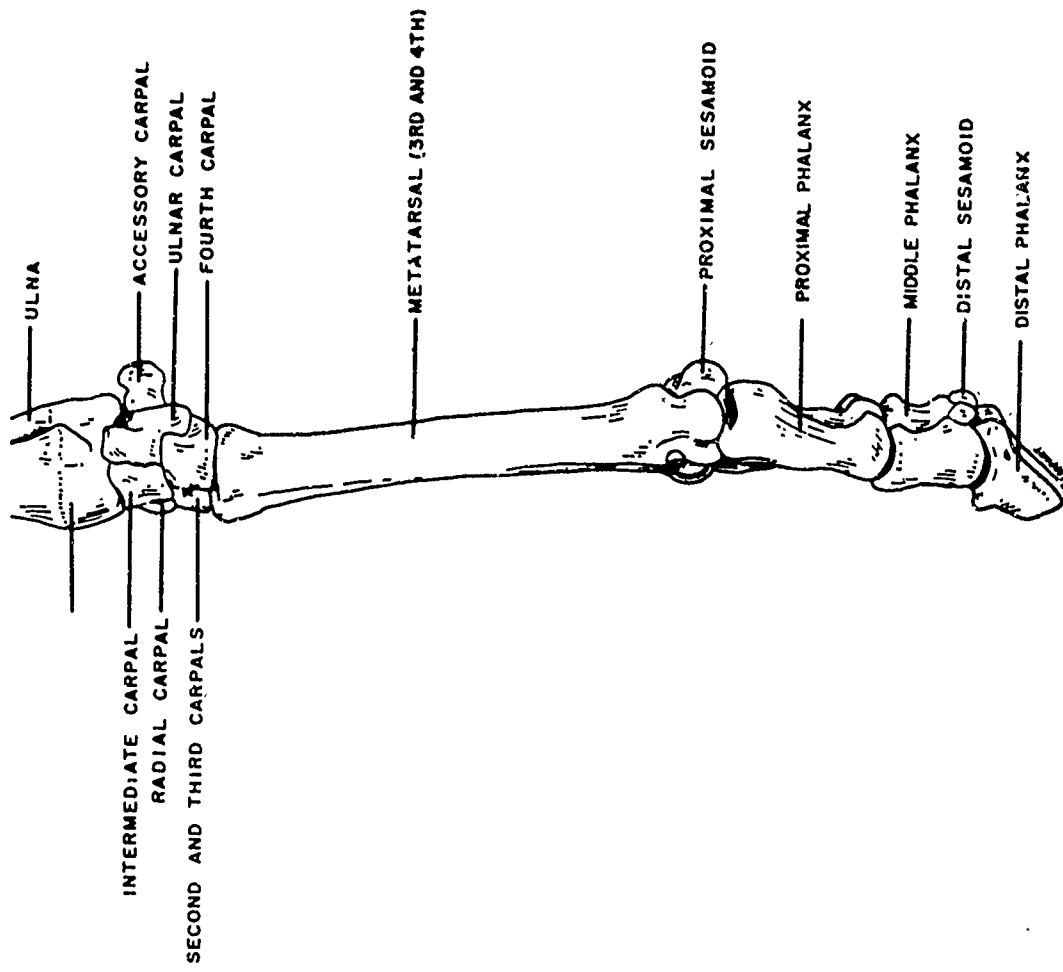


Figure 31. Left Pectoral Foot, Lateral Aspect

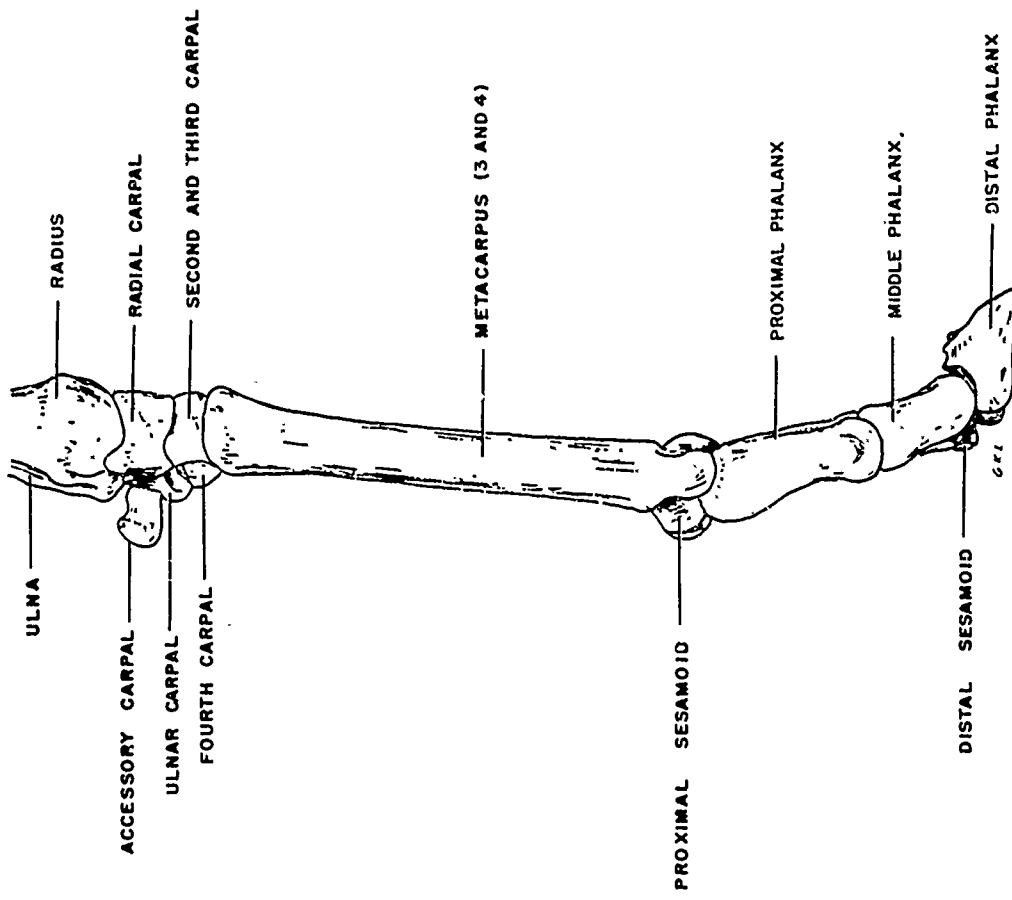


Figure 32. Left Pectoral Foot, Medial Aspect

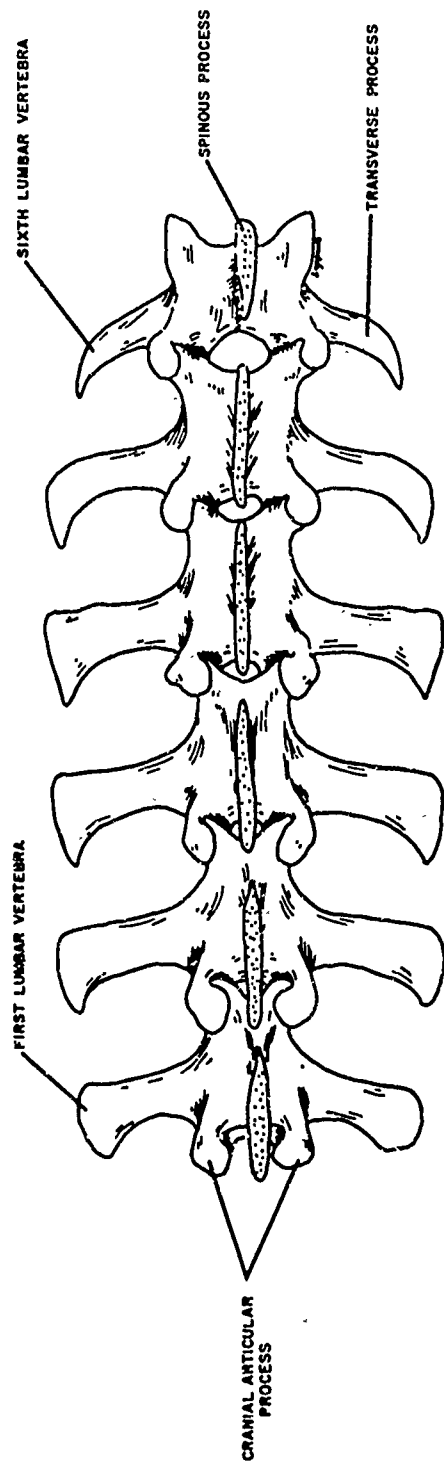


Figure 33. Lumbar Vertebrae, Dorsal Aspect

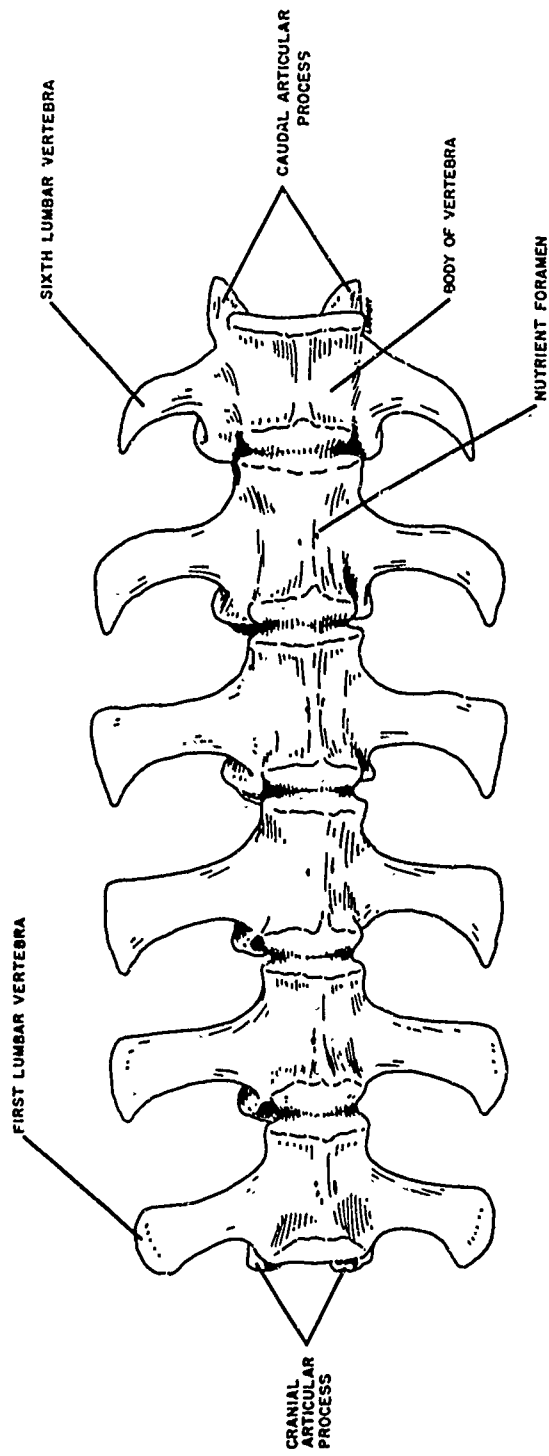


Figure 34. Lumbar Vertebrae, Ventral Aspect

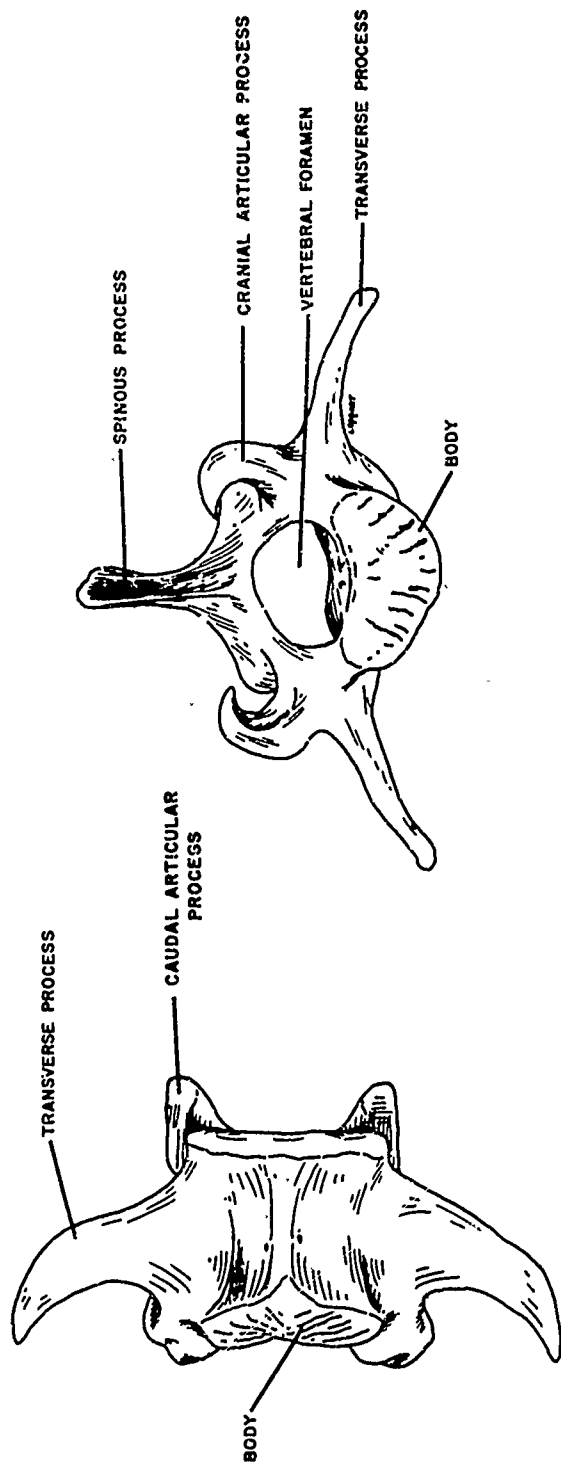


Figure 35. Sixth Lumbar Vertebra, Ventral and Cranial Aspects

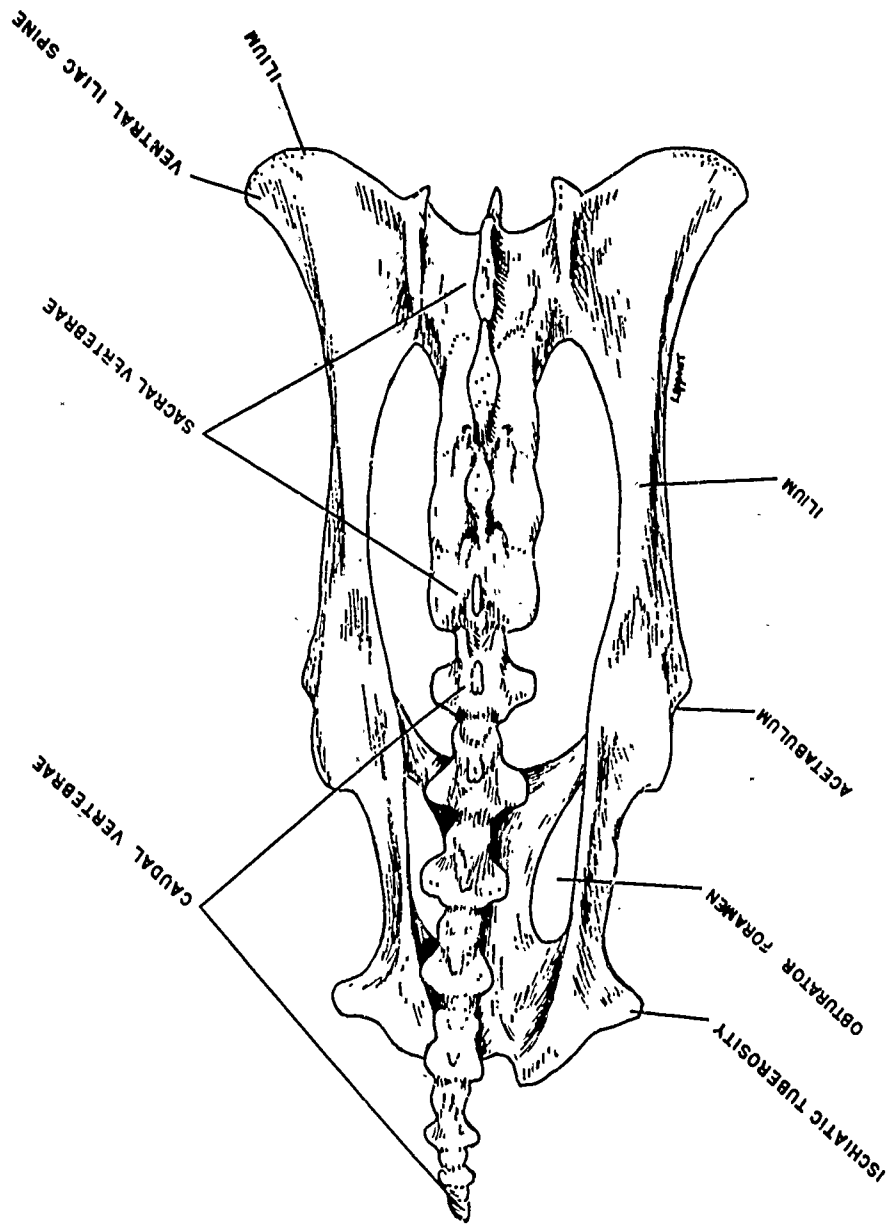


Figure 36. Pelvis With Sacral and Caudal Vertebrae Attached, Dorsal Aspect

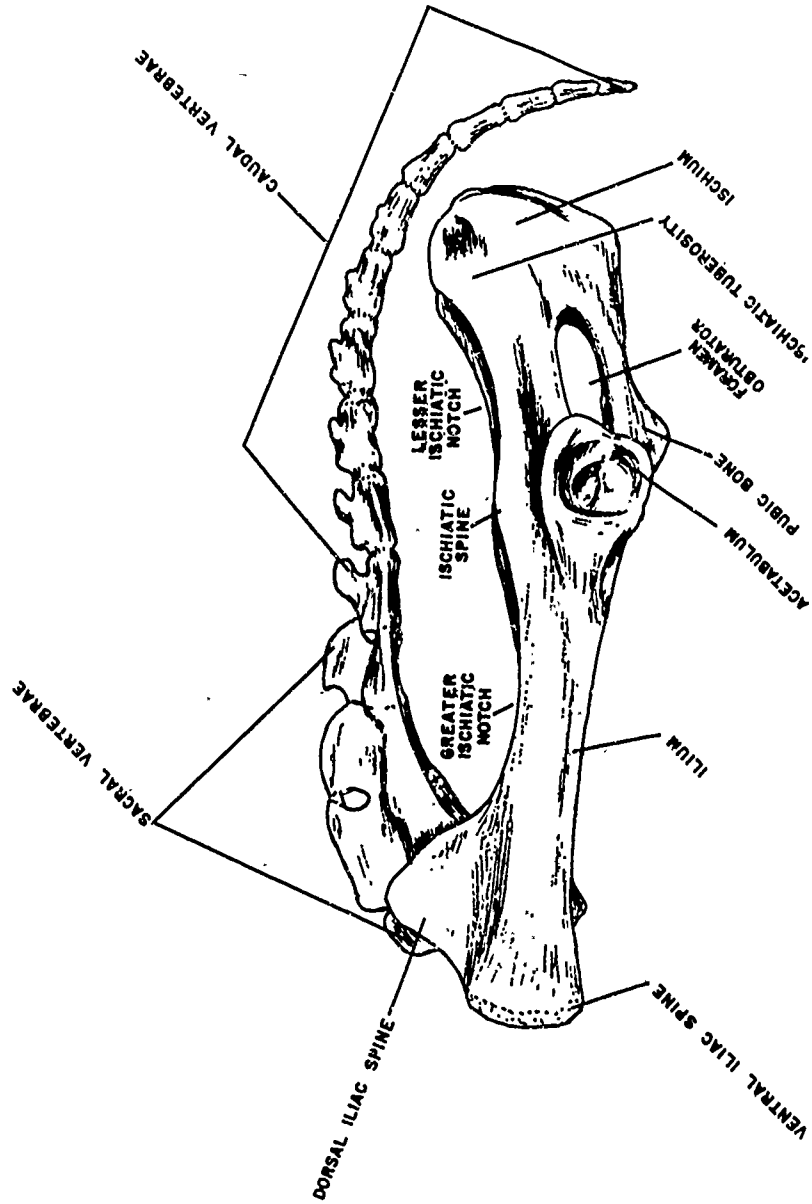


Figure 37. Pelvis With Sacral and Caudal Vertebrae Attached, Left Lateral Aspect

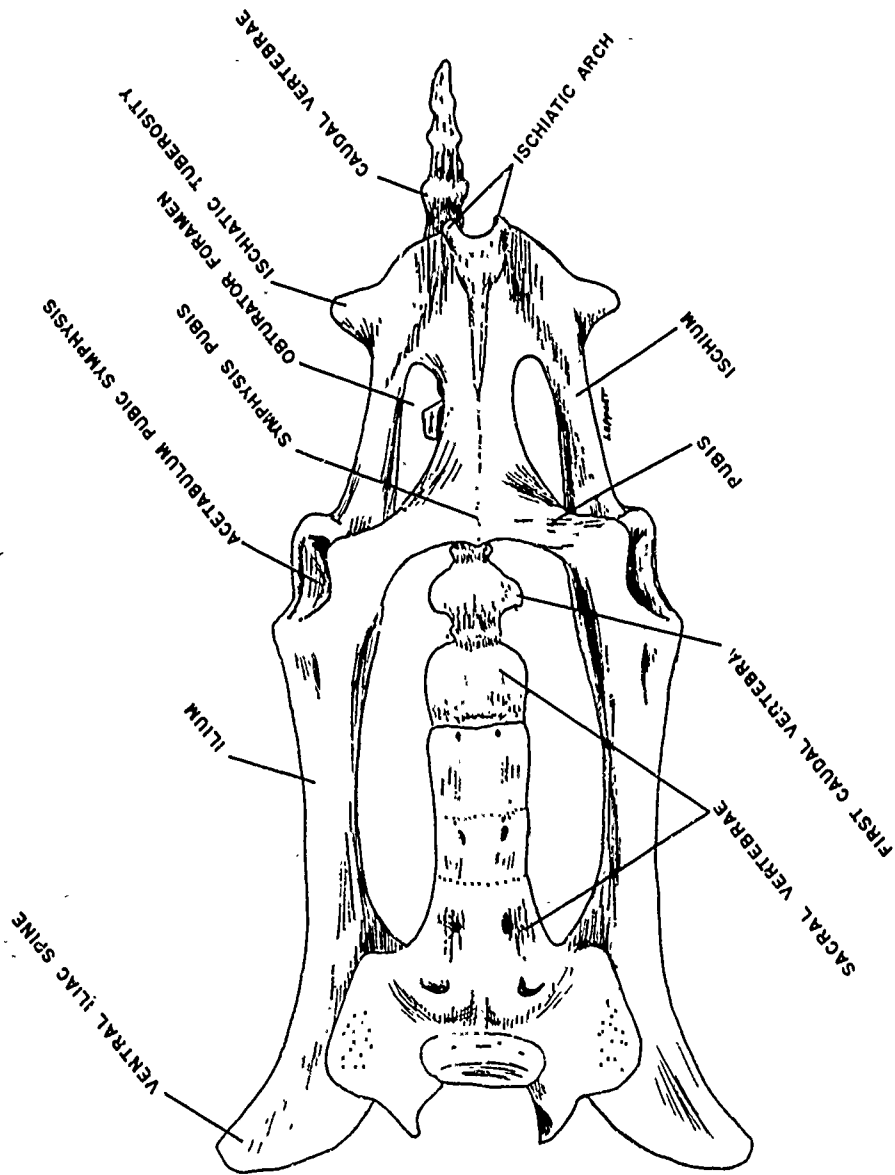


Figure 38. Pelvis With Sacral and Caudal Vertebrae Attached, Ventral Aspect

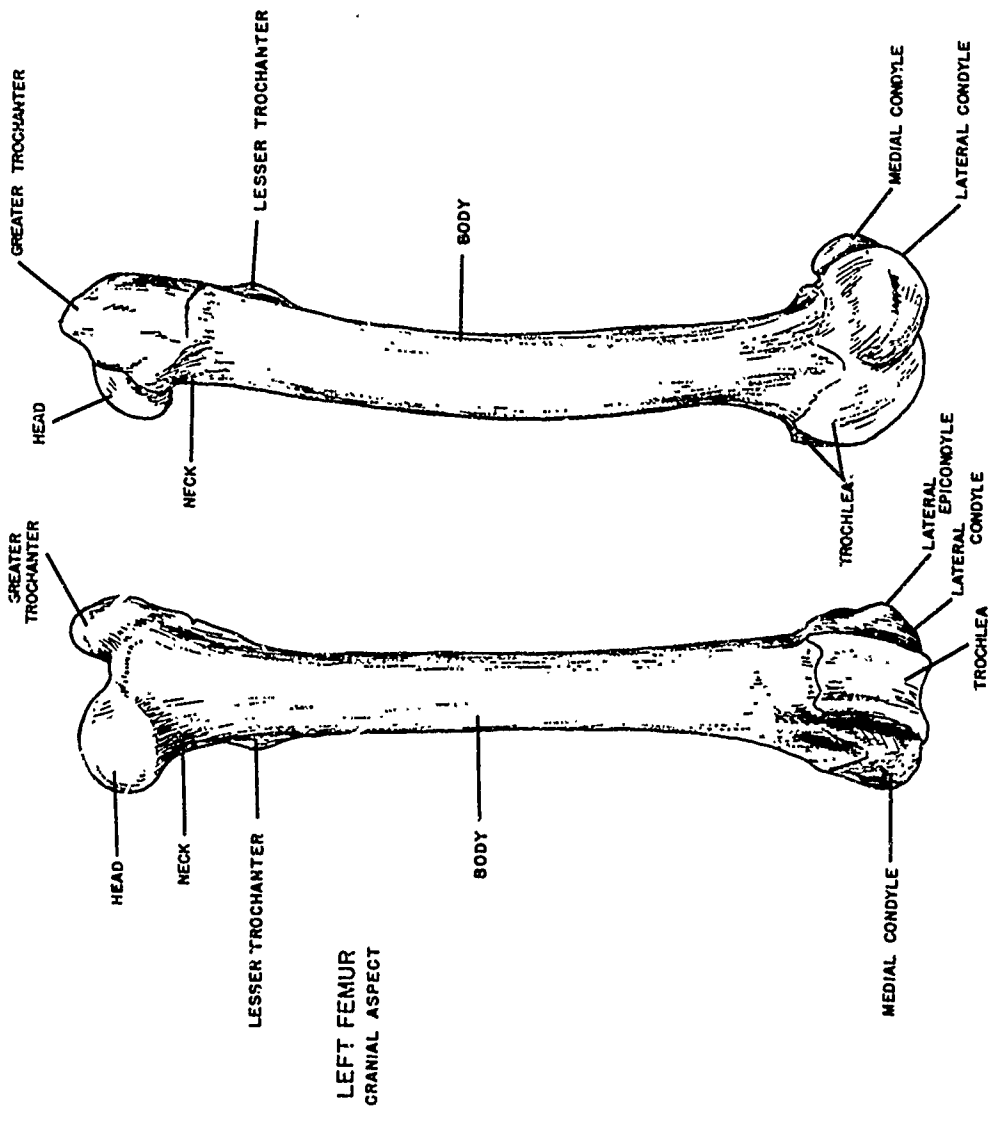


Figure 39. Left Femur, Cranial and Lateral Aspects

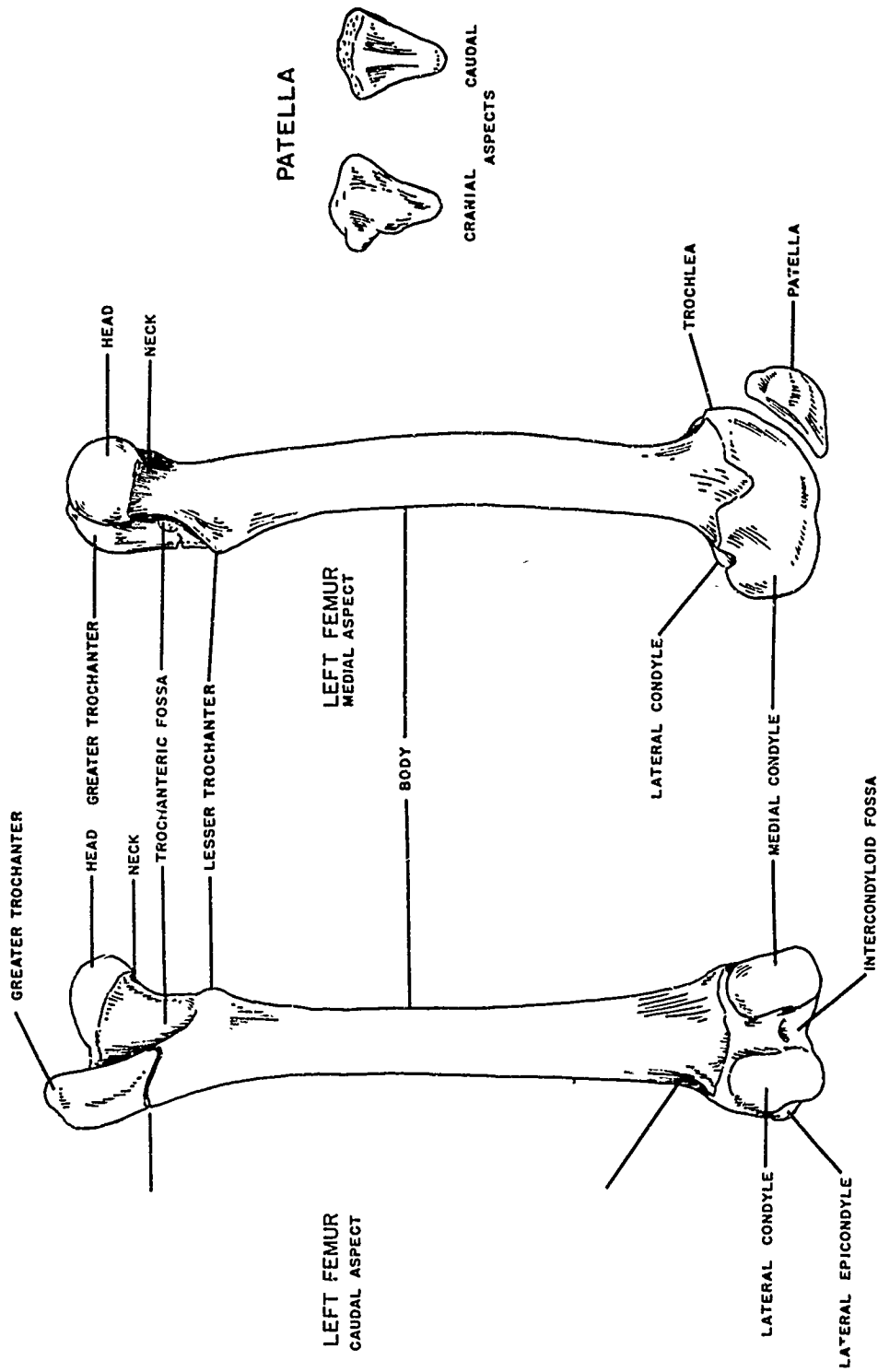


Figure 40. Left Femur, Caudal and Medial Aspects

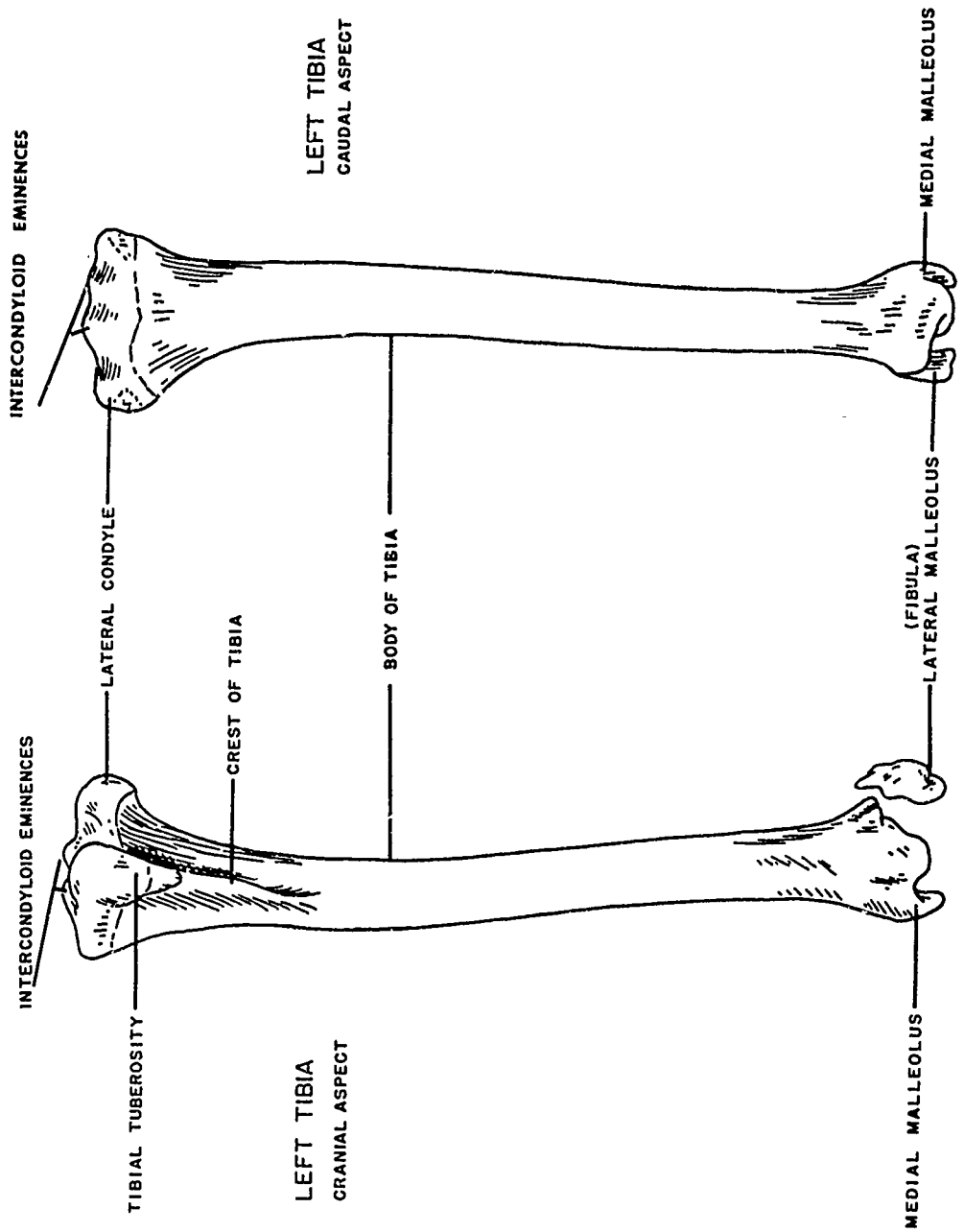


Figure 41. Left Tibia, Cranial and Caudal Aspects

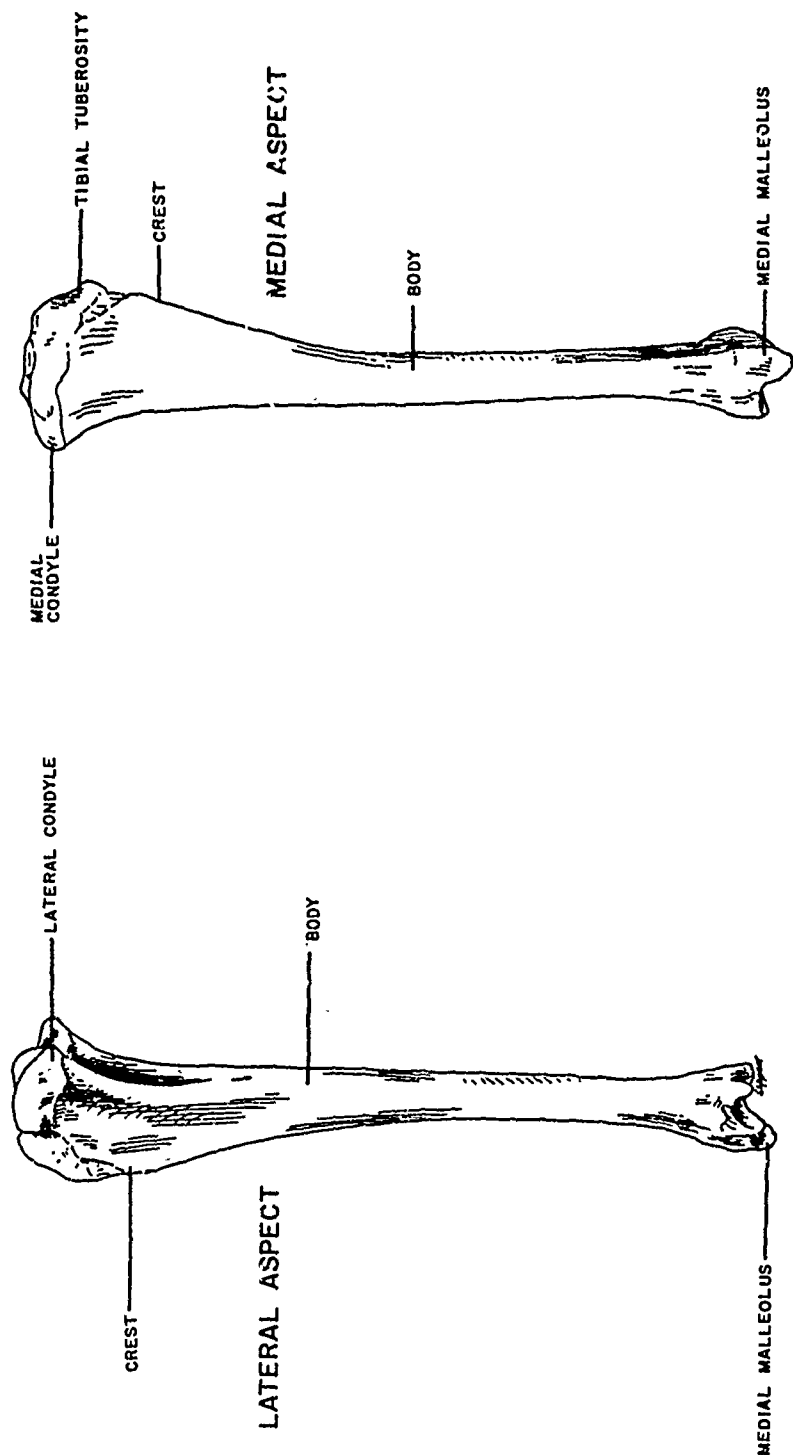


Figure 42. Left Tibia, Lateral and Medial Aspects

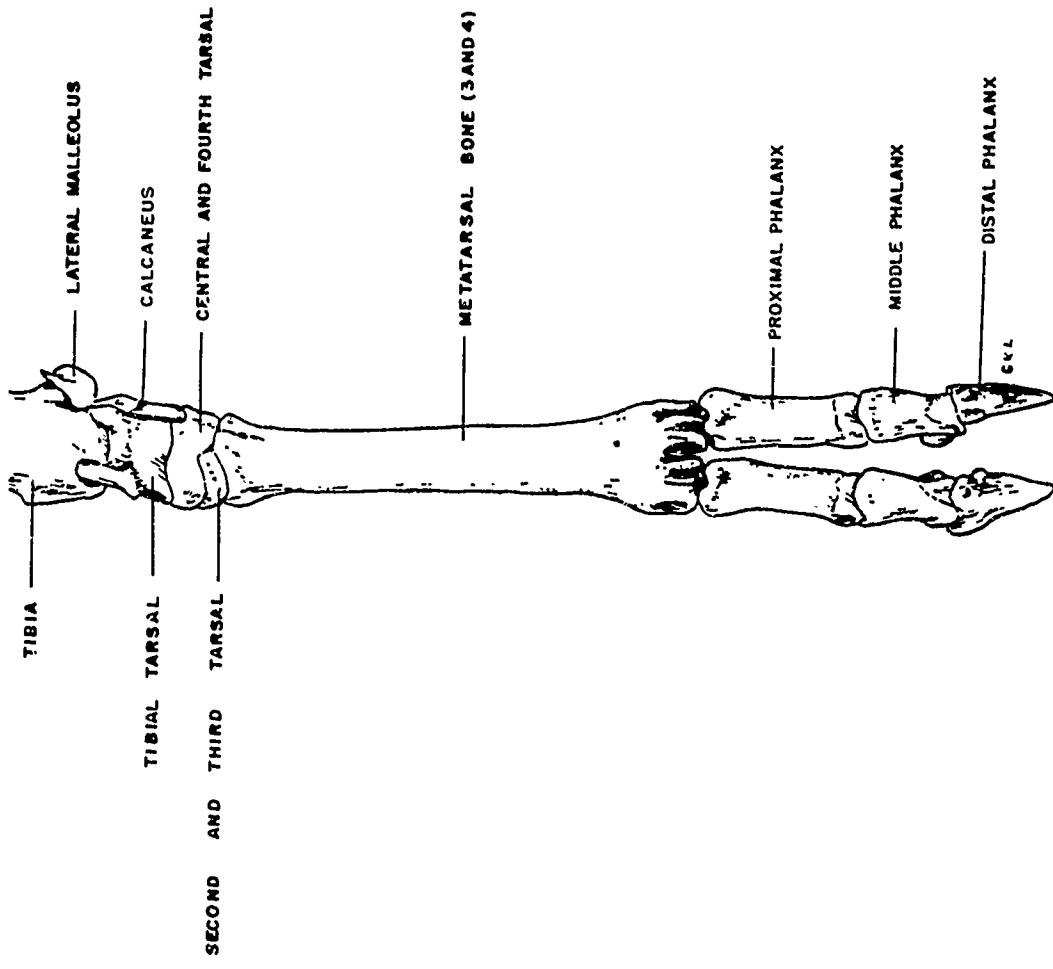


Figure 43. Left Pelvic Foot, Cranial Aspect

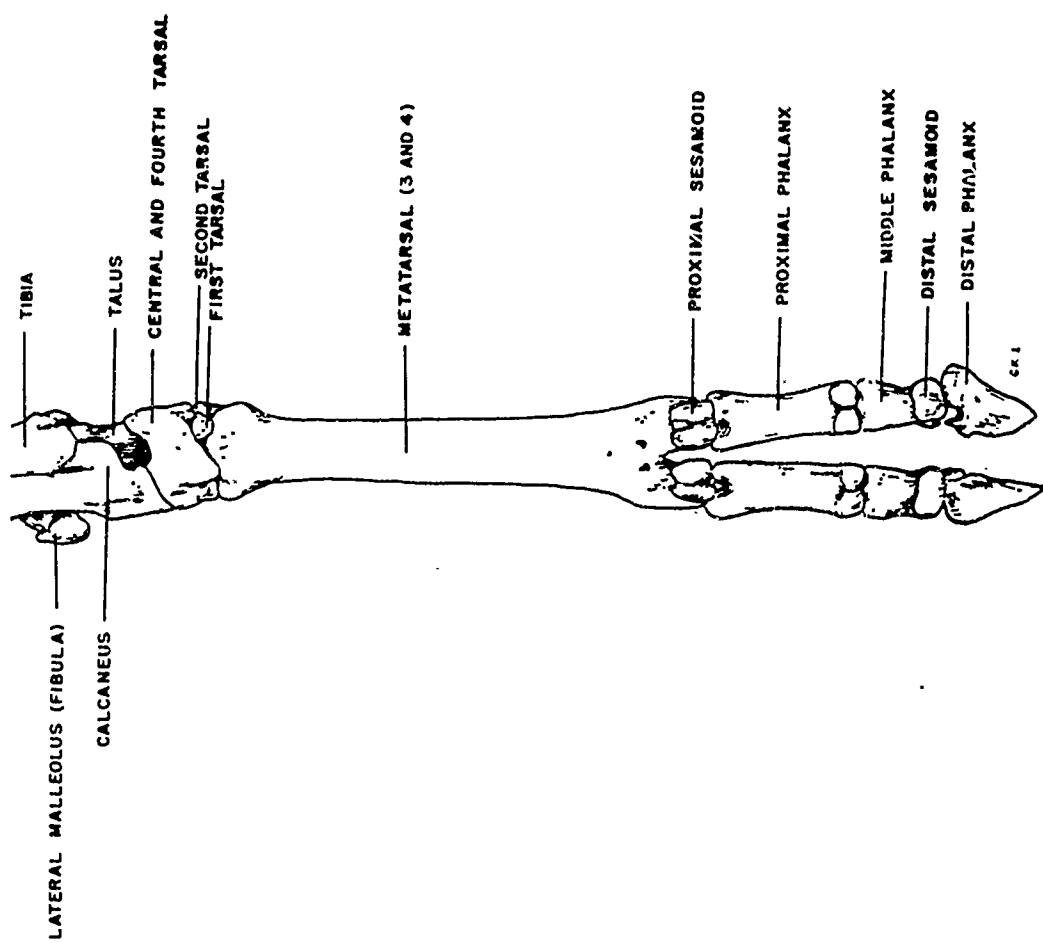


Figure 44. Left Pelvic Foot, Caudal Aspect

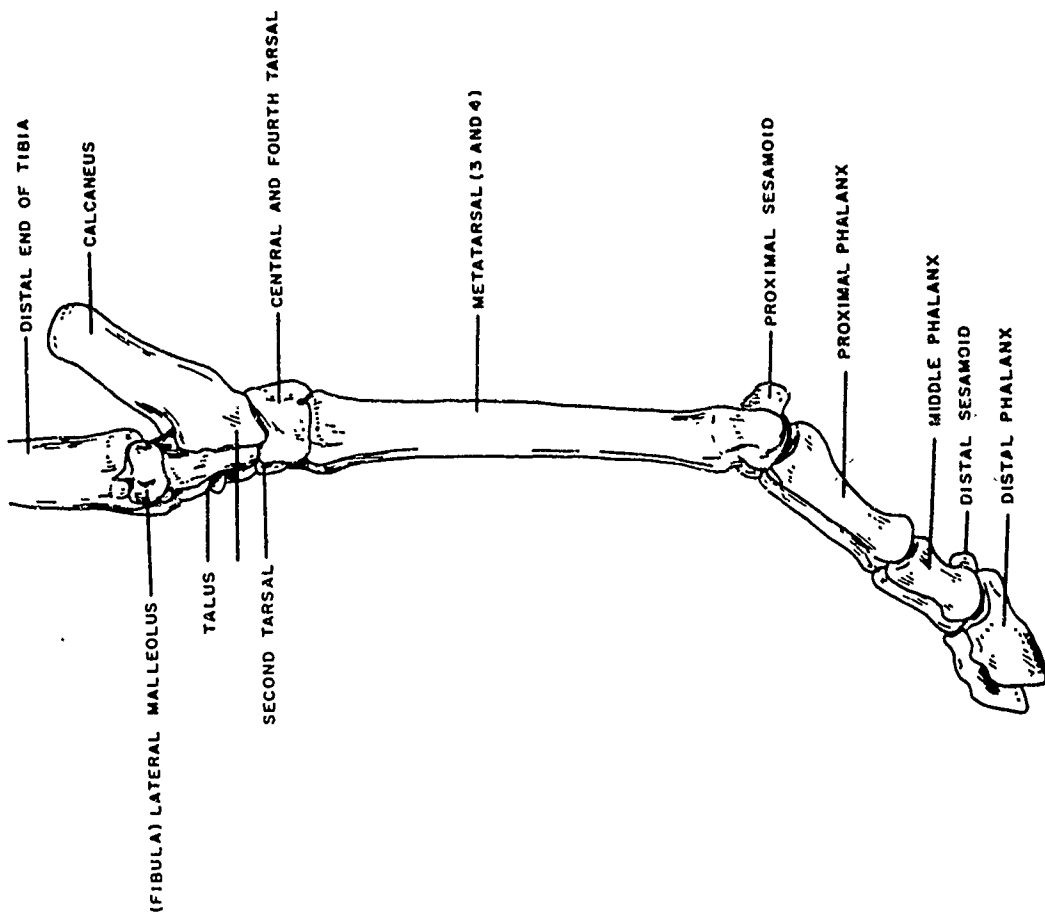


Figure 45. Left Pelvic Foot, Lateral Aspect

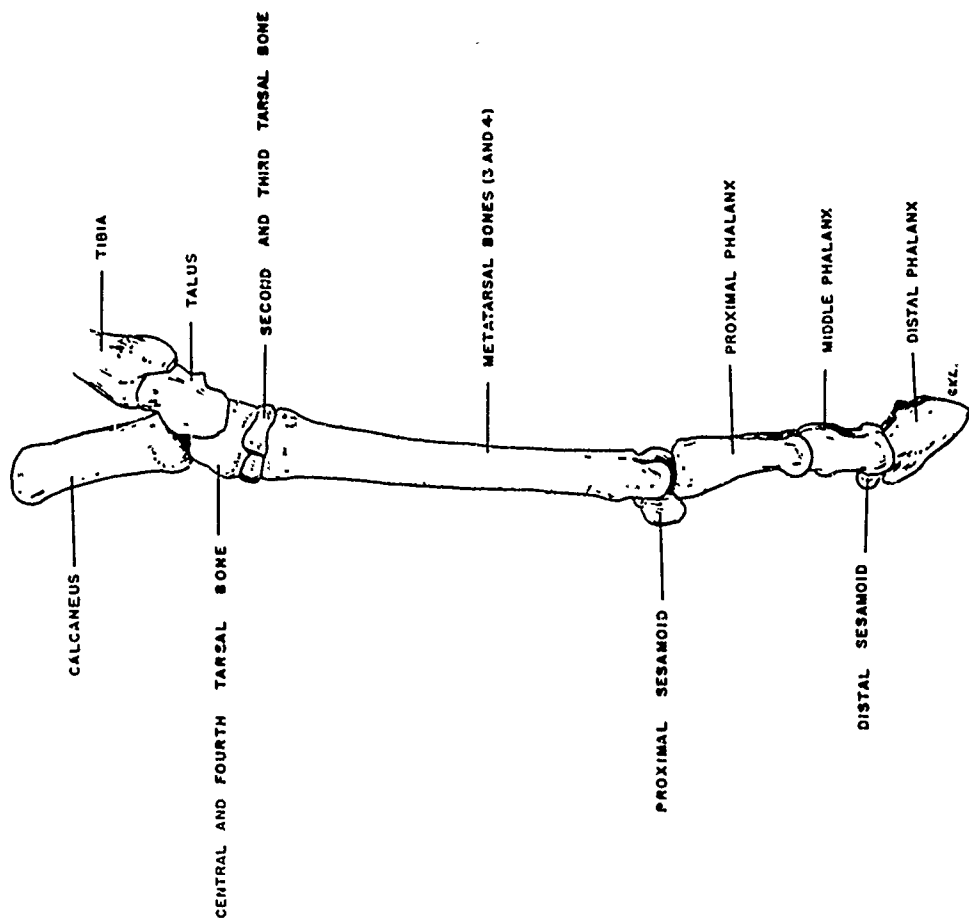


Figure 46. Left Pelvic Foot, Medial Aspect

SELECTED REFERENCES

1. May, Neil. The Anatomy of the Sheep. 2d Ed. University of Queensland Press, Wilke Company, Australia. 1964.

2. Miller, M. E., Christenson, G. C., and Evans, H.E. Anatomy of the Dog. W. B. Saunders Company, Philadelphia, Pennsylvania. 1964.

3. Sisson, S., and Grossman, J. D. The Anatomy of the Domestic Animals. 4th Ed. W. B. Saunders Company, Philadelphia, Pennsylvania. 1953.

APPENDIX

PREPARATION OF OSTEOLOGICAL SPECIMENS

By Clarence E. Hopkins, Sr.

This process is patterned after that used by Dr. M. L. Washburn, who introduced it to this laboratory. Dr. Washburn organized the osteology section of the Biophysics Laboratory in 1954 to provide autopsy support for projects involving the skeletal system.

The essential steps in this process are digestion of soft tissues with alkali and bleaching.

I. MATERIALS AND METHODS.

A. Equipment.

1. A large steel tank. For a moderate amount of work with an animal the size of a goat, a 50-gal steel drum is convenient.
2. Hot plate.
3. Wire baskets made with hardware cloth fine enough to prevent passage of small bones.
4. Thermometer 0° to 100°C.
5. Adjustable thermostwitch 100° to 400°F range, 20 amp at 115 volts.
6. Indicator light 110 volts.
7. Miscellaneous standard electrical connections.

B. Reagents.

1. Sodium hydroxide pellets.
2. Hydrogen peroxide.

C. Method.

1. Digestion.

Mount the tank so that the hot plate contacts the bottom but does not support weight. Connect the thermostwitch in series with the hot plate and indicator light; and insert the thermostwitch in the tank near the bottom. Lower the thermometer into the solution with a wire.

Table A. Times Required for Digestion

Bone	Time
	hrs
Scapula	16
Humerus	16-20
Radius-ulna	16-20
Cervical vertebra	18-24
Dorsal vertebra	24-30
Lumbar vertebra	24-36
Pelvis	24-30
Tarsals	36-40
Femur	30-36
Tibia	24-30
Metatarsals	36-48
Metacarpals	36-48
Phalanges (uncleaned)	48-72

Fill the tank with a 1% sodium hydroxide solution and cover. Plug the hot plate and indicator light into the thermostat and adjust it to maintain the digesting solution at 45°C as indicated by the thermometer.

Deflesh all bones as much as possible with a knife or scalper blade. Then place them in labeled wire baskets and immerse in the heated solution. Watch the bones closely, and every 2 to 3 hours remove them from the solution, rinse with tap water and gently clean with a small brush.

a. Time.

The time required varies, and bones that are left in the solution too long will scale and crack when dry. Table A gives the approximate times required but should be used only as a guide. The time actually required for best results with any given specimen must be determined by repeated observation.

b. Temperature.

The temperature of the alkali bath is quite important. A specimen that would require treatment for several weeks in a cold 1% sodium hydroxide solution can be processed completely in 1 or 2 days in a warm solution of the same strength. Even a moderate elevation of temperature (5° or 10°C) above room temperature causes marked acceleration of the process. A very high temperature, however, is detrimental because the bones are softened before the soft tissues have been digested sufficiently. For efficient work and successful results, a temperature between 45° and 48°C has proved to be very satisfactory.

c. Solution.

Other factors being equal, the time required for soft-tissue removal decreases as the concentration of the alkali is increased. A 1% solution of sodium hydroxide was found to be satisfactory.

d. Quantity of Soft Tissue.

The bones should be cleaned fairly well of soft tissue before digestion if that is possible without the risk of losing small bones, and they should be processed when fresh. In general, the softer the tissue, the faster the processing. Specimens that have been removed from the animal for a long time with dry hard tissues adhering to the bones or embalmed specimens require a longer period of processing than do fresh ones.

2. Bleaching.

A solution of hydrogen peroxide serves admirably as a bleach for bones. It has no noticeable decorative effect upon the bones and gives them a nice snow-white appearance. A solution of sodium hypochloride was tried as a substitute for hydrogen peroxide because it is much more economical, but the results were disappointing. The bones had a faint yellowish tinge, and they flaked excessively.

A 28% or 30% solution of hydrogen peroxide also may be used for bleaching with very good results, but a 3% solution conserves material and gives equally good results. The procedure for bleaching is as follows.

- a. Transfer the bones from the wire basket to a suitable container.
- b. Cover the bones with a 3% solution of hydrogen peroxide, and place a lid on the container. (The identification number of the bone should be marked on the container.)
- c. Allow the bones to bleach until white; 4 to 8 hours should be sufficient for bleaching.
- d. Remove the bones from the bleach, rinse them in water, and transfer them to a table to dry. Paper towels under the specimens aid drying.

3. Labeling.

Each individual bone should be labeled for identification as soon as it is bleached and dried. An India-ink label is more durable than a pencil label.

UNCLASSIFIED

Security Classification

DOCUMENT CONTROL DATA - R & D		
<i>(Security classification of title, body of abstract and indexing annotation must be entered when the overall report is classified)</i>		
1. ORIGINATING ACTIVITY (Corporate author) CO, Edgewood Arsenal ATTN: SMUEA-RB Edgewood Arsenal, Maryland 21010		2a. REPORT SECURITY CLASSIFICATION UNCLASSIFIED
		2b. GROUP NA
3. REPORT TITLE ATLAS OF GOAT ANATOMY. PART I: OSTEOLOGY		
4. DESCRIPTIVE NOTES (Type of report and inclusive dates) This work was started in September 1968 and completed in March 1970		
5. AUTHOR(S) (First name, middle initial, last name) Clarence E. Hopkins, Sr.; Thomas E. Hamm, Jr., CPT, VC; and Gary L. Leppart		
6. REPORT DATE September 1970	7a. TOTAL NO. OF PAGES 67	7b. NO. OF REFS 4
8a. CONTRACT OR GRANT NO.	9a. ORIGINATOR'S REPORT NUMBER(S) EATR 4431	
b. PROJECT NO. 1T062110A027		
c.	9b. OTHER REPORT NUM(S) (Any other numbers that may be assigned this report)	
d.		
10. DISTRIBUTION STATEMENT This document has been approved for public release and sale; its distribution is unlimited.		
11. SUPPLEMENTARY NOTES		12. SPONSORING MILITARY ACTIVITY
13. ABSTRACT The purpose of this investigation was to establish a reference source for the normal anatomy of the angora goat (<i>Capra hircus</i>). This report, the first in a series, presents the skeletal anatomy of this animal.		
14. KEYWORDS Angora goat <i>Capra hircus</i> Skeletal anatomy Bone digestion Osteology		

DD FORM 1473
NOV 65

REPLACES DD FORM 1473, 1 JAN 64, WHICH IS OBSOLETE FOR ARMY USE.

67

UNCLASSIFIED

Security Classification