

AD 678249

TRANSLATION NO. 142

DATE: Sept 1968 (1)

Russian

DDC AVAILABILITY NOTICE

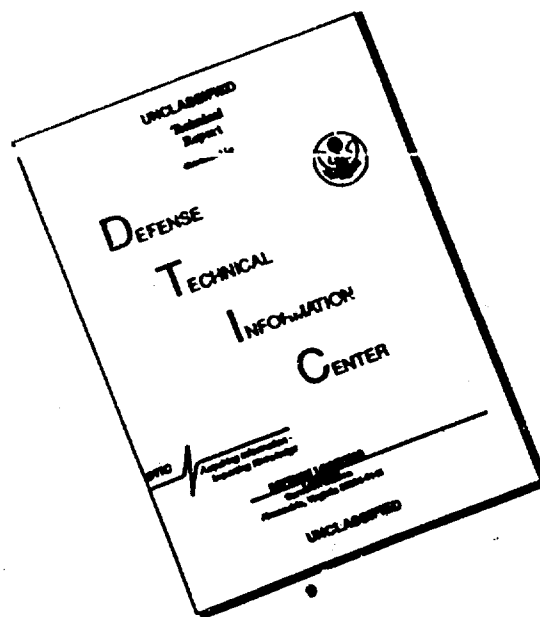
This document has been approved for public release and sale; its distribution is unlimited.

DDC
RECEIVED
DEC 2 1968

DEPARTMENT OF THE ARMY
Fort Detrick
Frederick, Maryland

Reproduced by the
CLEARINGHOUSE
for Federal Scientific & Technical
Information Springfield Va. 22151

DISCLAIMER NOTICE



THIS DOCUMENT IS BEST
QUALITY AVAILABLE. THE COPY
FURNISHED TO DTIC CONTAINED
A SIGNIFICANT NUMBER OF
PAGES WHICH DO NOT
REPRODUCE LEGIBLY.

#142
cy1
Neuropathology and Psychiatry, 16(1): 23-27, 1947

Velokh, B. S.

Several peculiarities of the acute period of Japanese encephalitis in 1946.

During our studies of the outbreak of Japanese encephalitis we devoted particular attention to the acute period, it being the most severe phase of illness. The basic virtue of the pathogenesis of Japanese encephalitis is a massive affection of the endothelia of the capillaries and precapillaries of the brain and parenchymatous organs, with the development of various degrees of hemorrhaging of the substances of the brain, severe edema of the brain, loss of conductivity of the impulses along the nerve waves and disruption of the connections of the synaptic apparatuses of the nerves, and in more severe cases- a degree of disruption of certain elements of neuroglia and nerve cells.

The disruptions of the elements of neuroglia and nerve cells comes on the horizon of expressed reactive-proliferative processes.

The enumerated components of the pathological action of the virus and its toxins on the nervous system relates to the action on the brain as a whole, and in more severe cases, to the spinal cord and parenchymatous organs. Those sections of the brain which are richest in capillaries and precapillaries suffer the most.

A significant role in the pathogenesis of Japanese encephalitis is played by the oxygen starvation of the nervous system.

Of the four periods of Japanese encephalitis, established by N. I. Grashchenkov, we are interested in the second, or acute, period, from the standpoint of neurological symptoms.

In the initial period, related to the first 2-3 days of illness, and connected with a high temperature and predominant general toxic

and infectious symptoms, the patient does not always fall into the scope of neuropathologists, thus, the neurological symptomatic in this period is relatively poor. Included in the early symptoms are various degrees of tension of the occipital muscle, varying degrees of hazy or lost consciousness, accelerated pulse, muscular hypertonia and variation of the eye movement faculties and pupil reaction.

Of the enumerated symptoms of the initial period, we can consider the variation of the muscle tone towards hypertonia and the variation of the eye functions and pupil reaction as neurological symptoms. As a further analysis of the neurological symptoms of the acute period and their localization would indicate, the said symptoms of the initial period can be connected with the early affection of the central brain, namely, the disruption of the penetrability of the capillaries of the central brain and edema of it with the commencement of decerebration rigidity, appearing first as expressed extensor reflexes, and also the nuclei of the eye movements, located in this section of the brain.

The acute period, following the initial period, takes place on the 4-6th days of illness. This is a period of stable or slightly fluctuating high temperatures, during which many symptoms or local affection of the brain appear. It should be mentioned that the predominant symptoms are the advanced muscle tone and acute decerebration rigidity. As a result of the great predominance of the extensor reflexes, essentially forming the decerebration rigidity, it is not possible to cause sinewy or peristaltic reflexes.

There also is an increase of the disruption of the eye movements and pupil reaction. This indicates the further disruption of the function of the brain stem due to the all increasing penetrability of the

capillaries in this section of the brain and edema. Obviously, the symptoms of the central brain are associated, in the acute period, with clearly established symptoms of disruption of the hypothalamic region. If we recognize the fact that the supply of blood vessels in the hypothalamic regions is almost 100 times that of any other sectional angioarchitecture of the brain, and if we keep in mind that the first mechanism in the pathogenesis of Japanese encephalitis is the affection of the capillaries and precapillaries, and their increased penetrability to large white molecules and elements of blood, not speaking of the virus circulating in the blood stream, then it is clear why the affection of the hypothalamic region is so clearly expressed and why it is disrupted so quickly. If we keep in mind the modern concepts on the physiology of the hypothalamic system and placement of the higher centers of vegetative nerve system in it, the sympathetic as well as parasympathetic, we can see how important this region is in the functioning of the organism. It controls all the types of volumes, such as: albuminous, oxygen, etc.

Further, an essential importance is given the thermo-regulation and regulation of the cardio-vascular activity. The role of this region is of great importance also in the general function of the organism. It is no accident during Japanese encephalitis that there is an early appearance of various degrees of dystrophic damage. Even the quick increase of temperature to 40-41 C and higher depends, possibly, on the disruption of the respective centers of thermo-regulation by the pathological processes, located in the hypothalamic region. It is known that the perspiration faculties are also located in this region. With this, in the acute period, we observed extensive perspiration of these patients; it did not always coincide with the high temperature and, we can surmise, was connected

with the disruption of the centers of perspiration control, located in the hypothalamous region. In the acute period of Japanese encephalitis the dominating symptoms are hyperemia of the face, sclera and upper section of the chest. This symptom cannot be explained by the peripheral disruption of the vasodilatations and vasoconstrictions, and only by the disruption of the hypothalamous regulation, or destruction of the walls of the vessels.

It is understandable that, as a result of the extensive edema of the cortex of the brain, and partially due to the microhemorrhaging in certain sections of the brain, in the acute period the patient is often troubled by loss of consciousness. There also are symptoms indicating the affection of the cortex, such as: labile aphasia, presence of hemiplegia of the central type, irregardless of the acute muscle tone; the frontal lobes of the brain suffer greatly. If frontal-pontocerebellar type symptoms increase, there are disruptions of coordination and presence of clear grasping reflexes. Affection of the lower segments of the parietal region are indicated by symptoms such as (later, after the return of consciousness) lengthy apraxia. After coming out of the acute status and regaining consciousness, the patients retain symptoms which indicate disruption of the function of the optic region of the brain. These include quick faintness during fixation of objects, inability to read, distinguish various light giving sources, hazyness, etc.

Curiously, examination of the field of vision and color perception at the termination of the acute period always indicated a sharp narrowing of the field of vision and disruption of the color perception, particularly to green, then to white colors.

Unusual also is the degree of affection of the temporal region of the cortex, the symptoms of which are disyness and noises in the ears,

with the full retainment of the vestibular apparatus. The facial expressions and skin 'oil' are related to it also, various forms of hyperkinesis in the form of choreatic-athetotic or chorea-type movements. We also observed a forced or fixed smile, tonic cramps without the clonic components.

However, Japanese encephalitis does not result in a post-encephalitic parkinsonism, which, as surmises N. I. Grashchenkov, is connected with the simultaneous forceful damage of the Sommering black substance, while with Ekonomo encephalitis this substance is not damaged, and the subcortical ganglions are affected more intensively by inflammatory processes.

Here are two case histories:

B. 20 years, entered hospital 11 Sep 46. Infected 7 Sep 57; headaches, felt sick, temperature rose; on entrance to hospital his status was medium severe, temperature 39.6. Slight hyperemia of face, slight increase of muscle tone, pulse 92, pressure satisfactory. Heart tones dull, no murmurs. Tongue furred, moist. Stomach soft, non-painful during palpation.

12 Sep. Tem. 37.5-39.4, pulse 88, dull heart tones. Breathing and swallowing normal. Rigidity of occipital muscle, hyperemia of face, two-sided ptosis, consciousness weak. Light hyperkinesis of upper right extremity. Sinevy reflexes decreased. Babinski symptom of left.

13 Sep. Pulse 120, breathing 30 p/m, tem. 40.4-40.9. Patient accurately examined neurologically. Condition severe, unconscious, slight movement faculties; abundant perspiration; face and chest covered by perspiration. Hyperemia of face, sclera and chest. Sharp tension of occipital muscle, two-sided Kernig symptoms. Contraction of muscles of upper extremities. Acute muscle hypertonia. Presence of neck-tonic

reflexes and symptoms of decerebration rigidity. Parietal and sinegy reflexes, in view of the severe condition of the patient, were not present. Abdominal reflexes not present, due to the tensions of the abdominal wall. Babinaki symptom on left.

Spinal puncture. 20 cm³ of fluid taken. Fluid clear, transparent, flows with difficulty, sometimes in droplets. Serum injected, intravenously at 10 cm³ and intramuscularly at 10 cm³. Intravenous injection of 40% glucose solution, lobeline under skin, acids, 5 cm³ of proserine subcutaneously.

14 Sep. Tem. 40.1, pulse 100, weak pressure, arrhythmic. Breathing 35 per minute, high. Condition near severe; acute cyanosis of face, extremities, severe perspiration, muscle tone decreased. No grasping reflexes. Sinegy and parietal reflexes medium, even. Patient very uncomfortable, changed to inability to move. Sprawled on bed, half open eyes.

Injected 1 cm³ of lobeline, 2 cm³ of camphor. Constant check of heart action and breathing, both disrupted. Death followed in 18 hours.

Pathoanatomical data: Acute edema and blood-filled soft sections of brain. Rare punctated, diffused hemorrhaging in the brain substances and soft membranes with predominant localisation in the frontal lobes; plethora and edema of lungs. Pin-point hemorrhaging in the mucous membrane of stomach, small and large intestines and urine sphincter. Flethoric and degenerated conditions in the parenchymatous organs. Acute excess of blood in the medulla of the suprarenal glands.

Complications of infection: Caseous tuberculosis of the lymphatic glands, mesentery in the ileocecal region. Ascariidosis. Tuberculosis of the lymphatic glands of the right lung in the stage of incapsulation and calcification of the caseous mass.

As an example of the acute development of all the above symptoms of affection of the central brain, hypothalamous region, cortex and subcortex regions, and the abatement of these symptoms, we offer the following:

Z. 19 yrs. Became ill 8 Sep 46. Entered hospital 11 Sep, complained of headaches, weakness, inability to work, general body pains. Tem. 39.6, pulse 80, breathing 36. Light hyperemia of face and sclera. Hearttones muffled. Poor pupil reaction to light. Expressed rigidity of occipital muscle. Two-sided Kernig symptom, also Babinski and Oppenheimer. Sinevy reflexes poor. By evening he lost consciousness. Paresis of sphincters. Constantly moving body position.

12 Sep. Tem 39.7, pulse 68, pressure normal, unconsciousness.

Neurological status: Patient in severe condition; motive disturbances noted, light hyperemia of face and sclera, two-sided pthosis, more to left. Pendulum type eye-ball movement. Acute variations of muscle hypertonia. Acute rigidity of occipital muscle and two-sided Kernig symptom. Sinevy and parietal reflexes lowered. Kinetic paresis of the right facial nerve. An exacting neurological status report was not possible due to the severe condition of the patient.

13 Sep. Lumbar puncture, fluid is in droplets, 15 cm³ of fluid injected. Examined by oculist. Pappilla of the optical nerve, some hyperemia. Physiological excavation barely noted. Border of the pappilla acutely outlined. Hyperemia of vessels; retina not varied.

General condition severe.

14 Sep. Tem. 37.7-37, pulse 104, breathing 48. Two-sided pthosis, more to left. Pendulum movement of eyeballs. Anisocoria OD > OS. Obliteration of right-nasal-labial fold. Muscle hypertonia is less expressed

in the joints. Accoucher hand. Decerebration rigidity clearly expressed. Flexation of the upper and lower extremities vary, according to the position of the head. Clear spontaneous Babinski symptom of the left; on the left the Oppenheimer symptoms also. Sinewy and parietal reflexes live- higher on left. Red dermatographism. Dry rasping in the lower sections of the lungs.

15 Sep. Tem. 36-37.3. Near conscious; responds to questions, fixes attention on hammer, obeys requests- extends tongue, but not actively.

16 Sep. Tem. 37.5-37.6. Weak condition, swallows poorly, chokes. No rasping in the lungs, heart tones muffled.

17 Sep. Tem. 37.8. Severe condition, unconscious. Pulse 100, tense, breathing 34. Significant rigidity of occipital muscle, swallows very poorly, chokes. In the lungs there are dry and moist raspings in the lower sections. Heart tones are muffled. Lumbar puncture: Fluid transparent, flows slowly, in droplets. 10 cm³ of fluid drawn. After the puncture he became more active. Could lift head.

Data of liquid analysis: cytosis 1.5, albumen 0.3 o/oo, globuline reaction positive.

18 Sep. Tem 36.2-36.4. Regained consciousness; answers questions, offers hand, follows object with eyes. Anisocoria O S > OD. Sinewy and parietal reflexes live, even. Pathologic absent. Muscle strenght acutely weakened. Two-sided Kernig symptom and rigidity of occipital muscle. Pulse 78 with a temperature of 36.2. Lumbar puncture.

The patient recovered completely and felt good on release.

Conclusions

As the two cases indicate, in the symptomatic the dominating damage is to the regions of the central brain and hypothalamus. Among other

symptoms, the affection of the cortex and subcortex regions and lower segments of the stem of the brain play an important role. The reverse development of the symptoms, as in Patient Z, can be explained only by the leading appearance of one of the symptoms and its localization, first working on the endothelia, capillaries and precapillaries of the respective sections of brain; the high penetrability of the walls of the vessels and development of acute edema of certain regions of the brain along with all the excreted matter, disrupt the function of the respective section of brain.

If a constant battle is waged against brain edema and oxygen lack, if the heart and respiratory action is maintained, and also if use is made of anti-edema mediums (proserine) to improve conductivity of the impulses on the disrupted nerves, then, irregardless of the severity of the case, one can attain some progress in the abatement of the damage in the respective regions. Our problem was to point out the basic pathologo-physiological mechanism of development of the symptoms of affection of certain regions of the brain by virus of Japanese encephalitis.