

REPORT NUMBER 513

EMERGENCY DENTAL TREATMENTS BY MEDICAL OFFICERS  
ON ISOLATED DUTY

by

William R. Shiller  
Commander, DC, USN

Bureau of Medicine and Surgery, Navy Department  
Research Work Unit MR005.19-6024.01

Released by:

Gerald J. Duffner, CAPT MC USN  
COMMANDING OFFICER NSMC  
28 February 1968

APPROVED FOR PUBLIC  
RELEASE - DISTRIBUTION  
UNLIMITED

EMERGENCY DENTAL TREATMENTS BY MEDICAL OFFICERS  
ON ISOLATED DUTY

by




William R. Shiller  
Commander, DC, USN

Submarine Medical Research Laboratory  
U. S. NAVAL SUBMARINE MEDICAL CENTER REPORT NO. 513

Research Work Unit MR005.19-6024.01

Reviewed and Approved by:



Charles F. Gell, M.D., D.Sc.(Med)  
SCIENTIFIC DIRECTOR  
Submarine Medical Research Laboratory

Approved and Released by:



Gerald J. Duffner  
Captain, MC, U. S. Navy  
COMMANDING OFFICER

## **SUMMARY PAGE**

### **THE PROBLEM**

The incidence of dental problems on FBM patrols and in other isolated environments makes it necessary for the medical department representative to have some dental skills and some appropriately written manual to help him care for these dental emergencies.

### **FINDINGS**

A manual has been prepared which is the fruition of four years of teaching a course in the management of dental emergencies to prospective submarine medical officers. It gives some dental background, presents the most likely dental problems to be met, and outlines practical techniques for their management.

### **APPLICATION**

This manual should be of use in management of dental problems by a medical department representative attached to an isolated crew.

### **ADMINISTRATIVE INFORMATION**

This investigation was conducted as a part of Bureau of Medicine and Surgery Research Work Unit MR005.19-6024—Effect of Stresses of Submarine Service on Oral Health. This report is No. 1 on the Work Unit cited. Eleven previous reports have been published under Work Units MR005 12-5220.1 and MF022.03.03-9001. This report was approved for publication on 28 February 1968 and designated as Submarine Medical Research Report No. 513.

**PUBLISHED BY THE NAVAL SUBMARINE MEDICAL CENTER**

## **PREFACE**

The isolated nature of many present day military duties add to the need for versatility in medical officers. Often, the nature of the duties or the small size of the groups makes it impractical or even impossible to provide all of the specialized health care services, including dentistry, which are present at large installations. Probably the most prevalent ailments of man are dental caries and periodontal disease. Necessity, therefore, has forced the realization that certain dental treatments must be taught to physicians who are assigned duties with groups not having dental services available.

Modern dentistry is certainly a highly specialized art and science which takes years to master. While it is not intended that physicians ever replace the need for dentists, still it is recognized that the physician must master some dental skills in order to provide dental care for his patients when no other choice is open to him. It is to this purpose that this text is dedicated.

## **ACKNOWLEDGMENTS**

Grateful acknowledgment is expressed to Mr. John Verges for his valuable assistance with the photography and layouts; to Mr. Elwood Kinne who did much of the photographic work; to Mr. Pasquale Gentile for his fine drawings, and finally to Mrs. Helen Sobolewski who cheerfully typed the many revisions of this manual during the years of its development.

## TABLE OF CONTENTS

	Page
PREFACE	iii
CHAPTER	
1. INTRODUCTION TO DENTAL PROBLEMS	1
2. DENTAL ANATOMY AND PHYSIOLOGY	5
3. CARIOLOGY	11
4. ODONTALGIA (TOOTHACHE)	15
5. EMERGENCY PERIODONTAL TREATMENT	21
6. ORAL HYGIENE	27
7. DENTAL RECORDS	31
8. EXODONTIA (EXTRACTION OF TEETH)	37
9. ANESTHESIA	41
10. MATERIALS AND PRACTICAL TECHNIQUES FOR MANAGEMENT OF DENTAL EMERGENCIES	43

## CHAPTER 1

### INTRODUCTION TO DENTAL PROBLEMS

While it is recognized that dental problems will occur at times and in places where professional dental care is not available very few reports of prevalences of this problem are in the literature.

During World War II the submarine force had a number of dental problems occurring on patrol. There were no dentists or physicians aboard these submarines. The medical department representative was a hospital corpsman. More recent surveys of the conventional diesel powered submarine show the incidence of dental emergencies still of importance. Table 1 illustrates the frequency of occurrence of dental problems in conventional submarine crews. This table is taken from a report by Neilsen.

**Table 1 — Dental Emergencies Recorded Aboard 71 Submarines During the Period 1 June 1959 through 1 June 1960**

Toothache	280
Bleeding and Sore Gums	150
Pericoronitis	100
Post-Extraction Pain or Bleeding	51
Temporary Fillings	23
Fractured Teeth	19
Periapical Abscess	5
Fractured Jaw	1
Other	12
<b>TOTAL</b>	<b>641</b>

With the advent of the polaris submarine an additional interest in these dental problems was generated. A significant incidence of dental emergencies in these crews has been shown.

**Table 2 — Incidence of dental cases on 43 FBM Patrols (Shiller)**

Diagnosis	Incidence	Percent of total	Average per patrol
Toothache (Pulpitis)	9	7%	21
Periapical infection	10	8%	23
Fractured tooth	13	11%	30
Fractured filling or loss of filling	29	24%	67
Toothache of undetermined origin	8	7%	19
Simple gingivitis	13	11%	30
Vincent's infection (necrotizing ulcerative gingivitis)	2	2%	.05
Periodontal abscess	7	6%	16
Pericoronitis	24	20%	56
Other	5	4%	.12
<b>Total cases</b>	<b>120</b>		<b>2.79 (Range 0-7)</b>

Other isolated crews have had the same problem. The 1939 Byrd Expedition to the Antarctic had a physician, Dr. Russell G. Frazier, included in the party. Dr. Frazier reported that "the most usual and most painful malady encountered was toothache." He cited instances in which he was faced with treating rather severe dental emergencies. The post World War II Deep Freeze operations have encountered but few instances of dental problems. This has resulted largely from a dentist being assigned the responsibility of getting the mouths of Antarctic personnel in near perfect condition. There has also been a wintering-over dentist attached to the Antarctic Support Group since 1955. Dental problems still occur in outlying stations. During Deep Freeze '61

a medical officer at Pole Station had to extract twelve teeth for one man who was not dentally evaluated prior to wintering-over.

The problems, then, are still present. There will be times when many physicians will be faced with treating some dental problem. Certain medical officers, by virtue of their being assigned to groups in isolated circumstances will have much need for understanding the treatment of dental emergencies.

#### **Reasons for the occurrences of dental emergencies.**

When thinking of the reason for occurrence of emergencies, the first fact we are faced with is the magnitude of the dental disease prevalence. The average naval recruit has over 13 decayed, missing, or filled teeth, and the average increase in decay in this age group is two teeth per year. Thus, the mere universality of dental disease makes it unsurprising that emergencies occur.

The chronic nature of most dental diseases and the relatively low degree of pain in the early stages result too often in patient neglect in having dental needs met. This is the big immediate reason for dental emergencies in an isolated group. There is very little logical reason for Navy men not having their necessary work done. Human nature being what it is, however, and some patients' outlook toward dentistry being what it is, much of this work is not accomplished because of the patient's lack of interest or even his aversion to having dental work done. In the Navy, this is a very real problem. Even though regular examinations are accomplished and even though some work is done at the first appointment, we find too often that some men will miss a subsequent appointment and will be no longer in the category receiving dental treatment. These two reasons, magnitude of the workload and patient neglect, will account for most of the emergencies.

There is a third reason, however, which would give rise to some emergencies even if the other two were corrected. That is the

non-predictability of dental disease or treatment outcome. Dentistry is not an exact science and even with the most modern treatment available some of the teeth so treated will still give rise to dental problems. Attempts are constantly being made to refine diagnoses and treatment to ever higher levels but as long as there are teeth in the mouth there probably will occur some emergencies for some physicians to treat.

#### **The Medical Department's Role.**

When a physician is attached to a unit not having dental facilities available to it, he is the most logical individual to care for the crew's dental needs. In line with the current thinking in dentistry, as well as medicine, preventive measures should be foremost in his program for the dental care of his unit. This may be accomplished in several ways.

##### **1. Good oral hygiene.**

Many studies are available to show that good oral hygiene is directly related to good oral health. When one accepts the concept of dental caries and periodontal disease as being infectious diseases, the importance of hygiene becomes paramount in one's thinking. The facet of oral hygiene which would concern the physician most is effective tooth-brushing. Studies in the submarine service have shown that 42% of the operating submarine crewmen admit to brushing their teeth less than once a day routinely. This certainly leads to the conclusion that there is much room for improvement. This is an area in which the physician could do much, and it will be developed in a future chapter on oral hygiene.

##### **2. Good dietary practices.**

Some of the evidence of relationship of diet to dental disease is unclear and some is of an indirect nature. The evidence, however, certainly points to types of food and eating habits being related to dental caries. The relationship between a high and frequent intake of readily fermentable carbohydrates and dental caries has become quite clear. There is good evidence to support the view that a reduction in ingestion of readily fermentable carbohydrates and particularly

the reduction in the frequency of such ingestion, such as in between meal snacks, will result in an appreciable decrease in the dental decay rate. The relationship between diet and periodontal disease is not nearly as clear. Epidemiology studies by Russell and others have failed to demonstrate any clear cut relationship.

A rational approach to diet in relation to dental health would be that a well balanced diet containing all the essential nutritive elements eaten at regular meals and containing the least necessary amount of readily fermentable carbohydrates should be impressed upon any crew.

### 3. Role of fluorides.

Since the early 1930's the role of fluorides in prevention of dental decay has been investigated. Controlled application of fluorides to drinking water has resulted in an appreciable reduction in dental decay in the populations utilizing this water. Fairly recently it has been shown that the application of fluorides, topically, to already erupted teeth even in mature individuals can result in a lowered incidence to tooth decay. The U. S. Navy is actively embarked on a program of such topical application. The other military services have similar programs. It is not expected that the physician would ever be called upon to apply this fluoride himself; however, it is necessary that he understands the importance of it and that he cooperates with the program and encourages such applications for his men.

### 4. Regular examination and treatment of the crew.

This area of prevention is largely one of administration as far as the physician is concerned. The role of patient neglect in production of dental emergencies has already been discussed. In order that this does not create problems in the unit to which the physician is attached, it is necessary that he insure that each man has a regular dental checkup, the frequency of which depends upon the operational nature of his unit. For more isolated units an examination every six months is recommended. It cannot be overly stressed that examinations alone are not

sufficient. It is necessary that the physician oversee the complete dental treatment of his men. He must be aware of who is being treated and how much work remains to be done. He must insure that each man meet his dental appointments and gets all his needed dental work done. The number of men for which a large dental clinic is responsible makes it almost impossible for these dental activities to perform the detailed administrative program that has been just described. The physician and other medical representatives of small units must assume this responsibility.

After prevention, the other role of the Medical Department personnel in dental care is, of course, the treatment of emergencies which may arise. This will be the theme of most of the remainder of this text.

## Bibliography

1. Duff, I F Medical study of the experiences of submariner as recorded in 1,471 submarine patrol reports in World War II. Bureau of Medicine and Surgery Report P-1295, 1947.
2. Nielsen, A. G. Oral health problems of submarine personnel and suggested program for their management. SMRL Memo Rept 63-14, December 1963.
3. Shiller, W. R. Incidence of dental problems and their management on FBM submarine patrols. SMRL Memo Rept. 67-4, April 1967.
4. Frazier, R. G. Acclimatization and the effects of cold on the human body as observed at Little America III, on the United States Antarctic Service Expedition 1939-1941. Proc. Am. Phil. Soc 89 249-255, 1945
5. Allensworth, T N. Deep Freeze '61 dental officers report. SMRL Memo Rept. 65-5, February 1965.
6. Shiller, W. R. Oral health of operating conventional submarine crews. A cross-sectional survey. SMRL Memo Rept 66-10, April 1966.
7. Russell, A. L. Periodontal disease in well and malnourished populations Arch. Environ. Health 5:153-157, 1962.
8. Russell, A. L., Littleton, N. W., Leatherwood, E. C., Sydow, G. E. and Greene, J. C. Dental surveys in relation to nutrition. Pub. Health Repts. 75:717-723, 1960.
9. McClure, F. J. (Ed.). Fluoride drinking waters. Pub. Health Service Pub. No. 825, 1962.





## CHAPTER 2

### DENTAL ANATOMY AND PHYSIOLOGY

The structures to be understood in relation to dental problems may be grouped into three main categories: (1) The teeth themselves; (2) The supporting structures intimately associated with the teeth; and (3) The structures which are of interest by virtue of their proximity to or their physiological association with the teeth.

#### The Teeth

The morphology and relationships of the teeth show variations among types but the similarities are great enough to permit using the mandibular first molar as a representative tooth to study (Figs. 1, 2).

That portion of the tooth which protrudes into the mouth is the crown. Its greater width in comparison to the roots makes possible a close contact with the crowns of the adjacent teeth. The roots of the mandibular first molar are two in number. The bifurcation of the root system occurs some distance from the crown. Normally the entire root area is covered by the oral tissue, the limit of attachment being generally on a line corresponding to the constricted neck (cervix) of the tooth. The precise demarcating line between the crown and the root is known as the cervical line.

There are four morphological types of teeth in the human mouth; incisors, canines (cuspids), premolars (bicuspid) and molars. Function is closely associated with morphology. Thus, the knife like incisors are used to sever pieces of food and the broad multiple cusped molars are used to grind the food prior to swallowing.

The root forms of the teeth vary with the morphology types (Fig. 3). The incisors tend to have rather short, conical roots. The cuspids usually have extremely long single roots. The roots of premolars are generally short and are usually single with the exception of the maxillary first premolar which most often has two root tips of a rather delicate nature. The mandibular molars have two roots and the maxillary molars have

three resembling a tripod, two roots on the facial side and one on the lingual side. The maxillary and mandibular third molar teeth (wisdom teeth) show wide variations in crown and root structure. They may have one or many root tips.

The teeth are arranged in the form of arches in such a way that they are mutually dependent and functionally integrated. Each individual tooth depends for its stability upon the other teeth of the arch, particularly, those immediately adjacent to it. Thus, when one tooth is lost its neighbors tend to drift and the integrity of the arch is lost (Fig. 4). The teeth are functionally integrated to act as a single mastication or chewing unit. It is noteworthy, in this regard that in the normal mouth each of the premolar and molar teeth occludes with two teeth of the opposite arch. Thus, the forces of molar mastication are always distributed among at least three teeth.

#### Structures supporting the teeth.

The teeth are not held rigidly in place in the mandible and maxilla; but rather are suspended in a specialized type of bone, the alveolar processes, by a specialized ligament, the periodontal membrane (Fig. 5). The integrity of the periodontal membrane is of utmost importance because without it the tooth is lost. The gingiva (gum tissue) covers the bone and periodontal membrane, and forms a protective cuff around the necks of the teeth. In the average patient there is a sulcus of up to 2mm depth between the tooth and the gingival margin. This sulcus is the area in which disease of the supporting structures begins; and when its depth becomes over 2 mm, a pathological process is recognized. The architecture of the gingivae is such that under normal conditions the mouth tends to be self-cleansing. The areas between the teeth are of particular importance from the standpoint of cleanliness. In the normal mouth the gingivae completely fill these areas with the interdental papillae (Fig. 6).




Fig. 1. Mandibular first molar, facial view  
a. crown b. root c. cervical line

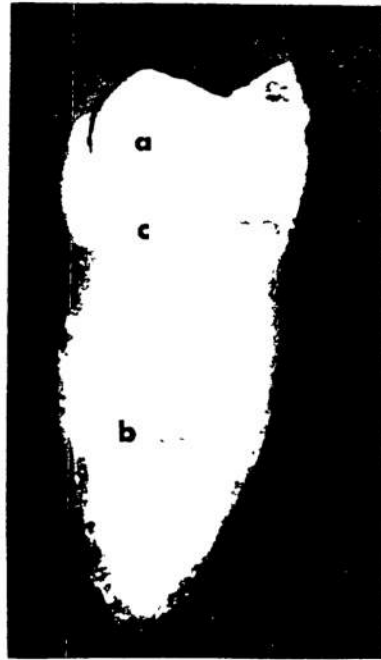


Fig. 2. Mandibular first molar, distal view.  
a. crown b. root c. cervical line

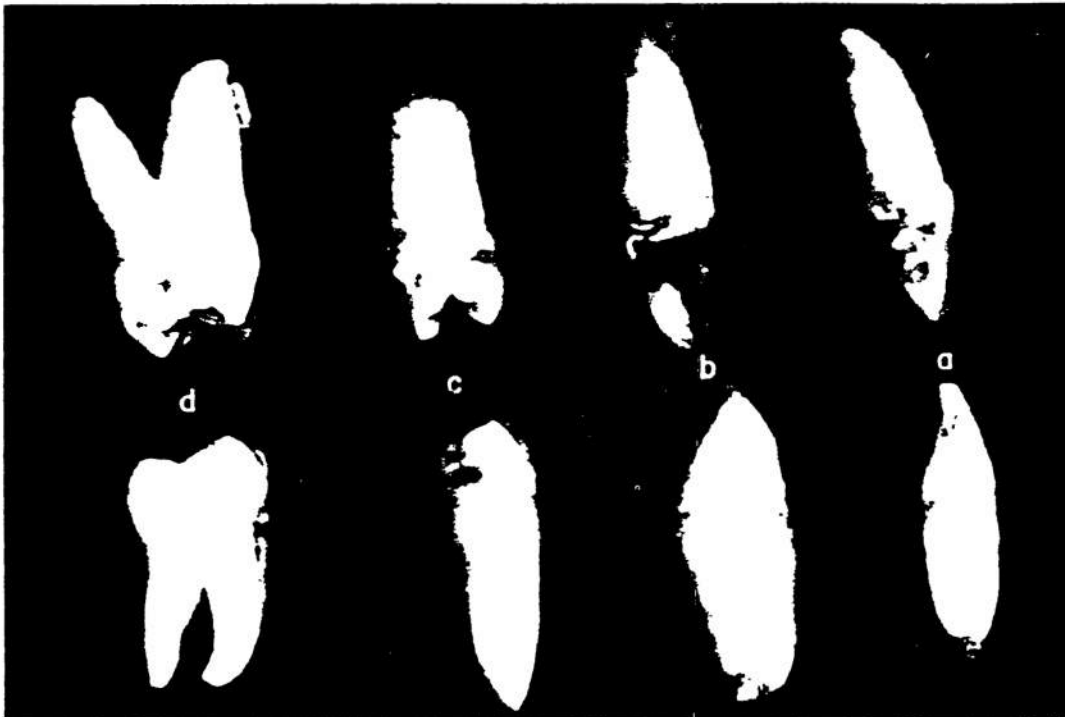

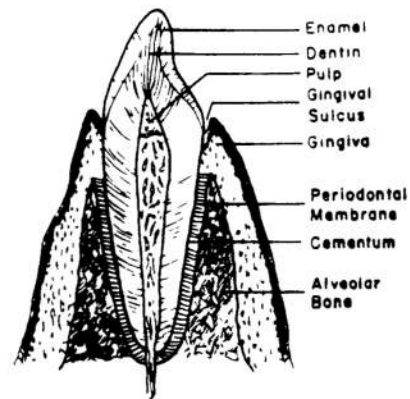
Fig. 3. Morphological types of teeth.  
a. incisors b. canines c. premolars d. molars



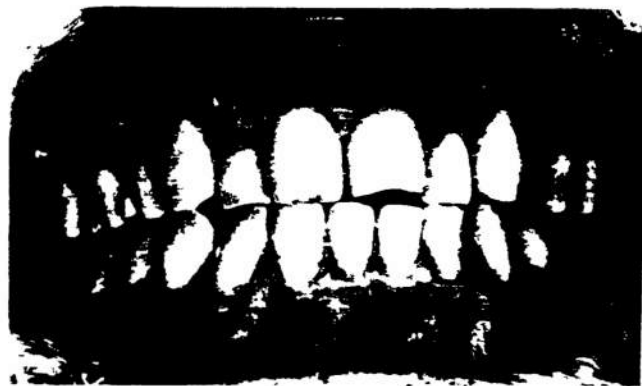**Fig. 4. Result of a missing tooth.**

- a. Second molar drifted mesially as a result of a missing first molar.
- b. Explorer in resulting hygiene problem area.

**DENTAL TISSUES**  
(diagrammatic representation)



**Fig. 5. Dental tissues.**



**Fig. 6. Normal mouth.**  
a. Interdental papilla.

### **Dental histology.**

In the dental structures, as in other areas of the body, dental histology, pathology and therapy are closely related. The teeth themselves contain four different tissues: enamel, dentin, cementum and the soft tissue of the pulp chamber and root canal (Fig. 5).

### **Enamel.**

The enamel is the hardest material in the body. It is composed of about 3% organic material, most of which is a keratin like protein. This is the organic matrix of the enamel. The remaining 97% is made up of mineral salts, primarily in apatite crystals. The formula  $\text{Ca}_{10}(\text{PO}_4)_6(\text{OH})_2$  is generally thought to represent the chemical proportions in the usual apatite crystal. Other elements and radicals, notably fluoride and carbonate, may be absorbed on the apatite crystals or may replace ions in the crystal itself. The solubility of the enamel is thought to be a function of the mineral present. The fluoride ion is of particular importance in this regard as its presence has been shown to reduce enamel solubility.

The enamel is made up of dense rods between which is an inter-prismatic substance of varying degrees of mineralization. The rods are directed, in general, at right angles to the dentino enamel junction. Even though the hardness of the rods is extremely great the enamel cleaves quite easily when it is not completely supported by underlying dentine. The enamel is thought to not possess any properties for healing. Changes do take place throughout life but these changes are of an inorganic nature consisting of replacement of ions and reorganization of the crystalline structure in the rods and inter-prismatic substance.

### **Cementum.**

Just as the enamel covers the crown of the tooth, so does the cementum cover the root portion. This covering is very thin. The cementum resembles cortical bone in chemical, anatomical and physiological properties. It is about 42% organic. The cementum reacts to injury and physiological stresses much as bone does. A healthy layer of

cementum is necessary for a normal attachment of the teeth in the alveolar bone.

### **Dentin.**

Dentin is somewhat more mineralized than bone, being about 28% organic. It is arranged in tubules much as the enamel is formed of rods. Within each tubule is found a cellular process, tomes fiber, which is an extension of the odontoblasts of the pulp. The odontoblasts are specialized mesenchymal cells lining the pulp chamber and are responsible for the laying down of the dentin matrix. Tomes fibers pass through the entire thickness of the dentin and impart the living quality to it.

The dentin reacts to injury in a limited manner. It is sensitive to manipulation and other stimuli even though only occasional nerve fibers are seen in it. It is believed that tomes fibers transmit the impulses to the pulp which contains many nerve fibers. Some injuries, including the carious process, may result in death of tomes fibers and an increase in the mineralization of the dentin beneath the injury.

### **Pulp tissue.**

The pulp chamber and root canal of the tooth is filled with connective tissue called the dental pulp. This tissue resembles connective tissue proper found elsewhere in the body, both in form and function. It differs from other connective tissue in its ability to lay down tooth substance. The ability is a characteristic of the odontoblasts which line the pulp chamber and root canal. Throughout the life of the tooth some additional dentin (secondary dentin) is formed and the amount is much increased in the presence of injury to the dentin. Thus, the pulp heals the tooth by forming additional thicknesses of hard tissue between itself and any noxious stimulus.

### **Periodontal membrane.**

The periodontal membrane is chiefly composed of collagenous, connective tissue fibers arranged in such a manner that the tooth is elastically suspended in its socket. Other elements in the periodontal membrane are blood vessels, nerves (both naked pain fibers

and proprioceptive endings) and epithelial remnants from stages of tooth development.

The periodontal membrane through its adaptive mechanisms makes possible the physiological movement of teeth during mastication and also enables orthodontic tooth movement to occur.

#### **Gingiva (gums).**

The gingivae, or gums, are the tissues firmly attached to the alveolar bone and to the teeth. There are many groups of oriented collagenous connective fibers in the gingivae. There is a specialized group of fibers which form a cuff like arrangement around the teeth to hold the gingivae snugly against the teeth. The gingivae are highly protective to the various tissue elements underlying them.

#### **The temporomandibular articulation**

This joint is a ginglymo-arthrodial articu-

lation and functionally it resembles the knee joint. It has two synovial cavities with an articular disc between them, thus permitting a sliding and a hinge movement simultaneously. A torsion movement is also possible.

It differs completely from other joints of the body in that the inclined planes of the teeth cusps determine the joint's movements when the mouth is being closed; and when the teeth are in full contact the cusps determine the positions of the mandibular condyles. The ligaments of the joint, therefore, must adapt to the dental mechanism.

#### **Bibliography**

1. Wheeler, R. C. A Textbook of Dental Anatomy and Physiology Saunders Co., Philadelphia, 1950.
2. Sicher, H. Oral Anatomy. Mosby Co., St. Louis, 1960.
3. Glickman, I. Clinical Periodontology Saunders Co., Philadelphia 1963.



## CHAPTER 3

### CARIOLOGY

The most common dental disease is dental caries. Man has recognized and written about this disease for many centuries. There are three main theories which have been or are held by dental scientists to explain dental caries.

#### **The proteolytic theory.**

This theory includes the concept that proteolytic bacteria liberate enzymes which destroy the tooth matrix, and that the resulting loss of support to the mineralized elements causes their loss and the formation of a cavity. This theory was particularly attractive to explain the progress of caries in the dentin of the tooth.

#### **The proteolysis-chelatin theory.**

This theory has recently received some interest among dental scientists. It includes the idea that destruction of the tooth may take place at a neutral or even a basic pH. As a result of this concept one may suppose that both destruction of the organic matrix or proteolysis and carrying away of the mineral substances of the enamel take place simultaneously. The destruction of the mineral material is explained by chelation or forming of complex salt combinations such as are formed when iron becomes combined with heme in hemoglobin. An example of the chelation process which may occur in the mouth is that of chelates of calcium formed with lactate.

#### **Acidogenic (chemo-parasitic) theory.**

This theory of dental caries with slight variations is the most widely held among dental scientists of today. It was proposed by W D Miller in 1882. It includes the idea that a bacterial plaque is present on the tooth surface. The bacteria by their metabolism liberate substances, chiefly acidic substances, which may act upon a susceptible tooth to dissolve the tooth substance and form a carious lesion.

All of the three theories of dental caries presuppose some form of bacterial infection. After having noted this, we may focus our attention on the acidogenic theory which is the one chiefly held at present. According

to this theory there are three conditions which must be present before dental caries can occur. There must be (1) a bacterial plaque upon the tooth surface with bacteria capable of causing the disease; (2) there must be nutrients or substrates which the bacteria require to produce the substances which cause the disease; and (3) there must be susceptible tissue, in this case dental enamel which may be acted upon by the materials liberated by the bacteria with the result that dental caries is formed.

Many interacting forces have been studied in relation to these three main factors of dental decay. The specific types of bacteria have been investigated for many years. At one time it was thought that lactobacillus acidophilus was the cause of dental decay. The chief reason for this assumption was that lactobacillus counts go up in the presence of carious lesions in the mouth and are largely absent when there is no caries. Lactobacillus counts are still used as good indications of caries activity; however, it is now felt that they may only occur concomitant with the other organisms that are chiefly responsible. Some of these other organisms are various species of acidogenic streptococci.

The components of the saliva have been studied intensively in relation to dental caries. There are some anti-bacterial factors in the saliva. The role of these, however, have not been clarified up to the present time. The one component which has been rather clearly delineated in regard to its caries relationship is the bicarbonate content of the saliva. Individuals with low caries activity tend to have higher bicarbonate concentrations than do those with high caries activity. The relationships are not absolute, however.

The types of diet in relation to caries have largely been concerned with the substrates needed by the bacterial plaque to produce the acids which dissolve the minerals of the enamel. Some work has been done with the trace elements of foods which may alter either the bacterial plaque or the surface en-



amel to resist decay process. The one area in which good agreement has been attained is the role of readily fermentable carbohydrates in dental caries. The simple sugars found in candies, certain desserts and other food of that nature have been strongly implicated as providing the rapidly metabolizable substrates for the bacterial plaque. It has been shown that when the easily fermentable carbohydrates are reduced in the diet, the acidogenic flora of the plaque is reduced to a level below that associated with dental decay.

The susceptibility of the host tissue to the disease of dental decay has also been studied extensively. The discovery of the role of fluoride in producing enamel which is resistant to decay was a great step in this field. The important action of fluoride in this respect is a reduction in the tooth enamel solubility. Contrarily, other studies have shown that an incorporation of carbonate in the enamel results in a more easily dissolved tooth substance and a higher caries attack rate. Other studies of mineral components have implicated other trace elements as anti-caries agents.

The gross morphology of the tooth has also been studied in relation to dental caries. Deep pits and fissures, excessively steep cusps and facial convexities have been positively related to dental caries rates. The mechanisms of these relationships are not completely clear but there may be more plaque retention in the areas of steep cusps, pits and fissures and great convexities.

When studying the actual morphology of the caries lesion we recognize two chief types—the smooth surface lesion and the pit or fissure lesion. These two types of carious lesions differ in their appearance and in the manner in which they attack the tooth substance. These differences are based upon the direction of the enamel rods and in the direction of the dentinal tubules in the area of attack. The pit and fissure lesion is characterized by a wider expansion of involved enamel beneath the surface than is apparent from the appearance on the surface (Figs. 7, 8). This is important in making a diagnosis. One must recognize that in pit and fissure areas a fairly small surface lesion can actually be a part of a very extensive subsurface lesion.

The smooth surface lesions contrarily most often spread more extensively on the outer surface of the enamel than on the deeper underlying surfaces (Figs. 9, 10). Thus, an apparently extensive smooth surface lesion often is not nearly as serious as a much smaller apparent pit and fissure lesion.

### Bibliography

1. Arnim, S. S and Sweet, A. P. S. Acid Production by Mouth Organisms. *Dent Radiography and Photography* 29:1-3, 1956
2. Goose, D. H and Hartles, R. L. Principles of Preventive Dentistry. MacMillan, New York, 1964
3. Sognnaes, R. F. (Ed.) Mechanisms of Hard Tissue Destruction. A. A. S., Washington, 1963
4. Staple, P. H. (Ed.) Advances in Oral Biology, Academic Press, New York, 1964



Fig. 7. Explorer inserted in a fissure cavity.



Fig. 8. Tooth of Fig. 7 split to show the extent of fissure caries.  
a. fissure b. enamel c. dentin  
d. pulp e. caries



Fig. 9. Explorer inserted in a smooth surface (interproximal) cavity.

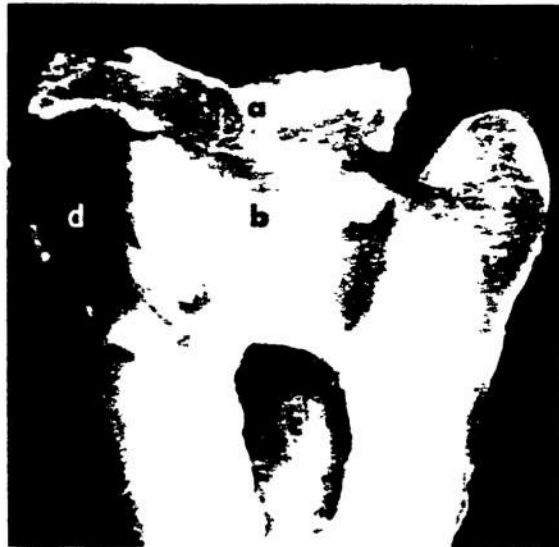

Fig. 10. Tooth of Fig. 9 split to show the extent of caries.  
a. enamel b. dentin c. pulp d. caries



## CHAPTER 4

### ODONTALGIA (TOOTHACHE)

The majority of instances in which a physician will be called upon to render dental treatment will be concerned with toothache. Pain will be a symptom of some degree in practically all of these cases. The source, the meaning, and the treatment of this pain is the purpose of this chapter. It is important to understand the anatomical and physiological basis to toothache. The nerve endings which are stimulated are found in the pulp of the tooth. This is the ultimate source of pain. The hard material of the tooth which protects the pulp is partly insensitive and partly sensitive. The enamel has no arrangement by which noxious stimuli to it can stimulate the nerve ending in the pulp. The dentin, however, can transmit stimuli to the pulp and cause pain. When considering toothaches we, therefore, are concerned with disease processes in the dentin and in the pulp.

There are conditions in which pain may occur without the presence of pulpal changes. In very early dental caries the ingestion of sweets may cause momentary pain without any real change in the pulp itself. The physician will very rarely be faced with this condition because the mildness of the symptoms will not prompt the patient to seek treatment. Usually, the toothaches brought to the physician's attention will be related to some pulpal changes.

The following is a listing of the pulp conditions in order of increasing severity with which the physician may be concerned:

#### **Hyperemia of the pulp or transitional stage.**

This is the mildest observable change in the pulp in which noxious stimuli have resulted in an adaptive change characterized by engorgement of blood vessels and extravasation of blood cells. If the noxious stimulus is removed this condition is reversible.

#### **Pulpitis without necrosis.**

This condition is characterized chiefly by a local round cell infiltration in an area of excessive stimulation of the pulp. This condition is also thought to be reversible.

#### **Pulpitis with partial necrosis.**

In this case the inflammatory condition is great enough to actually result in an area of necrosis of the pulp tissue. This area of destruction may be walled off by the remainder of the pulp. This condition in the adult is usually not considered reversible. In children, some of these pulps may be saved by partial pulp amputation.

#### **Chronic total pulpitis.**

The entire pulp is inflamed. There is an inflammatory cell infiltration throughout the pulp. These cases are irreversible.

#### **Total necrosis of the pulp.**

All the soft tissue elements have undergone necrotic change. The pulp chamber is filled with pus or tissue fluid and bacteria. If untreated, these pulp conditions may further lead to infectious processes around the roots of the teeth. These periapical pathological processes include cementitis, periapical granuloma, periapical cyst and periapical abscess.

Cementitis is an inflammation of the cementum and periodontal membrane.

Periapical granuloma is a condition in which the infectious process has spread into the periapical tissue and has destroyed bone but it is walled off from the remainder of the body by defense mechanisms of the tissue.

A periapical cyst results from an inflammatory reaction of epithelial cells which are present as remnants of tooth formation in the periodontal membrane. The cysts are usually formed as a result of long standing periapical granulomas.

A periapical abscess is characterized by an ascendancy of necrosis with pus formation over the repair process.

These periapical infections in turn may result in a fistula formation which will drain, most usually, into the oral cavity or they may result in a cellulitis which is much more serious and represents a diffuse infection of the soft tissues of the face. The type of se-

quela to periapical infections depends upon the infecting organisms and the ability of the tissues to localize the infection.

### Examination Factors

#### Dental history.

One of the first points to be ascertained in taking the history is that of former pain in the concerned tooth. This is extremely important in that teeth very rarely become inflamed to the point of being non-treatable at the time of the first pain episode. Knowing the character of the pain may be of some help in diagnosis. The only reaction possible in the dental pulp is pain; therefore, diagnostic characteristics of responses are largely absent. The effect of various agents on this pain, however, is very important. A history of pain being absent with hot or cold foods but being present when the teeth are occluded would be indicative of a periapical infection, for example. Pain that is only present as a response to sweets would be indicative of a carious involvement but with practically normal pulp tissue. Pain with hot or cold foods or drinks would be indicative of some sort of pulpitis.

It is also important to know the history of past work on the affected tooth. One source of this history is patient response. This, however, is not very reliable. The best source of this history is the recorded treatments in the Standard Form 603. The history of past work is important, for instance, to reveal the age of the restorations, the depth of the restoration, and whether or not the pulp was involved during treatment.

One very important factor in the examination is the examination of the X-rays which will be found in the patient's record. All Navy Dental Corps Type II examinations make use of two posterior bite-wing X-rays. These X-rays only include the crowns of the teeth but they can give a very good indication of the condition of the entire tooth if they are read with some insight. Thus, some teeth can be ruled out as offenders in any serious dental problem, if on viewing recent X-rays they are found to be free of any disease or deep restorations. Contrarily, suspicion will be directed to those teeth which in the X-rays appeared to have either extensive carious

lesions or extensive restorations which may have involved the pulp of the tooth.

#### Clinical examination.

After taking the history a visual examination is performed. It is important to have good light and it is advisable to have a mouth mirror and an explorer. All areas of the mouth should be visualized and carious lesions may be probed with the explorer. The entire mouth should be examined even though the patient can point out what to him is one particular offending tooth. After the initial overall look at the mouth then attention may be focused on the tooth pointed out by the patient. The examination should include an evaluation of the size and character of carious lesions, size and nature of existing restorations, and the condition of the soft tissue around the teeth.

#### Thermal tests.

Heat and cold stimuli have long been used as aids in the diagnosis of pulp conditions. The reaction will be interpreted by the patient as pain. The normal tooth will react and the pain will subside almost immediately when the stimulus is withdrawn. The diseased tooth will give an abnormal reaction; either there will be no reaction to heat or cold or the reaction will be exaggerated or sustained for some period after the stimulus is withdrawn. The use of heat presents somewhat of a problem, because under field conditions it is difficult for an inexperienced operator to control the amount of heat and direct it only to the tooth to be tested. In view of the equivocal nature of the responses elicited by heat, its use by physicians is to be discouraged under field conditions.

The use of cold as a stimulus is a much more usable and safe method in the hands of the physician. The cold stimulus may be in the form of an ice cube; one corner of which is held on the tooth to be tested until the patient expresses a response. The length of time for this response is noted. If there is no response to cold, this gives some indication that the tooth no longer contains any healthy pulp tissue and the prognosis is grave. If it does react to cold, and the pain subsides almost immediately when this stimulus is withdrawn, this indicates a healthy pulp and the

prognosis of this tooth is very good. When using thermal tests several teeth adjacent to the suspected one must be tested to obtain relative responses.

#### **Percussion.**

It is very important, if death of the pulp is suspected, that infection around the apex of the tooth be ruled out, for it is likely that the infection has extended from within the tooth to the surrounding structures. In this case, percussion is used as a diagnostic test. The best practice is to test all the teeth in one segment. For instance, in the lower left segment, start with either the first bicuspid and move posteriorly, or start with the third molar and move anteriorly. Give each tooth a couple light taps and ask the patient to respond when one tooth feels different from the others in the segment. This is a very good test to point suspicion to a tooth with a periapical infection.

#### **Practical diagnostic classification.**

There are many classifications of pulpitis. We recognize a simple hyperemic stage, chronic partial pulpitis without necrosis, chronic partial pulpitis with partial necrosis, chronic total pulpitis with partial necrosis, or finally total necrosis of the pulp. It is very difficult for the most experienced clinician to differentiate absolutely between these conditions when confronted with a patient complaining of pain. For this reason, a practical two category classification is used in this text: treatable (reversible) pulpitis or non-treatable (irreversible) pulpitis. Treatable pulpitis will refer to any condition up to chronic partial pulpitis without necrosis. A pulp condition of this severity or less may be expected to respond to conservative treatment; that is, treatment which involves retention of the pulp. Conditions more severe than this (as a general rule any pulpitis with necrosis) will probably be in the non-treatable or irreversible group and treatment will not result in the retention of the pulp. The pulp will either have to be extirpated or the tooth will have to be extracted. The matter of diagnosis, then, is important in assigning teeth to one of these two categories.

#### **Treatable (reversible) pulpitis.**

The history associated with this condition

may include presence of pain with sweets and/or intermittent pain with thermal stimuli. There may also be a history of recent restorative work on this tooth. A visual examination may disclose moderate to extensive caries or a deep recent restoration. Thermal tests will elicit sensitivity to cold. This sensitivity is usually of short duration. These teeth are usually not sensitive to percussion.

#### **Treatment.**

If it is decided that this is a treatable pulp (reversible pulpitis), simply excavate the lesion and insert a sedative filling of zinc oxide and eugenol.

#### **Non-treatable (irreversible) pulpitis.**

A history in this case usually includes previous episodes of pain. Hot or cold food may cause pain which persists in these teeth. Pain may be severe and throbbing in nature. A visual examination may reveal moderate to extensive caries. There may be an exposure of the pulp. There may be a deep restoration in the tooth.

A cold stimulus usually causes pain which is of marked duration. These teeth usually are not sensitive to percussion.

#### **Treatment.**

Excavate the caries and insert a sedative filling to try to maintain these teeth until they can be seen by a dental officer. If this treatment does not relieve the symptoms, the physician may open into the pulp chamber in order to establish drainage of the pulp contents. As a last resort, the physician may extract the tooth. It is to be noted that regardless of the diagnosis of pulpitis types it is desirable for the physician to try the most conservative treatment first. This is important for two reasons. The first is, that it is difficult even for an experienced dentist to be infallible in his diagnosis. It is, therefore, quite likely that a physician may mis-diagnose a dental case. The second reason is, that many irreversible pulpitis cases may be maintained if the lesion is excavated and a sedative filling inserted in the cavity. This treatment may suffice until a patient may be seen by a dentist and more expert treatment can be rendered.

### **Periapical infections.**

Cases of periapical infections usually have a history of past episodes of pain in the tooth. The patient complains that the tooth is sensitive when the teeth are occluded. This point should be clarified in the diagnosis of any dental case. The offending tooth can definitely be localized by the patient. This is not the case in toothaches arising from pulpitis. In other words, the patient can put his finger exactly on the offending tooth. The character of the pain is usually continuous, severe and throbbing. Visual examination will usually reveal extensive caries or an extensive restoration. Swelling of the soft tissue may be present in the area of the tooth. Thermal and percussion tests usually reveal that the tooth does not respond to cold stimuli and the tooth is sensitive to percussion. These cases are treated conservatively, if possible. Establishment of drainage is the primary treatment. This is accomplished by opening into the pulp chamber of the tooth and allowing the infectious material to drain through the opening. If this cannot be accomplished and the pain cannot be relieved, the physician may extract the tooth. If this is beyond the capability of the physician for any of several reasons, then the physician may administer broad spectrum antibiotics and analgesics to control the infection and pain.

### **Fractured crown.**

This is caused by trauma to the tooth. These cases are usually confined to the upper central incisor teeth. There are three categories in classifying fractures of the crown. It is important to recognize these categories from the standpoint of recommended treatment. If only the enamel is involved in the fracture, there usually is no great sensitivity and no treatment is required. If there is a dentinal involvement, there is usually marked sensitivity to the patient. In these cases, then, the crown must be covered for the patient's comfort. The third category is one in which the pulp is involved by the fracture. Upon examination actual pulp tissue can be observed. This type of injury results in a great amount of pain and requires placement of a dressing over the pulp. If available, a thin paste of calcium hydroxide is placed on

the pulp tissue and then a celluloid crown is cemented with zinc oxide and eugenol over this for protection. If this form of treatment does not take care of the pain, the pulp may be extirpated and the opening to the pulp chamber may be sealed with zinc oxide and eugenol placed over a sterile cotton pellet to avoid contamination of the pulp chamber with bacteria of the mouth. The celluloid crowns are cut to fit the individual teeth from stock crowns which are commercially available and are on the federal stock catalog. A thin mix of zinc oxide and eugenol is placed in the crown after it is cut to fit the tooth and the crown is slipped over the fractured tooth and the zinc oxide and eugenol is allowed to harden. These celluloid crowns provide excellent protection in such cases (See Chap. 10). If celluloid crowns are not available, a covering pack of zinc oxide and eugenol in which cotton fibers are embedded may be placed over the tooth (See Chap. 10).

### **Erosion.**

There is a type of dental pain not associated with caries which occasionally becomes severe enough to cause the patient to seek aid. The history in these cases reveals that pain occurs when brushing the teeth, when inspiring cold air and when eating or drinking cold food. The pain is of only a momentary duration. cursory examination reveals no apparent cause for this pain. Close examination around the necks of the teeth will reveal exposed dentin in these areas and the pain may be elicited by scraping and explorer point over these areas of erosion. If cold air is blown on these areas the intense momentary pain is elicited. The physician really has no means with which to treat these cases. The recommended treatment, therefore, is reassurance to the patient and advice to avoid cold stimuli as much as possible. It is important, then, to get the man to go to a dentist at the first opportunity.

### **High restoration.**

Occasionally, at the beginning of a period of isolation, a patient will complain of a sore tooth. The pain increases when the teeth are occluded. There is a history of a very recent restoration in the involved tooth. All other points of the history will be essentially normal. Examination will reveal a tooth that is

moderately tender to percussion. There is a new restoration present and close examination will reveal a shiny spot on the restoration. This is the area that has been left too high. The treatment merely consists of reducing the height of the restoration at the shiny spot.

#### **Restorations causing sensitivity to cold.**

The patient presents a history of sharp momentary pain when ingesting something cold. There is also a history of a recent metallic restoration being placed. Often this restoration will be found to have no insulating base beneath it. Examination will reveal a tooth that is sensitive to cold. The pain will be of momentary duration. A restoration is present and a record in the SF 603 may reveal no base having been placed beneath it. There is no treatment recommended except to advise avoidance of cold stimuli and reassure the patient that this usually subsides in a few days. The patient should be referred to a dental officer at the first opportunity.

#### **Tooth sensitive to sweets.**

These cases will present a history of sharp pain of moderate duration being caused after the ingestion of sweet foods. Examination will reveal the presence of a carious lesion or a "leaky" margin around a restoration. All other tests will be essentially negative. Treatment consists of avoidance of highly soluble sweets until the tooth can be restored. If desired, the physician may excavate the decay and a sedative filling may be inserted. Actually, this type case does not really present a classical dental emergency.

#### **Vague dull pain in maxillary posterior teeth.**

This vague dull pain may be relieved or intensified when occlusive pressure is applied. The patient will admit to a history of cold or sinusitis. Examination will reveal that pain cannot be well localized to one tooth. Several teeth may be slightly or moderately tender to percussion. Usually the nasal passages show evidence of congestion on the involved side and digital pressure over the facial aspect of the maxillary sinus may elicit the characteristic pain. These factors lead one to a diagnosis of maxillary sinusitis and the patient should be treated for maxillary sinusitis.

### **Bibliography**

1. Kerr, D A , Ash, M. M. and Mallard, H. D. *Oral Diagnosis*. Mosby, St. Louis, 1959.
2. McGehee, W. H. O , True, H A. and Inskip, E. F. *Operative Dentistry*. Blakiston, New York, 1956.
3. Seltzer, S., Bender, I. B. and Nazimov, H. *Differential Diagnosis of Pulp Conditions*. *J Oral Surg. Oral Med. and Oral Path.* 19 383-391, 1965.
4. Sommer, R F , Ostrander, F D. and Crowley, M. C. *Clinical Endodontics*. Saunders Co., Philadelphia, 1961.





## CHAPTER 5

### EMERGENCY PERIODONTAL TREATMENT

It is often stated that more teeth are lost because of periodontal disease than from dental caries. While the disease is most prevalent in older age groups it does occur at any age, including the rather young age groups that the military physician is called upon to treat. Periodontal disease in this discussion is restricted to the diseases which have their origin in the gingiva and which may affect the periodontal membrane and the bone.

Before considering pathological processes, it is well to review the normal periodontal tissue. The general architecture of the soft tissue under normal conditions is such that a self-cleansing effect is produced (Fig. 11). The interdental spaces are filled with tough tapered projections of the gingivae called interdental papillae. The gingiva near the tooth is firmly attached to the underlying bone thereby resisting excessive displacement when food is masticated. In the normal condition the gingiva or gum tissue is so arranged that it is closely adapted to the neck of the tooth. The connective tissue fibers within it provide resiliency necessary for this close adaptation to the tooth. There is a small space, the gingival sulcus (Fig. 12), between the marginal gingiva and the tooth which provides a site for bacteria, tissue fluid, etc. to collect. When only this area of the gingiva is inflamed, we may see clinically a reddened condition (marginal gingivitis). This is the most simple form of periodontal disease but it can and does often lead to other more serious forms. The tissue which actually holds the tooth in place is the periodontal membrane. It is made up of oriented connective tissue fibers which are attached from the alveolar bone to the cementum of the tooth. When these fibers are affected by periodontal disease a deepened crevice around the tooth results and a periodontal pocket is formed. Progression of this condition eventually leads to loss of the tooth. More acute phases of any of these conditions may result and require treatment.

#### **Gingivitis (simple).**

This is characterized by marginal inflammation of the gingiva (Fig. 13) and results

from the presence of bacteria in and around the gingival sulcus. Susceptibility to inflammatory processes caused by these bacteria may be different in different individuals and at different times. A systemic, particularly a hormonal, predisposing factor has been studied by several investigators. The role of the local irritants such as calculus and debris is fairly well accepted. The physician should chiefly be concerned with the local irritants and his principle treatment then would be improvement of the oral hygiene of the patient. Ordinarily, a simple gingivitis would not constitute an emergency situation for the physician, but in order to provide complete health service to his group and prevent more serious conditions from developing, these cases should be controlled.

#### **Necrotizing ulcerative gingivitis (Vincent's infection).**

Necrotizing ulcerative gingivitis is an acute type of gingivitis characterized by a predominance of necrosis. This infectious process has been written about for many years. Its high prevalence in the trenches in World War I resulted in its being called trench mouth. This term still persists to some extent.

The patient presents a history of bleeding gums, moderate pain, metallic taste in the mouth, excessive salivation and general malaise.

Examination of the patient reveals a crater-like ulcerative process destroying the interdental papillae (Fig. 14). These ulcerations are covered by a grayish pseudomembrane. The slightest manipulation of the tissue results in profuse bleeding. There is a characteristic fetid odor of the mouth and a low-grade fever may be present.

The etiology of this disease is not completely understood. Smears taken from the areas of ulceration will reveal a great number of spirochetes and fusiform bacilli. These are the predominating organisms and their great number is almost diagnostic. These organisms are found to some extent in the average mouth without infection being present. Vincent's infection has been considered con-

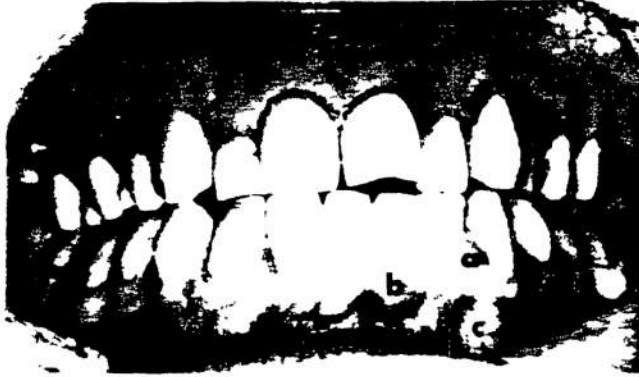

Fig. 11. Normal mouth.  
 a. Interdental papilla  
 b. Attached gingiva  
 c. Oral mucosa  
 d. Mucogingival line

DENTAL TISSUES  
 (diagrammatic representation)

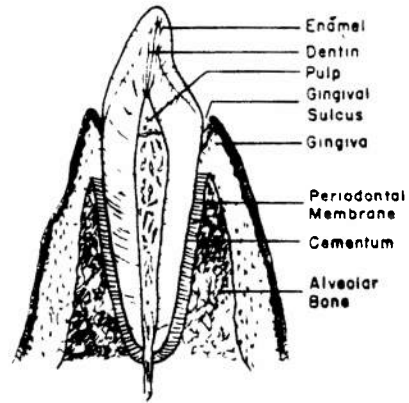


Fig. 12. Normal dental tissues.



Fig. 13. Marginal gingivitis.  
 a. Inflamed gingiva  
 b. Bacterial plaque



Fig. 14. Necrotizing Ulcerative Gingivitis  
 (Vincent's infection).  
 a. Cratered ulceration  
 b. Grayish pseudomembrane

tagious in the past. The predominant opinion now is that it is not contagious and the bacterial picture is of importance mainly as the most apparent factor in the disease. Predisposing or non-specific factors are of greater importance from the standpoint of control and treatment. These include: poor oral hygiene, fatigue, various stresses and local irritants.

The diagnosis of Vincent's infection is rather clear in the majority of cases. It may be confused with acute herpetic stomatitis which differs from Vincent's infection chiefly by not being confined to the interdental papillae in the early stages and by consisting of discreet lesions which may later coalesce. It may also be confused with erythema multiforme or Stevens-Johnson syndrome which again are not confined to the interdental papillae in the early stages and which exhibit characteristic skin lesions in addition to the oral lesions.

The treatment of Vincent's infection is usually rather simple and results, particularly in the younger patient's, in dramatic improvement. Often all that is necessary is to improve the oral hygiene of the individual either by more judicious use of the toothbrush or by forcible mouth rinses. In case the gingivae are extremely sensitive and brushing with a regular toothbrush is not possible, a very soft brush such as that recommended in the Bass system of toothbrushing may be used (See Chap. 6). Local oxidation treatment with 1½% hydrogen peroxide as a mouth wash may be used. The rationale behind this treatment is to provide an oxidizing atmosphere to the predominating anaerobic organisms. Another effect of the hydrogen peroxide probably of equal importance to the oxidation atmosphere is the cleansing effect that it has. The extreme foaming action tends to flush away the necrotic debris. In cases of extreme infection or in cases where control does not seem to be possible with the more conservative local treatment, systemic antibiotic therapy may be instituted. Penicillin and the tetracyclines have been widely used to control necrotizing ulcerative gingivitis.

Systemic factors have been closely related to Vincent's infection and an important part of the treatment is to build up the patient's

general resistance through good dietary habits and control of any other disease which may be present, and to relieve, if possible, the stresses which may be on the individual. It is necessary that the patient get enough rest. Even though the patient's disease may be well controlled by treatment, experience has shown that recurrence is likely. It is highly recommended that even the healed or cured patients be sent to a dentist at the earliest opportunity for complete oral health evaluation and hygiene instructions.

#### **Chronic periodontitis.**

The term chronic periodontitis is used to denote the cases of periodontal disease in which destruction of the periodontal membrane and the bone support have resulted in an increased depth to the crevice around the tooth with formation of a periodontal pocket (Fig. 15). Many of these cases are seen in the military population. The diagnosis is very easy in that the criterion used is the presence of a pocket around the tooth. A suitable instrument such as an explorer can be inserted into this pocket without difficulty (Fig. 16). It can readily be seen in these cases that cleansing of these areas is quite difficult for the patient, and these areas provide a continuous source of infection around the teeth. In the absence of acute infection these cases do not provide an emergency treatment situation; this does not mean that they are not of concern to the military physician or dentist. These cases should be referred to a dentist at the next opportunity so that they may be treated.

#### **Periodontal abscess.**

The periodontal abscess is an acute condition resulting usually from a long standing chronic periodontitis. Very briefly stated it is an acute infection of a periodontal pocket.

The patient will complain of moderate to severe pain, the pain usually increases when the teeth are occluded. He usually will admit to a history of gum trouble. There will usually be no history of sensitivity to sweets or to temperature changes.

Examination will disclose that the involved tooth can be well localized by the patient. The tooth will be moderately tender to percussion; it may be slightly or excessively loose; there

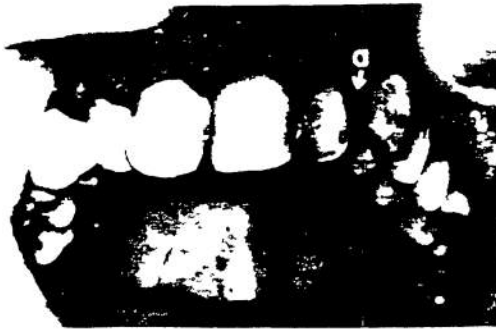


Fig. 15. Chronic periodontitis.  
a. Loss of interdental papilla.

PERIODONTAL ABSCESS  
(diagrammatic)

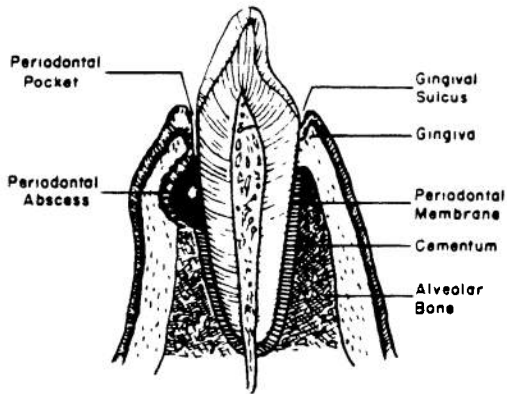
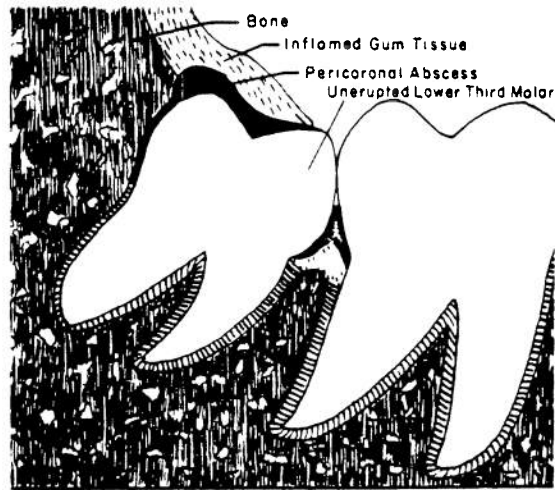


Fig. 17. Periodontal abscess.



Fig. 16. Chronic periodontitis.  
a periodontal pocket.  
a periodontal pocket.



PERICORONITIS

Fig. 18. Pericoronitis.

is usually some swelling of the soft tissue around the tooth. Roentgenograms in the dental record will reveal some loss of bone around the tooth. Most importantly, a periodontal pocket will be found around the tooth (Fig. 17).

The etiology is a bacterial infection in a periodontal pocket. The only condition which might be confused with a periodontal abscess is a periapical abscess. Differentiation is chiefly the fact that a periodontal pocket is present in the cases of periodontal abscess, and some carious process or result of caries is present in cases of periapical abscesses.

The treatment of a periodontal abscess is rather straightforward and chiefly consists of establishing drainage of the abscess. This usually can be accomplished through the periodontal pocket by inserting a suitable instrument such as an explorer or dressing pliers and widening the opening slightly. The pocket should be irrigated and an anti-septic may be instilled in the abscess area. The patient may be placed on hot saline rinses. An important part of the treatment is to instruct the patient in toothbrushing so that, if at all possible, the area of the pocket will be cleansed by inserting the bristles of the toothbrush into the pocket area.

#### **Pericoronitis.**

In the Navy, pericoronitis is largely restricted to the lower third molars. The condition is the result of an erupting tooth which is partially covered by gum tissue. An infection results from bacterial action beneath this tissue following food impaction or debris stagnation (Fig. 18).

The patient will complain of moderate pain, and because of the area involved there will be some trismus present in acute phases of the infection. Examination will reveal the presence of a partially erupted or impacted third molar (wisdom tooth) with inflamed tissue partially or totally covering the crown of the tooth.

The treatment is much the same as that for a periodontal abscess. Drainage is the chief factor in treatment. This may be accomplished by inserting a suitable instrument around the tooth to drain the abscess area. Daily irrigation may be accomplished

by using a blunt hypodermic needle with a hypodermic syringe. The patient will often be helped by using hot saline rinses. Do not attempt extraction of these teeth. It should never be necessary, and extraction in the face of the infection is contra-indicated. The high recurrence rate in these cases makes it highly advisable to have the patient report to a dental officer at the first opportunity for extraction or other treatment.

#### **Bibliography**

1. Colby, R A , Kerr, D A. and Robinson, H. B G Color Atlas of Oral Pathology. Lippincott, Philadelphia, 1961.
2. Glickman, I. Clinical Periodontology. Saunders Co., Philadelphia, 1963.



## CHAPTER 6

### ORAL HYGIENE

There are few, if any, instances of human societies regardless of how primitive that have not practiced some form of oral hygiene. All current theories of dental caries etiology and the prevalent idea of periodontal disease causes have as their basic premise bacterial action. The basic aim of oral hygiene, then, is to prevent disease, both dental caries and periodontal disease by removal of bacterial plaque and the remains of ingested food on the tooth. A secondary aim, but nonetheless one of great importance, is to improve the appearance and engender a feeling of pride and well-being in the individual. The bacterial masses with which we are concerned live and grow on the tooth within a covering of a mucoidal gel nature. The concern of oral hygiene techniques, then, is to remove or disturb this bacterial growth without causing injury to the hard or soft tissues of the mouth.

Various devices and procedures have been devised for accomplishing this.

**Toothbrush:** For general adult use, the straight trim, straight handle brush with a small head is desirable. The brushing surface dimension should be about one inch to one quarter inch long and  $\frac{5}{16}$ th to  $\frac{3}{8}$ ths inches wide (Fig. 19). Unfortunately, there is much difference in opinion among dentists and other workers in dental fields as to the desired stiffness of the bristle and as to the use of the brush in the mouth. The most uniformly accepted use is that of brushing down on the uppers and up on the lower teeth—"in the direction the teeth grow" (Figs. 20, 21). One method for use of the toothbrush which is gaining wider acceptance, at present, is that based on the Bass technique as also used by Arnim and others (Fig. 22). This technique employs a soft bristle brush with round ended bristles. It is designed in this way so that the bristles may be directed into the gingival sulcus around the teeth and the bacterial masses in these areas may be removed.

None of the toothbrushing techniques are very efficient in the cleansing of the contact areas between the teeth. For this reason the use of dental floss is recommended. Dental floss must be used judiciously, however, or

injury to the soft tissue may result. It is recommended that it be held firmly between two fingers and is guided rather than snapped through the contact areas of the teeth (Fig. 23). Each of the two adjacent surfaces are cleansed.

Many dentists now use a disclosing wafer for the patient to chew. The use of these allows the patient to see for himself areas that require further cleansing. The food dye in these will stain the bacterial plaques, and it is intended that the patient brush these deposits away (Figs. 24, 25). If he restrains after brushing and still finds some plaque, these should be removed also. This method of hygiene instruction is gaining wide acceptance in that it may be used with any toothbrushing method that the patient finds convenient for his own use, and it places emphasis upon the practical results of toothbrushing rather than the mere form. These wafers are available from several sources. Any physician interested in their use can get information from the dental clinic in the area in which he might be stationed.

One other group of devices used in oral hygiene requires some explanation. These are the water spray systems (Fig. 26). There are several of these available commercially. The reception of these devices by the dental profession has been mixed in regards to their use in routine hygiene. Their use in periodontal disease cases in which cleansing of periodontal pockets is a great problem has met with great enthusiasm by much of the dental profession. It is possible that physicians on isolated duty may find use for these water spray systems in the treatment of dental problems among their men.

One point cannot be too strongly emphasized. Men with clean mouths are less likely to become emergency dental patients than are those with debris laden mouths. A physician on isolated duty would be well advised to periodically examine his crew members and make certain that each man practices good oral hygiene. An effective hygiene program would certainly prevent most emergency periodontal problems.



### Bibliography

1. Arnim, S. S. The use of disclosing agents for measuring tooth cleanliness. *J. Period.* 34:227-245, 1963.
2. Emslie, R. D. The value of oral hygiene. *Brit. Dent. J.* 117 373-387, 1964.
3. Fosdick, L S Reduction of the incidence of dental caries. 1 Immediate toothbrushing with a neutral dentifrice. *J.A.D.A.* 40:133-143, 1950.
4. Goose, D. H. and Hartles, R. L. *Principles of Preventive Dentistry.* Pergamon Press, Oxford, 1964.
5. Krajewski, J. J., Giblin, J. and Gargiulo, A. W. Evaluation of a water pressure cleansing device as an adjunct to periodontal treatment. *Periodontics* 2:76-78, 1964.



Fig. 19. A satisfactory toothbrush.



Fig. 20. Brushing "up" on the lower teeth with a roll motion.



Fig. 21. Brushing "down" on the upper teeth with a roll motion.



Fig. 22. Bristles directed into the gingival sulci with the Bass brushing technique.

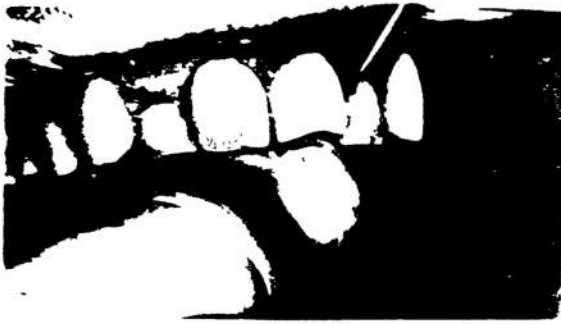

Fig. 23. Dental floss guided between the teeth to clean these surfaces.



Fig. 24. Teeth stained with a disclosing wafer.  
a. Stained bacterial plaque.



Fig. 25. Stain and plaque removed by thorough brushing and dental flossing.



Fig. 26. Tip of dental spray device directed to cleanse the gingival sulci.



## CHAPTER 7

### DENTAL RECORDS

A thorough knowledge of the type of dental records maintained on each Navy man is important to the medical officer for several reasons.

1. Records are necessary for proper diagnosis and treatment of the individual.

2. Records are used by the Navy to give an indication of Navy dental treatment needs. The statistics upon which Navy treatment programs are based are derived largely from the routine dental records.

3. Records are necessary for a complete preventive dentistry program both for the individual and for the group.

Actually, only one dental record is of importance to the physician. This is the Standard Form 603 which is contained in a Defense Department Form 722-1 (Dental Jacket). The 603 is a continuing dental case history for a man's entire naval career. The front part of this record is filled out when the man first enters the Navy. Pathological processes and dental characteristics are recorded along with the record of prior treatment. In item 4 is recorded the work that has been accomplished prior to entering in the Navy (Fig. 27). Item 5 contains the work which needs to be done. This front page is not changed during the entire time of the man's naval service. It, therefore, becomes a permanent record of the man's condition when he entered the Navy. The instructions for recording the conditions on the dental chart are contained in the Manual of the Medical Department, Article 6-117.

In Section I, Part 2, of the front page of the Form 603 is recorded the type of examination given this man. A type I examination is the ideal examination with full mouth X-rays plus additional X-rays as needed and a mouth mirror and explorer examination under good lighting conditions. A type 2 examination is one which utilizes only posterior bite-wing X-rays and a mouth mirror and explorer examination under good clinical light. A type 3 examination is one which utilizes no X-rays; only mouth mirror and explorer under good clinical light. Finally, type 4

examination utilizes the available light and mouth mirror and explorer examination.

Part 3 of Section 1 is the dental classification. This is an evaluation by the dental examiner of the urgency of the treatment needs of the patient. Class 1 denotes no work needed; class 2 denotes work needed but not of an immediate nature; class 3 denotes immediate work is needed; class 4 denotes prosthetic work is needed; and class 5 denotes an urgent or emergency condition is present.

Section 3 on the second page of the Form 603 consists of two parts; part 15 and part 16 (Fig. 28). In part 15 is recorded all of the work which is accomplished after a man enters the Navy. This becomes a permanent treatment chart; a record of the treatment rendered. Part 16 is the chart for recording diseases subsequent to the initial examination. The diseases or conditions requiring treatment are recorded in pencil. As they are accomplished they are then erased in part 16 and recorded in ink in part 15.

Part 17 is used for entering a written statement of the diagnosis and/or treatment for each visit by the patient to the dental officer or medical officer for dental problems. One item of great importance in part 17 is the class column. Each time the patient is treated or examined he is evaluated by the dentist and is given a classification as to needs for treatment. This can be of great help to a physician in planning treatment for his men while he is still near a dental activity. The abbreviations used in part 17 are standard abbreviations and are explained in the Manual of Medical Department, Article 6-115. As one 603 becomes filled, continuation forms, Standard Form 603-a (Fig. 29), are inserted in the dental jacket and on these the treatment records are continued.

The dental jacket, Form DD722-1, contains a coding system consisting of a piece of colored tape attached to it which denotes the treatment classification. The tape is changed by the dental officer each time the man's classification is changed. This enables anyone responsible for health care of a group

of men to see at a glance those men which are still in categories requiring treatment. A white tape denotes Class 1, or no treatment needed. A green tape denotes Class 2, or routine treatment required. A yellow tape denotes Class 3, or immediate treatment required. A blue tape denotes Class 4, or prosthetic treatment required, and a red tape denotes Class 5, or urgent or emergency treatment required. Using this system it becomes a rather simple matter for the medical officer to glance at his records and ensure that the men represented by red tabs, yellow tabs, and blue tabs are getting their treatment accomplished prior to deployment to an isolated environment. Of course, it is necessary for him periodically to review the other classes, for if a sufficient time elapses even a man represented by a white tab might require treatment.

#### **Use of the dental records by the physician.**

When a patient reports to a physician for emergency dental treatment the record and other material contained in the dental jacket becomes a very useful tool. The X-rays contained in the record should be viewed. The condition of the teeth at the last X-ray examination can be easily seen. In addition, the parts of the 603 in which treatment needs are recorded, primarily Part 5 of Section 1 and Part 16 of Section 3, should be looked at by the physician. The condition giving rise to the emergency may very likely be recorded on the 603. The next point to consider is Part 17 of Section 3. Prior diagnosis or prior treatment of the teeth or supporting structures involved may give a very good indication of the diagnosis of the present condition.

#### **Bibliography**

1. Manual of the Medical Department, U. S. Navy. NavMed P-117, Washington, 1952

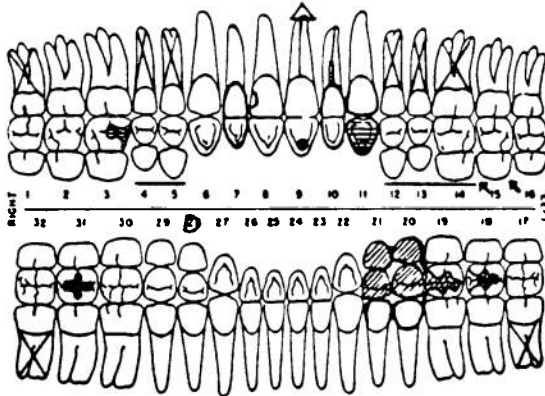
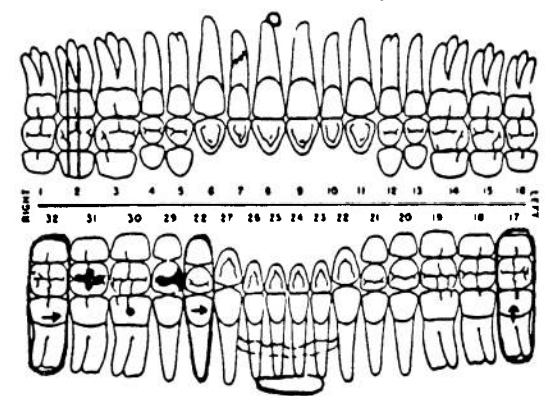
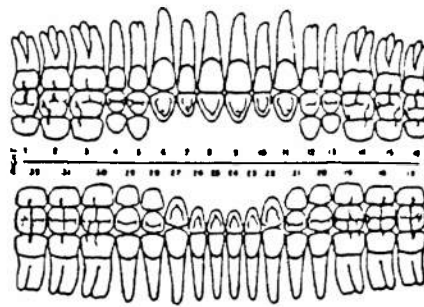
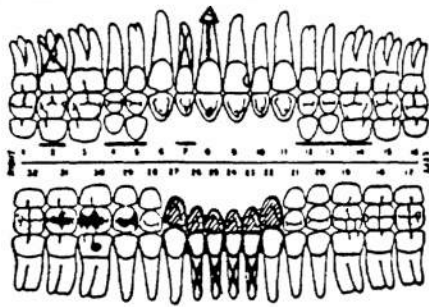
HEALTH RECORD				DENTAL										
<b>SECTION I DENTAL EXAMINATION</b>														
1. PURPOSE OF EXAMINATION						2. TYPE OF EXAM		3. DENTAL CLASSIFICATION						
<input checked="" type="checkbox"/> INITIAL	<input type="checkbox"/> SEPARATION	<input type="checkbox"/> OTHER (Specify)				<input checked="" type="checkbox"/> 1	<input type="checkbox"/> 2	<input type="checkbox"/> 3	<input type="checkbox"/> 4	<input type="checkbox"/> 1	<input type="checkbox"/> 2	<input type="checkbox"/> 3	<input checked="" type="checkbox"/> 4	<input type="checkbox"/> 5
4. MISSING TEETH AND EXISTING RESTORATIONS														
						REMARKS Cast Gold Pr. Dtr. with Porc. Teeth replacing 4, 5, 12, 13, & 14.								
5. DISEASES, ABNORMALITIES, AND X-RAYS						PLACE OF EXAMINATION NTC, Bainbridge, Md.			DATE 29 Aug 53					
						SIGNATURE OF DENTIST COMPLETING THIS SECTION W. T. Door, Captain, DC, USN								
C. STOMATITIS (Specify)						A. CALCULUS SLIGHT <input type="checkbox"/> MODERATE <input checked="" type="checkbox"/> HEAVY <input type="checkbox"/>								
D. DENTURES NEEDED (Include dentures needed after indicated attractions)						B. PERIODONTITIS LOCAL <input checked="" type="checkbox"/> GENERAL <input type="checkbox"/> INCIPIENT <input type="checkbox"/> MODERATE <input checked="" type="checkbox"/> SEVERE <input type="checkbox"/>								
E. INDICATE X-RAYS USED IN THIS EXAMINATION						GINGIVITIS <input type="checkbox"/> VINCENT'S <input type="checkbox"/>								
<input checked="" type="checkbox"/> FULL MOUTH PERIAPICAL <input checked="" type="checkbox"/> POSTERIOR BITE-WINGS <input type="checkbox"/> OTHER (Specify)						FULL <input type="checkbox"/> PARTIAL <input type="checkbox"/> U <input type="checkbox"/> L <input checked="" type="checkbox"/> U <input type="checkbox"/> L <input type="checkbox"/>								
DATE 29 Aug 53						ABNORMALITIES OF OCCLUSION—REMARKS 7, 8, 9, & 10 overbite approximately 10 mm.  7 overlaps 8 by 2 mm.  15 & 16 tilted mesially so only distal cusps in occlusion.								
PLACE OF EXAMINATION NTC, Bainbridge, Md.						SIGNATURE OF DENTIST COMPLETING THIS SECTION W. T. Door, Captain, DC, USN								
<b>SECTION II PATIENT DATA</b>														
6. SEX M		7. RACE CAU		8. GRADE, RATING, OR POSITION SR		9. ORGANIZATION UNIT		10. COMPONENT OR BRANCH		11. SERVICE, DEPT. OR AGENCY USN				
12. PATIENT'S LAST NAME—FIRST NAME—MIDDLE NAME DOE, John Joseph						13. DATE OF BIRTH (DAY—MONTH—YEAR) 1 Jun 38		14. IDENTIFICATION NO. 200 00 00						

Figure 27. Front of Standard Form 603.

SECTION III ATTENDANCE RECORD  
 16 RESTORATIONS AND TREATMENTS (Completed during service)      18 SUBSEQUENT DISEASES AND ABNORMALITIES



REMARKS

REMARKS

17 SERVICES RENDERED

DATE	DIAGNOSIS-TREATMENT	CLASS	OPERATOR AND DENTAL FACILITY	RITUALS
15SEP53	Vin. Tr.	5	W. J. ... NTC, Bainbridge, Md.	
29SEP53	Vin. Tr.	5	W. J. ... NTC, Bainbridge, Md.	
3SEP53	Vin. Tr.	3	W. J. ... NTC, Bainbridge, Md.	
4SEP53	30-F-ZnO.Eug. Sed., & Pro.	3	W. J. ... NTC, Bainbridge, Md.	
10SEP53	30-F-ZnO.Eug.R.-AM131-O-Cem.R.-AM.Anes.	3	W. J. ... NTC, Bainbridge, Md.	
15SEP53	29-MO-AM. Anes.	3	W. J. ... NTC, Bainbridge, Md.	
24SEP53	2-Ext. Anes.	3	W. J. ... NTC, Bainbridge, Md.	
25SEP53	2-P.O.T.	3	W. J. ... NTC, Bainbridge, Md.	
27SEP53	2-P.O.T.	3	W. J. ... NTC, Bainbridge, Md.	
29SEP53	2-P.O.T.	3	W. J. ... NTC, Bainbridge, Md.	
6OCT53	8-R.C. Tr.	3	W. J. ... NTC, Bainbridge, Md.	
17OCT53	8-R.C. Tr.	3	W. J. ... NTC, Bainbridge, Md.	
29OCT53	8-R.C.Fil.,AgPts. & Apcy. Anes.	3	W. J. ... NTC, Bainbridge, Md.	
26NOV53	7-Ext. Anes.	3	W. J. ... NTC, Bainbridge, Md.	
27NOV53	7-P.O.T., 8-I-Am	3	W. J. ... NTC, Bainbridge, Md.	
30NOV53	7-P.O.T.	3	W. J. ... NTC, Bainbridge, Md.	
10DEC53	2, 4, 5, 7, 12, 13, & 14-Max.Pr.Dtr.Ins.-			
	Patient declined old Pr,Dtr. Disposed			
	of according to current instructions	3	O.T. ... NTC, Bainbridge, Md.	
11DEC53	Max.Pr.Dtr.Adj.	3	O.T. ... NTC, Bainbridge, Md.	
16DEC53	Max.Pr.Dtr.Adj.	3	O.T. ... NTC, Bainbridge, Md.	
20JAN54	Abs., Inc.&Drn., Anterior Mand.Area Anes.			
	(Penicillin - 300,000 Units)	5	W. J. ... NTC, Bainbridge, Md.	
21JAN54	23to26-P,O,T.(Penicillin-300,000 Units)	5	W. J. ... NTC, Bainbridge, Md.	
22JAN54	23to26-P,O,T.(Penicillin-300,000 Units)	5	W. J. ... NTC, Bainbridge, Md.	
11FEB54	23, 24, 25, & 26-Surg.Ext., Alvy., Su., Anes.	5	W. J. ... NH, San Diego, Calif.	
12FEB54	23 to 26-P.O.T.	4	W. J. ... NH, San Diego, Calif.	
13FEB54	23 to 26-P.O.T.	4	W. J. ... NH, San Diego, Calif.	
15FEB54	23 to 26-P.O.T. Su. Removed	4	W. J. ... NH, San Diego, Calif.	
9MAR54	22, 23, 24, 25, 26, & 27-Max.Pr.Ins.	2	W. J. ... NH, San Diego, Calif.	
15JUN54	9-D-Cem.Sil. "Civ"	3	W. J. ... USS Coral Sea	
15JUN54	30-Do-Am "NDO"	2	W. J. ... USS Coral Sea	
15JUN54	17-Eruption noted	2	W. J. ... USS Coral Sea	
23JUN54	Sci., 17-Pecor. Tr.	2	W. J. ... USS Coral Sea	

PATIENT'S LAST NAME - FIRST NAME - MIDDLE NAME  
 DOB, John Joseph

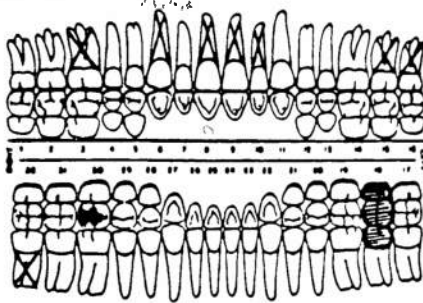
Figure 28. Back of Standard Form 603.

HEALTH RECORD

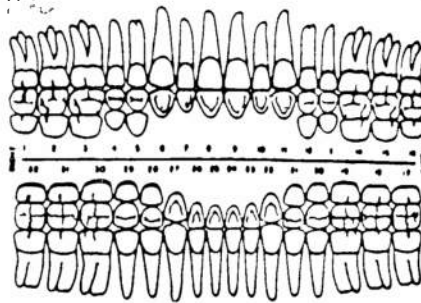
DENTAL—Continuation

SECTION III ATTENDANCE RECORD

16 RESTORATIONS AND TREATMENTS (Completed during service)



18 SUBSEQUENT DISEASES AND ABNORMALITIES



REMARKS

REMARKS

17 SERVICES RENDERED

DATE	DIAGNOSIS—TREATMENT	CLASS	OPERATOR AND DENTAL FACILITY	INITIALS
24JUN54	17-Pecor. Tr.	2	I. O. P. h. USS Coral Sea	
23AUG54	32-Surg. Ext., Su., Anes.	2	I. O. P. h. USS Coral Sea	
24AUG54	32-P.O.T.	2	I. O. P. h. USS Coral Sea	
27AUG54	32-P.O.T., Su. removed	1	I. O. P. h. USS Coral Sea	
25SEP54	32-Seq. removed	1	I. O. P. h. USS Coral Sea	
21SEP55	Exam (Type 2), 30 Red.Am.Overhang	1	I. O. P. h. USS Coral Sea	
24MAR57	Exam (Type 2)	4	G. J. [unclear] USS Coral Sea	
27MAR57	3-Ext. Anes.	4	G. J. [unclear] USS Coral Sea	
28MAR57	3-P.O.T.	4	G. J. [unclear] USS Coral Sea	
29MAR57	3-P.O.T.	4	G. J. [unclear] USS Coral Sea	
12APR57	15, 16-Ext. Anes.	4	G. J. [unclear] USS Coral Sea	
13APR57	15, 16-P.O.T.	4	G. J. [unclear] USS Coral Sea	
14APR57	15, 16-P.O.T.	4	G. J. [unclear] USS Coral Sea	
6JUL57	6,8,9,10, & 11-Surg. Ext., Su., Anes., Immediate Max.Dtr.Ine. (Patient accept- ed old partial)	2	G. J. [unclear] USS Coral Sea	
6JUL57	6,8,9,10, & 11-P.O.T., Max.Dtr.Adj.	2	G. J. [unclear] USS Coral Sea	
8JUL57	6,8,9,10, & 11-P.O.T., Su. Removed	1	G. J. [unclear] USS Coral Sea	
16APR59	Exam (Type 2)	2	R. O. Beck NH, St. Albans, N.Y.	
23APR59	30-DO-Cem.B.-Am., Anes.	2	R. O. Beck NH, St. Albans, N.Y.	
30APR59	18-Gold Cr.	2	R. O. Beck NH, St. Albans, N.Y.	
4MAY59	Rel. Max. Dtr.	1	R. O. Beck NH, St. Albans, N.Y.	
3MAR60	Exam (Type 2), 18 Recem. Cr.	1	R. O. Beck NH, St. Albans, N.Y.	

PATIENT'S LAST NAME FIRST NAME MIDDLE NAME

DOE, John Joseph

IDENTIFICATION NO

200 00 00

Figure 29. Continuation sheet, Standard Form 603-A.





## CHAPTER 8

### EXODONTIA (EXTRACTION OF TEETH)

It is hoped and expected that management of dental emergencies by medical officers will be predominantly conservative in nature. There may be occasions, however, when extraction of a tooth is the only course open to the medical officer in handling the dental problem. Some indications for extraction are: the presence of a periapical abscess when sufficient drainage cannot be established through the tooth; extensively fractured teeth; teeth with severe pulpitis and not enough crown remaining to retain a sedative filling; and teeth with severe pulpitis with intractable pain.

The great variability in teeth, patients and other factors makes it necessary to consider carefully each individual case before deciding to extract a tooth. Some factors to consider are:

1. Extraction by a medical officer should be resorted to only as an extreme measure after everything else has failed to control the dental emergency. Modern day dental procedures can often save teeth which any one but a dentist might think doomed to extraction.

2. The length of time remaining before a dental officer will be available should be considered. If this time is short, perhaps the patient can be carried on antibiotics and analgesics.

3. The expected root form of the tooth should be considered (Fig. 30). Thus, one would be unwise to elect a cuspid tooth which ordinarily has a large root. It should be realized that many variations may be present in root forms. Without the aid of good X-rays of the roots, extraction can become a tenuous proposition.

4. The bone in the areas of mandibular molars is very thick making these teeth quite difficult to extract. The differences in bone thickness in various areas of the mouth should be considered.

5. In the maxillary arch the close proximity of the maxillary molar roots to the maxillary sinus should be carefully considered so that the sinus will not become involved in the operation.

Extraction forceps are designed especially for use on each of the teeth. There are two universal forceps which may be used to extract any tooth in the mouth. These are forceps #150 and #151. It is recommended that a physician on isolated duty have at least these two forceps in his armamentarium. In addition to these, special forceps for special types of teeth may be desired. For the maxillary arch forceps #1 (Fig. 31) is used for the anterior teeth. Forceps #150 (Fig. 32) a universal forceps is very useful for the premolar and for the cuspid teeth. Forceps #53R and #53L (Fig. 33) are used for the maxillary molar teeth. For the mandibular teeth, the universal forceps #151 (Fig. 34) is used for the anterior teeth, the cuspid teeth, and the premolar teeth. Forceps #15 (Fig. 35) is used for the mandibular molar teeth. Forceps #16 (Fig. 36) is a specially shaped forceps which is used for mandibular molars which have well defined root bifurcations.

Forceps have one thing in common; they are designed to grasp the tooth below the enamel; that is, they actually are applied to the root portion of the tooth. They should have sharp, well shaped beaks so that they will not slip on the tooth.

In the actual extraction of the tooth there are certain basic procedures to avoid fracturing of the crown or root and to enable one to remove the tooth. The first step consists of preparing the tooth for application of the forceps. The attachment of the gingiva around the tooth is broken down to the level of the alveolar bone. This may be done with a periosteal elevator or, if none is available, with a curved curette or similar instrument. After the attachment of the gingivae is displaced from the tooth suitable forceps are placed with the beaks on the tooth. The ends of the beaks are guided toward the bone until they grip the root firmly. The beaks of the forceps are held in line with the long axis of the tooth. No slippage of the forceps on the tooth is tolerated. The forceps and the tooth become as one. Steady, controlled facial-lingual force is applied to the forceps,



Fig. 30. Various root forms to consider when electing to extract a tooth.



Fig. 31. Forceps #1 for maxillary incisors.



Fig. 32. Forceps #150, a universal forceps especially useful for maxillary canines and premolars.




Fig. 33. Forceps #53L for the maxillary left molar teeth.



Fig. 34. Forceps #151, a universal forceps especially useful for mandibular anterior and premolar teeth.



Fig. 35. Forceps #15 for mandibular molar teeth.



Fig. 36. Forceps #16 for mandibular molars.

and the tooth is loosened in the socket. When it is thought that the tooth is loose, it is delivered in the path of least resistance. This usually is to the facial aspect.

After the tooth is removed, the tooth and the socket are inspected. The tooth is inspected to see if all of it is present. The socket is cleaned and is inspected to see if any loose filling material or loose bone is present. If these are present, they are removed. A gauze 2 x 2 is folded and is placed over the socket. The patient is instructed to bite on this gauze and to hold pressure on it for approximately ten minutes at the end of which time he is to throw the gauze away. The patient is instructed to not forcibly rinse his mouth for the next 24 hours so that the blood clot is not disturbed.

It is highly recommended that any medical officer scheduled for deployment to isolated duty should visit a dental facility to observe dental operations. The practical techniques for extraction can best be learned by personal observation.

Several possible complications in the process of tooth extraction may occur. The most usual one is that the crown or the root may fracture. If this occurs and not enough tooth substance remains on which to apply the forceps, the physician is advised not to attempt any further work on this tooth. If a periapical abscess was the reason for the extraction attempt, the fracture of the crown may enable the physician to gain enough access to the abscess area through the root canal of the tooth. It is advisable to see if drainage of the abscess can be instituted in this manner. If this is not possible, the only recourse then will be to administer antibiotics and analgesics until the patient can be treated by a dentist and the remainder of the tooth removed. Another complication which is rather rare is fracture of large portions of the alveolar bone. This is not very serious except when it occurs at the floor of the maxillary sinus. In these cases, the wound should be disturbed as little as possible. Gauze packs are placed over the defect, and the patient should hold pressure on these attempting to have a clot form. The patient is very firmly instructed to not disturb this clot. He is also firmly instructed

to not blow his nose, since this might cause a permanent opening between the sinus and the oral cavity.

Several post-operative complications may occur in instances in which the physician performs the extraction, as well as, instances in which teeth are extracted just prior to deployment to isolated duty. In areas of the third molars some oozing of blood is expected up to a week after extraction. If the amount of hemorrhage is slight, the patient need only be reassured. If hemorrhage continues and the patient returns complaining of it, several methods of control are available. The first, and most simple, is to simply fold another gauze 2 x 2 place it over the socket and have the patient hold pressure on this again. This will often stop the hemorrhage. If this does not work, the next step is to remove the old blood clot which by this time acts as a foreign body in the socket. Inspect the socket carefully and if any loose bone is present, remove it. Loose bone or other foreign bodies are the cause of many cases of post-operative hemorrhage. After the socket is cleansed place another gauze pack over it and have the patient bite. Some cases can not be controlled even by this method. If gel foam or similar material is available this may be placed in the socket and a suture may be applied through the edges of the gingiva surrounding the socket to hold the gel foam in place. A gauze 2 x 2 is placed over this and pressure is applied. An alternate treatment is to apply a pack over the socket which has been soaked with tannic acid or with epinephrine 1:1000. This latter treatment should not be the one of choice but may be used in extreme instances to control the bleeding from the socket.

Another post-operative complication that may occur is alveolitis (dry socket). The diagnosis of alveolitis is extremely simple. The patient will complain of dull throbbing pain in the area of the recent extraction. Examination will reveal the absence of a clot in the socket. The bony walls of the socket are clearly visible. Treatment consists of irrigation with warm saline to remove all food particles and debris in the socket. Then an iodoform or plain gauze is packed into the socket to protect the walls. Several

drops of eugenol may be placed on this gauze to act as an obtundent. The dressing is changed and the socket is irrigated each day. Healing should take place in about one week. It is important to note that no attempt is made to reinstitute bleeding and attempt to have a clot reform in these cases.

#### **Bibliography**

1. Kruger, G. O. Textbook of Oral Surgery. Mosby, St. Louis, 1964.

## CHAPTER 9

### ANESTHESIA

Most of the treatment that a medical officer would render could be done very well without first obtaining anesthesia. In fact, in most instances the use of an anesthetic would be contra-indicated. For example, consider a large cavity being treated with a zinc-oxide and eugenol sedative filling. If an anesthetic is used the physician would have to wait until the anesthetic wore off to see if the sedative filling has eliminated the pain whereas without an anesthetic the pain relief can be seen almost instantaneously. It is anticipated that the physician will not often be manipulating really sensitive tooth structure, but will usually only be removing completely decayed material.

In cases where anesthetics are required, particularly in extractions, it is necessary that the physician have some acquaintance with the principles of all dental anesthesia. Any type syringe will be suitable for giving the injection. A carpule type is used by most dentists; however, a regular Luer-Lok syringe can be used. A 25 gauge stainless steel needle is desirable and it should be about one and a half inches long to be completely versatile. The anesthetic solution used by most dentists is lidocaine hydrochloride 2% with epinephrine 1:50,000 or 1:100,000.

The obtaining of anesthesia in the maxillary arch is rather simple in that infiltration anesthesia will suffice in practically all cases. This is the only type which will be discussed in this text. There are two landmarks to be concerned with in giving maxillary injections. One of these is the mucogingival line (Fig. 37). When the cheek is manipulated it is seen that the mucous membrane of the mouth is freely movable to a point a short distance from the neck of the tooth. This area which is not movable is termed the attached gingiva and contains many dense connective tissue fibers. An injection in this area would cause intense pain as the solution attempted to separate these fibers. The injection, therefore, is always given in the looser tissue above the mucogingival line.

The other landmark is the tooth itself which is intended to be anesthetized. The point of the needle is directed to an area at the apex of the root. When the needle rests against the bone in the area of the apex one half to one ml. of solution is injected slowly. If extraction is not contemplated, the injection need only be given on the facial aspect of the maxilla. If an extraction is required, the lingual mucosa must also be anesthetized. This is done in a manner similar to the injection on the facial; however, there is no loose tissue on the lingual aspect as is found on the facial aspect. For this reason a smaller amount of solution is injected and it is injected at a slower rate than on the facial aspect.

Infiltration anesthesia most often will not be effective in the mandibular arch because of the dense relatively non-porous nature of the mandibular bone. For this reason the inferior alveolar block is recommended and is most often necessary to anesthetize mandibular teeth.

The bony landmarks to consider for giving the inferior alveolar block are the anterior and posterior concavities of the mandibular ramus. An imaginary line is drawn connecting the points of greatest depths of these concavities, and the injection is given along this line (Fig. 38). The soft tissue landmark of note is the pterygomandibular raphe. The insertion of the needle is made just lateral to this band of tissue (Fig. 39). The needle is advanced until the point rests against the bone approximately midway between the two concavities of the ramus. About 1 ml. of solution is deposited at this point (Figs. 40, 41).

The prime reason for failing to obtain anesthesia with this injection is in injecting too low. It should be recognized that the broad area of insertion of the internal pterygoid muscle is just below the mandibular foramen. Injection in this area will result in immediate discomfort, prolonged trismus and absence of desired anesthesia.

If an extraction is not contemplated, the inferior alveolar block alone will suffice for

operations on a tooth on the side of injection. If an extraction is contemplated the lingual and facial mucosa must also be anesthetized. This may be accomplished by infiltrations much as in the maxilla.

### Bibliography

1. Sieher, H. Oral Anatomy. Mosby, St. Louis, 1960.
2. Manual of Local Anesthesia in General Dentistry. Cook-Waite Laboratories, Inc., New York, 1947.



Fig. 37. Infiltration anesthesia.  
a. Attached gingiva  
b. Oral mucosa  
c. Mucogingival line.



Fig. 38. Inferior alveolar nerve block, bony landmarks.  
a. Inferior alveolar nerve  
b. Anterior concavity of the ramus  
c. Posterior concavity of the ramus.



Fig. 39. Inferior alveolar nerve block, soft tissue landmarks.  
a. Pterygomandibular raphe  
b. Depression between raphe and the mandibular ramus.

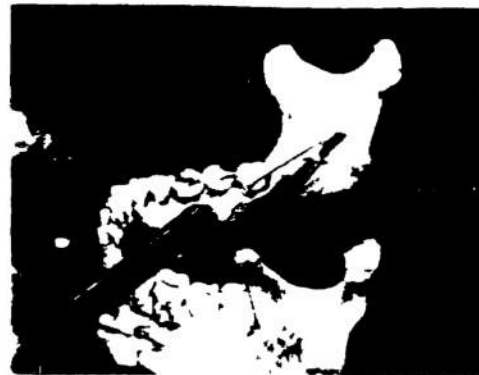

Fig. 40. Inferior alveolar block. Note the final position of syringe at about the opposite first molar.



Fig. 41. Inferior alveolar block.  
a. Pterygomandibular raphe  
b. Operator's thumb marking the greatest concavity of the anterior border of the mandibular ramus.

## CHAPTER 10

### MATERIALS AND PRACTICAL TECHNIQUES FOR MANAGEMENT OF DENTAL EMERGENCIES

It is expected that the medical officer on isolated duty will not have the ideal setup for treating dental cases. He will have to make do with the equipment ordinarily at hand plus a small armamentarium of selected dental instruments with which he has supplied himself prior to deployment to isolated duty.

It is recommended that the minimum supply of dental instruments and materials for physicians on isolated duty should include the following: mouth mirrors, explorers, dental dressing forceps, an air syringe, a set of Wedelstaedt chisels, a set of spoon excavators, a No. 2 Woodson plastic filling plugger, a cement mixing spatula, a supply of zinc oxide and eugenol, universal extraction forceps #150 and #151, and cotton roll holders. Several other items may be desired if the isolation is complete or of long duration, and transporting of supplies is not a problem. Additional special forceps for specific teeth may be desirable. Celluloid crowns for repairing fractured anterior teeth are very useful. These may be cemented in place to cover a fracture by filling the crown with zinc oxide and eugenol. Occasionally,

the use of a rotating cutting instrument may be required. If this is considered necessary, a bench type dental engine may be procured from any dental supply house. These are relatively inexpensive and will accommodate the regular navy stock dental handpiece for which burs such as AHP #37 and AHP #2 may be procured. It is recommended that if this setup is desired the advice and assistance of a dental officer be solicited prior to ordering this material.

The first consideration in treating a patient is to find a suitable chair or placement of the patient so that dental treatment may be rendered. It is highly unlikely that a headrest or chair with a headrest will be available. If one is available, the problem is solved; if not, a very satisfactory method is that of obtaining a regular office or ward-room type chair, backing it up to a desk and placing the patient's head upon a pillow on the desk (Fig. 42). The pillow can be folded to adjust the height of the patient's head. Many times depending on the type of operation and on the patient, no headrest need be provided. The usual position for right-handed people to work on patients is that of

#### Necessary Dental Supplies

Item	Federal Stock No.	Quality
Mirror, mouth examining	6520-541-8005	2
Handle, mouth examining mirror	6520-541-9350	2
Explorer, Dental #23	6520-528-1000	2
Excavator, Dental, Black #63	6520-536-3505	1
Excavator, Dental, Black #64	6520-536-3550	1
Forceps, Dental, Dressing #17	6520-542-7000	1
Syringe, Air, Dental	6520-501-8000	1
Chisel, Dental, Wedelstaedt #41	6520-515-1050	1
Chisel, Dental, Wedelstaedt #42	6520-515-1550	1
Plugger, Plastic filling, Woodson #2	6520-536-5405	1
Spatula, Dental, #324	6520-556-8000	1
Zinc oxide, 1 lb.	6505-150-1000	1
Eugenol, USP 1 oz.	6505-153-8379	1
Forceps, Tooth Extracting, #150	6520-532-3990	1
Forceps, Tooth Extracting #151	6520-532-4990	1
Holder, Cotton Roll, Right and Left	6520-616-9457	1 set



the right front or the right rear position. If the patient is placed correctly against a desk each of these positions becomes quite practical (Figs. 43, 44).

The light should be fairly easy to arrange; an electrical headlamp is available on the federal stock system and this works very well, particularly when the operator can stand in front of the patient. Most activities, regardless of the degree of isolation, have some arrangement for doing emergency surgery. This lighting arrangement will work very well for emergency dental procedures. It is necessary to make some arrangement for allowing the patient to expectorate during the operation. The Stevenson's resuscitator has an aspirator attachment; this works quite well in the hands of an assistant. If nothing else is available an emesis basin would be amply sufficient.

When working on a tooth it is necessary to isolate the tooth from the secretions of the mouth in order that the operation may be satisfactorily accomplished. This can easily be done by the use of cotton rolls or if these are not available by folding some 2 x 2 gauze squares. A set of cotton roll holders are very useful when working on the lower arch. There is a right and a left holder; these are on the federal stock table. A 2 x 2 gauze square may be rolled and this roll placed in each of two arms that is found on the cotton roll holder (Fig. 45). The holder is then placed in the mouth so that one piece of gauze is on either side of the posterior part of the mandibular arch. An extension fits beneath the chin and is tightened in place with a wing nut (Fig. 46). This holds the cotton roll holder in place. As an added advantage, the cotton roll holder keeps the tongue out of the field of operation. If these holders are not available, a piece of gauze held with the fingers on either side of the arch suffices (Fig. 47). When working on the maxillary arch it is only necessary to roll a piece of gauze and place it in the buccal vestibule so that it covers Stenson's ducts (the openings of the parotid salivary glands).

When using the cutting instruments, particularly the chisels, it is extremely important that the force with which these are

used be controlled at all times. To do this it is necessary that the physician practice the various grasps used in operating with these instruments. A rest is always used to control the force to prevent injury to the patient in the event that the instrument slips. The two most commonly used grasps with these instruments are the pen grasp and the palm and thumb grasp. With the pen grasp the instrument is held as a pen would be held and the third finger of the same hand is used as a rest for controlling the force (Fig. 48). With the palm and thumb grasp the instrument is held in the palm, and the thumb is used as a rest to control the force (Fig. 49).

It is well at this point to consider the steps in filling a tooth. After the patient has been seated and the light has been arranged, isolate the field with cotton rolls or gauze and complete the examination. If the lesion is not easily accessible, chisels may be used to remove the weakened enamel around the carious lesion (Fig. 50). The soft carious material is then excavated with the spoon excavators (Figs. 51, 52) and the cavity is cleansed and dried (Fig. 53). The zinc oxide and eugenol is mixed to a hard consistency so that it does not stick when manipulated (Figs. 54, 55), and is inserted into the cavity with the plastic filling plugger (Fig. 56). The patient is then asked to bite upon the filling so that it will not be left too high when it hardens. The filling is trimmed to the contour of the tooth (Fig. 57) and this marks its completion.

Another useful technique to consider is that for providing a covering for a fractured anterior tooth. If celluloid crown forms are available, the operation is greatly simplified. A crown form approximately the same size as the tooth is selected (Fig. 58). It is trimmed to the approximate contour and height of the gingival attachment and is tried on the tooth for proper fit (Figs. 59, 60). It is then filled with a thin mix of zinc oxide and eugenol and is placed on the tooth (Figs. 61, 62). The excess zinc oxide and eugenol paste is removed (Fig. 63).

If no celluloid crowns are available, a protective pack may be made by mixing cotton fibers in a zinc oxide and eugenol paste (Fig.

64). This paste is made to a very stiff consistency and is placed over several adjacent teeth in addition to the involved tooth (Fig. 65). The patient must be cautioned not to bite into food with these teeth.

#### Bibliography

1. McGehee, W. H. O., True, H. A. and Inskipp, E. F. Operative Dentistry. McGraw-Hill, New York, 1956.
2. Skinner, E. W. and Phillips, R. W. The Science of Dental Materials. Saunders Co, Philadelphia, 1963.



Fig. 42. Patient positioned with a pillow as a head rest.



Fig. 43. Right front operating position.



Fig. 44. Right rear operating position.

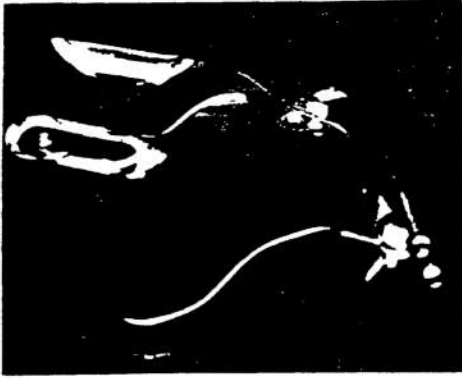


Fig. 45. Cotton roll holder, right.



Fig. 46. Left cotton roll holder in place.



Fig. 47. Field isolated with cotton rolls held in place by the operator's fingers.

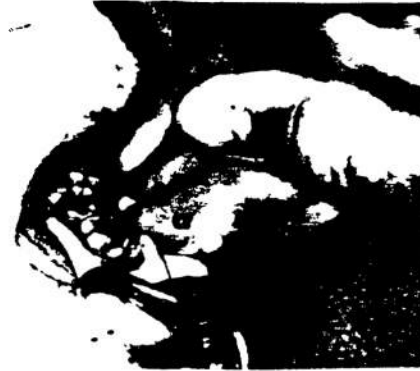

Fig. 48. Pen grasp.  
a. Third finger used as a rest to control the force.



Fig. 49. Palm and thumb grasp.  
a. Thumb used as a rest to control the force.



**Fig. 50.** Cleaving weakened enamel with a chisel.



**Fig. 51.** Removal of decay with a right excavator.



**Fig. 52.** Removal of decay with a left excavator.



**Fig. 53.** Soft decay removed from the cavity.




Fig. 54. Mixing of zinc oxide and eugenol.



Fig. 55. Proper consistency of zinc oxide and eugenol mix.



Fig. 56. Zinc oxide and eugenol inserted with a plugger.



Fig. 57. Completed temporary filling.

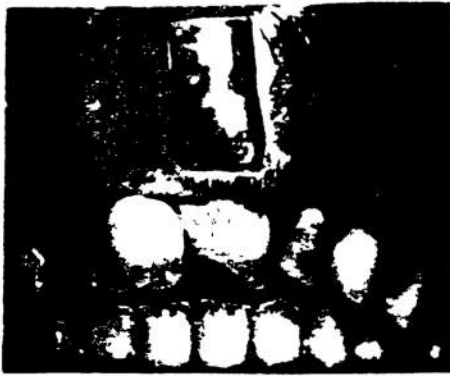


Fig. 58. Celluloid crown form selected for a fractured anterior tooth.




Fig. 59. Crown form trimmed to approximate size of the tooth crown.



Fig. 60. Crown form tried in the mouth for proper fit.



Fig. 61. Crown form fitted with a thin mix of zinc oxide and eugenol.

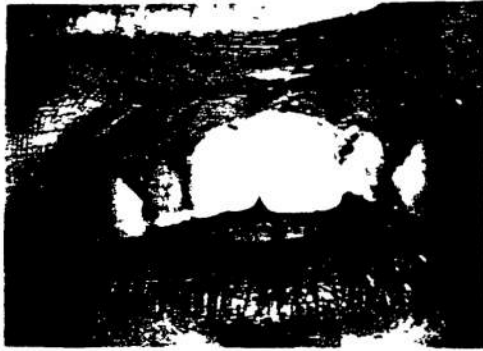

Fig. 62. Temporary crown pressed on the fractured tooth.



Fig. 63. Completed crown with excess zinc oxide and eugenol removed.



Fig. 64. Cotton fibers incorporated in a mix of zinc oxide and eugenol.



Fig. 65. Pack of zinc oxide and eugenol with cotton fibers protecting a fractured front tooth.

UNCLASSIFIED

Security Classification

DOCUMENT CONTROL DATA - R & D

*(Security classification of title, body of abstract and indexing annotation must be entered when the overall report is classified)*

1 ORIGINATING ACTIVITY (Corporate author) U.S. Naval Submarine Medical Center, Submarine Medical Research Laboratory	2a REPORT SECURITY CLASSIFICATION Unclassified
2b GROUP	

3 REPORT TITLE  
EMERGENCY DENTAL TREATMENTS BY MEDICAL OFFICERS ON ISOLATED DUTY

4 DESCRIPTIVE NOTES (Type of report and inclusive dates)  
Interim report on research work unit

5 AUTHOR(S) (First name, middle initial, last name)  
William R SHILLER, CDR, DC, USN

6 REPORT DATE 28 February 1968	7a TOTAL NO OF PAGES 65	7b NO OF REFS 33
-----------------------------------	----------------------------	---------------------

8a CONTRACT OR GRANT NO  b PROJECT NO MR005.19-6024.12 c d	9a ORIGINATOR'S REPORT NUMBER(S) SMRL Report No. 513
9b OTHER REPORT NO(S) (Any other numbers that may be assigned this report)	

10 DISTRIBUTION STATEMENT  
This document has been approved for public release and sale; its distribution is unlimited.

11 SUPPLEMENTARY NOTES	12 SPONSORING MILITARY ACTIVITY U.S. Naval Submarine Medical Center Box 600, Naval Submarine Base Groton, Conn. 06340
------------------------	--

13 ABSTRACT

Dental problems requiring treatment occur during Fleet Ballistic Missile submarine patrols with an average frequency of about three per patrol. There is no dental officer aboard. Therefore this manual "Emergency Dental Treatments by Medical Officers on Isolated Duty" has been written to assist the medical officer or hospital corpsman who must treat these cases.

UNCLASSIFIED

Security Classification

JND PPSO 13152



UNCLASSIFIED

Security Classification

14 KEY WORDS	LINK A		LINK B		LINK C	
	ROLE	WT	ROLE	WT	ROLE	WT
Emergency Dental Treatment Manual for Submarine Medical Personnel Dental problems occurring on isolated Naval duty; manual for treatment of						