

UNCLASSIFIED

AD NUMBER
ADB249656
NEW LIMITATION CHANGE
TO Approved for public release, distribution unlimited
FROM Distribution authorized to U.S. Gov't. agencies only; Proprietary Info.; May 99. Other requests shall be referred to U.S. Army Medical Research and Materiel Command, 504 Scott St., Fort Detrick, MD 21702-5012.
AUTHORITY
USAMRMC- Ft Detrick, MD, Ltr. dtd 24 Jul 2001.

THIS PAGE IS UNCLASSIFIED

AD _____

GRANT NUMBER DAMD17-96-1-6077

TITLE: Magnetic Resonance Spectroscopy: An Objective Modality
to Identify the Pathology of Breast Neoplasms

PRINCIPAL INVESTIGATOR: Carolyn Mountford, Ph.D.

CONTRACTING ORGANIZATION: University of Sydney,
Sydney, NSW, Australia 2006

REPORT DATE: May 1999

TYPE OF REPORT: Annual

PREPARED FOR: Commander
U.S. Army Medical Research and Materiel Command
Fort Detrick, Frederick, Maryland 21702-5012

DISTRIBUTION STATEMENT: Distribution authorized to U.S. Government
agencies only (proprietary information, May 99). Other requests
for this document shall be referred to U.S. Army Medical Research
and Materiel Command, 504 Scott Street, Fort Detrick, Maryland
21702-5012.

The views, opinions and/or findings contained in this report are
those of the author(s) and should not be construed as an official
Department of the Army position, policy or decision unless so
designated by other documentation.

DTIC QUALITY INSPECTED 4

19991208 166

NOTICE

USING GOVERNMENT DRAWINGS, SPECIFICATIONS, OR OTHER DATA INCLUDED IN THIS DOCUMENT FOR ANY PURPOSE OTHER THAN GOVERNMENT PROCUREMENT DOES NOT IN ANY WAY OBLIGATE THE U.S. GOVERNMENT. THE FACT THAT THE GOVERNMENT FORMULATED OR SUPPLIED THE DRAWINGS, SPECIFICATIONS, OR OTHER DATA DOES NOT LICENSE THE HOLDER OR ANY OTHER PERSON OR CORPORATION; OR CONVEY ANY RIGHTS OR PERMISSION TO MANUFACTURE, USE, OR SELL ANY PATENTED INVENTION THAT MAY RELATE TO THEM.

LIMITED RIGHTS LEGEND

Award Number: DAMD17-96-1-6077
Organization: University of Sydney

Those portions of the technical data contained in this report marked as limited rights data shall not, without the written permission of the above contractor, be (a) released or disclosed outside the government, (b) used by the Government for manufacture or, in the case of computer software documentation, for preparing the same or similar computer software, or (c) used by a party other than the Government, except that the Government may release or disclose technical data to persons outside the Government, or permit the use of technical data by such persons, if (i) such release, disclosure, or use is necessary for emergency repair or overhaul or (ii) is a release or disclosure of technical data (other than detailed manufacturing or process data) to, or use of such data by, a foreign government that is in the interest of the Government and is required for evaluational or informational purposes, provided in either case that such release, disclosure or use is made subject to a prohibition that the person to whom the data is released or disclosed may not further use, release or disclose such data, and the contractor or subcontractor or subcontractor asserting the restriction is notified of such release, disclosure or use. This legend, together with the indications of the portions of this data which are subject to such limitations, shall be included on any reproduction hereof which includes any part of the portions subject to such limitations.

THIS TECHNICAL REPORT HAS BEEN REVIEWED AND IS APPROVED FOR PUBLICATION.

_____ Almingtona Aleman 11/8/97

REPORT DOCUMENTATION PAGE

Form Approved
OMB No. 0704-0188

Public reporting burden for this collection of information is estimated to average 1 hour per response, including the time for reviewing instructions, searching existing data sources, gathering and maintaining the data needed, and completing and reviewing the collection of information. Send comments regarding this burden estimate or any other aspect of this collection of information, including suggestions for reducing this burden, to Washington Headquarters Services, Directorate for Information Operations and Reports, 1215 Jefferson Davis Highway, Suite 1204, Arlington, VA 22202-4302, and to the Office of Management and Budget, Paperwork Reduction Project (0704-0188), Washington, DC 20503.

1. AGENCY USE ONLY (Leave blank)		2. REPORT DATE May 1999	3. REPORT TYPE AND DATES COVERED Annual (29 Apr 98 - 28 Apr 99)	
4. TITLE AND SUBTITLE Magnetic Resonance Spectroscopy: An Objective Modality to Identify the Pathology of Breast Neoplasms			5. FUNDING NUMBERS DAMD17-96-1-6077	
6. AUTHOR(S) Carolyn Mountford, Ph.D.				
7. PERFORMING ORGANIZATION NAME(S) AND ADDRESS(ES) University of Sydney Sidney, NSW, Australia 2006			8. PERFORMING ORGANIZATION REPORT NUMBER	
9. SPONSORING/MONITORING AGENCY NAME(S) AND ADDRESS(ES) Commander U.S. Army Medical Research and Materiel Command Fort Detrick, Frederick, Maryland 21702-5012			10. SPONSORING/MONITORING AGENCY REPORT NUMBER	
11. SUPPLEMENTARY NOTES				
12a. DISTRIBUTION / AVAILABILITY STATEMENT Distribution authorized to U.S. Government agencies only (proprietary information, May 99). Other requests for this document shall be referred to U.S. Army Medical Research and Materiel Command, 504 Scott Street, Fort Detrick, Maryland 21702-5012.			12b. DISTRIBUTION CODE	
13. ABSTRACT (Maximum 200) Proton MRS on FNA distinguishes benign breast lesions from invasive cancer with a sensitivity and specificity of 95% and 96%, respectively. Carcinoma <i>in situ</i> specimens are ranked by proton MRS as benign or malignant. This ranking is not explained by standard histopathological criteria, suggesting MRS is reporting on differences which are not morphologically manifest. FNA MR spectra with signal to noise ratios (SNR)>25 are required to ensure a correlation of MRS and histopathological data with a high sensitivity and specificity when visual inspection methods alone are employed. Computerised Consensus Diagnosis (CCD), however, distinguishes benign and malignant lesions with high sensitivity and specificity for FNA spectra including those with SNR<25. CCD is also able to predict the presence or absence of vascular invasion and lymph node involvement for patients with invasive breast lesions. Two dimensional MRS fails to discriminate between breast tissues (due to large lipid contribution to the spectra) or breast FNAs (due to inadequate signal to noise). Proton MRS on FNA and Magic Angle Spinning (MAS) MRS detects metastatic disease in axillary lymph nodes from breast cancer patients.				
14. SUBJECT TERMS Breast Cancer			15. NUMBER OF PAGES 71	
			16. PRICE CODE	
17. SECURITY CLASSIFICATION OF REPORT Unclassified	18. SECURITY CLASSIFICATION OF THIS PAGE Unclassified	19. SECURITY CLASSIFICATION OF ABSTRACT Unclassified	20. LIMITATION OF ABSTRACT Limited	

FOREWORD

Opinions, interpretations, conclusions and recommendations are those of the author and are not necessarily endorsed by the U.S. Army.

___ Where copyrighted material is quoted, permission has been obtained to use such material.

___ Where material from documents designated for limited distribution is quoted, permission has been obtained to use the material.

___ Citations of commercial organizations and trade names in this report do not constitute an official Department of Army endorsement or approval of the products or services of these organizations.

___ In conducting research using animals, the investigator(s) adhered to the "Guide for the Care and Use of Laboratory Animals," prepared by the Committee on Care and use of Laboratory Animals of the Institute of Laboratory Resources, national Research Council (NIH Publication No. 86-23, Revised 1985).

For the protection of human subjects, the investigator(s) adhered to policies of applicable Federal Law 45 CFR 46.

___ In conducting research utilizing recombinant DNA technology, the investigator(s) adhered to current guidelines promulgated by the National Institutes of Health.

___ In the conduct of research utilizing recombinant DNA, the investigator(s) adhered to the NIH Guidelines for Research Involving Recombinant DNA Molecules.

___ In the conduct of research involving hazardous organisms, the investigator(s) adhered to the CDC-NIH Guide for Biosafety in Microbiological and Biomedical Laboratories.



PI - Signature

Date

TABLE OF CONTENTS

	Page
Standard Form 298.....	2
Foreword.....	3
Table of Contents.....	4
Introduction.....	6
Summary of Progress to April 1997.....	6
Summary of Progress April 1997 to April 1998.....	7
Summary of Progress April 1998 to April 1999.....	8
Body of Proposal.....	10
Purpose	10
Hypotheses	10
Expected Results	10
Research Plan and Progress to Date	11
A. Sample Preparation	11
B. Correlation with Histological Criteria	13
C. Can MRS redefine the Precursor States of Breast Neoplasia?	15
D. Can MRS identify Chemical Profiles Associated with a Predisposition to Breast Cancer?	17
E. Longitudinal Study	17
Methods	21
Selection of Patients	21
The Participating Surgeons	21
The Royal Adelaide Hospital	21
Westmead Hospital	22
Concord Hospital	23
Magnetic Resonance Spectroscopy	23
Sample Handling	23
Data Collection	24
Pulse Sequence	24
Processing of MRS Data	24
Mathematical Analysis of MR Data from the UNIX	25
Histopathology	26
Expertise of the Pathologists	26
Rationale for the extent of Histological Assessment	26
Tissue Preparation	26
Quantification of Cell Types	26
Statistical Analysis	27
Key Research Accomplishments.....	28
Reportable Outcomes.....	29
Conclusions.....	29
References.....	30

Progress Report April 29, 1998-April 28, 1999
DAMD17-96-1-6077

Appendix I: Acronym /Symbol Definition	Attached
Appendix II: Manuscript published in Radiology	Attached
Appendix III: Manuscript published in Australian and New Zealand Journal or Surgery	Attached
Appendix IV: Manuscript published in Life Sciences	Attached
Appendix V: Figures 1-13	Attached
Appendix VI: Tables 1- 4	Attached

INTRODUCTION

Recent improvement in breast cancer patient outcome is due to early diagnosis and effective management. The triage of mammography, clinical examination and fine needle aspiration biopsy is currently used to identify early breast cancers. Magnetic resonance imaging (MRI) has now been added to select women with breast abnormalities requiring biopsy. However, mammography and MRI are unable to distinguish cellular changes which correlate with the development of cancer and are unable to predict patient outcome. Fine needle aspiration cytology following mammography has reduced the incidence of unnecessary surgery but cannot predict at-risk status or tumour progression.

A new technology which could report on alterations to cellular chemistry and provide an adjunct to cytology would offer both independent and objective assessment of breast tissue. The potential then exists to identify an immediate or more distant predisposition towards breast cancer and thus screen, monitor and offer management protocols aimed at reducing tumour risk. Magnetic resonance spectroscopy offers this diagnostic modality and has been successfully developed to monitor tumour development and progression in other organs.

In the clinical situation where an established diagnosis of breast cancer has already been made, current predictors of patient outcome are of limited value. Despite methods of evaluation such as tumour typing and grading, surgico-histopathological staging, hormone and growth factor receptor status, genetic markers and ploidy, the reason for the variable clinical outcome in patients with established widespread metastatic disease remains unknown. The identification of biochemical markers both within primary and metastatic tumour deposits may be of great value in identifying patients who are likely to respond to specific therapeutic regimes.

This proposal is aimed at developing magnetic resonance spectroscopy to be used as an adjunct to diagnostic histopathology. The MRS method offers the possibility of earlier diagnosis of cellular abnormalities in predisposed women, a precise documentation of the biological abnormalities of the cells, conclusive predictive value, clear distinction between cellular atypia, progressive and non-progressive carcinoma *in situ* and invasive cancer and the potential to determine patient outcome. These advantages over current technology warrant the thorough investigation of the application of magnetic resonance spectroscopy to breast pathology.

SUMMARY OF PROGRESS to April 28, 1997

To the end of 1997 218 FNA have been obtained from patients undergoing breast surgery and analysed by proton MR spectroscopy at 360 MHz (8.5 Tesla) and results compared with histopathological analysis. The results of blinded MR analysis were compared with currently employed diagnostic approaches used in assessment of breast lesions. Invasive carcinoma was identified spectroscopically by an increased signal at 3.25 parts per million (ppm) attributable to choline-containing metabolites. Discrimination between invasive carcinoma (n=82) and normal or benign (n=106) or carcinoma *in situ* (n=17) was made based on the intensity of the 3.25 ppm resonance standardised to the resonance intensity at 3.05 ppm ($p < 0.0001$, Mann-Whitney U test). An MRS ratio of < 1.7 was recorded for 102 out of 106 normal or benign lesions. All carcinoma-*in-situ* samples with comedonecrosis or a microinvasive component (n=6) were ranked by MRS with invasive carcinoma while those with *in-situ* disease alone ranked with benign (n=11). The sensitivity and specificity of MRS on FNB for benign versus invasive breast cancer was 95% and 96% respectively

SUMMARY OF PROGRESS from April 29, 1997 to April 28, 1998

Publications:

1. Mackinnon WB, Barry PA, Malycha PL, Gillett DJ, Russell P, Lean, CL, Doran, ST, Barraclough BH, Bilous M, Mountford CE, FNB specimens of benign breast lesions distinguished from invasive cancer *ex vivo* with proton MRS, *Radiology*, 204:66, 1997.
2. Lo W, Lean CL, Dowd S, Malycha PL, Russell P and Mountford CE, Fine-needle biopsy of human lymph nodes. *Proc. Int. Soc. Mag. Res. Med.*, 1: 327, 1998.
3. Mountford CE, Breast Cancer and MRS, *Life Sciences*, Vol 10 (5) p 22, 1998.
4. Malycha PL and Mountford CE, *Australian Journal of Surgery*, In Press, 1998.

Experimental Progress:

Increase in Number of Breast FNA Biopsies

A further 68 FNA biopsies have been examined by 1 Dimensional MRS to determine the effect of A) storage time and B) method of collection (*ex vivo* or *in vivo*) on the MRS correlation with pathology.

A) Effect of Time Stored at -70°C

Experiments are underway to determine if time in storage at -70°C affects the MRS fingerprint in such a way as to invalidate the MRS correlation with pathology. Both benign and malignant specimens degrade in long term storage and this may result in the chemical markers becoming unreliable. Data shown in Figure 1 indicate that only specimens under six months are amenable to analysis.

B) Effect of Collection Method

Comparison of MR spectra of FNA biopsies obtained *in vivo* (prior to surgical excision) and *ex vivo* (following excision of the lesion) are underway (Figure 2). Preliminary data indicate that FNA obtained *in vivo* generate MR spectra equal in signal to noise and spectral resolution to *ex vivo* FNA spectra and thus amenable to visual and multivariate analysis. It has yet to be determined if the resonance ratio discriminating the two categories remains the same.

Multivariate Analysis of One Dimensional MR Data

Robust multivariate analysis has commenced in collaboration with the National Research Council of Canada. Initial classification of 55 benign and 69 malignant samples gave an accuracy of 90%. This will be improved by increasing the numbers in each pathology to at least 100 per class.

Two Dimensional (2D) MR Assessment of Breast Tissue and FNA Biopsies

Two dimensional (2D) Correlated Spectroscopy (COSY) has been successfully undertaken on intact breast tissues and FNA. Representative COSY spectra of lesions of malignant, ductal carcinoma *in situ* and benign pathologies are shown in Figure 3A, 3B and 3C, respectively. The COSY spectrum of an FNA from a malignant lesion is shown in Figure 4. The majority of crosspeaks assigned in adenocarcinoma from other organs have been identified in the spectra of adenocarcinoma of the breast (Table 1) including those from lipid, cellular metabolites and cell surface fucose (Figure 5). Data collection has now commenced.

FNA of lymph nodes from breast cancer patients and control subjects

The FNA technique has been extended to include biopsies from the axillary lymph nodes of breast cancer patients. Representative 1D MR spectra of tissue and FNA specimens of axillary nodes are shown in Figure 6. The signal to noise and spectral resolution of the FNA spectrum is adequate to allow visual and multivariate analysis of the data. Data collection has now commenced.

New Collaborations on MRS /FNA breast study

A collaborative program has been established between the Karolinska Institute in Sweden and the IMRR.

The Karolinska Institute will carry out an independent study.

Surgical students now being trained on this program

The IMRR is now training surgeons on this project under the Australian NH&MRC Clinical Centres of Excellence award.

SUMMARY OF PROGRESS from April 29, 1998 to April 28, 1999

Publications:

1. Mountford CE, Breast Cancer and MRS, *Life Sciences*, 10 (5), 22, 1998.
2. Malycha PL and Mountford CE, Magnetic Resonance Spectroscopy and Breast Cancer. *Australian and New Zealand Journal of Surgery*, 68, 859, 1998.
3. Himmelreich U, Mackinnon WB, Barry P, Russell P, Neilson G and Mountford CE. Proton MR for Pathological Cancer Diagnosis in Fine Needle Biopsy Specimen of Breast Cancer Lesions. *Proc. Int. Soc. Magn. Res.*, 788-789, 1998.
4. Lo W, Dowd S, Malycha P, Russell P, Mountford CE and Lean CL, Detection of Metastases in Lymph Nodes of Breast Cancer Patients Using Proton Magic Angle Spinning (MAS) MRS. *Proc. Int. Soc. Mag. Res. Med.*, 1: 451, 1999.

Experimental Progress

Increase in Number of Breast FNA Biopsies

A further 129 FNA biopsies were collected by participating surgeons during 1998/1999. Sixty of these specimens were deemed unsuitable for analysis due to having thawed during transport to the MRS facility (a result of incorrect handling by couriers). Of the 69 remaining FNAs, 45 were analysed using the standard one Dimensional MRS protocol (Figure 7A) and 24 were analysed using a newly developed automated MRS protocol (Figure 7B) in preparation for transfer of this technology to the clinical setting. The automation protocol is outlined in Figure 8.

Ductal Carcinoma *In Situ* Specimens.

MRS FNA data from an additional 6 ductal carcinoma *in situ* specimens were obtained and correlated with the step serial section histopathological data from the tissue surrounding the FNA site. By MRS criteria, 3 of these DCIS specimens were benign and 3 were malignant (Figure 7A). No standard histological features, including comedonecrosis or microinvasion, confirmed the MR diagnosis. However, of the three carcinoma *in situ* specimens ranked as malignant, two were obtained from re excisions from women with previous breast cancers. One of these women had nodal metastases present at the time of re excision. Confirmation of the MR diagnosis requires follow up of these patients and correlation with clinical outcomes.

Multivariate Analysis of One Dimensional MR Data

Analysis of FNA MR spectra by visual inspection distinguishes between malignant and benign pathologies with a high sensitivity and specificity only when the signal to noise ratio (SNR) of the spectra exceeds 25 (Figure 9).

Computerised consensus diagnosis (CCD), overcomes this limitation, successfully distinguishing malignant and benign pathologies, irrespective of SNR (Table 2). Computerised consensus diagnosis also predicts the presence or absence of (A) vascular invasion and (B) lymph node involvement with high degrees of sensitivity and specificity (Table 2).

FNA specimens analysed by MRS were deemed unsuitable for multivariate analysis if the spectra displayed incomplete suppression of the resonance from residual water or the presence of contaminant peaks. The problem of inadequate water suppression has now been overcome with the refinement and successful application of a new MR pulse sequence (Figure 10).

Two Dimensional (2D) MR Assessment of Breast Tissue and FNA Biopsies

Two dimensional (2D) COSY MRS was unable to discriminate between breast tissues of varying pathologies due to large contributions from lipid in most spectra which prevent metabolites present in lower concentrations being recorded (Table 3). 2D COSY (NS=48, NE=200, 4h experimental time) also fails to discriminate FNA specimens of varying pathologies due to inadequate signal to noise in the majority of spectra (Table 4). We are now investigating whether by increasing the number of accumulations acquired in each experiment (NS=192, 12h experiment time) the problem of inadequate signal to noise in FNA spectra can be overcome. A new MR technique, magic angle spinning (MAS), is also under investigation as a means of obtaining increased chemical information from intact breast tissue.

Assessment of Lymph Nodes from Breast Cancer patients and control subjects

MRS on FNA (n=15) discriminates between malignant and reactive nodes based on the ratio of intensities of resonances at 0.89ppm and 0.90ppm (resolved in spectra following resolution enhancement using a Gaussian-Lorentzian transformation, GB=0.08, LB=-7.0) plotted against the ratio of intensities of resonances at 3.2ppm and 0.9ppm (Figure 11). The discriminant capacity of MRS for detecting metastatic disease in human lymph nodes is supported by the MAS MRS data from intact lymph node tissues (n=17) shown in Figures 12 and 13. Malignant nodes were distinguished from reactive nodes based on the peak height ratio of the smallest to largest peaks resolved in the 0.9 ppm resonance multiplied by the peak height ratio of the choline and creatine resonances at 3.2 and 3.0ppm, respectively (Figure 13). Three of four axillary nodes, from breast cancer patients, which were clinically suspicious but diagnosed cancer free on routine histopathology had an MAS MRS ratio consistent with reactive nodes. The fourth node in this category was by MAS MRS criteria, malignant.

Surgeons being trained on this program

Dr Laurence Gluch, a fully trained surgeon, has in 1999 commenced a PhD program on this project supported by the Australian NH&MRC Clinical Centres of Excellence award.

BODY OF PROPOSAL

PURPOSE

1. To assess the sensitivity and specificity of ^1H MRS (*ex vivo*) in the detection of neoplasia in breast, based on altered cellular chemistry.
2. Correlate alterations to MRS detectable cellular chemistry associated with breast tumour development and progression with established clinicopathological criteria.
3. Ascertain MRS markers which correlate with known clinical, epidemiological and genetic risk factors to be used to identify women at-risk of developing breast cancer.

HYPOTHESES

Proton magnetic resonance spectroscopy can:-

1. Identify altered cellular chemistry in breast tissue independent of method of biopsy eg. open biopsy or fine needle biopsy.
2. Distinguish invasive cancer from normal breast tissue.
3. Distinguish between breast cancers of different type (e.g. lobular or ductal) and grade.
4. Distinguish between progressive and non progressive 'carcinoma *in situ*'.
5. Distinguish between 'normal' breast tissue and 'normal' breast tissue from women with differing risk factors for breast cancer (including age, pre- and post menopausal status, cyclic hormonal effects, genetic predisposition and family history).
6. Identify MRS markers of potential for malignancy in morphologically normal tissue from high risk patients.
7. Independent of histopathology, predict tumour behaviour and clinical outcome (e.g. response to therapy, patterns of metastases) and thereby be a significant predictor of patient survival.

EXPECTED RESULTS

- Expertise in optimal handling and methodological protocols for assessment of breast tissue.
- An MRS data bank on a full spectrum of breast tissue from normal (ie. benign) to high grade malignancy. This will allow discrimination of new subsets of cancer-bearing patients for streaming into different management regimes with attendant improved psychosocial, cost efficiency and clinical outcomes.
- Identification of new cellular chemistry parameters of tumour development in the breast.
- Definition of MRS markers which correlate with a predisposition for breast cancer development.
- Statistical verification of MR diagnostic criteria.

RESEARCH PLAN AND PROGRESS TO-DATE

(Results and progress during the last year are in bold)

A. SAMPLE PREPARATION

Objective 1.

Optimise specimen handling and MR data acquisition protocols.

Rationale: Breast tissue contains substantial levels of fat which mask the diagnostic markers of tumour development and progression. Removal of as much of this fat component as possible from the biopsy prior to MRS analysis is both achievable and necessary.

Results:

1996-1997

MRS handling criteria are established and global specimen handling protocols determined to ensure adequate histological correlation of MRS data on the test samples (see appendix II).

1997-1998

Effect of Time Stored at -70°C on FNA MRS Correlation with Pathology: To date 13 FNA were stored at -70°C for greater than six months but less than 22 months and then assessed by MRS according to the standard protocol outlined in Appendix II. The 3.25/3.05 ppm MR intensity ratio was correlated with the pathology of the lesions (Figure 1B) and the results compared with those obtained for 15 FNA assessed after storage for greater than 6 weeks but less than six months (Figure 1A). The MRS correlation with pathology was maintained for FNA under six months old. Samples stored for greater than six months were found to be not suitable for MRS assessment due to a higher than expected number of false negatives. This albeit small study indicates that both benign and malignant specimens biodegrade during longer storage and the resonance intensities of the diagnostic marks are no longer reliable.

Objective 2.

Ascertain if the same MR criteria can be obtained on fine needle biopsy or aspirate.

Rationale: If the same MR information can be obtained from a fine needle aspirate or needle core biopsy, open surgery may not be a prerequisite for determining the diagnostic parameters.

Results:

1996-1997

Breast: A previous study of MRS analysis on FNB of thyroid had established that as few as 10^6 cells were required to obtain one-dimensional MR spectroscopic data with adequate signal-to-noise in less than 15 minutes (256 accumulations) (39). To achieve an adequate breast sample, FNB was performed using multiple (typically 6) aspirated passes (23 gauge needle) either through the resected lesion *ex vivo* (n=129) or *in vivo* (n=89) after lesion identification during open biopsy. These techniques could be guaranteed to provide sufficient cells from the lesion and in addition, allowed the aspiration site to be identified at excision. Tissue from the aspiration site (3mm^3) was collected for correlative histopathology. Prior to the ^1H MRS experiment, each FNB specimen was thawed and transferred directly to a 5 mm MRS tube. The volume was adjusted to 300 μl with PBS/D₂O where necessary. The sample tube was fitted with a capillary insert containing 60 μl para-aminobenzoic acid (10 mM in PBS/D₂O) as an external standard.

1997-1998

Effect of FNA Collection Method (*in vivo* versus *ex vivo*): Specimen collection protocols have been established for obtaining FNA biopsies *in vivo* (prior to surgical excision of the lesion). This is an important step towards clinical trial of the MRS technology. A representative proton 1D MR spectrum of an FNA biopsy collected from a breast lesion *in vivo* is shown in Figure 2. The signal to noise and resolution of the *in vivo* spectra is of sufficient quality to allow correlation with histopathology on the basis of criteria generated from both visual inspection and multivariate analysis. This method of specimen collection is now used in the 1998-1999 year where clinically appropriate.

Lymph Nodes: Attempts to detect malignant cells in lymph nodes using 1D MRS have been limited by the high fat content of the tissue and the low spectral resolution. Using 2D COSY spectroscopy lymph nodes containing cancer cells were detected based on changes in the intensities of crosspeak resonances from lactate, choline, fucose and amino acids and these MR result were confirmed by xenographing the nodes into nude mice (41). COSY experiments are, however, time consuming (4-5 hours). Alternatively, the contribution from fat to the 1D MR spectrum can be reduced, as for breast tissues (Objective 1), by assessment of fine needle aspiration (FNA) biopsies of the lymph node tissue.

The proton MR spectrum obtained from solid lymph node tissue (Fig 6A) is of poor spectral resolution with predominant resonances from lipid at 0.89, 1.3, 1.7, 2.0, 2.2 and 5.37 ppm. These peaks represent $-\text{CH}_3$, $(-\text{CH}_2)_n$, $-\text{CH}_2-\text{CH}_2-(\text{CH}_2)_n$, $(-\text{CH}_2)_n-\text{CH}_2-\text{CH}=\text{}$, $-\text{COO}-\text{CH}_2-$ and $-\text{CH}=\text{CH}-$, respectively. Figure 6B shows the ^1H MR spectrum of the FNA biopsy. A marked improvement in the spectral resolution of the lipid resonances at 0.89, 1.3, 1.7, 2.0, 2.2 and 5.37 ppm is achieved which allows a number of other resonances of potential diagnostic importance to be observed. In particular the resonance that represent $-\text{CH}_2-\text{CH}_2-(\text{CH}_2)_n$ at 1.7 ppm is a distinct peak which was only observed as a shoulder in fig. 6A. The increase in spectral resolution is further evident in the choline peak at 3.2 ppm. In fig. 6A this peak is buried in noise while in fig. 6B the same resonance is resolved into its component (see insert fig. 6B). The component peaks at 3.20, 3.21 and 3.27ppm, representing choline, phosphocholine and inositol respectively, can all be distinguished.

1998-1999

MRS FNA of Lymph Nodes: FNA specimens from 20 malignant and 25 reactive lymph nodes have been analysed using 1D ^1H MRS. Of these, only 33% of FNA specimens (3 malignant and 12 reactive) gave rise to MR spectra with adequate signal to noise ratios. The initial high rate of inadequate FNB specimens is attributed to technical difficulties encountered by participating surgeons in acquiring sufficient cellular material from smaller nodes in the initial work up phase of this project.

Analysis of the 15 spectra with adequate signal to noise ratios show MRS on FNA discriminates between malignant and reactive nodes based on the ratio of intensities of resonances at 0.89ppm and 0.90ppm (resolved in spectra following resolution enhancement using a Gaussian-Lorentzian transformation, GB=0.08, LB=-7.0) plotted against the ratio of intensities of resonances at 3.2ppm and 0.9ppm (Figure 11).

Magic Angle Spinning (MAS) MRS of Lymph Nodes: The discriminant capacity of MRS to detect metastatic disease in human lymph nodes is supported by MAS MRS data from intact lymph node tissue (n=17) shown in Figures 12 and 13. The use of MAS significantly improves the resolution of proton 1D MR spectra of human axillary nodes, reducing the line width at half height of the 1.3ppm resonance from 30Hz (data not shown) to 8Hz (Figure 12B) and resolving this resonance and that at 0.9ppm into separate components (Figure 12B, insert). Resonances, assigned from 2D COSY,

include lipid and amino acids (0.9ppm), lipid and lactate (1.3ppm), creatine/phosphocreatine/lysine (3.0ppm) and choline metabolites (3.2ppm). Malignant nodes were distinguished from reactive nodes based on the peak height ratio of the smallest to largest peaks resolved in the 0.9 ppm resonance multiplied by the peak height ratio of the choline and creatine resonances at 3.2 and 3.0ppm, respectively (Figure 13). Three of four axillary nodes, from breast cancer patients, which were clinically suspicious but diagnosed cancer free on routine histopathology had an MAS MRS ratio consistent with reactive nodes. The fourth node in this category was by MAS MRS criteria, malignant.

Axillary lymph node involvement is a key prognostic indicator for breast cancer, yet accurate assessment of nodes is limited by sampling and observer errors. Here we demonstrate that MAS MRS has the potential to provide fast and accurate assessment of human axillary nodes from breast cancer patients and thus can significantly improve the diagnosis and management of this disease.

B. CORRELATION WITH HISTOLOGICAL CRITERIA

Objective 3.

Identify MRS criteria to facilitate distinction between resected carcinoma and normal tissue.

Rationale: The primary data base will be obtained from this section of the study. The 1D and 2D MR data are likely to contain the majority of resonances that need to be assigned to chemical species, biological criteria and clinicopathological criteria.

Results:

1996-1997

All pathological and MRS analyses were undertaken in a blinded study. Correlation of MRS data with clinicopathological criteria were made after all reports were filed. 218 FNB and tissue specimens for MRS analysis and correlative histopathology respectively were obtained from 191 consecutive patients undergoing diagnostic biopsy or definitive treatment (lumpectomy, quadrantectomy or mastectomy) for histologically proven invasive breast cancer. Indications for surgery included mammographically detected impalpable lesions as well as palpable mass lesions which were suspicious by mammography, FNA cytology and/or clinical examination. The age range of patients was 20 to 81 years (mean \pm SD, 52 \pm 14). Where mastectomy for invasive carcinoma was performed, control specimens of macroscopically uninvolved breast tissue (which was later confirmed histologically) were obtained in the same patient (n=27). The MR experimental methods, data processing and analysis, peak assignment procedures and histopathological assessment protocols are described in detail in Appendix II.

Invasive carcinoma was identified by resonances at 3.25 ppm attributable to choline-containing metabolites (Appendix II, Figure 2). A discrimination between invasive carcinoma (n=82) and normal or benign tissue (n=106) was made based on the intensity of the 3.25 ppm resonance standardised to the resonance intensity at 3.05 ppm containing contributions from creatine, phosphocreatine and lysine (p<0.0001, Mann-Whitney U test)(Appendix II, Figure 3). A receiver operating characteristic (ROC) curve using this intensity ratio is shown in Appendix I, Figure 4.

Of 106 benign samples, 102 gave a 3.25/3.05 ppm intensity ratio of less than 1.7. Four false positive results were obtained from 3 palpable fibroadenomas, none of which had FNA cytology performed, and 1 lesion comprising moderate ductal hyperplasia. The diagnoses were based on correlative histopathology. FNB from 4 of 82 carcinoma had a ratio of < 1.7. Correlative histopathology from the aspiration site showed that one sample had only benign fibrocystic changes in this region. The other three samples were confirmed as invasive carcinoma but with a marked inflammatory cell infiltrate.

Clinical Correlations: All cases presenting as mammographically suspicious (n=56), mammographically negative (n=23), or non-diagnostic (n=14) or atypical/suspicious (n=25) FNA cytology, were accurately categorised by MRS (as benign or malignant) as confirmed by histopathology on tissue excised from the aspiration site. MRS on F.B. correlated 96% with the final histological diagnosis of benign lesions (Appendix II, Table 2) and yet, biopsy was performed because of clinical (34%) and/or mammographic features (45%) and/or FNA cytology (31%). MRS on F.B. correlated with a malignant histological diagnosis in 95% of cases (Appendix II, Table 2). While combined triple assessment indicated biopsy for all the malignant cases studied, no single pre-operative modality was an improvement on MRS in identifying malignancy (physical examination 84%, mammography 82%, FNA cytology 92%).

1998-1999

A further 129 FNA were collected from participating surgeons during 1998/99 for MRS analysis. Of these, 60 were unsuitable for inclusion in the study due to incorrect handling by couriers (allowed to thaw) during transport to the MRS facility. Of the 69 remaining FNAs, 45 were examined using the standard 1 Dimensional MRS protocol (Figure 7A) and 24 were analysed using a newly developed automated MRS protocol (Figure 7B) in preparation for transfer of this technology to the clinical setting.

Automation of MRS Protocol: Proton MRS *ex vivo* has the potential to be a very useful diagnostic tool available for routine use in the clinic. There has to date, however, been no application of ¹H-MR spectroscopy in routine clinical pathology due to the technical complexity of acquiring and processing the proton MR spectra.

As a first step in overcoming this problem we have now developed an algorithm to enable high resolution proton MR spectra of breast FNA to be obtained using fully automated acquisition and processing procedures. The main components of the automation algorithm are shown in Figure 8. Twenty four FNA specimens were analyzed using this algorithm. The only tasks performed by the operator were placement of the MR tube in the magnet and the typing the start command. No manual probe tuning was necessary during the 40 days over which the data was collected.

The MRS data were correlated with the post-operative hospital pathology for each patient. Malignant and normal or benign tissue were discriminated with a sensitivity and specificity of 100% and 78%, respectively, using the standard protocol, ie. the ratio of MR resonances from choline-containing metabolites (3.25 ppm) and creatine (3.05 ppm). A MRS ratio < 1.7 was recorded for all normal/ benign lesions. Only three samples yielded spectra that could not be used due to a low signal-to-noise ratio.

These results show that the MRS FNA method may be readily developed into an easy-to-use diagnostic tool for routine clinical use. Further developments required include a fully automated determination of diagnostic signals using computerized consensus diagnosis and provision of this diagnosis

Objective 4.

Establish whether MRS can identify differences between variants of breast cancer (e.g. lobular and ductal carcinoma) which reflect altered biological behaviour (e.g. likelihood of response to treatment or location of secondary tumours).

Rationale: Lobular and ductal carcinoma have quite different patient outcome. Ductal carcinoma will

usually metastasise to the liver, brain, bone, lungs etc.. whereas lobular carcinoma frequently metastasises to unusual sites. If spectral differences exist between these two types of breast carcinoma and can be assigned to specific biological criteria eg. altered cell surface glycosylation which could reflect altered immunosuppression (50), ability to lodge at different sites (51-53), or adhesion properties (54), the patient outcome could be rationalised at an early stage in the diagnosis and treatment altered accordingly. The reasons for variable survival of women with established metastatic disease may be manifest in the cellular chemistry of the carcinoma cells.

Experimental: Underway. This aspect of the project has been delayed due to a shortage of lobular specimens.

Objective 5.

Correlate MRS properties with the established pathological characteristics of breast epithelial hyperplasia and neoplasia.

Rationale: It is important to identify which MRS characteristics are consistent with established pathological criteria. MRS will be used, as an adjunct to current histopathology, with each method contributing to a more thorough and refined diagnosis and patient management.

Experimental: Underway

C. CAN MRS REDEFINE THE PRECURSOR STATES OF BREAST NEOPLASIA?

Objective 6.

Compare simple hyperplasias, atypical hyperplasias and malignant tumours. Does MRS identify sub groups or categorise these histological states differently?

Rationale: The strength of the MR method as demonstrated in its application to other organs, was the identification of alterations to cellular chemistry which were not morphologically manifest, or which discriminated between subsets with overlapping or identical histological appearances (e.g. follicular adenoma and carcinoma of thyroid).

Experimental: Underway

Objective 7.

Assess resected tissue containing morphological carcinoma *in situ* to determine if the MR method can separate those, if any, which contain cells committed to invasion from those that cannot progress at that time.

Rationale: Diagnosis of carcinoma *in situ* (CIS) of the human cervix relies on the pathologist confirming that the cells (which are morphologically indistinguishable from invasive cancer) have not invaded. MRS has clearly shown that CIS of the cervix does not have the same cellular chemistry as those cell which are invasive. Does CIS of the breast have a different cellular chemistry from invasive cells? Can the distinction be made between a CIS which has cellular capability to invade from those which have yet to develop fully invasive properties?

Results:

1996-1997:

Specimens reported as ductal carcinoma-*in-situ* (DCIS) by routine hospital histopathology were obtained and assessed by MRS. Samples containing only DCIS (10 high grade, 1 low grade) all gave MR ratios ≤ 1.7 indicative of a low choline to creatine/lysine ratio similar to that obtained for benign lesions. Ductal cells had breached the basement membrane ($< 1\text{mm}$) in one or more focus of the entire DCIS specimen in the 4 samples denoted 'microinvasion'. This group as well as 2 samples of high grade DCIS with extensive comedonecrosis gave ratios > 1.7 similar to that obtained for malignant lesions.

1997-1998:

A further DCIS specimen was collected. By MRS criteria this specimen had a ratio greater than 1.7 making it malignant by MR criteria. Interestingly, the pathology indicated that the patient had invasive cancer elsewhere in the breast. This observation is consistent with data obtained on the prostate program where when cancer was present elsewhere in the organ a histologically benign specimen gave a MRS ratio consistent with malignant.

To further examine the extent to which MRS can record an adenoma-carcinoma sequence in breast neoplasia based on changes to cellular chemistry two dimensional (2D) correlated spectroscopy (COSY) techniques have been optimised for the assessment of intact breast tissue biopsies. Representative COSY spectra of lesions of malignant, ductal carcinoma *in situ* and benign pathologies are shown in Figures 3A, B and C, respectively.

There are in excess of 50 chemical species (crosspeaks) identifiable in the 2D COSY MR spectra of some invasive tumour biopsies and malignant cell lines (2). Many of these crosspeaks have been assigned (8). Those used in other organs as diagnostic markers include lipid, cell surface fucosylation and cellular metabolites.

Resonances from cell surface fucose are of particular interest in the characterisation of the malignant potential of preinvasive lesions. 2D COSY spectroscopy of adenomatous colorectal polyps displayed a progressive increase in the complexity in the spectral pattern from fucosylated species that correlated with the malignant potential of the adenoma, specifically with the histological degree of dysplasia.

Crosspeaks identified and assigned in the spectra of breast lesions including those from lipid, cellular metabolites and cell surface fucose (Figure 5) are summarised in Table 1.

1998-1999:

Two-dimensional MR analysis of breast FNA and tissue specimens has continued. Fifteen breast tissues have been analysed by two dimensional (2D) Correlated Spectroscopy (COSY). The resonances observed in the spectra of benign, malignant and DCIS (ductal carcinoma *in situ*) tissue specimens are summarised in Table 3. 2D COSY MRS fails to discriminate between breast tissues of varying pathologies due to large contributions from lipid in most spectra which prevent metabolites present in lower concentrations to be recorded. Sixteen breast FNA specimens have also been analysed using 2D COSY (NS=48, NE=200, 4h experimental time). Using these acquisition parameters, COSY also fails to discriminate FNA specimens of varying pathologies due to inadequate signal to noise in the majority of spectra (Table 4). We are now investigating whether by increasing the number of scans acquired in each experiment (NS=192, 12h experiment time) the problem of inadequate signal to noise in FNA spectra can be overcome. A new MR technique, magic angle spinning (MAS), is also under investigation as a means of obtaining increased chemical information from intact breast tissue.

A further six DCIS specimens have been examined by MRS during 1988/99 (Figure 7A). Three

specimens had an MR ratio consistent with the presence of malignant disease. Examination of the tissue surrounding the FNA site for the six cases found no evidence of malignancy in any of the tissues. Review of the pathology of these patients found no standard histological features, including comedonecrosis or microinvasion, that confirmed the MR diagnosis. However, of the three carcinoma *in situ* specimens ranked as malignant, two were obtained from re excisions from women with previous breast cancers. One of these women had nodal metastases present at the time of re excision. These data therefore suggests that MRS is reporting on changes in cellular chemistry that are not evident using histopathological techniques. Confirmation of the MR diagnosis requires follow up of these patients and correlation with clinical outcomes.

D. CAN MRS IDENTIFY CHEMICAL PROFILES ASSOCIATED WITH A PREDISPOSITION TO BREAST CANCER?

Objective 8.

Study morphologically normal tissue from women with differing risk factors for development of breast cancer.

Rationale: It is most likely that alterations to cellular chemistry are able to be documented in the above categories. Are there specific changes which can be identified in at-risk patients?

The effect of :-

age,
pre vs post menopausal status,
cyclic hormonal effects,
genetic predisposition,
family history,

on the spectral profile will be considered in a retrospective study in association with the breast data bank registries.

Experimental: Underway.

E. LONGITUDINAL STUDY

Objective 9.

Statistical and mathematical multivariate analysis to correlate MRS data with clinicopathological, epidemiological and genetic data.

Rationale: By examining tissue specimens by MRS, it may be possible to predict the precise progression of breast cancer in individual patients more accurately than histopathology.

Experimental: Underway

Results

1997-1998: MR spectra comprise a large number of variates, the intensities of absorption as a function of frequency. As many as 4000 variates may be available for each spectrum to be classified.

Extensive experience with classifying MR spectra indicated that better and more reliable classification is obtained if we only deal with the magnitude spectra. (The subjective spectral phasing step is completely eliminated.) Thus all analyses were conducted on the magnitude spectra.

Efficient application of multivariate analysis involves identification of the minimum number of variates required to classify the spectra accurately. We have developed a powerful and versatile preprocessing method (ORS_GA) that is Genetic Algorithm-driven and selects from the spectra those subregions that are optimally discriminatory (62). Reduction of the number of features to 1/5 – 1/10 of the number of samples per class is an essential requirement for creating reliable classifiers.

We used simple Linear Discriminant Analysis (LDA) with the selected optimal features (each such feature is the average intensity value of its spectral subregion). Classification robustness and reliability is achieved by our resampling procedure. This involves the random selection (with replacement) of ~half the samples from each class to use as the training set for the LDA, with the remainder serving as a test set. This is repeated N times (N is typically 500-1000), and the N sets of LDA coefficients averaged to produce a single, optimal set. (This combination of optimal region selection and resampled and averaged LDA has been successful for the accurate classification of MR and IR spectra of tissues and biofluids for a variety of diseases and disease stages.)

We applied the above classification strategy to the breast tissue spectra (water-suppressed, with 1250 data points per sample in the 0.5-4.0 ppm spectral range). There were 55 benign and 69 malignant samples. Three independent sets of 9 variates each gave very similar results: ~70% classification accuracy for the entire 124 spectra. However, when only the crisply (i.e., with probabilities to belong to a given class > 75%) classified spectra were considered, their classification accuracy reached ~90%. Unfortunately, the crisply classified spectra comprise only ~25% of the total number of spectra. Our consensus classifier, which uses the outputs of the three individual classifiers as inputs to another LDA classifier, increased the number of crisply classified spectra to 53%, but the overall accuracy of these remained at ~90%.

Further improvement requires:

- Increase in spectral data base to at least 100 per class.
- Removal of minor contaminants present in the storage D₂O solution present in some data files.
- Since the misclassified and fuzzily classified spectra are evenly distributed between the two classes, this suggests that better quality spectra would yield better classification results.
- Lipid suppression will also be tested.

1998-1999:

When the signal to noise ratio (SNR) of FNA spectra exceeds 25, analysis of spectral data by visual inspection distinguishes malignant and benign pathologies with a sensitivity and specificity of 100% and 80%, respectively (Figure 9B). However, if spectra with SNR<25 are included in this analysis the sensitivity and specificity of the method falls to 83% and 72%, respectively (Figure 9A).

Multivariate analysis methods, specifically computerised consensus diagnosis (CCD), successfully distinguishes malignant and benign pathologies with high sensitivity and specificity for all FNA spectra including those with SNR<25. The CCD method uses output probabilities from K independently created classifiers as input attributes to another classifier (e.g., Wolpert's combining rule). This produces classifiers whose output are much "crisper" than constituent classifiers. A high % crispness is of clinical relevance. For a 2-class problem, assignment that is considered "crisp probability" is that which equals or exceeds 75%.

Malignant or Benign FNAs (All SNR): Distinction of malignant (n=80) and benign (n=54) FNA for all data (including those with SNR<25) using CCD required combination of two classifier outcomes, both of which had 8 subregions, but were normalised differently. A sensitivity and specificity of

92% was recorded with an overall accuracy of 93% and an overall %crisp of 96% (Table 2A). This was a significant improvement on the 83% sensitivity and 72% specificity calculated from these data analysed by visual inspection.

Malignant or Benign FNAs (SNR>25): Applying the same protocol as above to FNA spectra with SNR>25 further improves the sensitivity and specificity of distinguishing benign from malignant specimens to 98% and 94% respectively, with an overall accuracy of 96% and an overall %crisp of 99% (Table 2B).

Lymph Node Involvement and Vascular Invasion: The CCD method was further able to predict the presence or absence of A) lymph node involvement and B) vascular invasion from the MRS FNA data. Identifying lymph node involvement using CCD required the combination of two classifier outcomes, one of which had 4 subregions, the other 5 subregions. A sensitivity and specificity of 96% and 94%, respectively was recorded, with an overall accuracy of 95% and an overall %crisp of 95% (Table 2C). Identifying vascular invasion again required two classifier outcomes, each with 7 subregions. A sensitivity and specificity of 84% and 100%, respectively was recorded, with an overall accuracy of 92% and an overall %crisp of 94% (Table 2D).

Pulse Sequence Refinements To Improve Water Suppression: One severe problem with the observation of MR spectra of FNA in an aqueous suspension is the suppression of the residual water signal. Incomplete suppression of this signal was a major reason for FNA specimens being unsuitable for multivariate analysis. This problem has now been overcome with the refinement and successful application of a new MR pulse sequence.

Saturation of the water resonance by pre-irradiation is one of the most commonly and successfully used sequences to suppress the water signal. However, the remaining H₂O signal is in many cases still several times larger than any other signal in the MR spectra of FNA (Figure 10A) even with the use of 99% D₂O for suspension of cellular material. This not only yields a large unwanted water signal but also a distortion of the baseline in the spectra.

The remaining water signal and baseline distortion influence multivariate analysis outcomes and make this analysis in many cases impossible. A recent pulse sequence published by Hwang and Shaka (63) that delivers pure phase spectra with flat baselines, and that allows excitation into almost arbitrary profiles, can overcome this problem. This pulse sequence is also useful for suppression of large solvent signals. The principle of the Hwang and Shaka pulse sequence is a simple echo sequence with a pulsed field gradient before and after the refocusing element. Any phase shift can be removed by applying this sequence twice. An introduction of a soft pulse into this $90E_x-G_1-90E_x-\tau-90E_x-G_1-G_2-90E_x-\tau-90E_x-G_2$ pulse sequence sharpens the excitation profile further.

We employed, similarly to Hwang and Shaka, a [soft 180E_x hard 180E_x] refocusing element. This pulse sequence returns all magnetisation to its starting point except for the water signal (soft 180E_x pulse was applied for the water signal). The delay τ was set to either 500 μ s (Figure 10B) or 600 μ s (Figure 10C). The larger τ value yields a narrower excitation profile but causes a second excitation at a frequency $1/\tau$ from the water frequency. This yielded minor suppression of intensity for signals close to the water frequency for $\tau=500\mu$ s and minor suppression of intensity for signals on the edges of the spectral width (>9ppm and <1ppm) for $\tau=600\mu$ s, respectively. This loss in signal intensity is negligible compared to signal loss due to pre-saturation of the water resonance.

Water suppression in the FNA spectra using this new method was 15000 " 1000 compared to 600 " 100 with the pre-irradiation method. Another feature of this method is the presence of OH/NH protons that would normally be suppressed by a pre-saturation pulse applied to the water signal due to exchange of protons from the water with these from OH/ NH-groups. This can be seen in Figure 10 in the chemical shift range 6-9 ppm. These signals may provide additional information in a multivariate analysis.

METHODS (*Methods additional to original submission are in bold*)

THE SELECTION OF PATIENTS

Biopsy specimens are to be obtained at the time of surgery on 500 patients undergoing surgery to excise benign and malignant lesions by participating surgeons. The indications for surgery include:

1. Mammographically detected impalpable lesions where malignancy cannot be excluded. Stereotactic fine needle aspiration biopsy will be the indicator for surgery.

In this subgroup approximately 50% will have small invasive cancers, 30% of patients can be expected to have benign lesions such as sclerosing adenosis whilst the remainder will have premalignant conditions like atypical hyperplasia through to carcinoma *in situ*.

2. Excisions of mass lesions which have been proven by mammography, fine needle biopsy, cytology and clinical examination to be malignant where breast conservation can be performed. This is generally for patients with smaller tumours but is dependent upon other factors such as breast size.

The attending surgeon would undertake to provide this follow-up through out this period with regular reports to a central registry office. Initially, patients will be recruited to the study consecutively. However, it is anticipated that, as the study progresses, selection criteria may be introduced to enhance the data base of specific subgroups of patients.

Lymph node biopsy specimens will be obtained at the time of surgery from the following patients undergoing surgery to excise benign and malignant lesions:

1. **All patients undergoing mastectomy or segmentectomy with axillary sampling or clearance.**
2. **Patients undergoing sentinel node sampling.**

THE PARTICIPATING SURGEONS

THE ROYAL ADELAIDE HOSPITAL

South Australian clinical material in the first instance will be obtained from the patients treated by one surgeon (PLM) from the Breast Endocrine and Surgical Oncology Unit at the Royal Adelaide Hospital. This unit treats 200 primary or new breast cancers per year and provides a dedicated service to a 900 bed teaching hospital on the campus of the University of Adelaide. All patients are treated according to protocol and management is reviewed by a multidisciplinary team prior to treatment. Patients are regularly entered into Australian, New Zealand and international trials where appropriate. The routine pathology service is provided by pathologists from the Institute of Medical and Veterinary Science who also provide a dedicated service and attend the multidisciplinary meetings.

The unit is undertaking research in the following fields:

1. Endocrine responses to oestrogen and progesterone in breast cancer with particular reference to insulin-like growth factor binding proteins.
2. The immunological response associated with human breast cancer with reference to tumour infiltrating lymphocytes (TILs) boosted by lymphocyte growth factors.
3. The evaluation of magnetic resonance imaging of the breast in two subgroups of patients:
 - a) young women with dense parenchymal breast tissue

- b) for the evaluation and accurate assessment of women with T3 breast cancers.
4. Dynamic doppler studies to evaluate vascular function in breast reconstruction using autologous tissues.
5. Angiogenesis in breast tumours determined by dynamic doppler.
6. A comparative study of carbon track localisation hook wire for mammographically detected impalpable breast lesions.
7. On-going evaluation of the following tumour markers: a) vimentin, b) cERB2, c) ER, d) PR, e) CA125, 153.
8. Open label study of high dose chemotherapy in patients with breast cancer using autologous peripheral blood, stem cells and G-CSF support.

All patients treated by the unit are reviewed at regular intervals according to protocols and information provided to the Cancer Registry.

The unit works in close association with the South Australian Breast X-ray Service which screens 30,00 women per year between the ages of 40 - 69 years. From 1994 the number of women screened will increase to 45,000 per annum. This service provides a constant supply of small tumours as 70% of lesions detected by the clinic are less than 2 cm in size. This service is closely audited and offers the service to the point of diagnosis with particular emphasis upon stereotactic fine needle aspiration biopsy and ultrasound guided needle biopsy. The program is independently audited.

This service can provide biological material ranging through benign, premalignant, ductal carcinoma *in situ* and carcinoma.

WESTMEAD HOSPITAL

The Breast Surgery Unit at Westmead Hospital is multidisciplinary involving all aspects of breast cancer patient care, with a major commitment to the management of patients with breast cancer irrespective of the stage of the disease at presentation. Approximately 150 patients with breast cancer are treated each year within the unit, with approximately 10% having advanced breast cancer and with an increasing number having *in situ* disease as the number of patients accessed through the Screening Unit increases.

The Unit is undertaking research in the following fields:

1. Since 1979 patients with operable breast cancer have had the option of a breast conservation approach involving 'lumpectomy', or 'quadrantectomy' with clear surgical margins, axillary clearance, and radiotherapy to the breast. A particular form of axillary clearance has been developed with improvements in the way the procedure can be taught to trainees and a video tape is in production and will be shown next year at surgical meetings of the Royal Australasian College of Surgeons.
2. Approximately 50 - 55% of the patients with operable breast cancer currently achieve breast conservation. An initial cohort of approximately 130 patients undergoing a breast preservation procedure have been followed and the results have been reported at 5 and 10 years. Patients needing mastectomy have been treated with total mastectomy and axillary clearance again using the axillary clearance technique developed by the unit.
3. A study has recently been completed to determine the value of the cERB2 antigen in predicting recurrence in node negative breast cancer patients followed for more than 5 years.
4. Apart from its own trails, the unit takes part in a number of international studies including the Zoladex trial for node positive breast cancer.
5. Ongoing evaluation of the following markers is being undertaken: a) ER, b) PR, c) ploidy, d) epidermal growth factor receptors.

The surgical team works closely with Radiation and Medical Oncologists, with the Breast Screening Unit and with the Cytology and Pathology Departments. Combined clinics are held and a major Breast Cancer Data Base has been established within the Radiation Oncology Department. Reports have been published on the efficacy of cytology prior to breast surgery, on the problems encountered with the procedures involved in breast conservation, and also the results from our 'Advanced Protocol Treatment' of advanced breast cancer at presentation. The senior surgeon is also the senior surgeon of the Screening Unit which now has considerable expertise in all aspects of Screening, and is recognised as a training unit for medical and paramedical professionals involved with Breast Screening. Surgical and radiotherapy trainees take part in the clinical program and for the past 12 months a 'Breast Fellow' has been appointed and this is a recognised post for the Royal Australasian College of Surgeons for postgraduate training breast surgery for young surgeons who have achieved Fellowship of the Royal Australasian College of Surgeons.

This service can provide biological material ranging through benign, premalignant, ductal carcinoma *in situ* and carcinoma.

CONCORD HOSPITAL

The Breast Endocrine Unit at Concord Hospital was established in 1986. It is composed of four dedicated surgeons working from a forty bed unit. It is closely associated with the University of Sydney and is involved in student teaching, registrar training and research.

Approximately 100 cases are seen per annum. The data collection is made on a standard protocol and processed using computer programs.

The unit is associated with the breast screening clinics of Central and Western Sydney. The principals attend these clinics and patients are then referred for treatment at Concord Hospital.

Multi-disciplinary meetings involving pathologists, radiologists and surgeons are held on a regular basis and a routine monthly review of all cases is undertaken. Standard protocols for breast treatment have been instituted and are followed by the treating surgeons.

Papers have been published on the accuracy of fine needle aspiration cytology in breast cancer patients, the incidence of mammography negative breast cancers seen through the clinic and the incidence of multi focal breast cancer.

This service can provide fewer specimens than the larger two centres but a strong collaboration between the MR Unit and surgeons at Concord Hospital is well established.

MAGNETIC RESONANCE SPECTROSCOPY

Magic Angle Spinning (MAS) MRS of Human Lymph Nodes: Sample Preparation: Axillary nodes were collected from breast cancer patients. Reactive jugular-digastric nodes were obtained from carotid endarterectomy patients. Nodes in 0.25 ml PBS/D₂O were frozen in liquid nitrogen and stored at -70°C for less than 3 months. For MRS, nodes washed in PBS/D₂O were placed in 4mm rotors (Bruker). ***¹H MAS MRS:*** A Bruker DRX 360 MHz spectrometer (Magnex magnet) and broad band MAS solid state probe were used with samples (37°C) spinning at 2.3 KHz. Water signals were suppressed by selective gated irradiation. 128 averages of 16K data points were acquired. Following MRS, nodes were fixed for histopathology. Data were zero filled to 32K and an LB=1Hz applied prior to Fourier transformation and polynomial baseline correction.

Sample Handling Tissues (tissue or FNA) obtained at surgery will be placed into a sterile tube containing pre-cooled (4 C) phosphate buffered saline in D₂O (PBS/D₂O) immediately after excision. Alternatively, biopsies will be snap frozen in liquid nitrogen, transported to the laboratory and stored at -70 C until ready for examination. Samples to be examined by MRS will be gently thawed, washed in PBS/D₂O (5 x 1 ml) and placed in a 5 mm MR tube containing sufficient PBS/D₂O to cover the biopsy. Placement within the transmitter/receiver coil will be ensured by either resting the biopsy on top of a plug

of glass wool (5), or by suspending the biopsy inside an inner capillary tube of 2.5 mm diameter (10,34). In the case of the capillary method, the external volume will be filled with 350 μ l of 1 mM p-aminobenzoic acid (PABA) in PBS/D₂O which serves as a chemical shift and concentration reference (34). **A third method is being included for the study of FNA from axillary lymph nodes. Samples suspended in PBS/D₂O (final volume 450 μ l) will be placed in specialised susceptibility matched 5 mm MR tubes containing a raised platform (Shigemi Co. NMR division).** As in the case of colorectal biopsies (21), prior to the MRS experiment the specimens will have excess adipose tissue and vasculature excised. Alternative methods such as passing the tissue through a metal sieve to trap the fat (see Page 17) will be explored.

F.B.: will be performed using 5 aspirated passes through the specimen with a 21 gauge needle (39). Previous studies (55) have shown that this combination gives the greatest number of cells, both single and in clumps, although it is not the preferred technique if clear cellular detail is required for accurate cytological examination. F.B. are washed with 2 x 1 ml PBS/D₂O. Between washes the samples are centrifuged (1000g for 5 min) and the supernatant discarded. The F.B. are suspended in PBS/D₂O (final volume 125 μ l) and then placed on top of a glass wool plug in a 5 mm MRS tube.

Data Collection Data will be collected on a Bruker AM360 wide-bore MR spectrometer equipped with an Aspect 3000 computer and a dedicated 5 mm or 8 mm ¹H probe. Temperature is maintained at 37 C using a Bruker VT1000 temperature regulation unit.

Pulse Sequences All pulse sequences to be used are functional in this laboratory at the time of application. Typical experiments are as follows:-

1D ¹H spectroscopy: 1D spectra (at 360 MHz) are obtained using a spectral width of 3600 Hz (10 ppm) and 8K data points. A relaxation delay of 2 sec is used during which gated decoupling (15 dB below 0.2 W) is applied for the final 1 sec to reduce the residual water signal (56). 128 transients are averaged.

CPMG: One-dimensional T₂- filtered experiments are performed using the Carr-Purcell-Meiboom-Gill pulse sequence (90_x-(-180_y-)_n-acquire) with an interpulse delay of = 1 msec and a 2 sec relaxation delay between acquisitions (48). Gated presaturation is used in the final 1 sec before data acquisition. 128 transients are collected using a spectral width of 10 ppm. T₂- filtered 1D experiments on biopsy specimens is performed using selected values of n. Typical values of n₂ = 16, 480, 720, 960 ms.

2D ¹H-¹H COSY spectroscopy: Magnitude-mode COSY spectra are performed using a standard two pulse sequence with the two pulses separated by an incremented delay (57). The sweep width in the t₂ domain is 3000 Hz, and the size in the t₂ domain is 2K data points. The initial delay between the 2 pulses is 1 msec with an increment time of 334 sec. There is a relaxation delay of 1 sec before each accumulation during which the water resonance is presaturated using a CW irradiation power of 30 dB below 0.2 W. The number of time domain points collected in t₁ (free induction decays, FIDs) is subject to the viability limits of the sample. Tissue experiments consist of 180-220 FIDs, each of 32-48 transients (plus 2 dummy scans) over a total experiment time of three to five hours.

T₂-filtered Correlation Spectroscopy: T₂-filtered correlation spectra are obtained by replacing the first pulse of a standard COSY pulse sequence with a CPMG sequence (48). Typical parameters are described above with n₂ equal to 500 - 750 msec. The sequence removes crosspeaks arising from short T₂ species, like lipid, leaving only resonances from more mobile metabolites. The pulse sequence is useful in resonance assignment in specimens, like breast, which contain large quantities of lipid that can be reduced or removed using this technique.

Processing of MRS Data Data will be processed on a Bruker X32 (UNIX) Data Station or a Silicon Graphics Indigo 2 work station equipped with Bruker XWINNMR data processing software. The complexities of processing FIDs from biological material containing a wide range of T₂ relaxation

values (0.3 - 1.5 s) has been addressed in this laboratory (17). The processing parameters vary according to the MR visible chemicals of each tissue type.

1D spectroscopy: One dimensional spectra (1D and CPMG) are routinely processed using a line broadening of 3 Hz applied before Fourier transformation. Data are phase corrected using zero and first order phase correction and baselines are corrected using a fourth order polynomial baseline correction routine. Linewidths or ratios of peak heights are measured in 1D spectra.

2D spectroscopy: COSY data matrices undergo zero filling to 1K in t_1 , Fourier transformation and magnitude calculation ($(\text{Real}^2 + \text{Imaginary}^2)$) to give 1024 x 1024 real data points for each COSY spectrum. Sine-bell window functions are uniformly applied in the t_1 domain and Lorentzian-Gaussian window functions of varying width and maximum positions are applied in the t_2 domain prior to Fourier transformation as previously described (17). Crosspeak volumes and subsequent ratios to external or internal reference peaks will be measured as previously described (2,7,8,58).

Referencing peak height integrals, or peak heights, to those of an external standard with a constant concentration and T_2 relaxation value allows a semi quantitative concentration measurement. However, differences in crosspeak volumes can arise from either concentration changes or from changes in T_2 relaxation of the species. These two effects cannot be separated, but an increase in crosspeak volume will reflect either a chemical change or a reorganisation of the compound within the cell, and may still have diagnostic relevance.

MATHEMATICAL ANALYSIS OF MR DATA FROM THE UNIX

Unprocessed MRS data will be transferred electronically via internet to the Silicon Graphics server at the Institute for Biodiagnostics, Winnipeg, Canada for a thorough mathematical analysis. The MR spectra will be prepared for analysis by means of the proprietary software ALLFIT (National Research Council of Canada), which provides appropriate baselines and integrals for each distinguishable peak. The spectra will then be preprocessed by formation of a correlation matrix to avoid problems due to widely disparate variate ranges. Principal component analysis will then be applied to the spectral regions of interest, in order to reduce the number of variable in the computation. One half the available data will be used as a training set, and the remaining half will be classified blindly. To make all analyses robust, the training set data will be analysed by the leave-one-out method *i.e.* train on k-1 of the k samples, classify the sample that was excluded from the training set, and repeat this k times, once for each sample.

Classification will be performed by a variety of methods, alone and in combination. The principal methods are linear and quadratic discriminant analysis (45), neural nets of various types (44), and genetic programming (46). Consensus analysis will be performed within each method using different regions of the spectrum and with combinations of methods, to increase accuracy of classification. Fuzzy logic methods will be applied where appropriate.

The steps in the multivariate analysis methods developed by Dr R Somorjai for the analysis of breast FNA specimens are as follows:

Preprocessing

- **Construct magnitude spectra**
- **Peak alignment of spectra**
- **Normalization to area of spectra**
- **Optimal region selection**

Classification

- **Classifier is robust, reliable LDA**
- **Bootstrap-based cross-validation**
- **Classifier outputs are probabilities**

Computerized Consensus Diagnosis (CCD)

- Uses output probabilities from independently created
- classifiers as input attributes to another classifier
- Produces crisper classifiers than constituent classifiers
- 2-class problem is considered crisp if probability $\geq 75\%$

HISTOPATHOLOGY

Every MR sample will be assessed by one of two pathologists.

Expertise of the Pathologists The two pathologists participating in this study are Senior Hospital Consultants, each with over 25 years experience. Professor P. Russell is an acknowledged authority (59) and Dr J. Phillips is well recognised internationally in the field of aspiration cytology. Each pathologist has indicated that he/she is willing and able to make the necessary contribution in time to ensure the success of this project.

Rationale for the Extent of Histological Assessment

1. Primary correlation is obtained by comparing the MRS result with standard hospital histopathological diagnosis. This involves no additional time spent by the pathologist. Long-term storage of fixed tissue for later re-examination will be required.
2. The MRS sample is always examined **initially** by six "step-sections" 7 μ m sections (taken at 350 μ m intervals) at x 40 magnification. The intervening sections are mounted, stained and stored for future assessment if required. Tissue preservation, cellular content and presence of potentially confounding factors such as fat and inflammatory cells are reported in addition to the diagnosis. This involves an additional 5-6 minutes of pathologist time per specimen and is undertaken without reference to clinical or MRS data (in both MRS specimens and remainder of surgical specimen).
3. Where disagreement exists between MRS diagnosis and histological diagnosis, the MRS sample will be step-serially sectioned every 7 μ m (refer to 2) and examined by the pathologist in a blind study. To avoid bias other specimens will be included at the same time.

Tissue Preparation

Routine: Tissue is fixed in 10% buffered formalin or FAA (formalin:acetic acid:alcohol), paraffin embedded and sectioned, stained with haematoxylin and eosin according to standard protocols.

Serial sectioning: Routine sectioning of paraffin blocks will be at 7 μ m. Step serial sectioning of paraffin blocks will be undertaken on selected specimens.

Criteria for establishing firm histological diagnosis of cancer and its precursors in the tissues to be included in this study, will follow established guidelines. In general terms, the various pathological subtypes of cancer will be classified according to the relevant WHO International Histological Tumour Classification and, where difficult diagnostic problems are encountered (particularly for borderline malignancies), the guidelines in the following reference text will be used *viz* Page D.L. & Anderson T.J. (1990) Diagnostic Histopathology of the Breast. Churchill Livingstone, United Kingdom.

Quantification of Cell Types This will be performed usually on 'step' or 'full' serial sections and is only intended to provide an approximate guide to relative proportions of study tissues to background stroma and reactive inflammatory infiltrates etc.

STATISTICAL ANALYSIS

The epidemiologist (O.D.) in Canberra will examine associations statistically between MRS assessment and pathology and clinical variables using comparisons between means, contingency tables and logistic regression. Associations between MRS spectra and patient survival will be assessed by Kaplan - Meier Survival analysis (60) and proportional hazards regression models (61).

KEY RESEARCH ACCOMPLISHMENTS

- Proton MRS on FNA distinguishes benign breast lesions from invasive cancer with a sensitivity and specificity of 95% and 96%, respectively.
- Proton MRS ranks carcinoma *in situ* specimens as benign or malignant.
- Spectra with a signal to noise ratios (SNR) > 25 are required to ensure a correlation of MR and histopathological data with a high sensitivity and specificity using visual inspection protocols.
- Multivariate analysis methods (Computerised Consensus Diagnosis, CCD) distinguishes benign and malignant breast lesions with high sensitivity and specificity including spectra with SNR<25.
- CCD predicts the presence or absence of vascular invasion and lymph node involvement for patients with invasive breast lesions.
- FNA breast specimens must be analysed by MRS within six months of collection to maintain the correlation with histopathological data.
- FNA specimens obtained through the skin generate MR spectra of adequate quality for analysis.
- Two dimensional MRS fails to discriminate between breast tissues (due to large lipid contribution to the spectra) or breast FNAs (due to inadequate signal to noise).
- Proton MRS on FNA and Magic Angle Spinning (MAS) MRS detects metastatic disease in axillary lymph nodes from breast cancer patients.

REPORTABLE OUTCOMES

Manuscripts, Abstracts and Presentations;

1. Mackinnon WB, Barry PA, Malycha PL, Gillett DJ, Russell P, Lean, CL, Doran, ST, Barraclough BH, Bilous M, Mountford CE, FNB specimens of benign breast lesions distinguished from invasive cancer *ex vivo* with proton MRS, *Radiology*,204:66,1997.
2. Lo W, Lean CL, Dowd S, Malycha PL, Russell P and Mountford CE, Fine-needle biopsy of human lymph nodes. *Proc. Int. Soc. Mag. Res. Med.*, 1: 327, 1998.
3. Mountford CE, Breast Cancer and MRS, *Life Sciences*, Vol 10 (5) p 22, 1998.
4. Malycha PL and Mountford CE, Magnetic Resonance Spectroscopy and Breast Cancer. *Australian and New Zealand Journal of Surgery*, 68, 859, 1998.
5. Himmelreich U, Mackinnon WB, Barry P, Russell P, Neilson G and Mountford CE. Proton MR for Pathological Cancer Diagnosis in Fine Needle Biopsy Specimen of Breast Cancer Lesions. *Proc. Int. Soc. Magn. Res.*, 788-789, 1998.
6. Lo W, Dowd S, Malycha P, Russell P, Mountford CE and Lean CL, Detection of Metastases in Lymph Nodes of Breast Cancer Patients Using Proton Magic Angle Spinning (MAS) MRS. *Proc. Int. Soc. Mag. Res. Med.*, 1: 451,1999.

Funding Applied For Based on Work Supported by the Award;

1. NHMRC, Clinical Centres of Excellence, 1998, 4 Years
2. US Army Medical Defense and Materiel Command, Early Detection of Breast Cancer Using Magnetic Resonance Techniques, 2000, 4 years
3. NHMRC, Detection of Metastases in Sentinel Nodes from Patients with Breast Cancer Using Proton MRS, 2000, 3 years
4. Leo and Jenny Foundation, Detection of Metastases in Sentinel Nodes from Patients with Breast Cancer Using Proton MRS, 2000, 1 year.

CONCLUSIONS 1997/98

- **This project is proceeding as outlined in the original document and as described above.**
- **Of the three “purposes” listed on page 6 all three are underway.**
- **Hypotheses 1 and 2 (page 6) have been shown to be correct. Data collected so far indicate that hypothesis 4 is also correct.**
- **No unforeseen difficulties have been encountered and the program is proceeding to schedule.**

CONCLUSIONS 1998/99

- **The project has proceeded as outlined in the original document with the addition of MRS detection of metastatic breast cancer in the axillary lymph nodes of breast cancer patients. Accurate identification of lymph node metastases is of primary importance in the staging and therefore management of breast cancer patients.**
- **All three purposes listed on page 7 are underway.**
- **Hypotheses 1 and 2 have now been shown to be correct by both visual inspection and CCD (multivariate analysis) methods. Additional data support hypothesis 4 also being correct.**
- **Difficulties that have been encountered include:**
 - **Small numbers of lobular cancers available**
 - **Problem of incomplete water suppression affecting multivariate analysis methods. Difficulty overcome with new pulse sequences.**
 - **Signal to noise ratio affecting sensitivity and specificity of visual inspection method. This was overcome using CCD (multivariate analysis) methods.**

REFERENCES (*References additional to original document in bold*)

1. Ferenezzy A, Winkler B (1987): *In: Blaustein's Pathology of the Female Genital Tract*, Kuman RJ (ed). Springer-Verlag, New York, Chap. 8, pp.218-256.
2. Mountford CE, Lean CL, Mackinnon WB, Russell, P (1993a): The use of proton MR in cancer pathology, in: *Annual Reports on NMR spectroscopy*, (ed.) G.A. Webb, Academic Press, Vol 27, pp. 173-215.
3. Cross KJ, Holmes KT, Mountford CE, Wright PE (1984): Assignment of acyl chain resonances from membranes of mammalian cells by two-dimensional NMR methods. *Biochemistry* 23:5895-5897.
4. May GL, Wright LC, Holmes KT, Williams PG, Smith, ICP, Wright PE, Fox RM, Mountford CE (1986): Assignment of methylene proton resonances in NMR spectra of embryonic and transformed cells to plasma membrane triglyceride. *J. Biol. Chem.* 261:3048-3053.
5. Mountford CE, Delikatny EJ, Dyne M, Holmes KT, Mackinnon WB, Ford R, Hunter JC, Truskett ID, Russell, P (1990): Uterine cervical punch biopsy specimens can be analysed by ¹H MRS. *Magn. Reson. Med.* 13:324-331.
6. Sze DY, Jardetzky O (1990): Determination of metabolite and nucleotide concentrations in proliferating lymphocytes by ¹H NMR of acid extracts. *Biochim. Biophys. Acta*, 1054:181-197.
7. Lean CL, Mackinnon WB, Mountford CE (1991): Fucose in ¹H COSY spectra of plasma membrane fragments shed from human malignant colorectal cells. *Magn. Reson. Med.* 20:306-311.
8. Lean CL, Mackinnon WB, Delikatny EJ, Whitehead RH, Mountford CE (1992): Cell surface fucosylation and magnetic resonance spectroscopy characterization of human malignant colorectal cells. *Biochemistry* 31:11095-11105.
9. Mackinnon WB, May GL, Mountford CE (1992a): Esterified cholesterol and triglyceride are present in plasma membranes of Chinese hamster ovary cells. *Eur. J. Biochem.* 205:827-839.
10. Delikatny EJ, Russell P, Hunter JC, Hancock R, Atkinson K, van Haften-Day C, Mountford CE (1993): Proton MR and human cervical neoplasia. I. *Ex vivo* spectroscopy allows distinction of invasive carcinoma of the cervix from carcinoma *in situ* and other preinvasive lesions. *Radiology* 188:791-796.
11. Russell P, Lean CL, Delbridge L, May G, Dowd S, Mountford CE (1994): Proton magnetic resonance and human thyroid neoplasia. I: Discrimination between benign and malignant follicular thyroid neoplasms by magnetic resonance spectroscopy. *Am J. Med.* 96:383-388.
12. Mountford CE, Saunders JKS, May GL, Holmes KT, Williams PG, Fox RM, Tattersall MHN, Barr JR, Russell P, Smith ICP (1986): Classification of human tumours by high-resolution magnetic resonance spectroscopy. *The Lancet* i:651-654.
13. Mountford CE, Tattersall MHN (1987): Proton magnetic resonance spectroscopy and tumour detection, in: *Cancer Surveys*, 6:285-314.
14. Mackinnon WB, Russell P, May GL, Mountford CE (1993): Cell surface fucosylation identifies human ovarian serous epithelial tumours. *Proc. Soc. Magn. Reson. Med.* 3:1156.
15. May GL, Wright LC, Dyne M, Mackinnon WB, Fox RM, Mountford CE (1988): Plasma membrane lipid composition of vinblastine sensitive and resistant human leukaemic lymphoblasts. *Int. J. Cancer* 42:728-733.
16. Mountford CE, Mackinnon WB, Bloom M, Burnell EE, Smith ICP (1984): NMR methods for characterizing the state of the surfaces of complex mammalian cells. *J. Biochem & Biophys Meth.* 9:323-330.

17. Delikatny EJ, Hull WE, Mountford CE (1991): The effect of altering time domains and window functions in two-dimensional proton COSY spectra of biological specimens. *J. Magn. Reson.* 94:563-573.
18. Hakomori S (1989): Aberrant glycosylation in tumours and tumour-associated carbohydrate antigens. *Adv. Cancer Res.* 52:257-331.
19. Kim YS, Yuan M, Itzkowitz SH, Sun Q, Kajzu T, Palekar A, Trump BF, Hakomori S (1986): Expression of Le^y and extended Le^y blood group-related antigens in human malignant, premalignant, and nonmalignant colonic tissue. *Cancer Res.* 46:5985-5992.
20. Wright LC, May GL, Gregory P, Dyne M, Holmes KT, Williams PG, Mountford CE (1988): Inhibition of metastatic potential by fucosidase: an NMR study identifies a cell surface metastasis marker. *J. Cell. Biochem.* 37:49-59.
21. Lean CL, Newland RC, Ende PA, Bokey EL, Smith ICP, Mountford CE (1993a): Assessment of human colorectal biopsies by ¹H MRS: correlation with histopathology. *Magn. Reson. Med.* 30:525-533.
22. Leibovitz A, Stinson JC, McCoombs (III) WB, McCoy CE, Mazur KC, Mabry ND (1976). Classification of human colorectal adenocarcinoma cell lines. *Cancer Res.*, 36:4562-4569.
23. Whitehead RH, Macrae FA, St. John DJB, Jeng MA (1985): A colon cancer cell line (LIM1215) derived from a patient with inherited nonpolyposis colorectal cancer. *J. Natl. Cancer Inst.* 74:759-765.
24. Rutzky LP (1984): The biology of human colon tumor cells in culture. *Adv. in Cell Culture*, 4:47-83.
25. Whitehead RH, Jones JK, Gabriel A, Lukeis RE (1987): A new colon carcinoma cell line (LIM1863) that grows as organoids with spontaneous differentiation into crypt-like structures *in vitro*. *Cancer Res.* 47:2683-2689.
26. Paraskeva C, Buckle BG, Sheer D, Wigley CB (1984): The isolation and characterization of colorectal epithelial cell lines at different stages in malignant transformation from familial polyposis coli patients. *Int. J. Cancer* 34:49-56.
27. Paraskeva C, Finerty S, Powell S (1988): Immortalization of a human colorectal adenoma cell line by continuous *in vitro* passage: possible involvement of chromosome 1 in tumour progression. *Int. J. Cancer*, 41:908-912.
28. Williams AC, Harper SJ, Paraskeva C (1990): Neoplastic transformation of a human colonic epithelial cell line: *in vitro* evidence for the adenoma to carcinoma sequence. *Cancer Res.* 50:4724.
29. Mackinnon WB, Lean C, Hancock R, Huschtscha L, Mountford CE (1992b): Cell surface fucosylation reflects loss of cellular differentiation in human colorectal cancer. *Proc. Soc. Magn. Reson. Med.* 2:3531.
30. Mackinnon WB, Huschtscha LI, Dent K, Hancock R, Paraskeva C, Mountford CE. (1994) Cellular differentiation in human colorectal carcinoma and adenoma cell lines reflected in proton magnetic resonance spectra *Int. J. Cancer* 59:248-261.
31. Ende D, Lean C, Mackinnon W, Bokey EL, Chapuis P, Newland R, Mountford C (1993a): Colorectal tissues assessed *ex vivo* by proton magnetic resonance spectroscopy, *Proc. Tripartite Colorectal Surgery Meeting*, Sydney.
32. Ende DA, Lean CL, Mackinnon WB, Chapuis P, Newland R, Russell P, Bokey EL, Mountford CE (1993b): Human colorectal adenoma-carcinoma sequence documented by ¹H MRS (*ex vivo*). *Proc. Soc. Magn. Reson. Med.* 2:1033.
33. Somorjai RL, Nikulin AE, Kuesel AC, Prefontaine M, Mikhael N, Smith ICP (1992):

- Classification of cervical biopsies based on ^1H NMR spectral information using feature extraction methods. *Proc. Soc. Magn. Res. Med.* p.56.
34. Kuesel AC, Kroft T, Saunders JK, Prefontaine M, Mikhael N, Smith ICP (1992): A simple procedure for obtaining high quality NMR spectra of semiquantitative value from small tissue specimens. *Magn. Reson. Med.* 27:349-355.
 35. Kunnecke BE, Delikatny EJ, Hunter JC, Russell P, Mountford CE (1994): Proton magnetic resonance and human cervical neoplasia II: *Ex vivo* chemical shift imaging. *J. Magn. Reson.* 104B:135-142.
 36. Fearon ER, Vogelstein B (1990): A genetic model for colorectal tumorigenesis. *Cell* 61:759-767.
 37. Mazzaferri EL (1993): Management of the solitary thyroid nodule. *New Eng. J. Med.* 328:553.
 38. Delbridge L, Lean CL, Russell P, May GL, Roman S, Dowd S, Reeve TS, Mountford CE (1994): Proton magnetic resonance and human thyroid neoplasia. II: Potential avoidance of surgery for benign follicular neoplasms. *World J. Surg.* 18:512-517.
 39. Lean CL, Delbridge L, Russell P, May GL, Roman S, Fahey III TJ, Dowd S, Mountford CE. (1995) Proton magnetic resonance and human thyroid neoplasms II: diagnosis of benign follicular adenomas by fine needle biopsy. *J. Clin. Endocrin. & Met.* 80:1306-1311.
 40. Rutter A, Kunnecke B, Russell P, Delbridge L, Mountford CE. (1995) Proton magnetic resonance and human thyroid neoplasia III: *Ex vivo* chemical shift microimaging *J. Mag Res.* B110:240-248.
 41. Mountford CE, Lean CL, Hancock R, Dowd S, Mackinnon WB, Tattersall MHN, Russell P (1993b): Magnetic resonance spectroscopy detects cancer in draining lymph nodes *Inv. Metastasis* 13:57-71.
 42. Daly PF, Cohen JS (1989): Magnetic resonance spectroscopy of tumors and potential *in vivo* clinical applications: a review. *Cancer Res.* 49:770-779.
 43. Krzanowski WJ (1988): *Principles of Multivariate Analysis - A User's Perspective* Oxford Science Publications, Clarendon Press, Oxford.
 44. Hertz J, Krogh A, Palmer RG (1991): *Introduction to the Theory of Neural Computation.* Addison- Wesley Publishing Co., Redwood City, California.
 45. Lachenbruch PA (1975): *Discriminant Analysis* Hafner press, London.
 46. Koza JR (1992): *Genetic Programming* MIT Press, Cambridge, Massachusetts.
 47. Somorjai RL, Pizzi N, Nikulin A, Jackson R, Mountford CE, Russell P, Lean CL, Delbridge L, Smith ICP (1993): Thyroid neoplasms: classification by means of consensus multivariate analysis of ^1H MR spectra. *Proc. Soc. Magn. Res. Med.* 1:72.
 48. Williams P, Saunders JK, Dyne M, Mountford CE, Holmes KT (1988): Application of a T_2 -filtered COSY experiment to identify the origin of slowly relaxing species in normal and malignant tissue. *Magn. Reson. Med.* 7:463-471.
 49. Lean CL, Russell P, Delbridge L, May GL, Dowd S, Mountford CE (1993b): Metastatic follicular thyroid diagnosed by ^1H MRS (*ex vivo*). *Proc. Soc. Magn. Res. Med.* 1:71.
 50. Yoogeswaran G, Granberg A, Welsh RM, Kiessling R (1983): Interferon induced increase in neuraminidase-releasable sialic acid and glycosphingolipid metabolism in mouse lymphoma and L1210 leukemic cell lines: correlation with susceptibility to natural killer cell-mediated lysis. *Int. J. Cancer* 31:501-507.
 51. Bolscher JGM, Schallier DCC, Smets LA, van Rooy H, Collard JG, Bruyneel EA, Mareel MMK (1986): Effect of cancer related and drug induced alterations in surface carbohydrates on the invasive capacity of mouse and rat cells. *Cancer Res.* 46:4080-4086.
 52. Dennis JW, Laferte S (1987): Tumor cell surface carbohydrate and the metastatic phenotype. *Cancer Metastasis Reviews* 5:185-204.
 53. Bresalier RS, Rockwell RW, Dahiya R, Duh QY, Kim YS (1990): Cell surface sialoprotein

- alterations in metastatic murine colon cancer cell lines selected in an animal model for colon cancer metastasis. *Cancer Res.* 50:1299-1307.
54. Schirmacher V, Altevogt P, Fogel M, Dennis J, Waller CA, Barz D, Schwartz R, Cheingsong-Popov R, Springer G, Robinson PJ, Nebe T, Brossmer W, Vlodaysky I, Paweletz N, Zimmerman H-P, Uhlenbruck G (1982): Importance of cell surface carbohydrates in cancer cell adhesion. *Invasion Metastasis*, 2:313-360.
 55. Fagin JA, Matsuo K, Karmaker A, Chen DL, Tang S, Koeffler HP (1993): High prevalence of mutations of p53 gene in poorly differentiated human thyroid carcinomas. *J. Clin. Invest.* 91:179-184.
 56. Jesson JP, Meakin P, Kneissell G (1973): Homonuclear decoupling and peak elimination of Fourier Transform nuclear magnetic resonance. *J. Amer. Chem. Soc.* 95:618-620.
 57. Bax A, Freeman R (1981): Investigation of complex networks of spin-spin coupling by two-dimensional NMR. *J. Magn. Reson.* 44:542-561.
 58. Dingley AJ, King NJC, King GF (1992): An NMR investigation of the changes in plasma membrane triglyceride and phospholipid precursors during the activation of T-lymphocytes. *Biochemistry* 31:9098-9106.
 59. Russell P, Bannatyne P (1989): *In: Surgical Pathology of the Ovaries.* Churchill Livingstone, Edinburgh, Chapters 22 - 31, pp.190-314.
 60. Kaplan EL, Meier P (1958): Nonparametric estimation from incomplete observations. *J. Amer. Stat. Assoc.* 53:457-481.
 61. Cox DR (1972): Regression models and life tables. *J. Roy. Stat. Soc. [B]* 34:187-202.
 62. **Nikulin AK, Dolenko B, Bezabeh T & Somorjai RL. Near-optimal region selection for feature space reduction: two novel preprocessing methods for classifying MR spectra. *NMR in Biomedicine* 11: 209-216; 1998.**
 63. **Tsang-Lin Hwang and A.J. Shaka: Water suppression that works. Excitation sculpting using arbitrary waveforms and pulsed field gradients. *J. Magn. Reson.* 112 (1995), 275-279**

APPENDIX I

ACRONYM /SYMBOL DEFINITION

1D	-	one dimensional
2D	-	two dimensional
^1H	-	proton
12p	-	chromosome 12 p (short) arm
18q	-	chromosome 18 q (long) arm
CA125	-	tumour marker
CA153	-	tumour marker
cERB2	-	tumour marker
CH/CH₂	-	methine to methylene ratio
CH₂/CH₃	-	methylene to methyl ratio
CIN	-	cervical intraepithelial neoplasia
CINI	-	cervical intraepithelial neoplasia - stage I
CINII	-	cervical intraepithelial neoplasia - stage II
CINIII	-	cervical intraepithelial neoplasia - stage III
CIS	-	carcinoma <i>in situ</i>
CPMG	-	Carr-Purcell-Meiboom-Gill
COSY	-	COrelated SpectroscopY
CW	-	continuous wave
dB	-	decibel
D₂O	-	deuterium oxide
ER	-	oestrogen receptor
f₁ and f₂	-	frequency in the first and second dimensions of a 2D MR experiment
FAA	-	formalin:acetic acid:alcohol
FID	-	free induction decay
FNB	-	fine needle biopsy
Fuc	-	fucose
GB	-	Gaussian broadening
G-CSF	-	granulocyte colony stimulating factor
H₅-H₆	-	coupling between protons attached to the C ₅ and C ₆ of

	-	carbohydrate moieties
Hz	-	Hertz
K-ras	-	oncogene
LB	-	Lorentzian broadening
Le^y	-	Lewis ^y (antigen)
MHz	-	mega Hertz
MRI	-	magnetic resonance imaging
MRS	-	magnetic resonance spectroscopy
MR	-	magnetic resonance
NRC	-	National Research Council of Canada
p53	-	tumour supressor gene
PABA	-	p-aminobenzoic acid
PBS	-	phosphate buffered saline
PCA	-	principal component analysis
ppm	-	parts per million (units of chemical shift)
PR	-	progesterone receptor
SFNAB	-	stereotactic fine needle aspiration biopsy
t₁ and t₂	-	first and second time domains in a 2D MR experiment
T1	-	tumour size less than 2 cm
T2	-	tumour size 2 - 5 cm
T3	-	tumour size greater than 5 cm
T₂	-	spin-spin (transverse) relaxation
Thr/Fuc	-	threonine/fucose
TIL	-	tumour infiltrating lymphocytes1.

Wanda B. Mackinnon, PhD • Peter A. Barry, MBBS • Peter L. Malycha, MBBS, FRACS
 David J. Gillett, MBBS, MS, FRACS • Peter Russell, MBBS, MD, FRCPA
 Cynthia L. Lean, PhD • Sinead T. Doran, BSc • Bruce H. Barraclough, MBBS, DDU, FRACS
 Michael Bilous, MBBS, FRCPA • Carolyn E. Mountford, DPhil

Fine-Needle Biopsy Specimens of Benign Breast Lesions Distinguished from Invasive Cancer *ex Vivo* with Proton MR Spectroscopy¹

PURPOSE: To determine whether invasive breast cancer can be distinguished from benign lesions with proton magnetic resonance (MR) spectroscopy *ex vivo* on the basis of altered cellular chemistry.

MATERIALS AND METHODS: Two hundred eighteen fine-needle biopsy specimens were obtained in 191 patients undergoing surgery and were analyzed with proton MR spectroscopy. MR spectroscopic and histopathologic findings were compared.

RESULTS: Invasive carcinoma produced increased signal at 3.25 ppm, attributable to choline-containing metabolites. Discrimination between invasive carcinoma ($n = 82$), benign lesions ($n = 106$), or carcinoma *in situ* ($n = 17$) was based on the resonance intensity at 3.25 ppm standardized to the resonance at 3.05 ppm ($P < .001$). The ratio of peak height intensities of resonances at 3.25 to those at 3.05 ppm was less than 1.7 in 102 of the 106 normal or benign lesions. All carcinoma *in situ* specimens with comedonecrosis or a microinvasive component ($n = 6$) were categorized at MR spectroscopy with invasive carcinoma, while others with *in situ* disease alone were categorized with benign lesions ($n = 11$). The sensitivity and specificity of MR spectroscopy in fine-needle biopsy specimens in distinguishing benign lesions from invasive cancer were 95% and 96%, respectively.

CONCLUSION: Proton MR spectroscopy of fine-needle biopsy specimens provides objective diagnostic information that complements findings of conventional preoperative investigations of breast lesions.

IN Australia, breast cancer is the leading cause of cancer-related death in women (1). The incidence of breast cancer outranks all other cancers in women older than 35 years. In the past decade, the incidence has risen by 25%, and the lifetime risk (from birth to the age of 74 years) of breast cancer in white women is comparable to Western world figures at one in 13 (1).

Recent improvement in breast cancer patient outcome is due to earlier diagnosis and more effective management (2,3). The combination of physical examination, mammography, and fine-needle aspiration cytologic analysis (triple assessment) is to date the most sensitive method for the preoperative diagnosis of clinically and radiographically detected breast lesions. While triple assessment has a high probability of detection of all malignant lesions, the suboptimal specificity results in diagnostic uncertainty; thus, open biopsy is needed to exclude malignancy in many women.

Physical examination has limitations due to individual variation in breast consistency, the site and size of the lesion (lesions smaller than 1 cm are usually impalpable), and the presence of a diffuse versus discrete tumor. Screening mammography guidelines ensure that biopsy is performed in approximately one benign lesion

for every malignant lesion detected (4). Even so, 10%–40% of palpable breast cancers are missed at mammography alone, especially in women younger than 50 years in whom radiographically opaque breast tissue may obscure changes associated with malignancy (5–8). Fine-needle aspiration cytologic analysis has a sampling error rate in the range of 1%–15% (9), which partly explains the varied sensitivity. While the complete sensitivity of fine-needle aspiration biopsy is 81%–97% (10), this includes the 50%–80% of cases with atypical and suspicious diagnoses in which cancer is typically confirmed histologically with open biopsy (11).

A technology that monitors cellular chemistry, which correlates with different cell behaviors, could offer both independent and objective assessment of breast tissue. The potential then would exist to identify a predisposition toward or early features of breast cancer and offer interventions aimed at reducing tumor development. Proton magnetic resonance (MR) spectroscopy is one diagnostic modality that has been successfully applied to monitor tumor development and progression in other organs (12–18). Pre-invasive cancer of the uterine cervix can be distinguished from invasive cancer by means of proton MR spectroscopy, with a sensitivity and speci-

Index terms: Breast, biopsy, 00.1261, 00.1262 • Breast neoplasms, diagnosis, 00.30 • Breast neoplasms, MR, 00.12145, 00.30 • Magnetic resonance (MR), spectroscopy, 00.12145

Abbreviation: DCIS = ductal carcinoma *in situ*.

Radiology 1997; 204:661–666

¹ From the Institute for Magnetic Resonance Research, University of Sydney, Blackburn Bldg, D06, Sydney, NSW 2006, Australia (W.B.M., P.A.B., P.R., C.L.L., S.T.D., C.E.M.); the Department of Surgery, Royal Adelaide Hospital, Adelaide, Australia (P.L.M.); the Department of Surgery, Repatriation General Hospital, Concord, Australia (D.J.G.); and the Departments of Surgery (B.H.B.) and Anatomical Pathology (M.B.), Westmead Hospital, Sydney, Australia. Supported by Australian National Health and Medical Research Council project grant 950215. Received March 7, 1997; revision requested April 21; revision received May 30; accepted June 2. Address reprint requests to C.E.M.

ficity of 98% and 94%, respectively (13). The technique also distinguishes between genuinely benign and malignant follicular lesions in the human thyroid (18) and helps discriminate between degrees of loss of cellular differentiation in ovarian tumors (16).

Preliminary unlocalized one- and two-dimensional proton MR spectroscopic examinations of excised breast tissue showed increased levels of glycerophosphocholine and phosphocholine in invasive breast carcinoma compared with levels in benign fibroadenomas (19). Specimens of benign fibrocystic disease were characterized by an absence of resonances from choline, amino acids, and other metabolites. However, the high adipose content in excised breast tissue resulted in major difficulty in attaining adequate spectral resolution. The intense broad MR resonances from this fat often masked other diagnostic resonances in the one-dimensional spectrum. This problem is largely overcome by applying a T2 filter (Bruker, Karlsruhe, Germany; Carr-Purcell-Meiboom-Gill sequence) during data collection (20), postacquisitional data processing, or both (21). A simpler remedy was to optimize specimen collection. Collection procedures substantially affected the amount of exogenous fat sampled. Fine-needle aspiration biopsy methods developed for thyroid sampling (17) provided cellular material adequate for assessment with MR spectroscopy with fat levels lower than those in excised tissue.

Our objectives for this study were (a) to assess the sensitivity and specificity of proton MR spectroscopy in fine-needle biopsy specimens for delineating invasive breast cancer *ex vivo*, (b) to determine whether carcinoma *in situ* can be distinguished from invasive carcinoma, and (c) to compare diagnosis with MR spectroscopy in fine-needle biopsy specimens with diagnosis with traditional preoperative investigations such as physical examination, mammography, and fine-needle aspiration cytologic analysis.

MATERIALS AND METHODS

All histopathologic and MR spectroscopic analyses were blind. MR spectroscopic data were correlated with clinicopathologic criteria after all reports were filed.

Patients

Two hundred eighteen fine-needle biopsy or tissue specimens for MR spectroscopic analysis or correlative histopatho-

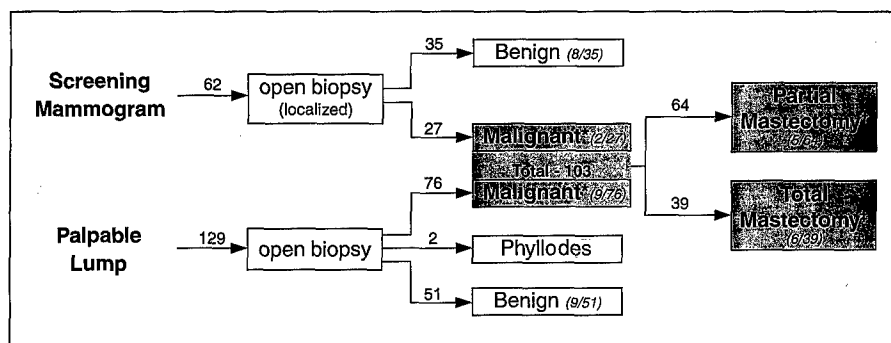


Figure 1. Flow chart for management and final histopathologic diagnosis. The numbers in parentheses indicate the numbers of patients who had an uncertain cytologic diagnosis during the diagnostic work-up. The numbers alongside the arrows indicate the total numbers of patients. Specimens obtained in 11 patients were rejected. * = invasive and *in situ* carcinoma, † = lumpectomy and quadrantectomy (nine of these patients underwent complete mastectomy [not shown]), ‡ = 12 for *in situ* carcinoma and 27 for invasive carcinoma.

logic analysis, respectively, were obtained in 191 consecutive patients undergoing diagnostic biopsy or definitive treatment (lumpectomy, quadrantectomy, or mastectomy) for histologically proved invasive breast cancer. Indications for surgery included mammographically detected palpable lesions, as well as palpable mass lesions, which had suspicious mammographic, fine-needle aspiration cytologic analysis, or clinical examination findings (Fig 1). The age range of patients was 20–81 years (mean age \pm standard deviation, 52 years \pm 14). When mastectomy for invasive carcinoma was performed, control specimens of macroscopically uninvolved breast tissue (which was later confirmed histologically) were obtained in the same patient ($n = 27$).

Specimen Collection

Previous findings of MR spectroscopic analysis in fine-needle biopsy thyroid specimens had established that as few as 10^6 cells are required to obtain one-dimensional MR spectroscopic data with an adequate signal-to-noise ratio in less than 15 minutes (256 accumulations) (17). To acquire an adequate breast specimen, fine-needle biopsy was performed with multiple (typically six) passes with a 23-gauge needle either through the resected lesion *ex vivo* ($n = 129$) or *in vivo* after lesion identification during open biopsy ($n = 89$). These techniques could be guaranteed to provide cells from the lesion and, in addition, allowed the aspiration site to be identified at excision. Tissue from the aspiration site (3 mm³) was collected for correlative histopathologic analysis.

Specimen Handling

Cells or tissue specimens were placed in polypropylene vials that contained 300 μ L of phosphate-buffered saline in deuterium oxide. All specimens were immediately immersed in liquid nitrogen and stored at -70°C for up to 6 weeks until MR spectroscopic analysis.

Preparation of Specimens for Proton MR Spectroscopy

Before proton MR spectroscopy, each fine-needle biopsy specimen was thawed and transferred directly to a 5-mm MR spectroscopic tube. The volume was adjusted to 300 μ L with phosphate-buffered saline in deuterium oxide when necessary. The sample tube was fitted with a capillary insert that contained 60 μ L of para-aminobenzoic acid (10 mmol/L in the phosphate-buffered saline-deuterium oxide solution) as an external standard.

Proton MR Spectroscopy

Proton MR spectroscopic assessment of all specimens was performed without knowledge of the final histologic diagnosis.

Data acquisition.—MR spectroscopic experiments were performed at 360 MHz or 8.5 T with a wide-bore spectrometer (model AM-360; Bruker) that was equipped with a computer (model 3000; Aspect, Karlsruhe, Germany) and a standard 5-mm dedicated proton probe head (Bruker). The sample was spun at 20 Hz, and the temperature was maintained at 37°C. Residual water signal was suppressed with selective gated irradiation by using low power (15 dB below 0.2 W). The chemical shifts of resonances were referenced to aqueous sodium 3-(trimethylsilyl)propanesulphonate at 0.00 ppm. One-dimensional spectra were acquired as previously described (19) over a sweep width of 3,597 Hz (10.0 ppm) by using a 90° pulse, 8,192 data points, 256 free induction decays, an acquisition time of 1.14 seconds, and a relaxation delay of 2.00 seconds, which resulted in a pulse repetition time of 3.14 seconds.

Data processing.—Data processing for each specimen was performed independently by two operators (P.A.B., S.T.D.) without access to the histopathology reports; one used the spectrometer's computer (model 3000; Aspect), and the other used a Unix workstation (model X32; Bruker). A line broadening of 3.0 Hz was applied to the data before Fourier transfor-

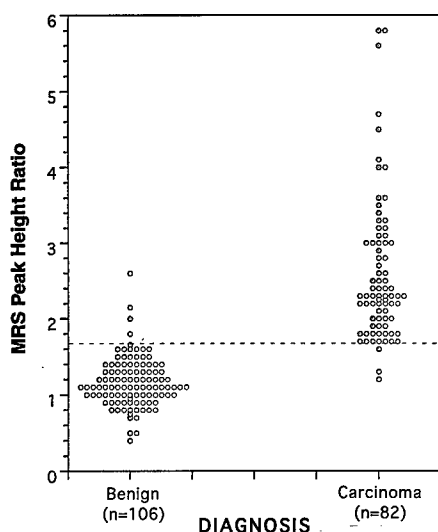


Figure 2. Breast fine-needle biopsy MR spectroscopic (MRS) findings of unequivocally benign versus infiltrating carcinoma. MR spectroscopic ratios determined as shown in Figure 3. Data are grouped on the basis of the final histopathologic findings in tissue specimens from the aspiration site.

Table 1
Summary of Histologic Subtypes of Fine-Needle Biopsy Specimens

Histopathologic Subtype	No. of Lesions
Benign (n = 106)	
Fibrocystic changes	68
Fibroadenoma	15
Ductal hyperplasia (mild to florid)	9
Fat necrosis	4
Sclerosing adenosis	2
Radial scar	2
Atypical ductal hyperplasia	2
Ductal ectasia	2
Miscellaneous	2
Phyllodes tumor	2
DCIS* (n = 17)*	
High grade	10
Low grade	1
Comedonecrosis	2
With microinvasion	4
Invasive carcinoma (n = 82)	
Ductal carcinoma of no special type	66
Ductal carcinoma of no special type with an extensive intraductal component	7
Lobular carcinoma	5
Tubular carcinoma	4

Note.—Histopathologic findings are the dominant findings in correlative histopathologic samples.

* DCIS = ductal carcinoma in situ.

mation. Zero- and first-order phase corrections were used in the data. Baselines were corrected by using a fourth-order polynomial baseline-correction routine.

Data analysis.—The ratio of the peak height intensities of spectral resonances at 3.25 ppm to those at 3.05 ppm (the MR spectroscopic ratio) was calculated by each operator, and the two results for each speci-

men were averaged. This ratio was used to generate Figure 2. Data were rejected because of an inadequate signal-to-noise ratio (in 11 specimens) if the peak intensity of the CH_2 resonance at 1.3 ppm in the fine-needle biopsy specimen spectrum was less than 40% of the intensities of those spectra generated by the external standard or if the calculated signal-to-noise ratio was less than 25.

Histopathologic Analysis

Diagnostic correlation was attained by comparing the diagnosis made with the MR spectroscopic ratio with the postoperative hospital histopathologic report in each patient. The final histologic diagnoses in the study group are shown in Table 1.

Without reference to clinical or MR spectroscopic data, cytologic analysis of the aspirate after MR spectroscopic analysis was attempted. However, cellular detail was compromised by autolytic changes, and this approach was not pursued. Therefore, to verify fine-needle biopsy sampling accuracy, a single pathologist (P.R.) separately performed histopathologic assessment in tissue specimens removed from the aspiration sites of the MR spectroscopic specimens (see Specimen Collection). These tissue specimens were thawed; fixed in a mixture of formalin, acetic acid, and alcohol; embedded in paraffin; sectioned at 7 μm ; stained with hematoxylin and eosin according to standard protocols; and reviewed by the pathologist under the light microscope without access to the clinical or MR spectroscopic data. Tissue preservation, the abundance of epithelial cells relative to stroma, and the presence of potentially confounding factors such as fat and inflammatory cells were reported in addition to the principal diagnosis.

Other Clinical Correlations

Comparisons were made with findings of other preoperative diagnostic investigations, which included physical examination, mammography, and fine-needle aspiration cytologic analysis (separate specimen than that in MR spectroscopy).

RESULTS

Sample Collection

The problem of high levels of MR-measurable fat in the solid breast tissue was successfully overcome with fine-needle aspiration biopsy. The resultant improvement in spectral resolution due to the reduction in exogenous fat was confirmed by means of histopathologic analysis (data not shown).

In 207 of the 218 fine-needle biopsy specimens obtained, sufficient cellular material was collected for adequate MR assessment under the chosen ex-

perimental conditions. Eleven specimens were discarded for technical reasons (see Materials and Methods, Proton MR Spectroscopy, Data analysis).

Benign Lesions versus Invasive Carcinoma

Invasive carcinoma was identified by means of resonances at 3.25 ppm that were attributable to choline-containing metabolites (Fig 3). A discrimination between invasive carcinoma ($n = 82$) and normal or benign tissue ($n = 106$) was made on the basis of the intensity of the 3.25 ppm resonance standardized to the resonance intensity at 3.05 ppm, indicating contributions from creatine, phosphocreatine, or lysine ($P < .001$, Mann-Whitney U test) (Fig 2). A receiver operating characteristic curve calculated by using this intensity ratio is shown in Figure 4.

Of 106 benign or normal samples, 102 had an MR spectroscopic ratio of less than 1.7. Four false-positive findings were obtained in three palpable fibroadenomas (fine-needle aspiration cytologic analysis had been performed in none of them) and in one moderate ductal hyperplastic lesion. The diagnoses were based on correlative histopathologic findings.

Fine-needle biopsy in four of 82 carcinomas had an MR spectroscopic ratio of less than 1.7. Correlative histopathologic findings in specimens from the aspiration site showed that one specimen had only benign fibrocystic changes in this region. The other three specimens were confirmed as invasive carcinoma, but with a marked inflammatory cell infiltrate.

Two specimens with phyllodes tumors were studied. The first was multifocal and had a ratio of more than 1.7, and the second was from a single mass and had a ratio of 1.6. Phyllodes tumors are classified as fibroepithelial proliferations with variable biologic activity. Their behavior ranges from benignity through a propensity to local recurrence to blood-borne metastasis. Both phyllodes tumors were excluded from all statistical analyses.

Carcinoma in Situ

The MR spectroscopic ratios for all samples reported as DCIS on routine hospital histopathology reports are shown in Figure 5. These were grouped according to the correlative histopathologic findings. No in situ disease was detected in the correlative histopathologic analysis of the six samples denoted "benign." Ductal cells had breached the basement membrane

(<1 mm) at one or more foci in the entirety of each of the four DCIS specimens denoted "microinvasion." This group, as well as two specimens of high-grade DCIS with extensive comedonecrosis had ratios of more than 1.7. Specimens that contained only DCIS (10 high grade, one low grade) all had ratios of at most 1.7, which is indicative of a low ratio of choline to creatine and lysine, similar to that in benign lesions.

Clinical Correlations

All cases that were mammographically suspicious ($n = 56$), mammographically negative ($n = 23$), or nondiagnostic ($n = 14$) or that had atypical or suspicious fine-needle aspiration biopsy cytologic findings ($n = 25$) were accurately categorized at MR spectroscopy as benign or malignant, as confirmed with histopathologic analysis of tissue excised from the aspiration site.

MR spectroscopic findings in fine-needle biopsy specimens correlated with the final histologic diagnosis of benign lesions in 96% of cases (Table 2); yet, biopsy was performed because of clinical (34%) or mammographic features (45%) or because of fine-needle aspiration biopsy cytologic analysis results (31%). MR spectroscopic findings in fine-needle biopsy specimens correlated with a malignant histologic diagnosis in 95% of cases (Table 2). While biopsy for all the malignant lesions studied was indicated with the triple assessment, no single preoperative modality was an improvement on MR spectroscopy in the identification of malignancy (physical examination, 84%; mammography, 82%; fine-needle aspiration cytologic analysis, 92%).

DISCUSSION

When compared with the histopathologic analysis, the peak intensity ratio in MR spectroscopy of fine-needle biopsy specimens has a sensitivity and specificity for the differentiation of invasive carcinoma from benign breast lesions of 95% and 96%, respectively. The increase in the ratio observed in carcinoma tissues is most likely due to elevated choline metabolite levels in malignant compared with benign tissues. This is consistent with a higher rate of cellular replication, specifically with increased phospholipid synthesis and membrane turnover (12).

Although triple assessment followed by open biopsy has an overall sensitivity that approaches 100%, it

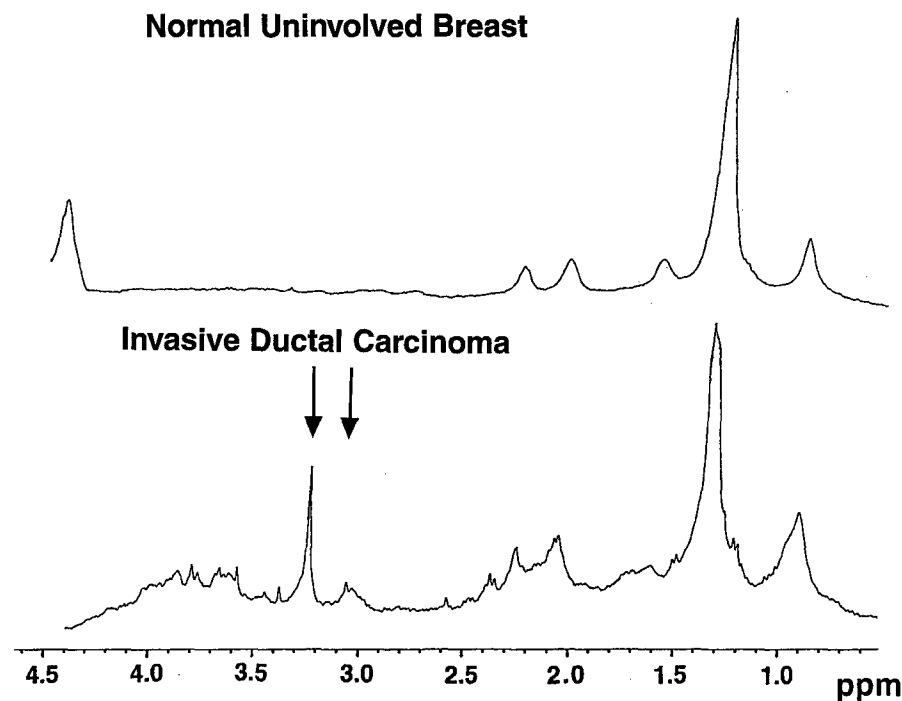


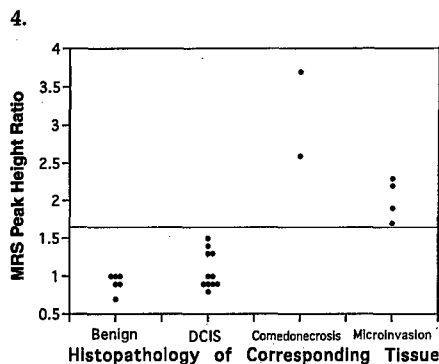
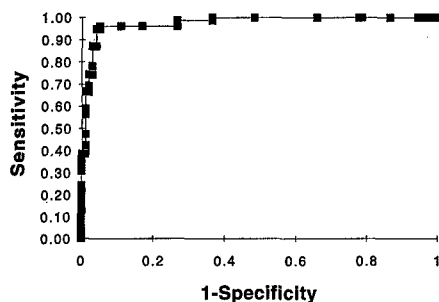
Figure 3. One-dimensional proton MR spectra (256 acquisitions) in fine-needle biopsy specimens obtained in a patient who underwent mastectomy. Spectra for a normal uninvolved breast and a breast with invasive ductal carcinoma. The distinction between normal breast and invasive carcinoma is based on an increase in the *N*-trimethyl resonance at 3.25 ppm normalized to that of creatine at 3.05 ppm (peaks indicated by arrows).

entails a large number of open biopsies for benign disease. This is especially the case when equivocal or suspicious mammographic findings are followed by either atypical or suspicious fine-needle aspiration cytologic or benign cytologic findings that are incongruous with clinical or radiologic findings. In our study, all atypical or suspicious fine-needle aspiration cytologic results in subsequently confirmed benign specimens had a benign MR spectroscopic ratio. While the MR spectroscopic findings were obtained in ex vivo aspirate, MR spectroscopy performed before cytologic analysis in in vivo aspirates may well be a valuable adjunct because it improves the specificity. Therefore, MR spectroscopy in fine-needle biopsy specimens could reduce the number of biopsies performed in benign lesions and could lead to a more conservative approach, such as continued observation or surveillance with repeat fine-needle aspiration cytologic analysis and MR spectroscopy. Used as a complementary modality to triple assessment, MR spectroscopy in fine-needle biopsy specimens may also provide further diagnostic confidence when open biopsy is requested for patient reassurance only.

MR spectroscopy in fine-needle biopsy specimens clearly distinguished pure DCIS without comedonecrosis or

microinvasion (MR spectroscopy ratio, ≤ 1.7) from invasive carcinoma. However, even when DCIS specimens contained comedonecrosis or a few foci of microinvasion, the specimen was categorized in the invasive category with MR spectroscopy in every case. This may demonstrate the selective sampling of necrotic cells or invasive disease in the MR spectroscopic fine-needle biopsy specimens but could also indicate chemical changes that occur in cells that progress from in situ to frankly invasive before morphologic manifestation. Pure DCIS was not distinguished from benign lesions on the basis of the MR spectroscopic ratio; however, more spectral information is available for comparison of the two groups, and this is being investigated. In particular, specific chemical differences characteristic of pure DCIS may be identified with two-dimensional MR spectroscopy. Alternatively, multivariate analysis as previously reported for thyroid neoplasms (22), yet to be undertaken, is likely to improve sensitivity and specificity.

Seventy-eight of the 82 invasive carcinomas had an MR spectroscopic ratio of greater than 1.7. Of the four false-negative specimens, one aspiration sample was found not to contain invasive carcinoma. The remaining three samples all had a marked inflam-



4. Figures 4, 5. (4) Receiver operating characteristic curve of the data from Figure 2 ($n = 188$) calculated from the MR spectroscopic ratios of all specimens. The ratios were ranked, and both the sensitivity and the specificity were calculated for all ratios. (5) MR spectroscopic (MRS) ratios in fine-needle biopsy specimens reported as containing DCIS ($n = 23$) at postoperative histologic analysis. Data are grouped on the basis of the final correlative histopathologic findings.

matory infiltrate, which, if sampled, may have accounted for a ratio of less than 1.7. In all the remaining carcinoma specimens, which includes those that were mammographically negative or had nondiagnostic fine-needle aspiration cytologic analysis results, MR spectroscopy correctly indicated malignancy.

In this study, fine-needle biopsy specimens for MR spectroscopy were collected intraoperatively from the exposed lesion to ensure accurate sampling. If MR spectroscopy in fine-needle biopsy specimens were used as a preoperative diagnostic modality, a sampling error could be introduced, similar to that experienced with fine-needle aspiration cytologic analysis, which would reduce the sensitivity and specificity recorded here. For example, in this patient sample, 14 of 143 cytology reports were nondiagnostic or insufficient. Further studies will directly compare MR spectroscopy with cytology in the same aspirate at the time of clinical assessment.

The potential clinical use of MR spectroscopy in fine-needle biopsy specimens is to complement triple assessment procedures, which would

Table 2
Diagnosis with MR Spectroscopy of Fine-Needle Biopsy Specimens Compared with Histopathologic Diagnosis of Tissue Samples

MR Spectroscopic Finding	Histopathologic Finding (N = 188)	
	Invasive Carcinoma	Normal or Benign
Positive*	78	4
Negative†	4	102

Note.—The sensitivity of MR spectroscopy was 95% (78 true-positive findings of 82 total findings), the specificity was 96% (102 true-negative findings of 106 total findings), the positive predictive value was 95% (78 true-positive findings of 82 total findings), and the negative predictive value was 96% (102 true-negative findings of 106 total findings).

* MR spectroscopic ratio of at least 1.7.

† MR spectroscopic ratio of less than 1.7.

reduce the number of unnecessary biopsies in benign lesions. Management of breast lesions varies, however, from country to country. In Australia, fine-needle biopsy is routinely used as part of the triple assessment; thus, introducing MR spectroscopy as a fourth modality would not alter management. In the United States, core biopsy is used more often. Core biopsy has two potential areas of usefulness, namely, to demonstrate an invasive focus within an area of DCIS and to histologically confirm radiologically suspected benign lesions. It is anticipated that MR spectroscopy in fine-needle biopsy specimens will be able to address both these questions as or more accurately than core biopsy, which would obviate the more invasive procedure. A core biopsy specimen may contain high levels of fat, which makes it unsuitable for MR spectroscopic analysis. Thus, in countries such as the United States, the choice of biopsy procedure will need to be reassessed and the re-introduction of fine-needle biopsy will need to be measured against MR spectroscopy, with the improved sensitivity and specificity.

Furthermore, it is likely that the technical obstacles to in vivo spectroscopy of the breast will be overcome. It has been shown in at least one U.S. site that the diagnostic chemical information reported here is available in vivo. Considerable research and development are required, however, before such techniques will be in routine clinical use.

MR spectroscopy in ex vivo fine-needle biopsy specimens may (a) complement triple assessment and reduce

the number of performances of unnecessary biopsy of benign lesions and (b) obviate open biopsy before the definitive therapy of invasive lesions by increasing the diagnostic specificity of the cytologic analysis. Preoperative diagnosis of breast lesions with proton MR spectroscopy thereby offers potential benefits in management by reducing the potential morbidity related to biopsy and by allaying anxiety due to an equivocal diagnosis. ■

Acknowledgments: The authors thank the Sydney Breast Cancer Institute, Royal Prince Alfred Hospital, Sydney, Australia; the Hanson Centre, Sydney, Australia; and the Institute of Medical and Veterinary Science, Adelaide, Australia for assistance with sample handling and Martin N. H. Tattersall, MBBChir, MD, FRACP, FRCP, for his assistance and guidance with preparation of this manuscript.

References

- Coates M, McCredie M, Armstrong B. Cancer in New South Wales: incidence and mortality, 1993. Sydney, Australia: Cancer Control Information Center, New South Wales Cancer Council, 1996.
- Tabar L, Fagerberg PG, Duffy SW, Day NE, Gad A, Grontoff O. Update of the Swedish two-county program of mammographic screening for breast cancer. *Radiol Clin North Am* 1992; 30:187-210.
- Shapiro S, Venet W, Strax P, et al. Ten-to-14-year effect of screening on breast cancer mortality. *J Natl Cancer Inst* 1982; 69:349-355.
- National Program for the Early Detection of Breast Cancer Monitoring and Evaluation Reference Group. National Program for the Early Detection of Breast Cancer: evaluation of phase one—1 July 1991-30 June 1994. Canberra, Australia: Commonwealth Department of Human Services and Health, 1994.
- Dodd GD. Present status of thermography, ultrasound and mammography in breast cancer detection. *Cancer* 1977; 39: 2796-2805.
- Mahony L, Csima A. Use and abuse of mammography in the early diagnosis of breast cancer. *Can J Surg* 1983; 26:262-265.
- Walker QJ, Gebski V, Langlands AO. The misuse of mammography in the management of breast cancer revisited. *Med J Aust* 1989; 151:509-512.
- Niloff PH, Sheiner NH. False-negative mammograms in patients with breast cancer. *Can J Surg* 1981; 24:50-52.
- Hiller G, Harney M, Legg S, Hart SA. Fine needle aspiration cytology in breast disease management: a four year experience. *Aust NZ J Surg* 1987; 57:239-242.
- Ingram DM, Sterrett GF, Sheiner HJ, Shilkin KB. Fine needle aspiration cytology in the management of breast disease. *Med J Aust* 1983; 2:170-173.
- Hermansen C, Poulsen HS, Jensen J, et al. Diagnostic reliability of combined physical examination, mammography and fine-needle puncture ("triple-test") in breast tumors. *Cancer* 1987; 60:1866-1871.
- Mountford CE, Lean C, Mackinnon WB, Russell P. The use of proton MR in cancer pathology. In: Webb GA, ed. Annual reports on NMR spectroscopy. Vol 27. London, England: Academic Press, 1993; 173-215.

13. Delikatny EJ, Russell P, Hunter JC, et al. Proton MR and human cervical neoplasia. I. Ex vivo spectroscopy allows distinction of invasive carcinoma of the cervix from carcinoma in situ and other preinvasive lesions. *Radiology* 1993; 188:791-796.
14. Russell P, Lean CL, Delbridge L, May G, Dowd S, Mountford CE. Proton magnetic resonance and human thyroid neoplasia. I. Discrimination between benign and malignant follicular thyroid neoplasms by magnetic resonance spectroscopy. *Am J Med* 1994; 96:383-388.
15. Ende DA, Lean CL, Mackinnon WB, et al. Human colorectal adenoma-carcinoma sequence documented by ^1H MRS (ex vivo) (abstr). In: Proceedings of the 12th Annual Scientific Meeting of the Society of Magnetic Resonance in Medicine 1993. Berkeley, Calif: Society of Magnetic Resonance in Medicine, 1993; 1033.
16. Mackinnon WB, Russell P, May GL, Mountford CE. Characterisation of human ovarian epithelial tumours (ex vivo) by proton magnetic resonance spectroscopy. *Int J Gynaecol Cancer* 1995; 5:211-221.
17. Lean CL, Delbridge L, Russell P, et al. Diagnosis of benign follicular thyroid lesions by proton magnetic resonance on fine needle biopsy. *J Clin Endocrinol Metab* 1995; 80:1306-1311.
18. Delbridge L, Lean CL, Russell P, et al. Proton magnetic resonance and human thyroid neoplasia. II. Potential avoidance of surgery for benign follicular neoplasms. *World J Surg* 1994; 18:512-517.
19. Roman S. A ^1H MRS study of breast cancer. Thesis. University of Sydney, Sydney, Australia, 1992.
20. Williams P, Saunders JK, Dyne M, Mountford CE, Holmes KT. Application of a T_2 -filtered COSY experiment to identify the origin of slowly relaxing species in normal and malignant tissue. *Magn Reson Med* 1988; 7:463-471.
21. Delikatny EJ, Hull WE, Mountford CE. The effect of altering time domains and window functions in two-dimensional proton COSY spectra of biological specimens. *J Magn Reson* 1991; 94:563-573.
22. Somorjai RL, Nikulin AE, Pizzi N, et al. Computerized consensus diagnosis: a classification strategy for the robust analysis of MR spectra. I. Application to ^1H spectra of thyroid neoplasms. *Magn Reson Med* 1995; 33:257-263.

CONTINUING MEDICAL EDUCATION

MAGNETIC RESONANCE SPECTROSCOPY AND BREAST CANCER

PETER MALYCHA* AND CAROLYN MOUNTFORD†

*Department of Surgery, Royal Adelaide Hospital and †Institute for Magnetic Resonance Research, Department of Magnetic Resonance in Medicine, University of Sydney, New South Wales, Australia

Key words: breast cancer, fine needle aspiration cytology, magnetic resonance, tumour development.

WHAT IS MAGNETIC RESONANCE?

The magnetic resonance (MR) experiment involves the excitation of a nuclear spin system. After excitation the system returns to equilibrium and depending on the type of experiment, several types of phenomena can be measured providing chemical and/or spatial information. Different nuclei can be examined (e.g. ^{31}P , ^1H and ^{13}C) but the vast majority of medical MR applications observe the proton (^1H) nucleus. The sample assessed by MR may be a fine needle aspiration (FNA) biopsy, a tissue biopsy or a whole patient. If one considers the many protons in a single cell, not to mention an entire organ, the need for computational assistance in collecting and processing the MR data becomes clear.

Magnetic resonance imaging

Magnetic resonance imaging (MRI) gives rise to computer-generated images of water protons within the body which provide detailed spatial information. The MR data, collected at the single frequency of water protons, are reconstructed into an image that allows anatomy and disease to be identified simultaneously. However, water-based MRI techniques are not able to provide the pathological diagnosis offered by current histological or microbiological techniques. For example, the size and position of a brain lesion can be identified by MRI but a biopsy is usually required to distinguish tumour from infection.

Magnetic resonance spectroscopy

Magnetic resonance spectroscopy (MRS) measures protons over a range of frequencies, thus collecting information on a large number of chemical species (including water) present in the sample. The water signal is usually predominant and must therefore be suppressed in order to record chemicals present in much smaller quantities. The basis of MRS is molecular motion. Thus, only chemicals present in reasonable concentrations and mobile on the MR time scale will be recorded.

The magnet in which the data are collected also varies and determines the type of experiment performed. For larger specimens, for example a human body, the bore of the magnet needs to be approximately 60 cm. The strength of the magnet for whole-body MRI is usually 1.5 Tesla, although strengths as high as 4 Tesla whole-body systems are available. For imaging purposes 1.5 Tesla is adequate. However, for spectroscopy, higher field strengths allow greater separation of the many measurable

chemical species and thus for human *in vivo* spectroscopy a 3 or 4 Tesla magnet is of great benefit. Tissue biopsies examined *ex vivo* are assessed using a magnet strength of 8 Tesla with a narrow bore of 10 cm.

HISTORY AND RECENT DEVELOPMENT OF MRS

Magnetic resonance spectroscopy has been used by biochemists for over 30 years for the evaluation of cellular chemistry. Magnetic resonance technology was applied to medical diagnoses with the introduction of MRI. This effectively bypassed spectroscopy, the original science from which MRI was developed. The early experiments using proton MRS for cancer diagnoses were not reproducible. It was originally thought that it was the spectroscopy method at fault. We now know that the chemistry of cancer cells changes from the time the cell ceases to be normal until the patient dies from secondary disease and that the MRS was correctly reporting this ongoing change.

The 'gold standard' for cancer diagnosis, histopathology, relies on alterations to cell morphology and tissue architecture to make a diagnosis. It is clear from retrospective studies of clinical outcome that diagnostic information is being missed when using currently available techniques. Magnetic resonance studies undertaken in Australia over the last two decades have been aimed at addressing this problem, the premise being that diseased cells have pools of chemicals measurable by MRS that are both diagnostic and prognostic. By reporting upon the chemical status of the cell at each stage of tumour development, a temporal study is obtained which records early variations that are not morphologically manifest and thus not detectable by light microscopy. The potential then exists to identify a pre-disposition towards or the early features of cancer and offer intervention aimed at reducing tumour development.

The pioneering work to assess MRS in the characterization of tumour development and progression was originally undertaken in the Department of Cancer Medicine, University of Sydney and is now under way at the Institute for Magnetic Resonance Research (IMRR), established in 1995. Pathologists and surgeons have provided vast quantities of clinical material, the characterization of which has led to a new MRS-based medical science. To date cervix, colon, ovary, lung, thyroid, lymph nodes, oesophagus, prostate, brain and, of course, breast have been studied.

Two consistent outcomes from these research programmes, irrespective of which organ has been studied, are:

1. Invasive biopsies can be distinguished from benign and healthy tissues with a sensitivity and specificity approaching 99%.
2. Pre-invasive states that are morphologically benign and indistinguishable under the light microscope have different chemical fingerprints as measured by MRS.

Correspondence: Peter Malycha, 333 South Terrace, Adelaide 5000, South Australia.
Email: <malycha@hcn.net.au>

Some histologically benign lesions have been identified by MRS as having a chemical profile closer to malignancy than benign. These were all in patients with malignant disease elsewhere in the same organ, indicative of a commitment to malignancy.

BREAST CANCER

Over 250 breast patients took part in the first study.¹ Fine needle aspiration biopsies were taken from the breast and examined

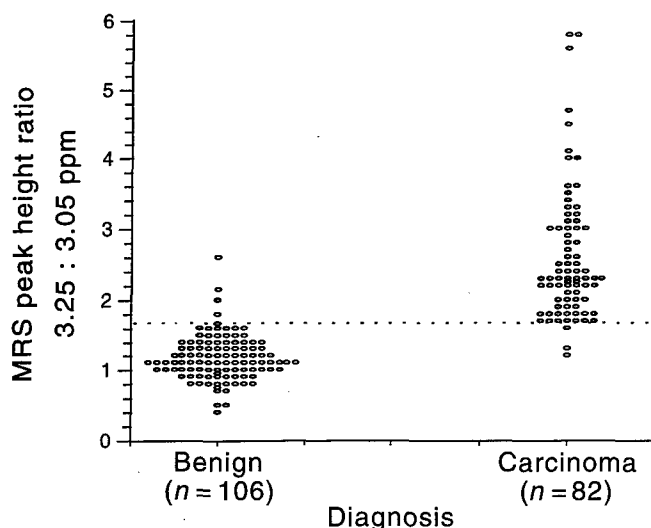


Fig. 1. One-dimensional magnetic resonance spectroscopy (8.5 Tesla) obtained from fine needle biopsy specimens from patients who underwent mastectomy. Spectra for normal non-involved breast and from invasive ductal carcinoma. The distinction between normal breast and invasive carcinoma is based upon an increase in the N-trimethyl resonance at 3.25 ppm normalized to that of creatine at 3.05 ppm.

by MRS and then conventional histology. Comparisons were made with other pre-operative diagnostic investigations including physical examination, mammography and FNA cytology.

Invasive cancer was identified by the presence of choline-containing metabolites (Fig. 1). Magnetic resonance spectroscopy discriminated between invasive cancer and normal or benign tissue based on the amount of choline when standardized to the creatine, phosphocreatine and lysine present in the sample (Fig. 2). Magnetic resonance spectroscopy on FNAB when compared with the histopathological diagnosis has a sensitivity and specificity for the distinction of invasive carcinoma from benign breast lesions of 95% and 96%, respectively. These data have now been sent to the National Research Council of Canada where a team of mathematicians will produce an algorithm to allow a robust, non-subjective diagnosis to be made which is independent of human involvement.

All samples reported as ductal carcinoma *in situ* (DCIS) by routine hospital histopathology ($n = 21$) were grouped according to the correlative histopathology on the MRS specimen. Magnetic resonance spectroscopy subcategorized DCIS into two categories. In category A (high choline to creatine/lysine ratio) there were four DCIS samples where ductal cells had breached the basement membrane (< 1 mm) in one or more foci and four samples where micro-invasion was identified. These eight samples as well as two samples of high-grade DCIS with extensive comedo necrosis were malignant by MR criteria. Group B (low choline to creatine/lysine ratio) contained 10 high-grade and one low-grade DCIS; all had MR profiles similar to that obtained for benign lesions.

Thus MRS on FNAB clearly distinguished pure DCIS (without comedo necrosis or micro-invasion) from invasive carcinoma. However, when DCIS specimens contained comedo necrosis or minute foci of micro-invasion undetected by histopathology, MRS ranked the specimen in the invasive category in every case. This indicates that chemical changes are occurring in cells

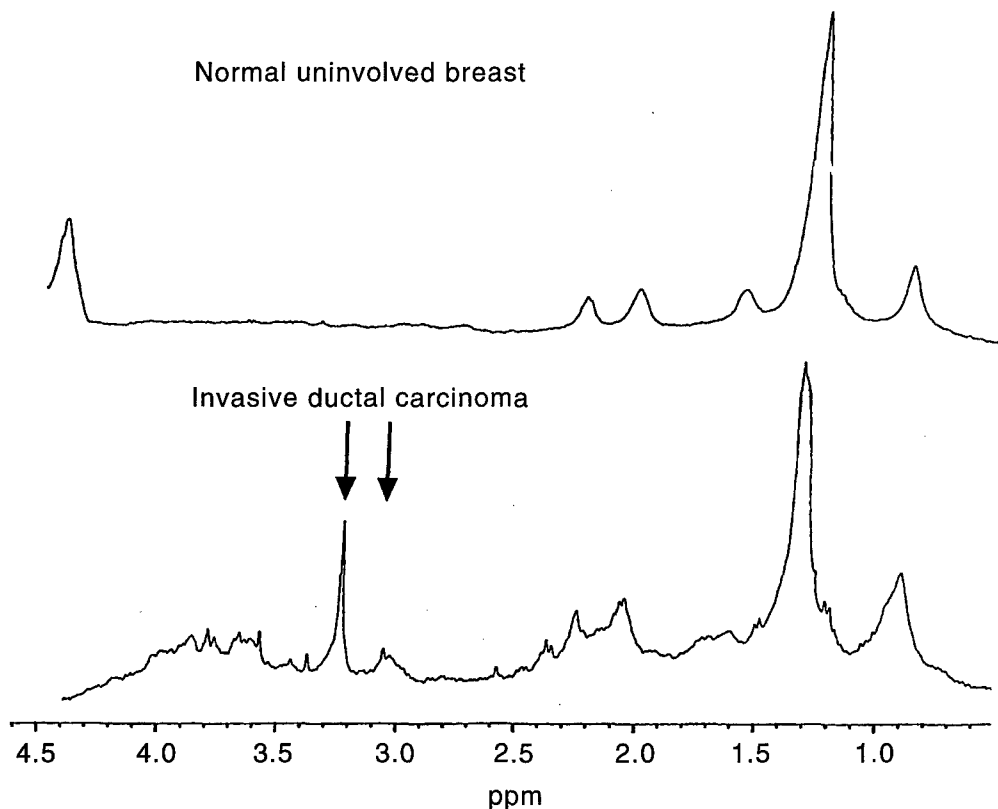


Fig. 2. Plot of the ratio of the intensity of resonances at 3.25 and 3.05 ppm. measured from magnetic resonance spectra as shown in Fig. 1. Unequivocally benign and invasive lesions are compared. Data are grouped on the basis of the final histopathology of tissue specimens taken from the aspiration site.

progressing from *in situ* to frankly invasive prior to morphological manifestation. Pure DCIS was not distinguished from benign lesions based on the ratios evaluated.

The breast study has been effective in further characterizing a group of patients where FNAB has been inconclusive or negative but where diagnosis remains unclear. The first application of MRS to breast disease may therefore be to reduce the false negative (sensitivity) biopsy rate by identifying suspicious lesions with malignant potential. Biopsy is currently necessary to prove that a lesion is benign.

Magnetic resonance spectroscopy on FNAB in breast lesions may therefore complement 'triple assessment' and reduce the need for unnecessary biopsy of benign lesions. This obviates the need for open biopsy prior to definitive therapy of invasive lesions by increasing diagnostic specificity of cytology. Pre-operative diagnosis of breast lesions by proton MRS offers benefits in patient management by reducing potential morbidity related to biopsy and allaying anxiety due to equivocal diagnosis.

LYMPH NODES

The first study undertaken to determine the sensitivity and specificity of MRS for detecting micrometastases was carried out on nodes from tumour-bearing rats.² In the present study, two-dimensional MRS, a more time-consuming method, was necessary due to the high levels of fat in the nodes. Micrometastases missed by conventional histological sectioning procedures were detected by MRS. Moreover, even when serial sectioning was used, MRS still identified micrometastases missed by the histopathologists. The presence of malignant cells was identified by the appearance of lactate, in the MR spectrum. At the disease stage when lactate but not choline was detectable by MRS, light microscopy failed to diagnose the presence of malignant cells. When MRS detected choline in addition to lactate, histopathology was also able to make the correct diagnosis. Thus, MRS could detect malignant cells prior to extensive proliferation, whereas the light microscope needed clusters of cells to make a diagnosis. The MRS method was supported by xenografting the nodes into nude mice.²

Recently, a collaborative programme between Dr Cynthia Lean from the IMRR and the NMR Centre at MGH, Harvard Medical School, has developed a new and faster method of collecting data on human nodes which will allow the detection of micrometastases in human nodal tissue in less than 12 min, examining the whole specimen (C.L. Lean *et al.*, unpubl. data).³

In yet another approach, assessment of FNA taken from nodes of breast cancer patients also offers significant promise as a routine method of biopsy and diagnosis by MRS.⁴

OTHER ORGANS

Follicular thyroid lesions

Magnetic resonance spectroscopy distinguishes benign and malignant subtypes of follicular thyroid lesions that cannot be discerned by light microscopy.² This method will now be evaluated within a clinical trial in which the 'benign' group will be offered conservative management and continued observation rather than invasive surgery.^{5,6}

Colon

The adenoma carcinoma sequence, first documented by Fearon and Vogelstein,⁷ was also able to be recorded by MRS. The identi-

fication, by MRS, of cell surface fucosylated molecules which increased in complexity with increased dysplasia was consistent with the adenoma carcinoma model.⁸

Prostate

Magnetic resonance spectroscopy subdivides histologically determined benign prostatic hypertrophy (BPH) into a genuinely benign form and one which is 'switched on' with some malignant features. This study also shows that determination of the correct pathology is best made when each of the four prostate zones are considered separately (P. Swindle, unpubl. data, 1998).⁹

Oesophagus

Barrett's oesophagus can be subdivided into a benign and a malignant subtype that cannot be determined by light microscopy.¹⁰

Confirmation by other sites around the world

The contentious nature of this programme has been overcome by sites overseas who verify the research. The National Research Council of Canada (NRC) has reproduced the IMRR data on ovary, colon, and cervix and was the first to publish *ex vivo* data on the prostate. The NRC's major contribution has been the development of multivariate analysis (artificial intelligence) to provide a robust objective data interpretation. This was first undertaken on the IMRR thyroid database.¹¹

CONCLUSION

Magnetic resonance spectroscopy, which is the original science behind MRI, has been 'rediscovered' to provide an objective method in determining whether a lesion is benign, in the malignant transfer process or truly malignant. When used as an adjunct with MRI it will offer a technology where lesions can be localized macroscopically by imaging and then diagnosed microscopically (at a cellular level) by spectroscopy: two technologies using the same principles and similar or the same equipment.

A second and most exciting aspect of the IMRR MR programme is the subcategorization of pre-invasive conditions such as DCIS of the breast, Barrett's oesophagus, and prostatic BPH where lesions already committed to malignancy but not detectable by light microscopy can be identified.

ACKNOWLEDGEMENTS

The authors would like to acknowledge contributions made by the clinical and scientific staff of the IMRR and the many Australians who have contributed to this project since 1978. Special thanks go to the pathologist, Peter Russell, who has contributed to this project tirelessly for two decades, to Ian Truskett, the first Australian surgeon to see the light and start the cervix programme, and ICP Smith (NRC), who supported these studies from the beginning when the hypothesis was still to be proven.

REFERENCES

1. Mackinnon WB, Barry P, Malycha P *et al.* Fine needle biopsy specimens of benign breast lesions distinguished from invasive cancer *ex vivo* by MRS. *Radiology* 1997; **204**: 661-6.
2. Mountford CE, Lean CL, Hancock R *et al.* Magnetic resonance spectroscopy detects cancer in draining lymph nodes. *Invasion Metastasis* 1993; **13**: 57-71.

3. Cheng LL, Lean CL, Bogdanova A *et al.* Enhanced resolution of proton NMR spectra of malignant lymph nodes using magic angle spinning. *Magnetic Resonance Med.* 1996; **36**: 653-8.
4. Lo W, Lean C, Dowd S, Malycha P, Russell P, Mountford CE. Fine needle biopsy of human lymph nodes. International Society for Magnetic Resonance in Medicine, Sixth Scientific Meeting and Exhibition, Sydney, Australia, April 18-24, 1998; 1685.
5. Russell P, Lean CL, Delbridge L, May G, Dowd S, Mountford CE. Proton magnetic resonance and human thyroid neoplasia: I. Discrimination between benign and malignant follicular thyroid neoplasms by magnetic resonance spectroscopy. *Am. J. Med.* 1994; **96**: 383-8.
6. Lean CL, Delbridge L, Russell P *et al.* Diagnosis of benign follicular thyroid lesions by proton magnetic resonance on fine needle biopsy. *J. Clin. Endocrinol. Metabolism* 1995; **80**: 1306-11.
7. Fearon ER, Vogelstein B. A genetic model for colorectal tumorigenesis. *Cell* 1990; **61**: 759-67.
8. Ende DA, Lean CL, Mackinnon WB *et al.* Human colorectal adenoma-carcinoma sequence documented by ^1H MRS (*ex vivo*). *Proc. Soc. Magn. Reson. Med.* 1993; **2**: 1033.
9. Swindle P, Khadra M, Lean C, Dowd S, Russell P, Mountford C. Prostate carcinoma distinguished from benign prostatic hyperplasia by *ex-vivo* proton magnetic resonance spectroscopy. International Society for Magnetic Resonance in Medicine, Sixth Scientific Meeting and Exhibition, Sydney, Australia, April 18-24, 1998; 1686.
10. Doran S, Wadstrom C, Barry P *et al.* Pathology of Barrett's oesophagus subcategorized by ^1D ^1H MRS. International Society for Magnetic Resonance in Medicine, Sixth Scientific Meeting and Exhibition, Sydney, Australia, April 18-24, 1998; 327.
11. Somorjai R, Nikulin SE, Pizzi N *et al.* Computerized consensus diagnosis: A classification strategy for the robust analysis of MR spectra. I. Application to ^1H spectra of thyroid neoplasms. *Magnetic Resonance Med.* 1995; **33**: 257-63.

BREAST CANCER AND MAGNETIC RESONANCE SPECTROSCOPY


Proton magnetic resonance spectroscopy (MRS), which reports alterations to cellular chemistry, could monitor the development of breast tumours.

BY CAROLYN E MOUNTFORD

Earlier diagnosis and more effective management of breast cancer have led to improvement in breast cancer patient outcomes [1,2]. However combining physical examination, mammography and fine needle aspiration cytology (known as triple assessment) — the most sensitive way of diagnosing pre-operative clinical and radiographically detected breast lesions [3,4] — is flawed. Triple assessment has a high probability of detecting all malignant lesions but its sub-optimal specificity results in uncertainty, needing open biopsy (surgical intervention) to exclude malignancy.

Physical examination has limitations due to individual variation in breast consistency, the site and size of the lesion (less than 1cm is usually impalpable), and the presence of a diffuse versus discrete tumour. Screening mammography guidelines ensure that about one benign lesion is biopsied for every malignant lesion detected [3]. Even so, 10–40% of palpable breast cancers are missed by mammography alone, especially in women under 50 in whom radiographically dense breast tissue may mask changes associated with malignancy [4,5].

The golden standard for diagnosis, histopathology, relies on alterations to cellular morphology and tissue architecture. Fine needle aspiration (FNA) cytology has a sampling error of about 1–15% [6], partly explaining its variable sensitivity. While the complete sensitivity of FNA is 81–97% [7], this includes atypical and suspicious diagnoses that typically lead to histological confirmation of cancer by open biopsy.



The cornerstone of breast cancer diagnosis — triple assessment — might not be the only way of monitoring and diagnosing this disease. What part can magnetic resonance spectroscopy play?

sy in 50–80% of cases [8].

We have investigated the possibility that a new method, proton magnetic resonance spectroscopy (MRS) which reports on alterations to cellular chemistry, could monitor the development of breast tumours (Figure 1). MRS detects pools of chemicals that are mobile on the MR time scale. Therefore, the technology reports not on the total chemical content of the cells but on pools of chemicals that are active at a particular stage of development. By reporting such alterations to cellular chemistry that often do not manifest morphologically and therefore cannot be seen under the light microscope, MRS may provide a robust and accurate way of diagnosing breast cancer.

A technology like MRS, which monitors cellular chemistry correlating with different cell behaviour, could offer both independent and objective assessment of breast tissue. The potential then exists to identify a predisposition towards, or early features of, breast cancer and therefore offer interventions aimed at reducing tumour development. MRS is one diagnostic method that has been successfully applied to monitor tumour development and progression in other organs [7, 9–12].

Proton MRS can distinguish pre-invasive from invasive cervical cancer with a sensitivity and specificity of 98% and 94%, respectively [7]. It also distinguishes genuinely benign from malignant follicular lesions in human thyroid [12] and discriminates degrees of loss of cellular differentiation in ovarian tumours [11].

Preliminary investigations of excised breast tissue by 1-D and 2-D proton MRS detected increased levels of glycerophosphocholine and phosphocholine in invasive breast carcinoma compared with benign fibroadenomas [15]. Specimens of benign fibrocystic disease were characterised by an absence of resonances from choline, amino acids and other metabolites. However, we had problems obtaining adequate spectral resolution from excised breast due to the high adipose content of the tissue (Figure 2). The intense broad MR resonances from this fat often masked other diagnostic resonances in the 1-D spectrum. This problem is largely overcome by applying a T₂ filter (Carr-Purcell-Meiboom-Gill sequence) during data collection [13] and/or with post-acquisitional data processing [14].

A simpler remedy was to optimise specimen collection. Collection methods substantially affect the amounts of exogenous

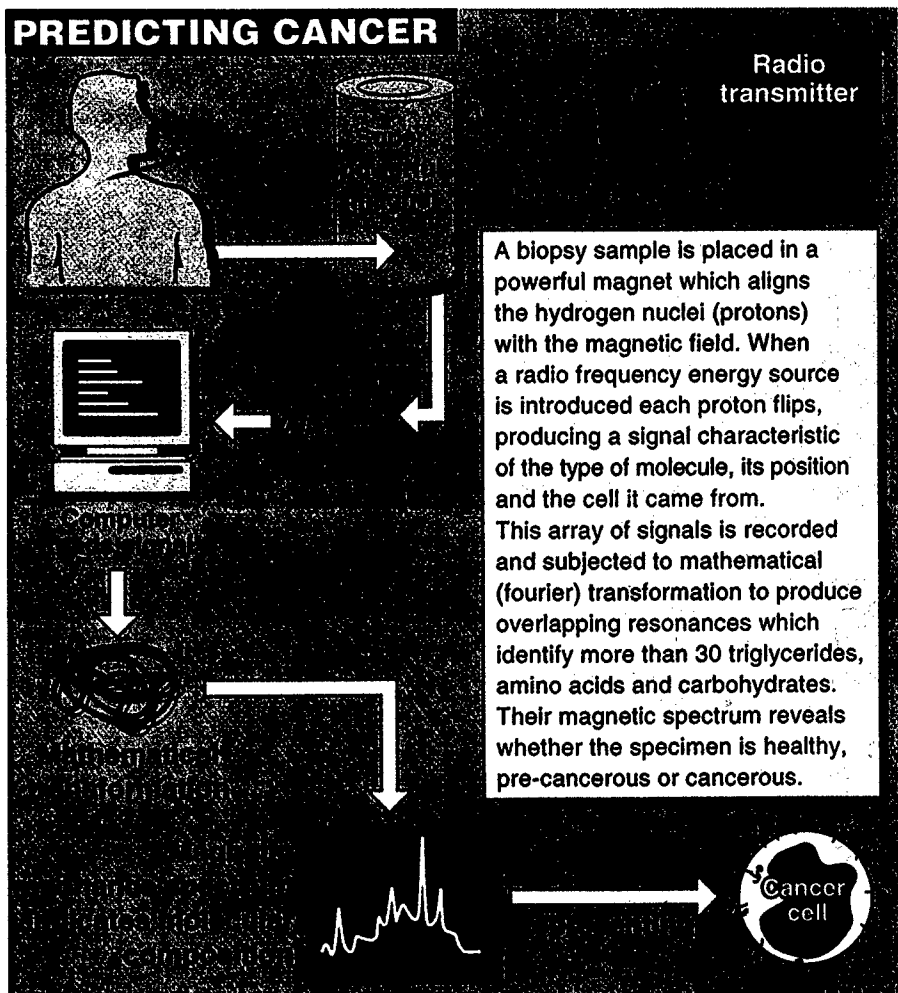


Figure 1. Predicting cancer with magnetic resonance spectroscopy (MRS).

fat sampled. FNA biopsy methods developed for thyroid sampling [12] provided cellular material adequate for assessment by MRS with reduced fat levels compared with excised tissue (Figure 2).

The study

Over 250 patients took part in the study [15], with a summary of histological diagnoses shown in Table 1. Fine needle aspiration biopsies (FNB) were taken from the breast and examined by MRS and then conventional histology. Comparisons were made to other pre-operative diagnostic investigations including physical examination, mammography and FNB cytology. Invasive cancer was identified by the presence of choline-containing metabolites. MRS discriminated between invasive cancer and normal or benign tissue based on the amount of choline when standardised to the creatine, phosphocreatine and lysine present in the same sample. MRS on FNB,

when compared with the histopathological diagnosis, has a sensitivity and specificity for distinguishing invasive carcinoma from benign breast lesions of 95% and 96% respectively, based on the 1-D peak intensity ratio of 3.25/3.05ppm (Figure 3 and Table 2). This data has now been sent to the National Research Council of Canada for a team of mathematicians to produce an algorithm to allow a robust, non subjective diagnosis independent of human involvement [14]. Preliminary outcomes place the sensitivity and specificity close to 99% [1–6].

All samples reported as ductal carcinoma-in situ (DCIS) by routine hospital histopathology (n = 21), were grouped according to the correlative histopathology on the MR specimen. MRS subcategorised DCIS into two categories. In category A (high choline to creatine/lysine ratio) were four DCIS samples where ductal cells had breached the basement mem-

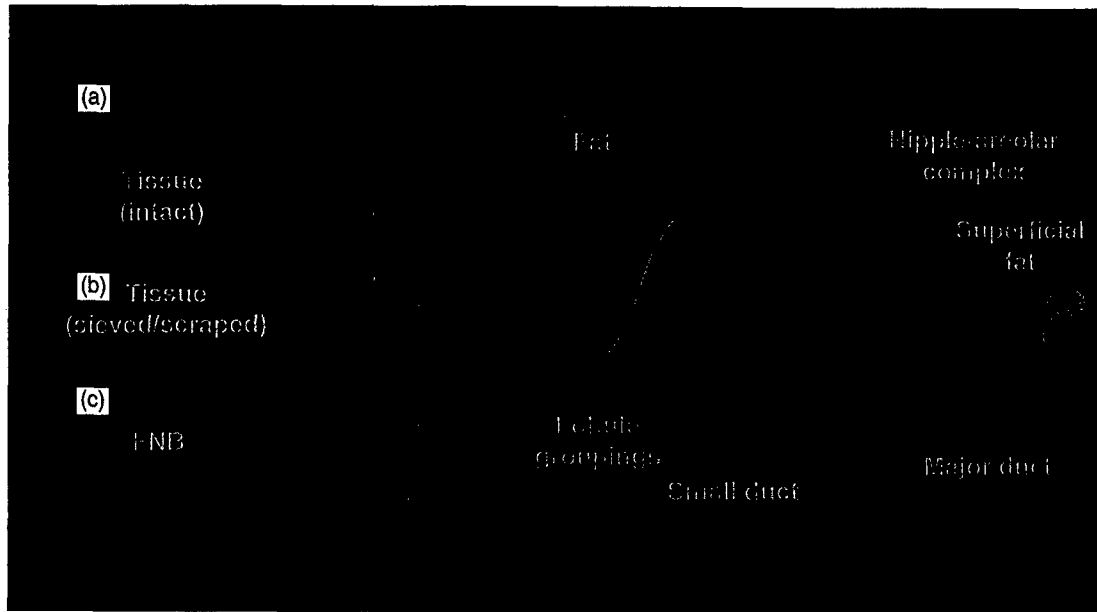


Figure 2. MRS on human breast (ex vivo). 8.5 Tesla MRS spectra obtained from (a) breast tissue from a histologically diagnosed invasive tumour; (b) same tissue as (a) but dissociated mechanically; and (c) FNA biopsy from a patient with invasive breast cancer.

brane (under 1mm) in one or more focus and microinvasion was identified in another four samples. This group of eight as well as two samples of high grade DCIS with extensive comedo necrosis were malignant by MR criteria. Group B containing DCIS (10 high grade, 1 low grade) all had a low choline to creatine/lysine ratio similar to that obtained for benign lesions.

Therefore, MRS on FNB clearly distinguished pure DCIS without comedo necrosis or microinvasion from invasive carcinoma. However, even when DCIS specimens contained comedo necrosis or a few foci of

microinvasion, MRS ranked the specimen in the invasive category in every case. This may indicate chemical changes occurring in cells progressing from in situ to frankly invasive before morphological manifestation. Pure DCIS was not distinguished from benign lesions based on the 1-D 3.25/3.05ppm ratio.

MRS on FNB may therefore complement triple assessment and reduce the need for unnecessary biopsy of benign lesions, while obviating the need for open biopsy before definitive therapy of invasive lesions by increasing diagnostic specificity of cytology. Pre-operative diagnosis of breast lesions by proton MRS therefore offers potential benefits in patient management by reducing potential morbidity related to biopsy and allaying anxiety due to equivocal diagnosis.

However, a most exciting aspect of this program is the subcategorisation of DCIS where some lesions already are committed to malignancy but are not detectable by light microscopy.

Acknowledgements

The multi-disciplinary nature of this project involved surgeons, pathologists, scientists and technologists from the Institute for Magnetic Resonance Research based at the University of Sydney. These include Bruce Barraclough, Peter Barry, Michael Bilous, Sinead Doran, Susan Dowd, David Gillett, Cynthia Lean, Wanda

Benign	
Fibrocystic changes	68
Fibroadenoma	15
Ductal hyperplasia (mild/florid)	9
Fat necrosis	4
Sclerosing adenosis	2
Radial scar	2
Atypical ductal hyperplasia	2
Duct ectasia	2
Miscellaneous	2
Total	106
Phyllodes tumour	
	2
Ductal carcinoma in-situ	
DCIS (high grade)	10
DCIS (low grade)	1
DCIS (comedo necrosis)	2
DCIS + microinvasion	4
Total	17
Invasive carcinoma	
Ductal carcinoma (NST)	66
Ductal carcinoma (NST), EIC positive	7
Lobular carcinoma	5
Tubular carcinoma	4
Total	82

Table 1. Summary of histological subtypes of FNB samples. DCIS = Ductal carcinoma in situ; NST = no special type; EIC = extensive intraductal component. Histopathology according to dominant findings on correlative histopathology samples.

BREAST FNB Benign vs Infiltrating Carcinoma

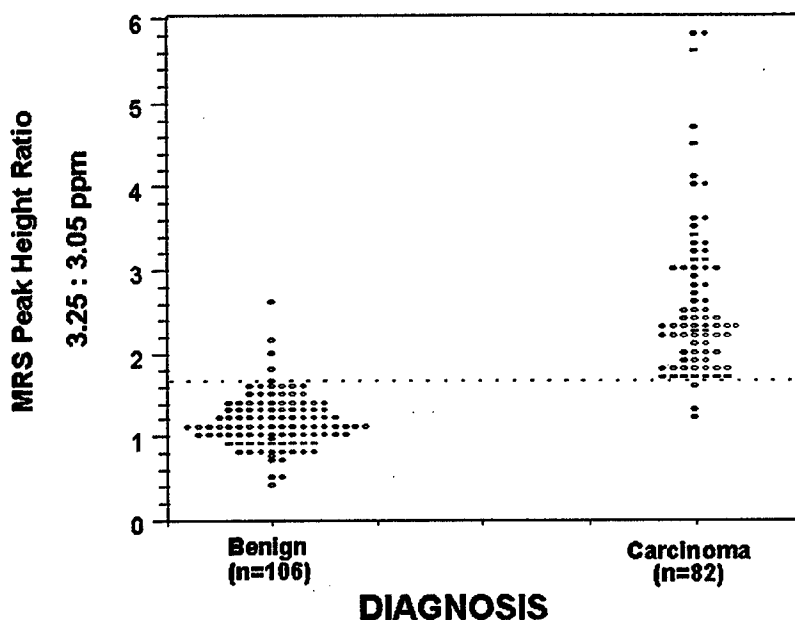


Figure 3. Plot of ratio of intensity of resonances at 3.25 and 3.05ppm measured from MR spectra as shown in Figure 2. Benign and invasive lesions (unequivocal) are compared. Data are grouped on the basis of the final histopathology of tissue specimens taken from the aspiration site.

	Invasive carcinoma	Normal/benign	
MRS (FNB) positive ratio > 1.7	78 (TP)	4 (FP)	PPV 95% (78/82)
MRS (FNB) negative ratio under 1.7	4 (FN)	102 (TN)	NPV 96% (102/106)
	Sensitivity 95% (78/82)	Specificity 96% (102/106)	Total = 180

Table 2. Test result probabilities for diagnosis by MRS on FNB compared with histological diagnosis on tissue. TP = true positive; FN = false negative; FP = false positive; TN = true negative; PPV = positive predictive value; NPV = negative predictive value; Sensitivity or true-positive rate = frequency of positive test result (ie. MRS ratio 1.7) in those with malignant disease; Specificity or true-negative rate = frequency of negative test result (MRS ratio under 1.7) in those without malignant disease as judged by histopathology of breast tissue excised from the aspiration site.

Mackinnon and Peter Russell.

Carolyn Mountford is executive director of the Institute of Magnetic Resonance Research at the University of Sydney.

References

- 1 Tabar L, et al (1992) *Radiologic Clinics of North America* 30:187.
- 2 Shapiro S, et al (1982) *J Natl Canc Inst* 69:349.
- 3 National Program for the Early Detection of Breast Cancer (Monitoring and Evaluation Reference Group) (1994) *Ntl Prog*

for the Early Detection of Breast Cancer — Evaluation of phase one: 1 July 1991–30 June 1994 Commonwealth Department of Human Services and Health, Canberra, Australia.

- 4 Dodd GD (1977) *Cancer* 39:2796.
- 5 Walker QJ, et al (1989) *Med J Aust* 151:509.
- 6 Hillier G, et al (1987) *Aust NZ J Surg* 57:239.
- 7 Delikatny EJ, et al (1993) *Radiology* 188:791.
- 8 Hermansen C, et al (1987) *Cancer* 60:1866.
- 9 Russell P, et al (1994) *Am J Med* 96:383.
- 10 Ende DA, et al (1993) *Proc Soc Magn Reson Med* 2:1033.
- 11 Mackinnon WB, et al (1995) *Int J Gynaecol Cancer* 5:211.
- 12 Lean CL, et al (1995) *J Clin Endocrinol & Metab* 80:1306.
- 13 Williams P, et al (1988) *Magn Reson Med* 7:463.
- 14 Somorjai RL, et al (1995) *Magn Reson Med* 33:257.
- 15 Mackinnon WB, et al (1997) *Radiology* 204:661.

Next month in

today's LIFE SCIENCE

In June, we bring you the second of our quarterly microbiology supplements, *Today's Microbiology*.

This month's focus is Environmental Microbiology, which covers:

- microbial indicators of river health
- stunning images from the Image of the Year award
- book reviews
- microbiology products

Next month, we also:

- preview the Haematology Society of Australia/Australian Society for Blood Transfusion conference
- focus on immunoassay/serology products
- publish the LabLink Catalogue

Out at the end of June

FNA stored at -70°C less than 6 months

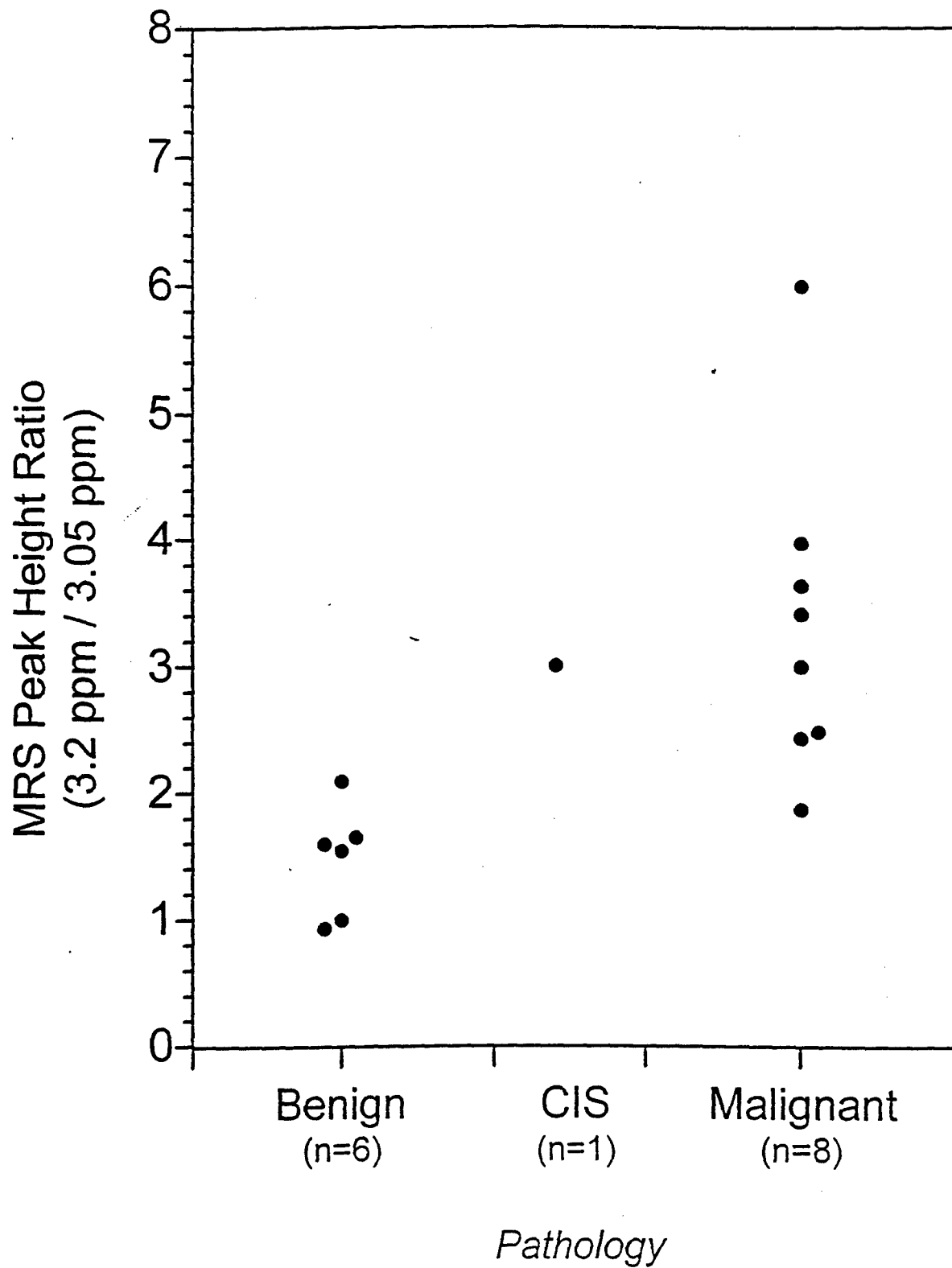


Figure 1A: Breast FNA specimens: MR ratios of benign, carcinoma and carcinoma *in situ* specimens stored less than 6 months at -70°C.

FNA stored at -70°C for 6-22 months

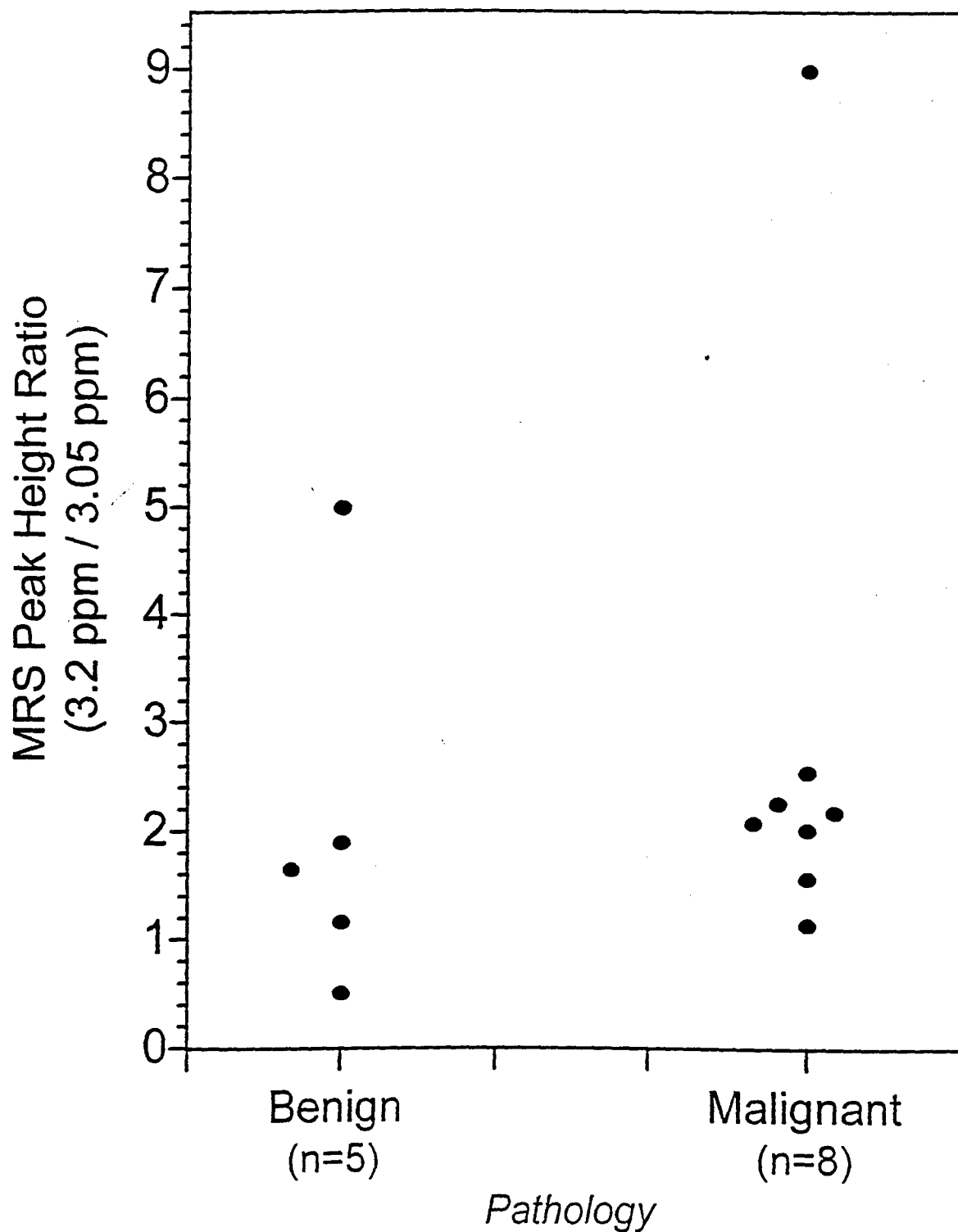


Figure 1B: Breast FNA: MR ratios of benign and carcinoma specimens stored longer than 6 months and less than 22 months at -70°C.

FNA specimen collected from breast
lesion *in vivo*

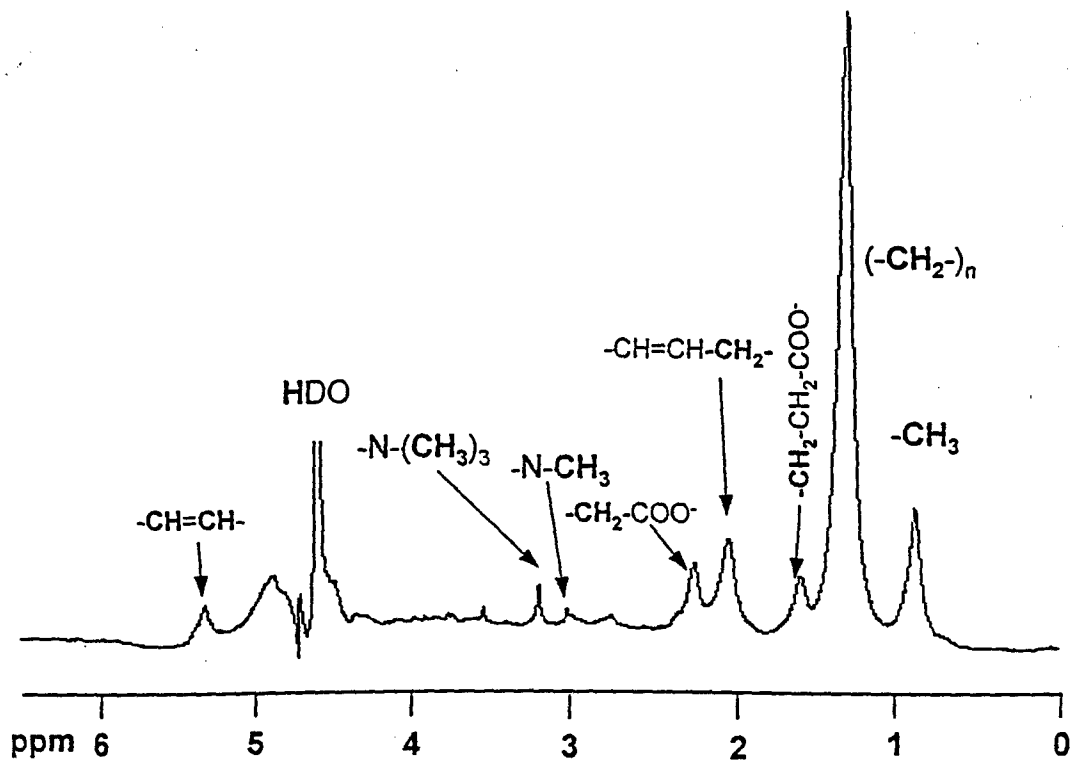
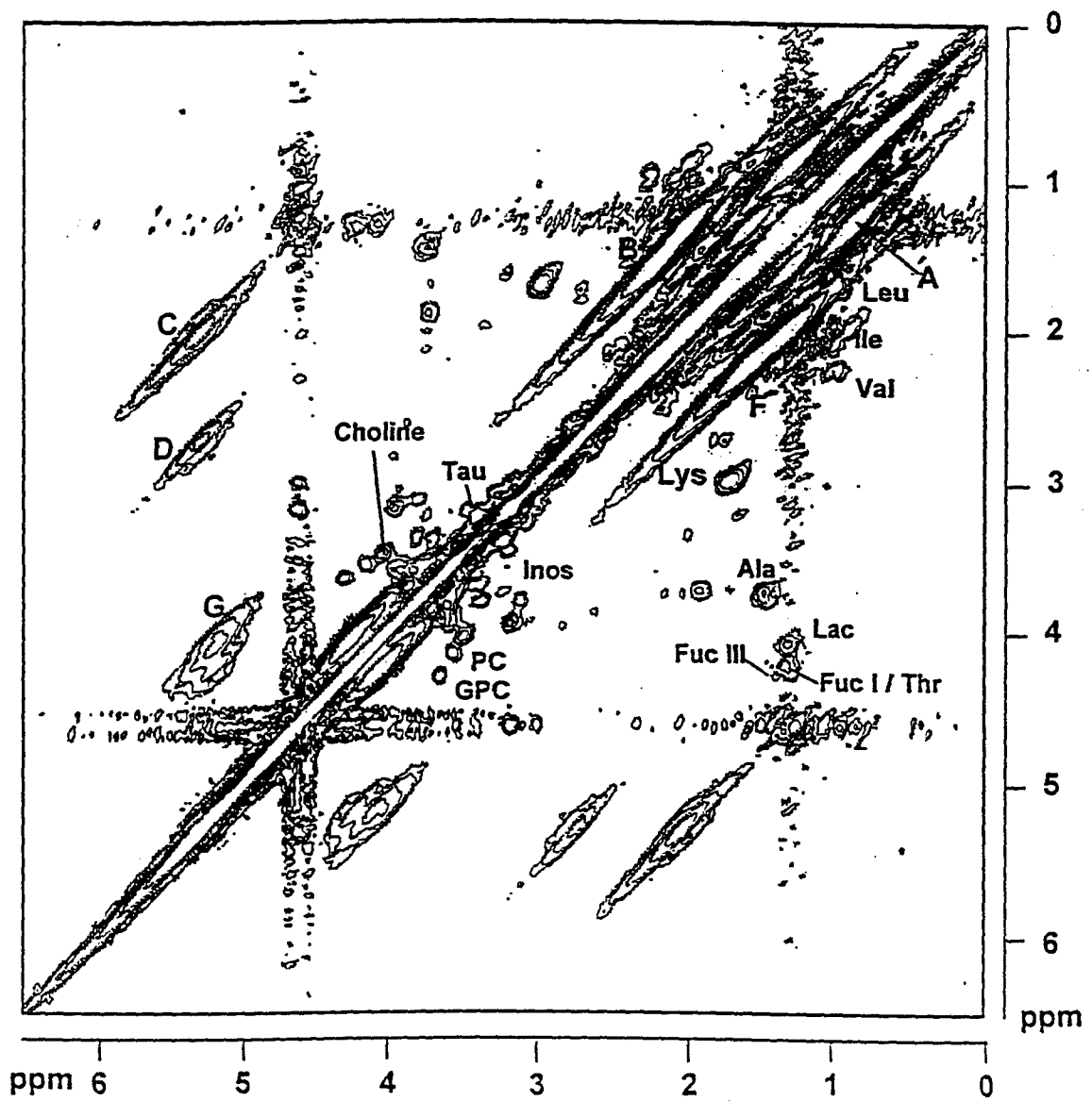
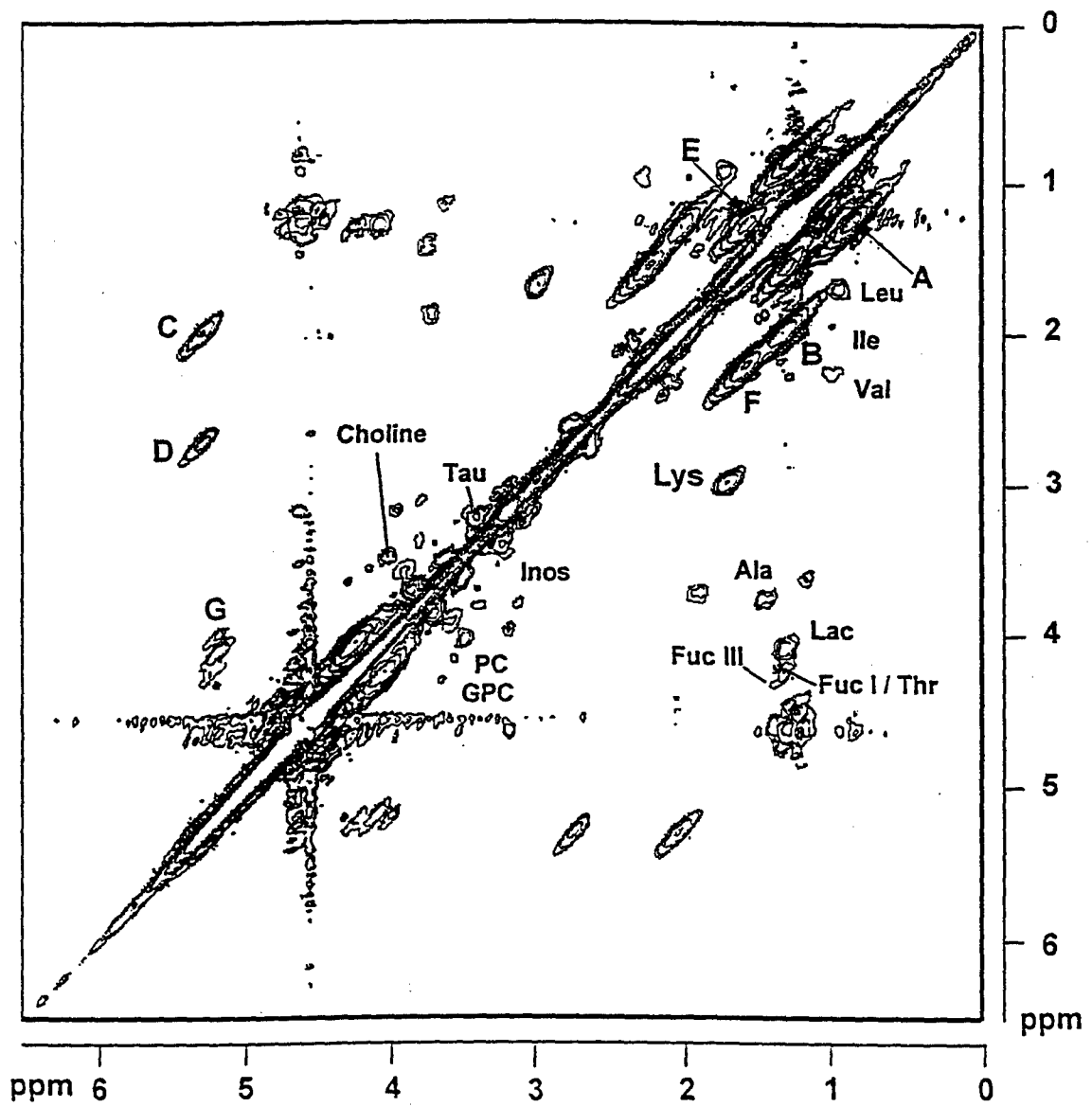


Figure 2: ^1H MR 1D spectrum (360 MHz) of malignant breast FNA collected *in vivo*. Both specimens have malignant histology. Spectra (256 scans, sweep width 3597 Hz) were collected at 37°C with the sample spinning at 20 Hz on a Bruker AM360 MR spectrometer. Residual water was suppressed by selective gated irradiation. A line broadening of 3 Hz was applied before Fourier transformation.

3A: Malignant (tissue specimen)



3B: Carcinoma in situ (tissue specimen)



3C: Benign (tissue specimen)

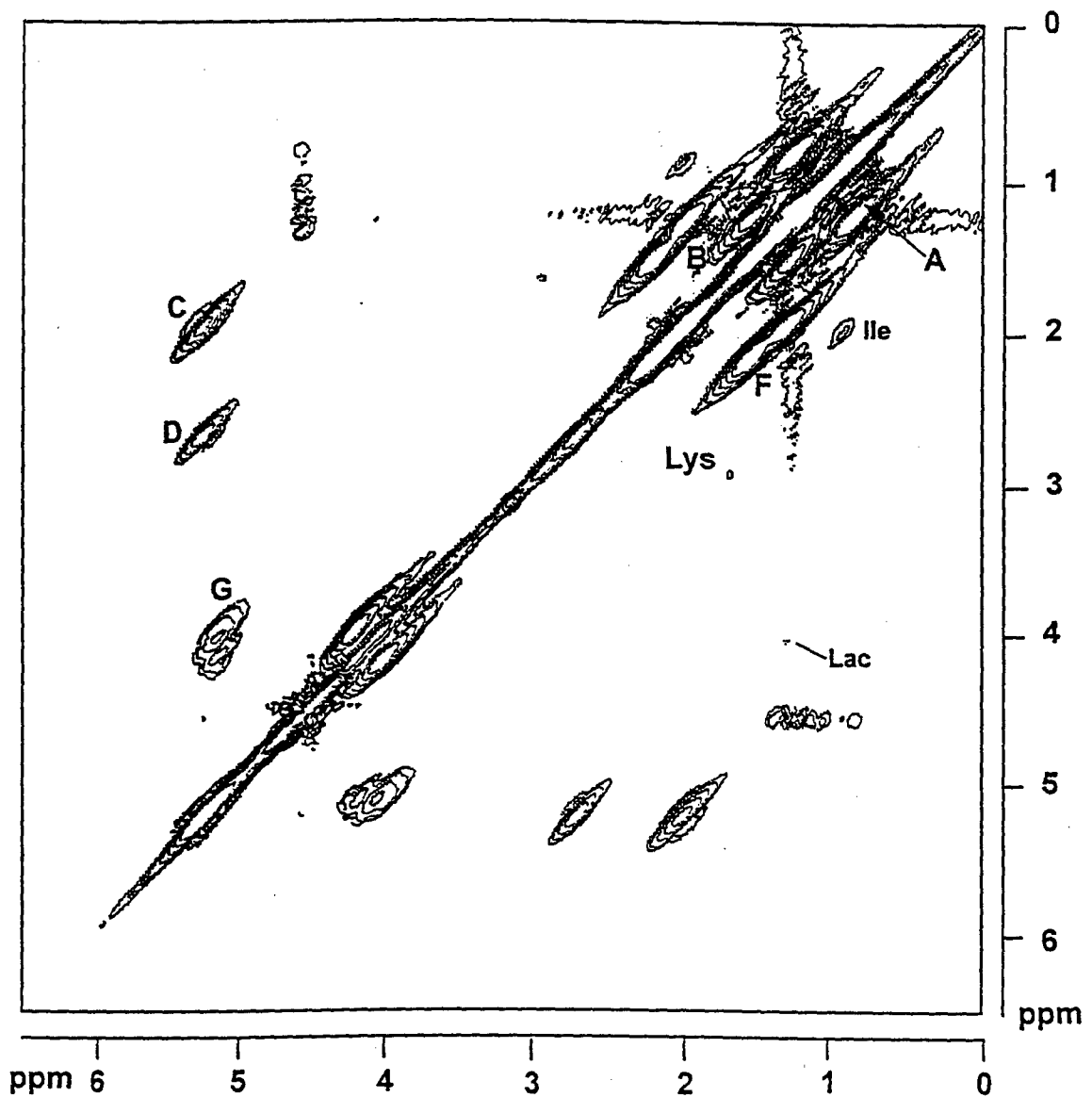


Figure 3: 360 MHz ¹H MR symmetrized COSY spectra of breast tissue specimens in PBS/D₂O, (NS=32, NE=200). A) Malignant; B) *Carcinoma in situ*; C) Benign tissue. Data were collected at 37°C with sweep width 3597 Hz. A sinebell window function in t₁ domain, and a Lorentzian-Gaussian window function (LB = -40, GB = 0.15) in the t₂ domain were applied before Fourier transformation.

Malignant breast FNA.

Specimen collected intraoperatively

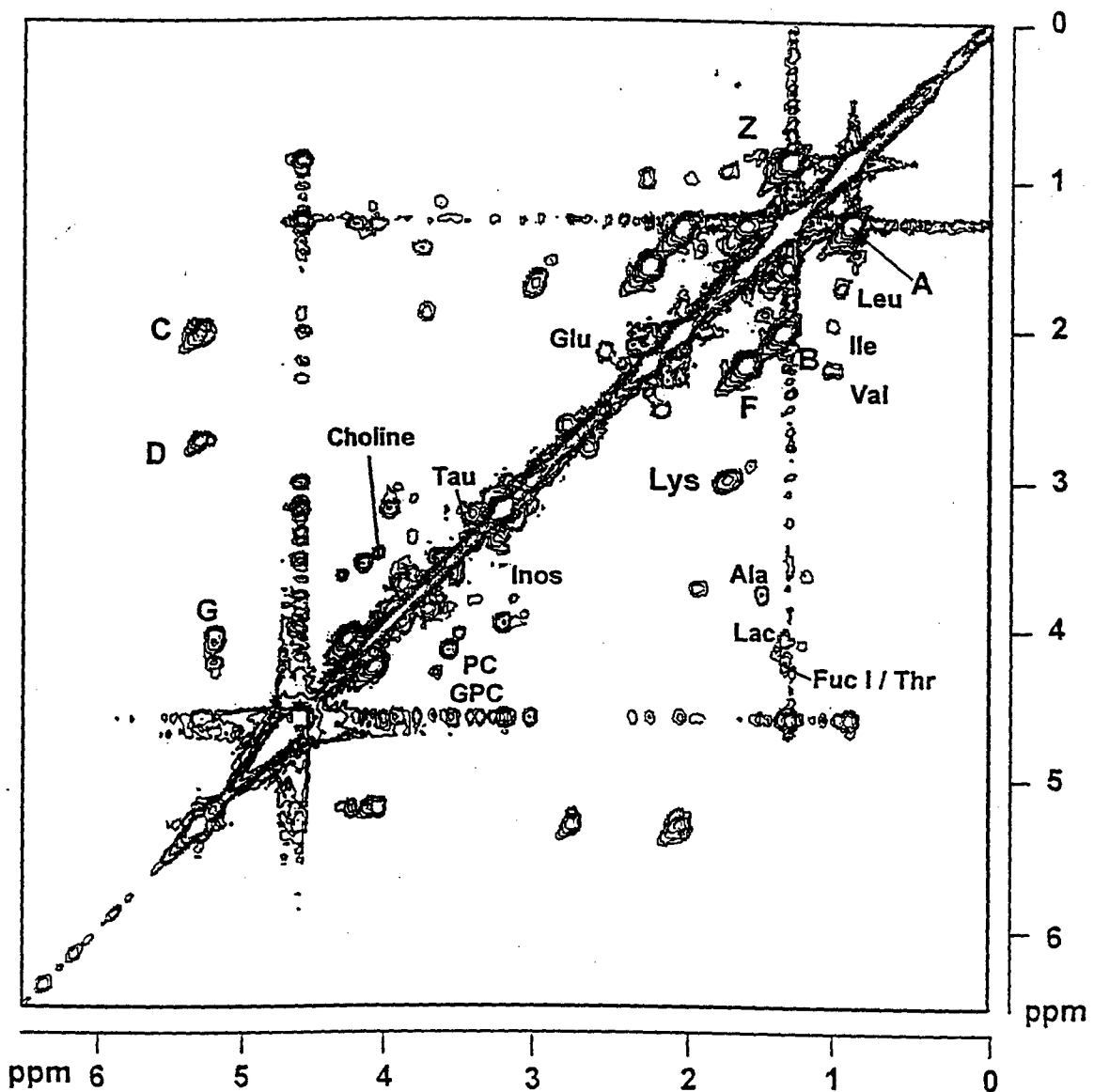


Figure 4: 360 MHz ¹H MR symmetrized COSY spectra of malignant breast FNA specimen, (NS=32, NE=200). Data were collected at 37°C with sweep width 3597 Hz. A sinebell window function in t_1 domain, and a Lorentzian-Gaussian window function (LB = -40, GB = 0.15) in the t_2 domain were applied before Fourier transformation.

Methyl-methine coupling region from COSY

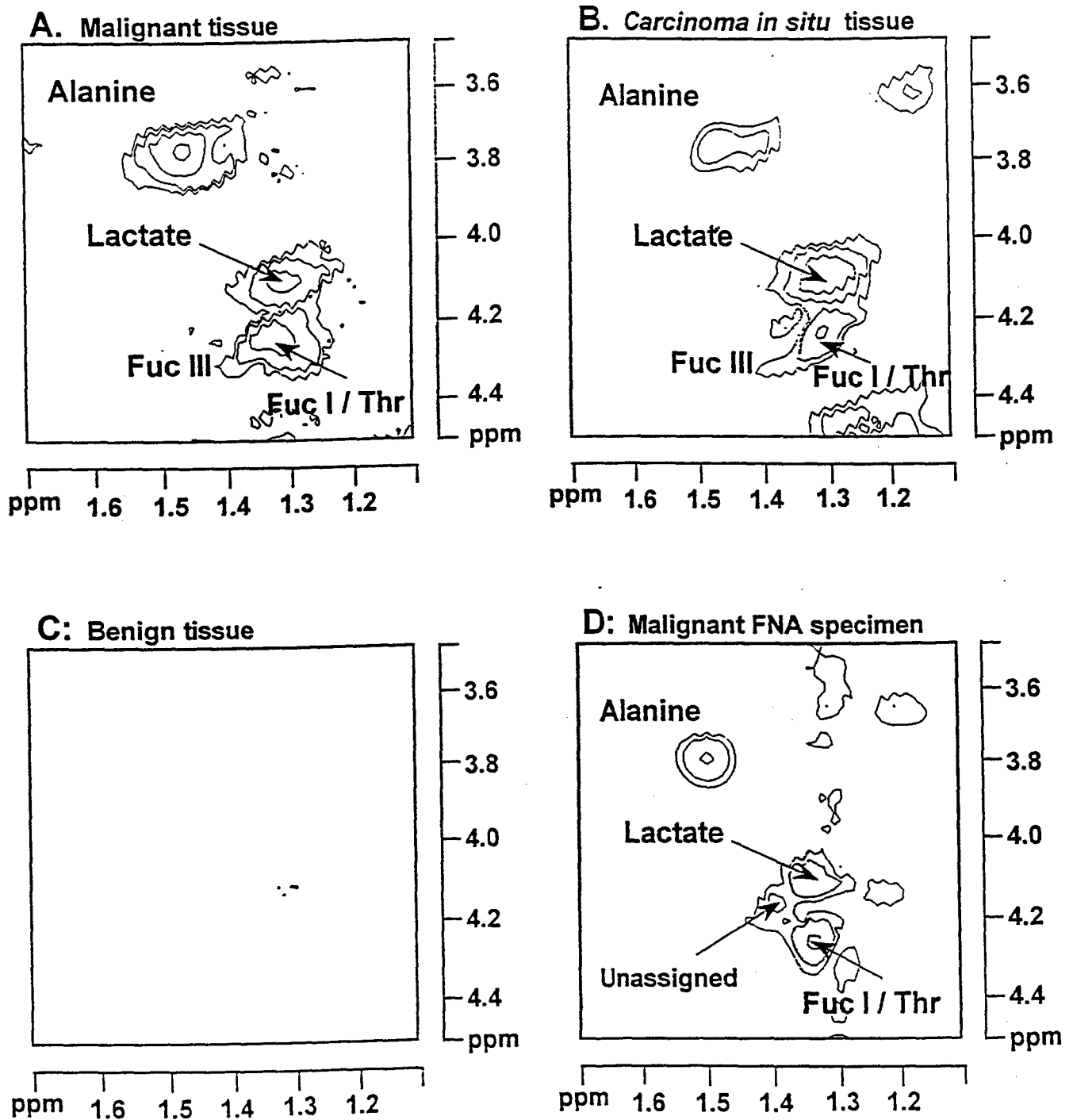


Figure 5: methyl - methine coupling region ($F_1 = 3.5 - 4.5$ ppm, $F_2 = 1.1 - 1.7$ ppm) from 360 MHz ^1H MR symmetrized COSY spectra of breast specimens (NS=32, NE=200). A) malignant tissue; B) *Carcinoma in situ* tissue; C) benign tissue; D) malignant FNA. Data were collected and processed as described in Figure legends 3+4.

Human Lymph Node Tissue Assessed by MRS

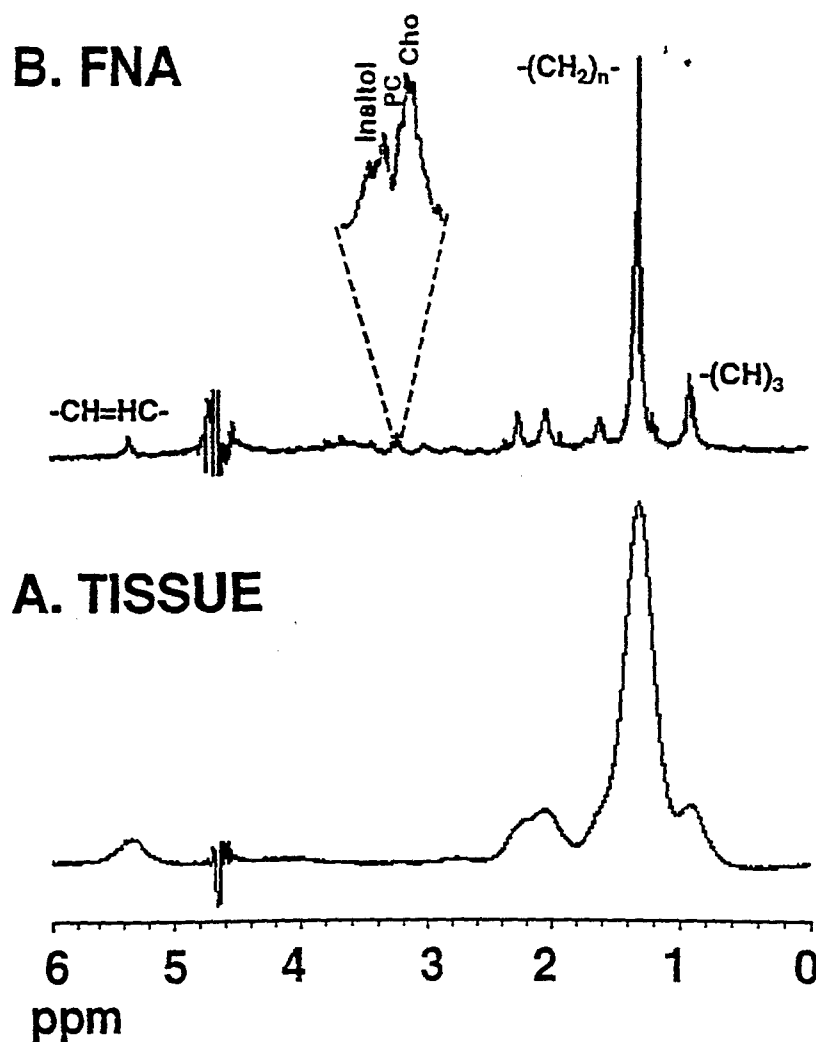


Figure 6: ^1H MR spectra (360MHz) of human lymph nodes. A. Tissue B. FNA biopsy. Spectra (128 scans, sweep width 3597 Hz) were collected at 37°C with the sample spinning at 20 Hz on a Bruker AM360 MR spectrometer. Residual water was suppressed by selective gated irradiation. A line broadening of 1Hz was applied before Fourier transformation.

Data Analysed by Visual Inspection

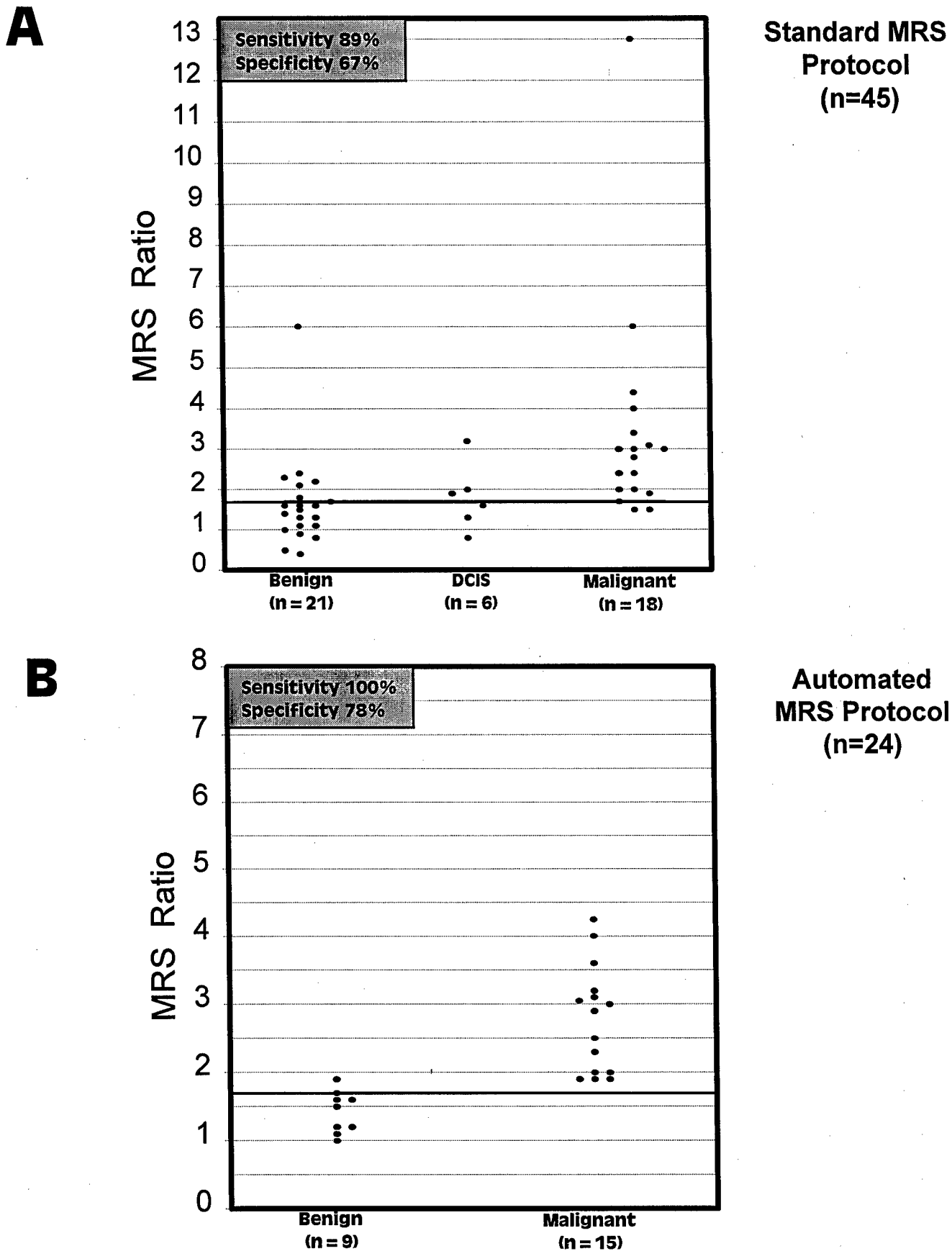


Figure 7. MRS data collected from FNA of breast lesions during 1998/99.
A - MRS FNA data collected using standard MRS protocol;
B - MRS FNA data collected using newly developed automated MRS protocol outlined in Figure 8.

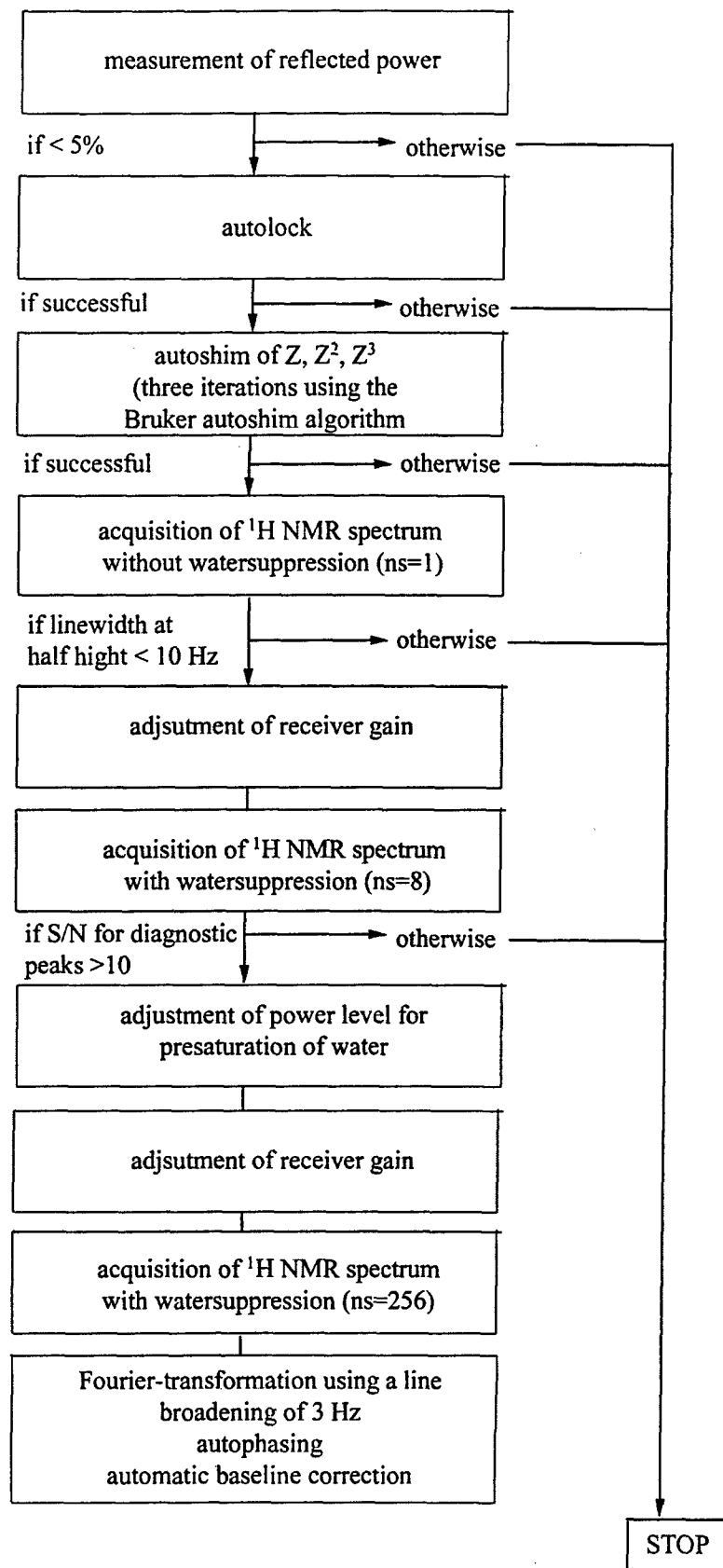
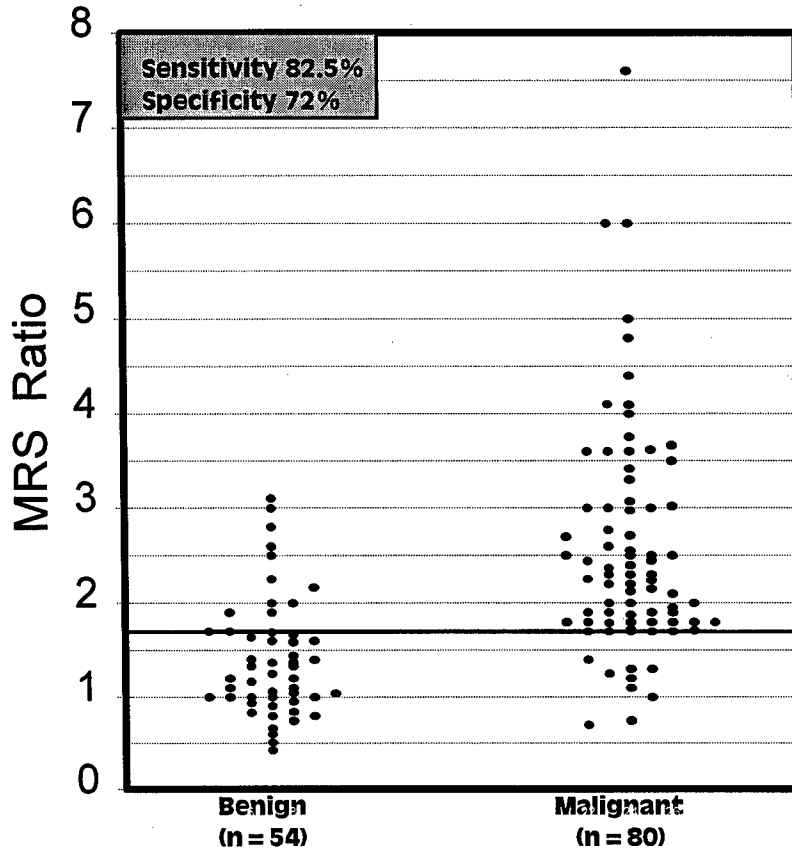


Figure 8: Simplified algorithm for automatic data acquisition and processing of ^1H MR spectra of breast FNB

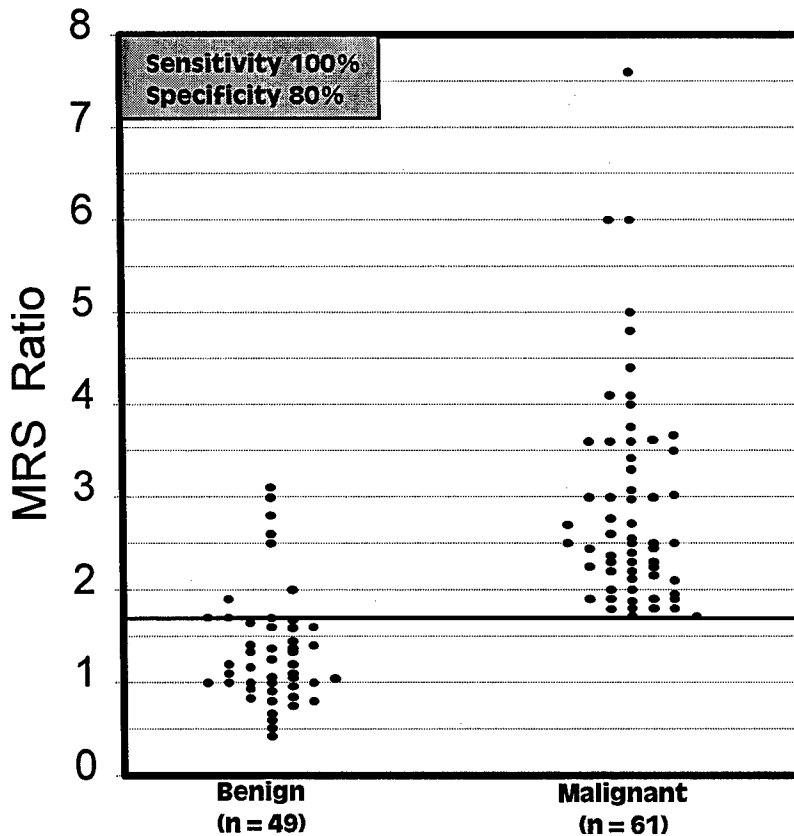
Data Analysed by Visual Inspection

A



All Data Suitable For
CCD analysis
(i.e. spectra with adequate
H₂O suppression and no
contaminants)
(n=134)

B



Data Suitable For CCD
Analysis With SNR_≥25
(n=110)

Figure 9. MRS data collected from FNA of breast lesions. The MRS ratio was calculated following visual inspection of the spectra and determination of peak height ratios. This figure shows the MRS ratio correlated with the histopathology of the lesion.
A - All MRS FNA data suitable for multivariate CCD analysis
B - MRS FNA data suitable for multivariate CCD analysis with SNR_≥25

Improved Water Suppression Method

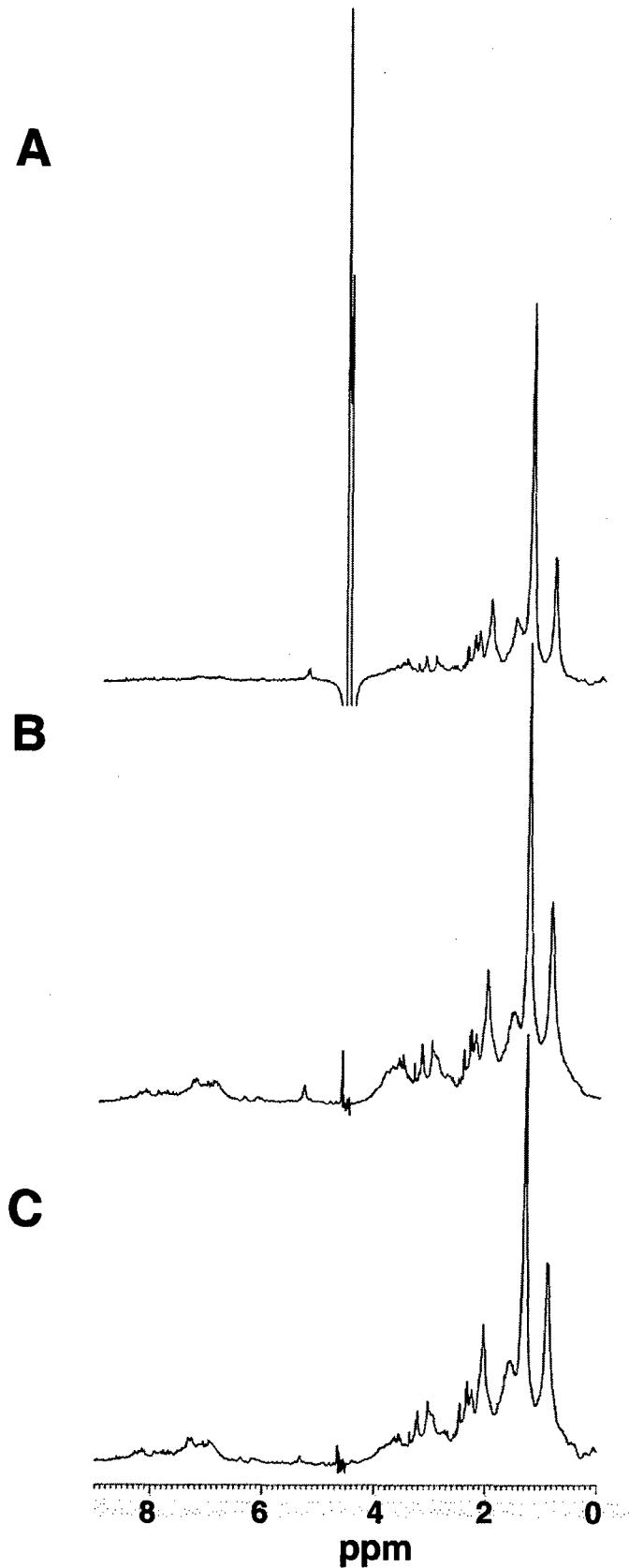
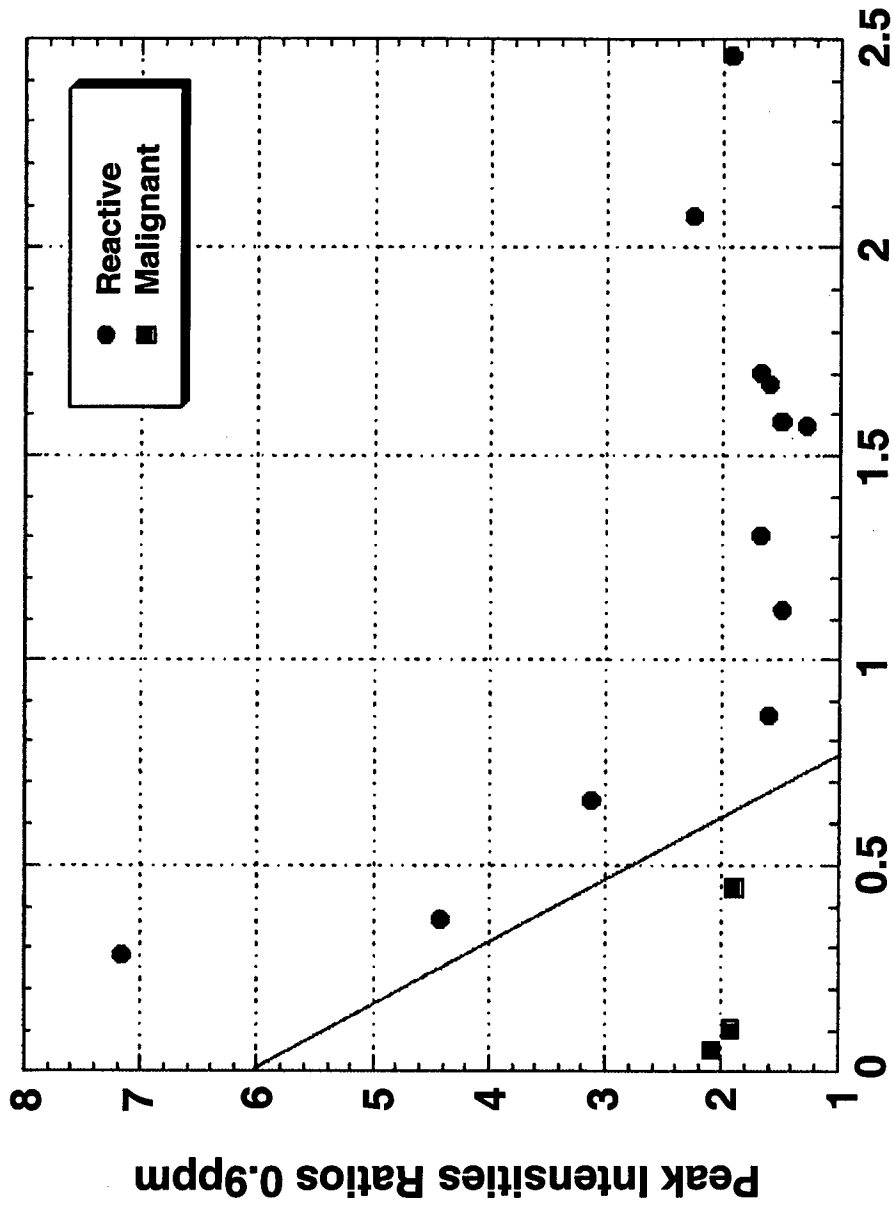


Figure 10: Spectra obtained from the same breast FNA at 37°C. A) Spectrum obtained with presaturation for 2s (water suppression ~600). B) Spectrum obtained with a double PFG echo sequence with a [soft 180°_x hard 180°_x] refocusing element, $\tau=500\mu\text{s}$ (water suppression ~15000). C) Same as B) with $\tau=600\mu\text{s}$ (water suppression ~17000). The absolute intensity scale is the same in all spectra.

MRS on FNA of Human Lymph Nodes



Peak Intensities Ratios of 3.2ppm/0.9ppm

Figure 11 A 2-Dimensional Plot of MRS Data from FNAs of Malignant and Reactive Lymph Nodes. The Data were Derived from Spectra Resolution Enhanced using a Gaussian Lorentzian Transformation (GB=0.08, LB=-7.0)

Figure 12: ^1H MAS MRS of Human Lymph Nodes

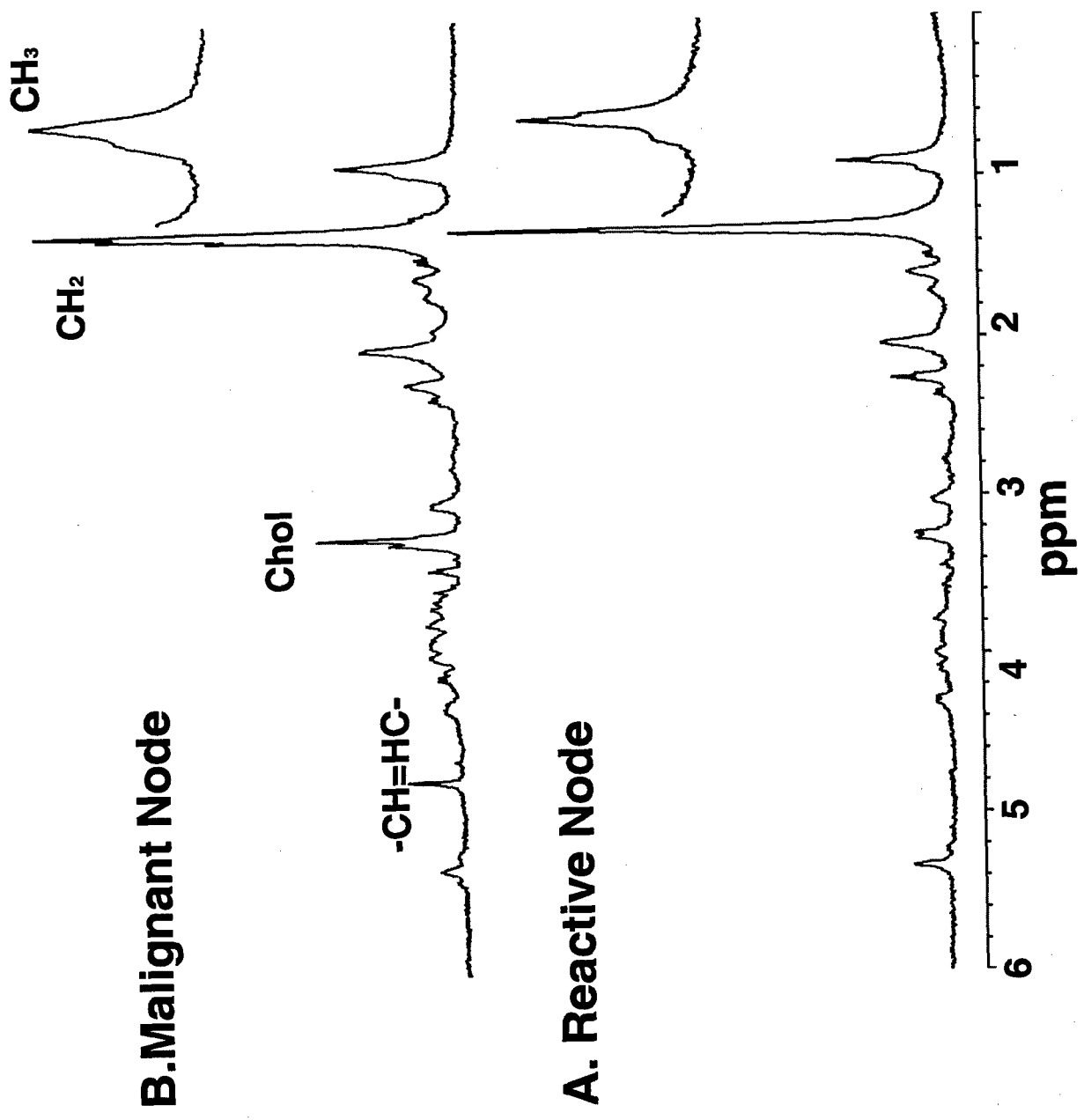


Figure 13: ^1H MAS MRS of Human Axillary Lymph Nodes

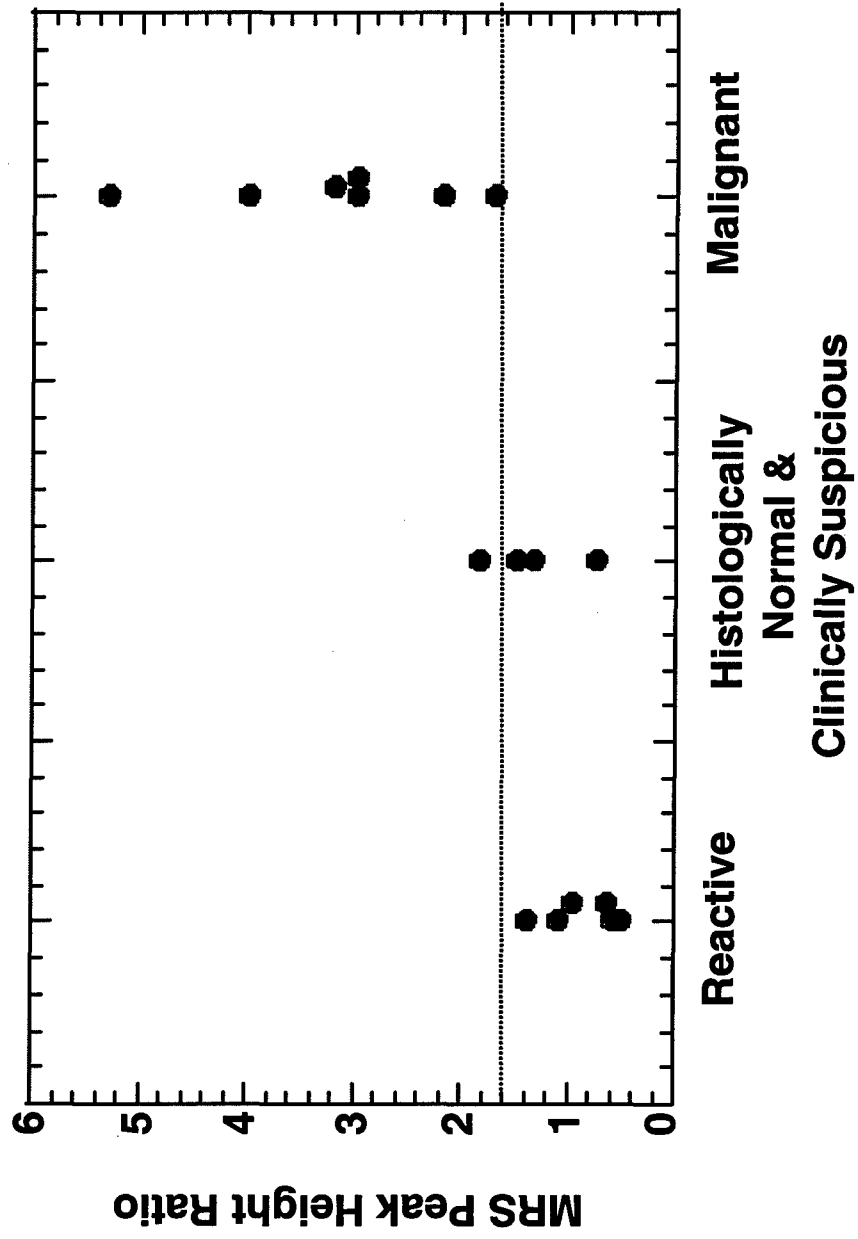


Table 1. Chemical species identified in 2D ^1H MR spectra of human breast specimens.

Molecules	Abbreviation	Coupling Partners (bold face)	Cross-peak Coordinates (ppm)
LIPIDS			f 2, f 1
Cholesterol	Z	$\text{CH}_3\text{-CH-ring}\alpha$	0.85, 1.52
Choline	Chol	$(\text{CH}_3)_3\text{N}^+\text{-CH}_2\text{-CH}_2\text{-OH}$	3.50, 4.07
Glycero-PC	GPC	$(\text{CH}_3)_3\text{N}^+\text{-CH}_2\text{-CH}_2\text{-OP(O)-O-CH}_2\text{-}$	3.69, 4.38
Phosphoethanolamine	PE	$(\text{CH}_3)_3\text{N}^+\text{-CH}_2\text{-CH}_2\text{-OPO}_3^-$	3.30, 4.14
Phosphocholine	PC	$(\text{CH}_3)_3\text{N}^+\text{-CH}_2\text{-CH}_2\text{-OPO}_3^-$	3.61, 4.25
Triacylglycerol	A	$\text{-CH}_2\text{-CH}_2\text{-CH}_3$	1.33, 0.90
	B	$\text{=CH-CH}_2\text{-CH}_2\text{-CH}_2\text{-}$	2.01, 1.33
	C	$\text{-CH}_2\text{-CH}_2\text{-CH=CH-}$	2.02, 5.38
	D	$\text{-CH=CH-CH}_2\text{-CH=CH-}$	5.38, 2.84
	E	$\text{-O-C(O)-CH}_2\text{-CH}_2\text{-CH}_2\text{-CH}_2\text{-}$	1.62, 1.33
	F	$\text{-O-C(O)-CH}_2\text{-CH}_2\text{-CH}_2\text{-CH}_2\text{-}$	2.30, 1.60
	G (vicinal)	$\text{RO-CH}_2\text{-CH (OR)-CH}_2\text{-OR}$	4.12, 5.26
G' (geminal)	$\text{RO-CHH}'\text{-CH-OR}$	4.09, 4.29	
AMINO ACIDS			
Alanine	Ala	-CH-CH_3	3.79, 1.49
Glutamate	Glu	$\text{-CH-CH}_2\text{-CH}_2\text{-COO}^-$	2.21, 2.62
Isoleucine	Ile	$\text{-CH}_2\text{-CH}_3$	2.12, 0.97
Leucine	Leu	$\text{-CH(CH}_3)_2$	1.78, 0.97
Lysine/polyamines	Lys	$\text{-CH}_2\text{-CH}_2\text{-CH}_2\text{-N}^+\text{H}_3$	1.72, 3.05
Threonine	Thr	-CH-CH (OH)-CH_3	4.27, 1.33
Valine	Val	$\text{-CH(CH}_3)_2$	2.34, 1.03
CARBOHYDRATE MOIETIES			
Fucose	Fuc I	-CH-CH_3	4.27, 1.33
	Fuc II	-CH-CH_3	4.28, 1.25
	Fuc III	-CH-CH_3	4.30, 1.41
OTHER METABOLITES			
Inositol	Inos	-CH (OH)-CH (OH)	3.28, 3.64
Lactate	Lac	-CH (OH)-CH_3	4.12, 1.33
Taurine	Tau	$\text{H}_3\text{N}^+\text{-CH}_2\text{-CH}_2\text{-OSO}_3^-$	3.28, 3.50
Unassigned			3.96, 3.11
			3.76, 1.92
			4.22, 1.35
			3.63, 1.15

Table 2
Computerized Consensus Diagnosis of MRS on FNA

A Malignant vs Benign (SNR <25)

	Sensitivity	Specificity	%Crisp
Present	93%	92%	96%
Absent	92%	92%	95%

Overall Accuracy: 93%
Overall % crisp: 96%

B Malignant vs Benign (SNR >25)

	Sensitivity	Specificity	%Crisp
Present	94%	98%	100%
Absent	98%	94%	98%

Overall Accuracy: 96%
Overall % crisp: 99%

Table 2 continued

C Lymph Node Infiltration

	Sensitivity	Specificity	%Crisp
Present	96%	94%	90%
Absent	94%	96%	100%

Overall Accuracy: 95%
Overall % crisp: 95%

D Vascular invasion

	Sensitivity	Specificity	%Crisp
Present	84%	100%	94%
Absent	100%	84%	94%

Overall Accuracy: 92%
Overall % crisp: 94%

Table 3: Molecules identified in the ¹H MR COSY spectra of tissue specimens taken from primary breast lesions.

Molecules	Abbreviation	Coupling Partners (bold face)	Cross-peak Coordinates (ppm)	Number of crosspeaks			
				benign (n=8)	CIS (n=3)	malignant (n=4)	
LIPID							
Cholesterol	Z	CH₂-CH -ringα	0.85, 1.52	0	0	0	
Choline	Cho	(CH₂)₂N⁺-CH₂-CH₂-OH	3.50, 4.07	1	0	0	
Glycerophosphocholine	Gro-P-Cho	(CH₂)₂N⁺-CH₂-CH₂-OP(O)-O-	3.69, 4.38	1	0	0	
Phosphocholine	Cho-P	(CH₂)₂N⁺-CH₂-CH₂-OPO₃⁻	3.61, 4.25	0	0	0	
Triacylglycerol	A	-CH₂-CH₂-CH₂-CH₃	1.33, 0.89	7	3	3	
	B	=CH-CH₂-CH₂-CH₂-	2.01, 1.33	7	3	3	
	C	-CH₂-CH₂-CH=CH-	2.01, 5.38	5	3	2	
	D	-CH=CH-CH₂-CH=CH-	5.38, 2.84	5	3	2	
	E	-O-C(O)-CH₂-CH₂-CH₂-CH₂	1.62, 1.33	6	3	3	
	F	-O-C(O)-CH₂-CH₂-CH₂-CH₂	2.30, 1.60	4	3	3	
	G (vicinal)	RC-CH₂-CH (OR)-CH₂-OR	4.12, 5.26; 4.26, 5.26	3	3	3	
G' (geminal)	RC-CHH'-CH-OR	4.09, 4.29	6	3	2		
AMINO ACIDS							
Alanine	Ala	-CH-CH₃	α-β	3.79, 1.49	2	0	0
Glutamate/glutamine	Glu/Gln	-CH-CH₂-CH₂-COO⁻	β-γ	2.10, 2.41	0	0	0
Isoleucine	Ile	-CH-CH₃	α-β	1.98, 1.02	2	3	1
Leucine	Leu	-CH-(CH₃)₂	γ-δ	1.71, 0.97	2	0	1
Lysine/polyamines	Lys	-CH₂-CH₂-CH₂-N⁺H₃	δ-ε	1.72, 2.98	3	0	3
Threonine	Thr	-CH-CH (OH)-CH₃	β-γ	4.27, 1.33	2	1	1
Valine	Val	-CH-(CH₃)₂	β-γ	2.34, 1.02	0	0	0
CARBOHYDRATES							
Fucose	Fuc I	-CH-CH₃		4.27, 1.33	2	1	1
	Fuc II	-CH-CH₃		4.28, 1.25	0	0	0
	Fuc III	-CH-CH₃		4.30, 1.41	1	0	0
OTHER METABOLITES							
myc-Inositol	Ins	H5-H6	-CH (OH)-CH (OH)	3.25, 3.64	0	0	0
Lactate	Lac		-CH (OH)-CH₃	4.12, 1.33	0	1	0
Taurine	Tau		H₃N⁺-CH₂-CH₂-	3.40, 3.26	1	0	0
Ethanol	EtOH		H₃C-CH₂-CH₃	3.66, 1.18	1	0	2

Table 4: Molecules identified in the ¹H MR COSY spectra of FNA specimens taken from primary breast lesions.

Molecules	Abbreviation	Coupling Partners (bold face)	Cross-peak Coordinates (ppm)	Number of crosspeaks		
				benign (n=2)	malignant (n=14)	
LIPID						
Cholesterol	Z	CH ₃ -CH-ring α	0.85, 1.52	0	5	
Choline	Cho	(CH ₃) ₃ N ⁺ -CH ₂ -CH ₂ -OH	3.50, 4.07	0	4	
Glycerophosphocholine	Gro-P-Cho	(CH ₃) ₃ N ⁺ -CH ₂ -CH ₂ -OP(O)-O-	3.69, 4.38	0	1	
Phosphocholine	Cho-P	(CH ₃) ₃ N ⁺ -CH ₂ -CH ₂ -OPO ₃ ⁼	3.61, 4.25	0	5	
Tricetylgerol	A	-CH ₂ -CH ₂ -CH ₂ -CH ₃	1.33, 0.89	2	14	
	B	=CH-CH ₂ -CH ₂ -CH ₂ -	2.01, 1.33	2	13	
	C	-CH ₂ -CH ₂ -CH=CH-	2.01, 5.38	1	8	
	D	-CH=CH-CH ₂ -CH=CH-	5.38, 2.84	0	4	
	E	-O-C(O)-CH ₂ -CH ₂ -CH ₂ -CH ₂	1.62, 1.33	2	14	
	F	-O-C(O)-CH ₂ -CH ₂ -CH ₂ -CH ₂	2.30, 1.60	2	12	
	G (vicinal)	RO-CH ₂ -CH (OR)-CH ₂ -OR	4.12,5.26; 4.26,5.26	0	3	
	G' (geminal)	RO-CHH'-CH-OR	4.09, 4.29	0	8	
AMINO ACIDS						
Alanine	Ala	-CH-CH ₃	α - β	3.79, 1.49	0	3
Glutamate/glutamine	Glu/Gln	-CH-CH ₂ -CH ₂ -COO ⁻	β - γ	2.10, 2.41	2	3
Iscieucine	Ile	-CH-CH ₃	α - β	1.98, 1.02	0	2
Leucine	Leu	-CH-(CH ₃) ₂	γ - δ	1.71, 0.97	0	2
Lysine/polyamines	Lys	-CH ₂ -CH ₂ -CH ₂ -N ⁺ H ₃	δ - ϵ	1.72, 2.98	1	7
Threonine	Thr	-CH-CH (OH)-CH ₃	β - γ	4.27, 1.33	1	3
Valine	Val	-CH-(CH ₃) ₂	β - γ	2.34, 1.02	1	3
CARBOHYDRATES						
Fucose	Fuc I	-CH-CH ₃	4.27, 1.33	1	3	
	Fuc II	-CH-CH ₃	4.28, 1.25	0	3	
	Fuc III	-CH-CH ₃	4.30, 1.41	0	2	
OTHER METABOLITES						
m/o-Inositol	Ins	H5-H6	-CH (OH)-CH (OH)	3.25, 3.64	0	2
Lactate	Lac		-CH (OH)-CH ₃	4.12, 1.33	1	11
Taurine	Tau		H ₃ N ⁺ -CH ₂ -CH ₂ -	3.40, 3.26	1	9
Ethanol	EtOH		HO-CH ₂ -CH ₃	3.66, 1.18	2	6



DEPARTMENT OF THE ARMY
US ARMY MEDICAL RESEARCH AND MATERIEL COMMAND
504 SCOTT STREET
FORT DETRICK, MARYLAND 21702-5012

*Rec'd
7/24/2001*

REPLY TO
ATTENTION OF:

MCMR-RMI-S (70-1y)

MEMORANDUM FOR Administrator, Defense Technical Information
Center (DTIC-OCA), 8725 John J. Kingman Road, Fort Belvoir,
VA 22060-6218

SUBJECT: Request Change in Distribution Statement

1. The U.S. Army Medical Research and Materiel Command has reexamined the need for the limitation assigned to technical reports. Request the limited distribution statement for reports on the enclosed list be changed to "Approved for public release; distribution unlimited." These reports should be released to the National Technical Information Service.

2. Point of contact for this request is Ms. Judy Pawlus at DSN 343-7322 or by e-mail at judy.pawlus@det.amedd.army.mil.

FOR THE COMMANDER:

Encl

PHYLLIS M. RINEHART
Deputy Chief of Staff for
Information Management