




Contents lists available at [SciVerse ScienceDirect](http://www.elsevier.com/locate/injury)

Injury

journal homepage: [www.elsevier.com/locate/injury](http://www.elsevier.com/locate/injury)



## Articular exposure with the swashbuckler versus a “Mini-swashbuckler” approach<sup>☆</sup>

Michael J. Beltran<sup>a,\*</sup>, James A. Blair<sup>a</sup>, Jeannie Huh<sup>a</sup>, Jess M. Kirby<sup>b</sup>, Joseph R. Hsu<sup>c,e</sup>, the Skeletal Trauma Research Consortium(STReC)<sup>d</sup>

<sup>a</sup> Department of Orthopaedics and Rehabilitation, San Antonio Military Medical Center, San Antonio, TX 78234, United States

<sup>b</sup> Department of Orthopaedics, USATTC/Ryder Trauma Center, Miami, FL 33136, United States

<sup>c</sup> Department of Orthopaedics and Rehabilitation, United States Army Institute of Surgical Research, Fort Sam Houston, TX 78234, United States

### ARTICLE INFO

#### Article history:

Accepted 21 October 2012

#### Keywords:

Swashbuckler  
Distal femur  
Minimally invasive  
Articular

### ABSTRACT

**Objective:** To quantify the articular exposure obtained with a Swashbuckler approach to the distal femur and compare this to a “Mini-swashbuckler” approach.

**Methods:** Forty surgical approaches in 20 fresh-frozen hemipelvis specimens were performed using a Mini-swashbuckler approach followed by a traditional Swashbuckler. Key anatomic landmarks, including the posterior femoral condyles, intercondylar notch, and medial articular margin, were either directly visualised or palpated with a tonsil clamp. Calibrated digital photographs were taken from the surgeon’s viewing perspective after each approach. The digital images were then analyzed using a computer software programme, *ImageJ* (NIH, Bethesda, MD), to calculate the articular surface square area exposed.

**Results:** The Mini-swashbuckler exposed 87% of the articular surface compared to the Swashbuckler approach (29.48 cm<sup>2</sup> vs 34.03 cm<sup>2</sup>,  $p < 0.0001$ ). Key anatomic landmarks were directly visualised with both exposures in all subjects, including limbs with severe osteoarthritis. Greater exposure with the Mini-swashbuckler correlated with male gender ( $p < 0.05$ ) and height ( $p = 0.03$ ) but not weight or BMI.

**Conclusions:** Although exposure is improved with the use of a Swashbuckler, this difference may not be of clinical importance, since both approaches give either direct visual or tactile access to all critical areas of the distal femur, including the trochlea, entire medial compartment, and both posterior femoral condyles. A less invasive approach allows a smaller surgical dissection without sacrificing the ability to visualise the majority of the articular surface.

Published by Elsevier Ltd.

### Introduction

Displaced intercondylar distal femur fractures require anatomic reduction of the articular surface to improve outcomes and reduce the incidence of post-traumatic arthritis.<sup>1–9</sup> Although indirect reduction manoeuvres are available, direct joint exposure with

visualisation of the articular surface is recommended to ensure an anatomic reduction.<sup>10,11</sup> Multiple approaches to the distal femur have been described, and inherent to all of them is the critical need to adequately visualise the entire articular surface. Popular approaches to the distal femur are laterally based, and it has been recommended that sufficient articular exposure requires extensile measures in order to gain access to the medial compartment of the knee.<sup>1,6,12–13</sup>

Recently Starr et al. have described their preferred “Swashbuckler” approach to the distal femur.<sup>14</sup> Because this extensile approach utilises an anterior incision at the knee, the authors argue that it does not compromise future skin incisions necessary for total knee arthroplasty. Extensile approaches to the distal femur, particularly those which expose the metadiaphysis, have previously been associated with an increased incidence of infection and need for autogenous bone grafting.<sup>1–4,15–16</sup> Modern minimally invasive plating techniques which utilise indirect reduction of the metadiaphysis, even in the presence of medial comminution, have led to predictably high rates of union without the need for grafting,

<sup>☆</sup> Investigation performed at the United States Army Institute of Surgical Research, Fort Sam Houston, TX 78234.

\* Corresponding author at: Department of Orthopaedics and Rehabilitation, Brooke Army Medical Center, Fort Sam Houston, TX 78234, United States. Tel.: +1 210 916 3410/617 849 2949; fax: +1 210 916 7323.

E-mail addresses: [Michael.beltran@amedd.army.mil](mailto:Michael.beltran@amedd.army.mil), [mibeltran0514@gmail.com](mailto:mibeltran0514@gmail.com) (M.J. Beltran), [James.blair@amedd.army.mil](mailto:James.blair@amedd.army.mil) (J.A. Blair), [Jeannie.huh@amedd.army.mil](mailto:Jeannie.huh@amedd.army.mil) (J. Huh), [Joseph.Hsu@amedd.army.mil](mailto:Joseph.Hsu@amedd.army.mil) (J.M. Kirby), [Jess.Kirby@amedd.army.mil](mailto:Jess.Kirby@amedd.army.mil) (J.R. Hsu).

<sup>d</sup> The Skeletal Trauma Research Consortium (STReC) is a corporate author.

<sup>e</sup> Dr Joseph Hsu receives institutional research support from the Geneva Foundation and is a committee member for the Society of Military Orthopaedic Surgeons (SOMOS).

# Report Documentation Page

Form Approved  
OMB No. 0704-0188

Public reporting burden for the collection of information is estimated to average 1 hour per response, including the time for reviewing instructions, searching existing data sources, gathering and maintaining the data needed, and completing and reviewing the collection of information. Send comments regarding this burden estimate or any other aspect of this collection of information, including suggestions for reducing this burden, to Washington Headquarters Services, Directorate for Information Operations and Reports, 1215 Jefferson Davis Highway, Suite 1204, Arlington VA 22202-4302. Respondents should be aware that notwithstanding any other provision of law, no person shall be subject to a penalty for failing to comply with a collection of information if it does not display a currently valid OMB control number.

1. REPORT DATE <b>01 FEB 2012</b>		2. REPORT TYPE <b>N/A</b>		3. DATES COVERED <b>-</b>	
4. TITLE AND SUBTITLE <b>Articular exposure with the swashbuckler versus a Mini-swashbuckler approach</b>				5a. CONTRACT NUMBER	
				5b. GRANT NUMBER	
				5c. PROGRAM ELEMENT NUMBER	
6. AUTHOR(S) <b>Beltran M. J., Blair J. A., Huh J., Kirby J. M., Hsu J. R.,</b>				5d. PROJECT NUMBER	
				5e. TASK NUMBER	
				5f. WORK UNIT NUMBER	
7. PERFORMING ORGANIZATION NAME(S) AND ADDRESS(ES) <b>United States Army Institute of Surgical Research, JBSA Fort Sam Houston, TX</b>				8. PERFORMING ORGANIZATION REPORT NUMBER	
9. SPONSORING/MONITORING AGENCY NAME(S) AND ADDRESS(ES)				10. SPONSOR/MONITOR'S ACRONYM(S)	
				11. SPONSOR/MONITOR'S REPORT NUMBER(S)	
12. DISTRIBUTION/AVAILABILITY STATEMENT <b>Approved for public release, distribution unlimited</b>					
13. SUPPLEMENTARY NOTES					
14. ABSTRACT					
15. SUBJECT TERMS					
16. SECURITY CLASSIFICATION OF:			17. LIMITATION OF ABSTRACT <b>UU</b>	18. NUMBER OF PAGES <b>5</b>	19a. NAME OF RESPONSIBLE PERSON
a. REPORT <b>unclassified</b>	b. ABSTRACT <b>unclassified</b>	c. THIS PAGE <b>unclassified</b>			

with a low incidence of infection and low estimated blood loss.<sup>10–11,17–18</sup>

At our institution we routinely use a modification of the Swashbuckler,<sup>14</sup> which we have termed the “Mini-swashbuckler.” It utilises a smaller lateral skin incision with a comparable deep dissection, allowing access to the articular surface of the distal femur, including the medial compartment and posterior condyles, without the need for extensile measures. Using a cadaveric model, we hypothesised that the Mini-swashbuckler would provide nearly equivalent access to the articular surface compared to the traditional Swashbuckler approach, with a traditional Swashbuckler providing no more than an additional 20% articular exposure. Furthermore, we hypothesised that any difference in exposure would not be clinically relevant, with both approaches affording equal access to all critical articular surfaces necessary for anatomic reduction of displaced intercondylar femur fractures.

### Materials and methods

This study was conducted under a protocol reviewed and approved by the US Army Medical Research and Materiel Command Institutional Review Board, and in accordance with the approved protocol. Twenty fresh frozen cadaveric hemipelvis specimens were obtained (LifeLegacy, Phoenix, AZ). All specimens were confirmed to have no prior surgeries about the knee, and each was confirmed to have no surgical scars. Specimens were positioned on a 30° radiolucent triangle at a height most comfortable for the surgeon, in order to most closely approximate actual operating room conditions. All approaches were then performed by the senior author (J.R.H.), a fellowship-trained orthopaedic traumatologist. A Mini-swashbuckler approach was first performed on each specimen, followed by extending the incision to a traditional Swashbuckler exposure. Anatomic landmarks were either directly visualised or palpated with the use of a tonsil clamp. Once each exposure was complete, a small metric ruler was placed on the articular surface and a calibrated digital photograph of the exposed distal femur was taken from an angle best representing the operating surgeon’s perspective. To afford maximal articular exposure, the knee was flexed off the table for each photograph. These photographs were analyzed using a computer software program, *ImageJ* (NIH, Bethesda, MD), which compares a known distance (i.e. the metric ruler in each image) to the actual number of pixels in the digital photograph. The software uses this information to calculate the square area of the articular distal femur seen in each exposure.

### Description of approach

To perform the Mini-swashbuckler approach a 12 cm incision is made extending from the lateral edge of the tibial tubercle to the superolateral corner of the patella. Sharp dissection is then used to develop full thickness skin flaps. Flaps are developed only enough to visualise the underlying lateral patellar retinaculum. A trapezoidal shaped incision (Fig. 1) through the retinaculum is then used to gain access to the knee joint. This incision begins distally at the lateral edge of the patellar tendon, and extends proximal along the lateral margin of the patella before being carried laterally across the retinaculum at the distal end of the vastus lateralis muscle belly. Four sequential steps are then utilised to gain improved access to the distal femur. First, the patellar tendon is bluntly swept off the retropatellar fat pad with finger dissection, and an Army–Navy retractor placed to protect the tendon. Second, the entire fat pad and synovial reflection is excised en bloc to the level of the intermeniscal ligament, taking care to protect the menisci and the intermeniscal ligament. The third step involves ensuring complete release of the retinaculum distally to

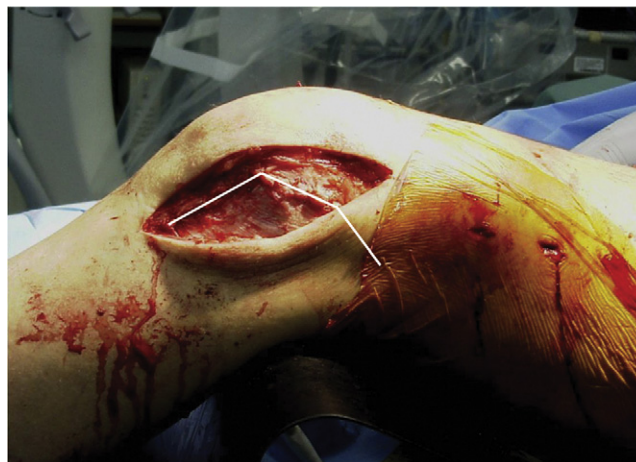

Fig. 1. Clinical photograph demonstrating outline of trapezoidal-shaped retinacular incision. Note that proximally the incision remains within the lateral retinaculum and does not violate the vastus muscle belly.

the tibial tubercle. Finally, the superior retinaculum is released proximally enough to gain access to the suprapatellar pouch. Two sharp Hohmann retractors are then placed to improve exposure. The first Hohmann retractor is placed through the medial capsule, just over the medial meniscus onto the medial proximal tibia and aids in retraction of the patella. The second Hohmann retractor is placed across the suprapatellar pouch. At this point the Mini-swashbuckler exposure is complete (Fig. 2).

The traditional extensile Swashbuckler approach was performed by extending the incision proximally in a longitudinal fashion to a length of 30 cm using a metric ruler. This length was arbitrarily chosen because it extends the incision approximately one-third the length of the thigh; no standardised length is described by Starr et al.<sup>14</sup> The deep dissection was performed in an identical fashion to the Swashbuckler approach. The vastus fascia was incised in line with the skin incision and elevated off the underlying vastus lateralis until the intermuscular septum was met. Using a Cobb elevator, the vastus lateralis muscle belly was elevated off the intermuscular septum. Two additional Homan retractors were then placed across the femoral shaft and the muscle belly was retracted medially. If an accessory genu

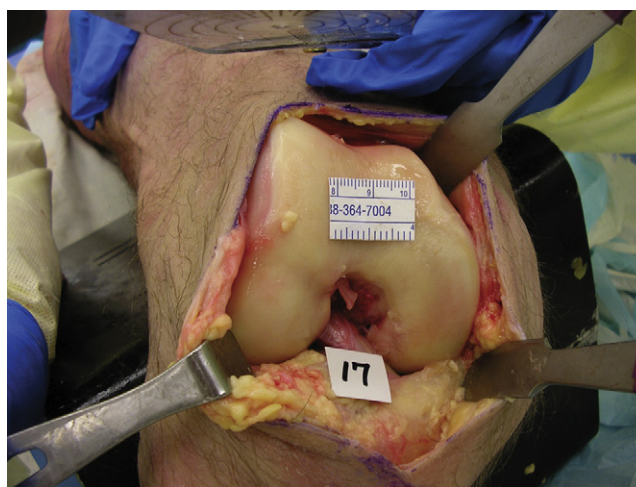
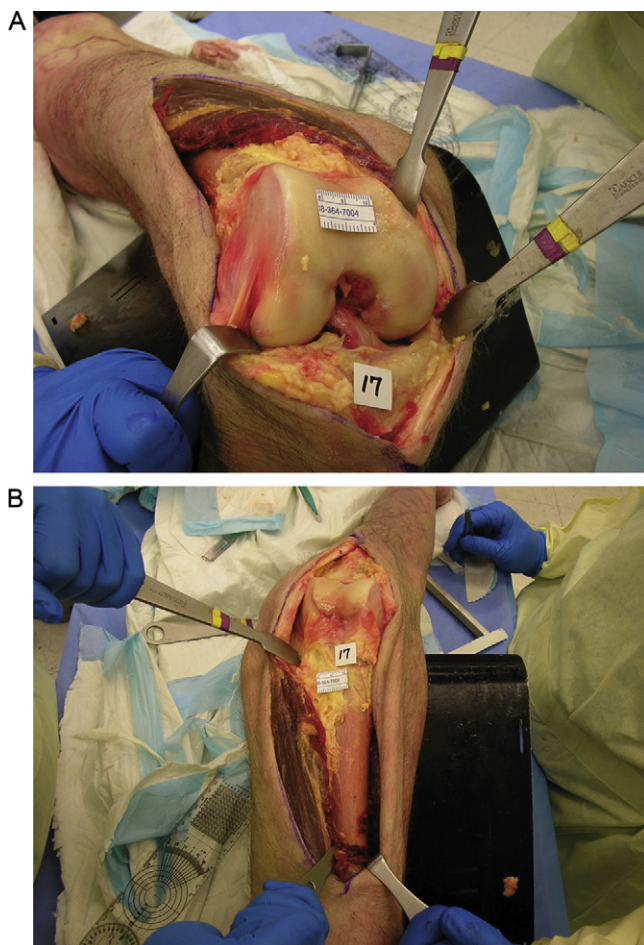


Fig. 2. Thirty degree optimal viewing angle of surgeon after Mini-swashbuckler approach. A metric ruler is used to calibrate the digital photograph. Note that nearly the entire articular surface of the distal femur is available for direct visualisation.

articularis muscle was present, this was mobilised off the distal femoral shaft and also retracted medially (Fig. 3A and B).

**Data collection**

Demographic data for each cadaveric specimen was collected to include: age, gender, height, weight, and body mass index (BMI). We defined osteoarthritis as the presence of osteophytes and complete cartilage eburnation with exposed subchondral bone. Severe osteoarthritis existed if the changes were so severe as to alter the bony morphology of the distal femur. In each dissection the following six anatomic landmarks were identified: proximal extent of trochlear cartilage, medial margin of the articular surface of the medial femoral condyle, superior articular margin of both the lateral and medial femoral condyle, and posterior extent of both the medial and lateral femoral condyles. The posterior extent of each condyle was defined as the apex of the posterior femoral condyles with the knee flexed to the standard 30°. The surgeon's best viewing perspective was determined to be 30° from the axis of the femoral shaft. In addition, after each extensile exposure, an additional digital photograph was taken, with length standardised using a metric ruler, to determine the most proximal extent of the femoral shaft. This photograph was obtained variably at different angles, and not at the standardised 30° used for the articular surface visualisation.



**Fig. 3.** (A) The same extremity after surgical extension to a traditional Swashbuckler approach. Although exposure is dramatically improved in the metadiaphyseal region, the difference at the joint is subtle. (B) Superior view demonstrating the extent of proximal shaft exposure after a Swashbuckler approach. The entire metadiaphyseal region and much of the diaphysis is easily exposed.

**Data analysis**

Collected data was analyzed for statistical significance of observed differences in outcomes. Continuous variables and scores were compared via the Student's *t*-test for parametric data. Dichotomous variables were compared using the Chi-square test or Fisher Exact test, as appropriate. All reported *p*-values are 2-tailed, with a  $p \leq 0.05$  determining statistical significance. Statistical analysis was performed with SAS 9.1 (Cary, NC).

**Results**

The described approaches were successfully performed in all specimens in sequential fashion. Full demographic data regarding the cadaveric specimens is shown in Table 1. There were 12 right limbs and 8 left limbs. No significant differences were found between right and left limbs with respect to age, gender, height, weight, BMI, or presence of osteoarthritis. Out of the 20 limbs, 9 (45%) had evidence of osteoarthritis, with 2 of those 9 (10%) having evidence of severe osteoarthritis. In all 20 specimens the 6 key anatomic landmarks (proximal extent of trochlear cartilage, medial articular margin of medial femoral condyle, superior articular margin of lateral and medial femoral condyles, and posterior extent of lateral and medial femoral condyles) could be identified with direct visualisation. The average articular surface square area exposed with the Mini-swashbuckler approach was 28.63 cm<sup>2</sup> (range 19.23–38.65, std 6.12). Articular exposure with the Mini-swashbuckler approach correlated with male gender ( $r = 0.60, p < 0.05$ ) and height ( $r = 0.48, p = 0.03$ ). The average articular surface square area exposed with the traditional Swashbuckler approach was 33.95 cm<sup>2</sup> (range 21.34–45.63, std 6.78). The surface area seen with the extensile exposure also correlated with male gender ( $r = 0.46, p = 0.04$ ) but not with height ( $r = 0.37, p = 0.11$ ). Neither exposure correlated with weight or BMI. There was no statistically significant difference in the exposure obtained with either a Mini-swashbuckler or traditional Swashbuckler approach between the limbs with or without osteoarthritis ( $p = 0.1781, 0.2451$ ). Using an outlier subgroup analysis, we eliminated the 2 limbs demonstrating evidence of severe osteoarthritis. In the remaining 18 cadaveric limbs, the average articular surface area exposed with the traditional Swashbuckler was 34.03 cm<sup>2</sup> versus 29.48 cm<sup>2</sup> with the Mini-swashbuckler. In these 18 limbs, using average articular surface square area, the Mini-swashbuckler exposed 87% of the articular

**Table 1**  
Age and demographic data for all twenty cadaveric specimens.

	Age	Gender	Height (in.)	Weight (lb)	BMI	Side
1	84	M	65	100	17	R
2	84	M	65	100	17	L
3	92	M	64	151	26	R
4	73	F	65	76	13	L
5	79	F	64	120	21	L
6	95	F	61	120	23	R
7	80	F	65	166	28	L
8	80	F	65	166	28	R
9	57	M	70	173	25	L
10	72	M	68	155	24	L
11	88	M	67	112	18	R
12	79	F	64	120	21	R
13	88	M	67	112	18	L
14	73	F	65	76	13	R
15	53	F	66	194	31	R
16	69	M	70	110	16	R
17	62	M	73	133	18	R
18	54	M	69	104	15	R
19	54	M	69	104	15	L
20	69	M	70	110	16	R

surface compared to the Swashbuckler ( $p < 0.0001$ ). The average proximal extent of the femoral shaft exposed with the Swashbuckler approach was 17.03 cm (range 12.13–20.96, std 2.17).

## Discussion

Displaced intercondylar distal femur fractures require anatomic reduction of the articular surface. Multiple authors have previously shown that articular incongruity leads to poor outcomes.<sup>1–3,5,8,9</sup> In order to anatomically reduce articular fractures, the surgeon must be able to directly visualise the joint to gauge the quality of reduction. The classic lateral approach to the distal femur described by Marcy in 1947 remains popular and has been well described in commonly used textbooks of orthopaedics and surgical approaches.<sup>12,19</sup> This approach has been criticised, however, for providing poor access to the intercondylar notch and medial compartment of the knee, areas where intra-articular fracture planes are common and may be initially missed.<sup>20,21</sup> Access to the medial compartment may be improved by modifying the classic lateral approach, either with the use of a J-shaped or hockey-stick type incision; some have even recommended tibial tubercle osteotomy to gain exposure.<sup>1,6,13</sup> Although the classic medial parapatellar arthrotomy remains the workhorse approach to the knee for arthroplasty, its use for distal femur fractures is limited because of difficulty with proximal extension.

Starr et al. have recently described their recommended “Swashbuckler” approach to the distal femur, one which they argue allows complete exposure of the entire distal femur, while at the same time sparing the extensor mechanism and allowing for future knee arthroplasty.<sup>14</sup> The major drawback of this approach remains its large extensile skin incision and extensive soft tissue dissection of the quadriceps off the distal femur. Because of its extensile nature, the additional soft tissue stripping necessary may leave metadiaphyseal fractures prone to problems with union. A higher blood loss and decreased periosteal perfusion may also result from disruption of the segmental perforating femoral vessels or nutrient artery.<sup>22</sup>

The data presented suggest that a small less invasive skin incision with a well-performed dissection allows access to all important intra-articular regions of the knee, including the trochlea and entire medial compartment as far as the medial articular margin. The importance of the deep dissection cannot be overemphasised. The four sequential steps described gradually increase articular exposure, particularly the excision of the fat pad and synovial reflection. This step is the most critical if one wishes to see into the notch and across the medial condyle. Although concerns regarding fat pad excision causing patellar tendon contracture are warranted, the current literature has failed to identify a strong relationship between the two.<sup>23,24</sup> In all specimens we were also able to visualise or easily palpate the posterior aspect of both the lateral and medial condyles, areas critical in the accurate reduction of coronal plane fractures. Because these fractures are more common than previously thought, their identification and anatomic reduction must not be overlooked.<sup>16</sup> Furthermore the approach adheres to biologically friendly principles and avoids dissection in the area of the metadiaphysis; this technique has been shown to lead to high rates of union without need for bone grafting, even in open fractures.<sup>17,18</sup>

The Mini-swashbuckler was shown to expose 87% of the articular surface possible with the traditional Swashbuckler approach. Despite this quantitative difference, clinically there remains little difference between the two approaches, as the operating surgeon has visual and tactile access to all critical areas of the distal femur.

There are a number of weaknesses in the present study. As a cadaveric study it relied on the limbs of older patients – the

average cadaver age in our subjects was 67 years, much older than the average age of trauma patients. However, elderly distal femur fractures secondary to low energy mechanisms are increasing, and our data indicates that a less invasive approach represents a viable option in this expanding patient population. Because of the elderly nature of the subjects, many of the limbs had evidence of osteophytosis and associated soft tissue contracture, making exposure more difficult. In clinical practice, knees of this type may be better suited for arthroplasty than open reduction and internal fixation. Furthermore the digital software used relies on a two dimensional image to approximate the surface area of a three dimensional structure. This last point may in fact *overestimate* the difference in articular exposure between the mini and traditional Swashbuckler approaches by not taking into account the surgeon's ability to utilise a “mobile window” of exposure and to adjust his/her sight line to see different areas of the joint.

Another major weakness included a slight difference in the skin incision than that described by Starr et al.<sup>14</sup> While they utilise a midline incision at the knee that curves laterally and proximally, we extended our oblique incision, as that represents the standard location for the Mini-swashbuckler. Because this lateral incision lies only a few centimetres from the midline, we feel it probably does nothing to limit or influence the critical dissection necessary with the approach.

In conclusion, this study has demonstrated that in a cadaveric model the Mini-swashbuckler approach exposes 87% of the articular surface compared to the Swashbuckler approach in limbs without osteoarthritis. A Mini-swashbuckler allows direct visual access to all critical areas of the knee joint, including the entire trochlea, medial articular margin, and posterior femoral condyles, areas where fracture planes are common and anatomic reduction critical. Future clinical studies are needed to confirm these results and determine the true efficacy of utilising a Mini-swashbuckler approach for the management of displaced intercondylar distal femur fractures.

## References

1. Olerud S. Operative treatment of supracondylar–condylar fractures of the femur. Technique and results in fifteen cases. *The Journal of Bone and Joint Surgery* 1972;**54**:1015–32.
2. Schatzker J, Lambert DC. Supracondylar fractures of the femur. *Clinical Orthopaedics and Related Research* 1979;**138**:77–83.
3. Schatzker J, Horne G, Waddell J. The Toronto experience with the supracondylar fracture of the femur, 1966–1972. *Injury* 1974;**6**:113–28.
4. Giles JB, DeLee JC, Heckman JD, Keever JE. Supracondylar–intercondylar fractures of the femur treated with a supracondylar plate and lag screw. *The Journal of Bone and Joint Surgery* 1982;**64**:864–70.
5. Johnson EE. Combined direct and indirect reduction of comminuted four-part intra-articular T-type fractures of the distal femur. *Clinical Orthopaedics and Related Research* 1988;**231**:154–62.
6. Mize RD, Buchholz RW, Grogan DP. Surgical treatment of displaced, comminuted fractures of the distal end of the femur. *The Journal of Bone and Joint Surgery* 1982;**64**:871–9.
7. Johnson KD, Hicken G. Distal femoral fractures. *Orthopedic Clinics of North America* 1987;**18**:115–32.
8. Rademakers MV, Kerkhoffs GM, Siersevelt IN, Raaymakers EL, Marti RK. Intra-articular fractures of the distal femur – a long-term follow-up study of surgically treated patients. *Journal of Orthopaedic Trauma* 2004;**18**:213–9.
9. Healy WL, Brooker AF. Distal femoral fractures. Comparison of open and closed methods of treatment. *Clinical Orthopaedics and Related Research* 1983;**174**:166–71.
10. Bolhofner BR, Carmen B, Clifford P. The results of open reduction and internal fixation of distal femur fractures using a biologic (indirect) reduction technique. *Journal of Orthopaedic Trauma* 1996;**10**:372–7.
11. Ostrum RF, Geel C. Indirect reduction and internal fixation of supracondylar femur fractures without bone graft. *Journal of Orthopaedic Trauma* 1995;**9**:278–84.
12. Marcy GH. The posterolateral approach to the femur. *The Journal of Bone & Joint Surgery* 1947;**29**:676–8.
13. Muller ME, Allgower M, Schneider R, Willenegger H. *Manual of internal fixation: techniques recommended by the AO-ASIF group*. 3rd ed. Berlin: Springer-Verlag; 1991.

14. Starr AJ, Jones AL, Reinert CM. The “Swashbuckler”: a modified anterior approach for fractures of the distal femur. *Journal of Orthopaedic Trauma* 1999;13:138–40.
15. Sanders R, Regazzoni P, Ruedi TP. Treatment supracondylar-intercondylar fractures of the femur using the dynamic condylar screw. *Journal of Orthopaedic Trauma* 1989;3:214–22.
16. Sanders R, Swiontkowski M, Rosen H, Helfet D. Double-plating of comminuted, unstable fractures of the distal part of the femur. *The Journal of Bone and Joint Surgery* 1991;73:341–6.
17. Weight M, Collinge C. Early results of the less invasive stabilization system for mechanically unstable fractures of the distal femur (AO/OTA types A2, A3, C2, and C3). *Journal of Orthopaedic Trauma* 2004;18:503–8.
18. Kregor PJ, Stannard JA, Zlowodski M, et al. Treatment of distal femur fractures using the less invasive stabilization system. Surgical experience and early clinical results in 103 fractures. *Journal of Orthopaedic Trauma* 2004;18:509–20.
19. Hoppenfeld S, DeBoer P, Buckley R. *Surgical exposures in orthopaedics: the anatomic approach*. Philadelphia: Lippincott Williams and Wilkins; 2009.
20. Nork SE, Segina DN, Aflatoon K, Barei DP, Henley MB, Holt S, et al. The association between supracondylar-intercondylar distal femur fractures and coronal plane fractures. *The Journal of Bone and Joint Surgery* 2005;87:564–9.
21. Butler MS, Brumback RJ, Ellison TS, Poka A, Bathon GH, Burgess AR. Interlocking intramedullary nailing for ipsilateral fractures of the femoral shaft and distal part of the femur. *The Journal of Bone and Joint Surgery* 1991;73:1492–502.
22. Farouk O, Krettek C, Miclau T, Schandelmaier P, Guy P, Tscherne H. Minimally invasive plate osteosynthesis and vascularity: preliminary results of a cadaver injection study. *Injury* 1997;28(Suppl. 1):A7–12.
23. Macule F, Sastre S, Lasurt S, Sala P, Segur JM, Mallofre C. Hoffa’s fat pad resection in total knee arthroplasty. *Acta Orthopaedica Belgica* 2005;71:714–7.
24. Meneghini RM, Pierson JL, Bagsby D, Berend ME, Ritter MA, Meding JB. The effect of retropatellar fat pad excision on patellar tendon contracture and functional outcomes after total knee arthroplasty. *Journal of Arthroplasty* 2007;22:47–50.