

Does the Zone of Injury in Combat-Related Type III Open Tibia Fractures Preclude the Use of Local Soft Tissue Coverage?

Travis C. Burns, MD,* Daniel J. Stinner, MD,* Daniel R. Possley, DO,* Andrew W. Mack, MD,†
Tobin T. Eckel, MD,† Benjamin K. Potter, MD,† Joseph C. Wenke, PhD,‡ and
Joseph R. Hsu, MD,‡ the Skeletal Trauma Research Consortium (STReC)

Objectives: Does the large zone of injury in high energy, combat related open tibia fractures limit the effectiveness of rotational flap coverage?

Design: Retrospective consecutive series.

Setting: This study was conducted at Brooke Army Medical Center, Walter Reed Army Medical Center, and National Naval Medical Center between March 2003 and September 2007.

Patients/Participants: We identified 67 extremities requiring a coverage procedure out of 213 consecutive combat related Type III open diaphyseal tibia fractures.

Intervention: The 67 Type III B tibia fractures were treated with rotational or free flap coverage.

Main Outcome Measures: Flap failure, reoperation, infection, amputation, time to union, and visual pain scale.

Results: There were no differences between the free and rotational flap cohorts with respect to demographic information, injury characteristics, or treatment before coverage. The reoperation and amputation rates were significantly lower for the rotational coverage group (30% and 9%) compared with the free flap group (64% and 36%; $P = 0.05$ and $P = 0.03$, respectively). The coverage failure rate was also lower for the rotational flap cohort (7% versus 27%, $P = 0.08$). The average time to fracture union for the free flap group

was 9.5 months (range, 5–15.8 months) and 10.5 months (range, 3–41 months) for the rotational flap group ($P = 0.99$).

Conclusions: There was a significantly lower amputation and reoperation rate for patients treated with rotational coverage. Contrary to our hypothesis and previous reports, the zone of injury in combat related open tibia fractures does not preclude the use of local rotational coverage when practicable.

Key Words: open, tibia, fracture, flap, rotational

(*J Orthop Trauma* 2010;24:697–703)

INTRODUCTION

Many soft tissue defects associated with open diaphyseal tibia fractures can be covered with rotational flap techniques, most commonly gastrocnemius or soleus muscle flaps.¹ Free tissue transfer is reserved for soft tissue defects in the distal third of the tibia, soft tissue defects too large for rotational coverage, or severely injured extremities without viable local tissue available for rotation. Compared with rotational coverage, free tissue transfer is a more technically demanding procedure requiring microsurgical expertise.² Furthermore, use of free tissue transfer incurs the morbidity associated with the donor site.^{3–5} Conversely, several authors have cautioned against the use of local rotational flaps in severe lower extremity trauma as a result of high failure rates ostensibly secondary to unrealized large zones of injury involving the rotated tissue.^{6,7}

Multiple studies have evaluated soft tissue coverage outcomes in civilian patients with open tibia fractures injured predominantly in motor vehicle collisions, but there is a paucity of data on outcomes of soft tissue coverage for open tibia fractures in combat-injured patients.⁸ An open tibia fracture caused by a blast mechanism would seem to be the least tolerant of local rotational coverage with the highest wound complications as a result of a large and evolving zone of injury.⁹ We hypothesized that the open Type III B and III C tibia fractures from Operation Iraqi Freedom and Operation Enduring Freedom would have a higher complication rate when treated with rotational versus free soft tissue coverage.

Accepted for publication December 9, 2009.

From *Brooke Army Medical Center, Fort Sam Houston, TX; †Walter Reed Army Medical Center, Washington, DC; and ‡US Army Institute of Surgical Research (USAISR), Fort Sam Houston, TX.

The authors report no financial disclosures related to their work on this manuscript. Drs. Stinner and Wenke report that Smith & Nephew provided institutional support in the form of Negative Pressure Wound Therapy (NPWT) supplies for research not related to this project.

This study was presented in part at the 11th Annual George E. Omer, Jr. Research and Alumni Lectureship, San Antonio, TX, 2009.

The opinions or assertions contained herein are the private views of the authors and are not to be construed as official or as reflecting the views of the Department of the Army or the Department of Defense.

Reprints: Travis C. Burns, MD, Brooke Army Medical Center, Building 3600, 3851 Roger Brook Drive, Ft. Sam Houston, TX 78234-6200 (e-mail: Travis.Burns@amedd.army.mil).

Copyright © 2010 by Lippincott Williams & Wilkins

Report Documentation Page

Form Approved
OMB No. 0704-0188

Public reporting burden for the collection of information is estimated to average 1 hour per response, including the time for reviewing instructions, searching existing data sources, gathering and maintaining the data needed, and completing and reviewing the collection of information. Send comments regarding this burden estimate or any other aspect of this collection of information, including suggestions for reducing this burden, to Washington Headquarters Services, Directorate for Information Operations and Reports, 1215 Jefferson Davis Highway, Suite 1204, Arlington VA 22202-4302. Respondents should be aware that notwithstanding any other provision of law, no person shall be subject to a penalty for failing to comply with a collection of information if it does not display a currently valid OMB control number.

1. REPORT DATE 01 NOV 2010	2. REPORT TYPE N/A	3. DATES COVERED -		
4. TITLE AND SUBTITLE Does the zone of injury in combat-related Type III open tibia fractures preclude the use of local soft tissue coverage?		5a. CONTRACT NUMBER		
		5b. GRANT NUMBER		
		5c. PROGRAM ELEMENT NUMBER		
6. AUTHOR(S) Burns T. C., Stinner D. J., Possley D. R., Mack A. W., Eckel T. T., Potter B. K., Wenke J. C., Hsu J. R.,		5d. PROJECT NUMBER		
		5e. TASK NUMBER		
		5f. WORK UNIT NUMBER		
7. PERFORMING ORGANIZATION NAME(S) AND ADDRESS(ES) United States Army Institute of Surgical Research, JBSA Fort Sam Houston, TX		8. PERFORMING ORGANIZATION REPORT NUMBER		
9. SPONSORING/MONITORING AGENCY NAME(S) AND ADDRESS(ES)		10. SPONSOR/MONITOR'S ACRONYM(S)		
		11. SPONSOR/MONITOR'S REPORT NUMBER(S)		
12. DISTRIBUTION/AVAILABILITY STATEMENT Approved for public release, distribution unlimited				
13. SUPPLEMENTARY NOTES				
14. ABSTRACT				
15. SUBJECT TERMS				
16. SECURITY CLASSIFICATION OF:			17. LIMITATION OF ABSTRACT	
a REPORT unclassified	b ABSTRACT unclassified	c THIS PAGE unclassified	UU	18. NUMBER OF PAGES 7
				19a. NAME OF RESPONSIBLE PERSON

PATIENTS AND METHODS

Between March 2003 and September 2007, 193 patients with 213 Gustilo and Anderson Type III open diaphyseal tibia fractures were treated at our three institutions. We included all active-duty personnel injured in combat operations in Operation Iraqi Freedom or Operation Enduring Freedom that sustained an open Type III diaphyseal tibia fractures requiring soft tissue coverage of a traumatic wound. We defined diaphyseal as those fractures that did not extend to within 5 cm of the tibial plateau or tibial plafond.¹⁰ We identified 67 Type III B or C fractures that received a soft tissue coverage procedure with average follow up of 24 months (range, 5–54 months) after injury. The study group included 56 patients who received a local rotational flap and 11 patients who received a free soft tissue transfer for soft tissue coverage. We reviewed the medical records and radiographs of these patients to record mechanism of injury, injury characteristics, treatment data, complications, and time to radiographic fracture healing. The study was approved by our Institutional Review Boards.

Data were collected at each participating institution from local trauma databases, operative logs, the Joint Theater Trauma Registry, and local inpatient and outpatient records. The severity of the injury was characterized by the soft tissue defect and recorded based on the Gustilo and Anderson classification.^{11–13} The fracture severity was classified according to the Orthopaedic Trauma Association AO fracture classification.¹⁴

Data Analysis

To determine if the morbidity of the injury to the surrounding zone of soft tissue affects the success rate of local rotational soft tissue coverage in combat-related open tibia fractures, we compared the success of coverage, complication rates, visual pain scores, time to radiographic fracture union, and progression to amputation for local rotational coverage and free soft tissue transfers. Flap infections were defined as a wound infection at the coverage site within 2 weeks of rotational or free flap coverage that required a return to the operating room. A deep soft tissue infection was defined as any soft tissue infection greater than 2 weeks after the coverage procedure that was not successfully treated by antibiotics and required a return to the operating room. Osteomyelitis was defined as a deep infection with positive intraoperative bone cultures during the return to the operating room. Failure of soft tissue coverage was assessed by need to return to the operating room for a revision coverage operation. Partial necrosis of the coverage procedure was defined as partial flap necrosis that required a return to the operating room for débridement but did not require a revision coverage procedure. The total reoperation rate is the percentage of patients that returned to the operating room for revision coverage after flap failure, débridement of partial necrosis, or débridement of a flap infection. Time to radiographic union was defined as bridging callus across three of four cortices on orthogonal radiographs evaluated by one investigator at each site.

Statistical analyses were performed to assess for differences between the groups with regard to patient age and sex, mechanism of injury, soft tissue location, fracture severity, fracture stabilization, and patient Injury Severity

Scores and Abbreviated Injury Scale. The collected data were then analyzed for statistical significance of observed differences in outcomes. Descriptive statistical analysis for demographic data included the means and standard deviations. Continuous variables and scores were compared through the Wilcoxon test for nonparametric and score data, and Student *t* test for parametric data. Dichotomous variables were compared using the chi square test or Fisher exact test, as appropriate. All reported *P* values are two-tailed with an $\alpha \leq 0.05$ determining statistical significance. Statistical analysis was performed with SAS 9.1 (Cary, NC).

RESULTS

There were 67 extremities that required soft tissue coverage procedures in 63 patients, 11 free tissue transfers and 56 local rotational flaps. All free tissue transfers were performed by fellowship-trained surgeons experienced in microvascular repair. The patients evaluated in the study had an average of 26.7 months (range, 5–56 months) follow up after their injury. The mean age of the patients undergoing reconstruction was 27 years (range, 19–45 years). The free and rotational flap groups were not different with respect to demographic information, injury severity, injury location, fracture stabilization, or injury treatment.

Specifically, there were no detectable differences between the free and rotational coverage groups with respect to age, sex, injury mechanism, Injury Severity Score, or Abbreviated Injury Score (Table 1). Of the 67 open fractures, 43 were treated with a circular external fixator, 12 were treated with an intramedullary nail, 11 were treated with a monolateral external fixator, and one was definitively managed with an open reduction and plate osteosynthesis. Each fracture was treated according to the preference of the treating staff physician. There were no detectable differences in injury severity or management before coverage between the two groups as evaluated by soft tissue and fracture classifications, number of débridements before coverage, timing of coverage, Gustilo and Anderson classification, Orthopaedic Trauma Association fracture classification, or presence of a segmental osseous defect (Table 2).

Rotational and free flaps were used to treat a similar percentage of injuries in the proximal, middle, and distal

TABLE 1. Distributions of Patient Characteristics

	Rotational (n = 56)	Free (n = 11)	<i>P</i>
Patient characteristics			
Age, mean ± SD (yr)	27 ± 6	27 ± 4	0.47
Male, % (n)	96% (54)	91% (10)	0.42
Mechanism, % (n)			
Blast	80 (45)	73 (8)	0.69
GSW	16 (9)	18 (2)	1.00
Other	4 (2)	9 (1)	0.49
Injury scores, mean ± SD			
ISS	15 ± 10	13 ± 7	0.41
AIS	3.8 ± 2	4.1 ± 2	0.10

TABLE 2. Comparison of Injury Characteristics

	Rotational (n = 56)	Flap (n = 11)	P
Days to coverage, mean ± SD	19.8 ± 13	19.5 ± 11	0.98
Soft Tissue Classification, % (n)			
Gustilo Anderson type IIIB	93 (52)	91 (10)	1.00
Gustilo Anderson type IIIC	7 (4)	9 (1)	1.00
OTA Fracture classification, % (n)			
OTA type A	11 (6)	9 (1)	1.00
OTA type B	27 (15)	18 (2)	0.72
OTA type C	63 (35)	73 (8)	0.33
Soft tissue defect location, % (n)			
Proximal	30 (17)	27 (3)	1.00
Middle	43 (24)	27 (3)	0.50
Distal	27 (15)	45 (5)	0.28
Osseous defect, % (n)			
Segmental defect present	29 (16)	45 (5)	0.30

aspect of the leg. Although there was no difference in the distribution of injuries between the two cohorts, there were significant differences in outcomes. Specifically, subgroup analyses comparing distal third soft tissue coverage with more proximal defects revealed significant differences. Rotational flaps used to cover defects in the proximal and middle third of the leg had a significantly lower failure rate (2%) than free flaps used in the same location (33%; $P = 0.004$) (Fig. 1A, B).

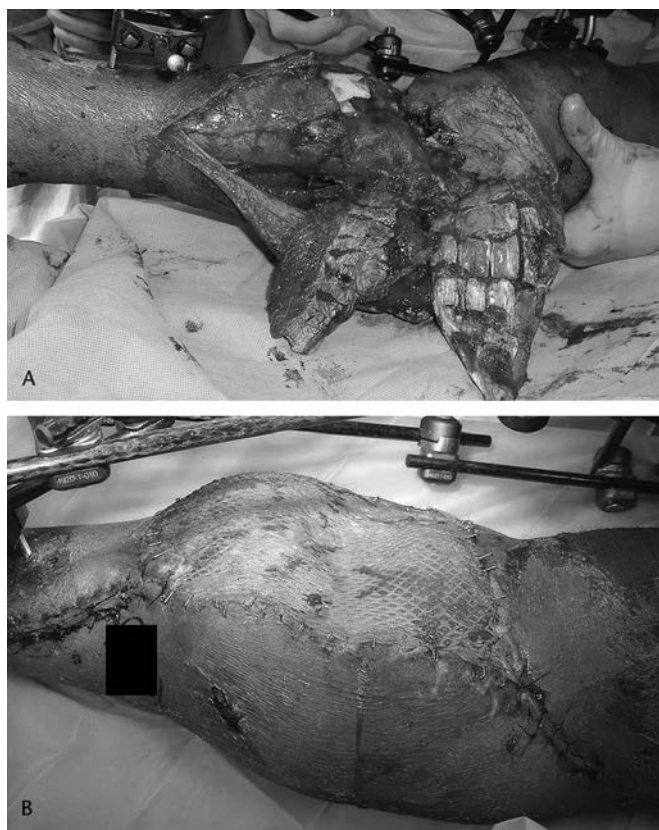


FIGURE 1. (A) Rotational coverage of proximal third open Type III (B) tibia fracture.

Within the rotational flap cohort, there was a significant increase in rotational flap failure rate in the distal third of the leg (20%) compared with those performed in the middle and proximal portion of the tibia (2%; $P = 0.02$).

There were significant differences in the overall complication rates between the free flap and rotational coverage groups (Table 3). There was a free flap failure rate of 27% (three of 11). Two of the three patients with failed free flaps required a below-knee amputation at 3 and 4 weeks after injury. The third was treated successfully with a second free tissue transfer. Rotational flaps demonstrated a failure rate of 7% (four of 56; $P = 0.08$). Two patients required an amputation and two were successfully treated with serial negative pressure dressing changes. Although the flaps remained viable, three additional free flaps required a return to the operating room for débridement of partial flap necrosis (Fig. 2). One additional patient required a return to the operating room for débridement of an infection, resulting in an overall free tissue coverage reoperation rate of 64%. Eight rotational flaps required a return to the operating room for débridement of partial flap necrosis and five additional patients developed flap infections for a total rotational coverage reoperation rate of 30% ($P = 0.046$).

Nine patients ultimately required an amputation at an average of 11.8 months (range, 3 weeks to 20 months) after injury. Two patients in the free flap cohort received an amputation for failure of soft tissue coverage with a deep infection, one for an infected tibial nonunion over 1 year after injury and the last for chronic pain despite wound healing and osseous union 1 year after injury. In the rotational coverage cohort, five patients ultimately required an amputation. Two patients received amputations for infected tibial nonunions at 10 months and 20 months, respectively. One received an amputation for a refracture nonunion with persistent pain, one for rotational coverage failure with severe hindfoot injuries and one for chronic pain and dysesthesias 18 months after injury.

Four of the 13 (31%) free flaps and 10 of the 55 (18%) rotational flaps had wound infections within 14 days of flap coverage ($P = 0.22$). One wound infection in the free flap group led to flap failure, whereas the other three infections were successfully treated with débridement and intravenous antibiotics. Three wound infections in the rotational flap group led to coverage failure, whereas the remaining seven were successfully treated with débridement and intravenous antibiotics.

TABLE 3. Comparison of Coverage Outcomes

	Rotational (n = 56)	Free (n = 11)	P
Flap failure, % (n)	7 (4)	27 (3)	0.081
Reoperation rate, % (n)	30 (17)	64 (7)	0.046
Deep infection, % (n)	32 (18)	46 (5)	0.49
Flap infection, % (n)	18 (10)	36 (4)	0.22
Time to union, mo	10.5	9.5	0.99
Amputation rate, % (n)	9 (5)	36 (4)	0.034
VAS at discharge, mean ± SD	2.9 ± 2	2.7 ± 2	0.30
VAS at follow-up, mean ± SD	1.8 ± 2	4.0 ± 4	0.32

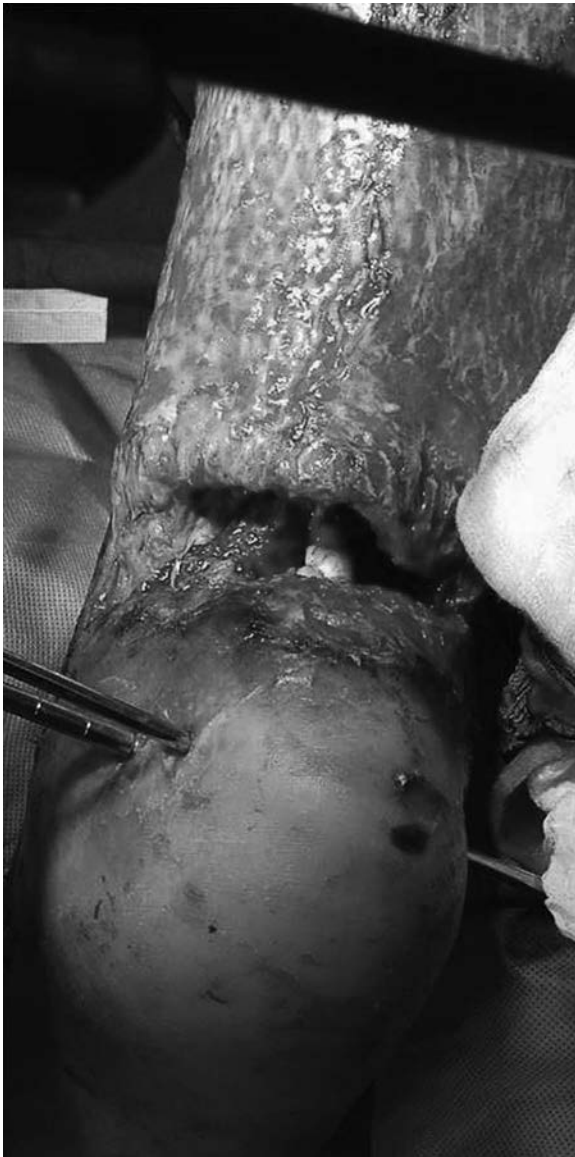

FIGURE 2. Free flap partial flap necrosis.

Definitive soft tissue coverage with a free or rotational flap was performed after an average of 20 days after initial injury with no difference between cohorts. There was no difference in complications or failure rate with respect to timing of the coverage procedure (Table 4). In subgroup analyses, however, the rotational flaps performed after 14 days had a significantly lower reoperation rate (24%) than free flaps performed after 14 days (57%; $P = 0.03$). Finally, there was a significant increase in failure rate and reoperation rate in Orthopaedic Trauma Association Type C fractures treated with a free flap. Type C fractures treated with a free flap had a 38% failure rate and a 75% reoperation rate compared with a failure rate of 6% ($P = 0.04$) and a reoperation rate of 31% for extremities treated with a rotational flap ($P = 0.04$).

In comparison to fractures with a segmental defect, defined as complete loss of osseous contact resulting from bone loss, there was a statistical difference in coverage

outcomes between the free and rotational coverage groups. The injuries with segmental osseous defects treated with free tissue transfer had a higher flap failure rate (50%) and a higher reoperation rate (67%) compared with injuries treated with rotational coverage (8% and 33%, respectively; $P = 0.028$ and $P = 0.048$).

An additional bony procedure was defined as any return to the operating room that included an osseous operative intervention aimed at achieving union (ie, primary or revision instrumentation, bone grafting, or application of bone morphogenic protein) or an amputation. The average number of bony procedures was 1.8 (range, 1–11) and 2.2 (range, 1–10) in the rotational and free flap cohorts, respectively. There was no difference in the average time to fracture union for patients treated with a rotational flap (mean, 10.5 months; range, 3.4–41 months) compared with the free flap group (9.5 months; range, 5–15.8 months; $P = 0.99$) (Fig. 3). Including late amputations, the overall amputation rate in the free flap group in our series was 36% (four of 11) and 9% (five of 56) in the rotational flap group ($P = 0.03$).

DISCUSSION

An open lower extremity fracture usually results from high-energy trauma that can threaten limb viability. Early amputation versus limb salvage for mangled lower extremities remains a controversial and unresolved dilemma despite substantial research attention.^{15,16} The most commonly reported injury mechanism for lower extremity trauma in civilian series is motor vehicle-related, whereas the predominant mechanism in combat-related military injuries is secondary to explosive blasts.¹⁷ These mechanisms are decidedly different, and the resulting fracture type distribution in the current series is slightly more severe than those reported in the civilian literature.¹⁰ However, we found a similar percentage of Type III tibia fractures that required formal soft tissue coverage as that reported by the LEAP study group.⁷ In contrast to their results, rotational soft tissue coverage in our series had a lower complication rate while treating similar injuries.

Determinations regarding the type of soft tissue coverage depend on numerous factors to include wound size, anatomic location, patient characteristics, local available tissue, and the experience of the treating physicians and/or the availability of specialty services. Fasciocutaneous rotation flaps, transposed muscle flaps, and microvascular free tissue transfers have all been described to cover soft tissue defects of the lower extremity.^{3,18–24} Gastrocnemius, soleus, and fasciocutaneous rotational flaps were used most commonly for coverage of open tibia fractures in our series. Microvascular free muscle flaps, in this series and others, are most often required for coverage of large tissue defects and for wounds in the distal leg.^{20,25,26} Rectus abdominis and latissimus dorsi were the most commonly used free tissue donor sites in our series.

The goal of treatment for severe open fractures is a healed soft tissue envelope and fracture union while retaining or restoring as much limb function as possible. Although 91% of our open Type IIIB tibia fractures eventually united, 13% ultimately underwent an amputation. The overall rate of amputation is similar to that published previously, but there

TABLE 4. Comparison of Coverage and Complications

	Rotational (n = 56)		Free Flap (n = 11)		P	
	Failure	Reoperation	Failure	Reoperation	Failure	Reoperation
Time to coverage, % (n)						
7-14 d	13.6 (3 of 22)	41 (9 of 22)	50 (2 of 4)	75 (3 of 4)	0.15	0.31
15-21 d	0 (0 of 18)	11 (2 of 18)	0 (0 of 3)	33 (1 of 3)	NA	0.39
22-28 d	0 (0 of 7)	71 (5 of 7)	0 (0 of 2)	50 (1 of 2)	NA	1.00
>28 d	11 (1 of 9)	11 (1 of 9)	50 (1 of 2)	100 (2 of 2)	0.35	0.05
Defect location, % (n)						
Proximal	0 (0 of 17)	18 (3 of 17)	66 (2 of 3)	100 (3 of 3)	0.02	0.02
Middle	4 (1 of 24)	38 (9 of 24)	0 (0 of 3)	33 (1 of 3)	1.00	1.00
Distal	20 (3 of 15)	33 (5 of 15)	20 (1 of 5)	60 (3 of 5)	1.00	0.35
OTA fracture classification, % (n)						
Type A	0 (0 of 6)	17 (1 of 6)	0 (0 of 1)	100 (1 of 1)	NA	0.29
Type B	13 (2 of 15)	33 (5 of 15)	0 (0 of 2)	0 (0 of 2)	1.00	1.00
Type C	6 (2 of 35)	31 (11 of 35)	38 (3 of 8)	75 (6 of 8)	0.04	0.04
Segmental osseous defect, % (n)						
Defect present	6 (1 of 16)	25 (4 of 16)	50 (3 of 6)	67 (4 of 6)	0.03	0.05
Defect absent	8 (3 of 40)	33 (13 of 40)	0 (0 of 7)	57 (4 of 7)	1.00	0.05

was a statistically significant difference between the groups in this study.²⁷ Specifically, 46% of the patients who received a free flap ultimately required an amputation, whereas only 9% of the rotational coverage cohort underwent amputation ($P = 0.03$). Although this may ostensibly be attributed to an undetected bias of more severe injuries preferentially treated with free flap coverage, subgroup analysis revealed that the most complex fracture patterns, Orthopaedic Trauma Association Type C, had fewer complications when treated with rotational coverage ($P = 0.04$; Table 4). Previously reported average times to union for open tibia fractures range from 23 to 28 weeks with up to 60% requiring a bone grafting to achieve union.^{6,22,28,29} The average time to fracture union in this series was not different between the groups at 10.5 and 9.5 months for the rotational flap and free tissue cohorts, respectively ($P = 0.99$).

Infection rates for open tibia fractures range from 9% to 83% and vary with injury severity, contamination, and timing of coverage.^{12,22,26,27} Early coverage of soft tissue defects for severe open fractures of the lower extremity has proven to be critical in multiple series, whereas the definition of early coverage ranges from 24 hours to 11 days.²⁹⁻³² Most authors, however, recommend coverage within 5 to 7 days for optimal outcomes.^{29,30,33-36} Delays in coverage beyond 14 days may allow for increased colonization with bacterial flora resulting in frequent infection and flap failure.³¹ Godina's review of 532 patients with microsurgical reconstruction of extremity soft tissue defects showed a significantly lower flap failure rate, postoperative infection rate, time to bony healing, length of hospital stay, and number of operations for patients treated within 72 hours of injury with free soft tissue coverage.³⁶ Gopal et al²⁹ supported even earlier coverage times showing a reduced infection rate and a shorter time to bone healing with coverage within 24 hours of injury. However, both of these studies were nonrandomized and retrospective, and therefore these findings may have been influenced by selection bias with

regard to patients, fractures, and wounds that were amenable to early coverage.

The average time to coverage in the present study is 19.8 days for the rotational coverage group and 19.5 days for the free flap group. All of the wounded soldiers in our series were provisionally treated at up to three other facilities along the evacuation chain before definitive management at our Level V facilities. The evacuation time during Operation Enduring Freedom for orthopaedic injuries averages 7.9 days and there is an average of 2.6 procedures performed before presentation.³⁷ The time for transportation from theater to the definitive treatment facility inevitably places soft tissue coverage timing into the delayed category as defined in most series. Although previous authors reported favorable short-term outcomes for soft tissue coverage procedures in the military population, our findings reflect higher failure and increased complication rates compared with those in the civilian literature managed with early coverage.^{29,38} Our results, however, are comparable to the outcomes of delayed treatment in the civilian literature.^{29,32,36}

Increased energy delivered to the surrounding soft tissue, the so-called zone of injury, has been associated with increased soft tissue and osseous complications during management of the injuries, including delayed union, non-union, and deep infection.³⁹ The large zone of injury surrounding the open fracture site led to the rationale that free flap coverage with tissue transferred from outside the zone of injury may reduce complication rates and decrease healing time.⁶ Pollak and coauthors⁷ reported rotational flap coverage of severe open tibia fractures were 4.3 times more likely to develop short-term wound complications than free soft tissue transfer.⁷ They proposed that the boundaries of the zone of injury may be unclear early in the course of treatment, and tissue selected for rotational coverage may be partially devitalized. Our data conflict these results, possibly in part as a result of the increased time to coverage in our series. Although this delay necessitated by the casualty evacuation

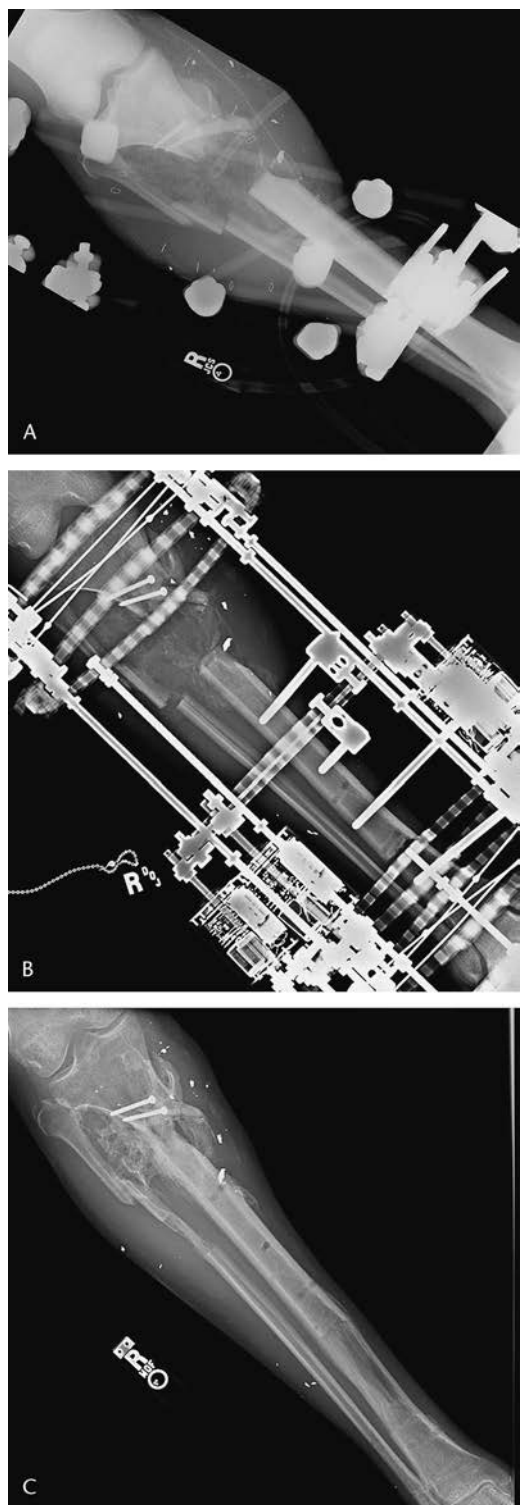


FIGURE 3. (A) Anteroposterior radiograph of proximal third tibia fracture after initial stabilization. (B) Anteroposterior radiograph of proximal third tibia fracture after circular fixator. (C) Anteroposterior radiograph of proximal third tibia fracture after osseous union.

process may increase the risk of complications, it may also permit better delineation of the viability of adjacent soft tissues, thus providing for safer local rotational coverage.

Although free tissue transfer is technically demanding, it is highly successful with early success rates as high as 96% to 100% reported.^{8,29,40} Low infection rates have also been reported in several studies^{8,22} and the most common complication leading to failure of free tissue transfer is thrombosis of the arterial or venous anastomoses.^{22,38,40} Although free tissue transfer remote from the site of injury provides untraumatized tissue for coverage and revascularization, there are inherent disadvantages not associated with rotational tissue transfers. Donor site morbidity and possible need for skin coverage of the harvest site are additional patient costs associated with free flaps. Shoulder or abdominal weakness, loss of endurance, numbness, and unacceptable scar appearance are known complications of free tissue transfer.^{3,41,42} Additionally, free tissue transfers are anastomosed to pristine recipient vessels outside of the zone of injury, which is often not possible in blast-injured patients with large zones of injury. Finally, free tissue transfer requires lengthy operating times, microvascular expertise, specialized microvascular equipment, and tissue transfer experience not available in all institutions. For these reasons, local rotational coverage of tissue defects in open tibia fractures is appealing to both patients and treating physicians when practicable. Another soft tissue coverage option if local rotational tissue is unavailable or insufficient is acute fracture shortening or angulation followed by gradual, delayed correction.^{43,44} This technique has been used more recently as an alternative to free flap coverage.⁴⁵

The current study is retrospective in nature and retains the associated weaknesses, potential biases, and limitations of all retrospective studies. Fracture and wound management, although consistently similar, were not standardized among patients, surgeons, or institutions and soft tissue coverage type was influenced by surgeon preference in addition to local wound characteristics. Furthermore, the surgeon decision to return to the operating room for débridement for partial necrosis in the postoperative period is subjective in nature and likely differed between treating surgeons. There may be an undetected difference between the patients or injuries that were treated with a rotational flap versus a free flap. In addition, the sample size prevented further analysis of complications within subgroups and may have limited our ability to identify subtle but potentially significant differences between the groups, particularly where clear trends were found.

In patients with combat-related Type III open tibia fractures that required soft tissue coverage, 84% had the soft tissue defect covered with a rotational flap, whereas 16% received free tissue transfer. There was no statistical difference in infectious complications or healing time between free tissue transfer and local rotational coverage. There were significantly lower reoperation and amputation rates for patients who received a rotational flap for soft tissue coverage. There was also a trend toward lower flap failure rate with the rotational flap coverage ($P = 0.08$). Possible explanations for the differences in our outcomes between rotational and free tissue transfer and the civilian literature include the differences in injury mechanism, relatively more severe fracture patterns, and

our increased time to soft tissue coverage. The longer time to wound coverage may allow more accurate delineation of the viability of local tissue and prevent rotational coverage with marginally viable tissue. In our series, the wide zone of injury in combat-related open tibia fractures did not preclude the use of available local soft tissue for rotational coverage.

REFERENCES

- Heller L, Levin S. Bone and soft tissue reconstruction. In: Buchholz RW, ed. *Rockwood and Green's Fractures in Adults*. Philadelphia: Lippincott Williams & Wilkins; 2002:415-462.
- Bagg MR, Levin LS. Moderators' summary: wound management (session II). *J Am Acad Orthop Surg*. 2006;14:S73-S74.
- Adams WP Jr, Lipschitz AH, Ansari M, et al. Functional donor site morbidity following latissimus dorsi muscle flap transfer. *Ann Plast Surg*. 2004;53:6-11.
- Daigeler A, Dodic T, Awiszus F, et al. Donor-site morbidity of the pedicled rectus femoris muscle flap. *Plast Reconstr Surg*. 2005;115:786-792.
- Kramers-de Quervain IA, Lauffer JM, Kach K, et al. Functional donor-site morbidity during level and uphill gait after a gastrocnemius or soleus muscle-flap procedure. *J Bone Joint Surg Am*. 2001;83:239-246.
- Burgess AR, Poka A, Brumback RJ, et al. Management of open grade III tibial fractures. *Orthop Clin North Am*. 1987;18:85-93.
- Pollak AN, McCarthy ML, Burgess AR. Short-term wound complications after application of flaps for coverage of traumatic soft-tissue defects about the tibia. The Lower Extremity Assessment Project (LEAP) Study Group. *J Bone Joint Surg Am*. 2000;82:1681-1691.
- Kumar AR. Standard wound coverage techniques for extremity war injury. *J Am Acad Orthop Surg*. 2006;14:S62-S65.
- Crabtree TG. Scope of wounds. *J Am Acad Orthop Surg*. 2006;14:S75-S76.
- Court-Brown CM, McBurnie J. The epidemiology of tibial fractures. *J Bone Joint Surg Br*. 1995;77:417-421.
- Gustilo RB, Anderson JT. Prevention of infection in the treatment of one thousand and twenty-five open fractures of long bones: retrospective and prospective analyses. *J Bone Joint Surg Am*. 1976;58:453-458.
- Gustilo RB, Gruninger RP, Davis T. Classification of type III (severe) open fractures relative to treatment and results. *Orthopedics*. 1987;10:1781-1788.
- Gustilo RB, Mendoza RM, Williams DN. Problems in the management of type III (severe) open fractures: a new classification of type III open fractures. *J Trauma*. 1984;24:742-746.
- Muller M. *The Comprehensive Classification of Fractures of Long Bones*. New York: Springer; 1990.
- Bosse MJ, MacKenzie EJ, Kellam JF, et al. An analysis of outcomes of reconstruction or amputation after leg-threatening injuries. *N Engl J Med*. 2002;347:1924-1931.
- Busse JW, Jacobs CL, Swiontkowski MF, et al. Complex limb salvage or early amputation for severe lower-limb injury: a meta-analysis of observational studies. *J Orthop Trauma*. 2007;21:70-76.
- Owens BD, Kragh JF Jr, Wenke JC, et al. Combat wounds in Operation Iraqi Freedom and Operation Enduring Freedom. *J Trauma*. 2008;64:295-299.
- Culliford AT, Spector J, Blank A, et al. The fate of lower extremities with failed free flaps: a single institution's experience over 25 years. *Ann Plast Surg*. 2007;59:18-21.
- Fix RJ, Vasconez LO. Fasciocutaneous flaps in reconstruction of the lower extremity. *Clin Plast Surg*. 1991;18:571-582.
- Hammert WC, Minarchek J, Trzeciak MA. Free-flap reconstruction of traumatic lower extremity wounds. *Am J Orthop*. 2000;29:22-26.
- Mathes SJ, McCraw JB, Vasconez LO. Muscle transposition flaps for coverage of lower extremity defects: anatomic considerations. *Surg Clin North Am*. 1974;54:1337-1354.
- Shepherd LE, Costigan WM, Gardocki RJ, et al. Local or free muscle flaps and unreamed interlocked nails for open tibial fractures. *Clin Orthop Relat Res*. 1998;350:90-96.
- Spector JA, Levine S, Levine JP. Free tissue transfer to the lower extremity distal to the zone of injury: indications and outcomes over a 25-year experience. *Plast Reconstr Surg*. 2007;120:952-959.
- Wiss DA, Sherman R, Oechsel M. External skeletal fixation and rectus abdominis free-tissue transfer in the management of severe open fractures of the tibia. *Orthop Clin North Am*. 1993;24:549-556.
- Khouri RK, Shaw WW. Reconstruction of the lower extremity with microvascular free flaps: a 10-year experience with 304 consecutive cases. *J Trauma*. 1989;29:1086-1094.
- te Velde EA, Hulscher JB, Werker PM, et al. Free muscle transplantation after complex fractures of the lower leg and ankle: results from 32 patients. *Ned Tijdschr Geneesk*. 1999;143:2102-2107.
- Caudle RJ, Stern PJ. Severe open fractures of the tibia. *J Bone Joint Surg Am*. 1987;69:801-807.
- Tornetta P 3rd, Bergman M, Watnik N, et al. Treatment of grade-IIIb open tibial fractures. A prospective randomised comparison of external fixation and non-reamed locked nailing. *J Bone Joint Surg Br*. 1994;76:13-19.
- Gopal S, Majumder S, Batchelor AG, et al. Fix and flap: the radical orthopaedic and plastic treatment of severe open fractures of the tibia. *J Bone Joint Surg Br*. 2000;82:959-966.
- Cierny G 3rd, Byrd HS, Jones RE. Primary versus delayed soft tissue coverage for severe open tibial fractures. A comparison of results. *Clin Orthop Relat Res*. 1983;178:54-63.
- Gustilo RB, Merkow RL, Templeman D. The management of open fractures. *J Bone Joint Surg Am*. 1990;72:299-304.
- Templeman DC, Gulli B, Tsukayama DT, et al. Update on the management of open fractures of the tibial shaft. *Clin Orthop Relat Res*. 1998;350:18-25.
- Sanders R, Swiontkowski M, Nunley J, et al. The management of fractures with soft-tissue disruptions. *J Bone Joint Surg Am*. 1993;75:778-789.
- Cole JD, Ansel LJ, Schwartzberg R. A sequential protocol for management of severe open tibial fractures. *Clin Orthop Relat Res*. 1995;315:84-103.
- Dornseifer U, Ninkovic M. Timing of management of severe injuries of the lower extremity by free flap transfer. *Bosn J Basic Med Sci*. 2005;5:7-13.
- Godina M. Early microsurgical reconstruction of complex trauma of the extremities. *Plast Reconstr Surg*. 1986;78:285-292.
- Lin DL, Kirk KL, Murphy KP, et al. Orthopedic injuries during Operation Enduring Freedom. *Mil Med*. 2004;169:807-809.
- Kumar AR, Grewal NS, Chung TL, et al. Lessons from operation Iraqi freedom: successful subacute reconstruction of complex lower extremity battle injuries. *Plast Reconstr Surg*. 2009;123:218-229.
- Phieffer LS, Goulet JA. Delayed unions of the tibia. *J Bone Joint Surg Am*. 2006;88:206-216.
- Nieminen H, Kuokkanen H, Tukiainen E, et al. Free flap reconstructions of 100 tibial fractures. *J Trauma*. 1999;46:1031-1035.
- Kimata Y, Uchiyama K, Ebihara S, et al. Anterolateral thigh flap donor-site complications and morbidity. *Plast Reconstr Surg*. 2000;106:584-589.
- Fraulín FO, Louie G, Zorrilla L, et al. Functional evaluation of the shoulder following latissimus dorsi muscle transfer. *Ann Plast Surg*. 1995;35:349-355.
- Lerner A, Fodor L, Soudry M, et al. Acute shortening: modular treatment modality for severe combined bone and soft tissue loss of the extremities. *J Trauma*. 2004;57:603-608.
- Nho SJ, Helfet DL, Rozbruch SR. Temporary intentional leg shortening and deformation to facilitate wound closure using the Ilizarov/Taylor spatial frame. *J Orthop Trauma*. 2006;20:419-424.
- Hsu JR, Beltran MJ; Skeletal Trauma Research Consortium. Shortening and angulation for soft-tissue reconstruction of extremity wounds in a combat support hospital. *Mil Med*. 2009;174:838-842.