

REPORT DOCUMENTATION PAGE			Form Approved OMB NO. 0704-0188		
<p>The public reporting burden for this collection of information is estimated to average 1 hour per response, including the time for reviewing instructions, searching existing data sources, gathering and maintaining the data needed, and completing and reviewing the collection of information. Send comments regarding this burden estimate or any other aspect of this collection of information, including suggestions for reducing this burden, to Washington Headquarters Services, Directorate for Information Operations and Reports, 1215 Jefferson Davis Highway, Suite 1204, Arlington VA, 22202-4302. Respondents should be aware that notwithstanding any other provision of law, no person shall be subject to any penalty for failing to comply with a collection of information if it does not display a currently valid OMB control number. PLEASE DO NOT RETURN YOUR FORM TO THE ABOVE ADDRESS.</p>					
1. REPORT DATE (DD-MM-YYYY) 06-08-2015		2. REPORT TYPE Final Report		3. DATES COVERED (From - To) 1-Jul-2010 - 31-Mar-2014	
4. TITLE AND SUBTITLE Final Report: Self-Expanding, Tough Biodegradable Elastomers for Wound Stasis			5a. CONTRACT NUMBER		
			5b. GRANT NUMBER W911NF-10-C-0089		
			5c. PROGRAM ELEMENT NUMBER 0620BE		
6. AUTHORS Upma Sharma			5d. PROJECT NUMBER		
			5e. TASK NUMBER		
			5f. WORK UNIT NUMBER		
7. PERFORMING ORGANIZATION NAMES AND ADDRESSES Arsenal Medical, Inc. 480 Arsenal St.  Watertown, MA 02472 -2891			8. PERFORMING ORGANIZATION REPORT NUMBER		
9. SPONSORING/MONITORING AGENCY NAME(S) AND ADDRESS (ES) U.S. Army Research Office P.O. Box 12211 Research Triangle Park, NC 27709-2211			10. SPONSOR/MONITOR'S ACRONYM(S) ARO		
			11. SPONSOR/MONITOR'S REPORT NUMBER(S) 58207-LS-DRP.5		
12. DISTRIBUTION AVAILABILITY STATEMENT Approved for Public Release; Distribution Unlimited					
13. SUPPLEMENTARY NOTES The views, opinions and/or findings contained in this report are those of the author(s) and should not be construed as an official Department of the Army position, policy or decision, unless so designated by other documentation.					
14. ABSTRACT BACKGROUND:  Noncompressible abdominal bleeding is a significant cause of preventable death on the battlefield and in the civilian setting, with no effective therapies available at point of injury. We previously reported that a self-expanding polyurethane foam significantly improved survival in a lethal hepatoportal injury model of massive venous hemorrhage. In this study, we hypothesized that foam treatment could improve survival in a lethal iliac					
15. SUBJECT TERMS non-compressible hemorrhage, abdominal, lethal					
16. SECURITY CLASSIFICATION OF:		17. LIMITATION OF ABSTRACT	15. NUMBER OF PAGES	19a. NAME OF RESPONSIBLE PERSON	
a. REPORT	b. ABSTRACT			c. THIS PAGE	Maria Palasis
UU	UU	UU	UU	19b. TELEPHONE NUMBER 000-000-0000	



## Report Title

Final Report: Self-Expanding, Tough Biodegradable Elastomers for Wound Stasis

### ABSTRACT

#### BACKGROUND:

Noncompressible abdominal bleeding is a significant cause of preventable death on the battlefield and in the civilian setting, with no effective therapies available at point of injury. We previously reported that a self-expanding polyurethane foam significantly improved survival in a lethal hepatoportal injury model of massive venous hemorrhage. In this study, we hypothesized that foam treatment could improve survival in a lethal iliac artery injury model in noncoagulopathic swine.

#### METHODS:

In swine with a closed abdomen, an iliac artery transection was created, resulting in massive noncompressible exsanguination. After injury, animals were treated with damage-control fluid resuscitation alone ( $n = 14$ ) or foam treatment in addition to fluids. Two doses of foam treatment were studied: 100 mL ( $n = 12$ ) and 120 mL ( $n = 13$ ); all animals were monitored for 3 hours or until death.

#### RESULTS:

Foam treatment at both doses resulted in a significant survival benefit and reduction in hemorrhage rate relative to the control group. Median survival time was 135 minutes and 175 minutes for the 120-mL and 100-mL doses, compared with 32 minutes in the control group ( $p < 0.001$  for both groups). Foam resulted in an immediate, persistent improvement in mean arterial pressure and a transient increase in intra-abdominal pressure. The median hemorrhage rate was 0.27 g/kg per minute in the 120-mL group and 0.23 g/kg per minute in the 100-mL group, compared with 1.4 g/kg per minute in the control group ( $p = 0.003$  and  $0.006$ , respectively, as compared with the control).

#### CONCLUSION:

Self-expanding foam treatment significantly improves survival in an otherwise lethal, noncompressible, massive, arterial injury. This treatment may provide a prehospital intervention for control of noncompressible abdominal hemorrhage.

---

**Enter List of papers submitted or published that acknowledge ARO support from the start of the project to the date of this printing. List the papers, including journal references, in the following categories:**

**(a) Papers published in peer-reviewed journals (N/A for none)**

<u>Received</u>	<u>Paper</u>
08/06/2015	4.00 Miroslav P. Peev, Adam Rago, John O. Hwabejire, Michael J. Duggan, John Beagle, John Marini, Greg Zugates, Rany Busold, Toby Freyman, George S. Velmahos, Marc A. Demoya, Daniel Dante Yeh, Peter J. Fagenholz, Upma Sharma, David Richard King. Self-expanding foam for prehospital treatment of severe intra-abdominal hemorrhage, Journal of Trauma and Acute Care Surgery, (03 2014): 0. doi: 10.1097/TA.0000000000000126
08/06/2015	3.00 Adam Rago, John Marini, John Beagle, Miroslav Peev, George Velmahos, Upma Sharma, David R. King, Michael J. Duggan. Development of a lethal, closed-abdomen, arterial hemorrhage model in noncoagulopathic swine, Journal of Surgical Research, (04 2014): 0. doi: 10.1016/j.jss.2013.12.005
08/06/2015	1.00 Ali Y. Mejaddam, Michael J. Duggan, John Beagle, Marc A. deMoya, George C. Velmahosa, Hasan B. Alam, Adam Rago, Greg Zugates, Rany Busold, Toby Freyman, Upma Sharma, David R. King. Development of a lethal, closed-abdomen grade V hepato-portal injury model in non-coagulopathic swine, Journal of Surgical Research, (06 2013): 0. doi: 10.1016/j.jss.2012.07.048
08/06/2015	2.00 Michael Duggan, Adam Rago, Upma Sharma, Greg Zugates, Toby Freyman, Rany Busold, John Caulkins, Quynh Pham, Yuchao Chang, Ali Mejaddam, John Beagle, George Velmahos, Marc deMoya, Lawrence Zukerberg, Tat Fong Ng, LTC David R. King. Self-expanding polyurethane polymer improves survival in a model of noncompressible massive abdominal hemorrhage, Journal of Trauma and Acute Care Surgery, (06 2013): 0. doi: 10.1097/TA.0b013e31828da937
<b>TOTAL:</b>	<b>4</b>

**Number of Papers published in peer-reviewed journals:**

---

**(b) Papers published in non-peer-reviewed journals (N/A for none)**

<u>Received</u>	<u>Paper</u>
-----------------	--------------

**TOTAL:**

**Number of Papers published in non peer-reviewed journals:**

---

**(c) Presentations**

Number of Presentations: 0.00

---

**Non Peer-Reviewed Conference Proceeding publications (other than abstracts):**

Received      Paper

**TOTAL:**

Number of Non Peer-Reviewed Conference Proceeding publications (other than abstracts):

---

**Peer-Reviewed Conference Proceeding publications (other than abstracts):**

Received      Paper

**TOTAL:**

Number of Peer-Reviewed Conference Proceeding publications (other than abstracts):

---

**(d) Manuscripts**

Received      Paper

**TOTAL:**

Number of Manuscripts:

---

**Books**

Received      Book

**TOTAL:**

Received      Book Chapter

**TOTAL:**

**Patents Submitted**

---

**Patents Awarded**

---

**Awards**

---

**Graduate Students**

NAME

PERCENT SUPPORTED

**FTE Equivalent:**

**Total Number:**

**Names of Post Doctorates**

NAME

PERCENT SUPPORTED

**FTE Equivalent:**

**Total Number:**

**Names of Faculty Supported**

<u>NAME</u>	<u>PERCENT SUPPORTED</u>	National Academy Member
David King	0.50	
<b>FTE Equivalent:</b>	<b>0.50</b>	
<b>Total Number:</b>	<b>1</b>	

**Names of Under Graduate students supported**

<u>NAME</u>	<u>PERCENT SUPPORTED</u>
<b>FTE Equivalent:</b>	
<b>Total Number:</b>	

**Student Metrics**

This section only applies to graduating undergraduates supported by this agreement in this reporting period

The number of undergraduates funded by this agreement who graduated during this period: ..... 0.00

The number of undergraduates funded by this agreement who graduated during this period with a degree in science, mathematics, engineering, or technology fields:..... 0.00

The number of undergraduates funded by your agreement who graduated during this period and will continue to pursue a graduate or Ph.D. degree in science, mathematics, engineering, or technology fields:..... 0.00

Number of graduating undergraduates who achieved a 3.5 GPA to 4.0 (4.0 max scale):..... 0.00

Number of graduating undergraduates funded by a DoD funded Center of Excellence grant for Education, Research and Engineering:..... 0.00

The number of undergraduates funded by your agreement who graduated during this period and intend to work for the Department of Defense ..... 0.00

The number of undergraduates funded by your agreement who graduated during this period and will receive scholarships or fellowships for further studies in science, mathematics, engineering or technology fields:..... 0.00

**Names of Personnel receiving masters degrees**

<u>NAME</u>
<b>Total Number:</b>

**Names of personnel receiving PHDs**

<u>NAME</u>
<b>Total Number:</b>

**Names of other research staff**

<u>NAME</u>	<u>PERCENT SUPPORTED</u>
<b>FTE Equivalent:</b>	
<b>Total Number:</b>	

---

**Sub Contractors (DD882)**

1 a. Massachusetts General Hospital

1 b. 165 Cambridge St.

Boston MA 021142600

**Sub Contractor Numbers (c):**

**Patent Clause Number (d-1):**

**Patent Date (d-2):**

**Work Description (e):**

**Sub Contract Award Date (f-1):**

**Sub Contract Est Completion Date(f-2):**

---

1 a. Massachusetts General Hospital

1 b. 165 Cambridge St.

Cambridge MA 021142600

**Sub Contractor Numbers (c):**

**Patent Clause Number (d-1):**

**Patent Date (d-2):**

**Work Description (e):**

**Sub Contract Award Date (f-1):**

**Sub Contract Est Completion Date(f-2):**

---

1 a. Sanford-Burnham Medical Research Institute

1 b. Sanford-Burnham Medical Research  
6400 Sanger Road

Orlando FL 328277400

**Sub Contractor Numbers (c):**

**Patent Clause Number (d-1):**

**Patent Date (d-2):**

**Work Description (e):**

**Sub Contract Award Date (f-1):**

**Sub Contract Est Completion Date(f-2):**

---

1 a. Sanford-Burnham Medical Research Institute

1 b. Sanford-Burnham Medical Research  
6400 Sanger Road

Orlando FL 328277400

**Sub Contractor Numbers (c):**

**Patent Clause Number (d-1):**

**Patent Date (d-2):**

**Work Description (e):**

**Sub Contract Award Date (f-1):**

**Sub Contract Est Completion Date(f-2):**

---



1 a. Tanaka Kapec Design Group

1 b. 11 Brookfield Street

Norwalk CT 06851

**Sub Contractor Numbers (c):**

**Patent Clause Number (d-1):**

**Patent Date (d-2):**

**Work Description (e):**

**Sub Contract Award Date (f-1):**

**Sub Contract Est Completion Date(f-2):**

---

1 a. Troy Polymers

1 b. 330 East Maple Road, Suite L

Troy MI 48083

**Sub Contractor Numbers (c):**

**Patent Clause Number (d-1):**

**Patent Date (d-2):**

**Work Description (e):**

**Sub Contract Award Date (f-1):**

**Sub Contract Est Completion Date(f-2):**

---

## Inventions (DD882)

### 5 In situ forming hemostatic foam implants

Patent Filed in US? (5d-1) Y

Patent Filed in Foreign Countries? (5d-2) Y

Was the assignment forwarded to the contracting officer? (5e) N

Foreign Countries of application (5g-2): PCT

5a: Upma Sharma

5f-1a: Arsenal Medical

5f-c: 480 Arsenal Street

Watertown MA 02472

5a: Irina Gitlin

5f-1a: Arsenal Medical

5f-c: 480 Arsenal Street

Watertown MA 02472

5a: Greg Zugates

5f-1a: Arsenal Medical

5f-c: 480 Arsenal Street

Watertown MA 02472

5a: Adam Rago

5f-1a: Arsenal Medical

5f-c: 480 Arsenal Street

Watertown MA 02472

5a: Jeffrey Carbeck

5f-1a: Arsenal Medical

5f-c: 480 Arsenal Street

Watertown MA 02472

5a: Robert Caulkins

5f-1a: Arsenal Medical

5f-c: 480 Arsenal Street

Watertown MA 02472

5a: Toby Freyman

5f-1a: Arsenal Medical

5f-c: 480 Arsenal Street

Watertown MA 02472

5a: Quynh Pham

5f-1a: Arsenal Medical

5f-c: 480 Arsenal Street

Watertown MA 02472

5a: Changcheng You

5f-1a: Arsenal Medical

5f-c: 480 Arsenal Medical  
Watertown

MA 02472

5a: Parisa Zamiri

5f-1a: Arsenal Medical

5f-c: 480 Arsenal Street  
Watertown

MA 02472

## **Scientific Progress**

## **Technology Transfer**

Provided for non-commercial research and education use.  
Not for reproduction, distribution or commercial use.



This article appeared in a journal published by Elsevier. The attached copy is furnished to the author for internal non-commercial research and education use, including for instruction at the authors institution and sharing with colleagues.

Other uses, including reproduction and distribution, or selling or licensing copies, or posting to personal, institutional or third party websites are prohibited.

In most cases authors are permitted to post their version of the article (e.g. in Word or Tex form) to their personal website or institutional repository. Authors requiring further information regarding Elsevier's archiving and manuscript policies are encouraged to visit:

<http://www.elsevier.com/authorsrights>

Available online at [www.sciencedirect.com](http://www.sciencedirect.com)

ScienceDirect

journal homepage: [www.JournalofSurgicalResearch.com](http://www.JournalofSurgicalResearch.com)

## Development of a lethal, closed-abdomen, arterial hemorrhage model in noncoagulopathic swine

Michael J. Duggan, DVM,<sup>a</sup> Adam Rago, BS,<sup>b</sup> John Marini, BS,<sup>b</sup>  
John Beagle, BS,<sup>a</sup> Miroslav Peev, MD,<sup>a</sup> George Velmahos, MD, PhD,<sup>a</sup>  
Upma Sharma, PhD,<sup>b</sup> and David R. King, MD<sup>a,\*</sup>

<sup>a</sup> Division of Trauma, Emergency Surgery and Surgical Critical Care, Department of Surgery, Massachusetts General Hospital and Harvard Medical School, Boston, Massachusetts

<sup>b</sup> Arsenal Medical, Inc., Watertown, Massachusetts

### ARTICLE INFO

#### Article history:

Received 12 September 2013

Received in revised form

19 November 2013

Accepted 6 December 2013

Available online 12 December 2013

#### Keywords:

Trauma

Bleeding

Hemorrhage

Iliac

Battlefield

Artery

Resuscitation

Exsanguination

### ABSTRACT

**Background:** Prehospital treatment for noncompressible abdominal bleeding, particularly due to large vascular injury, represents a significant unmet medical need on the battlefield and in civilian trauma. To date, few large animal models are available to assess new therapeutic interventions and hemostatic agents for prehospital hemorrhage control.

**Methods:** We developed a novel, lethal, closed-abdomen injury model in noncoagulopathic swine by strategic placement of a cutting wire around the external iliac artery. The wire was externalized, such that percutaneous distraction would result in vessel transection leading to severe uncontrolled abdominal hemorrhage. Resuscitation boluses were administered at 5 and 12 min.

**Results:** We demonstrated 86% mortality (12/14 animals) at 60 min, with a median survival time of 32 min. The injury resulted in rapid and massive hypotension and exsanguinating blood loss. The noncoagulopathic animal model incorporated clinically significant resuscitation and ventilation protocols based on best evidenced-based prehospital practices.

**Conclusion:** A new injury model is presented that enables screening of prehospital interventions designed to control noncompressible arterial hemorrhage.

© 2014 Elsevier Inc. All rights reserved.

## 1. Introduction

Uncontrolled traumatic hemorrhage continues to be a dominant cause of death, accounting for almost 50% of potentially survivable battlefield casualties [1,2]. There are currently no available prehospital treatments for noncompressible intra-abdominal hemorrhage other than rapid transport to surgical care. Based on the critical nature of this problem, reproducible, lethal, large animal models are required to investigate new therapeutic protocols, pharmaceutical, and device interventions for hemorrhage control.

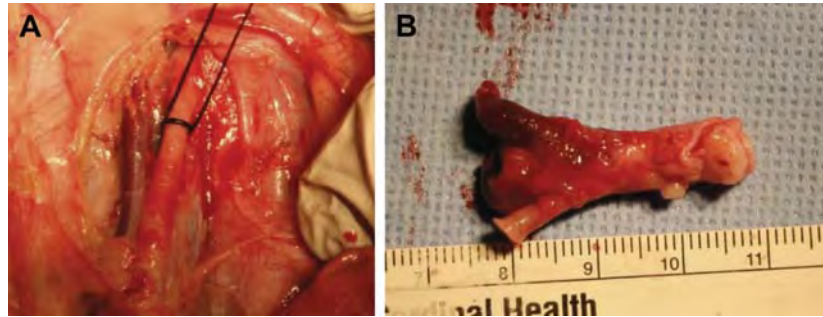
On the battlefield, the majority of arterial injuries occur due to explosions and gunshot wounds [3], whereas in civilian trauma, injury mechanism is split between blunt and penetrating trauma [4]. In an epidemiologic study of vascular injury in the Wars in Iraq and Afghanistan, White *et al.* [3] reported that the majority of vascular injuries within the torso involved the iliac artery (31%). In a survey of the National Trauma Data Bank, Markov *et al.* [4] observed that approximately 10% of noncompressible abdominal injuries were associated with the iliac artery. In military, patients who died of noncompressible torso hemorrhage, major arterial injuries were the

\* Corresponding author. Division of Trauma, Emergency Surgery, and Surgical Critical Care, Massachusetts General Hospital and Harvard Medical School, 165 Cambridge Street, Suite 810, Boston, MA 02141. Tel.: 617-643-2433.

E-mail address: [dking3@partners.org](mailto:dking3@partners.org) (D.R. King).

0022-4804/\$ – see front matter © 2014 Elsevier Inc. All rights reserved.

<http://dx.doi.org/10.1016/j.jss.2013.12.005>



**Fig. 1 – External iliac artery injury.** The external iliac artery was dissected from retroperitoneal tissue and instrumented with a cutting wire (A). After the study, the relevant vasculature was explanted for analysis (B). (Color version of figure is available online.)

second-leading cause of mortality (26%; odds ratio with mortality 3.38) [5]. In a matched study of military and civilian noncompressible abdominal arterial injury, Markov *et al.* [4] demonstrated that the military population had a significantly lower mortality rate than civilian counterparts (11% versus 36%). In both civilian and military populations, noncompressible trauma represents a significant unmet need; novel therapeutic strategies must first be tested in preclinical animal models.

Several previous studies have used arterial injury models to investigate hemostatic agents for hemorrhage control. These studies have focused on variations of only two models: punch biopsy injuries in the open abdomen [6–8] and longitudinal dissection injuries in the closed abdomen [9–13]. These models vary in mortality and relevance to the pre-hospital setting.

We previously described a closed-abdomen, lethal, grade V hepatoportal injury model in noncoagulopathic swine [14]. Wires were placed strategically around hepatic vasculature and externalized percutaneously. Distraction of these wires resulted in severe uncontrolled hemorrhage and rapid mortality in a low-pressure, high-flow scenario. In this work, we hypothesized that a similar technique targeting arterial vasculature and simulating high-pressure, high-flow non-compressible injuries would result in severe uncontrolled hemorrhage and rapid mortality.

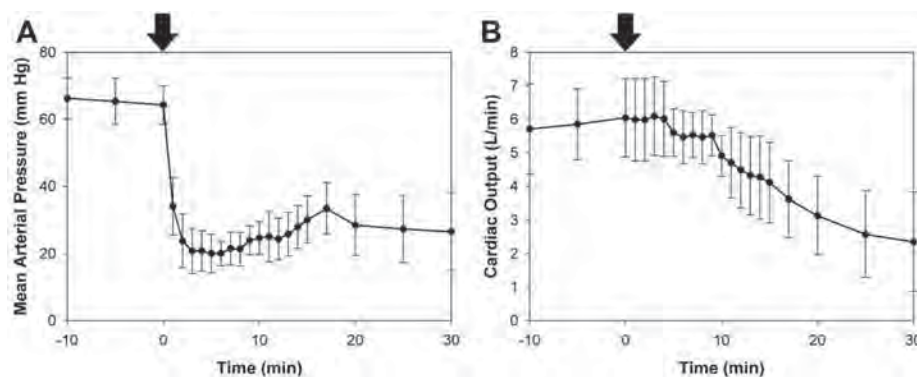
## 2. Materials and methods

### 2.1. Animals

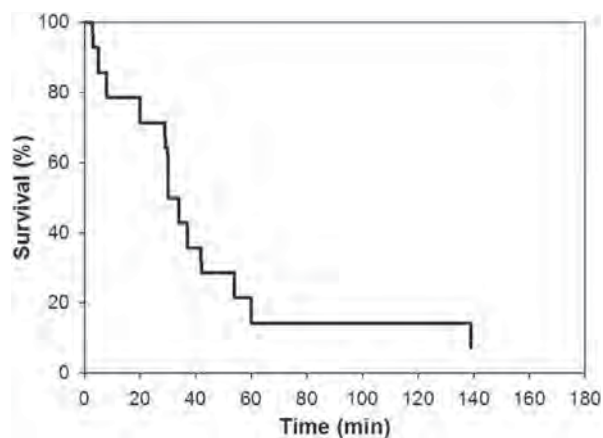
Yorkshire swine (*Sus scrofa domestica*) 39–50 kg were obtained (Tufts University School of Veterinary Medicine, North Grafton, MA) and maintained in a facility accredited by the Associated for the Assessment and Accreditation of Laboratory Animal Care International (AAALAC). The study was approved by the Institutional Animal Care and Use Committee of the Massachusetts General Hospital (IACUC) and the Animal Use and Review Office of the US Army medical Research and Materiel Command (ACURO). Animal received care in accordance with the Guide of the Care and Use of Laboratory Animals (Health, 2011 #17).

### 2.2. Instrumentation and monitoring

All swine ( $n = 14$ ) were allowed to acclimate for 2 d and examined by a veterinarian to ensure good health. Food was withheld the night before surgery but access to drinking water was provided. On the day of surgery, animals were anesthetized with an intramuscular injection of 5 mg/kg Telazol (50 mg/mL of tiletamine hydrochloride and 50 mg/mL of zolazepam hydrochloride; Fort Dodge Animal Health, Overland Park, KS) mixed with 1.5 mg of atropine sulfate (Med-Pharmex Inc, Pomona, CA).



**Fig. 2 – MAP (A) and CO (B) as a function of time.** Vital signs dropped rapidly after injury at time = 0 (black arrows).



**Fig. 3 – Kaplan-Meier survival curve. Twelve of 14 animals died within 60 min, with a median survival time of 32 min.**

Animals were intubated and mechanical ventilation was started (Integra Anesthesia System, DRE Veterinary, Louisville, KY). Initial respiratory settings included a tidal volume of 10 mL/kg body weight, peak pressure of 20 cm H<sub>2</sub>O, and a respiratory rate of 10 breaths per minute to maintain a pH of 7.4 and p<sub>a</sub>CO<sub>2</sub> of approximately 40 mm Hg, as reflected by arterial blood gas analysis. The fraction of inspired oxygen was 21%. General anesthesia was maintained using isoflurane (1.5%–2.5%) and room air.

The right carotid artery (5F catheter—invase blood pressure monitoring, blood gas analysis—Boston Scientific, Natick, MA), right internal jugular vein (14G angiocatheter—fluid resuscitation—Becton-Dickinson, Sandy, UT), and right external jugular vein (9F catheter—Cordis, Miami Lakes, FL—Swan-Ganz catheter; Edwards Lifesciences, Irvine, CA) were cannulated using a cut down technique.

Cardiac output (CO), pulmonary artery pressure, and core body temperature were monitored continually from the Swan-Ganz catheter (Vigilance II Monitor; Edwards Lifesciences). Invasive hemodynamic monitoring was continually performed (Eagle 4000 Patient Monitor; GE Marquette, Piscataway, NJ). Vital signs (pulse oximetry [SpO<sub>2</sub>], heart rate, invasive arterial pressure, respiratory rate, and central venous pressure) were recorded every 5 min. End-tidal CO<sub>2</sub> (ETCO<sub>2</sub>) was also measured throughout the experiment (V9004; SurgiVet, Waukesha, WI).

A midline laparotomy was performed to place a cystostomy tube (18F 2-way Foley Catheter; Rusch, Research Triangle Park, NC) for measurement of intra-abdominal pressure using the Abviser Transducer Device (ConvaTec Inc, Skillman, NJ).

### 2.3. Experimental procedure

The abdomen was accessed by a midline laparotomy and small bowel was retracted to identify the abdominal aorta and vena cava. The peritoneum was incised along a 3 cm length of the right external iliac artery, resulting in this vessel being intraperitonealized.

To create the injury, the artery was instrumented with a cutting suture (braided #0 silk; Ethicon, Somerville, NJ). The suture was wrapped around the vessel twice as shown in Figure 1A. Bowel was carefully replaced and the suture externalized percutaneously. Routine abdominal fascial closure was performed using #1 Nylon suture (Ethicon). Retraction of the cutting wire in a sawing motion resulted in complete transection of the external iliac artery.

Animals were resuscitated with two 500 mL boluses of Lactated Ringer Solution, administered at 5 min and again at 12 min after injury. Resuscitation was performed at a rate of 100 mL/min, up to a maximum total volume of 1 L, using a peristaltic pump (Masterflex L/S; Cole-Parmer Instrument Co, Court Vernon Hills, IL). This hypotensive resuscitation protocol was adapted from Tactical Combat Casualty Care (TCCC) guidelines.

End of experiment was defined as either an observation period of 180 min after injury or upon death (defined by ETCO<sub>2</sub> < 8, mean arterial pressure [MAP] < 15 mm Hg). At this end point, the abdomen was rapidly re-entered and ongoing hemorrhage was controlled by clamping the transected vessel. Liquid blood was aspirated from the abdomen and weighed. Blood clots were removed by hand and weighed. These values were summed to determine the total hemorrhage volume per kilogram body weight to normalize for interanimal weight variability. Hemorrhage rate was calculated by dividing hemorrhage volume by survival time. The external iliac artery and surrounding vasculature was explanted (Fig. 1B) and the injured vessel characterized.

## 3. Results

The external iliac artery was successfully transected in 14 animals by percutaneous distraction of a strategically placed cutting suture. The distance from the transected artery to the aortic bifurcation was 10 ± 5 mm in all but one case.

The injury resulted in a rapid, severe drop in MAP and CO (Fig. 2). Baseline MAP of animals was 64 ± 5.7 mm Hg. MAP decreased by approximately 30 mm Hg in the first minute after injury and was 20 ± 5.7 mm Hg at 5 min, the time of the

**Table 1 – Summary of hemodynamic parameters.**

Parameter	Initial value (n = 14)	T = 5 min value (n = 11)	T = 12 min value (n = 8)	Final value (n = 14)
Lactate (mmol/L)	1.2 ± 0.54	2.1 ± 0.78	5.0 ± 2.0	8.0 ± 4.1
Hematocrit (%)	31 ± 2.4	32 ± 4.0	25 ± 2.6	25 ± 4.3
pH	7.428 ± 0.031	7.522 ± 0.048	7.491 ± 0.055	7.499 ± 0.062
Platelets (×10 <sup>3</sup> /μL)	321 ± 87	—	—	230 ± 68

Intermediate time points were collected for a subset of animals; platelets were measured only at the beginning and end of studies.

**Table 2 – Swine models of arterial hemorrhage within the abdomen.**

Authors	Closed/open abdomen	Injury model	Vent percent O <sub>2</sub>	Resuscitation protocol	Duration	Mortality	Blood loss
Sondeen et al. [7]	Open	4.4 mm perforation of abdominal aorta	100%	300 mL/min IV lactated Ringer solution	60 min	88%	905 mL
Bickell et al. [10]	Closed	5 mm longitudinal infrarenal aortotomy	60%	None	120 min	0%	22 mL/kg
Bickell et al. [9]	Closed	5 mm longitudinal infrarenal aortotomy	60%	Saline/4 mL/kg (1 min) LRS 80 mL/kg (6 min) Control	120 min	37.5% 100% 0%	43 g/kg 68 g/kg 25 g/kg
Bruttig et al. [11]	Closed	5 mm longitudinal infrarenal aortotomy	100%	4 mL/kg saline (1 min bolus) 4 mL/kg saline (12 min infusion) Control	120 min	1.46% 2.22% 3.50%	23 g/kg 18 g/kg 15 g/kg
Kheirabadi et al. [6]	Open	4.4 mm perforation of infrarenal aorta	100%	Lactated Ringers, 3× pretreatment blood volume at 100 mL/min	96 h	100%	39.8 ± 8.5 mL/kg
Riddez et al. [12]	Closed	5 mm longitudinal infrarenal aortotomy		Saline/dextran: 1, 2, or 4 mL/kg in 5 min	120 min	1 mL (20%) 2 mL (50%) 4 mL (50%)	1 mL: 25 g/kg 2 mL: 38 g/kg 4 mL: 41 g/kg
Riddez et al. [13]	Closed	5 mm longitudinal infrarenal aortotomy		None LRS 1:1 LRS 2:1 LRS 3:1	120 min	50% 25% 25% 50%	33 cc/kg 36 cc/kg 41 cc/kg 55 cc/kg
Vournakis et al. [8]	Open	4 mm punch biopsy of abdominal aorta	100%	Fluids administered to SBP 90 mm Hg	120 min	60%	39 cc/kg

IV = intravenous; LRS = Lactated Ringer Solution; SBP = systolic blood pressure.



first resuscitation bolus. CO decreased steadily after a measurement delay of approximately 5 min attributed to data integration (Edwards continuous CO monitor).

The injury was lethal in 13 of 14 animals, and 11 of 14 animals died before the 60-min end point (Fig. 3). The median survival time was 32 min with a range from 3 to 139 min. One study was censored at 60 min as part of method development but is included in these analyses.

The mean normalized hemorrhage volume was  $3.19 \pm 4.36$  g/kg/min. Blood lactate accumulated throughout the experiment to a final value of  $8.0 \pm 4.1$  mmol/L (Table 1). Animals exhibited only moderate hemodilution as a result of the hypotensive resuscitation protocol. Baseline hematocrit was  $31\% \pm 2.5\%$  and was  $25\% \pm 4.3\%$  at the time of death.

#### 4. Discussion

Percutaneous transection of the external iliac artery resulted in rapid exsanguinating hemorrhage. We demonstrated a median survival time of 32 min and >85% mortality at 1 h. Injury resulted in significant hypotension and a decrease in CO. We attribute these results to the high-pressure, high-flow hemorrhage provided by the arterial transection.

In Yorkshire swine, the external iliac arteries branch from the distal aorta, which then terminate distally as the common femoral arteries at the inguinal ligament. The right external iliac artery was transected approximately 1 cm distal to the aortic bifurcation in swine. The cutting suture was wrapped around the iliac artery twice (“double-looping” to prevent slippage) before externalizing, resulting in a highly reproducible and consistent transected vessel length.

Several investigators have designed intra-abdominal hemorrhage models of arterial injury in the abdomen (Table 2). In one class of models [6,7], a punch biopsy injury was created in the abdominal aorta. In control groups without intervention, this model was lethal (60%–100% mortality at 2 h) [6–8]. The punch biopsy model incorporated high-volume crystalloid resuscitation and ventilation with 100% oxygen, a condition that is not necessarily representative of the prehospital setting. In addition, this model required an open abdomen and direct visualization of the target tissue for direct application of hemostatic interventions. Although these models provide a stringent mortality challenge, the closed-cavity nature of noncompressible hemorrhage is not captured.

In another class of models [9,10], a suture was placed longitudinally through the abdominal aorta and externalized through the skin, such that distracting the wire would result in uncontrolled abdominal hemorrhage. This injury mechanism was similar to that described in this manuscript and facilitated closed-abdomen hemorrhage studies. However, without fluid resuscitation, mortality at 120 min varied from 0% to 50%. Incorporation of fluid resuscitation increased mortality to 20%–100%, although methods and results were inconsistent across studies [9–13].

The iliac artery transection model described in this manuscript includes several advantages over existing models. First, the model is consistently lethal in the majority of animals, with a median survival time of 32 min. This feature enables definitive testing of hemostatic interventions,

resuscitation protocols, or blood products intended for the treatment of noncompressible trauma primarily based on survival outcomes. Second, the injury is created in a closed cavity, simulating clinical injuries where the site of bleeding and position within the abdomen cannot be visualized or confirmed. Third, the animal model incorporates fluid resuscitation and ventilation protocols adapted from clinical guidelines. By administering two bolus infusions of limited volume, the model avoids dilutional coagulopathy associated with aggressive, high-rate/high-volume resuscitation. Ventilation with room air (roughly 21% oxygen) is more consistent with gas available for ventilation support on the battlefield or austere prehospital environment. Fourth, the instrumentation is simple and results extremely reproducible if the cutting suture is double-looped to prevent slippage. This prevents some transections from migrating distally on suture distraction, which may result in a less lethal injury. Fifth, the injury model does not require artificial manipulation of the coagulation cascade using pharmacologic methods. Finally, the injury modality—complete transection—is more representative of arterial injuries observed in combat, which are usually managed with vascular shunts [15].

There are two limitations to this study. First, the resuscitation protocol was adapted from TCCC guidelines, but we chose to use Lactated Ringer Solution instead of a colloid resuscitation fluid, although both remain a TCCC option. In addition, the rate of fluid resuscitation, 100 mL/min, is likely idealizing the fastest rate of administration that can be delivered in a prehospital setting. The rate of fluid administration in the prehospital environment is poorly characterized by the literature for this kind of injury, but we felt this idealized approach offered the best evidenced-based therapy for massive, profound hypotension. The minimum and maximum survival time varied substantially from 3 to 139 min. However, the majority of experimental animals died within 1 h, and we believe this model represents a significant yet sensitive challenge to hemostatic interventions.

In summary, we created a novel, lethal, closed-cavity arterial injury model that is simple and reproducible. This hemorrhage model can be useful for testing prehospital hemostatic interventions, resuscitation, and other interventions in a clinically relevant closed-abdominal cavity with hemostatic resuscitation.

#### Acknowledgment

This work was supported by DARPA and ARO contract W911NF-10-C-0089. The authors thank Kyle Sims, Dr Julius Chang, Drs Bijan Kheirabadi, Jill Sondeen, Mike Dubick, John Holcomb, Martin Schreiber, and Peter Rhee for consultation and feedback.

#### REFERENCES

- [1] Eastridge BJ, Hardin M, Cantrell J, et al. Died of wounds on the battlefield: causation and implications for improving combat casualty care. *J Trauma* 2011;71:54.

- 
- [2] Eastridge BJ, Mabry RL, Seguin P, et al. Death on the battlefield (2001-2011): implications for the future of combat casualty care. *J Trauma Acute Care Surg* 2012;73:S431.
- [3] White JM, Stannard A, Burkhardt GE, Eastridge BJ, Blackbourne LH, Rasmussen TE. The epidemiology of vascular injury in the wars in Iraq and Afghanistan. *Ann Surg* 2011;253:1184.
- [4] Markov NP, DuBose JJ, Scott D, et al. Anatomic distribution and mortality of arterial injury in the wars in Afghanistan and Iraq with comparison to a civilian benchmark. *J Vasc Surg* 2012;56:728.
- [5] Stannard A, Morrison JJ, Scott DJ, Ivatury RA, Ross JD, Rasmussen TE. The epidemiology of noncompressible torso hemorrhage in the wars in Iraq and Afghanistan. *J Trauma Acute Care Surg* 2013;74:830.
- [6] Kheirabadi BS, Acheson EM, Deguzman R, et al. Hemostatic efficacy of two advanced dressings in an aortic hemorrhage model in Swine. *J Trauma* 2005;59:25. discussion 34-25.
- [7] Sondeen JL, Pusateri AE, Coppes VG, Gaddy CE, Holcomb JB. Comparison of 10 different hemostatic dressings in an aortic injury. *J Trauma* 2003;54:280.
- [8] Vournakis JN, Demcheva M, Whitson AB, Finkielstein S, Connolly RJ. The RDH bandage: hemostasis and survival in a lethal aortotomy hemorrhage model. *J Surg Res* 2003;113:1.
- [9] Bickell WH, Bruttig SP, Millnamow GA, O'Benar J, Wade CE. Use of hypertonic saline/dextran versus lactated Ringer's solution as a resuscitation fluid after uncontrolled aortic hemorrhage in anesthetized swine. *Ann Emerg Med* 1992;21:1077.
- [10] Bickell WH, Bruttig SP, Wade CE. Hemodynamic response to abdominal aortotomy in the anesthetized swine. *Circ Shock* 1989;28:321.
- [11] Bruttig SP, O'Benar JD, Wade CE, Dubick MA. Benefit of slow infusion of hypertonic saline/dextran in swine with uncontrolled aortotomy hemorrhage. *Shock* 2005;24:92.
- [12] Riddez L, Drobin D, Sjostrand F, Svensen C, Hahn RG. Lower dose of hypertonic saline dextran reduces the risk of lethal rebleeding in uncontrolled hemorrhage. *Shock* 2002;17:377.
- [13] Riddez L, Johnson L, Hahn RG. Central and regional hemodynamics during crystalloid fluid therapy after uncontrolled intra-abdominal bleeding. *J Trauma* 1998;44:433.
- [14] Duggan MJ, Mejaddam AY, Beagle J, et al. Development of a lethal, closed-abdomen grade V hepato-portal injury model in non-coagulopathic swine. *J Surg Res* 2013; 182:101.
- [15] Rasmussen TE, Clouse WD, Jenkins DH, Peck MA, Eliason JL, Smith DL. The use of temporary vascular shunts as a damage control adjunct in the management of wartime vascular injury. *J Trauma* 2006;61:8. discussion 12-15.

# Self-expanding foam improves survival following a lethal, exsanguinating iliac artery injury

Adam Rago, MS, Michael J. Duggan, DVM, John Marini, John Beagle, George Velmahos, MD, PhD, Marc A. De Moya, MD, Upma Sharma, PhD, John Hwabejire, MD, and David Richard King, MD, Boston, Massachusetts

**BACKGROUND:** Noncompressible abdominal bleeding is a significant cause of preventable death on the battlefield and in the civilian setting, with no effective therapies available at point of injury. We previously reported that a self-expanding polyurethane foam significantly improved survival in a lethal hepatoportal injury model of massive venous hemorrhage. In this study, we hypothesized that foam treatment could improve survival in a lethal iliac artery injury model in noncoagulopathic swine.

**METHODS:** In swine with a closed abdomen, an iliac artery transection was created, resulting in massive noncompressible exsanguination. After injury, animals were treated with damage-control fluid resuscitation alone (n = 14) or foam treatment in addition to fluids. Two doses of foam treatment were studied: 100 mL (n = 12) and 120 mL (n = 13); all animals were monitored for 3 hours or until death.

**RESULTS:** Foam treatment at both doses resulted in a significant survival benefit and reduction in hemorrhage rate relative to the control group. Median survival time was 135 minutes and 175 minutes for the 120-mL and 100-mL doses, compared with 32 minutes in the control group ( $p < 0.001$  for both groups). Foam resulted in an immediate, persistent improvement in mean arterial pressure and a transient increase in intra-abdominal pressure. The median hemorrhage rate was 0.27 g/kg per minute in the 120-mL group and 0.23 g/kg per minute in the 100-mL group, compared with 1.4 g/kg per minute in the control group ( $p = 0.003$  and  $0.006$ , respectively, as compared with the control).

**CONCLUSION:** Self-expanding foam treatment significantly improves survival in an otherwise lethal, noncompressible, massive, arterial injury. This treatment may provide a prehospital intervention for control of noncompressible abdominal hemorrhage. (*J Trauma Acute Care Surg.* 2014;77: 73–77. Copyright © 2014 by Lippincott Williams & Wilkins)

**KEY WORDS:** Foam; bleeding; trauma; iliac; battlefield.

Noncompressible abdominal bleeding, particularly caused by large vascular injury, represents a significant unmet medical need on the battlefield and in civilian trauma. This type of injury accounts for approximately 50% of potentially survivable battlefield casualties.<sup>1–4</sup> A survey of the Department of Defense Trauma Registry found that within this population, more than 80% of lethal abdominal vascular injuries involved major arterial hemorrhage.<sup>5,6</sup> Reviews of the National Trauma Data Bank have found similarities in anatomic causes of noncompressible hemorrhage between military and civilian populations and that such injuries were associated with high mortality.<sup>7,8</sup> There are currently no available prehospital treatments other than rapid transport to definitive surgical care, and many patients die en route to this intervention.<sup>2</sup>

We previously investigated the dose-dependent efficacy of a self-expanding polyurethane foam in a lethal, noncompressible,

Grade V hepatoportal injury model of massive venous bleeding.<sup>9</sup> Results suggested that foam treatment promoted survival, while the control group (fluid resuscitation alone) exsanguinated rapidly. This model tested a low-pressure, high-flow venous bleeding scenario.<sup>9,10</sup> A limitation of this model, however, was high-volume crystalloid resuscitation and ventilation with 100% oxygen,<sup>11</sup> features inconsistent with current Tactical Combat Casualty Care (TCCC) guidelines.<sup>12</sup> This initial work specifically tested the durability of hemostasis under conditions known to promote bleeding. The purpose of the current study was to demonstrate efficacy of foam treatment in a model of massive, noncompressible arterial hemorrhage (high-pressure, high-flow arterial bleeding) while incorporating TCCC guidelines. We hypothesized that foam treatment would improve survival in this TCCC resuscitation-compliant model of arterial abdominal exsanguination.

Submitted: November 1, 2013, Revised: December 12, 2014, Accepted: January 21, 2014.

From the Division of Trauma, Emergency Surgery and Surgical Critical Care (M.J.D., J.B., G.V., M.A.D., J.H., D.R.K.), Department of Surgery, Massachusetts General Hospital and Harvard Medical School, Boston; and Arsenal Medical, Inc. (A.R., J.M., U.S.), Watertown, Massachusetts.

This study was presented at the 27th Annual Scientific Assembly of the Eastern Association for the Surgery of Trauma, January 14–18, in Naples, Florida. Winner of EAST's 2014 Best Manuscript award.

Address for reprints: LTC David Richard King, MD, MC, USAR, Division of Trauma, Emergency Surgery, and Surgical Critical Care, Massachusetts General Hospital, 165 Cambridge St, Suite 810, Boston, MA 02141; email: dking3@mgh.harvard.edu.

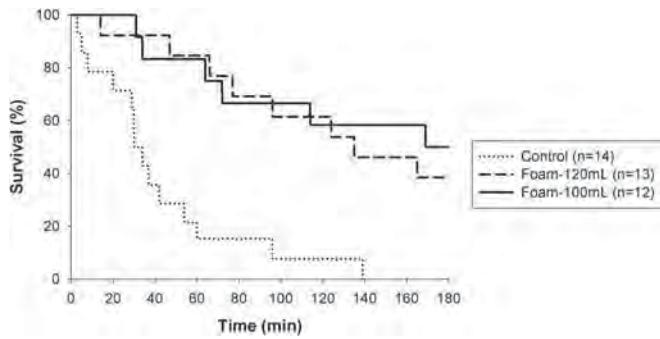
DOI: 10.1097/TA.0000000000000263

*J Trauma Acute Care Surg*  
Volume 77, Number 1

## MATERIALS AND METHODS

The poly(urea)urethane foam formulation was made as previously described.<sup>9</sup> A lethal, closed-abdomen iliac artery transection injury model<sup>13</sup> was tested in *Sus scrofa domestica* (45 ± 2.7 kg). All work was conducted with Institutional Animal Care and Use Committee approval.

Briefly, animals were intensively instrumented for hemodynamic and intra-abdominal pressure (IAP) monitoring. The retroperitoneum was dissected to expose and isolate the right external iliac artery. A cutting wire was double-looped



**Figure 1.** Kaplan-Meier survival curve. Foam administration resulted in a significant survival benefit at the 100-mL and 120-mL dose relative to the control group.

around the vessel and was exteriorized, and the abdomen was closed. A closed-cavity iliac artery transection was created by percutaneous distraction of the wire. Fluid resuscitation was limited to two 500-mL boluses of lactated Ringer’s solution at 5 minutes and 12 minutes after injury.

One minute after injury, experimental animals received foam at two different initial volumes or “treatment doses” as follows: 100 mL or 120 mL. Control animals received fluid resuscitation alone. Vital signs and intra-abdominal pressure (IAP, via bladder pressure) were recorded continually. Animals were observed for 180 minutes after injury or until death (defined by  $\text{ETCO}_2 < 8$  or mean arterial pressure [MAP]  $< 15$  mm Hg), whichever came first. Surviving animals were euthanized at 180 minutes. “Final” measurements of vital signs, blood gas, and blood counts were collected at 180 minutes or the time of death. One control animal was censored at 60 minutes during model development and was included in the analysis. Following death, the foam was rapidly removed as a single block. Ongoing hemorrhage was controlled with vascular clamps. Liquid blood and clots were removed and massed to determine the total hemorrhage volume per kilogram body weight to normalize for weight variability between animals. Overall hemorrhage rate was calculated by dividing hemorrhage volume by survival time. The external iliac artery and surrounding vasculature were explanted, and the iliac injury was characterized for consistency.

Continuous variables were summarized using mean  $\pm$  SD and compared between the treatment and control groups using two-sample *t* tests or summarized using median with interquartile

ranges and compared using Wilcoxon rank-sum tests. Category variables were summarized using percentage and compared using Fisher’s exact tests. Survival time was censored at 3 hours and summarized using median and interquartile ranges. Kaplan-Meier curves were used to depict survival over time, and log-rank tests were used to compare between groups. Two-sided  $p < 0.05$  was considered statistically significant. All analyses were performed using SAS version 9.3 (The SAS Institute, Inc., Cary NC).

## RESULTS

A self-expanding polyurethane foam was injected into the abdomen in the presence of a severe iliac artery injury. Foam expanded approximately 37-fold from the original volume of 100 mL or 120 mL. Foam treatment resulted in a significant survival advantage at both doses (Fig. 1). Survival at 1 hour was 85% at 120 mL and 83% at 100 mL, compared with 21% in the control group ( $p = 0.005$  and  $0.005$ , respectively). The median survival time was 135, 175, and 32 minutes for the 120-mL, 100-mL, and control groups, respectively (Table 1). Survival decreased as a function of time, with no differences between the 100-mL and 120-mL dose groups. At 3 hours, we observed 39% survival in the 120-mL group and 50% survival in the 100-mL dose group compared with 0% in the control group ( $p = 0.039$  and  $0.005$ , respectively).

At both doses, foam administration resulted in a decrease in hemorrhage rate relative to the control group. The median hemorrhage volume was 0.27 g/kg per minute in the 120-mL group and 0.23 g/kg per minute in the 100-mL group, compared with 1.4 g/kg per minute in the control group ( $p = 0.003$  and  $0.006$ , respectively, for the 120-mL and 100-mL groups compared with the controls).

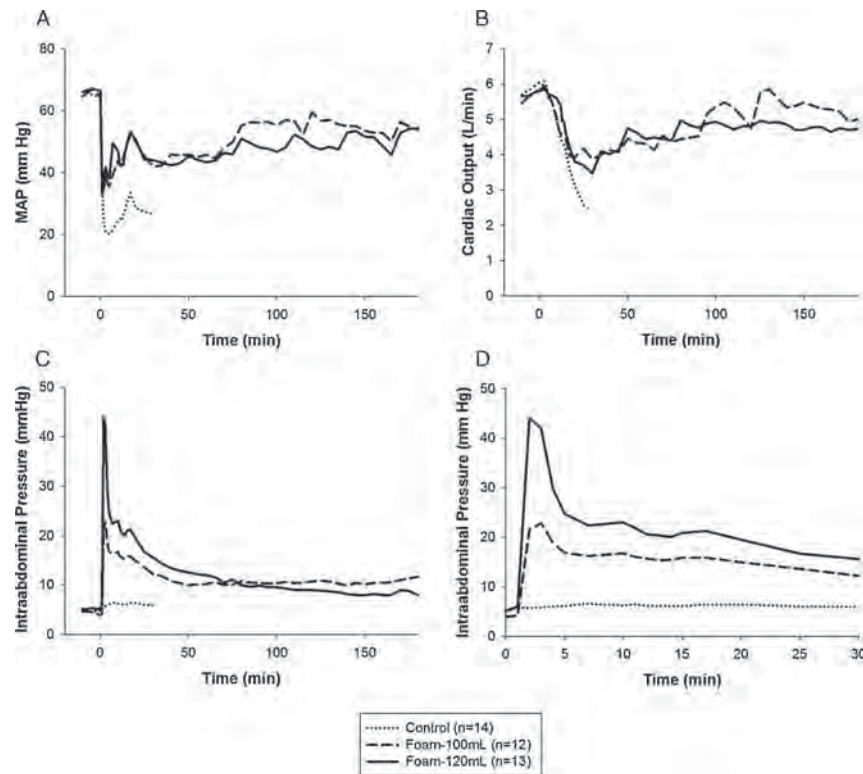
The iliac artery transection resulted in a rapid drop in MAP (Fig. 2A), with a mean  $\pm$  SD of  $35 \pm 12$  mm Hg at 1 minute after injury, leaving animals in pulseless electrical activity. A simultaneous decrease in cardiac output was observed, reflecting massive, exsanguinating hemorrhage (Fig. 2B). Foam treatment resulted in an immediate increase in MAP and IAP (Fig. 2A, C, and D). MAP was maintained between 40 mm Hg and 60 mm Hg for the duration of the experiment in surviving animals, while control animals were not responsive to resuscitation alone and died. The increase in IAP was dose dependent, with a maximum

**TABLE 1.** Primary and Secondary Outcomes

	Control (n = 14)	100 mL (n = 12)	<i>p</i>	120 mL (n = 13)	<i>p</i>
Survival at 1h	3/14	10/12	0.005	11/13	0.002
Survival at 3 h	0/13	6/12	0.005	5/13	0.04
Survival time, min	32 (23–51)	175 (70–180)	<0.001	135 (77–180)	<0.001
Hemorrhage rate, g/kg/min	1.4 (0.93–2.4)	0.23 (0.10–0.65)	0.006	0.27 (0.15–0.53)	0.003
Final MAP, mm Hg	14 (13–15)	21 (14–54)	0.04	17 (14–50)	0.06
Final CO, L/min	1.3 (1.1–4.1)	1.2 (1.1–4.5)	0.96	3.5 (1.2–5.4)	0.30
Final lactate, mmol/L	8.0 $\pm$ 4.1	6.7 $\pm$ 5.0	0.48	9.0 $\pm$ 4.7	0.59
Final hematocrit, %	25 $\pm$ 4.4	30 $\pm$ 3.1	0.004	30 $\pm$ 4.5	0.007
Final platelets, $\times 10^6/\mu\text{L}$	230 $\pm$ 68	271 $\pm$ 40	0.08	283 $\pm$ 68	0.06

Median values are reported with interquartile ranges for survival time, hemorrhage rate, and vital signs. Mean values  $\pm$  SD are presented for lactate, hematocrit, and platelets. *p* values are reported relative to the control group.





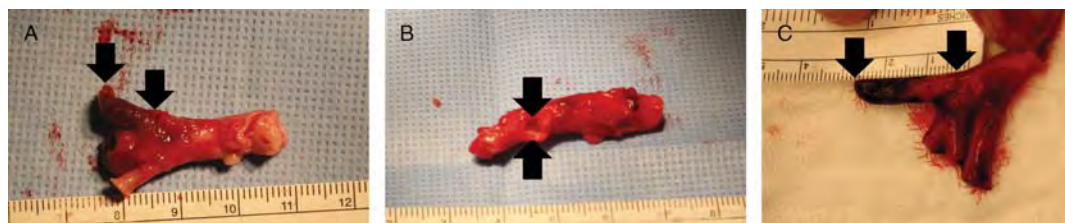
**Figure 2.** MAP (A), cardiac output (B), and intra-abdominal pressure (C) following foam deployment in an arterial injury model. Intraabdominal pressure during the first 30 minutes is shown in D. All curves represent mean values from surviving animals as a function of time. MAP and CO decreased following injury, resulting in exsanguination within the control group. Foam administration resulted in a transient increase in IAP and recovery of vital signs.

value of  $50 \pm 22$  in the 120-mL group and  $23 \pm 10$  in the 100-mL group. The increase in IAP after deployment was transient, but IAP remained tonically elevated throughout the experiment. Cardiac output stabilized within 30 minutes and, in some cases, recovered to near-baseline measurements (Fig. 2B). Hematocrit at 180 minutes or death was significantly higher in the foam groups (Table 1).

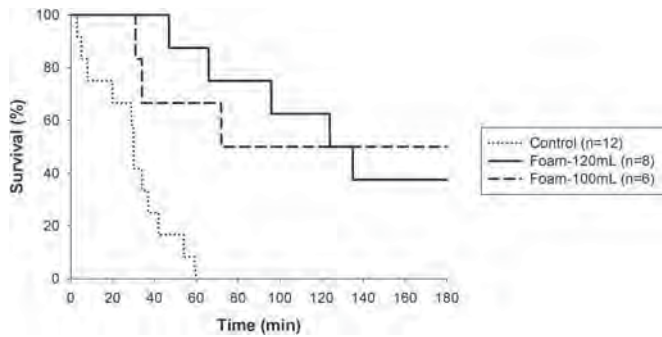
Foam was removed from the abdomen as a single block, in less than two minutes. The foam material did not adhere to tissues, although in certain cases, abdominal organs were encapsulated by the material and freed manually. In addition, gross pathology of all abdominal organs after foam deployment was unremarkable except for the observation of focal, ecchymotic lesions on small and large bowel,<sup>9,14</sup> which would require repair or resection for long-term survival.

During necropsy, all iliac vessels and aortic attachments were explanted and characterized for injury consistency. We

observed that the majority of iliac vessels were transected approximately 10 mm from the aortic bifurcation (Fig. 3). However, in some cases, we observed a short vessel stub or avulsion injury directly from the side of the aorta (Fig. 3B) or a longer vessel stub (Fig. 3C). A subset analysis was conducted to exclude animals in which the transection was not within  $10 \pm 5$  mm in length and where the MAP was greater than 40 mm Hg at 1 minute. Applying these criteria to select for a more homogeneous anatomic and physiologic injury, 8, 6, and 12 samples were analyzed in the 120-mL, 100-mL, and control groups, respectively. In this more homogenous population, foam administration resulted in a significant survival benefit at 1 hour (88% and 67% vs. 8% for the 120-mL and 100-mL dose groups vs. control;  $p < 0.001$  and  $p = 0.022$ , respectively, Fig. 4). Median survival time was significantly improved in both groups relative to the control (130 minutes and 126 minutes vs. 30 minutes



**Figure 3.** Representative images of injury anatomy after explant. A, Target transection length, 10 mm distal to the aorta. Potentially excluded anatomies include a transection length less than 5 mm (B) or longer than 15 mm (C). Arrows indicate the beginning and end of the transected external iliac. Note that the swine aortic anatomy differs from the human anatomy.



**Figure 4.** Kaplan-Meier survival curve. Foam administration resulted in a significant survival benefit at the 100-mL and 120-mL dose relative to the control group when analyzed according to transected vessel length and MAP at 1 minute.

for the 120-mL and 100-mL dose group vs. control;  $p < 0.001$  and  $p = 0.019$ , respectively). Additional secondary end points are reported in Table 2.

## DISCUSSION

This investigation demonstrated that a self-expanding polyurethane foam improves survival in a model of massive, exsanguinating, intra-abdominal, arterial hemorrhage. These results augment our previous work, where efficacy was established in a low-pressure, high-flow model of massive hepatoportal venous hemorrhage.<sup>9,10</sup> To test similar foam treatments in a different injury model, we selected doses for this study (100 mL and 120 mL) based on effective doses in the hepatoportal injury model. The combination of these findings supports the preclinical efficacy of foam treatment in multiple, lethal, bleeding scenarios.

Despite differences in animal models, the normalized hemorrhage rate was similar in this study to our previous model. At the 100-mL dose, the median hemorrhage rate was 0.23 g/kg per minute in the iliac artery model and 0.37 g/kg per minute in the liver injury model. These results support our hypothesis that foam administration slows bleeding to a sublethal rate, promoting survival relative to the control group.

We noted variation in the MAP at 1 minute and variable survival time in control animals. In an attempt to analyze animals with similar injury patterns, we conducted a subset analysis to exclude animals with nonuniform injuries based on an anatomic criteria (transected vessel length) and a physiologic criteria (MAP). This was done to eliminate animals with a survival (or death) bias caused by anatomic injury variation or animals with physiology suggesting an unusual prosurvival phenotype. The number of acceptable samples in the foam groups decreased by approximately 40%, while the sample size decreased by 14% in the control group (Table 2). Nevertheless, both foam doses resulted in a significant survival benefit relative to the control group and a significant reduction in hemorrhage rate. We conclude that the findings are similar in the full data set and in the subgroup analysis. A trend toward dose dependence was observed but was not significant between the 100-mL and 120-mL dose groups. Median survival time decreased in all groups when evaluating the subgroup, suggesting that the injury model may represent a more significant challenge under these subgroup conditions. Finally, no differences were observed across groups in lactate, hematocrit, or platelets, which is also consistent with the findings when analyzing the full data set.

There is no universally accepted animal model for the testing of prehospital interventions. Therefore, it is important to test hemostatic devices over a broad range of bleeding scenarios,<sup>15</sup> especially high-pressure, high-flow arterial hemorrhage where death is swift and certain without intervention. Multiple testing scenarios further reduce the risk of false-positive findings based on assumptions inherent to animal models. For example, the Hemcon chitosan dressing for external injuries was found to be effective against venous bleeding,<sup>16</sup> but results were inconclusive in mixed (arterial and venous)<sup>17</sup> and arterial bleeding.<sup>18,19</sup> Likewise, QuikClot Zeolite granules were effective in venous and mixed bleeding<sup>17,20</sup> but were not as effective in high-pressure, high-flow arterial bleeding scenarios.<sup>18</sup> We believe that this investigation fills an important gap in understanding the risks, benefits, limitations, and performance characteristics of this new hemostatic intervention.

Acute safety of the foam treatment was evaluated in this study, and as previously stated, we observed focal bowel damage associated with local pressure generated by the confirmation of foam to tissues. To evaluate the long-term safety

**TABLE 2.** Primary and Secondary Outcomes in a Retrospective Subgroup Analysis

	Control (n = 12)	100 mL (n = 6)	p	120 mL (n = 8)	p
Survival at 1h	1/12	4/6	0.022	7/8	<0.001
Survival at 3 h	0/11	3/6	0.029	3/8	0.058
Survival time, min	30 (17–38)	126 (34–180)	0.019	130 (81–180)	<0.001
Hemorrhage rate, g/kg/min	1.6 (1.2–3.7)	0.42 (0.15–1.5)	0.07	0.39 (0.18–0.56)	0.003
Final MAP, mm Hg	14 (12–15)	21 (14–50)	0.07	15 (14–37)	0.11
Final CO, L/min	1.4 (1.1–4.7)	1.2 (1.1–4.0)	0.85	1.4 (1.1–3.6)	1.0
Final lactate, mmol/L	8.1 ± 4.4	7.4 ± 4.5	0.78	11 ± 4.4	0.25
Final hematocrit, %	25 ± 4.5	30 ± 3.6	0.04	32 ± 3.8	0.001
Final platelets, × 10 <sup>6</sup> /μL	234 ± 74	247 ± 36	0.64	281 ± 74	0.19

Median values are reported with interquartile ranges for survival time, hemorrhage rate, and vital signs. Mean values ± SD are presented for lactate, hematocrit, and platelets. *p* values are reported relative to the control group.

MAP, mean arterial pressure; CO, cardiac output.

of the intervention and the repair of these complications, we conducted a dose-ranging safety study in a swine model.<sup>14</sup> The material was removed after 3 hours, and the animals were monitored during a 28-day period. All animals survived without clinical complications, and abdominal adhesions were similar to the study control group. Ongoing studies are assessing longer-term safety of foam treatment.

There are several limitations to this study. First, foam deployment in this model took place 1 minute after injury. This intervention time is faster than what would be expected in field use, especially when factoring in diagnosis and device preparation time. However, given the rapid rate of exsanguination within the control group, this rapid intervention time was required to prevent significant mortality before treatment. The intervention time is consistent with previous arterial injury models<sup>21</sup> used to test hemostatic agents. In addition, it may be reasonable to believe that if foam treatment is efficacious in this severe injury model with early intervention, it would also be efficacious in lesser injury with a treatment delay. Second, the goal of the study was to enroll 12 animals in each group. In this case, animal numbers varied between all groups because of logistic challenges, such as running a control experiment on a day a foam experiment was scheduled if foam was unavailable. All data, however, are presented for completeness instead of limiting groups to the predetermined 12 per arm. Third, blood loss is reported as hemorrhage rate (hemorrhage volume normalized for survival time), despite the fact that the true rate of bleeding likely changed with intervention and with time. This was done to account for the distinction between animals with rapid, unmitigated blood loss and slow blood loss largely treated by the foam. Fourth, animals were not randomized to experimental groups for planning and technical reasons. Finally, the device used to inject foam in this study was a prototype delivery system. A fieldable, ruggedized delivery system is being designed, but the fundamental, functional properties are expected to be consistent with the prototype tested in this study.

In summary, we demonstrated that a self-expanding foam improved survival in a high-pressure, high-flow lethal, arterial injury model on noncompressible, intra-abdominal exsanguination. When combined with our previous work in massive hepatoportal venous hemorrhage, these results indicate that foam treatment can improve survival in a range of noncompressible abdominal injuries. While further translational research is required, one can imagine this intervention providing a prehospital “hemostatic bridge” for severely bleeding casualties, who would otherwise bleed to death in the field, such that they can arrive alive to a surgical treatment facility.

#### AUTHORSHIP

A.R., M.J.D., J.M., and J.B. performed the data collection. G.V. and M.A.D. performed the data interpretation. A.R., U.S., M.J.D., and D.R.K. contributed in the literature search, study design, interpretation, and writing.

#### ACKNOWLEDGMENT

We thank Drs. John Holcomb, Martin Schreiber, Bijan Kheirabadi, Jill Sondeen, Mike Dubick, and Julius Chang for their input into the guidance of this project.

#### DISCLOSURE

This study was supported by DARPA and ARO contracts W911NF-10-C-0089 and W911NF-12-C-0066.

#### REFERENCES

1. Eastridge BJ, Hardin M, Cantrell J, et al. Died of wounds on the battlefield: causation and implications for improving combat casualty care. *J Trauma*. 2011;71:S4–S8.
2. Eastridge BJ, Mabry RL, Seguin P, et al. Death on the battlefield (2001–2011): implications for the future of combat casualty care. *J Trauma Acute Care Surg*. 2012;73:S431–S437.
3. Morrison JJ, Rasmussen TE. Noncompressible torso hemorrhage: a review with contemporary definitions and management strategies. *Surg Clin North Am*. 2012;92:843–858.
4. Morrison JJ, Stannard A, Rasmussen TE, et al. Injury pattern and mortality of noncompressible torso hemorrhage in UK combat casualties. *J Trauma Acute Care Surg*. 2013;75:S263–S268.
5. White JM, Stannard A, Burkhardt GE, et al. The epidemiology of vascular injury in the wars in Iraq and Afghanistan. *Ann Surg*. 2011;253:1184–1189.
6. Stannard A, Morrison JJ, Scott DJ, et al. The epidemiology of non-compressible torso hemorrhage in the wars in Iraq and Afghanistan. *J Trauma Acute Care Surg*. 2013;74:830–834.
7. Kisat M, Morrison JJ, Hashmi ZG, et al. Epidemiology and outcomes of non-compressible torso hemorrhage. *J Surg Res*. 2013;184:414–421.
8. Markov NP, DuBose JJ, Scott D, et al. Anatomic distribution and mortality of arterial injury in the wars in Afghanistan and Iraq with comparison to a civilian benchmark. *J Vasc Surg*. 2012;56:728–736.
9. Peev MP, Rago A, Hwabejire JO, Duggan MJ, Beagle J, Marini J, Zugates G, Busold R, Freyman T, Velmahos GS, Demoya MA, et al. Self-expanding foam for prehospital treatment of severe intra-abdominal hemorrhage: dose finding study. *J Trauma Acute Care Surg*. 2013;76:619–624.
10. Duggan M, Rago A, Sharma U, et al. Self-expanding polyurethane polymer improves survival in a model of noncompressible massive abdominal hemorrhage. *J Trauma Acute Care Surg*. 2013;74:1462–1467.
11. Duggan MJ, Mejaddam AY, Beagle J, et al. Development of a lethal, closed-abdomen grade V hepato-portal injury model in non-coagulopathic swine. *J Surg Res*. 2012;182:101–107.
12. Butler FK. Tactical combat casualty care: update 2009. *J Trauma*. 2010;69:S10–S13.
13. Duggan M, Rago AP, Marini J, Beagle J, Velmahos GS, Demoya MA, Sharma U, King DR. Development of a lethal, closed-abdomen arterial transection injury model in non-coagulopathic swine. *J Surg Res*. 2013.
14. Rago A, Duggan MJ, Beagle J, Peev MP, Marini J, Hwabejire JO, Hannett P, Zugates G, Busold R, Velmahos GS, et al. Self-expanding foam for prehospital treatment of intra-abdominal hemorrhage: 28-day survival and chronic safety. *J Trauma Acute Care Surg*. 2013.
15. Pusateri AE, Holcomb JB, Kheirabadi BS, et al. Making sense of the preclinical literature on advanced hemostatic products. *J Trauma*. 2006;60:674–682.
16. Pusateri AE, McCarthy SJ, Gregory KW, et al. Effect of a chitosan-based hemostatic dressing on blood loss and survival in a model of severe venous hemorrhage and hepatic injury in swine. *J Trauma*. 2003;54:177–182.
17. Alam HB, Chen Z, Jaskille A, et al. Application of a zeolite hemostatic agent achieves 100% survival in a lethal model of complex groin injury in swine. *J Trauma*. 2004;56:974–983.
18. Acheson EM, Kheirabadi BS, Deguzman R, et al. Comparison of hemorrhage control agents applied to lethal extremity arterial hemorrhages in swine. *J Trauma*. 2005;59:865–875.
19. Kheirabadi BS, Acheson EM, Deguzman R, et al. Hemostatic efficacy of two advanced dressings in an aortic hemorrhage model in swine. *J Trauma*. 2005;59:25–35.
20. Pusateri AE, Delgado AV, Dick EJ Jr, et al. Application of a granular mineral-based hemostatic agent (QuikClot) to reduce blood loss after grade V liver injury in swine. *J Trauma*. 2004;57:555–562.
21. Sondeen JL, Pusateri AE, Coppes VG, et al. Comparison of 10 different hemostatic dressings in an aortic injury. *J Trauma*. 2003;54:280–285.



# Self-expanding foam for prehospital treatment of intra-abdominal hemorrhage: 28-day survival and safety

Adam P. Rago, MS, Michael J. Duggan, DVM, John Beagle, Miroslav P. Peev, MD, John Marini, John O. Hwabejire, MD, Patricia Hannett, Greg Zugates, PhD, Rany Busold, Marc Helmick, George Velmahos, MD, PhD, Marc A. Demoya, MD, Daniel Dante Yeh, MD, Peter J. Fagenholz, MD, Upma Sharma, PhD, and David R. King, MD, Boston, Massachusetts

- BACKGROUND:** Intracavitary noncompressible hemorrhage remains a significant cause of preventable death on the battlefield and in the homeland. We previously demonstrated the hemostatic efficacy of an in situ self-expanding poly(urea)urethane foam in a severe, closed-cavity, hepatoportal exsanguination model in swine. We hypothesized that treatment with, and subsequent explantation of, foam would not adversely impact 28-day survival in swine.
- METHODS:** Following a closed-cavity splenic transection, animals received either fluid resuscitation alone (control group, n = 6) or resuscitation plus foam treatment at doses of 100 mL (n = 6), 120 mL (n = 6), and 150 mL (n = 2). Foam was allowed to polymerize in situ and was explanted after 3 hours. The animals were recovered and monitored for 28 days.
- RESULTS:** All 18 animals in the 100-mL, 120-mL, and control groups survived to the 28-day endpoint without complications. The 150-mL group was terminated after the acute phase (n = 2). En bloc explantation of the foam took less than 2 minutes and was associated with millimeter-sized remnant particles. All foam animals required some level of enteric repair (imbrication or resection). Excluding the aborted 150-mL group, all animals survived, with no differences in renal or hepatic function, serum chemistries, or semiquantitative abdominal adhesion scores. Histologic analysis demonstrated that remnant particles were associated with a fibrotic capsule and mild inflammation, similar to that of standard suture reaction. In addition, safety testing (including genotoxicity, pyrogenicity, and cytotoxicity) was performed consistent with the ISO-10993 standard, and the materials passed all tests.
- CONCLUSION:** For a distinct dose range, 28-day recovery after foam treatment and explantation for noncompressible, intra-abdominal hemorrhage is not associated with significant physiologic or biochemical evidence of end-organ dysfunction. A foam volume exceeding the maximum tolerable dose was identified. Bowel repair is required to ensure survival. (*J Trauma Acute Care Surg.* 2014;77: S127–S133. Copyright © 2014 by Lippincott Williams & Wilkins)
- KEY WORDS:** Noncompressible; abdominal hemorrhage; survival; safety; swine.

Intra-abdominal, noncompressible hemorrhage represents a significant cause of prehospital mortality, with no effective treatments other than rapid evacuation and emergency surgical intervention. This injury pattern accounts for approximately 50% of potentially survivable fatalities (as determined by a team of military medical experts<sup>1</sup>) during Operation Iraqi Freedom and Operation Enduring Freedom.<sup>1–4</sup> In the homeland, severe abdominal trauma affects nearly 50,000 patients and resulted in more than 11,000 deaths per year.<sup>5</sup> Kisat et al.<sup>6</sup> reported a 45% mortality rate in patients with noncompressible hemorrhage presenting at US Level 1 trauma centers, and data from the National Trauma Data Bank indicated greater than

30% mortality from 2008 to 2011 in patients requiring laparotomy within 2 hours.<sup>5</sup>

To address this need, we developed an in situ-forming poly(urea)urethane foam that can be percutaneously administered into the peritoneal space, self-expands, conforms to injured tissues, and provides a tamponade effect to slow or stop bleeding,<sup>7</sup> thereby keeping animals alive (that would otherwise die) for up to 3 hours and allowing them to be safely evacuated to surgical intervention. The material consists of two liquid phases, which are mixed and injected simultaneously. The components react, resulting in approximately 30-fold material expansion. This expansion is coupled with a cross-linking reaction that converts the mixed liquid into solid, creating mechanical integrity and applying pressure to bleeding surfaces as well as enabling easy removal at time of definitive care.

Foam systems were previously proposed for the treatment of noncompressible trauma and provided effective hemostasis when applied directly to injuries. However, these interventions were not successful in closed-abdomen injury models, in which foams could not reach injured tissue.<sup>8,9</sup> Our previous work demonstrated that foam treatment improved survival and reduced rate of hemorrhage in a closed-cavity, Grade V, hepatoportal exsanguination model in swine. Deployment of the foam significantly improved survival relative to resuscitation alone.<sup>7</sup> The unique reaction and material

Submitted: December 3, 2013, Revised: January 21, 2014, Accepted: January 22, 2013.  
From the Arsenal Medical, Inc. (A.R., J.M., P.H., G.Z., R.B., M.H., U.S.), Watertown; and Department of Surgery (M.J.D., J.B., M.P.P., J.O.H., G.V., M.A.D., D.D.Y., P.J.F., D.R.K.), Division of Trauma, Emergency Surgery and Surgical Critical Care, Massachusetts General Hospital & Harvard Medical School, Boston, Massachusetts.

This study was presented at the 2013 Military Health System Research Symposium, August 12–15, 2013 in Fort Lauderdale, Florida.

Address for reprints: LTC David Richard King, MD, MC, USAR, Department of Surgery, Division of Trauma, Emergency Surgery and Surgical Critical Care, Massachusetts General Hospital, 165 Cambridge St, Suite 810, Boston, MA 02141; email: dking3@mgh.harvard.edu.

DOI: 10.1097/TA.0000000000000380

*J Trauma Acute Care Surg*  
Volume 77, Number 3, Supplement 2

S127



properties of the foam polymer represented a key advance beyond previous development efforts.<sup>8,9</sup> A subsequent dose-finding study by our group defined the range of effective doses for the foam, showing that efficacy improved with increased dose.<sup>10</sup>

Despite a demonstration of efficacy, acute testing identified several potential safety risks associated with foam use. Specifically, we observed that use of the foam, while lifesaving, resulted in transient intra-abdominal hypertension, raising the potential concern of end-organ injury from abdominal compartment syndrome. Second, we observed focal ecchymotic lesions in the small and large intestines, associated with regions closely apposed to the polymer. Third, we noted that the abdominal cavity temperature increased marginally following foam deployment because of the exothermic nature of the polymerization reaction. Finally, the long-term impact of exposure to remnants of an in situ curing poly(urea)urethane required investigation. Modulation of initial dose may mitigate each of these complications, but we expect all efficacious doses to be associated with some safety risk.<sup>11</sup> To test these potential safety risks, we conducted a dose-finding study in a splenic hemorrhage model. We hypothesized that treatment with, and subsequent explantation of, foam would not adversely impact 28-day survival.

## MATERIALS AND METHODS

The foam formulation was made as previously described.<sup>7,10,12</sup> In addition, each phase was sterile filtered at 0.2  $\mu\text{m}$  and packaged aseptically before use. A nonlethal, noncoagulopathic, closed-cavity, noncompressible splenic injury model, adapted from our laboratory's previous work by Velmahos et al.,<sup>13</sup> was tested in *Sus scrofa domestica* (mean [SD], 46 [2.9] kg). All work was conducted with Institutional Animal Care and Use Committee approval.

Briefly, animals were intensively instrumented for hemodynamic and intra-abdominal pressure (IAP) monitoring. An electronic thermocouple was sutured to the internal surface of the peritoneum to monitor intra-abdominal temperature at the interface between foam and tissue. A closed-cavity splenic injury was created by percutaneous wire distraction, resulting in full transection of the distal 10 cm of the spleen. Fluid resuscitation was initiated with Lactated Ringer's solution (LRS) when mean arterial pressure decreased lower than 60 mm Hg. Ten minutes after injury, the animals received hemostatic foam at different initial doses of 100, 120, and 150 mL or fluid resuscitation alone. These dose volumes were administered to understand how safety endpoints might be affected by dose. Vital signs and IAP were recorded continually. Arterial blood gases, complete blood cell counts, and serum chemistry measurements were taken at baseline and at 60-minute intervals for 180 minutes. At 180 minutes, all animals underwent laparotomy, splenorrhaphy, and (in foam-treated animals) foam explantation by hand as a single block followed by abdominal lavage with 2 L of LRS. The final foam volume was determined by displacement and corrected for water and blood absorption.

Gross examination of the viscera was conducted by a veterinary surgeon to identify abnormal findings. Focal ecchymotic bowel lesions were identified and quantified by idealizing lesions

as an ellipse in two dimensions. The bowel was repaired via imbrication with 2-0 Vicryl Ethicon (Somerville, NJ) suture or resection and end-to-end anastomosis at the discretion of the surgeon.

The abdomen was lavaged and aspirated twice with a total of 2 L of LRS to reduce the presence of remnant particles. All instrumentation was removed, tissue was repaired when appropriate, and incisions were closed using standard multi-layer closure and skin staples. Incisions were blocked with bupivacaine 0.25%, and pain control was provided with fentanyl transdermal patches (12  $\mu\text{g}/\text{h}$ ).

The animals were recovered and monitored for a 28-day period. Complete blood cell count and blood chemistry samples were collected at 1, 7, 14, 21, and 28 days after surgery. The animals were euthanized at 28 (2) days.

Immediately after euthanasia, the abdominal cavity was surveyed for abnormalities, and abdominal adhesions were assessed using a scale previously described by Kutlay et al.<sup>14</sup> Multiple samples of all abdominal organs were collected for histologic analysis. In addition, specimens from any anomalous gross pathology, visible remnant particles, or repair sites were collected for histology. Tissues were fixed in 10% neutral-buffered formalin and embedded in paraffin. Five-micrometer sections were cut, stained with hematoxylin and eosin, and analyzed by a blinded pathologist.

Statistical analysis was performed by summarizing continuous variables using mean (SD), and results were compared between the two treatment groups using two-sample *t* tests. Two-sided *p* values of less than 0.05 were considered as statistically significant. All analyses were done using SAS (SAS Institute, Cary, NC) version 9.3. Statistical analysis was not performed on the 150-mL dose group.

In a separate study, preformed foam samples were characterized according *ISO Standard-10993: Biological Evaluation of Medical Devices*.<sup>15</sup> Foam samples were generated by combining the polyol and isocyanate phases and mixing with an impeller mixer. The materials were allowed to react in vitro and cure into solid foam. Foam samples were subsequently cut to the necessary size for standard tests, packaged, and sterilized via ethylene oxide. All studies according to ISO-10993 were conducted at North American Science Associates, Inc. (Northwood, Ohio). Foam samples were characterized in a comprehensive package evaluating cytotoxicity, intracutaneous irritation, sensitization, acute systemic toxicity, pyrogenicity, genotoxicity, and local reaction following intramuscular implantation in mice, guinea pigs, and rabbits, as appropriate.

## RESULTS

Six animals were included in each of the 100-mL, 120-mL, and control groups; two animals were tested in the 150-mL group before additional testing in that group was aborted. Excluding the 150-mL group, all animals survived the 180-minute acute phase of the study (Table 1). In all groups, the volume of blood loss from the injury was less than 100 mL. One animal in the 150-mL group died shortly after polymer deployment when cardiac output decreased suddenly with foam deployment, resulting in low-flow state and death (Fig. 1). The other animal in the 150-mL group was euthanized at 180 minutes when multifocal colon

**TABLE 1.** Summary of Acute-Phase Endpoints

	Control	100	120	150
Survival	6/6	6/6	6/6	1/2
Hemorrhage volume	<100 mL	<100 mL	<100 mL	<100 mL
Lactate (180 min), mmol/L	1.5 (0.15)	1.6 (0.17)	1.5 (0.26)	N/A
Maximum IAP, mm Hg	4.8 (1.8)	23 (9.3)*	53 (19)*	99
Maximum temperature, °C	39 (0.66)	41 (1.1)*	41 (6.3)	40.2

\*Statistical significance relative to the control group.  
N/A, not applicable.

necrosis was noted. In this case, total abdominal colectomy would be required for survival, which was prohibited by our Institutional Animal Care and Use Committee approval.

The foam conformed around abdominal tissues, resulting in relief features of the small bowel, the large bowel, the liver, and the spleen. As seen previously, a small volume of blood was absorbed to the outer surface of the foam but did not penetrate internally, consistent with its hydrophobic properties.<sup>7</sup> The maximum IAP was dose dependent, with larger doses of foam leading to higher IAP. The maximum IAP was 23 (9.3), 53 (19), and 99 mm Hg for the 100-mL, 120-mL, and 150-mL dose groups, respectively ( $p < 0.01$  relative to control for all groups), which decreased to near-baseline levels within approximately 10 minutes (Table 1). We observed a similar dose-dependent increase in peak airway pressure, which decreased within the same time frame (data not shown). Temperature changes were transient, but the maximum temperature was 41°C (1.1°C) in the 100-mL group and 41°C (6.3°C) in the 120-mL group ( $p = 0.91$  between groups). Lactate was similar between groups ( $p = 0.90$ ).

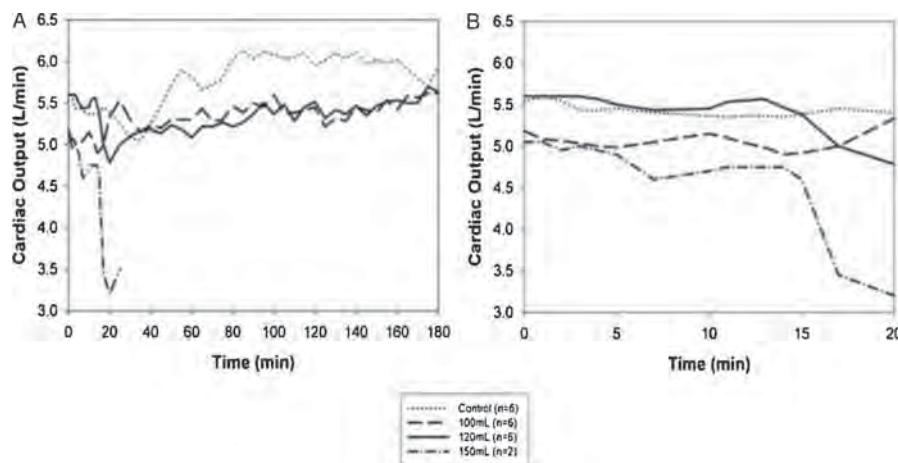
Foam explantation took less than 2 minutes in all animals. After explantation, no gross thermal injuries were noted. In all foam groups, we observed several focal echymotic

lesions in the small bowel and/or the large bowel (Fig. 2). Histology was consistent with local edema and mild pressure necrosis. Lesions were quantified and repaired by imbrication or resection. The number of lesions and the number of repairs were dose dependent (Fig. 3).

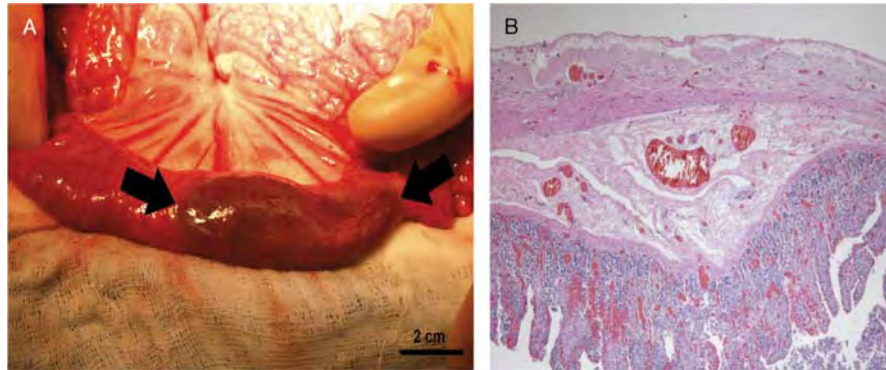
All animals in the 100-mL, 120-mL, and control groups survived 28 days. No complications were observed. Neurologic status was normal by modified swine veterinary coma score.<sup>16</sup> Elevated leukocyte counts were not observed. In all groups, blood laboratory assays did not demonstrate any end-organ failure and were similar in the foam groups relative to the control group (Fig. 4). Weight gain was not different between the 100-mL and control groups (12 [3.2] kg vs. 13 [3.6] kg, respectively); the 120-mL group did not gain as much weight (6.6 [4.9] kg,  $p < 0.05$  vs. controls). Liver enzymes were mildly elevated initially but were no different from that of controls (Fig. 4).

All animals were euthanized according to schedule. At necropsy, the extent of adhesions was graded using a semi-quantitative scale and was found to be no different between groups (1.0 [0], 1.3 [0.44], and 1.3 [0.50] for control, 100-mL, and 120-mL groups, respectively), as was the severity of the adhesions (1.2 [0.32], 1.2 [0.45], and 1.2 [0.22] for control, 100-mL, and 120-mL groups, respectively). Adhesions were largely limited to the midline laparotomy closure. Remnant foam particles were observed but were not specifically associated with adhesiogenesis.

Histologic sampling of the abdominal organs did not reveal any evidence of adverse toxicology, pathology, or embolization of remnants. The liver, the spleen, the bladder, the small bowel, the spiral colon, and the peritoneum of all groups were similar to those of the control group (data not shown). Of note, no tissues had any evidence of thermal-related coagulative necrosis or sequelae of healed necrosis. Foam particles were found on serosal surfaces and were encapsulated by a fibrocellular reaction, and edema was not associated with granulomatous tissue. The inflammatory response to foam particles was similar to that of biodegradable suture (Fig. 5).



**Figure 1.** Cardiac output as a function of time. A, All data. B, Inset, 20 minutes. Polymer was deployed at 10 minutes. Cardiac output is delayed by approximately 5 minutes because of data integration. Curves represent the mean of all samples in a group; error bars were omitted for clarity.



**Figure 2.** Small bowel damage resulting from foam deployment. Gross pathology (A) and histopathology (B).

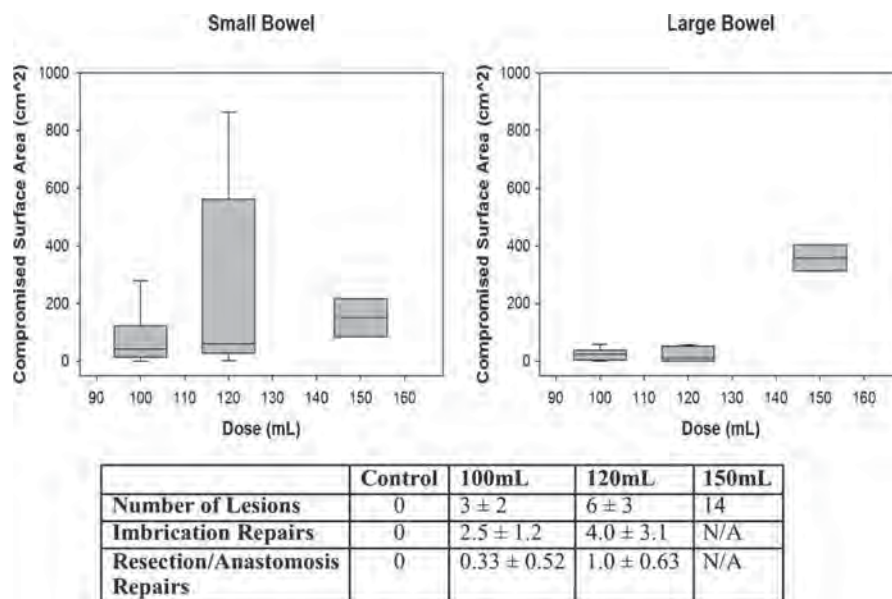
In a separate series of tests, foam biocompatibility was evaluated according to ISO-10993 standards for the evaluation of medical device biocompatibility. The foam samples satisfied the requirements for all ISO-10993 assays. The material was not found to be cytotoxic, sensitizing, irritating, acutely toxic, pyrogenic, and genotoxic. The foam did not have an unacceptable local inflammatory response following intramuscular implantation for 30 days.

### DISCUSSION

This investigation demonstrates that 28-day survival and complete recovery are possible after intraperitoneal treatment with this hemostatic foam. Of particular importance is the absence of abdominal compartment syndrome or end-organ dysfunction with 100-mL and 120-mL doses. Although transient intra-abdominal hypertension is demonstrated, the magnitude and duration of intra-abdominal hypertension with the 100-mL

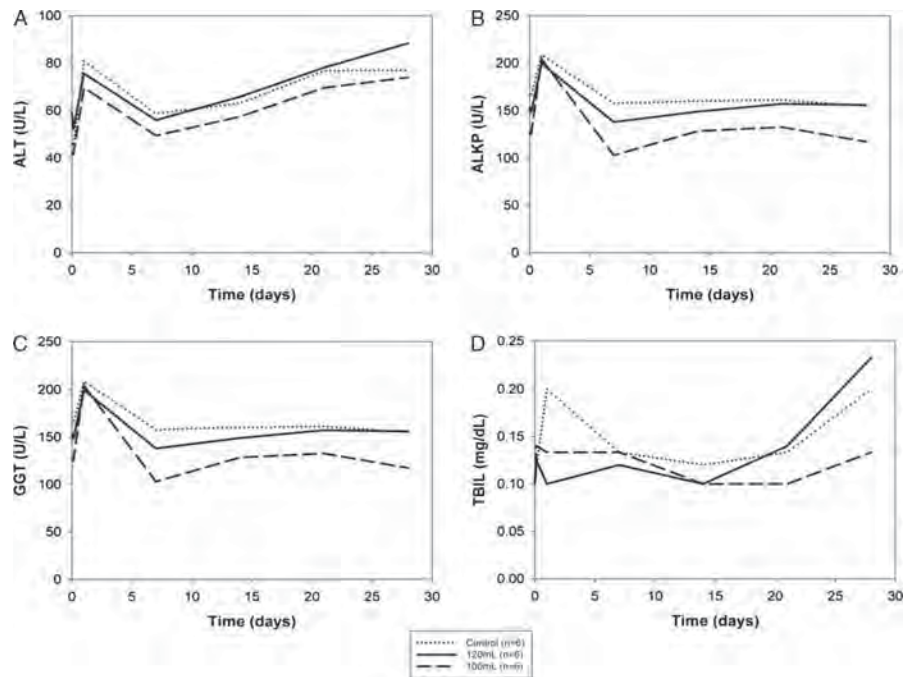
and 120-mL doses did not cause abdominal compartment syndrome for the 3-hour foam residence duration tested. This finding is significant since 3 hours is much longer than the current mean evacuation time on the battlefield and in civilian trauma, allowing a safe, extended window of opportunity for evacuation to surgical care.

Focal necrosis of the bowel was observed in all groups and was associated with tissue directly compressed by the polymer. Bowel necrosis was not observed in areas not in direct contact with the foam material, suggesting that focal necrosis is a local event from direct pressure and contact and not from global, transient increased IAP. This finding suggests that bowel necrosis, in this case, is unlikely a result of compartment syndrome. Histologic findings were consistent with mild, localized pressure necrosis, and damaged surface area increased in a dose-dependent fashion. Notably, histology demonstrated that the damaged areas were not associated with thermal or chemical necrosis. The animals in the 120-mL group did not



**Figure 3.** Summary of bowel damage and repair. Compromised surface area was quantified in the small bowel (left box plot) and the large bowel (right box plot) as a function of dose. The number of lesions and the number of repairs are summarized by dose in the table below. N/A, not applicable.

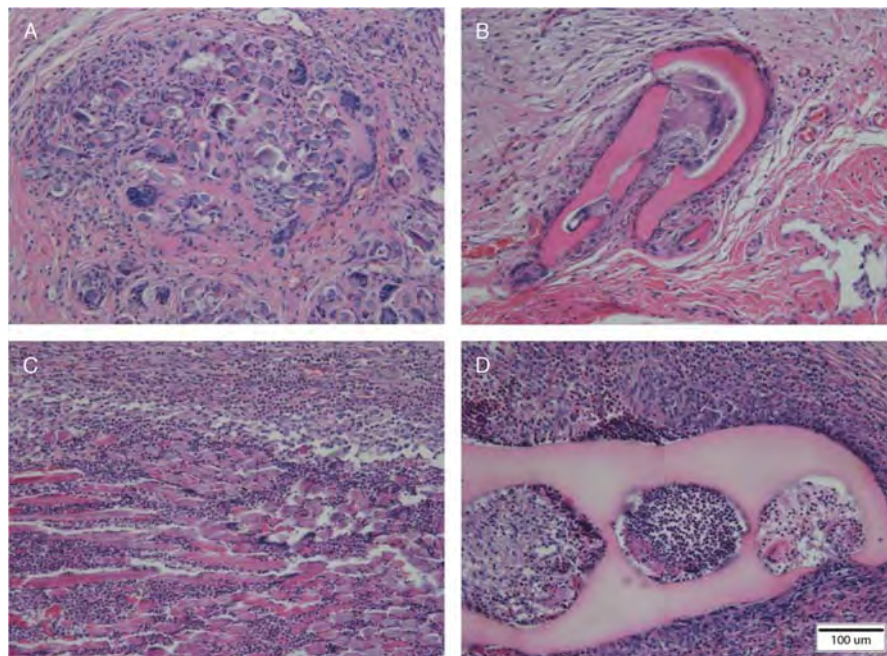




**Figure 4.** Serum enzyme levels and total bilirubin (TBIL) collected during the 28-day study period. All ALT (A), ALKP (B), GGT (C), and TBIL (D) values were found within reference ranges for swine. Curves represent the mean of all samples in a group; error bars were omitted for clarity. ALT, alanine transaminase; ALKP, alkaline phosphatase; GGT, gamma-glutamyl transferase.

gain as much weight as those in the 100-mL group or the control group. Although weight gain is a multifactorial endpoint, we attributed this finding primarily to the ileus, related to more bowel repairs and resections in the 120-mL group. These

lesions, if not repaired, would likely progress to full-thickness necrosis and perforation. Furthermore, on the basis of the expected trauma burden in military populations,<sup>17,18</sup> bowel injury is common, and many casualties will require bowel



**Figure 5.** Histology of degradable suture (left) compared with foam remnant particles (right). Remnants on the bladder (A and B) and the small bowel (C and D) were encapsulated by a thin fibrocellular capsule, and inflammatory response was similar to degradable suture.

surgery associated with their initial traumatic insult. In a survey of 3,442 Operation Iraqi Freedom patients, Vertrees et al.<sup>19</sup> noted that 34% of patients underwent primary bowel repair and 19% underwent resection and reanastomosis following injury. If the requirement for additional bowel surgery associated with foam use in swine translates to humans, then the risk-benefit analysis likely favors hemostasis and survival with required bowel repair over a prehospital death from exsanguination since a significant portion of these casualties will require bowel surgery anyway.

The 150-mL dose group was terminated early. This dose likely represents the upper limit (or past the limit) of the therapeutic window for this foam, and this result is consistent with our previous pilot work. We believe that the first, early death from the 150-mL dose may represent acute abdominal compartment syndrome. The second animal in the 150-mL group was euthanized after multifocal colon necrosis was noted upon foam explantation. There were multiple focal lesions in the colon, such that repair or segmental resection was not possible. Consequently, survival would have required colectomy, which we were not approved to perform. This may also be a representation of a combination of abdominal compartment syndrome and local pressure necrosis. Additional dose translation studies are required to ensure that these complications are not observed in humans. Besides the events described for the 150-mL group, we did not observe any clinical consequences of the in situ foam formation process. Additional studies are required to evaluate the biocompatibility of this in situ reaction.

Exothermic reactions of hemostatic agents, such as early-generation granular zeolite, have resulted in patient injury.<sup>20,21</sup> In this study, the reaction between liquid polyol and isocyanate resulted in a temperature increase of approximately 4°C at the peritoneal surface (baseline temperature was similar between all groups). This moderate increase was transient and returned to baseline levels within 30 minutes to 60 minutes. We did not observe any thermal damage acutely or chronically at 28 days. The duration and temperature exposure associated with foam deployment are not consistent with known exposure patterns resulting in cutaneous burns.<sup>22</sup>

Foam remnants were not adhesiogenic. Adhesions were localized to the midline incision, were generally mild in severity, and were no different from those in the controls. Retained foam particles were observed on the serosal surfaces and estimated at less than 100 mg in total mass. Mild-to-moderate inflammation around remnants was observed and characterized by a pathologist as similar to expected inflammation for an absorbable suture at 28 days.

Distal embolization of hemostatic agents has been identified as a significant safety risk with some devices, hemostatic powders, and clays. Kheirabadi et al.<sup>23</sup> noted that a smectite granule procoagulant WoundStat was made by TraumaCure (Bethesda, MD) could result in endothelial damage, enter systemic vasculature, and result in distal thrombosis of vital organs. In this study, no clinical or physiologic evidence of material embolization was observed.

Preformed samples of the foam material satisfied all requirements for biocompatibility assessment according to *ISO-10993: Biological Evaluation of Medical Devices*.<sup>15</sup> This

series of standard tests is designed to evaluate device safety as a supplement to the intended-use study described in this article. Data demonstrating that the material is not acutely toxic, cytotoxic, pyrogenic, and irritating confirm conclusions from the swine study. ISO-10993 testing further characterizes gaps that cannot be tested easily in large animals. We established that the material was not sensitizing and was not genotoxic in in vitro and in vivo models. This 28-day swine data, combined with the complete ISO-1099 toxicologic data, suggest a favorable biocompatibility profile.

There are several limitations to the current study. First, the splenic injury model resulted in only mild bleeding and not massive exsanguination. This model was selected intentionally to create mild uncontrolled hemorrhage while maintaining animal survival in the control group to 180 minutes and eliminating resuscitation/reperfusion injury and the need for blood transfusion since this would confound any conclusions regarding inflammatory impact of foam remnants. Second, the 150-mL group was aborted early, with clinical findings consistent with some prior exploratory work. The manner of these two deaths in the 150-mL group was sufficient enough to conclude that this dose was clearly unsafe, and additional work with that dose would be wasteful. Third, the animals were not randomized at the time of injury since foam manufacturing had to be planned weeks ahead of time and animals were scheduled similarly. Finally, the 28-day endpoint was selected for practical reasons, and because 28 days is considered a marker of survival in critically ill patients, 90-day studies may be required to confirm results from this study in the longer term.

In summary, this study supports a safe and favorable 28-day risk-benefit profile of intraperitoneal administration of hemostatic foam in swine for doses of 120 mL or less. Our hypothesis is not supported in the 150-mL group. Compartment syndrome is not appreciated at lower doses, bowel injuries are manageable, thermal injury is not appreciated, and remnant particles seem to be well tolerated. We conclude that this study, combined with the previous work on this foam, suggests that prehospital foam treatment of noncompressible hemorrhage has the potential to alter the current standard of care for exsanguinating patients. Ongoing work is required to evaluate longer-term safety and translate the swine dose for humans.

#### AUTHORSHIP

A.R., J.O.H., M.J.D., M.P.P., J.M., P.H., G.Z., R.B., M.H., D.D.Y., and P.J.F. contributed to data collection and interpretation. G.V. and M.A.D. contributed to data interpretation and analysis. U.S., D.R.K., A.R., and M.J.D. contributed to study conception, study design, data collection, and interpretation.

#### ACKNOWLEDGMENT

We thank Chris Murphy; Kyle Sims, Drs. Bijan Kheirabadi, Jill Sondeen, Mike Dubick, Peter Rhee, Martin Schreiber, John Holcomb, Ali Salim, and Hasan Alam, for their input into the guidance of this project. We thank Drs. William Wustenberg and Lucas Brennecke for their help interpreting liver enzyme and histopathology, respectively.

#### DISCLOSURE

This study was supported by DARPA and ARO contracts W911NF-10-C-0089 and W911NF-12-C-0066.

## REFERENCES

1. Eastridge BJ, Hardin M, Cantrell J, Oetjen-Gerdes I, Zubko T, Mallak C, Wade CA, Simmons J, Mace J, Mabry R, et al. Died of wounds on the battlefield: causation and implications for improving combat casualty care. *J Trauma*. 2011;71:S4–S8.
2. Eastridge BJ, Mabry RL, Seguin P, Cantrell J, Tops T, Uribe P, Mallett O, Zubko T, Oetjen-Gerdes L, Rasmussen TE, et al. Death on the battlefield (2001–2011): implications for the future of combat casualty care. *J Trauma Acute Care Surg*. 2012;73:S431–S437.
3. Holcomb J, Caruso J, McMullin N, Wade CE, Pearse L, Oetjen-Gerdes L, Champion HR, Lawnick M, Farr W, Rodriguez S, et al. Causes of death in US Special Operations Forces in the global war on terrorism: 2001–2004. *US Army Med Dep J*. 2007 Jan-Mar:24–37.
4. Kelly JF, Ritenour AE, McLaughlin DF, Bagg KA, Apodaca AN, Mallak CT, Pearse L, Lawnick MM, Champion HR, Wade CE, et al. Injury severity and causes of death from Operation Iraqi Freedom and Operation Enduring Freedom: 2003–2004 versus 2006. *J Trauma*. 2008;64:S21–S26 discussion S26–S27.
5. Committee on Trauma ACoS. *NTDB Version 2012*. Chicago, IL; 2013. Accessed May 7, 2013.
6. Kisat M, Morrison JJ, Hashmi ZG, Efron DT, Rasmussen TE, Haider AH. Epidemiology and outcomes of non-compressible torso hemorrhage. *J Surg Res*. 2013;184:414–421.
7. Duggan M, Rago A, Sharma U, Zugates G, Freyman T, Busold R, Caulkins J, Pham Q, Chang Y, Mejaddam A, et al. Self-expanding polyurethane polymer improves survival in a model of noncompressible massive abdominal hemorrhage. *J Trauma Acute Care Surg*. 2013;74:1462–1467.
8. Holcomb JB, McClain JM, Pusateri AE, Beall D, Macaitis JM, Harris RA, MacPhee MJ, Hess JR, et al. Fibrin sealant foam sprayed directly on liver injuries decreases blood loss in resuscitated rats. *J Trauma*. 2000;49:246–250.
9. Kheirabadi BS, Sieber J, Bukhari T, Rudnicka K, Murcin LA, Tuthill D. High-pressure fibrin sealant foam: an effective hemostatic agent for treating severe parenchymal hemorrhage. *J Surg Res*. 2008;144:145–150.
10. Peev MP, Rago A, Hwabejire JO, Duggan MJ, Beagle J, Marini J, Zugates G, Busold R, Freyman T, Velmahos GS, et al. Self-expanding foam for prehospital treatment of severe intra-abdominal hemorrhage: dose finding study. *J Trauma Acute Care Surg*. 2014;76(3):619–623 discussion 623–624.
11. King DR, Rago A, Marini J, Sharma U, Zugates G, Busold R, Helmick M, Hannett P, Beagle J, Peev M, et al. *Prehospital Battlefield Treatment of Massive, Lethal Non-Compressible Hemorrhage*. Military Health System Research Symposium (MHSRS). Fort Lauderdale, FL; 2012.
12. Duggan MJ, Mejaddam AY, Beagle J, Demoya MA, Velmahosa GC, Alam HB, Rago A, Zugates G, Busold R, Freyman T, et al. Development of a lethal, closed-abdomen grade V hepato-portal injury model in non-coagulopathic swine. *J Surg Res*. 2013;182:101–107.
13. Velmahos GC, Spaniolas K, Duggan M, Alam HB, Tabbara M, de Moya M, Vosburgh K, et al. Abdominal insufflation for control of bleeding after severe splenic injury. *J Trauma*. 2007;63(2):285–288 discussion 288–290.
14. Kutlay J, Ozer Y, Isik B, Kargici H. Comparative effectiveness of several agents for preventing postoperative adhesions. *World J Surg*. 2004;28(7):662–665.
15. ISO. *Biological Evaluation of Medical Devices*. ISO 10993. Geneva, Switzerland : ISO. 2009.
16. King DR, Cohn SM, Proctor KG. Changes in intracranial pressure, coagulation, and neurologic outcome after resuscitation from experimental traumatic brain injury with hetastarch. *Surgery*. 2004;136:355–363.
17. DePalma RG, Burris DG, Champion HR, Hodgson MJ. Blast injuries. *N Engl J Med*. 2005;352:1335–1342.
18. Owens BD, Kragh JF Jr, Wenke JC, Macaitis J, Wade CE, Holcomb JB. Combat wounds in operation Iraqi Freedom and Operation Enduring Freedom. *J Trauma*. 2008;64:295–299.
19. Vertrees A, Wakefield M, Pickett C, Greer L, Wilson A, Gillern S, Nelson J, Aydelotte J, Stojadinovic A, Shriver C, et al. Outcomes of primary repair and primary anastomosis in war-related colon injuries. *J Trauma*. 2009;66:1286–1291 discussion 1291–1283.
20. Rhee P, Brown C, Martin M, Salim A, Plurad D, Green D, Chambers L, Demetriades D, Velmahos G, Alam H, et al. QuikClot use in trauma for hemorrhage control: case series of 103 documented uses. *J Trauma*. 2008;64:1093–1099.
21. Wright JK, Kalns J, Wolf EA, Traweck F, Schwarz S, Loeffler CK, Snyder W, Yantis LD Jr, Eggers J, et al. Thermal injury resulting from application of a granular mineral hemostatic agent. *J Trauma*. 2004;57:224–230.
22. Moritz AR. Studies of thermal injury: III. The pathology and pathogenesis of cutaneous burns. An experimental study. *Am J Pathol*. 1947;23(6):915–941.
23. Kheirabadi BS, Mace JE, Terrazas IB, Fedyk CG, Estep JS, Dubick MA, Blackbourne LH, et al. Safety evaluation of new hemostatic agents, smectite granules, and kaolin-coated gauze in a vascular injury wound model in swine. *J Trauma*. 2000;68:269–278.