

AWARD NUMBER: W81XWH-14-1-0421

TITLE: Improving Viability and Functional Outcome After Whole Eye Transplantation

PRINCIPAL INVESTIGATOR: Dr. Kia Washington

CONTRACTING ORGANIZATION: University of Pittsburgh  
Pittsburgh, PA 15213

REPORT DATE: October 2015

TYPE OF REPORT: Annual

PREPARED FOR: U.S. Army Medical Research and Materiel Command  
Fort Detrick, Maryland 21702-5012

DISTRIBUTION STATEMENT: Approved for Public Release;  
Distribution Unlimited

The views, opinions and/or findings contained in this report are those of the author(s) and should not be construed as an official Department of the Army position, policy or decision unless so designated by other documentation.

REPORT DOCUMENTATION PAGE				Form Approved OMB No. 0704-0188	
Public reporting burden for this collection of information is estimated to average 1 hour per response, including the time for reviewing instructions, searching existing data sources, gathering and maintaining the data needed, and completing and reviewing this collection of information. Send comments regarding this burden estimate or any other aspect of this collection of information, including suggestions for reducing this burden to Department of Defense, Washington Headquarters Services, Directorate for Information Operations and Reports (0704-0188), 1215 Jefferson Davis Highway, Suite 1204, Arlington, VA 22202-4302. Respondents should be aware that notwithstanding any other provision of law, no person shall be subject to any penalty for failing to comply with a collection of information if it does not display a currently valid OMB control number. <b>PLEASE DO NOT RETURN YOUR FORM TO THE ABOVE ADDRESS.</b>					
1. REPORT DATE October 2015		2. REPORT TYPE Annual		3. DATES COVERED 15 Sep 2014 - 14 Sep 2015	
4. TITLE AND SUBTITLE  Improving Viability and Functional Outcome After Whole Eye Transplantation				5a. CONTRACT NUMBER	
				5b. GRANT NUMBER W81XWH-14-1-0421	
				5c. PROGRAM ELEMENT NUMBER	
6. AUTHOR(S) Kia M. Washington; Hongkun Wang; Maxine Miller; Gadi Wollstein; Bo Wang; Kevin Chan; Yang Li; Chiaki Komatsu; Joel S. Schuman  E-Mail: washingtonkm@upmc.edu				5d. PROJECT NUMBER	
				5e. TASK NUMBER	
				5f. WORK UNIT NUMBER	
7. PERFORMING ORGANIZATION NAME(S) AND ADDRESS(ES)  University of Pittsburgh Department of Plastic Surgery E1500 Biomedical Science Tower 200 Lothrop Street Pittsburgh, PA 15213				8. PERFORMING ORGANIZATION REPORT NUMBER	
9. SPONSORING / MONITORING AGENCY NAME(S) AND ADDRESS(ES)  U.S. Army Medical Research and Materiel Command Fort Detrick, Maryland 21702-5012					
12. DISTRIBUTION / AVAILABILITY STATEMENT  Approved for Public Release; Distribution Unlimited				10. SPONSOR/MONITOR'S ACRONYM(S)	
13. SUPPLEMENTARY NOTES				11. SPONSOR/MONITOR'S REPORT NUMBER(S)	
14. ABSTRACT BACKGROUND: Approximately 37 million people throughout the world suffer from blindness with up to 20% having only visual light perception or less. The permanent nature of vision loss is largely due to the inability of retinal ganglion cells to regenerate. Whole eye transplantation (WET) gives the opportunity to provide viable retinal ganglion cells and the entire optical system to recipients with vision loss and irreversible injury to the eye. We have recently established a whole eye transplant model in the rat. The purpose of our study is to evaluate viability, structural integrity, and functional outcome after whole eye transplantation. METHODS: All syngeneic whole eye transplants were performed. Slit lamp examination, OCT imaging of the cornea, and intraocular pressure evaluation were performed. RESULTS: All eyes experienced certain degrees of corneal neovascularization. OCT imaging confirmed transparency of the cornea and lens, preservation of the structural layers of the retina, and blood flow throughout the eye. Intraocular pressure in the transplanted eyes was within normal range. Histology confirmed neovascularization of the cornea as well as preservation of the structural integrity of the retina, with the exception of thinning of the retinal ganglion cell layer. CONCLUSION: We have established a viable orthotopic model for vascularized whole eye transplantation in the rat with relative maintenance of structural integrity and ocular physiology.					
15. SUBJECT TERMS whole eye transplantation (WET; Vascularized composite allotransplantation (VCA); Composite tissue allotransplantation (CTA); face transplant; animal model; optical coherence tomography (OCT; magnetic resonance imaging (MRI; vision loss; optic nerve; retina; aqueous humor dynamics; ocular tissue permeability					
16. SECURITY CLASSIFICATION OF:			17. LIMITATION OF ABSTRACT	18. NUMBER OF PAGES	19a. NAME OF RESPONSIBLE PERSON
a. REPORT Unclassified	b. ABSTRACT Unclassified	c. THIS PAGE Unclassified			USAMRMC
			Unclassified		19b. TELEPHONE NUMBER (include area code)

## Table of Contents

	<u>Page</u>
1. Introduction.....	4
2. Keywords.....	4
3. Accomplishments.....	4
4. Impact.....	18
5. Changes/Problems.....	19
6. Products.....	20
7. Participants & Other Collaborating Organizations.....	25
8. Special Reporting Requirements.....	26
9. Appendices.....	26

## 1. INTRODUCTION:

Approximately 39 million people worldwide suffer from blindness. Ocular trauma is second only to cataracts in major causes of visual impairment in the US, with permanent vision loss in over 1 million civilians per year. Combat ocular trauma is severe and ranges from perforations to open globe ruptures. Ocular trauma has a poor prognosis despite the best available interventions, which results in a decline in quality of life and ability to return to the workforce for patients and presents challenges to the medical and military communities. The poor prognosis of ocular trauma or disease results from irreversible damage to the optic nerve. The difficulty with recovery is due to inability of retinal ganglion cells, the cells whose axons comprise the optic nerve, to regain function after traumatic or ischemic injury. Whole eye transplantation is the holy grail of vision restoration, regardless of the underlying etiology, as it offers the opportunity to provide viable retinal ganglion cells and an entire optical system to recipients with irreversible blindness. We have established the first vascularized orthotopic whole eye transplant model in the rat, which gives the unprecedented ability to forward the field of eye transplantation with basic science research. Our goal is to perform a comprehensive approach to whole eye transplantation through exploring viability, immune response, and optic nerve regeneration after whole eye transplantation.

## 2. KEYWORDS:

whole eye transplantation (WET); Vascularized composite allotransplantation (VCA); Composite tissue allotransplantation (CTA); face transplant; animal model; optical coherence tomography (OCT); magnetic resonance imaging (MRI); vision loss; optic nerve; retina; aqueous humor dynamics; ocular tissue permeability; total human eye allotransplantation.

## 3. ACCOMPLISHMENTS:

### What were the major goals of the project?

Aim 1: To evaluate the viability, structural integrity, and functional properties after whole eye transplantation in a rat model.

Aim 2: To evaluate optic nerve function in the whole eye transplant (WET) model after application of optic nerve directed fetal optic nerve derived Extracellular Matrix nerve wrap therapy.

Aim 3: To evaluate the immune response after whole eye allotransplantation.

### What was accomplished under these goals?

#### Quarter 1

### 3. Major Activities:

- a. Obtained ACURO approval December 8, 2014
- b. Performed syngeneic whole eye transplants in the rat
- c. Started fundoscopic examination of whole eye transplants for evaluation of structural integrity
- d. Started transplant viability analyses with Optical Coherence Tomography

### 4. Specific Objectives:

- a. Task 1.1: Syngeneic transplants are performed
- b. Task 1.2: Fundoscopic examination of whole eye transplants for evaluation of structural integrity post operative days 10,30,90,120
- c. Task 1.3: Optical Coherence Tomography (OCT) for evaluation of viability and retinal cell ganglion survival post operative days 10,30,90,120

## 5. Significant results:

### a. Syngeneic transplants

#### *Whole eye transplant is established in a rodent model*

We first performed 10 syngeneic transplants in twenty 8-10 week old Lewis rats (RT1<sup>l</sup>). The donor graft consisted of the whole eye and optic nerve including hemi-facial skin and the ear. The pedicles were the common carotid artery and the external jugular vein. The recipient was prepared by removing the hemi-facial skin and globe, and cutting the optic nerve at the base of the globe. The graft was transplanted to the recipient rat. The optic nerve was sutured with 11-0 nylon suture with interrupted stitches. The vascular pedicles of the common carotid artery and the external jugular vein were sutured together with 10-0 nylon suture. The graft was then sutured into place with 5-0 chromic absorbable suture. (figure 1)

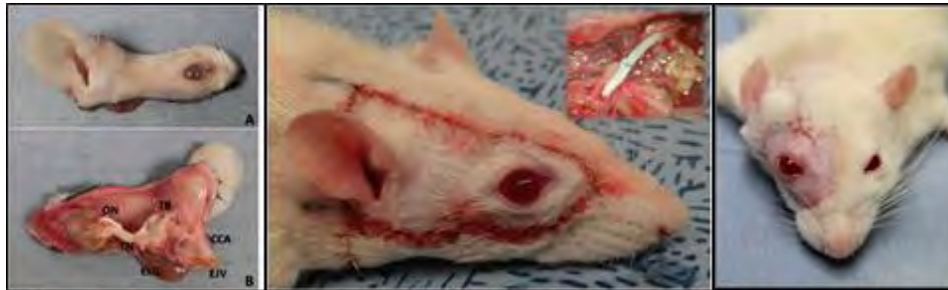

Figure 1. A. Whole eye transplant donor graft. B. (ON: Optic Nerve; TB: Temporal Bone; TN: Trigeminal Nerve; ELG: External Lacrimal Gland; CCA: Common Carotid Artery; EJV: External Jugular Vein.) C. Graft insetting with optic nerve apposition.

Eight out of 10 animals survived the transplantation process. One rat died from respiratory failure 2 hours after surgery and one rat died from post-operative bleeding on postoperative day one. Graft survival rate averaged 80%. Ischemia time averaged 1.96 hours. The average donor surgery time was 1.03 hours. The average recipient surgery time was 2.72 hours. Average weight reduction at post-operative day 7 was 21.3%. Complications included post-operative bleeding and respiratory failure.

Syngeneic Transplant Results	
Rat survival rate	80%
Graft survival rate	80%
Average Ischemia time	1.96 hours
Average donor time	1.03 hours
Average recipient time	2.72 hours
Longest surviving transplant	22 days
Average weight reduction POD 7	21.3%
Complications	Post-operative bleeding; respiratory failure

### b. Fundoscopic examination

**Fundoscopic examination was performed at post-operative day 10 in the transplants to evaluate viability and structural integrity.** Slit lamp examination was used to assess the eyelids, conjunctiva, cornea, anterior chamber, iris, lens and fundus. All rats examined under slit lamp had a vascularly intact transplant with a patent vascular network. There was mild chemosis and hemorrhage in the conjunctiva, mild paralimbal injections, mostly transparent cornea with some degree of peripheral neovascularization, mild to moderate cataracts of the lens, and red reflex elicited on all fundus exams. These ocular findings improved or remained the same during the follow up period. (figure 2)

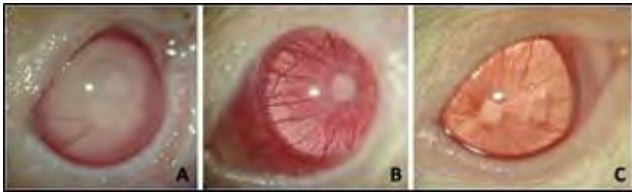

Fig. 2. Ocular blood supply. A: Eyeball in transplant graft after heparin perfusion; B: Eyeball immediately after transplantation and vascular anastomoses; C: Normal eyeball

### c. Optical Coherence Tomography

An SD-OCT device (Bioptigen Inc, Research Triangle Park, NC) was used to image a 2.5mm x 2.5mm x 2mm (512 x 512 x 1024 samplings) volume centered on the cornea, lens and Optic nerve head (ONH). The SD-OCT device had a wide-bandwidth light source centered on 870nm, which results in a theoretical axial resolution of 1.3 $\mu$ m. When possible, Doppler imaging was performed to assess blood flow in the eye. Doppler OCT was performed in a 2.5mm x 2.5mm x 2mm (700 x 20 x 1024 samplings) region. Eight Doppler frames were acquired with an acquisition rate of 28 kHz, resulting in a Nyquist limit of 4.62 mm/s normal to the scanning beam.

OCT imaging demonstrated the structural integrity of the cornea, albeit with evidence of neo-vascularization. **(Fig. 3)** The structural integrity of the retinal layers was maintained. **(Fig. 4)** There was thinning of the retina, especially the anterior hyperreflective layer. Blood flow was observed in the retina, as well as the optic nerve head of the transplanted eye. **(Fig. 5)** Aliasing, and indication of turbulent/high blood flow, flow too high to be detected, noted for blood flow exceeding 4.62 mm/s normal to the scanning beam, was evident in all 6 surviving subjects.

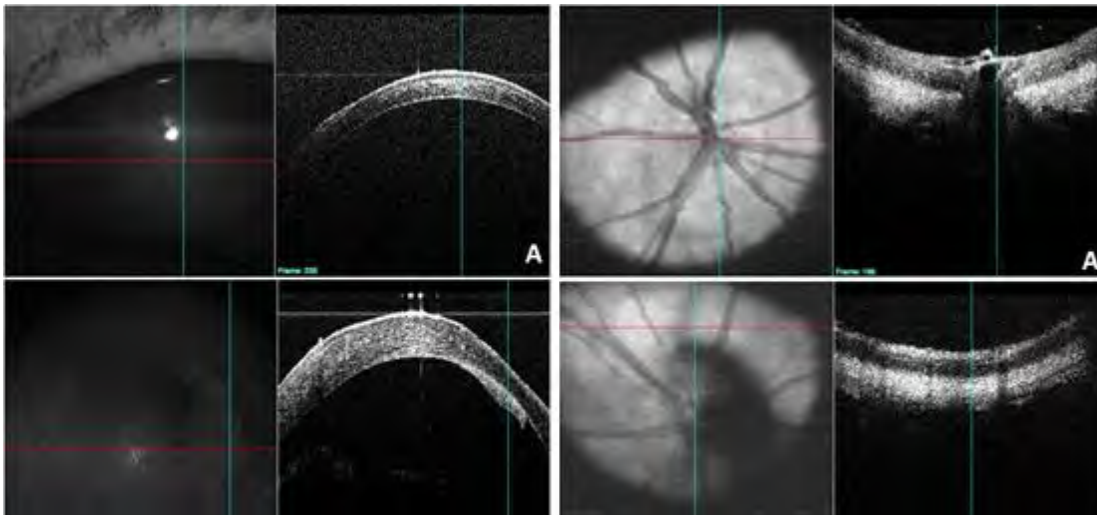


Fig. 3. Cornea with OCT. A: Control cornea; B: Transplanted cornea POD 7.

Fig. 4. Fundus vascularization with OCT. A: Control fundus; B: Transplanted fundus POD 7.

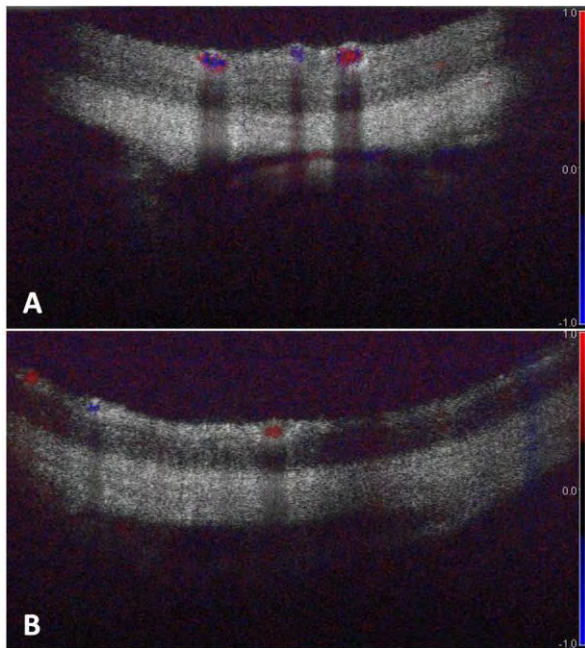


Fig. 5. Retina vascularization with Doppler. A: Control retina; B: Transplanted retina.

#### d. Other Achievements

##### Intraocular pressure analysis of transplants:

Intraocular pressures of the uninjured left eye and transplanted right eye were  $15.9 \pm 3.1$  mmHg and  $16.5 \pm 3.2$  mmHg respectively at 3 weeks post transplantation in 3 transplanted rats.

## Quarter 2

### 1. Major Activities:

- a. Performed additional syngeneic whole eye transplants in the rat
- b. Continued fundoscopic examination of whole eye transplants for evaluation of structural integrity
- c. Continued transplant viability analyses with Optical Coherence Tomography
- d. Performed electroretinogram analyses of transplants
- e. Preparation of ECM derived nerve wraps

### 2. Specific Objectives:

- a. Task 1.1: Syngeneic transplants are performed
- b. Task 1.2: Fundoscopic examination of whole eye transplants for evaluation of structural integrity
- c. Task 1.3: Optical Coherence Tomography (OCT) for evaluation of viability and retinal cell ganglion survival
- d. Task 1.4: Electroretinogram analysis is performed on transplants to assess optic nerve regeneration
- e. Task 1.5: Further electrophysiological analysis is performed on transplants that elicit a response in ERG
- f. Task 2.1: Preparation of ECM optic nerve wraps



### 3. Significant results:

#### a. Syngeneic transplants

##### *Whole eye transplant is established in a rodent model*

We performed 20 syngeneic transplants in twenty 8-10 week old Lewis rats (RT1<sup>l</sup>). The donor graft consisted of the whole eye and optic nerve including hemi-facial skin and the ear. The pedicles were the common carotid artery and the external jugular vein. The recipient was prepared by removing the hemi-facial skin and globe, and cutting the optic nerve at the base of the globe. The graft was transplanted to the recipient rat. The optic nerve was sutured with 11-0 nylon suture with interrupted stitches. The vascular pedicles of the common carotid artery and the external jugular vein were sutured together with 10-0 nylon suture. The graft was then sutured into place with 5-0 chromic absorbable suture. (figure 1)

16 out of 20 animals survived the transplantation process. Graft survival rate averaged 86.7%. Ischemia time averaged 1.98 hours. The average donor surgery time was 1.15 hours. The average recipient surgery time was 2.8 hours. Average weight reduction at post-operative day 7 was 22.1%. Complications included post-operative bleeding and respiratory failure. The oldest transplant to date is 98 days old. (Figure 1)

Figure 1. Syngeneic transplant results.

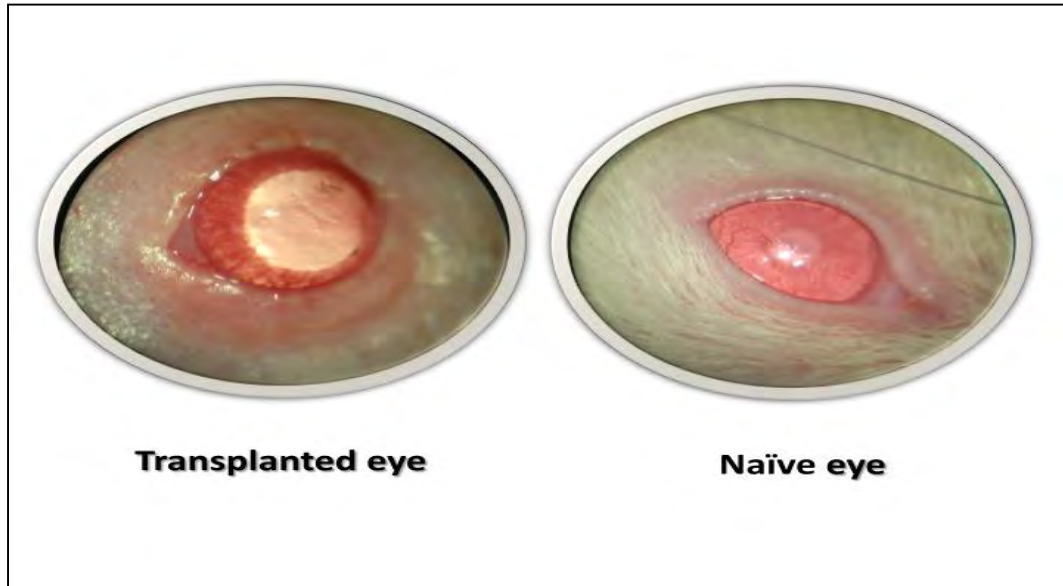
Syngeneic Transplant Results	
Rat Survival Rate	80% (16/20)
Graft Survival Rate	86.7% (13/15)
Average Ischemic Time	1.98 hours
Average Donor Time	1.15 hours
Average Recipient Time	2.8 hours
Longest Surviving Transplant	98 days
Average Weight Reduction POD 7	22.1%
Complications	Post-operative bleeding; respiratory failure



## **b. Fundoscopic examination**

**Fundoscopy examination was performed at post-operative day 30 and 60 in the transplants to evaluate viability and structural integrity.** Slit lamp examination was used to assess the eyelids, conjunctiva, cornea, anterior chamber, iris, lens and fundus. All rats examined under slit lamp had a vascularly intact transplant with a patent vascular network. There was mild chemosis and hemorrhage in the conjunctiva, mild paralimbal injections, mostly transparent cornea with some degree of peripheral neovascularization, mild to moderate cataracts of the lens, and red reflex elicited on all fundus exams. These ocular findings improved or remained the same during the follow up period at 30 and 60 days. (Figure 2)

Figure 2: Transplanted eye (left) and contralateral eye (right) 1 week after transplantation.



## **c. Optical Coherence Tomography**

An SD-OCT device (Bioptigen Inc, Research Triangle Park, NC) was used to image a 2.5mm x 2.5mm x 2mm (512 x 512 x 1024 samplings) volume centered on the cornea, lens and Optic nerve head (ONH). The SD-OCT device had a wide-bandwidth light source centered on 870nm, which results in a theoretical axial resolution of 1.3 $\mu$ m. When possible, Doppler imaging was performed to assess blood flow in the eye. Doppler OCT was performed in a 2.5mm x 2.5mm x 2mm (700 x 20 x 1024 samplings) region. Eight Doppler frames were acquired with an acquisition rate of 28 kHz, resulting in a Nyquist limit of 4.62 mm/s normal to the scanning beam.

OCT imaging was performed sequentially on the same animals to assess for maintenance of structural integrity over time. We found that on OCT examination there appeared to be maintenance of structural integrity over time in the lens, cornea, and retina. There was also maintenance of blood flow in the retina. (Figure 3)

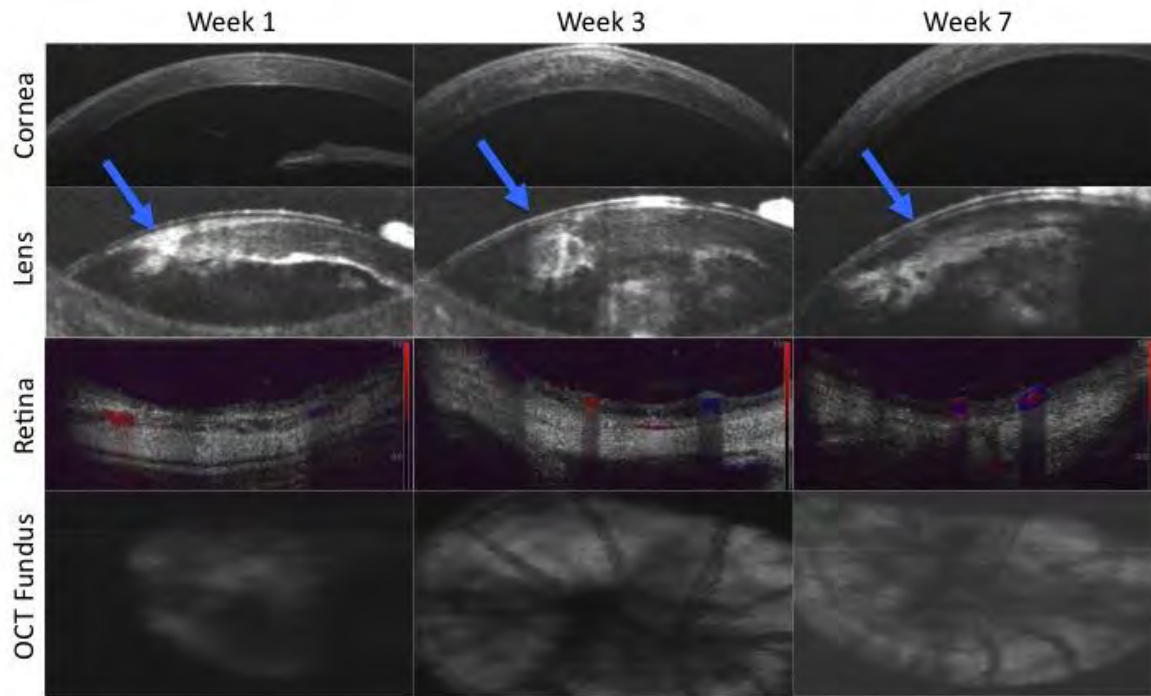


Figure 3. OCT evaluation of the cornea, lens, retina, and optic nerve head was performed on the same animal at week 1, 3, and 7 to evaluate the maintenance of structural integrity over time. The structures appeared to maintain their integrity over time. Note the opacities in the lens (blue arrow). These are thought to be due to the ischemia or ischemia/reperfusion injury. The opacities appear to improve by week 7. There is evidence of blood flow in the retina at week 1, 3, and 7.

#### **d. Electroretinogram**

Electroretinogram, is a test in which the electrical potentials generated by the retina are measured when the retina is stimulated by light. Rats underwent electroretinogram evaluation. Rats had overnight dark adaptation in a black box housed in the animal facility. An Espion E3 Electroretinography system (Diagnosys LLC) was integrated with a Dell PC equipped with a fast DSP microprocessor that controls and synchronized data acquisition and stimulator timing. A rodent lab cradle with heated platform allowed for ERG measurements in rats. Rats were prepared under a dim red light in a light-sealed room. Rats were anesthetized with Nembutal. Rats were placed on a heated platform to maintain the body temperature at 37 degrees Celsius. The recording electrodes, which are made of two 3-mm gold wire loops (Diagnosys) were placed to gently contact the corneal surface of eyes pre-coated with a 2.5% hydroxypropyl-methylcellulose solution (Gonak, Akorn). A subdermal needle electrode (Viasys Healthcare, Chicago, IL) between the ears served as a common reference while the other subdermal needle electrode was inserted at the base of the left leg to act as a ground. Retinal responses were recorded simultaneously from both eyes. Light stimuli was delivered via a Ganzfeld. Different stimulus strengths were used.

Preliminary data from functional evaluation by electroretinogram (ERG) showed a decrease in optic nerve and retinal ganglion cell function after transplantation. It showed no response to light in the transplanted eyes in comparison to control eyes. (Figure 4) Based on these results and in agreement with previous studies, transected RGCs in our WET model fail to regenerate functional connections. These results are expected given the inability of RGCs to withstand trauma. Thus, in specific aim 2 we are planning to implement therapy through ECM nerve wrap technology to induce optic nerve regeneration.

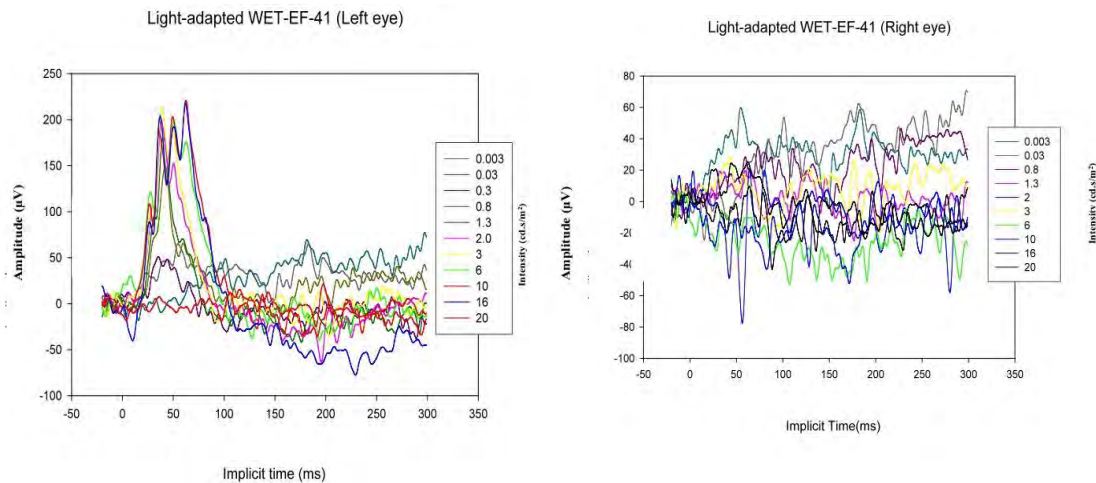


Figure 4: ERG of transplanted eye (right) shows no organized electrical response in the retina in comparison to a normal response in the naïve eye (left)

### e. Preparation of Extracellular Matrix (ECM) nerve wraps

ECM technology uses ECM bioscaffolds that are derived by decellularizing healthy tissues or organs. ECM bioscaffolds have been used to reduce scarring and to promote tissue reconstruction in numerous tissues and organs, in part, by modulating the innate immune response towards an M2 pro-repair phenotype. Previous studies comparing ECM bioscaffolds from different age and tissue sources showed ECMs derived from younger, homologous tissues are generally more efficacious than ECMs derived from non-homologous tissues. Therefore in collaboration with the laboratory of Michael Steketee, we will be implementing ECM bioscaffolds, derived from fetal porcine brain and applying them to the optic nerve of our transplants. We have done preliminary studies to prepare the fetal ECM wraps and have compared the regeneration in a peripheral nerve model with immunohistochemical staining.

*Biohybrid nerve wrap preparation.* ECM will be prepared by decellularizing porcine optic nerve, in a novel decellularization chamber designed for delicate tissues. In brief, the tissues will be subjected to a series of decellularization agents without agitation to harvest the ECM. The decellularization process consists of a series of non-agitated baths: distilled, deionized H<sub>2</sub>O, 3% triton-X 100, 3M NaCl, and distilled, deionized H<sub>2</sub>O (30 minutes per wash). This procedure is repeated 2-4 times followed by 100 kU/mL DNase and 0.1% peracetic acid in 4.0% ethanol (120 minutes) washes followed by 15 min washes with PBS, deionized water, PBS, and deionized water. All ECMs will be lyophilized and stored dry until digestion and solubilization. Digestion and solubilization is accomplished by incubating dried and powdered (400-1000µm particle size) ECM scaffolds in 1.0 mg/ml pepsin in 0.01 N HCl for 48-72 hours until a viscous solution has formed. The viscous solution is then electrosprayed with poly (lactic-co-glycolic) acid PLGA.

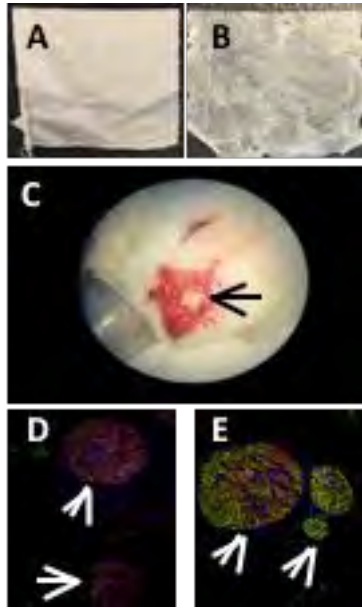


Figure 4. A. Adult ECM wrap. B. Fetal ECM wrap. C. Trigeminal nerve wrapped with fetal ECM wrap in rat (arrow). D. Controls show little axon regeneration (green) compared to E. fetal ECM wraps, which show dramatic regeneration. Unpublished data: Washington and Steketee labs.

**f. Other achievements:**

none

### **Quarter 3**

**1. Major Activities:**

- a. Performed additional syngeneic whole eye transplants in the rat
- b. Continued fundoscopic examination of whole eye transplants for evaluation of structural integrity
- c. Continued transplant viability analyses with Optical Coherence Tomography
- d. Performed electroretinogram analyses of transplants
- e. Preparation of ECM derived nerve wraps

**2. Specific Objectives:**

- a. Task 1.1: Syngeneic transplants are performed
- b. Task 1.2: Fundoscopic examination of whole eye transplants for evaluation of structural integrity
- c. Task 1.3: Optical Coherence Tomography (OCT) for evaluation of viability and retinal cell ganglion survival
- d. Task 1.4: Electroretinogram analysis is performed on transplants to assess optic nerve regeneration
- e. Task 1.5: Further electrophysiological analysis is performed on transplants that elicit a response in ERG
- f. Task 2.1: Preparation of ECM optic nerve wraps
- g. Task 2.1. Preparation of fetal optic nerve derived ECM nerve wraps
- h. Task 2.2. Syngeneic transplants are performed with ECM nerve wraps around the optic nerve

- i. Task 2.3. Optical Coherence Tomography (OCT) of WET with ECM nerve wraps for evaluation of viability and retinal ganglion cell survival
- j. Task 2.4 Electroretinogram analysis is performed on transplants to assess optic nerve regeneration
- k. Task 2.5 Further electrophysiological analysis is performed on WET that elicit a response on ERG
- l. Task 2.6 Histological preparation and assessment of WET and optic nerve
- m. Task 2.7. Data archiving, collation, analyses
- n. Task 3.1. Allogeneic Whole eye transplants are performed (n=20) (animals=40)

### 3. Significant results:

#### a. Histological Analysis:

Histological staining of transplanted eyes and the contralateral naïve eye were performed after sacrifice of rats one month after transplantation. The transplant of the cornea appears to have maintained structural integrity with the exception of neovascularization. (Figure 1)

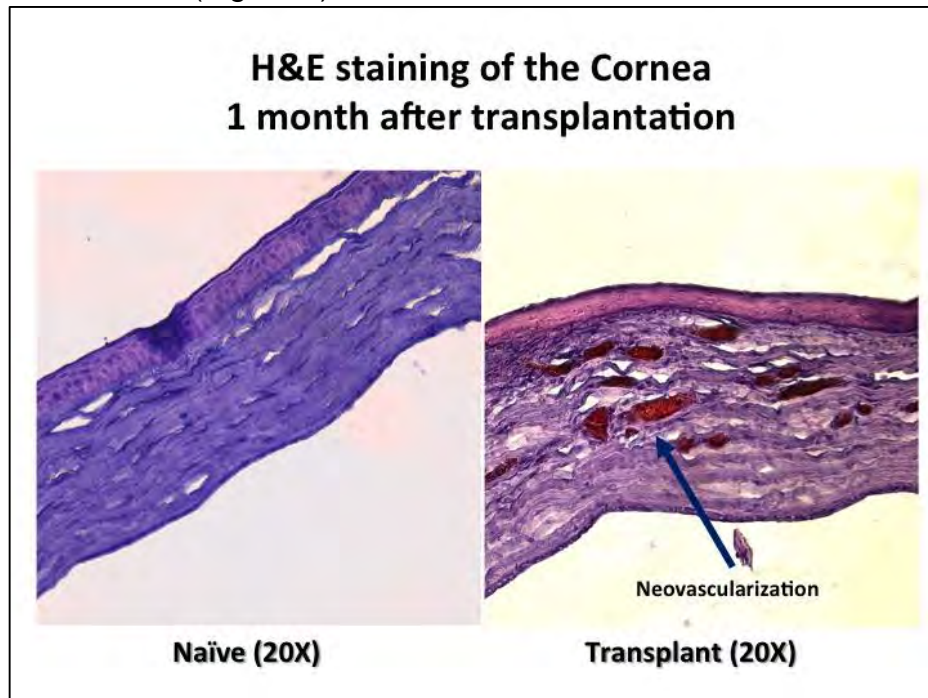


Figure 1: H&E staining of the cornea (20X) 1 month after transplantation shows neovascularization in the transplanted cornea.



Histological staining of transplanted eyes and the contralateral naïve eye were performed after sacrifice of rats one month after transplantation. The transplant of the retina appears to have maintained relative structural integrity with the exception of thinning of the nerve fiber layer. (Figure 2)

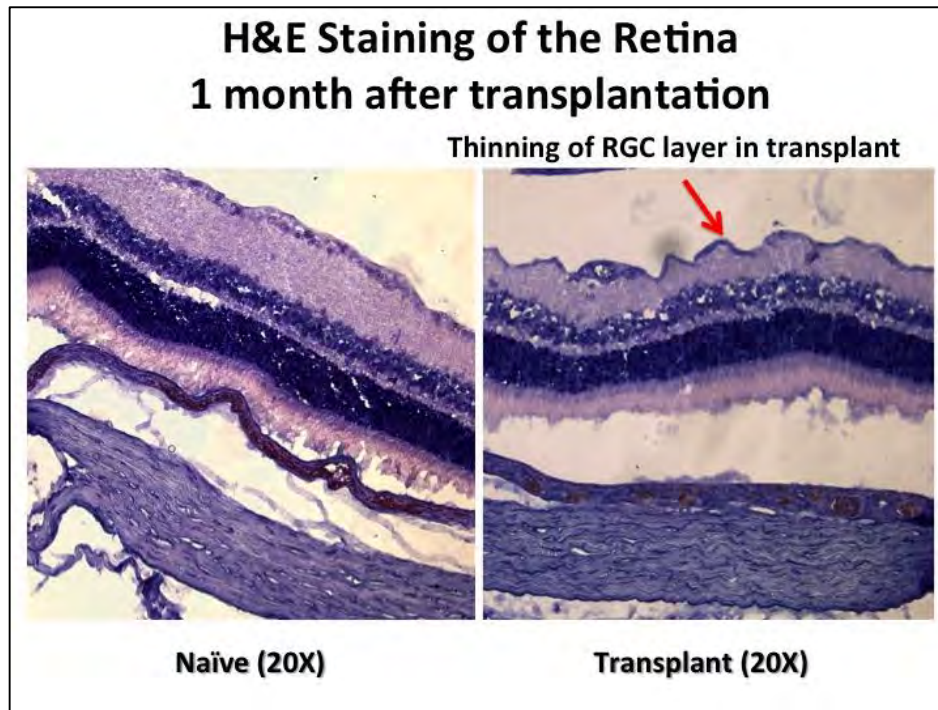


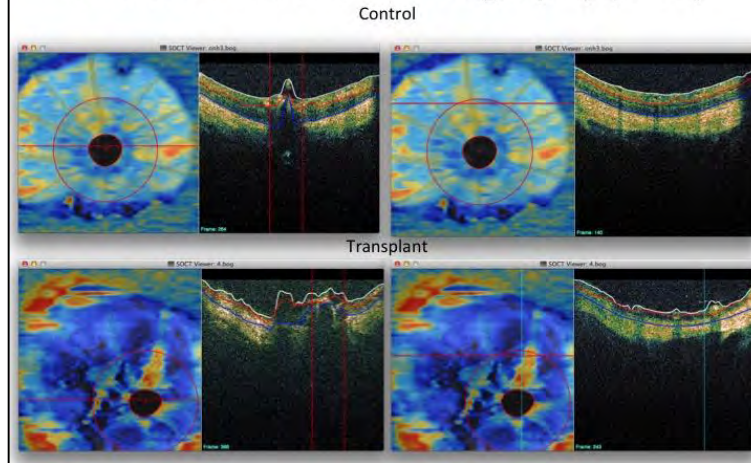
Figure 2: Thinning of the nerve fiber layer and lack of retinal ganglion cells is displayed in the retina of transplants one month after transplantation.

#### **b. Retinal Thickness quantification with OCT**

An SD-OCT device (Bioptigen Inc, Research Triangle Park, NC) was used to image a 2.5mm x 2.5mm x 2mm (512 x 512 x 1024 samplings) volume centered on the cornea, lens and Optic nerve head (ONH). The SD-OCT device had a wide-bandwidth light source centered on 870nm, which results in a theoretical axial resolution of 1.3 $\mu$ m. When possible, Doppler imaging was performed to assess blood flow in the eye. Doppler OCT was performed in a 2.5mm x 2.5mm x 2mm (700 x 20 x 1024 samplings) region. Eight Doppler frames were acquired with an acquisition rate of 28 kHz, resulting in a Nyquist limit of 4.62 mm/s normal to the scanning beam.


Specialized software was used to quantify retinal thickness in the naïve and transplanted eye. Preliminary data shows comparable retinal thickness at 1 week after transplantation, but decreased thickness 3 and 7 weeks after transplantation respectively. This is likely due to the thinning of the nerve fiber layer that was present on histology. This is preliminary data, however, and more quantification is necessary to make this conclusion. (Figure 3)

## Retinal Thickness Comparison with Ocular Coherence Tomography (OCT)

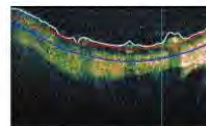


## Retinal Thickness

	Region	Week 1 (pixels)
Naive	Total	119.0
	Superior	119.3
	Inferior	118.6
	Superior left	122.9
Transplant	Superior left	106.4



	Region	Week 3 (pixels)	Week 7 (pixels)
Naive	Total	128.1	N/A
	Superior	123.7	N/A
	Inferior	132.4	N/A
Transplant	Superior	75.6	62.1



(1 pixel = 2 microns)

Figure 3: Retinal thickness was quantified in transplants and naïve eyes. At one week, retinal thickness in the transplant was comparable to the naïve eye. Retinal thickness decreased at 3 and 7 weeks respectively.

### c. Intraocular Pressure Quantification

IOP is one of the most significant clinical factors in ophthalmology for the correct function of the eye and its structures. Because the globe can expand marginally, intraocular pressure is a result of the balance between production and drainage of intraocular fluid. It is important that intraocular pressure is in a normal range of values, from 12-22, with an average of 16mm Hg. Naïve and transplanted eyes have comparable, intraocular pressures of  $15.9 \pm 3.1$  mmHg for the naïve eye and  $16.5 \pm 3.2$  mmHg for the transplanted eye. We see this at 3 weeks and 10 weeks after transplantation. (Figure 4)



## Intraocular pressure (IOP) measurements

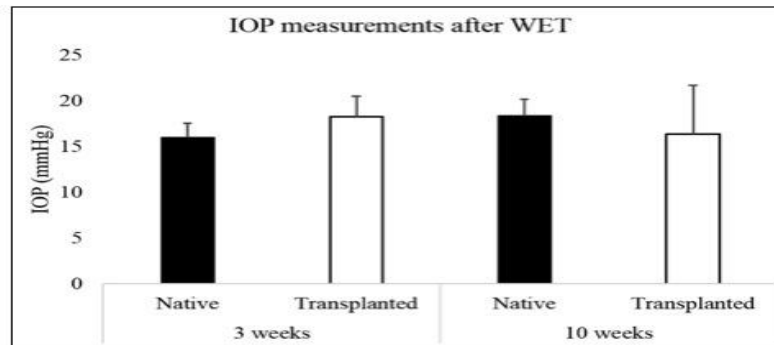


Figure 4: Naïve and transplanted eyes have comparable, intraocular pressures of  $15.9 \pm 3.1$  mmHg for the naïve eye and  $16.5 \pm 3.2$  mmHg for the transplanted eye. We see this at 3 weeks and 10 weeks after transplantation.

### d. Dark-adapted Electretinogram (ERG)

Rats were housed in a dark box overnight. Recording electrodes are placed to gently contact the cornea. Sub-dermal needle electrodes are placed between the ears and on the left leg. During a recording, eyes are exposed to standardized stimuli and the resulting signal is displayed showing the time course of the signal's amplitude/ voltage. The retinal responses are recorded simultaneously. Signals are measured in microvolts. Dark adapted ERG at 1 week after transplantation showed an organized response to electrical stimulus, while the retina in the transplants did not display a response.

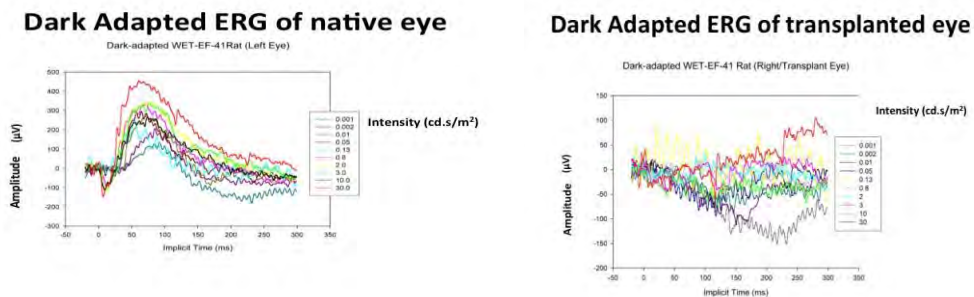


Figure 5: Dark adapted ERG of transplanted eye (right) shows no organized electrical response in the retina in comparison to a normal response in the naïve eye (left)

### e. Other achievements:

none

## **Quarter 4**

### **1. Major Activities:**

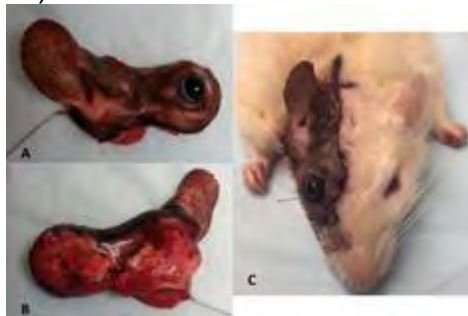- a. Performed additional syngeneic whole eye transplants in the rat
- b. Continued fundoscopic examination of whole eye transplants for evaluation of structural integrity
- c. Continued transplant viability analyses with Optical Coherence Tomography
- d. Performed electroretinogram analyses of transplants
- e. Preparation of ECM derived nerve wraps

### **2. Specific Objectives:**

- a. Task 1.1: Syngeneic transplants are performed
- b. Task 1.2: Fundoscopic examination of whole eye transplants for evaluation of structural integrity
- c. Task 1.3: Optical Coherence Tomography (OCT) for evaluation of viability and retinal cell ganglion survival
- d. Task 1.4: Electroretinogram analysis is performed on transplants to assess optic nerve regeneration
- e. Task 1.5: Further electrophysiological analysis is performed on transplants that elicit a response in ERG
- f. Task 2.1: Preparation of ECM optic nerve wraps
- g. Task 2.1. Preparation of fetal optic nerve derived ECM nerve wraps
- h. Task 2.2. Syngeneic transplants are performed with ECM nerve wraps around the optic nerve
- i. Task 2.3. Optical Coherence Tomography (OCT) of WET with ECM nerve wraps for evaluation of viability and retinal ganglion cell survival
- j. Task 2.4 Electroretinogram analysis is performed on transplants to assess optic nerve regeneration
- k. Task 2.5 Further electrophysiological analysis is performed on WET that elicit a response on ERG
- l. Task 2.6 Histological preparation and assessment of WET and optic nerve
- m. Task 2.7. Data archiving, collation, analyses
- n. Task 3.1. Allogeneic Whole eye transplants are performed and the procedure is optimized

### **3. Significant Results:**

Allogeneic transplant are performed. We proceeded to optimize the allogeneic transplant procedures. The donor and recipient procedures are the same as reported above, with the exception of using a Brown-Norway rat for the donor. (Figure 1)



**What opportunities for training and professional development has the project provided?**

The project has offered the opportunity for post-doctoral students to learn microsurgical expertise as well as learn the technical skills to perform Optical Coherence Tomography. In addition, the research has been presented in multiple forums by post-doctoral students and laboratory members. The PI has provided intensive training sessions and one-on-one mentorship on presentations skills and techniques. Thus many of the presentations resulted in awards on both the regional and national levels. Through mentorship, one of the Post-doctoral students, Maxine Miller was able to obtain a T-32 award. Part of this award involves instructional courses on the visual system. The PI has been an invited speaker at the McGowan Institute for Regenerative Medicine internal retreat and also the 5th Annual International Conference Vision Restoration: Regenerative Medicine in Ophthalmology. In the forums the PI has educated the participants about whole eye transplantation.

**What do you plan to do during the next reporting period to accomplish the goals and objectives?**

During the next reporting period, we will continue work on specific aim 2, by optimizing our ECM wrap as well as implanting them into syngeneic transplants. We will continue to optimize our allogeneic transplants and start to analyze the immunoresponse in the setting of allogeneic transplantation, according to the goals of specific aim 3. We will also start to define immune rejection in the setting of whole eye transplantation.

**4. IMPACT:****What was the impact on the development of the principal discipline(s) of the project?**

We have successfully created the world's first orthotopic vascularized whole eye transplant small animal model. Prior to our study, it was not known before whether or not the eye could be viable and maintain its physiologic dynamics after transplantation into its anatomic position. Our studies thus far have proven maintenance of gross morphology, retinal blood flow, aqueous humor dynamics, intraocular pressures and blood-ocular barriers in transplants. This new model gives the unprecedented ability to collect high quality data in carefully controlled experiments to bring WET towards clinical reality. The work has spearheaded a multi-disciplinary, multi-institutional effort on making eye transplantation a clinical solution for blindness.

**What was the impact on other disciplines?**

The work that we have completed extends across multiple disciplines. In the field of Ophthalmology we have shown the eye's ability to tolerate ischemia and ischemia reperfusion, while maintaining its structure, which can serve as information for further therapeutic treatments in the setting of eye trauma and disease. Also, our model can serve as a platform to study technology used to target optic nerve regeneration, as it gives unprecedented exposure to the optic nerve. Lastly, our model can serve as a platform to study local drug delivery in the eye. In addition our work has an impact in the fields of neuroscience and transplantation. We have shown that the retina does maintain some of its structural integrity after transplantation, and we are exploring the structure of the optic nerve. These findings will give insight into the ability to transplant

central nervous system tissue, which can have broad reaching implications for other central nervous system disease processes. With our model, we have the ability to study the brain's ability to reorganize and remodel after transplantation, which also gives insight into other disease processes involving the visual cortex and the sensory portions of the cortex in general.

**What was the impact on technology transfer?**

Nothing to report

**What was the impact on society beyond science and technology?**

Blindness in service members resulting from trauma and degenerative disease causes a significant decline in quality of life and ability to return to the workforce, and therefore presents challenges to the medical and military communities. For many of these patients, there are no treatments available to restore vision. Whole eye transplantation (WET) offers the opportunity to provide viable retinal ganglion cells and an entire optical system to those with irreversible blindness and with it the potential to restore vision. This project to restore form and function after vision loss through whole eye transplantation is revolutionary and has the potential to help service members with irreversible vision loss, and can also have broad reaching impact on civilian medicine.

**5. CHANGES/PROBLEMS:**

**Actual or anticipated problems or delays and actions or plans to resolve them**

**Quarter 1:**

ACURO approval was not obtained until December 8, 2014, thus our ability to collect data for functional analyses for the 30,90 and 120 day time points were delayed. This was resolved shortly after obtaining ACURO approval.

**Quarter 2:**

We are also still optimizing the fetal ECM nerve wraps so we have not yet implanted them in our transplants. We are continuing to optimize the wraps through looking at different in vitro release kinematics.

**Quarter 3:**

We are still perfecting the allogeneic transplants. Since the allogeneic transplants involve using different breeds of animals, we are optimizing the allogeneic transplants before we start doing the immunological studies.

**Quarter 4:**

We changed our rat supplier recently, as they were appearing weaker than they should after surgery. Since we changed suppliers, they have been faring better.

The last part of Specific Aim 1 is to perform electrophysiological analysis on animals that have positive findings on electroretinogram. There is a chance that there will be no response on electroretinogram, in which case, further invasive electrophysiological analysis will not be necessary.

## Changes that had a significant impact on expenditures:

None

## 6. Products:

### Publications, conference papers, and presentations

#### Journal Publications:

1. **An animal model for whole eye transplantation: A look into the past and vision for the future.** Debra Bourne, MD; Yang Li, MD, PhD, Chiaki Komatsu, MD Edward Davidson, MA, MBBS; Maxine Miller, MD, Hongkun Wang, Li Wei Dong, MD, Mario Solari, MD; Vijay Gorantla, MD, PhD; Joel Schuman, MD, Kia Washington, MD (Plastic and Reconstructive Surgery; submitted); federal support is acknowledged

#### Books or other non-periodical, one-time publications:

1. **Total Human Eye Allotransplantation: Taking an Eye for and Eye to State of the Art.** Kia M. Washington (Plastic Surgery Pulse); federal support acknowledged

#### Other publications, conference papers and presentations:

1. American Society for Reconstructive Microsurgery, January 2015; Paradise Island, Bahamas. **Evaluation of Viability and Structural Integrity after Whole Eye Transplantation.** Yang Li, Chiaki Komatsu, Bo Wang, Maxine Miller, Hongkun Wang, Yolandi van der Merwe, Leon Ho, Nataliya Kostereva, Wensheng Zhang, Bo Xiao, Mario Solari, Larry Kagemann, Shuzhong Guo, Gadi Wollstein, Joel Schuman, Kevin Chan, Vijay Gorantla, Kia M. Washington
2. The 61st Annual Scientific Meeting of the Robert H Ivy/Pennsylvania Plastic Surgery Society, March 2015; Hershey, PA.
3. The Association of VA Surgeons 39th Annual Meeting, May 2015; Miami, FL. **Viability, Structural Integrity and Ocular Physiology are Established in an Orthotopic Whole Eye Transplant Model.** Hongkun Wang, M.D., Yang Li, M.D., Ph.D., Chiaki Komatsu, M.D., Bo Wang, B.S., Maxine R. Miller, M.D., Yolandi van der Merwe, B. Eng, Leon C. Ho, B. Eng, Nataliya Kostereva, Ph.D., Wensheng Zhang, M.D., Ph.D., Bo Xiao, M.D., Ph.D., Ernest Manders M.D., Mario G. Solari, M.D., Michael B. Steketee, Ph.D., Shuzhong Guo M.D., Ph.D., Jeffrey L. Goldberg, M.D., Ph.D., Larry Benowitz, M.D., Ph.D., Lawrence Kagemann, M.D., Gadi Wollstein, M.D., Joel S. Schuman, M.D., Kevin C. Chan, Ph.D., Vijay S. Gorantla, M.D., Ph.D., Kia M. Washington, M.D. and The Whole Eye Transplant Consortium

4. The Association of VA Surgeons 39th Annual Meeting, May 2015; Miami, FL.  
**Total Human Eye Allotransplantation (THEA): Developing surgical protocols for donor and recipient procedures.**  
 Edward H. Davidson MA (Cantab.) MBBS, Eric W. Wang MD, Jenny Y. Yu MD, Juan C. Fernandez-Miranda MD, Dawn J. Wang MD, Yang Li MD Ph.D., Mario G. Solari MD, Joel S. Schuman MD, Vijay S. Gorantla MD, Ernest K Manders MD, Kia M. Washington MD
5. The Association for Research in Vision and Ophthalmology Annual Meeting, May 2015; Denver, CO (Poster).  
**Viability, Structural Integrity and Aqueous Humor Dynamics are Established in an Orthotopic Whole Eye Transplant Model.**  
 Kia M. Washington, Yang Li, Bo Wang, Maxine R. Miller, Yolandi van der Merwe, Leon Ho, Michael Steketee, Joel S. Schuman, Kevin C. Chan, Vijay S. Gorantla and The Whole Eye Transplant Consortium
6. The Association for Research in Vision and Ophthalmology Annual Meeting, May 2015; Denver, CO (Poster).  
**Surgical Considerations in Vascularized Composite Allotransplantation of the Eye.**  
 Nikisha Richards , Edward Davidson , Eric Wang , Jenny Y. Yu , Juan Fernandez-Miranda , Kia M. Washington
7. Plastic Surgery Research Council's 60th Annual Meeting, May 2015, Seattle, WA.  
**Evaluation of Viability, Structural Integrity and Functional Outcome after Whole Eye Transplantation.**  
 Yang Li, M.D., Ph.D., Chiaki Komatsu, M.D., Bo Wang, B.S., Maxine R. Miller, M.D., Hongkun Wang, M.D., Yolandi van der Merwe, B.Eng., Leon C. Ho, B. Eng, Nataliya Kostereva, Ph.D., Wensheng Zhang, M.D., Ph.D., Bo Xiao, M.D., Ph.D., Edward H. Davidson, M.A. (Cantab.) M.B.B.S., Mario G. Solari, M.D., Michael B. Steketee, Ph.D., Shuzhong Guo M.D., Ph.D., Lawrence Kagemann, M.D., Gadi Wollstein, M.D., Joel S. Schuman, M.D., Kevin C. Chan, Ph.D., Vijay S. Gorantla, M.D., Ph.D., Kia M. Washington, M.D.
8. Ohio Valley Society of Plastic Surgery 58th Annual Meeting, May 2015, Covington, KY.  
**Viability, Structural Integrity and Ocular Humor Dynamics are Established after Whole Eye Transplantation.**  
 Maxine R. Miller, M.D., Yang Li, M.D., Ph.D., Chiaki Komatsu, M.D., Hongkun Wang, M.D., Bo Wang, B.S., Yolandi van der Merwe, B. Eng, Leon C. Ho, B. Eng, Nataliya Kostereva, Ph.D., Wensheng Zhang, M.D., Ph.D., Bo Xiao, M.D., Ph.D., Edward H. Davidson MA (Cantab.) MBBS., Mario G. Solari, M.D., Shuzhong Guo M.D., Ph.D., Jeffrey L. Goldberg, M.D., Ph.D., Larry Benowitz, M.D., Ph.D., Joel S. Schuman, M.D., Kevin C. Chan, Ph.D., Vijay S. Gorantla, M.D., Ph.D., Kia M. Washington, M.D.
9. Ohio Valley Society of Plastic Surgery 58th Annual Meeting, May 2015, Covington, KY.

**Total Human Eye Allotransplantation (THEA): Developing surgical protocols for donor and recipient procedures.**

Edward H Davidson MA (Cantab.) MBBS, Eric W. Wang MD, Jenny Y. Yu MD, Juan C. Fernandez-Miranda MD, Dawn J. Wang MD, Yang Li MD, Maxine Miller MD, Mario G. Solari MD, Joel S. Schuman MD, Vijay S. Gorantla MD, Kia M Washington MD

10. The International Society for Magnetic Resonance in Medicine 23rd Annual Meeting, June 2015; Toronto, Ontario, Canada.

**In vivo evaluation of ocular physiology and structural integrity of the optic nerve upon whole eye transplantation using gadolinium-enhanced MRI and diffusion tensor imaging.**

Yolandi van der Merwe, Leon C. Ho, Yang Li, Maxine R. Miller, Chiaki Komatsu, Hongkun Wang, Michael B. Steketee, Seong-Gi Kim, Joel S. Schuman, Kia M. Washington, Kevin C. Chan and the WET Consortium

11. Northeastern Society of Plastic Surgery Meeting, September 2015, Philadelphia, PA.

**Evidence of Retinal Blood Flow, Aqueous Humor Dynamics and Relatively Preserved Blood-Ocular and Aqueous-Vitreous Barriers are seen in an Orthotopic Whole Eye Transplant Model.**

Maxine R. Miller, MD, Yang Li, MD PhD, Chiaki Komatsu, MD, Hongkun Wang, MD, Bo Wang, BS, Yolandi van der Merwe, B. Eng, Leon Ho, B. Eng, Nataliya Kostereva, PhD, Tigran Kostanyan, MD, Wensheng Zhang, MD PhD, Bo Xiao, MD PhD, Edward H. Davidson, MA (Cantab.) MBBS, Mario G. Solari, MD, Michael B. Steketee, PhD, Shuzhong Guo, MD PhD, Jeffrey L. Goldberg, MD PhD, Larry Benowitz, MD, PhD, Lawrence Kagemann, MD, Gadi Wollstein, MD, Joel S. Schuman, MD, Kevin C. Chan, PhD, Vijay S. Gorantla, MD PhD, Kia M. Washington, MD

12. Northeastern Society of Plastic Surgery Meeting, September 2015, Philadelphia, PA.

**Total Human Eye Allotransplantation (THEA): Developing surgical protocols for donor and recipient procedures.**

Edward H. Davidson MA (Cantab.) MBBS, Eric W. Wang MD, Jenny Y. Yu MD, Juan C. Fernandez-Miranda MD, Dawn J. Wang MD, Yang Li MD Ph.D., Mario G. Solari MD, Joel S. Schuman MD, Vijay S. Gorantla MD, Ernest K Manders MD, Kia M. Washington MD

13. McGowan Institute for Regenerative Medicine Retreat, March 2015; Nemocolin, PA.

**Progress Toward Whole Eye Transplantation.**

Invited Speaker: Kia M. Washington, MD

14. McGowan Institute for Regenerative Medicine Retreat, March 2015; Nemocolin, PA (Poster).

**Evaluation of Viability and Structural Integrity after Whole Eye Transplantation.**

Chiaki Komatsu, M.D., Yang Li, M.D., Ph.D., Bo Wang, B.S., Maxine Miller, M.D., Hongkun Wang, M.D., Nataliya Kostereva, Ph.D., Wensheng Zhang,



M.D., Ph.D., Bo Xiao, M.D., Ph.D., Mario Solari, M.D., Jeffrey Goldberg, M.D., Ph.D., Larry Benowitz, Ph.D., Larry Kagemann, Ph.D., Michael Steketee, Ph.D., Shuzhong Guo, M.D., Ph.D., Gadi Wollstein, M.D., Joel Schuman, M.D., Vijay Gorantla, M.D., Ph.D., Kia Washington, M.D.

15. 5th Annual International Conference Vision Restoration: Regenerative Medicine in Ophthalmology, June 2015; Pittsburgh, PA.

**Progress toward whole eye transplantation.**

Invited Speaker: Kia M. Washington, MD

16. University of Pittsburgh Department of Ophthalmology Vision Research Day, June 2015; Pittsburgh, PA (Poster).

**Evidence of Retinal Blood Flow, Aqueous Humor Dynamics and Intact Blood-Retinal and Aqueous-Vitreous Barriers are seen in an Orthotopic Whole Eye Transplant Model.**

Maxine R. Miller, M.D., Yang Li, M.D., Ph.D., Chiaki Komatsu, M.D., Hongkun Wang, M.D., Bo Wang, B.S., Yolandi van der Merwe, B.Eng., Leon C. Ho, B.Eng., Nataliya Kostereva, Ph.D., Tigran Kostanyan, M.D., Wensheng Zhang, M.D., Ph.D., Bo Xiao, M.D., Ph.D., Edward H. Davidson, M.A. (Cantab.) M.B.B.S., Mario G. Solari, M.D., Michael B. Steketee, Ph.D., Shuzhong Guo M.D., Ph.D., Jeffrey L. Goldberg, M.D., Ph.D., Larry Benowitz, M.D., Ph.D., Lawrence Kagemann, M.D., Gadi Wollstein, M.D., Joel S. Schuman, M.D., Kevin C. Chan, Ph.D., Vijay S. Gorantla, M.D., Ph.D., Kia M. Washington, M.D.

17. University of Pittsburgh Department of Ophthalmology Vision Research Day, June 2015; Pittsburgh, PA (Poster).

**In vivo evaluation of ocular physiology and structural integrity of the optic nerve upon whole eye transplantation using gadolinium-enhanced MRI and diffusion tensor imaging.**

Yolandi van der Merwe, Leon C. Ho, Yang Li, Maxine R. Miller, Chiaki Komatsu, Hongkun Wang, Michael B. Steketee, Seong-Gi Kim, Joel S. Schuman, Kia M. Washington, Kevin C. Chan and the WET Consortium

18. Pitt Plastic Surgery Resident Research Day, June 2015, Pittsburgh, PA.

**Gross Morphology and Viability are Established in a Whole Eye Transplant Model.**

Chiaki Komatsu, Yang Li, M.D., Ph.D., Hongkun Wang M.D., Chiaki Komatsu, M.D., Maxine Miller M.D., Bo Wang, B.S., Nataliya Kostereva, Ph.D., Wensheng Zhang, M.D., Ph.D., Mario Solari, M.D., Vijay Gorantla, M.D., Kia Washington, M.D.

19. Pitt Plastic Surgery Resident Research Day, June 2015, Pittsburgh, PA.

**Evaluation of structural integrity, aqueous humor dynamics and functional return after whole eye transplantation.**

Maxine R. Miller, M.D., Yang Li, M.D., Ph.D., Chiaki Komatsu, M.D., Hongkun Wang, M.D., Bo Wang, B.S., Yolandi van der Merwe, B.Eng., Leon C. Ho, B.Eng., Nataliya Kostereva, Ph.D., Tigran Kostanyan, M.D., Wensheng Zhang, M.D., Ph.D., Bo Xiao, M.D., Ph.D., Edward H. Davidson, M.A. (Cantab.) M.B.B.S., Mario G. Solari, M.D., Michael B. Steketee, Ph.D.,

Shuzhong Guo M.D., Ph.D., Jeffrey L. Goldberg, M.D., Ph.D., Larry Benowitz, M.D., Ph.D., Lawrence Kagemann, M.D., Gadi Wollstein, M.D., Joel S. Schuman, M.D., Kevin C. Chan, Ph.D., Vijay S. Gorantla, M.D., Ph.D., Kia M. Washington, M.D.

20. Pitt Plastic Surgery Resident Research Day, June 2015, Pittsburgh, PA.

**Total Human Eye Allotransplantation (THEA): Developing surgical protocols for donor and recipient procedures.**

Edward H. Davidson MA (Cantab.) MBBS, Eric W. Wang MD, Jenny Y. Yu MD, Juan C. Fernandez-Miranda MD, Dawn J. Wang MD, Yang Li MD Ph.D., Mario G. Solari MD, Joel S. Schuman MD, Vijay S. Gorantla MD, Ernest K. Manders MD, Kia M. Washington MD

21. Military Health System Research Symposium, August 2015 (Poster).

**Viability, Aqueous Humor Dynamics and Maintenance of Structural Integrity are established in an Orthotopic Whole Eye Transplant Model.**

Maxine R. Miller, M.D., Yang Li, M.D., Ph.D., Chiaki Komatsu, M.D., Hongkun Wang, M.D., Bo Wang, B.S., Yolandi van der Merwe, B.Eng, Leon C. Ho, B. Eng, Nataliya Kostereva, Ph.D., Edward H. Davidson, M.A. (Cantab.) M.B.B.S., Mario G. Solari, M.D., Michael B. Steketee, Ph.D., Shuzhong Guo M.D., Ph.D., Jeffrey L. Goldberg, M.D., Ph.D., Larry Benowitz, M.D., Ph.D., Lawrence Kagemann, M.D., Gadi Wollstein, M.D., Joel S. Schuman, M.D., Kevin C. Chan, Ph.D., Vijay S. Gorantla, M.D., Ph.D., Kia M. Washington, M.D.

22. Emerging Vision Scientist Day, October 2015, Washington, D.C. (Poster).

**Total human eye allotransplantation: from experimental model to clinical reality.**

Kia M. Washington.

**Websites or other Internet sites:**

Nothing to report

**Technologies or techniques:**

Nothing to report

**Inventions, patent applications, and/or licenses:**

Nothing to report

**Other Products:**

**Awards:**

2015 Outstanding Paper Award, American Society of Reconstructive Microsurgery Annual Meeting, January 2015; Paradise Island, Bahamas

2015 Best Overall Paper Presentation, Ohio Valley Society of Plastic Surgeons 58th Annual Meeting, May 2015; Covington, KY

2015 First Place, Basic Science, Ohio Valley Society of Plastic Surgeons 58th Annual Meeting, May 2015; Covington, KY

- 2015 Magna Cum Laude Award, International Society for Magnetic Resonance Imaging in Medicine 23rd Annual Meeting, June 2015; Toronto, Ontario, Canada
- 2015 Second Place Basic Science Paper, Pitt Plastic Surgery Resident Research Day, June 2015; Pittsburgh, PA
- 2015 Military Health System Research Symposium's Research Accomplishment/Individual/Academia; sponsored by the Assistant Secretary of Defense for Health Affairs
- 2015 Alliance for Eye and Vision Research Emerging Vision Scientist

## 7. Participants & Other Collaborating Organizations

Name: Kevin Chan  
 Project Role: Collaborator  
 Nearest person month worked: 4 CYPM  
 Contribution to Project: Dr. Chan has performed MRI analysis of 3 transplants.

Name: Michael Steketee, MD  
 Project Role: Co-Investigator  
 Nearest person month worked: 4 CYPM  
 Contribution to Project: Dr. Steketee has assisted in the development of the ECM nerve wraps.

Name: Kia M. Washington  
 Project Role: Principal Investigator  
 Nearest person month worked: 4 CYPM  
 Contribution to Project: Dr. Washington has served in the role of principal investigator.

Name: Hongkun Wang  
 Project Role: Postdoctoral Student  
 Nearest person month worked: 3 CYPM  
 Contribution to Project: Dr. Wang has worked in the area of animal transplants and surgical care of the animals

Name: Maxine Miller  
 Project Role: Postdoctoral Student  
 Nearest person month worked: 3 CYPM  
 Contribution to Project: Dr. Miller has worked in the area of Optical Coherence Tomography of the whole eye transplants, and post-surgical care of animals

Name: Gadi Wollstein  
 Project Role: Graduate Student  
 Nearest person month worked: 4 CYPM  
 Contribution to Project: Dr. Wollstein has worked in assisting with interpretation of Optical Coherence Tomography and slit lamp examination of whole eye transplants.

Name: Bo Wang  
 Project Role: Postdoctoral Student

Nearest person month worked:  
Contribution to Project:

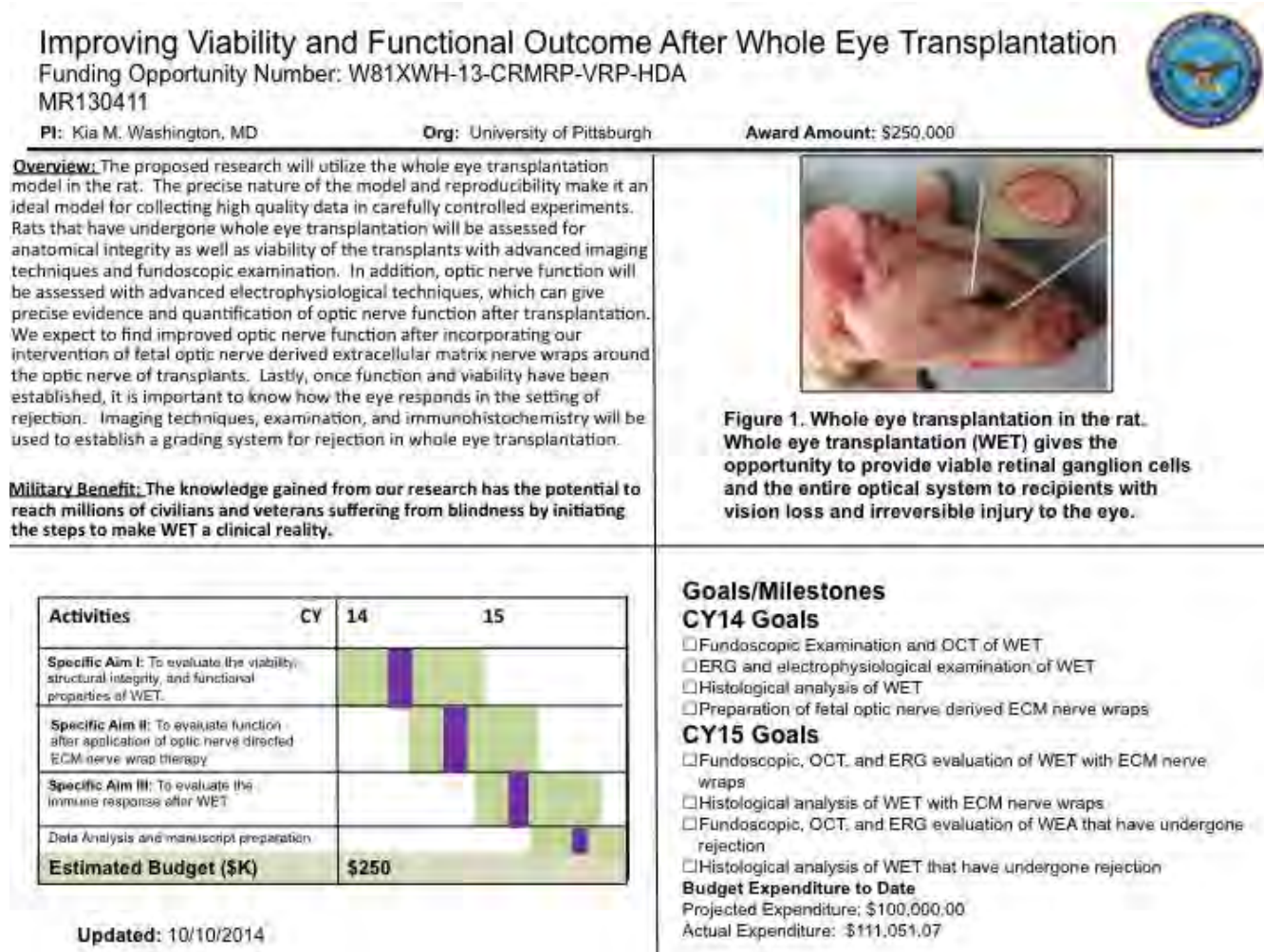
1 CYPM  
Mr. Wang has assisted with Optical Coherence  
Tomography evaluation of whole eye transplants.

Name:  
Project Role  
Nearest person month worked:  
Contribution to project:

Yang Li  
Postdoctoral student  
6 CYPM  
Mr. Yang worked on the development of the animal model

## 8. Special Reporting Requirements:

### Quad Chart:



## 9. Appendices:



# SECOND SIGHT

Eye transplants are science fiction. A team of researchers wants to change that

By Jennifer Couzin-Frankel

In his first-floor lab at the University of Pittsburgh Medical Center (UPMC) in Pennsylvania, Vijay Gorantla is hunched over a blind pig. Under the glare of an operating room light, he's venturing into a shadowy landscape.

Gorantla's terrain is an elegant, tightly controlled 7.5-gram bundle of cells: the eye. Pigs and humans share similar ocular anatomy, and Gorantla, a plastic and reconstructive surgeon, has sliced this animal's optic nerve in two. Now the question is, can he help it see again?

When an eye is lost, darkness reigns. And those who treat eye trauma and disease are, in a sense, groping in the dark themselves. They have little to offer the young girl who tripped while trick-or-treating one Halloween night, cracking her skull and severing the optic nerve, or the 60-year-old who sees only light and shadows, because glaucoma has destroyed cells in that same conduit.

Physicians have transplanted hearts and lungs, faces and hands, a uterus, the abdominal wall. Now, Gorantla wants the eye on that list. He and his colleagues have their work cut out for them. The most daunting challenge is coaxing nerves to regenerate and connect the donor eye to the recipient's brain. But they must also establish blood flow to a transplanted eye; control how the immune system responds to it; and preserve the intricate mechanisms that keep the eye moist, blinking, and able to focus. No one has achieved success even in an animal, and Gorantla is starting from humble beginnings: removing a pig's eye and reattaching it.

Those holding the purse strings are ready to gamble. Last fall, the Department of Defense (DOD) awarded \$1.25 million over 2 years to three centers, including Gorantla's, to develop animal models for whole-eye transplantation. In 2013, the National Eye Institute (NEI) in Bethesda, Maryland, announced the winner of its "audacious goal initiative," a reachable but ambitious target for eye research. The choice—"regenerate neurons and neural connections in the eye

and visual system"—encompasses eye transplants, though isn't limited to them, says Paul Sieving, director of NEI. "Science fiction becomes reality eventually, doesn't it?"

Or, as Gorantla puts it, "if you don't think about something being a possibility, nothing can happen."

**GORANTLA HAS HELD TIGHT** to that motto since at least 1998, when he flew from Manchester, U.K., to Louisville, Kentucky. Fresh from surgical training in England, he was en route to one of the world's premier hand surgery programs. In the Manchester airport before his departure, Gorantla grabbed a copy of *Time*—and was startled to learn that his new home was gearing up for what would be the world's first successful hand transplant. The 15-hour surgery took place 6 months later, in January 1999, on a 37-year-old who had lost his hand in a fireworks accident.

Hand transplants were very different from the organ transplants that preceded them. "With a solid organ, the minute you transplant it" and reconnect the blood vessels, "it starts functioning," Gorantla explains. "All it needs is a blood supply." Hands include nerves, skin, bones, and bone marrow. Each of these needs to work for a transplant to succeed. Peripheral nerves connecting the new hand to the rest of the body have to regenerate—which they do, albeit just 1 millimeter a day. In Louisville, Gorantla assisted in two hand transplant surgeries and followed the patients for years afterward. "It was a process of self-education and discovery," he remembers. "I was right there in front of the patient every day, understanding how rejection happens ... understanding how patients adapt."

In 2006, he relocated to UPMC to establish a hand transplant program there. Face transplants were just beginning, and

## Restoring vision

Because of the eye's complex anatomy and its connection to the brain, transplants come with a host of hurdles.

## REJECTION

The donor eye is likely to be attacked as foreign; doctors need to understand how to detect rejection and treat it.

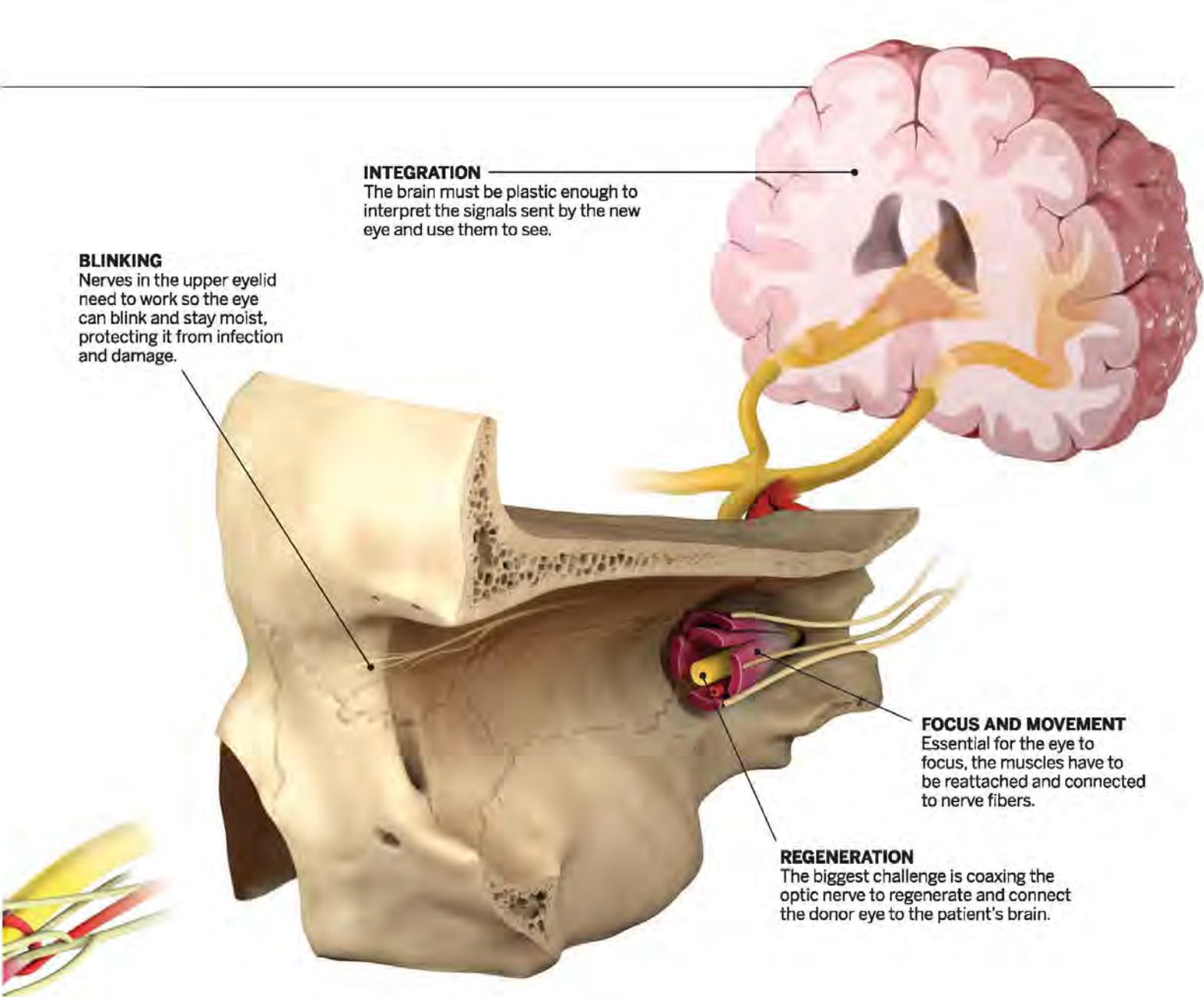


## CELL SURVIVAL

Scientists have to preserve cells in the retina, which can die quickly in the time between donation and transplant.

ILLUSTRATION: V. ALTOUNIAN/SCIENCE





#### BLINKING

Nerves in the upper eyelid need to work so the eye can blink and stay moist, protecting it from infection and damage.

#### INTEGRATION

The brain must be plastic enough to interpret the signals sent by the new eye and use them to see.

#### FOCUS AND MOVEMENT

Essential for the eye to focus, the muscles have to be reattached and connected to nerve fibers.

#### REGENERATION

The biggest challenge is coaxing the optic nerve to regenerate and connect the donor eye to the patient's brain.

Gorantla wondered whether he might take them on. The candidates he met were often Iraq War veterans, their faces blown away.

Although Gorantla could offer these veterans a new face, many had lost their eyes as well, and he couldn't restore their sight. For them, as for other blind people, the preferred strategy for navigating the world is a Seeing Eye dog. "We've outsourced it," says Andrew Huberman, a neuroscientist at the University of California, San Diego (UCSD). "That's the best thing we've got."

So rather than dive into face transplants, Gorantla focused on vision. About 5 years ago, he began broaching the subject of eye transplants with ophthalmologists. "I thought, 'It's crazy,'" remembers Joel Schuman, director of the eye center at UPMC. "The barriers to success are very high." The greatest: Parts of the eye belong to the central nervous system, and unlike peripheral nerves in the hands and face, the central nervous system was thought

incapable of repairing itself. Gorantla was eager to defy dogma. "People said I was too disruptive; they distanced themselves from me," he recalls.

He turned to history. Digging into medical archives, Gorantla uncovered illustrations and handwritten notes from 1885, when a Parisian ophthalmologist had transplanted a rabbit's eye into a young girl. Other efforts followed. All failed miserably, of course—"the rabbit eye was rejected immediately," Gorantla says. But still, the early attempts "really gave me confidence to get back on track. ... I was not being completely stupid" to consider this.

**MORE THAN A MILLION** retinal ganglion cells form a layer in the retina of the human eye. Running from each is a nerve fiber called an axon that stretches back into the brain. Together, these fibers assemble into the optic nerve, "a cable of 1 million phone wires," as NEI's Sieving describes it.

In *Nature* in 2011, Harvard University neuroscientist Zhigang He and his colleagues described crushing the optic nerve of mice and deleting two genes in their retinal ganglion cells. Losing those two genes helped neurons sense stress and proliferate, and, remarkably, they activated a host of others that prompted at least 10% of the nerves to regenerate. The work was replicated by other labs, confirming that "it's possible to get mouse axons to regenerate long distance," says Ben Barres, a neuroscientist at Stanford University in Palo Alto, California, who wasn't directly involved.

But did the newly sprouted nerve fibers travel to the right place? In 2012, Harvard neuroscientist Larry Benowitz, working independently, supplied early evidence that they did, at least partially: The axons reached into visual centers of the brain. Preliminary data hinted that the pupils of the mice responded to light, suggesting they had regained some vision, albeit a minuscule amount. In a dif-





Surgeons Kia Washington and Vijay Gorantla (right) at the University of Pittsburgh are hoping pigs and rats will offer an eye transplant road map.

ferent Harvard lab. He is studying how the regenerated nerves function, performing electrophysiology on the cells and behavior studies on his animals.

Also unknown is how many nerve cells must regenerate so the eyes can see. "The brain is exceptionally good at taking relatively deprived input and making the most of it," says UCSD's Huberman, but no one knows what the minimum number is. When cochlear implants were introduced to restore hearing, many scientists were shocked that they work with as few as 16 electrodes applied to the auditory nerve. "Everyone thought it would take thousands of electrodes to stimulate thousands of nerve fibers for this to happen," says John Dowling, a neuroscientist at Harvard who studies the retina.

The discovery that the optic nerve can regenerate has raised hopes, and not just for transplants: Eye transplants are far in the future, and they'll be appropriate for only a subset of blind individuals. But even if the transplants never succeed, the regeneration studies could help drive "all sorts of spinoff science and technology," says Jeffrey Goldberg, a neuroscientist and ophthalmologist at UCSD. Those might include ways to combine regenerative techniques with treatments for vision loss like retinal prostheses, gene therapy, or stem cells to replace cells that have been lost.

In 2012, Benowitz and Goldberg, who also works in optic nerve regeneration, were invited to speak at the University of Pittsburgh's Fox Center for Vision Restoration. "Vijay was in the audience," Benowitz says. Afterward, the surgeon approached the neuroscientist to evangelize on eye transplants.

The following year, the three began to collaborate. Quickly, the group expanded to include other neuroscientists, surgeons, and ophthalmologists. Researchers at nine institutions joined with Pitt. To augment their funding from DOD, they're seeking grant

money from foundations and government sources. It's "like our moonshot," Pitt ophthalmologist Schuman says, recalling the famous speech by John F. Kennedy in 1961, when Schuman was 2 years old. Transplanting an eye may take longer to achieve than the decade Kennedy promised for the moon landing, he acknowledges, "but I'm sure that we're going to reach" it, too.

Even some of the doubters have come around. Fifteen years ago José-Alain Sahel, director of the Vision Institute in Paris, regarded his countrymen's failed rabbit eye experiments 130 years ago as the first and last word on the matter. A gifted student of his was desperate to graft an eye; Sahel told her the project was outlandish and, with no other goals in mind, she quit science after finishing her Ph.D. Now he's collaborating with the researchers at Pitt, Harvard, and UCSD. "All of this is no longer deemed impossible, it is just a huge, huge crazy effort," he says.

**EARLY STEPS TO BRIDGE** fantasy and reality are being plotted in a lab not far from Gorantla's, where a young plastic and reconstructive surgeon, Kia Washington, is transplanting the eyes and faces of rats. It's the first eye transplant model in a warm-blooded animal. Washington is focused on reattaching dozens of blood vessels, muscle fibers, and the optic nerve. Many of the fibers are less than a millimeter in diameter. To keep immune reactions at bay, she uses genetically identical rats as donors and recipients, much like the first successful kidney transplant in 1954 from a brother to his identical twin.

"It doesn't look like there's function" in the rat eyes, Washington says, but she isn't surprised, because she hasn't tried to induce nerve regeneration. Using cutting-edge optical imaging with Schuman's help, she's found that the transplanted eyes look healthy—even if, practically speaking, they're

useless. "You can actually see blood flow in the eye and in the retina," she says, and MRIs suggest the eyes produce moisture as they're supposed to. As her work progresses, Washington expects to team up with her neuroscientist collaborators to stimulate optic-nerve regeneration. Assessing the outcome will require new kinds of imaging tools, such as measuring how retinal cells grow in real time. NEI plans to release \$5 million to fund several imaging awards this spring.

A rat eye is too small to transplant on its own, so Washington combines it with facial tissue from the same donor. This is how Gorantla imagines the first eye transplants: a combination of face and eye for a patient who's lost both. "You have nothing to lose," because immunosuppressants are already part of the face transplant package, Gorantla notes. The team is readying its first paper, describing Washington's rat eye transplants, for publication. And Washington is about to shift to genetically diverse animals, so she can study how to manage the expected immune response to the transplant.

For his part, Gorantla is ramping up his pig model—and, thinking far ahead, considering where human donor eyes might come from. "The common criteria for organ donors is brain death," he says, and "most of the donors have significant brain trauma or head trauma." That's worrying when it comes to eyes, because brain damage can inflict injury on the optic nerve. One group of collaborators, at the L V Prasad Eye Institute in Hyderabad, India, is testing eye function in brain-dead individuals on ventilators in an intensive care unit. Gorantla is also considering how best to preserve the eye once it's removed—right now, a human retina lives only about 4 hours outside the body.

"There's so much we don't know," Gorantla says. "We don't even know what we don't know." In a way, that's what excites him the most. ■



# SIGHT + SOUND

## SPRING EDITION



## Stop the Ringing

by Zack Butovich

**"We are at a point in our research where I feel I can say that we are one million dollars away from a cure for tinnitus," states Dr. Jonas Johnson, Chairman of our Department of Otolaryngology, where some of world's leading research on the condition known as tinnitus takes place.**

Making this bold statement in a room full of University of Pittsburgh alumni and friends in Naples, Florida, it was met with audible surprise. For anyone suffering tinnitus (over 10% of Americans), the prospect of a cure for the permanent ringing sound, which can sometimes be as severe as a loud crashing or exploding, is a dream come true.

In previous issues of *Sight + Sound*, we have mentioned the incredible progress Thanos Tzounopoulos, PhD, has made in his tinnitus research since arriving at the University of Pittsburgh in 2008 as part of the then brand new Auditory Sciences Center in our Department of Otolaryngology. He has helped to locate the source of tinnitus (the brain, not the ear); actually see it in action on a circuit and cellular level; identified possible causes of the "phantom sound" (a decrease of a specific potassium channel associated with the auditory control center within the brain); and recently, and most significantly, Dr. Tzounopoulos has hypothesized a way to prevent the development of tinnitus.

Dr. Tzounopoulos, in collaboration with the Drug Discovery Institute at the University of Pittsburgh, has identified at least a dozen molecules or combinations of molecules (essentially the chemicals that makes medicine and drug therapies), with the potential to restore the activity of the deficient potassium channel in the auditory center of the brain, thereby relieving the tinnitus effect.

**This is the closest any research has ever gotten to finding an explanation and a potential cure for tinnitus.**

Dr. Tzounopoulos is excited to begin working towards clinical trials with many of the molecules he has identified. Collaboration with Catherine Palmer, PhD, in the Department of Audiology, and Yael Raz, MD, in the Department of Otolaryngology, has begun, in an effort to identify how to test these potential treatments for tinnitus.

"My studies have elucidated the mechanisms underlying the induction of tinnitus; the next crucial step in my research is the determination of the mechanisms underlying the maintenance of long-term tinnitus," says Dr. Tzounopoulos. This is an important distinction, because sometimes new onset tinnitus may have different origins or characteristics than tinnitus that has been maintained for a significant period of time. Furthermore, Dr. Tzounopoulos believes that the

*continued on page 6*

## In This Issue

Re-Imagining Sight -  
Seeing with our Brain  
and Not With Our Eyes 2

In Search of a New Business  
Model to Improve Patient Care 3

Optic Nerve Regeneration  
for Transplant and Repair 4

Personalized Medicine for  
Head and Neck Cancer 5

Exciting Development in  
Treating Damaged Corneas 6

Focus Turned to Otitis Media 7

Setting Expectations and  
Overcoming Obstacles 8

*Pictured above: Thanos Tzounopoulos,  
PhD, Assistant Professor,  
Department of Otolaryngology,  
University of Pittsburgh  
Photo by Joshua Franzos.*



# Optic Nerve Regeneration for Transplant and Repair

by Zack Butovich

**W**hy fight biology when we are on the same team? Regenerative medicine approaches are shifting how we approach previously unsolvable problems like central nervous system regeneration. The University of Pittsburgh, the Louis J. Fox Center for Vision Restoration, and the McGowan Institute for Regenerative Medicine have one of the most comprehensive and successful regenerative medicine collaborations ever established. Within this collaboration, enthusiasm is now growing in developing functional optic nerve repair and regeneration strategies to prevent vision loss after injury or disease, as well as enabling a whole eye transplant (WET) procedure, an idea more fitting for science fiction just a decade ago.

Regenerating this optic nerve functionality is the goal of Michael Stoketee, PhD and his lab, as part of the Fox Center for Vision Restoration.

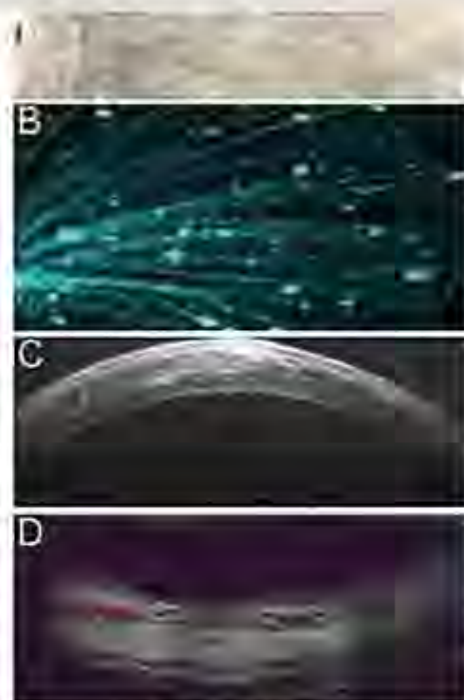
The standard model for any regeneration tests typically involves severing the tissue and observing the scar response. While a scar on your arm or leg may have a permanent appearance, but otherwise makes no difference to your ability to use your arm or leg, a scar on your optic nerve completely interrupts blood flow and restricts the neural communication between the eye and the brain. Therefore, the key to rebuilding healthy, functional tissue, is to keep the occurrence of natural scarring at a minimal level. By utilizing extra-cellular matrix (ECM) from the labs of Dr. Steven Badylak, and bio-hybrid wraps designed by Dr. William Wagner (both of the McGowan Institute), Dr. Stoketee has found remarkable success in reducing scarring and increasing regeneration in optic nerve models.

This success implies that repairing the optic nerve after trauma (which can be the result of physical force, but also degenerative diseases such as glaucoma), is possible. Furthermore it suggests ECM technology may be beneficial when used in conjunction with the WET project, as a way to replace lost ocular and optic nerve structures, potentially restoring communication between the eye and the brain, and restoring vision.

Success such as this has helped lead to the growing optimism for the previously unthinkable goal of whole eye transplant. Adding to that, is Kia M. Washington, MD, a physician-scientist with UPMC and the VA, and highly skilled plastic surgeon. Dr. Washington is the first surgeon in the world to successfully develop a vascularized ophthalmic transplant model in mammals – in other words, a full transplant of an entire eye from a donor to a recipient in a reliable, repeatable, and sustainable way that maintains tissue health, structural integrity, and connects the optic nerve from donor to recipient.

However, due to the eye's status of being one of the human body's most complicated systems, succeeding in the vascular transplant of the eye is not enough to restore a patient's sight (how can we be sure, that following transplant, the eye will actually see?). This embodies the next crucial step of the project: ensuring the transplanted eye can connect and then communicate visual information to the brain, which can only be achieved with a healthy optic nerve that transmits neural stimuli from the retina in the eye to the visual cortex in the brain, enabling usable perception.

Luckily, determining the functionality of ophthalmic structures, especially following degeneration, treatment, and potentially, transplant, is the expertise



An DGT image: A. Fetal urinary bladder extracellular matrix nerve wrap. B. Retinal ganglion cell axons projecting into the optic nerve head. C. Intact cornea. D. and an intact retina showing restored blood flow after whole eye transplant ion.

of Dr. Kevin C. Chan, PhD, whose lab in our Department of Ophthalmology, is pioneering new and innovative ways at imaging the structural integrity of the eye. Dr. Chan has designed ways to test vision in animal models, potentially creating a way to test the success of Dr. Stoketee's optic nerve regeneration techniques following trauma or transplant, as well as examine the viability of internal tissue integrity.

Yoland Van Der Merwe, a master's level student, is acting as a bridge between the labs of Dr. Stoketee and Dr. Chan. Ms. Van der Merwe, whose background is in bioengineering, has developed an important model for evaluating the healing properties of ECM on retinal blood flow and structural integrity after injury in glaucoma and stroke models. Her efforts bring together the expertise of both robust research labs, allowing the necessary advances in regenerative medicine approaches to ocular repair to accurately tracked and evaluated in ways previously unimagined. This is an example of the power of the Louis J. Fox Center for Vision Restoration and the McGowan Institute for Regenerative Medicine.

These types of interdisciplinary collaborations, highly encouraged,  
*continued on page 7*



# Focus Turned to Otitis Media

by Zack Butovitch



Charles D. Bluestone, MD,  
founding member of the  
Society for Middle Ear Disease

**D**r. Charles D. Bluestone officially retired in June 2014 from the University of Pittsburgh's Department of Otolaryngology as Distinguished Professor Emeritus of Otolaryngology in the School of Medicine, the highest possible honor that can be accorded to a faculty member at the University. A giant in the field of pediatric otolaryngology and former Chairman of the Department of Pediatric Otolaryngology at Children's Hospital of Pittsburgh, Dr. Bluestone is an internationally respected otolaryngologist and specialist in middle-ear disease. Even though now retired from direct patient care, he remains active in the Society for Middle-Ear Disease (SMED), which he founded in 2012.

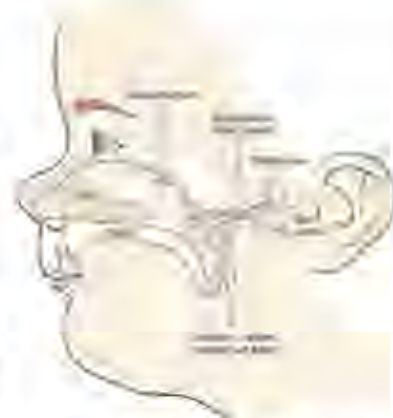Middle ear disease occurs between the ear drum at the end of ear canal, and the inner ear, where the cochlea and other important auditory tissues are located. The most frequently encountered middle ear disease is otitis media, which is an infection that usually causes severe pain in young children, and is often related to dysfunction of the Eustachian tube and inflammation of the mucous membranes in the back of the throat.

While relatively common throughout the US (approximately 11% of the population is affected each year, of whom half are under the age of 5), otitis media is very treatable with a variety of options, ranging from medication to simple surgery. However, if left untreated, otitis media can cause long-term or permanent hearing damage, or

most significantly, in some cases, death (in 2013, complications of otitis media resulted in approximately 2,400 deaths primarily in developing countries).

Despite its treatability with simple interventions, otitis media is very often under-treated in developing nations and in impoverished regions, such as South-Central Asia and Aboriginal Australia. Adding to the lack of available care, access to it, or awareness of the disease, is the fact that many of these populations are highly genetically susceptible to otitis media. Australian Aborigines, for example, have a nearly 50% chance of developing otitis media in their childhood. Inuit populations in Alaska have a similar rate of infection. Populations in Eastern Africa, Thailand, Malaysia, and the Asian Sub-Continent all exhibit high risk factors for otitis media.

Identifying this prevalent issue around the world, Dr. Bluestone, in the years leading up to his retirement, worked to create SMED to help provide information on, bring awareness to, and ultimately unite physicians around the world on the issues of otitis media, middle-ear disease, and the need for greater education and care worldwide. SMED is a not for profit international advocacy society with leading experts in middle-ear disease from around the world as its advisors. Relying upon support from the Eye & Ear Foundation, Children's Hospital Foundation, the DePaul School for Hearing and Speech, the University of Pittsburgh, and a vast consortium of clinical specialists from all over the world, SMED is dedicated



to helping provide resources for those suffering from middle-ear disease, their families, and their care providers.

The Society for Middle-Ear Disease is now working directly with the Eye & Ear Foundation of Pittsburgh to establish funding for an International Visiting Scholars Program. This program would grant physicians from developing nations the chance to learn from experts in middle ear disease at the University of Pittsburgh, thereby enabling them to provide the best quality care and information for the patients in their country suffering from middle-ear diseases, especially otitis media. This Visiting Scholars program may be a crucial first step in delivering important treatment and prevention of middle ear disease to developing areas around the world in a way that is sustainable and self-perpetuating. §§

*More information on the Society for Middle-Ear Disease, including information on advances in middle ear evaluation and treatment, can be found at [societyformiddleear.org](http://societyformiddleear.org). Donations in support of the Society can be made at [eyeandear.org](http://eyeandear.org).*

## Optic Nerve Regeneration *continued from page 4*

and more importantly, supported at the University of Pittsburgh, not only advance the capability of Dr. Steketeer and Dr. Washington's labs, but advance the field closer toward clinical translation. As Dr. Joel S. Schuman, Chairman of the Department of Ophthalmology, has quoted time and again, "The idea

of the lone scientist working in his lab no longer applies. It's not how you can succeed in science anymore. Collaboration is the key to everything." It is also the cornerstone to the optimism surrounding optic nerve repair and the WET project. With so many brilliant researchers, working together in so many open and collaborative ways, optimism prevails in that we may just have the keys to success. §§

# PITTSBURGH BUSINESS TIMES

## HEALTH CARE

### *VA researcher honored for eye transplant work*

KRIS B. MAMULA  
Pittsburgh Business Times

VA Pittsburgh Health-care System researcher Dr. Kia Washington is being honored by the Department of Defense for her work in the field of eye transplantation.

Washington has been working to develop animal models for eye transplants, exploring ways to reconnect microscopic blood vessels and optic nerves to a transplanted eye.

The goal is to give sight to soldiers who have been blinded in the line of duty.

Washington's work will be spotlighted at the DOD's annual Military Health System Research Symposium, which will be held Aug. 17-20 in Fort Lauderdale, Fla. Her research is a collaboration between the VA Pittsburgh and UPMC.





# PITTSBURGH BUSINESS TIMES

## HEALTH CARE

### Q&A: Dr. Kia Washington

KRIS B. MAMULA  
Pittsburgh Business  
Times

*Dr. Kia Washington is associate director of the hand transplantation program at UPMC, and she also holds academic and clinical appointments at the VA Pittsburgh Healthcare System and University of Pittsburgh. The 39-year-old Washington was honored by the Department of Defense with the individual investigator award for her research into whole eye transplantation.*

**Could Pittsburgh become a center for whole eye transplants?**

Oh, definitely. A lot of our research is done at the Starzl Institute and in the Ophthalmology Department. There have been over 95 hand and face transplants worldwide – face transplants have really advanced in the last five to 10 years. That in itself is really exciting.

**When will whole eye transplantation become a reality?**

It's high-risk, high-reward research. I believe it will happen several years from now. That would really be amazing, almost a miracle. When people first

started doing face and hand transplants, no one thought it would really happen. But now, people throughout the world have benefited from face and hand transplants.

**What are the roadblocks to making these operations successful?**

We've been successful at transplanting the whole eye intact in rats. Now, we're joining researchers at Harvard and Stanford with their optic-nerve research to get the rat to see.

**What is the biggest issue?**

Optic-nerve rejection is a major issue. We don't know how the eye will respond to rejection. It may undergo the same kind of rejection as an organ. Of course, there's immunosuppressants for that, but that's something we need to study.

**Is transplanting eyes a new idea?**

No, it's been around since the 1800s. A French doctor transplanted a rabbit eye into a little girl, which didn't work because of rejection.

**Do you have trouble juggling your schedule?**

I wear a lot of hats. I have



RONALD FONTANA

VA eye researcher Dr. Kia Washington

a large clinical practice, with about a quarter of my time spent on research. It's a tough balance, but when you find something you're passionate about, it makes the balance easier.

**What is your clinical practice specialty?**

Upper extremity surgery, microsurgery is what it's called. Most of my patients have had some kind of trauma. We try to restore form and function to the hand or other part of the body, but most of my practice is hand and upper extremity surgery.