



# Recipient wound bed characteristics affect scarring and skin graft contraction

Lloyd F. Rose, PhD; Jesse C. Wu, MS; Anders H. Carlsson, PhD; David I. Tucker, DDS; Kai P. Leung, PhD; Rodney K. Chan, MD, FACS

US Army Institute of Surgical Research, Dental and Trauma Research Detachment, JBSA Fort Sam Houston, Texas

## Reprint requests:

Lloyd Rose, US Army Institute of Surgical Research, Dental and Trauma Research Detachment, 3698 Chambers Pass, JBSA Fort Sam Houston, Texas 78234  
Fax: 210-539-9190  
Email: lloyd.f.rose2.vol@mail.mil

Manuscript received: November 19, 2014  
Accepted in final form: January 30, 2015

DOI:10.1111/wrr.12267

The opinions or assertions contained herein are the private views of the authors and are not to be construed as official or as reflecting the views of the Department of the Army or the Department of Defense.

This study has been conducted in compliance with the Animal Welfare Act, the implementing Animal Welfare Regulations, and the principles of the Guide for the Care and Use of Laboratory Animals.

Injuries resulting in loss of dermal coverage are typically treated by means of eschar excision or wound debridement followed by coverage with split thickness skin grafts (STSGs). As a consequence, skin replacement therapy has been a topic of intense investigation for decades, with the ultimate goal being the best quality skin for the least amount of donor skin investment. Thicker grafts generally result in better quality skin<sup>1</sup>; however, thicker skin grafts are not always possible and in any case are associated with higher donor-site morbidity. The long-term effect of thinner, low quality skin replacement is the development of function-limiting scar contractures.

Although it is known that grafting onto more mobile tissues results in reduced contraction,<sup>2,3</sup> most research into regenerating skin has focused on restoration of an intact dermis using a combination of scaffolds, cells, and growth factors. However, data suggests that having an intact hypodermis may be equally important.<sup>2-4</sup> This seems to be especially relevant in extremity burns, where contractions located near joints frequently limit range of motion.<sup>5</sup> Patients who receive skin grafts onto fat report better range of motion compared with patients who receive skin grafts directly onto fascia.<sup>3</sup> The same study also found that patients with grafts onto fat had normal sensation compared with those receiving grafts onto

## ABSTRACT

The use of autograft skin is essential in the treatment of full thickness burns and large cutaneous defects. Both autograft thickness and condition of the wound bed modulate aesthetic and functional outcomes. Thicker autografts contract less and maintain greater functionality as the scar matures. The presence of hypodermis can also positively affect the eventual appearance and functionality of the wound site by modulating contraction and alleviating inflammation and cellular stress responses. In this study, we characterize wound-site physical and cellular characteristics following split-thickness skin grafting onto hypodermis vs. onto fascia. Compared to autografts grafted onto fascia, identical thickness autografts grafted onto fat demonstrated reduced contraction, enhanced mobility and vascularity, and reduced topographical variability. Grafts onto fat also showed reduced levels of myofibroblasts and leukocytic infiltration. The status of the wound bed prior to engraftment is an important contributor of skin quality outcome. The presence of hypodermis is associated with improved functional and aesthetic qualities of split thickness skin grafts, which are correlated with reduced presence of myofibroblasts and leukocytic infiltration.

fascia, suggesting grafts onto fat become better innervated during graft maturation. Sultan et al. reported that mice receiving fat grafts showed enhanced neovascularization and reduced expression of scar-associated cytokine TGF- $\beta$ .<sup>4</sup> However, the mechanism by which hypodermis induces these alterations is unclear. Although the ability to preserve hypodermis is usually dictated by the severity of injury and may not always be possible, restoration of the hypodermis through tissue engineering, before or after graft application, may diminish graft contraction and decrease scarring.

In this study, we utilized an established porcine model of wound healing to characterize the effect on contraction and hypertrophic scarring of autologous skin grafting onto hypodermis compared with grafting directly onto fascia. By both subjective and objective measurements, we corroborate previous reports that grafting onto fat improves final scar quality. Further, with histological and histochemical analysis, we extend those findings to report that the molecular components of the extracellular matrix more closely resemble normal skin when autograft is applied onto fat. Finally, with immunohistochemical analysis, we demonstrate alterations in the cellular populations of the healing wound that suggest a mechanism for the role of fat in improved wound healing.

# Report Documentation Page

*Form Approved  
OMB No. 0704-0188*

Public reporting burden for the collection of information is estimated to average 1 hour per response, including the time for reviewing instructions, searching existing data sources, gathering and maintaining the data needed, and completing and reviewing the collection of information. Send comments regarding this burden estimate or any other aspect of this collection of information, including suggestions for reducing this burden, to Washington Headquarters Services, Directorate for Information Operations and Reports, 1215 Jefferson Davis Highway, Suite 1204, Arlington VA 22202-4302. Respondents should be aware that notwithstanding any other provision of law, no person shall be subject to a penalty for failing to comply with a collection of information if it does not display a currently valid OMB control number.

1. REPORT DATE <b>13 FEB 2015</b>	2. REPORT TYPE <b>N/A</b>	3. DATES COVERED -			
4. TITLE AND SUBTITLE <b>Recipient wound bed characteristics affect scarring and skin graft contraction.</b>		5a. CONTRACT NUMBER			
		5b. GRANT NUMBER			
		5c. PROGRAM ELEMENT NUMBER			
6. AUTHOR(S) <b>Rose L. F., Wu J. C., Carlsson A. H., Tucker D. I., Leung K. P., Chan R. K.,</b>		5d. PROJECT NUMBER			
		5e. TASK NUMBER			
		5f. WORK UNIT NUMBER			
7. PERFORMING ORGANIZATION NAME(S) AND ADDRESS(ES) <b>United States Army Institute of Surgical Research, JBSA Fort Sam Houston, Tx 78234</b>		8. PERFORMING ORGANIZATION REPORT NUMBER			
		10. SPONSOR/MONITOR'S ACRONYM(S)			
9. SPONSORING/MONITORING AGENCY NAME(S) AND ADDRESS(ES)		11. SPONSOR/MONITOR'S REPORT NUMBER(S)			
		12. DISTRIBUTION/AVAILABILITY STATEMENT <b>Approved for public release, distribution unlimited</b>			
13. SUPPLEMENTARY NOTES					
14. ABSTRACT					
15. SUBJECT TERMS					
16. SECURITY CLASSIFICATION OF:			17. LIMITATION OF ABSTRACT <b>SAR</b>	18. NUMBER OF PAGES <b>10</b>	19a. NAME OF RESPONSIBLE PERSON
a. REPORT <b>unclassified</b>	b. ABSTRACT <b>unclassified</b>	c. THIS PAGE <b>unclassified</b>			

## MATERIALS AND METHODS

### Animals

Yorkshire cross-bred female pigs (Midwest Research Swine, Gibbon, MN) aged 6 months and weighing 40–50 kg were used for all experiments. A total of 19 pigs were used in this study, which was reviewed and approved by the Institutional Animal Care and Use Committee at the United States Army Institute of Surgical Research (USAISR, JBSA Fort Sam Houston, TX). All animals received care in strict compliance with the 2011 Guide for the Care and Use of Laboratory Animals by the National Research Council and were maintained in a facility accredited by the Association for Assessment and Accreditation of Laboratory Animal Care International.

### Full thickness excision and grafting

Prior to wounding, the backs of anesthetized pigs were shaved, with remaining hair removed using a depilatory (Nair, Church & Dwight, Ewing, NJ), followed by rinse with sterile water. Throughout the course of surgical procedures temperature probes were used to monitor core body temperature, which was maintained with underbody warming pads and Bair Hugger Long Blankets (3M Company, St Paul, MN). Using a permanent marker, 10 preoperative 6 cm diameter markings were inscribed, five down each dorsal side, situated 2 cm from the spine and 4 cm apart from each other. The edges of the marked wound-borders were tattooed using an electric tattoo marker (Superior Tattoo, Phoenix, AZ). The back of the pig was then sterilized with povidone-iodine solution and sterility maintained throughout the procedure. In addition, because the animals' weights increased by at least a factor of 2, two additional 6 cm circles not slated for excision were tattooed to normalize the size of each wound with respect to animal growth (Supporting Information Figure S1). Total wound area accounted for less than 10% total body surface area.

The 10 marked wound sites were then excised down to either muscle fascia or down to hypodermis (i.e., only epidermis and dermis were excised). Wounds were then grafted using autologous skin taken from a hind limb donor site (as is done clinically). The autografts (3 × 3 in) were harvested using a dermatome adjustable to the different thicknesses tested: 6/1,000, 12/1,000, 20/1,000, and 30/1,000th of an inch. Autograft thickness was confirmed histologically. Donor skin was cut to 6 cm diameter circles and secured in position over the excised wounds using nonabsorbable sutures (Ethicon, Perma-Hand Silk, Johnson & Johnson, New Brunswick, NJ). Autograft locations were randomized to account for differences in anatomical locations of graft sites. Different graft thicknesses were rotated through all possible wound sites to prevent unintentional bias arising from wound sites that might be more or less prone to contraction. Full thickness autograft skin was taken from the material excised from the original full thickness wounds with hypodermis removed.

Wound dressings, a bolster consisting of an antibiotic-impregnated petrolatum (Xeroform, Medtronic, Minneapolis, MN) and cotton gauze, were secured to the wound bed for 7 days. Additional protective dressing using Ioban (3M Company) and cloth jackets were applied. After removal

of the initial dressing at day seven postoperation, additional dressings were applied only when tissue biopsies were taken. These dressings consisted of Xeroform, cotton gauze and Ioban.

### Observer scar assessment scale

Subjective scar assessment was measured by the observer portion of the Patient Observer Scar Assessment Scale (POSAS), a comprehensive scale designed to evaluate measures of scar quality including vascularity, pigmentation, relief or texture, thickness, pliability, surface area, pain, and itching.<sup>6,7</sup> The scale was adapted for use with pigs, eliminating all measurements normally requiring patient input (i.e., pain and itching). Pigmentation was omitted in favor of an objective measurement (described below in Colorimetry). Measurements for remaining parameters were compared to normal skin using a 10-point scale. For vascularity, relief, and pliability, the lowest score of "1" corresponded to normal skin while the highest score of "10" indicated the worst possible scar (purple in appearance, highly irregular surface, and stiff, immobile scar, respectively). Trained observers were nonblinded because all investigators were intimately involved in the surgeries.

### Contraction analysis

Photographs of the wounds were analyzed by ImageJ software (National Institutes of Health, Bethesda, MD) to quantify graft or scar size, calculated as a percentage of the initial graft size and expressed as graft contraction over time. In individual images, measurements were calibrated to a ruler placed alongside the wounds. The wound tattoo was then outlined and total surface calculated. All measurements were normalized to the unexcised growth circles from each pig. For contraction analysis,  $n = 8-10$  wounds for each graft thickness.

### Colorimetry

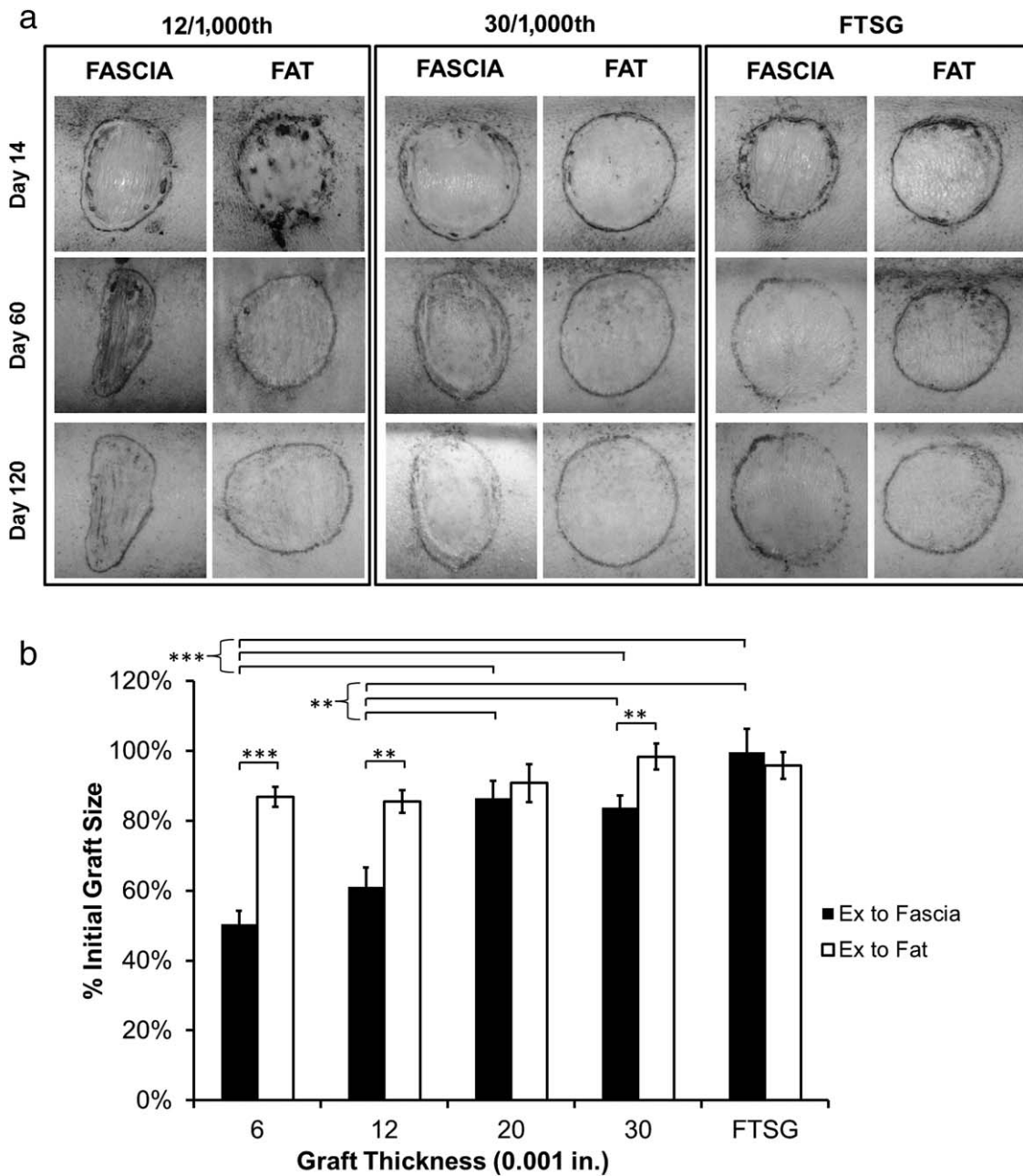
A Cortex Technology DSMII Colorimeter (CyberDerm Inc., Broomall, PA) was used to assess color changes in scars caused by variation in hemoglobin and melanin content. Based on the known absorption spectra of hemoglobin and melanin chromophores, the change in melanin and hemoglobin content between the scar tissue and adjacent healthy skin was quantified. Erythema and melanin indices were selected as the color system. Higher readings indicate higher hemoglobin or melanin content.

### Skin biopsy

On days 7, 14, 30, 60, 90, and 120 postgrafting, all animals were anesthetized and one biopsy sample taken for histology and immunohistochemistry. Histological samples were comprised of a 12 mm punch from the periphery of the graft. The periphery was used in order to compare bordering host tissue with the graft and scar tissue. Biopsy sites for each subsequent assessment were rotated through a star pattern.

### Histology

Biopsied tissues were fixed in 10% neutral-buffered formalin, dehydrated, and embedded in paraffin for histological analysis. Five- $\mu$ m thick sections were deparaffinized and



**Figure 1.** Grafts on fat or fascia. Various thicknesses of autograft skin were grafted onto fascia or hypodermis. Wounds grafted with thin split-thickness skin (6 and 12/1,000th in.), thick split-thickness skin (20 and 30/1,000th in.) and full-thickness skin (FTSG), visualized at days 14, 60, and 120. (A) Representative images of thin and thick grafts on fascia or hypodermis at indicated time points. (B) Contraction is reported as a percentage of original graft size at day 120 and normalized to unexcised growth control tattoos. Wounds were distributed among 19 pigs with the following wound *n* for fascia/fat: 6/1,000 = 8/8, 12/1,000 = 10/9, 20/1,000 = 8/8, 30/1,000 = 8/8, FTSG = 10/9. Statistical significance was determined by nonparametric pairwise comparison using Wilcoxon method and results reported as mean  $\pm$  standard error of the mean. \**p* < 0.05, \*\**p* < 0.005, \*\*\**p* < 0.0005.

stained with hematoxylin & eosin (H&E), Verhoeff’s Elastic Masson’s Trichrome for total collagen and elastin, or picrosirius red for differential detection of Type I and III

collagen. All sections were photographed (Eclipse 55i and DS-Fi1, Nikon, Melville, NY) under white light or plane-polarized light (picrosirius red).

**Immunohistochemistry**

After deparaffinization and hydration, antigen retrieval was performed and sections were blocked with 10% normal goat serum for 1 hour at room temperature. Sections were then incubated with primary antibodies, either rabbit pAb alpha-smooth muscle actin ( $\alpha$ -SMA) (AbCam clone 1A4, Cambridge, MA) or mouse mAb  $\alpha$ -CD45 (AbCam clone MIL13), overnight at 4 °C. Endogenous peroxidase activity was blocked with 3% hydrogen peroxide. Primary antibody was detected with HRP-conjugated secondary antibody (goat anti-rabbit or goat anti-mouse) (Bio-Rad, Hercules, CA), followed by 3'3'-diaminobenzidine (DAB) developer (Vector Lab, Burlingame, CA). Slides were observed utilizing a Nikon Eclipse 55i light microscope and photographs were taken with a Nikon DS-Fi1 camera.

**Statistical analysis**

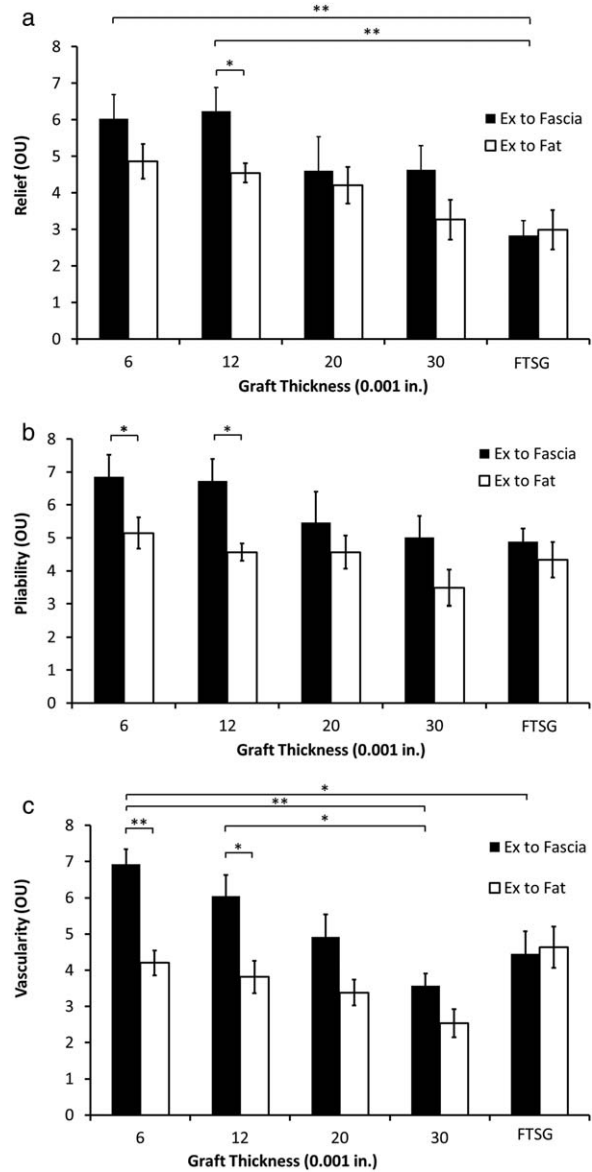
Statistical differences for Observer Scar Assessment Scale (OSAS) scoring, colorimetry and graft contraction were determined by nonparametric pairwise comparison using Wilcoxon's method. Results were presented as mean  $\pm$  standard error of the mean (SEM).  $p < 0.05$  was considered significant. For OSAS analysis,  $n = 7-10$  wounds. Total number of wounds in a given group may not correspond to the number of animals used because not all grafts survived and each animal did not necessarily have one of each skin graft thickness. In addition, wounds slated for contraction analysis were not biopsied to avoid the possibility that disruption of the continuity of the graft might alter final wound contraction.

**RESULTS**

**STSG onto hypodermis is resistant to contraction**

It has been reported that autograft thickness is negatively correlated with contraction.<sup>1</sup> We have observed the same phenotype,<sup>8</sup> confirming that our porcine model faithfully replicates the human wound healing condition. We also correlated autograft thickness with levels of inflammatory infiltrate and with levels of  $\alpha$ -SMA-expressing pericytes and myofibroblasts. To examine the effect hypodermis exerts on wound healing and scarring processes, we excised wounds down to the level of the hypodermis to compare with wounds excised down to muscle fascia. We then grafted STSGs of the varying thicknesses described above.

Over the course of 120 days, we monitored the status of the wound and contraction (Figure 1A). As we have previously shown, when STSGs are grafted directly onto fascia and compared to full thickness skin graft (FTSG), the amount of contraction is directly correlated with the thickness of the STSG.<sup>8</sup> FTSGs demonstrate minimal or no contraction, while grafts of 6/1,000th in. contract up to 50% of their original size. By comparison, STSGs grafted onto hypodermis demonstrate no correlation with graft thickness. In short, even when thin grafts are grafted directly onto fat, there is no significant contraction. Measurement of graft surface area at day 120 reveals that even the thinnest skin graft maintains almost 90% of its original surface area (Figure 1B).



**Figure 2.** Subjective assessment of skin quality. At day 120 all wounds were assessed by trained surgeons for specific parameters of skin graft quality. Y-axis values are reported as “OSAS units” (OU) with 10 indicating poor quality and one indicating good quality. (A) “Relief” reflects topographical variability of the scar above or below the plane of normal skin. (B) “Pliability” reflects the suppleness of the skin and its mobility on the underlying strata. (C) “Vascularity” reflects the redness of the scar compared to normal skin. Wounds were distributed among 19 pigs with the following wound  $n$  for fascia/fat: 6/1,000 = 8/9, 12/1,000 = 10/9, 20/1,000 = 8/8, 30/1,000 = 8/8, FTSG = 7/9. Statistical significance within categories (graft thickness) was determined by nonparametric pairwise comparison using Wilcoxon method and results are reported as mean  $\pm$  standard error of the mean. Statistical analysis of trends was analyzed by ANCOVA. \* $p < 0.05$ , \*\* $p < 0.005$ .

### Thin STSGs grafted on fat show significant improvements in subjective assessments of scar quality

Beyond the objective measurement of contraction, the POSAS can be used to measure scarring subjectively.<sup>6,7</sup> We adapted the observer portion of this test (OSAS) to assess scar quality. As with contraction, increasing graft thickness is directly correlated with improved OSAS scores when STSGs are grafted directly onto fascia (Figure 2A–C).

Relief is a measure of the height, subsidence or irregularity of the surface of the scar. Although only the 12/1,000th in. graft showed statistically significant differences between grafting onto fascia vs. fat using nonparametric pairwise comparison, a statistically significant trend, as determined by ANCOVA analysis, demonstrated that grafting on fat improved this scar assessment (Figure 2A). Pliability is a measure of the suppleness of the scar. Compared to regular skin, many scars become stiff and immobile. In our evaluation, when grafted over fat, all graft thicknesses demonstrated improved pliability scores (Figure 2B). Pliability of the thinnest grafts demonstrated statistically significant differences between fat and fascia in pairwise comparison, and as with relief assessments, the pliability trend was statistically significant. Vascularity is a measure of scar redness. In our evaluation, compared to grafting onto fascia, grafting onto fat improved this scar feature for all STSGs (Figure 2C). As with pliability measurements, in pairwise comparison the thinnest grafts showed statistically significant improvement in vascularity measurements from grafting onto fat, though the trend did not meet statistical significance.

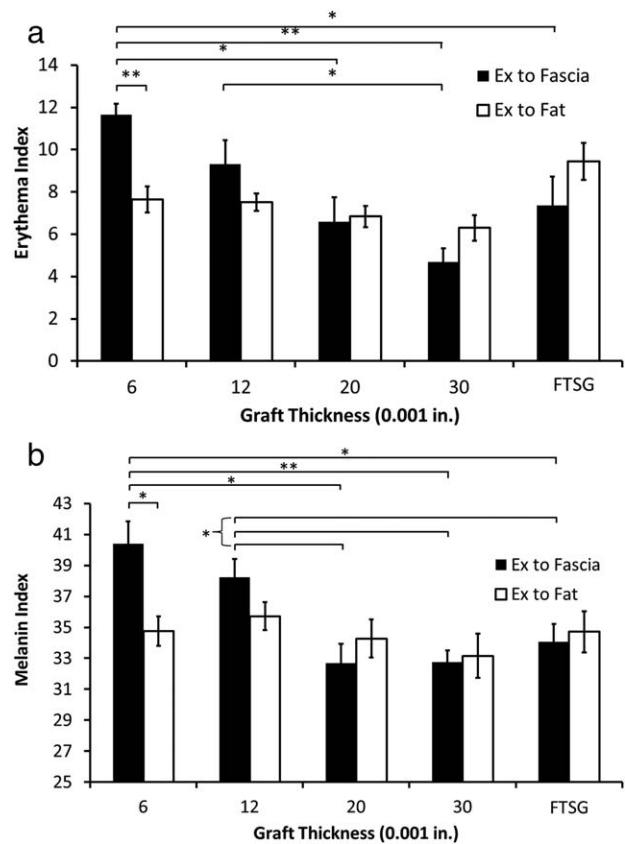
### Thin STSG grafted onto fat shows significant improvements in objective assessments of scar quality

While subjective measurement of skin quality is an accepted methodology for assessing the severity of scarring, some POSAS categories are amenable to objective analysis: melanization and erythema, both of which rely on colorimetry measurements. In light skinned individuals, the melanin content of scars is often increased, leading to poor cosmesis. Poor quality skin resulting from STSG is associated with enhanced capillary formation in the dermis, leading to increased scar redness. Erythema is a measure of the vascularity and hence of redness.

Using a colorimeter, we showed that the objective erythema measurements correlated well with our subjective measurements of vascularity (Figure 3A). In particular, when grafted onto fat the thinnest STSG showed statistically significant improvement over grafting onto fascia. Similarly, when compared with grafts onto fascia, objective measurements of melanization of the thinnest STSG grafted onto fat showed statistically significant improvement (Figure 3B).

### Thin STSGs grafted onto fat show improved collagen organization

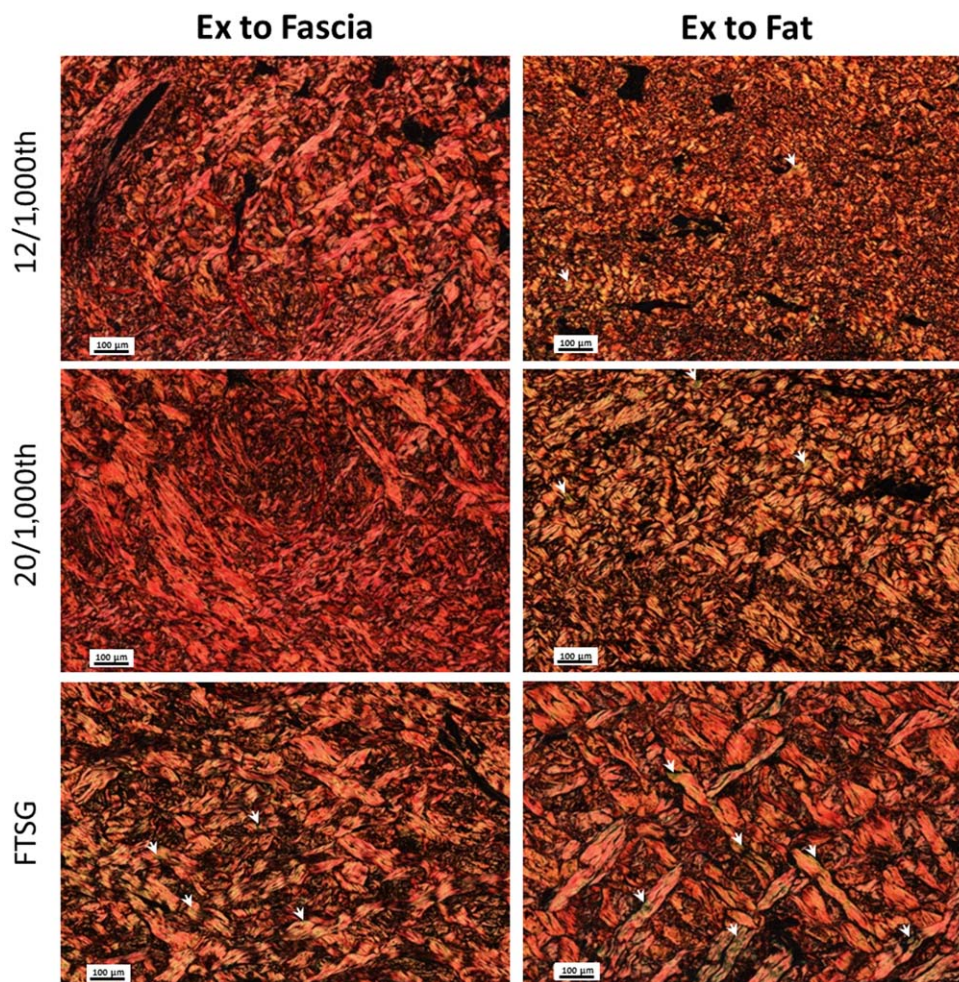
As indicated above, the nonpliable nature of poor quality skin, a negative feature associated with skin grafting, is



**Figure 3.** Objective measurements of skin quality. At day 120 all wounds were assessed for vascularity and melanization with a Cortex Technology DSMII Colorimeter. Based on the known absorption spectra of hemoglobin and melanin chromophores Y-axis values are reported as arbitrary numerical units with higher readings reflecting higher hemoglobin concentration (erythema) or higher pigmentation (melanin). (A) Erythema Index. (B) Melanin Index. Wounds were distributed among 19 pigs with the following wound *n* for fascia/fat: 6/1,000 = 8/9, 12/1,000 = 10/9, 20/1,000 = 8/8, 30/1,000 = 8/8, FTSG = 10/9. Statistical significance was determined by nonparametric pairwise comparison using Wilcoxon method and results are reported as mean  $\pm$  standard error of the mean. \* $p < 0.05$ , \*\* $p < 0.005$ .

primarily an effect of deposition of excessive amounts of disorganized collagen. Staining with picrosirius red and viewing under polarized light allows visualization of the collagen structure. As the fiber density increases the color changes from green to yellow to orange to red; as wound healing progresses, collagen fiber density increases.<sup>9</sup>

Picrosirius red staining for collagen on day 120 (Figure 4) showed differences between both the various autograft thicknesses and between the presence or absence of fat. Whether grafted on fat or fascia, staining of full-thickness grafts revealed interwoven collagen bundles. In addition, the orange coloration indicated that these bundles were not very dense, more closely resembling normal skin. We also observed an increase in green coloration in thin grafts on fat and in thicker grafts on both fat and fascia (Figure 4,



**Figure 4.** Collagen deposition and structure in grafts onto fascia vs. grafts onto fat. Picrosirius red stains collagen and is viewed under polarized light. As fiber density increases the color changes from green to yellow to orange and red. Biopsy samples at day 120 are shown for thin STSG (12/1,000th), thick STSG (20/1,000th) and full-thickness skin graft. White arrowheads indicate areas of green polarization.

white arrowheads), consistent with increased presence of type III collagen. Although difficult to quantify, the collagen in the FTSG grafted on fat appeared to demonstrate greater interweaving. By contrast, thinner grafts showed distinct differences between grafting onto fascia or fat. Thin grafts on fascia resulted in more intense red staining, indicating densely packed fibers. These fibers were also visibly much thinner. Both increased density and thin fibers are consistent with scar collagen.

**Grafting onto fat results in reduced numbers and duration of myofibroblasts**


To assess the status of the fibroblasts in the graft and wound bed, we used immunohistochemistry to stain for  $\alpha$ -SMA. Myofibroblasts are identified by the expression of  $\alpha$ -SMA.<sup>10</sup> When grafts are placed onto fat, myofibroblasts are observed in all wounds by day 7 except for the full thickness skin graft (Figure 5A). Followed out over time, myofibroblast staining wanes and disappears in a trend correlated with the thickness of the autograft. By contrast with grafts onto fat, grafts onto fascia demonstrate intense staining of myofibroblasts in all graft thicknesses, includ-

ing full-thickness grafts (Figure 5B). In addition, when compared with grafts on fat (dashed black line in Figure 5B), myofibroblasts stay in the wound longer (solid black line in Figure 5B). Enlarged versions of selected images are included as Supporting Information figures (Figure S2).

Pericytes surrounding capillaries also stain positive for  $\alpha$ -SMA, and when comparing grafts on fat to grafts on fascia, there appears to be more pericyte staining in grafts on fascia. This correlates well with our observations that grafts on fascia tend to exhibit increased vascularity compared to grafts on fat (Figures 2C and 3A).

**Grafts onto fat demonstrate reduced infiltration of immune cells**

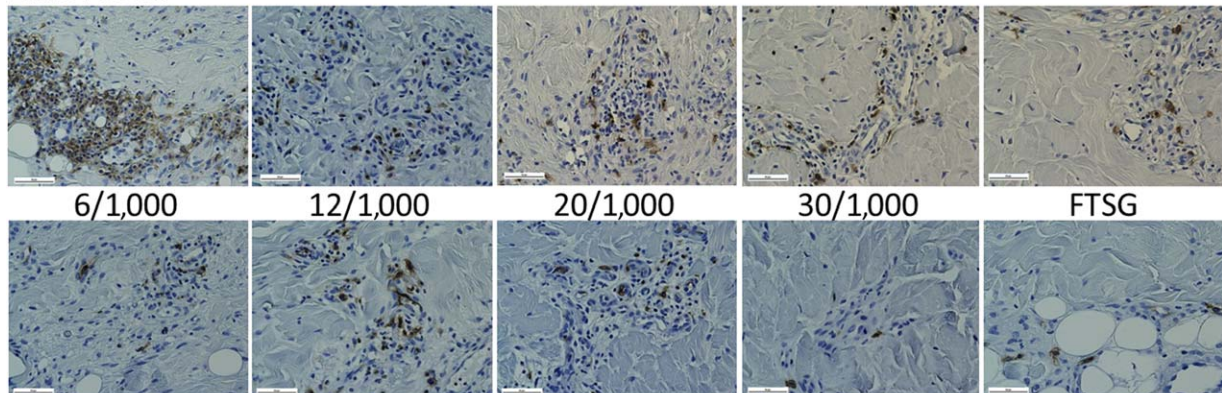
At day 7, we looked for differences in leukocyte infiltration between grafts on fat and grafts on fascia by staining for CD45, the leukocyte common antigen (LCA) (Figure 6). Although we did not observe any differences in thicker grafts, we did note enhanced staining of CD45 in the thinnest STSG (6/1,000th in.) grafted onto fascia. The inflammatory phase of wound healing is typically considered to



**Figure 5.** Immunohistochemical staining of  $\alpha$ -SMA in wounds excised down to (A) hypodermis or (B) fascia. Dark, highly localized staining in the upper portions of the cross-section represents pericytes (black arrowheads), which also express  $\alpha$ -SMA. More diffused staining in the host tissue and concentrated below the graft-host interface indicates presence of myofibroblasts. Solid black line indicates the time period at which intense staining of myofibroblasts subsides to near-background levels. The dashed black line in (B) represents the boundary from the excision-to-fat staining in (A), included for comparison.



## Ex to Fascia



## Ex to Fat

**Figure 6.** Immunohistochemical staining of CD45/LCA (Leukocyte Common Antigen). The presence of differential levels of CD45-expressing cells between grafts on fascia compared to grafts on hypodermis were noted only at day 7 postgraft and only for the thinnest graft (6/1,000th in.).

be waning or over by day 7, so it is possible that greater differences could be observed at earlier time points. In future studies, we anticipate incorporating earlier time points into our experiments.

## DISCUSSION

The negative long-term effect of applying thin skin grafts to wounds is the development of function-limiting contractures, especially when applied onto the face, hands, and over joints. The deformities resulting from contraction and other hypertrophic scarring can be corrected. However, this generally involves secondary scarred skin replacement either in the form of a skin graft or skin flap, and patients can commit years to multiple operations, significantly delaying their return to normal function. The ideal skin replacement therapy requires the fewest possible operations while achieving as many normal skin functions as possible, including: (1) barrier protective function; (2) elasticity to allow joint motion; (3) temperature homeostasis; and (4) aesthetic appearance.<sup>11–13</sup> The gold standard of skin replacement therapy is to substitute “like with like” and diminish the need for repeated skin replacements for mobility or cosmesis after acute skin replacement therapy. The gap in achieving satisfactory results lies in our inability to produce and maintain durable, fully functional skin.

To explore the role of the hypodermis in wound healing, wound contraction and scarring, we utilized a porcine model developed in our facility. Pigs have proven to be a useful animal model of human wound healing.<sup>14</sup> Unlike rodents, which primarily heal via contraction, pigs heal by reepithelialization. Again unlike rodents and more closely resembling human skin architecture, pigs also contain a subcutaneous fat layer. Since increased levels of melanin have been correlated with enhanced wound contraction in both humans<sup>15,16</sup> and pigs,<sup>17</sup> we utilized white Yorkshire pigs to avoid potential complicating factors.

In this study, we examined the role of hypodermis in scarring and contraction following application of split

thickness skin grafts. As we have previously shown, when skin grafts are grafted onto fat, the amount of contraction is negligible.<sup>8</sup> This is in stark contrast to grafts grafted onto fascia: the thinnest grafts on fascia contracted up to 50% of their original size. The proximate cause of graft contraction is the transition of fibroblasts into myofibroblasts in response to TGF- $\beta$  and PDGF.<sup>18,19</sup> The contractile force of actin in these cells results in the drawing together of the wound edges. When a skin graft is used to cover an open wound, the graft will contract with the wound bed, resulting in a ruffled, irregular surface. Thicker grafts are presumably better able to resist this contractile force, either by virtue of mechanical forces or because of alterations of the microenvironment. Our assessment of several subjective measures of scarring, including vascularity, pliability, and relief found in all cases that grafts onto fat performed as well as, or better than, grafts onto fascia. The improvement in these measures of scarring was especially notable in the thinnest grafts. Further, objective measurements of melanization and erythema using a colorimeter confirm this improvement in the thinnest grafts. The marked enhancement in thin STSG is especially significant for clinical practice because STSGs used in the clinic are typically in the range of 8–12/1,000th of an inch.

The maintenance of fat within the wound bed may modulate scarring and contraction in multiple ways. The research on the role of hypodermis in wound healing has heretofore been limited to retrospective clinical observations and case studies.<sup>2–5</sup> Little has been reported in terms of cellular contributions or molecular mechanisms. Our research suggests two possible contributions. First, the hypodermal layer may provide simple mechanical resistance to contraction. This is supported by the fact that despite the presence of myofibroblasts in the wound bed for extended periods of time in the thinnest grafts, contraction is minimal when those thinnest grafts are on fat. Others have also reported mechanical resistance to contraction offered by the hypodermal layer. When the hypodermal layer is surgically separated from the

underlying substrate in a skin flap model, contraction is increased.<sup>20</sup> Conversely, the diminished staining intensity and the shorter duration of myofibroblast presence in the wounds containing fat suggest additional factors are involved. Thus, a second possible mechanism is that the hypodermis alters the molecular microenvironment, resulting in different cell populations or different cytokines and growth factors. Adipose tissue is known to harbor populations of multipotent stem cells as well as to be a source of adipocytokines, such as adiponectin, which are anti-inflammatory, and leptins, which increase expression of VEGF.<sup>21</sup> Of course, these two hypotheses are not mutually exclusive. Mechanical forces are capable of altering gene expression via interactions with integrins and focal adhesions.<sup>22</sup>

The mechanism by which fat influences scarring isn't always clear and may be indirect. The effect of fat on the topography of the graft surface (relief) is almost certainly related to its inhibition of contraction. When the wound bed contracts, the graft is bunched up, resulting in a ruffled appearance that may be only partly modified in the ensuing months.

By contrast, vascularity and erythema are a reflection of increased numbers of capillaries and are therefore more likely influenced by alterations of the microenvironment, such as changes in expression of angiogenic factors like VEGF. VEGF is produced by numerous cells in the wound, both resident mesenchymal cells and infiltrating immune cells. The apparent reduction in staining of pericytes in thin STSGs on fat suggests that fat alters the angiogenic trajectory of wound healing. This is supported by the reported upregulation of proangiogenic factors by adipocytes,<sup>23</sup> consistent with our observation of reduced numbers of inflammatory cells in thin STSGs on fat. Numerous reports in the literature cite the anti-inflammatory effects of adipocytes and adipose derived stem cells.<sup>24–27</sup> However, it has also been reported that fat grafting accelerates vascularization following burn injury.<sup>4</sup> Early during wound healing, the enhanced metabolic needs of cells in the wound induce a hyperproliferation of capillary tubes. However, once the proliferation phase is complete and the metabolic requirements of the resident cells are reduced, the excess capillaries are degraded.<sup>28</sup> Perhaps fat tissue not only enhances vascularity of the wound bed, but also positively regulates the reduction in the numbers of capillaries in the remodeled scar tissue.

The mobility or pliability of the scar tissue is a reflection of the connective tissue laid down during scar remodeling. The structure of the collagen in grafts on fat more closely resembled the collagen architecture of normal skin, both in the thickness and density of fibers, as well as their organization. This suggests that the presence of fat alters the deposition and remodeling of collagen by fibroblasts, which is again an effect mediated either directly or indirectly by changes in the microenvironment. One of the indirect effects of adipose tissue is the inhibition of inflammation. Inflammation stimulates fibroblasts to transdifferentiate into myofibroblasts which results in both scar contraction and prolific collagen deposition, an effect that our data shows is attenuated by the presence of fat.

Based on the observations described above, we conclude that the presence of hypodermis influences the cellular environment of the wound in ways that result in reduced

scarring and contraction. In surgical environments, it is not always possible to retain hypodermis. However, our work suggests that when possible, hypodermis should be retained in the wound bed. Alternatively, restoration of hypodermis prior to STSG may be a viable option to reduce the need for future contracture releases and secondary skin replacements. It may even be possible to induce scar remodeling by grafting of fat underneath existing scars.<sup>4,29–32</sup> Regardless of which method may be useful in a given situation, it is clear that the hypodermis plays an underappreciated role in the wound healing process.

The mechanism by which fat influences scarring and contraction is still unknown but likely involves a combination of mechanical resistance and alterations in the cytokines and growth factors present in the wound bed. Some of the parameters measured for the comparison of STSG on fascia vs. fat are more qualitative in nature (e.g., myofibroblasts and CD45 + cells). Future studies will include quantification and characterization of these parameters in wounds under different test conditions using cell fractionation and sorting. Furthermore, we will seek to elucidate these mechanisms by tying healing and scarring outcomes to changes in wound tissue gene expression as well as in resident stromal cells or infiltrating leukocytes.

*Conflict of interest:* The authors have no disclosures to report.

*Source of funding:* Funding for this research is provided through the US Army Medical Research and Materiel Command, Clinical Rehabilitative Medicine Research Directorate.

## REFERENCES

1. Padgett EC. Indications for determination of the thickness of split skin grafts. *Am J Surg* 1946; 72: 683–93.
2. Corps BV. The effect of graft thickness, donor site and graft bed on graft shrinkage in the hooded rat. *Br J Plast Surg* 1969; 22: 125–33.
3. Jones T, McDonald S, Deitch EA. Effect of graft bed on long-term functional results of extremity skin grafts. *J Burn Care Rehabil* 1988; 9: 72–4.
4. Sultan SM, Barr JS, Butala P, Davidson EH, Weinstein AL, Knobel D, et al. Fat grafting accelerates revascularisation and decreases fibrosis following thermal injury. *J Plast Reconstr Aesthet Surg* 2012; 65: 219–27.
5. Schneider JC, Holavanahalli R, Helm P, Goldstein R, Kowalske K. Contractures in burn injury: defining the problem. *J Burn Care Res* 2006; 27: 508–14.
6. Draaijers LJ, Tempelman FR, Botman YA, Tuinebreijer WE, Middelkoop E, Kreis RW, et al. The patient and observer scar assessment scale: a reliable and feasible tool for scar evaluation. *Plast Reconstr Surg* 2004; 113: 1960–5; discussion 1966–7.
7. van de Kar AL, Corion LU, Smeulders MJ, Draaijers LJ, van der Horst CM, van Zuijlen PP. Reliable and feasible evaluation of linear scars by the Patient and Observer Scar Assessment Scale. *Plast Reconstr Surg* 2005; 116: 514–22.
8. Chan RK, Rose LF, Wu JC, Tucker DI, Chan MC, Christy R, et al. Autologous graft thickness affects scar contraction and skin quality in a porcine excisional wound model. *Plast Reconstr Surg* 2015. In press.

9. Rich L, Whittaker P. Collagen and picrosirius red staining: a polarized light assessment of fibrillar hue and spatial distribution. *Braz J Morphol Sci* 2005; 22: 97–104.
10. Bertolami C, Donoff RB. The effect of full-thickness skin grafts on the actomyosin content of contracting wounds. *J Oral Surg* 1979; 37: 471–6.
11. Proksch E, Brandner JM, Jensen JM. The skin: an indispensable barrier. *Exp Dermatol* 2008; 17: 1063–72.
12. Madison KC. Barrier function of the skin: “la raison d’être” of the epidermis. *J Invest Dermatol* 2003; 121: 231–41.
13. Burkitt HG, Young B, Heath JW. *Wheater’s functional histology*, 3rd ed. New York, NY: Churchill Livingstone, 1993.
14. Sullivan TP, Eaglstein WH, Davis SC, Mertz P. The pig as a model for human wound healing. *Wound Repair Regen* 2001; 9: 66–76.
15. Ketchum LD, Cohen IK, Masters FW. Hypertrophic scars and keloids. A collective review. *Plast Reconstr Surg* 1974; 53: 140–54.
16. Gao FL, Jin R, Zhang L, Zhang YG. The contribution of melanocytes to pathological scar formation during wound healing. *Int J Clin Exp Med* 2013; 6: 609–13.
17. Gallant CL, Olson ME, Hart DA. Molecular, histologic, and gross phenotype of skin wound healing in red Duroc pigs reveals an abnormal healing phenotype of hypercontracted, hyperpigmented scarring. *Wound Repair Regen* 2004; 12: 305–19.
18. Watts GT, Grillo HC, Gross J. Studies in wound healing: II. The role of granulation tissue in contraction. *Ann Surg* 1958; 148: 153–60.
19. Gross J, Farinelli W, Sadow P, Anderson R, Bruns R. On the mechanism of skin wound “contraction”: a granulation tissue “knockout” with a normal phenotype. *Proc Natl Acad Sci USA* 1995; 92: 5982–6.
20. Ford CN, Anderson AG, Jr. Techniques to enhance utilization of advancement flaps. *Arch Otolaryngol* 1983; 109: 449–53.
21. Tilg H, Moschen AR. Adipocytokines: mediators linking adipose tissue, inflammation and immunity. *Nat Rev Immunol* 2006; 6: 772–83.
22. Fouchard J, Bimbarde C, Bui N, Durand-Smet P, Proag A, Richert A, et al. Three-dimensional cell body shape dictates the onset of traction force generation and growth of focal adhesions. *Proc Natl Acad Sci USA* 2014; 111: 13075–80.
23. Aleffi S, Petrai I, Bertolani C, Parola M, Colombatto S, Novo E, et al. Upregulation of proinflammatory and proangiogenic cytokines by leptin in human hepatic stellate cells. *Hepatology* 2005; 42: 1339–48.
24. Martinez-Gonzalez I, Cruz MJ, Moreno R, Morell F, Muñoz X, Aran JM. Human mesenchymal stem cells resolve airway inflammation, hyperreactivity, and histopathology in a mouse model of occupational asthma. *Stem Cells Dev* 2014; 23: 2352–63.
25. Singer K, Morris DL, Oatmen KE, Wang T, DelProposto J, Mergian T, et al. Neuropeptide Y is produced by adipose tissue macrophages and regulates obesity-induced inflammation. *PLoS One* 2013; 8: e57929.
26. Jiang D, Qi Y, Walker NG, Sindrilaru A, Hainzl A, Wlaschek M, et al. The effect of adipose tissue derived MSCs delivered by a chemically defined carrier on full-thickness cutaneous wound healing. *Biomaterials* 2013; 34: 2501–15.
27. Chen YT, Sun CK, Lin YC, Chang LT, Chen YL, Tsai TH, et al. Adipose-derived mesenchymal stem cell protects kidneys against ischemia-reperfusion injury through suppressing oxidative stress and inflammatory reaction. *J Transl Med* 2011; 9: 51.
28. Davis GE, Saunders WB. Molecular balance of capillary tube formation versus regression in wound repair: role of matrix metalloproteinases and their inhibitors. *J Invest Dermatol Symp Proc* 2006; 11: 44–56.
29. Roh MR, Jung JY, Chung KY. Autologous fat transplantation for depressed linear scleroderma-induced facial atrophic scars. *Dermatol Surg* 2008; 34: 1659–65.
30. Patel N. Fat injection in severe burn outcomes: a new perspective of scar remodeling and reduction. *Aesthetic Plast Surg* 2008; 32: 470–2.
31. Klinger M, Caviggioli F, Klinger FM, Giannasi S, Bandi V, Banzatti B, et al. Autologous fat graft in scar treatment. *J Craniofac Surg* 2013; 24: 1610–5.
32. Coleman SR. Structural fat grafting: more than a permanent filler. *Plast Reconstr Surg* 2006; 118 (3 Suppl): 108S–120S.

## Supporting Information

Additional Supporting Information may be found in the online version of this article.

**Figure S1.** Wound distribution. Ten 6-cm wounds were tattooed and excised down to fascia or fat. Two circles were tattooed but not excised to serve as growth controls. All wounds were separated from each other by 4 cm and were two cm from the backbone. Graft harvest sites are indicated by rectangles on the hindquarters of the pig.

**Figure S2.** (A) Immunohistochemical staining for alpha-smooth muscle actin (alpha-SMA). Enlarged image of 20/1,000th in. skin graft at Day 7 following grafting onto fascia. (B) Immunohistochemical staining for alpha-smooth muscle actin (alpha-SMA). Enlarged image of 2/1,000th in. skin graft at Day 7 following grafting onto fat.