

AD _____

Award Number: W81XWH-09-2-0059

TITLE: SEALING PENETRATING EYE INJURIES USING
PHOTOACTIVATED BONDING

PRINCIPAL INVESTIGATOR: Anthony Johnson

CONTRACTING ORGANIZATION: Henry M. Jackson Foundation For the Advancement
of Military Medicine
Rockville, MD 20852

REPORT DATE: October 2014

TYPE OF REPORT: Final

PREPARED FOR: U.S. Army Medical Research and Materiel Command
Fort Detrick, Maryland 21702-5012

DISTRIBUTION STATEMENT: Approved for public release; distribution unlimited

The views, opinions and/or findings contained in this report are those of the author(s) and should not be construed as an official Department of the Army position, policy or decision unless so designated by other documentation.

REPORT DOCUMENTATION PAGE		<i>Form Approved</i> <i>OMB No. 0704-0188</i>	
Public reporting burden for this collection of information is estimated to average 1 hour per response, including the time for reviewing instructions, searching existing data sources, gathering and maintaining the data needed, and completing and reviewing this collection of information. Send comments regarding this burden estimate or any other aspect of this collection of information, including suggestions for reducing this burden to Department of Defense, Washington Headquarters Services, Directorate for Information Operations and Reports (0704-0188), 1215 Jefferson Davis Highway, Suite 1204, Arlington, VA 22202-4302. Respondents should be aware that notwithstanding any other provision of law, no person shall be subject to any penalty for failing to comply with a collection of information if it does not display a currently valid OMB control number. PLEASE DO NOT RETURN YOUR FORM TO THE ABOVE ADDRESS.			
1. REPORT DATE (DD-MM-YYYY) October 2014	2. REPORT TYPE FINAL	3. DATES COVERED (From - To) 30Sep2010 - 14Jul2014	
4. TITLE AND SUBTITLE SEALING PENETRATING EYE INJURIES USING PHOTOACTIVATED BONDING		5a. CONTRACT NUMBER	
		5b. GRANT NUMBER W81XWH-09-2-0059	
		5c. PROGRAM ELEMENT NUMBER	
6. AUTHOR(S) Anthony Johnson and Irene Kochevar email: anthony.j.johnson138.mil@mail.mil		5d. PROJECT NUMBER	
		5e. TASK NUMBER	
		5f. WORK UNIT NUMBER	
7. PERFORMING ORGANIZATION NAME(S) AND ADDRESS(ES) Henry M. Jackson Foundation For the Advancement of Military Medicine Rockville, MD 20852		8. PERFORMING ORGANIZATION REPORT NUMBER	
9. SPONSORING / MONITORING AGENCY NAME(S) AND ADDRESS(ES) U.S Army Medical Research and Materiel Command Fort Detrick, Maryland 21702-5012		10. SPONSOR/MONITOR'S ACRONYM(S)	
		11. SPONSOR/MONITOR'S REPORT NUMBER(S)	
12. DISTRIBUTION / AVAILABILITY STATEMENT Approved for public release; distribution unlimited			
13. SUPPLEMENTARY NOTES			
14. ABSTRACT Purpose: To develop a light-activated technology with the potential to decrease vision loss and ocular complications in warfighters sustaining penetrating eye injuries. Scope: To establish, in ex vitro and in vivo animal models, the treatment parameters for sealing corneal and scleral penetrating wounds and to close lacerations in thin (eyelid-like) skin. To design and evaluate a prototype light delivery device. Major findings: We established that bonding amniotic membrane over penetrating cornea and scleral wounds produced immediate, water-tight seals that withstood an intraocular pressure of 350 mm Hg. We closed lacerations in eyelid-like skin with the dye +light treatment, which showed less inflammation than after sutured closure, and closed corneal and scleral lacerations with minimal inflammation noted in suture or light treated eyes. A prototype light delivery system was designed, constructed and tested to deliver retina-safe light levels while providing light levels sufficient for sealing amniotic membrane over corneal wounds. Studies demonstrated that thermal damage to the iris is not a concern.			
15. SUBJECT TERMS ectropion, cornea, burn scars, amniotic membrane, protein crosslinks, photomedicine, photochemistry			
16. SECURITY CLASSIFICATION OF:	17. LIMITATION OF ABSTRACT	18. NUMBER OF PAGES	19a. NAME OF RESPONSIBLE PERSON USAMRMC

a. REPORT U	b. ABSTRACT U	c. THIS PAGE U	UU	42	19b. TELEPHONE NUMBER (include area code)
----------------	------------------	-------------------	----	----	-------------------------------------------

Standard Form 298 (Rev. 8-98)
Prescribed by ANSI Std. Z39.18

Table of Contents

	Pg
Introduction	3
Body	3
Key Research Accomplishments	6
Reportable Outcomes	7
Conclusion	7
References.....	8
Appendix 1.....	9
Appendix 2-9.....	12

INTRODUCTION:

The overall goal of this research was to find a more efficient method of sealing complex corneal lacerations. The technology that we used to achieve this goal was to develop a light-activated technology in which amniotic membrane impregnated with Rose Bengal dye (a common photoactive vital dye used as a diagnostic tool for staining ocular surface abnormalities) was cross-linked to the surface of the cornea to achieve a water-tight seal.

Fragments and debris propelled at high velocity by improvised explosive devices (IEDs) have increased the incidence of penetrating eye injuries in the current conflicts. At the height of this conflict, 29% of all evacuations from Iraq were due to ocular injuries.¹ When an eye sustains a penetrating or perforating injury rapid closure with the formation of a water tight seal is critical to preventing infection and preventing surface epithelium from gaining entry into the eye. This stabilizes the eye until further reconstructive surgery can occur. Despite the fact that the normal human eye is only 24mm in diameter, the repair of this structure can take in excess of 4 hours in severe injuries, and involves the use of an operative microscope and placement of suture that are thinner than the human hair. This suturing requires specialized training. In complex lacerations, in which flat objects are propelled through the cornea, the lamella of the cornea can shred, making closure by suture impossible. In these cases surgical adjuncts are used to close the wound, none of which are approved by the FDA for this purpose. The most commonly used item is Cyanoacrylate glue (medical super glue). The cyanoacrylate glue can bind to the cornea surface creating a water-tight seal. Unfortunately, it sticks to the sutures and is difficult to remove. Additionally it is opaque preventing any further operative procedures.

Our method is rapid and uses currently FDA approved materials/devices (clinical laser, rose Bengal dye, amniotic membrane) and thus may be moved rapidly to the deployed environment with materials already in the ophthalmic surgical set.

The scope of my research involved evaluating the clinical methodology to employing this light-activated closing of penetrating injuries, and evaluating the clinical response to this new technique in comparison to suture closure (the current standard of care).

BODY

This research project is a translational research project involving a collaboration between myself and Dr. Irene Kochevar from the Wellman Group, Department of Dermatology, Massachusetts General Hospital, Boston. In this project, through telephone consultation with myself, Dr. Kochevar developed designed, and constructed the argon green laser delivery hand piece, the laser parameters, and treatment thresholds for the rabbit.² I then performed experimentation in vivo using the New Zealand White Rabbit to perfect the surgical technique and to evaluate the clinical and histopathological effects of this technique compared to suture closure.

This report describes the results of clinical studies carried out at the United States Army Institute of Surgical Research. Dr. Kochevar submitted a separate final report.

Brief Summary

We established the light-activated treatment parameters that produce strong, immediate water-tight sealing of penetrating cornea and sclera wounding. We determined that in abattoir eyes the sealing withstood an intraocular pressure of 350 mm Hg, more than 10 times normal pressure.² In a live rabbit model this technique was also effective obtaining a water tight closure to physiologic pressures, without evidence of thermal damage to the iris or cornea structures. Dr. Kochevar further demonstrated that lacerations of thin skin in a mouse, similar to the skin of the eyelid could also be sealed with this technique. In the skin model the light activated technique sealed with less

inflammation that suture closure, and in the live rabbit eye, similar low levels of inflammation were present with both suture and light activated closure techniques.³

A prototype light delivery system was designed, constructed and tested to deliver diffuse retina-safe light levels while providing light levels sufficient for sealing corneal wounds. All studies employed a clinical laser, that emits light at 532 nm. The dye used, Rose Bengal, is approved for diagnosis of corneal defects, and human amniotic membrane is a FDA-allowed device for treatment of corneal abnormalities and ocular surface reconstruction.

Task 1. Evaluate photo-activated bonding for sealing amniotic membrane over cornea lacerations.

During years 1 and 2 of the study, Dr. Kochevar conducted ex vivo studies determining the appropriate laser parameters for sealing the amniotic membrane to the surface of the eye. As a corneal surgeon I provided consultation in perfecting the appropriate surgical technique. Additionally, I was able to assist in the technique development via 2 on site visits, in which I was able to visit her laboratory while in Boston for unrelated medical conferences.

Once her technique and laser parameters were developed, during the 3rd year and during my extension year I evaluated the technique in live rabbits. To evaluate this procedure I conducted an initial model development experiment in which the in-vivo technique was perfected and then 2 separate experiments. In the model development stage we determined that due to gaping of the central lacerations and the larger V shaped laceration, and brisk aqueous outflow, a direct closure with amniotic membrane was near impossible, and put the patient at risk because the scar required to fill the gap would decrease visual function, the amniotic membrane over the gap would tectonically be too weak, and the brisk outflow would also prevent adhesion of the amnion to the cornea prior to crosslinking. (this was not evident in the abattoir eyes because there was no aqueous outflow and the low pressure did not cause wound gap). Thus the technique was modified to place one suture in the wound to approximate the corneal stromal surfaces. This accomplished three things. It minimized the scar size, tectonically strengthen the cornea and allowed air or viscoelastic to block the outflow of aqueous sufficient to crosslink amnion to the cornea.

Technique:

In experiment 1, I performed a simple 4mm length laceration in the center of the visual axis of 30 New Zealand White Rabbits. Half of the rabbits were repaired with 10-0 nylon sutures, and the other half were repaired with light-activated bonding. Each treatment group was further subdivided into 3, 7 and 28 days, for clinical and pathologic evaluation.

The rabbit was placed under anesthesia by the Veterinary technicians, then prepped and draped in the normal sterile fashion for eye surgery. A lid speculum was placed in the eye and centered under the operating microscope. A surgical ruler was used to measure the central 4mm of the cornea and 2 dots were placed. A diamond knife was then used to make a central laceration between the dots. (this resulted in a gaping of the wound and collapse of the anterior chamber). Then epithelium in the center of the cornea was debrided. Viscoelastic was injected into the wound to protect the lens and deepen the chamber. One central 10-0 nylon suture was placed. Pre-prepared amniotic membrane impregnated with Rose Bengal was then placed on the cornea, centered on the wound. The amnion was gently stroked with a 27 gauge cannula until it dried sufficiently that it was tacky to the cornea. The microscope was moved, the laser hand piece was centered over the wound and the amnion was irradiated. Laser Parameters 400 mw/Continuous Wave/ 13mm diameter beam/ 250 seconds. (***Over 1000 seconds exceeded the calculated safety threshold. Dr. Kochevar successfully cross-linked the amnion at 400 seconds. 250 seconds gave about 90% strength- we used 250 seconds). Thus at 400s 2 attempts could be made, and at 250 3-4 tries).*²

Afterwards the wound was tested for water-tightness with fluorescein staining, and a tonopen was used to ensure the eye was at physiologic pressure.

In experiment 2, first a small peripheral paracentesis was placed to control the anterior chamber. Then a V shaped laceration, in an equilateral triangle configuration, with each leg 3mm was made. The epithelium was debrided. Again viscoelastic was injected to deepen the chamber. One 10-0 nylon suture was placed at the apex. Air was injected into the A/C using either the central wound or paracentesis. When no aqueous outflow was noted, the amnion was placed and stroked to sufficient tackiness, and the cornea was irradiated (using the same parameters as above). Afterwards the wound was tested for water-tightness with fluorescein staining, and a tonopen was used to ensure the eye was at physiologic pressure.

The cross-linked repaired rabbits were compared to an equal number of rabbits in which the lacerations were repaired with sutures. The techniques between the two arms were similar except that I did not need to debride the epithelium in the suture closure, and sealed the wounds with 5 simple interrupted 10-0 nylon sutures.

Task 2. Evaluate photo-activated bonding for sealing amniotic membrane over scleral lacerations.

Utilizing the knowledge gained on the first 2 experiments, we performed the final laceration experiment. Due to the difference in tissue types we used a combined corneal-scleral laceration. Dr. Kochevar had noted the strength of the sealing scleral lacerations in her experiments. Due to the presence of the vitreous cavity (with no aqueous outflow), there was less difference between the abattoir eye and in-vivo rabbit experiments, hence our choice of a more complex model.

Technique:

In experiment 3, I performed a 4mm length laceration that straddled the limbus of 30 New Zealand White Rabbits. Half of the rabbits were repaired with 10-0 nylon sutures, and the other half were repaired with light-activated bonding. Each treatment group was further subdivided into 3, 7 and 28 days, for clinical and pathologic evaluation.

The rabbit was placed under anesthesia by the Veterinary technicians, then prepped and draped in the normal sterile fashion for eye surgery. A lid speculum was placed in the eye and centered under the operating microscope. A 3 clock hour peritomy was placed from 10 o'clock until 1 o'clock, on the rabbit eye. A surgical ruler was used to measure the 4mm lacerations, centered on the limbus in the 11:30 meridian. Two dots were placed at each end of the laceration. A diamond knife was then used to make a laceration between the dots. (this resulted in a gaping of the wound and collapse of the anterior chamber). Then epithelium in the cornea aspect of the laceration was debrided, additionally I scrapped the scleral surface to include the surface of collagen available to crosslink. Viscoelastic was injected into the wound to protect the lens and deepen the chamber. One central 10-0 nylon suture was placed, across the limbus. Pre-prepared amniotic membrane impregnated with Rose Bengal was then placed on the limbus, centered on the wound. The amnion was gently stroked with a 27 gauge cannula until it dried sufficiently that it was tacky. The microscope was moved, the laser handpiece was centered over the wound and the amnion was irradiated. Laser Parameters 400 mw/Continuous Wave/ 13mm diameter beam/ 250 seconds. (***Over 1000 seconds exceeded the calculated safety threshold. Dr. Kochevar successfully cross-linked the amnion at 400 seconds. 250 seconds gave about 90% strength- we used 250 seconds). Thus at 400s 2 attempts could be made, and at 250 3-4 tries*). After the crosslinking procedure was finished, the peritomy was repaired, and the wounds were check with fluorescein staining (siedel test) to ensure water tightness. A tonopen and finger tension was used to verify physiologic pressure. Then subconjunctival injections of vigamox (commercial preparation), and Dexamethasone4mg/ml (0.3cc) was injected.

The cross-linked repaired rabbits were compared to an equal number of rabbits in which the lacerations were repaired with sutures. The techniques between the two arms were similar except that I did not need to debride the epithelium in the suture closure, and sealed the wounds with 9-0 nylon across the sclera, 8-0 nylon on the sclera and 10-0 nylon across the cornea.

Findings:

Histopathological analysis of the eyes was performed by Dr. Rose Grimm, Vet Pathology. Statistical Analysis of the histopathological grading system was provided by Dr. James Aden. I performed slit lamp photo analysis.

The following criteria were used to evaluate the groups: Edema, Epithelial Degeneration, Stromal Thickening, Endothelial necrosis, Inflammation (mononuclear and Polymorphonuclear), and the Amount of Neovascularization. (scaled score 0-4: 0=none, 1=minimal, 2=mild, 3=moderate, 4=severe). For the amount of inflammation Dr. Rose Grimm counted the number of inflammatory cells /hpf.

We utilized a 2-way ANOVA to evaluate the effects of using laser vs. suture at all the various time points, in order to understand the healing response to our interventions. Additional analysis between laser closure and suture closure demonstrated no difference in neovascularization, endothelial necrosis, inflammation, edema or stromal thickening between the 3 treatment arms.

(See Appendix 1)

Between suture repair and Crosslinking repair for the same time points there were no statistically differences in any of the categories except epithelial hyperplasia at day 3, reflecting the healing of the surface after scraping, and neovascularization with none of the animals scoring over 1 on the 0-4 scale. Per the comments of the pathologist the neovascularization noted was related to anterior chamber and iris changes that the rabbit developed while the anterior chamber was flat. (on two rabbits the iris stuck to the underside of the cornea-noted on slit lamp evaluation). This is not an uncommon response and likewise occurs in humans when the iris comes in contact with cornea for a period of time and the iris is irritated or inflamed. This could contribute to gradual loss of endothelial cells, and could prompt a return to the operating room in the future to remove the iris if the adhesion was significant or evidence of endothelial failure was present. There appeared to be no neovascularization responses to the cross-linking procedure in the wounds.

On Slit lamp evaluations, the sutured corneas remained clearer than the cross-linked corneas at the 3 and 7 day time points. At 28 days there were no significant differences. Of note, by 7 days all the corneas were sufficiently clear to see iris detail, sufficient to have allow reconstructive surgery to be performed.

Key Research Accomplishments (Johnson and Kochevar)

- Identified the PTB treatment parameters that produce strong bonding of an amnion patch over corneal wounds, and scleral wounds in ex vivo, and in vivo rabbit eyes.
- Determined that a fluence of 100 J/cm² of 532 nm (green) laser light strongly bonds a Rose Bengal-stained amnion patch over a penetrating corneal injury in the central cornea in vivo. The seal formed resists opening at intraocular pressures up to 350 mm Hg, >15 times higher than the normal intraocular pressure in abattoir eyes, and physiologic pressure in in vivo eyes (we did not test maximum pressures in in-vivo rabbit eyes).
- Determined that sealing penetrating cornea wounds using a dye-stained amniotic membrane patch and green light is superior to direct photo-activated bonding of the wound walls, due to the aqueous outflow present in simple lacerations. It may be possible to direct bond however we would have to develop a gel or product resistant to the aqueous outflow.
- Identified the treatment parameters for strongly sealing amniotic membrane over a puncture

wound in sclera using light-activated bonding. The amnion patch size and shape, and light fluence were established for the subsequent in vivo study.

- Demonstrated that PTB can be used to seal lacerations in thin skin (e.g., eyelid or periorbital skin) without deep sutures and that the repair requires less time than suturing and stimulates less inflammation than sutures.
- Designed and constructed a light delivery system for direct light-activated bonding of penetrating injuries in the central cornea. The irradiance at the retina is below the thresholds for damage when using the fluences that bond amnion to the cornea surface.
- Demonstrated that the prototype retina-safe optical delivery system effectively seals amnion to cornea and substantially reduces the treatment time compared to our conventional fiber system.
- Established that the irradiation parameters used to seal amnion over cornea wounds are below the threshold for thermal damage to the iris.
- Developed the surgical technique to produce water-tight bonding of the amnion patch to the cornea and sclera in simple, complex and cornea-scleral lacerations
- Demonstrated that histopathologically, the amnion patched corneas did not cause any adverse reactions in the rabbits, despite previous reports of granulomatous inflammation associated with the use of amniotic membrane in albino rabbits.⁵

REPORTABLE OUTCOMES

1. Verter EE, Gisel TE, Yang P, Johnson AJ, Redmond RW, Kochevar IE. Light-initiated bonding of amniotic membrane to cornea. Invest Ophthalmol Vis Sci. 2011 Dec 9;52(13):9470-7.
2. Yang P, Yao M, DeMartelaere SL, Redmond RW, Kochevar IE. Light-activated sutureless closure of wounds in thin skin. Lasers Surg Med. 2012 Feb;44(2):163-167.
3. Johnson AJ, Cora S, Ecklund B, Wang H-C, Remond RW, Verter E, Kochevar IE. Crosslinking Repair of Corneal Lacerations In the New Zealand White Rabbit. Poster presented at the 2013 Military Health System Research Symposium (MHSRS), Fort Lauderdale FL, August 12-15, 2013.
4. Light-initiated bonding of amniotic membrane to cornea. E. Verter, A.J. Johnson, T. Gisel, P. Yang, R.W. Redmond and I.E. Kochevar. Platform presentation at the 2011 ATACCC Conference, Fort Lauderdale FL, August 15-18, 2011.
5. Rose Bengal photosensitized crosslinking of collagen for repair of penetrating eye injuries E. Verter, M. Yao, A. Blanden, A.J. Johnson, R.W. Redmond and I.E. Kochevar, Invited Presentation at the American Society for Photobiology Annual Meeting, June 12-16, 2011, Providence RI
6. Light-activated technology for repair and regeneration after traumatic injury. I. E. Kochevar and R.W. Redmond, ATACCC 2010 Conference, August 16-19, St. Pete Beach FL (Poster # RM14).
7. Photoactivated technology for repair of penetrating eye injuries. E. Verter, A.J. Johnson, M. Yao, R.W. Redmond and I.E. Kochevar. Poster presented at the 4th Military Vision Symposium, Schepens Eye Research Institute, Boston, MA, September 27-29, 2010

CONCLUSIONS

The results of these studies established that a light-activated method can be used for sealing penetrating wounds in the cornea, sclera and for lacerations in eyelid skin. In all applications a strong seal was produced immediately. The best method for sealing corneal and scleral wounds is to bond amniotic membrane over the wound using a dye and green laser light, after any significant gaps in the stroma have been reduced with sutures. Thus, for these experiments this technology appears to be best employed as an adjunct to sutures in cases with brisk aqueous outflow, as occurs in simple lacerations.

In war, many of the lacerations that occur results from a combination of blunt trauma and sharp trauma (i.e, objects are propelled that strike the cornea and lacerate at the same time- personal observation.) In such cases the significant trauma to the anterior segment results in intraocular bleeding and clot formation, along with a reduction of aqueous outflow. Having repaired 130 of these lacerations/globe ruptures in war, only a small minority occurred in which I had to contend with brisk aqueous outflow. It is therefore possible that in actual combat the light-activated technique might be more readily used (without the need of sutures) since there is rarely aqueous outflow issues in significant traumatized eyes in which blunt trauma forces occur.

Lacerations in thin skin were closed by bonding the wound edges together. The advantages of using this sutureless and glueless method for repair of eye wounds and eyelid/periorbital skin lacerations include formation of an immediate water-tight seal without tedious, time-consuming suturing and avoiding damage to eye tissues caused by sutures and glues that leads to scarring. We did not identify problems or obstacles that will inhibit the translation of this light-activated repair technique to clinical use. In addition, this treatment involves off-label use of three FDA-allowed materials/devices (clinical laser, Rose Bengal dye, human amniotic membrane), which may facilitate translation to the clinic.

The clinical and histological evaluations of the rabbits did not find any significant difference between suture closure and Light activated bonding. Interestingly, we were made aware of a small study which indicated that New Zealand rabbits develop a significant immune response to human amniotic membrane after 10 days. Our pathologist reviewed the previous paper⁵ and then our pathologic specimens and did not find evidence of this immune response in our study.

REFERENCES

1. Joint Theater Trauma Report, provided by Robert Mazzoli, Evacuation incidents 2002-2012.
2. E. Eri Verter, Thomas E Gisel, Penggao Yang, Anthony J Johnson, Robert W Redmond, and Irene Kochevar, Light-Initiated Bonding of Amniotic Membrane to Cornea, IOVS, December 2011, vol 52, no. 13, 9470-9477.
3. Irene Kochevar, Final Report: Sealing Penetrating Eye injuries with Photoactivated bonding, September 2013.
4. American National Standard for Safe Use of Lasers (ANSI 136.1-2000). *The Laser Institute of America. Orlando FL.*
5. Keith Barton, Donald L Budenz, Peng T. Khaw, and Scheffer C. G. Tseng, Glaucoma Filtration Surgery using Amniotic Membrane Transplantation. IOVS, July 2001, vol 42, No. 8, 1762-1768.

Personnel supported by this grant

All personnel are employed at USAISR

Stephen Cora, technician

Stephanie Roth (year 1), technician

Jennifer Crawford (year 2) technician

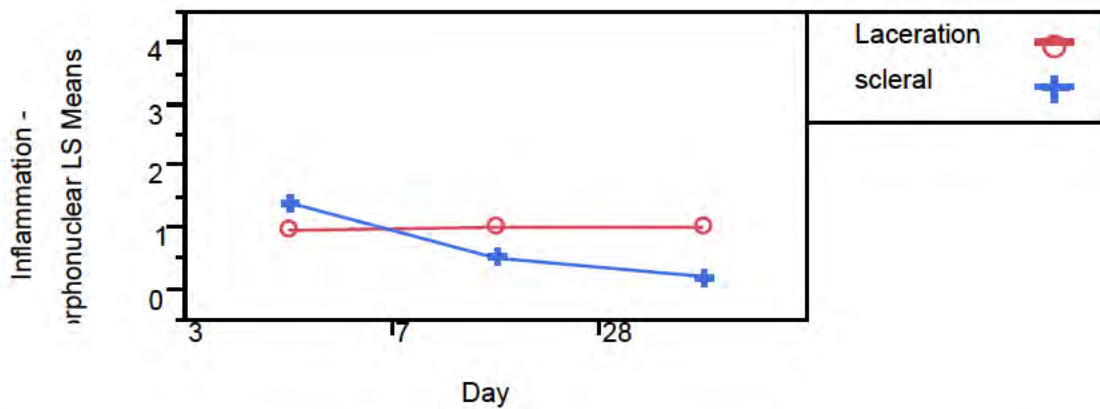


Figure 1: In comparing closure locations the scleral closures resulted in slightly more inflammation initially. This is likely related to the proximity of the scleral lacerations to a healthy blood supply. The lacerations have minimal effect, when promptly closed.

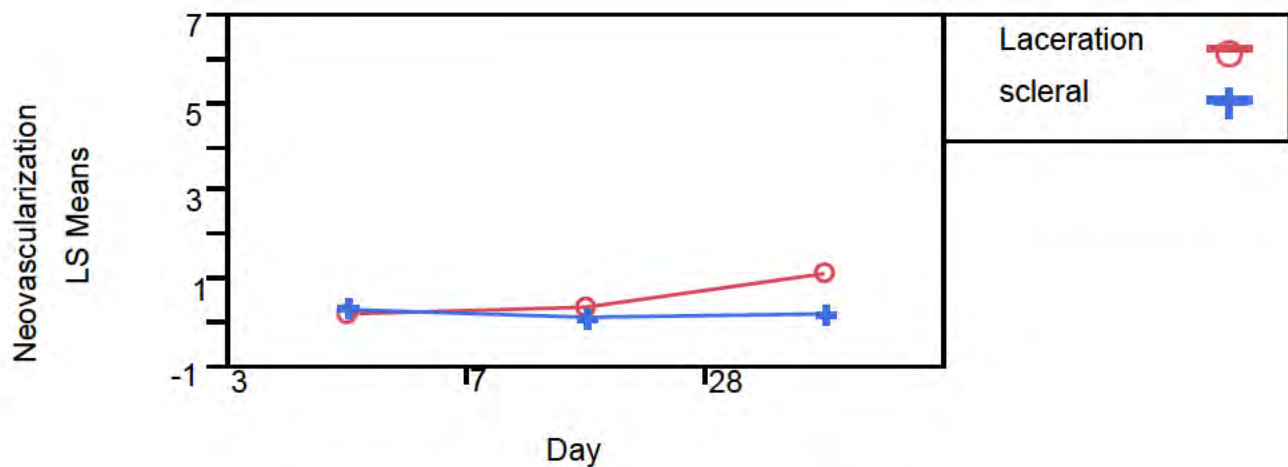


Figure 2: Evaluation of neovascularization reveals both closure techniques result in minimal amounts of neovascularization

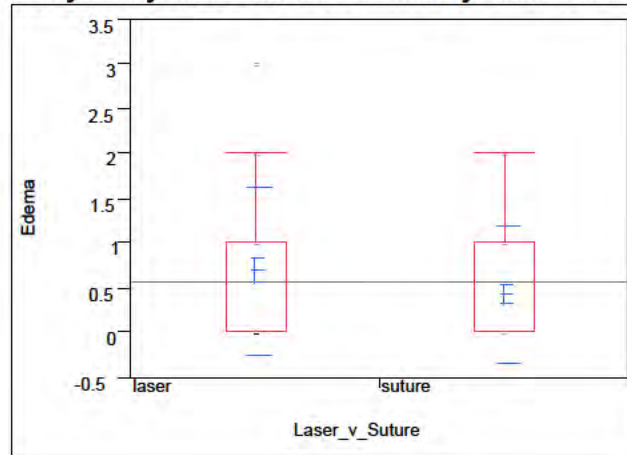
One-Way Analysis of Edema Induced By Laser vs. Suture

Figure 3. There is no significant induced edema to the corneal stroma compared to crosslinking and suture closure.

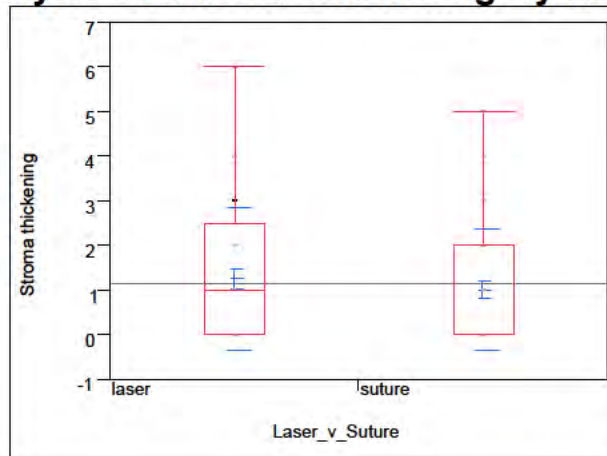
One-Way Analysis of Stroma Thickening By Laser vs. Suture

Figure 4: No significant difference in induced thickening from crosslinking vs. suture.

One-Way Analysis of Endothelial Necrosis by Laser vs. Suture

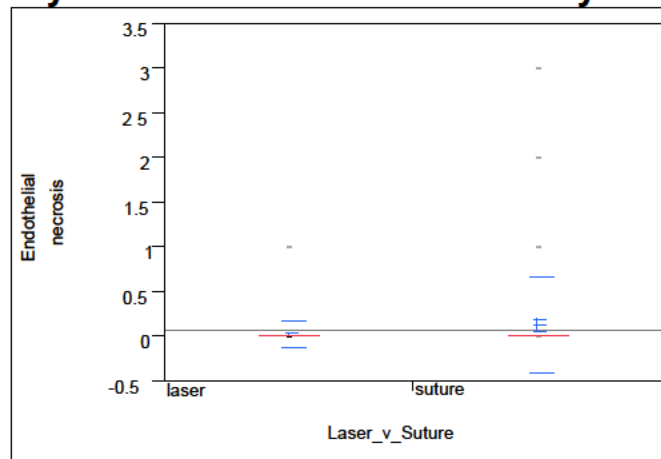


Figure 5. Previous studies indicate that Rose Bengal demonstrated potential toxicity to the endothelium. This evaluation indicates that using crosslinking is no more destructive than suture.

One-Way Analysis of Inflammation - induced By Laser vs. Suture

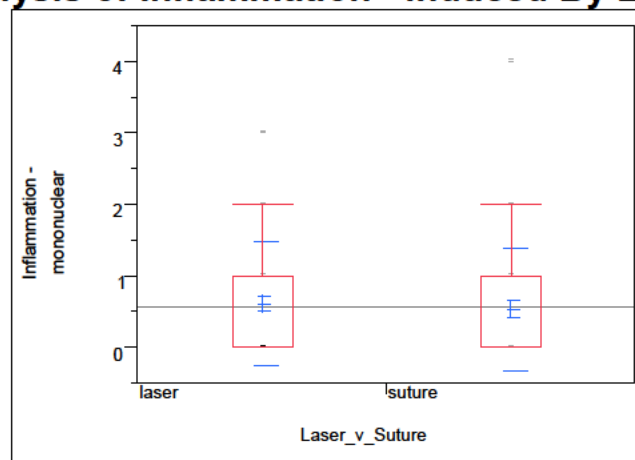


Figure 6: Analysis reveals the laser does not cause any additional inflammation compare to nylon (permanent) suture.

Appendix 2.

AD _____
(Leave blank)

Award Number: W81XWH-09-2-0050

TITLE: Sealing penetrating eye injuries with photoactivated bonding

PRINCIPAL INVESTIGATOR: Irene E. Kochevar, Ph.D.

CONTRACTING ORGANIZATION:

Massachusetts General Hospital
Boston MA 02114-2621

REPORT DATE: September, 2013
(Enter month and year, i.e., January 2001)

TYPE OF REPORT: Final report

PREPARED FOR: U.S. Army Medical Research and Materiel Command
Fort Detrick, Maryland 21702-5012

DISTRIBUTION STATEMENT: (Check one)

Approved for public release; distribution unlimited

Distribution limited to U.S. Government agencies only;
report contains proprietary information

The views, opinions and/or findings contained in this report are those of the author(s) and should not be construed as an official Department of the Army position, policy or decision unless so designated by other documentation.

REPORT DOCUMENTATION PAGE

Form Approved
OMB No. 0704-0188

Public reporting burden for this collection of information is estimated to average 1 hour per response, including the time for reviewing instructions, searching existing data sources, gathering and maintaining the data needed, and completing and reviewing this collection of information. Send comments regarding this burden estimate or any other aspect of this collection of information, including suggestions for reducing this burden to Department of Defense, Washington Headquarters Services, Directorate for Information Operations and Reports (0704-0188), 1215 Jefferson Davis Highway, Suite 1204, Arlington, VA 22202-4302. Respondents should be aware that notwithstanding any other provision of law, no person shall be subject to any penalty for failing to comply with a collection of information if it does not display a currently valid OMB control number. **PLEASE DO NOT RETURN YOUR FORM TO THE ABOVE ADDRESS.**

1. REPORT DATE (DD-MM-YYYY) 20-09-2013		2. REPORT TYPE Final report		3. DATES COVERED (From - To) 1 Sept 2010-30 August 2013	
4. TITLE AND SUBTITLE Sealing penetrating eye injuries with photoactivated bonding				5a. CONTRACT NUMBER	
				5b. GRANT NUMBER W81XWH-09-2-0050	
				5c. PROGRAM ELEMENT NUMBER	
6. AUTHOR(S) Irene E. Kochevar				5d. PROJECT H-09-2-0070NUMBER	
				5e. TASK NUMBER	
				5f. WORK UNIT NUMBER	
7. PERFORMING ORGANIZATION NAME(S) AND ADDRESS(ES) Massachusetts General Hospital, Boston Massachusetts 02114-2621				8. PERFORMING ORGANIZATION REPORT NUMBER	
9. SPONSORING / MONITORING AGENCY NAME(S) AND ADDRESS(ES) US Army Medical Research and Material Command Fort Detrick Maryland 21702-5012				10. SPONSOR/MONITOR'S ACRONYM(S)	
				11. SPONSOR/MONITOR'S REPORT NUMBER(S)	
12. DISTRIBUTION / AVAILABILITY STATEMENT Approved for public release; distribution unlimited					
13. SUPPLEMENTARY NOTES					
14. ABSTRACT Purpose: To develop a light-activated technology with the potential to decrease vision loss and ocular complications in warfighters sustaining penetrating eye injuries. Scope: To establish, in ex vitro and in vivo animal models, the treatment parameters for sealing corneal and scleral penetrating wounds and to close lacerations in thin (eyelid-like) skin. To design and evaluate a prototype light delivery device. Major findings: We established that bonding amniotic membrane over penetrating cornea and scleral wounds produced immediate, water-tight seals that withstood an intraocular pressure of 350 mm Hg. We closed lacerations in eyelid-like skin with the dye + light treatment, which showed less inflammation than after sutured closure. A prototype light delivery system was designed, constructed and tested to deliver retina-safe light levels while providing light levels sufficient for sealing amniotic membrane over corneal wounds. Studies demonstrated that thermal damage to the iris is not a concern during these repair treatments.					
15. SUBJECT TERMS cornea, sclera, eyelid skin, penetrating wound, laser, photochemistry					
16. SECURITY CLASSIFICATION OF:			17. LIMITATION OF ABSTRACT UU	18. NUMBER OF PAGES 16	19a. NAME OF RESPONSIBLE PERSON USAMRMC
a. REPORT U	b. ABSTRACT U	c. THIS PAGE U			19b. TELEPHONE NUMBER (include area code)

Table of Contents

	<u>Page</u>
Introduction.....	4
Body	4
Key Research Accomplishments.....	9
Reportable Outcomes.....	10
Conclusion.....	10-11
References.....	11
Appendices.....	12-30

INTRODUCTION

The overall goal of this research is to develop a light-activated technology with the potential to decrease vision loss and ocular complications in warfighters sustaining penetrating eye injuries. Fragments and debris propelled at high velocity by improvised explosive devices (IEDs) have increased the incidence of penetrating eye injuries in the current conflicts compared to earlier wars. Rapid closure of penetrating eye wounds with formation of a water tight seal is critical to preventing infection and stabilizing the eye for further surgery, thus improving vision outcomes. Suturing the cornea, sclera and eyelid skin requires specialized training to precisely place hair-fine sutures and requires long surgery time. Cyanoacrylate glues can complicate further surgery by sticking to sutures and possibly causing additional damage when removed. Our sutureless, glueless method is rapid and uses currently FDA-allowed materials/devices (clinical laser, dye, human amniotic membrane) and thus may move rapidly to the deployment environment. The scope of the research includes evaluating two light-activated approaches to closing penetrating injuries in the cornea and sclera of rabbit eyes. In one method, amniotic membrane is stained with the dye, placed over the wound and treated with green light; in the other, the dye is applied to the wound walls and activated by green light to directly close the wound. The scope also includes developing a light-activated method for rapid closure of eyelid lacerations using hairless mouse skin as a model. Finally, the scope includes designing, constructing and evaluating a green laser light delivery system that meets ANSI standards for retina and iris safety.

BODY

This research project is a collaboration with COL Anthony J. Johnson, MD at the US Army Institute for Surgical Research. Dr. Kochevar and Dr. Johnson communicated frequently by phone, reciprocal visits and discussions at conferences during the course of these studies. This final report describes the results of studies carried out in Dr. Kochevar's lab at the Massachusetts General Hospital. Dr. Johnson has received an extension of the grant period and will submit a final report separately.

Brief Summary

We established the light-activated treatment parameters that produce strong, immediate water-tight sealing of penetrating cornea and scleral wounds using rabbit eye models. The seal withstood an intraocular pressure of 350 mm Hg, more than 10 times the normal intraocular pressure. The wound sealing was accomplished by light-activated bonding of amniotic membrane to the cornea or scleral surface around the wound. We also demonstrated that lacerations in thin skin, a model for eyelid and periorbital skin, were immediately sealed with the dye + light treatment and less inflammation was generated than after sutured closure.

A prototype light delivery system was designed, constructed and tested to deliver retina-safe light levels while providing light levels sufficient for sealing corneal wounds. Initial studies demonstrated that thermal damage to the iris are not a concern. All of the studies employed a clinical laser that emits green light at 532 nm. The dye used, Rose Bengal, is approved for diagnosis of defects in corneal and sclera surface, and human amniotic membrane is a FDA-allowed device.

Task 1. Evaluate photoactivated bonding for sealing amniotic membrane over corneal lacerations (Specific aim 1.a)

During years 1 and 2 all ex vivo studies and non-survival in vivo studies were completed for this

Task and described in the Annual Reports. A paper was published with the results of these studies. It is included as Appendix #1 to this Final Report. Consequently, the results will be only briefly summarized here.

The approach taken to sealing penetrating cornea wounds was to seal a layer of amniotic membrane over the ocular surface containing the wound using a light-activated technology. Cryopreserved human amniotic membrane, stained with Rose Bengal (RB) dye, was placed over a full-thickness wound in de-epithelialized rabbit cornea and was then treated with green laser light (532 nm). This process seals the amnion to the cornea surface by forming covalent crosslinks between proteins on the amnion and cornea surfaces. The intraocular pressure that broke the seal (IOP_L) was measured, and adhesion was measured with a peel test. Parameters that were studied to obtain the optimal treatment conditions included: the light fluence and irradiance, RB concentration, and the side of the amnion (stromal versus basement membrane) surface bonded. Epithelial cell migration on the photo-crosslinked treated amnion was also measured.

Brief summary of results (Figure numbers refer to the figures in the published paper, Appendix 1) A procedure was established for reproducible bonding of amnion to de-epithelialized rabbit cornea (Figure 1) using RB dye and green light. After sealing amniotic membrane over cornea using 0.1% RB and 0.25 W/cm^2 , the intraocular pressure required to break the seal (IOP_L) measured ex vivo (Figure 3A) increased with increasing fluence (50–150 J/cm^2). Irradiating with a fluence of 150 J/cm^2 and an irradiance of 0.25 W/cm^2 at 532 nm produced an IOP_L of $261 \pm 77 \text{ mm Hg}$ ex vivo, a pressure considerably higher than the normal human IOP of $\sim 20 \text{ mm Hg}$. A peel test that measures adhesion of amnion to cornea demonstrated that the adhesion after RB + green light treatment was greater than after using fibrin glue (Figure 3B). The bonding strength was not influenced by irradiance used over the range 0.125 to 0.500 W/cm^2 ; 0.250 W/cm^2 was selected because higher irradiances produced a greater temperature increase and lower irradiances required a long irradiation time (Figure 3D). Equivalent bonding strengths were produced for bonding basement membrane or stromal surfaces of the amnion (Figure 4B). The bonding treatment was not toxic to keratocytes in the cornea stroma but slightly reduced the migration of corneal epithelial cells on amnion ex vivo (Figure 6).

Based on the results of these ex vivo studies, we proceeded to a (non-survival) in vivo study. Amnion was photobonded over V-shaped wounds in rabbit cornea in vivo and the bonding strength was measured as for ex vivo studies. As shown in Figure 5, the IOP_L increased with increasing fluence (50–150 J/cm^2), reaching $448 \text{ mm} \pm 212 \text{ mm Hg}$, a pressure higher than had been obtained when amnion was bonded ex vivo to rabbit eyes.

These studies lead to the conclusion that our rapid, light-activated technique (PTB) produces strong, immediate bonding between amnion and cornea to seal penetrating cornea wounds. Further in vivo studies to evaluate longer term effects of this process on rabbit eyes are being carried out by our collaborator, COL Anthony J. Johnson MD at USAISR.

Task 2. Evaluate photoactivated bonding for direct sealing of corneal lacerations (Specific aim 2.a)

An additional approach to sealing full thickness corneal wounds was evaluated. In this approach, PTB was used to directly bond the wound edges together. This approach was challenging for highly irregular or stellate lacerations but has the advantage that amniotic membrane is not needed. In earlier studies, we demonstrated linear corneal incisions were effectively sealed using PTB without amnion and also used PTB for penetrating keratoplasty to seal between sutures (1,2). To identify the appropriate parameters and methodology for directly

sealing non-linear corneal wounds, we used V-shaped wounds in the central cornea of rabbit eyes. The strength of the bonding was assessed by IOP measurements, as described previously (see method in Appendix 1).

Sealing V-shaped incisions in the central cornea proved to be highly challenging for our research group at MGH. Maintaining close contact between the walls of the incision and minimizing fluid between the walls is essential for forming covalent protein-protein crosslinks between these surfaces using PTB. After the V-shaped incision was made in ex vivo rabbit eyes, the cornea did not maintain its shape and the incision walls did not align. All attempts, using a variety of techniques, to seal the wound with PTB were unsuccessful. Attempting to stabilize the contact between the incision walls with sutures, either one in each arm of the V or one at the apex of the V also did not lead to successful photobonding.

It became apparent that our team, which does not contain a corneal surgeon, did not have the experience and technical expertise to use PTB to directly seal V-shaped corneal wounds. Dr. Johnson, who has extensive experience with suturing irregular corneal wounds, provided excellent advice during a visit to MGH. However, his skills were not readily transferred to our inexperienced hands and we have not completed the planned ex vivo studies. Dr. Johnson is currently sealing V-shaped wounds in cornea by bonding amnion over the wound in vivo in rabbit eyes.

Task 3. Evaluate photoactivated bonding for sealing puncture wounds in sclera (Specific aim 1.c.)

Sealing amnion over penetrating wounds in the sclera differs from bonding amnion over cornea wounds since the surface composition of the two tissues differs, and consequently the photobonding efficiency may differ. For these studies, the wound was made in an area of sclera after removal of the conjunctiva.

First, the effect of circular patch size (7 mm vs 10 mm diameter) was evaluated for sealing 3-mm incisions made perpendicular to the limbus and 3-4 mm away from the limbus. The RB-stained patch was exposed to green laser light (50-100 J/cm²). The control was RB-stained amnion that is not irradiated. A modified procedure was used to measure bonding strength by determining the intraocular pressure (IOP_L) at which leakage from underneath the amnion was detected. As shown in Figure 1, the bonding strength was significantly greater for 10-mm circular patches. Similar studies (detailed in Year 3 report) showed that the circular patches produced stronger bonding than rectangular patches. Interestingly, the bonding strength after sealing amnion to sclera under the optimal conditions was very similar to those we measured for bonding amnion to cornea (Appendix 1). Values for IOP_L were in the range 200-250 mm Hg for both tissues.

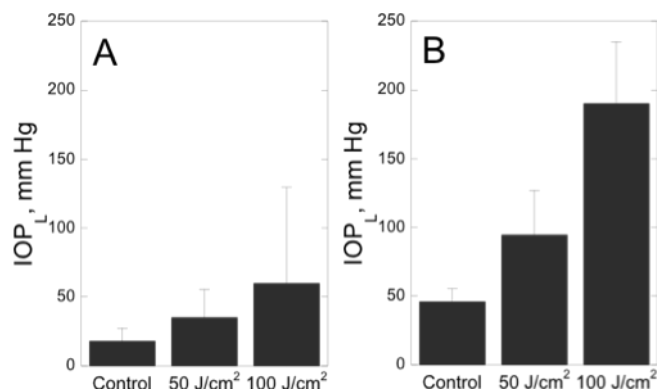


Figure 1. Photobonding RB-stained amnion patches over 3-mm linear incision wounds in rabbit sclera ex vivo. (A) circular amnion 7 mm diameter (B) circular amnion 10 mm diameter. The IOP_L indicates the bonding strength.

Photobonding amnion over a more challenging type of wound was also evaluated. Our initial motivation for photobonding amnion over penetrating eye injuries was wounds involving both the cornea and the sclera such as shown in Fig. 2A. Incisions (3.5 mm) were made perpendicular and across the limbus, covered with 10-mm RB-stained amnion disc patches and irradiated with 100 J/cm² or not irradiated. As shown in Fig. 2B, reasonably strong bonding was achieved (~130 mm Hg, measured in anterior chamber) indicating that our approach can be used for these severe wounds.

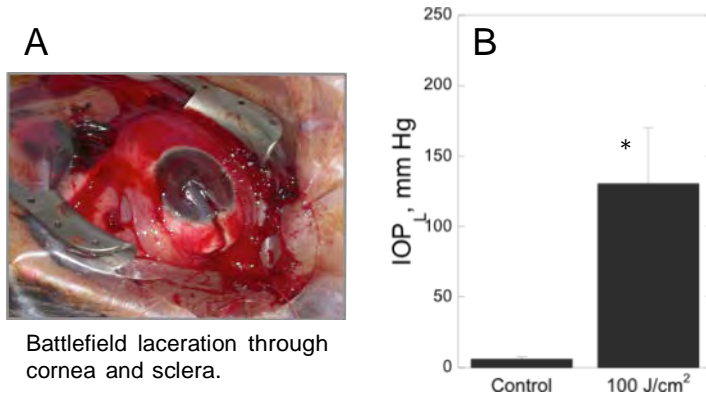


Figure 2. Photobonding amnion over corneal/sclera incisions in rabbit eyes ex vivo. (A) Cornea/sclera penetrating wound from battlefield trauma. (B) Photobonding amnion over 3.5-mm corneal/scleral incisions. 10 mm RB amnion patches and green laser used. The IOP_L indicates the bonding strength. * indicates p < 0.01.

In summary, we have established the amnion patch size and shape that strongly seals RB-stained amnion over penetrating scleral wounds and wounds that span both the cornea and sclera.

Task 4. Identify best treatment parameters for sealing eyelid skin lacerations (Specific Aim 2.)

During year 2 the studies for this Task were completed and reported. A paper was written that contained the results of those studies and was published in 2011. This paper is Appendix #2 to this Final report. The results are briefly summarized here.

Repairing lacerations in eyelid skin and the adjacent periorbital area, which are frequently caused by flying debris and fragments, is particularly problematic because the skin is very thin and delicate. We proposed that light-activated tissue bonding (PTB) might substantially reduce the time required for closing eyelid skin lacerations compared to sutured closure and also have the advantages of allowing normal mobility of this skin compared to the stiffness produced by cyanoacrylate glues or skin tapes.

We had already demonstrated in porcine skin that PTB is an excellent replacement treatment for superficial interrupted sutures in a layered closure of full thickness surgical wounds in skin (3). In this study, we used dorsal skin of the SKH-1 hairless mouse as a model for eyelid skin. This mouse is albino, hairless and immunocompetent. Only a single layer closure was performed.

Incisions (1.2 cm-long) were treated with 0.1% Rose Bengal dye followed by exposure to 532 nm radiation (25, 50, or 100 J/cm²; 0.25 W/cm²). Other incisions were sutured (five 10-0 monofilament), exposed only to 532 nm (100 J/cm²), or not treated. Outcomes were immediate seal strength (pressure causing leakage through incision of saline infused under wound), skin strength at 1, 3, and 7 days (measured by tensiometry), inflammatory infiltrate at 1, 3, and 7 days (histological assessment), and procedure time.

- The immediate seal strength, as measured by leak pressure, was equivalent for all PTB fluences and for sutures (27–32 mmHg); these pressures were significantly greater than for

- the controls (untreated incisions or laser only treatment; $P < 0.001$).
- The ultimate strength of PTB-sealed incisions was greater than the controls at day 1 ($P < 0.05$) and day 3 ($P < 0.025$) and all groups were equivalent at day 7.
- Sutures produced greater inflammatory infiltrate at day 1 than observed in other groups ($P = 0.019$).
- The average procedure time for sutured closure (311 seconds) was longer than for the PTB group treated with 25 J/cm^2 (160 seconds) but shorter than the group treated with 100 J/cm^2 (460 seconds).

From these results we concluded that PTB produces an immediate seal of lacerations in thin, delicate skin (similar to eyelid and periorbital skin) that heals well, does not require painful suture removal and less initial inflammation suggesting that less scarring might be produced.

Task 5. Design, construct and test safe light delivery systems for direct bonding of corneal injuries (Specific aim 3.)

Light-activated sealing of corneal wounds requires a light source that does not cause retinal damage during the irradiation with green (532 nm) light. Light that is not absorbed by the Rose Bengal or blocked by the iris will enter through the pupil and reach the retina. Light at 532 nm can cause thermal and photochemical damage to retinal photoreceptor cells. Light exposure standards for exposure of retina to cw lasers have been compiled in the American National Standard for Safe Use of Lasers (ANSI 136.1) (4).

Optics were designed that deliver an amount of light that is safe for the retina when using the laser parameters that seal a corneal wound (Figure 3A). Details of the design are given in Year 1 report. The requisite irradiance thus falls on the cornea, but light passing beyond the cornea is strongly divergent so that it spreads safely over a wide area of the retina. The image of the beam on the retina produced by this system exposes the retina to an irradiance and fluence that are well below the ANSI damage thresholds. Measuring the laser power at the corneal plane indicated that the irradiance delivered was safe by ANSI standards.


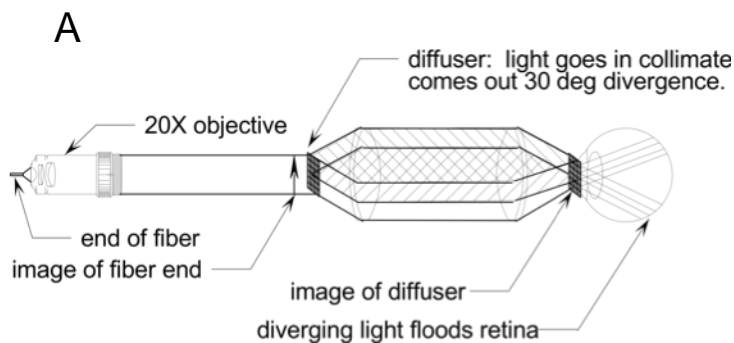


Figure 3. Schematic diagram (A) and prototype of light delivery system (B) for photobonding on the cornea that reduces the laser power at the retina to below the threshold for damage according to ANSI 136.1 standards.

The prototype light delivery system was constructed (Figure 3B) and described in detail in Year 2 report. The ability of light delivered by this system to bond amnion to the cornea surface was compared to that produced by our conventional, bare fiber system using *ex vivo* rabbit eyes and the standard treatment protocol (Appendix 1). The bonding strength produced by two fluences, 50 and 100 J/cm², was determined by measuring the leak pressure (IOP_L) immediately after bonding as described previously. The results indicated that the bonding strength produced by the prototype safe light delivery system was equivalent to that produced using our conventional bare fiber delivery.

Another possible safety concern of irradiation with green light is thermal damage to the pigmented iris since the green light is absorbed by melanin in the iris and the energy is converted to heat. If the rate of light energy absorption is greater than the rate of dissipation of the thermal energy, the temperature will rise. We measured the change in iris temperature under the conditions used for bonding amnion to the cornea (irradiance = 0.25 W/cm², fluence = 100 J/cm².) using freshly enucleated swine eyes with darkly pigmented irises. The temperature of the posterior surface of the iris was measured with a pair of thermocouples. The temperature increased slowly and reached approximately 4°C higher than the starting temperature (Year 3 report) indicating that photobonding amnion onto cornea will not cause thermal damage to the iris.

In summary, these results indicate that the prototype optical delivery system delivers safe levels of green light to the retina and iris when the treatment parameters are applied that securely bond amnion over penetrating cornea wounds.

KEY RESEARCH ACCOMPLISHMENTS

- Identified the PTB treatment parameters that produce strong bonding of an amnion patch over corneal wounds in *ex vivo* rabbit eyes.
- Determined that a fluence of 100 J/cm² of 532 nm (green) laser light strongly bonds a Rose Bengal-stained amnion patch over a penetrating corneal injury in the central cornea *in vivo*. The seal formed resists opening at intraocular pressures up to 350 mm Hg, >15 times higher than the normal intraocular pressure.
- Determined that sealing penetrating cornea wounds using a dye-stained amniotic membrane patch and green light is superior to direct photo-activated bonding of the wound walls.
- Identified the treatment parameters for strongly sealing amniotic membrane over a puncture wound in sclera using light-activated bonding. The amnion patch size and shape, and light fluence were established for the subsequent *in vivo* study.
- Demonstrated that PTB can be used to seal lacerations in thin skin (e.g., eyelid or periorbital skin) without deep sutures and that the repair requires less time than suturing and stimulates less inflammation than sutures.
- Designed and constructed a light delivery system for direct light-activated bonding of penetrating injuries in the central cornea. The irradiance at the retina is below the thresholds for damage when using the fluences that bond amnion to the cornea surface.
- Demonstrated that the prototype retina-safe optical delivery system effectively seals amnion to cornea and substantially reduces the treatment time compared to our conventional fiber system.
- Established that the irradiation parameters used to seal amnion over cornea wounds are below the threshold for thermal damage to the iris.

REPORTABLE OUTCOMES

1. Verter EE, Gisel TE, Yang P, Johnson AJ, Redmond RW, Kochevar IE. Light-initiated bonding of amniotic membrane to cornea. Invest Ophthalmol Vis Sci. 2011 Dec 9;52(13):9470-7.
2. Yang P, Yao M, DeMartelaere SL, Redmond RW, Kochevar IE. Light-activated sutureless closure of wounds in thin skin. Lasers Surg Med. 2012 Feb;44(2):163-167.
3. Johnson AJ, Cora S, Ecklund B, Wang H-C, Remond RW, Verter E, Kochevar IE. Crosslinking Repair of Corneal Lacerations In the New Zealand White Rabbit. Poster presented at the 2013 Military Health System Research Symposium (MHSRS), Fort Lauderdale FL, August 12-15, 2013.
4. Light-initiated bonding of amniotic membrane to cornea. E. Verter, A.J. Johnson, T. Gisel, P. Yang, R.W. Redmond and I.E. Kochevar. Platform presentation at the 2011 ATACCC Conference, Fort Lauderdale FL, August 15-18, 2011.
5. Rose Bengal photosensitized crosslinking of collagen for repair of penetrating eye injuries E. Verter, M. Yao, A. Blanden, A.J. Johnson, R.W. Redmond and I.E. Kochevar, Invited Presentation at the American Society for Photobiology Annual Meeting, June 12-16, 2011, Providence RI
6. Light-activated technology for repair and regeneration after traumatic injury. I. E. Kochevar and R.W. Redmond, ATACCC 2010 Conference, August 16-19, St. Pete Beach FL (Poster # RM14).
7. Photoactivated technology for repair of penetrating eye injuries. E. Verter, A.J. Johnson, M. Yao, R.W. Redmond and I.E. Kochevar. Poster presented at the 4th Military Vision Symposium, Schepens Eye Research Institute, Boston, MA, September 27-29, 2010

CONCLUSIONS

The results of these studies established that a light-activated method can be used for sealing penetrating wounds in the cornea and sclera and for lacerations in eyelid skin. In all applications a strong seal was produced immediately. The best method for sealing corneal and scleral wounds is to bond amniotic membrane over the wound using a dye and green laser light. Lacerations in thin skin were closed by bonding the wound edges together.

The advantages of using this sutureless and glueless method for repair of eye wounds and eyelid/periorbital skin lacerations include formation of an immediate water-tight seal without tedious, time-consuming suturing and avoiding damage to eye tissues caused by sutures and glues that leads to scarring. We did not identify problems or obstacles that will inhibit the translation of this light-activated repair technique to clinical use. In addition, this treatment involves off-label use of three FDA-allowed materials/devices (clinical laser, Rose Bengal dye, human amniotic membrane), which may facilitate translation to the clinic. Our collaborator, COL Anthony Johnson MD, is carrying out longer-term studies of this technology for sealing penetrating cornea wounds in rabbit eyes.

Initial studies demonstrated that thermal damage to the iris are not a concern during the

treatment. A prototype light delivery system was designed and constructed to deliver retina-safe light levels. Further safety studies will be needed before clinical use.

REFERENCES

1. Proano, C. E., D. T. Azar, M. C. Mocan, R. W. Redmond and I. E. Kochevar (2004) Photochemical keratodesmos as an adjunct to sutures for bonding penetrating keratoplasty corneal incisions. *J Cataract Refract Surg*, **30**, 2420-4.
2. Proano, C. E., L. Mulroy, E. Jones, D. T. Azar, R. W. Redmond and I. E. Kochevar (2004) Photochemical keratodesmos for bonding corneal incisions. *Invest Ophthalmol Vis Sci*, **45**, 2177-81.
3. Tsao, S., M. Yao, H. Tsao, F. P. Henry, Y. Zhao, J. J. Kochevar, R. W. Redmond and I. E. Kochevar (2012) Light-activated tissue bonding for excisional wound closure: a split-lesion clinical trial. *Br J Dermatol*, **166**, 555-63.
4. American National Standard for Safe Use of Lasers (ANSI 136.1-2000). *The Laser Institute of America. Orlando FL.*

Personnel supported by this grant

All personnel are employed by the Massachusetts General Hospital, Boston MA.

Irene E. Kochevar, PhD, Principal Investigator

Robert W. Redmond, PhD, Investigator

E. Eri Verter, MS, Senior Technologist

Thomas Gisel, MS, Senior Technologist

Francis Doyle, MS, Technologist

Light-Initiated Bonding of Amniotic Membrane to Cornea

E. Eri Verter,¹ Thomas E. Gisel,¹ Penggao Yang,^{1,2} Anthony J. Johnson,³ Robert W. Redmond,¹ and Irene E. Kochevar¹

PURPOSE. Suturing amniotic membrane to cornea during surgery is time consuming, and sutures may further damage the eye. The authors introduce a novel sutureless, light-activated technique that securely attaches amnion to cornea through protein-protein crosslinks.

METHODS. Cryopreserved human amniotic membrane, stained with Rose Bengal (RB), was placed over a full-thickness wound in deepithelialized rabbit cornea and was treated with green laser. The intraocular pressure that broke the seal (IOP_L) was measured, and adhesion was measured with a peel test. The influences on bonding strength of fluence, irradiance, RB concentration, and amnion surface bonded were measured. Epithelial cell migration on treated amnion and keratocyte viability after bonding were also measured. The involvement in the bonding mechanism of oxygen, singlet oxygen, and association of RB with stromal collagen was investigated.

RESULTS. Sealing amniotic membrane over cornea using 0.1% RB and 150 J/cm² at 532 nm produced an IOP_L of 261 ± 77 mm Hg ex vivo and 448 mm ± 212 mm Hg in vivo. The ex vivo IOP_L increased with increasing fluence (50–150 J/cm²). Equivalent IOP_L was produced for bonding basement membrane or stromal amnion surfaces. The bonding treatment was not toxic to keratocytes but slightly reduced the migration of corneal epithelial cells on amnion ex vivo. Mechanism studies indicated that RB forms two complexes with amnion stromal collagen, that bonding requires oxygen, and that singlet oxygen mediates protein crosslinking.

CONCLUSIONS. A rapid, light-activated technique produces strong, immediate bonding between amnion and cornea and merits further evaluation for ocular surface surgeries. (Invest Ophthalmol Vis Sci. 2011;52:9470–9477) DOI:10.1167/iovs.11-7248

Amniotic membrane is frequently used in corneal and scleral surgery as a temporary patch or a reconstructive graft.¹ Uses of amniotic membrane transplantation (AMT) in-

clude covering persistent epithelial defects, pterygium surgery, and ocular surface reconstruction in stem cell deficiency. Amniotic membrane is composed of a single layer of epithelial cells attached to a basement membrane that lies over a stromal layer containing primarily types I and III collagen, proteoglycans, and fibroblasts. Currently amnion is sutured to the cornea, a time-consuming process requiring high skill to place hair-fine sutures. In addition, suturing may injure the eye and, because sutures act as a foreign body, can lead to persistent inflammation, infection, and granuloma.^{1,2}

We have evaluated an additional application of AMT, namely, sealing amniotic membrane over penetrating corneal wounds using a novel light-activated technology called photochemical tissue bonding (PTB). PTB produces an immediate seal between tissue surfaces without additional glues or proteins. Covalent crosslinks are formed that bridge proteins between the tissue surfaces by a photochemical, nonthermal mechanism.^{3–12} After applying a photoactive dye, the tissue surfaces are placed in contact, and the area is treated with a green laser to activate the dye and initiate the bonding chemistry. The dye, Rose Bengal (RB), is approved by the US Food and Drug Administration for the diagnosis of ocular surface damage.

A rabbit eye model of penetrating eye injury was chosen to challenge the ability of PTB to form a strong and secure seal between amniotic membrane and the corneal surface. In this study we identified the PTB treatment conditions that produced strong bonding, evaluated potential side effects, and investigated mechanisms for crosslink formation between amnion and corneal surface proteins.

MATERIALS AND METHODS

Materials

Frozen albino rabbit eyes from Pel-Freeze Biologicals (Rogers AR) were used at room temperature. Rose Bengal (95%; Sigma-Aldrich, St. Louis, MO) was a 0.1% wt/vol solution in phosphate-buffered saline (PBS; Sigma-Aldrich). Fibrin sealant (Tisseel) was from Baxter (Deerfield, IL). Nitrogen (Ultra High Purity) and oxygen (99.5%) were from Airgas (Cambridge, MA). New Zealand White rabbits (weight range, 2–2.5 kg) were purchased from Charles River Laboratories (Wilmington MA). The in vivo study was approved by the Massachusetts General Hospital Subcommittee on Research Animal Care and was conducted in accordance with the ARVO Statement for the Use of Animals in Ophthalmic and Vision Research. Amniotic membrane was obtained from scheduled caesarean deliveries, as we have done previously.⁹ This research adhered to the tenets of the Declaration of Helsinki. The amnion epithelium was removed with trypsin (0.25%, 90 minutes, 37°C) and light rubbing. Amnion was stored on nitrocellulose paper at –80°C in 1:1 glycerol/Dulbecco's modified Eagle's medium (DMEM) with 1% penicillin-streptomycin and 0.05% amphotericin B (Sigma-Aldrich).

From the ¹Wellman Center for Photomedicine, Massachusetts General Hospital, Harvard Medical School, Boston, Massachusetts; the ²Department of Burns and Plastic Surgery, No. 3 People's Hospital, Shanghai, China; and the ³Department of Ophthalmology, Brooke Army Medical Center, San Antonio, Texas.

Supported by US Department of the Army Award number W81XWH-09-2-0050 and Air Force Office of Scientific Research Grant FA9550-10-1-0537.

Submitted for publication January 18, 2011; revised March 9, April 2, and September 2, 2011; accepted October 14, 2011.

Disclosure: E.E. Verter, None; T.E. Gisel, None; P. Yang, None; A.J. Johnson, None; R.W. Redmond, Aura Medsystems (C), P; I.E. Kochevar, Aura Medsystems (C), P

Corresponding author: Irene E. Kochevar, Wellman Center for Photomedicine, Massachusetts General Hospital, Thier Building, Room 212, 55 Fruit Street, Boston, MA 02114; kochevar@helix.mgh.harvard.edu.

Absorption Spectra

Spectra of RB on amnion or on amnion bonded to cornea were measured on glass slides using a microplate reader (Spectramax M5; Molecular Devices, Sunnyvale CA). To correct for scattering from these tissues, spectra of amnion or cornea (without RB) were subtracted.

Association of Rose Bengal with Amnion

Amnion samples (1.1–1.3 mg) were stained on the stromal surface with 0.1% RB (5 minutes) and were briefly washed with PBS before absorption spectra were measured. Samples were then placed individually in 1 mL PBS and kept in the dark at room temperature until absorption spectra were measured. After each measurement, the samples were placed in fresh PBS.

Preparation of Amnion Patch


Amniotic membrane was first rinsed in PBS for 45 minutes to remove glycerol from the storage medium, then transferred from the nitrocellulose backing to Parafilm with the stromal surface upward and allowed to dry. A 13-mm diameter circle was cut from the amnion and Parafilm backing (Fig. 1A). RB solution (0.1% in PBS, 200 µL) was placed on the amnion stromal surface for 5 minutes (Fig. 1B), and excess was removed to produce slightly moist, but not wet, amnion. The dye-stained amnion was peeled from the backing (Fig. 1C).

Bonding Amniotic Membrane to Rabbit Cornea

The same procedure for photobonding amnion to cornea was followed for both ex vivo and in vivo rabbit eyes, except for the differences noted. In vivo, the nictitating membrane was displaced and held with a suture (Fig. 1D). The epithelial layer was removed with 70% ethanol (10–15 seconds), and a full-thickness incision was made in the central cornea (ex vivo: V-shaped, 90° angle, 2-mm arms; in vivo, linear 3 mm) (Fig. 1E). The RB-stained amnion was placed with its stromal surface in contact with the cornea, and wrinkles were removed (Figs. 1G, 1H). A 4-mm diameter pupil-blocking opaque white disc was placed over the center cornea (Fig. 1I) before irradiation (Fig. 1J). A green laser (Ocu-Light OR KTP; Iridex Corp., Mountain View, CA) emitting cw 532 nm radiation was used for irradiances 0.25 W/cm². A 532 nm cw Nd:YAG laser (Aura i; Laserscope, San Jose, CA) was used to deliver 0.5 W/cm². The beam was transmitted through a 600-µm optical fiber and passed through a microscope objective (20X or 40X) to produce a homogeneous beam at the corneal surface. Laser power was measured with a spectroradiometer (SPR-01; Luzchem, Ottawa, ON, Canada). The amnion surface was lightly misted with water every 90 seconds during irradiations.

To evaluate the influence of oxygen on photobonding, the cornea was stained instead of the amnion because RB photobleaches more rapidly in the presence of oxygen. Thus, more green light would have reached the cornea-amnion interface through the RB-stained amnion in the presence of oxygen. The deepithelialized corneal surface was

Staining amniotic membrane with Rose Bengal (RB)



Sealing amniotic membrane over corneal wound using PTB

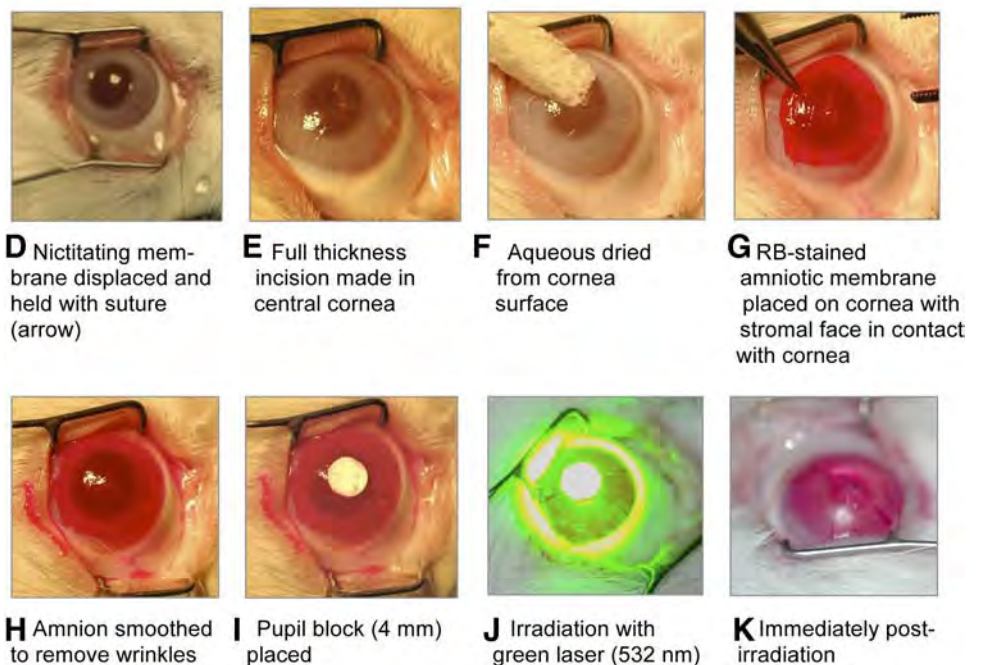


FIGURE 1. (A–C) Preparation of RB-stained amniotic membrane and (D–K) use of PTB to seal amnion over full-thickness incisional wounds in rabbit cornea.

placed in 1% RB for 2 minutes and then briefly washed. After an incision was made and the amnion patch was placed, the eye was placed in a 3-cm diameter, 7.5-cm tall plastic cylinder. To maintain humidity, water-saturated gases were used to purge the cylinder before (10-minute) and during irradiation. The amnion-covered cornea was irradiated through the plastic top (150 J/cm^2 , 0.25 W/cm^2).

When H_2O and D_2O were compared, the corneal surface was immersed in either D_2O or H_2O for 30 minutes before the incision. The amnion was treated for 5 minutes with 0.1% RB prepared in either D_2O or H_2O .

For bonding with fibrin sealant (Tisseel; Baxter), 11 μL thrombin solution was spread on the amniotic membrane and 11 μL fibrinogen solution was spread on the cornea, as described previously.¹³ The amnion was then placed over the V-shaped wound in the cornea, and any wrinkles were removed. The eye was allowed to stand at least 15 minutes before bonding strength was measured.

Measurement of Bonding Strength

Bonding strength between the amnion and cornea was determined by slowly infusing PBS into the anterior chamber through a 22-gauge needle inserted into the cornea 1 mm anterior of the limbus and parallel to the iris. A mini-infuser (Genie Plus Infusion/Withdrawal Pump, Kent Scientific, Torrington, CT) and a pressure transducer (Isotec; Harvard Apparatus, Holliston, MA) were connected by a T-coupler to the needle. The increase in IOP was measured immediately after photobonding by the method used previously.^{8,12} The amnion surface was wetted before measurement to ensure that drying of the amnion on the cornea did not contribute to the bonding strength. The pressure attained immediately before fluid leaks from under the amnion, the leak pressure (IOP_L), is a measure of bonding strength. For in vivo studies, the animals were euthanized immediately after the measurement.

Adhesion was also measured using a peel test. A 5-mm wide, 20-mm long strip of amnion was bonded to a 6-mm wide and 10-mm long strip of cornea using PTB or fibrin sealant (Tisseel; Baxter). The bonded overlap area measured 5 mm \times 10 mm (Supplementary Material and Fig. S1, <http://www.iovs.org/lookup/suppl/doi:10.1167/iovs.11-7248/-DCSupplemental>). The PTB bonding procedure mimicked that used to seal amnion to the intact cornea as described. A previously described procedure was followed for bonding amnion to cornea with fibrin sealant.¹³ Equal volumes (7.5 μL) of thrombin and fibrinogen solutions were applied to the amnion and corneal surfaces, respectively, which were then placed in tight contact. After at least 1 hour, the force generated while peeling amnion from the cornea was measured using a universal testing system (Nano UTM; Surface Systems and Technology GmbH, Hueckelhoven, Germany) with a separation rate of 5.0 mm/min. The mean force (milliNewtons [mN]) generated while peeling amnion from the cornea, after the initial peak, was taken as the adhesion strength.

Keratoocyte Viability

RB-stained amnion and a 4-mm opaque disc were placed on the central corneas of freshly harvested rabbit eyes, which were then exposed to either 100 or 200 J/cm^2 . The amnion was removed, and the eye was

maintained in organ culture in DMEM at 37°C and 5% CO_2 .¹⁴ After 24 hours, the corneas were fixed in 10% formalin, paraffin-embedded, sectioned, and stained with hematoxylin and eosin. Vertical sections (5 μm) contained both the irradiated peripheral and the light-blocked central areas. The keratoocytes in 12 areas, each measuring 0.25-mm^2 , adjacent to the anterior corneal surface were counted in both the non-light-treated area and the surrounding irradiated areas.

Migration of Corneal Epithelial Cells on Photocrosslinked Amnion

Amnion was treated with 0.1% RB for 5 minutes before brief washing and irradiation with fluence of 532 nm between 0 and 150 J/cm^2 . Excess RB was removed by soaking amnion in PBS for 18 hours. Immortalized human

corneal-limbal epithelial cells¹⁵ (4×10^4) were placed on the basement membrane of deepithelialized amnion within a 6-mm cloning ring for 3 hours. At 24 to 96 hours after the ring was removed, the distance from the ring to the edge of the migrating cells was measured at six evenly separated locations on the circumference of the circle.

Statistical Analysis

Student's t-test for unpaired data was used to compare groups; significance was set at $P < 0.05$.

RESULTS

Rose Bengal Associates with Amniotic Membrane Components

The amount of RB associated with amnion was calculated from the absorbance of RB at 532 nm after treating the stromal surface with RB (0.05% and 0.1%, 200 μL) for 5 or 10 minutes and briefly washing. As shown in Figures 2A and 2B, the RB absorption approximately doubled between 5 and 10 minutes of staining. The mean RB concentration was estimated using an absorption coefficient for RB at 532 of $3.9 \times 10^4 \text{ M}^{-1} \cdot \text{cm}^{-1} \cdot \text{nm}$ (measured for RB bound to type I collagen in solution, (Y. Tang, unpublished result, 2010). Because amnion demonstrates a location-dependent variation in thickness, the absorption by RB is expected to vary.¹⁶ Using a mean amnion thickness of 50 μm , the stromal RB was calculated to be 2.56 and 5.12 mM after 5 minutes of staining with 0.05% and 0.10% RB, respectively. These RB concentrations are approximately five-fold greater than the RB staining solutions (0.05% and 0.10% correspond to 0.5 and 1 mM RB), indicating that RB complexes with components in amnion.

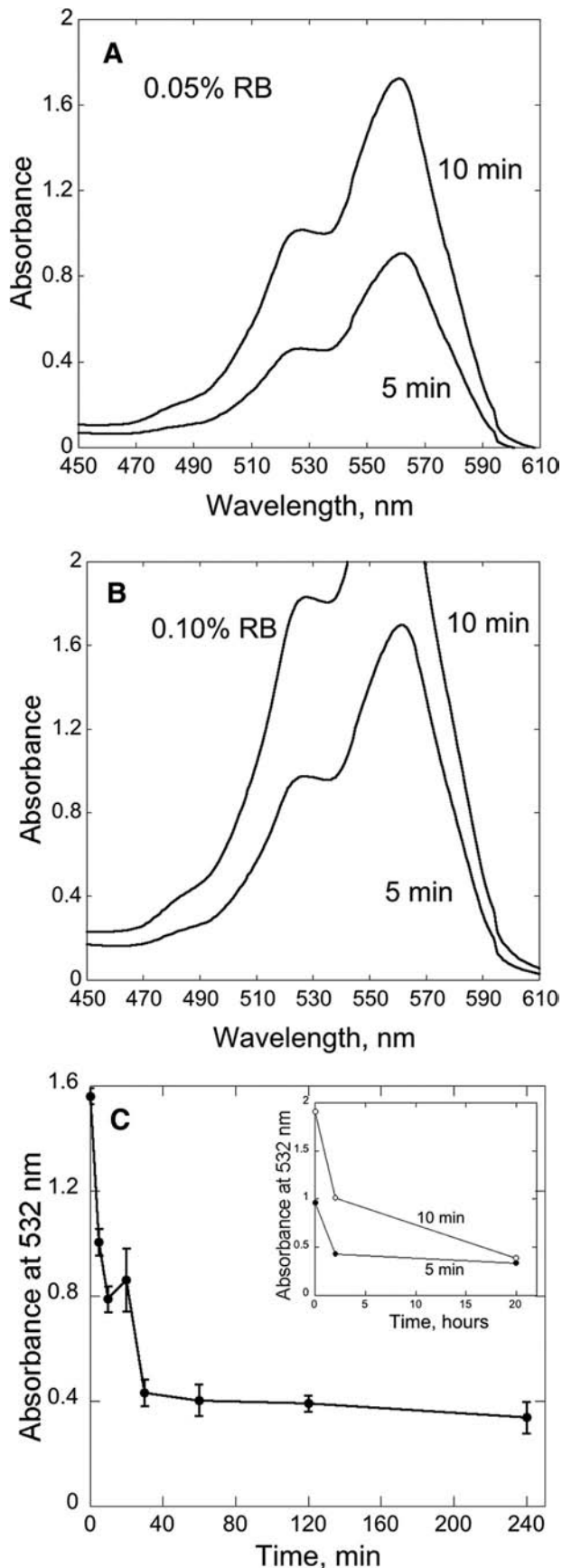
To further investigate this association, amnion was stained with 0.1% RB for 5 minutes and then was incubated in PBS for varying times. The decrease in RB absorption over time indicated that a portion of the RB diffused from the membrane (Fig. 2C). After 30 minutes, only approximately 25% of the RB was retained in the membrane. When the staining period was 10 minutes, the initial absorbance was higher, but the final amount of RB retained was the same (Fig. 3C, inset). Thus, RB appears to associate with amnion collagen in tight-binding sites that retain RB even after extended washing and in a larger number of loose-binding sites.

Bond Strength Increases with Fluence

The relationship between fluence and bond strength was measured using three fluences, 50, 100, and 150 J/cm^2 , delivered in 3.3, 6.7, and 10 minutes, respectively, to amnion stained with 0.1% RB. Controls were amnion stained with RB but not irradiated, unstained amnion treated with 150 J/cm^2 , and amnion sutured to the cornea with eight nylon sutures. As shown in Figure 3A, strong bonding was produced using all three fluences; the mean IOP_L values of 95 to 261 mm Hg are significantly higher than the normal IOP_L of human eyes (20 mm Hg). The IOP_L produced by 100 and 150 J/cm^2 differed significantly from the control ($P < 0.001$) and from each other ($P < 0.03$). Bonding strength for the controls were all < 20 mm Hg. Fibrin sealant produced an IOP_L of 66.6 ± 18.8 mm Hg, significantly different from the control ($P < 0.05$).

The adhesion of amnion to cornea was also measured using a 180° peel test (Fig. 3B). The force generated while peeling amnion from cornea after bonding with PTB was greater than that for the control using either 100 or 50 J/cm^2 ($P < 0.0005$). The adhesion strength after bonding amnion to cornea with fibrin sealant did not differ significantly from the control ($P = 0.085$).

Although the trend in the results in Figure 3A suggests that fluences higher than 150 J/cm^2 might produce even stronger



bonding, RB was destroyed (i.e., photobleached) during the irradiation as seen by the decrease in the RB absorption (Fig. 3C), suggesting that higher fluences would not proportionally increase the IOP_L .

Relationships among Irradiance, Temperature, and Bonding

Higher irradiance delivers the same fluence in a shorter time according to the relationship: Irradiance (W/cm^2) \times Time (s) = Fluence (J/cm^2). However, it might also produce a damaging temperature increase. We measured IOP_L after delivering 100 J/cm^2 at irradiances varying by a factor of 4, which required 13.3, 6.7, and 3.3 minutes of irradiation, respectively. Surface temperature was measured during the irradiations with an infrared thermometer (model 572; Fluka, Mississauga, ON, Canada). As shown in Figure 3D, the mean IOP_L for the three irradiances were 206 to 304 mm Hg, with no significant differences between these values.

The maximum temperatures attained using 0.125, 0.250, and 0.500 W/cm^2 were 22.2°C, 27.8°C, and 36.7°C, respectively (Fig. 3D); thus, a substantial increase over the control (18.3°C) was produced only by the highest irradiance. However, even 36.7°C is much lower than what is used for thermal laser welding ($\sim 75^\circ C$).^{17,18} To eliminate any potential thermal effect, 0.25 W/cm^2 was used throughout these studies.

Other Factors Influencing Bond Strength

A fixed fluence (100 J/cm^2) and irradiance (0.25 W/cm^2) were used to test variables that might affect the IOP_L . A higher RB concentration might increase bond strength because of greater light absorption (Fig. 2) and more photocrosslinking sites. As shown in Figure 4A, the IOP_L using 0.10% or 0.05% RB did not differ ($P > 0.05$). The amnion surface in contact with the cornea might also have affected the IOP_L . RB was applied to the stromal surface of deepithelialized amnion, and either the stromal or the basement membrane surface was in contact with the deepithelialized cornea. The IOP_L did not differ (Fig. 4B, second and third bars), indicating that RB applied to the stromal surface penetrates the basement membrane surface. When the epithelial layer was not removed, applying RB to the epithelial face and placing the epithelial face in contact with the cornea during irradiation produced an IOP_L that did not differ from the control (Fig. 4B, fourth bar). Finally, RB-stained amnion was washed for 1 hour to remove loosely associated RB before irradiation. The IOP_L did not differ from the control IOP_L (Fig. 4B, fifth bar), indicating that photoactivation of the tightly associated RB in the amnion was not sufficient to produce strong bonding. Further studies are required to assess the effect on photobonding of the known variation in amnion thickness and transparency.¹⁶

In Vivo Bonding of Amniotic Membrane to Rabbit Cornea

The bonding procedure shown in Figure 1 was used with 50, 100, or 150 J/cm^2 (3.3, 6.7, and 10 minutes' irradiation, respec-

FIGURE 2. Association of RB with amniotic membrane. Absorption spectra of amniotic membrane after staining with (A) 0.05% or (B) 0.10% RB for 5 and 10 minutes. (C) RB-stained amnion (0.1%, min) was suspended in PBS at room temperature for varying times, and the absorption at 532 nm RB retained in the membrane was measured (mean \pm SD). Inset: amnion was stained with RB for 5 or 10 minutes, then suspended in PBS, and absorption was measured at times up to 20 hours.

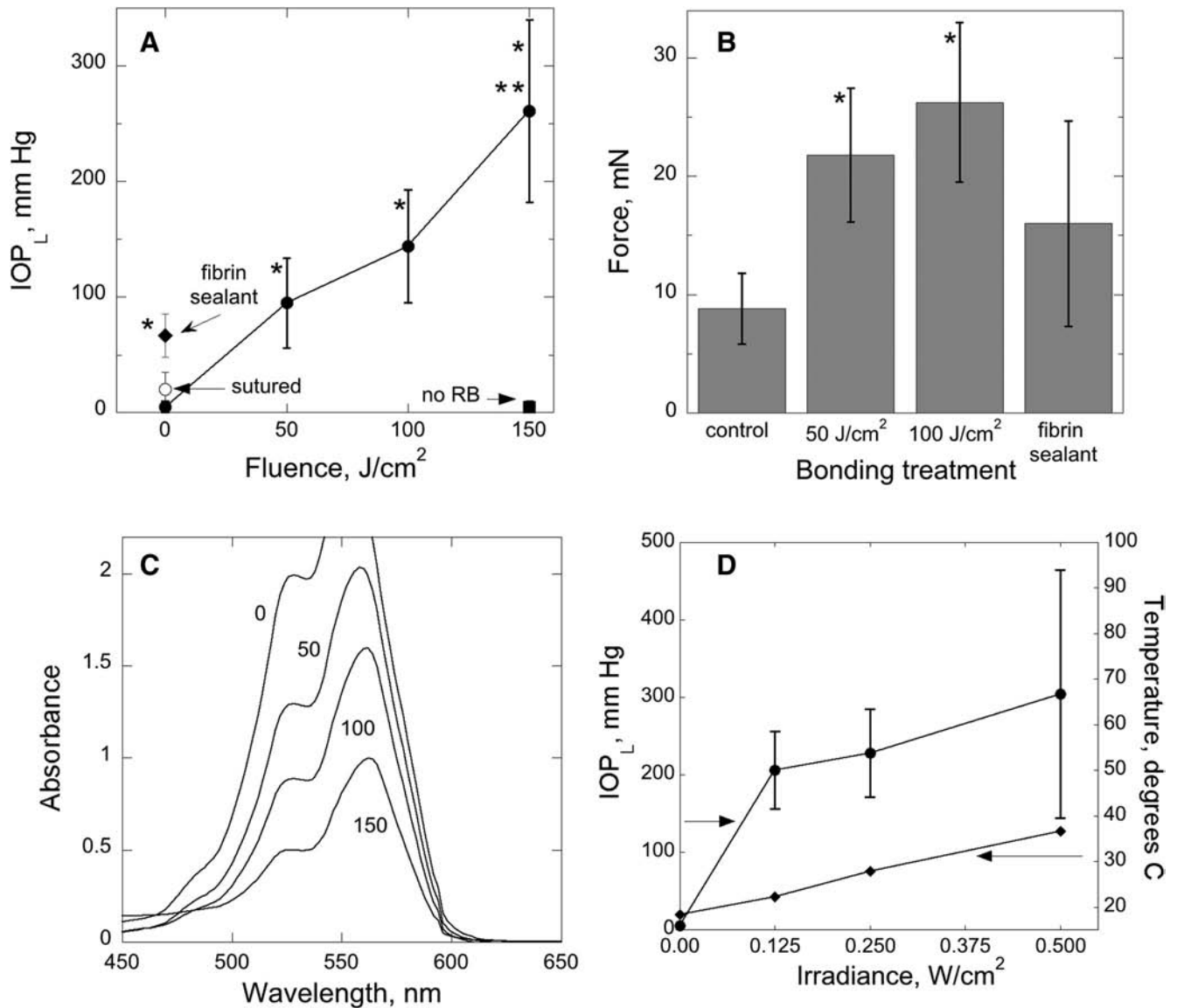


FIGURE 3. Bonding RB-stained amnion to ex vivo rabbit eyes. (A) Fluence was varied and irradiance was constant at 0.25 W/cm². Comparison was made with amnion sutured to cornea and amnion sealed to cornea with fibrin sealant. IOP_L was measured immediately after bonding treatment. Mean \pm SD; n = 6–8. *P < 0.05 versus the unirradiated control. **P < 0.05 versus the 100 J/cm² group. (B) Adhesion was measured as the force (mN) generated while peeling amnion that had been bonded to the cornea with PTB or with fibrin sealant. n = 6–8. *P < 0.05 versus the unirradiated control. (C) Photobleaching of RB-stained amnion on cornea after irradiation with fluences used for photobonding. (D) Irradiance was varied and fluence was constant at 100 J/cm². IOP_L (mean \pm SD) is shown on the left y-axis. n = 6. Temperatures measured during the irradiation are shown for irradiance on the right y-axis.

tively). Strong immediate bonding was produced at all fluences, and the bond strength increased with fluence (Fig. 5). Controls (RB-stained amnion not irradiated or unstained amnion irradiated with 150 J/cm²) did not bond. Photobonding amnion to cornea was not toxic to keratocytes (Supplementary Fig. S2, <http://www.iovs.org/lookup/suppl/doi:10.1167/iovs.11-7248/-/DCSupplemental>).

Corneal Epithelial Cell Migration on Photocrosslinked Amnion

Because RB diffuses the stroma, green light may crosslink multiple stromal proteins, including those in the basement membrane. The migration of corneal epithelial cells involves interaction with basement membrane proteins and is influenced by the properties of the surface^{19,20}; therefore, we

tested whether PTB treatment might alter the migration of these cells on amnion. As shown in Figure 6, the PTB treatment conditions used for bonding, 100 and 150 J/cm², decreased the extent of migration by approximately 15% to 30%.

Mechanism for Photobonding Amnion to Cornea

Photoactivated RB generates singlet oxygen (¹O₂), a reactive oxygen species that initiates protein-protein crosslinking by oxidizing amino acid side chains, especially histidine.^{21–23} Oxidized histidine then reacts with certain amino acids, mainly lysine, to form protein-protein crosslinks. Photoexcited RB may also transfer an electron to or from certain amino acids (AA) to form radical ions.²⁴ Crosslinks may form without oxygen when the protonated AA^{•+} combines or when AA^{•-} reacts with oxygen to form products that subsequently lead to pro-

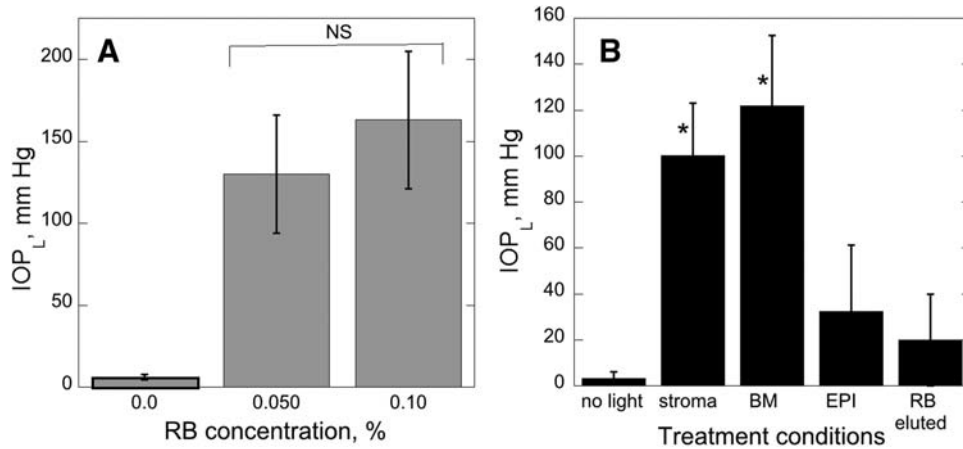


FIGURE 4. Factors potentially influencing seal strength for bonding amnion to rabbit eyes ex vivo. (A) RB concentration used to stain amnion for 5 minutes was varied. NS = $P > 0.05$. (B) Influence on IOP_L of the surface stained with RB, the surface bonded to the cornea, and removal of loosely bound RB. Amnion-covered corneas treated with 100 J/cm² and 0.25 W/cm² in all experimental groups. S, stromal surface stained, then bonded; BM, stromal surface stained but basement membrane surface bonded; EPI, epithelial layer stained, then bonded; RB eluted, loosely bound RB removed by soaking in PBS for 1 hour, then stromal surface bonded. Mean ± SD shown; n = 5. * $P < 0.05$ compared with no light group.

tein-protein crosslinks. These processes are shown in Supplementary Fig. S3, <http://www.iovs.org/lookup/suppl/doi:10.1167/iovs.11-7248/-DCSupplemental>.

To determine whether photobonding requires oxygen, irradiation was carried out in air, oxygen, or nitrogen atmospheres. Control corneas were irradiated in oxygen but were not stained with RB. Irradiations in air and oxygen produced IOP_L of 178 ± 12 and 208 ± 81 mm Hg, respectively (Fig. 7A). Irradiation in nitrogen produced a substantially lower IOP_L (66 ± 44 mm Hg) that did not differ from the control, indicating that oxygen participated in at least a portion of the reactions leading to covalent crosslinks.

To test for the involvement of ¹O₂, we used the inherently longer lifetime of ¹O₂ in D₂O than in H₂O, which will lead to

increased crosslink formation.²⁵ As shown in Figure 7B, using D₂O produced a higher IOP_L irradiation than using H₂O. Thus, the protein photocrosslinking responsible for bonding between amnion and cornea is mediated, at least partially, by ¹O₂.

DISCUSSION

These studies demonstrate that a light-activated technology that joins tissue surfaces by forming molecular crosslinks between proteins can securely attach amniotic membrane to the corneal surface. The seal formed was immediate and strong enough to seal penetrating eye wounds. The seal strength

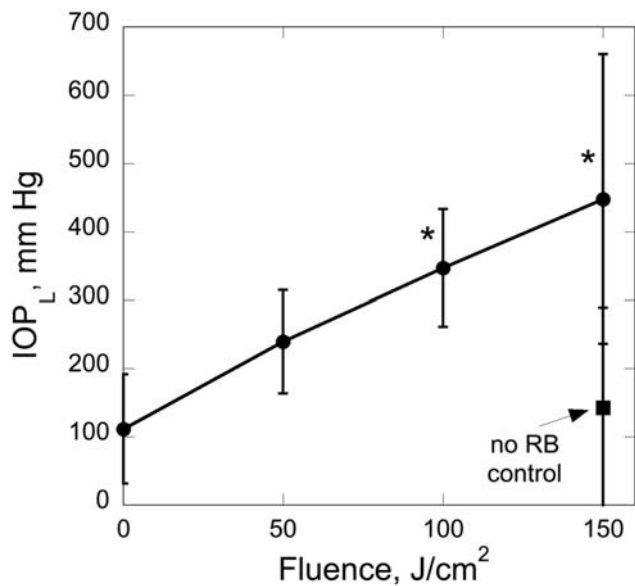


FIGURE 5. In vivo bonding of RB-stained amnion to corneal surface of rabbit eyes. Varying fluences were delivered at 0.25 W/cm² after staining with 0.1% RB for 5 minutes. No RB control, unstained amnion irradiated with 150 J/cm²; n = 5. * $P < 0.05$ compared with no RB control.

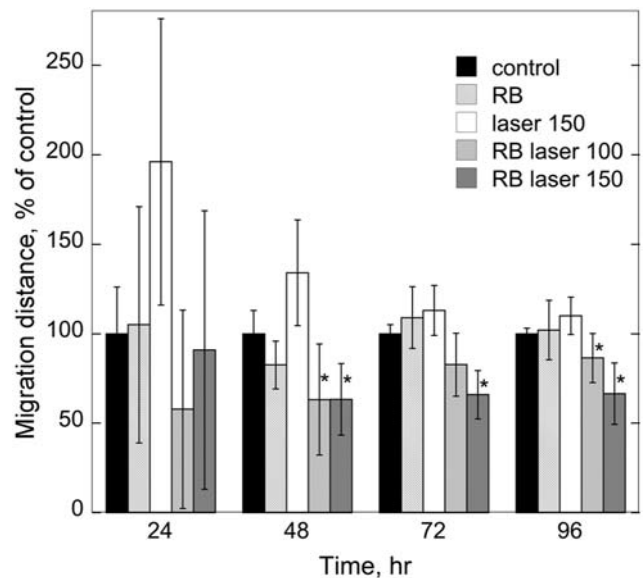


FIGURE 6. Migration of corneal epithelial cells on RB- and light-treated amniotic membrane. Cells attached to irradiated (0.1% RB, 100 and 150 J/cm²) and control amnions were allowed to migrate away from a circle, and the migration distance was measured. Mean ± SD, cumulative results from three experiments with duplicate samples. * $P < 0.05$.

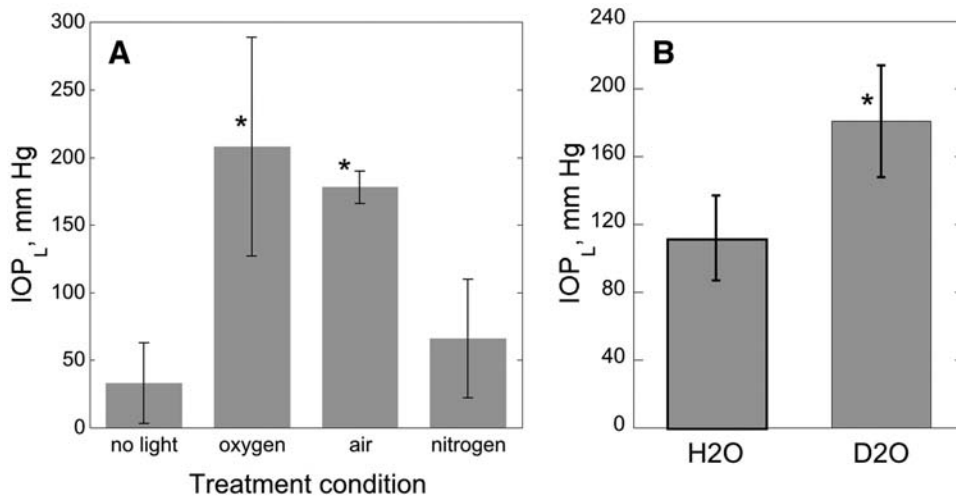


FIGURE 7. (A) Comparison of oxygen and nitrogen atmospheres on bond strength after PTB using ex vivo rabbit eyes. After conditioning eyes in oxygen, air, or nitrogen atmospheres, RB-stained amnion patches on corneas were irradiated with 100 J/cm²; n = 4/group. *P < 0.05 compared with no light control. (B) Effect of D₂O on IOP_L. RB was prepared in H₂O or D₂O, and eyes were incubated in H₂O or D₂O before bonding using 100 J/cm²; n = 5/group. *P < 0.05 compared with samples treated in H₂O.

increased with increasing fluence and required a short irradiation time.

Sutureless attachment of amnion to cornea has the advantages of being rapid, forming an immediate water-tight seal and not causing additional damage to the cornea compared with the use of sutures. Although fibrin glue has been used for sealing amnion to the ocular surface^{26,27} and is used for low-tension applications, clinical experience indicates that it has insufficient bonding strength required for large lacerations and stellate lacerations. The results of this study using a V-shaped incision mimicking a large irregular laceration support this experience. Fibrin sealant produced a lower bonding strength (Fig. 3A) and adhesion strength (Fig. 3B) than PTB. In addition, fibrin adhesive is sticky, difficult to use on cornea, and must be prepared immediately before use. PTB can be simplified for clinical application by using prestained, dry-stored amnion discs and a compact, inexpensive, non-laser light source (e.g., LED) that can deliver higher irradiances that shorten the irradiation time.

Photosensitized crosslinking of collagen is well established and is under evaluation for the treatment of keratoconus using riboflavin-5-phosphate (RF-5P).²⁸ RB also photosensitizes cross-link formation in collagen gels and scaffolds.^{29,30} Our results (Fig. 6) indicate that RB, like RF-5P,³¹ initiates protein cross-links by a mechanism involving ¹O₂. However, riboflavin has been shown to be phototoxic to keratocytes,¹⁴ whereas our results indicate that PTB will not damage keratocytes (Supplementary Fig. S2, <http://www.iovs.org/lookup/suppl/doi:10.1167/iovs.11-7248/-DCSupplemental>). We have previously shown that PTB was not phototoxic to dermal cells in vivo when PTB was used to seal skin wounds.³² A small decrease in the extent of corneal epithelial cell migration was observed (Fig. 6). Whether this response will be observed in vivo must be tested. The opaque disc over the central cornea effectively blocked light from entering the pupil, but other treatment geometries may not allow this approach. We are testing optical delivery devices that prevent focusing on the retina and thus keep the irradiance below established damage thresholds.³³

Collagens type I and III provide multiple positively charged lysines and arginines that may be sites for ionic bonding with negatively charged RB. Sequence-specific and hydrophobic interactions³⁴ also contribute because other negatively charged dyes (i.e., riboflavin-5-phosphate) do not bind in amnion (unpublished results, 2010). Tight RB-collagen complexes might involve sites within the collagen fibers, and loosely bound RB may be associated with the fiber surfaces. This model is consistent with the observation (Fig. 4B) that amnion containing only tightly bound RB does not photocrosslink to the cornea

because, to bond the tissue surfaces, the protein-protein cross-links must form between amino acids on the external surface of collagen fibers.

The full-thickness wounds used for this study are frequent in both civilian and military populations, in which they constitute approximately 50% of the eye wounds in current wars.^{35,36} Sealing amnion with PTB over these difficult-to-suture wounds has distinct advantages. In addition, our results suggest that PTB can be used for sealing amnion in corneal surgery, including pterygium excision, forniceal reconstruction, corneal melting syndromes, and attachment of composite limbal stem cell and amnion grafts.³⁷ We have initiated a detailed study of longer term biological responses to photo-bonding amnion to cornea.

Acknowledgments

The authors thank Min Yao for helpful discussions, Yijin Tang for measuring the RB absorption coefficient, Gregory Rutledge and Simon Choong for use of the universal testing system and help with the adhesion measurements, William Farinelli for technical advice, Ilene Gipson for corneal epithelial cells, and James Kobler for use of the operating microscope.

References

- Dua HS, Gomes JA, King AJ, Maharajan VS. The amniotic membrane in ophthalmology. *Surv Ophthalmol.* 2004;49:51–77.
- Christo CG, van Rooij J, Geerards AJ, Remeijer L, Beekhuis WH. Suture-related complications following keratoplasty: a 5-year retrospective study. *Cornea.* 2001;20:816–819.
- Chan BP, Amann C, Yaroslavsky AN, et al. Photochemical repair of Achilles tendon rupture in a rat model. *J Surg Res.* 2005;124:274–279.
- Chan BP, Kochevar IE, Redmond RW. Enhancement of porcine skin graft adherence using a light-activated process. *J Surg Res.* 2002;108:77–84.
- Henry FP, Goyal NA, David WS, et al. Improving electrophysiologic and histologic outcomes by photochemically sealing amnion to the peripheral nerve repair site. *Surgery.* 2009;145:313–321.
- Johnson TS, O'Neill AC, Motarjem PM, et al. Photochemical tissue bonding: a promising technique for peripheral nerve repair. *J Surg Res.* 2007;143:224–229.
- Kamegaya Y, Farinelli WA, Vila Echague AV, et al. Evaluation of photochemical tissue bonding for closure of skin incisions and excisions. *Lasers Surg Med.* 2005;37:264–270.
- Mulroy L, Kim J, Wu I, et al. Photochemical keratodesmos for repair of lamellar corneal incisions. *Invest Ophthalmol Vis Sci.* 2000;41:3335–3340.

9. O'Neill AC, Randolph MA, Bujold KE, et al. Photochemical sealing improves outcome following peripheral neurotomy. *J Surg Res*. 2009;151:33–39.
10. O'Neill AC, Winograd JM, Zeballos JL, et al. Microvascular anastomosis using a photochemical tissue bonding technique. *Lasers Surg Med*. 2007;39:716–722.
11. Proano CE, Azar DT, Mocan MC, Redmond RW, Kochevar IE. Photochemical keratodesmos as an adjunct to sutures for bonding penetrating keratoplasty corneal incisions. *J Cataract Refract Surg*. 2004;30:2420–2424.
12. Proano CE, Mulroy L, Jones E, et al. Photochemical keratodesmos for bonding corneal incisions. *Invest Ophthalmol Vis Sci*. 2004;45:2177–2181.
13. Kheirkhah A, Casas V, Sheha H, Raju VK, Tseng SC. Role of conjunctival inflammation in surgical outcome after amniotic membrane transplantation with or without fibrin glue for pterygium. *Cornea*. 2008;27:56–63.
14. Wollensak G, Spoerl E, Wilsch M, Seiler T. Keratocyte apoptosis after corneal collagen crosslinking using riboflavin/UVA treatment. *Cornea*. 2004;23:43–49.
15. Gipson IK, Spurr-Michaud S, Argueso P, et al. Mucin gene expression in immortalized human corneal-limbal and conjunctival epithelial cell lines. *Invest Ophthalmol Vis Sci*. 2003;44:2496–2506.
16. Connon CJ, Douth J, Chen B, et al. The variation in transparency of amniotic membrane used in ocular surface regeneration. *Br J Ophthalmol*. 2010;94:1057–1061.
17. Simhon D, Ravid A, Halpern M, et al. Laser soldering of rat skin, using fiberoptic temperature controlled system. *Lasers Surg Med*. 2001;29:265–273.
18. Cilesiz I, Thomsen S, Welch AJ. Controlled temperature tissue fusion: argon laser welding of rat intestine in vivo, part one. *Lasers Surg Med*. 1997;21:269–277.
19. Kimura K, Kawano S, Mori T, et al. Quantitative analysis of the effects of extracellular matrix proteins on membrane dynamics associated with corneal epithelial cell motility. *Invest Ophthalmol Vis Sci*. 2010;51:4492–4499.
20. Saez A, Ghibaudo M, Buguin A, Silberzan P, Ladoux B. Rigidity-driven growth and migration of epithelial cells on microstructured anisotropic substrates. *Proc Natl Acad Sci U S A*. 2007;104:8281–8286.
21. Kochevar IE, Redmond RW. Photosensitized production of singlet oxygen. *Methods Enzymol*. 2000;319:20–28.
22. Verweij H, Van Steveninck J. Model studies on photodynamic crosslinking. *Photochem Photobiol*. 1982;35:265–267.
23. Shen HR, Spikes JD, Kopeckova P, Kopecek J. Photodynamic crosslinking of proteins, II: photocrosslinking of a model protein-ribonuclease A. *J Photochem Photobiol B*. 1996;35:213–219.
24. Lambert CR, Kochevar IE. Electron transfer quenching of the Rose Bengal triplet state. *Photochem Photobiol*. 1997;66:15–25.
25. Ogi by P, Foote C. *J Am Chem Soc*. 1983;105:3423–3430.
26. Kheirkhah A, Casas V, Raju VK, Tseng SC. Sutureless amniotic membrane transplantation for partial limbal stem cell deficiency. *Am J Ophthalmol*. 2008;145:787–794.
27. Uhlig CE, Busse H, Groppe M. Use of fibrin glue in fixation of amniotic membranes in sterile corneal ulceration. *Am J Ophthalmol*. 2006;142:189–191.
28. Wollensak G, Redl B. Gel electrophoretic analysis of corneal collagen after photodynamic crosslinking treatment. *Cornea*. 2008;27:353–356.
29. Ibusuki S, Halbesma GJ, Randolph MA, et al. Photochemically crosslinked collagen gels as three-dimensional scaffolds for tissue engineering. *Tissue Eng*. 2007;13:1995–2001.
30. Chan BP, Hui TY, Chan OC, et al. Photochemical crosslinking for collagen-based scaffolds: a study on optical properties, mechanical properties, stability, and hemocompatibility. *Tissue Eng*. 2007;13:73–85.
31. McCall AS, Kraft S, Edelhauser HF, et al. Mechanisms of corneal tissue crosslinking in response to treatment with topical riboflavin and long-wavelength ultraviolet radiation (UVA). *Invest Ophthalmol Vis Sci*. 2010;51:129–138.
32. Yao M, Yaroslavsky A, Henry FP, Redmond RW, Kochevar IE. Phototoxicity is not associated with photochemical tissue bonding of skin. *Lasers Surg Med*. 2010;42:123–131.
33. American National Standard for Safe Use of Lasers (ANSI 136.1–2000). Orlando: Laser Institute of America, 2000.
34. Alarcon E, Edwards AM, Aspee A, et al. Photophysics and photochemistry of dyes bound to human serum albumin are determined by the dye localization. *Photochem Photobiol Sci*. 2010;9:93–102.
35. Mader TH, Carroll RD, Slade CS, et al. Ocular war injuries of the Iraqi insurgency, January–September 2004. *Ophthalmology*. 2006;113:97–104.
36. Thach AB, Johnson AJ, Carroll RB, et al. Severe eye injuries in the war in Iraq: 2003–2005. *Ophthalmology*. 2008;115:377–382.
37. Wang Y, Kochevar IE, Redmond RW, Yao M. A light-activated method for repair of corneal surface defects. *Lasers Surg Med*. 2011;43:481–489.

Light-Activated Sutureless Closure of Wounds in Thin Skin

Penggao Yang, MD,^{1,2} Min Yao, MD, PhD,^{1,2,3} Sheri L. DeMartelaere, MD,⁴ Robert W. Redmond, PhD,¹ and Irene E. Kochevar, PhD¹

¹Wellman Center for Photomedicine, Massachusetts General Hospital, Harvard Medical School, Boston, Massachusetts

²Department of Burns and Plastic Surgery, No. 3 People's Hospital, Shanghai 201900, China

³Institute of Traumatic Medicine, School of Medicine, Shanghai Jiao Tong University, Shanghai 201900, China

⁴Ophthalmology Service, San Antonio Military Medical Center, San Antonio, Texas

Background and Objectives: Closing lacerations in thin eyelid and periorbital skin is time consuming and requires high skill for optimal results. In this study we evaluate the outcomes after single layer closure of wounds in thin skin with a sutureless, light-activated photochemical technique called PTB.

Study Design/Materials and Methods: Dorsal skin of the SKH-1 hairless mouse was used as a model for eyelid skin. Incisions (1.2 cm) were treated with 0.1% Rose Bengal dye followed by exposure to 532 nm radiation (25, 50, or 100 J/cm²; 0.25 W/cm²) for PTB. Other incisions were sutured (five 10-0 monofilament), exposed only to 532 nm (100 J/cm²), or not treated. Outcomes were immediate seal strength (pressure causing leakage through incision of saline infused under wound), skin strength at 1, 3, and 7 days (measured by tensiometry), inflammatory infiltrate at 1, 3, and 7 days (histological assessment), and procedure time.

Results: The immediate seal strength, as measured by leak pressure, was equivalent for all PTB fluences and for sutures (27–32 mmHg); these pressures were significantly greater than for the controls (untreated incisions or laser only treatment; $P < 0.001$). The ultimate strength of PTB-sealed incisions was greater than the controls at day 1 ($P < 0.05$) and day 3 ($P < 0.025$) and all groups were equivalent at day 7. Sutures produced greater inflammatory infiltrate at day 1 than observed in other groups ($P = 0.019$). The average procedure time for sutured closure (311 seconds) was longer than for the PTB group treated with 25 J/cm² (160 seconds) but shorter than the group treated with 100 J/cm² (460 seconds).

Conclusion: PTB produces an immediate seal of incisions in thin, delicate skin that heals well, is more rapid than suturing, does not require painful suture removal and is easy to apply. *Lasers Surg. Med.*

© 2011 Wiley Periodicals, Inc.

Key words: eyelid; incision; laceration; laser welding; photochemical tissue bonding; Rose Bengal; wound healing; wound closure

INTRODUCTION

Repairing lacerations and closing surgical incisions in eyelid skin and the adjacent periorbital area is particularly problematic because the tissue is very thin and delicate. Sutures are the current gold standard for closure of these

wounds, but are time-consuming, especially for long or multiple lacerations, and require skilled placement of fine sutures. Suture marks may be caused by epidermal ingrowth along the suture track when the sutures are tied too tightly or remain in place too long [1]. In addition, suture removal is painful, generally requiring sedation in pediatric patients.

A sutureless light-activated technique has been introduced for wound repair that reconnects extracellular matrix proteins to form a continuous molecular seal. With this technique, called photochemical tissue bonding (PTB), a photoactive dye is applied to the tissue surfaces that are then placed in contact and irradiated with green light. The visible light does not thermally damage the tissue [2,3]. PTB is a light-activated chemical process that produces molecular bridges (crosslinks) between tissue surface proteins. We have already demonstrated in porcine skin [4] and in a clinical study (ClinicalTrials.gov, NCT00586040) that PTB is an excellent replacement treatment for superficial interrupted sutures in a layered closure of full thickness surgical wounds. After deep sutures were used to approximate the wound edges, PTB produced excellent healing and less scarring than epidermal sutures.

Eyelid skin is generally less than 1 mm thick and lacerations require only superficial sutures, not a layered closure. PTB may substantially reduce the time required for closing eyelid skin lacerations compared to sutured closure and has the advantages of allowing normal mobility of this skin compared to the stiffness produced by cyanoacrylate glues or Steri-StripsTM (3M, St. Paul, MN). However, forming a strong seal edge-to-edge in thin eyelid skin may be a challenge for PTB, because the strength of

Conflict of Interest: The PTB technology has been licensed by the Massachusetts General Hospital to Aura Medsystems, Inc. I.E.K. and R.W.R. have consulted for Aura Medsystems and will share in any income received by the hospital from the license agreement in accordance with hospital policy.

Contract grant sponsors: Department of the Army; Grant number: W81XWH-09-2-0050 and Air Force Office of Scientific Research; Grant number: FA9550-10-1-0537.

*Corresponding to: Irene E. Kochevar, PhD, Wellman Center for Photomedicine, Massachusetts General Hospital, 50 Blossom Street, Boston, MA 02114.

E-mail: kochevar@helix.mgh.harvard.edu

Accepted 20 September 2011

Published online in Wiley Online Library

(wileyonlinelibrary.com).

DOI 10.1002/lsm.21137

the bond is dependent on the size of the tissue areas in contact. In the present study, we used dorsal skin of the SKH-1 hairless mouse as a model for eyelid skin. This mouse is albino, hairless, and immunocompetent, and the back skin is 0.4–0.5 mm thick [5]. The processes of wound healing and inflammation are well characterized and readily observed in this strain of mice [6].

The broad aim of this study was to evaluate the efficacy of PTB for the single layer repair of incisions in very thin skin. Outcome measures were initial seal strength, adherence at 1, 3, and 7 days, inflammatory infiltrate, and procedure time.

MATERIALS AND METHODS

Surgical Procedure

The Subcommittee on Research Animal Care at Massachusetts General Hospital approved all procedures in this study. A total of 32 female SKH-1 hairless mice (Charles River Laboratories, Wilmington, MA), 7–8 weeks old, weighting 17–19 g, were anesthetized with ketamine (90 mg/kg) and xylazine (9 mg/kg) by intraperitoneal injection. The skin area for incision was cleaned with a 10% solution of povidone iodine (Clinipad Corporation, Guilford, CT) and rinsed with sterile saline solution before surgery. Four full-thickness incisions (1.2 cm long) were made in the skin on the back of each mouse, two on the upper flank of each side. All incisions were made perpendicular to the spine (Fig. 1A). After surgery, the incisions were dressed with Tegaderm™ film (3M Health Care) and observed once each day for 3 days.

Photochemical Tissue Bonding

A solution of 0.1% (w/v) Rose Bengal (Aldrich Chemical Co., Milwaukee, WI) in phosphate buffered saline was

applied to the walls of the incision with a cotton swab and allowed to absorb for 1 min. A cw KTP laser (Oculight, IRIDEX Corporation, Mountain View, CA) was used to produce 532 nm radiation, which is strongly absorbed by Rose Bengal (absorption coefficient $\approx 30,000 \text{ M}^{-1} \text{ cm}^{-1}$ at 532 nm). The laser irradiation was delivered with a 0.6 mm diameter fiber to a 1.13 cm^2 circular area. The irradiance was 0.25 W/cm^2 . PTB was evaluated in three groups ($n = 5$ each) using laser fluences of 25, 50, or 100 J/cm^2 (100-, 200-, and 400- second exposures, respectively) to close the incisions. For the first minute of the irradiation, the wound was very gently held closed using forceps with slight eversion of the wound edges.

Control groups ($n = 5$ each) received either no treatment or laser only (100 J/cm^2 , 532 nm). In another group ($n = 5$) the incisions were closed using black monofilament 10-0 nylon (Ethilon, Ethicon, Somerville, NJ). Five sutures, perpendicular to the wound line, were evenly spaced (0.2 cm) and of equal length (0.2 cm) and closed with 2-1-1 knots. The incisions were randomized, using a prescribed order for treatments that did not follow an obvious pattern. Thus, the quality of the incision was not related to the treatment group.

Leak Pressure (LP) Measurement

The integrity of the tissue seal was determined at day 0 (immediately after treatment) by infusing saline into a compartment between the dermis and subcutaneous layers and measuring the pressure required to cause leakage of saline through the incision. This procedure is shown in Figure 1B. Before treatment, an angiocath (IV catheter needle, 24 GA, Becton Dickinson, Franklin Lakes, NJ) was inserted through normal skin 3 mm from one end of the incision and placed between the dermis and subcutaneous layer to the middle-point of the incision. The inner metal needle was

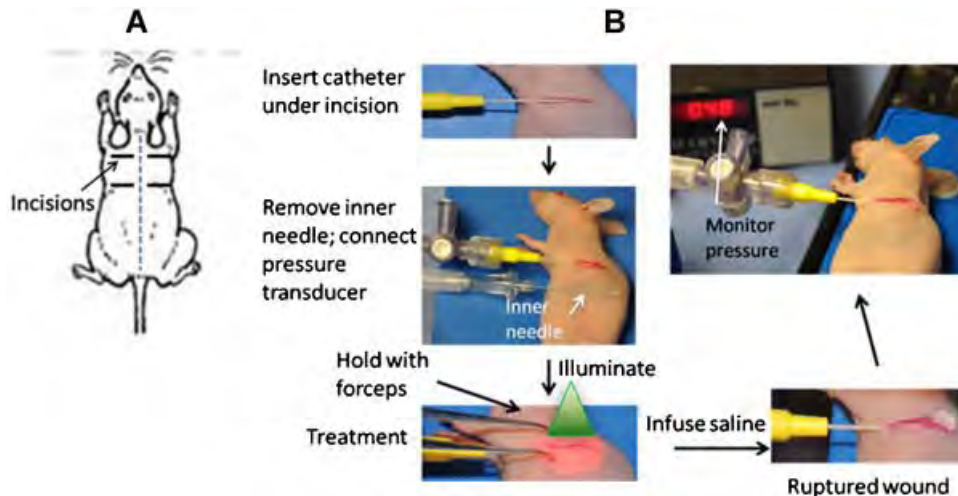


Fig. 1. Schematic diagrams of incisions and procedure for measurement of seal strength. A: Sites of 1.2 cm incisions on dorsal skin of mouse. B: Steps in measurement of leak pressure. After insertion of catheter (top left) and connecting to pressure transducer, the incision is closed with PTB, sutures, laser only, or untreated (lower left). After treatment, saline is infused under the incision (lower right) and the pressure that causes rupture is recorded.

removed so that the remaining flatheaded plastic hollow needle did not penetrate into the surrounding tissue. The needle was then connected to both a calibrated blood pressure transducer (Harvard Apparatus, South Natick, MA) and a mini-infuser (Model 400; Bard Harvard) through a T-coupler. The pressure was gradually increased by infusion of saline (0.2 ml/min) through the angiocath. The signal generated by the transducer-amplifier combination indicates the pressure. The pressure was increased until either the incision opened or fluid leaked from the incision. For groups that were not closed with PTB or sutures, each incision was held together with forceps for 400 seconds allow for formation of a natural fibrin seal.

Adherence Test

After euthanization on days 1, 3, 7, and 14, two strips (0.3 cm wide and \approx 0.8 cm long) were made across the treated incisions, one for tissue strength measurements and one for histology. The force needed to break the skin at the incision was measured with a tensiometer coupled to a digital force gauge (Zwick Roell Z010, Kennesaw, GA) with a 10 N load cell. The peak force for rupture is divided by the cross sectional area of the skin strip (width \times thickness) to determine the ultimate stress. The data were recorded by computer software (testXpert II V3.1, Zwick Roell).

Procedure Time

For the PTB groups, the time from applying RB to the wound edges to the time for completion of illumination was recorded. For the suture group, the time from opening the suture package to the time for completion of suturing was recorded.

Histology

A total of 65 specimens were obtained postoperatively: 5 specimens for the untreated, laser only, PTB (25) and PTB (100) groups were taken at day 1 and 3 and for all groups at day 7 and 14. The specimens were fixed in 10% buffered formalin and embedded in paraffin. Five micrometer vertical sections were cut to include the incision site and stained with H&E. All slides were coded and evaluated in a blinded manner by four researchers. Severity of skin inflammation was semi-quantitatively analyzed and scored on a three value scale: grade 0, normal; grade 1 (infiltrating inflammatory cells were present in <10% in the 200 \times histology image), grade 2 (10–50%), grade 3 (>50%).

Statistics

The level of significance between different groups was analyzed by ANOVA with SPSS 13.0 software. Values of $P < 0.05$ were considered statistically significant.

RESULTS

Acute Bond Strength

The influence of closure method on the pressure required to open the wound immediately after sealing (leak

pressure, LP) was evaluated. The three PTB groups were treated with laser fluences of 25, 50, or 100 J/cm² delivered over 100, 200, and 400 seconds, respectively, at a constant irradiance of 0.25 W/cm². Control incisions were untreated or treated with laser only (100 J/cm²). One group was closed with 10-0 suture. The results are shown in Figure 2. The LP for incisions treated with laser only was not significantly different from the untreated control. The LP was \approx 3-fold greater for all PTB-treated incisions than for the untreated or laser only group ($P < 0.001$). There was no significant difference of LP among PTB-treated groups ($P > 0.05$). The saline infusion endpoint for all sutured incisions was leakage between the sutures. None of the sutured incisions dehiscd. The LP for all PTB groups was equivalent to that for the suture group ($P > 0.05$). No signs of thermal damage, such as tissue shrinkage, were observed under the irradiation conditions used.

Adherence Strength

Incision adherence was assessed by tensiometry to determine ultimate strength (MPa), elongation (%), and Young's Modulus (MPa). One-way ANOVA showed that incision ultimate strength and Young's modulus increased with time after closure (Fig. 3). Ultimate strength for the PTB (25) and PTB (100) groups on days 1 and 3 were significantly higher than those for the untreated and laser only groups ($P < 0.05$). The suture group could not be tested on days 1 and 3 because removing the sutures separated the incision. There was no significant difference in ultimate strength amongst all groups on day 7. Elongation and Young's modulus were equivalent in all groups at all treatment times except for a difference in elongation

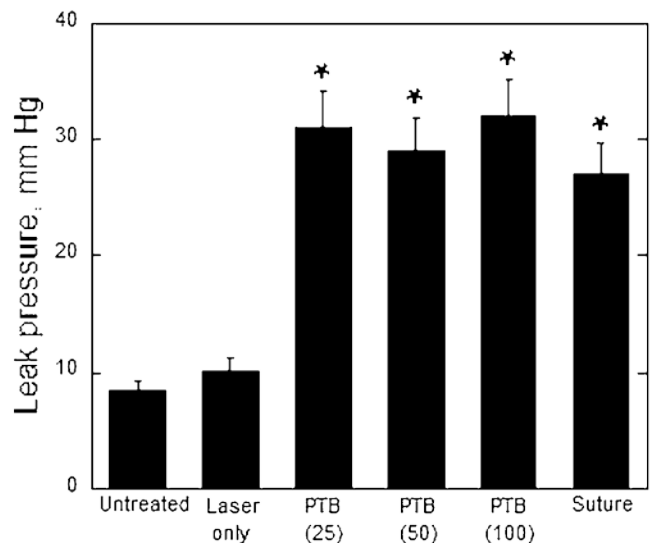


Fig. 2. Relationship between closure methods and leak pressure. Immediately after treatment, saline was infused under incisions and the pressure causing leakage through the incision recorded. $P < 0.001$ compared to the untreated and laser only groups.

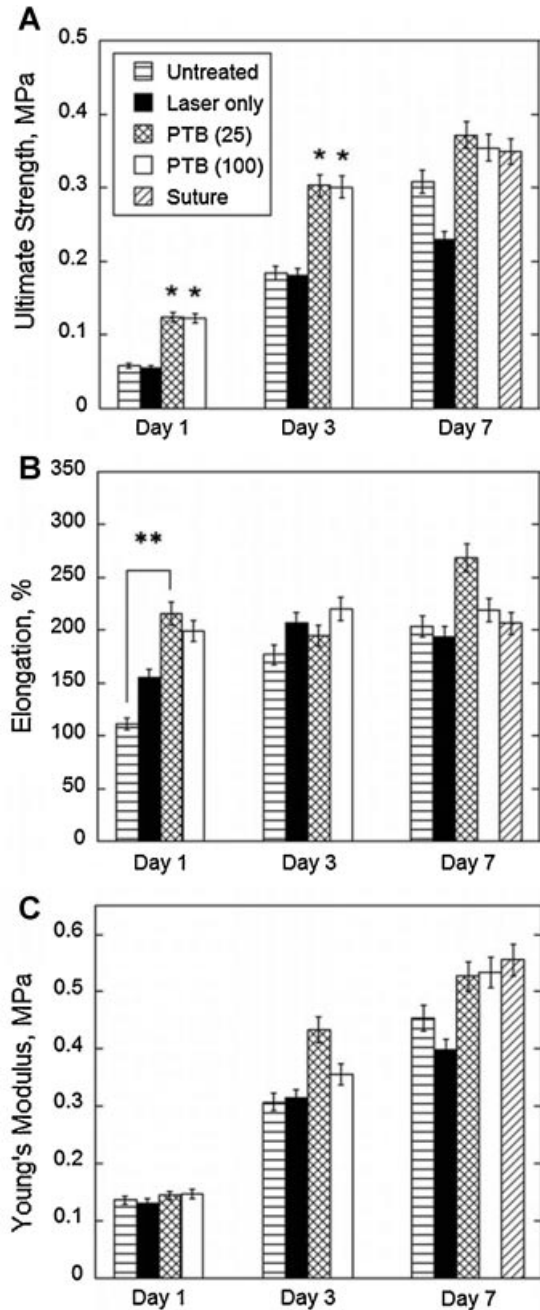


Fig. 3. Measurements of physical properties of incision site on days 1, 3, and 7 after closure with PTB, sutures, laser only, or no treatment. Measurements were made on skin strips 0.3 cm wide \times 0.8 cm long. $N = 3$ or 4. A: Ultimate strength. B: Percent elongation. C: Young's modulus. $P < 0.05$ compared with the untreated and laser only groups. $P < 0.05$ compared with the untreated group.

between untreated and PTB (25) groups on day 1 ($P > 0.05$). The results for samples taken at day 14 could not be analyzed because a decrease in the measured force occurred before the skin broke at the incision.

Procedure Time

The time required for incision closure in PTB (25), PTB (100) and the suture group was measured. For the PTB (25) and PTB (100) groups, the average times required were 160 and 460 seconds, respectively. The average time required in the suture group (311 seconds) was shorter than for the PTB (100) group ($P < 0.05$), but is about two times longer than the PTB (25) group ($P < 0.05$).

Histology

We assessed inflammation by scoring the severity of infiltration of leukocytes into the dermis. One day after surgery, we observed relatively more inflammatory cell infiltrate in the suture group (Table 1). Many fewer leukocytes were observed in the other groups. From day 3 to 14, there were no significant differences in the amount of infiltrating cells amongst all the groups. Although the suture group showed the greatest infiltrate, this was not statistically significant after day 1.

DISCUSSION

In this study, the PTB technique was found to generate immediate adherence and good healing in a mouse skin incision model that mimicked an eyelid skin wound. Moreover, this technique produced less inflammation and required less time than conventional suture wound closure. These results suggest that PTB may be applicable to single layer skin wound closure in emergency wound treatment and cosmetic surgeries.

The formation of an immediate and continuous seal is a significant feature of eyelid wound closure with PTB. Since it is difficult to apply an occlusive water-tight dressing to eyelids after suture closure of wounds, sealing the incisions with PTB would allow patients to wash and shower. In addition, an immediate wound seal may reduce infections. The protein-protein crosslinks that create the immediate seal are expected to form through the entire thickness in mouse skin and at least 0.5 mm of human eyelid skin based on our previous modeling of PTB for skin incision closure [7]. This deep seal accounts for the greater pressure required to open PTB-closed wounds than those of the control (untreated and laser only) groups (Fig. 2). Sutures, however, are significantly stronger than the PTB seal. They remained intact during the strength measurements made immediately after repair with leakage occurring only between sutures.

Healing after PTB and sutured closure of incisions appeared to be similar with an increase in inflammatory cells one day after surgery and a decrease over the following 2 weeks in all groups (Table 1). The PTB groups did not show greater levels of inflammatory cells than the other groups, consistent with our previous study demonstrating that PTB was not toxic to skin cells *in vivo* [7]. In fact, on day 1 more inflammatory cells were observed in the suture group, likely due to a foreign body reaction to the suture. This result suggests that PTB will not cause greater scarring than sutured closure. Scarring cannot be assessed in a mouse skin model, but in a pilot clinical

TABLE 1. Evaluation of Inflammation After Closure of Incisions in Hairless Mouse Skin

Groups	Leukocyte infiltration			
	Day 1	Day 3	Day 7	Day 14
Untreated	1.38 ± 0.52	1.50 ± 0.51	1.38 ± 0.51	1.08 ± 0.29
Laser (100)	1.25 ± 0.46	1.65 ± 0.49	1.45 ± 0.52	1.09 ± 0.30
PTB (25)	1.17 ± 0.39	1.35 ± 0.49	1.36 ± 0.50	1.08 ± 0.29
PTB (100)	1.13 ± 0.35	1.35 ± 0.49	1.13 ± 0.35	1.00 ± 0.00
Suture	2.00 ± 0.71	1.67 ± 0.89	1.50 ± 0.53	1.25 ± 0.46

Values are mean ± SE of five samples per group.

P < 0.05 compared to suture group at day 1.

study PTB caused less scarring than superficial sutures for closure of skin excisions (unpublished results). An increase in the strength of the skin at the wound site over the first 7 days was also observed, indicating deposition and organization of new collagen (Fig. 3A). Although sutures are stronger than the PTB seal immediately and probably at early times, by 7 days the skin strength was the same for PTB-treated and sutured (with sutures removed) wounds.

A shorter procedure time is an advantage of PTB over sutured repair. The PTB (25) group, which produced equivalent wound strength to the PTB (100) group (Figs. 2 and 3), required one-half the time as the suture group. The ratio of time required for PTB compared to suturing would be even greater for longer incisions because the beam size can be lengthened and the laser power increased to treat a longer incision in the same time used for the 1.2-cm incision in this study. Another time saving step for PTB may be reducing the 1 min delay between applying RB and irradiation. A caveat for comparing procedure times is, however, that the 10-0 sutures we used to close the very thin and soft mouse skin took longer to place than the 6-0 to 8-0 sutures generally used for patient eyelid skin.

Other comparisons of PTB and sutures can be made. Closure of eyelid wounds with PTB eliminates the need for painful suture removal, which in children generally requires sedation. Other sutureless methods, namely, cyanoacrylate glues and skin tapes, restrict opening and closing of the eyelids compromising vision [8]. Potential suture-related complications are also eliminated with PTB. These include placing sutures too deeply and incorporating the orbital septum during closure. This is particularly a problem in traumatic injuries and may lead to cicatricial ectropion and cicatricial lagophthalmos [9,10]. PTB is also very simple to apply, only requiring application of a dye solution to the wound edges, apposition of the edges, and exposure of the site to green light. The need for careful and evenly spaced placement of sutures is eliminated.

Since PTB utilizes a bright green light, a contact lens-like nonreflective corneal shield would be placed on the patient's eye, and the surgeon and operative team would wear eye protection. A small green clinical laser (Oculight, IRIDEX Corp., Mountain View, CA) was used in this study. Closure of eyelid incisions only required

25 J/cm² suggesting that small compact light sources might be used in the future. As blood also absorbs green light, the PTB irradiation should not be carried out in the presence of active bleeding.

In summary, these results demonstrate the potential of PTB to close full-thickness incisions in thin skin. The repair procedure produces an immediate watertight seal that heals equivalently to sutured closure, requires a shorter time than suturing, does not require painful suture removal, and is easy to apply. PTB merits further evaluation for closing wounds to eyelid and periorbital skin and may have particular application to traumatic injuries and to pediatric patients.

ACKNOWLEDGMENTS

We thank Dr. Jenny Zhao for assistance with the histology and Salvador Cervantes for help with the tensiometry measurements.

REFERENCES

1. Stegman SJ. Suturing techniques for dermatologic surgery. *J Dermatol Surg Oncol* 1978;4(1):63-68.
2. Mulroy L, Kim J, Wu I, Scharper P, Melki SA, Azar DT, Redmond RW, Kochevar IE. Photochemical keratodesmos for repair of lamellar corneal incisions. *Invest Ophthalmol Vis Sci* 2000;41(11):3335-3340.
3. Chan BP, Kochevar IE, Redmond RW. Enhancement of porcine skin graft adherence using a light-activated process. *J Surg Res* 2002;108(1):77-84.
4. Kamegaya Y, Farinelli WA, Vila Echague AV, Akita H, Gallagher J, Flotte TJ, Anderson RR, Redmond RW, Kochevar IE. Evaluation of photochemical tissue bonding for closure of skin incisions and excisions. *Lasers Surg Med* 2005;37(4):264-270.
5. Kochevar IE, Moran M, Lyon N, Flotte T, Siebert E, Gange RW. Effects of systemic indomethacin, meclizine, and BW755C on chronic ultraviolet B-induced effects in hairless mouse skin. *J Invest Dermatol* 1993;100(2):186-193.
6. Benavides F, Oberyszyn TM, VanBuskirk AM, Reeve VE, Kusewitt DF. The hairless mouse in skin research. *J Dermatol Sci* 2009;53(1):10-18.
7. Yao M, Yaroslavsky A, Henry FP, Redmond RW, Kochevar IE. Phototoxicity is not associated with photochemical tissue bonding of skin. *Lasers Surg Med*; 42(2):123-131.
8. Currie LJ, Sharpe JR, Martin R. The use of fibrin glue in skin grafts and tissue-engineered skin replacements: A review. *Plast Reconstr Surg* 2001;108(6):1713-1726.
9. Glavas IP. The diagnosis and management of blepharoplasty complications. *Otolaryngol Clin North Am* 2005;38(5):1009-1021.
10. Hartstein ME, Kikkawa D. How to avoid blepharoplasty complications. *Oral Maxillofac Surg Clin North Am* 2009; 21(1):31-41 (v-vi).

Poster presented at the 2013 Military Health System Research Symposium (MHSRS), Fort Lauderdale FL, August 12-15, 2013.

Crosslinking Repair of Corneal Lacerations In the New Zealand White Rabbit.

Johnson AJ, Cora S, Ecklund B, Wang H-C, Remond RW, Verter E, Kochevar IE.

Objective To compare clinical and histologic healing of corneal lacerations repaired by sutures or with a single suture augmented with amniotic membrane crosslinking

Methods A central full-thickness 3-mm laceration was made in the right eyes of 30 New Zealand White Rabbits. Half of the wounds were treated with 3 interrupted 10-0 nylon sutures. The other half were treated with one suture to reapproximate the stroma then crosslinked with amniotic membrane impregnated with rose Bengal dye. Slitlamp examination was performed at daily for 7 days, and weekly for 21 days. Animals were humanely euthanized at days 3, 7, and 28 for histologic examination to evaluate corneal healing.

Results Both methods were equally effective at maintaining physiologic pressure. Histologic observations on days 3, 7, and 28 showed crosslinked corneas exhibited lower amounts of inflammation. Clinically, all sutured corneas remained clear while crosslinked corneas did not reach an equivalent clarity until day 7. The procedure was about 2 times faster with sutures.

Conclusion Corneal lacerations treated with crosslinking compares with sutures for the treatment of simple corneal lacerations.

Clinical Relevance Crosslinking technologies represent a safe, effective, and technically easier alternative to traditional suture repair of corneal perforations. Due to the rapid ability to close a simple laceration the suturing was faster; however as the complexity of the laceration increases cornea crosslinking is expected to provide superior closure times.

Abstract: Platform presentation at 2011 ATACCC Conference, Fort Lauderdale FL, August 15-18, 2011

Sealing Penetrating Eye Injuries Using Photoactivated Bonding

A.J. Johnson, E.E. Verter, T. Gisel, P. Yang, R.W. Redmond, I.E. Kochevar

Objective: To rapidly seal irregular-shaped penetrating wounds in cornea and sclera with less scarring, better visual outcomes and reduced OR time requirement.

Background: Closure of penetrating eye wounds with sutures is a time-consuming procedure that produces scarring and consequent poor visual outcome. We have developed a tissue repair technology (PTB) that bonds tissue surfaces together using a dye and green light. Light-activation of the dye cross-links proteins to bridge the tissue surfaces thus producing a water-tight seal. PTB has been used successfully in a clinical study for superficial wound closure and in preclinical studies for reattachment of peripheral nerves, blood vessel anastomosis and tendon repair. In this study, PTB was used to seal human amniotic membrane (HAM) over penetrating cornea wounds.

Methods: A HAM patch (13-mm diameter) was stained on the stromal side with Rose Bengal (RB) and placed over a V-shaped incision in de-epithelialized central cornea. A 4-mm opaque disc was placed over the incision before green light treatment (532 nm KTP laser). The strength of the seal was measured by infusing saline into the anterior chamber and measuring the pressure that produced leakage (IOP_L).

Results: Sealing HAM over cornea wounds in rabbit eyes produced IOP_L significantly higher than the normal IOP. Bonding with 0.1% RB and 150 J/cm^2 at 532 nm produced an IOP_L of $448 \text{ mm} \pm 212 \text{ mm Hg}$ in vivo. Bonding ex vivo eyes showed that the IOP_L increased with increasing fluence ($50\text{-}150 \text{ J/cm}^2$; 3.3 to 10 min); the IOP_L attained over this range was 95 to 261 mm Hg. HAM sutured over the wound produced an IOP_L of 20 mm Hg. A small temperature increase was observed, from room temperature to 36°C , during ex vivo bonding. Equivalent IOP_L was produced for bonding basement membrane or stromal HAM surfaces to the cornea surface.

Conclusions: These results indicate that PTB may be a useful clinical approach for rapid sutureless sealing of penetrating eye injuries.

Abstract: Invited presentation at the Annual Meeting of the American Society for Photobiology, June 12-16, 2011, Providence RI.

Rose Bengal photosensitized crosslinking of collagen for repair of penetrating eye injuries

E. Verter¹, M. Yao¹, A. Blanden¹, A. Blanden¹, A.J. Johnson², R.W. Redmond¹ and I.E. Kochevar¹

¹Wellman Center for Photomedicine, Massachusetts General Hospital, Boston MA and ²Brooke Army Medical Center, San Antonio, TX

We are developing a rapid, simple method for tissue repair that may replace sutures in many types of surgery. Rose Bengal (RB) photosensitization is used to initiate formation of covalent crosslinks between extracellular matrix proteins between tissue surfaces in a process called Photochemical Tissue Bonding (PTB). Although RB is widely known to be phototoxic to cells in vitro, our previous study indicated that PTB is not cytotoxic when used to bond skin in vivo.

In this study, we used PTB to seal penetrating eye injuries. V-shaped incisions were made centrally in the cornea of ex vivo rabbit eyes. A circular "patch" of human amniotic membrane (13 mm diameter) was stained on the stromal side with RB and placed over the corneal incision. A small opaque disc (4 mm diameter) was placed over the central cornea. The corneal surface was exposed to green light from a 532 nm KTP laser to bond the amnion to the cornea surface. The strength of the seal was measured by infusing saline into the anterior chamber and determining the intraocular pressure that produced leakage (IOP_L) at the wound site. The IOP_L increased with increasing RB concentration (0.01 – 1%) and with increasing light fluence (25 – 150 J/cm²). Treatment with 0.1% RB in PBS and 100 J/cm² produced an IOP_L of 250 mm Hg, which is >10-fold higher than the IOP in normal eyes. Purging the cornea + amnion with nitrogen during the irradiation in a special chamber inhibited bonding. Chemically blocking amnion protein lysines, which are frequently involved in protein crosslinks, did not alter the PTB-induced bond strength. These results indicate that PTB may be a useful clinical approach for sealing penetrating eye injuries.

Abstract: Poster presented at the 2010 ATACCC Conference, St. Pete Beach FL, August 16-19, 2010

Light-activated repair of traumatic injuries

Irene E. Kochevar and Robert W. Redmond

We have developed a light-activated tissue repair technology to attach tissue surfaces and create engineered tissues that is applicable to repair of traumatic injuries. The technology, called Photo Tissue Bonding (PTB), is based on photochemical crosslinking of tissue proteins and produces an immediate, water-tight and strong bond. PTB has been successfully used in preclinical studies to seal corneal incisions and transplants, seal skin incisions and to reattach peripheral nerves, small blood vessels and tendons. A pilot clinical study to skin excisional wounds demonstrated that PTB produced less scarring than epidermal sutures. Light-activated crosslinking of proteins has also been used in the generation of neocartilage.

In the PTB process, a light-sensitive dye (Rose Bengal) is applied to the tissue surfaces, the surfaces are placed in contact and the dye-stained area is exposed to green light (532 nm; KTP laser) for a few minutes without causing thermal damage. Recent results from three studies will be presented.

1) Peripheral nerve repair: Neurorrhaphy of severed rabbit peroneal nerve using PTB to seal a wrap of RB-coated human amnion over the repair site demonstrated greater histological and electrophysiologic recovery than sutured repair. This result suggests that PTB seals and isolates the internal nerve environment for optimal nerve regrowth as well as reducing needle trauma. 2) Sealing skin excisional wounds: In a pilot clinical study, PTB was compared with sutures for superficial closure of excisional wounds (collaboration with S. Tsao, MD). In 31 wounds, after placement of deep sutures, one half was closed with sutures and one half closed with PTB. At 2 weeks post surgery the PTB-closed side showed much less inflammation than sutured closure and at 6 months showed less scarring. 3) Sealing penetrating eye injuries: PTB was used to seal amnion over corneal and scleral wounds in rabbit eyes ex vivo (collaboration with Col A.J. Johnson MD). Wounds sealed with PTB resisted intraocular pressures up to 200 mm Hg.

Abstract: Poster presented at 4th Military Vision Symposium, Schepens Eye Research Institute, Boston MA September 27-29, 2010

Photoactivated technology for repair of penetrating eye injuries

E. Verter¹, A.J. Johnson², M. Yao¹, R.W. Redmond¹ and I.E. Kochevar¹

¹Wellman Center for Photomedicine, Massachusetts General Hospital, Boston MA and ²Brooke Army Medical Center, San Antonio, TX

Objectives: To develop a method to rapidly and effectively seal irregular-shaped penetrating wounds in cornea and sclera without sutures.

Background: We are developing a rapid, simple method for tissue repair that may replace sutures in many types of surgery. A photoactive dye (Rose Bengal) is applied to the tissue surfaces, then excited with green light to initiate formation of covalent crosslinks between proteins on the tissue surfaces. This process, called Photochemical Tissue Bonding (PTB), does not require a temperature increase. PTB technology has been used in a pilot clinical study for superficial wound closure as well as in preclinical studies for reattachment of peripheral nerve, blood vessel anastomosis and tendon repair.

Suturing amniotic membrane to cornea during surgery is time-consuming and sutures may further damage the eye. We introduce a novel sutureless light-activated technique that securely attaches amnion to cornea via protein-protein crosslinks.

Methods: In this study, we used PTB to seal penetrating eye injuries. V-shaped incisions were made centrally in the cornea of ex vivo rabbit eyes. A circular "patch" of human amniotic membrane (13 mm diameter) was stained on the stromal layer with RB (0.1% solution in PBS) and placed over the corneal incision. A small opaque disc (4 mm diameter) was placed over the central cornea to prevent light entering the pupil. The amnion and corneal surface was exposed to green light from a 532 nm KTP laser to activate the RB dye, which created a strong bond between the amnion and the cornea surface. The strength of the seal was measured by infusing saline into the anterior chamber and measuring the intraocular pressure that produced leakage (IOP_L) at the wound site.

Cryopreserved human amniotic membrane, stained with Rose Bengal (RB), was placed over a full-thickness wound in de-epithelialized rabbit cornea and treated with green laser. The intraocular pressure that broke the seal (IOP_L) was measured. The influences on IOP_L of fluence, irradiance, RB concentration and amnion surface bonded were measured. Epithelial cell migration on treated amnion and keratocyte viability after bonding were measured. The involvement of oxygen, singlet oxygen and association of RB with stromal collagen in the bonding mechanism was investigated.

Results: The IOP_L increased with increasing RB concentration (0.01 – 1%) and with increasing light fluence (25 – 150 J/cm²). Treatment with 0.1% RB in PBS and 100 J/cm² produced an IOP_L of 250 mm Hg, which is >10-fold higher than normal IOP. Purging the cornea + amnion with nitrogen during the irradiation in a special treatment chamber inhibited bonding suggesting that the bonding mechanism involves formation of reactive oxygen species. Pilot studies using PTB to seal amnion over wounds in vivo in rabbit eyes produced similar results. This approach was also effective for sealing penetrating scleral wounds.

Sealing amniotic membrane over cornea using 0.1% RB and 150 J/cm^2 at 532 nm produced an IOP_L of $261 \pm 77 \text{ mm Hg}$ ex vivo and $448 \text{ mm} \pm 212 \text{ mm Hg}$ in vivo. The ex vivo IOP_L increased with increasing fluence ($50\text{-}150 \text{ J/cm}^2$) but not with irradiance (0.125 to 0.50 W/cm^2). Equivalent IOP_L was produced for bonding basement membrane or stromal amnion surfaces. The bonding treatment was not toxic to keratocytes but slightly reduced the migration of corneal epithelial cells on amnion ex vivo. Mechanism studies indicated that RB forms two complexes with amnion stromal collagen, that bonding requires oxygen and that singlet oxygen mediates protein crosslinking.

Conclusions: These results indicate that PTB may be a useful clinical approach for sutureless sealing of penetrating eye injuries.

A rapid, light-activated technique produces strong, continuous bonding between amnion and cornea without sutures and merits further evaluation for ocular surface surgeries.