

Blast-induced moderate neurotrauma (BINT) elicits early complement activation and tumor necrosis factor alpha (TNF α) release in a rat brain

Jurandir J. Dalle Lucca ^{a,*}, Mikulas Chavko ^b, Michael A. Dubick ^a, Saleena Adeeb ^b, Michael J. Falabella ^a, Jessica L. Slack ^a, Richard McCarron ^b, Yansong Li ^a

^a Immunomodulation of Trauma Program, US Army Institute of Surgical Research, 3650 Chambers Pass, BHT2/Building 3610, Fort Sam Houston, TX 78234, USA

^b Department of Trauma and Resuscitation Medicine, Naval Medical Research Center, 503 Robert Grant Avenue, Silver Spring, MD 20910, USA

ARTICLE INFO

Article history:

Received 25 August 2011

Received in revised form 26 January 2012

Accepted 1 February 2012

Available online 25 April 2012

Keywords:

Blast overpressure

Blast-induced neurotrauma

Complement activation

Edema

Inflammatory cytokine

Leukocyte infiltration

ABSTRACT

Blast induced neurotrauma (BINT) is a major medical concern yet its etiology is largely undefined. Complement activation may play a role in the development of secondary injury following traumatic brain injury; however, its role in BINT is still undefined. The present study was designed to characterize the complement system and adaptive immune inflammatory responses in a rat model of moderate BINT.

Anesthetized rats were exposed to a moderate blast (120 kPa) using an air driven shock tube. Brain tissue injury, systemic and local complement, cerebral edema, inflammatory cell infiltration, and pro inflammatory cytokine production were measured at 0.5, 3, 48, 72, 120, and 168 h. Injury to brain tissue was evaluated by histological evaluation. Systemic complement was measured via ELSIA. The remaining measurements were determined by immunohistofluorescent staining.

Moderate blast triggers moderate brain injuries, elevated levels of local brain C3/C5b 9 and systemic C5b 9, increased leukocyte infiltration, unregulated tumor necrosis factor alpha (TNF α), and aquaporin 4 in rat brain cortex at 3 and 48 hour post blast. Early immune inflammatory response to BINT involves complement and TNF α , which correlates with hippocampus and cerebral cortex damage. Complement and TNF α activation may be a novel therapeutic target for reducing the damaging effects of BINT inflammation.

Published by Elsevier B.V.

1. Introduction

Blast induced neurotrauma (BINT) is the signature life threatening wound of current military casualties in Operation Iraqi Freedom and Operation Enduring Freedom and casualties in the overseas contingency operations. According to the Department of Defense "Personnel & Procurement Statistics," more than 73% of all US military casualties in Operation Enduring Freedom and Operation Iraqi Freedom are caused by explosive weaponry [1]. Our military casualties exposed to blast injuries are frequently subjected to delayed medical evacuation to higher echelons of care, which ranges from 1 h to several days [2]. During this time frame, secondary neurodegenerative molecular responses promote further neuronal injury. Therefore, the identification of culprit molecules and pathways associated with neuronal injury after blast provides insight for the development of new pharmacotherapeutic strategies aimed at decreasing the hyperinflammatory response to blast and the progression of secondary injuries associated with this condition.

BINT is characterized by primary brain injury (unavoidable mechanical brain damage), which results in the disruption of brain parenchyma and cerebral blood vessels immediately. The subsequent development

of secondary brain injury is defined by the various pathogenic events at cellular, biochemical, and molecular levels, including inflammation, ischemia, cell/axon damage, physiological disturbances (hypotension, metabolic alteration, electrolytic abnormality, homeostatic change), and hemorrhage, which progressively contribute to the worsened neurological impairment [3–5]. These secondary mechanisms involve the initiation of an acute inflammatory response, including breakdown of the blood brain barrier (BBB), edema formation and swelling, infiltration of peripheral blood cells, and activation of resident immunocompetent cells as well as the intrathecal release of numerous immune mediators such as interleukins and chemotactic factors.

Previous studies have demonstrated that a moderate level of blast overpressure (BOP) (126 kPa) resulted in brain inflammation with widespread fiber degeneration and dysfunction of neurologic and neurobehavioral performance [6]. Reactive gliosis, neuronal swelling, and cytoplasmic vacuolization also have been observed in the hippocampus of rats subjected to thoracic blast injury [7,8]. Furthermore, rats exposed to moderate levels of BOP (120 kPa) have been shown to display increased BBB permeability, oxidative stress, and activated microglia [9].

Complement activation has been suggested to play a critical role in the development of secondary injury following traumatic brain injury (TBI). In clinical studies, elevated levels of alternative pathway complement components C3 and factor B as well as activated soluble C5b 9 were detected in the cerebral spinal fluid (CSF) of patients

* Corresponding author. Tel.: +1 210 539 3698; fax: +1 210 539 6244.
E-mail address: Jurandir.dallelucca@us.army.mil (J.J. Dalle Lucca).

Report Documentation Page

Form Approved
OMB No. 0704-0188

Public reporting burden for the collection of information is estimated to average 1 hour per response, including the time for reviewing instructions, searching existing data sources, gathering and maintaining the data needed, and completing and reviewing the collection of information. Send comments regarding this burden estimate or any other aspect of this collection of information, including suggestions for reducing this burden, to Washington Headquarters Services, Directorate for Information Operations and Reports, 1215 Jefferson Davis Highway, Suite 1204, Arlington VA 22202-4302. Respondents should be aware that notwithstanding any other provision of law, no person shall be subject to a penalty for failing to comply with a collection of information if it does not display a currently valid OMB control number.

1. REPORT DATE 01 JUL 2015	2. REPORT TYPE N/A	3. DATES COVERED -			
4. TITLE AND SUBTITLE Blast-induced moderate neurotrauma (BINT) elicits early complement activation and tumor necrosis factor alpha (TNFalpha) release in a rat brain		5a. CONTRACT NUMBER			
		5b. GRANT NUMBER			
		5c. PROGRAM ELEMENT NUMBER			
6. AUTHOR(S) Dalle Lucca J. J., Chavko M., Dubick M. A., Adeeb S., Falabella M. J., Slack J. L., McCarron R., Li Y.,		5d. PROJECT NUMBER			
		5e. TASK NUMBER			
		5f. WORK UNIT NUMBER			
7. PERFORMING ORGANIZATION NAME(S) AND ADDRESS(ES) United States Army Institute of Surgical Research, JBSA Fort Sam Houston, TX		8. PERFORMING ORGANIZATION REPORT NUMBER			
9. SPONSORING/MONITORING AGENCY NAME(S) AND ADDRESS(ES)		10. SPONSOR/MONITOR'S ACRONYM(S)			
		11. SPONSOR/MONITOR'S REPORT NUMBER(S)			
12. DISTRIBUTION/AVAILABILITY STATEMENT Approved for public release, distribution unlimited					
13. SUPPLEMENTARY NOTES					
14. ABSTRACT					
15. SUBJECT TERMS					
16. SECURITY CLASSIFICATION OF:			17. LIMITATION OF ABSTRACT UU	18. NUMBER OF PAGES 9	19a. NAME OF RESPONSIBLE PERSON
a REPORT unclassified	b ABSTRACT unclassified	c THIS PAGE unclassified			

with severe head trauma injuries [10,11]. Complement mediated secondary brain injury after TBI has been observed in clinical [11] and experimental studies [12]. Severe secondary insults in TBI were paralleled by more pronounced complement activation, particularly by the end product C5b 9 [13]. These secondary injuries include the recruitment of inflammatory cells into the intrathecal compartment, the induction of BBB dysfunction by the anaphylatoxins C3a and C5a, the induction of neuronal apoptosis through the C5a receptor (C5aR) expressed on neurons, and homologous cell lysis mediated by complement activation through the membrane attack complex (MAC/C5b 9) [14]. A recent study from our group has shown that complement activation is associated with hypoxia induced disruption of neuronal network, loss of dendritic spine, and neuronal apoptosis [15]. Complement activation may represent a crucial mediator of neuroinflammation and neurodegeneration after TBI. The complement system has also been considered as a functional bridge between the innate and the adaptive immune system [16–18]. Adaptive immune responses and their deleterious effects have been documented after TBI [19]. The neuroinflammatory cascade is characterized by the activation of glial cells, release of proinflammatory cytokines and chemokines, upregulation of endothelial adhesion molecules, and intracranial activation of the complement system, resulting in release of potent inflammatory anaphylatoxins [14].

Although BINT may share similar components of the inflammatory response to closed TBI, the characterization of the signature pathophysiological profile of BINT remains to be determined. The present study was designed to characterize the complement system and adaptive immune inflammatory responses in a rat model of moderate BINT.

2. Materials and methods

This study has been conducted in compliance with the Animal Welfare Act and the implementing Animal Welfare Regulations and in accordance with the principles of the Guide for the Care and Use of Laboratory Animals. The study was approved by the Walter Reed Institute of Research (WRAIR) Institutional Animal Care and Use Committee.

2.1. Experimental design and exposure to blast overpressure

Exposure to blast was conducted as previously described [20]. Briefly, adult pathogen free male Sprague Dawley rats weighing 250 to 300 g were anesthetized with intraperitoneal (i.p.) injection of ketamine or xylazine (60/5 mg/kg) and randomly assigned to each experimental group. Anesthetized animals were placed in a transverse prone position into the end of the expansion chamber of a compressed air driven shock tube (2.5 ft compression chamber connected to a 15 ft expansion chamber) and fixed in a holder to restrict any accelerated body movement from blast impact and prevent subsequent secondary or tertiary blast injuries. Animals were then subjected to a short duration blast wave with a mean peak overpressure of 120 ± 7 kPa (Fig. 1). The animals were enrolled in one of seven experimental groups:

• Control	Animals underwent anesthesia, suspension, time delays except for BOP exposure (n=6).
• BOP – 0.5 h	Animals were subjected to BOP and recovered for 0.5 h (n=6).
• BOP – 3 h	Animals were exposed to BOP and recovered for 3 h (n=5).
• BOP – 48 h	Rats underwent BOP and recovered for 48 h (n=5).
• BOP – 72 h	Animals were exposed to BOP and recovered for 72 h (n=6).
• BOP – 120 h	Animals were exposed to BOP and recovered for 120 h (n=7).
• B – 168 h	Animals were exposed to BOP and recovered for 168 h (n=7). Animals that did not survive exposure (10%) were excluded from further analysis.

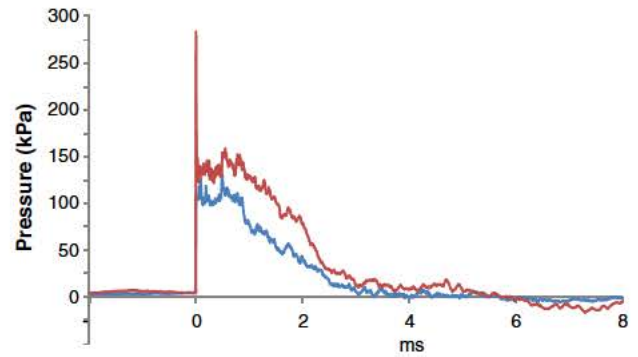


Fig. 1. Schematic diagram of the short duration blast wave. Representative picture of the duration of the pressure pulse and the pressure traces as measured inside the shock tube and during blast. Total pressure (red line), static pressure (blue line). Please note that animals were fixed therefore acceleration movement did not contribute to resultant injuries.

2.2. Sampling

At the end of each aforementioned recovery period, animals were anesthetized with ketamine or xylazine, and blood was withdrawn by heart puncture. Ethylenediaminetetraacetic (EDTA) plasma samples were collected by centrifuging at 4000 rpm for 5 min and stored at -80°C until use for in an enzyme linked immunosorbent assay (ELISA) of C5b 9. The brain tissues were removed and inspected for gross pathology. The brains were transferred to be frozen on dry ice and stored at -80°C for determining protein expression by Western blotting, 4% of paraformaldehyde in phosphate buffered saline (PBS) for frozen blocks or 10% formalin solution for paraffin blocks. For preparation of frozen blocks, the paraformaldehyde fixed brains were cryoprotected by subsequent immersion in 20% sucrose in PBS at 4°C overnight. To make frozen blocks, the brains were then rapidly frozen with optimal cutting temperature (OCT) compound 4853 (embedding medium for frozen tissue specimens, Miles Inc., Elkhart, IN) using a HistoPrep disposable base mold (15 × 15 × 5 mm, Fisher Scientific, Pittsburgh, PA) on dry ice for 30 min. Frozen blocks were kept at -80°C until the frozen section was cut.

2.3. Reagents and antibodies

Rat C5b 9 ELISA kits were from Cedarlane (Burlington, NC). Chick en anti mouse C3/C3a, mouse anti rat CD45, mouse anti rat aquaporin 4 (AQP 4), and anti actin (Abcam, Cambridge, MA) antibodies were obtained from Abcam Inc. (Cambridge, MA). Mouse anti rat C5b 9 antibody was obtained from Cell Sciences (Canton, MA). Goat anti human TNF α antibody was purchased from Santa Cruz Biotechnology Inc. (Santa Cruz, CA). Goat anti chicken Alexa Fluor 594, goat anti mouse Alexa Fluor 488, and donkey anti goat Alexa Fluor 488 IgG (H + L) conjugated secondary antibodies and Pro Long Gold antifade reagent were from Invitrogen (Carlsbad, CA).

2.4. Histological evaluation

10% formalin fixed tissues were embedded in paraffin, sectioned at a 5 μm thickness, and stained with hematoxylin and eosin (H&E). Histological images were recorded under a light microscope (Olympus AX80, Center Valley, PA) at $\times 200$ and $\times 400$ magnifications by a pathologist blinded to the treatment groups.

2.5. Injury score of cortex gray matter

Histological slides from each animal's cerebral cortex were examined under a microscope at $\times 200$ magnification, and tissue damage

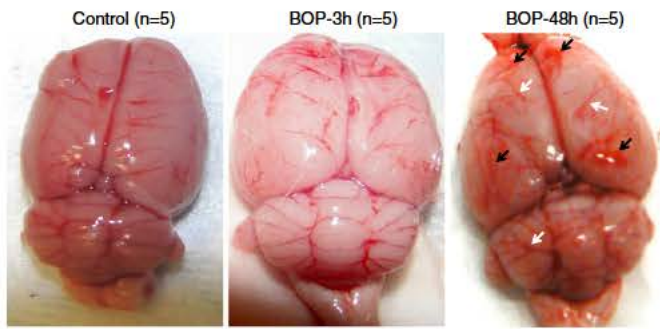


Fig. 2. Gross observation of brain tissue in rats exposed to moderate BOP. Representative rat brain tissue from rats without exposure to BOP (control), at 3 (BOP – 3 h) and 48 h (BOP – 48 h) after exposure to BOP. A swollen brain with marked flattening of the gyri and narrowing of the sulci was observed following BOP either at 3 or at 48 h. Obvious pale brain was present in rats at 3 h after exposure to BOP, indicating severe brain edema and vasospasm. Widely spread subarachnoid vessel dilation (white arrow) and hemorrhage (black arrow) were shown in the superior surface of rat brain at 48 h post blast.

was assessed by a pathologist using four distinct morphological parameters: cytotoxic edema, vasogenic edema, inflammatory cell infiltration, and hemorrhage in the brain cortex and subarachnoid space. The changes were scored according to their extent (score 0, 1, 2, 3, and 4 for an extent of 0%, <25%, 25–50%, 50–75%, and 75–100%, respectively) and the severity of the injury (score 0 = normal histology, score 1 = slight, 2 = mild, 3 = moderate, and 4 = severe alterations). The injury score represents the sum of the extent and the severity of injury.

2.6. Evaluation of hippocampus injury

A pathologist used two H&E stained histological slides from each animal to assess hippocampus damage in a blind fashion. The neuronal loss was assessed by counting neurons at hippocampus CA1, CA2, CA3 and dentate gyrus (DG) subregions at $\times 400$ magnification. The neurodegeneration was determined by counting degenerated neurons characterized by pyramidal cell degeneration with the morphologic features consisting of shrinkage of the cell body, pyknosis of the nucleus, disappearance of the nucleolus, and loss of Nissl substance, with intense eosinophilia of the cytoplasm. The degree of neuronal

loss and neurodegeneration was determined by the number of neurons or morphological alterations per field, respectively.

2.7. Immunohistochemical staining

Frozen sections were cut at a 5 μm thickness with a cryostat and fixed in cold methanol for 20 min. The fixed sections were permeabilized with 0.2% Triton X 100 in PBS for 10 min and blocked with 2% BSA in PBS for 30 min at room temperature. The following antibodies were utilized for our immunohistochemistry studies: anti C3, anti C5b 9 (cerebral complement deposition/formation), anti CD45 (leukocyte infiltration), anti TNF α (proinflammatory cytokine production), and anti AQP 4 (a biomarker for cerebral cytotoxic edema predominantly expressed in brain cells). Cerebral tissue histological sections were incubated with the primary antibodies for 1 h at room temperature, washed, and then incubated with the appropriate secondary antibodies labeled with Alexa Fluor[®] 488 and 594 (Invitrogen, Carlsbad, CA) for 1 h at room temperature. After washing, the sections were mounted with ProLong[®] Gold (Invitrogen, Carlsbad, CA) antifade solution containing 4',6'-diamidino 2 phenylindole (DAPI) and visualized under a confocal laser scanning microscope (Radiance 2100; Bio Rad, Hercules, NJ) at $\times 200$ or $\times 400$ magnification. Negative controls were conducted by substituting the primary antibodies with corresponding immunoglobulin isotypes. Captured digital images were processed by Image J software (National Institutes of Health, Bethesda, MD).

2.8. Immunofluorescent quantification

This procedure was based on a modified method as previous described [21]. Briefly, four to six images from each animal were opened using the Adobe Photoshop software and adjusted until only the fluorescent deposits and no background tissue were visible. The image was changed to black and white pixels with black representing deposits of the target proteins and white representing nonstained areas of the image using the Image J software. Using the image Adjust Threshold command, the image was then changed to red and white (fluorescent deposits were in red). Image analysis resulted in the red total area in pixels squared. Values for total area for all animals in each group were averaged to give the average area of fluorescent deposit.

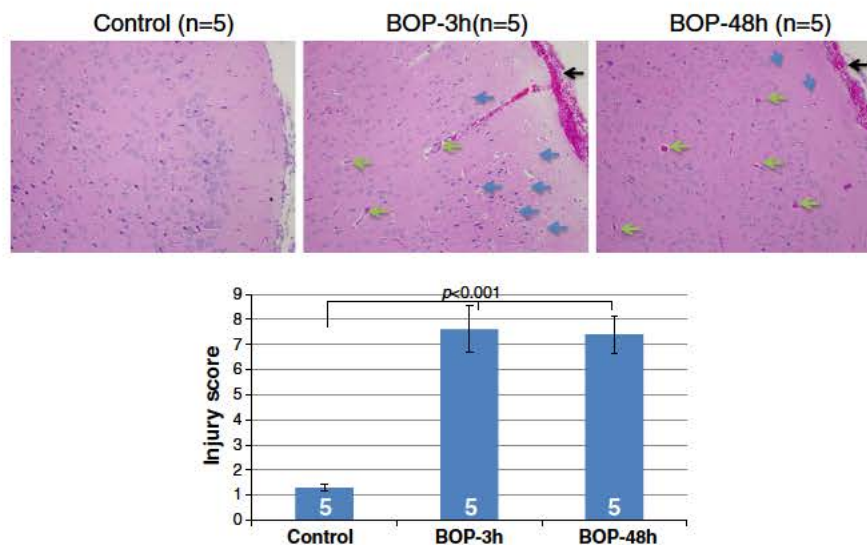


Fig. 3. Histopathological alterations of the cortex from rats subjected to moderate BOP. Representative photomicrographs of the cortex from the paraffin section stained with hematoxylin and eosin (top). The blue arrows indicate cytotoxic edema, the green arrows display vasogenic edema, and the black arrow shows subarachnoid space hemorrhage. Cortex injury scores were calculated using the scale stated in Section 2, Materials and methods, from each animal (bottom). Original magnification was $\times 200$. Group data was expressed as mean \pm SEM and compared using one-way ANOVA followed by Tukey's multiple comparison with p values of <0.05 considered significant.

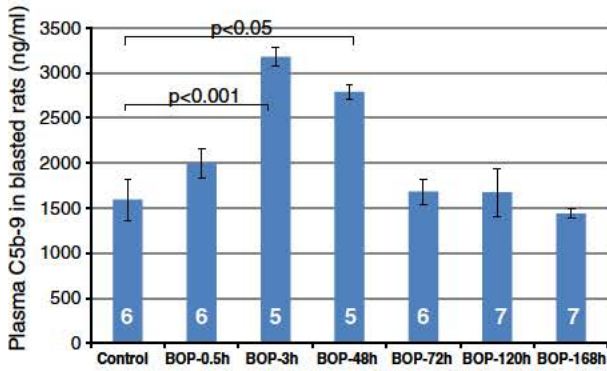


Fig. 4. Profile of plasma C5b-9 in rats with moderate BOP. Rats were exposed to moderate BOP, and plasma was collected at various time points (0.5 to 168 h) post blast. Plasma levels of C5b-9 were assessed using an ELISA kit for rat terminal complement complex C5b-9. Group data was expressed as mean ± SEM and compared using one-way ANOVA followed by Bonferroni's multiple comparison test with p values of <0.05 considered significant.

2.9. Quantification of plasma C5b 9

Plasma concentration of the soluble form of the complement system cytolitic terminal membrane attack complex, C5b 9, was measured as a marker for systemic complement activation in duplicate using a rat C5b 9 ELISA kit according to the manufacturer's instructions (Cedarlane Laboratories USA, Burlington, NC).

2.10. Western blot analysis

Frozen rat brain tissue was thawed, suspended in cold lysis buffer (20 mM Tris HCl, 1 mM EGTA, 1 mM EDTA, 1% sodium deoxycholate and protease inhibitor cocktail), minced, and sonicated on ice. The supernatants were subsequently denatured in laemmli solution by boiling. The samples were separated on a 4–12% Bis Tris gel (Invitrogen) and transferred to a nitrocellulose membrane for western blot analysis. The membranes were probed with anti TNFalpha antibody, anti C3 antibody, or anti actin antibody. Protein bands were detected by chemiluminescence reagents (Amersham Biosciences). The density of each band was measured using Image J software (National Institutes of Health, Bethesda, MD).

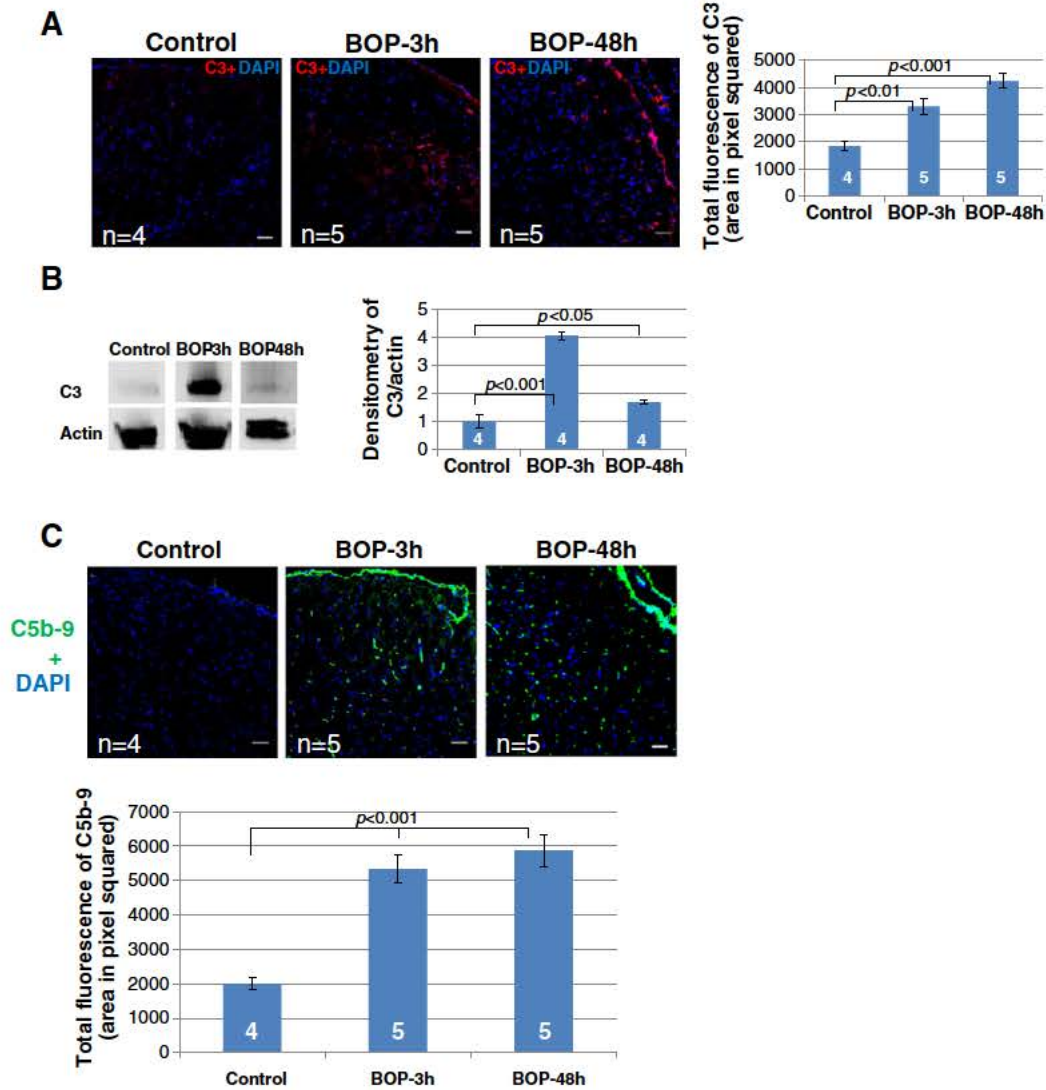


Fig. 5. Complement deposition and activation in the cortex from blast-exposed rats. Representative immunohistochemical images of C3 deposition (A), Western blot analysis (B) and immunohistochemical images of C5b-9 formation (C). The total fluorescence or density quantification of C3 deposition and C5b-9 formation is displayed at the left panel of the corresponding images. Original magnification was ×200. Scale bars in the pictures are 50 μm. Group data was expressed as mean ± SEM and compared using one-way ANOVA followed by Bonferroni's multiple comparison test with p values of <0.05 considered significant.

2.11. Statistical analysis

Data are expressed as mean \pm standard error of the mean (SEM). One way analysis of variance (ANOVA) following with Bonferroni or Tukey's post test was performed using GraphPad Prism® (4.0, GraphPad Software, San Diego, CA). P value < 0.05 was considered significant.

3. Results

3.1. Gross changes of brain in rats undergoing blast overpressure

Moderate BOP exposure resulted in brain swelling characterized by marked pale brain, flattening of gyri, and narrowing of the sulci, indicating severe brain cytotoxic edema, which was observed at 3 hour post BOP (Fig. 2).

At 48 h after BOP exposure, gross examination of animal brains displayed blood vessel dilation and congestion, widely spread subdural and/or subarachnoid hemorrhage and moderate brain edema in the superior surface (Fig. 2).

3.2. Histomorphological alterations of brain cortex in rats subjected to blast overpressure

As shown in Fig. 3, histological analysis of a rat cortex from a 3 hour BOP exposure revealed microscopic changes in the gray matter of the cortex. These changes were abundant cell swelling, nucleus shrinkage, and cytoplasmic vacuolization or spongy change, which indicated cytotoxic edema accompanied by moderate vasogenic edema with perivascular vacuolization of the brain. At 48 h after BOP, histological analysis of rat cerebral cortex slides revealed a reduction of cytotoxic and enhanced vasogenic edema. Subarachnoid space hemorrhage was observed in animals from both groups at 3 and 48 h post BOP.

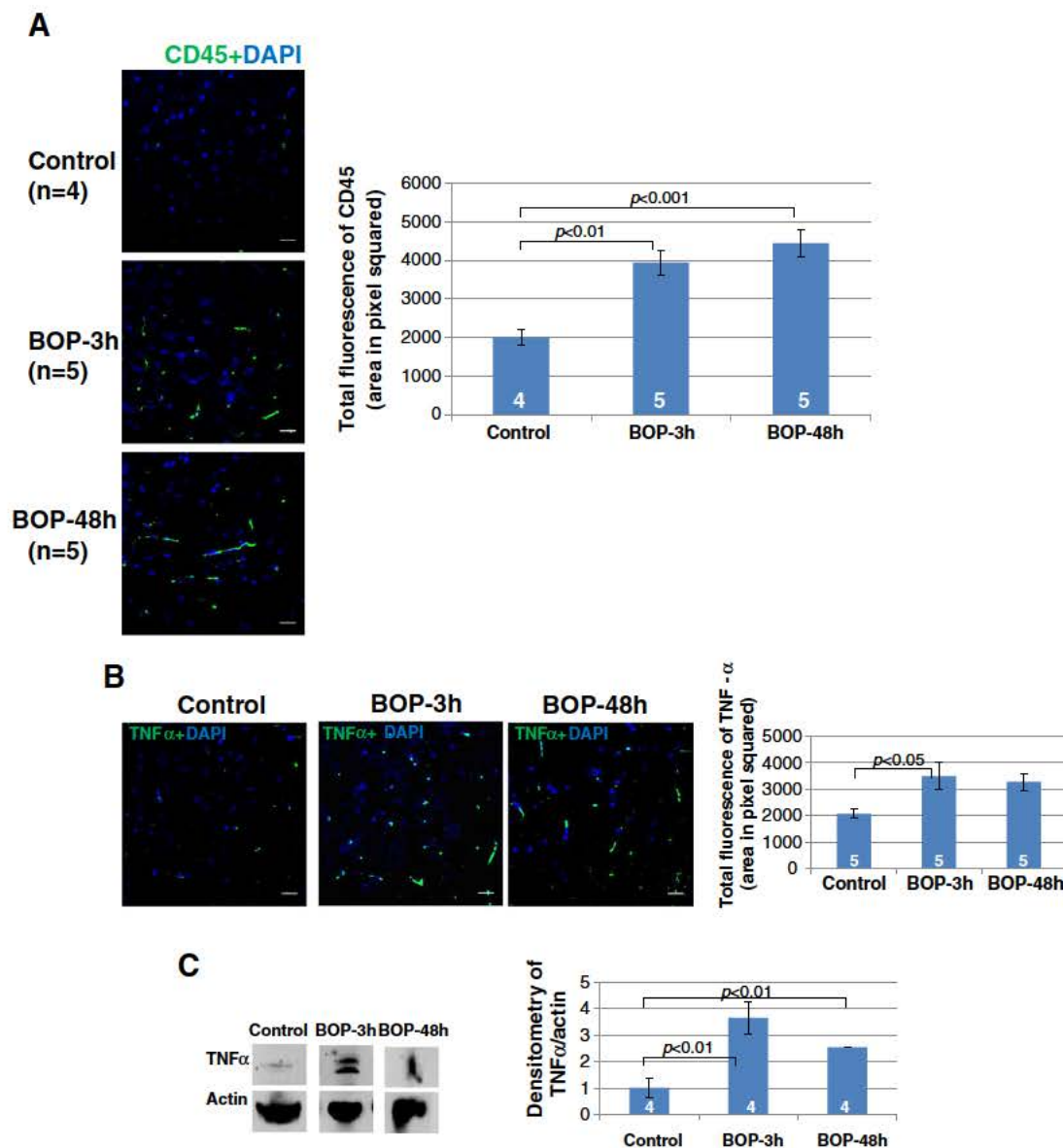


Fig. 6. Evaluation of inflammatory cells and TNF- α in the cortex from blast-exposed rats. Immunohistochemistry was performed in the cortex of rats undergoing blast. Inflammatory cells (A) and TNF- α level (B and C) of the cortex were determined by anti-rat CD45 and anti-rat TNF- α immunostaining and Western blot analysis, respectively. The total fluorescence and density quantification of the aforementioned complement deposition is displayed at the left panel of the graphs. Original magnification was $\times 400$. Scale bars in the pictures are 100 μ m. Group data was expressed as mean \pm SEM and compared using one-way ANOVA followed by Bonferroni's multiple comparison test with p values of < 0.05 considered significant.

No evident change was observed in the white matter of cortex (data not shown).

3.3. BOP triggers early systemic complement activation

Increases in plasma C5b 9 were found in rats as early as 3 h after BOP and remained elevated during the first 48 h when compared to controls. Plasma levels of C5b 9 returned to pre BOP exposure levels at 72 h after BOP exposure and remained low for the remainder of the 168 hour observation period post BOP (Fig. 4).

3.4. BOP augments complement activation and deposition in a rat's superficial cortex

Increased deposition of C3 (Fig. 5A) and C5b 9 (Fig. 5C) was detected at the superficial layers of the rat's cortex and was mostly associated with cortical vasculature at 3 and 48 h after BOP exposure. High amounts of C3 in the cortex were confirmed by Western blot analysis at 3 and 48 h after BOP exposure (Fig. 5B).

3.5. BOP stimulates infiltration of inflammatory cells and production of TNFα in a rat's brain cortex

Leukocyte infiltration in a rat's cortex was evaluated by immunohistochemistry using anti CD45 antibody. Fig. 6A shows an increased presence of CD45 positive cells in the outer layer of the rat's cortex at 3 and 48 h post BOP. Fig. 6B reveals an increase in TNFα expression and distribution in the cortex tissue from injured animals at 3 h post BOP. Western blot analysis of cortex confirmed the increase in TNFα expression (Fig. 6C).

3.6. BOP increases AQP 4 expression in a rat's cortex

Numerous brain cells expressed AQP 4 intensively in the outer layer of a rat's cortex at 3 h, but not at 48 h, post injury (Fig. 7, left panel). The quantification data displayed a significant increase of AQP 4 expression at 3 h after BOP compared to the control (Fig. 7, right panel).

3.7. BOP induces neuronal loss and neurodegeneration in rat hippocampus

Histopathologic morphology demonstrated that at 3 h and at 48 h post BOP, there were significant differences in the CA1, CA2, CA3, and DG subregions of the hippocampus when compared to the control. The subregions are characterized by neuronal loss and pyramidal cell degeneration with the morphologic features consisting of shrinkage of the cell body, pyknosis of nucleus, disappearance of the nucleolus, and loss of Nissl substance, with intense eosinophilia of the cytoplasm (Fig. 8A). The neuronal densities of the hippocampus in the animals post BOP were significantly lower than that of the control (Fig. 8B). The neurodegeneration of the hippocampus in the groups post BOP was also markedly higher than that of the control (Fig. 8C). No significant difference in the neuronal loss and neurodegeneration between the exposed groups existed.

3.8. BOP induces complement C3 deposition and C5b 9 formation in rat brain hippocampus tissue

Hippocampus deposition of C3 in animals subjected to BOP was significantly increased when compared to the control animals (Fig. 9A and B). Although it was not significant, there was a trend toward increased C3 deposition at 48 h post BOP in the DG subregion. Increased amounts of C5b 9 were detected by immunohistochemistry in hippocampus tissues from the animals exposed to BOP when compared to the control (Fig. 9C and D). C3 and C5b 9 were shown to accumulate at the neurons located in the hippocampus post injury (Fig. 9A and C). Similarly, there was no difference in C3 deposition and C5b 9 formation between the two blast exposed groups.

4. Discussion

An air driven shock tube was used in this study to simulate blast effects in rats. Animals exposed to the short duration blast wave with a mean peak overpressure of 120 kPa presented with moderate pulmonary damage, acute inflammation [20], breach of BBB integrity, increased oxidative stress, and activated microglia [9]. This model

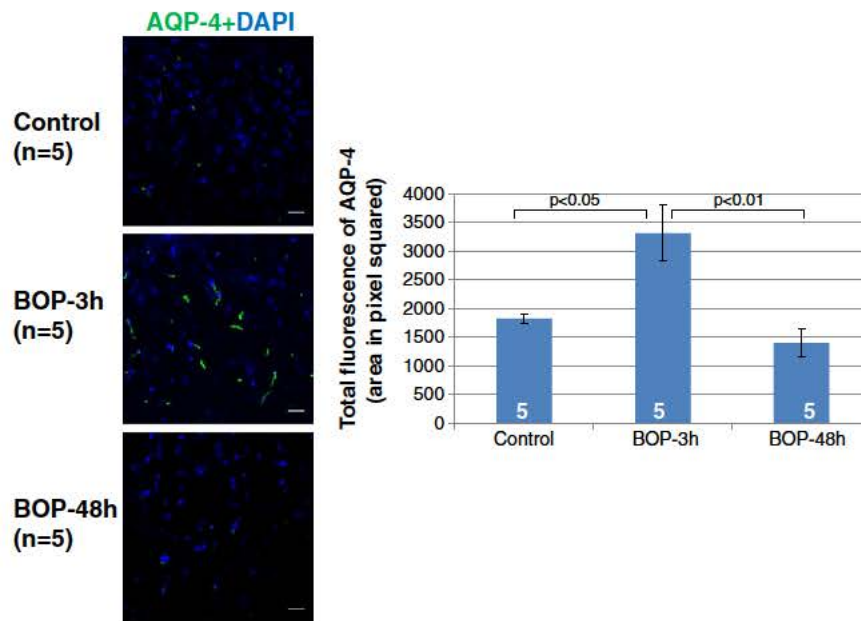


Fig. 7. Expression of Aquaporin 4 (Aqp4) in the cortex from blast-exposed rats. Expression of Aqp4 in the cortex (top) was assessed by immunohistochemistry using anti-rat Aqp4 antibody. The total fluorescence quantification of the aforementioned Aqp4 expression is displayed at the left panel of the microphotographs. Original magnification was $\times 400$. Scale bars in the pictures were 100 μm . Group data was expressed as mean \pm SEM and compared using one-way ANOVA followed by Bonferroni's multiple comparison test with p values of <0.05 considered significant.

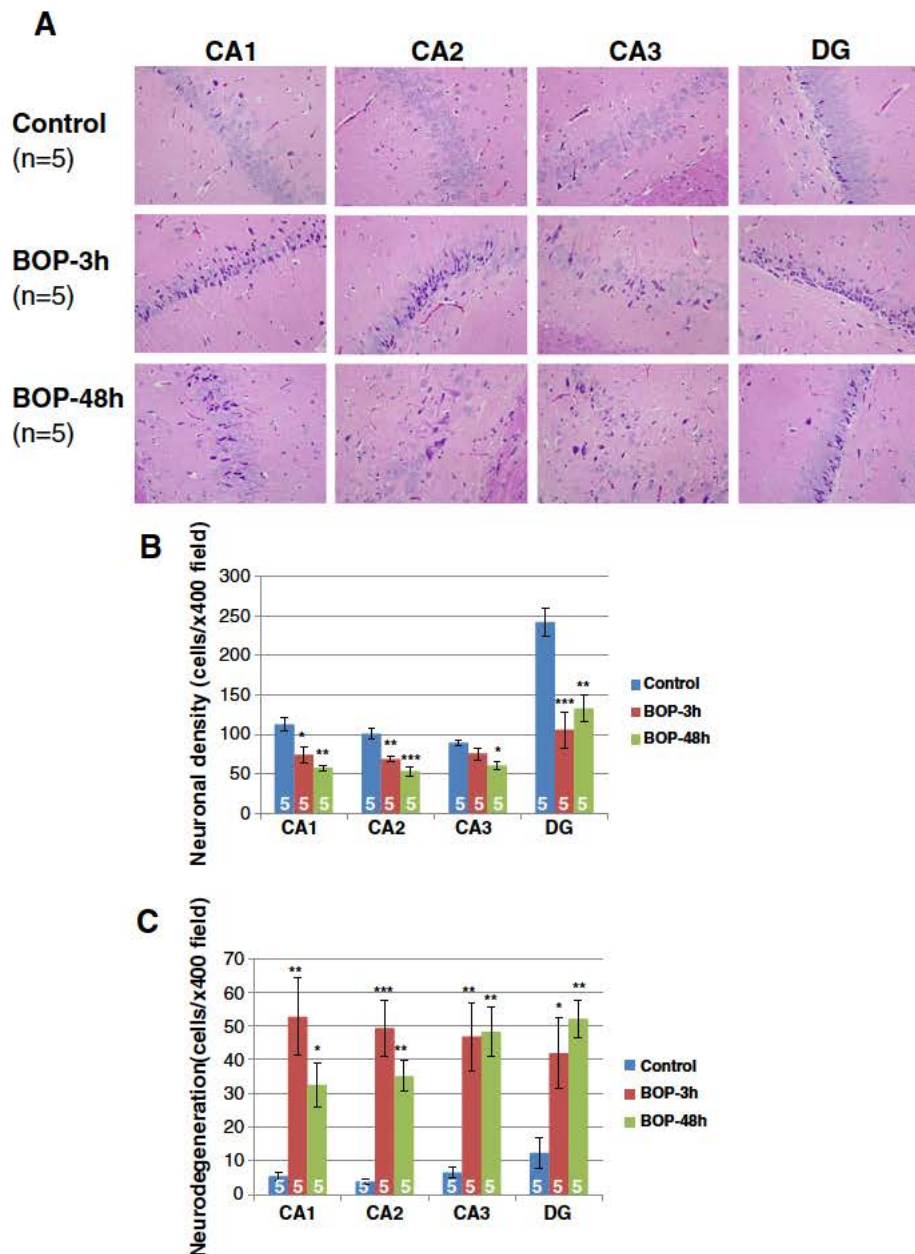


Fig. 8. Neuronal density and neurodegeneration of the hippocampus post blast. (A) Representative histological microphotographs (H&E staining) of the hippocampus. Original magnification was $\times 400$. Neuronal density (B) and neurodegeneration (C) of the hippocampus were assessed using the scales stated in Section 2, Materials and methods, for each animal. Group data was expressed as mean \pm SEM and compared using one-way ANOVA followed by Tukey's multiple comparison test with p values of <0.05 considered significant. * $p < 0.05$, ** $p < 0.01$, and *** $p < 0.001$.

resulted in survivable conditions with 90% survival rate of rats under which TBI can be studied. In the present study, we characterized the early complement system and pro inflammatory response of rats subjected to moderate BINT. Additional studies are needed to verify if these results are relevant in the pathology of mild BINT.

Our results demonstrated that moderate blast (120 kPa) triggered systemic and local complement activation as early as 3 h persisting for at least 48 h following BOP. Complement activation directly correlated with blast induced moderate neuronal damage as well as to leukocyte infiltration and TNF α production of injured rat brain tissues.

Although activation of the complement system has been documented after closed head TBI [11,22–26], the kinetics of complement activation following BINT and the contributing source of complement proteins and activation at the local environment of trauma has not been clearly defined. The present study revealed an increase of plasma

C5b 9 as early as 3 h and persisting for up to 48 h post blast. Furthermore, the study demonstrated that the higher accumulation of C3 and C5b 9 located in the outer layer of cortex was associated with the vasculature. In the hippocampus, accumulation of C3 and C5b 9 was associated with neuronal cells at 3 and 48 h post BOP. The different distribution patterns of C3 and C5b 9 between cortex and hippocampus implicate different contributing sources of complement proteins and activation at the local environment of BINT. In this blast model, BBB breakdown occurs early and is limited to the outer layer of the cortex [9], suggesting that systemic complement activation may be the source of complement proteins accumulated in the cortex by crossing a dysfunctional BBB. On the other hand, recent findings revealed that brain cells have the ability to produce complement proteins [15,27,28]. Thus, the complement protein accumulation observed in the hippocampus could have been produced locally after injury.

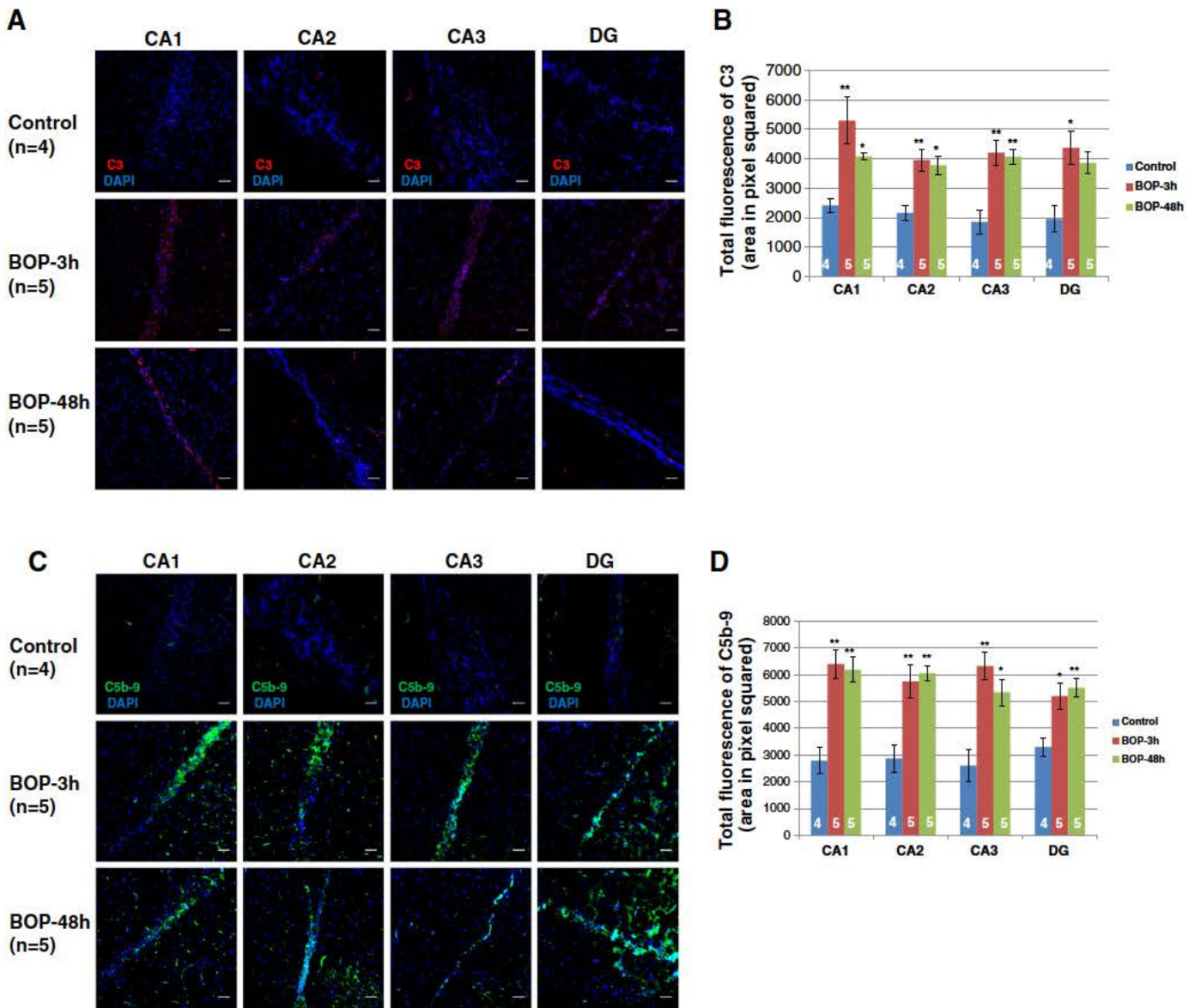


Fig. 9. Complement deposition and activation of rat hippocampus after blast. Representative immunohistochemical images of C3 deposition (A) and C5b-9 formation (C) in the brain cortex tissues. The total fluorescence quantification of C3 deposition (B) and C5b-9 formation (D) was measured as described in Section 2, Materials and methods. Original magnification was $\times 200$. Scale bars in the pictures are 50 μm . Group data was expressed as mean \pm SEM and compared using one-way ANOVA followed by Bonferroni's multiple comparison test with p values of <0.05 considered significant. * $p < 0.05$ and ** $p < 0.01$.

The increased leukocyte accumulation in an injured brain observed in blast exposed animals correlated with complement activation and accumulation in cerebral tissues. This observation is consistent with previous finding from closed head models of TBI in which complement activation is associated with leukocyte infiltration [29]. Our findings that increased accumulation of TNF α and leukocytes in injured rat brain tissues is associated with brain tissue damage agree with previously reported findings showing that an increase in plasma TNF α from blast injured trauma patients directly relates with the severity of injury [30].

Brain edema is a frequent and potentially lethal consequence of casualties suffering from BINT. Our data as well as that of others revealed that early cerebral edema is the signature event of BINT, and it is characterized by cytotoxic edema in the early phase (2–24 h) of TBI [31,32]. Aqp4, a water channel protein expressed predominantly in astrocyte foot processes (blood brain border), in the glia limitans (subarachnoid cerebrospinal fluid brain border), and ependyma (ventricular cerebrospinal fluid brain border), has been

shown to facilitate cerebral cytotoxic edema formation [33,34]. This study reports that blast exposed rats show an overexpression of Aqp4 in brain that correlates with the early cytotoxic edema, which was observed by others as well [33,34]. In addition, since complement system activation has been reported to enhance Aqp4 expression [35], the observed increase in complement activation in BINT animals may play an important role in brain cytotoxic edema induced by Aqp4.

In summary, our data demonstrates that early immune inflammatory response to moderate BINT involves complement system activation and accumulation of the pro inflammatory cytokine TNF α , both of which directly correlated with hippocampus and cerebral cortex tissue damage. Furthermore, these findings raise the possibility of a utilization of a new pharmacotherapeutic approach with early local or systemic administration of complement inhibitors and/or TNF α blockers as potential treatment of military and civilian casualties exposed to moderate blast. Finally, the present study exposes a potential role of early complement activation detection as a predictive biomarker for brain injury or as a

decision supporting tool to first responder assessment of blast exposed casualties.

Conflicts of interest

The authors have no conflicts of interest to declare.

Author disclosure statement

Disclaimer: The opinions or assertions contained herein are the private views of the author and are not to be construed as official or as reflecting the views of the Department of the Army, Department of the Navy, or the Department of Defense.

Acknowledgments

This study was funded by the Defense Medical Research and Development Program (DMRDP) and US Army Medical Research and Materiel Command Combat Casualty Care Research Program and the Office of Naval Research.

The authors would like to thank Shawn L. Dalle Lucca for editorial assistance.

References

- Defense Manpower Data Center [internet]. 2008[cited August 16, 2009]. Global War on Terrorism: casualties by reason. Available from: http://siadapp.dmdc.osd.mil/personel/CASUALTY/gwot_reason.pdf.
- Tenuta JJ. From the battlefields to the States: the road to recovery. The role of Landstuhl Regional Medical Center in US military casualty care. *J Am Acad Orthop Surg* 2006;14:S45–7.
- Cernak I, Noble-Haesslein IJ. Traumatic brain injury: an overview of pathobiology with emphasis on military populations. *J Cereb Blood Flow Metab* 2010;30:255–66.
- Dewitt DS, Prough DS. Blast-induced brain injury and posttraumatic hypotension and hypoxemia. *J Neurotrauma* 2009;26:877–87.
- Mellor SG. The pathogenesis of blast injury and its management. *Br J Hosp Med* 1998;39:536–9.
- Long JB, Bentley TL, Wessner KA, Cerone C, Sweeney S, Bauman RA. Blast overpressure in rats: recreating a battlefield injury in the laboratory. *J Neurotrauma* 2009;26:827–40.
- Cernak I, Wang Z, Jiang J, Bian X, Savic J. Cognitive deficits following blast injury-induced neurotrauma: possible involvement of nitric oxide. *Brain Inj* 2001;15:593–612.
- Cernak I, Wang Z, Jiang J, Bian X, Savic J. Ultrastructural and functional characteristics of blast injury-induced neurotrauma. *J Trauma* 2001;50:695–706.
- Readnower RD, Chavko M, Adeeb S, Conroy MD, Pauly JR, McCarron RM, et al. Increase in blood–brain barrier permeability, oxidative stress, and activated microglia in a rat model of blast-induced traumatic brain injury. *J Neurosci Res* 2010;88:3530–9.
- Kossmann T, Stahel PF, Morganti-Kossmann MC, Jones JL, Barnum SR. Elevated levels of the complement components C3 and factor B in ventricular cerebrospinal fluid of patients with traumatic brain injury. *J Neuroimmunol* 1997;73:63–9.
- Stahel PF, Morganti-Kossmann C, Perez D, Redaelli C, Gloor B, Trentz O, et al. Intrathecal levels of complement-derived soluble membrane attack complex (sC5b-9) correlate with blood–brain barrier dysfunction in patients with traumatic brain injury. *J Neurotrauma* 2001;18:773–81.
- Stahel PF, Flierl MA, Morgan BP, Persigehl I, Stoll C, Conrad C, et al. Absence of the complement regulatory molecule CD59a leads to exacerbated neuropathology after traumatic brain injury in mice. *J Neuroinflamm* 2009;6:2.
- Bellander BM, Olafsson IH, Ghatan PH, Bro Skejjo HP, Hansson LO, Wanecek M. Secondary insults following traumatic brain injury enhance complement activation in the human brain and release of the tissue damage marker S100B. *Acta Neurochir (Wien)* 2011;153:90–100.
- Schmidt OI, Infanger M, Heyde CE, Ertel W, Stahel PF. The role of neuroinflammation in traumatic brain injury. *Eur J Trauma* 2004;30:135–49.
- Wang Y, Li Y, Dalle Lucca SL, Simovic M, Tsokos GC, Dalle Lucca JJ. Decay accelerating factor (CD55) protects neuronal cells from chemical hypoxia-induced injury. *J Neuroinflamm* 2010;7:24.
- Carroll MC. The complement system in regulation of adaptive immunity. *Nature Immunol Rev* 2004;5:981–6.
- Dunkelberger JR, Song WC. Complement and its role in innate and adaptive immune response. *Cell Res* 2010;20:34–50.
- Ricklin D, Lambris JD. Complement-targeted therapeutics. *Nat Biotechnol* 2007;25:1265–75.
- Morganti-Kossmann MC, Lenzlinger PM, Hans V, Stahel P, Csuka E, Ammann E, et al. Production of cytokines following brain injury: beneficial and deleterious for the damaged tissue. *Mol Psychiatry* 1997;2:133–6.
- Chavko M, Prusaczyk WK, McCarron RM. Lung injury and recovery after exposure to blast overpressure. *J Trauma* 2006;61:933–42.
- Weeks C, Moratz C, Zacharia A, Stracener C, Egan R, Peckham R, et al. Decay-accelerating factor attenuates remote ischemia–reperfusion-initiated organ damage. *Clin Immunol* 2007;124:311–27.
- Anderson AJ, Robert S, Huang W, Young W, Cotman CW. Activation of complement pathways after contusion-induced spinal cord injury. *J Neurotrauma* 2004;21:1831–46.
- Bellander BM, von Holst H, Fredman P, Svensson M. Activation of the complement cascade and increase of clusterin in the brain following a cortical contusion in the adult rat. *J Neurosurg* 1996;85:468–75.
- Bellander BM, Singhrao SK, Ohlsson M, Mattsson P, Svensson M. Complement activation in the human brain after traumatic head injury. *J Neurotrauma* 2001;18:1295–311.
- Bellander BM, Bendel O, Von Euler G, Ohlsson M, Svensson M. Activation of microglial cells and complement following traumatic injury in rat entorhinal–hippocampal slice cultures. *J Neurotrauma* 2004;21:605–15.
- Wood A, Wing MG, Benham CD, Compston DA. Specific induction of intracellular calcium oscillations by complement membrane attack on oligodendroglia. *J Neurosci* 1993;13:3319–32.
- Arumugam TV, Woodruff TM, Lathia JD, Selvaraj PK, Mattson MP, Taylor SM. Neuroprotection in stroke by complement inhibition and immunoglobulin therapy. *Neurosci* 2009;158:1074–89.
- Ingersoll SA, Martin CB, Barnum SR, Martin BK. CNS-specific expression of C3a and C5a exacerbate demyelination severity in the cuprizone model. *Mol Immunol* 2010;48:219–30.
- Keeling KL, Hicks RR, Mahesh J, Billings BB, Kotwal GJ. Local neutrophil influx following lateral fluid-percussion brain injury in rats is associated with accumulation of complement activation fragments of the third component (C3) of the complement system. *J Neuroimmunol* 2000;105:20–30.
- Surbatovic M, Filipovic N, Radakovic S, Stankovic N, Slavkovic Z. Immune cytokine response in combat casualties: blast or explosive trauma with or without secondary sepsis. *Mil Med* 2007;172:190–5.
- Barzó P, Marmarou A, Fatouros P, Hayasaki K, Corwin F. Contribution of vasogenic and cellular edema to traumatic brain swelling measured by diffusion-weighted imaging. *J Neurosurg* 1997;87:900–7.
- Unterberg AW, Stover J, Kress B, Kiening KL. Edema and brain trauma. *Neuroscience* 2004;129:1021–9.
- Liang D, Bhatta S, Gerzanich V, Simard JM. Cytotoxic edema: mechanisms of pathological cell swelling. *Neurosurg Focus* 2007;22:E2.
- Saadoun S, Papadopoulos MC. Aquaporin-4 in brain and spinal cord oedema. *Neuroscience* 2010;168:1036–46.
- Alexander JJ, Bao L, Jacob A, Kraus DM, Holers VM, Quigg RJ. Administration of the soluble complement inhibitor, Crry-Ig, reduces inflammation and aquaporin 4 expression in lupus cerebritis. *Biochim Biophys Acta* 2003;1639:169–76.