

Extracorporeal Membrane Oxygenation in a Patient With Refractory Acute Respiratory Distress Syndrome Secondary to Toxic Epidermal Necrolysis

Christy R. Sine, MD,* Kevin K. Chung, MD,†‡ Jeremy C. Pamplin, MD,*‡
Andriy I. Batchinsky, MD,† James E. Hull, MD,* Booker T. King, MD,†
Stephen Derdak, DO,* Josh Walker, CPP,* Jeffrey D. McNeil, MD,*
Evan M. Renz, MD,†‡ Jeremy W. Cannon, MD*‡

Toxic epidermal necrolysis (TEN) is a rare condition affecting an estimated 1 to 2 cases per million per year, with reported mortality between 30% and 50% typically because of multiorgan failure or sepsis.¹ Acute pulmonary complications from this disorder include bronchial mucosal sloughing, pulmonary edema, and infectious pneumonitis. Pulmonary complications in TEN occurred in 46% of patients in one series.²

Use of extracorporeal life support (ECLS) in adults with acute respiratory distress syndrome (ARDS) has increased markedly during the past few years after successful treatment in adults with swine flu (H1N1)³ and publication of the CESAR (conventional ventilation or ECMO for severe adult respiratory failure) trial,⁴ which demonstrated a lower mortality and disability at 6 months for patients referred to an ECLS center. The suggested ideal candidate for ECLS would be one with an acute, reversible, survivable illness if not for associated ARDS, no significant comorbidities, no contraindication to systemic anticoagulation, less than 8 days on mechanical ventilation, and younger than 65 years of age.⁴

CASE REPORT

A 37-year-old woman presented to a local emergency department with eye irritation and itching as well as

a macular rash starting on the medial aspect of her right foot. The day before, she had complained of a sore throat, some difficulty in breathing, and chest pain. Two weeks earlier, she had started lamotrigine for depression. On her initial evaluation in the emergency department, she was thought to have an upper respiratory infection and was given azithromycin. She was discharged home but returned the following morning when her pruritic rash progressed and blurry vision developed.

She was admitted to the local intensive care unit and subsequently transferred to our burn center for further management. On arrival, she was alert and oriented but slightly anxious. Her vital signs were only remarkable for tachycardia of 120 bpm and pulse oximetry of 95% on 2-L nasal cannula. Her physical examination revealed a diffuse macular rash. On wound mapping, her macular rash involved 90% of her body, including ocular and oral areas. Desquamation on presentation was approximately 46%.

During the first 24 hours of admission, her respiratory status progressively declined, and she required intubation for airway protection and ventilator support. On bronchoscopy, her airway mucosa was seen to be detached from the underlying structures (Figure 1). Despite escalating ventilator support for 7 days with airway pressure release ventilation, high levels of fraction of inspired oxygen (FiO₂), and, later out of clinical necessity, heavy sedation and paralytics, her saturations remained low (70–80%), with mean airway pressures in the mid-30s and a rising lactate. Prone positioning was considered but not offered because of the low likelihood of success, given her underlying lung pathology. Decision was made to initiate venovenous (VV) ECLS as a rescue therapy (Figure 2). A dual-lumen 27-Fr internal jugular cannula (Avalon® Elite; Maquet, Wayne, NJ) was placed percutaneously in the intensive care unit

*From the *San Antonio Military Medical Center, Fort Sam Houston, Texas; †United States Army Institute of Surgical Research, Fort Sam Houston, Texas; and ‡Uniformed Health Services, University of the Health Sciences, Bethesda, Maryland.*

The opinions or assertions contained herein are the private views of the authors and are not to be construed as official or as reflecting the views of the Department of the Air Force, Department of the Army, or the Department of Defense.

Address correspondence to Kevin K. Chung, MD, 3698 Chambers Pass, Fort Sam Houston, Texas 78234.

*Copyright © 2014 by the American Burn Association
1559-047X/2014*

DOI: 10.1097/BCR.000000000000008

Report Documentation Page

Form Approved
OMB No. 0704-0188

Public reporting burden for the collection of information is estimated to average 1 hour per response, including the time for reviewing instructions, searching existing data sources, gathering and maintaining the data needed, and completing and reviewing the collection of information. Send comments regarding this burden estimate or any other aspect of this collection of information, including suggestions for reducing this burden, to Washington Headquarters Services, Directorate for Information Operations and Reports, 1215 Jefferson Davis Highway, Suite 1204, Arlington VA 22202-4302. Respondents should be aware that notwithstanding any other provision of law, no person shall be subject to a penalty for failing to comply with a collection of information if it does not display a currently valid OMB control number.

1. REPORT DATE 01 DEC 2014		2. REPORT TYPE N/A		3. DATES COVERED -	
4. TITLE AND SUBTITLE Extracorporeal Membrane Oxygenation in a Patient With Refractory Acute Respiratory Distress Syndrome Secondary to Toxic Epidermal Necrolysis.				5a. CONTRACT NUMBER	
				5b. GRANT NUMBER	
				5c. PROGRAM ELEMENT NUMBER	
6. AUTHOR(S) Sine C. R., Chung K. K., Pamplin J. C., Batchinsky A. I., Hull J. E., King B. T., Derdak S., Walker J., McNeil J. D., Renz E. M., Cannon J. W.,				5d. PROJECT NUMBER	
				5e. TASK NUMBER	
				5f. WORK UNIT NUMBER	
7. PERFORMING ORGANIZATION NAME(S) AND ADDRESS(ES) United States Army Institute of Surgical Research, JBSA Fort Sam Houston, TX				8. PERFORMING ORGANIZATION REPORT NUMBER	
9. SPONSORING/MONITORING AGENCY NAME(S) AND ADDRESS(ES)				10. SPONSOR/MONITOR'S ACRONYM(S)	
				11. SPONSOR/MONITOR'S REPORT NUMBER(S)	
12. DISTRIBUTION/AVAILABILITY STATEMENT Approved for public release, distribution unlimited					
13. SUPPLEMENTARY NOTES					
14. ABSTRACT					
15. SUBJECT TERMS					
16. SECURITY CLASSIFICATION OF:			17. LIMITATION OF ABSTRACT UU	18. NUMBER OF PAGES 3	19a. NAME OF RESPONSIBLE PERSON
a. REPORT unclassified	b. ABSTRACT unclassified	c. THIS PAGE unclassified			

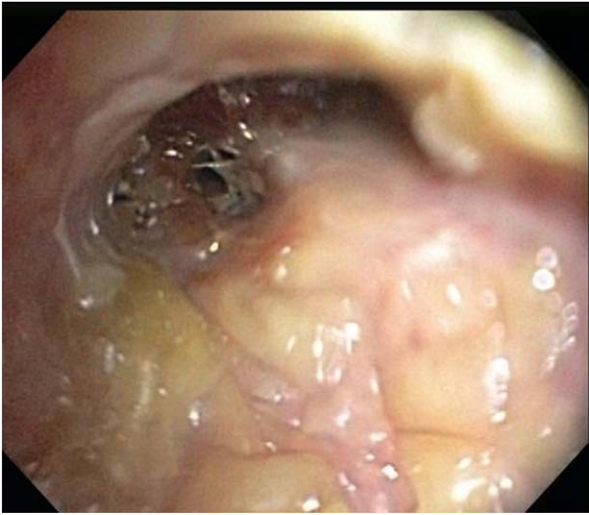


Figure 1. Bronchoscopy hospital day 6 demonstrating sloughing of tracheobronchial mucosa.

under ultrasound and fluoroscopic guidance. The patient was maintained on VV ECLS with intermittent bronchoscopy for clearance of mucous plugs and cellular debris. During this time, 46% of her TBSA desquamated and then healed with wound care, which consisted primarily of silver nitrate dressings that require fewer dressing changes than other therapies. Lung-protective ventilator settings were implemented during her 23-day ECLS run. For the first 5 days on ECLS, the patient remained paralyzed on pressure-assist control mode, with driving pressures anywhere from 20 to 25 cm H₂O to target

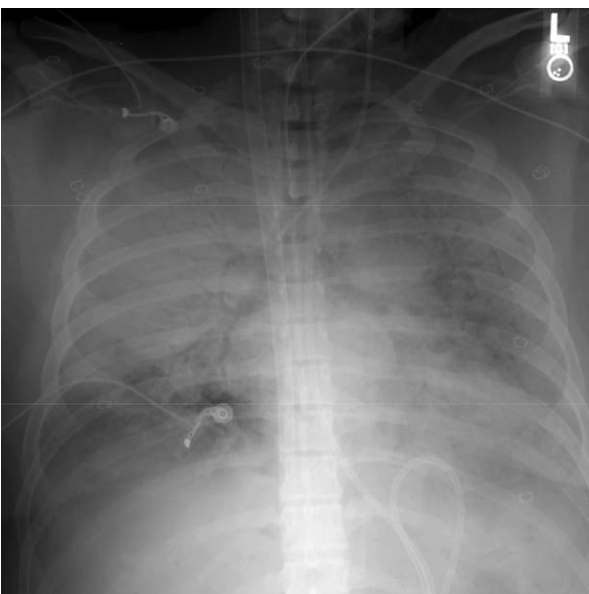


Figure 2. Chest radiograph on the day of extracorporeal life support initiation.

tidal volumes less than 6 ml/kg. We then weaned the paralytic off and placed her on pressure support ventilation at the same driving pressures and over time and weaned the pressure down to 10 cm H₂O. Positive end-expiratory pressure was also weaned to 10 cm H₂O from a high of 15 cm H₂O. FiO₂ was adjusted up and down throughout the ECLS run as needed while maintaining a partial pressure of oxygen greater than 45 mm Hg with oxygen saturation greater than 84%. These settings met our target goals of mean airway pressure of ≤ 20 cm H₂O and tidal volumes of 4 to 6 ml/kg. Her VV ECLS circuit settings at initiation were a blood flow of 3.2 L per minute, FiO₂ of 100%, and sweep gas flow of 10 L per minute. The first couple of days on VV ECLS, there was consideration of adding an additional venous drainage cannula because negative pressures from venous drainage cannula limited blood flow capabilities of circuit to no higher than 4 L per minute; however, she showed improvement and therefore did not receive another cannula. This blood flow limitation did result in higher ventilator FiO₂ requirement and potentially more blood transfusion requirements because we targeted a hemoglobin goal of 10 g/dL in an effort to optimize oxygen delivery. She did not have any significant bleeding or infections during her ECLS course; however, she did have a persistent cough not responsive to opioids or sedatives. The cough was eventually controlled with 2% lidocaine instilled through her tracheostomy every 4 hours as needed. On ECLS day 21, her lung compliance began to improve, and on ECLS day 23 she underwent a trial “off” ECLS with the oxygen and sweep gas disconnected from the ECLS circuit. She tolerated this trial well and was able to be safely decannulated to minimal-pressure ventilator support. She was subsequently removed from mechanical ventilation 8 days after decannulation, and her tracheostomy was removed another 8 days later. She was discharged to a rehabilitation facility on hospital day 49, and she has since transitioned home, where she is ambulatory and functionally independent (Figure 3). At her 6-month follow-up evaluation, the results of her full pulmonary function tests were normal and she walked 1000 feet in 6 minutes without the need for supplemental oxygen.

DISCUSSION

This case illustrates the use of ECLS in TEN, a rare condition occasionally associated with pulmonary complications.⁵⁻⁹ The only previous reported case is in a pediatric ECLS case series.¹⁰ The Extracorporeal Life Support Organization registry¹¹ also has one

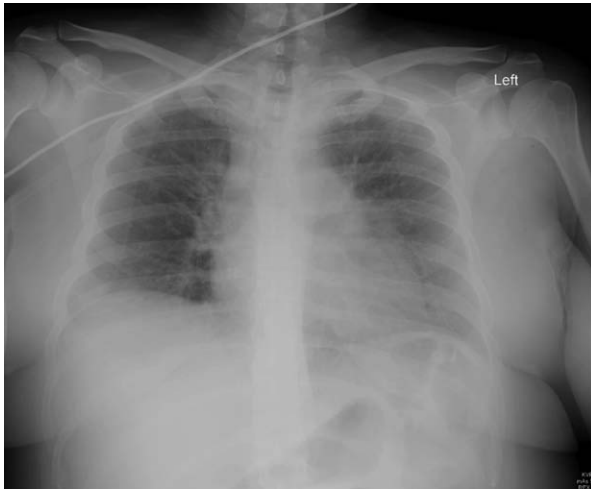


Figure 3. Chest radiograph on the day of discharge.

adult patient with TEN who survived, but to our knowledge this case has not been reported. The high mortality associated with TEN is typically the result of infectious complications; however, if sepsis does not develop, patients can recover fully. The most commonly reported long-term respiratory complication is severe bronchiolitis obliterans, which has required lung transplantation in some instances.⁶⁻⁹ Because full recovery is typical in TEN, this is an ideal condition for the use of ECLS when severe pulmonary dysfunction develops as demonstrated by this case.¹

CONCLUSION

To our knowledge, this case is the first reported use of ECLS in an adult patient with ARDS secondary to TEN. ECLS is feasible in the setting of refractory

pulmonary failure in TEN and thus should be considered as a rescue therapy.

REFERENCES

1. Borchers AT, Lee JL, Naguwa SM, Cheema GS, Gershwin ME. Stevens-Johnson syndrome and toxic epidermal necrolysis. *Autoimmun Rev* 2008;7:598-605.
2. Lebargy F, Wolkstein P, Gisselbrecht M, et al. Pulmonary complications in toxic epidermal necrolysis: a prospective clinical study. *Intensive Care Med* 1997;23:1237-44.
3. Brodie D, Bacchetta M. Extracorporeal membrane oxygenation for ARDS in adults. *N Engl J Med* 2011;365:1905-14.
4. Peek GJ, Mugford M, Tiruvoipati R, et al.; CESAR trial collaboration. Efficacy and economic assessment of conventional ventilatory support versus extracorporeal membrane oxygenation for severe adult respiratory failure (CESAR): a multicentre randomised controlled trial. *Lancet* 2009;374:1351-63.
5. Rzany B, Correia O, Kelly JP, Naldi L, Auquier A, Stern R. Risk of Stevens-Johnson syndrome and toxic epidermal necrolysis during first weeks of antiepileptic therapy: a case-control study. Study Group of the International Case Control Study on Severe Cutaneous Adverse Reactions. *Lancet* 1999;353:2190-4.
6. Chou P, Blei ED, Shen-Schwarz S, Gonzalez-Crussi F, Reynolds M. Pulmonary changes following extracorporeal membrane oxygenation: autopsy study of 23 cases. *Hum Pathol* 1993;24:405-12.
7. Timsit JF, Mion G, Rouyer N, Le Gulluche Y, Carsin H. Bronchopulmonary distress associated with toxic epidermal necrolysis. *Intensive Care Med* 1992;18:42-4.
8. Chan HL, Stern RS, Arndt KA, et al. The incidence of erythema multiforme, Stevens-Johnson syndrome, and toxic epidermal necrolysis. A population-based study with particular reference to reactions caused by drugs among outpatients. *Arch Dermatol* 1990;126:43-7.
9. Kamada N, Kinoshita K, Togawa Y, et al. Chronic pulmonary complications associated with toxic epidermal necrolysis: report of a severe case with anti-Ro/SS-A and a review of the published work. *J Dermatol* 2006;33:616-22.
10. Ryan DP, Doody DP. Treatment of acute pulmonary failure with extracorporeal support: 100% survival in a pediatric population. *J Pediatr Surg* 1992;27:1111-6; discussion 1116-7.
11. Extracorporeal Life Support Organization. ECMO registry of extracorporeal life support organization. <http://www.elsonet.org/>.