

Experience with Proctectomy to Manage Combat Casualties Sustaining Catastrophic Perineal Blast Injury Complicated by Invasive *Mucor* Soft-Tissue Infections

MAJ Jonathan B. Lundy, MC USA; MAJ Ian R. Driscoll, MC USA

ABSTRACT Catastrophic pelviperineal injuries have become more commonplace on the modern battlefield as a result of dismounted blast mechanism and the survival benefits afforded by far forward resuscitation and surgery. Inherent in the survival of casualties with such devastating injuries is both the risk for invasive infections and the need for complex reconstruction. We report a series of two combat casualties sustaining the constellation of catastrophic pelviperineal blast injury, anal sphincter complex destruction, complicated by invasive fungal infection managed with completion proctectomy. Our experience, although lacking numbers to qualify as high level evidence to guide care, will assist future surgeons' care for similar patients.

INTRODUCTION

As a result of dismounted blast-injured combat casualties receiving far-forward resuscitation, damage control surgery, and rapid evacuation in recent overseas contingency operations (OCO), surgeons at role IV and V facilities are caring for survivors with increasingly complex open pelviperineal soft-tissue injuries.¹ The pattern of injury frequently encountered can include bilateral lower extremity traumatic amputations, open pelvic fracture, external genitourinary injuries, and perianal/perirectal injuries. Some of the most catastrophic patients cared for at the U.S. Army Institute of Surgical Research (USAISR) Burn Center have been found to have complete disruption of the perineal body and anal sphincter complex and have also developed histopathologic evidence of invasive *Mucor* species infection.

The purpose of this report is to describe two catastrophically injured combat casualties with pelviperineal blast injuries with loss of anal sphincter complex treated initially with damage control techniques including fecal diversion who went on to develop invasive mold infections in pelvic soft tissues with continued contamination of perineal wounds because of fecal/mucous soilage managed with completion proctectomy. To the best of our knowledge, this report is the first of its kind to describe this surgical technique in conjunction with a markedly complex injury/infection pattern.

METHODS

The USAISR Burn Center is the Department of Defense's only burn center. During current OCO, we have cared for over 1,000 combat casualties sustaining severe thermal injury and blast injuries with complex soft-tissue wounds, invasive

bacterial and fungal infections, and abdominal injuries. These patients are similar to massively burned patients and necrotizing soft-tissue infection patients in that they receive great benefit from the multidisciplinary care provided in our burn center, specifically the expertise available for complex wound care, surgical intervention, nutrition support, rehabilitation, and reconstruction. We conducted a retrospective chart review of combat casualties admitted to the USAISR Burn Center with complex blast-related soft-tissue wounds with loss of anal sphincter complex managed with completion proctectomy during the current OCO. Standard demographics, hospital course, and outcomes were collected to provide observational data to report for the purpose of this series.

RESULTS

Since the recent spike in dismounted improvised explosive device blast injuries during OCO, 23 combat casualties with blast injury (exclusive of thermal injury) as their primary diagnosis have been transferred to our burn center. Of these, two were managed with completion proctectomy for loss of anal sphincter complex, invasive *Mucor* species pelvic soft-tissue infection, and continued soilage of perineal wounds.

Combat Casualty 1

A 25-year-old Hispanic man sustained blast injury during dismounted patrol. Initial injuries included traumatic cardiac arrest, bilateral above-knee traumatic amputations, open pelvic fracture with right hemipelvis dissociation, retroperitoneal hematoma, traumatic left orchiectomy, penile urethral transection, disruption of right groin and perirectal soft tissues, and destruction of the anal sphincter complex. Initial surgical management included resuscitative thoracotomy, pelvic external fixation, laparotomy for proximal vascular control and fecal diversion, and debridement of traumatic lower extremity soft-tissue wounds. The patient arrived at Brooke Army Medical Center approximately 6 days after

U.S. Army Institute of Surgical Research, 3698 Chambers Pass, Fort Sam Houston, TX 78234.

The opinions or assertions contained herein are the private views of the author and are not to be construed as official or as reflecting the views of the Department of the Army or the Department of Defense.

doi: 10.7205/MILMED D 13 00493

Report Documentation Page

Form Approved
OMB No. 0704-0188

Public reporting burden for the collection of information is estimated to average 1 hour per response, including the time for reviewing instructions, searching existing data sources, gathering and maintaining the data needed, and completing and reviewing the collection of information. Send comments regarding this burden estimate or any other aspect of this collection of information, including suggestions for reducing this burden, to Washington Headquarters Services, Directorate for Information Operations and Reports, 1215 Jefferson Davis Highway, Suite 1204, Arlington VA 22202-4302. Respondents should be aware that notwithstanding any other provision of law, no person shall be subject to a penalty for failing to comply with a collection of information if it does not display a currently valid OMB control number.

1. REPORT DATE 01 MAR 2014	2. REPORT TYPE N/A	3. DATES COVERED -			
4. TITLE AND SUBTITLE Experience with Proctectomy to Manage Combat Casualties Sustaining Catastrophic Perineal Blast Injury Complicated by Invasive Mucor Soft-Tissue Infections		5a. CONTRACT NUMBER			
		5b. GRANT NUMBER			
		5c. PROGRAM ELEMENT NUMBER			
6. AUTHOR(S) Lundy J. B., Driscoll R. I.,		5d. PROJECT NUMBER			
		5e. TASK NUMBER			
		5f. WORK UNIT NUMBER			
7. PERFORMING ORGANIZATION NAME(S) AND ADDRESS(ES) United States Army Institute of Surgical Research, JBSA Fort Sam Houston, TX		8. PERFORMING ORGANIZATION REPORT NUMBER			
9. SPONSORING/MONITORING AGENCY NAME(S) AND ADDRESS(ES)		10. SPONSOR/MONITOR'S ACRONYM(S)			
		11. SPONSOR/MONITOR'S REPORT NUMBER(S)			
12. DISTRIBUTION/AVAILABILITY STATEMENT Approved for public release, distribution unlimited					
13. SUPPLEMENTARY NOTES					
14. ABSTRACT					
15. SUBJECT TERMS					
16. SECURITY CLASSIFICATION OF:			17. LIMITATION OF ABSTRACT UU	18. NUMBER OF PAGES 4	19a. NAME OF RESPONSIBLE PERSON
a. REPORT unclassified	b. ABSTRACT unclassified	c. THIS PAGE unclassified			

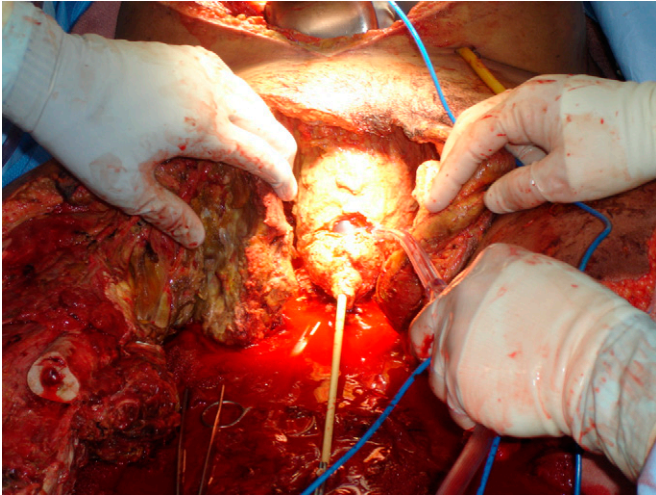


FIGURE 1. View of perineal wounds including complete disruption of external genitalia, bilateral above knee residual limbs with degloving because of blast and necrosis/IFI necessitating debridement. Foley catheter is seen entering bladder neck after penectomy/prostatectomy.

injury and was transferred to the USAISR Burn Center on postinjury day 8 for management of extensive soft-tissue injuries and open abdomen. Invasive mucormycosis of the right hemipelvis, residual left lower extremity, and perirectal soft tissues were identified from intraoperative biopsies (Figs. 1 and 2). A transabdominal completion proctectomy was performed to allow debridement of perirectal and presacral tissues. Right hemipelvectomy was performed in the same operative setting to remove the exposed pelvic ring and mucor-involved pelvic girdle musculature. The resulting pelvic soft-tissue defect was covered with ipsilateral vastus lateralis and temporary dressings of mafenide acetate/amphotericin B solution.² The patient required a massive

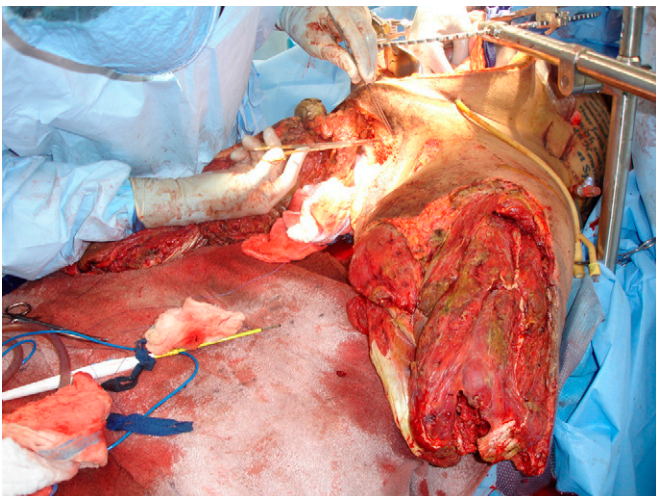


FIGURE 2. Residual lower limbs and perineal soft tissue after right hemipelvectomy, proctectomy, and debridement of left above knee residual limb. Areas of necrosis and histopathologically confirmed invasive *Mucor* species are evident on left anterior thigh.

transfusion to replace blood losses during the combined procedures. Eventual definitive wound closure was achieved with negative pressure wound therapy and split thickness skin grafts without further evidence of infection. The patient's recovery was complicated by wound dehiscence, pressure-related sacral soft-tissue injury, and respiratory failure. He sustained a respiratory arrest on postinjury day 71 requiring cardiopulmonary resuscitation. Although spontaneous circulation returned, the patient sustained anoxic brain injury and remains in a persistent nonarousable state.

Combat Casualty 2

A 30-year-old Caucasian man sustained blast injury during dismounted patrol. Initial injuries included bilateral above-knee traumatic amputations, open pelvic fracture with left sacroiliac joint dissociation, traumatic right orchiectomy, penile burns with membranous urethral injury, destruction of the anal sphincter complex and perineal body, degloving of the anus and extraperitoneal rectum, L5 transverse process fracture, penetrating cecal injury, and bilateral tympanic membrane rupture. Resuscitative surgery included pelvic external fixation, debridement of grossly contaminated bilateral lower extremity traumatic amputations, and damage control laparotomy for cecal repair, ileostomy creation, and fecal diversion. The patient arrived at Brooke Army Medical Center on postinjury day 9 and underwent successive soft-tissue debridements of bilateral residual lower limbs closure of his open abdomen. He was transferred to the USAISR Burn Center approximately 26 days after injury while demonstrating severe sepsis and acute renal failure requiring continuous renal replacement therapy. On operative exploration of his soft-tissue wounds, extensive necrosis of the left pelvic musculature was noted along with soiling of the perineal tissues from the rectal stump. After debridement, histopathologic evidence of angioinvasive mucormycosis was found in the left gluteal muscles and perirectal soft tissues. The patient returned to the operating room for further pelvic soft-tissue debridement and transperineal completion proctectomy. This was performed in the left lateral decubitus position and was facilitated by a short rectal stump. Proctectomy allowed adequate exposure of presacral and perirectal tissues for appropriate debridement. Temporary dressings of dilute sodium hypochlorite solution³ were placed over the left pelvis and resulting perineal defect. Left hip disarticulation was performed on the second postoperative day. This allowed the abductor compartment muscles to cover the perineal soft-tissue defect and the anterior compartment muscles to cover the left pelvis and sacrum. Continued histopathologic evidence of deep *Mucor* colonization of the anterior compartment muscles required further debridement. The left sacrum was eventually granulated over with negative pressure wound therapy and split thickness skin graft, but will require eventual soft-tissue flap coverage (Fig. 3). Proctectomy was complicated by a posterior membranous urethral laceration

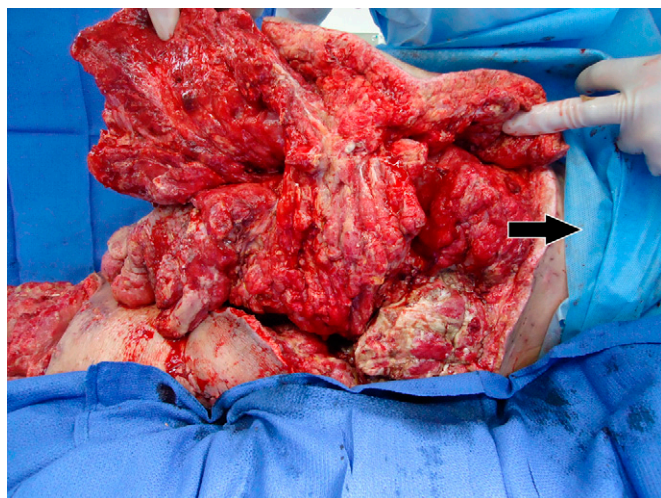


FIGURE 3. View of posterior torso/sacral soft tissue wounds after multiple complex debridements of serially necrotic and infected soft tissue. Note evidence of soft tissue defect because of loss after blast injury and IFI in region of ischioanal fossa. Wounds now granulating without evidence of infection. Arrow oriented toward patient's head.

primarily repaired on the second postoperative day. Wound closure was achieved and the soldier remains an inpatient at our facility receiving physical rehabilitation.

DISCUSSION

Recent OCO have resulted in some of the most devastating injuries from conflict surviving beyond the battlefield. In addition to exsanguination, traumatic amputation, disruption of tissue planes with degloving and destruction of perineal/pelvic musculoskeletal structures, and devastating genitourinary and anorectal injuries, these patients are at increased risk for invasive fungal infection (IFI). Specific risk factors for IFI identified in a recent review of combat casualties include dismantled blast injury mechanism, extensive perineal/pelvic soft-tissue injury, bilateral traumatic above-knee amputations, and supermassive transfusion (25 or more units of blood product transfused within 24 hours of injury).⁴ A recent clinical practice guideline addressing IFI has been published by the Department of Defense Joint Theater Trauma System because of a concerning rise in IFI in service members.⁵ Key messages from this clinical practice guideline include early recognition of patients at risk for IFI, use of topical antimicrobials with fungal coverage (specifically 0.0025% Dakins solution) as a postoperative dressing after aggressive debridement of all nonviable tissue and embedded organic material, biopsy of concerning tissue for histopathologic evaluation for colonization or invasive infection because of fungus, and initiation of broad-spectrum, empiric antifungals (voriconazole and liposomal amphotericin B) when serial debridements reveal progressive, unexpected tissue necrosis or verification of IFI. As with other disease processes concerning necrosis and infection, the key to success and survival is adequate

surgical debridement. As this series illustrates, with the complexity of wounds created in blast-injured patients on recent OCO, debrided tissue may include important genitourinary, anorectal, musculoskeletal, and vascular tissue.

To the best of our knowledge, this series represents the first of its kind to describe proctectomy for the constellation of catastrophic perineal blast injury, anal sphincter complex destruction, and IFI. Best evidence suggests that resection should be used for destructive colorectal lesions.⁶ In addition, extraperitoneal rectal injuries are recommended to be managed with fecal diversion.⁷ On rare occasion, isolated extensive perineal wounds are managed with fecal diversion as well. Proctectomy is an aggressive intervention for combined anal sphincter injury, catastrophic perineal injury, and IFI; however, we feel that this procedure was prudent and facilitated wound closure, thorough debridement of pelvic soft tissues involved with *Mucor* colonization, and prevented further perineal soilage. We have been involved in the care of less severely injured casualties with combined noninfected perineal and anal sphincter injuries that were ultimately managed with wound closure followed by sphincteroplasty (T.A. Erchinger, personal communication, October 16, 2013). The patients in this series had nonreconstructable sphincter injuries with severe associated pelvic injuries making restoration of intestinal continuity impossible.

This series is limited by its retrospective nature and small number of patients. We also are confident that because of the catastrophically injured casualties surviving injuries during recent conflicts, there are similar patients treated with proctectomy that we have not included in this series. We feel this does not take away from the benefit of describing our experience to assist future surgeons faced with similar situations.

CONCLUSION

We report our experience with the management of catastrophically injured combat casualties found to have a constellation of dismantled blast injury, complex pelvic/perineal soft-tissue injuries including complete disruption of anal sphincter complex, and IFI of soft tissues treated with proctectomy. This is the first series to describe the management of this pattern of injuries using proctectomy. Although this manuscript does not provide a guideline for managing this type of injury, it does provide the military surgeon with a description of one approach we have found successful in the management of patients with such severe injuries.

REFERENCES

1. Mossadegh S, Tai N, Midwinter M, Parker P: Improvised explosive device related pelvi perineal trauma: anatomic injuries and surgical management. *J Trauma Acute Care Surg* 2012; 73(2 Suppl 1): S24–S31.
2. Pendleton RA, Holmes JH 4th: Systemic absorption of amphotericin B with topical 5% mafenide acetate/amphotericin B solution for grafted burn wounds: is it clinically relevant? *Burns* 2010; 36: 38–41.

Case Report

3. Hggers JP, Sazy JA, Stenberg BD, Strock LL, McCauley RL, Herndon DN, et al: Bactericidal and wound healing properties of sodium hypochlorite solutions: the 1991 Lindberg award. *J Burn Care Rehabil* 1991; 12: 420-4.
 4. Warkentien T, Rodriguez C, Lloyd B, Wells J, Weintrob A, Dunne JR, et al: Invasive mold infections following combat related injuries. *Clin Infect Dis* 2012; 55: 1441-9.
 5. Department of Defense Joint Theater Trauma System. [http://www.usaisr.amedd.army.mil/assets/cpgs/Invasive Fungal Infection in War Wounds 1 Nov 12.pdf](http://www.usaisr.amedd.army.mil/assets/cpgs/Invasive_Fungal_Infection_in_War_Wounds_1_Nov_12.pdf); accessed October 21, 2013.
 6. Johnson EK, Steele SR: Evidence based management of colorectal trauma. *J Gastrointest Surg* 2013; 17: 1712-9.
 7. Brogden TG, Garner JP: Anorectal injury in pelvic blast. *J R Army Med Corps*. 2013; 159(Suppl 1): i26-31.
-