

Management of complex abdominal wall defects associated with penetrating abdominal trauma

G Suren Arul,¹ B J Sonka,² J B Lundy,³ R F Rickard,^{4,5} S L A Jeffery⁴

¹212 Field Hospital, Sheffield, UK

²Department of Surgery, William Beaumont Army Medical Centre, El Paso, Texas, USA

³San Antonio Military Medical Centre, Joint Base Sane Antonio, San Antonio, Texas, USA

⁴Department of Surgery, Royal Centre for Defence Medicine, Birmingham, UK

⁵Derriford Hospital, Plymouth, UK

Correspondence to

Lt Col G Suren Arul, Department of Surgery, Birmingham Children's Hospital, Steelhouse Lane, Birmingham B4 6NH, UK; surenarul@doctors.org.uk

Received 25 March 2014
Accepted 27 March 2014

ABSTRACT

Introduction The paradigm of Damage Control Surgery (DCS) has radically improved the management of abdominal trauma, but less well described are the options for managing the abdominal wall itself in an austere environment. This article describes a series of patients with complex abdominal wall problems managed at the UK-led Role 3 Medical Treatment Facility (MTF) in Camp Bastion, Afghanistan.

Method Contemporaneous review of a series of patients with complex abdominal wall injuries who presented to the Role 3 MTF between July and November 2012.

Results Five patients with penetrating abdominal trauma associated with significant damage to the abdominal wall were included. All patients were managed using DCS principles, leaving the abdominal wall open at the end of the first procedure. Subsequent management of the abdominal wall was determined by a multidisciplinary team of general and plastic surgeons, intensivists and specialist nurses. The principles of management identified included minimising tissue loss on initial laparotomy by joining adjacent wounds and marginal debridement of dead tissue; contraction of the abdominal wall was minimised by using topical negative pressure dressing and dermal-holding sutures. Definitive closure was timed to allow oedema to settle and sepsis to be controlled. Closure techniques include delayed primary closure with traction sutures, components separation, and mesh closure with skin grafting.

Discussion A daily multidisciplinary team discussion was invaluable for optimal decision making regarding the most appropriate means of abdominal closure. Dermal-holding sutures were particularly useful in preventing myostatic contraction of the abdominal wall. A simple flow chart was developed to aid decision making in these patients. This flow chart may prove especially useful in a resource-limited environment in which returning months or years later for closure of a large ventral hernia may not be possible.

INTRODUCTION

The concept of damage control surgery (DCS), introduced over the last two decades, has radically changed the surgical approach to major trauma and penetrating abdominal injuries in particular.^{1–4}

In penetrating abdominal injuries, DCS means a laparotomy, control of haemorrhage and visceral contamination, temporary abdominal closure and transfer of the patient to the intensive care unit. Temporary abdominal closure allows a relatively quick means of ending a laparotomy, reduces the risk of abdominal compartment syndrome and demands a need for a second-look laparotomy to search for further injuries. This second-look laparotomy is performed when the patient's physiology

Key messages

- ▶ Complex abdominal wall wounds result from battlefield injuries.
- ▶ Topical negative pressure and dermal-holding sutures can prevent loss of abdominal fascial domain while waiting for control of sepsis and a resolution of oedema.
- ▶ A multidisciplinary team is essential for management.
- ▶ A simple algorithm is provided to help in the decision making for the most appropriate means of definitive closure.

has normalised, usually at 12–72 h after the damage control procedure.

Closure of the midline abdominal wall fascia and skin at this second procedure is usually straightforward. However, in the context of significant injury to the abdominal wall, especially following tissue loss due to combat-related trauma from blast, fragmentation or multiple gunshot wounds, this may prove challenging. Furthermore, severe oedema or dilatation of the bowel may prevent closure of the abdominal wall without causing ischaemia to the abdominal wall or the abdominal contents. This article uses a series of cases to illustrate a simple algorithm for the staged management of complex abdominal wall problems.

PATIENTS AND METHODS

Five Afghan adult male patients were admitted to the Role 3 Medical Treatment Facility (MTF) in Camp Bastion, Afghanistan between July and November 2012 following ballistic trauma. All had suffered penetrating abdominal injuries with bowel perforation and significant peritoneal soiling at the time of injury; they all had loss of abdominal wall skin, muscle and fascia. The grading system of abdominal wall injury described by Dennis *et al*⁵ following blunt abdominal trauma was adopted, as there is minimal literature regarding abdominal wall injury following major penetrating trauma (Table 1).

Initial management of all five cases involved damage control (abbreviated) surgery with bowel disconnection, thorough peritoneal lavage with the abdomen left open with a topical negative pressure (TNP) dressing; extremity wounds were debrided and dressed with TNP (Table 2). The following case reports focus on the management of the abdominal wall following the principles outlined in the (Box 1).

To cite: Arul GS, Sonka BJ, Lundy JB, *et al*. *J R Army Med Corps* Published Online First: [please include Day Month Year] doi:10.1136/jramc-2014-000276

Report Documentation Page

Form Approved
OMB No. 0704-0188

Public reporting burden for the collection of information is estimated to average 1 hour per response, including the time for reviewing instructions, searching existing data sources, gathering and maintaining the data needed, and completing and reviewing the collection of information. Send comments regarding this burden estimate or any other aspect of this collection of information, including suggestions for reducing this burden, to Washington Headquarters Services, Directorate for Information Operations and Reports, 1215 Jefferson Davis Highway, Suite 1204, Arlington VA 22202-4302. Respondents should be aware that notwithstanding any other provision of law, no person shall be subject to a penalty for failing to comply with a collection of information if it does not display a currently valid OMB control number.

1. REPORT DATE 01 MAR 2015		2. REPORT TYPE N/A		3. DATES COVERED -	
4. TITLE AND SUBTITLE Management of complex abdominal wall defects associated with penetrating abdominal trauma				5a. CONTRACT NUMBER	
				5b. GRANT NUMBER	
				5c. PROGRAM ELEMENT NUMBER	
6. AUTHOR(S) Arul G. S., Sonka B. J., Lundy J. B., Rickard R. F., Jeffery S. L. A.,				5d. PROJECT NUMBER	
				5e. TASK NUMBER	
				5f. WORK UNIT NUMBER	
7. PERFORMING ORGANIZATION NAME(S) AND ADDRESS(ES) US Army Institute of Surgical Research, JBSA Fort Sam Houston, TX				8. PERFORMING ORGANIZATION REPORT NUMBER	
9. SPONSORING/MONITORING AGENCY NAME(S) AND ADDRESS(ES)				10. SPONSOR/MONITOR'S ACRONYM(S)	
				11. SPONSOR/MONITOR'S REPORT NUMBER(S)	
12. DISTRIBUTION/AVAILABILITY STATEMENT Approved for public release, distribution unlimited					
13. SUPPLEMENTARY NOTES					
14. ABSTRACT					
15. SUBJECT TERMS					
16. SECURITY CLASSIFICATION OF:			17. LIMITATION OF ABSTRACT UU	18. NUMBER OF PAGES 8	19a. NAME OF RESPONSIBLE PERSON
a. REPORT unclassified	b. ABSTRACT unclassified	c. THIS PAGE unclassified			

Table 1 Abdominal wall injury grade as defined by Dennis *et al*⁵

Grade	Definition
I	Subcutaneous tissue contusion
II	Abdominal wall muscle haematoma
III	Single abdominal wall muscle disruption
IV	Complete abdominal wall muscle disruption
V	Complete abdominal wall disruption with herniation of abdominal contents
VI	Complete abdominal wall disruption with evisceration

Case 1

Injury to the epigastric area from improvised explosive device (IED) blast resulted in significant loss of abdominal wall and a sternal fracture. Re-look laparotomy at 48 h allowed

anastomosis of all bowel disconnections, an omental flap was prepared to cover the sternum, debridement of the abdominal wall and the abdomen left as a laparostomy with a TNP dressing. A further 48 h later, he returned to theatre (Figure 1A) where a full component separation was performed (Figure 1B–E)) with the skin left open with a TNP dressing. A tracheostomy was performed on Day 10 and he underwent a further five trips to theatre to re-dress the abdominal wound before it successfully underwent split skin graft on Day 24. He was transferred to a local facility on Day 25.

Case 2

Initial DCS involved laparotomy, packing of the liver and bowel disconnection. Bowel was anastomosed at 48 h; closure by component separation was initially attempted, but after raising of the suprafascial flaps it was considered that the abdomen would be too tight to close even allowing for the extra length that

Table 2 Details of the five patients with abdominal wall injury—all underwent damage control laparotomy for their abdominal injuries. All had abdominal wall muscle loss of at least 10×10 cm, required topical negative pressure dressings to their wounds and had at least one episode of wound sepsis.

	1	2	3	4	5
Admission details					
Mechanism	IED	Blast/fragment	GSW	IED	Blast/fragment
Military ISS	37	34	8	38	33
Initial pH	7.0	7.19	7.34	7.15	6.8
Lactate on admission (mmol/L)	6.3	6.4	1.18	3.34	15.2
Blood transfusion (units of RBC +FFP+Plt)	11+11+1	10+10+1	2+2	13+13+2	18+18+2
Injuries	Small bowel (×4) Colon Right superficial femoral artery Sternal fracture	Liver laceration Small bowel (×2) Colon	Colon Large flank defect with evisceration	Small bowel (×2) Right superficial femoral artery Scrotum Right BKA Blinded	Small bowel (×2) Internal iliac artery Large right buttock and leg wounds
Abdominal wall					
Abdominal wall wounds	2 large areas with loss of skin and muscle in epigastrium and left iliac fossa	Multiple fragment wounds	Small entry wound with large exit wound in flank	Multiple small entry wounds to torso and 50% loss of skin and subcutaneous tissue	Severe penetrating wound from right hip into peritoneal cavity. Multiple small torso wounds
Abdominal skin loss	Yes	Significant (50% of anterior abdominal wall)	Yes	Yes	Yes
Grade of abdominal wall injury ⁴	V	IV	VI	V	V
Prolonged ileus or severe bowel dilatation	No	Yes	No	Yes	Yes
Closure and outcomes					
Closure achieved?	Components separation	Vicryl mesh	Vicryl mesh just to flank	DPC	DPC
Duration of open fascia	5 days	10 days	2 days	13 days	10 days
Duration of open skin	24 days, then SSG	16 days Dermal-holding sutures & DPC	20 days Dermal-holding sutures & DPC	20 days Dermal-holding sutures, DPC & SSG	Skin not closed, dermal-holding sutures
Wound sepsis organisms	Resistant <i>E coli</i> (ESBL)	<i>Acinetobacter</i>	Resistant <i>E coli</i> (ESBL)	<i>Pseudomonas acinetobacter</i> Resistant <i>E coli</i> (ESBL)	<i>Acinetobacter Klebsiella</i> Coliform
ITU LOS	14 days	12 days	4 days	13 days	13 days
Hospital LOS	25 days	18 days	20 days	20 days	13 days

BKA, below knee amputation; DPC, delayed primary closure; FFP, fresh frozen plasma; GSW, gunshot wound; IED, improvised explosive device; ISS, Injury Severity Score; ITU, intensive treatment unit; LOS, length of stay; Plt, platelets; RBC, packed red blood cells; SSG, split skin graft.

Box 1 Some of the principles of management of the open abdomen associated with major penetrating trauma

'Join the wounds principle': We tried if at all possible to connect wounds near the midline when making the initial laparotomy wound, dissecting in a suprafascial plane until the linea alba was reached. Though it did not give the usual simple midline incision it prevented being left with small bridges of healthy tissue surrounded by damaged areas that subsequently need debridement causing even more loss of domain.

Topical Negative Pressure: We used topical negative pressure in all situations over both the open abdomen and the fascia when this was closed but the skin was open. Whenever visceral contents were exposed, a non-adherent, protective barrier such as a sterile plastic cover for radiography devices was used to protect the viscera from direct contact with the suction device. The TNP removed excess tissue fluid, reduced the bacterial load to the wound and encouraged tissue granulation.

Dermal Holding Sutures: Heavy (0 PDS) sutures placed into the dermis were particularly good at preventing loss of domain while waiting for resolution of bowel oedema and paralytic ileus. In case 2 we had already dissected the fascia from the skin with a plan to proceed to components separation before this was abandoned because the gap was too large. In this situation the dermal holding sutures worked well at preventing loss of skin domain but did not prevent the loss of the fascial domain. In cases 3, 4 and 5 there had been no dissection of the fascia and dermal holding sutures worked well at preventing loss of both the skin and fascial domains. The preferred approach following these few cases was to use dermal holding sutures early (from the point of the first relook) without any separation of the skin and fascia. When the abdomen is open the sutures would be placed above the TNP dressing to prevent the taut sutures potentially damaging the bowel. This way the both the skin and fascia are in relatively good condition when it is finally deemed that they are ready for definitive closure.

Delayed skin closure: Closing the skin when there is any evidence of sepsis invariably leads to on-going skin wound sepsis, failure to heal, and potential fascial dehiscence. The advantage of the dermal holding sutures was that the skin could be left open after fascial closure with TNP underneath so that the wound would be clean, healthy and granulating prior to closure.

would be created, this was therefore abandoned before the fascial components were separated. The reason for the difficulty was due to the combination of the loss of abdominal wall from injuries and debridement and significant bowel oedema and dilatation from the ileus. The abdomen was left open, and

subdermal-holding sutures inserted and covered with TNP dressing. An multidisciplinary team (MDT) decision was made to wait until the oedema and ileus had settled before any further attempts were made to close the abdomen; bowel function was slow to improve due to the systemic sepsis. It was only

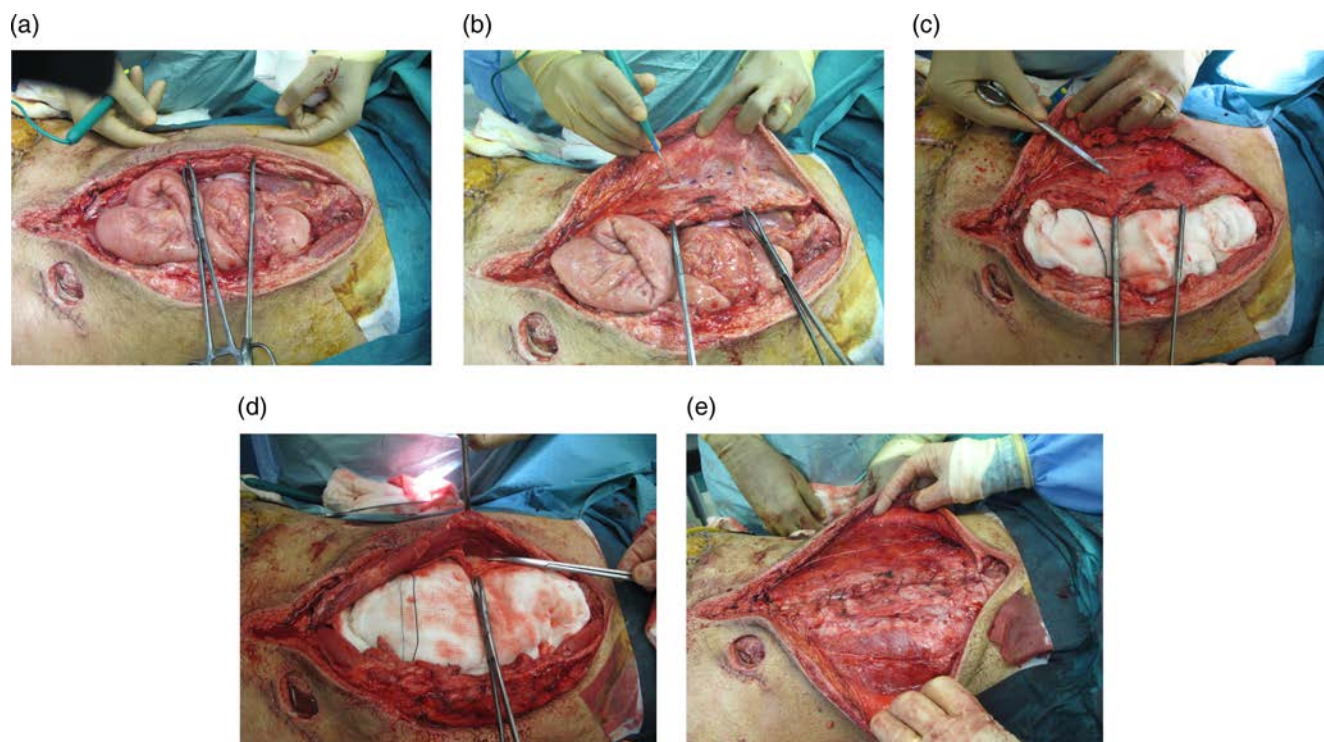


Figure 1 Patient 1. (A) at Day 5 after laparotomy, and debridement of the abdominal injuries most of which were in the midline. A large abdominal defect remains. (B) Component separation of the abdominal wall—initial raising of the subcutaneous flap to the edge of the rectus abdominis. (C) Component separation—release of the lateral rectus component. (D) Component separation—release of the medial rectus. (E) Component separation—closure of fascia.

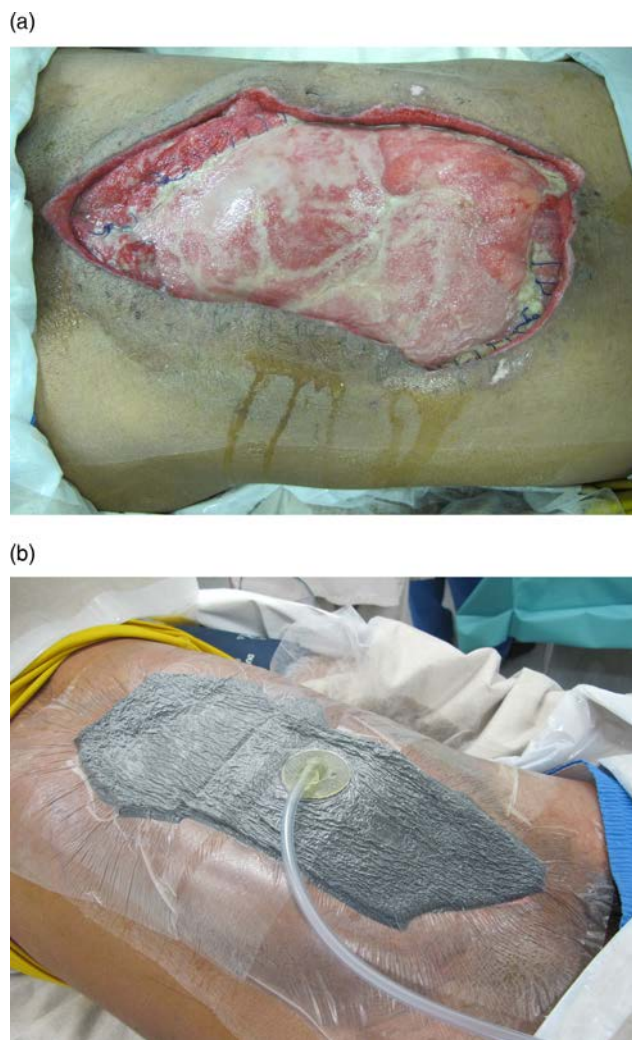


Figure 2 Patient 2. (A) Day 10 after injury with the vicryl mesh as inlay. (B) Black foam topical negative pressure dressing over the vicryl mesh.

considered reasonable to close his abdomen on Day 10. We found, however, that because the skin had already been separated from the fascia of the rectus sheath (following the abandoned components separation) that the subdermal-holding sutures were not as effective at preventing the rectus sheath retraction as in the other cases; at the subsequent re-look it was not possible to perform a component separation. Polygalactin

mesh (Vicryl, Ethicon, USA) was inserted as an inlay and TNP dressing using foam placed to encourage granulation (Figure 2A, B). Seven days later he underwent a successful split skin graft to his abdominal wound. He was discharged back to a local facility with a plan to close his ventral hernia in 1 year's time.

Case 3

The patient was injured by a through and through gun shot wound with evisceration of bowel (Figure 3A). At laparotomy there was injury to the colon with faecal contamination, and the zone of injury of the exit wound was much wider than the actual hole with the area of devitalised tissue corresponding to the bruising (Figure 3B); following bowel disconnection, lavage and debridement, the abdomen was left open. The bowel was reanastomosed at 48 h, and the midline wound closed. The flank wound was closed under a moderate amount of tension using pulley sutures through the surrounding muscle and fascia, and an on-lay polygalactin mesh placed over this. Dermal-holding sutures were placed over the midline wound and the flank wound. By Day 20, it was possible to close the midline skin wound by delayed primary closure, but a split skin graft was required for the flank wound.

Case 4

The patient underwent DCS wounds following IED injury, with debridement of all with a TNP dressing to his abdomen. On second look in theatre, these small wounds on the abdomen were found to be still grossly contaminated and infected and needed further debridement resulting in the loss of almost 50% of the abdominal skin and subcutaneous tissue. Initial attempts to close the skin were not successful, so dermal-holding sutures were placed, and on Day 20 it was possible to close the midline wound, but he did need a split skin graft to cover all the areas of debridement.

Case 5

The patient suffered significant blast and fragmentation injuries from military grade ordnance with wounds to his abdomen, legs and right buttock and hip joint. Initial DCS involved laparotomy, small bowel disconnection, and debridement and packing of the cavity of his right buttock. There was significant disruption of the abdominal wall musculature (Figure 4A) Bowel was reanastomosed at Day 2, but due to ongoing sepsis, he had a significant ileus (Figure 4B). His abdomen was left open with dermal-holding sutures to prevent retraction of the skin (Figure 4C,D); the abdomen was closed at Day 10 (Figure 4E) but unfortunately he died at Day 13 due to systemic sepsis.

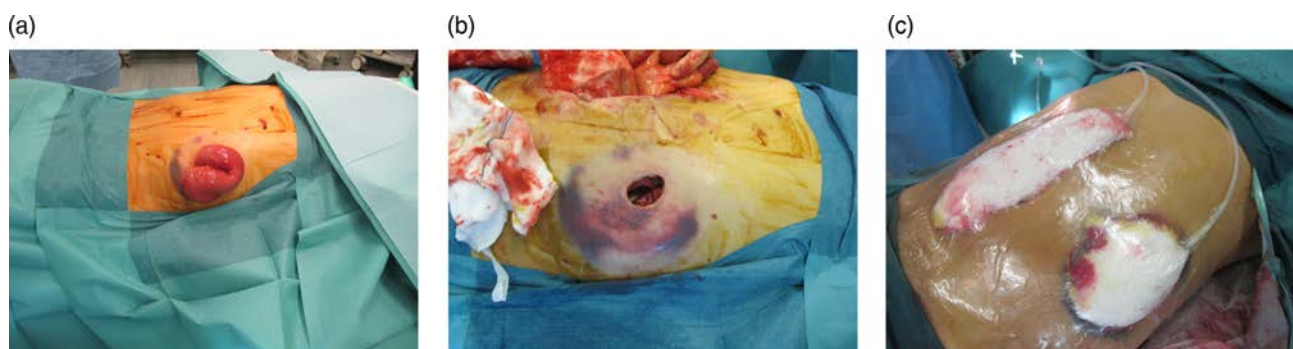

Figure 3 Patient 3 (A) Traumatic abdominal wall injury with evisceration through high-energy transfer gunshot exit wound. (B) The contusion reflects the underlying dead muscle, fascia and skin caused by the cavitation associated with energy transfer. (C) The dead areas required debridement and were then covered with topical negative pressure.

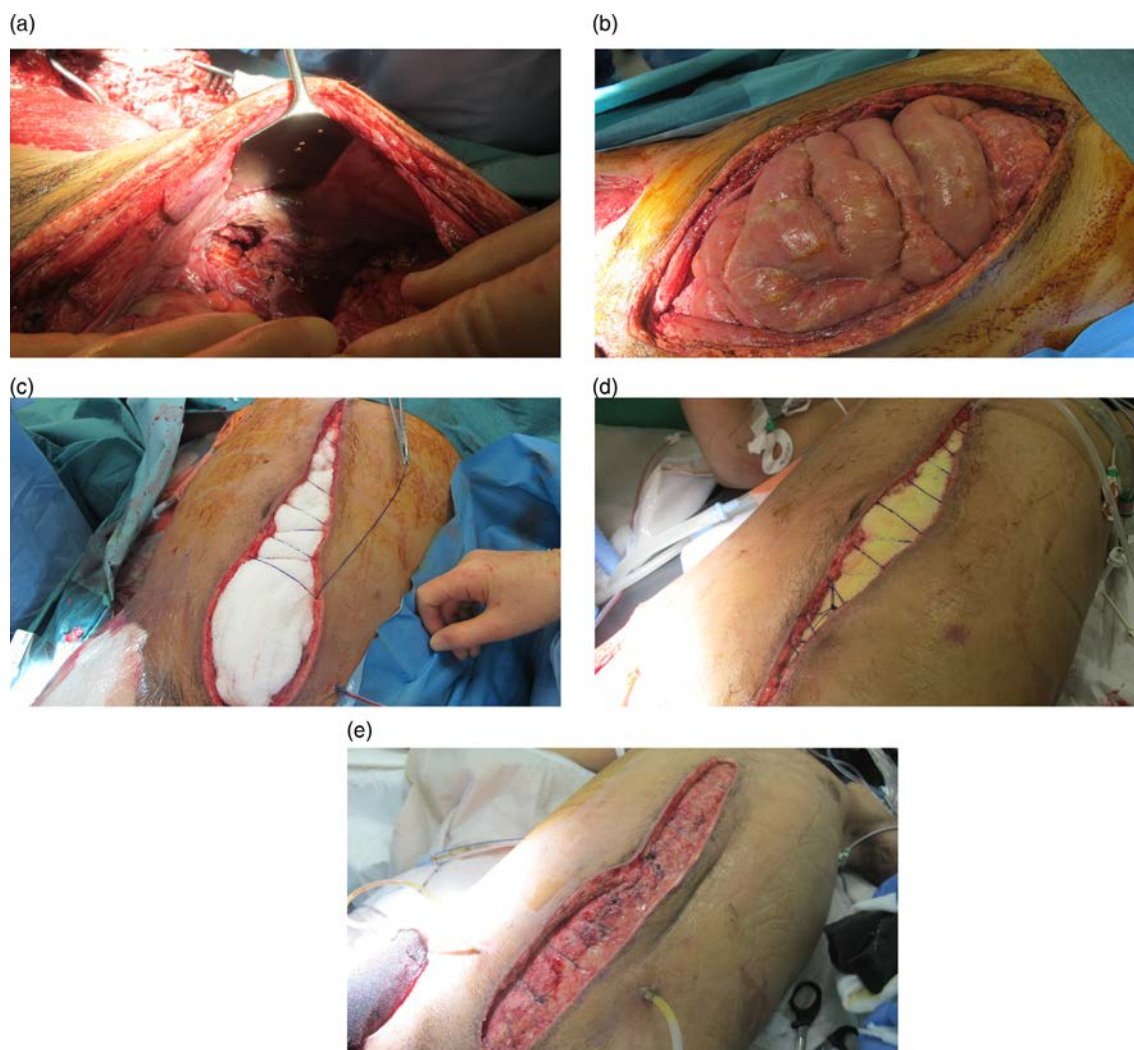

Figure 4 Patient 5 (A) Laparotomy following blast injury with penetration of cavity. The degree of disruption of the abdominal wall muscle is evident from within the abdomen. A significant amount of abdominal wall injury in the midline also needed to be debrided, and it was damage to the lateral abdominal wall that prevented the use of component separation. (B) Change of dressing on Day 5 postinjury. The bowel was reanastomosed on Day 2, but a significant ileus remained. It was not possible to close the abdomen, but dermal-holding sutures were placed to prevent further retraction of the abdominal wall. (C) Change of dressing on Day 7. As the ileus resolves, the tension on the abdominal wall relaxed and the dermal-holding sutures are gradually tightened. The suture goes over the gauze to prevent the risk of bowel damage. Topical negative pressure continues to be used. (D) Change of dressing on Day 8. Further tightening of the dermal-holding sutures as the ileus resolves. (E) Change of dressing on Day 10. It is now possible to close the abdominal wall fascia primarily. Skin left open.

Reconstructive options

Loss of abdominal wall may result from the initial injury and the subsequent debridement. Early discussion within a multidisciplinary setting started at the first re-look operation (at 12–72 h) when it became obvious that simple abdominal closure alone would not be an option. The multidisciplinary team included the general surgeons, plastic surgeon, burns and plastic surgery nurse specialist, microbiology, intensive care, the hospital medical director and the orthopaedic surgeons if there was concomitant bony or extremity injury. Our understanding of the problems associated with these injuries, and especially the use of dermal-holding sutures evolved over the course of this series.

Following marginal debridement of all necrotic material,⁶ the treatment decisions could be divided into the following:

- ▶ conservative management using TNP with re-look surgery in 12–72 h
- ▶ delayed primary closure of fascia and/or skin using dermal-holding sutures in combination with TNP to gradually recruit tissue.⁷ Dermal-holding sutures were placed with 0

loop polydioxanone suture (PDS) into the subcutaneous layer and taking a firm bite of the dermal layer—it did not pierce the epidermis or the rectus abdominis fascia. The tension of the sutures is enough to prevent retraction, but did not attempt to close the wound

- ▶ components separation of the musculoaponeurotic abdominal wall⁸
- ▶ vicryl mesh to close the abdominal fascial defect
- ▶ skin grafting either directly onto muscle or fascia, or onto the vicryl mesh once granulation was established.

Once the patient's physiology had improved, they could be extubated and fed, even with an open abdomen; hence, decisions after this could be based purely upon the surgical needs of how best to close the abdominal wall. As surgical follow-up was not readily available in Afghanistan, the preferred approach was to avoid implanting foreign materials because of the risk of infection and the need to repair a ventral hernia, however, where this was not possible (ie, cases 2 and 3) we used polygalactin mesh.

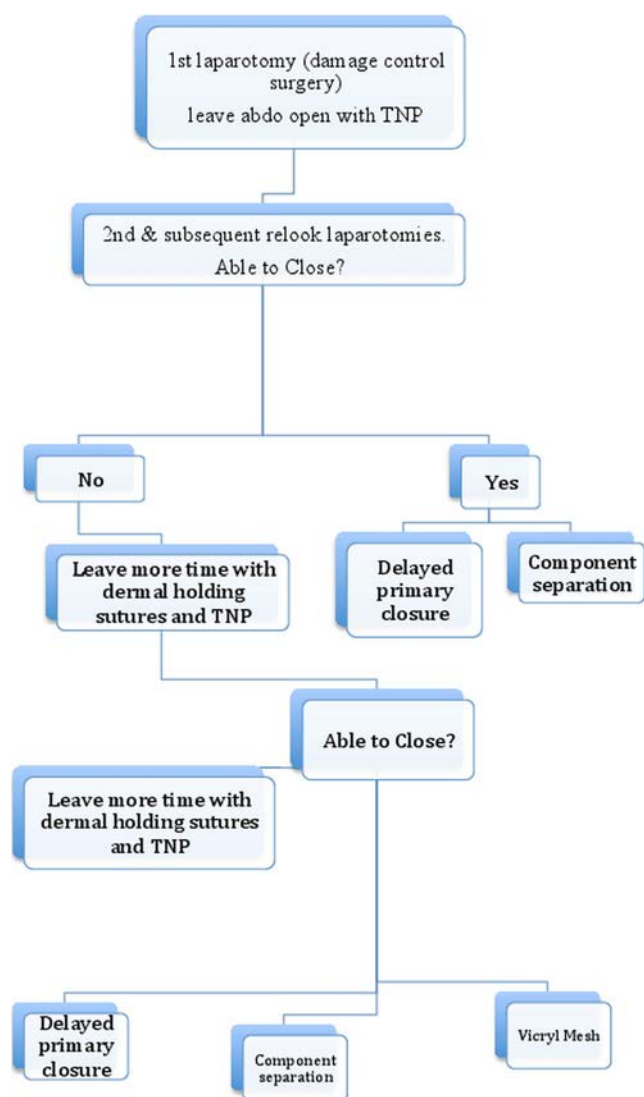


Figure 5 Simple treatment algorithm for management of significant abdominal wall trauma from ballistic injury.

Flow chart

After reviewing the management of these five cases and the principles followed, a simple treatment algorithm was conceived (Figure 5). It was important not to be too hasty with closure if there was further tissue to debride, any evidence of tightness or ongoing sepsis. Dermal-holding sutures, in combination with vacuum dressings prevented retraction of the skin and musculoaponeurotic abdominal wall, providing no dissection to separate the two layers had been performed; this made primary fascial closure a much more viable option once the abdominal wall oedema and bowel dilatation from ileus had settled. The skin should be left open after delayed primary closure of the fascia to reduce the risks of wound infection leading to dehiscence. Once the risk of wound sepsis has passed, and the tissue is clean and granulating, a decision can be made to either proceed to delayed primary skin closure or split skin graft for large skin defects.⁹

DISCUSSION

The first description of a series of laparostomies was by Steinberg in 1979.¹⁰ During the early 1980s, a number of groups described

the physiological events associated with major abdominal trauma, such as coagulopathy¹¹ and abdominal compartment syndrome,^{12–13} and the benefits of DCS and laparostomy were highlighted.^{1–4–14} The use of a temporary vacuum dressing to collect exudate was first described by Brock *et al* in 1995.¹⁵

It was not until the 1990s that the problems with laparostomy started to be addressed. One of the disadvantages of the open abdomen approach is the loss of the musculo-aponeurotic fascia and skin domain,¹⁶ and failure to be able to subsequently close the abdomen following this approach has been reported in up to 60% of cases.¹⁷ This is particularly an issue when associated with military patterns of wounding, as there can be significant abdominal wall damage from blast, shrapnel and high-energy transfer gunshot wounds. Feliciano and Burch¹² described various ways to temporarily close the abdomen, and the second-order effect of these large abdominal defects. In 1994, Fabian *et al*¹⁸ described an initial series of over 80 patients with open abdomens closed by either permanent mesh, vicryl mesh or a modification of Ramirez' original method of components separation. These authors concluded that the modified components separation was good for smaller defects, while vicryl mesh was better for larger defects.

TNP dressings are now standard practice for UK military combat wounds. There is little in the way of randomised controlled trial evidence for their use in the military setting,^{19–20} but they have been shown to be very effective at exudate management and wound isolation.²¹

A number of groups have used TNP dressings in combination with sutures placed through the rectus abdominis fascia to recruit tissues following retraction of the abdominal wall. TNP dressings in conjunction with vacuum-assisted devices have also been described as helping in the management of the open abdomen.^{22–23} Garner *et al*,²⁴ and Miller *et al*²⁵ described the use of serially smaller VAC sponges (KCI International, San Antonio, Texas, USA) placed beneath a running skin suture in order to prevent retraction of the abdominal wall. In a prospective case series using this method, Miller *et al*²⁵ obtained a primary abdominal closure rate of 88% at a mean of 9.6 days (range 1–21 days), with no increase in enteric complications or abdominal compartment syndrome being reported.

Procedures, such as mesh closure of the open abdomen, have been described,^{25–26} and in the only randomised controlled trial showed no statistical difference in complications between TNP compared with polyglactin mesh closure²⁷; though both groups of this trial underwent skin grafting and delayed repair of the resulting ventral hernia. It was felt that permanent or polyglactin mesh closure had disadvantages in a field hospital because the risks of infection and the lack of surgical follow-up meant there may be no possibility of local national patients having ventral hernia repair at a later stage. Other techniques, such as the Wittman patch, were not available in this setting.²⁸

Components separation has the advantage of using the patient's native abdominal wall, but may be more challenging to perform if there has been damage to the rectus muscle. Its use in the acute setting has only recently been described,²⁹ but anecdotally has been used in austere environments with great success allowing approximately 14 cm of additional laxity.³⁰ We found that the benefits of dermal-holding sutures allowed time for the visceral oedema to settle, sepsis to be managed and ileus to resolve without loss of domain. As time went on, confidence in simply waiting until conditions were optimal before attempting definitive closure increased. Skin closure would be further delayed until all risks of wound sepsis had passed and the underlying tissue was granulating. The advantages in a resource-limited

environment are the benefits of getting primary closure at the initial admission as returning for follow-up surgery after months may prove difficult to coordinate.

CONCLUSION

We found the most crucial factor in the management of patients with complex abdominal wall defects following penetrating trauma was having a multidisciplinary team available so that all aspects of clinical care and logistics could be taken into account. Dermal-holding sutures, in conjunction with TNP dressings, allowed time for the ileus, bowel oedema and sepsis to settle prior to choosing the most appropriate means of abdominal wall closure. A simple algorithm was developed to help with decisions regarding management and subsequent closure of the abdominal wall.

Acknowledgements The authors would like to thank Christine Bratton, specialist, burns and plastics nurse, for her invaluable assistance in managing these patients in Camp Bastion.

Contributors GSA conceived the idea of the project and collected the data. BJS, JBL, RFR and SLAJ were all part of the group that analysed the data and helped draw up the flowchart. All five authors contributed significantly to the writing of the manuscript.

Competing interests None.

Patient consent Obtained.

Provenance and peer review Not commissioned; externally peer reviewed.

REFERENCES

- 1 Rotondo MF, Schwab CW, McGonigal MD, *et al.* 'Damage control': an approach for improved survival in exsanguinating penetrating abdominal injury. *J Trauma* 1993;35:375–82; discussion 82–3
- 2 Midwinter MJ. Damage control surgery in the era of damage control resuscitation. *J R Army Med Corps* 2009;155:323–6.
- 3 Jansen JO, Thomas R, Loudon MA, *et al.* Damage control resuscitation for patients with major trauma. *BMJ* 2009;338:b1778.
- 4 Bowley DM, Barker P, Boffard KD. Damage control surgery—concepts and practice. *J R Army Med Corps* 2000;146:176–82.
- 5 Dennis RW, Marshall A, Deshmukh H, *et al.* Abdominal wall injuries occurring after blunt trauma: incidence and grading system. *Am J Surg* 2009;197:413–17.
- 6 Taylor CJ, Hettiaratchy S, Jeffery SL, *et al.* Contemporary approaches to definitive extremity reconstruction of military wounds. *J R Army Med Corps* 2009;155:302–7.
- 7 Van der Velde M, Hudson DA. VADER (vacuum-assisted dermal recruitment): a new method of wound closure. *Ann Plast Surg* 2005;55:660–4.
- 8 Ramirez OM, Ruas E, Dellon AL. 'Components separation' method for closure of abdominal-wall defects: an anatomic and clinical study. *Plast Reconstr Surg* 1990;86:519–26.
- 9 Bhangu A, Singh P, Lundy J, *et al.* Systemic review and meta-analysis of randomized clinical trials comparing primary vs delayed primary skin closure in contaminated and dirty abdominal incisions. *JAMA Surg* 2013;148:779–86.
- 10 Steinberg D. On leaving the peritoneal cavity open in acute generalized suppurative peritonitis. *Am J Surg* 1979;137:216–20.
- 11 Stone HH, Strom PR, Mullins RJ. Management of the major coagulopathy with onset during laparotomy. *Ann Surg* 1983;197:532–5.
- 12 Feliciano DV, Burch JM. Towel clips, silos and heroic forms of wound closure. *Adv Trauma Crit Care* 1991;6:231–35.
- 13 Duff JH, Moffat J. Abdominal sepsis managed by leaving abdomen open. *Surgery* 1981;90:774–8.
- 14 Feliciano DV, Mattox KL, Jordan GL Jr. Intra-abdominal packing for control of hepatic hemorrhage: a reappraisal. *J Trauma* 1981;21:285–90.
- 15 Brock WB, Barker DE, Burns RP. Temporary closure of open abdominal wounds: the vacuum pack. *Am Surg* 1995;61:30–5.
- 16 Fabian TC. Damage control in trauma: laparotomy wound management acute to chronic. *Surg Clin North Am* 2007;87:73–93.
- 17 Ivatury RR. Update on open abdomen management: achievements and challenges. *World J Surg* 2009;33:1150–3.
- 18 Fabian TC, Croce MA, Pritchard FE, *et al.* Planned ventral hernia. Staged management for acute abdominal wall defects. *Ann Surg* 1994;219:643–50; discussion 651–3.
- 19 Runkel N, Krug E, Berg L, *et al.* Evidence-based recommendations for the use of negative pressure wound therapy in traumatic wounds and reconstructive surgery: steps towards an international consensus. *Injury* 2011;42(Suppl.1):S1–12.
- 20 Fries CA, Jeffery SL, Kay AR. Topical negative pressure and military wounds—a review of the evidence. *Injury* 2011;42:436–40.
- 21 Taylor CJ, Jeffery SL. Management of military wounds in the modern era Wounds UK. 2009;5:50–8.
- 22 DeFranzo AJ, Pitzer K, Molnar JA, *et al.* Vacuum-assisted closure for defects of the abdominal wall. *Plast Reconstr Surg* 2008;121:832–9.
- 23 Argenta LC, Morykwas MJ, Marks MW, *et al.* Vacuum-assisted closure: state of clinic art. *Plast Reconstr Surg* 2006;117(7 Suppl):1275–42S.
- 24 Garner GB, Ware DN, Cocanour CS, *et al.* Vacuum-assisted wound closure provides early fascial reapproximation in trauma patients with open abdomens. *Am J Surg* 2001;182:630–8.
- 25 Miller PR, Meredith JW, Johnson JC, *et al.* Prospective evaluation of vacuum-assisted fascial closure after open abdomen: planned ventral hernia rate is substantially reduced. *Ann Surg* 2004;239:608–14; discussion 14–6.
- 26 Jernigan TW, Fabian TC, Croce MA, *et al.* Staged management of giant abdominal wall defects: acute and long-term results. *Ann Surg* 2003;238:349–55; discussion 355–7.
- 27 Bee TK, Croce MA, Magnotti LJ, *et al.* Temporary abdominal closure techniques: a prospective randomized trial comparing polyglactin 910 mesh and vacuum-assisted closure. *J Trauma* 2008;65:337–42; discussion 42–4.
- 28 Weinberg JA, George RL, Griffin RL, *et al.* Closing the open abdomen: improved success with Wittmann Patch staged abdominal closure. *J Trauma* 2008;65:345–8.
- 29 Ferguson E, Oswanski M, Stombaugh H, *et al.* Early definitive closure of abdomen using components separation technique after damage control surgery. *Am Surg* 2011;77:E74–75.
- 30 Nott D, Veen H, Matthew P. Damage control in the austere environment. *Bulletin R Coll Surg* 2014;96:82–3.

JRAMC

Management of complex abdominal wall defects associated with penetrating abdominal trauma

G Suren Arul, B J Sonka, J B Lundy, R F Rickard and S L A Jeffery

J R Army Med Corps published online May 9, 2014

Updated information and services can be found at:

<http://jramc.bmj.com/content/early/2014/05/09/jramc-2014-000276>

References

These include:

This article cites 28 articles, 4 of which you can access for free at:
<http://jramc.bmj.com/content/early/2014/05/09/jramc-2014-000276#BIBL>

Email alerting service

Receive free email alerts when new articles cite this article. Sign up in the box at the top right corner of the online article.

Notes

To request permissions go to:

<http://group.bmj.com/group/rights-licensing/permissions>

To order reprints go to:

<http://journals.bmj.com/cgi/reprintform>

To subscribe to BMJ go to:

<http://group.bmj.com/subscribe/>