

AWARD NUMBER: W81XWH-08-2-0162

Á
Á

TITLE: Clinical Utility and Pitfalls of Ultrasound Guided
Foreign Body Removal in War Fighters

Á

Á

PRINCIPAL INVESTIGATOR: William E. Shiels II, D.O.

Á

CONTRACTING ORGANIZATION: Nationwide Children's Hospital
Columbus, Ohio 43205

REPORT DATE: October 2013

Á
Á

TYPE OF REPORT: Annual

Á
Á

PREPARED FOR: U.S. Army Medical Research and Materiel Command
Fort Detrick, Maryland 21702-5012

Á

DISTRIBUTION STATEMENT:

~~Approved for public release; distribution unlimited~~

The views, opinions and/or findings contained in this report are those of the author(s) and should not be construed as an official Department of the Army position, policy or decision unless so designated by other documentation.

REPORT DOCUMENTATION PAGE

Form Approved
OMB No. 0704-0188

Public reporting burden for this collection of information is estimated to average 1 hour per response, including the time for reviewing instructions, searching existing data sources, gathering and maintaining the data needed, and completing and reviewing this collection of information. Send comments regarding this burden estimate or any other aspect of this collection of information, including suggestions for reducing this burden to Department of Defense, Washington Headquarters Services, Directorate for Information Operations and Reports (0704-0188), 1215 Jefferson Davis Highway, Suite 1204, Arlington, VA 22202-4302. Respondents should be aware that notwithstanding any other provision of law, no person shall be subject to any penalty for failing to comply with a collection of information if it does not display a currently valid OMB control number. **PLEASE DO NOT RETURN YOUR FORM TO THE ABOVE ADDRESS.**

1. REPORT DATE (DD-MM-YYYY) October 2013		2. REPORT TYPE Annual		3. DATES COVERED (From - To) 29 Sep 2012 - 28 Sep 2013	
4. TITLE AND SUBTITLE Clinical Utility and Pitfalls of Ultrasound Guided Foreign Body Removal in War Fighters				5a. CONTRACT NUMBER	
				5b. GRANT NUMBER W81XWH-08-2-0162	
				5c. PROGRAM ELEMENT NUMBER	
6. AUTHOR(S) William E. Shiels II, DO Go ckr'dgj Q cgwr vgb pcvkqpy kf gej kf tgpuQti				5d. PROJECT NUMBER	
				5e. TASK NUMBER	
				5f. WORK UNIT NUMBER	
7. PERFORMING ORGANIZATION NAME(S) AND ADDRESS(ES) Research Institute at Nationwide Children's Hospital Columbus, OH 43205-2662				8. PERFORMING ORGANIZATION REPORT NUMBER	
9. SPONSORING / MONITORING AGENCY NAME(S) AND ADDRESS(ES) U.S. Army Medical Research and Material Command Fort Detrick, Maryland 21702-5012				10. SPONSOR/MONITOR'S ACRONYM(S)	
				11. SPONSOR/MONITOR'S REPORT NUMBER(S)	
12. DISTRIBUTION / AVAILABILITY STATEMENT Approved for public release; distribution unlimited.					
13. SUPPLEMENTARY NOTES					
14. ABSTRACT Part 1 of the 3 part study was conducted on 13 May 2009 at Nationwide Children's Hospital. This was a cadaver cohort study with video comparison between radiologists with percutaneous USFBR, conventional surgical foreign body removal, and surgical foreign body removal with wire localization comparing incision size, time of procedure, wound closure (number of sutures), overall removal success and procedural differences. In this component, comparison data was collected using human cadaver thighs for testing differences between the surgical and percutaneous techniques. Part 1 was completed with success in year 1 using the tasks described in the approved SOW. The hypothesis for Part 1 was proven partially correct. The hypothesis was that ultrasound guided foreign body removal (USFBR) is faster and more effective than open surgical removal, with smaller incisions. The results found that USFBR is more effective than open surgical removal, with smaller incisions. However, the results also showed that the surgical method was faster. No progress was made in year 2 or year 3. A no cost extension (NCE) for future years 4, 5 and 6 were approved. No progress was made in year 4. Part 2 was approved and four of the Part 2 trainings occurred in year 5. One research training class was conducted at each of the participating MTFs (TAMC, BAMC, MAMC, and WRNMMC). A second training for each site has been scheduled for year 6. The continuing review has been submitted to NCH IRB. We are currently working on the continuing reviews for TAMC, BAMC, MAMC, and WRNMMC. Part 3 is still being reviewed by TAMC. Once approved we will submit site specific documents to each MTF for local IRB approval and deferral to TAMC IRB and final approval form ORP HRPO.					
15. SUBJECT TERMS					
16. SECURITY CLASSIFICATION OF:			17. LIMITATION OF ABSTRACT UU	18. NUMBER OF PAGES 26	19a. NAME OF RESPONSIBLE PERSON
a. REPORT U	b. ABSTRACT U	c. THIS PAGE U			19b. TELEPHONE NUMBER (include area code)

Table of Contents

	<u>Page</u>
Introduction.....	4
Body.....	4
Key Research Accomplishments.....	10
Reportable Outcomes.....	11
Conclusion.....	11
References.....	11
Appendices.....	12

Introduction:

This is a three part study: Part 1 is a cadaver cohort study with video comparison between radiologists with percutaneous ultrasound guided foreign body removal (USFBR), conventional surgical foreign body removal, and wire localization followed by surgical foreign body removal, comparing incision size, time of procedure, wound closure (number of sutures), overall removal success and procedural differences. Part 2 is an educational efficacy research project. The physicians are trained with a turkey breast simulator. They will be evaluated and measured on their performance and competency development with USFBR. Part 3 is a clinical implementation of USFBR in military health care setting as part of patient care of wounded war fighters with symptomatic soft tissue foreign bodies retained after blast injuries.

Body:

The original SOW and budget justification was approved 29 Sept 2008.

The unanticipated retirement of the part 2 PI, slowed down the submission process to the local IRB at USUHS. We worked in year 1 to change the PI but he later declined. The SOW and budget justification was revised and modification P00001 was approved by TATRC on 23Sept2011. The revisions included the change of PI for part 2, participating MTFs, as well as the location change from USUHS to NCH. A revised SOW was submitted to TATRC and approved for a no cost extension for years 4 and 5.

A second revised SOW and budget justification were submitted to TATRC and modification P00002 was approved by TATRC on 15 October 2012 which included changes in equipment supplies and new co-investigators at the participating MTFs. There we no changes in the study design.

A third revised SOW (v6 8Nov2012) and budget justification (v9 27Nov2012) were submitted to TATRC and modification P00003 was approved by TATRC on 21 Jan 2013 which included a no cost extension for year 6, the GOR from Dr. Peterson to Dr. Pacifico and budget revisions for travel. There we no changes in the study design.

A fourth revised SOW (v7 15Apr2013) was submitted which included revised version and date, corrected AI titles, updated estimates for actuals for year 4, added CPT Jeffery Meadows, MD, MC, USA as an AI at TAMC, removed CRD William R. Carter, MD, MC, USN and added CRD Frank E. Mullens, MD, MPH, MC, USN as the AI at WRNMMC because Dr. Carter left WRNMMC, revised supplies to more accurate estimates, added additional cabbage cases, added lunch and additional shipping equipment fees, changed travel budget to remove Dr. Murakami in year 5 travel and add TAMC staff to year 5, changed travel budget to include both Dr. Shiels and Dr. Murakami in year 6 and allow a TAMC AI to substitute travel if Dr. Murakami cannot attend, updated "other" category to reflect current left over amount that will be spent or returned to TATRC, updated indirects as necessary and corrected minor typos. There we no changes in the study design. The budget justification (v10 15Apr2013) which included revised version and date , corrected AI titles, clarification that the physicians as subjects in Part 2 and 3 are "DoD healthcare beneficiaries", added CPT Jeffery Meadows, MD, MC, USA as an AI at TAMC, removed

CRD William R. Carter, MD, MC, USN and added CRD Frank E. Mullens, MD, MPH, MC, USN as the AI at WRNMMC because Dr. Carter left WRNMMC, added staff to Part 3 that was left off of previous versions, clarified that there is not travel for Part 3 and corrected minor typos. Both the revised SOW and revise budget justification were submitted to TATRC and modification P00004 was approved by TATRC on 13 May 2013.

PART 1:

As previously reported in earlier annual reports, Part 1 of the 3 part study was conducted on 13 May 2009 at Nationwide Children's Hospital (NCH). All of part 1 was completed in year 1. This was a cadaver cohort study with video comparison between radiologists with percutaneous USFBR, conventional surgical foreign body removal, and surgical foreign body removal with wire localization comparing incision size, time of procedure, wound closure (number of sutures), overall removal success and procedural differences. In this component, comparison data was collected using human cadaver thighs for testing differences between the surgical and percutaneous techniques. Procedures were videotaped for a detailed analysis and accurate documentation of major and minor procedural differences. Statistical analysis projected 9 removals per procedures type would provide complete data sets for demonstration of statistical significance. Local IRB at NCH and secondary IRB approval through DOD ORP HRPO were obtained. Part 1 was completed with success in year 1 using the tasks described in the approved SOW.

The PI, William E. Shiels II, DO (Radiologist) implanted a total of 27 foreign bodies into human cadaver tissue. The anatomical materials used were human cadaver thighs. To remain consistent, all foreign bodies were the same. A 1 cm piece of a wooden toothpick was used to represent a traditional foreign body implanted in the cadaver tissue. Each cadaver thigh had 3 foreign bodies positioned into the tissue by Dr. Shiels. The study coordinator, Beth M. Haeuptle, MA timed, observed and documented the foreign body removals. Brad Hoehne (Graphic Animation Artist) had 2 digital video cameras on tripods documenting the procedures. He also hand held a high powered video camera which allowed for close up video to substantiate the findings. This same footage was used to develop future training materials in part 2 of the 3 part study. Dr. Shiels monitored the research efforts. Brian D. Kenney MD (surgeon) and James W. Murakami, MD (Radiologist) performing the foreign body removals; both physicians self-reported the start and end time, the incision size, number of sutures as well as the success or failure of the foreign body removal. This was done in conjunction with the written and video documentation for accuracy of findings.

Using a traditional surgical method following the skin marking of the foreign body location, Brian D. Kenney, MD completed 9 foreign body removals (3 in each thigh). The incision size for each removal ranged from 30mm – 58mm with a mean of 45.78 mm. The number of sutures ranged from 4 to 9 in order to effectively close the wound. The time to complete the procedure (skin to skin time) ranged from 4-15 minutes with a mean of 8.33 min.; 7 of the 9 removal attempts were successful. One foreign body was unable to be located by the surgeon. In a live situation the surgeon would send the 5 patient to Radiology for wire localization and then the surgeon would re-operate with the wire localization method or percutaneous ultrasound guided foreign body removal would be completed by a radiologist.

Dr. William E. Shiels II, DO used ultrasound guidance for placement of localization wires at the site of each of 9 foreign bodies (3 in each thigh). Brian D. Kenney, MD then used an operative method following the wire localization to remove the foreign bodies. The incision size for each removal ranged from 24mm – 39mm with a mean of 32.1 mm. The number of sutures ranged from 3 to 6 in order to effectively close the wound. The time to complete the procedure (skin to skin time) ranged from 4-12 minutes with a mean of 7.1 min.; 8 of the 9 removals were successful. One foreign body was unable to be located by the surgeon.

The third removal type was percutaneous interventional radiological ultrasound guided foreign body removal. The technique was performed by James W. Murakami, MD. He completed 9 foreign body removals (3 in each thigh). The incision size for each removal ranged from 5mm – 9mm with a mean of 6.4 mm. Sutures are not needed for this removal technique due to the minimal incision size. A Band-Aid placed over the wound is standard of care. The time to complete the procedure (skin to skin time) ranged from 3-26 minutes with a mean of 12.2 min.; all 9 percutaneous removals were successful.

There are no previously reported findings to compare to our data.

No publications or presentations have been submitted, to date, for this research.

Unforeseen technical issues with cadaver materials occurred with both the surgical and the radiological procedures. The surgeon, Brian D. Kenney, MD commented that operative removal was a much easier in a cadaver compared to a live human because operative sites were not complicated by bleeding. During a procedure with a live patient the surgeon would need to stop every few minutes to manage bleeding which would lengthen the procedure time. During his first removal he commented that “this is necessitating significant tissue destruction to find the foreign body”. Additionally, the surgeon felt that blunt dissection facilitated movement of the foreign bodies in the surgical field; the surgeon switched from a blunt dissection to a sharp dissection to alleviate the movement issue. Both the surgeon and the radiologist reported the remarkable amount of movement with the foreign body removal. The surgeon noted that the 3 foreign bodies implanted in the third thigh with the traditional surgical removal were placed in the subcutaneous fat and not the muscle which made locating the foreign body easier. The wooden toothpicks were colored which the surgeon commented helped when searching for the foreign bodies. This is an advantage to the surgical method in the cadaver because the radiological method does not use an open operative field in which to see the color of the toothpick to help with localization. Dr. Kenney also verbalized the learning process of following the fascial penetration site for his operative approach; he said that once he adapted to that technique then the process was simplified. Live human tissue with a foreign body and the time it takes to seek treatment would not leave such an easy hole to follow in order to locate the foreign body. This is seen as an advantage to the operative procedure in a cadaver. With respect to wire localization procedure, Dr. Kenney noted that wire localization made the removal process much easier. The key to success with this method was having an experienced interventional radiologist provide 6 proper placement of the localization wire. If someone other than an experienced radiologist placed the wire, the failure rate would most likely increase. The radiologist in this study, Dr. Murakami, has performed over 100 foreign body removal procedures on living patients and expressed that it is was very difficult working with cadaveric material. The mechanical (elastic) properties of the

cadaver tissue effect the percutaneous ultrasound guided foreign body removal, seeming to add a degree of difficulty to cadaveric removal not experienced in live humans.

The findings demonstrated that percutaneous ultrasound guided foreign body removal technique has much less tissue destruction as compared with operative techniques; the incision size is also much smaller with this technique. This would result in a faster healing time if the foreign body removal was performed in a live patient. Sutures are not needed in the radiological method. The success rate was 100% for the percutaneous ultrasound guided foreign body removal technique. Whereas the removal success rate for the traditional surgical method was 78% successful and the surgical with wire localization was 89% successful.

PART 2:

Part 2 of the 3 part study is the competency training, testing, and documentation of military physicians in USFBR techniques.

This phase of the research has formalized and standardized procedural training, with development of clinical guidelines for physicians. Competency testing and training will involve one day of didactic and hand-on training, with pre-test and post-test components. Physicians will undergo pre-testing with the removal of one wooden foreign body from a turkey breast that simulates the tissue of a human with documentation of procedural omissions and errors for removal success, time to removal, demonstration of technical component proficiency, and successful recognition/management of technical pitfalls. Didactic training will incorporate a slide presentation, and video animations. Hands-on tissue model mentored training will incorporate the subjects practicing removal of both wooden and metal foreign bodies from a turkey breast while the trainers teach them ways to improve their techniques using the content from the didactic lecture and video animations. The post-test will document competency in a tissue model (turkey breast) and document incorporation of standardized procedural steps in USFBR procedures with proper procedural steps and recognition/management of procedural pitfalls with the same grading as in the pre-test. Each physician will be required to successfully remove 5 wooden foreign bodies to demonstrate procedural proficiency. The training and testing will be videotaped for review later for accuracy and proper documentation success.

I. Standardized percutaneous USFBR training

1. Training 1

a. Pretest doctors

- i. Video demonstration of USFBR procedure
- ii. Hands-on pre-training
- iii. Written analysis of video documentation detailing the foreign body removal technique
 1. Time to removal
 2. Success/failure of removal attempt after 15 minutes
 3. Proper/errant alignment of insonation and instruments
 4. Proper/errant hand position and transducer position

5. Proper/errant use of forceps in field of operation
 6. Proper/errant stepwise foreign body definition
 7. Proper/errant forceps grasp of foreign body
 8. Recognition/lack thereof-volume averaging artifact
 9. Recognition/lack thereof-oblique crosscut artifact
- b. Phase one of standardized competency training of percutaneous ultrasound guided soft tissue foreign body removal
- i. Didactic classroom training (Powerpoint discussion with animations)
 1. Essentials of sonography-rationale and scientific basis
 - a. Contact scanning
 2. Sonographic foreign body characterization
 - a. Wood, metal, glass, plastic, stone/ceramic
 3. Standardized stepwise instruction in USFBR
 - a. Includes options for forceps position-vertical vs. horizontal
 - b. Forceps open vs. closed
 - c. Foreign body definition prior to removal
 - d. Blunt dissection vs. sharp dissection
 - e. Hydrodissection
 4. Options for instrumentation-forceps
 5. Clinical management following USFBR
 6. Pitfalls
 - a. Volume averaging artifact
 - b. Oblique crosscut artifact
 - c. Transducer angulation
 - d. Central foreign body grasp
 - e. Forceful foreign body grasp
 - f. Tissue grasp vs. clean foreign body grasp
 - ii. Hands on training-turkey breast tissue model with mentored training
 1. Physicians will perform USFBR
 - a. Mentored training with live removal of wood and metallic

- foreign bodies in tissue models.
- b. Train to proficiency
- c. Post test
 - i. Each physician removes 5 wood
 - ii. Video documentation of post-test
 - iii. Written analysis of video documentation detailing the foreign body removal technique
 - iv. Written analysis of video documentation detailing the foreign body removal technique
 - 1. Time to removal
 - 2. Success/failure of removal attempt after 15 minutes
 - 3. Proper/errant alignment of insonation and instruments
 - 4. Proper/errant hand position and transducer position
 - 5. Proper/errant use of forceps in field of operation
 - 6. Proper/errant stepwise foreign body definition
 - 7. Proper/errant forceps grasp of foreign body
 - 8. Recognition/lack thereof-volume averaging artifact
 - 9. Recognition/lack thereof-oblique crosscut artifact

The Part 2 protocol was approved by Nationwide Children's Hospital (NCH). BAMC, MAMC and WRNMMC entered into an IAIR to defer to TAMC IRB. The full study was submitted and reviewed by TAMC IRB as the lead site. Site specific documents were completed in IRBnet and each MTF's IRB reviewed the study approved and forwarded it to TAMC as the lead site and deferred for approval. The study received final approval from ORP HRPO.

The Part 2 training and testing component was held one time at each participating MTF (TAMC, BAMC, MAMC and WRNMMC) in year 5 and will be held one time at each MTF in year 6. Dr. Shiels, Dr. Murakami, Dr. Rooks or AI from TAMC will conduct the training and testing (and data collection). COL Rooks will serve as the PI at TAMC and assist with IRB approval as the lead site and in the recruitment of Army physicians at TAMC. The AIs at each MTF will assist in the recruitment at their MTF. Each session of Part 2 training will have 6 military physicians as subjects.

PART 3:

Part 3 is a clinical implementation study documenting USFBR procedural parameters such as time to removal, incision size, type of foreign body, fragmentation during removal, success for failure of removal attempt, blunt vs. sharp dissection, complications, technical pitfalls encountered, time to return to function, time of wound healing, and subjective patient evaluation of the experience. In part 3, clinical comparison will be made with similar parameters, as possible, with patients who have undergone traditional surgical fragment removal (chart review or documentation from patients undergoing both procedures). In this clinical component, the objective will be for symptomatic foreign bodies in soft tissues to be removed with USFBR, with referral always at the discretion of the primary physician.

Specific procedural objectives would include USFBR incisions to be no longer than either the width of the removal forceps or the width of the foreign body being removed. Local anesthesia, sedation, or general anesthesia determinations will be made by the radiologist/physician removing the foreign body. Expectations are for soft tissue foreign bodies to be successfully removed intact, with greater than 90% success. Complications are to be recorded, but expected complications should only include simple wound infections as the anticipated complication (less than 10% occurrence). Pain following USFBR should be little to none (less than 2 on a 10 point scale). Post-procedural care should be the same as for routine wound care management from a sutured or non-sutured wound. Sutures should be used if wounds are clean, larger than 5-6 mm in length, and if longer than 6 mm, best closed with suture as opposed to tissue adhesive. Infected wounds should be allowed to heal by secondary intention, without sutures. Implementation of USFBR care should be completed in at least 5 war fighters by month 12 in order to demonstrate successful implementation in at least one military MTF to meet milestone.

Part 3 data collection will be performed in year 6. Dr. Shiels and Nationwide Children's Hospital will be responsible for parallel clinical state-of-the-art procedural and care algorithm development using ultra-high resolution sonography, with linear, compact linear, phased array, and convex linear transducers.

The study for Part 3 has been submitted to TAMC and the requested revisions have been submitted. We are waiting for TAMC approval so we can submit for NCH approval and then submit the site specific documented to the other MTFs and ORP HRPO for final approval. COL Veronica J. Rooks, MD, MC will serve as the PI at Tripler Army Medical Center (TAMC). William E. Shiels II, DO will be the Co-PI for Part 3.

Key Research Accomplishments

Part 1 was completed with success in year 1 using the tasks described in the approved SOW.

Four of the eight Part 2 trainings were conducted in year 5 of the project. One training was held at each of the participating MTFs including TAMC on 29 Jan 2013, BAMC 10 May 2013, WRNMMC 14 June 2013 and MAMC 2 Jul 2013.

Part 3 has been submitted to TAMC and we are waiting for approval.

Reportable Outcomes

No manuscripts, abstracts, presentations or other reportable outcomes have resulted from this research at this time.

Conclusion

The hypothesis for part 1 was proven partially correct. The hypothesis was that ultrasound guided foreign body removal (USFBR) is faster and more effective than open surgical removal, with smaller incisions. The results found that USFBR is more effective than open surgical removal, with smaller incisions. However the results also showed that the surgical method was faster. The results could have been affected by taking into account the differences in live tissue versus the dead tissue used with the cadaver thigh in this study. During future work or another comparison between radiologists with percutaneous USFBR, conventional surgical foreign body removal, and surgical foreign body removal with wire localization some changes would be recommended. Natural colored wooden 11 toothpicks would be a better choice than colored toothpicks that are easy to see in the cadaver tissue. Live tissue would alleviate the movement of the foreign body; but there would be no way to conduct a study on live patients with standardized implanting foreign bodies. A study could be done with live patients with existing foreign bodies but then there would not be any controls. Live patients would also have blood to make the operative portions of the study more life-like; however a researcher would not ever subject a patient to undue trauma from a surgical method if the percutaneous ultrasound guided foreign body removal technique were available. The findings showed the percutaneous ultrasound guided foreign body removal technique to have much less tissue destruction than operative techniques; the incision size is also much smaller in this technique. This would result in a faster healing time if the foreign body removal was performed in a live patient. Sutures are not needed in the radiological method. The success rate was 100% for the percutaneous ultrasound guided foreign body removal technique; whereas, the success rate for traditional surgical method and surgical with wire localization were only 78% and 89% respectively. The knowledge gained from this research demonstrates that USFBR is a more effective and less traumatic method of removing foreign bodies and should be readily implemented into the military system by training military physicians in part 2 with a clinical implementation in part 3. There are no conclusions for Part 2 and Part 3 at this time.

References

Shiels WE II, Babcock DS, Wilson JL, Burch RA. Localization and Guided Removal of Soft-tissue Foreign Bodies with Sonography. *AJR* 1990; 155(6):1277-128.

Shiels II WE: Soft Tissue Foreign Bodies: Sonographic Diagnosis and Therapeutic Management. *Ultrasound Clinics*. October 2007. Vol. 2, Issue 2, 669-81.

Close JK, Shiels WE II, Foster JA, Powell DA: Percutaneous Ultrasound-guided Intraorbital Foreign Body Removal. *Ophthal Plast Reconstr Surg*. 2009 Jul-Aug; 25(4):335-7.

Appendices

APPENDICES:

Appendix 1: Foreign Body Removal Record Form

Appendix 2: Cadaver Cohort Study Data Spreadsheet

Appendix 3: Cadaver Cohort Comparison Study-Incision size

Appendix 4: Cadaver Cohort Comparison Study-Removal Time

Appendix 5: Cadaver Cohort Study – Wound Closure (Number of Sutures)

Appendix 6: Cadaver Cohort Study - Overall Success

APPENDIX 1

Foreign Body Removal Record Form

Date: _____

Surgical procedure

Removal technique: () Surgical - traditional surgical removal following skin marking of foreign body location

Cadaver thigh: () #1
FB location () #1 () #2 () #3

Cadaver thigh: () #2
FB location: () #1 () #2 () #3

Cadaver thigh: () #3
FB location: () #1 () #2 () #3

Surgical procedure

Removal technique: () Wire localization - surgical removal of the foreign bodies following ultrasound guided placement of localization wires at the site of each foreign body.

Cadaver thigh: () #4
FB location: () #1 () #2 () #3

Cadaver thigh: () #5
FB location: () #1 () #2 () #3

Cadaver thigh: () #6
FB location: () #1 () #2 () #3

Radiological procedure

Removal technique: () Percutaneous - interventional radiological ultrasound guided foreign body removal

Cadaver thigh: () #7
FB location: () #1 () #2 () #3

Cadaver thigh: () #8
FB location: () #1 () #2 () #3

Cadaver thigh: () #9
FB location: () #1 () #2 () #3

FB type: wood

Incision size (self report): _____

Incision size (video confirmation): _____

Time of procedure (self report): _____

Time of procedure (video confirmation): _____

Wound closure/number of sutures (self report): _____

Wound closure/number of sutures (video confirmation): _____

Overall removal success: (self report): _____

Overall removal success: (video confirmation): _____

Procedural differences as noted by study coordinator from documentation during procedure and review of video documentation: Notes: (see back of page)

APPENDIX 2

	Thigh #	Cadaver Specimen Information	Size of wooden FB (part of a toothpick) to be removed in cm	Incision size in mm	Overall removal success	Time determined that FB could not be located	(Self report & study coordinator observe) Time of procedure to remove FB w/o closure or stopped looking for FB	(Self report & study coordinator observe) Time of procedure to remove FB (w/ sutures) skin to skin time	# of sutures	Suture style
Surgical Procedure - traditional surgical removal following skin marking of foreign body location	S1	#5862 Female, 87 years old Cause of death: Alzheimer's	1	44	No	11	11	15	8	continuous
Surgical Procedure - traditional surgical removal following skin marking of foreign body location	S2	#5862 Female, 87 years old Cause of death: Alzheimer's	1	41	No	10	10	11	8	continuous
Surgical Procedure - traditional surgical removal following skin marking of foreign body location	S3	#5862 Female, 87 years old Cause of death: Alzheimer's	1	58	Yes		1	4	9	continuous

	Thigh #	Cadaver Specimen Information	Size of wooden FB (part of a toothpick) to be removed in cm	Incision size in mm	Overall removal success	Time determined that FB could not be located	(Self report & study coordinator observe) Time of procedure to remove FB w/o closure or stopped looking for FB	(Self report & study coordinator observe) Time of procedure to remove FB (w/ sutures) skin to skin time	# of sutures	Suture style
Surgical Procedure - traditional surgical removal following skin marking of foreign body location	S4		1	54	Yes	5	10	6	interrupted	
Surgical Procedure - traditional surgical removal following skin marking of foreign body location	S5		1	43	Yes	2	4	5	interrupted	
Surgical Procedure - traditional surgical removal following skin marking of foreign body location	S6		1	30	Yes	2	5	4	interrupted	

	Thigh #	Cadaver Specimen Information	Size of wooden FB (part of a toothpick) to be removed in cm	Incision size in mm	Overall removal success	Time determined that FB could not be located	(Self report & study coordinator observe) Time of procedure to remove FB w/o closure or stopped looking for FB	(Self report & study coordinator observe) Time of procedure to remove FB (w/ sutures) skin to skin time	# of sutures	Suture style
Surgical Procedure - traditional surgical removal following skin marking of foreign body location	S7		1	39	Yes		2	7	5	interrupted
Surgical Procedure - traditional surgical removal following skin marking of foreign body location	S8		1	58	Yes		5	11	6	interrupted
Surgical Procedure - traditional surgical removal following skin marking of foreign body location	S9		1	45	Yes		4	8	5	interrupted

	Thigh #	Cadaver Specimen Information	Size of wooden FB (part of a toothpick) to be removed in cm	Incision size in mm	Overall removal success	Time determined that FB could not be located	(Self report & study coordinator observe) Time of procedure to remove FB w/o closure or stopped looking for FB	(Self report & study coordinator observe) Time of procedure to remove FB (w/ sutures) skin to skin time	# of sutures	Suture style
Surgical Procedure - Wire localization - surgical removal of the foreign bodies following ultrasound guided placement of localization wires at the site of each foreign body	W1	#5849 right leg Male 91 years old Cause of death: Dementia & Heart Disease	1	30	Yes	3	8	4	interrupted	
Surgical Procedure - Wire localization - surgical removal of the foreign bodies following ultrasound guided placement of localization wires at the site of each foreign body	W2	#5849 right leg Male 91 years old Cause of death: Dementia & Heart Disease	1	25	Yes	1	4	3	interrupted	
Surgical Procedure - Wire localization - surgical removal of the foreign bodies following ultrasound guided placement of localization wires at the site of each foreign body	W3	#5849 right leg Male 91 years old Cause of death: Dementia & Heart Disease	1	24	Yes	3	6	3	interrupted	

	Thigh #	Cadaver Specimen Information	Size of wooden FB (part of a toothpick) to be removed in cm	Incision size in mm	Overall removal success	Time determined that FB could not be located	(Self report & study coordinator observe) Time of procedure to remove FB w/o closure or stopped looking for FB	(Self report & study coordinator observe) Time of procedure to remove FB (w/ sutures) skin to skin time	# of sutures	Suture style
Surgical Procedure - Wire localization - surgical removal of the foreign bodies following ultrasound guided placement of localization wires at the site of each foreign body	W4	#5849 left leg Male 91 years old Cause of death: Dementia & Heart Disease	1	30	Yes	4	7	5	interrupted	
Surgical Procedure - Wire localization - surgical removal of the foreign bodies following ultrasound guided placement of localization wires at the site of each foreign body	W5	#5849 left leg Male 91 years old Cause of death: Dementia & Heart Disease	1	39	No	8	8	12	6	interrupted
Surgical Procedure - Wire localization - surgical removal of the foreign bodies following ultrasound guided placement of localization wires at the site of each foreign body	W6	#5849 left leg Male 91 years old Cause of death: Dementia & Heart Disease	1	30	Yes	6	10	4	interrupted	

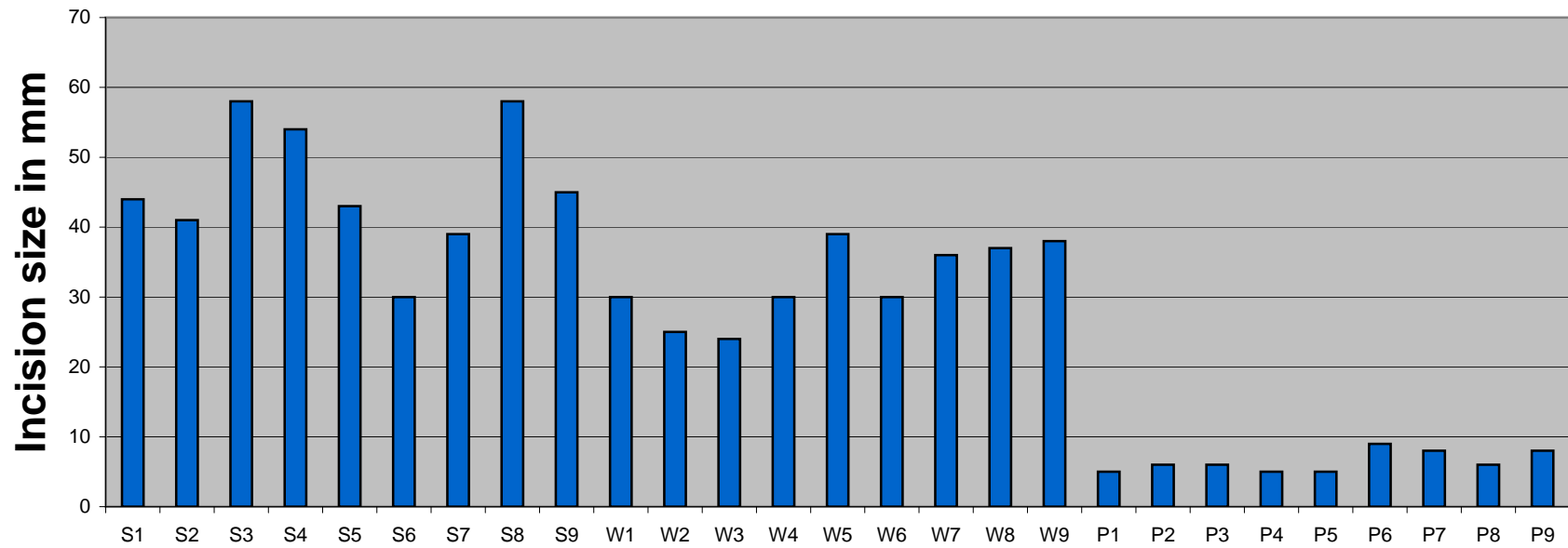
	Thigh #	Cadaver Specimen Information	Size of wooden FB (part of a toothpick) to be removed in cm	Incision size in mm	Overall removal success	Time determined that FB could not be located	(Self report & study coordinator observe) Time of procedure to remove FB w/o closure or stopped looking for FB	(Self report & study coordinator observe) Time of procedure to remove FB (w/ sutures) skin to skin time	# of sutures	Suture style
Surgical Procedure - Wire localization - surgical removal of the foreign bodies following ultrasound guided placement of localization wires at the site of each foreign body	W7	#5348 Male 81 years old Cause of death: Liver Disease	1	36	Yes	2	5	5	interrupted	
Surgical Procedure - Wire localization - surgical removal of the foreign bodies following ultrasound guided placement of localization wires at the site of each foreign body	W8	#5348 Male 81 years old Cause of death: Liver Disease	1	37	Yes	1	6	6	interrupted	
Surgical Procedure - Wire localization - surgical removal of the foreign bodies following ultrasound guided placement of localization wires at the site of each foreign body	W9	#5348 Male 81 years old Cause of death: Liver Disease	1	38	Yes	2	6	6	interrupted	

	Thigh #	Cadaver Specimen Information	Size of wooden FB (part of a toothpick) to be removed in cm	Incision size in mm	Overall removal success	Time determined that FB could not be located	(Self report & study coordinator observe) Time of procedure to remove FB w/o closure or stopped looking for FB	(Self report & study coordinator observe) Time of procedure to remove FB (w/ sutures) skin to skin time	# of sutures	Suture style
Radiological Procedure Removal Technique - Percutaneous - interventional radiological ultrasound guided foreign body removal	P1	#5862 Female Right leg 87 years old Cause of death: Alzheimer's	1	5	Yes		10	10	0	N/A
Radiological Procedure Removal Technique - Percutaneous - interventional radiological ultrasound guided foreign body removal	P2	#5862 Female Right leg 87 years old Cause of death: Alzheimer's	1	6	Yes		10	10	0	N/A
Radiological Procedure Removal Technique - Percutaneous - interventional radiological ultrasound guided foreign body removal	P3	#5862 Female Right leg 87 years old Cause of death: Alzheimer's	1	6	Yes		4	4	0	N/A

	Thigh #	Cadaver Specimen Information	Size of wooden FB (part of a toothpick) to be removed in cm	Incision size in mm	Overall removal success	Time determined that FB could not be located	(Self report & study coordinator observe) Time of procedure to remove FB w/o closure or stopped looking for FB	(Self report & study coordinator observe) Time of procedure to remove FB (w/ sutures) skin to skin time	# of sutures	Suture style
Radiological Procedure Removal Technique - Percutaneous - interventional radiological ultrasound guided foreign body removal	P4	#5861 Female Right leg 68 years old Cause of death: Huntington's Chorea	1	5	Yes		23	23	0	N/A
Radiological Procedure Removal Technique - Percutaneous - interventional radiological ultrasound guided foreign body removal	P5	#5861 Female Right leg 68 years old Cause of death: Huntington's Chorea	1	5	Yes		26	26	0	N/A
Radiological Procedure Removal Technique - Percutaneous - interventional radiological ultrasound guided foreign body removal	P6	#5861 Female Right leg 68 years old Cause of death: Huntington's Chorea	1	9	Yes		17	17	0	N/A

	Thigh #	Cadaver Specimen Information	Size of wooden FB (part of a toothpick) to be removed in cm	Incision size in mm	Overall removal success	Time determined that FB could not be located	(Self report & study coordinator observe) Time of procedure to remove FB w/o closure or stopped looking for FB	(Self report & study coordinator observe) Time of procedure to remove FB (w/ sutures) skin to skin time	# of sutures	Suture style
Radiological Procedure Removal Technique - Percutaneous - interventional radiological ultrasound guided foreign body removal	P7	#5861 Female Left leg 68 years old Cause of death: Huntington's Chorea	1	8	Yes		4	4	0	N/A
Radiological Procedure Removal Technique - Percutaneous - interventional radiological ultrasound guided foreign body removal	P8	#5861 Female Left leg 68 years old Cause of death: Huntington's Chorea	1	6	Yes		13	13	0	N/A
Radiological Procedure Removal Technique - Percutaneous - interventional radiological ultrasound guided foreign body removal	P9	#5861 Female Left leg 68 years old Cause of death: Huntington's Chorea	1	8	Yes		3	3	0	N/A

Cadaver Cohort Comparison Study



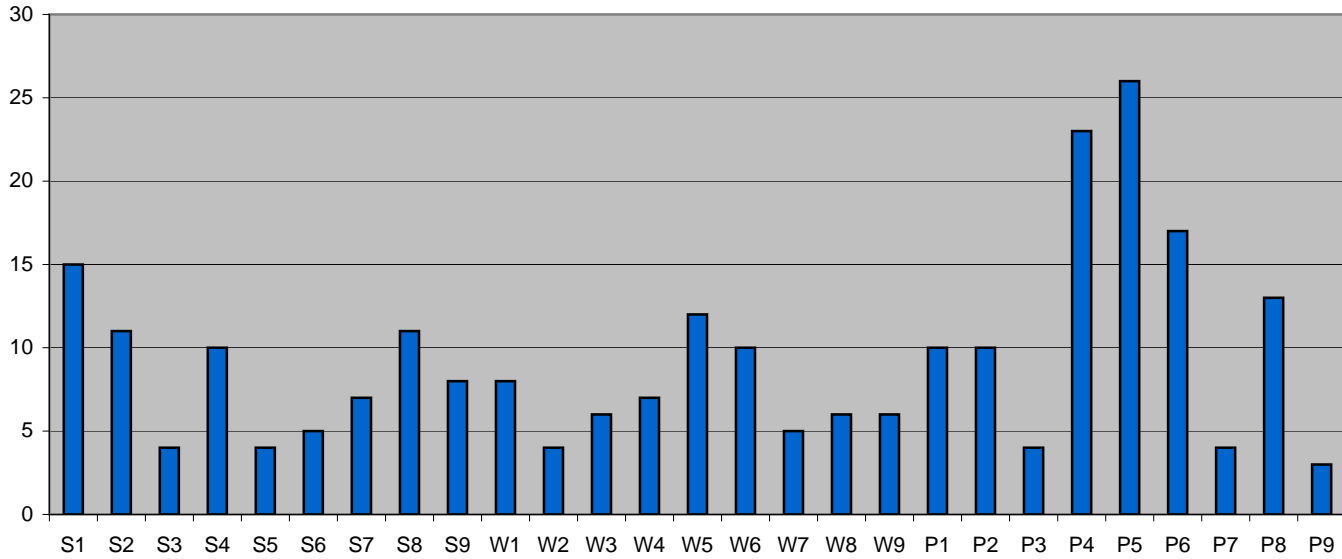
S=Traditional Surgical

W=Surgical with Wire Localization

P=Radiological/Percutaneous US

Cadaver Cohort Comparison Study

Time in Minutes to Remove Foreign Body

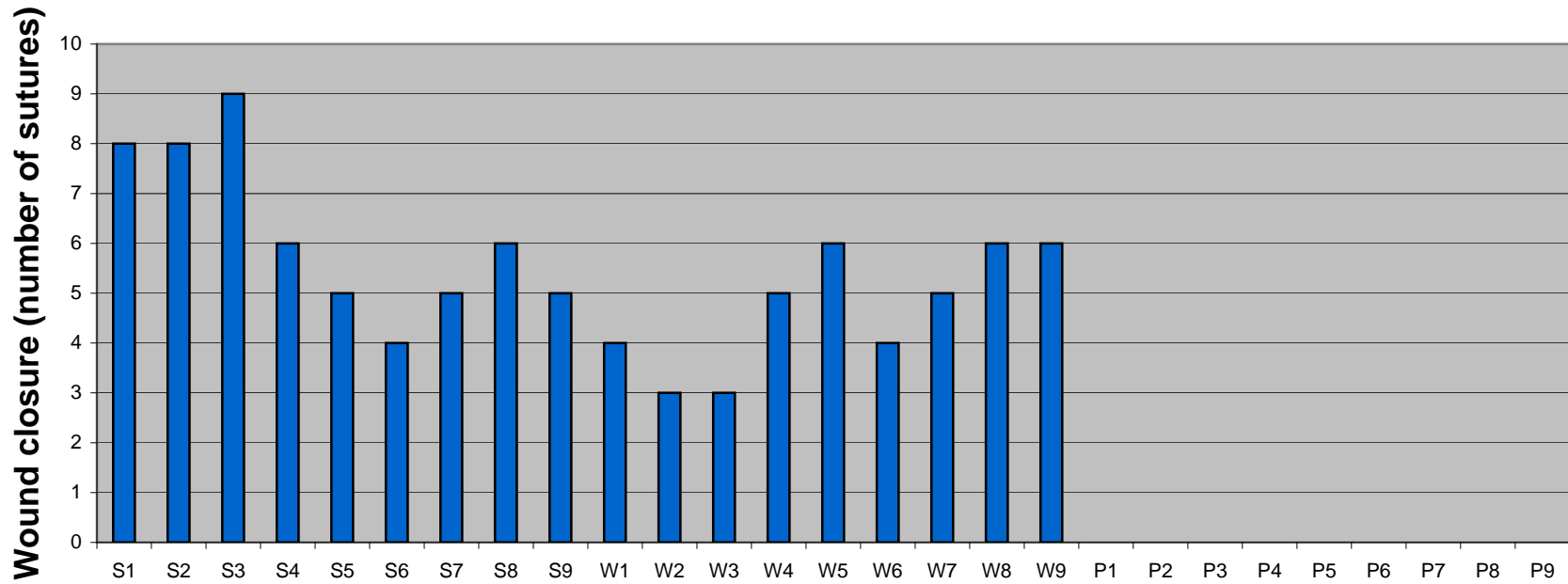


S = Traditional Surgical Procedure

S=Surgical Procedure with Wire Localization

P = Radiological Procedure - Percutaneous US

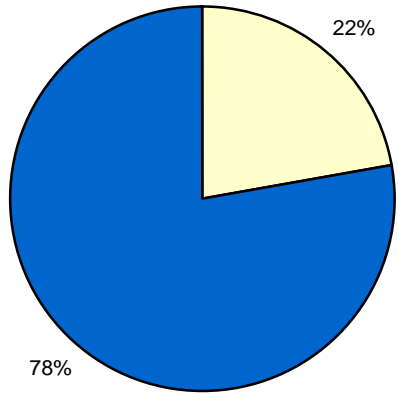
Cadaver Cohort Comparison Study



S=Traditional Surgical
W=Surgical with wire localization
P=Radiological/Percutaneous US

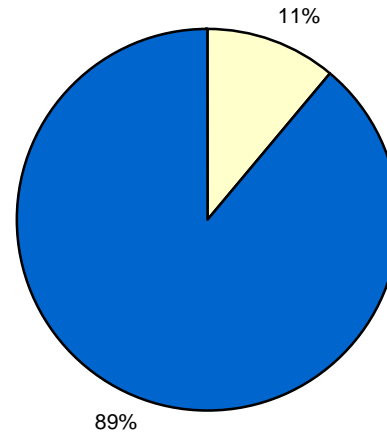
Cadaver Cohort Comparison Study

Traditional Surgical



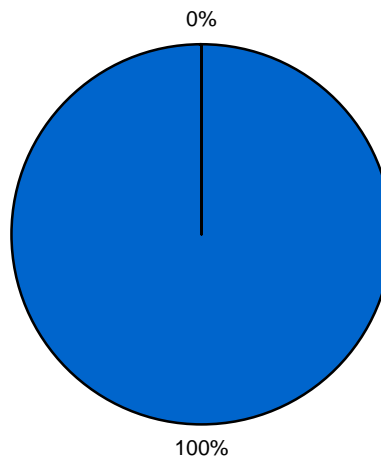
Failure Rate Success Rate

Surgical with Wire Localization



Failure Rate Success Rate

Radiological/Percutaneous US



Failure Rate Success Rate