

AD_____

Award Number: W81XWH-11-1-0145

TITLE: Nerve Degeneration and Regeneration Associated with NF1 Tumors

PRINCIPAL INVESTIGATOR: David F. Muir

CONTRACTING ORGANIZATION: University of Florida
Gainesville, FL 32611-5500

REPORT DATE: September 2014

TYPE OF REPORT: Final

PREPARED FOR: U.S. Army Medical Research and Materiel Command
Fort Detrick, Maryland 21702-5012

DISTRIBUTION STATEMENT: Approved for Public Release;
Distribution Unlimited

The views, opinions and/or findings contained in this report are those of the author(s) and should not be construed as an official Department of the Army position, policy or decision unless so designated by other documentation.

REPORT DOCUMENTATION PAGE

Form Approved
OMB No. 0704-0188

Public reporting burden for this collection of information is estimated to average 1 hour per response, including the time for reviewing instructions, searching existing data sources, gathering and maintaining the data needed, and completing and reviewing this collection of information. Send comments regarding this burden estimate or any other aspect of this collection of information, including suggestions for reducing this burden to Department of Defense, Washington Headquarters Services, Directorate for Information Operations and Reports (0704-0188), 1215 Jefferson Davis Highway, Suite 1204, Arlington, VA 22202-4302. Respondents should be aware that notwithstanding any other provision of law, no person shall be subject to any penalty for failing to comply with a collection of information if it does not display a currently valid OMB control number. **PLEASE DO NOT RETURN YOUR FORM TO THE ABOVE ADDRESS.**

1. REPORT DATE September 2014		2. REPORT TYPE Final		3. DATES COVERED 15 May 2011 - 14 May 2014	
4. TITLE AND SUBTITLE Nerve Degeneration and Regeneration Associated with NF1 Tumors				5a. CONTRACT NUMBER	
				5b. GRANT NUMBER W81XWH-11-1-0145	
				5c. PROGRAM ELEMENT NUMBER	
6. AUTHOR(S) David F. Muir Betty Diamond E-Mail: muir@ufl.edu				5d. PROJECT NUMBER	
				5e. TASK NUMBER	
				5f. WORK UNIT NUMBER	
7. PERFORMING ORGANIZATION NAME(S) AND ADDRESS(ES) University of Florida Gainesville, FL 32611-5500				8. PERFORMING ORGANIZATION REPORT NUMBER	
9. SPONSORING / MONITORING AGENCY NAME(S) AND ADDRESS(ES) U.S. Army Medical Research and Materiel Command Fort Detrick, Maryland 21702-5012				10. SPONSOR/MONITOR'S ACRONYM(S)	
				11. SPONSOR/MONITOR'S REPORT NUMBER(S)	
12. DISTRIBUTION / AVAILABILITY STATEMENT Approved for Public Release; Distribution Unlimited					
13. SUPPLEMENTARY NOTES					
14. ABSTRACT Infiltrating peripheral nerve sheath tumors (PNST) are associated with significant neurological deficits and nerve damage. An initial aim of this project is to determine how tumor progression leads to loss of nerve function. A second aim is to determine if nerve damage caused by PNST is reversible and the potential for nerve regeneration after PNST eradication. Additional aims will test photodynamic therapy as modality for eradication of PNST without incurring substantial collateral damage to functioning nerve. We have completed all aims in a highly conclusive manner. Our work tested that hypothesis that tumor-induced nerve damage and loss of neurological function is reversible. Findings indicate that this is true only in the formative stages of tumor growth associated with low-level functional deficits. Tumor progression leads to increasing and permanent loss of nerve function. Function deficits persist even after tumor eradication. Results indicate that the tumor destroys the nerve, ablates supporting cells and replaces nerve structure with an impenetrable fibrotic mass. Even though afflicted neurons remain viable they fail to regrow axons into the fibrotic mass (even when devoid of tumor cells). The main conclusion of our findings is that tumor eradication does not induce or support nerve regeneration. Instead, a fibrotic mass remains that must be resolved for axonal regrowth to occur. We conclude that early stage tumors (that incur low to moderate nerve damage) can be effectively killed by PDT with a good prognosis for recovery of the nerve function that was not initially compromised by tumor growth. However, PDT is not indicated for the treatment of advance PNST with substantial loss of nerve function. Instead, the PNST must be surgically resected and a nerve graft implanted to bridge the gap and restore nerve continuity.					
15. SUBJECT TERMS peripheral nerve sheath tumor, neurofibroma, photodynamic therapy, neurological deficit					
16. SECURITY CLASSIFICATION OF:			17. LIMITATION OF ABSTRACT	18. NUMBER OF PAGES	19a. NAME OF RESPONSIBLE PERSON
a. REPORT	b. ABSTRACT	c. THIS PAGE			19b. TELEPHONE NUMBER (include area code)
U	U	U	UU	13	USAMRMC

Table of Contents

	<u>Page</u>
Introduction.....	1
Body.....	2
Key Research Accomplishments.....	5
Reportable Outcomes.....	5
Conclusion.....	5
Supporting data.....	7

INTRODUCTION

Infiltrating peripheral nerve sheath tumors (PNST) are associated with significant neurological deficits and defy surgical removal without incurring further nerve damage. PNSTs often cause progressive demyelination, Schwann cell displacement and variable loss of supporting cells and axons within the tumor. An initial objective of this project is to determine how tumor progression leads to loss of nerve function. A second objective is to determine if nerve damage caused by infiltrating PNST is reversible and the potential for nerve regeneration after PNST eradication. Our studies will test the hypothesis that tumor-induced nerve damage and loss of neurological function is reversible. We will determine the potential for both spontaneous and experimentally induced nerve regeneration after tumor eradication. Photodynamic therapy (PDT) is a promising modality for the eradication of PNSTs. Our preliminary studies indicate that PDT effectively kills human NF1 tumor xenografts growing in mouse nerve. However, we found that highly tumoricidal PDT protocols targeted at normal nerves can cause significant nerve damage. Our preliminary studies show the neurological deficits incurred by PDT are transient and recovery of function occurs naturally in mice. We will test the hypothesis that PDT applied to infiltrating PNSTs can be highly tumoricidal without substantial permanent collateral damage to normal nerve.

BODY

OBJECTIVE 1: Determine the regenerative potential of nerves damaged by peripheral nerve sheath tumors.

Task 1: Examine PNST-induced damage to nerve: [months 1-6].

PROGRESS

Task 1 was completed (see Progress Report for Y1).

Task 2: Evaluate nerve regeneration after immunorejection of PNST: [months 3-12]

PROGRESS

Task 2 was completed (see Progress Report for Y1).

OBJECTIVE 2: Determine the mechanisms and pharmacodynamics of PDT induced nerve damage.

Task 1: Test various drug-light intervals in PDT applied to normal nerve and evaluate nerve damage: [months 12-16]

PROGRESS

Task 2 was completed (see Progress Report for Y2).

Task 2: Test various drug-light intervals in PDT applied to normal nerve and evaluate nerve regeneration: [months 14-20]

PROGRESS

After PDT there was a rapid and complete loss of sensory and motor functions mediated by the sciatic nerve. This aim tested if recovery of function and nerve regeneration is better or worse with different drug-light intervals. As found in Objective 2, Aim 1, all subjects showed immediate loss of sciatic nerve function with all drug-light intervals (see Progress Report for Y2). Function testing over a 12-week recovery period showed excellent recovery in all conditions (Table 1). The sciatic function index scores indicated that subjects in all groups recovered 84-101% and there were no statistical differences by ANOVA in the mean scores for function with the different drug-light intervals. Task 2 was completed.

OBJECTIVE 3: Determine the tumoricidal effects of LS11-PDT applied to intraneural tumor xenografts.

Task 1: Test various drug-light intervals in PDT applied to xenograft tumors and evaluate tumor kill: [months 20-24].

PROGRESS

This Aim determined the parameters for an effective PDT applied to infiltrating, intraneural PNST xenografts. Various drug-light intervals in LS11-PDT were tested on PNST xenografts. Three days after PDT, mice were terminated and tumors examined for extent and distribution of cell death by TUNEL staining. The goal of these tests was to determine the extent and distribution of tumor and normal neural cell death.

PDT was applied to tumors using the photosensitizer LS11 at 5 mg/kg and photoactivation by LED irradiation (664nm wavelength; 200 Joules/cm). Drug-light intervals of 0.5 and 6 hours were tested. At 6 weeks after tumor initiation we found tumor cells partial occupy nerve and observed the onset of nerve destruction by invading tumor (Fig. 1A). Tumors at this stage cause minor functional deficit of the nerve. PDT applied to 6-week tumors (that partially occupy the nerve) resulted in quantitatively complete tumor cell death (Fig. 1B). Similar results were obtained for drug-light intervals of 0.5 and 6 hours. TUNEL labeling showed the mean tumor cell death was 92% for a 0.5 hour drug-light interval and 94% for a 6 hour interval.

At 8 weeks or more after initiation tumors fully occupy the nerve around the site of injection and greatly expand the tissue structure. These tumors destroy and appear to consume all nerve elements resulting in a complete loss of nerve continuity and function (Fig. 2A). PDT applied to >8-week tumors (that fully occupy the nerve) resulted in high levels of tumor cell death with both 0.5 and 6 hour drug-light intervals (Fig. 2B). TUNEL labeling showed the mean tumor cell death was 89% for a 0.5 hour drug-light interval and 95% for a 6 hour interval. Taken together, these findings indicate that LS11-PDT, using short and long drug-light intervals, is highly effective for tumor cell kill within the nerve at various stages of tumor progression. Task 1 was completed.

Task 2: Determine the most tumoricidal mode of PDT, vascular versus cell targeting: [months 20-26].

PROGRESS

This Task determined if tumor and nerve cell death is attributed to vascular disruption or direct cellular phototoxicity. We anticipated that LS11-PDT, especially with a short drug-light interval, would cause vascular collapse and hemorrhage- leading to anoxic cell death. Instead, we observed a different kind of vascular disruption. LS11-PDT resulted primarily in vascular occlusion. This was evident by the clog of cells within blood vessels and little if any hemorrhaging (see Fig. 1A). Vascular occlusion was evident throughout the areas of normal nerve, tumor margin and tumor mass exposed to light and with both short and long drug-light intervals. Vascular occlusion also correlated well with the distribution of TUNEL-positive cells, further indicating that apoptotic cell death resulting from PDT primarily involved vascular occlusion and anoxia. We hypothesized that the blood-nerve vascular barrier would limit systematically administered LS11 from entering the inner compartment of normal nerve and thereby protect nerve fibers from PDT phototoxicity. Apparently this prospect of nerve protection was not realized because LS11 persisted within endothelium even at the longest drug-light interval, resulting in nerve cell death and axonal damage due to vascular occlusion. This was unexpected based on published pharmacodynamics stating that LS11 is largely cleared from endothelium 6 hours after administration. This data was not acquired for nerve tissue and perhaps the unique vasculature in the nervous system sequesters and retains LS11 more than the blood vessels in other organs. Task 2 was completed.

OBJECTIVE 4: Determine the regenerative potential of nerves after tumoricidal PDT treatment.

Task 1: Evaluate long-term regression of nerve sheath tumor xenografts after PDT: [months 26-36].

PROGRESS

This Task determined the long-term outcome of LS11-PDT on nerve sheath tumor xenografts. As stated previously, LS11-PDT caused extensive and nearly quantitative tumor cell death (see Fig. 2). TUNEL and total cell counting indicated that PDT caused at least 95% cell death throughout the tumors and, in most tissue fields scored all tumor cells were TUNEL-positive (100% cell death). After PDT, tumor expansion and nerve damage/loss of function was halted for several weeks. However, in all subjects tumor expansion was evident by 4 weeks after PDT. All mice reached termination criteria due to tumor enlargement 8 weeks after PDT. Therefore, we concluded that, despite excellent tumor cell kill, a single dose of LS-11 PDT was insufficient to prevent tumor recurrence in this mouse model. This outcome is not unexpected because the tumor xenografts are established using a highly aggressive and transformed tumor cell line. Also, the mouse host is immunodeficient thereby precluding naturally occurring synergistic immunological response (known to be part of the PDT effect in immunocompetent subjects). Nevertheless, this information was essential for our next Task to evaluate nerve regeneration after tumoricidal PDT. Task 1 was completed.

Task 2: Evaluate long-term effects of tumoricidal PDT on nerve regeneration and recovery of function: [months 26-36].

PROGRESS

This Task determined the extent of nerve regeneration and recovery of function after LS11-PDT was applied to intraneural PNST. We now know that in our PNST model tumor progression causes extensive nerve damage. As described in all previous Progress reports, the tumors destroyed nerve resulting in complete loss of function over time. Furthermore, we established a method to kill all tumor cells by immunorejection after bone marrow reconstitution in the immunodeficient scid mouse host (see Progress Report for Y1). Tumor eradication resulted in the formation of a dense, acellular fibrotic scar that prevented nerve regrowth into the region once occupied by tumor. The same observation was made after tumoricidal PDT. LS11-PDT caused extensive tumor cell death. However, the residual tumor tissue did not diminish significantly and soon became a dense fibrotic scar that prevented axonal regrowth into the region (Fig. 3). In no case did we observe recovery of function. As stated above, despite excellent tumor cell kill after PDT, the PNST eventually recurred. Therefore, we terminated a subset of animals 4 weeks after PDT (before substantial tumor regrowth). Again, there were no signs of axonal growth into the fibrotic tissue once occupied by tumor. Based on these corroborative findings we conclude that PNST irreversibly damages nerve tissue and, even after tumor eradication, the formation of a fibrotic tissue mass within the nerve prevents nerve cell infiltration and axonal regrowth. The inability of axons to regrow distally prevented target reinnervation and precluded recovery of function. This outcome indicates that LS11-PDT is not indicated for advanced PNST with substantial nerve damage and loss of function.

PNSTs are most often benign and rarely destroy nerve to the extent that all function is lost. More likely PNST will present in the clinic associated with only partial nerve damage, especially with early detection. In this case there will be symptoms of moderate neuropathy, indicating substantial intact and functioning nerve bundles. We also examined nerve regeneration after PDT was applied to PNSTs that only partially occupied nerve, a stage associated with minor functional deficits (see Progress Report for Y1). LS11-PDT resulted in extensive tumor cell death. As expected, PDT also caused nerve damage and complete loss of function. However, the PDT-induced nerve damage was reversible and allowed for nerve regeneration within the nerve bundles not damaged by tumor (see Fig 4.). Task 2 was completed.

KEY RESEARCH ACCOMPLISHMENTS

1. Determined that LS11-PDT is highly tumoricidal but tumor recurrence in our sciatic mouse model was inevitable with a single dose PDT.
2. Obtained evidence that LS11-PDT is not indicated for managing advanced PNST that also involves substantial loss of nerve function. When possible, the PNST should be surgically resected and a nerve graft implanted to bridge the gap and restore nerve continuity.
3. Demonstrated that early stage tumors (that incur low to moderate nerve damage) can be effectively killed by PDT with a good prognosis for recovery of the nerve function that was not initially compromised by tumor.

REPORTABLE OUTCOMES

1. Animal model for application of LS11-PDT for eradication of nerve tumors.
2. Fellowship from the Clinical and Translational Science Institute renewed for graduate student J. Graham.
3. Resubmitted a grant application to the Florida Biomedical Research Program in Cancer based on work supported by this award.

CONCLUSIONS

Our work tested that hypothesis that tumor-induced nerve damage and loss of neurological function is reversible. Findings indicate that this is true only in the formative stages of tumor growth associated with low-level functional deficits. Tumor progression leads to increasing and permanent loss of nerve function. Function deficits persist even after tumor eradication. Results indicate that the tumor destroys the nerve, ablates supporting cells and replaces nerve structure with an impenetrable fibrotic mass. We found that the neurons remain viable but fail to regrow axons into the fibrotic mass (even when devoid of tumor cells). This has several implications for managing PNST. Most often the treatment of PNST involves a "wait and see approach" when symptoms are minor and there is little loss of function. This approach is contraindicated by our findings. More disturbing is that substantial tumor damage to nerve may not be reversible even after effective tumor eradication. The main conclusion of our findings is that eradication of well-established tumors does not induce or support nerve regeneration.

LS11-PDT causes immediate nerve damage and loss of function. This outcome occurs at various drug-light intervals (1 to 6 hours). These results indicate that when using a highly tumoricidal dose of LS11 the drug-light interval is not a parameter for minimizing collateral nerve damage with PDT. However, results indicate that at various drug-light intervals PDT-induced nerve damage is reversible and recovery of function will occur without surgical intervention.

LS11-PDT effectively killed PNST cells growing in the mouse sciatic nerve. Nearly

complete tumor kill is achieved for tumors at various stages of progression. However, some PNST cells must survive a single dose PDT because tumor recurrence was consistently observed. Results indicate that early stage tumors (that incur low to moderate nerve damage) can be effectively killed by PDT with a good prognosis for recovery of the nerve function that was not initially compromised by tumor growth. LS11-PDT effectively kills advanced stages of PNST. Advanced PNST destroys the nerve region it occupies and creates a significant loss of nerve continuity. Therefore, PDT is not indicated for the treatment of advance PNST with substantial loss of nerve function. Instead, the PNST must be surgically resected and a nerve graft implanted to bridge the gap and restore nerve continuity.

SUPPORTING DATA

Table 1. Effects of various drug-light intervals on PDT induced nerve damage and recovery of function.

Drug-light interval	Vascular Occlusion	Axonal degeneration	Supportive cell death	Function deficit (% of normal)	Function recovery (% of normal)
1 hour	complete	widespread	92%	2%	94%
6 hours	complete	widespread	84%	4%	95%

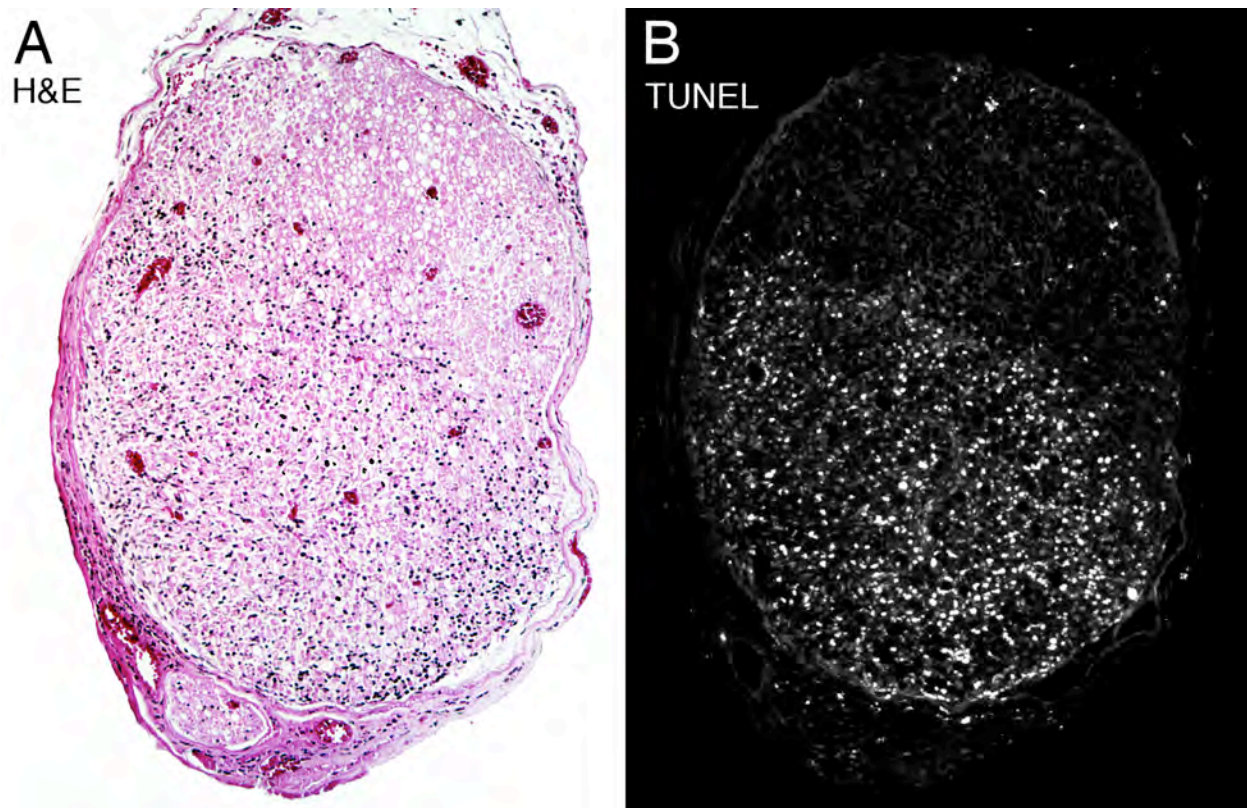
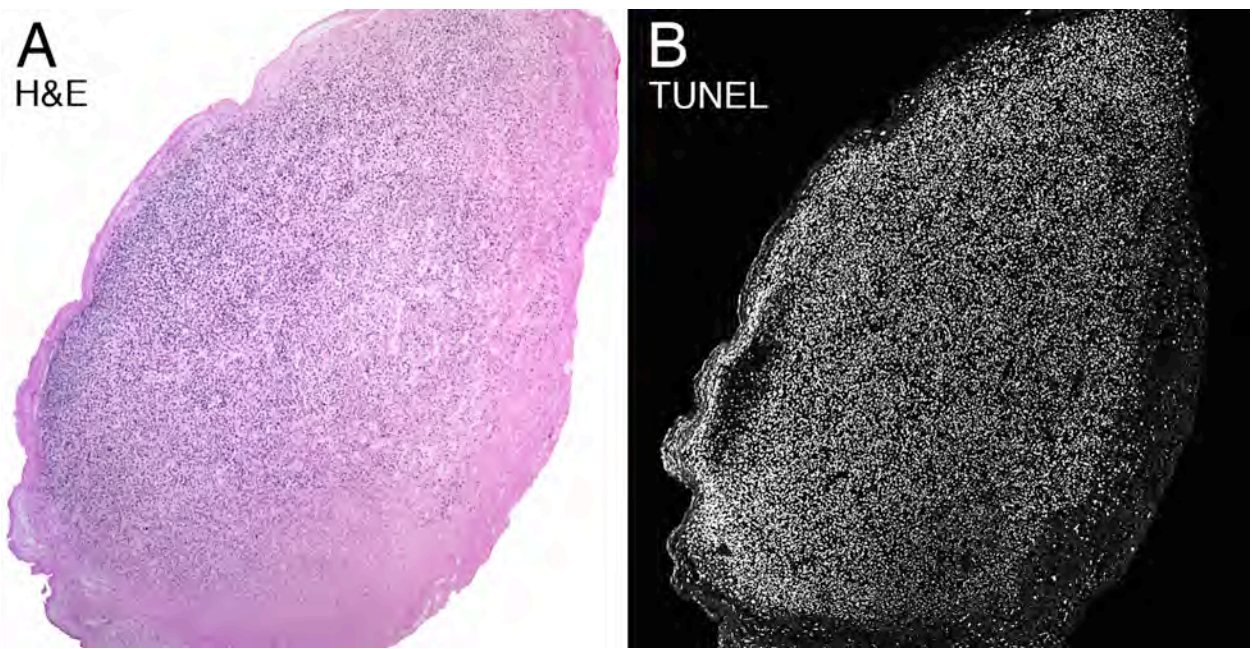
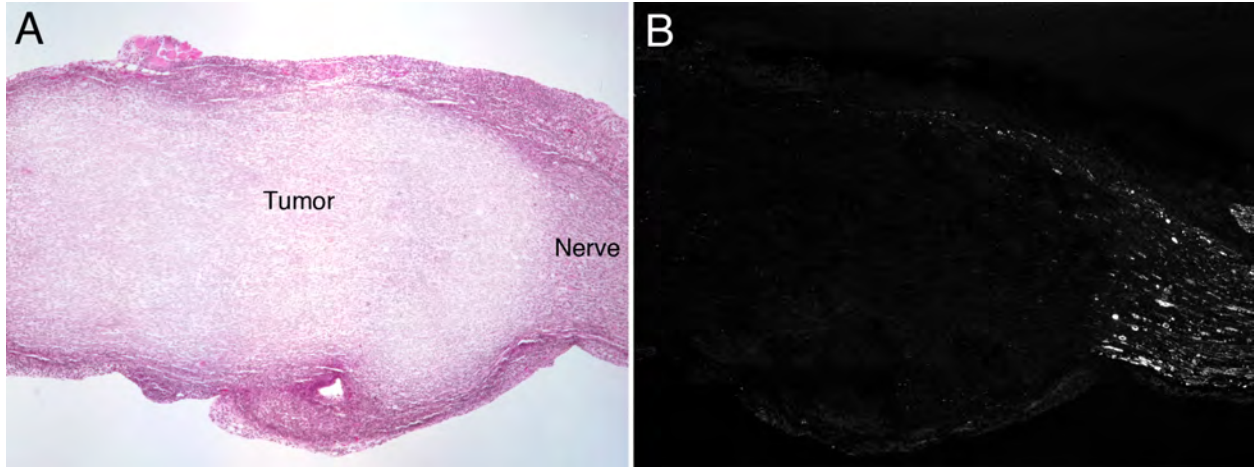


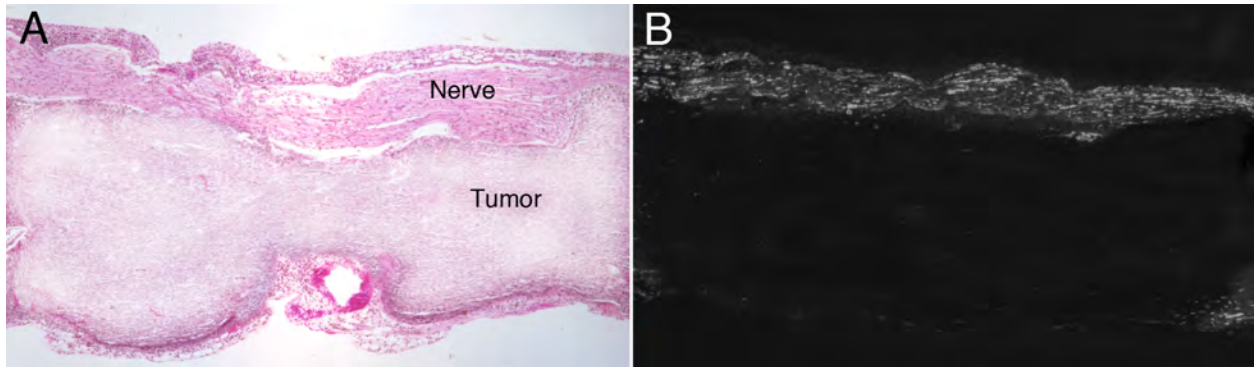
Fig. 1. Representative photomicrographs of early stage tumor xenografts in the sciatic nerves in mice after LS11-PDT. (A) H&E staining revealed tumor hypercellularity (cell nuclei appear blue) vascular disruption, hemorrhages (blood cells appear dark pink) and edema after PDT. (B) TUNEL staining for apoptotic cells (bright white) showed PDT caused extensive death of tumor and neural cells within the area of treated nerve.



□ **Fig. 2.** Representative photomicrographs of late stage tumor xenografts in the sciatic nerves in mice after LS11-PDT. (A) H&E staining revealed a large hypercellular tumor mass (cell nuclei appear blue) and the absence of all nerve elements and structure. The tumor is encapsulated by fibrotic tissue (pink). (B) TUNEL staining for apoptotic cells (bright white) showed PDT caused extensive death of tumor cells within the treated area.



□ **Fig. 3.** PDT applied to advanced PNST creates a barrier to nerve regeneration. A) PDT induced extensive PNST cell death. One month after PDT the tumor tissue became a fibrotic scar. The proximal nerve was recellularized and axons regrew to the region once occupied by tumor. Inflammatory cells encapsulated the treated tissue (H&E stain). B) Neurofilament immunolabeled axons regrew from the proximal nerve but stall at the fibrotic tissue once occupied by PNST.



□ **Fig. 4.** PDT applied to PNST that only occupies the nerve partially allows for regional nerve regeneration. A) PDT induced extensive PNST cell death as well as damaging the axons that were not previously destroyed by tumor. One month after PDT the tumor tissue became fibrotic and acellular. At the same time, the nerve was recellularized. B) Neurofilament immunolabeled axons regrew from the proximal nerve and traversed the PDT-induced lesion allowing nerve regeneration and reinnervation of distal target organs.

