

RESEARCH ARTICLE

Assessment of geographical variation in the respiratory toxicity of desert dust particles

Karen Taylor¹, Melanie L. Foster¹, J. McHugh Law¹, Jose A. Centeno², Elisa Fornero², M. Stephen Henderson¹, Sabrina A. Trager¹, Michael G. Stockelman³, and David C. Dorman¹¹Department of Molecular Biomedical Sciences, College of Veterinary Medicine, North Carolina State University, Raleigh, NC, USA, ²The Joint Pathology Center, Division of Biophysical Toxicology/Biophysical Toxicology Laboratory, Malcolm Grow Medical Clinic, Joint Base Andrews Naval Air Facility, MD, USA, and ³Center for Biomolecular Science and Engineering, Naval Research Laboratory, Washington, DC, USA

Abstract

The health consequences of sand particle inhalation are incompletely understood. This project evaluated the respiratory toxicity of sand particles collected at military bases near Fort Irwin USA, in Iraq (Camp Victory, Taji and Talil), and Khost Afghanistan. Our primary focus was on assessing the role of soluble metals in the respiratory toxicity of the sand particles using *in vitro* and *in vivo* methods. Replicating rat type II alveolar cell cultures (RLE-6TN) were exposed to sand extracts or vehicle control in serum-free media for ≤ 24 h. Cytotoxicity was determined using the 3-(4,5-dimethylthiazol-2-yl)-2,5-diphenyltetrazolium bromide assay and assessment of lactate dehydrogenase leakage. The relative *in vitro* cytotoxicity of the sand extracts was Taji \approx Talil $>$ Afghanistan $>$ Camp Victory \approx Fort Irwin. We also assessed extracts of Camp Victory, Afghanistan, and Taji sand for acute and delayed pulmonary toxicity in rats following intratracheal administration. Assessments included biochemical analysis of bronchoalveolar lavage fluid (BALF) and lung histopathology. The *in vitro* cytotoxicity assay results were partially predictive of *in vivo* responses. The more cytotoxic Taji sand extract induced an acute irritant response in rats following intratracheal administration. Rats given the less cytotoxic Camp Victory sand extract had minimal biochemical or cytological BALF changes whereas rats given either the Afghanistan or Taji sand extracts demonstrated BALF changes that were suggestive of mild lung inflammation. Unexpectedly, we observed similar lung pathology in all extract-exposed rats. The results of our study can be used to prioritize future particle inhalation studies or guide epidemiological study design.

Keywords

Cytotoxicity, dust inhalation, *in vitro*, *in vivo*, particle toxicity, pulmonary toxicity, rat

History

Received 19 March 2013
Revised 10 April 2013
Accepted 16 April 2013
Published online ■■■

Introduction

Airborne particulate matter (PM) has been linked to a range of serious respiratory and cardiovascular health problems. It is well recognized that lung deposition of a variety of PM sources can result in the generation of inflammatory cytokines and the subsequent development of lung injury (Dreher et al., 1997; Gavett et al., 1997; Kodavanti et al., 1999; Scapellato & Lotti, 2007). Epidemiological studies have provided information concerning PM sources and composition of potentially toxic particles with increased risk of strokes and other cardiovascular effects, chronic obstructive pulmonary disease, and other diseases with significant public health concern.

There is growing evidence that soluble metals found in PM may contribute to lung injury (Adamson et al., 1999; Chen & Lippmann, 2009). For example, vanadium, nickel and iron are the causative constituents of residual oil fly ash

(ROFA)-induced acute and, probably, prolonged lung injury (Dreher et al., 1997; Gavett et al., 1997; Kodavanti et al., 1999). Thus, metals either singly or in combination may induce different effects on the respiratory tract. Differences in response may reflect metal-activated formation of reactive oxygen species, anti-oxidant interactions with metal ions, differences in the bioavailability and clearance of metals, and other host factors (Goodman et al., 2011; Kovacic & Somanathan, 2009; Li et al., 2008; Mazzoli-Rocha et al., 2010; Tao et al., 2003).

An important PM source is re-suspended crustal dust and soil, especially in deserts and other dry and windy environments. A large number of US and coalition forces troops (~ 100 K) have been deployed to Iraq and Afghanistan where sand and dust storms are a frequent occurrence, especially during the spring and summer months. Airborne particulate levels (as PM₁₀; i.e. particle size $< 10 \mu\text{m}$) in such regions can exceed $10\,000 \mu\text{g}/\text{m}^3$, significantly higher than the $150 \mu\text{g}/\text{m}^3$ threshold set for a 24-h period by either the Military Exposure Guideline (Engelbrecht et al., 2009; see <http://phc.amedd.army.mil/PHC%20Resource%20Library/TG230.pdf>) or National Ambient Air Quality Standard.

Address for correspondence: David C. Dorman, DVM, PhD, North Carolina State University, College of Veterinary Medicine, 4700 Hillsborough Street, Raleigh, NC 27606, USA. E-mail: david_dorman@ncsu.edu

Report Documentation Page

Form Approved
OMB No. 0704-0188

Public reporting burden for the collection of information is estimated to average 1 hour per response, including the time for reviewing instructions, searching existing data sources, gathering and maintaining the data needed, and completing and reviewing the collection of information. Send comments regarding this burden estimate or any other aspect of this collection of information, including suggestions for reducing this burden, to Washington Headquarters Services, Directorate for Information Operations and Reports, 1215 Jefferson Davis Highway, Suite 1204, Arlington VA 22202-4302. Respondents should be aware that notwithstanding any other provision of law, no person shall be subject to a penalty for failing to comply with a collection of information if it does not display a currently valid OMB control number.

1. REPORT DATE 2013		2. REPORT TYPE		3. DATES COVERED 00-00-2013 to 00-00-2013	
4. TITLE AND SUBTITLE Assessment of geographical variation in the respiratory toxicity of desert dust particles				5a. CONTRACT NUMBER	
				5b. GRANT NUMBER	
				5c. PROGRAM ELEMENT NUMBER	
6. AUTHOR(S)				5d. PROJECT NUMBER	
				5e. TASK NUMBER	
				5f. WORK UNIT NUMBER	
7. PERFORMING ORGANIZATION NAME(S) AND ADDRESS(ES) The Joint Pathology Center, Division of Biophysical Toxicology/,Biophysical Toxicology Laboratory,Malcolm Grow Medical ,Clinic, Joint Base Andrews Naval,Air Facility,MD,20762				8. PERFORMING ORGANIZATION REPORT NUMBER	
9. SPONSORING/MONITORING AGENCY NAME(S) AND ADDRESS(ES)				10. SPONSOR/MONITOR'S ACRONYM(S)	
				11. SPONSOR/MONITOR'S REPORT NUMBER(S)	
12. DISTRIBUTION/AVAILABILITY STATEMENT Approved for public release; distribution unlimited					
13. SUPPLEMENTARY NOTES Inhal Toxicol, 2013; 25(7): 405-416					
14. ABSTRACT					
15. SUBJECT TERMS					
16. SECURITY CLASSIFICATION OF:			17. LIMITATION OF ABSTRACT Same as Report (SAR)	18. NUMBER OF PAGES 13	19a. NAME OF RESPONSIBLE PERSON
a. REPORT unclassified	b. ABSTRACT unclassified	c. THIS PAGE unclassified			

Inhalation of sand dust has been associated with a variety of adverse health effects. Several epidemiological studies report that respiratory symptom reporting is increased in troops during deployment to the Middle East (Perdue et al., 1992; Richards et al., 1993; Smith et al., 2009). Desert inhabitants can also develop Desert Lung Syndrome, a rare non-progressive non-occupational dust pneumoconiosis associated with silica-containing dust depositing in the lungs (Bar-Ziv & Goldberg, 1974). This syndrome generally develops after years of heavy exposure to sand particles (Nouh, 1989). An acute desert-related lung disease described as Desert Storm pneumonitis was found to occur following inhalation of fine Saudi dust and pigeon droppings (Korenyi-Both et al., 1992, 1997). Sporadic cases of severe acute eosinophilic pneumonitis with unknown etiology have also been reported among several US military personnel deployed to Southwest Asia (Shorr et al., 2004). Asian sand dust exposure is associated with increased daily mortality in Seoul, Korea, and Taipei, Taiwan (Kwon et al., 2002) and cardiovascular and respiratory dysfunction in Taipei (Bell et al., 2008). Experimental studies to further confirm these epidemiological results are needed.

There has been a paucity of experimental studies evaluating the respiratory toxicity of Middle Eastern sands. Wilfong et al. (2011) reported on the respiratory toxicity of Kuwaiti sand in male Sprague-Dawley rats following a single intratracheal (IT) instillation of 1, 5 or 10 mg of the sand (as PM₁₀). Johnson et al. (2007) reported that young male Sprague-Dawley rats given a single IT high dose of saline-suspended Iraqi sand (up to 15 mg/kg body weight) developed alveolitis, alveolar hyperplasia, pneumonitis and eosinophilic infiltration in the lungs by 3–7 days after particle instillation. Our laboratory recently reported the results of an inhalation study in which male rats were exposed to dust materials collected at Camp Victory a military base near Baghdad, Iraq, purified silica, or air (Dorman et al., 2012). This experiment used pre-exposure to mainstream cigarette smoke to induce lung pathology prior to Iraqi sand or silica exposure. Dorman et al. (2012) found that rats exposed to sand from Camp Victory developed only mild inflammation in the anterior nose and lung. This effect was not potentiated by pre-exposure to cigarette smoke. The chemical composition of Middle Eastern sand can vary among different geographical locations (Lyles et al., 2011). To our knowledge, studies evaluating the relative toxicity of sand particles from different geographic regions have not been completed. The overarching goal of this project is to further characterize the relative hazard associated with exposure to soluble aqueous extracts of sand samples collected from US military bases in the Middle East.

Materials and methods

Cell culture materials

Tissue culture media and reagents were obtained from Sigma-Aldrich (St. Louis, MO) with the following exceptions: trypsin–EDTA, fetal bovine serum, penicillin/streptomycin solution were obtained from American Type Culture Collection (Gaithersburg, MD) and epidermal growth factor was obtained from Invitrogen (Life Technologies, Grand Island, NY).

Surface sand samples

Surface sand samples were collected for the Naval Health Research Center Detachment Environmental Health Effects Laboratory by military personnel under the guidance of US Army Public Health Command. Sand samples were collected from military facilities located at Fort Irwin (CA), Camp Victory (Iraq), Camp Taji (Iraq), Talil Air Base (Iraq) and Khost (Afghanistan). Two sand samples were collected at Camp Taji – one was a tan-colored fine particulate sand sample (Location 1) while the other was a darker fine particulate sand material (Location 2). Sand samples collected in Afghanistan were provided after some *in vitro* studies began; therefore, a more limited set of *in vitro* experiments was performed with this material. The surface dust was collected in an area no larger than 15.24 m × 15.24 m, and sampling was confined to local soil containing no fill material, rocks, or stained or contaminated soil. Samples were then transferred to plastic zip top bags for transportation. The sand samples were irradiated at the Armed Forces Radiobiology Research Institute (Bethesda, MD), using a Cobalt-60 (⁶⁰Co) source for 4 h to eliminate microbiological flora. The sand was sieved to remove pebbles, twigs, and other large objects.

Preparation of sand extracts

A 50% (w/v) extract of sand was prepared by weighing 10 g of the sand/dust sample into a sterile centrifuge tube, adding 10 mL of either serum-free media (*in vitro* studies) or Dulbecco's phosphate-buffered saline (PBS) (instillation studies) and placing the suspension on a vigorous orbital shaker overnight at room temperature. The resulting liquid was filtered through a 0.2 μm cellulose acetate filter (Nalgene, Thermo Fisher Scientific, Rochester, NY) and stored at 4 °C prior to use. All treatments used sand-extract samples that were warmed to ~20 °C (instillation studies) or 37 °C (*in vitro* studies) prior to exposure. Control cells or animals were given vehicle (serum-free media or saline) only. Representative samples of the sand extracts were used for high-resolution inductively coupled plasma-mass spectrometry (HR-ICP-MS) analysis of the inorganic component of the sand extract using previously described methods (Dorman et al., 2012). Representative samples of the sand extracts were also analyzed for endotoxin content by a kinetic chromogenic limulus amoebocyte lysate (LAL) assay (Lonza, Walkersville, MD).

In vitro procedures

RLE-6TN rat lung epithelial cells derived from alveolar type II cells obtained from American Type Culture Collection (Manassas, VA) were cultivated at 37 °C in a humidified atmosphere with 5% (v/v) CO₂ and held in Ham's F-12 supplemented with (final concentrations) 10% (v/v) fetal bovine serum, 2 mM L-glutamine, 25 mM 4-(2-hydroxyethyl)-1-piperazineethanesulfonic acid, 1.176 mg/mL sodium bicarbonate, 10 μg/mL bovine pituitary extract, 5 μg/mL insulin, 2.5 ng/mL insulin-like growth factor, 25 μg/mL transferrin, 2.5 ng/mL epidermal growth factor and 0.5% penicillin/streptomycin. For experiments, cells were trypsinized at near confluency, seeded into 24-well tissue culture plates and grown until near confluency. Prior to extract exposure, the

cells were rinsed with serum-free media and 250 μ L of the sand extract were added. For MTT and protein assays, cell monolayers were rinsed with serum-free media immediately after the end of the treatments. This was done to remove the sand extract, detached (dead) cells and cell debris. Cell cultures were exposed for up to 24 h before the impact on cell metabolism was evaluated using an MTT [3-(4,5-dimethylthiazol-2-yl)-2,5-diphenyltetrazolium bromide] assay. This tetrazolium salt is cleaved to formazan by the succinate-tetrazolium reductase system in active mitochondria and correlates with the metabolic activity of the cells. Fifty microliters of MTT solution were added to 250 μ L of serum-free medium in each well, and the plate was then incubated at 37 °C for 4 h. The solution was removed, and 200 μ L of 0.04 N hydrochloric acid in isopropanol was added to each well to dissolve the crystalline formazan product. Absorbance was measured at 570 nm on a multi-well plate reader (μ Quant, Bio-Tek Instruments, Winooski, VT). Leakage of the cytosolic enzyme, lactate dehydrogenase (LDH), into the culture medium was determined using a commercially available assay kit (Sigma-Aldrich, St. Louis, MO). Aliquots (75 μ L) of medium were removed at the end of the incubation, and LDH activity was quantitated using absorbance at 490 nm (μ Quant, Bio-Tek Instruments, Winooski, VT). Intracellular LDH activity was determined at the end of the incubations after solubilization of the cells with 5% Triton X-100 for 5 min at room temperature. Leakage of LDH was expressed as a portion of total activity.

Limited *in vitro* studies were also performed to assess morphological changes in RLE-6TN rat lung epithelial cells following exposure to more toxic sand extracts (as assessed using the MTT assay). For electron microscopy studies, RLE-6TN cells were grown in confluent monolayers in T-75 tissue culture flasks at 37 °C, 5% CO₂. Exposures were conducted by rinsing the cells with serum-free media to remove residual serum proteins, then adding 15 mL of serum-free media or the Talil extract to the control or treated flasks, respectively. Cells were incubated at 37 °C during exposure. After ~3 h of exposure, images were taken of the cells on a Nikon 2000S inverted photomicroscope (Melville, NY) using Hoffman interference contrast. Cells were returned to the incubator until a 4-h exposure was completed. Cells were scraped from the flask and pelleted by centrifuging at 250g for 3 min to remove the media. Cells were re-suspended in modified McDowell's and Trump's 4F:1G fixative and refrigerated overnight. Samples were rinsed three times in 0.1 M Sorensen's phosphate buffer, suspended in 3–4% agar, and re-centrifuged as described above (Dykstra, 1993). After the agar had solidified, the cell pellets were cut into pieces no thicker than 1 mm. The pellet sections were post-fixed with 1% osmium in 0.1 M phosphate buffer for 1 h at room temperature. Samples were rinsed twice with distilled water and dehydrated in an ethanolic series ending with two changes of 100% acetone. Tissues were then placed in a mixture of Spurr resin and acetone (1:1) for 30 min, followed by 2 h in 100% resin with two changes. Samples were placed in molds in fresh 100% resin and polymerized at 70 °C overnight. Semi-thin (0.5 μ m) sections were cut with glass knives and stained with 1% toluidine blue-O in 1% sodium borate. Ultrathin (90 nm) sections were cut with a glass knife,

stained with methanolic uranyl acetate followed by lead citrate and examined with an FEI Philips EM208S Transmission Electron Microscope (Hillsboro, OR).

Animals

The experiments reported herein were conducted in compliance with the Animal Welfare Act and in accordance with the principles set forth in the Guide for the Care and Use of Laboratory Animals (National Academies of Sciences, 1996). *In vivo* studies were performed at North Carolina State University (NCSU) in a facility accredited by the Association for the Assessment and Accreditation of Laboratory Animal Care (AAALAC, International), the Institutional Animal Care and Use Committees at NCSU and the Naval Health Research Center.

Detachment Environmental Health Effects Laboratory approved all experimental protocols. One hundred and sixty male Crl:CD(SD) rats were obtained from a commercial breeder (Charles River Laboratories, Raleigh, NC), weighed on arrival and allowed to acclimate for 2 weeks. The rats were 10 weeks old and 300–320 g on arrival. Rats were randomized by entry weight, uniquely identified by ear tag and assigned one of four treatment groups ($n = 8$ rats/group): PBS Control, Camp Victory, Taji (Location 1) and Afghanistan. Rats were euthanized and samples collected at five time-points; 8, 24 and 72 h, 2 and 4 weeks after dosing. Shipments of rats were staggered to ensure rats were of comparable age at dosing. Rats were pair housed in standard rat microisolator cages on cellulose bedding (ALPHA-DRI, Shepherd Specialty Papers, Creedmoor, NC), were fed a standard rodent block *ad libitum* (Purina Laboratory Rodent Diet 5001, Kalamazoo, MI) and were provided municipal tap water (Raleigh, NC) from water bottles. Each cage of rats was provided enrichment *manipulada* (Nylabone, Neptune, NJ). The light cycle was 12:12, the room temperature ranged from 18 to 25 °C, and relative humidity 30–70%.

IT instillation of sand extracts

Rats were weighed the morning of dosing and transported to an approved research surgical facility. Individual rats were placed in an anesthesia induction chamber (Braintree Scientific, Inc., Braintree, MA) with 2–3 L/min of oxygen run through a precision vaporizer using isoflurane (Butler Schein Company, Dublin, OH) set at a delivery rate of 4–5% until the animal lost righting reflex (~3–4 min). The rat was removed from the chamber and placed on a rodent work stand (Braintree Scientific, Inc., Braintree, MA) suspended by its upper incisors. An operating otoscope fitted with a modified speculum was used to visualize the larynx and a 3.5 French, 5.5" open-ended tom cat catheter (Kendall/Covidien, Mansfield, MA) was advanced through the laryngeal folds to the carina based on external landmarks. If an animal began to react, the animal was either returned to the chamber or a nose cone was used to administer additional anesthetic gas. A 1 mL syringe was attached to the catheter and 0.5 mL of test article was delivered to the rat lungs followed by a sufficient amount of air to clear the catheter and administer the full dose. Rats were placed in an empty cage with paper toweling to recover from anesthesia (maintaining sternal recumbency and making

purposeful forward motion) which took ~2–5 min. When all rats were dosed and recovered from anesthesia, they were returned to their housing room and water bottles returned. Rats were observed daily by the research staff for 5 days after the procedure to document clinical abnormalities.

Bronchoalveolar lavage fluid and lung tissue collection

The right lung lobes were tied off at the level of the right bronchus and the left lobes flushed. A 14 gauge, 3.2 mm catheter was advanced into the trachea to the level of the carina. Five aliquots of 3 mL of PBS were used to flush the left lung lobes. Each 3 mL aliquot was injected, withdrawn, re-injected, withdrawn and placed in sample collection tubes. Following bronchoalveolar lavage fluid (BALF) collection, the right lung lobes were severed away from the trachea, placed in tubes, flash frozen in liquid nitrogen, and saved for future analysis. The left lobes were insufflated with 10% neutral buffered formalin (NBF), tied off at the trachea and placed in containers of NBF for histopathology. Lungs were trimmed, routinely processed, embedded in paraffin, sectioned at 3 μ m, and stained with hematoxylin and eosin. During the light microscope examination, histopathologic diagnoses for tissues of each animal were recorded. Most microscopic findings were graded using a subjective grading scale [P = present (non-gradable), 1 = minimal, 2 = slight/mild, 3 = moderate, 4 = moderately severe, 5 = severe/high]. A board-certified veterinary pathologist evaluated all tissues.

The first and second BAL washes were pooled, volume estimated, and visibly examined for the presence of blood. The sample was vortexed and then centrifuged at 200 g, 4 °C, for 10 min. Five 250 μ L aliquots of the subsequent supernatant were dispensed into cryotubes, frozen and stored at –80 °C for analysis of LDH, total protein and cytokines. The contents of the third to fifth BAL washes were pooled and centrifuged as above; however, the supernatant was discarded and the pellet re-suspended with 1 mL of complete growth media, as used with the RLE-6TN cells. The re-suspended cell pellet was then combined with the cell pellet from the first and second BAL washes. These suspensions were used to calculate BALF total and differential cell counts.

Total BALF cell counts were performed manually using a hemacytometer (Hausser Scientific, Horsham, PA). Differential cell counts were determined for cytocentrifuge preparations (Cytospin Model II; Shandon, Pittsburgh, PA) stained with Diff-Quick (IMEB, Inc., San Marcos, CA) with subsequent enumeration of 200 cells per slide. A commercially available kit (LDH Cytotoxicity Detection Kit Roche Diagnostics, Indianapolis, IN), plate reader (μ Quant, Bio-Tek Instruments, Winooski, VT) and analysis software (KC Junior software version 1.41.8; Bio-Tek Instruments, Inc.) were used to determine LDH concentration in BALF. A commercially available kit (BCA Protein Assay Kit, Thermo Scientific Pierce, Rockford, IL) was used to determine protein levels in BAL samples. A commercially available kit (Bio-Plex, Bio-Rad Laboratories, Hercules, CA) was utilized to measure rat TNF- α , IL1- β , IL-6 and IL-10. The vendor supplied pre-prepared 96-well microplates that allowed simultaneous measurement of the four cytokines using multiplex bead-

based technology. A value of 1 pg/mL was assigned when an individual cytokine sample result was below detection limit.

Statistical analysis

Data that upon visual inspection were deemed to be potential outliers were subjected to analysis using the Grubbs' test for outliers. Levene's test for homogeneity ($p < 0.05$), followed by one-way analysis of variance (ANOVA) ($p < 0.05$) and Dunnett's test ($p < 0.05$) were performed for homogeneous data. A natural log (ln) transformation of the data was used when Levene's test for homogeneity indicated the data to be non-homogeneous. A Levene's test followed by a one-way ANOVA ($p < 0.05$) and Dunnett's test ($p < 0.05$) were performed on the transformed data. In the event that Levene's test on the transformed data indicated non-homogeneous data, a Kruskal–Wallis test ($p < 0.05$) or Wilcoxon two-sample Rank-Sum test ($p < 0.05$) were used. Histopathological findings were evaluated using a χ^2 test. For all analyses, group differences were considered significant if the test's statistical type I error was < 0.05 .

Results

Chemical and endotoxin analysis of dust sample extracts

Results from the HR-ICP-MS analysis of representative samples of the sand extracts are presented in Tables 1 and 2. A number of metals including iron, aluminum, nickel, manganese, vanadium and chromium were detected in the sand sample extracts used in our experiments. As expected, metal concentrations in the sand extracts varied among geographical locations. Certain metals (e.g. aluminum, iron) present in the sand samples were poorly solubilized using the mild extraction methods used in our experiments (Table 2). Endotoxin concentrations varied between sand extracts. Extract endotoxin concentrations in the stock solutions were < 0.05 (PBS buffer), < 2 (Taji and Talil), 21.9 (Afghanistan), 38.0 (Camp Victory) and 398 (Fort Irwin) endotoxin units (EU)/mL. In comparison, free endotoxin is toxic to lung cells *in vitro* at concentrations of ~ 1000 EU/mL (Cotten et al., 1994).

In vitro findings

Time-dependent increases in cytotoxicity are shown in Figures 1 and 2. Extracts prepared from sand collected from Taji and Talil had similar cytotoxicity *in vitro*. For example, a $> 50\%$ reduction (as percentage of control) in MTT metabolism in RLE-6TN cells was seen following an 8-h incubation with either the Taji or Talil sand extracts. In comparison, MTT activity remained at near normal levels ($> 90\%$) in cells treated with either the Camp Victory or Fort Irwin sand extracts (Figure 1). A similar response was seen following 12–24 h of extract exposure. The ability of the RLE-6TN cells to metabolize MTT following exposure to a Taji or Talil sand extract was $< 5\text{--}10\%$ of the saline-treated control cells. In comparison, cells treated with either the Afghanistan or Fort Irwin sand samples retained $> 50\%$ of their baseline enzymatic activity at these time-points (Figure 2).

In vitro exposure of RLE-6TN cells to sand extracts also resulted in cellular degeneration and necrosis. This effect was

Table 1. Compositional (ICP-MS) analysis of trace metals in the sand sample extracts in serum-free media used for the *in vitro* exposures (mean \pm standard deviation, $n = 2$ replicate analyses).

Analyte	Camp Victory	Fort Irwin	Taji Location 1	Taji Location 2	Talil
Arsenic	30.5 \pm 9.19	47 \pm 2.83	32 \pm 1.414	13.5 \pm 0.707	21.5 \pm 0.707
Cadmium	<LOD	<LOD	6.9 \pm 0.424	6.05 \pm 0.353	2.4 \pm 0.141
Cobalt	89 \pm 1.4	55 \pm 1.41	169.5 \pm 6.36	129.5 \pm 3.535	34.5 \pm 0.707
Copper	17 \pm 0	26.5 \pm 0.707	49.5 \pm 2.12	37 \pm 4.24	<LOD
Manganese	438.5 \pm 23.3	91 \pm 4.24	3302.5 \pm 249.61	2067 \pm 57.98	200 \pm 7.07
Molybdenum	19.5 \pm 0.707	17.5 \pm 0.707	17 \pm 2.828	16 \pm 1.414	37.5 \pm 0.707
Nickel	113 \pm 2.83	<LOD	73 \pm 5.66	46 \pm 4.24	<LOD
Strontium	8.3 \pm 0.283	6.2 \pm 0.141	43.25 \pm 3.606	70.95 \pm 0.212	12.15 \pm 0.636
Vanadium	14.65 \pm 0.21	6.45 \pm 0.212	5.55 \pm 0.071	5.55 \pm 0.0707	10.85 \pm 0.212
Zinc	26.5 \pm 2.12	35.5 \pm 0.707	22 \pm 2.83	11 \pm 1.414	17 \pm 1.414

See Table 2 for compositional analysis of the Afghanistan sand extract and analysis of PBS vehicle. LOD: below assay limit of detection. Analyte concentrations in parts per billion (ppb).

Table 2. Compositional (ICP-MS) analysis of trace metals in the bulk sand material and the subsequent aqueous extracts used for the *in vivo* exposures.

Analyte	Bulk sand sample			PBS ppb	Sand extract		
	Camp Victory ppm	Afghanistan ppm	Taji Location 1 ppm		Camp Victory ppb	Afghanistan ppb	Taji Location 1 ppb
Aluminum	29 256.1	29 614.4	23 933.3	<LOD	<LOD	<LOD	<LOD
Arsenic	8.6	5.1	5.6	<LOD	87.2	72.0	7.4
Barium	108.7	59.0	87.13	2.5	60.1	45.6	1868.5
Cadmium	0.2	0.1	0.3	<LOD	0.8	<LOD	5.3
Cesium	26.2	18.8	21.1	0.0	0.0	<LOD	0.0
Cobalt	20.0	15.3	15.9	0.1	6.9	0.5	24.4
Chromium	122.2	124.7	124.13	0.7	0.4	0.2	0.6
Copper	36.5	26.0	27.33	0.1	15.3	2.8	7.1
Iron	34 275.1	33 550.8	24 414.6	2.8	4.3	<LOD	12.0
Lithium	20.2	24.9	17.9	<LOD	34.0	8.9	9.4
Manganese	654.1	657.4	495.3	0.1	772.1	3.3	2698.0
Molybdenum	0.3	0.2	0.3	0.2	32.6	3.1	6.5
Nickel	180.5	123.8	163.26	<LOD	15.3	<LOD	57.7
Strontium	247.6	240.6	300.2	21.3	11 655.8	834.5	38 129.9
Titanium	709.7	538.1	635.5	1.1	0.6	0.6	0.5
Thallium	0.2	0.1	0.1	0.0	0.5	0.4	0.6
Vanadium	69.2	56.0	57.89	<LOD	18.9	8.8	3.9
Zinc	67.5	57.5	51.03	12.1	0.9	38.2	30.7

LOD: below assay limit of detection. Analyte concentrations in parts per billion (ppb) and parts per million (ppm).

most noted in cells treated with the Taji and Talil sand extracts (Figure 3). Less significant morphological effects were seen with extracts from Afghan sand (Figure 3) or sand collected from either Fort Irwin or Camp Victory (data not shown). A follow-up electron microscopy study examining earlier morphological changes associated with the Talil sand extract revealed marked cytotoxicity characterized by cellular dissociation, loss of membrane integrity and necrosis (Figure 4).

Effects seen following IT instillation of sand extracts

Some rats (6/40) developed dyspnea immediately after administration of the Taji sand extract. This response was statistically significant ($p = 0.01$) when compared with the controls (response incidence 0/40 rats). Two out of 40 rats administered Camp Victory extract also developed dyspnea; however, this was not statistically significant ($p = 0.15$). This effect was observed for ~ 5 –15 min after the instillation procedure. No additional signs were seen in these or other extract- or vehicle-treated rats. Sand-extract administration did not affect body weight gain in any of the treatment groups (Figure 5).

Data from our cytological evaluation of BALF are presented in Figure 6. Rats given the Afghanistan sand extract developed a 49% increase in total BALF cell number when evaluated 8 h after extract administration. There was also a change in the relative proportion of individual cell types seen in the BALF of these rats. At 8 h after dosing, rats given the Afghanistan sand extract had decreased relative percentage of macrophages and an increased proportion of neutrophils and eosinophils in their BALF (versus control animals). Total BALF cell number returned to control levels between 24 and 72 h after Afghanistan sand-extract administration. Rats in this exposure group developed a significant 39% decline in BALF cell number at 2 weeks after extract administration (versus control values). In contrast, a statistically significant increase in total BALF cell number occurred 4 weeks after administration of the Taji sand extract and no individual cell type predominated in this cellular response. Biochemical (LDH and total protein) evaluations of BALF are presented in Figure 7. A 30% decrease in BALF LDH activity was seen in rats evaluated 8 h after Afghanistan sand-extract administration. In contrast, a 35% increase in BALF LDH activity was seen in rats

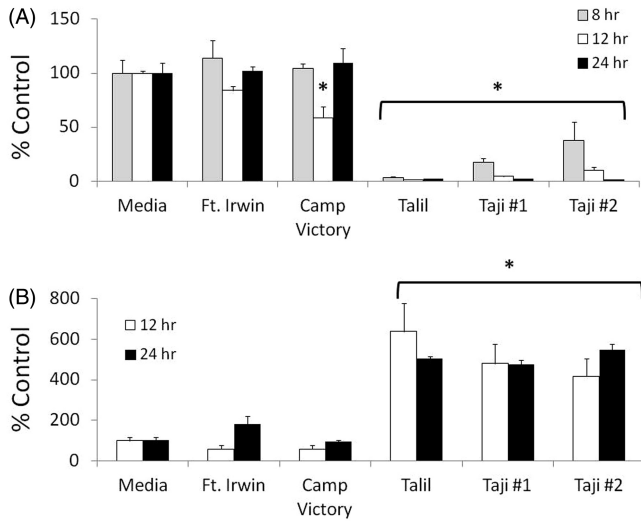


Figure 1. Time-dependent cytotoxicity seen in RLE-6TN rat lung epithelial cells following an 8–24-h exposure to serum-free media extracts of sand collected from Fort Irwin, Talil or Taji (two locations) as assessed by metabolism of MTT (A) and LDH leakage (B). Asterisk represents significantly different versus media-treated control. $p < 0.05$.

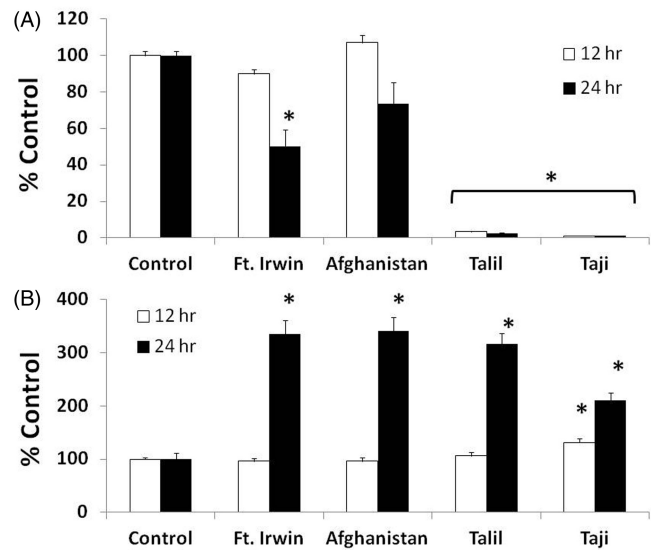


Figure 2. Time-dependent cytotoxicity seen in RLE-6TN rat lung epithelial cells following a 12 or 24 h exposure to either serum-free media or extracts of sand collected from Fort Irwin, Talil or Taji (Location 1), or Afghanistan as assessed by metabolism of MTT (A) or LDH leakage (B). Asterisk represents significantly different versus media-treated control. $p < 0.05$.

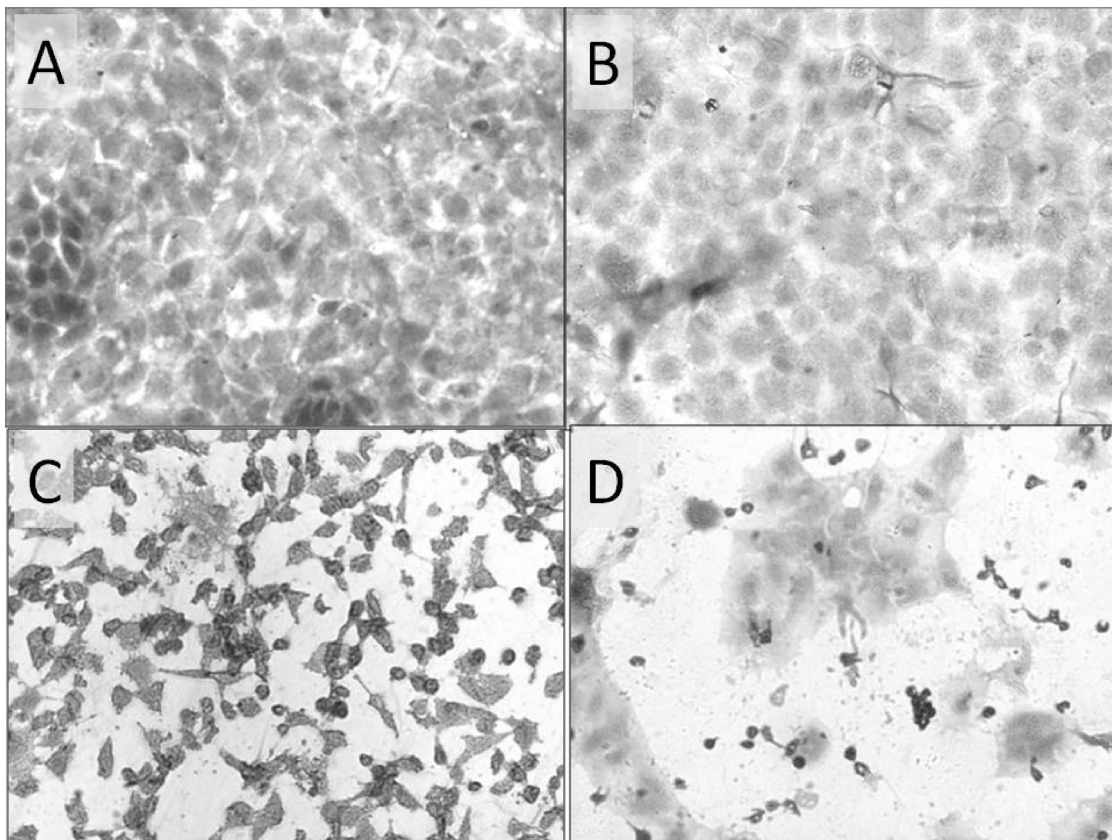


Figure 3. Morphological changes seen in RLE-6TN rat lung epithelial cells following a 24-h exposure to either serum-free media (A), or extracts of sand collected from Afghanistan (B), Talil (C) or Taji Location 1 (D). Marked pyknosis and loss of cellular detail can be observed in cells treated with either the Talil or Taji extract. Less extensive cytotoxic responses are seen in cells treated with the Afghanistan extract.

evaluated 72 h after Taji sand-extract administration. No change in BALF total protein concentration was observed following sand-extract administration. Minimal changes in BALF cytokine concentrations were seen following sand-extract administration (Figure 8). Rats given the Camp

Victory sand extract had a significant decrease in BALF TNF- α concentration when examined 8 h after administration (versus PBS-treated controls). All rats given sand extracts had decreased BALF IL-10 concentrations at 2 weeks post-exposure.

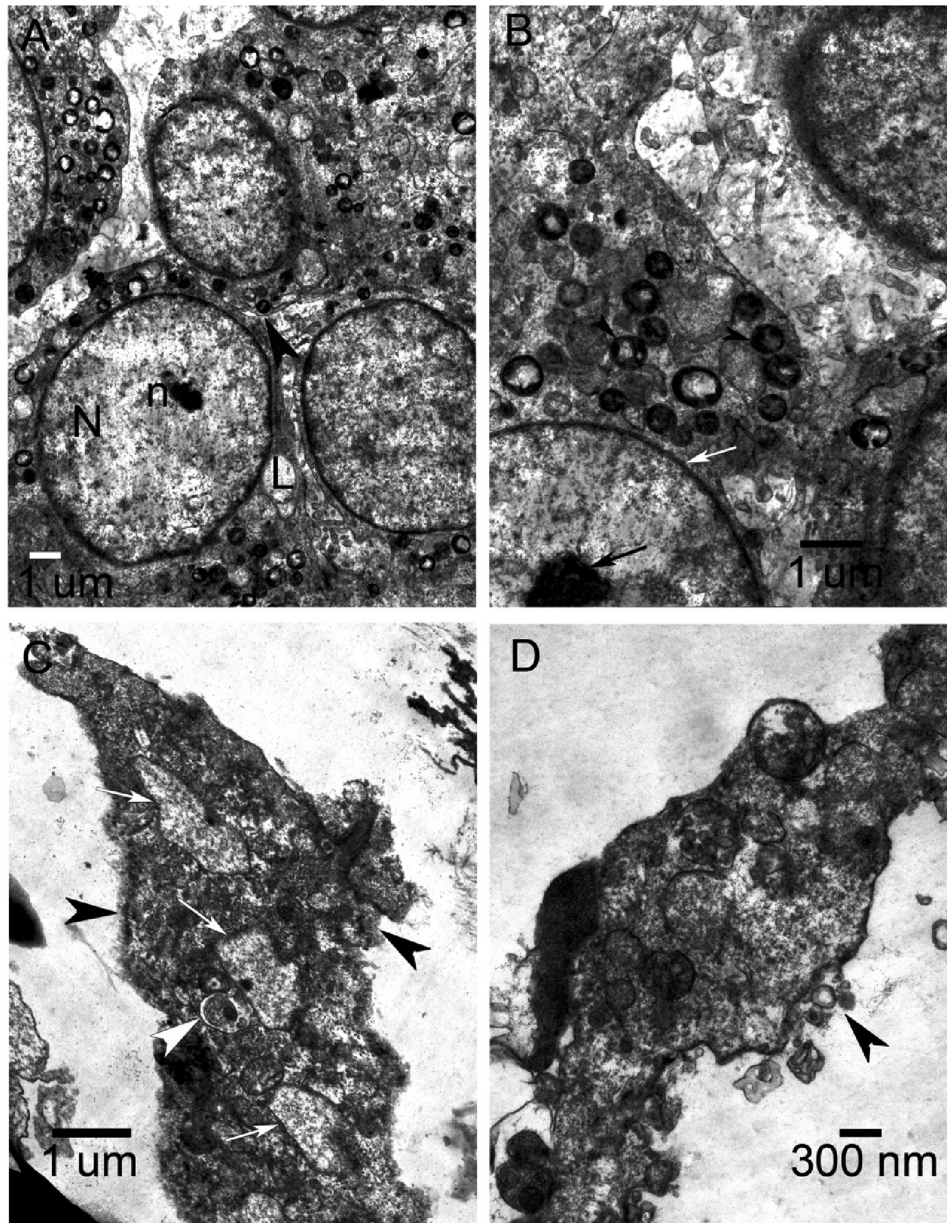


Figure 4. Control RLE-6TN cells (A and B) have a cuboidal shape with a large nucleus (N) and dense nucleolus (n). There is close contact between the cells (arrowhead). The cytoplasm has many lamellar bodies – small, spherical, membrane-bound, osmiophilic, lamellar structures that contain phospholipid. Note the intact nuclear membrane (white arrow) and nucleolus (black arrow) and several lamellar bodies in the cytoplasm in B. (A: 5000 \times and B: 10 000 \times electron microscope magnification). Cells treated for 4 h with an extract of sand from Talil Air Base show clear cytotoxicity (C and D). Cells dissociate and show a loss of membrane integrity. Panel C (10 000 \times) shows remnants of three cells, with three nuclei (white arrows) that are greatly reduced in size and are not characteristically round. Black arrowheads show loss of intact cell membranes. The white arrowhead may be a lamellar body. Cellular contents can be seen leaking out of the cell in D (15 000 \times) at the black arrowhead, where there is a disruption of the cell membrane.

The incidences of statistically significant airway lesions are presented in Table 3. Rats given the Camp Victory sand extract developed mild alveolar septal thickening with edema and hemorrhage. This lesion was not seen in any other treatment groups. Afterwards the most common lesion seen after sand-extract exposure was mild-to-moderate bronchointerstitial pneumonia with or without neutrophil and activated macrophage infiltration (Figure 9). This lesion was seen in all extract-exposed treatment groups from 24 h to 2 weeks after the extract instillation. This lesion was moderately severe (mean severity score 1.8–2.4) in all extract-treated groups at 24 h after exposure and was more mild at later time-points. All lung lesions resolved by 4 weeks after sand-extract administration.

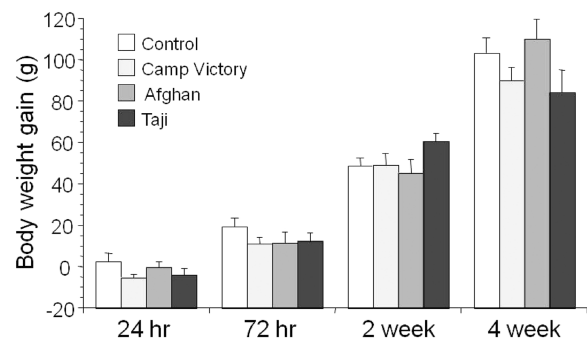
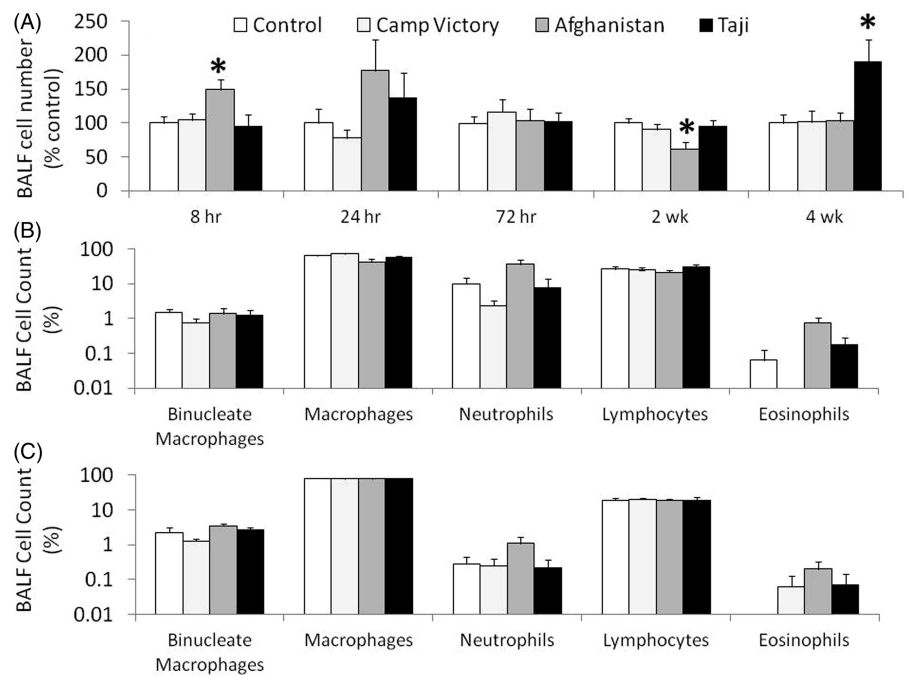


Figure 5. Body weight gain (mean \pm standard error of mean) seen in adult male rats given a single dose of sand extract. No statistically significant effects were observed.

Figure 6. Total number of cells observed in BALF (mean \pm standard error of mean) following administration of sand extract (A). Individual cell type data from 8 h (B) to 4 week time-points (C) are also shown. Asterisk represents significantly different versus PBS-treated control. $p < 0.05$.



Discussion

The overall objective of this study was to evaluate the pulmonary hazard potential of different sand particles of relevance to US military personnel. Our study used a combination of *in vitro* and *in vivo* approaches to characterize the respiratory toxicity of several different sand samples. One goal in using this approach was to assess whether simple *in vitro* toxicity assays could be used to screen sand particles for respiratory tract toxicity. We also used aqueous sand extracts since the presence of soluble metals has been associated with respiratory epithelial toxicity of other particles (Adamson et al., 1999; Dreher et al., 1997). The resulting sand extract represents a complex mixture of nickel, manganese, vanadium, cadmium, cobalt, chromium and other toxic metals. Duplicate sand extracts prepared from samples collected at one geographical location (e.g. Camp Victory) demonstrated differences in metal content (Tables 1 and 2). These differences could often be quite large and most likely reflect the non-homogenous nature of the sand samples. These differences could also contribute to the variability in responses seen between our *in vivo* and *in vitro* studies. We also found that the metal content and *in vitro* cytotoxicity of the extracts depended upon the geographical origin of the sand particles. Qualitatively, the Taji sand extract had higher cadmium, cobalt, copper, manganese and strontium concentrations than those seen in extracts created from sand collected in Talil, Camp Victory or Fort Irwin. Despite marked differences in the concentration of individual metals in the Talil and Taji sand extracts, we found that the *in vitro* cytotoxicity of the extracts created from these two regions were qualitatively similar. Extracts developed from Taji and Talil sands were significantly more cytotoxic than those developed from sands collected in other desert locations. Among the sand particles, we found that the extracts

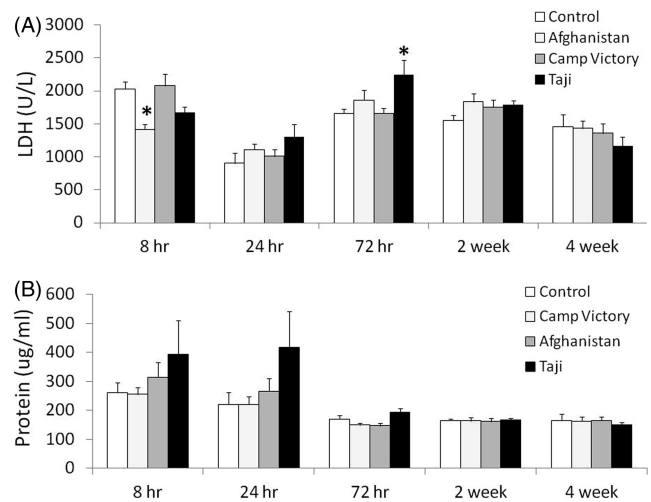


Figure 7. Total amount of LDH (A) and total protein (B) released in BALF (mean \pm standard error of mean) following administration of sand extract. Asterisk represents significantly different versus PBS-treated control. $p < 0.05$.

developed from Camp Victory and Fort Irwin had minimal *in vitro* cytotoxicity. Our study does not allow us to elucidate the individual toxic metal(s) that contributed to the *in vitro* toxicity seen in the present study.

Based upon our *in vitro* data we selected the following sands for additional *in vivo* assessment: Camp Victory (low *in vitro* cytotoxicity), Afghanistan sand (intermediate *in vitro* cytotoxicity) and Taji (high *in vitro* cytotoxicity). In the present study, IT administration of the aqueous extracts was used as a surrogate for direct IT administration or inhalation of the sand particles. Although IT administration has some disadvantages (e.g. bypasses the upper respiratory tract), this

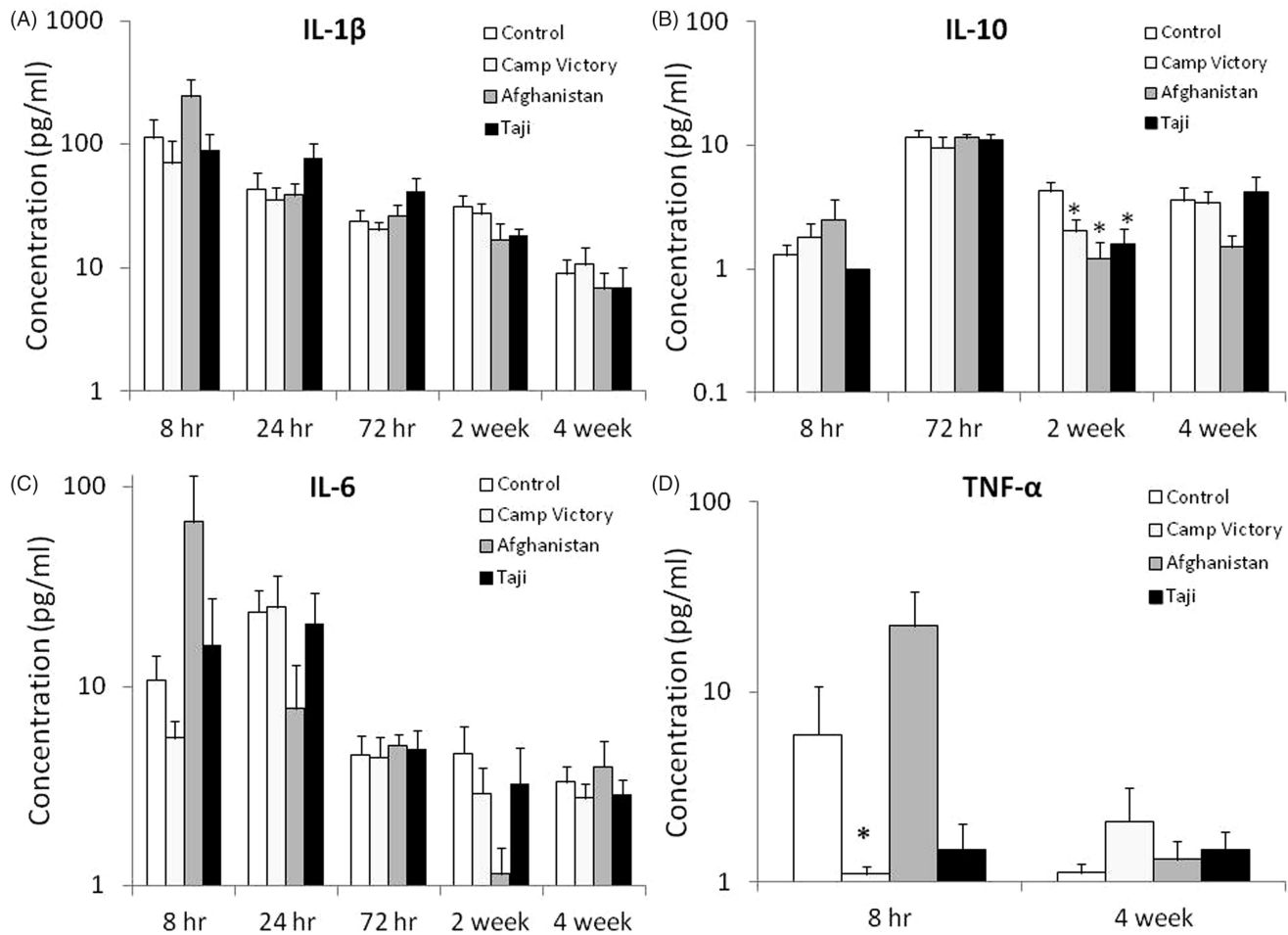


Figure 8. Mean (\pm standard error of mean) cytokine concentrations seen in BALF following administration of sand extract (left). Missing data for IL-10 (B) and TNF- α (D) occur because the majority of samples at those time-points had levels below the assay detection limit. Asterisk represents significantly different versus PBS-treated control. $p < 0.05$.

Table 3. Incidence of statistically significant lung lesions observed in rats given sand extracts.

Finding	Control	Camp Victory	Afghanistan	Taji Location 1
8 h				
Alveolar septal thickening	0/8	5/8 (1.0)	0/8	0/8
Edema and hemorrhage	0/8	5/8 (1.0)	0/8	0/8
24 h				
Bronchointerstitial pneumonia	0/8	8/8	6/8	7/8
Bronchointerstitial pneumonia with neutrophils	0/8	4/8 (2.4)	6/8 (1.8)	4/8 (2.0)
Type II pneumocyte hyperplasia	0/8	0/8	4/8	3/8
72 h				
Bronchointerstitial pneumonia	1/8	7/8 (1.93)	6/8 (1.50)	7/8 (1.38)
2 week				
Bronchointerstitial pneumonia	0/8	4/8 (1.25)	3/8 (1.50)	4/8 (1.63)

Bold numbers represent statistically significant increases versus PBS-treated control rats ($p < 0.05$, Pearson's χ^2). Numbers given in parenthesis represent mean severity scores. Severity scores are not provided for observations with a mean severity score of < 1 (mild, see text for additional details). Lesions were not observed at 4 weeks after sand-extract administration.

exposure method provides a cost-effective way to assess the relative toxicity of different types of particles (Broekaert et al., 1997; Hatch et al., 1985; Roberts et al., 2009). The use of low-volume extracts also negates the impact of lung overload associated with direct IT administration of the sand particles. Another advantage to the use of filtered sand extracts is that it reduces the impact of potentially infectious

microorganisms found in Middle Eastern sands (Perdue et al., 1992).

Our study examined extract-treated rats for acute (up to 72 h) and more delayed (2–4 weeks) pulmonary responses following IT administration of the sand extracts. Endpoints examined included cytological and biochemical assessment of BALF. During the course of our study we did not see changes

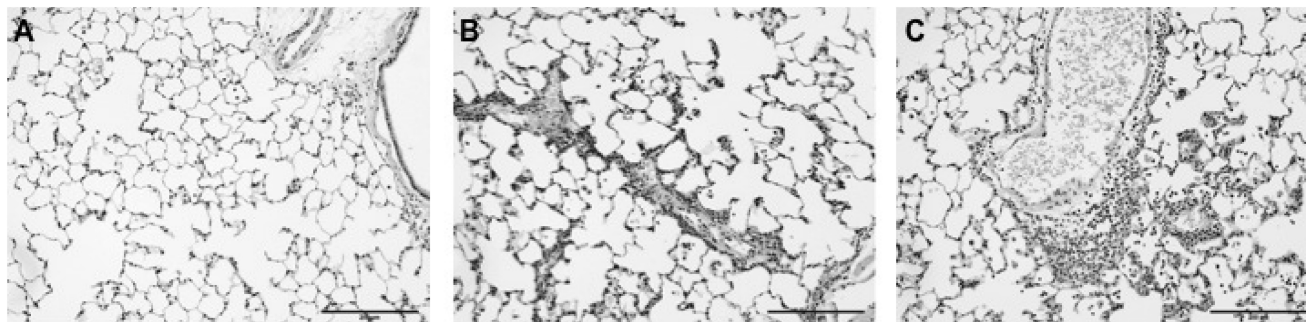


Figure 9. (A) Histopathology of a PBS-treated control rat lung. In this section, alveolar septae and air spaces are within normal limits morphologically and lack any remarkable inflammatory cell infiltrate. (B) Sections of lung from a rat 24 h after treatment with Camp Victory sand extract. In this section, alveolar septae and perivascular areas are thickened by moderately heavy infiltrates of neutrophils. Some neutrophils are in the alveolar space, along with scattered foamy/activated macrophages. (C) Sections of lung from a rat 72 h after treatment with the Taji sand extract. In this section, alveolar septae and perivascular areas are thickened by moderately heavy infiltrates of neutrophils. Many neutrophils have spilled into the alveolar space, along with scattered foamy/activated macrophages. HE staining.

in BALF protein concentrations, and only transient changes in BALF LDH concentration were observed. Alterations in these parameters have been associated with lung inflammation and pulmonary edema (Henderson, 2005). Lung lavage levels of key inflammatory (IL-1 β , IL-6 and TNF- α) and anti-inflammatory (IL-10) cytokines were also measured, as they have been shown to be fundamental modulators of injury and inflammation (Hocke et al., 2006). In the cytokine network model in the lung (Barnes, 2009), alveolar cells initially respond to a stimulus by secreting TNF- α and/or IL-1 β . These cytokines then act in an autocrine or paracrine fashion, leading to IL-6 release and triggering an inflammatory response. Exposure to sand extracts in our study was associated with minimal changes in these cytokines. Rats given the Camp Victory sand extract had a significant decrease in BALF TNF- α concentration when examined 8 h after administration (versus PBS-treated controls). An initial decrease in BALF TNF- α concentration has been seen following administration of ROFA, copper smelting dusts, tungsten and other particles (Broeckaert et al., 1997, 1999). This effect has been attributed to non-specific particle effects that would not occur with the filtered extract solutions used in our experiment. When compared with the other extract solutions, the Camp Victory sand extract had an approximately 5-fold higher molybdenum concentration. Other investigators have shown that administration of tetrathiomolybdate-inhibited TNF- α production and attenuated bleomycin-induced fibrosis in mice (Brewer et al., 2004). Additional efforts will be needed to determine whether the higher levels of molybdenum seen in the Camp Victory sand extract could account for the acute inhibitory effect on TNF- α production seen in the present study.

A transient delayed effect on BALF IL-10 concentration was also observed. This cytokine is primarily produced by lung monocytes and macrophages and one of its main functions is to down regulate inflammation by blocking the production of IL-6 and other pro-inflammatory cytokines (Mocellin et al., 2003). Although IL-10 production is often beneficial, over-expression of IL-10 in the lung can result in the up-regulation of several chemokines, increased cellular infiltration and lung fibrosis (Sun et al., 2011). In the present study, we observed decreased BALF IL-10 concentrations in

all extract-exposed rats. This effect was only observed at 2 weeks following IT administration of the extract and was not associated with changes in the expression of other lung cytokines. The observed change in lung IL-10 expression may have been involved in the resolution of the mild bronchopneumonia that was observed with all sand extracts since this lesion resolved within 4 weeks following extract administration.

We also saw minimal changes in BAL total cell numbers and differential cell counts. Rats given the Afghanistan sand extract demonstrated a short-lived BAL cellular response that was only seen at 8 h after extract administration. BAL differential cell counts in rats exposed to the Afghanistan sand extract revealed decreased macrophages and increased neutrophils and eosinophils at this time-point. Although BALF IL-6 levels were initially higher (at 8 h) in rats treated with the Afghan sand extract, this effect was not statistically significant. It is difficult to conclude whether the increase in IL-6 was associated directly with pulmonary neutrophilia or triggered resident lung cells to secrete neutrophil-attracting chemokines (Rossi et al., 2010). The observed changes in differential cell count are non-specific and not indicative of eosinophilic pneumonitis. This conclusion was confirmed by the lack of histopathologic evidence of inflammatory lung disease at this time-point. We also saw a statistically significant decline in total BALF cell number without a change in differential cell count at 2 weeks after Afghanistan sand-extract administration. The toxicological significance of this response is unknown. Administration of the Taji sand extract increased the total number of cells per milliliters of BAL fluid but had little effect on cell differential 4 weeks after IT administration of the extract. No histopathologically apparent lung changes were seen in this exposure group suggesting that the change in BALF cellularity had minimal toxicological significance.

Clinically we observed a marked acute response in rats given the Taji extract. IT administration of the Taji extract resulted in an immediate (within 5 min of administration) onset of dyspnea and other signs consistent with acute airway irritation. This response was not seen in any other treatment group. This observation is consistent with the observed *in vitro* data; however, the underlying cause of this response is

unknown. Sand-extract administration was associated with several other acute histopathologic responses. Rats given the sand extracts had few lesions seen at the first (8-h) time-point. Histologically apparent lung effects at this time were confined to rats given the Camp Victory sand extract. These animals developed mild alveolar thickening. Rats given sand extracts also developed mild-to-moderate bronchointerstitial pneumonia with or without neutrophil and activated macrophage infiltration. This lesion emerged at 24 h after IT administration of the extract and was resolved 4 weeks later. Qualitatively the incidence and severity of this response was similar between sand-extract exposure groups. Our finding of minimal airway responses following the IT administration of the Camp Victory sand extract in the present study is consistent with our previous rodent inhalation study (Dorman et al., 2012). In our previous 2-week inhalation study we saw minimal histopathologic changes that were confined to the anterior nose and lung.

In conclusion, our studies show that the metal content and respiratory toxicity of Middle Eastern sand can vary between geographic regions. The use of RLE-6TN rat lung epithelial cells was an effective way to rank order the *in vitro* toxicity of different sand extracts. Extracts produced from Taji and Talil were more cytotoxic than those produced from sand collected elsewhere (e.g. Camp Victory). The results of our *in vitro* cytotoxicity assay were partially predictive of *in vivo* responses. The more cytotoxic Taji sand extract induced an acute irritant response in rats following IT administration. Rats given the less cytotoxic Camp Victory sand extract had minimal biochemical or cytological BALF changes, consistent with minimal lung injury. In contrast, rats given either the Afghanistan or Taji sand extracts demonstrated BALF changes that were suggestive of mild lung inflammation. Unexpectedly, we observed similar lung pathology in all extract-exposed rats. The results of our study can be used to prioritize future particle inhalation studies or guide epidemiological study design. We hypothesize that long-term exposure to sand from the Taji and Talil regions would be more toxic than that collected from either Camp Victory or Afghanistan.

Acknowledgements

We acknowledge Bobbi McQuown, Elise Grover, and the staff of the NCSU College of Veterinary Medicine's Laboratory Animal Resource, Histology, and Central Procedures Laboratories for their assistance with this project.

Declaration of interest

This study was sponsored and funded by the Office of Naval Research and Global War on Terrorism, the US Army Medical Research and Materiel Command (USAMRMC) and the Military Operational Medicine Research Program (W911QY-08-P-0473). The views expressed are those of the authors and do not reflect the official policy or position of the Department of the Navy, Department of the Army, Department of Defense or the US Government. Citation of commercial organizations or trade names in this article do not constitute an official Department of the Navy or Department of the Army endorsement or approval of the products or services of these organizations. The authors report no

conflicts of interest. The authors alone are responsible for the content and writing of this article.

Disclaimers

Several authors are military service members (or employee of the US Government) and this work was prepared as part of their official duties. Title 17 USC §105 provides that "Copyright protection under this title is not available for any work of the United States Government". Title 17 USC §101 defines all US Government work as a work prepared by a military service member or employee of the US Government as part of that person's official duties.

References

- Adamson IY, Prieditis H, Vincent R. (1999). Pulmonary toxicity of an atmospheric particulate sample is due to the soluble fraction. *Toxicol Appl Pharmacol* 157:43–50.
- Bar-Ziv J, Goldberg GM. (1974). Simple siliceous pneumoconiosis in Negev Bedouins. *Arch Environ Health* 29:121–6.
- Barnes PJ. (2009). The cytokine network in chronic obstructive pulmonary disease. *Am J Respir Cell Mol Biol* 41:631–8.
- Bell ML, Levy JK, Lin Z. (2008). The effect of sandstorms and air pollution on cause-specific hospital admissions in Taipei, Taiwan. *Occup Environ Med* 65:104–11.
- Brewer GJ, Dick R, Ullenbruch MR, et al. (2004). Inhibition of key cytokines by tetrathiomolybdate in the bleomycin model of pulmonary fibrosis. *J Inorg Biochem* 98:2160–7.
- Broeckaert F, Buchet JP, Delos M, et al. (1999). Coal fly ash- and copper smelter dust-induced modulation of ex vivo production of tumor necrosis factor-alpha by murine macrophages: effects of metals and overload. *J Toxicol Environ Health A* 56:343–60.
- Broeckaert FB, Buchet JP, Huaux F, et al. (1997). Reduction of the ex vivo production of tumor necrosis factor-alpha by alveolar phagocytes after intratracheal administration of coal fly ash and copper smelter dust. *J Toxicol Environ Health* 51:189–202.
- Chen LC, Lippmann M. (2009). Effects of metals within ambient air particulate matter (PM) on human health. *Inhal Toxicol* 21:1–31.
- Cotten M, Baker A, Saltik M, et al. (1994). Lipopolysaccharide is a frequent contaminant of plasmid DNA preparations and can be toxic to primary human cells in the presence of adenovirus. *Gene Ther* 1: 239–46.
- Dorman DC, Mokashi V, Wagner DJ, et al. (2012). Biological responses in rats exposed to cigarette smoke and Middle East sand (dust). *Inhal Toxicol* 24:109–24.
- Dreher KL, Jaskot RH, Lehmann JR, et al. (1997). Soluble transition metals mediate residual oil fly ash induced lung injury. *J Toxicol Environ Health* 50:285–305.
- Dykstra MJ. (1993). A manual of applied techniques for biological electron microscopy. New York: Plenum Press. 257p.
- Engelbrecht JP, McDonald EV, Gillies JA, et al. (2009). Characterizing mineral dusts and other aerosols from the Middle East. Part 1. Ambient sampling. *Inhal Toxicol* 21:297–326.
- Gavett SH, Madison SL, Dreher K, et al. (1997). Metal and sulfate composition of residual oil fly ash determines airway hyper-reactivity and lung injury in rats. *Environ Res* 72:162–72.
- Goodman JE, Prueitt RL, Thakali S, Oller AR. (2011). The nickel ion bioavailability model of the carcinogenic potential of nickel-containing substances in the lung. *Crit Rev Toxicol* 41:142–74.
- Hatch GE, Boykin E, Graham JA, et al. (1985). Inhalable particles and pulmonary host defense: *in vivo* and *in vitro* effects of ambient air and combustion particles. *Environ Res* 36:67–80.
- Henderson RF. (2005). Use of bronchoalveolar lavage to detect respiratory tract toxicity of inhaled material. *Exp Toxicol Pathol* 57: 155–9.
- Hocke AC, Ermert M, Althoff A, et al. (2006). Regulation of interleukin IL-4, IL-13, IL-10, and their downstream components in lipopolysaccharide-exposed rat lungs. Comparison of the constitutive expression between rats and humans. *Cytokine* 33:199–211.
- Johnson EW, Wilfong ER, Fullenkamp HJ, et al. (2007). The Effects of desert sand (PM10) on the rat airway. Presented at the 46th Annual

- Meeting and ToxExpo of the Society of Toxicology Conference; 2007 March 29; North Carolina.
- Kodavanti UP, Jackson MC, Ledbetter AD, et al. (1999). Lung injury from intratracheal and inhalation exposures to residual oil fly ash in a rat model of monocrotaline induced pulmonary hypertension. *J Toxicol Environ Health* 57:543–63.
- Korenyi-Both AL, Korenyi-Both AL, Juncer DJ. (1997). Al Eskan disease: Persian Gulf syndrome. *Mil Med* 162:1–13.
- Korenyi-Both AL, Molnar AC, Fidelus-Gort R. (1992). Al Eskan disease: desert Storm pneumonitis. *Mil Med* 157:452–62.
- Kovacic P, Somanathan R. (2009). Pulmonary toxicity and environmental contamination: radicals, electron transfer, and protection by antioxidants. *Rev Environ Contam Toxicol* 201:41–69.
- Kwon HJ, Cho SH, Chun Y, et al. (2002). Effects of the Asian dust events on daily mortality in Seoul, Korea. *Environ Res* 90:1–5.
- Li N, Xia T, Nel AE. (2008). The role of oxidative stress in ambient particulate matter-induced lung diseases and its implications in the toxicity of engineered nanoparticles. *Free Radic Biol Med* 44: 1689–99.
- Lyles MB, Fredrickson HL, Bednar AJ, et al. (2011). Medical geology in the Middle East: potential health risks from mineralized dust exposure. *Proceedings of International Society for Photogrammetry and Remote Sensing*. Available from: <http://www.isprs.org/proceedings/2011/isrse-34/211104015Final00898.pdf> [Last accessed: 13 November 2012].
- Mazzoli-Rocha F, Fernandes S, Einicker-Lamas M, Zin WA. (2010). Roles of oxidative stress in signaling and inflammation induced by particulate matter. *Cell Biol Toxicol* 26:481–98.
- Mocellin S, Panelli MC, Wang E, et al. (2003). The dual role of IL-10. *Trends Immunol* 24:36–43.
- National Academies of Sciences (NAS). (1996). *Guide for the care and use of laboratory animals*. Institute of Laboratory Animals Resources, National Research Council. Washington: National Academy Press.
- Nouh MS. (1989). Is the desert lung syndrome (nonoccupational dust pneumoconiosis) a variant of pulmonary alveolar microlithiasis? Report of 4 cases with review of the literature. *Respiration* 55: 122–6.
- Perdue P, Kazarian KK, Odeyale C, et al. (1992). The surgical significance of Persian Gulf sand. *Mil Med* 157:375–7.
- Richards AL, Hyams KC, Watts DM, et al. (1993). Respiratory disease among military personnel in Saudi Arabia during Operation Desert Shield. *Am J Public Health* 83:1326–9.
- Roberts JR, Young SH, Castranova V, Antonini JM. (2009). The soluble nickel component of residual oil fly ash alters pulmonary host defense in rats. *J Immunotoxicol* 6:49–61.
- Rossi EM, Pylkkänen L, Koivisto AJ, et al. (2010). Airway exposure to silica-coated TiO₂ nanoparticles induces pulmonary neutrophilia in mice. *Toxicol Sci* 113:422–33.
- Scapellato ML, Lotti M. (2007). Short-term effects of particulate matter: an inflammatory mechanism? *Crit Rev Toxicol* 37:461–87.
- Shorr AF, Scoville SL, Cersovsky SB, et al. (2004). Acute eosinophilic pneumonia among US military personnel deployed in or near Iraq. *JAMA* 292:2997–3005.
- Smith B, Wong CA, Smith TC, et al. (2009). Newly reported respiratory symptoms and conditions among military personnel deployed to Iraq and Afghanistan: a prospective population-based study. *Am J Epidemiol* 170:1433–42.
- Sun L, Louie MC, Vannella KM, et al. (2011). New concepts of IL-10-induced lung fibrosis: fibrocyte recruitment and M2 activation in a CCL2/CCR2 axis. *Am J Physiol Lung Cell Mol Physiol* 300:L341–53.
- Tao F, Gonzalez-Flecha B, Kobzik L. (2003). Reactive oxygen species in pulmonary inflammation by ambient particulates. *Free Radic Biol Med* 35:327–40.
- Wilfong ER, Lyles M, Rietcheck RL, et al. (2011). The acute and long-term effects of Middle East sand particles on the rat airway following a single intratracheal instillation. *J Toxicol Environ Health A* 74: 1351–65.