

**REPORT DOCUMENTATION PAGE**

*Form Approved  
OMB No. 0704-0188*

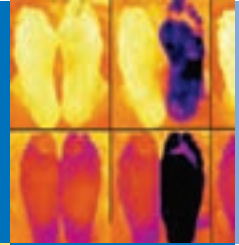
The public reporting burden for this collection of information is estimated to average 1 hour per response, including the time for reviewing instructions, searching existing data sources, gathering and maintaining the data needed, and completing and reviewing the collection of information. Send comments regarding this burden estimate or any other aspect of this collection of information, including suggestions for reducing the burden, to Department of Defense, Washington Headquarters Services, Directorate for Information Operations and Reports (0704-0188), 1215 Jefferson Davis Highway, Suite 1204, Arlington, VA 22202-4302. Respondents should be aware that notwithstanding any other provision of law, no person shall be subject to any penalty for failing to comply with a collection of information if it does not display a currently valid OMB control number.

**PLEASE DO NOT RETURN YOUR FORM TO THE ABOVE ADDRESS.**

<b>1. REPORT DATE (DD-MM-YYYY)</b> 2012		<b>2. REPORT TYPE</b> Book Chapter-Wilderness Medicine Textbook		<b>3. DATES COVERED (From - To)</b>	
<b>4. TITLE AND SUBTITLE</b> Nonfreezing Cold-Induced Injuries				<b>5a. CONTRACT NUMBER</b>	
				<b>5b. GRANT NUMBER</b>	
				<b>5c. PROGRAM ELEMENT NUMBER</b>	
<b>6. AUTHOR(S)</b> C.H.E. Imray, J.W. Castellani				<b>5d. PROJECT NUMBER</b>	
				<b>5e. TASK NUMBER</b>	
				<b>5f. WORK UNIT NUMBER</b>	
<b>7. PERFORMING ORGANIZATION NAME(S) AND ADDRESS(ES)</b> Thermal and Mountain Medicine Division U.S. Army Research Institute of Environmental Medicine Natick, MA 01760-5007				<b>8. PERFORMING ORGANIZATION REPORT NUMBER</b> M10-29	
<b>9. SPONSORING/MONITORING AGENCY NAME(S) AND ADDRESS(ES)</b> Same as #7 above.				<b>10. SPONSOR/MONITOR'S ACRONYM(S)</b>	
				<b>11. SPONSOR/MONITOR'S REPORT NUMBER(S)</b>	
<b>12. DISTRIBUTION/AVAILABILITY STATEMENT</b> Approved for public release; distribution unlimited.					
<b>13. SUPPLEMENTARY NOTES</b>					
<b>14. ABSTRACT</b> Nonfreezing cold-induced injury (NFCI) is a clinical syndrome that results from damage caused to tissues exposed to cold temperatures at or above the freezing point of water (0 ° to 15 ° C [32 ° to 59 ° F]). NFCI does not involve tissue freezing, which distinguishes it both clinically and pathologically from frostbite. 36 The earliest descriptions of this syndrome had their origins in the military. Baron Dominique Jean Larrey, Napoleon ' s chief surgeon, used the word congelation to describe the nonfreezing injuries together with frostbite casualties that occurred during the 1812 assault on Russia. 92 Historically, infantry regiments have been decimated by cold and wet conditions, and many medical advances in understanding the pathophysiology and clinical course of NFCI have occurred after wars. 2,35 However, it has been observed that the continuity of research tends to lag during the periods between major military campaigns. 98 Developments in prevention of cold injury have flourished as new clothing and footwear have been designed, but little progress has been made in the treatment of NFCI. There is a rise in the number of people pursuing recreational activities in harsh environments, and as a consequence, civilian NFCI is becoming more prevalent. However, because					
<b>15. SUBJECT TERMS</b> non-freezing cold injury, congelation, harsh environments					
<b>16. SECURITY CLASSIFICATION OF:</b>			<b>17. LIMITATION OF ABSTRACT</b> Unclassified	<b>18. NUMBER OF PAGES</b> 10	<b>19a. NAME OF RESPONSIBLE PERSON</b> J.W. Castellani
<b>a. REPORT</b> Unclassified	<b>b. ABSTRACT</b> Unclassified	<b>c. THIS PAGE</b> Unclassified			<b>19b. TELEPHONE NUMBER (Include area code)</b> 508-233-4953

Reset

# Nonfreezing Cold-Induced Injuries



CHRISTOPHER H.E. IMRAY AND JOHN W. CASTELLANI

Nonfreezing cold-induced injury (NFCI) is a clinical syndrome that results from damage caused to tissues exposed to cold temperatures at or above the freezing point of water (0° to 15°C [32° to 59°F]). NFCI does not involve tissue freezing, which distinguishes it both clinically and pathologically from frostbite.<sup>36</sup> The earliest descriptions of this syndrome had their origins in the military. Baron Dominique Jean Larrey, Napoleon's chief surgeon, used the word *congelation* to describe the nonfreezing injuries together with frostbite casualties that occurred during the 1812 assault on Russia.<sup>92</sup> Historically, infantry regiments have been decimated by cold and wet conditions, and many medical advances in understanding the pathophysiology and clinical course of NFCI have occurred after wars.<sup>2,35</sup> However, it has been observed that the continuity of research tends to lag during the periods between major military campaigns.<sup>98</sup> Developments in prevention of cold injury have flourished as new clothing and footwear have been designed, but little progress has been made in the treatment of NFCI.

There is a rise in the number of people pursuing recreational activities in harsh environments, and as a consequence, civilian NFCI is becoming more prevalent. However, because many physicians are unfamiliar with NFCI, it may go undiagnosed during assessment of the cold-exposed victim.<sup>98</sup> This results in unnecessary hospital admissions and potentially harmful and expensive therapy.<sup>41</sup> Proper education and awareness of the hazards innate to the cold environment should mean that NFCI is preventable in most circumstances.

This chapter explores the history, epidemiology, pathophysiology, and current prevention and treatments of NFCI, as well as pernio (chilblains), cryoglobulinemia, and cold urticaria.

## Epidemiology

Individuals suffering cold and wet extremities for extended periods are at risk for NFCI. During the 1800s, NFCI was observed more frequently when the temperature hovered around the freezing point—when the ground was muddy rather than frozen.<sup>43,91</sup> Standing or sitting for long periods, wearing constrictive footwear, malnutrition, fatigue, or the blunt trauma of marching on cold, wet feet all added to the severity of injury.<sup>92</sup> Original animal studies that modeled NFCI demonstrated that cold temperatures near the freezing point were more likely to cause injury when the extremities were wet than when they were dry.<sup>10,91</sup> Ambient temperature and wind speed can both influence cooling.<sup>32,114</sup>

With “shelter limb” (dependency without cold) and “paddy foot” (wet but not cold), one observes an injury that has no apparent distinguishing differential feature from NFCI. This suggests that neither cold nor wet is a prerequisite to developing the injury. It appears that NFCI is a reperfusion injury that develops after a sustained period of peripheral vasoconstriction.<sup>98</sup>

## MILITARY

In combat settings, there is rarely the time, equipment, or opportunity to apply appropriate remedies to NFCI. In the 1854 Crimean War, cold injury was documented more often among “the men in the trenches [who] were so restricted in their movements.... Frequently this position happened to be the bottom of a trench knee-deep in mud and water or half-filled with snow.”<sup>91</sup> In November 1944, during World War II, American forces sustained

11,000 cases of trench foot.<sup>110</sup> Evaluation of possible risk factors for cold injury during the 1982 war in the Falkland Islands has been published. A year after exposure, there were no cases of cryoglobulinemia or hematologic evidence to suggest that any of the men who developed cold injury had abnormal circulating proteins, plasma hyperviscosity, or indicators of alcohol abuse.<sup>30</sup> In the 1990s, both the U.S. Army and the Israel Defense Forces recorded that the majority of nonfreezing cold injuries occurred during routine training exercises, rather than during combat operations.<sup>26,68,73</sup>

## ETHNICITY

Historically, the first reports of increased susceptibility in certain ethnic groups (blacks) to cold-weather injury came from the American Civil War.<sup>87</sup> It was also noted that there was an increased incidence of cold injuries among blacks in the cold winter conflict in the Ardennes in 1944 during World War II.<sup>110</sup> A major retrospective study looking at 2143 U.S. Army cold-weather injury hospital admissions between 1980 and 1999 found that the injury rates for men and women were 13.9 and 13.3 per 100,000 soldiers, respectively.<sup>26</sup> Increased rank and experience were associated with a decrease in cold-weather injuries. There were 3.3 times more blacks hospitalized than whites, (95% confidence interval [CI], 3.1-3.7), and infantry and gun crews appeared to be at greater risk. There was a marked reduction in the number of soldiers admitted to the hospital between 1980 and 1999, from greater than 30 cases per 100,000 soldier years to almost zero.

Young male African Caribbeans in the British Army have been found to have a 30 times greater chance of developing peripheral cold injury and are more severely affected than are their white counterparts following similar climatic exposure, using similar clothing and equipment. Pacific Islanders carry a 2.6 times increased risk, whereas being a Gurkha appears to be protective.<sup>15</sup> Peripheral vascular responses to a local cold stress were studied in four groups of Indians: South Indians, North Indians, Gurkhas, and high-altitude natives of 3,500 meters (11,483 feet). The heat output and cold-induced vasodilation (CIVD) were highest in high-altitude natives, with the lowest observed in South Indians.<sup>67</sup>

## PREVALENCE

In most North Atlantic Treaty Organization (NATO) countries, prevalence of NFCI injuries appears to be static or decreasing among military personnel. However, in the British military, there appears to be a marked increase in the incidence of reported cold-weather injury. Over a 4-year period, the reported rate increased from 9 per 1000 to 30 per 1000 recruits, with the majority of cases (90%) originating during field-based training. Independent factor analysis demonstrated that African Caribbeans were 13.2 (95% CI, 9.5-18.4, probability [*p*] <0.01) times more likely to report cold injury and 27.3 (95% CI, 16.3-45.9, *p* <0.01) times more likely to be medically discharged than were whites.<sup>113</sup> The rise in NFCI in the military of the United Kingdom (UK) may be caused by increased exposure, lower threshold to diagnose the condition, increased awareness, or recruiting of a different and more sensitive population. Alternatively, the rise may be caused by a type I statistical error (poor specificity of the tests used to diagnose NFCI or excessive credulity) or a type II error

(poor sensitivity of the tests used to diagnose NFCl). Perhaps other countries are failing to diagnose and report the condition.<sup>52</sup>

## CIVILIAN

The environmental conditions that can produce NFCl in military settings are also found in the context of wilderness medicine. Outdoor recreation may lead to cold, dehydrated, exhausted, and wet hikers exposed to the elements for an extended period. These individuals may be unwilling or unable to take the time and effort to care for their wet boots and socks, and they may be unaware of the risks inherent in the situation. Other civilian populations at risk for NFCl include the homeless,<sup>116</sup> older adults,<sup>83</sup> and alcoholics.<sup>98</sup>

### Personal Administration

Proper protective equipment and appropriate use are important factors reducing the incidence of NFCl. Factors affecting the incidence of frostbite are closely related to those affecting NFCl. A surprisingly high incidence of frostbite has been reported in mountaineers. In one study, the mean incidence was 366 per 1000 population per year. Mild (grade 1) injury (83.0%) and hand (26.4%) and foot (24.1%) involvement were most common. There was a significant relation between lack of proper equipment (odds ratio 14.3) or guide ( $p < 0.001$ ) and the injury. Inappropriate clothing, lack or incorrect use of equipment, and lack of knowledge of how to deal with cold and severe weather were claimed to be the main reasons for the injury.<sup>47</sup>

Cold injury is uncommon in Antarctica. Despite this, it warrants a continued high profile, because under most circumstances, it may be regarded as an entirely preventable occurrence.<sup>16</sup> It has been suggested that prolonged heavy load carriage during a 109-day Arctic expedition may have impaired blood flow or nerve conduction in the hands and inhibited cold acclimatization. However, a different response was observed in the feet, where there was improvement in cold acclimatization despite development of moderate trench foot.<sup>77</sup>

### Civilian Case Reports

Laden and colleagues<sup>64</sup> reported cold injury to a diver's hand after a 90-minute dive in 6°C (42.8°F) water. With the advent of "technical diving," characterized by going deeper for longer (often in cold water), and adventure tourism, it was suggested that this extremely painful condition was likely to increase in prevalence.

Older adult patients commonly present to the hospital following their collapse and a period of distressing immobilization on the floor. A case of bilateral trench foot in an older adult immobile patient has been reported.<sup>112</sup>

## Skin—A Thermoregulatory Organ

Thermoregulation is a major function of skin in humans, and it is achieved by large fluxes in cutaneous blood flow.<sup>65</sup> The metabolic requirements of skin are fixed and relatively modest; the observed large fluctuations in cutaneous blood flow are primarily determined by the individual's thermoregulatory needs. Arteriovenous anastomoses (AVAs) abound in the extremities. The AVAs are coiled muscular-walled vessels approximately 35  $\mu\text{m}$  in diameter and have little basal tone. They are under dual control. First, there is central hypothalamic control via the sympathetic nervous system. Second, there is direct local control allowing dilation under warm conditions and constriction with a cold stimulus. The two effects may be additive. Cutaneous vessels are controlled by sympathetic adrenergic vasoconstrictor fibers, and vascular smooth muscles have both  $\alpha$ - and  $\beta$ -receptors. When core temperature exceeds 37.5°C (99.5°F), the hypothalamus reduces vasoconstrictor drive to the AVAs and vasodilation occurs. As a result, a low-resistance shunt in the dermal venous plexus opens, which in turn increases local heat loss. Under cold conditions there is an increase in sympathetic tone, resulting in local arteriovenous vasoconstriction and reduction in cutaneous blood flow.

Under basal conditions, a 70-kg (154.3-lb) person has a total cutaneous blood flow of 200 to 500 mL/min. With external

heating to maintain skin temperature at 41°C (105.8°F), this may increase to 7000 to 8000 mL/min, whereas cooling the skin to 14°C (57.2°F) may diminish it to 20 to 50 mL/min. Heat is dissipated by four processes: radiation, conduction, convection, and evaporation.

Cutaneous vascular tone is inversely related to ambient temperature. Cold-induced vasoconstriction is attenuated by  $\alpha_2$ -receptor blockers and by sympathetic inhibition. Reduction in ambient temperature results in insertion of more  $\alpha_2$ -receptors from the myocyte Golgi apparatus into the plasma membrane, raising affinity for the sympathetic neurotransmitter norepinephrine. At the same time, endothelial nitric oxide synthase (eNOS) activity declines, resulting in vasoconstriction of AVAs. Core temperatures have a strong influence over cutaneous sympathetic vasomotor activity.

Vascular endothelium regulates local vascular tone by secreting vasoactive agents, including the vasoconstrictor endothelin and the vasodilators nitric acid and prostacyclin. Endothelin causes long-lasting vasoconstriction and is elevated in hypoxia, preeclampsia, and hemorrhagic stroke.

### ORTHOSTASIS

Orthostasis causes immediate reduction in local blood flow. Indeed, cutaneous perfusion is reduced by approximately two-thirds as a result of the poorly understood arteriolar-venous response. It is believed that this response helps maintain central arterial pressure during standing and also reduces dependent edema formation. Long periods of sitting or standing tend to exacerbate this response.

### COLD-INDUCED VASODILATION

When the hand or foot is cooled to 15°C (59°F), maximal vasoconstriction and minimal blood flow occur. If cooling continues to 10°C (50°F), vasoconstriction is interrupted by periods of vasodilation and an associated increase in blood and heat flow. This CIVD, or "hunting response," occurs in 5- to 10-minute cycles to provide some protection from the cold. Prolonged repeated exposure to cold increases CIVD and offers some degree of acclimatization. Inuit, Sami, and Nordic fishermen have a very strong CIVD response and very short intervals between dilations, which may contribute to maintenance of hand function in the cold environment.<sup>44</sup> CIVD responses are more pronounced when the body core and skin temperatures are warm (hyperthermic state) and suppressed when they are cold (hypothermic state), when compared with normothermia.<sup>22,23,78</sup> Cheung and Mekjavic<sup>17</sup> investigated whether CIVD responses of one finger can predict the responses of other fingers and also whether the CIVD of fingers could predict CIVD responses of the feet and toes. They found that CIVD is highly variable across the fingers and is not a generalizable response across either digits or limbs. Paradoxical CIVD will normally prevent tissue damage, but in conditions such as Raynaud's disease, the vessels of the toes and fingers exhibit an exaggerated and sustained vasoconstriction response, resulting in blanching, numbness, and paresthesias and in severe cases tissue loss.

Subjects with a weak CIVD to experimental cold-water immersion of the fingers in a laboratory setting have been shown to have a higher risk for local cold injuries when exposed to cold in real life.<sup>24</sup> There is a strong relationship between the mean temperature of the fingers during cold-water immersion and toes during cold-air exposure (correlation coefficient for bivariate analysis [ $r$ ] = 0.83,  $p < 0.01$ ), showing that a weak CIVD response in the hand correlates with a weak response in the foot.<sup>105</sup> Felicijan and colleagues<sup>33</sup> found evidence for significant enhancement of the CIVD response after brief high-altitude acclimatization and that these changes were especially prominent in the feet of Alpinists when compared with controls.

Temperatures of the extremities can drop surprisingly quickly in the field. Toe temperatures of 10 subjects were monitored in the field in Arctic Norway (minimum air temperature  $-27^\circ\text{C}$  [ $-16.6^\circ\text{F}$ ]). The lowest skin temperature recorded was 1.9°C (35.4°F). The mean estimated time for toe temperature to cool from 25°C (77°F) to 5°C (41°F) was 109 minutes (standard

deviation [SD], 10.2) at an ambient temperature of  $-21^{\circ}\text{C}$  ( $-5.8^{\circ}\text{F}$ ). One subject experienced a toe temperature below  $5^{\circ}\text{C}$  ( $41^{\circ}\text{F}$ ) for 2.9 hours during a 27-hour period. Surprisingly, none of the subjects demonstrated clinical signs of cold injury, but this does not mean that this exposure was without risk.<sup>101</sup>

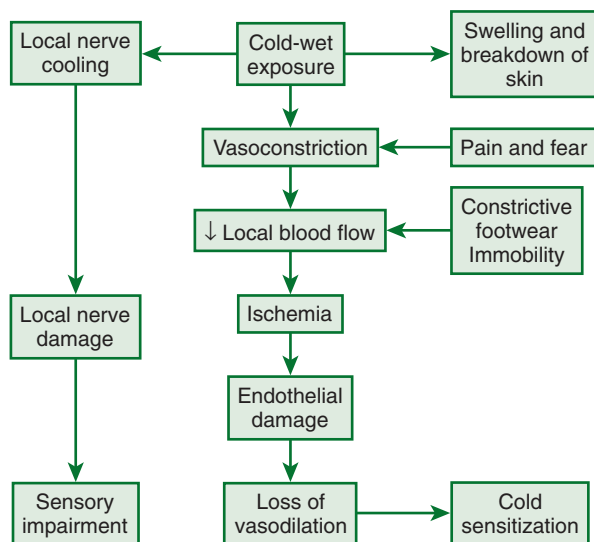
The cutaneous microcirculation of skin was assessed in patients with sequelae from local cold injuries. All patients reported cold intolerance 3 to 4 years after the primary cold injury (sustained during military service).<sup>4</sup> The transcutaneous oxygen tension was decreased, but oxygen reappearance time, oxygen recovery index, postocclusive reactive hyperemia, and venoarterial reflex were normal. No capillary nailfold abnormalities were found. Local cold injuries appear to cause disturbances in the CIVD, impaired cold tolerance, and increase the risk for future cold injuries. There is evidence to suggest disturbances of reflex mechanisms mediated by the central nervous system. Neurophysiologic factors seem more important than ischemic mechanisms in the pathophysiology of late sequelae with peripheral cold-weather injuries.

## Trench Foot (Immersion Foot)

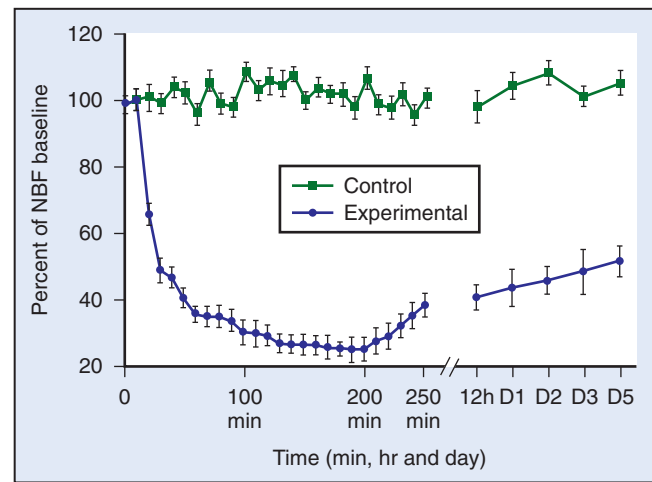
### PATHOPHYSIOLOGY

Continuous exposure to a cold, wet environment causes skin breakdown, directly cools nerves in the area of exposure, and causes prolonged vasoconstriction. NFCI is primarily caused by prolonged vasoconstriction, which in turn causes direct injury to the vessels (and endothelium) that supply blood to nerves, fat, and muscle cells.<sup>49,72,98</sup> Pain, fear, constrictive footwear, and immobility interact in maintaining vasoconstriction through a heightened sympathetic nervous system response or by mechanically limiting blood flow (Figure 7-1). Nerve cooling has been suggested as a contributing factor in the development of NFCI. Large myelinated fibers (C fibers) are most susceptible to prolonged cold exposure.<sup>53,61,62,88</sup> In severe nonfreezing cold injury, there is characteristic peripheral nerve damage and tissue necrosis.<sup>54</sup> Clinical sensory tests indicate damage to both large- and small-diameter nerves. The prolonged cold injury affects blood vessels serving these large myelinated fibers, with subsequent ischemia causing decreased oxygen to the nerve, resulting in the appearance of a primary nervous system injury<sup>58,59</sup> (Figures 7-2 to 7-5).

Vasoconstriction is mediated by presynaptic vesicle release of norepinephrine and neuropeptide Y from sympathetic nerve fibers that interact postsynaptically on smooth muscle at  $\alpha_{2c}$ ,<sup>6,18</sup> and Y1<sup>95</sup> receptors. Recent work<sup>100</sup> demonstrated that cold-induced vasoconstriction is mediated by Rho kinase. The prolonged decrease in blood flow caused by vasoconstriction causes



**FIGURE 7-1** Schematic of factors and mechanisms that contribute to nonfreezing cold injuries.



**FIGURE 7-2** Laser Doppler mean nerve blood flow (NBF) in control and experimental animals at 10-minute intervals during nerve cooling and rewarming (up to 250 minutes) and at follow-up examination immediately before sacrifice (at various times up to 5 days). Note that the nerve blood flow falls steeply over 20 minutes and reaches its nadir (25% of baseline) 180 minutes after the onset of cooling. Nerve blood flow remains significantly reduced up to 5 days after cold injury. (Modified from Jia J, Pollock M: The pathogenesis of non-freezing cold nerve injury: Observations in the rat, *Brain* 120:631, 1997.)

direct injury to capillary endothelium. Studies indicate that the endothelial lining separates from underlying cells, leaving “gaps.”<sup>31</sup> Leukocytes and platelets fill in these gaps and accumulate to further decrease capillary blood flow, leading to ischemia and eventual tissue hypoxia (Figure 7-6, online). The degree and duration of cold exposure determine severity of the injury.

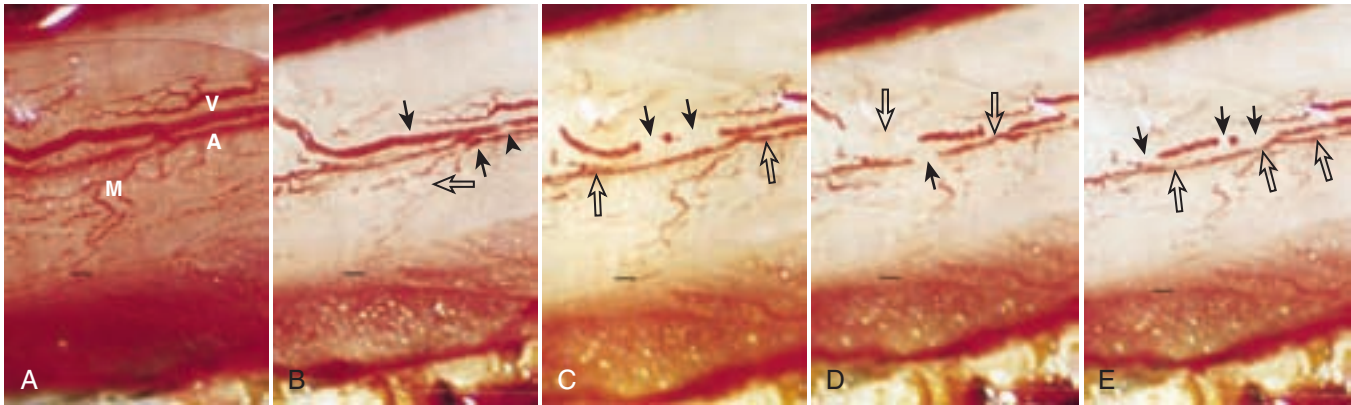
Animal models have been developed to understand the underlying pathophysiology of NFCI. Thomas and co-workers<sup>99</sup> developed a rat model of NFCI by immersing the tail in  $1^{\circ}\text{C}$  ( $33.8^{\circ}\text{F}$ ) water for 6 to 9 hours and characterized the loss of CIVD and a prolonged decrease in tail blood flow followed by an increase in blood flow above baseline. This pattern is similar to that clinically observed in humans during the prehyperemic phase followed by the hyperemic phase. In rats, absence of CIVD with prolonged cold exposure is similar to this prominent and consistent finding of NFCI in humans.

Stephens and associates<sup>95</sup> used the rat tail model in an attempt to elucidate possible mechanisms that cause vascular endothelial damage. Their preliminary data suggest that acute cold-water exposure causes loss of nitric oxide–dependent endothelial function and possibly a change in smooth muscle contractility. Using a rabbit hind limb model, Irwin<sup>53</sup> demonstrated that cold-water immersion damaged large myelinated fibers while sparing small myelinated and unmyelinated fibers.

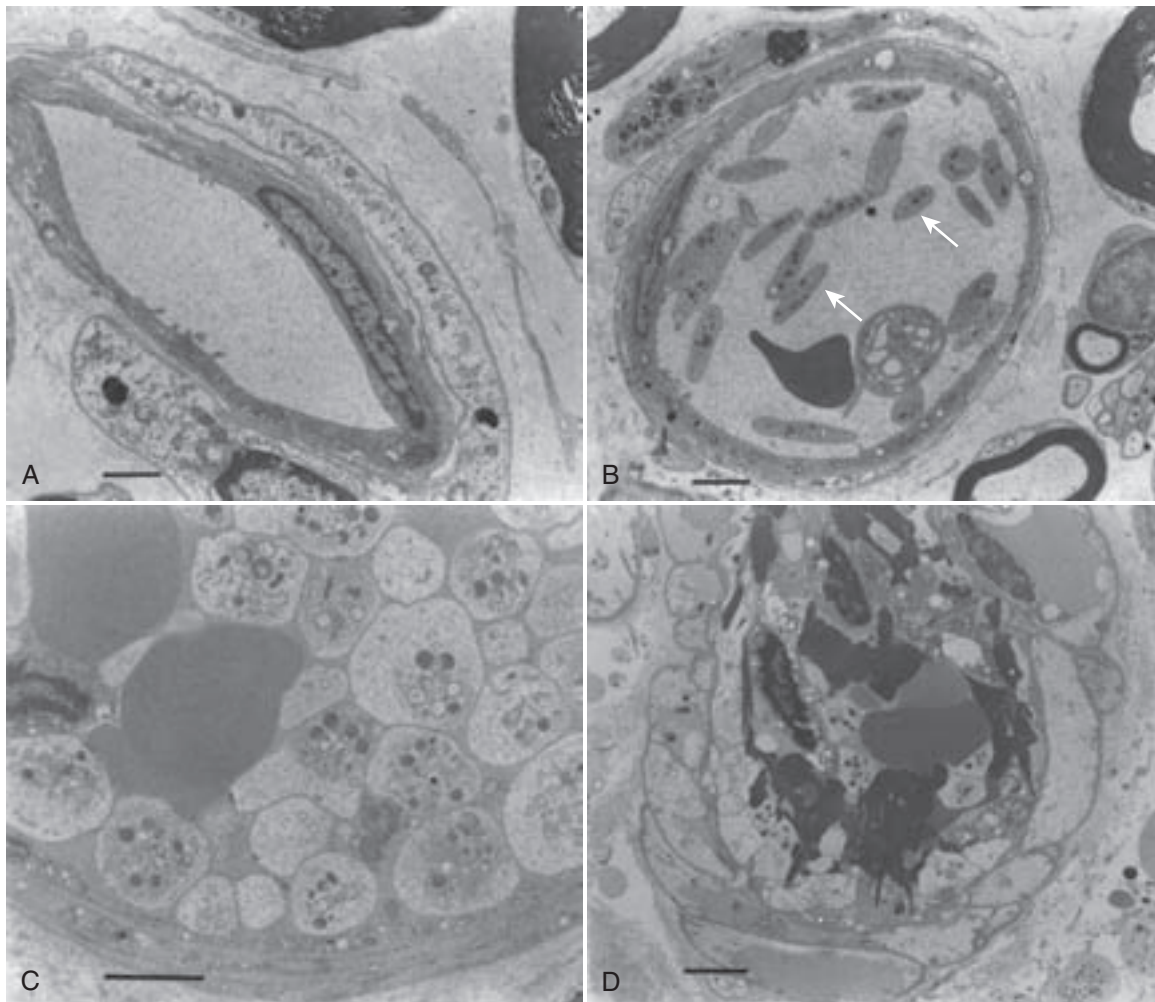
Nonfreezing cold injuries affect many different types of tissue. Pathologic examination of specimens displays a variety of lesions in skin, muscle, nerves, and bone.<sup>8,9,38</sup> Muscles exhibit separation of cells and damage to muscle fibers, described as acidophilic and hyalinized (Zenker’s hyaline degeneration). The myoplasm within muscle loses its cross striation, and the healing muscle appears to undergo fibrous tissue replacement.

One of the major pathologic processes in cold injury is progressive microvascular thrombosis following reperfusion of the ischemic limb, with cold-damaged endothelial cells playing a central role in the outcome of these cold-injured tissues.<sup>71</sup> Reperfusion of previously ischemic tissues causes free radical formation, leading to further endothelial damage and subsequent edema. With restoration of blood flow, there is reintroduction of oxygen species within cells that further damages cellular proteins, DNA, and the plasma membrane. Free radical species may also act indirectly in redox signaling to initiate apoptosis. Leukocytes may accumulate in small capillaries, obstructing them and leading to more ischemia.<sup>59</sup>

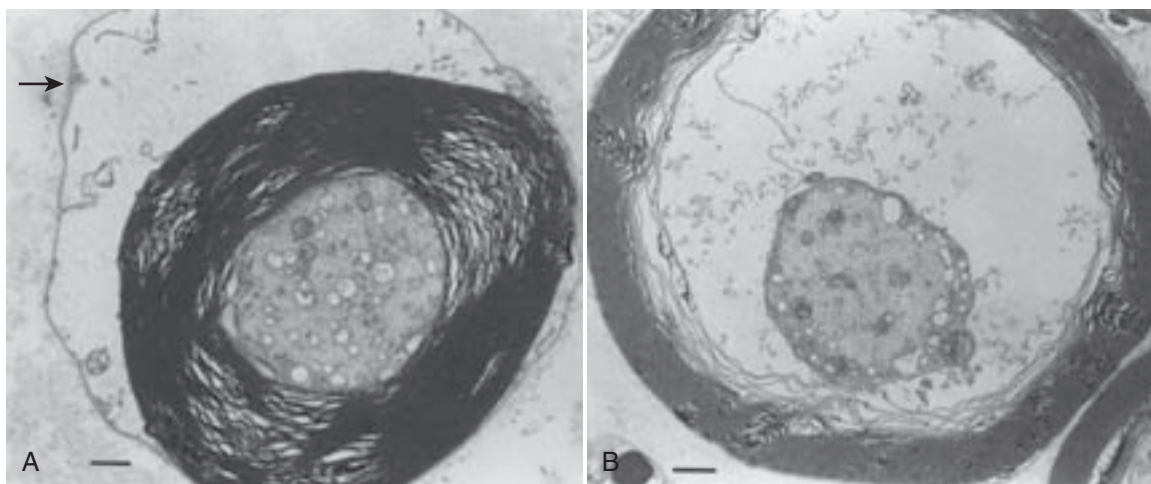
In an in vivo rabbit hind limb model subjected to 16 hours of cold immersion ( $1^{\circ}$  to  $2^{\circ}\text{C}$  [ $33.8^{\circ}$  to  $35.6^{\circ}\text{F}$ ]), there was



**FIGURE 7-3** Sciatic nerve epineurial microvessels before, during, and following nerve cooling ( $1^{\circ}$  to  $5^{\circ}\text{C}$  [ $33.8^{\circ}$  to  $41^{\circ}\text{F}$ ]). **A**, Normothermia. Arteriole (A), venule (V), and metarterioles (M) have a normal appearance. **B**, One hour after the commencement of nerve cooling the diameter of both the arteriole and venule are reduced by approximately 40%. Under a dissecting microscope, erythrocytes present a granular appearance in both vessels (arrows). Note occlusive aggregations (open arrow) in metarteriole and the suggestion of leukocyte clumping in the venule (arrow head). **C**, Two hours after nerve cooling, segmental occlusive aggregates are seen in the venule (arrows). The arterioles contain prominent rou-leaux (open arrows). **D**, Three hours after nerve cooling, there is stasis of flow in both vessels. An occlusive aggregate (arrow) is now seen in the arteriole, and those in the venule have extended (open arrows). **E**, After 1 hour of nerve rewarming ( $37.5^{\circ}\text{C}$  [ $99.5^{\circ}\text{F}$ ]), the venule still exhibits multiple segmental occlusions (arrows). Erythrocyte granulations (open arrows) in the arteriole indicate poor reperfusion. Bars represent 100  $\mu\text{m}$ . (From Jia J, Pollock M: *The pathogenesis of non-freezing cold nerve injury: Observations in the rat*, Brain 120:631, 1997.)



**FIGURE 7-4** Electron micrographs of endoneurial vessels in cooled sciatic nerve. **A**, An empty capillary with a degenerating pericyte 1 hour after nerve rewarming. Bar represents 2  $\mu\text{m}$ . **B**, Aggregating platelets (arrows) 24 hours after cooling. Bar represents 2  $\mu\text{m}$ . **C**, Platelets, adherent to the endothelium of a venule, show varying degrees of degranulation without pseudopod formation, 48 hours after nerve cooling. Two red blood cells are trapped within this platelet thrombus. Bar represents 1  $\mu\text{m}$ . **D**, A thrombus formed of platelets, red blood cells, and fibrin 5 days after nerve cooling. The blood vessel wall is necrotic. Bar represents 2  $\mu\text{m}$ . (From Jia J, Pollock M: *The pathogenesis of non-freezing cold nerve injury: Observations in the rat*, Brain 120:631, 1997.)



**FIGURE 7-5** Electron micrographs of cooled sciatic nerve fibers. **A**, A rat sciatic nerve fiber, 12 hours after nerve cooling, illustrating myelin unraveling and intramyelinic edema (arrow). **B**, A rat sciatic nerve fiber 2 days after cooling, exhibiting a shrunken axon and marked periaxonal edema. Bars represent 1  $\mu\text{m}$ . (From Jia J, Pollock M: *The pathogenesis of non-freezing cold nerve injury: Observations in the rat*, *Brain* 120:631, 1997.)

reduction in the number of myelinated nerve fibers of all sizes, most marked in large-diameter fibers, a feature consistent with ischemic neuropathy and reperfusion injury.<sup>54</sup> Unmyelinated fibers showed only minor damage. The resulting evidence has suggested that both of these mechanisms may contribute to the nerve injury. There is further extensive supporting evidence that established NFICI is associated with histologic and/or clinical evidence of nerve damage.<sup>27,30,59,76</sup>

Das and colleagues<sup>25</sup> demonstrated that quinacrine, an antioxidant, decreased damage to cell membrane phospholipids upon rewarming and reperfusion, although more recent studies<sup>97</sup> have shown no benefit from antioxidant use. Most importantly, both these studies used models that assumed that cold-induced nerve injury, rather than capillary or endothelial damage, is the primary cause of NFICI.

## CLINICAL PRESENTATION

Trench foot and immersion foot are clinically and pathologically indistinguishable but have different etiologies. The term *trench foot* originated during the trench warfare of World War I,<sup>110</sup> when soldiers wore wet boots and socks for prolonged periods.<sup>5</sup> Immersion foot was first medically documented during World War II among shipwreck survivors whose feet had been continuously immersed in cold water.<sup>21</sup> Both injuries occur when tissue is exposed to cold and wet conditions at temperatures ranging from 0° to 15° C (32° to 59° F). Colder temperatures decrease the time required to induce NFICI.<sup>10,92</sup> Severe nerve damage from immersion foot has been seen after exposure periods of 14 to 22 hours.<sup>103,104</sup> Immersion foot injury may extend proximally and involve the knees, thighs, and buttocks, depending on the depth of immersion.<sup>111</sup> Clinically, NFICI is insidious in onset, with progression from initial exposure through three distinctive phases (prehyperemic, hyperemic, posthyperemic). These phases have variable time courses and may overlap.

### Prehyperemic Phase

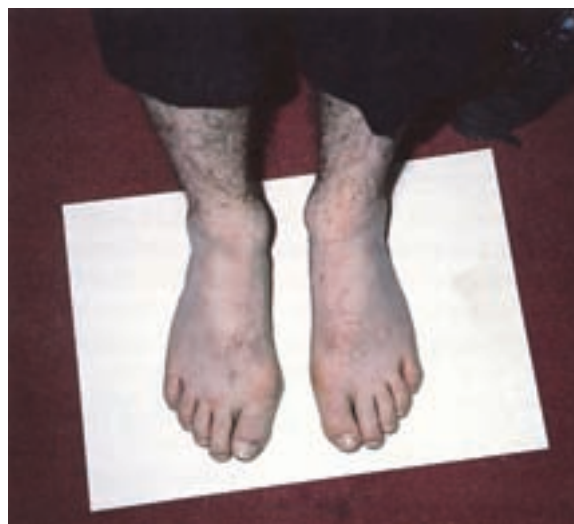During the prehyperemic phase, the affected limb, both during and immediately after cold exposure, appears blanched, yellowish white, or mottled but seldom blistered (Figure 7-7).<sup>104</sup> Whayne and DeBakey<sup>110</sup> state that the degree of edema during this prehyperemic stage is less severe if the feet are intermittently rewarmed during the course of exposure. Whereas muscle cramps are common, pain is rare.<sup>43,92</sup> The single most important diagnostic criterion is loss of a sensory modality, most typically complete local anesthesia, which is distinct from premonitory feelings of extreme cold in the affected periphery, almost invariably in the feet although hands can also be affected. With further exposure, the cold sensation leads to complete anesthesia with loss of proprioception, resulting in numbness and gait disturbances. This sensation has been described as “walking on air” or “walking on

cotton wool.”<sup>104</sup> Capillary refill is sluggish, and pedal arterial pulses are usually absent, except through Doppler examination.<sup>70</sup> Intense vasoconstriction is the predominant feature of this stage.<sup>46</sup>

### Hyperemic Phase

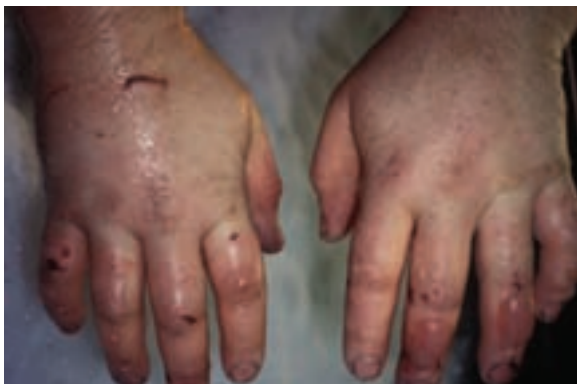Within several hours after rewarming, the extremities become hot, erythematous, painful, and swollen (Figures 7-8 to 7-11; [Figure 7-9, online](#)), with full bounding pulses.<sup>109</sup> Impairment of the microcirculation is evident through delayed capillary refill<sup>98</sup> ([Figure 7-12, online](#)) and petechial hemorrhages.<sup>45</sup> Sensation returns first to proximal regions and then extends distally, rapidly progressing to a severe, burning, or throbbing pain and reaching maximal intensity in 24 to 36 hours.<sup>103,104</sup> Affected areas have marked hyperalgesia to light touch. This pain is aggravated by heat and dependent positioning and often worsens at night, when even the pressure of sheets may become unbearable.<sup>46</sup> After 7 to 10 days, the nature of the pain changes to “shooting or stabbing.”<sup>103</sup> The sensory deficits usually diminish, but paresthesias continue, and anesthesia may be extensive on the toes and plantar foot surfaces.<sup>111</sup> Vibratory sensation is reduced or lost, whereas proprioception is usually retained. Anhidrosis coincides with the extent of sensory loss.<sup>98</sup>

Vascular injury is evident in vessel reactivity. Skin temperature gradients are absent, with digits often as warm or warmer than the groin or axillae. When the affected limbs are lowered, blood pools, turning the extremity a deep purple-red color, whereas

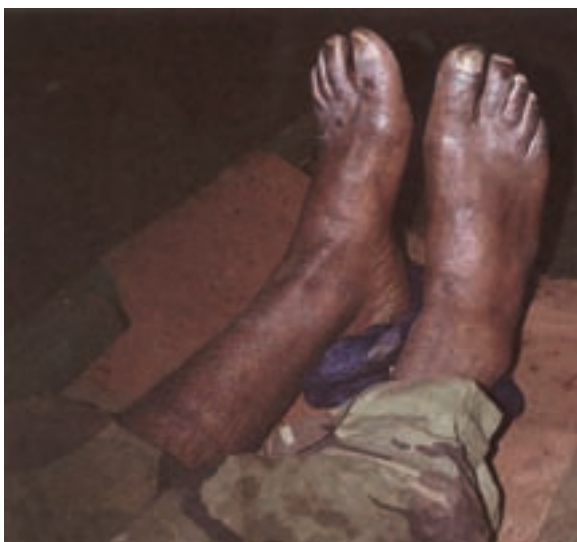

**FIGURE 7-7** Prehyperemic phase of immersion foot. These feet are still mostly numb and very cold to the touch. (British Crown Copyright/MOD.)

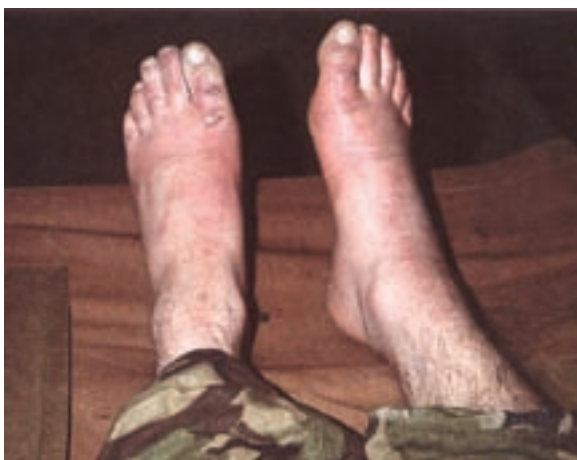blanching occurs when the limb is raised. Tense edema becomes marked during this stage. Blisters containing serous or hemorrhagic fluid may form, indicating more severe injury.<sup>98</sup> The superficial epidermis becomes thick, indurated, and desquamated. Eschars form (Figures 7-13 and 7-14) and eventually



**FIGURE 7-8** Hyperemic phase of nonfreezing cold injury. This person spent 18 hours during the winter bailing out a boat that threatened to capsize in Prince William Sound, Alaska. (Courtesy James O'Malley, MD.)



**FIGURE 7-10** Hyperemic phase of immersion foot. The characteristic redness of the stage is absent because of the pigmented skin, but the feet are swollen and painful. (British Crown Copyright/MOD.)



**FIGURE 7-11** Hyperemic phase in moderately severe nonfreezing cold injury. Swollen, red, and persistent pain in the feet of an infantry soldier from the Falklands War. (British Crown Copyright/MOD.)

slough, leaving a pink dermis (Figure 7-15). In more severe cases, the skin may become gangrenous (Figure 7-16). This is rare, and with appropriate care, gangrene is usually minimal.<sup>1,109,110</sup>

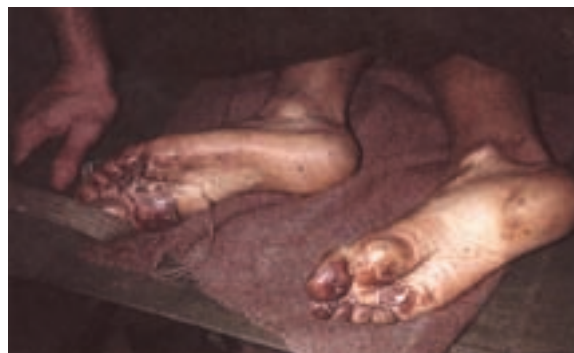Muscles may show weakness with impaired electrical responses, slowing of plantar deep tendon reflexes, and intrinsic muscle atrophy.<sup>103,104</sup> In milder cases, this stage peaks at 24 hours; in more severe cases, the hyperemic phase may take 6 to 10 weeks to resolve.<sup>98</sup>

### Posthyperemic Phase

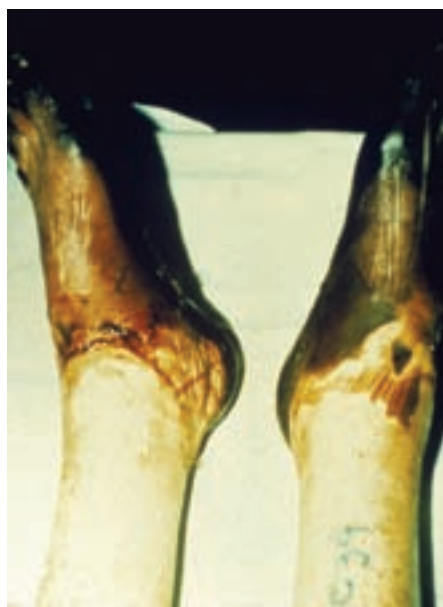The posthyperemic phase lacks obvious physical signs. In mild cases, this phase may be absent<sup>104</sup>; in other cases, it may last weeks, months, or years after the hyperemic phase has subsided.<sup>70,103</sup> The extremities transition from a consistent warmth to noted coolness, with affected areas becoming cold sensitive, remaining so for hours after exposure despite normal warming processes.

After 6 to 10 weeks, patients often complain of spontaneous hyperhidrosis, and sweat rashes are common in areas with heavy perspiration.<sup>103</sup> On a warm day, socks are quickly soaked; extremities may sweat excessively, even when cold. Hyperhidrosis predisposes to chronic paronychia infections. Sweating may be more pronounced at the margins of anhidrotic and analgesic areas.<sup>104</sup>

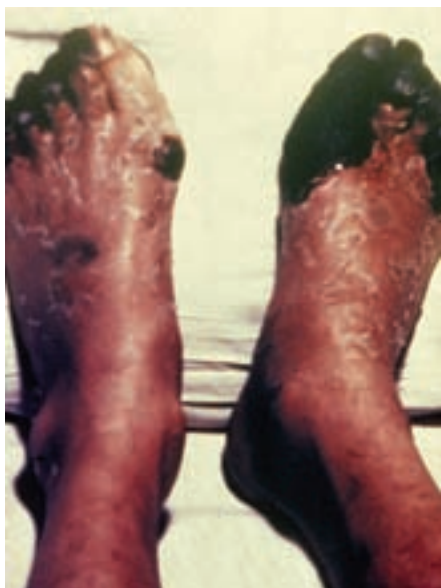During the posthyperemic phase, the paresthesias and extreme pains typical of the hyperemic phase have usually resolved, replaced by dull aches and anesthesia that may persist for months to years.<sup>110</sup> Recurrent edema of the feet, return of paresthesia,



**FIGURE 7-13** Severe nonfreezing cold injury. This Argentinian soldier had been unable to care for his feet for many weeks. (British Crown Copyright/MOD.)



**FIGURE 7-14** Severe nonfreezing cold injury in an Argentinian mine layer who wore his boots for 47 straight days during the Falklands War. (Courtesy M.P. Hamlet.)



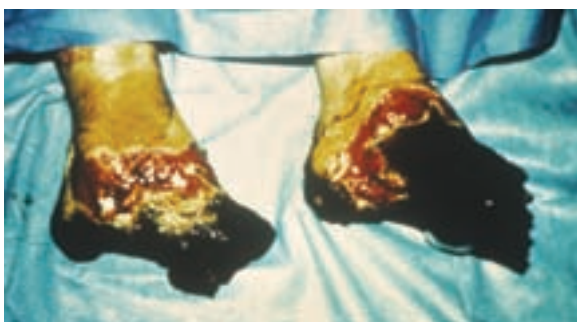**FIGURE 7-15** Severe nonfreezing cold injury in a British sailor during World War II. (Courtesy M.P. Hamlet.)

and further blistering are common, especially after long walks. Intrinsic muscle and ligament atrophy tend to resolve,<sup>104</sup> but in severe cases, fibrous scarring may lead to rigidity and permanent contracture of the toes.<sup>111</sup> Decalcification of bones similar to that seen with osteoporosis is frequently observed.<sup>102</sup> Immobility and pain in severe cases may lead to prolonged convalescence of 6 or more months.<sup>111</sup>

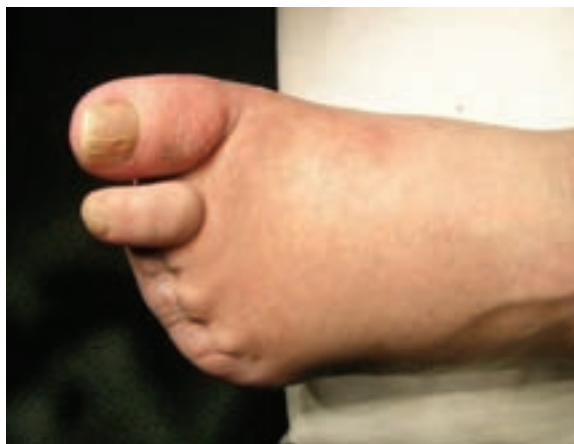In the most severe cases, gangrene can develop, and ablative surgery in the form of amputations of digits or even major lower limb amputation becomes necessary. Neuropathic tissue is susceptible to local trauma, ulceration, and eventually local osteomyelitis and sinus development (Figures 7-17 to 7-19). Appearance and behavior of the neuropathic foot have many similarities to those of the diabetic foot. In the diabetic foot, infections tend to be polymicrobial with *Staphylococcus aureus*, *Staphylococcus epidermidis*, and *Enterococcus* and *Streptococcus* species being most commonly isolated from bone culture. However, aerobic gram-negative rods (such as *Pseudomonas aeruginosa*) and obligate anaerobic species may be found.<sup>52</sup> Partial foot amputations may result in significant alterations in functional biomechanics of the foot. Because this is often associated with alterations in the sensory nerve supply to the feet, ongoing disabling problems can persist (Figure 7-20).<sup>52</sup>

#### More Severe Injuries

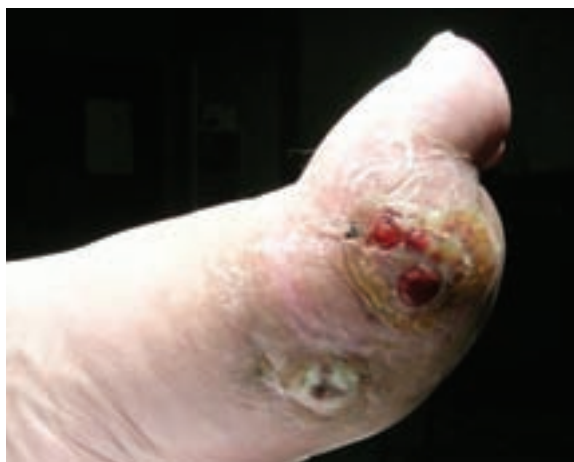NFCI can vary in severity from mild to severe. In severe cases, cold sensitization is so serious that individuals are unable to work outside. There is often persisting edema and hyperhidrosis, making the individual susceptible to fungal infections. Chronic pain may resemble causalgia or reflex sympathetic dystrophy. The profound sensory neuropathic foot can develop ulcerations



**FIGURE 7-16** The Argentinian mine layer seen in Figure 7-14, several weeks later. (Courtesy M.P. Hamlet.)

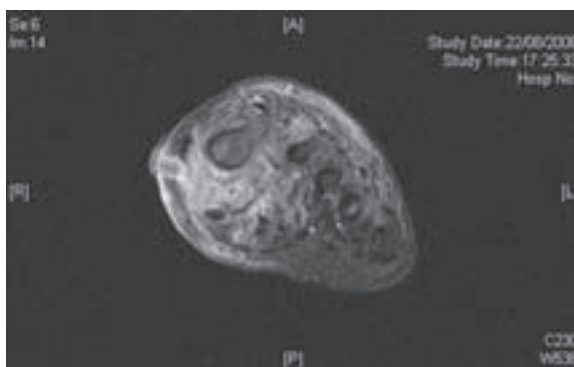


**FIGURE 7-17** Patient 24 months after nonfreezing cold injury. Amputation of third, fourth, and fifth toes on the left foot. (Courtesy Christopher H.E. Imray, MD.)



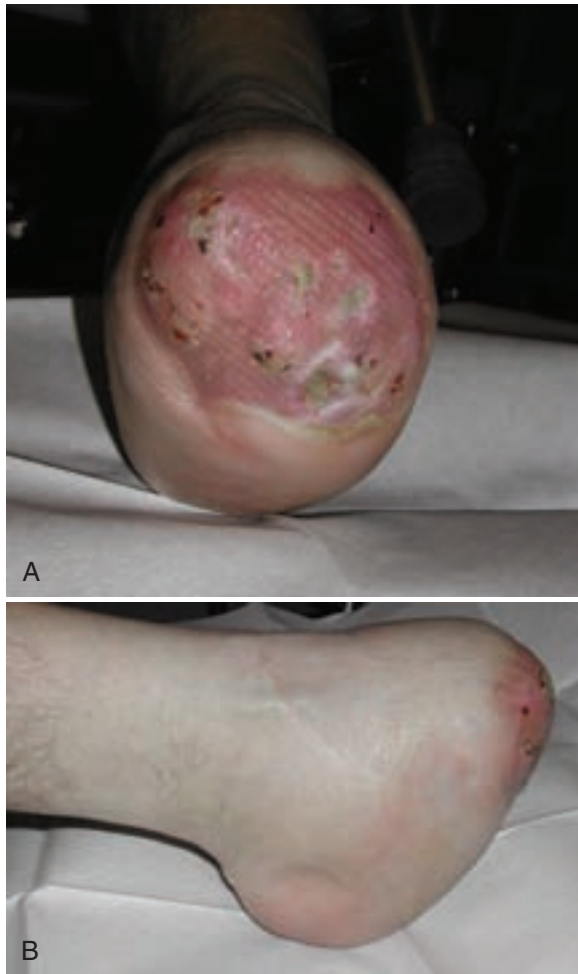
**FIGURE 7-18** Same patient as in Figure 7-17, 24 months after nonfreezing cold injury with chronic discharging sinuses from osteomyelitis of the first metatarsal. (Courtesy Christopher H.E. Imray, MD.)

and tissue loss, ultimately resulting in either minor or major lower limb amputation. Ongoing care with a foot specialist who can arrange for custom-made shoes and insoles appears to improve functional outcome. Multidisciplinary team approaches to coordinating care leading to healing of the ulcerated neuropathic foot using patella weight-bearing orthoses has been described.<sup>63</sup> NFCI pain is often so severe as to require tricyclic antidepressants, which may need to be instituted at an early stage.<sup>51,98</sup> Failure to do so increases the risk for developing severe chronic pain resistant to all subsequent treatment modalities. Early involvement of



**FIGURE 7-19** Magnetic resonance imaging scan of the patient in Figures 7-17 and 7-18, 24 months after nonfreezing cold injury with chronic discharging sinuses from osteomyelitis of the first metatarsal head. (Courtesy Christopher H.E. Imray, MD.)





**FIGURE 7-20** A guillotine transmetatarsal amputation of the left foot was undertaken 6 months after severe nonfreezing cold injury. The patient was treated with delayed primary split-skin grafting. This photograph was taken 12 months after the original injury and shows that the split-skin graft has taken, but is now ulcerated as a result of the shear forces generated by walking on the insensate tissue. **A**, Transverse view from the bottom of the foot. **B**, Lateral view. (Courtesy Christopher H.E. Imray, MD.)

pain specialists is important. It is essential to control pain following NFCI at the earliest opportunity.

## TREATMENT

### Hypothermia

The treatment required for the general effects of cold is different from that needed for localized NFCI. Core temperature must be raised while the extremities are kept cool.<sup>109-111</sup> Injured feet should be elevated and exposed to steady cool air from a fan.<sup>109,111</sup> Extremity cooling lowers metabolic requirements to a point where vascular oxygen supply can sustain tissue demand. Continuous cooling brings rapid improvement in pain, edema, and vesiculation.<sup>109,111</sup> Local cooling should be continued until pain is relieved, circulation has recovered, and hyperemia subsides.<sup>111</sup> The affected extremities should never be rubbed, which may compound the injury.<sup>2</sup>

### Rewarming

Treatment is limited to symptomatic relief and reversing ischemia while minimizing progression of disease. Rewarming injured tissues increases metabolic demand of damaged cutaneous cells to a greater extent than can be provided by the supply capability of the injured subcutaneous blood vessels.<sup>111</sup> Tissue anoxia and endothelial cell injury, coupled with reflex vasodilation, lead to fluid transudation, increasing edema, skin necrosis, and worsening pain.<sup>109,111</sup>

### Sympathectomy

Recovery during the posthyperemic phase may be hastened with physiotherapy and exercise to rehabilitate atrophied intrinsic muscles.<sup>110,111</sup> Lumbar sympathectomy has been theorized to reduce disabling contracture by decreasing vascular tone, increasing circulation, and hastening collagen and fibrous tissue absorption. In severe cases of NFCI exhibiting atrophic rigid feet, small case studies have shown symptomatic improvement after sympathectomy,<sup>111</sup> but other clinicians feel that there is little therapeutic advantage to the procedure.<sup>109</sup>

### Tissue-Freezing Complications

Frostbite and NFCI injuries do not necessarily occur in isolation, so when assessing an individual, both diagnoses need to be entertained. Following exposure to severe cold, careful appraisal of the injury allows selection of optimal treatment.

### Drugs

Diagnosis of NFCI is often difficult or delayed. In view of involvement of the  $\alpha$ -receptors in the control of peripheral circulation and the apparent noradrenergic sensitization,<sup>36</sup> it was believed that vasodilators or  $\alpha$ -blocking drugs might be beneficial. However, there is no evidence to support this approach.

Because painful rewarming and persistent pain are features of NFCI, it is important to attempt to alleviate pain at an early stage. Although simple analgesics may be of benefit, Thomas and Oakley<sup>98</sup> observed that quinine sulfate (200 to 400 mg, given at night) appeared more successful than regular analgesics, although others have since commented that they are not useful. Since 1982, the standard treatment in the armed forces of the United Kingdom, first proposed by Riddell,<sup>85</sup> has been amitriptyline hydrochloride, in doses of 50 to 100 mg given at night. Incremental increases in dosage may be required with both drugs if pain breaks through after initial relief.<sup>37</sup>

## ASSESSING THE SEVERITY OF NONFREEZING COLD-INDUCED INJURY

Following the initial injury, there develops increased sensitivity to cold. There are often few objective clinical signs of a nonfreezing cold injury. A careful history of cold exposure, clear history of the typical rewarming symptoms and signs, detailed examination, and special investigations combine to build a case consistent with NFCI. Corroborative evidence of an appropriate cold exposure and symptoms consistent with NFCI from medical records is vital.

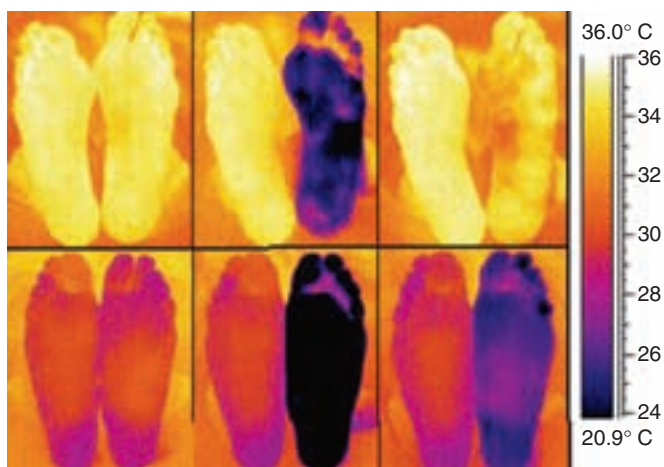
### Special Investigations

Infrared thermography can be used to assess the individual's response to a standardized cold stress and may be helpful in confirming the diagnosis, assessing the severity of injury, and monitoring recovery from NFCI (Figure 7-21). Although the infrared thermography test is used extensively by the UK military, it is not widely used elsewhere.<sup>50,57</sup> There appears to be significant intraindividual variability in the responses of some individuals to the current infrared thermography test. As a result, interest is shown in the use of gentle exercise before the infrared thermography cold sensitivity test and also in the use of laser Doppler flowmetry to try to improve the assessment used to classify nonfreezing cold injury.<sup>29</sup> Careful experimental design to validate any potential new tests against suitable controls, both preexposure and postexposure, will be required.

## PREVENTION

The simplest way to prevent NFCI is to avoid prolonged exposure to cold, wet environments. This can be difficult to achieve. During military conflict, completing the assigned mission may require performing in a cold, wet environment for sustained periods of time in cramped, immobile positions. During mountain rescues, individuals may be so focused on helping to save others that they do not take adequate care to prevent NFCI.

Prevention can be achieved by encouraging activities that promote blood flow to the feet, rotating personnel out of cold,



**FIGURE 7-21** Infrared thermography in the assessment of the consequences of nonfreezing cold injury. The upper sequence of three images was taken from an uninjured, asymptomatic control; the lower sequence from a patient who had sustained nonfreezing cold injury and subsequently complained of sensitivity. In both the control and patient, the first (left) image was taken after resting in ambient air temperature of 30°C (86°F). The second (center) image was taken immediately after the foot had been immersed in water at 15°C (59°F) for 2 minutes. The final (right) image was taken 5 minutes after removal from the water, again in 30°C (86°F) air. The upper series shows feet that were warm at rest, which rewarmed briskly after mild cold stress, and recovered almost completely within 5 minutes after removal from the water. The lower series shows a severe degree of cold sensitization; the feet were much colder than the surrounding air at rest, and once cooled, took a long time to rewarm, remaining much cooler than the control foot at 5 minutes after immersion. The scale at far right indicates the color-temperature relationship. (Copyright British Crown Copyright/MOD. Reproduced with the permission of Her Britannic Majesty's Stationery Office. From Thomas JR, Oakley HN: Nonfreezing cold injury. In Pandolf KB, Burr RE, editors: Textbook of military medicine: Medical aspects of harsh environments, vol 1, Washington, DC, 2002, Office of the Surgeon General, Borden Institute, pp 467-490.)

wet environments on a regular basis, keeping feet dry by early changing of wet socks, maintaining core body temperature by limiting sweat accumulation into clothing and dressing in layers, and by educating people about the early signs and symptoms of nonfreezing cold injuries. Changing socks two to three times during the day is mandatory in cold, wet environments. The military suggests that optimal care entails air drying feet for at least 8 hours out of every 24.<sup>14,116</sup> Vapor-barrier boots do not allow sweat to evaporate, and in some situations, this increases maceration.<sup>3</sup> These boots should be taken off each day, wiped to remove moisture and debris, and allowed to dry. Footwear should not constrict blood flow; sizing is important as is educating the user not to tie his or her shoelaces too tightly.

Prophylactic treatment with topical skin silicone preparations (antiperspirants) has proved effective.<sup>40</sup> The effect is believed to be caused by prevention of hyperhydration of the stratum corneum.<sup>14,28</sup> However, stickiness, adherence of sand and grit to the foot, and product bulkiness make this technique marginally acceptable to infantry soldiers in combat situations.<sup>40</sup> In small clinical trials, silicone ointment applied only to the sole of the foot instead of to the entire foot (thus reducing surface area exposed to dirt retention, amount of material transported by the soldier, and expense) was sufficient to prevent NFICI.<sup>28</sup>

As a consequence of the apparent increasing incidence of NFICI in the British military, preventive steps are being taken. These include improved education of recruits and existing personnel about prevention measures and equipment and early recognition. Well-designed equipment, supplied to appropriate personnel, and used in a timely and appropriate way should reduce the incidence of injury.

The severity of current UK military NFICI events appears to be relatively mild in comparison with civilian NFICI injuries (see Figures 7-17 to 7-19) and military historical controls (see Figures 7-13 to 7-16). This raises the question of whether (1) there is a

continuous spectrum of disease, (2) there is a bimodal distribution of the disease with milder and more severe forms of NFICI, or (3) the commonly presenting form is the same disease process that has been investigated in the past. Perhaps the lack of clarity lies in the UK military's decision to use infrared thermography as one of the bases for diagnosis, severity, and progression of NFICI. There appears to be a lack of published control data on subjects' prior response to cold exposure, so that the test cannot be compared with the normal variability in the population.

One approach would be to screen potential recruits. This requires a test with high sensitivity and specificity. However, individual variation in the control of peripheral blood flow is so great that no assessment currently available meets these requirements.<sup>12,22,24,98</sup>

Reducing the incidence of cold injury in military training requires striking a delicate balance between training, realism, and safety. Training in demanding environments runs real risks of injuring personnel, but the benefits to soldiers in their necessary field skills are vital if they are to avoid future NFICI.<sup>98</sup>

## Pernio (Chilblains)

Pernio (perniones), or chilblains, are localized, inflammatory, bluish red lesions caused by an abnormal reaction to a cold, damp environment. This mild form of cold injury is prevalent in the temperate climates of northwestern Europe,<sup>66</sup> and it is found worldwide throughout temperate and northern zones.<sup>41,69,70,79</sup> Pernio is less common in very cold climates where well-heated houses and adequate warm clothing are common.<sup>80</sup>

In a study of 111 patients, 67 (60.4%) were males and 44 (39.6%) were females. Eighty-nine (80.2%), 90 (81.1%), and 90 (81.1%) patients had onset in relation to lower temperature (<10°C [50°F]), relatively low atmospheric pressure (<1500 kPa), and higher relative humidity (>60%), respectively. Susceptibility to chilblains appeared to increase when ambient temperature was less than 10°C (50°F) and relative humidity more than 60%.<sup>84</sup>

Acute pernio has a seasonal incidence, with reversible symptoms more common in cold weather. The acute form is seen primarily in schoolchildren and young adults under the age of 20 years, with the highest incidence in adolescent females.<sup>66</sup> It can occur in mildly cold settings such as logging, kayaking, snowmaking,<sup>46</sup> winter horseback riding, and hiking.<sup>82</sup> Pernio can be caused by brief (30 minutes) cold exposure, often appearing several hours after exposure, with the skin lesions fully developed within 12 to 24 hours.<sup>79</sup> Characteristic locations for these lesions are the feet, hands, legs, and thighs. Single or multiple, erythematous, purplish, edematous lesions form, with vesicles in severe cases. Symptoms include intense pruritus, burning, or pain, often worsened by subsequent warmth. The lesions of acute pernio are self-limited and usually resolve within a few days to 3 weeks,<sup>80</sup> occasionally leaving residual hyperpigmentation.<sup>19</sup> Although the healing process appears to occur as the plaques resolve, pain often persists. Subsequent mild cold exposure may trigger paresthesias, edema, and skin scaling.<sup>46</sup>

Chronic pernio usually progresses over several winters after repeated episodes of acute pernio, rarely progressing from the initial injury to chronic irreversible skin changes within a single season.<sup>66</sup> Repeated episodic seasonal lesions may become edematous, with permanent discoloration and subcutaneous nodule formation. The nodules are firm and painful, ultimately rupturing, which provides pain relief and leaves a shallow ulcer with pigmented atrophic skin. These ulcers may grow larger and coalesce, remaining open, which leads to permanently swollen extremities, scaly pigmented skin, and unremitting pain aggravated by light pressure.

Pernio is believed to be caused by prolonged cold-induced vasoconstriction with subsequent hypoxemia and vessel wall inflammation.<sup>41,55</sup> Subcutaneous arterial vasoconstriction is documented by both pathologic<sup>66</sup> and arteriographic studies.<sup>93</sup> Histologic examinations show a lymphocytic vasculitis and papillary dermal edema with pervasive inflammatory changes.<sup>41,55,66</sup> The differential diagnosis includes lupus erythematosus, Raynaud's disease, polycythemia vera, atheromatous embolization, erythema nodosum, and livedo vasculitis with ulcerations.

Treatment of pernio is accomplished by drying and gently massaging the affected skin. Active warming above 30°C (86°F) significantly worsens the pain and should be avoided.<sup>46</sup> Although therapeutic regimens in the literature include nicotinic acid,<sup>42</sup> ultraviolet irradiation,<sup>48</sup> thymoxamine,<sup>56</sup> intravenous calcium combined with intramuscular vitamin K,<sup>34</sup> corticosteroids,<sup>39</sup> and sympathectomy in severe cases,<sup>66</sup> few have proved to be either effective or universally accepted. Recently, nifedipine (20 mg, 3 times daily) has been shown to be effective for treatment of severe perniosis. Patients treated had a significantly reduced time for clearance of lesions, decreased pain and irritation of existing lesions, and less development of new pernio.<sup>41,86</sup>

Preventing pernio is relatively simple. Recommended prophylactic measures include minimizing cold exposure with suitable clothing when outdoors and maintaining adequate warm temperatures indoors.

## Cryoglobulinemia

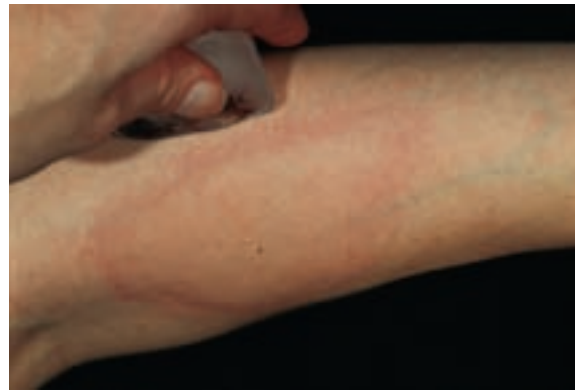Cryoglobulins are cold-precipitable serum immunoglobulins.<sup>96</sup> These cryoimmunoglobulins were first reported in a patient with multiple myeloma<sup>115</sup> and were subsequently recognized to occur in a diverse group of hematologic malignancies, acute and chronic infections, and collagen vascular diseases.<sup>94,106</sup> Cryoglobulins are classified as three types. Type I cryoglobulins (10% to 15% of total) are composed of a monoclonal immunoglobulin, primarily IgG. Type II cryoglobulins (50% to 60% of total) are polyclonal, most frequently IgG and IgM. The IgM fraction usually has rheumatoid factor activity. Type III cryoglobulins (25% to 30% of total) are also composed of polyclonal IgG and IgM fractions.

In general, the higher the protein concentration, the higher the temperature at which precipitation begins. Of clinical relevance is the composition of the cryoprecipitate. For example, IgM is intrinsically more viscous than is IgG, and patients with monoclonal IgM cryoglobulin have an amplified hyperviscosity. Because extremity temperatures can reach 30°C (86°F), *in vivo* cryoprecipitation may directly contribute to impaired capillary blood flow.<sup>46</sup>

There are many clinical conditions that are associated with cryoglobulinemia.<sup>96</sup> Infections (viral, bacterial, fungal, parasitic), hematologic diseases (chronic lymphocytic leukemia, multiple myeloma), and autoimmune diseases (rheumatoid arthritis, pulmonary fibrosis, inflammatory bowel disease) are all associated with cryoglobulinemia. Hepatitis C is considered a principal trigger of cryoglobulinemia. Serum cryoglobulin values do not usually correlate with clinical severity or disease prognosis<sup>96</sup> but may serve as a marker of the disease.

Cryoglobulinemia is characterized by a clinical triad of purpura, weakness, and arthralgias. A large clinical trial showed that two-thirds of patients diagnosed with cryoglobulinemia initially presented with symptoms of skin lesions or Raynaud's disease-like vasomotor attacks. Mucosal bleeding, visual disturbances, and abdominal pain were less common. Cold sensitivity was apparent in less than one-half of these patients.<sup>13</sup> Symptoms associated with cryoglobulins include typical Raynaud's phenomenon, dependent purpura, cutaneous vasculitis with ulceration, retinal hemorrhages, coagulopathies, glomerulonephritis, renal failure, and cerebral thrombosis.

Treatment of cryoglobulinemia should be directed at the severity of the symptoms and to the disease causing the cryoglobulinemia. Because hepatitis C virus (HCV) is implicated in many cases of types II and III cryoglobulinemia, targeting HCV is the treatment of choice to eliminate cryoglobulinemia. Interferon, prednisone, and ribavirin have all been used to treat HCV and associated cryoglobulinemia. For non-HCV-associated cryoglobulinemia with mild to moderate symptoms (purpura, arthralgia, sensory neuropathy), immunosuppression with corticosteroids and analgesics is the treatment of choice.<sup>96</sup> A low-antigen-content diet (rice, fresh vegetables, fruit, tea) has been shown to improve purpura.<sup>81</sup> With severe manifestations of disease such as renal failure, neurologic impairment, disabling paresthesias or myalgias, plasmapheresis may be helpful in reducing the cryoimmunoglobulin concentration below a critical point to alleviate symptoms.<sup>13</sup> Plasmapheresis is used in conjunction with corticosteroids or other drugs, because discontinuing



**FIGURE 7-22** Cold urticaria. The hives occurred within minutes of holding an ice cube against the skin. (From Habif TP: *Clinical dermatology*, ed 4, Philadelphia, 2004, Mosby, with permission.)

plasmapheresis treatment usually causes reappearance of the cryoglobulinemia.<sup>96</sup>

## Cold Urticaria

Cold urticaria is a physical urticaria characterized by development of either localized or generalized wheals and itching after skin exposure (air, liquid, object) to cold<sup>89</sup> (Figure 7-22). It most frequently affects young adults with a duration of 4 to 5 years, although primary cold urticaria can occur at any age. Women are twice as likely to be affected.<sup>90</sup> The incidence rate is approximately 0.05% of the population.

Symptoms are usually limited to cold-exposed skin areas.<sup>89</sup> Local symptoms include redness, itching, wheals, or edema of the exposed skin. The wheals last approximately 30 minutes. Systemic reactions can also occur, and symptoms of this include fatigue, headache, dyspnea, and hypotension. Swimming in cold water is the most common trigger of severe reactions. This may lead to hypotension, fainting, shock, and possibly death.<sup>7,45</sup> Suffocation may also occur after consuming cold drinks as a result of pharyngeal angioedema.<sup>89</sup>

Secondary urticaria occurs in 5% of patients with cold urticaria.<sup>45</sup> The wheals are more persistent and may be associated with purpura and vasculitis on skin biopsy. This disorder is associated with an underlying disorder such as cryoglobulinemia, cold agglutinins, paroxysmal hemoglobinuria, or connective tissue disease.<sup>107</sup> In addition, there is a rare autosomal dominant familial form that has its onset in infancy and is associated with arthralgias and leukocytosis.<sup>108</sup>

The cause of cold urticaria is unknown. Cold urticaria has been associated with viral or bacterial infections,<sup>89,90</sup> as well as infections of the upper respiratory tract, teeth, and urogenital tract. It has been reported to involve the release of histamine,<sup>60</sup> leukotrienes, and other mast-cell mediators,<sup>90</sup> possibly mediated by IgE and IgM. Support for an IgE-mediated mechanism comes from successful treatment<sup>11</sup> using an anti-IgE (omalizumab). The diagnosis of cold urticaria is made through the ice cube test in the majority of patients,<sup>74</sup> in which a hive is induced by holding an ice cube to skin for 3 to 5 minutes. If the results are equivocal, a cold-water immersion test of submerging a forearm for 5 to 15 minutes in water at 0° to 8° C (32° to 46.4° F) establishes the diagnosis.

Treating cold urticaria with antihistamines is the most effective option. However, to sufficiently reduce symptoms may require dosing up to four times the recommended dose.<sup>75,89,90</sup> In addition, other therapies include leukotriene antagonists, cyclosporine, corticosteroids, and anti-IgE.<sup>90</sup> Individuals with severe reactions should have an emergency kit containing corticosteroids, antihistamines, and epinephrine. Based on the finding that infectious disease may be a trigger for cold urticaria, earlier treatment with antibiotics for infectious diseases may also be warranted.<sup>90</sup>

## REFERENCES

Complete references used in this text are available online at [www.expertconsult.com](http://www.expertconsult.com).