

Heterotopic Ossification in Wartime Wounds

LCDR Jonathan Agner Forsberg, MD,^{1,2} and MAJ Benjamin Kyle Potter, MD¹⁻³

Heterotopic ossification (HO) refers to the formation of mature lamellar bone in nonosseous tissue. In the setting of high-energy wartime extremity wounds, HO is expected to complicate up to 64% of patients, has a predilection for the residual limbs of amputees, and remains a significant source of disability. Although the inciting events and the definitive cell(s) of origin continue to remain elusive, animal models and human histology samples suggest that HO formation follows a predictable sequence of events culminating in endochondral ossification. Primary prophylaxis is not medically or logistically practical in most cases because patients have generally sustained massive wounds and are undergoing serial debridements during an intercontinental aeromedical evacuation. Surgical excision of symptomatic lesions is warranted only after an appropriate trial of conservative measures and is associated with low recurrence rates in appropriately selected patients. Future research regarding prognostication and defining the early molecular biology of ectopic bone may permit individualized prophylaxis and development of novel targeted therapies. (Journal of Surgical Orthopaedic Advances 19(1):54–61, 2010)

Key words: heterotopic ossification, trauma, war wounds

The term heterotopic ossification (HO) refers to the formation of mature lamellar bone in nonosseous tissue. In moderate and severe cases, this disorder can lead to significant disability, though most cases are mild and asymptomatic. Classically, HO is associated with severe systemic insults including spinal cord injury, traumatic brain injury, and neoplasm (1–8). Also, HO forms as sequelae to hip arthroplasty and fractures of the acetabulum or elbow, particularly those requiring operative fixation (9–12). These associations imply a relationship between HO and muscle traumatized due to injury and/or

surgical dissection (9, 12–20). Less common causes of heterotopic bone formation include the genetic disorders fibrodysplasia ossificans progressiva and progressive osseous heteroplasia (21–23). Although both proven risk factors and genetic predispositions exist, the underlying cause(s) of HO, the initiating molecular biology, and the cellular origin remain largely unknown.

The Combat Wounded Population

Recently, HO has been observed to be more common than previously reported in patients sustaining high-energy wartime extremity wounds (24–26). Blasts and high-velocity projectiles inflict a high percentage of modern war wounds and predominately affect the extremities (27–38). This injury mechanism results in a unique injury pattern — one comprised of severely traumatized limbs, open fractures, and extensive zones of injury with frequent bone and soft tissue loss, often in association with both gross foreign body and bacterial contamination. Serial debridement procedures are performed every 24–72 hours prior to definitive wound closure or coverage in an effort to remove devitalized tissue and gross contamination. Antibiotic-impregnated polymethylmethacrylate beads are routinely used to reduce the bacterial bioburden, as are negative pressure wound dressings. Despite the severity of these injury patterns, patient survival approaches 90%, due in part to improved body armor, the judicious use of tourniquets, and a robust casualty treatment and evacuation system (39).

From ¹Regenerative Medicine Department, Combat Casualty Care, Naval Medical Research Center, Silver Spring, MD; ²Department of Surgery, Uniformed Services University of Health Sciences, Bethesda, MD; ³Integrated Department of Orthopaedics and Rehabilitation, Walter Reed National Military Medical Center, Bethesda, MD. Address correspondence to: Lcdr Jonathan Agner Forsberg, MD, Regenerative Medicine Department, Combat Casualty Care, Naval Medical Research Center, 503 Robert Grant Avenue, Silver Spring, MD 20910; e-mail: jaforsberg@mac.com.

Each author certifies that his institution has approved the human protocol for this investigation and that all investigations were conducted in conformity with ethical principles of research. The views expressed in this article are those of the authors and do not necessarily reflect the official policy or position of the Department of the Army, Department of the Navy, Department of Defense, or the United States Government.

This work was supported by the US Navy Bureau of Medicine and Surgery under the Medical Development Program (PE 0604771N).

Received for publication September 8, 2009; accepted for publication October 5, 2009.

For information on prices and availability of reprints call 410-494-4994 X226.

1548-825X/10/1901-0054\$22.00/0

Copyright © 2010 by the Southern Orthopaedic Association

Report Documentation Page

Form Approved
OMB No. 0704-0188

Public reporting burden for the collection of information is estimated to average 1 hour per response, including the time for reviewing instructions, searching existing data sources, gathering and maintaining the data needed, and completing and reviewing the collection of information. Send comments regarding this burden estimate or any other aspect of this collection of information, including suggestions for reducing this burden, to Washington Headquarters Services, Directorate for Information Operations and Reports, 1215 Jefferson Davis Highway, Suite 1204, Arlington VA 22202-4302. Respondents should be aware that notwithstanding any other provision of law, no person shall be subject to a penalty for failing to comply with a collection of information if it does not display a currently valid OMB control number.

1. REPORT DATE 2010	2. REPORT TYPE	3. DATES COVERED 00-00-2010 to 00-00-2010			
4. TITLE AND SUBTITLE Heterotopic Ossification in Wartime Wounds		5a. CONTRACT NUMBER			
		5b. GRANT NUMBER			
		5c. PROGRAM ELEMENT NUMBER			
6. AUTHOR(S)		5d. PROJECT NUMBER			
		5e. TASK NUMBER			
		5f. WORK UNIT NUMBER			
7. PERFORMING ORGANIZATION NAME(S) AND ADDRESS(ES) Naval Medical Research Center, Regenerative Medicine Department, 503 Robert Grant Avenue, Silver Spring, MD, 20910		8. PERFORMING ORGANIZATION REPORT NUMBER			
9. SPONSORING/MONITORING AGENCY NAME(S) AND ADDRESS(ES)		10. SPONSOR/MONITOR'S ACRONYM(S)			
		11. SPONSOR/MONITOR'S REPORT NUMBER(S)			
12. DISTRIBUTION/AVAILABILITY STATEMENT Approved for public release; distribution unlimited					
13. SUPPLEMENTARY NOTES					
14. ABSTRACT					
15. SUBJECT TERMS					
16. SECURITY CLASSIFICATION OF:			17. LIMITATION OF ABSTRACT	18. NUMBER OF PAGES	19a. NAME OF RESPONSIBLE PERSON
a. REPORT unclassified	b. ABSTRACT unclassified	c. THIS PAGE unclassified			

The incidence of HO in combat-wounded service members has consistently been reported as 63%–64.6%, far greater than that described in civilian trauma centers. Formation of HO in this patient population is associated with blast injuries, a combat-related amputation within the zone of injury, and injury severity scores greater than 16 (24, 26). In contrast, the largest civilian series examining fracture care and HO found that ectopic bone complicated the extremities in 11% of severe traumatic brain-injured patients and 20% of spinal cord injuries (40). Earlier work in civilian patients reported baseline rates of ectopic bone growth in various long-bone fractures, including forearm fractures (20%) (16), femoral shaft fractures (52%) (41), and tibial shaft fractures (0%) (42), all in the setting of significant head injury. The authors are aware of no consensus regarding the rate of heterotopic ossification in civilian long-bone extremity trauma without concomitant head injury. Nevertheless, the incidence of clinically relevant or symptomatic HO in this setting is generally considered to be low (7, 43–45).

Amputees

The predilection of heterotopic bone for growth within the residual limbs of amputees is an important recent observation (24, 26). Definitive amputations are often performed within or near the zone of injury (which is extensive in blast injuries) in an effort to preserve residual limb length, joint levels, and subsequent function. As a result, there exists a strong association between these injuries and the subsequent development of both radiographic and symptomatic HO (26).

Several grading classification systems exist to classify its formation about the hip, knee, and elbow (5, 9, 10, 20, 46–48). These were later extrapolated to other joints, but none apply or adapt directly to the residual limbs of amputees. For these patients, a classification system,

originally described by one of the authors (BKP) has been adopted. The severity of HO is graded using the single radiographic projection (anteroposterior, lateral, or oblique) that maximizes the extent of the ectopic bone within the soft tissues of the residual limb. For example, ectopic bone formation is considered to be mild if it occupies less than 25%, moderate if it occupies 25%–50%, and severe if it occupies >50% of the soft tissues on a single radiographic projection (Fig. 1).

Basic Science Efforts

Recent HO research by Gannon and others (49) has successfully identified genetic mutations that localize to chromosome 4q (27–31). Although the BMP4 gene itself does not harbor a genetic mutation, overexpression of BMP4 and its receptor BMPRIA coupled with underexpression of its antagonists is thought to be required for HO formation (49–52). This phenomenon, first identified in patients with fibrodysplasia ossificans progressiva, firmly establishes a link between some forms of HO and traditional osteoblastic signaling. Davis, in association with Gannon (53), further defined the microenvironment by identifying the presence of brown (hypoxic) adipocytes in the early stages of HO development. The hypoxic environment induces both chondrogenesis and neovascularization. The result is an increase in oxygen tension enabling endochondral ossification to occur. Nesti and coauthors (54) isolated a population of mesenchymal progenitor cells present in traumatized muscle. The authors concluded, based on their ability to demonstrate pluripotency, that these cells may play a central role in the pathologic osteogenic response. The team also noted that the progenitor cells derived from traumatized muscle had a certain propensity to become osteoprogenitor cells, more so than those derived from non-age- or sex-matched geriatric bone marrow donors (55). They further concluded that

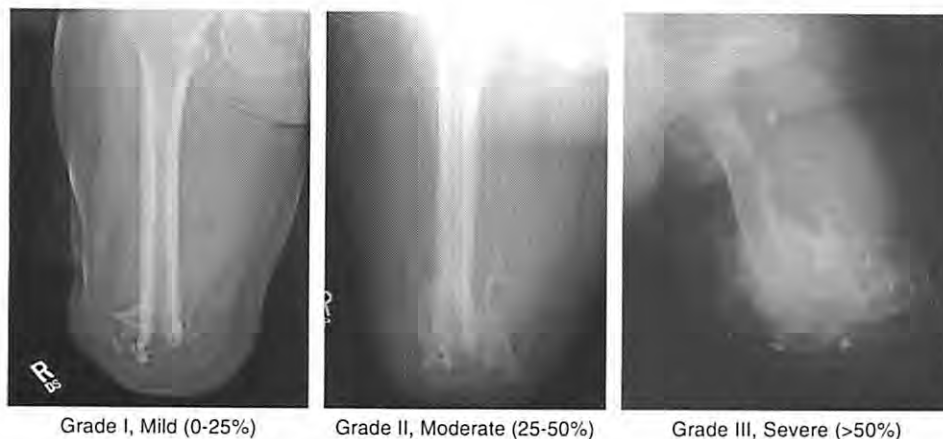


FIGURE 1 Walter Reed classification of heterotopic ossification in residual limbs of amputees.

muscle-derived progenitor cells are the “putative osteo-progenitor cells that initiate ectopic bone formation in HO,” but provided no suitable justification for this conclusion and thus the matter requires further study. In another study, Lounev and others (56) implicate progenitor cells of a vascular lineage. It is therefore plausible that more than one source of progenitor cells plays a role in the initiation of ectopic bone formation, either as the cells of origin or the source of the sentinel cellular signals, but the precise inciting event(s) and cellular origin(s) remain elusive.

Ongoing studies from our own institutions examine sera, tissue, and wound effluent from high-energy wartime extremity wounds. We are developing predictive biomarker and gene-based profiles for HO formation in these patients. These profiles will permit the early identification of patients most at risk for HO via computer-based algorithms, potentially allowing aggressive primary prophylaxis. We are characterizing the differentiation propensity and genetic expression of muscle-derived progenitor cells isolated from high-energy wounds, compared to age- and sex-matched healthy controls. Finally, we have successfully induced stem-cell production of bone in vitro utilizing patient sera and wound effluent, with the composite goal of identifying molecular triggers of HO production, evaluating therapeutic targets, and developing and testing novel preventative treatments.

Factors Associated With HO Formation

The Injury Severity Score (ISS) is associated with the development of HO (24, 57). Critics of ISS utility as a prognostic factor for HO growth argue that head-injured patients score higher and therefore are inherently more likely to develop heterotopic bone. However, Steinberg and coauthors (43) reported that the ISS, independent of a head injury, remained an important predictor of the development of HO in a civilian trauma population after intramedullary nailing of femoral fractures. These findings add to the growing body of evidence suggesting that systemic factors, arguably related to the degree of systemic inflammation, initiate or contribute to an exaggerated osteogenic response that may ultimately be responsible for the development of heterotopic bone.

The association between heterotopic bone growth and the number and method of surgical debridement procedures, including the use of intermediate-pressure pulsatile lavage irrigation devices and negative pressure wound therapy, is not well understood. Two recent studies reported trends toward an association between HO formation and the number of debridement procedures as well as the duration of negative pressure dressing therapy (24, 26). However, these results should be interpreted with caution because the increases in both the number

of debridement procedures and the duration of negative pressure dressing therapy are ostensibly also indicators of greater local injury severity; therefore, establishment of a causal linkage between local ectopic bone and these wound care modalities is difficult and fraught with confounding factors.

The type of definitive fracture treatment (internal fixation, external fixation, or amputation) appears unrelated to the formation of HO in extremity trauma, despite an historic association with certain surgical approaches to the hip and acetabulum (9, 11, 15, 20, 58–62). This theoretical concern has not been borne out in clinical studies of extremity trauma (24).

Prophylaxis

Several randomized studies have documented the efficacy of primary prophylaxis for the prevention of HO. This type of prophylaxis is given following high-risk index procedures, such as revision total hip arthroplasty or operative fixation of acetabular fractures (63–73). Typically, 5–10 Gy of local radiation therapy is dosed in a single fraction, with or without nonsteroidal anti-inflammatory medication. Nonsteroidal anti-inflammatory medications alone can be expected to provide a cost-effective, dose-related decrease in heterotopic bone formation, though the risk of treatment-related complications (i.e., gastrointestinal, renal, or hemorrhagic), as well as patient noncompliance, appears higher (64, 74). Although some randomized series have demonstrated no difference in ectopic bone formation between nonsteroidal treatment and radiation therapy (63, 69, 72), the bulk of the literature, including two meta-analyses, modestly favors radiation therapy, arguably related to compliance issues with medical treatment (67, 73, 75, 76). Two randomized series found no difference between preoperative and postoperative radiation when dosing single fraction of 7–10 Gy, provided it is given less than 4 hours prior or 48 hours after surgery (65, 71).

Evidence supporting secondary prophylaxis following excision of symptomatic HO is lacking. The authors are aware of no randomized trials of any secondary prevention modality. Nevertheless, the rate of recurrence in the appropriate surgical candidate is generally accepted to be low, and the theoretical benefit of secondary prophylaxis outweighs the risks of symptomatic recurrence for most patients.

Pitfalls of Prophylaxis

The use of the aforementioned methods of primary and secondary HO prophylaxis is not without consequence. Following radiation therapy, wound- and implant-related

complications have been reported (60, 73). Considering the relatively high prevalence of wound and fracture-related complications in patients with high-energy penetrating extremity wounds, external beam radiation is theorized to result in an unacceptably high wound complication rate as well as potential untoward effects on fracture healing. As such, radiation as primary prophylaxis for HO remains highly controversial and is not currently recommended by the authors for use in this patient population.

Nonsteroidal anti-inflammatory drugs (NSAIDs) may also be problematic in certain patient populations. Cyclooxygenase-2 is required for endochondral bone formation, a mechanism critical to the development of heterotopic ossification, as well as early fracture healing (53). Concerns about NSAIDs in an orthopaedic population stem from this blunting of “helpful” inflammation necessary for endochondral ossification (77–81), leading to increased time to union and increase in the number of delayed unions in several studies (77, 78, 80–83). NSAIDs are also contraindicated in patients with intracranial vascular trauma that is common in severe traumatic brain and penetrating head injuries. The potential benefit of NSAIDs for HO prophylaxis must be weighed heavily against potential fracture-related complications. The authors, nevertheless, emphasize the importance of individualizing primary prophylaxis and that the concerns regarding fracture healing are somewhat moot in patients without long-bone fractures, including many amputees.

Etidronate is the only drug FDA approved for the primary prophylaxis of HO and thus warrants discussion. The FDA label states that etidronate is indicated following total hip replacement or spinal cord injury, though the drug has been evaluated off-label in other settings such as civilian orthopaedic extremity trauma and in burns. Etidronate blocks the aggregation, growth, and mineralization of hydroxyapatite crystals, necessary for the formation of heterotopic bone. Early randomized and pseudo-randomized trials demonstrated efficacy (84–89), but only as long as the drug was administered. “Rebound” formation of HO following cessation of therapy was common (84–87, 89), and follow-on studies failed to corroborate earlier results (90–92). In fact, a recent Cochrane database review did not demonstrate pharmacologic efficacy and could not recommend etidronate treatment for the primary prophylaxis of HO (93). Additionally, etidronate is relatively nonselective and inhibits osteoblasts as well as osteoclasts, prompting concerns similar to those applicable to NSAIDs, which are known to delay fracture healing in orthopaedic trauma patients. For these reasons, etidronate is infrequently utilized for primary HO prophylaxis in our patient population.

Treatment

The treatment of heterotopic ossification is individualized. Numerous series in many different patient populations report that most cases are mild and result in little or no functional impairment (10, 11, 14, 15, 17, 46–48, 57, 58, 62, 66–68, 70, 71, 74, 94–102). Moderate to severe cases can be highly debilitating, particularly in periarticular locations or in the residual limbs of amputees (26, 96, 103). Once heterotopic ossification has been identified by plain radiographs, one must assess the impact on the patient’s level of function and activities of daily living. In amputees, it is imperative that other likely sources of residual limb pain, such as painful bursae, myodesis failure, and neuromata, are identified and treated, prior to considering surgical management (104, 105).

Conservative management including rest, local and systemic medications, activity modification, and prosthetic socket/suspension modifications requires a multidisciplinary approach. Close consultation with skilled prosthetists, physical therapists, and physiatrists is critical. Likewise, in nonamputees, alternative causes of pain and functional limitations, including infection, fracture nonunion, and neuropathic pain syndromes, must be evaluated and treated. Surgical excision is reserved for pain, ulceration, or joint stiffness attributable to HO that remains refractory to exhaustive conservative measures.

Timing and Results of Excision

The timing of excision for symptomatic lesions remains controversial. Historically, excision was advocated only after prolonged observation ensuring that the ectopic bone was “mature,” as evidenced by quiescent three-phase bone scans and the relative normalization of the serum alkaline phosphatase (106–108). This practice has long been questioned because these measures do not accurately predict recurrence (5). Numerous other studies support earlier excision based on the roentgenographic appearance of the lesion(s) (26, 109–119). This approach has been shown to allow earlier range of motion and return of functional mobility, with recurrence rates similar to that of late excision (110). Garland (5) identified other prognostic factors for HO excision in patients with head injuries, using a classification system based on the patient’s cognitive and physical disability. In his series, motion-related outcomes and recurrence rates were excellent in classes I and II and uniformly poor, with a 100% recurrence rate, in class V. He theorized that the latter group of patients possessed a systemic osteogenic stimulus, possibly the result of a prolonged systemic inflammation, which may persist for years after the initial injury. Knowledge of this can help set patient and family expectations, particularly in cases involving severe traumatic brain injury.

After appropriate patient selection and preoperative counseling, we advocate surgical excision as soon as symptoms warrant following appropriate efforts at conservative management. Regarding the amputee with variable cognitive and minimal other physical disability, excellent results of excision can be achieved. In one series of 25 combat-related amputations, an 8% recurrence rate of mild, asymptomatic ectopic bone has been reported with secondary prophylaxis treatment in 84% of cases (26).

Conclusion

Heterotopic ossification is a complex disorder with numerous proven and putative risk factors and varied initiating external stimuli, ultimately resulting from both local and systemic internal biologic factors. Lesions are often asymptomatic but can result in profound patient disability due to pain and joint stiffness. Primary prophylaxis via radiation therapy is neither practical nor recommended in patients with high-energy penetrating extremity wounds, though nonsteroidal anti-inflammatory drugs may be effective in carefully selected patients. After an appropriate trial of conservative measures, operative excision of symptomatic heterotopic bone provides generally good results with low recurrence rates in appropriately selected patients treated with secondary prophylaxis. Future research regarding biomarker-based prognostication and identification of initiating chemokines, genes, and cellular origin of ectopic bone may permit individualized prophylaxis and development of novel targeted therapies.

References

- Kypson, A. P., Morpew, E., Jones, R., et al. Heterotopic ossification in rectal cancer: rare finding with a novel proposed mechanism. *J. Surg. Oncol.* 82:132–136; discussion 137, 2003.
- Kaplan, F. S., Glaser, D. L., Hebel, N., et al. Heterotopic ossification. *J. Am. Acad. Orthop. Surg.* 12:116–125, 2004.
- Hoffer, M. M., et al. The orthopaedic management of brain-injured children. *J. Bone Joint Surg.* 53-A:567–577, 1971.
- Garland, D. E., Razza, B. E., Waters, R. L. Forceful joint manipulation in head-injured adults with heterotopic ossification. *Clin. Orthop. Relat. Res.* 169:133–138, 1982.
- Garland, D. E., Hanscom, D. A., Keenan, M. A., et al. Resection of heterotopic ossification in the adult with head trauma. *J. Bone Joint Surg.* 67-A:1261–1269, 1985.
- Garland, D. E., Keenan, M. A. Orthopedic strategies in the management of the adult head-injured patient. *Phys. Ther.* 63:2004–2009, 1983.
- Garland, D. E. A clinical perspective on common forms of acquired heterotopic ossification. *Clin. Orthop. Relat. Res.* 263:13–29, 1991.
- Como, J. J., Yowler, C. J., Malangoni, M. A. Extensive heterotopic mesenteric ossification after penetrating abdominal trauma. *J. Trauma* 65:1567, 2008.
- Brooker, A. F., Bowerman, J. W., Robinson, R. A., et al. Ectopic ossification following total hip replacement. Incidence and a method of classification. *J. Bone Joint Surg.* 55-A:1629–1632, 1973.
- Riegler, H. F., Harris, C. M. Heterotopic bone formation after total hip arthroplasty. *Clin. Orthop. Relat. Res.* 117:209–216, 1976.
- Triantaphilopoulos, P. G., et al. Long-term results in surgically treated acetabular fractures through the posterior approaches. *J. Trauma* 62:378–382, 2007.
- Sanchez-Sotelo, J., Torchia, M. E., O'Driscoll, S. W. Complex distal humeral fractures: internal fixation with a principle-based parallel-plate technique. *J. Bone Joint Surg.* 89-A, 961–969, 2007.
- Mikic, Z. D., Vukadinovic, S. M. Late results in fractures of the radial head treated by excision. *Clin. Orthop. Relat. Res.* 181:220–228, 1983.
- Kamineni, S., Morrey, B. F. Distal humeral fractures treated with noncustom total elbow replacement. *J. Bone Joint Surg.* 86-A:940–947, 2004.
- Giannoudis, P. V., Grotz, M. R., Papakostidis, C., et al. Operative treatment of displaced fractures of the acetabulum. A meta-analysis. *J. Bone Joint Surg.* 87-B:2–9, 2005.
- Garland, D. E., Dowling, V. Forearm fractures in the head-injured adult. *Clin. Orthop. Relat. Res.* 176:190–196, 1983.
- Garland, D. E., O'Hollaren, R. M. Fractures and dislocations about the elbow in the head-injured adult. *Clin. Orthop. Relat. Res.* 168:38–41, 1982.
- Dias, D. A. Heterotopic para-articular ossification of the elbow with soft tissue contracture in burns. *Burns Incl. Therm. Inj.* 9:128–134, 1982.
- Ahrengart, L. Periarticular heterotopic ossification after total hip arthroplasty. Risk factors and consequences. *Clin. Orthop. Relat. Res.* 263:49–58, 1991.
- Morrey, B. F., Adams, R. A., Cabanela, M. E. Comparison of heterotopic bone after anterolateral, transtrochanteric, and posterior approaches for total hip arthroplasty. *Clin. Orthop. Relat. Res.* 188:160–167, 1984.
- Kaplan, F. S., Hahn, G. V., Zasloff, M. A. Heterotopic ossification: two rare forms and what they can teach us. *J. Am. Acad. Orthop. Surg.* 2:288–296, 1994.
- Kaplan, F. S., et al. Genetic transmission of fibrodysplasia ossificans progressiva. Report of a family. *J. Bone Joint Surg.* 75-A:1214–1220, 1993.
- Kaplan, F. S., Shore, E. M. Progressive osseous heteroplasia. *J. Bone Miner. Res.* 15:2084–2094, 2000.
- Forsberg, J. A., et al. Heterotopic ossification in high-energy wartime extremity injuries: prevalence and risk factors. *J. Bone Joint Surg.* 91-A:1084–1091, 2009.
- Potter, B. K., Burns, T. C., Lacap, A. P., et al. Heterotopic ossification in the residual limbs of traumatic and combat-related amputees. *J. Am. Acad. Orthop. Surg.* 14:S191–197, 2006.
- Potter, B. K., Burns, T. C., Lacap, A. P., et al. Heterotopic ossification following traumatic and combat-related amputations. Prevalence, risk factors, and preliminary results of excision. *J. Bone Joint Surg.* 89-A:476–486, 2007.
- London, P. S. Medical lessons from the Falkland Islands' Campaign. Report of a meeting of the United Services Section of the Royal Society of Medicine held at the Royal College of Surgeons on February 17 and 18, 1983. *J. Bone Joint Surg.* 65-B:507–510, 1983.
- Gofrit, O. N., et al. The trimodal death distribution of trauma victims: military experience from the Lebanon War. *Mil. Med.* 162:24–26, 1997.
- Mabry, R. L., et al. United States Army Rangers in Somalia: an analysis of combat casualties on an urban battlefield. *J. Trauma* 49:515–528; discussion 528–529, 2000.

30. Islinger, R. B., Kuklo, T. R., McHale, K. A. A review of orthopedic injuries in three recent U.S. military conflicts. *Mil. Med.* 165:463–465, 2000.
31. Covey, D. C. Blast and fragment injuries of the musculoskeletal system. *J. Bone Joint Surg.* 84-A:1221–1234, 2002.
32. Champion, H. R., Bellamy, R. F., Roberts, C. P., et al. A profile of combat injury. *J. Trauma* 54:S13–19, 2003.
33. Lin, D. L., Kirk, K. L., Murphy, K. P., et al. Evaluation of orthopaedic injuries in Operation Enduring Freedom. *J. Orthop. Trauma* 18:S48–53, 2004.
34. Patel, T. H., et al. A U.S. Army Forward Surgical Team's experience in Operation Iraqi Freedom. *J. Trauma* 57:201–207, 2004.
35. Covey, D. C. Combat orthopaedics: a view from the trenches. *J. Am. Acad. Orthop. Surg.* 14:S10–17, 2006.
36. Hofmeister, E. P., Mazurek, M., Ingari, J. Injuries sustained to the upper extremity due to modern warfare and the evolution of care. *J. Hand Surg.* 32A:1141–1147, 2007.
37. Fox, C. J., et al. Damage control resuscitation for vascular surgery in a combat support hospital. *J. Trauma* 65:1–9, 2008.
38. Hayda, R. A., et al. From Iraq back to Iraq: modern combat orthopaedic care. *Instr. Course Lect.* 57:87–99, 2008.
39. Kragh, J. F. J., et al. Survival with emergency tourniquet use to stop bleeding in major limb trauma. *Ann. Surg.* 249:1–7, 2009.
40. Garland, D. E. Clinical observations on fractures and heterotopic ossification in the spinal cord and traumatic brain injured populations. *Clin. Orthop. Relat. Res.* 233:86–101, 1988.
41. Garland, D. E., Rothi, B., Waters, R. L. Femoral fractures in head-injured adults. *Clin. Orthop. Relat. Res.* 166:219–225, 1982.
42. Garland, D. E., Toder, L. Fractures of the tibial diaphysis in adults with head injuries. *Clin. Orthop. Relat. Res.* 150:198–202, 1980.
43. Steinberg, G. G., Hubbard, C. Heterotopic ossification after femoral intramedullary rodding. *J. Orthop. Trauma* 7:536–542, 1993.
44. Spencer, R. F. The effect of head injury on fracture healing. A quantitative assessment. *J. Bone Joint Surg.* 69-B:525–528, 1987.
45. Giannoudis, P. V., et al. Accelerated bone healing and excessive callus formation in patients with femoral fracture and head injury. *Injury* 37 (suppl 3):S18–24, 2006.
46. Lazansky, M. G. Complications revisited. The debit side of total hip replacement. *Clin. Orthop. Relat. Res.* 95:96–103, 1973.
47. Ritter, M. A., Vaughan, R. B. Ectopic ossification after total hip arthroplasty. Predisposing factors, frequency, and effect on results. *J. Bone Joint Surg.* 59-A:345–351, 1977.
48. Dalury, D. F., Jiranek, W. A. The incidence of heterotopic ossification after total knee arthroplasty. *J. Arthroplasty* 19:447–452, 2004.
49. Shafritz, A. B., et al. Overexpression of an osteogenic morphogen in fibrodysplasia ossificans progressiva. *N. Engl. J. Med.* 335:555–561, 1996.
50. de la Pena, L. S., et al. Fibrodysplasia ossificans progressiva (FOP), a disorder of ectopic osteogenesis, misregulates cell surface expression and trafficking of BMPRIA. *J. Bone Miner. Res.* 20:1168–1176, 2005.
51. Roush, W. Protein builds second skeleton. *Science* 273:1170, 1996.
52. Feldman, G., et al. Fibrodysplasia ossificans progressiva, a heritable disorder of severe heterotopic ossification, maps to human chromosome 4q27–31. *Am. J. Hum. Genet.* 66:128–135, 2000.
53. Olmsted-Davis, E., et al. Hypoxic adipocytes pattern early heterotopic bone formation. *Am. J. Pathol.* 170:620–632, 2007.
54. Nesti, L. J., et al. Differentiation potential of multipotent progenitor cells derived from war-traumatized muscle tissue. *J. Bone Joint Surg.* 90-A:2390–2398, 2008.
55. Jackson, W. M., Aragon, A. B., Bulken-Hoover, J. D., et al. Putative heterotopic ossification progenitor cells derived from traumatized muscle. *J. Orthop. Res.* 27:1645–1651, 2009.
56. Lounev, V. Y., et al. Identification of progenitor cells that contribute to heterotopic skeletogenesis. *J. Bone Joint Surg.* 91-A:652–663, 2009.
57. Brumback, R. J., et al. Heterotopic ossification about the hip after intramedullary nailing for fractures of the femur. *J. Bone Joint Surg.* 72-A:1067–1073, 1990.
58. Griffin, D. B., Beaulé, P. E., Matta, J. M. Safety and efficacy of the extended iliofemoral approach in the treatment of complex fractures of the acetabulum. *J. Bone Joint Surg.* 87-B:1391–1396, 2005.
59. Oh, C. W., et al. Results after operative treatment of transverse acetabular fractures. *J. Orthop. Sci.* 11:478–484, 2006.
60. Petsatodis, G., et al. Surgically treated acetabular fractures via a single posterior approach with a follow-up of 2–10 years. *Injury* 38:334–343, 2007.
61. Rath, E. M., Russell, G. V. J., Washington, W. J., et al. Gluteus minimus necrotic muscle debridement diminishes heterotopic ossification after acetabular fracture fixation. *Injury* 33:751–756, 2002.
62. Schara, K., Herman, S. Heterotopic bone formation in total hip arthroplasty: predisposing factors, classification and the significance for clinical outcome. *Acta Chir. Orthop. Traumatol. Cech.* 68:105–108, 2001.
63. Burd, T. A., Lowry, K. J., Anglen, J. O. Indomethacin compared with localized irradiation for the prevention of heterotopic ossification following surgical treatment of acetabular fractures. *J. Bone Joint Surg.* 83-A:1783–1788, 2001.
64. Fransen, M., Neal, B. Non-steroidal anti-inflammatory drugs for preventing heterotopic bone formation after hip arthroplasty. *Cochrane Database Syst. Rev.* CD001160, 2004.
65. Gregorich, S. J., Chadha, M., Pelligrini, V. D., et al. Randomized trial comparing preoperative versus postoperative irradiation for prevention of heterotopic ossification following prosthetic total hip replacement: preliminary results. *Int. J. Radiat. Oncol. Biol. Phys.* 30:55–62, 1994.
66. Knelles, D., et al. Prevention of heterotopic ossification after total hip replacement. A prospective, randomised study using acetylsalicylic acid, indomethacin and fractional or single-dose irradiation. *J. Bone Joint Surg.* 79-B:596–602, 1997.
67. Kolbl, O., et al. Randomized trial comparing early postoperative irradiation vs. the use of nonsteroidal antiinflammatory drugs for prevention of heterotopic ossification following prosthetic total hip replacement. *Int. J. Radiat. Oncol. Biol. Phys.* 39:961–966, 1997.
68. Kolbl, O., et al. Preoperative irradiation versus the use of nonsteroidal anti-inflammatory drugs for prevention of heterotopic ossification following total hip replacement: the results of a randomized trial. *Int. J. Radiat. Oncol. Biol. Phys.* 42:397–401, 1998.
69. Moore, K. D., Goss, K., Anglen, J. O. Indomethacin versus radiation therapy for prophylaxis against heterotopic ossification in acetabular fractures: a randomised, prospective study. *J. Bone Joint Surg.* 80-B:259–263, 1998.
70. Pakos, E. E., et al. Prevention of heterotopic ossification in high-risk patients with total hip arthroplasty: the experience of a combined therapeutic protocol. *Int. Orthop.* 30:79–83, 2006.
71. Pellegrini, V. D. J., Kanski, A. A., Gastel, J. A., et al. Prevention of heterotopic ossification with irradiation after total hip arthroplasty. Radiation therapy with a single dose of eight hundred centigray administered to a limited field. *J. Bone Joint Surg.* 74-A:186–200, 1992.
72. Seegenschmiedt, M. H., et al. Prevention of heterotopic ossification about the hip: final results of two randomized trials

- in 410 patients using either preoperative or postoperative radiation therapy. *Int. J. Radiat. Oncol. Biol. Phys.* 39:161–171, 1997.
73. Sell, S., et al. The suppression of heterotopic ossifications: radiation versus NSAID therapy — a prospective study. *J. Arthroplasty* 13:854–859, 1998.
 74. Matta, J. M., Siebenrock, K. A. Does indomethacin reduce heterotopic bone formation after operations for acetabular fractures? A prospective randomised study. *J. Bone Joint Surg.* 79-B:959–963, 1997.
 75. Blokhuis, T. J., Frolke, J. P. Is radiation superior to indomethacin to prevent heterotopic ossification in acetabular fractures?: a systematic review. *Clin. Orthop. Relat. Res.* 467:526–530, 2009.
 76. Pakos, E. E., Ioannidis, J. P. Radiotherapy vs. nonsteroidal anti-inflammatory drugs for the prevention of heterotopic ossification after major hip procedures: a meta-analysis of randomized trials. *Int. J. Radiat. Oncol. Biol. Phys.* 60:888–895, 2004.
 77. Bergenstock, M., Min, W., Simon, A. M., et al. A comparison between the effects of acetaminophen and celecoxib on bone fracture healing in rats. *J. Orthop. Trauma* 19:717–723, 2005.
 78. Herbenick, M. A., Sprott, D., Stills, H., et al. Effects of a cyclooxygenase 2 inhibitor on fracture healing in a rat model. *Am. J. Orthop.* 37:E133–137, 2008.
 79. Mullis, B. H., et al. Effect of COX-2 inhibitors and non-steroidal anti-inflammatory drugs on a mouse fracture model. *Injury* 37:827–837, 2006.
 80. Simon, A. M., Manigrasso, M. B., O'Connor, J. P. Cyclo-oxygenase 2 function is essential for bone fracture healing. *J. Bone Miner. Res.* 17:963–976, 2002.
 81. Simon, A. M., O'Connor, J. P. Dose and time-dependent effects of cyclooxygenase-2 inhibition on fracture healing. *J. Bone Joint Surg.* 89-A:500–511, 2007.
 82. Macfarlane, R. J., et al. Pharmacological treatment of heterotopic ossification following hip and acetabular surgery. *Exp. Opin. Pharmacother.* 9:767–786, 2008.
 83. O'Connor, J. P., Lysz, T. Celecoxib, NSAIDs and the skeleton. *Drugs Today (Barc)* 44:693–709, 2008.
 84. Banovac, K. The effect of etidronate on late development of heterotopic ossification after spinal cord injury. *J. Spinal Cord Med.* 23:40–44, 2000.
 85. Banovac, K., Gonzalez, F., Renfree, K. J. Treatment of heterotopic ossification after spinal cord injury. *J. Spinal Cord Med.* 20:60–65, 1997.
 86. Banovac, K., Gonzalez, F., Wade, N., et al. Intravenous disodium etidronate therapy in spinal cord injury patients with heterotopic ossification. *Paraplegia* 31:660–666, 1993.
 87. Spielman, G., Gennarelli, T. A., Rogers, C. R. Disodium etidronate: its role in preventing heterotopic ossification in severe head injury. *Arch. Phys. Med. Rehabil.* 64:539–542, 1983.
 88. Finerman, G. A., Stover, S. L. Heterotopic ossification following hip replacement or spinal cord injury. Two clinical studies with EHDP. *Metab. Bone Dis. Relat. Res.* 3:337–342, 1981.
 89. Stover, S. L., Niemann, K. M., Miller, J. M.. Disodium etidronate in the prevention of postoperative recurrence of heterotopic ossification in spinal cord injury patients. *J. Bone Joint Surg.* 58-A:683–688, 1976.
 90. Garland, D. E., Alday, B., Venos, K. G., et al. Diphosphonate treatment for heterotopic ossification in spinal cord injury patients. *Clin. Orthop. Relat. Res.* 176:197–200, 1983.
 91. Hu, H. P., Kuijpers, W., Slooff, T. J., et al. The effect of bisphosphonate on induced heterotopic bone. *Clin. Orthop. Relat. Res.* 272:259–267, 1991.
 92. Thomas, B. J., Amstutz, H. C. Results of the administration of diphosphonate for the prevention of heterotopic ossification after total hip arthroplasty. *J. Bone Joint Surg.* 67-A:400–403, 1985.
 93. Haran, M., Bhuta, T., Lee, B. Pharmacological interventions for treating acute heterotopic ossification. *Cochrane Database Syst. Rev.* CD003321, 2004.
 94. Back, D. L., Smith, J. D., Dalziel, R. E., et al. Incidence of heterotopic ossification after hip resurfacing. *ANZ. J. Surg.* 77:642–647, 2007.
 95. Ebraheim, N. A., Patil, V., Liu, J., et al. Sliding trochanteric osteotomy in acetabular fractures: a review of 30 cases. *Injury* 38:1177–1182, 2007.
 96. Garland, D. E., Blum, C. E., Waters, R. L. Periarticular heterotopic ossification in head-injured adults. Incidence and location. *J. Bone Joint Surg.* 62-A:1143–1146, 1980.
 97. Grohs, J. G., Schmidt, M., Waniwenhaus, A. Selective COX-2 inhibitor versus indomethacin for the prevention of heterotopic ossification after hip replacement: a double-blind randomized trial of 100 patients with 1-year follow-up. *Acta Orthop.* 78:95–98, 2007.
 98. Higo, T., Mawatari, M., Shigematsu, M., et al. The incidence of heterotopic ossification after cementless total hip arthroplasty. *J. Arthroplasty* 21:852–856, 2006.
 99. Kasetti, R. J., Shetty, A. A., Rand, C. Heterotopic ossification after uncemented hydroxyapatite-coated primary total hip arthroplasty. *J. Arthroplasty* 16:1038–1042, 2001.
 100. Kreder, H. J., et al. Determinants of functional outcome after simple and complex acetabular fractures involving the posterior wall. *J. Bone Joint Surg.* 88-B:776–782, 2006.
 101. Saudan, M., et al. Celecoxib versus ibuprofen in the prevention of heterotopic ossification following total hip replacement: a prospective randomised trial. *J. Bone Joint Surg.* 89-B:155–159, 2007.
 102. van der Heide, H. J., Rijnberg, W. J., Van Sorge, A., et al. Similar effects of rofecoxib and indomethacin on the incidence of heterotopic ossification after hip arthroplasty. *Acta Orthop.* 78:90–94, 2007.
 103. Hendricks, H. T., Geurts, A. C., van Ginneken, B. C., et al. Brain injury severity and autonomic dysregulation accurately predict heterotopic ossification in patients with traumatic brain injury. *Clin. Rehabil.* 21:545–553, 2007.
 104. Potter, B. K., et al. In *Rehabilitation of Combat Casualties With Limb Loss*, edited by P. C. R. Pasquina, Borden Institute, Washington, DC, 2008.
 105. Ehde, D. M., Smith, D. G. Chronic pain management. In *Atlas of Amputations and Limb Deficiencies: Surgical, Prosthetic, and Rehabilitation Principles*, 3rd ed., edited by D. G. Smith, J. W. Michael, J. H. Bowker, pp. 711–726, American Academy of Orthopaedic Surgeons, 2004.
 106. Furman, R., Nicholas, J. J., Jivoff, L. Elevation of the serum alkaline phosphatase coincident with ectopic-bone formation in paraplegic patients. *J. Bone Joint Surg.* 52-A:1131–1137, 1970.
 107. Hsu, J. D., Sakimura, I., Stauffer, E. S. Heterotopic ossification around the hip joint in spinal cord injured patients. *Clin. Orthop. Relat. Res.* 112:165–169, 1975.
 108. Pittenger, D. E. Heterotopic ossification. *Orthop. Rev.* 20:33–39, 1991.
 109. Beingsner, D. M., Patterson, S. D., King, G. J. Early excision of heterotopic bone in the forearm. *J. Hand Surg.* 25A:483–488, 2000.
 110. Chalidis, B., Stengel, D., Giannoudis, P. V. Early excision and late excision of heterotopic ossification after traumatic brain injury are equivalent: a systematic review of the literature. *J. Neurotrauma* 24:1675–1686, 2007.
 111. Ellerin, B. E., et al. Current therapy in the management of heterotopic ossification of the elbow: a review with case studies. *Am. J. Phys. Med. Rehabil.* 78:259–271, 1999.

112. Freebourn, T. M., Barber, D. B., Able, A. C. The treatment of immature heterotopic ossification in spinal cord injury with combination surgery, radiation therapy and NSAID. *Spinal Cord* 37:50–53, 1999.
113. Garland, D. E., Orwin, J. F. Resection of heterotopic ossification in patients with spinal cord injuries. *Clin. Orthop. Relat. Res.* 242:169–176, 1989.
114. McAuliffe, J. A., Wolfson, A. H. Early excision of heterotopic ossification about the elbow followed by radiation therapy. *J. Bone Joint Surg.* 79-A:749–755, 1997.
115. Mitsionis, G. I., et al. Functional outcome after excision of heterotopic ossification about the knee in ICU patients. *Int. Orthop.* 33:1619–1625, 2008.
116. Moritomo, H., Tada, K., Yoshida, T. Early, wide excision of heterotopic ossification in the medial elbow. *J. Shoulder Elbow Surg.* 10:164–168, 2001.
117. Tsionos, I., Leclercq, C., Rochet, J. M. Heterotopic ossification of the elbow in patients with burns. Results after early excision. *J. Bone Joint Surg.* 86-B:396–403, 2004.
118. Viola, R. W., Hanel, D. P. Early “simple” release of posttraumatic elbow contracture associated with heterotopic ossification. *J. Hand Surg.* 24A:370–380, 1999.
119. Wysocki, R. W., Cohen, M. S. Radioulnar heterotopic ossification after distal biceps tendon repair: results following surgical resection. *J. Hand Surg.* 32A:1230–1236, 2007.