

# Heterotopic Ossification Following Combat-Related Trauma

By MAJ Benjamin K. Potter, MD, LCDR Jonathan A. Forsberg, MD, Thomas A. Davis, PhD, CPT Korboi N. Evans, MD, MAJ Jason S. Hawksworth, MD, Doug Tadaki, PhD, Trevor S. Brown, PhD, Nicole J. Crane, PhD, MAJ Travis C. Burns, MD, CPT Frederick P. O'Brien, MD, and CDR Eric A. Elster, MD

## Introduction

The term *heterotopic ossification* refers to the aberrant formation of mature, lamellar bone in nonosseous tissue. Translated from its Greek (*heteros* and *topos*) and Latin (*ossificatio*) etymologic origins, heterotopic ossification can be literally defined as "bone formation in other location." The first written account of heterotopic ossification describes the treatment of symptomatic lesions. Al-Zahrawi (more commonly known in Western cultures as Albucasis), widely considered the father of surgery, wrote in the year 1000 C.E., "This callus often occurs after the healing of a fracture. . .and sometimes there is limitation of the natural function of the limb. . .if the callus is stony hard and its removal is urgent, incise the place and cut away the superfluous prominence, or pare it away with a scraper until it is gone; and dress the wound until it heals."<sup>1</sup> Currently, orthopaedic surgeons faced with treating mature, refractory, symptomatic heterotopic ossification are left with few options other than operative excision. Although it is remarkable that the treatment of heterotopic ossification has scarcely changed in the last millennium, it is generally accepted that prophylaxis against heterotopic ossification is far preferable than the later treatment of symptomatic lesions. As such, the focus of scientific effort in recent years has been directed toward prophylaxis, not treatment.

The formation of heterotopic ossification has been observed following total hip arthroplasty, acetabular and elbow fracture surgery, electrocution and burn injuries, and traumatic brain injury or spinal cord injury.<sup>2</sup> Following most traumatic injuries in the civilian population, the formation of heterotopic ossification is relatively rare in the absence of head injury. Even following traumatic brain injury or spinal cord injury, heterotopic ossification develops in only 20% and 11% of patients, respectively.<sup>3</sup> Rates of heterotopic ossification formation exceed 50% only in the setting of femoral shaft fractures with con-

comitant head injury<sup>4</sup>, although reported rates following acetabular and elbow fractures vary substantially. Numerous combat-related injury and amputation studies from the latter half of the twentieth century make no specific mention of heterotopic ossification, suggesting that it was not a common occurrence in prior conflicts<sup>5-8</sup>. However, military medical texts from the U.S. Civil War and World War I<sup>9,10</sup> make specific mention of heterotopic ossification as a common problem following amputation, as described by Huntington: ". . .the stumps became conical sooner or later; short stumps sometimes remained well-rounded, long stumps rarely; but when they remained full it was often due to osteophytes, which in time became troublesome."<sup>10</sup>

Thus, since the birth of both surgery and modern warfare, heterotopic ossification has been recognized as a nameless condition that occurs following trauma. Indeed, in the current conflicts in Iraq and Afghanistan, heterotopic ossification has proven to be a frequent occurrence and a common clinical problem. The goals of the present manuscript are to summarize recent findings and the current state of science with regard to combat-related heterotopic ossification as well as to present the preliminary findings of ongoing studies and future directions.

## Source of Funding

The aforementioned studies were supported, in part, by research grants from USAMRAA OTRP W81XWH-07-1-0222, the Office of Naval Research and U.S. Navy BUMED Advanced Medical Development 6.4/5 Program 604771N.0933.001.A0604.

## Epidemiology of and Risk Factors for Combat-Related Heterotopic Ossification

The trend in modern warfare has shifted toward a higher percentage of extremity injuries<sup>11-18</sup>. This, coupled with the

**Disclosure:** In support of their research for or preparation of this work, one or more of the authors received, in any one year, outside funding or grants in excess of \$10,000 from the U.S. Navy Bureau of Medicine and Surgery under the Medical Development Program and Office of Naval Research work unit number 604771N.0933.001.A0604 and USAMRAA OTRP W81XWH-07-1-0222. Neither they nor a member of their immediate families received payments or other benefits or a commitment or agreement to provide such benefits from a commercial entity.

**Disclaimer:** The views expressed in this manuscript are those of the authors and do not reflect the official policy of the Department of the Army, the Department of the Navy, the Department of Defense or the United States Government. We are military service members (or employees of the U.S. Government). This work was prepared as part of our official duties. Title 17 U.S.C. 105 provides the "Copyright protection under this title is not available for any work of the United States Government." Title 17 U.S.C. 101 defines a U.S. Government work as a work prepared by a military service member or employee of the U.S. Government as part of that person's official duties.

# Report Documentation Page

Form Approved  
OMB No. 0704-0188

Public reporting burden for the collection of information is estimated to average 1 hour per response, including the time for reviewing instructions, searching existing data sources, gathering and maintaining the data needed, and completing and reviewing the collection of information. Send comments regarding this burden estimate or any other aspect of this collection of information, including suggestions for reducing this burden, to Washington Headquarters Services, Directorate for Information Operations and Reports, 1215 Jefferson Davis Highway, Suite 1204, Arlington VA 22202-4302. Respondents should be aware that notwithstanding any other provision of law, no person shall be subject to a penalty for failing to comply with a collection of information if it does not display a currently valid OMB control number.

1. REPORT DATE <b>2010</b>		2. REPORT TYPE		3. DATES COVERED <b>00-00-2010 to 00-00-2010</b>	
4. TITLE AND SUBTITLE <b>Heterotopic Ossification Following Combat-Related Trauma</b>				5a. CONTRACT NUMBER	
				5b. GRANT NUMBER	
				5c. PROGRAM ELEMENT NUMBER	
6. AUTHOR(S)				5d. PROJECT NUMBER	
				5e. TASK NUMBER	
				5f. WORK UNIT NUMBER	
7. PERFORMING ORGANIZATION NAME(S) AND ADDRESS(ES) <b>Naval Medical Research Center, 503 Robert Grant Avenue, Silver Spring, MD, 20910</b>				8. PERFORMING ORGANIZATION REPORT NUMBER	
9. SPONSORING/MONITORING AGENCY NAME(S) AND ADDRESS(ES)				10. SPONSOR/MONITOR'S ACRONYM(S)	
				11. SPONSOR/MONITOR'S REPORT NUMBER(S)	
12. DISTRIBUTION/AVAILABILITY STATEMENT <b>Approved for public release; distribution unlimited</b>					
13. SUPPLEMENTARY NOTES					
14. ABSTRACT					
15. SUBJECT TERMS					
16. SECURITY CLASSIFICATION OF:			17. LIMITATION OF ABSTRACT	18. NUMBER OF PAGES	19a. NAME OF RESPONSIBLE PERSON
a. REPORT <b>unclassified</b>	b. ABSTRACT <b>unclassified</b>	c. THIS PAGE <b>unclassified</b>			

introduction of improved body armor, the judicious use of tourniquets, and the availability of forward-deployed surgical units, has given rise to highly survivable yet paradoxically devastating extremity injury patterns<sup>19,20</sup>. As a result, the current prevalence of heterotopic ossification has been found to be higher than expected in the combat-wounded patient population<sup>21-23</sup>.

We were the first to report this increased prevalence of heterotopic ossification in a cohort of 330 patients with 373 combat-related amputations, which are an important subset of combat casualties<sup>23</sup>. The study evaluated whether the mechanism of injury (blast or nonblast) correlated with either the presence or severity of heterotopic ossification. Surgery-related variables, such as the level of amputation (either within or proximal to the zone of injury), the number of irrigation and debridement procedures, the time from injury to definitive wound closure, and the prevalence of early wound complications following definitive closure, were also evaluated. The study found clinically detectable heterotopic ossification in 63% of residual limbs and, with the use of univariate analysis, identified the following important risk factors for the eventual development of heterotopic ossification: blast mechanism of injury ( $p < 0.05$ ), and amputations performed in the zone of injury ( $p < 0.05$ ). The latter risk factor also correlates with the severity of lesions, with use of the newly described Walter Reed Classification of heterotopic ossification<sup>23</sup> (Figs. 1-A, 1-B, and 1-C). Interestingly, only twenty-five limbs (6.7%) required surgical excision of symptomatic lesions and a variety of prophylactic measures against secondary recurrence were used, including a single fraction of radiation therapy (700 cGy), indomethacin, cyclooxygenase (COX)-2 inhibitors, and other nonsteroidal anti-inflammatory drugs. Importantly, despite the various means of secondary prophylaxis used, the rate of symptomatic recurrence in this subgroup was low at 0%.

We also defined the prevalence of heterotopic ossification in a separate cohort of patients with combat-related extremity trauma requiring orthopaedic intervention<sup>21</sup>. Two hundred and forty-three patients requiring amputation, external fixation, or internal fixation were evaluated. This cohort study compared 157 patients who developed heterotopic ossification (the study group) to eighty-six patients who did not (the control group). This design enabled us to estimate the prevalence of heterotopic ossification not only in amputees (66% of lower-extremity amputees and 30% of upper-extremity amputees), but also in patients undergoing limb salvage (60.1%). The findings from the former study<sup>21</sup> corroborated our earlier findings<sup>23</sup>. The data from the later study<sup>21</sup> suggested that combat-related injuries, in general, are associated with a higher-than-expected prevalence of heterotopic ossification, when compared with civilian data<sup>3,4,24-29</sup>.

This study<sup>21</sup> also identified several important risk factors for the development of heterotopic ossification in this patient population. Traumatic brain injury was associated with both the presence ( $p = 0.006$ ) and the severity ( $p = 0.003$ ) of heterotopic ossification on univariate but not multivariate analysis. Regression analysis revealed that the Injury Severity Score (as a continuous variable) and an Injury Severity Score of  $\geq 16$  ( $p = 0.02$ , odds ratio = 2.2) were significant predictors, as was multiple

limb trauma requiring orthopaedic intervention ( $p = 0.002$ , odds ratio = 3.9). The most striking observation, however, was that the presence of an amputation was, itself, independently associated with the development of heterotopic ossification ( $p = 0.048$ , odds ratio = 2.9).

The association between heterotopic bone growth and the number and method of surgical debridement procedures, including the use of negative-pressure wound therapy, is controversial. We have observed, on univariate analysis, that patients who subsequently developed heterotopic ossification have undergone more debridement procedures ( $p < 0.001$ ) and thus have been exposed to a longer duration of negative-pressure wound therapy ( $p < 0.001$ )<sup>21</sup>. Nevertheless, these results should be interpreted with caution because the increases in both the number of debridement procedures and the duration of negative-pressure wound therapy are likely more indicative of the severity of injury than they are causal. This is supported by the nonsignificant relationship between the formation of ectopic bone and these wound-care modalities as revealed by multivariate analysis<sup>21</sup>. Although local factors may play a supporting role, current data<sup>21,23</sup> suggest that the development of heterotopic ossification in this patient population is largely due to systemic factors.

#### Barriers to Primary Prophylaxis

Given the high prevalence of combat-related heterotopic ossification in our war-wounded patients, a primary prophylaxis regimen including radiation therapy, conventional nonsteroidal anti-inflammatory drugs, and/or etidronate (an older, nonselective bisphosphonate and the only medication currently approved by the U.S. Food and Drug Administration for the treatment or prevention of heterotopic ossification) would be extremely appealing. Local radiation therapy, generally administered within twenty-four hours preoperatively to forty-eight hours postoperatively in patients at risk for heterotopic ossification, and nonsteroidal anti-inflammatory drugs have well-documented efficacy in the prevention of primary heterotopic ossification<sup>21,23,30-40</sup>. Recent meta-analyses and reviews have suggested that radiation therapy may be slightly more effective than nonsteroidal anti-inflammatory drugs for this purpose, although most of this difference is thought to be related to patient noncompliance with medication<sup>35,41</sup>. Unfortunately, the vast majority of severely injured combatants have multiple medical contraindications to prophylaxis against heterotopic ossification that make the interventions listed above difficult to accomplish. Commonly encountered relative and absolute contraindications to prophylaxis against heterotopic ossification include severe systemic polytrauma, open and contaminated wounds, concomitant traumatic brain injury and/or long bone fractures or spinal column injuries requiring operative stabilization and fusion, and the need for serial surgical procedures. Additionally, substantial potential for impaired renal function, bleeding, and stress gastritis have precluded widespread use of nonsteroidal anti-inflammatory drugs to date. Logistical limitations at remote, far-forward medical facilities in the theater of war are additional hurdles, particularly for the timely administration of radiation therapy.

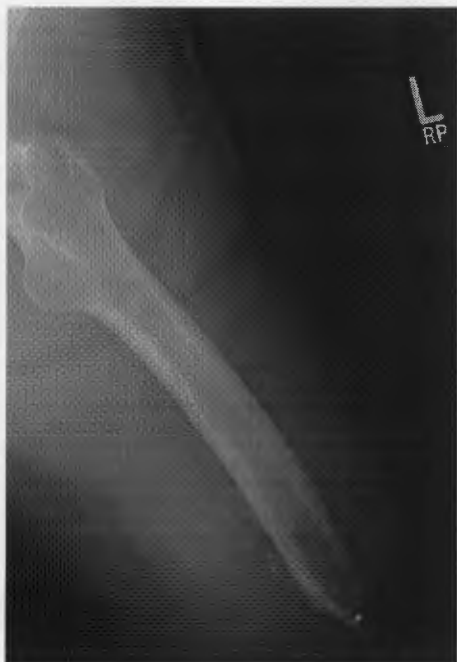

Fig. 1-A

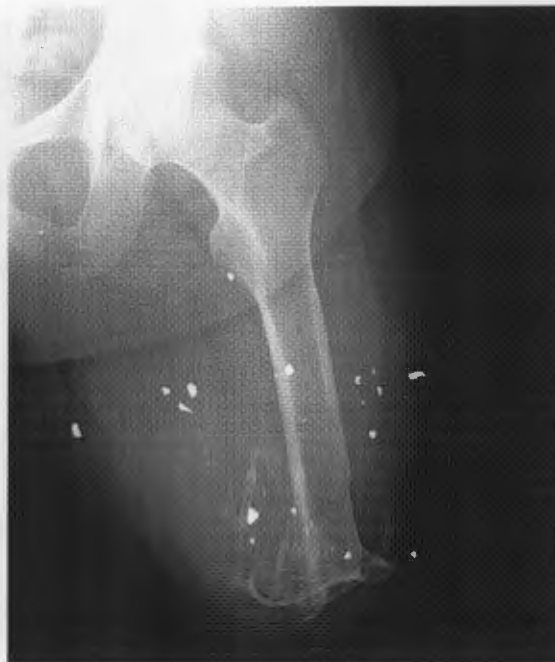

Fig. 1-B

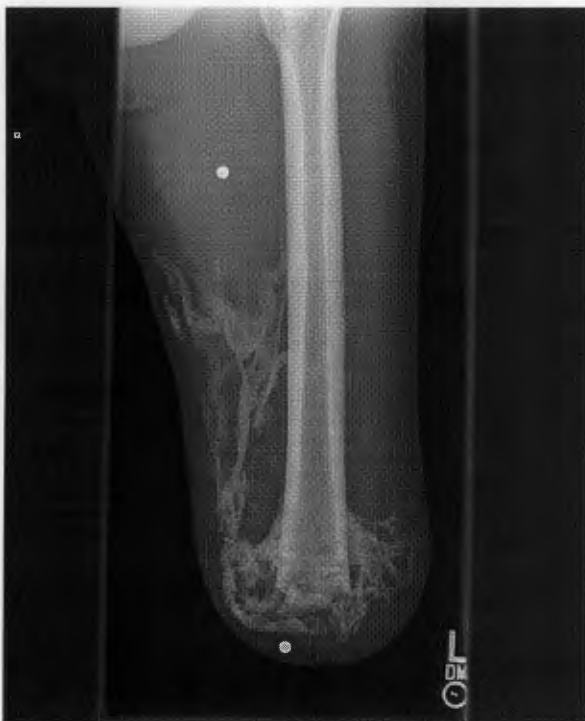

Fig. 1-C

**Figs. 1-A, 1-B, and 1-C** Representative radiographs depicting the Walter Reed classification system for grading the severity of heterotopic ossification in the residual limbs of amputees. The severity of heterotopic ossification is graded on the basis of the single radiographic projection (either anteroposterior or lateral) that demonstrates the greatest amount of ectopic bone within the soft tissues of the residual limb. The heterotopic ossification is considered to be (Fig. 1-A) Grade I (mild) if it occupies <25% of the cross-sectional area of the residual limb on the radiograph; (Fig. 1-B) Grade II (moderate) if it occupies 25% to 50% of the cross-sectional area; and (Fig. 1-C) Grade III (severe) if it occupies >50% of the cross-sectional area.

Etidronate can be administered later in the period after injury, but there can be problems with late mineralization or formation of heterotopic ossification after the cessation of medication. Thus, the efficacy of etidronate has recently been called into question by, among others, a recent Cochrane Database review<sup>42</sup>. Etidronate is also a relatively nonselective osteoclast inhibitor, potentially owing to its limited efficacy to osteoblast in-

hibition, and may inhibit fracture-healing and spinal fusion. Corticosteroids, colchicine, retinoid agonists, coumarin derivatives, and calcitonin have all been studied for their value with regard to prophylaxis against heterotopic ossification; however, the data on human usage is either limited or absent and these drugs share many of the same medical concerns and contraindications as nonsteroidal anti-inflammatory drugs<sup>23,43-48</sup>. Thus, no

practicable primary prophylactic regimen for combat-related heterotopic ossification has been identified, although a trial of the COX-2 inhibitor celecoxib is in development, as discussed below.

### Clinical Sequelae of Combat-Related Heterotopic Ossification

Fortunately, some patients with combat-related heterotopic ossification remain entirely asymptomatic and no specific treatment is indicated. In many others, lesions are transiently painful or bothersome and symptoms subside as adjacent joint motion improves, residual limb "toughening" occurs, and the combat-related heterotopic ossification transitions from its more inflammatory formative phase into a more quiescent maturation phase. Many patients, however, develop symptoms directly attributable to their combat-related heterotopic ossification that persist indefinitely. These symptoms may be localized pain, including, but not limited to, residual limb pain and prosthetic fitting difficulties; ulceration, particularly when the combat-related heterotopic ossification develops beneath an overlying skin graft (Figs. 2-A and 2-B); overt joint ankylosis; secondary arthrofibrosis due to osseous impingement (Figs. 3-A and 3-B); muscle entrapment (Fig. 4); or neurovascular entrapment (Figs. 5-A and 5-B). The treatment of symptomatic combat-related heterotopic ossification is individualized to the patient and the symptoms associated with their combat-related heterotopic ossification.

### Management of Symptomatic Combat-Related Heterotopic Ossification

In the absence of overt ulceration causing concomitant deep infection or overt joint ankylosis, the initial management of symptomatic combat-related heterotopic ossification is nonoperative. This generally includes a period of rest, physical therapy, and gentle stretching and splinting to treat secondary contractures. Taking pressure off of symptomatic areas by positioning, pads or prosthetic socket adjustments, and optimizing pain control and medication regimens are also important. Other potentially contributing causes of pain should be investigated and treated appropriately including infection, fracture non-union, internal derangement of adjacent joints, symptomatic neuromata, phantom pain, and complex regional pain syndrome. When nonoperative measures fail, concurrent procedures in addition to "simple" heterotopic ossification excision are often indicated and appropriate including amputation revision, neuroma excision, quadricepsplasty, contracture release, and/or skin graft excision. The most common indications for excision of combat-related heterotopic ossification in our military patients are pain that is caused by wearing a prosthesis and that has proven to be refractory to multiple socket adjustments, and arthrofibrosis in patients for whom limb salvage will be attempted.

Abundant recent evidence suggests that a prolonged waiting period of twelve to twenty-four months for heterotopic ossification "maturation" prior to excision is not necessary in the post-extremity trauma setting, particularly in the absence of traumatic injury to the brain or spinal cord<sup>23,49-58</sup>. Instead, a waiting period of six months after injury appears to be adequate

to permit sufficient bone maturation to ensure the presence of a gross cortical rind to facilitate marginal excision and to permit a diligent trial of nonoperative treatments. Patients with recalcitrant ulcerations or severe secondary joint contractures may become operative candidates as early as three to four months after injury.

### Operative Planning and Three-Dimensional Modeling

The operative approach to combat-related heterotopic ossification must account for the local anatomy, the location and severity of the heterotopic ossification, and the patient's prior wounds and incisions. We advocate a direct approach utilizing, when feasible, existing incisions, followed by marginal excision of the symptomatic lesion(s). The entirety of the heterotopic ossification need not be removed when the patient's symptoms are focal, particularly when access to the entire lesion would be difficult and the combat-related heterotopic ossification has a mature cortical shell. Wide excision to prevent recurrence would not be feasible in most patients because of the magnitude of tissue sacrifice that would be required. We have noted infrequent recurrences following excision about the elbow, but no symptomatic recurrences in residual limbs or about the thigh in more than 100 patients (unpublished data). This surgical approach has been coupled with the judicious use of secondary prophylaxis with nonsteroidal anti-inflammatory drugs. The decision was made to incorporate the use of secondary prophylaxis into our treatment protocol because of the high rate of wound complications in our initial series of amputees who were treated with radiation, which is used along with nonsteroidal anti-inflammatory drugs in patients with the most severe conditions<sup>23,38</sup>. However, the prognosis for concomitant excision and quadricepsplasty of the thigh for treatment of combat-related heterotopic ossification is guarded as a result of anecdotally high rates of wound complications, recurrent arthrofibrosis, extensor mechanism compromise, or preexisting arthrosis due to prior fractures, prolonged immobilization, or ankylosis.

Computed tomography-based three-dimensional modeling is very useful in the evaluation and treatment of symptomatic combat-related heterotopic ossification (Figs. 6-A and 6-B). Clinically, it is useful for allowing patients, therapists, and prosthetists to anatomically localize symptomatic areas and take efforts to avoid irritation through the use of activity modification, prosthetic socket relief, or model-assisted stereolithographic socket design. For the patient with symptomatic combat-related heterotopic ossification, resin models are useful for both preoperative planning and intraoperative referencing. The formation of combat-related heterotopic ossification distorts normal anatomy, placing critical neurovascular structures and muscle groups at risk for inadvertent injury. In some instances, major nerves and vessels may pass directly through and be incarcerated in the combat-related heterotopic ossification. The physical resin models serve as intraoperative anatomical guides that are based on heterotopic ossification topography. This is particularly helpful for patients in whom the condition is severe or for patients in whom excision of the focal, symptomatic combat-related

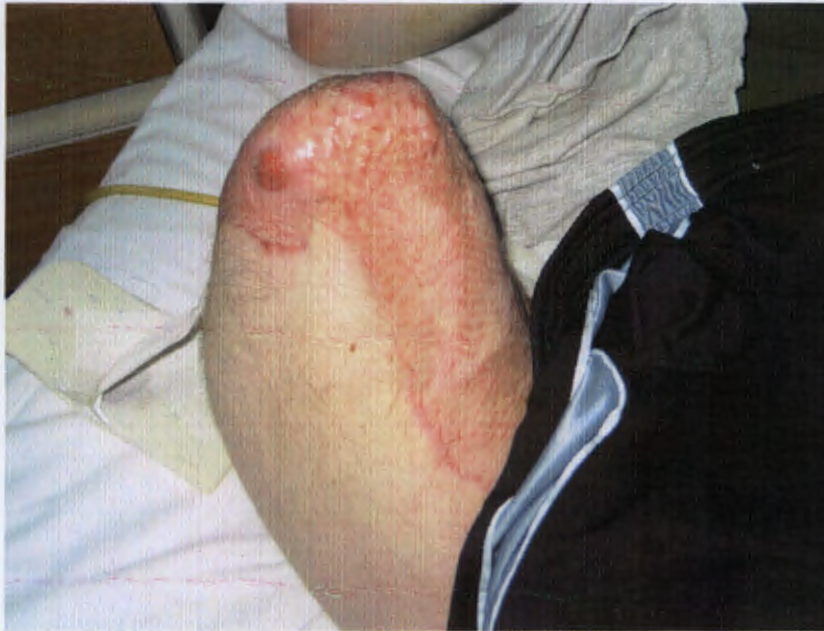

Fig. 2-A

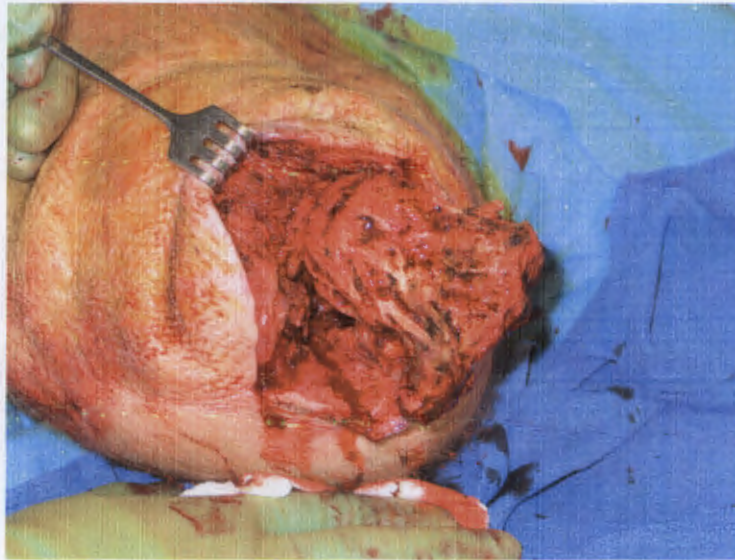


Fig. 2-B

**Fig. 2-A** Clinical photograph demonstrating overt ulceration of split-thickness skin graft of a transfemoral amputation due to underlying heterotopic ossification.

**Fig. 2-B** Intraoperative photograph during marginal excision of the heterotopic ossification with concurrent revision of the amputation in the same patient.

heterotopic ossification is attempted in an effort to avoid complete takedown of the myodesis and revision of the amputation stump.

#### Biochemical Signature of Heterotopic Ossification

It is generally accepted that systemic inflammation is associated with the development of heterotopic ossification. Evans et al.<sup>59</sup> examined the systemic and local wound inflammatory response in twenty-four patients with high-energy, penetrating extremity wounds. In preparation for the development of

a prognostic clinical decision model, the goal of this pilot study was to identify whether a particular cytokine and chemokine profile could be identified in those at risk of developing heterotopic ossification. Serum and wound effluent samples were collected prior to each of these procedures in a manner previously described<sup>60,61</sup>. Twenty-two cytokines and chemokines (including interleukin [IL]-1 through 8, 10, 12, 13, and 15; interferon [IFN]- $\gamma$ ; eotaxin; tumor necrosis factor [TNF]- $\alpha$ ; monocyte chemoattractant protein [MCP]-1; granulocyte colony stimulating factor [G-CSF]; macrophage inflammatory protein

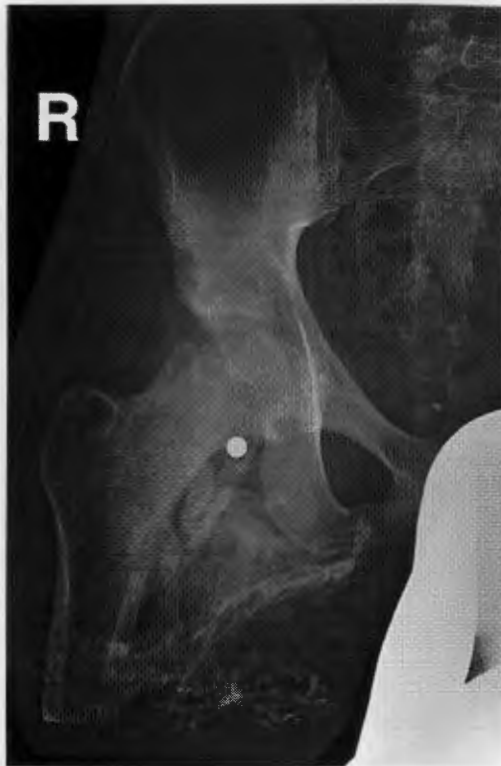

Fig. 3-A

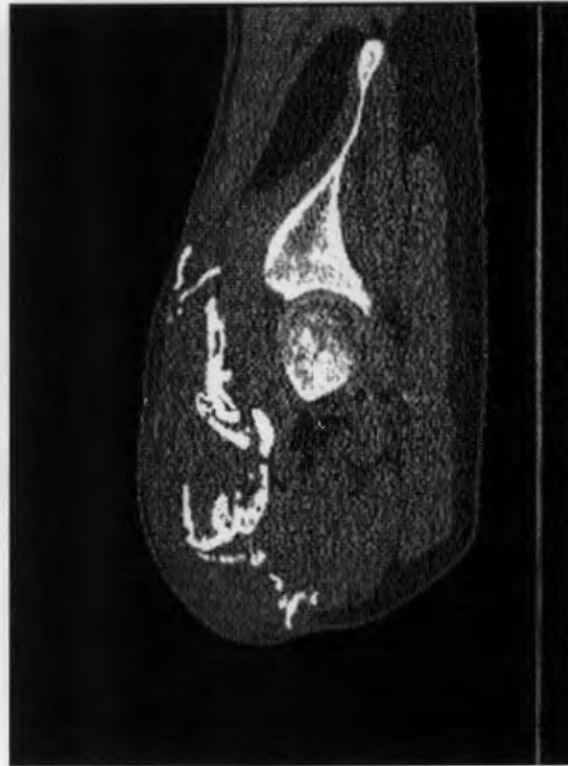

Fig. 3-B

**Figs. 3-A and 3-B** Anteroposterior radiograph (Fig. 3-A) and sagittal computed tomography reconstruction (Fig. 3-B) of a transfemoral amputation with limited hip flexion due to direct impingement of severe heterotopic ossification against the anterior pelvic brim and acetabulum.

[MIP]-1 $\alpha$ ; the protein regulated on activation, normal T expressed and secreted [RANTES]; and IFN- $\gamma$  inducible protein-10) were quantified. After a minimum follow-up of two months, subjects were then stratified according to a two-author (K.N.E. and J.A.F.) blinded review of radiographs into a study group and a control group, on the basis of the presence or absence of heterotopic ossification within the wounded extremity.

Serum analysis demonstrated a profound systemic inflammatory response in the study group. Of the twenty-two serum cytokines and chemokines analyzed, only three (IL-6, IL-10, and human MCP-1 [also known as chemokine (C-C motif) ligand 2, or CCL-2]) differed significantly between the two groups (unpublished data). Specifically, IL-6 remained elevated at all time points, as did MCP-1. Both are inflammatory agents and recruit monocytes and macrophages to the site(s) of injury, indicating sustained inflammation throughout the debridement process. MCP-1, however, is also involved in bone remodeling and may be an early indicator of this process. Interestingly, concentrations of IL-10, an anti-inflammatory cytokine that is important in inhibiting the production of pro-inflammatory cytokines, became significantly more concentrated in the study group approximately two weeks after injury, as compared that in the control group. The late upregulation of this anti-inflammatory mediator also signifies the presence of persistent systemic inflammation and supports our previous observation<sup>62</sup> that the systemic

inflammatory response in this patient population has aberrant regulation.

An analysis of the local wound effluent during the serial debridement process produced similar findings. Wounds that developed heterotopic ossification expressed significantly higher concentrations of MIP-1 $\alpha$  and lower concentrations of IFN- $\gamma$ -inducible protein-10 in the study group as compared with controls. Although both are considered pro-inflammatory, their prolonged, discordant expression, without a demonstrable compensatory anti-inflammatory component, also appears dysregulated. The change in the regulation of the inflammatory response that was observed systemically also seems to persist within the local wound environment. As such, the association between these biomarkers and heterotopic ossification may not simply be related to the difference in concentration between the two groups, but rather, the relationship between pro-inflammatory and anti-inflammatory mediators as well as their relative time-dependent concentrations as measured throughout the debridement process.

#### Progenitor Cell Research

The cellular and biochemical etiology and pathophysiology of heterotopic ossification remain unclear. A postulate theory is that heterotopic ossification results from the presence of osteoprogenitors that pathologically are induced by an imbalance of local and/or systemic factors in soft tissue following traumatic injury. It is thought that a systemic increase in the

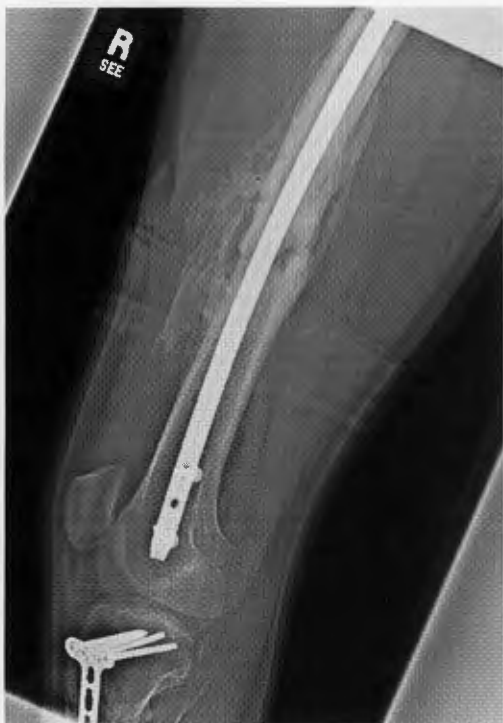

Fig. 4

Lateral radiograph of the distal part of the femur of a patient with fractures of the femoral shaft and tibial plateau, above a transtibial amputation. The radiograph shows arthrofibrosis of the knee joint secondary to entrapment of the quadriceps muscle by heterotopic ossification at the anterior portion of the femur, extending from the femoral shaft fracture callus. The patient had only 10° of total knee motion (5° to 15°) at eight months after a blast injury. He underwent excision of the heterotopic ossification with concurrent release of the knee and quadricepsplasty and achieved an intraoperative range of motion of 0° to 115°. Following a subsequent manipulation under anesthesia at seven weeks postoperatively, the patient was able to maintain a range of motion of 0° to 105°. In our experience, however, such results are not typical, with frequent recurrence of arthrofibrosis, infection, and/or compromise of the extensor mechanism, generally occurring even in the absence of recurrent heterotopic ossification.

osteogenic potential of endogenous muscle progenitor cells occurs in these severely injured patients in the immediate period after trauma.

Mesenchymal stem cells are multipotent, adult progenitor cells of great interest because of their unique immunologic properties and regenerative potential<sup>63</sup>. Mesenchymal stem cells reside within most adult connective tissues and organs<sup>64</sup>. Muscle-derived mesenchymal progenitor cells have been shown to be inherently plastic, enabling them to differentiate along multiple lineages; they promote wound-healing and regeneration

of surrounding tissues by migrating to the site of injury, promoting repair and regeneration of damaged tissue, modulating immune and inflammatory responses, stimulating the proliferation and differentiation of resident progenitor cells, and secreting other trophic factors that are important in wound-healing and tissue remodeling<sup>63,65-68</sup>. Several recent reports describe the isolation and characterization of extensively passaged mesenchymal cell-like progenitor cells (MPCs) isolated from tissue collected following surgical debridement of traumatic orthopaedic extremity wounds<sup>67,69-71</sup>. Yet, the effects of acute and often prolonged aberrant inflammation<sup>62</sup> on muscle-derived mesenchymal cells are unclear.

We speculate that the initiation of heterotopic ossification involves a complex interplay of signaling molecules secreted from the injured tissue. Proliferation and recruitment of local and/or circulating progenitor cells and the aberrant commitment, growth, and differentiation of these cells into bone occur early in the process of wound-healing and repair. In a series of preliminary studies, we have found that wound effluent collected strictly from patients with heterotopic ossification at times of early wound debridement is highly osteogenic, which accelerates the directed *in vitro* osteogenic differentiation of multipotent bone-derived mesenchymal stem cells in culture (Fig. 7). In contrast, mesenchymal stem-cell cultures treated with wound effluent alone, without exogenous exposure to standard induction media, had no measurable effect on the induction of bone formation. Therefore, there is some strong preliminary evidence that severe trauma leads to the release and delivery of osteogenic factors. The identity of these factors and how they interact with progenitor-cell signaling remain unknown.

Currently, little is known about the precursor cell to heterotopic ossification or the environment that permits formation of heterotopic ossification. Understanding the signaling pathways and the involvement of MPC differentiation is essential for the development of early diagnostic and prognostic tests and the development of novel prophylactic therapies. We have developed a unique cell-isolation process and *in vitro* culture system to easily quantify functionally assayable multipotent muscle-derived progenitor cells at the clonal level. The multipotent differentiation capacity of individual clonal cell-derived colonies can be easily assessed by their ability to undergo osteogenic, chondrogenic, and adipogenic differentiation when incubated with specific differentiation induction media. Using this system, we tested the hypothesis that endogenous muscle-derived progenitor cells following severe blunt trauma are greater in number and have a stronger osteogenic potential in patients in whom wound-healing is associated with the formation of combat-related heterotopic ossification than in patients whose wounds heal uneventfully. We prospectively collected wound muscle biopsies during debridements of ten active-duty service members who sustained high-energy penetrating injuries of an extremity during combat operations. Ectopic bone formation was determined by follow-up radiographic assessment at various intervals during the recovery period and was compared with culture results. We also collected hamstring muscle as control tissue from five healthy



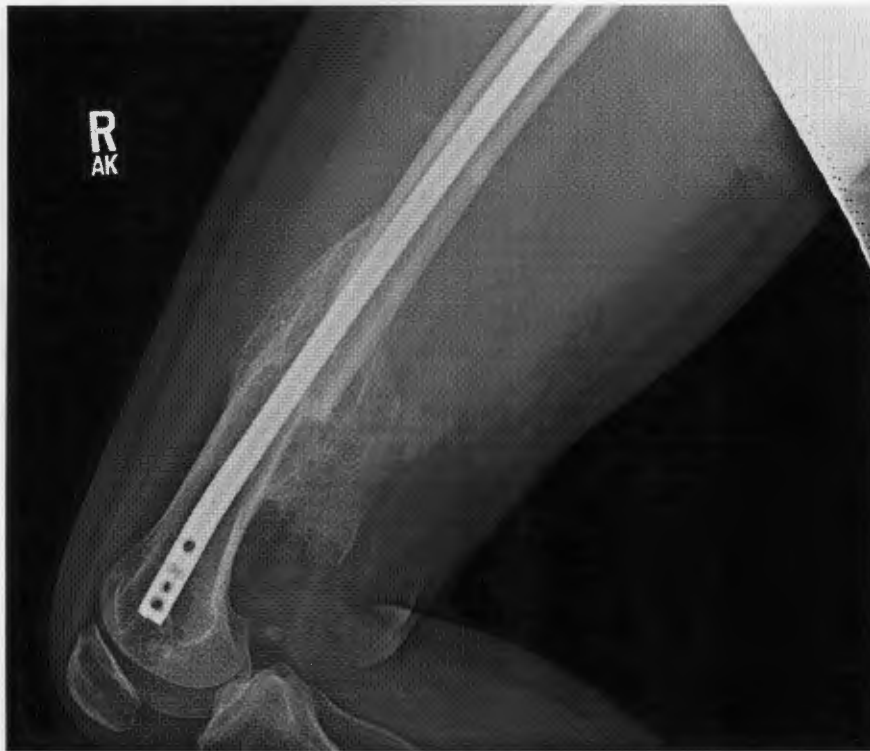

Fig. 5-A

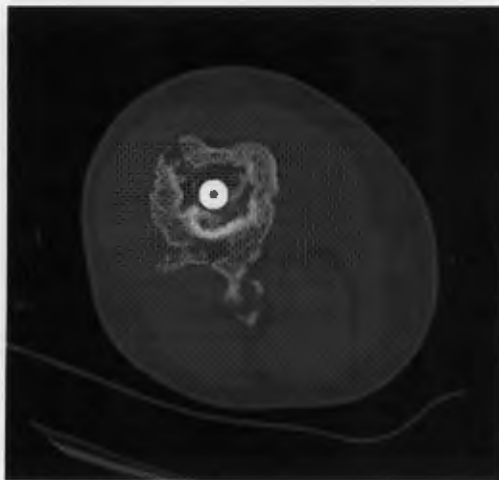


Fig. 5-B

**Figs. 5-A and 5-B** Lateral radiograph (Fig. 5-A) and axial computed tomography scan (Fig. 5-B) showing a femoral shaft fracture. Fracture-healing was complicated by heterotopic ossification, which caused symptomatic entrapment of the sciatic nerve (i.e., decreased distal motor function and dysesthesia of the foot, exacerbated by deep knee flexion). Partial excision of the heterotopic ossification was performed along with neurolysis and decompression of the sciatic nerve. Distal motor and sensory function were retained, and the patient's symptoms abated.

patients undergoing elective anterior cruciate ligament reconstruction with hamstring autograft. We found that the number of adherent colony-forming progenitor cells that could be isolated per gram of tissue from wartime wounds was profoundly increased (range, thirty-two-fold to fiftyfold) compared with the number in the uninjured muscle tissue of the control group (Fig. 8). Quantification of progenitor cells with osteogenic potential showed that the measured 2.3-fold increase in osteogenic progenitors in tissue from patients with combat-related heterotopic ossification compared with that in tissue from patients with noncombat-related heterotopic ossification was significant ( $p < 0.007$ )<sup>72</sup>. Therefore, these findings suggest

that wounds that present with a higher prevalence of resident assayable osteoprogenitors in the tissue, presumably supported through local and/or systemic reactions, correlate with the eventual formation of ectopic bone in traumatized tissue.

#### Raman Spectroscopy

Raman spectroscopy is a scattering technique that can be used to gain information about the structure and composition of molecules from their vibrational transitions. A Raman spectrum can be thought of as a chemical "fingerprint" and is thought of as a complementary technique to the more widely known infrared spectroscopic techniques. The vibra-

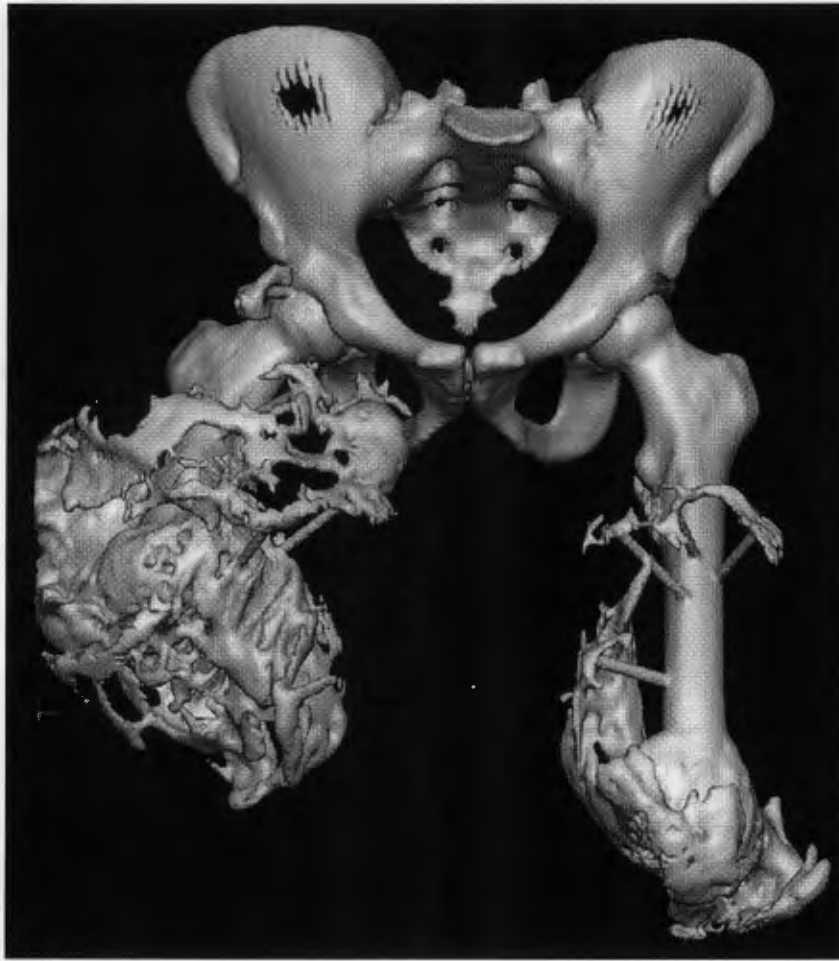

Fig. 6-A

**Figs. 6-A and 6-B** Digital three-dimensional computed tomography reconstruction (Fig. 6-A) and photograph of the corresponding life-size three-dimensional resin model (Fig. 6-B) of both residual limbs and the pelvis of a blast-injured bilateral transfemoral amputee with severe heterotopic ossification of both residual limbs. The model was a useful reference intraoperatively during the staged surgical procedures to excise the heterotopic ossification and revise the amputation, as it provided a “roadmap” of the surface topography of the ectopic bone.

tional (and rotational) bands in a Raman spectrum are specific to the chemical bonds and particular structure of the molecule(s) being investigated. In addition, the band area of a Raman vibrational band is proportional to the amount of analyte present. Thus, Raman spectroscopy can identify the components that are present and quantify the amount of each component.

Over the past fifteen years, Raman spectroscopy has become an attractive technology for probing biomedical samples for several reasons. First, Raman spectroscopy can be used to study both organic and inorganic components (i.e., protein and mineral). Second, Raman spectroscopy can be applied non-invasively. Recent *in vivo* Raman spectroscopic studies include incorporation of a Raman probe into an endoscope for examination of the esophagus and stomach<sup>73,74</sup>, detection of cervical dysplasia<sup>75</sup>, diagnosis of nonmelanoma skin cancer<sup>76</sup>, characterization of psoriatic skin<sup>77</sup>, observation of human-swine coronary xenografts after transplantation<sup>78</sup>, measure-

ment of macular carotenoids in the eye<sup>79-82</sup>, and transcutaneous monitoring of bone<sup>83</sup>. Third, most biological samples contain water, and unlike infrared spectroscopy, the Raman spectra of biological samples do not suffer from spectral interference of water vibrational bands. Fourth, Raman spectroscopy is a scattering technique, requiring very little, if any, sample preparation. Finally, the technological advances during the past fifteen years, such as holographic notch filters, small-form diode lasers, and thermoelectrically cooled charge-coupled device detectors, have enabled the production of less expensive, compact, and portable Raman spectroscopic systems.

While Raman spectroscopy has been used extensively to study the process of biomineralization<sup>84-98</sup>, it has not been previously used to provide insight into the pathologic process of heterotopic ossification. We have collected Raman spectra of uninjured muscle, injured muscle, and combat-injured tissue with pre-heterotopic ossification (defined as palpably firm or “woody” tissue without roentgenographic evidence

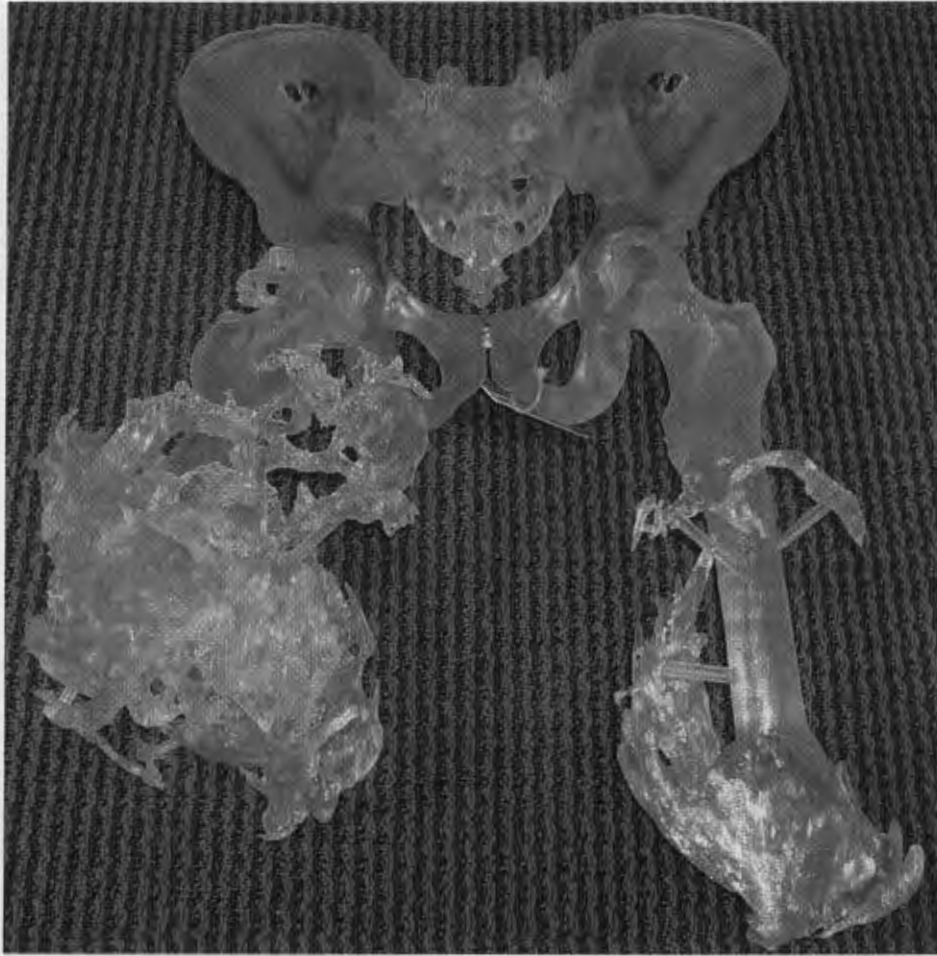


Fig. 6-B

of heterotopic ossification) found within high-energy penetrating wounds (Fig. 9). When comparing uninjured to injured muscle, there is an apparent decrease in the 1340 and 1320  $\text{cm}^{-1}$  vibrational bands in the injured muscle as well as an increase in the 1266  $\text{cm}^{-1}$  vibrational band. This suggests collagen-specific alterations within the tissue, as a result of traumatic injury. In one case, a patient exhibited combat-injured muscle with pre-heterotopic ossification during a debridement procedure. On Raman spectroscopic examination, it was clear that the tissue was indeed mineralized, even in “soft” tissue areas. Mineral vibrational bands at 1070, 960, and 591  $\text{cm}^{-1}$ , typical of a carbonated apatite, were prominent in the spectrum. These vibrational bands are attributed to the phosphate and carbonate stretching modes of bone<sup>99</sup>. Thus, Raman spectroscopy can potentially be utilized to identify areas of tissue affected by early combat-related heterotopic ossification as well as areas of tissue that may be predisposed to the formation of combat-related heterotopic ossification.

#### Small Animal Model

A critical hurdle in our investigation of the etiology, treatment, and prevention of combat-related heterotopic os-

sification is the absence of a reliable and reproducible small animal model in which to further characterize the formation of combat-related heterotopic ossification, potentially identifying new therapeutic targets, and to test new therapeutic interventions. Currently, several small animal models exist. These models include the forcible passive manipulation of the hindlimbs of paralyzed rabbits<sup>100,101</sup>; implantation of Matrigel (basement membrane/collagen-IV matrix; BD Biosciences, Bedford, Massachusetts) impregnated with recombinant human bone morphogenetic protein (rhBMP)-2<sup>98</sup> or BMP-4<sup>102</sup> in genetically predisposed mice; implantation of genetically engineered, BMP-2-producing human or murine fibroblasts into immunocompromised mice<sup>103</sup>; and crush injury of the quadriceps augmented with syngeneic bone-marrow stem cells in inbred rats<sup>104</sup>. Our current understanding of heterotopic ossification suggests that these models have important limitations that may make them unsuitable proxies for combat-related heterotopic ossification. Specifically, these models all lack the systemic injury (e.g., blast injury and/or traumatic brain injury) components commonly seen in injured military personnel with combat-related heterotopic ossification. Additionally, no induced wound with associated bacterial contamination and resulting bioburden, as is the

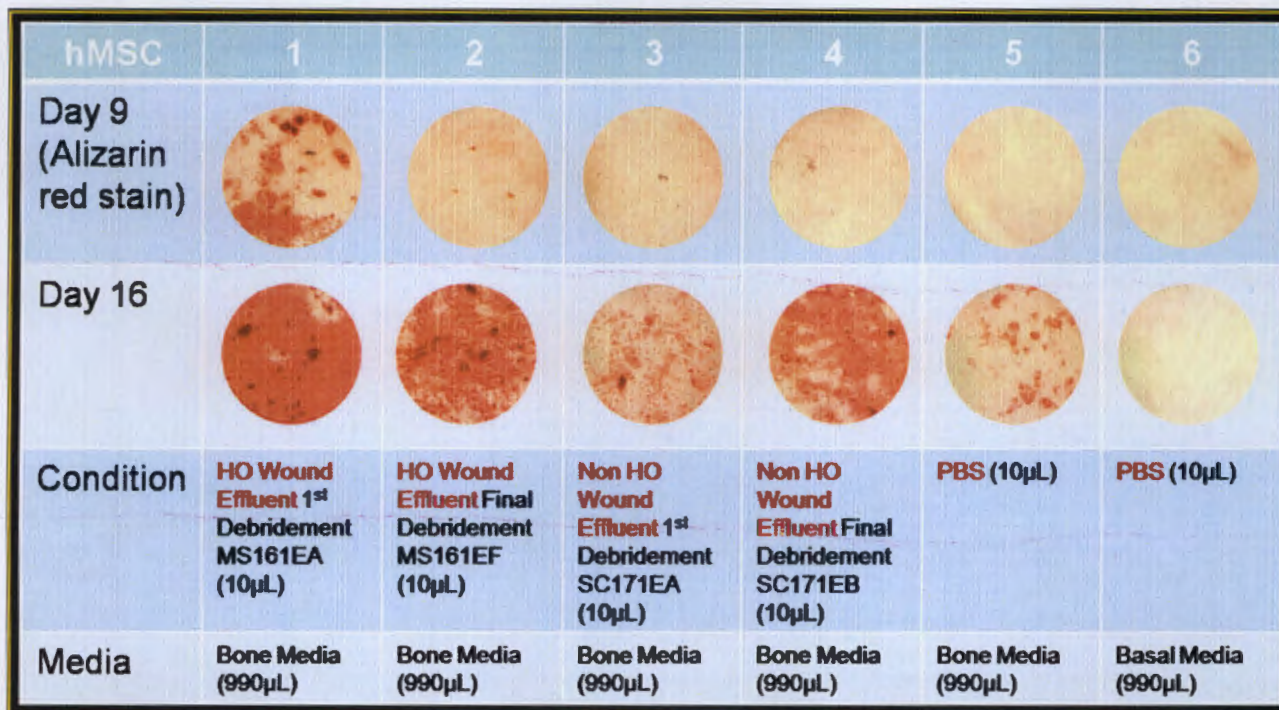


Fig. 7

Microphotographs of commercially available adult mesenchymal stem cells (hMSC) cultured in standard bone or basal media, with the addition of wound effluent from blast-injured patients who developed heterotopic ossification at the same site, blast-injured patients who did not develop ectopic bone, or phosphate-buffered saline solution, at days 9 and 16 of cell culture. Alizarin red (bone) staining ( $\times 10$  magnification) demonstrated increased osteogenesis in the cells cultured with wound effluent from a patient who developed heterotopic ossification. HO = heterotopic ossification, and PBS = phosphate-buffered saline.

rule rather than the exception for combat injuries, is associated with these models. Moreover, there is a lack of general agreement within the current literature as to whether all inciting events lead to heterotopic ossification via the same cellular mechanisms and even whether all heterotopic ossification occurs via enchondral ossification<sup>2,22,105</sup>. Finally, these models are non-physiologic in that they artificially induce bone growth in the soft tissues of small animals through augmentation or manipulation of cellular signals, genetic predispositions, and/or cell presence. Previously described small-animal models therefore produce ectopic bone growth that may have little, if any, relationship to the clinical heterotopic ossification that is seen in human patients in general or in combat-injured patients in particular.

We have conceived of a physiologic rodent model that we hope will fill this research gap. Our model incorporates blast exposure, soft-tissue crush injury, and bacterial contamination, augmented with one of several additional systemic insults to invoke additional systemic inflammation. The fracture component will be omitted to limit rodent mortality as well as avoid confounding results due to exuberant fracture callus, if it were to occur. It is our hope that this model will reliably produce heterotopic ossification through mechanisms similar to that seen in our combat-wounded patients and that it will allow further characterization of this pathologic process. Once validated, this

model may permit future identification of novel therapeutic targets as well as testing of various described and original therapeutic modalities.

#### Prospective Randomized Trial of Primary Prophylaxis in Combat-Injured Patients

As noted, due to medical contraindications and logistical constraints, no practicable primary prophylaxis regimen has yet been developed, tested, or widely utilized in wounded servicemen despite the exceedingly high rate of heterotopic ossification in this population. Recently, COX-2 inhibitors such as celecoxib have been shown to be safe and efficacious for the prevention of heterotopic ossification following hip and acetabular surgery<sup>106-108</sup> and may be useful in our patient population. COX-2 is required for endochondral bone formation, a mechanism implicated in the development of heterotopic ossification<sup>103</sup>. Although not prescribed as prophylaxis against heterotopic ossification, COX-2 inhibitors are currently used in this institution as part of a comprehensive pain-management regimen and are thought to decrease the patient's opioid requirement. Concerns about COX-2 inhibitors in an orthopaedic population stem from the blunting of "helpful" inflammation necessary for endochondral ossification in early fracture-healing<sup>109-113</sup>. Nevertheless, several studies evaluating COX-2 inhibitors found

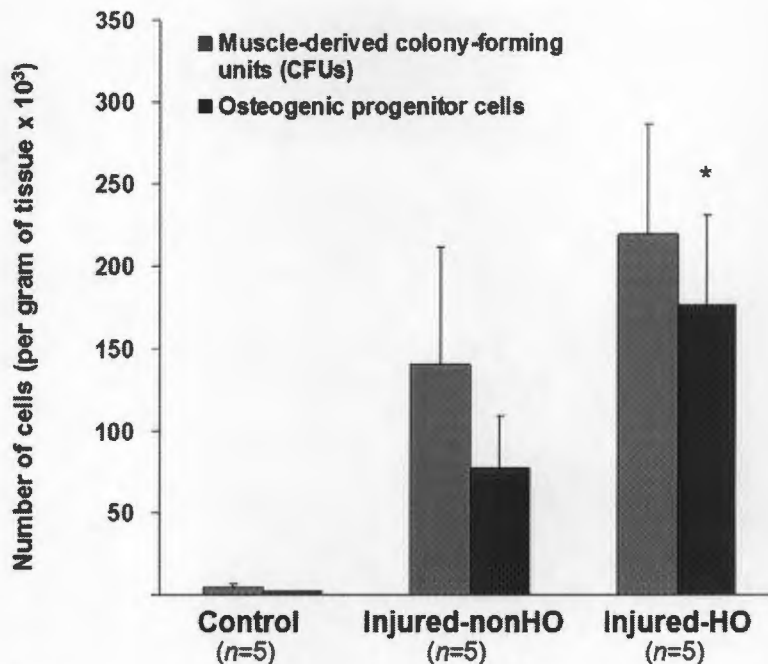


Fig. 8

Graphical depiction of the number of muscle-derived colony-forming units and osteogenic progenitor cells cultured from muscle tissue of normal (control) patients, combat-injured patients who did not develop heterotopic ossification (Injured-nonHO), and combat-injured patients who developed heterotopic ossification (Injured-HO). Even with these preliminary results ( $n = 5$  patients per group) a significant (\*,  $p < 0.05$ ) increase in the number of osteogenic progenitor cells is evident in patients who developed heterotopic ossification as compared with patients in the other two groups. (Error bars indicate 95% confidence interval.)

little or no deleterious effect on fracture-healing or osseous healing<sup>99,114-117</sup>.

In order to address the safety and efficacy of COX-2 inhibition in combat-related heterotopic ossification, a prospective randomized trial of celecoxib, started within five days after injury for a two-week treatment period (200 mg by mouth twice a day), will begin enrolling patients this year. The study will enroll as many as 100 patients (fifty in the treatment arm and fifty in the control arm), and is powered to detect a 30% relative decrease in the rate of formation of combat-related heterotopic ossification (e.g., a decrease from 60% to 40%). Primary study end points are the overall prevalence and severity of combat-related heterotopic ossification in study patients. This decrease in combat-related prevalence of heterotopic ossification is well below that anticipated on the basis of a putative 56% to 67% reduction in heterotopic ossification rates with use of nonsteroidal anti-inflammatory drugs in other populations<sup>31</sup>. Testing for this lower rate of reduction appears reasonable because the actual effect of nonsteroidal anti-inflammatory drugs may differ in patients with combat-related heterotopic ossification, because treatment cannot practicably be initiated at the point and time of injury, and because testing would serve to ensure adequate power of the trial. Secondary end points include fracture nonunion, time to

fracture union, rate of impaired wound-healing, medical and drug-related complications (e.g., gastrointestinal problems and renal dysfunction), and patient pain ratings and opioid requirements.

The concern that celecoxib may delay fracture-healing is an important one. Nevertheless, its effect may be tempered by the timing of fracture fixation in a high-energy penetrating injury of an extremity. In most cases, fracture fixation is not performed until ten to fourteen days after injury, which is the time it takes to debride and prepare the wound for closure or flap coverage. Prophylaxis against heterotopic ossification is started as soon after injury as possible and continued for fourteen days. Ideally, celecoxib dosing for the purpose of prophylaxis against heterotopic ossification will be complete prior to definitive fracture fixation. Goodman and colleagues demonstrated that COX-2 inhibitors, if given within the first fourteen days following fracture, did not result in appreciable impairment of fracture-healing<sup>118</sup>. There is also no evidence to suggest that celecoxib significantly affects fracture-healing in our combat-wounded patient population. Nevertheless, "nonunion" and "time to union" will be reported as secondary outcomes in this study. Of note, short-term use of celecoxib in patients without fractures, including amputees, has not been associated with any negative effects.

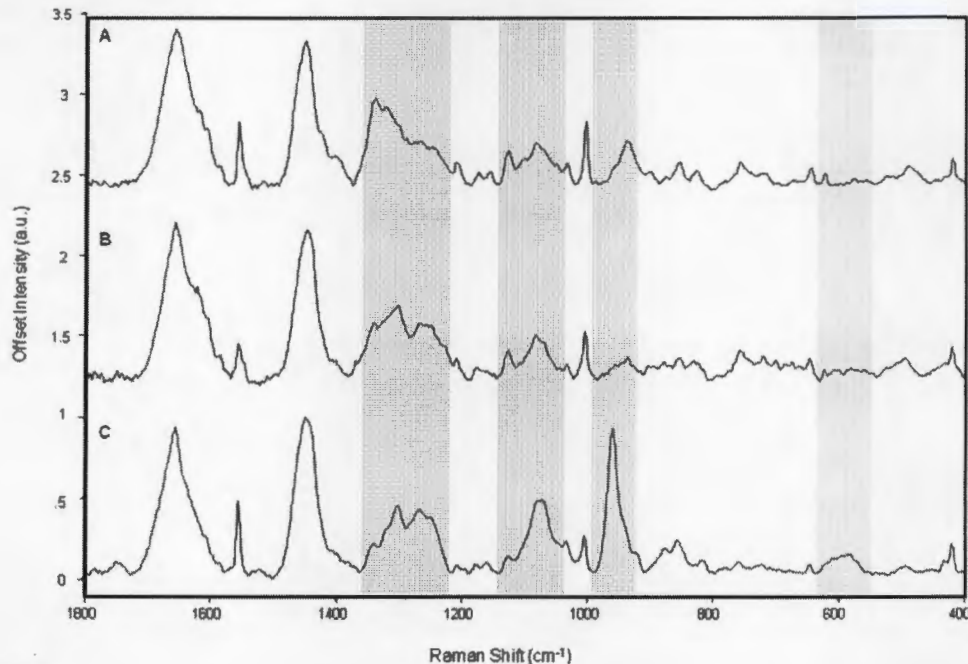


Fig. 9

Raman spectra of (A) uninjured muscle (control tissue), (B) combat-injured muscle, and (C) combat-injured muscle with pre-heterotopic ossification. The gray bands highlight spectral changes in the amide-III envelope (1340-1240  $\text{cm}^{-1}$ ) and the appearance of mineral vibrational bands at 1070, 960, and 591  $\text{cm}^{-1}$ .

### Conclusions and Future Directions

Combat-related heterotopic ossification is exceptionally common and is often a harbinger of a complex and difficult clinical course. Operative excision of symptomatic combat-related heterotopic ossification lesions is generally successful and associated with low rates of recurrence but can be technically demanding and fraught with complications, particularly about the knee when concurrent quadricepsplasty is required. We have identified numerous clinical factors and biological markers that are predictive of eventual formation of combat-related heterotopic ossification. Through ongoing and future research efforts by our consortium, we hope to further elucidate the biochemical and cellular basis for the formation of combat-related heterotopic ossification, further define the relative roles of local and systemic inflammation, continue to develop new means of early diagnosis and prognostication, and test and validate both conventional and novel practicable primary prophylactic treatment modalities. It is our hope that, through a combination of new diagnostic and therapeutic interventions, we can affect both the incidence and clinical management of combat-related heterotopic ossification. ■

Note: The authors acknowledge the research and/or clinical support of the following individuals: Fred Gage; Wesley Stepp, MS; Steve Ahlers, PhD; COL James Ficke, MD; COL(ret) William Doukas,

MD; LTC(P) Romney Andersen, MD; LTC(P) Dan White, MD; LTC Scott Shawen, MD; CDR John Keeling, MD; MAJ Wade Gordon, MD; Stephen Rouse, PhD; Peter Liacouras, PhD; LTC(P) Tad Gerlinger, MD; LTC(P) Donald Gajewski, MD; MAJ(P) Joseph Hsu; and H. Michael Frisch, MD.

MAJ Benjamin K. Potter, MD  
LCDR Jonathan A. Forsberg, MD  
CPT Korboi N. Evans, MD  
MAJ Jason S. Hawksworth, MD  
CPT Frederick P. O'Brien, MD  
Walter Reed National Military Medical Center,  
6900 Georgia Avenue N.W., Bldg 2, Clinic 5A, Washington, DC 20307.  
E-mail address for B.K. Potter: kyle.potter@us.army.mil

Thomas A. Davis, PhD  
Doug Tadaki, PhD  
Trevor S. Brown, PhD  
Nicole J. Crane, PhD  
CDR Eric A. Elster, MD  
Naval Medical Research Center,  
503 Robert Grant Avenue, Silver Spring, MD 20910

MAJ Travis C. Burns, MD  
San Antonio Military Medical Center,  
3851 Roger Brooke Drive, Fort Sam Houston, Texas 78234

### References

1. Al-Zahrawi AQK. *Albucasis on surgery and instruments*. Berkeley: University of California Press; 1972.

2. Kaplan FS, Glaser DL, Hebela N, Shore EM. Heterotopic ossification. *J Am Acad Orthop Surg*. 2004;12:116-25.

3. Garland DE. Clinical observations on fractures and heterotopic ossification in the spinal cord and traumatic brain injured populations. *Clin Orthop Relat Res.* 1988; 233:86-101.
4. Garland DE, O'Hollaren RM. Fractures and dislocations about the elbow in the head-injured adult. *Clin Orthop Relat Res.* 1982;168:38-41.
5. Dougherty PJ. Long-term follow-up study of bilateral above-the-knee amputees from the Vietnam War. *J Bone Joint Surg Am.* 1999;81:1384-90.
6. Dougherty PJ. Transtibial amputees from the Vietnam War. Twenty-eight-year follow-up. *J Bone Joint Surg Am.* 2001;83:383-9.
7. Hull JB. Traumatic amputation by explosive blast: pattern of injury in survivors. *Br J Surg.* 1992;79:1303-6.
8. Johnson DE, Fleming A, Wongrukmitr B, Traverso LW. Combat casualties in northern Thailand: emphasis on land mine injuries and levels of amputation. *Mil Med.* 1981;146:682-5.
9. Brackett EG. Care of the amputated in the United States. In: *The medical department of the United States army in the world war. Vol. 2.* Washington, DC: US Government Printing Office; 1927. p 713-48.
10. Otis GA, Huntington DL. Wounds and complications. In: *The medical and surgical history of the civil war. Vol. 2, pt. 3.* Washington, DC: US Government Printing Office; 1883. p 880.
11. Covey DC. Blast and fragment injuries of the musculoskeletal system. *J Bone Joint Surg Am.* 2002;84:1221-34.
12. Covey DC. Combat orthopaedics: a view from the trenches. *J Am Acad Orthop Surg.* 2006;14(10 Spec No.):S10-7.
13. Gofrit ON, Leibovici D, Shapira SC, Shemer J, Stein M, Michaelson M. The trimodal death distribution of trauma victims: military experience from the Lebanon War. *Mil Med.* 1997;162:24-6.
14. Islinger RB, Kukio TR, McHale KA. A review of orthopedic injuries in three recent U.S. military conflicts. *Mil Med.* 2000;165:463-5.
15. Lin DL, Kirk KL, Murphy KP, McHale KA, Doukas WC. Evaluation of orthopaedic injuries in Operation Enduring Freedom. *J Orthop Trauma.* 2004;18(8 Suppl): S48-53.
16. London PS. Medical lessons from the Falkland Islands' Campaign. Report of a meeting of the United Services Section of the Royal Society of Medicine held at the Royal College of Surgeons on February 17 and 18, 1983. *J Bone Joint Surg Br.* 1983;65:507-10.
17. Mabry RL, Holcomb JB, Baker AM, Cloonan CC, Uhorchak JM, Perkins DE, Canfield AJ, Hagmann JH. United States Army Rangers in Somalia: an analysis of combat casualties on an urban battlefield. *J Trauma.* 2000;49:515-29.
18. Mazurek MT, Ficke JR. The scope of wounds encountered in casualties from the global war on terrorism: from the battlefield to the tertiary treatment facility. *J Am Acad Orthop Surg.* 2006;14(10 Spec No.):S18-23.
19. Fox CJ, Gillespie DL, Cox ED, Kragh JF Jr, Mehta SG, Salinas J, Holcomb JB. Damage control resuscitation for vascular surgery in a combat support hospital. *J Trauma.* 2008;65:1-9.
20. Kragh JF Jr, Walters TJ, Baer DG, Fox CJ, Wade CE, Salinas J, Holcomb JB. Survival with emergency tourniquet use to stop bleeding in major limb trauma. *Ann Surg.* 2009;249:1-7.
21. Forsberg JA, Pepek JM, Wagner S, Wilson K, Flint J, Andersen RC, Tadaki D, Gage FA, Stojadinovic A, Elster EA. Heterotopic ossification in high-energy wartime extremity injuries: prevalence and risk factors. *J Bone Joint Surg Am.* 2009;91:1084-91.
22. Forsberg JA, Potter BK. Heterotopic ossification in wartime wounds. *J Surg Orthop Adv.* 2010;19:54-61.
23. Potter BK, Burns TC, Lacap AP, Granville RR, Gajewski DA. Heterotopic ossification following traumatic and combat-related amputations. Prevalence, risk factors, and preliminary results of excision. *J Bone Joint Surg Am.* 2007;89:476-86.
24. Garland DE. A clinical perspective on common forms of acquired heterotopic ossification. *Clin Orthop Relat Res.* 1991;263:13-29.
25. Garland DE, Blum CE, Waters RL. Periarticular heterotopic ossification in head-injured adults. Incidence and location. *J Bone Joint Surg Am.* 1980;62:1143-6.
26. Garland DE, Dowling V. Forearm fractures in the head-injured adult. *Clin Orthop Relat Res.* 1983;176:190-6.
27. Giannoudis PV, Mushtaq S, Harwood P, Kambhampati S, Dimoutsos M, Stavrou Z, Pape HC. Accelerated bone healing and excessive callus formation in patients with femoral fracture and head injury. *Injury.* 2006;37 Suppl 3:S18-24.
28. Spencer RF. The effect of head injury on fracture healing. A quantitative assessment. *J Bone Joint Surg Br.* 1987;69:525-8.
29. Steinberg GG, Hubbard C. Heterotopic ossification after femoral intramedullary rodding. *J Orthop Trauma.* 1993;7:536-42.
30. Burd TA, Lowry KJ, Anglen JO. Indomethacin compared with localized irradiation for the prevention of heterotopic ossification following surgical treatment of acetabular fractures. *J Bone Joint Surg Am.* 2001;83:1783-8.
31. Fransen M, Neal B. Non-steroidal anti-inflammatory drugs for preventing heterotopic bone formation after hip arthroplasty. *Cochrane Database Syst Rev.* 2004; 3:CD001160.
32. Gregoritch SJ, Chadha M, Pelligrini VD, Rubin P, Kantorowitz DA. Randomized trial comparing preoperative versus postoperative irradiation for prevention of heterotopic ossification following prosthetic total hip replacement: preliminary results. *Int J Radiat Oncol Biol Phys.* 1994;30:55-62.
33. Matta JM, Siebenrock KA. Does indomethacin reduce heterotopic bone formation after operations for acetabular fractures? A prospective randomised study. *J Bone Joint Surg Br.* 1997;79:959-63.
34. Moore KD, Goss K, Anglen JO. Indomethacin versus radiation therapy for prophylaxis against heterotopic ossification in acetabular fractures: a randomised, prospective study. *J Bone Joint Surg Br.* 1998;80:259-63.
35. Pakos EE, Ioannidis JP. Radiotherapy vs. nonsteroidal anti-inflammatory drugs for the prevention of heterotopic ossification after major hip procedures: a meta-analysis of randomized trials. *Int J Radiat Oncol Biol Phys.* 2004;60:888-95.
36. Pellegrini VD Jr, Kanski AA, Gastel JA, Rubin P, Evarts CM. Prevention of heterotopic ossification with irradiation after total hip arthroplasty. Radiation therapy with a single dose of eight hundred centigray administered to a limited field. *J Bone Joint Surg Am.* 1992;74:186-200.
37. Koelbl O, Seufert J, Pohl F, Tauscher A, Lehmann H, Springorum HW, Flentje M. Preoperative irradiation for prevention of heterotopic ossification following prosthetic total hip replacement results of a prospective study in 462 hips. *Strahlenther Onkol.* 2003;179:767-73.
38. Moed BR, Letoumel E. Low-dose irradiation and indomethacin prevent heterotopic ossification after acetabular fracture surgery. *J Bone Joint Surg Br.* 1994;76: 895-900.
39. Seegenschmiedt MH, Goldmann AR, Martus P, Wölfel R, Hohmann D, Sauer R. Prophylactic radiation therapy for prevention of heterotopic ossification after hip arthroplasty: results in 141 high-risk hips. *Radiology.* 1993;188:257-64.
40. Seegenschmiedt MH, Goldmann AR, Wölfel R, Hohmann D, Beck H, Sauer R. Prevention of heterotopic ossification (HO) after total hip replacement: randomized high versus low dose radiotherapy. *Radiother Oncol.* 1993;26:271-4.
41. Blokhuis TJ, Frölke JP. Is radiation superior to indomethacin to prevent heterotopic ossification in acetabular fractures?: a systematic review. *Clin Orthop Relat Res.* 2009;467:526-30.
42. Haran M, Bhuta T, Lee B. Pharmacological interventions for treating acute heterotopic ossification. *Cochrane Database Syst Rev.* 2004;18:CD003321.
43. Buschbacher R, McKinley W, Buschbacher L, Devaney CW, Coplin B. Warfarin in prevention of heterotopic ossification. *Am J Phys Med Rehabil.* 1992;71:86-91.
44. Guillemin F, Mainard D, Rolland H, Delagoutte JP. Antivitamin K prevents heterotopic ossification after hip arthroplasty in diffuse idiopathic skeletal hyperostosis. A retrospective study in 67 patients. *Acta Orthop Scand.* 1995;66:123-6.
45. Günal I, Hazer B, Seber S, Göktürk E, Turgut A, Köse N. Prevention of heterotopic ossification after total hip replacement: a prospective comparison of indomethacin and salmon calcitonin in 60 patients. *Acta Orthop Scand.* 2001;72:467-9.
46. Moed BR, Karges DE. Prophylactic indomethacin for the prevention of heterotopic ossification after acetabular fracture surgery in high-risk patients. *J Orthop Trauma.* 1994;8:34-9.
47. Salai M, Langevitz P, Blankstein A, Zemmer D, Chechick A, Pras M, Horoszowski H. Total hip replacement in familial Mediterranean fever. *Bull Hosp Jt Dis.* 1993;53: 25-8.
48. Shimono K, Morrison TN, Tung WE, Chandraratna RA, Williams JA, Iwamoto M, Pacifici M. Inhibition of ectopic bone formation by a selective retinoic acid receptor alpha-agonist: a new therapy for heterotopic ossification? *J Orthop Res.* 2010;28: 271-7.
49. Beingessner DM, Patterson SD, King GJ. Early excision of heterotopic bone in the forearm. *J Hand Surg Am.* 2000;25:483-8.
50. Freebourn TM, Barber DB, Able AC. The treatment of immature heterotopic ossification in spinal cord injury with combination surgery, radiation therapy and NSAID. *Spinal Cord.* 1999;37:50-3.
51. Garland DE, Hanscom DA, Keenan MA, Smith C, Moore T. Resection of heterotopic ossification in the adult with head trauma. *J Bone Joint Surg Am.* 1985;67: 1261-9.

52. Garland DE, Orwin JF. Resection of heterotopic ossification in patients with spinal cord injuries. *Clin Orthop Relat Res.* 1989;242:169-76.
53. McAuliffe JA, Wolfson AH. Early excision of heterotopic ossification about the elbow followed by radiation therapy. *J Bone Joint Surg Am.* 1997;79:749-55.
54. Moritomo H, Tada K, Yoshida T. Early, wide excision of heterotopic ossification in the medial elbow. *J Shoulder Elbow Surg.* 2001;10:164-8.
55. Shehab D, Elgazzar AH, Collier BD. Heterotopic ossification. *J Nucl Med.* 2002;43:346-53.
56. Tsiornos I, Leclercq C, Rochet JM. Heterotopic ossification of the elbow in patients with burns. Results after early excision. *J Bone Joint Surg Br.* 2004;86:396-403.
57. VanLaeken N, Snelling CF, Meek RN, Warren RJ, Foley B. Heterotopic bone formation in the patient with burn injuries. A retrospective assessment of contributing factors and methods of investigation. *J Burn Care Rehabil.* 1989;10:331-5.
58. Viola RW, Hanel DP. Early "simple" release of posttraumatic elbow contracture associated with heterotopic ossification. *J Hand Surg Am.* 1999;24:370-80.
59. Evans KN, Forsberg JA, Potter BK, Hawksworth JS, Brown TS, Andersen RC, Dunne JR, Stojadinovic A, Tadaki D, Elster EA. Inflammatory cytokine and chemokine expression is associated with heterotopic ossification in high-energy penetrating war injuries. Read at the Annual Uniformed Services University Surgical Associates Day; 2009 Mar 23; Bethesda, MD.
60. Forsberg JA, Elster EA, Andersen RC, Nylen E, Brown TS, Rose MW, Stojadinovic A, Becker KL, McGuigan FX. Correlation of procalcitonin and cytokine expression with dehiscence of wartime extremity wounds. *J Bone Joint Surg Am.* 2008;90:580-8.
61. Utz ER, Elster EA, Tadaki DK, Gage F, Perdue PW, Forsberg JA, Stojadinovic A, Hawksworth JS, Brown TS. Metalloproteinase expression is associated with traumatic wound failure. *J Surg Res.* 2010;159:633-9.
62. Hawksworth JS, Stojadinovic A, Gage FA, Tadaki DK, Perdue PW, Forsberg J, Davis TA, Dunne JR, Denobile JW, Brown TS, Elster EA. Inflammatory biomarkers in combat wound healing. *Ann Surg.* 2009;250:1002-7.
63. Uccelli A, Moretta L, Pistoia V. Mesenchymal stem cells in health and disease. *Nat Rev Immunol.* 2008;8:726-36.
64. da Silva Meirelles L, Chagastelles PC, Nardi NB. Mesenchymal stem cells reside in virtually all post-natal organs and tissues. *J Cell Sci.* 2006;119:2204-13.
65. Caplan AI. Adult mesenchymal stem cells for tissue engineering versus regenerative medicine. *J Cell Physiol.* 2007;213:341-7.
66. Chamberlain G, Fox J, Ashton B, Middleton J. Concise review: mesenchymal stem cells: their phenotype, differentiation capacity, immunological features, and potential for homing. *Stem Cells.* 2007;25:2739-49.
67. Jackson WM, Nesti LJ, Tuan RS. Potential therapeutic applications of muscle-derived mesenchymal stem and progenitor cells. *Expert Opin Biol Ther.* 2010;10:505-17.
68. Phinney DG, Prockop DJ. Concise review: mesenchymal stem/multipotent stromal cells: the state of transdifferentiation and modes of tissue repair—current views. *Stem Cells.* 2007;25:2896-902.
69. Jackson WM, Aragon AB, Bulken-Hoover JD, Nesti LJ, Tuan RS. Putative heterotopic ossification progenitor cells derived from traumatized muscle. *J Orthop Res.* 2009;27:1645-51.
70. Jackson WM, Aragon AB, Djouad F, Song Y, Koehler SM, Nesti LJ, Tuan RS. Mesenchymal progenitor cells derived from traumatized human muscle. *J Tissue Eng Regen Med.* 2009;3:129-38.
71. Nesti LJ, Jackson WM, Shanti RM, Koehler SM, Aragon AB, Bailey JR, Sracic MK, Freedman BA, Giuliani JR, Tuan RS. Differentiation potential of multipotent progenitor cells derived from war-traumatized muscle tissue. *J Bone Joint Surg Am.* 2008;90:2390-8.
72. O'Brien FP, Anam K, Potter BK, Tadaki D, Forsberg JA, Elster EA, Davis TA. Heterotopic ossification formation in complex orthopedic combat wounds: quantification and characterization of mesenchymal stem/progenitor cell activity in traumatized muscle. Read at the Robert A Phillips Resident Research Competition; 2010 Apr 16; Bethesda, MD.
73. Hattori Y, Komachi Y, Asakura T, Shimosegawa T, Kanai G, Tashiro H, Sato H. In vivo Raman study of the living rat esophagus and stomach using a micro-Raman probe under an endoscope. *Appl Spectrosc.* 2007;61:579-84.
74. Shim MG, Song LM, Marcon NE, Wilson BC. In vivo near-infrared Raman spectroscopy: demonstration of feasibility during clinical gastrointestinal endoscopy. *Photochem Photobiol.* 2000;72:146-50.
75. Robichaux-Viehoever A, Kanter E, Shappell H, Billheimer D, Jones H 3rd, Mahadevan-Jansen A. Characterization of Raman spectra measured in vivo for the detection of cervical dysplasia. *Appl Spectrosc.* 2007;61:986-93.
76. Lieber CA, Majumder SK, Ellis DL, Billheimer DD, Mahadevan-Jansen A. In vivo non-melanoma skin cancer diagnosis using Raman microspectroscopy. *Lasers Surg Med.* 2008;40:461-7.
77. Egawa M, Kunizawa N, Hirao T, Yamamoto T, Sakamoto K, Terui T, Tagami H. In vivo characterization of the structure and components of lesional psoriatic skin from the observation with Raman spectroscopy and optical coherence tomography: a pilot study. *J Dermatol Sci.* 2010;57:66-9.
78. Chau AH, Motz JT, Gardecki JA, Waxman S, Bouma BE, Teamey GJ. Fingerprint and high-wavenumber Raman spectroscopy in a human-swine coronary xenograft in vivo. *J Biomed Opt.* 2008;13:040501.
79. Bernstein PS, Zhao DY, Sharifzadeh M, Ermakov IV, Gellermann W. Resonance Raman measurement of macular carotenoids in the living human eye. *Arch Biochem Biophys.* 2004;430:163-9.
80. Bernstein PS, Zhao DY, Wintch SW, Ermakov IV, McClane RW, Gellermann W. Resonance Raman measurement of macular carotenoids in normal subjects and in age-related macular degeneration patients. *Ophthalmology.* 2002;109:1780-7.
81. Gellermann W, Bernstein PS. Noninvasive detection of macular pigments in the human eye. *J Biomed Opt.* 2004;9:75-85.
82. Zhao DY, Wintch SW, Ermakov IV, Gellermann W, Bernstein PS. Resonance Raman measurement of macular carotenoids in retinal, choroidal, and macular dystrophies. *Arch Ophthalmol.* 2003;121:967-72.
83. Schulmerich MV, Cole JH, Kreider JM, Esmonde-White F, Dooley KA, Goldstein SA, Morris MD. Transcutaneous Raman spectroscopy of murine bone in vivo. *Appl Spectrosc.* 2009;63:286-95.
84. Akkus O, Adar F, Schaffler MB. Age-related changes in physicochemical properties of mineral crystals are related to impaired mechanical function of cortical bone. *Bone.* 2004;34:443-53.
85. Crane NJ, Popescu V, Morris MD, Steenhuis P, Ignelzi MA Jr. Raman spectroscopic evidence for octacalcium phosphate and other transient mineral species deposited during intramembranous mineralization. *Bone.* 2006;39:434-42.
86. Gajjaraman S, Narayanan K, Hao J, Qin C, George A. Matrix macromolecules in hard tissues control the nucleation and hierarchical assembly of hydroxyapatite. *J Biol Chem.* 2007;282:1193-204.
87. Kohn DH. Ultrastructural changes during the fatigue of bone. *JOM J Miner Metals Mater Soc.* 2006;58:46-50.
88. Kozloff KM, Carden A, Bergwitz C, Forlino A, Uveges TE, Morris MD, Marini JC, Goldstein SA. Brittle IV mouse model for osteogenesis imperfecta IV demonstrates postpubertal adaptations to improve whole bone strength. *J Bone Miner Res.* 2004;19:614-22.
89. Lakshmi RJ, Alexander M, Kurien J, Mahato KK, Kartha VB. Osteoradionecrosis (ORN) of the mandible: a laser Raman spectroscopic study. *Appl Spectrosc.* 2003;57:1100-16.
90. McCreddie BR, Morris MD, Chen TC, Sudhaker Rao D, Finney WF, Widjaja E, Goldstein SA. Bone tissue compositional differences in women with and without osteoporotic fracture. *Bone.* 2006;39:1190-5.
91. Morris MD, Finney WF, Rajachar RM, Kohn DH. Bone tissue ultrastructural response to elastic deformation probed by Raman spectroscopy. *Faraday Discuss.* 2004;126:159-63.
92. Nalla RK, Kruzic JJ, Kinney JH, Balooch M, Ager JW III, Ritchie RO. Role of microstructure in the aging-related deterioration of the toughness of human cortical bone. *Mater Sci Eng C.* 2006;26:1251-60.
93. Penel G, Leroy G, Rey C, Bres E. MicroRaman spectral study of the PO4 and CO3 vibrational modes in synthetic and biological apatites. *Calcif Tissue Int.* 1998;63:475-81.
94. Rehman I, Smith R, Hench LL, Bonfield W. Structural evaluation of human and sheep bone and comparison with synthetic hydroxyapatite by FT-Raman spectroscopy. *J Biomed Mater Res.* 1995;29:1287-94.
95. Smith R, Rehman I. Fourier transform Raman spectroscopic studies of human bone. *J Mater Sci.* 1994;5:775-8.
96. Tamowski CP, Ignelzi MA Jr, Morris MD. Mineralization of developing mouse calvaria as revealed by Raman microspectroscopy. *J Bone Miner Res.* 2002;17:1118-26.
97. Wopenka B, Kent A, Pasteris JD, Yoon Y, Thomopoulos S. The tendon-to-bone transition of the rotator cuff: a preliminary Raman spectroscopic study documenting the gradual mineralization across the insertion in rat tissue samples. *Appl Spectrosc.* 2008;62:1285-94.
98. Yerramshetty JS, Lind C, Akkus O. The compositional and physicochemical homogeneity of male femoral cortex increases after the sixth decade. *Bone.* 2006;39:1236-43.



- 99.** Persson PE, Sisask G, Nilsson O. Indomethacin inhibits bone formation in inductive allografts but not in autografts: studies in rat. *Acta Orthop.* 2005;76:465-9.
- 100.** Vanden Bossche LC, Van Maele G, Wojtowicz I, De Cock K, Vertriest S, De Muynck M, Rimbaut S, Vanderstraeten GG. Free radical scavengers are more effective than indomethacin in the prevention of experimentally induced heterotopic ossification. *J Orthop Res.* 2006;25:267-72.
- 101.** Izumi K. Study of ectopic bone formation in experimental spinal cord injured rabbits. *Paraplegia.* 1983;21:351-63.
- 102.** Glaser DL, Economides AN, Wang L, Liu X, Kimble RD, Fandl JP, Wilson JM, Stahl N, Kaplan FS, Shore EM. In vivo somatic cell gene transfer of an engineered Noggin mutein prevents BMP4-induced heterotopic ossification. *J Bone Joint Surg Am.* 2003;85:2332-42.
- 103.** Olmsted-Davis E, Gannon FH, Ozen M, Ittmann MM, Gugala Z, Hipp JA, Moran KM, Fouletier-Dilling CM, Schumara-Martin S, Lindsey RW, Heggness MH, Brenner MK, Davis AR. Hypoxic adipocytes pattern early heterotopic bone formation. *Am J Pathol.* 2007;170:620-32.
- 104.** Rapuano BE, Boursiquot R, Tomin E, Macdonald DE, Maddula S, Raghavan D, Lane JM, Helfet DL. The effects of COX-1 and COX-2 inhibitors on prostaglandin synthesis and the formation of heterotopic bone in a rat model. *Arch Orthop Trauma Surg.* 2008;128:333-44.
- 105.** Cipriano CA, Pill SG, Keenan MA. Heterotopic ossification following traumatic brain injury and spinal cord injury. *J Am Acad Orthop Surg.* 2009;17:689-97.
- 106.** Macfarlane RJ, Ng BH, Gamie Z, El Masry MA, Velonis S, Schizas C, Tsidiris E. Pharmacological treatment of heterotopic ossification following hip and acetabular surgery. *Expert Opin Pharmacother.* 2008;9:767-86.
- 107.** Saudan M, Saudan P, Pemeger T, Riand N, Keller A, Hoffmeyer P. Celecoxib versus ibuprofen in the prevention of heterotopic ossification following total hip replacement: a prospective randomised trial. *J Bone Joint Surg Br.* 2007;89:155-9.
- 108.** Xue D, Zheng Q, Li H, Qian S, Zhang B, Pan Z. Selective COX-2 inhibitor versus nonselective COX-1 and COX-2 inhibitor in the prevention of heterotopic ossification after total hip arthroplasty: a meta-analysis of randomised trials. *Int Orthop.* 2009 Oct 15 [Epub ahead of print].
- 109.** Bergenstock M, Min W, Simon AM, Sabatino C, O'Connor JP. A comparison between the effects of acetaminophen and celecoxib on bone fracture healing in rats. *J Orthop Trauma.* 2005;19:717-23.
- 110.** Herbenick MA, Sprott D, Stills H, Lawless M. Effects of a cyclooxygenase 2 inhibitor on fracture healing in a rat model. *Am J Orthop (Belle Mead NJ).* 2008;37: E133-7.
- 111.** Mullis BH, Copland ST, Weinhold PS, Miclau T, Lester GE, Bos GD. Effect of COX-2 inhibitors and non-steroidal anti-inflammatory drugs on a mouse fracture model. *Injury.* 2006;37:827-37.
- 112.** Simon AM, Manigrasso MB, O'Connor JP. Cyclo-oxygenase 2 function is essential for bone fracture healing. *J Bone Miner Res.* 2002;17:963-76.
- 113.** Simon AM, O'Connor JP. Dose and time-dependent effects of cyclooxygenase-2 inhibition on fracture-healing. *J Bone Joint Surg Am.* 2007;89:500-11.
- 114.** Brown KM, Saunders MM, Kirsch T, Donahue HJ, Reid JS. Effect of COX-2-specific inhibition on fracture-healing in the rat femur. *J Bone Joint Surg Am.* 2004; 86:116-23.
- 115.** Gerstenfeld LC, Thiede M, Seibert K, Mielke C, Phippard D, Svagr B, Cullinane D, Einhorn TA. Differential inhibition of fracture healing by non-selective and cyclooxygenase-2 selective non-steroidal anti-inflammatory drugs. *J Orthop Res.* 2003;21:670-5.
- 116.** Keller J. Effects of indomethacin and local prostaglandin E2 on fracture healing in rabbits. *Dan Med Bull.* 1996;43:317-29.
- 117.** Reikeraas O, Engebretsen L. Effects of ketoralac tromethamine and indomethacin on primary and secondary bone healing. An experimental study in rats. *Arch Orthop Trauma Surg.* 1998;118:50-2.
- 118.** Goodman SB, Ma T, Mitsunaga L, Miyanishi K, Genovese MC, Smith RL. Temporal effects of a COX-2-selective NSAID on bone ingrowth. *J Biomed Mater Res A.* 2005;72:279-87.