

## Radiology Corner

### Emergency Decompressive Craniotomy with Banked Skull Flap in Subcutaneous Pocket

**Guarantor:** COL Les Folio, USAF, MC, SFS

**Contributors:** COL Les Folio, USAF, MC, SFS;<sup>1,2</sup> 2LT Steven Craig, USA;<sup>1</sup> LCDR Brian Singleton, USN;<sup>1,2</sup> 2LT Brian Adams, USA<sup>1</sup>

*Note: This is the full text version of the radiology corner question published in the May 2006 issue, with the abbreviated answer in the June 2006 issue.*

#### Introduction

The following is a more detailed description of the case introduced in the May and June issues of Military Medicine's Radiology Corner.

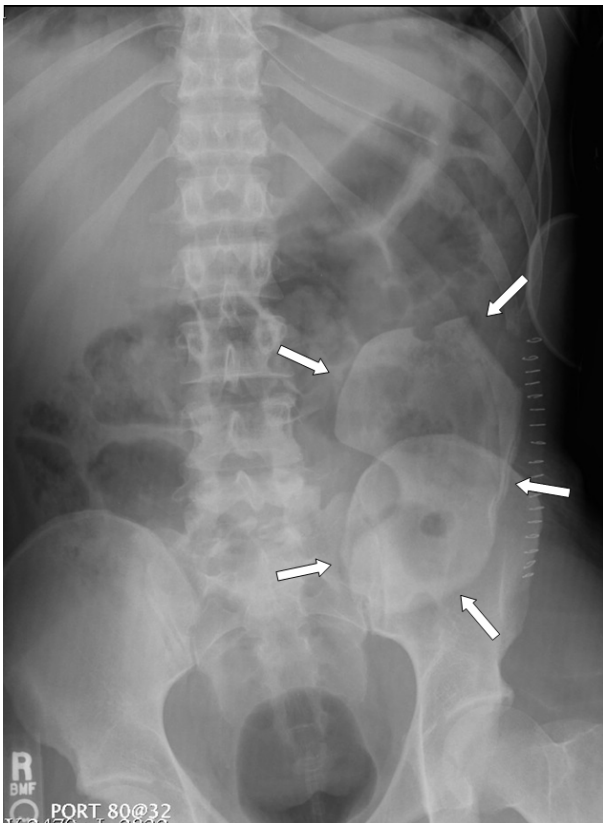


Figure 1 Plain computed radiology of abdomen demonstrate the skull flap overlying the left lower quadrant (arrows). Surgical clips and an enteric tube within stomach are seen. No other abnormalities.

<sup>1</sup> Department of Radiology and Radiological Sciences; Uniformed Services University of the Health Sciences, Bethesda, Maryland 20814-4799

<sup>2</sup> Department of Radiology National Naval Medical Center, Bethesda, Maryland 20814-4799

Reprint & Copyright © by Association of Military Surgeons of U.S., 2006

#### Summary of Imaging Findings

The abdominal KUB (Kidneys, Ureters, and Bladder, also sometimes referred to as “Flat Plate”) demonstrates a smooth, large, calcific opacity in the left lower quadrant (see figure 1). An enteric tube is also noted with its tip in stomach; surgical staples are noted peripherally to skull cap. No other abnormalities are present on the KUB.

The axial CT of the abdomen localizes the skull cap to the anterior abdominal wall subcutaneous tissue (see figure 2). CT also shows 10 x 6 x 1.5 cm non-enhancing homogeneous low attenuating fluid collection posterior to the skull cap.

For providers that have not heard of banking the skull cap in the abdomen, this type of finding can be perplexing. This procedure became common in recent military combat operations; however, the trend may change due to unique infection potential in other continents.

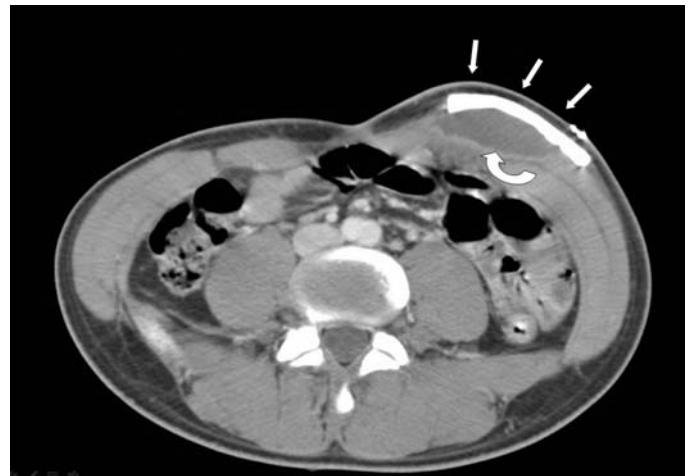

Figure 2. Note the skull cap (arrows) with the posterior homogeneous attenuating fluid collection (curved arrow) in left anterior abdominal wall.

Axial head CT (figure 3) demonstrates the craniectomy site (arrows). Additionally, there is left parieto-occipital encephalomalacia. There are metallic fragments/shrapnel (bone windows not included) causing beam hardening artifact in occipital bone (curved arrow).

# Report Documentation Page

*Form Approved*  
*OMB No. 0704-0188*

Public reporting burden for the collection of information is estimated to average 1 hour per response, including the time for reviewing instructions, searching existing data sources, gathering and maintaining the data needed, and completing and reviewing the collection of information. Send comments regarding this burden estimate or any other aspect of this collection of information, including suggestions for reducing this burden, to Washington Headquarters Services, Directorate for Information Operations and Reports, 1215 Jefferson Davis Highway, Suite 1204, Arlington VA 22202-4302. Respondents should be aware that notwithstanding any other provision of law, no person shall be subject to a penalty for failing to comply with a collection of information if it does not display a currently valid OMB control number.

1. REPORT DATE <b>2006</b>	2. REPORT TYPE	3. DATES COVERED <b>00-00-2006 to 00-00-2006</b>			
4. TITLE AND SUBTITLE <b>Emergency Decompressive Craniotomy with Banked Skull Flap in Subcutaneous Pocket</b>		5a. CONTRACT NUMBER			
		5b. GRANT NUMBER			
		5c. PROGRAM ELEMENT NUMBER			
6. AUTHOR(S)		5d. PROJECT NUMBER			
		5e. TASK NUMBER			
		5f. WORK UNIT NUMBER			
7. PERFORMING ORGANIZATION NAME(S) AND ADDRESS(ES) <b>Uniformed Services University of the Health Sciences, Department of Radiology and Radiological Sciences, 4301 Jones Bridge Road, Bethesda, MD, 20814</b>		8. PERFORMING ORGANIZATION REPORT NUMBER			
9. SPONSORING/MONITORING AGENCY NAME(S) AND ADDRESS(ES)		10. SPONSOR/MONITOR'S ACRONYM(S)			
		11. SPONSOR/MONITOR'S REPORT NUMBER(S)			
12. DISTRIBUTION/AVAILABILITY STATEMENT <b>Approved for public release; distribution unlimited</b>					
13. SUPPLEMENTARY NOTES					
14. ABSTRACT					
15. SUBJECT TERMS					
16. SECURITY CLASSIFICATION OF:			17. LIMITATION OF ABSTRACT <b>Same as Report (SAR)</b>	18. NUMBER OF PAGES <b>3</b>	19a. NAME OF RESPONSIBLE PERSON
a. REPORT <b>unclassified</b>	b. ABSTRACT <b>unclassified</b>	c. THIS PAGE <b>unclassified</b>			

## Patient Discussion

This patient had an emergency craniectomy in a deployed field hospital for intracranial hypertension secondary to head trauma during military combat in Iraq. The removed skull cap was placed subcutaneously in his abdominal wall for preservation during aeromedical evacuation.

After successful transfer to a referral medical center in the U.S. the patient developed persistent GI symptoms. Tissue culture of the fluid posterior to the skull flap was negative for bacteria.

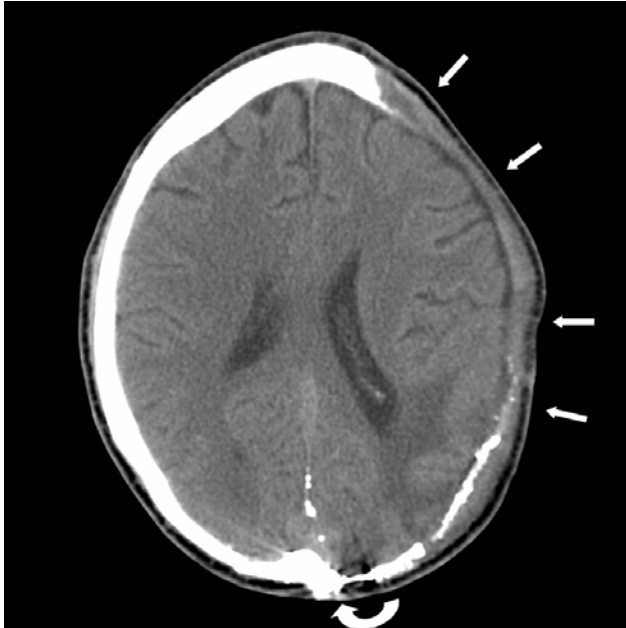


Figure 3: Axial head CT demonstrates the craniectomy site (arrows). Encephalomalacic changes are noted in the left parieto-occipital lobes. Beam hardening artifact is noted from metallic shrapnel (curved arrow).

This case demonstrates a skull cap in anterior abdominal wall with low attenuation area consistent with the following differential diagnosis: liquified hematoma, seroma, abscess, or proteinaceous fluid collection. Since the cultures were negative for bacteria, liquified hematoma was the working diagnosis.

After surgical removal of skull cap from abdomen, it was decided to use prosthetic cranioplasty material instead. Developing literature on (MDR) *Acinetobacter* species<sup>1</sup> is one of several factors weighing into using synthetic material. As the patient was recovering and before closing the gap in the skull, the patient ambulated with a hockey helmet for protection of the area.

Decompressive craniectomy is a common surgical procedure used to relieve intra-cranial hypertension. Upon resolution of the intra-cranial hypertension, a cranioplasty is performed to close the hole in the skull. There are a number of suitable materials that can be used for this purpose. One such material

is the patient's own bone flap (removed segment of skull). This option is cost-effective, strong, immunologically compatible with the host, and cosmetically pleasing. Several techniques for preserving the bone flap exist to include freezing, placement in storage solutions, and in this case, placement in the subcutaneous tissue of the patient's abdominal wall.

## Discussion

Decompressive craniectomy is a neurosurgical procedure aimed at relieving elevated intra-cranial pressure (ICP) by removing the patient's rigid skull.<sup>2</sup> Decompressive craniectomy is a surgical procedure for the treatment of elevated ICP in cases where medical management fails and in acute severe traumatic brain injury. The surgery alone has been shown to reduce ICP by 15% and up to 70% if the surgeon opens the dura.<sup>3</sup> More than 40,000 cranial surgeries are performed in the United States each year. The most frequent principle diagnosis in patients receiving such surgeries is subdural hemorrhage.<sup>4</sup> Recent studies demonstrate efficacy of banked bone grafts in the abdomen.<sup>5</sup>

In austere environments and special situations (like combat injuries), the skull cap was often placed into the abdominal wall for preservation to allow for potential replacement after transport to a referral medical center. This trend may change due to recent literature on increasing infection potential and improved prosthetic technology. Aeromedical evacuation from combat to US military medical centers can occur within 24-48 hours.

*Note: Follow this link for Category 1 CME or CNE in the case of the week in the MedPix™ digital teaching file.*

<http://rad.usuhs.mil/medpix/medpix.html?mode=single&recnum=6969&th=-1#top>

## References

- 
- <sup>1</sup> Davis KA, Moran A, McAllister K, Gray P. Multidrug-Resistant *Acinetobacter* Extremity Infections in Soldiers. Emerging Infectious Diseases. www.cdc.gov/eid. 2005 Aug;11(8):1218-24.
  - <sup>2</sup> Flannery T; McConnell RS; Cranioplasty: why throw the bone flap out? British Journal of Neurosurgery, 2001; 15(6): 518-520.
  - <sup>3</sup> Jourdan C; Convert J; Mottolese C; Bachour E; Gharbi S; Artru F.; Evaluation of the clinical benefit of decompression hemicraniectomy in intracranial hypertension not controlled by medical treatment, Neurochirurgie 1993;39(5):304-10.
  - <sup>4</sup> Buczko W.; Cranial surgery among Medicare beneficiaries. The Journal of Trauma. 2005 Jan;58(1):40-6.
  - <sup>5</sup> Movassaghi K, Ver Halen J, Ganchi P, Amin-Hanjani S, Mesa J, Yaremchuk MJ. "Cranioplasty with subcutaneously preserved autologous bone grafts." Plast Reconstr Surg. 2006 Jan;117(1):202-6.