

Radiology Corner: Case # 17

Brodie Abscess

Guarantor: Catherine H McHugh

Contributors: 2nd LT Catherine H McHugh USAFR, MSC¹, Lorraine G Shapeero, M.D.^{1,2}, COL Les Folio, USAF^{1,2}, Mark Murphey, M.D.^{1,2,3}

Note: This is the full text version of the radiology corner question published in the September 2007 issue, with the abbreviated answer in the October 2007 issue.

Introduction

Brodie abscess is a rare bone lesion that forms as a result of subacute osteomyelitis. Patients typically present with a several month history of non-specific pain and swelling, often lacking an inciting traumatic event and systemic symptoms. While radiographs are the initial diagnostic modality, Magnetic Resonance (MR) imaging can be useful in the further delineation of the disease. We present a typically appearing case, with initial normal radiography before findings became manifest.

History: A 15 year old white male presented to clinic due to six months of right ankle pain. The physical examination revealed mild swelling and tenderness to palpation at the medial ankle and the patient was treated for an ankle sprain. The patient returned to clinic due to unresolved symptoms and increased swelling and erythema over a 3 week period. Fifteen months prior to presentation, the patient presented to the emergency department due to a right ankle injury. Ankle radiographs were negative at that time. Follow-up radiographs (months later) and MR imaging of the right leg were performed.

Summary of Imaging Findings

Initial anteroposterior (AP) radiograph (Figure 1A) of the right distal tibia and fibula 15 months prior to the current presentation showed no evidence of fracture and mild soft tissue swelling around the lateral malleolus. Follow-up AP radiograph (Figure 1B) of the right distal tibia and fibula 15 months after the initial injury shows a multiloculated lytic lesion with metaphyseal (narrow arrow) and epiphyseal components (wide arrow) extending across the epiphyseal plate at the medial aspect of the tibia.

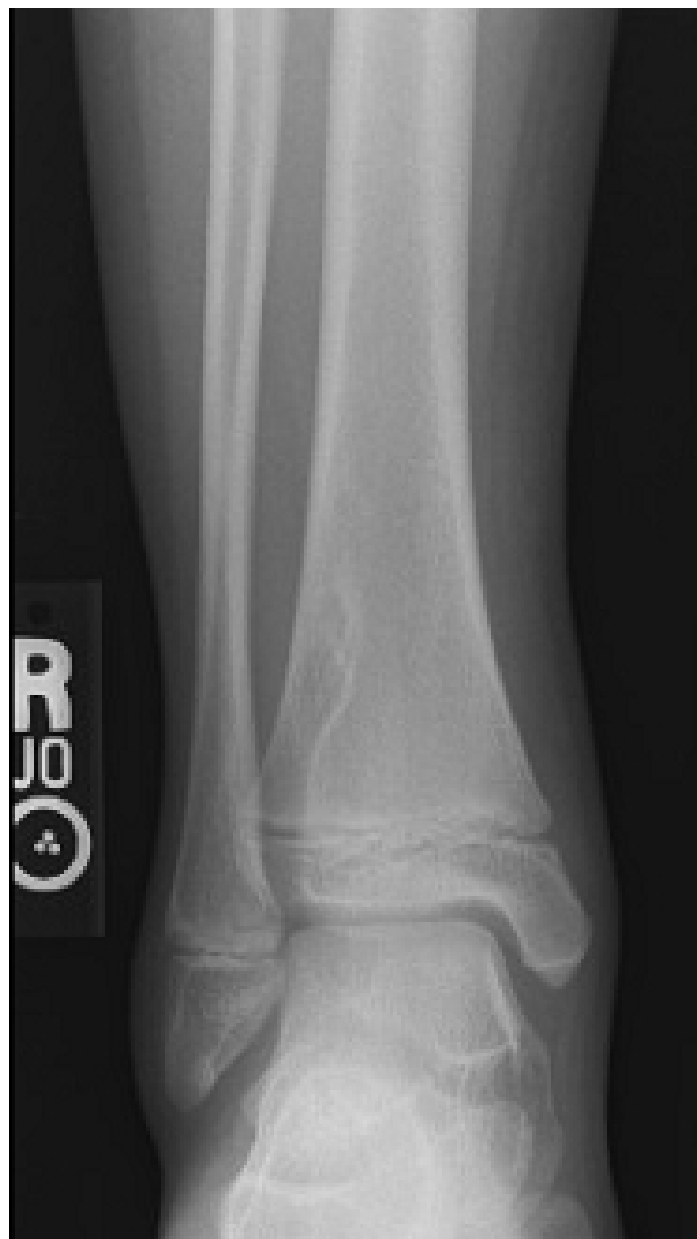

Figure 1A: Initial AP radiograph of normal right ankle.

¹ Department of Radiology and Radiological Sciences; Uniformed Services University of the Health Sciences, Bethesda, Maryland 20814-4799

² Department of Radiology and Radiological Sciences; Walter Reed Army Medical Center

³ Department of Radiologic Pathology; Armed Forces Institute of Pathology

The opinions or assertions contained herein are the private views of the authors and not to be construed as official or reflecting views of the Uniformed Services University or the Health Sciences, Walter Reed Army Medical Center, AFIP or the Department of Defense.

Reprint & Copyright © by Association of Military Surgeons of U.S., 2007.

Report Documentation Page				Form Approved OMB No. 0704-0188	
Public reporting burden for the collection of information is estimated to average 1 hour per response, including the time for reviewing instructions, searching existing data sources, gathering and maintaining the data needed, and completing and reviewing the collection of information. Send comments regarding this burden estimate or any other aspect of this collection of information, including suggestions for reducing this burden, to Washington Headquarters Services, Directorate for Information Operations and Reports, 1215 Jefferson Davis Highway, Suite 1204, Arlington VA 22202-4302. Respondents should be aware that notwithstanding any other provision of law, no person shall be subject to a penalty for failing to comply with a collection of information if it does not display a currently valid OMB control number.					
1. REPORT DATE OCT 2007		2. REPORT TYPE		3. DATES COVERED 00-00-2007 to 00-00-2007	
4. TITLE AND SUBTITLE Brodie Abscess				5a. CONTRACT NUMBER	
				5b. GRANT NUMBER	
				5c. PROGRAM ELEMENT NUMBER	
6. AUTHOR(S)				5d. PROJECT NUMBER	
				5e. TASK NUMBER	
				5f. WORK UNIT NUMBER	
7. PERFORMING ORGANIZATION NAME(S) AND ADDRESS(ES) Uniformed Services University of the Health Sciences, Department of Radiology and Radiological Sciences, 4301 Jones Bridge Road, Bethesda, MD, 20814				8. PERFORMING ORGANIZATION REPORT NUMBER	
9. SPONSORING/MONITORING AGENCY NAME(S) AND ADDRESS(ES)				10. SPONSOR/MONITOR'S ACRONYM(S)	
				11. SPONSOR/MONITOR'S REPORT NUMBER(S)	
12. DISTRIBUTION/AVAILABILITY STATEMENT Approved for public release; distribution unlimited					
13. SUPPLEMENTARY NOTES					
14. ABSTRACT					
15. SUBJECT TERMS					
16. SECURITY CLASSIFICATION OF:			17. LIMITATION OF ABSTRACT Same as Report (SAR)	18. NUMBER OF PAGES 5	19a. NAME OF RESPONSIBLE PERSON
a. REPORT unclassified	b. ABSTRACT unclassified	c. THIS PAGE unclassified			

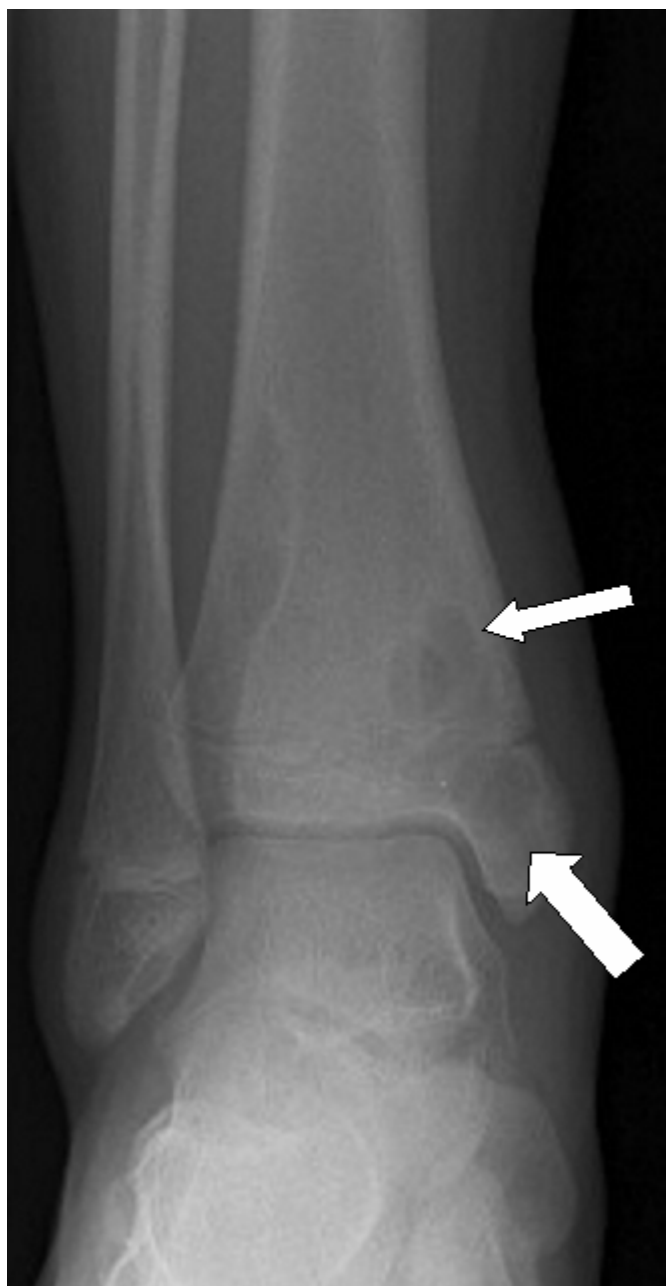

Figure 1B: Follow-up AP radiograph of right ankle showing bilocular lytic lesion (narrow arrow) and unilocular lesion in epiphysis (wide arrow).

The lesion is surrounded by a well defined sclerotic border with benign-appearing periosteal reaction and mild soft tissue swelling medially. There are no fracture lucencies and the ankle joint space is maintained.

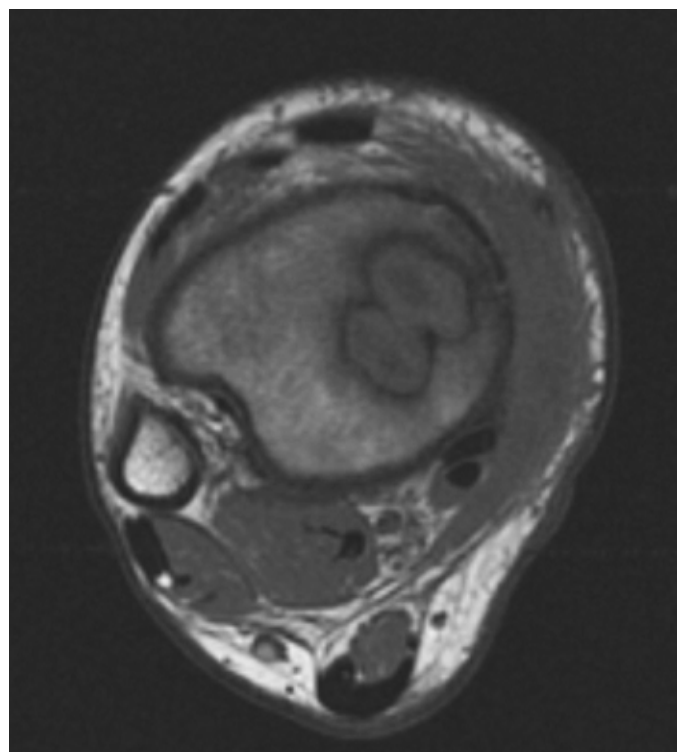


Figure 2A

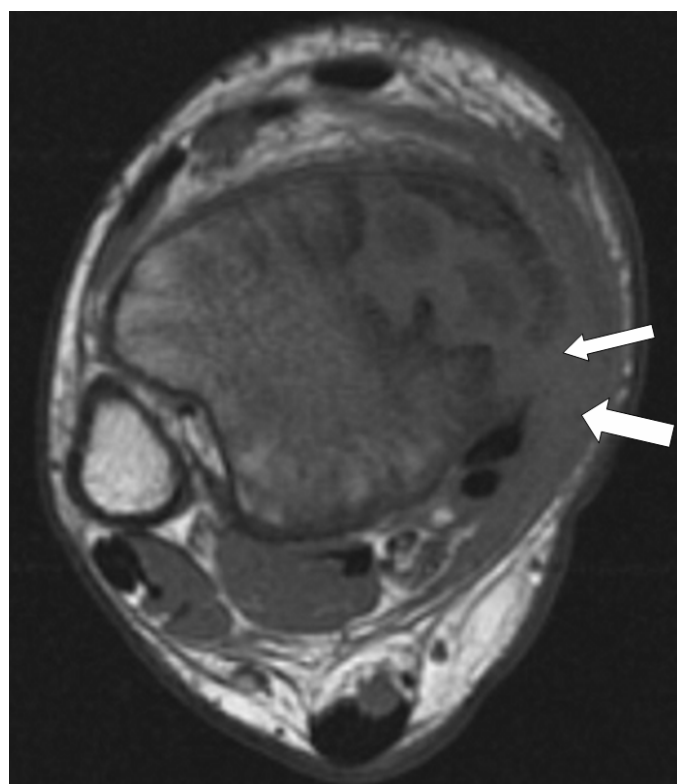


Figure 2B: Figure 2A and 2B: Axial T1-weighted MR images of right leg. In figure 2B note extension of inflammatory process (narrow arrow) through cortex to involve adjacent soft tissues (wide arrow).

Axial T1-weighted MR images (Figure 2A and 2B) of right leg reveal the multiloculated well defined mass-like focus of marrow replacement surrounded by a thick intermediate signal intensity rim with a low signal intensity periphery. The

inflammatory process extends posteromedially through the cortex of the tibial epiphysis to involve the adjacent soft tissues. On axial T2-weighted fat saturated MR images (Figure 3A and 3B) of the right leg, the mass becomes high-signal intensity surrounded by intermediate and low signal intensity rims. There is high signal intensity edema and inflammation in the surrounding bone marrow and adjacent soft tissues. The soft tissue inflammatory thickening medially also extends anteriorly to the margin of the anterior-tibial tendon and posteriorly to the lateral aspect of the tibial tendon, flexor digitorum longus tendon and flexor hallucis longus tendon.

Coronal (Figure 4A) T1-weighted MR image after contrast demonstrates the bilobed mass-like area of marrow replacement with non-enhancing peripheral rim. The non-enhancing central lesions correspond to the low signal intensity centers seen on T1-weighted MR and high signal intensity centers seen on T2-weighted MR, which together is consistent with a fluid or cystic region. The lesion extends across the physis creating a confluence between the metaphyseal and epiphyseal components. Oblique (Figure 4B) T1-weighted MR image after contrast shows high-signal-intensity bone marrow edema extending 5.5cm proximally along the distal tibial diaphysis from the site of the lesions. The soft tissue inflammation also shows diffuse enhancement.

Patient Discussion

On imaging studies, our patient showed findings consistent with a Brodie abscess with extension across the growth plate into the epiphysis and cortical invasion into adjacent soft tissues. The differential diagnosis in this case includes eosinophilic granuloma and rare metastases such as from rhabdomyosarcoma.¹⁵ These alternate diagnoses can be excluded by the extensive bone marrow and soft tissue inflammation, thick rim enhancement with fluid centrally, and the absence of a lesion 15 months prior to presentation. Histopathologic confirmation and positive cultures for *Staphylococcus aureus*, however, provided the definitive diagnosis of a Brodie abscess in our case.

Discussion

In the 1830's, Sir Benjamin Collins Brodie recognized a chronic inflammatory process in the tibia without acute symptoms or known precipitating infection.¹⁻³ This rare lesion, known today as a Brodie abscess, is a localized type of subacute or chronic pyogenic osteomyelitis.¹⁻⁴ Pathogenesis is due to an insidious bacteremia with septic emboli to a normal or minimally traumatized long bone, often from an infection with *Staphylococcus aureus*.^{5,6} The lesion is predominant in young males with unfused epiphyseal plates, typically presenting during the second decade of life.^{2,3} Brodie abscess is described as a small, eccentric, localized, lytic lesion with surrounding reactive sclerosis.^{2,4} It is characteristically found in the metaphyseal region of long bones of the lower extremity, most commonly in the tibia.¹⁻³ The usual presenting complaint is recurrent pain and localized swelling;^{1,2} systemic symptoms are typically absent.³

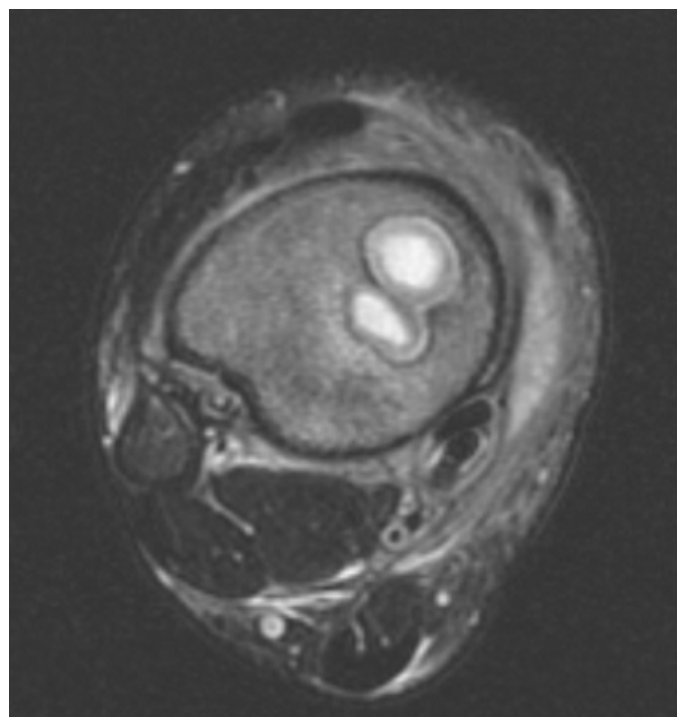


Figure 3A

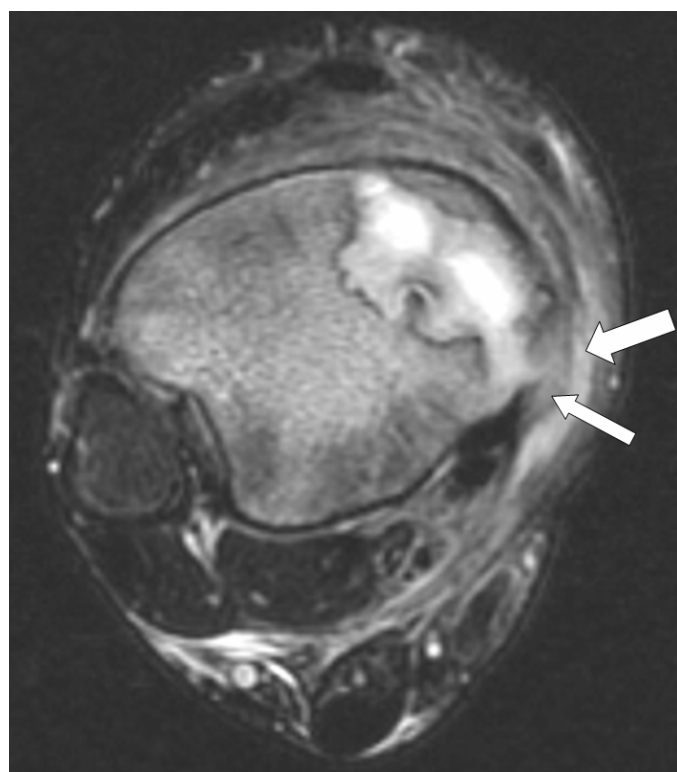


Figure 3B: Figure 3A and B: Axial T2-weighted FSE MR images of right leg. In Figure 3B note extension of inflammatory process through cortex (narrow arrow) to involve adjacent soft tissues (wide arrow).

Radiographs of a Brodie abscess often demonstrate a localized area of radiolucency with surrounding sclerosis.^{1,7} The lucent region is commonly located in the metaphysis where it may extend to or through the growth plate. Detection of this focal metaphyseal abscess with involvement of the

growth plate is diagnostic for osteomyelitis.⁸ Lesions are frequently much longer than their width, creating a channel-like morphology, and important feature suggesting an infectious etiology. Radiographs should be the initial imaging study for evaluating osteomyelitis although, in early infection they are usually normal⁹ or may show only nonspecific soft tissue swelling or benign periosteal reaction. Our case shows an initially normal radiograph prior to the findings that arose in the images 15 months later.

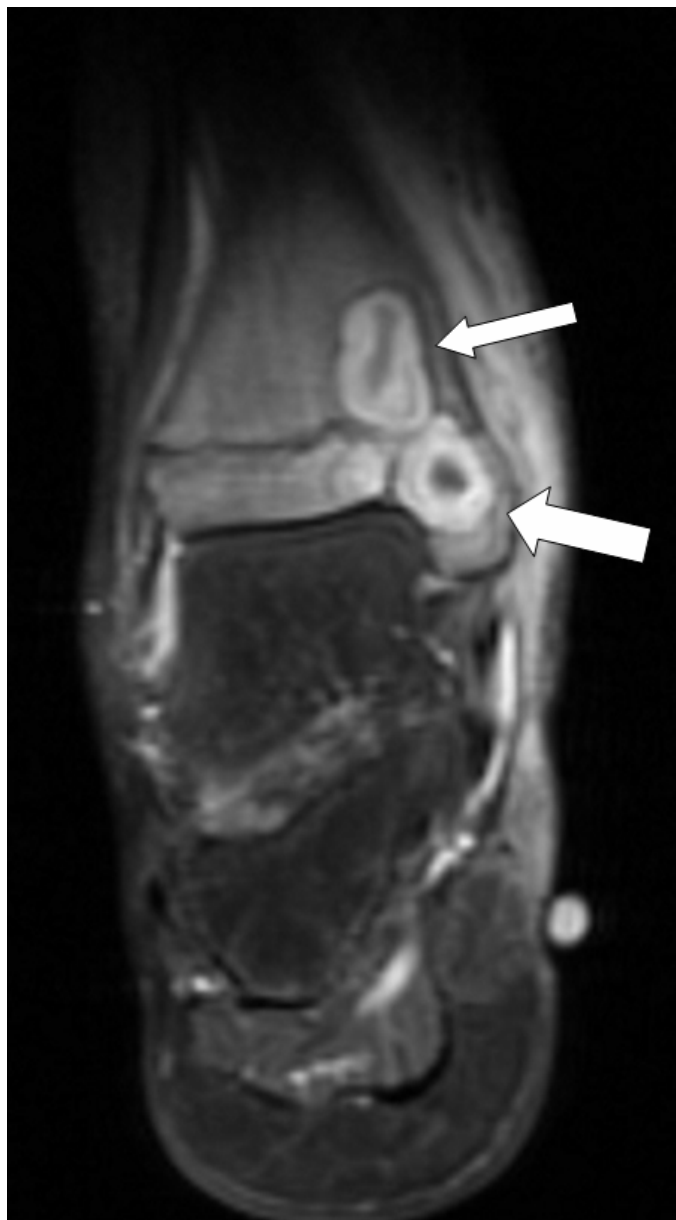

Figure 4A: Coronal T1-weighted MR image after contrast shows well defined masses (arrows) with non-enhancing centers, enhancing thick rim, and non-enhancing periphery.

Bone scans are more sensitive than radiographs for the early detection of osteomyelitis⁹ and show increased uptake in all phases (dynamic, blood pool, and static images). In a meta-analysis of technetium bone scan performance in the diagnosis of osteomyelitis by Littenberg and Mushlin, sensitivities were

between 70-80%.¹⁰ On scintigraphy, a focal area of radiopharmaceutical uptake at the site of suspected infection with central photopenia suggests a Brodie abscess. Although bone scan is not as sensitive as MR, it provides a useful imaging modality when MR imaging is not available or contraindicated.

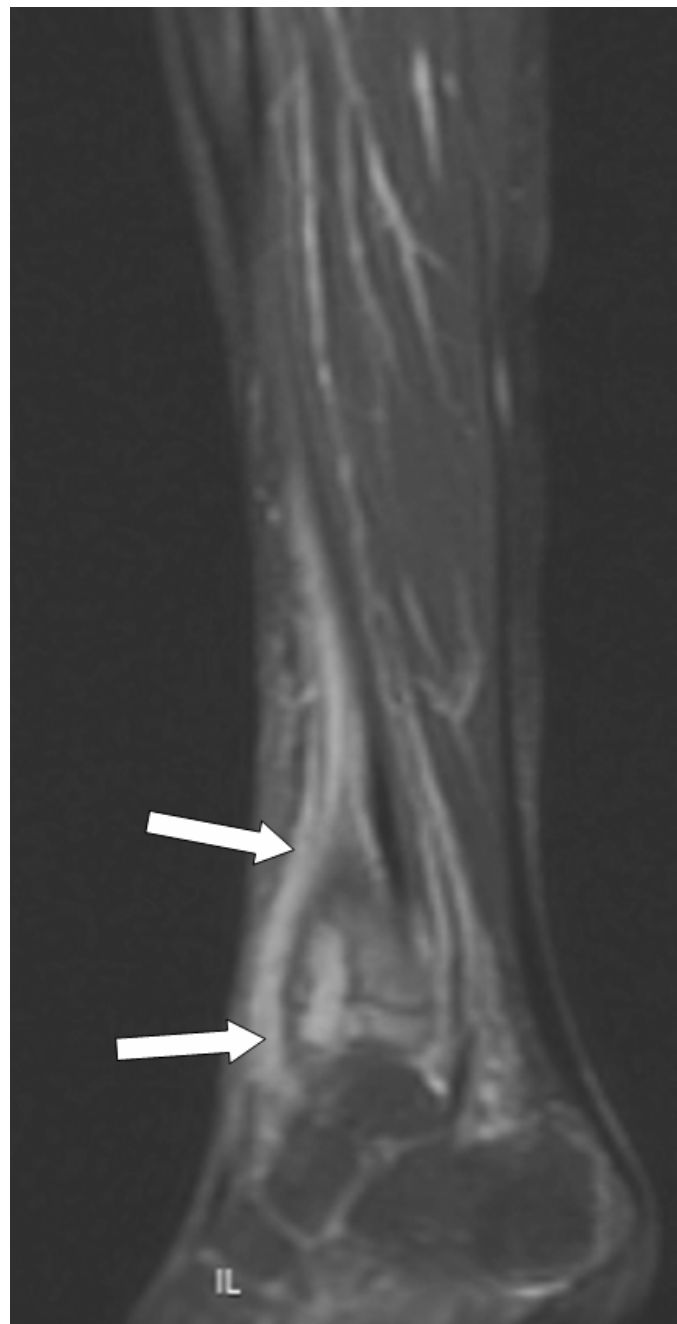

Figure 4B: Oblique T1-weighted MR image after contrast. shows high-signal-intensity bone marrow edema (arrows) extending 5.5cm proximally along the distal tibial diaphysis from the site of the lesions.

MR imaging provides a greater accuracy in delineating the extent of disease, a more rapid evaluation, and the ability to perform the study without ionizing radiation.⁹ In a review of the literature by Matowe and Gilbert, the average sensitivity of MR imaging in osteomyelitis was 91%, the average specificity

was 82%, the average accuracy was 88%, and the average positive likelihood ratio was 7.8.¹¹ On MR imaging, a Brodie abscess is seen as a focal fluid collection in the marrow with surrounding fibrous wall and adjacent inflammatory reaction. This reveals a low signal intensity mass-like area of marrow replacement on T-weighting with a low signal intensity rim that becomes a high intensity signal centrally with a thick, low intensity rim on T2 weighted MR images.^{9,12} The abscess may rarely extend into the cortex and into soft tissues.^{2,9} In addition, the infection may traverse the open growth plate, to involve the epiphysis.¹³ Supportive secondary MR findings of osteomyelitis include cortical bone thickening or destruction, sequestra, sinus tracts to the adjacent soft tissues, and adjacent soft tissue ulcers.^{11,14} Post-contrast MR images show a nonenhancing central area, which presents the infected fluid collection, with a surrounding enhancing fibrous wall and nonenhancing sclerotic rim.¹²

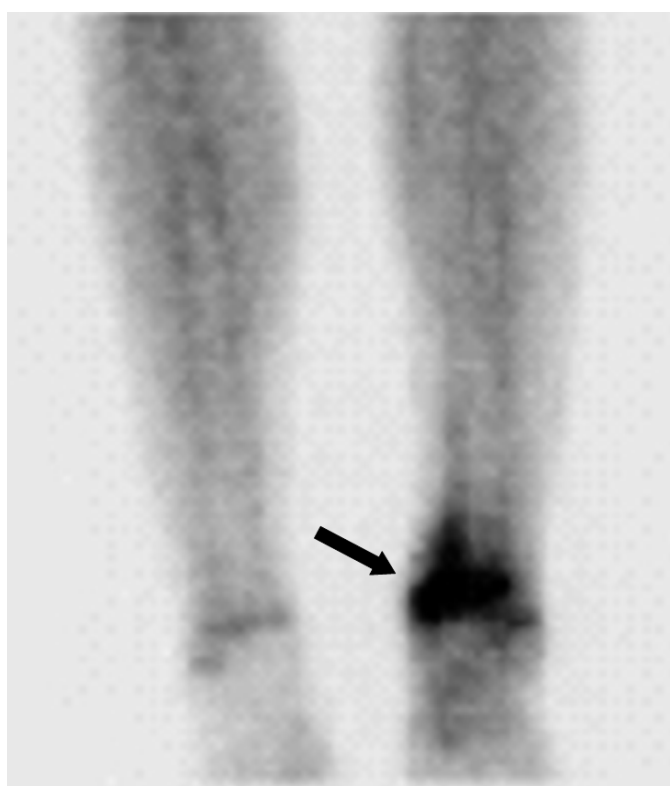


Figure 5: Bone scan demonstrating increased uptake in distal tibial metaphysis and epiphysis.

Treatment for Brodie abscess includes surgical debridement and antibiotic therapy.^{1,3,6} A sterile abscess may be treated without antibiotics only if there is symptomatic improvement and radiographic regression of the lesion.¹ Ross also suggests that antibiotics alone may be sufficient treatment for children with cavities typical of subacute osteomyelitis.¹³ Aggressive treatment, such as debridement followed by bone grafting,

may be needed for abscesses that form slightly before or after bone maturation and do not resolve with surgical treatment.^{3,6}

Note: Follow this link for Category 1 CME or CNE in the case of the week in the MedPix™ digital teaching file.

<http://rad.usuhs.mil/amsus.html>

References

1. Bagatur AE, Zorer G. Brodie's abscess of the cuboid bone. *Clin Orthop Rel Res* 2003;408:292-294.
2. Miller WB, Murphy WA, Gilula LA. Brodie abscess: Reappraisal. *Radiology* 1979;132:15-23.
3. Stephens MM, MacAuley P. Brodie's abscess, a long-term review. *Clin Orthop Rel Res* 1988;234:211-216.
4. Strobel K, Hany T, Exner GU. PET/CT of a Brodie abscess. *Clin Nucl Med* 2006;31:210.
5. Chambler AFW, Chapman-Sheath PJ, Pearse MF, Hollingdale J. Symmetrical Brodie's abscess. *Postgrad Med J* 1997;73:660-661.
6. Dunn EC, Singer L. Operative treatment of Brodie's abscess. *J Foot Surg* 1991;30:443-445.
7. Yoshikawa M, Sugawara Y, Kikuchi T, Nakata S et al. Two cases of pediatric bone disease (eosinophilic granuloma and Brodie's abscess) showing similar scintigraphic and radiographic findings. *Clin Nucl Med* 2000;25:986-990.
8. Resnick D. Osteomyelitis: radiographic and pathologic abnormalities. *Diagnosis of Bone and Joint Disorders*. Vol 3. Ed 4. Philadelphia, WB Saunders Company 2390-2396, 2002.
9. Tang J, Gold R, Bassett L, Seeger L. Musculoskeletal infection of the extremities: evaluation with MR imaging. *Radiology* 1988;166:205-209.
10. Littenberg B, Mushlin AI. Technetium bone scanning in the diagnosis of osteomyelitis: a meta-analysis of test performance. *J Gen Intern Med* 1992;7:158-64.
11. Matowe L, Gilbert FJ. How to synthesize evidence for imaging guidelines. *Clin Radiol* 2004;59:63-68.
12. Dangman BC, Hoffer FA, Rand FF, O'Rourke EJ. Osteomyelitis in children: Gadolinium-enhanced MR imaging. *Radiology* 1992;182:743-7.
13. Ross ER, Cole WG. Treatment of subacute osteomyelitis in childhood. *J Bone Joint Surg Br* 1985;67:443-448.
14. Collins MS, Schaar MM, Wenger DE, Mandrekar JN. T1-weighted MRI characteristics of pedal osteomyelitis. *AJR Am J Roentgenol* 2005;185:386-93.
15. Shapeero LG, Couanet D, Vanel D, Ackerman LV, et al. Bone metastases as the presenting manifestation of rhabdomyosarcoma in childhood. *Skeletal Radiol* 1993;22:433-438.