

Radiology Corner

Distal Biceps Tendon Rupture

Contributors: CPT Michael Huppmann MC, USA¹; Lorraine G. Shapeero, M.D.^{1,2,3}
Guarantor: Lorraine G. Shapeero, M.D.

Note: This is the full text version of the radiology corner question published in the June 2008 issue, with the abbreviated answer in the July 2008 issue.

This article discusses the evaluation and treatment of a 56-year-old man with complete rupture of the distal biceps tendon. The mechanism of injury, symptoms, and findings at physical examination may suggest the diagnosis. However, magnetic resonance imaging (MRI) and, to a lesser extent, sonography can define the point of tear and can be used in pre-operative planning.

Introduction

Rupture of the distal biceps tendon is a relatively uncommon injury, but delayed diagnosis may result in permanent and debilitating loss of function and strength in the injured extremity. Although complete distal biceps tendon ruptures may be diagnosed by characteristic clinical and physical exam findings, cross-sectional imaging with magnetic resonance (MR) imaging and, to a lesser extent, sonography can be useful for confirming the diagnosis and showing the exact point of tear, particularly when the clinical diagnosis is in doubt. This article describes the clinical presentation, imaging findings, and treatment of complete ruptures of the distal biceps tendon.

Summary of Imaging Findings

Initial anteroposterior and lateral radiographs of the left elbow demonstrated no significant radiographic abnormality. There was no radial tuberosity avulsion fracture, joint effusion, or soft tissue swelling (Fig. 1).

Triplanar MR images demonstrated the distal biceps tendon retracted 9 cm proximally with peritendinous and intratendinous proton density and T2 high signal consistent with edema and hemorrhage (Fig. 2A-E). Proton density and T2-weighted MR images showed posttraumatic inflammation and hematoma surrounding the retracted tendon and filling the gap between the retracted tendon and the radial tuberosity appearing as heterogeneous high signal intensity (Fig. 2A-D). Proton density MR images at the level of the proximal forearm

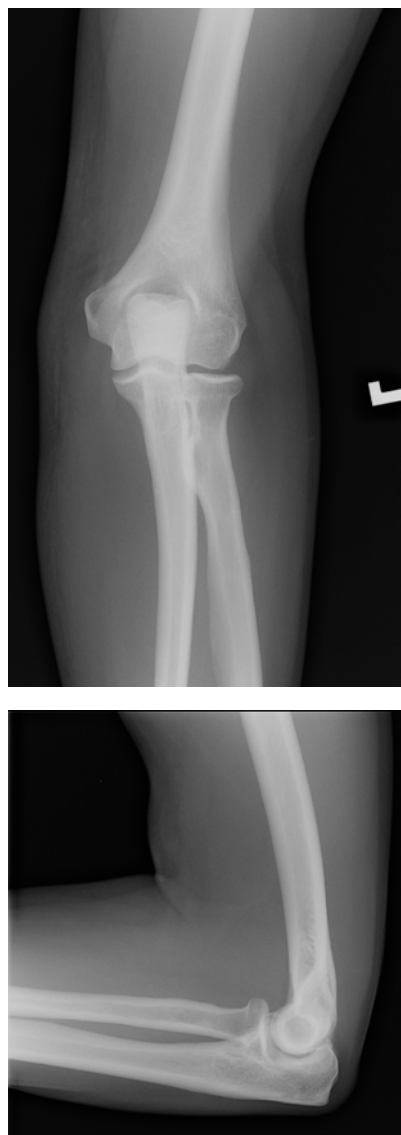


Fig. 1 Anteroposterior and lateral radiographs of the left elbow reveal no osseous or soft tissue abnormality.

¹Department of Radiology, Walter Reed Army Medical Center, Washington, DC 20307

²Department of Radiology; Uniformed Services University of the Health Sciences, Bethesda, MD 20814

³Bone and Soft Tissue Sarcoma Program, United States Military Cancer Institute, Washington, DC 20307

Report Documentation Page				Form Approved OMB No. 0704-0188	
Public reporting burden for the collection of information is estimated to average 1 hour per response, including the time for reviewing instructions, searching existing data sources, gathering and maintaining the data needed, and completing and reviewing the collection of information. Send comments regarding this burden estimate or any other aspect of this collection of information, including suggestions for reducing this burden, to Washington Headquarters Services, Directorate for Information Operations and Reports, 1215 Jefferson Davis Highway, Suite 1204, Arlington VA 22202-4302. Respondents should be aware that notwithstanding any other provision of law, no person shall be subject to a penalty for failing to comply with a collection of information if it does not display a currently valid OMB control number.					
1. REPORT DATE JUN 2010		2. REPORT TYPE		3. DATES COVERED 00-00-2010 to 00-00-2010	
4. TITLE AND SUBTITLE Distal Biceps Tendon Rupture				5a. CONTRACT NUMBER	
				5b. GRANT NUMBER	
				5c. PROGRAM ELEMENT NUMBER	
6. AUTHOR(S)				5d. PROJECT NUMBER	
				5e. TASK NUMBER	
				5f. WORK UNIT NUMBER	
7. PERFORMING ORGANIZATION NAME(S) AND ADDRESS(ES) Uniformed Services University of the Health Sciences, Department of Radiology and Radiological Sciences, 4301 Jones Bridge Road, Bethesda, MD, 20814				8. PERFORMING ORGANIZATION REPORT NUMBER	
9. SPONSORING/MONITORING AGENCY NAME(S) AND ADDRESS(ES)				10. SPONSOR/MONITOR'S ACRONYM(S)	
				11. SPONSOR/MONITOR'S REPORT NUMBER(S)	
12. DISTRIBUTION/AVAILABILITY STATEMENT Approved for public release; distribution unlimited					
13. SUPPLEMENTARY NOTES Military Medicine 2010 Jun;175(6): ix-x					
14. ABSTRACT					
15. SUBJECT TERMS					
16. SECURITY CLASSIFICATION OF:			17. LIMITATION OF ABSTRACT Same as Report (SAR)	18. NUMBER OF PAGES 4	19a. NAME OF RESPONSIBLE PERSON
a. REPORT unclassified	b. ABSTRACT unclassified	c. THIS PAGE unclassified			

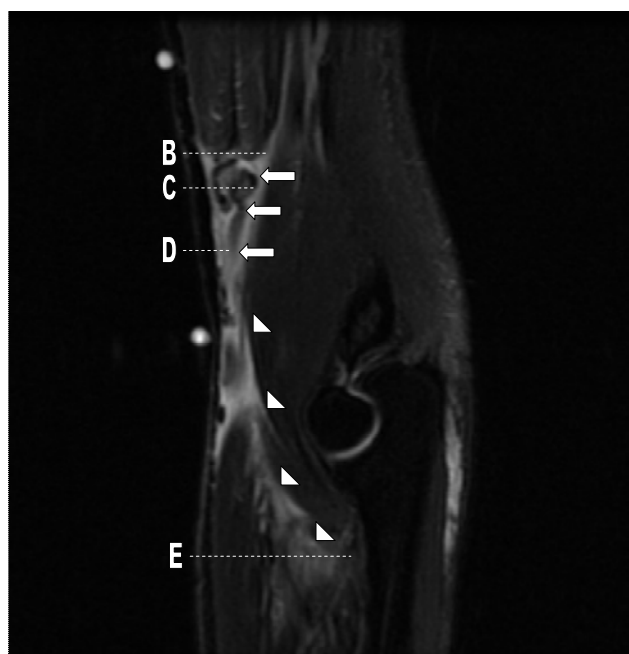


Figure 2A

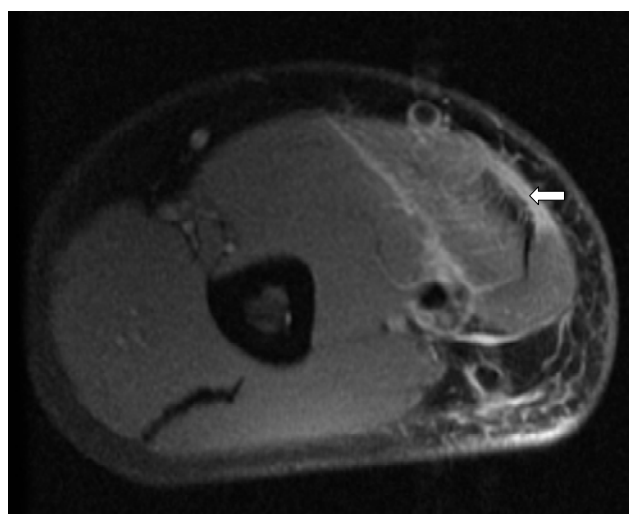


Figure 2B

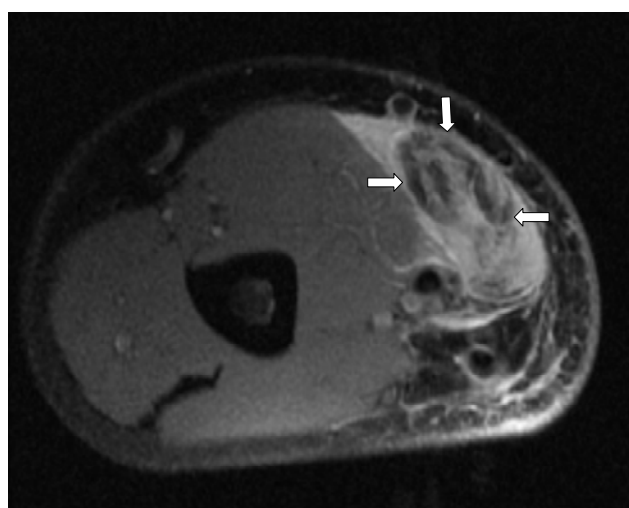


Figure 2C

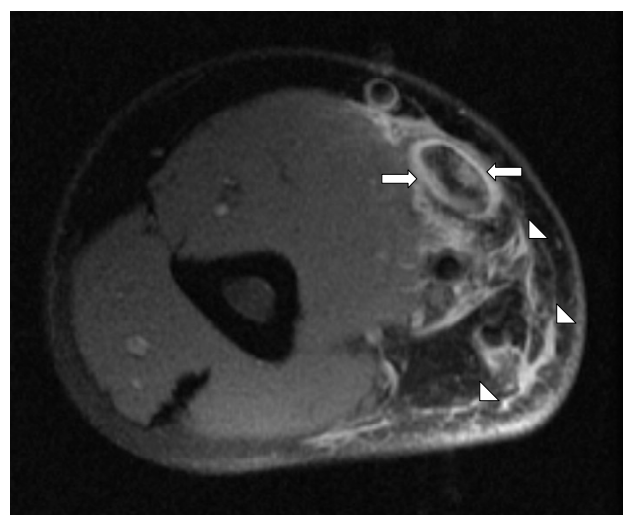


Figure 2D

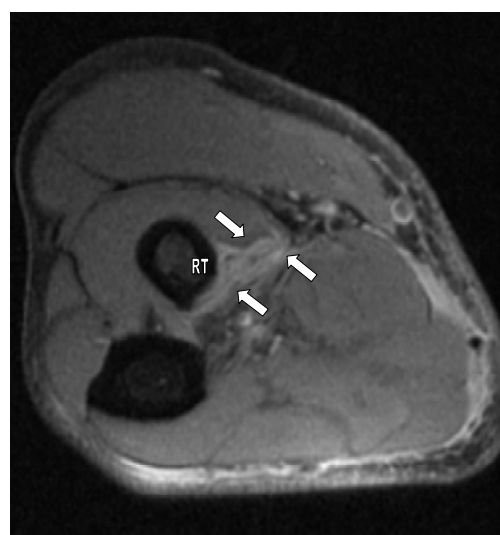


Figure 2E

Fig. 2 (A) Sagittal T2-weighted fat-saturated MR image of the left elbow demonstrates high intensity fluid signal surrounding the retracted and curled free end of the distal biceps tendon (arrows) with extension along the intermuscular fascia (arrowheads) into the forearm. The levels of subsequent, representative axial images are labeled accordingly. (B) Axial proton density-weighted MR image of the left arm demonstrates mild, high intensity fluid signal around a thickened, but intact, distal biceps tendon (arrow) at the musculotendinous junction. (C) Axial proton density-weighted MR image of the distal left arm demonstrates high intensity fluid signal within and surrounding the retracted and curled free end of the distal biceps tendon (arrows) within the distal arm. (D) Axial proton density-weighted MR image of the left arm, distal to (C), demonstrates high intensity fluid signal surrounding the free end of the distal biceps tendon (black arrows) with high signal fluid in the surrounding soft tissues (arrowheads). (E) Axial proton density-weighted MR image of the left forearm demonstrates absence of the distal biceps tendon at the radial tuberosity (RT) and high signal along the intermuscular fascia (arrows).

demonstrated nonvisualization of the distal biceps tendon at its expected insertion on the radial tuberosity (Fig. 2E).

Immediate post-operative radiographs of the elbow demonstrated a new surgical tunnel through the proximal radius with a tendon button along the dorsal surface of the radius at the approximate location of the insertion of the distal biceps tendon on the radial tuberosity (Fig. 3).

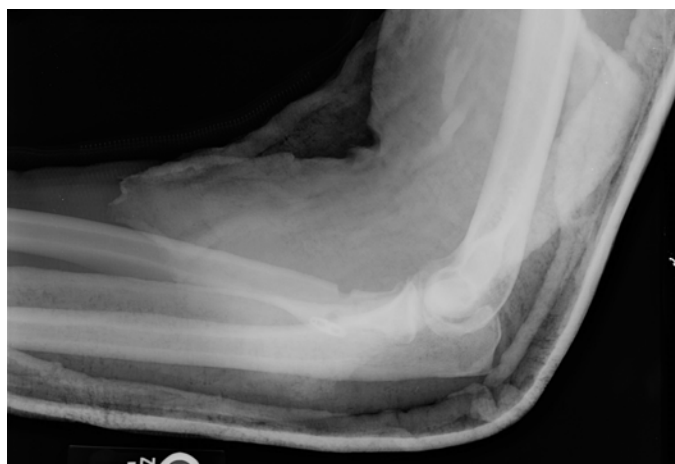

Fig. 3: A lateral post-operative radiograph of the elbow demonstrates a new cortical tunnel through the proximal radius with a tendon button along the dorsal radial cortex.

Discussion

Tears of the distal biceps tendon are uncommon injuries with a reported incidence of 1.2 per 100,000 patients.¹ Ninety-seven percent of biceps tendon tears involve the proximal tendon, whereas only 3% are distal injuries.² Complete distal biceps tendon tears occur more frequently in men, most commonly between ages 40 and 60 years, than in women; although case reports of distal biceps tendon ruptures in women exist.³ Distal biceps tendon ruptures are classified as acute (injuries less than four weeks old) or chronic and complete or partial.⁴ Complete tears are more commonly found. The dominant arm is usually injured.⁵

The mechanism of injury associated with complete tears of the distal biceps tendon is an excessive load applied to a flexed, supinated forearm, particularly in sports such as weightlifting, football, and rugby and work-related incidents.⁴ The patient may complain of pain and swelling in the antecubital fossa and around the elbow.⁶ Physical examination reveals tenderness, swelling, and ecchymoses in the antecubital fossa; asymmetry of the biceps muscles; and weakness with forearm supination and elbow flexion. In addition, in patients with complete tears, a palpable defect from the radial tuberosity to the lower arm represents the gap between the retracted, ruptured distal biceps tendon and its insertion site.⁷

Although excessive loads usually result in complete tears of the distal biceps tendon from the radial tuberosity, the extent of tendon retraction is dependent upon the integrity of the bicipital aponeurosis. This band of fibers originates from the distal biceps tendon, radiates to the ulna, and then merges with the deep fascia. This fibrous band, if intact, secures the distal biceps tendon in place and prevents its proximal migration. Complete tears of the distal biceps tendon also can occur at the musculotendinous junction, although they are less frequent than complete tears at the radial tuberosity.⁸ The underlying pathophysiology contributing to distal biceps tendon rupture is likely multifactorial. Theories include degenerative changes within the tendon, mechanical factors resulting from the limited space between the ulna and radial tuberosity through

which the tendon passes, and the relative hypovascularity of the distal tendon similar in nature to the critical zone seen in the rotator cuff.^{3,4}

In patients with complete tears of the distal biceps tendon, plain radiographs of the elbow and arm are usually normal. However, infrequent findings include soft tissue density in the distal arm representing the retracted biceps muscle or avulsion of the radial tuberosity. As sonography is inexpensive and is increasingly available in the emergency room, it can be used to demonstrate the extent of complete tears with variable lengths of retraction from the radial tuberosity and the interposing fluid filling the gap between the tendon and tuberosity.^{9,10} With partial tears, sonography may show thickening of the biceps tendon with an irregular or wavy contour, but the tendon can be seen in its entire length to its attachment to the radial tuberosity.⁹ Loss of the fibrillar echotexture seen in the normal distal biceps tendon is a less reliable indicator of tendon pathology because perceived abnormal tendon echotexture may be artifactual when sonographic technique is suboptimal.¹¹ MR imaging is helpful when the history and the physical examination findings are indeterminate or if the tear is incomplete. Partial ruptures are characterized by T2 high signal intensity within an abnormally thickened or thinned distal tendon. Although these findings overlap with those seen in tendinopathy, the presence of bone marrow edema at the radial tuberosity and fluid in the bicipitoradial bursa suggests a partial tear rather than tendinopathy.³ When the distal biceps tendon tear is complete, MR imaging shows absence of the tendon at its insertion site with interposing T2 high signal intensity fluid and variable lengths of tendon retraction.⁶

Treatment of acute distal biceps tendon rupture usually consists of early surgical repair.⁴ If surgery is delayed for greater than 4 weeks after injury, the operation may be complicated by scarring around the distal tendon with less desirable clinical results. Surgical repair is by either a one or two incision technique, both of which have many variations. The single incision technique involves an anterior elbow incision and dissection to expose the distal tendon and radial tuberosity, while the two-incision technique utilizes an additional posterior incision over the dorsolateral aspect of the forearm to facilitate attachment of the tendon to the radius.^{1,8} Both techniques are associated with the risk of injury to nerves and heterotopic bone formation. The single incision approach is facilitated by the use of suture anchors or, in the case of the current patient, a tendon button.⁴ With this technique, the distal tendon is attached to the tendon button and then passed through a tunnel in the radial tuberosity at which point the tendon button is fixed to the posterior cortex of the radius securing the tendon in place.¹

Complete tears of the distal biceps tendon are relatively uncommon injuries, but the correct, timely diagnosis is vital to patients regaining strength and function. Cross-sectional imaging with sonography and MR imaging play vital roles in confirming the diagnosis or resolving uncertain diagnoses.

Note: Follow this link for Category 1 CME or CNE in the case of the week in the MedPix™ digital teaching file.

<http://rad.usuhs.mil/medpix/medpix.html?mode=single&recnum=6969&th=-1#top>

References

1. Safran MR, Graham SM. Distal biceps tendon ruptures: incidence, demographics, and the effect of smoking. Clin Orthop Relat Res 2002;404:275-283.
2. Fitzgerald SW, Curry DR, Erickson SJ, Quinn SF, Friedman H. Distal biceps tendon injury: MR imaging diagnosis. Radiology 1994;191:203-206.
3. Kijowski R, Tuite M, Sanford M. Magnetic resonance imaging of the elbow. Part II: abnormalities of the ligaments, tendons, and nerves. Skeletal Radiol 2005;34:1-18.
4. Vidal AF, Drakos MC, Allen AA. Biceps tendon and triceps tendon injuries. Clin Sports Med 2004;23:707-722.
5. Mazzocca AD, Spang JT, Arciero RA. Distal biceps rupture. Orthop Clin N Am. 2008;39:237-249.
6. Falchok FS, Zlatkin MB, Erbacher GE, Moulton JS, Bisset GS, Murphy BJ. Rupture of the distal biceps tendon: evaluation with MR imaging. Radiology 1994;190:659-663.
7. Hargrove R, Griffiths DE, Clasper J. Ruptured distal biceps in military personnel. J R Army Med Corps 2006;152:26-29.
8. Rettig AC. Traumatic elbow injuries in the athlete. Orthop Clin N Am 2002;33:509-522.
9. Miller TT, Adler RS. Sonography of tears of the distal biceps tendon. Am J Roentgenol 2000;175: 1081-1086.
10. Lozano V, Alonso P. Sonographic detection of the distal biceps tendon rupture. J Ultrasound Med 1995;14:389-391.
11. Fornage BD. The hypoechoic normal tendon: a pitfall. J Ultrasound Med 1987;6:19-22.

The information or content and conclusions are those of the authors and do not necessarily represent the official position or policy of, nor should any official endorsement be inferred by, the Uniformed Services University of the Health Sciences, the United States Military Cancer Institute, the Department of the Army, the Department of Defense, or the U.S. Government.