

Radiology Corner

Progressive Atelectasis Secondary to GSW to Airway

Contributors: 2LT James Cassleman, MC, USAF¹; ENS Mike Zakaroff, MC, USN¹; COL Les Folio, MC, FS, USAF¹

Note: This is the full text version of the radiology corner question published in the April 2009 issue, with the abbreviated answer in the May 2009 issue.

Radiographic interpretation of atelectasis bears particular importance in the setting of aspiration, which involves added dangers of infection, inflammation and interstitial edema. While the consequences of pulmonary aspiration are ultimately a function of the type, volume and acidity of aspirated material, the overall result is often diminished gas exchange and loss of lung volume. Regardless of the mechanism, this loss of lung volume frequently occurs in a predictable manner that can be assessed using various diagnostic tools, of which the quickest and most direct tool is likely the chest X-ray (CXR). Essential to such interpretation with CXR is an understanding of specific lobar patterns of atelectasis and the radiographic findings associated with these patterns. Similarly, it is important to recognize the pathophysiology of aspiration and the capacity for aspirated fluid to produce lobar atelectasis in a given patient.

Introduction

This article contains analysis of the unique findings for one such patient: a 32 year old male who suffered a gun shot wound (GSW) to the mandible. After presenting to the ER in Iraq with progressive dyspnea, the patient was assessed with follow-up chest x-rays in the ICU showing progressive atelectasis. Consequently, urgent bronchoscopy performed shortly afterwards revealed the presence of blood in the patient's airway, completely obstructing his right mainstem bronchus.

Summary of Findings, Diagnosis of the case:

Figure 1: Figure 1 is a CT scout of the chest that demonstrates several findings. Beginning with the arrow labeled A, notice the fracture of the right mandible caused by the entry of the bullet. A bullet fragment indicated by arrow B is lodged in the trachea adjacent to the ET tube at the level of C2-C3. Also, notice that arrow C points to an ill-defined opacity of the right lower lobe. The CXR also shows mild tracheal deviation to the patient's right as well as downward displacement of the patient's right hilum in the direction of the

lower right lung field. The right hemidiaphragm appears more elevated than would be expected of its normal physiologic position, which rests slightly above the left hemidiaphragm due to the anatomical position of the heart within the chest cavity and underlying liver. Also, the cardiac silhouette is maintained. In particular, the right atrial border can be clearly differentiated from the adjacent air space. A chest tube is also noted on the right.

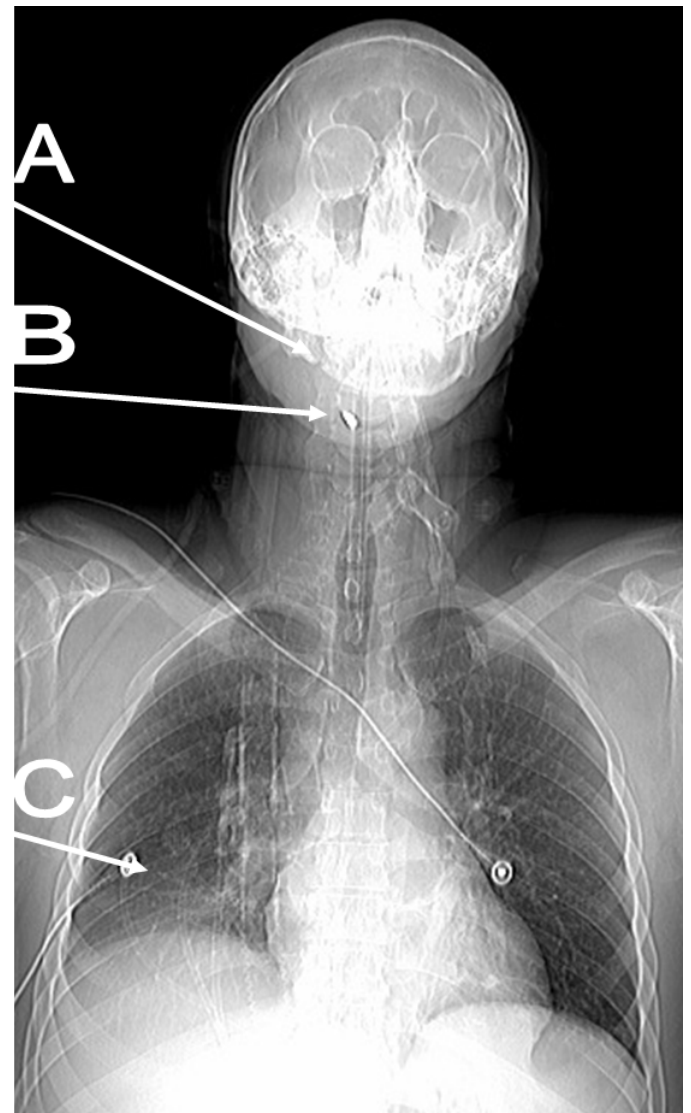


Fig. 1: Radiograph of GSW patient. Note fracture of mandible (A), bullet (B) and developing RLL atelectasis (C).

¹ Department of Radiology and Radiological Sciences; Uniformed Services University of the Health Sciences, Bethesda, Maryland 20814-4799
Reprint & Copyright © by Association of Military Surgeons of U.S., 2006.

Report Documentation Page

Form Approved
OMB No. 0704-0188

Public reporting burden for the collection of information is estimated to average 1 hour per response, including the time for reviewing instructions, searching existing data sources, gathering and maintaining the data needed, and completing and reviewing the collection of information. Send comments regarding this burden estimate or any other aspect of this collection of information, including suggestions for reducing this burden, to Washington Headquarters Services, Directorate for Information Operations and Reports, 1215 Jefferson Davis Highway, Suite 1204, Arlington VA 22202-4302. Respondents should be aware that notwithstanding any other provision of law, no person shall be subject to a penalty for failing to comply with a collection of information if it does not display a currently valid OMB control number.

1. REPORT DATE MAY 2009	2. REPORT TYPE	3. DATES COVERED 00-00-2009 to 00-00-2009			
4. TITLE AND SUBTITLE Progressive Atelectasis Secondary to GSW to Airway		5a. CONTRACT NUMBER			
		5b. GRANT NUMBER			
		5c. PROGRAM ELEMENT NUMBER			
6. AUTHOR(S)		5d. PROJECT NUMBER			
		5e. TASK NUMBER			
		5f. WORK UNIT NUMBER			
7. PERFORMING ORGANIZATION NAME(S) AND ADDRESS(ES) Uniformed Services University of the Health Sciences, Department of Radiology and Radiological Sciences, 4301 Jones Bridge Road, Bethesda, MD, 20814		8. PERFORMING ORGANIZATION REPORT NUMBER			
9. SPONSORING/MONITORING AGENCY NAME(S) AND ADDRESS(ES)		10. SPONSOR/MONITOR'S ACRONYM(S)			
		11. SPONSOR/MONITOR'S REPORT NUMBER(S)			
12. DISTRIBUTION/AVAILABILITY STATEMENT Approved for public release; distribution unlimited					
13. SUPPLEMENTARY NOTES					
14. ABSTRACT					
15. SUBJECT TERMS					
16. SECURITY CLASSIFICATION OF:			17. LIMITATION OF ABSTRACT Same as Report (SAR)	18. NUMBER OF PAGES 4	19a. NAME OF RESPONSIBLE PERSON
a. REPORT unclassified	b. ABSTRACT unclassified	c. THIS PAGE unclassified			

Figure 2: A 3D reconstruction displaying the approximate location of the bullet fragment in the patient's trachea. In addition, one can appreciate the fractured mandible indicating bullet entrance.

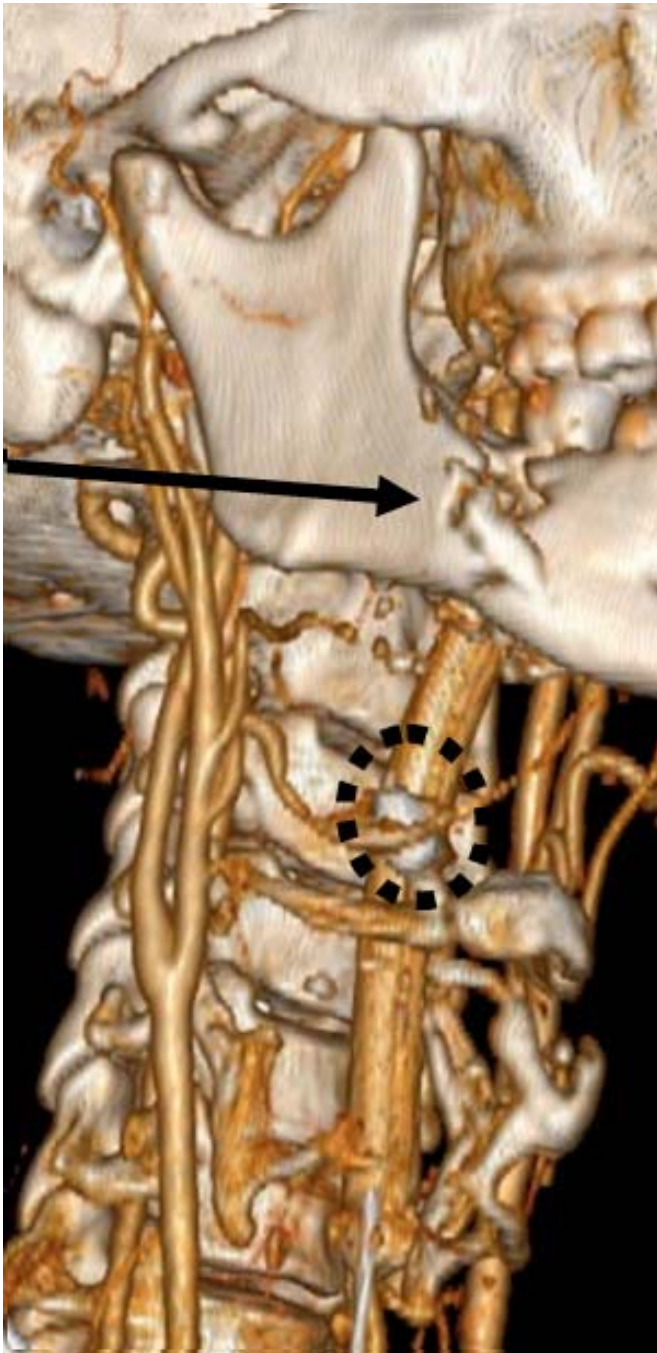


Fig. 2. 3D reconstruction showing fractured mandible and localized bullet fragment adjacent to ET tube.

Fig. 3 is a CXR of the same patient several hours after the radiograph in Fig. 1 was taken. There is obvious opacification of the right lower lobe with obliteration of the right hemidiaphragm and the right costophrenic angle. Also, the right heart border is becoming obscured. Fig. 4, a CXR taken several hours after Fig. 3, displays complete collapse of the

right lung. Following bronchoscopy, the right lung became better aerated (Fig. 5).

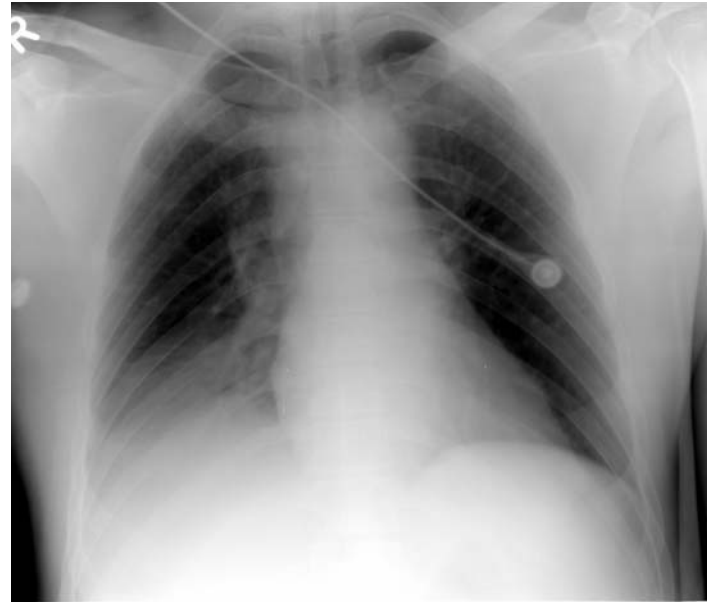

Fig. 3. CXR showing right lower lobe atelectasis. Note increasing opacification of right lower lung field, decreasing conspicuity of right hemidiaphragm, crowding of vasculature, while maintaining right heart border.

Diagnosis

Progressive Atelectasis Secondary to GSW to Airway

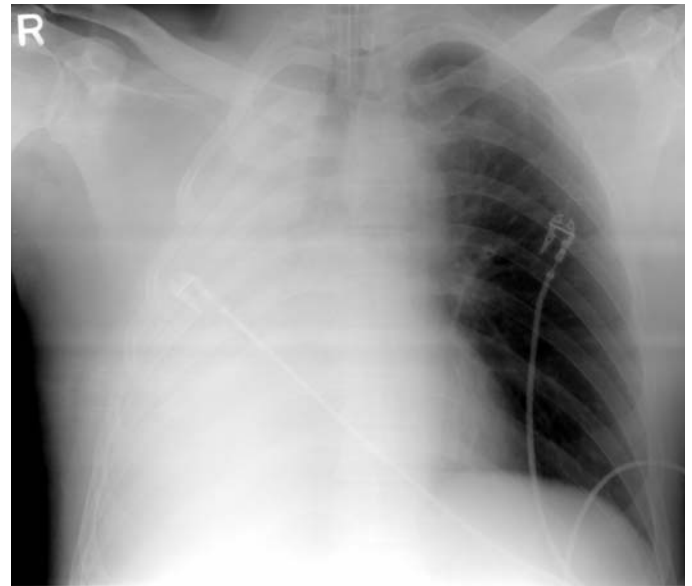

Fig. 4 Follow-up AP portable chest in ICU showing near-complete opacification of right hemithorax, tracheal deviation to right, loss of right heart border, downward angulation of right ribs.

Discussion

Underlying any atelectasis observed on radiographic film is a corresponding pathophysiologic process. Atelectasis is typically categorized according to cause by one of four main mechanisms: compression, cicatrization, adhesion and

resorption. Compression atelectasis occurs when extrinsic pressure from air, fluid, or mass within the pleural cavity creates mechanical stress to the lung parenchyma [1]. Compression atelectasis, which encompasses space-occupying processes such as pneumothorax, lung abscess and tumor, may result in retraction or entire collapse of lung lobes. The next main cause of atelectasis, cicatrization, is also produced by the interaction of mechanical forces. In cicatrization atelectasis, pulmonary fibrosis stiffens the alveoli, causing a decrease in compliance and alveolar volume. Cicatrization may present as localized atelectasis, commonly associated with granulomatous infection, or as more diffuse atelectasis, as seen in idiopathic pulmonary fibrosis [1]. The third common mechanism of atelectasis, resorption, is typically caused by interference in the production of surfactant. In this case, alveoli collapse due to the decreased surface tension that is associated with diminished levels of surfactant. Such decreased surfactant may be due to an initial inability in surfactant formation, as in hyaline membrane disease, or from damage to functional type II pneumocytes by inhaled anesthetic or radiation [1].

Resorption constitutes the final major mechanism of atelectasis and results from bronchial obstruction. Blood within alveolar capillaries resorbs oxygen back into the circulation from the airspace distal to the obstruction, causing these distal alveoli to collapse. The obstruction responsible for resorption atelectasis may be an inhaled foreign object, mucus plugging or aspiration of fluid. Atelectasis may also occur in the post-operative setting of thoracic surgery or with diaphragmatic injury, but these are less common causes than those mentioned previously [1].

Given adequate consideration of the causes and mechanisms by which atelectasis occurs, it is now appropriate to assess the unique presentation of the patient under consideration. Our patient presumably has compressive atelectasis secondary to accumulation of aspirated blood from the GSW. It is important to note that in addition to bullet fragments, broken teeth or bone fragments may also puncture the trachea and cause aspiration of blood. Due to the more vertical disposition of the right mainstem bronchus compared to the left, aspirated fluid more commonly flows into the right bronchial tree. Consistent with this anatomical characteristic, aspirated blood in this patient flowed into the lower lobe of the right lung.

There are a variety of radiographic findings associated with atelectasis. The most direct of these signs is displacement of the interlobular fissures. As a lobe collapses, the lung's fissures are displaced in a predictable manner. Collapse of a lower lobe causes the major and minor fissures to move downward and backward. Collapse of the right upper lobe will displace the major fissure anteriorly and the minor fissure superiorly. Since there is no left minor fissure, collapse of the left upper lobe occurs differently than right upper lobe collapse, as atelectasis displaces the major fissure anteriorly [2].

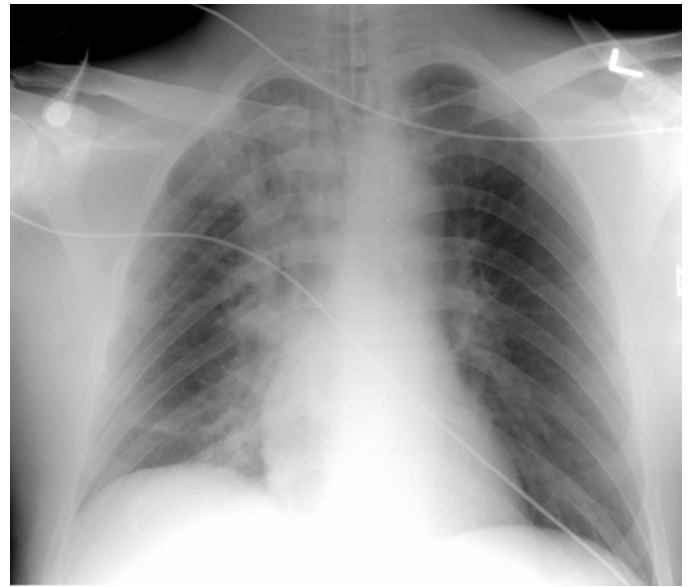


Fig. 5: Following bronchoscopy and removal of blood clot, the right hemithorax is now better aerated with some residual atelectasis.

Lobar atelectasis patterns:

See Fig. 6 and 7 for example lobar patterns of atelectasis. Left Upper Lobe collapse: Due to lack of a left minor fissure the appearance of LUL collapse is much different than RUL, except when an accessory left minor fissure is present, then the upper division of the LUL atelectasis will look like RUL atelectasis. The left major fissure is displaced anteriorly, roughly parallel to the anterior chest wall and there is a band of opacity anterior to the major fissure. On PA view there is a hazy opacity which silhouettes the left heart border.

Lower Lobes collapse: This pattern is similar on both sides. Collapse is in posterior, medial and inferior direction. The major fissure swings downward and backward. The hilum is displaced inferiorly, the hemidiaphragm is elevated. On the PA view there is a triangular opacity adjacent to the spine with the base on the hemidiaphragm. On lateral view there is increased opacity over the lower thoracic vertebrae with or without a smooth anterior margin, depending upon if the major fissure is tangential to the x-ray beam. The posterior aspect of the hemidiaphragm is obscured, unless the patient has an incomplete pulmonary ligament. Another indirect sign is the vascular nodular sign, which is result of compensatory hyperinflation of the upper lobe. This is radiographically seen as "hair-pin" turning of vessels and "too-many nodules" along the cardiac margin, which are end-on vessels. Kattan's triangle sign may also be seen, which is the shifted v-shaped opacity superior to the anterior junction line.

In addition to displacement of the fissures, there are a number of indirect signs on CXR that indicate a diagnosis of atelectasis. The first is shift of the ipsilateral mediastinum towards the area of atelectasis, with resultant hilar displacement. Another indirect sign is the presence of pulmonary vasculature that is closely packed together, sometimes appearing as nodules that represent vessels that have been turned on end due to hyperinflation of the upper lobe [3]. Thus, compensatory hyperinflation of the unaffected

lobes is another common finding in atelectasis. Aforementioned opacification and elevation of the hemidiaphragm at the collapsed lobe are also considered indirect signs [4,5].

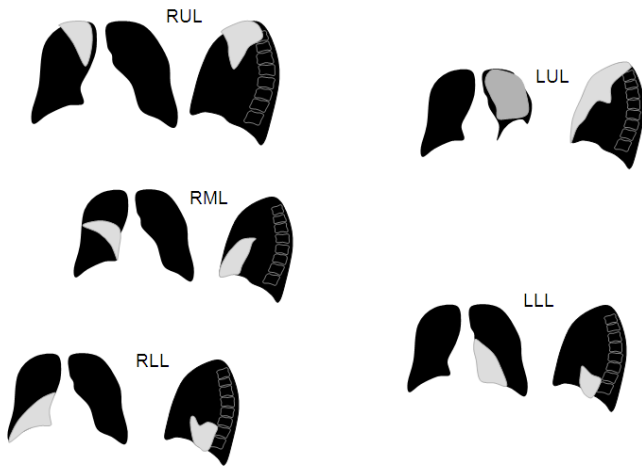


Fig. 6 Characteristic lobar patterns of atelectasis seen on radiographic imaging.

deviation, mediastinal shift and hilar displacement as well as crowded vasculature. Fig. 3 shows a triangular shaped opacity of the right lower lobe consistent with the classic radiographic pattern of atelectasis displayed in Fig. 4.

Additionally, Fig. 3 shows the right lung in the process of collapsing as air volume in the right lower lobe decreases and hypoxia ensues. The patient's condition soon deteriorated, as CXR taken several hours later displays collapse of the entire right lung. Severe lung collapse such as this is often characterized by inward movement of the chest wall. This results in narrowing of the space between affected ribs, as seen in Fig. 4 [2]. Note the sharp downward angle of the affected ribs. Also notice the significant tracheal deviation, narrowing of the left heart border formed by the left ventricle and slight flattening of the left hemidiaphragm in Fig. 4 compared to Fig. 3, which are indicative of compensatory hyperinflation of the unaffected left lung [3].

Category 1 CME or CNE can be obtained on the MedPix™ digital teaching file on similar cases by opening the following link. Many Radiology Corner articles are also a MedPix™ Case of the Week where CME credits can be obtained.

<http://rad.usuhs.mil/amsus.html>

Category 1 CME or CNE can be obtained on related cases in the MedPix™ digital teaching file following the same link.

The authors would like to graciously thank Sofia del Castillo for her excellent artwork.

References:

1. Fraser, R.S. Et al; Diagnosis of Diseases of the Chest Fourth Edition. W.B Sanders Company, 1999, Vol 1; p. 513-514.
2. Hansell, David M. Et al; Imaging of the Diseases of the Chest Fourth Edition. Elsevier Limited, 2005, p98-101; 754.
3. Gurney, Jud W. Et al; Diagnostic Imaging: Chest. First Edition. Amirsys Inc., 2006, Part IV-1-2.
4. Fishman, Alfred P. Et al; Fishman's Pulmonary Disease and Disorders Third Edition. McGraw Hill Companies Inc., 1998, Vol 1; p454-55,62
5. MedPix™ Medical Imaging Database of USUHS. "Atelectasis." <http://medpix.net/medpix/master.php3?mode=single&recnum=5380&table=card&srchstr=&search=>

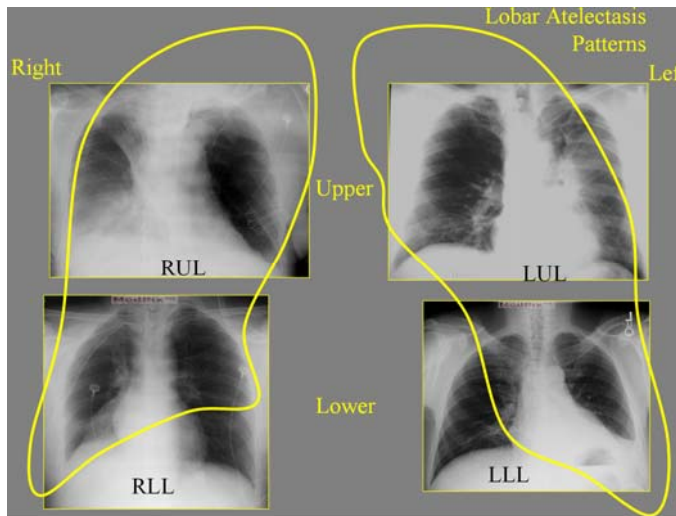


Fig. 7: Lobar patterns of atelectasis oriented in graphic used in teaching at USU.

The patient displays a number of these signs in Fig. 1 and Fig. 3. Although displacement of the interlobar fissures are not well visualized in either figure, Fig. 1 shows the indirect signs of ipsilateral hemidiaphragm elevation, tracheal