

How I Do It

Pacifying the open abdomen with concomitant intestinal fistula: a novel approach

Maj. Brian Layton, U.S.A.F., M.C.^{a,*}, Maj. Joe DuBose, U.S.A.F., M.C.^b,
Maj. Shawnn Nichols, U.S.A.F., M.C.^b, Lt. Col. James Connaughton, U.S.A.F., M.C.^b,
Lt. Col. Tracy Jones, U.S.A.F., M.C.^b, Col. Jerry Pratt, U.S.A.F., M.C.^b

^aDepartment of Surgery, Wake Forest University Baptist Medical Center, Medical Center Boulevard, Winston-Salem, NC 27157; ^b332nd Air Force Theater Hospital, Balad, Iraq

KEYWORDS:

Intestinal fistula;
Open abdomen;
Enterocutaneous
fistula;
Wound vac;
Abdominal sepsis;
Trauma

Abstract. The management of the open abdomen, particularly when complicated by the presence of intestinal fistula, remains a significant challenge of modern trauma care. Although several approaches have been proposed, these varied and complex cases defy the application of a universal approach to local therapy. Ultimately, abdominal closure is desired but is not always possible. Accordingly, surgeons must be well versed in the application of a number of useful approaches that may serve to facilitate control of fistula drainage while permitting management of the surrounding open wound. We contribute a management approach that is simplistic in design, provides for effective fistula control, and permits the subsequent unhindered granulation of the surrounding wound in abdomens not amenable to delayed closure techniques.

© 2010 Published by Elsevier Inc.

The management of the open abdomen remains a significant challenge of modern surgical care, particularly after trauma. Further confounding the situation, concomitant intestinal fistulization may occur in 1.5% to 25% of cases and contributes significantly to subsequent morbidity and medical costs.^{1–4} Efforts to control the drainage from a fistula within the open abdomen, or an “enteroatmospheric fistula,” may prove significantly more challenging than those used in the management of enterocutaneous varieties. Commonly surrounded by an adhered mass of granulating bowel without an appropriate surface amenable to appliance place-

ment, even the initial diversion of drainage from the wound is a substantial problem.

Methods

After irrigation and removal of contamination, we place the soft base of a standard baby bottle nipple of latex or silicone over the fistula (Fig. 1). If of soft consistency, the nipple can be placed directly on the bowel, or, alternatively, one may place it over an underlying ring of colostomy paste (Adapt Paste; Hollister International, Libertyville, IL). Although not typically necessary, a ring of colostomy paste can be used to provide an additional barrier to leakage in those cases in which a seal at the level of the surrounding bowel/granulation tissue proves difficult. To provide connection to gravity drainage via Foley tubing, we then cut an approximately 3- to 4-mm hole in the tip of the nipple through which a Malecot or Foley catheter with a slightly

The opinions and assertions contained herein are the private views of the author(s) and are not to be construed as the official policy or position of the United States Government, the Department of Defense, or the Department of the Air Force.

* Corresponding author. Tel.: +1-336-716-4241; fax: +1-336-716-5414.

E-mail address: b.layton@hotmail.com

Manuscript received April 20, 2009; revised manuscript May 8, 2009.

Report Documentation Page

Form Approved
OMB No. 0704-0188

Public reporting burden for the collection of information is estimated to average 1 hour per response, including the time for reviewing instructions, searching existing data sources, gathering and maintaining the data needed, and completing and reviewing the collection of information. Send comments regarding this burden estimate or any other aspect of this collection of information, including suggestions for reducing this burden, to Washington Headquarters Services, Directorate for Information Operations and Reports, 1215 Jefferson Davis Highway, Suite 1204, Arlington VA 22202-4302. Respondents should be aware that notwithstanding any other provision of law, no person shall be subject to a penalty for failing to comply with a collection of information if it does not display a currently valid OMB control number.

| | | | | | |
|--|------------------------------------|---|---|---------------------------------|---------------------------------|
| 1. REPORT DATE 2010 | 2. REPORT TYPE | 3. DATES COVERED 00-00-2010 to 00-00-2010 | | | |
| 4. TITLE AND SUBTITLE Pacifying the open abdomen with concomitant intestinal fistula: a novel approach | | 5a. CONTRACT NUMBER | | | |
| | | 5b. GRANT NUMBER | | | |
| | | 5c. PROGRAM ELEMENT NUMBER | | | |
| 6. AUTHOR(S) | | 5d. PROJECT NUMBER | | | |
| | | 5e. TASK NUMBER | | | |
| | | 5f. WORK UNIT NUMBER | | | |
| 7. PERFORMING ORGANIZATION NAME(S) AND ADDRESS(ES) 332nd Air Force Theater Hospital, Balad, Iraq, | | 8. PERFORMING ORGANIZATION REPORT NUMBER | | | |
| 9. SPONSORING/MONITORING AGENCY NAME(S) AND ADDRESS(ES) | | 10. SPONSOR/MONITOR'S ACRONYM(S) | | | |
| | | 11. SPONSOR/MONITOR'S REPORT NUMBER(S) | | | |
| 12. DISTRIBUTION/AVAILABILITY STATEMENT Approved for public release; distribution unlimited | | | | | |
| 13. SUPPLEMENTARY NOTES | | | | | |
| 14. ABSTRACT see report | | | | | |
| 15. SUBJECT TERMS | | | | | |
| 16. SECURITY CLASSIFICATION OF: | | | 17. LIMITATION OF ABSTRACT Same as Report (SAR) | 18. NUMBER OF PAGES 3 | 19a. NAME OF RESPONSIBLE PERSON |
| a. REPORT unclassified | b. ABSTRACT unclassified | c. THIS PAGE unclassified | | | |

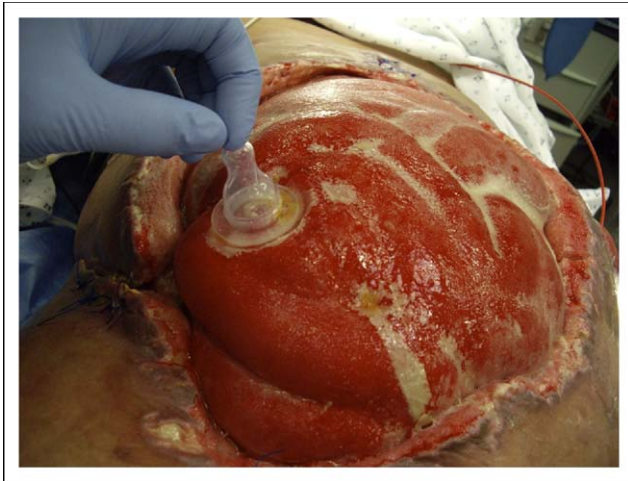

Figure 1 Baby nipple coverage of fistula in a chronically frozen abdomen.

inflated balloon can be connected (Fig. 2). The catheter is properly positioned in the apex of the nipple so as not to contact the bowel or fistula orifice directly (Fig. 3). A nonadherent, petroleum jelly-impregnated gauze or clear Telfa sheet (Tyco Healthcare, Mansfield, MA) is then placed over the bowel excluding the area that the nipple covers in the region of the fistula. Finally, an abdominal wound vac (Wound Vac; KCI, Corp., San Antonio, TX) sponge is tailored to fit over the petroleum dressing covering the exposed bowel. We do not advocate direct contact of the sponge with the exposed bowel because of concerns for additional fistula development.

During final positioning, a small hole is cut in an appropriate location to accommodate the nipple/catheter apparatus. If an appropriately sized orifice has been cut, one should be able to obtain a seal around and onto the nipple itself. If necessary, however, the plastic covering the sponge can be extended onto the catheter itself to ensure an adequate seal for subsequent vacuum. Particular care should be taken

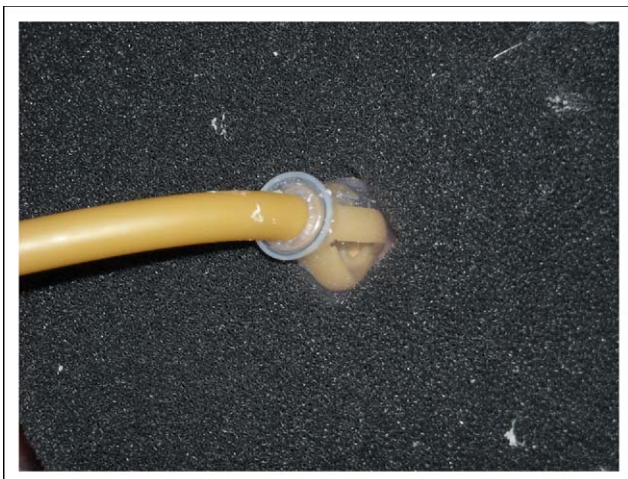

Figure 2 Connection of gravity drainage to the nipple using Malecot drain through the superficial side of the sponge.

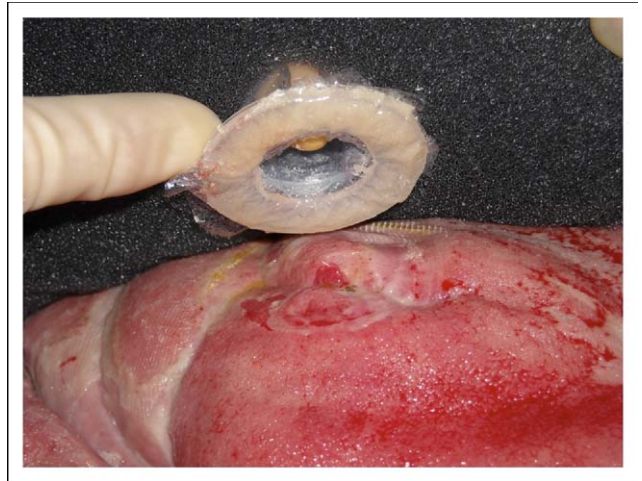


Figure 3 Appropriate positioning of drainage catheter tip to avoid contact with bowel.

during the final stages of plastic coverage to ensure that the nipple remains appropriately oriented over and perpendicular to the fistula opening. Once the vacuum is sealed, the sponge should condense and hold the nipple in proper alignment to facilitate atraumatic drainage control. The fistula catheter is placed to gravity drainage, and the surrounding wound vac suction is set for continuous settings at 125 mm Hg of suction (Fig. 4).

As described, our method has the potential to provide for both control of the fistula effluent and accurate measurement and collection of the subsequent output. Additionally, this technique can promote the creation of a bed of granulation tissue over the bowel amenable to subsequent skin grafting. After subsequent grafting, we have also effectively used the same technique to aid in fistula control and bolstering of our split-thickness skin graft during the process of initial graft in-growth. Once the skin graft has taken, more traditional stoma appliances or other methods can be used to

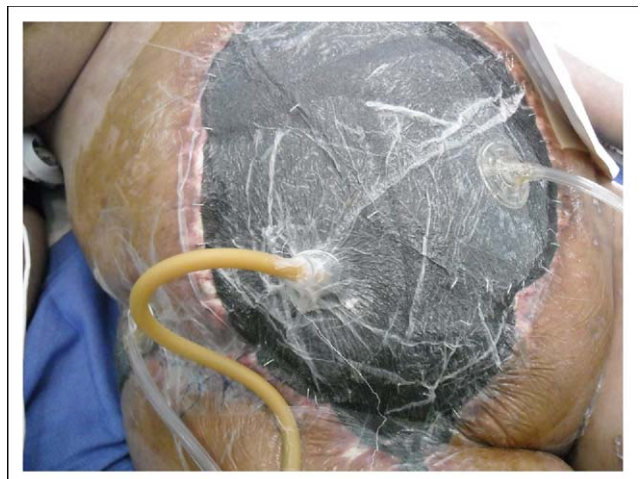


Figure 4 A completed dressing showing gravity drainage of fistula with vacuum dressing (Wound Vac; KCI, Corp, San Antonio, TX) of the surrounding frozen abdomen.

control the fistula output until the fistula resolves or more definitive surgical treatment of the fistula can be performed.

Comments

Intestinal fistulas manifesting within the open abdomen are challenging management dilemmas. Although fistula closure or resection of the affected segment of bowel may prove ideal, it is not always possible. Abdominal closure may subsequently prove not to be feasible without the concern for the development of intra-abdominal sepsis. The resulting open cavity with exposed bowel creates a surface surrounding the fistula that is not amenable to the placement of traditional ostomy appliances. Previous authors have proposed various techniques for use in these challenging situations, including the creation of a "floating stoma" through a plastic silo,⁵ patching with acellular dermal matrix and fibrin glue,¹ and cannulation of the fistula with tubes and catheters.^{6,7} The latter of these proposals remains particularly problematic⁷ because intubation of the fistula may result in the creation of a larger, more difficult to control lesion. Although vacuum therapy remains another option, the evacuated succus may prove too thick for sufficient drainage through the vacuum sponge, also leading to inadequate diversion.

We describe a novel approach to a challenging entity that provides atraumatic control of drainage from an enteroatmospheric fistula without the need for cannulization of the offending orifice. Using this method, the fistula output can be easily quantified for accurate estimation of fluid, electrolyte, and nutritional needs because the output is collected in a simple Foley catheter collection bag by gravity drainage. The technique is cost-effective and uses supplies commonly found in any hospital. It also facilitates the concomitant use of vacuum therapy to promote a clean wound that granulates effectively for subsequent skin grafting at a lower

labor cost than traditional wet-to-dry dressing changes. The use of the wider aperture of the nipple also permits for the adequate drainage of thicker fistulous effluent at consistencies that might not be easily evacuated by other means. Although we have not yet employed the use of multiple nipple use to treat more than 1 fistula in a single open abdomen, this also remains a potential application that is feasible using our described technique.

The enteroatmospheric fistula remains a significant problem for surgical providers who are faced with this challenge. No single approach will prove ideal in each circumstance. In our experience, however, the effective employment of the described technique creates the optimal end state in the open abdomen that is not amenable to closure because of a persistent enteroatmospheric fistula, a well-controlled fistula surrounded by a granulation bed amenable to skin grafting.

References

1. Girard S, Sideman M, Spain DA. A novel approach to the problem of intestinal fistulization arising in patients managed with open peritoneal cavities. *Am J Surg* 2002;184:166–7.
2. Fisher JE. A cautionary note: the use of vacuum-assisted closure systems in the treatment of gastrointestinal cutaneous fistula may be associated with higher mortality from subsequent fistula development. *Am J Surg* 2008;196:1–2.
3. Teixeira PG, Inaba K, Dubose J, et al. Enterocutaneous fistula complicating trauma laparotomy: a major resource burden. *Am Surg* 2009;75:30–2.
4. Bosscha K, Hulstaert PF, Visser MR, et al. Open management of the abdomen and planned reoperations in severe bacterial peritonitis. *Eur J Surg* 2000;166:44–9.
5. Subramanian MJ, Liscum KR, Hirshberg A. The floating stoma: A new technique for controlling exposed fistulae in abdominal trauma. *J Trauma* 2002;53:386–8.
6. Al-Khoury G, Kaufman D, Hirshburg A. Improved control of exposed fistula in the open abdomen. *J Am Coll Surg* 2008;206:397–8.
7. Schecter WP, Ivatury RR, Rotondo MF, et al. Open abdomen after trauma and abdominal sepsis: A strategy for management. *J Am Coll Surg* 2006;203:390–6.