

AD _____

Award Number: W81-XWH-08-1-0738

"

TITLE: Characterization of the pathological and biochemical markers that correlate to the
"clinical features of autism

"

PRINCIPAL INVESTIGATOR: Jerzy Wegiel, Ph.D.

CONTRACTING ORGANIZATION: Research Foundation for Mental Hygiene, Inc.,
"Staten Island, New York 10314

REPORT DATE: October 2009

TYPE OF REPORT: Annual

PREPARED FOR: U.S. Army Medical Research and Materiel Command
"Fort Detrick, Maryland 21702-5012

"

DISTRIBUTION STATEMENT:

Approved for public release; distribution unlimited

The views, opinions and/or findings contained in this report are those of the author(s) and should not be construed as an official Department of the Army position, policy or decision unless so designated by other documentation.

REPORT DOCUMENTATION PAGE			Form Approved OMB No. 0704-0188		
1. REPORT DATE 21/10/09	2. REPORT TYPE Annual		3. DATES COVERED (From - To) 22 Sept 2008 –21 Sept 2009		
4. TITLE AND SUBTITLE Characterization of the pathological and biochemical markers that correlate to the clinical features of autism.			5a. CONTRACT NUMBER		
			5b. GRANT NUMBER W81XWH-08-1-0738		
			5c. PROGRAM ELEMENT NUMBER		
6. AUTHOR(S) Jerzy Wegiel, Ph.D., D.V.M., Go ckn"lay gi lgrB o up@qo "			5d. PROJECT NUMBER		
			5e. TASK NUMBER		
			5f. WORK UNIT NUMBER		
7. PERFORMING ORGANIZATION NAME(S) AND ADDRESS(ES) Research Foundation for Mental Hygiene, Inc. Staten Island, New York 10314 USA			8. PERFORMING		
9. SPONSORING / MONITORING AGENCY NAME(S) AND ADDRESS(ES) U.S. Army Medical Research and And Medical Command Fort Detrick, MD. 21702-5012			10. SPONSOR/MONITOR'S ACRONYM(S)		
			11. SPONSOR/MONITOR'S NUMBER(S)		
12. DISTRIBUTION / AVAILABILITY STATEMENT Approved for public release; distribution unlimited					
13. SUPPLEMENTARY NOTES					
14. ABSTRACT The study of 22 brain subdivisions in 13 autistic and 14 control subjects with unbiased stereological methods revealed that autism is associated with profound global desynchronization of neuronal growth within the developing brain. Desynchronization is reflected in: (a) very significant delay of neuronal growth in the n. accumbens (-37%), thalamus (-33%), reduced volume of Purkinje cells (-32%), globus pallidus (-31%), amygdala (-28%), entorhinal cortex (-28%); (b) moderate delay of neuronal growth within putamen (-17%), caudate (-16%) and in the dentate nucleus (-19%); and (c) unchanged trajectory of neuronal development within the cornu Ammonis and in the lateral geniculate nucleus. Developmental delay of neuronal growth and related neuronal networks may contribute to the main functional anomalies observed in autism. Developmental delay in the striatal circuitry may contribute to repetitive and stereotyped behaviors. Developmental changes in the nucleus accumbens may enhance engagement in ritual and stereotyped behavior. Verbal and nonverbal communication deficits, sensory abnormalities, skeletal muscle hypotonia, and intellectual deficits could be result of developmental abnormalities in the thalamus and cerebellum. The emerging pattern of developmental delay of neuronal growth could be the target for development of early interventions stimulating neuronal growth and preventing structural and functional deterioration.					
15. SUBJECT TERMS Autism, Developmental Delay of Neuronal Growth, Desynchronization of Brain Development					
16. SECURITY CLASSIFICATION OF:			17. LIMITATION UU	18. NUMBER ; 6	19a. NAME OF RESPONSIBLE PERSON USAMRMC
a. REPORT U	b. ABSTRACT U	c. THIS PAGE U			19b. TELEPHONE NUMBER (include area code)

**Table of Contents
Subproject 2**

	<u>Page</u>
Introduction.....	4
Body.....	4
Key Research Accomplishments.....	17
Reportable Outcomes.....	17
Conclusion.....	18
References.....	20
Appendices.....	21

SUBPROJECT 2

Contribution of significant delay of neuronal development and metabolic shift of neurons

to clinical phenotype of autism

P.I.: Jerzy Wegiel, D.V.M., Ph.D.

INTRODUCTION

Three components of this Program Project are focused on different aspects of (a) pathomechanisms and (b) morphological and biochemical markers of autism, (c) correlations between pathology and clinical manifestations of autism, and (d) the detection of those pathological domains that might be a target for treatment.

Projects 1 and 2 are integrated with two overall hypotheses:

1. Focal qualitative neuropathological changes (altered neurogenesis, migration and dysplastic changes of cytoarchitecture) contribute to interindividual differences and expansion of spectrum of clinical manifestations of autism.

2. Clinical manifestations of three diagnostic domains of autism (a) communication deficits, (b) social deficits, and (c) stereotypic behaviors, are the effect of developmental abnormalities present in very early childhood. Desynchronization of development of brain networks, caused by delay of neuronal growth in many brain structures, is the major contributor to clinical changes which are the basis for clinical diagnosis of autism by age three.

The results of the first year of the study strongly support these two hypotheses. We assume that detected developmental delay of neuronal growth could be the baseline for development of early interventions stimulating neuronal growth and preventing structural and functional deterioration.

BODY

Etiological and clinical diversity in autism has been reported and is reflected in the broad spectrum of neuropathological changes. The majority of reported changes are rather quantitative than qualitative and some require application of morphometric methods and statistical analysis to be detected. Bauman and Kemper [1985, 1997] reported three major types of neuropathological changes in the brains of people with autism: (1) curtailed development of neurons in the structures that are substrates for memory and emotions – the entorhinal cortex, hippocampus, subiculum, anterior cingulate gyrus, and mamillary body; (2) a congenital decrease in the number of Purkinje cells in the cerebellum; and (3) age-related differences in cell size and number of neurons in the cerebellar nuclei, and the inferior olivary nucleus. The summary of results from approximately 40 brains, reported between 1980 and 2004, describes increased cell packing in the limbic system, reduced numbers of Purkinje cells, age related changes in cerebellar nuclei and inferior olives, cortical dysgenesis, and increased brain size in young autistic children [Palmen et al 2004]. Casanova et al [2002, 2006] detected an increased number of minicolumns and narrowing of minicolumns, and reduced size of neurons in Brodmann areas 9, 21, and 22 suggesting prenatal developmental abnormalities. Our study revealed deregulation of neuronal growth with lifelong structural consequences (Wegiel et al 2009).

Hypothesis. We hypothesized that mechanisms regulating neuron growth in early childhood are the target of factors that are the cause of autism. The result of deregulation of these mechanisms are:

- (a) brain structure specific delayed growth of neuronal body and nucleus,
- (b) desynchronization of development of anatomical and functional brain systems and
- (c) functional deficits corresponding to these structural developmental alterations.

Aim.

- (a) To define the age of onset, and duration of developmental delay of neuronal growth of neurons in the brain of autistic subjects.
- (b) To identify anatomical and functional brain domains prone and resistant to developmental delay.
- (c) To detect the pattern of desynchronization of brain development in childhood and adulthood.
- (d) To evaluate potential contribution of structural developmental alterations to clinical phenotype.

Material. One brain hemisphere of 13 autistic subjects and 14 control subjects was embedded, cut into serial sections, stained/immunostained, and examined by neuropathologists and morphometrists (Table 1). This is the first morphometric study of autistic and age-matched cohorts based on a rigorous clinical and neuropathological exclusion criteria. Exclusion of 31% of cases not matching the clinical and neuropathological criteria, to be included in the morphometric studies, reduced the risk of inaccurate results and false conclusions.

Methods.

Structures examined morphometrically. A broad spectrum of functional abnormalities typical for autism, including: impairments in reciprocal social interactions, impairments in verbal and non-verbal communication, restricted repetitive and stereotyped patterns of behavior, interests, and activities suggest that many brain regions/structures of autistic subjects are affected and contributing to the clinical phenotype. Onset of clinical features of autism prior to the age of 3 years (Rapin 1997, Lord et al 2000) suggests that some changes of brain structure leading to autism occur during infancy.

To detect quantitative changes, we examined

- (a) limbic system involved in emotions, social behavior (amygdala) and memory processing (entorhinal cortex) and storage (cornu Ammonis);
- (b) several subdivisions of the striatal networks involved with stereotypic behaviors (caudate, putamen, globus pallidus) and reward (nucleus accumbens);
- (c) the thalamus as a key component of networks implicated in attention, memory, language, and emotional processing;
- (d) cerebellum (Purkinje cells and dentate nucleus) involved in language and motor functions.

Sections: Cresyl violet stained celloidin serial 200- μ m-thick sections.

Equipment: Image analyzer with computer controlled automatic stage and Nucleator software (Microbrightfield, VA, USA).

Stereology: Volume of brain structures was estimated with Cavalieri method, the number of neurons with fractionator, and the volume of cell body and cell nucleus with Nucleator.

Objective lens: 2.5 x (volumetry), 40 x (dissector; final magnification 1,480 x), and 60x (nucleator; final magnification 2,150 x). The mean number of neurons measured with Nucleator per one region/case was in range from 250 to 350 with Schaffer coefficient of error in range from 0.01 to 0.05.

Statistical analysis: The normality of distributions was estimated with Kolmogorov/Smirnov test, the homogeneity of variance with Levy method, and the significance of difference between groups was estimated with ANOVA.

Table 1. Material examined

#	Group	Brain Bank #	Sex	Age	Cause of death	PMI (h)	H	Brain weight (g)
1	A	IBR425-02	M	4	Drowning	30	R	1,280
2	A	UMB-1627	F	5	Trauma, multiple injuries	13.2	R	1,390
3	A	B-6403	M	7	Drowning	25	R	1,610
4	A	B-5666	M	8	Rhabdomyosarcoma	22.2	R	1,570
5	A	B-5342	F	11	Drowning, seizure related	12.9	L	1,460
6	A	B-5535	M	13	Seizure related	8	L	1,470
7	A	B-6115	F	17	Cardiac arrest related to cardiomyopathy	25	L	1,580
8	A	UMB-1638	F	21	Seizure related respiratory failure	50	R	1,108
9	A	B-6337	M	22	Seizure related	25	R	1,375
10	A	IBR93-01	M	23	Status epilepticus related to respiratory failure	14	R	1,610
11	A	B-6212	M	36	Cardiac arrest	24	R	1,480
12	A	B-6276	M	56	Cardiac arrest	3.35	R	1,570
13	A	B-7090	M	60	Pancreatic cancer	26.5	R	1,210
1	C	B-6736	F	4	Acute bronchopneumonia	17	R	1,530
2	C	UMB-1499	F	4	Lymphocytic myocarditis	21	R	1,222
3	C	UMB-4898	M	7	Drowning	12	R	1,240
4	C	UMB-1708	F	8	Trauma, multiple injuries	20	R	1,222
5	C	BTB-3638	M	14	Electrocution	20	R	1,464
6	C	UMB-1843	F	15	Trauma, multiple injuries	9	R	1,250
7	C	UMB-1846	F	20	Trauma, multiple injuries	9	R	1,340
8	C	UMB-1646	M	23	Ruptured spleen	6	R	1,520
9	C	UMB-4543	M	29	Traumatic multiple injuries	13	R	1,514
10	C	UMB-1576	M	32	Trauma, compressional asphyxia	24	R	1,364
11	C	BTB-3899	M	48	Atherosclerotic heart disease	24	L	1,412
12	C	IBR252-02	M	51	Myocardial infarct	18	L	1,450
13	C	BTB-3983	M	52	Heart atherosclerosis	13	R	1,430
14	C	B-6874	M	64	Cardiac arrest	28	R	1,250

PMI – Postmortem Interval,

H – hemisphere

R–right; L– left

Results

Results are summarized in three sections characterizing developmental alterations in three anatomical and functional domains:

1. Delayed growth of neurons in the limbic system involved in emotions, social behavior (amygdala) and memory processing (entorhinal cortex) and storage (cornu Ammonis).
2. Delayed development of neurons in striatal networks involved with stereotypic behaviors (caudate, putamen, globus pallidus) and reward (nucleus accumbens) in autism.
3. Contribution of thalamic developmental alterations to the autistic phenotype.

1. Delayed growth of neurons in the amygdala, the entorhinal cortex and in the cornu Ammonis.

The mean volume of limbic system subdivisions

The mean volume of the amygdala was significantly less (by 34%) in autistic children as compared to the control subjects from 4 to 8 years of age (228 mm³ and 334 mm³, respectively). In 4 to 56 years of age autistic subjects the mean volume was 24% less than in the control group.

The mean volume of the entorhinal cortex was insignificantly lower (by 14%) in the autistic group compared to the control children from 4 to 8 years of age (415 mm³ and 481 mm³, respectively) and from 4 to 56 years of age subjects (483 mm³ and 501 mm³, respectively).

The mean volume of the cornu Ammonis was similar in both the autistic and control children 4 – 8 years of age (554 mm³ and 576 mm³, respectively) and from 4 to 56 years of age subjects (628 mm³ and 599 mm³, respectively).

There was no correlation between the volume of the amygdala, the entorhinal cortex, and the cornu Ammonis with respect to the age in autistic subjects.

The mean total number of neurons

The mean total number of neurons in the amygdala was significantly lower (by 50%) in autistic than control children from 4 to 8 years of age (5 million and 10 million, respectively) and 30% less in autistic than control subjects from 4 to 56 years of age (7 million and 10 million, respectively).

The mean total number of neurons in the entorhinal cortex was insignificantly less (by 21%) in the autistic group than in the control children from 4 to 8 years of age (11 million and 14 million, respectively) and in autistic subjects and controls from 4 to 56 years of age subjects (12 million and 13 million, respectively).

There was no significant difference between the mean total number of neurons in the cornu Ammonis for both the autistic and control children from 4 to 8 years of age (16 million and 17 million, respectively) and in autistic subjects and control from 4 to 56 years of age (16 million and 15 million, respectively). There was no correlation between the number of neurons in the amygdala, the entorhinal cortex and the cornu Ammonis with respect to age in autistic cohort.

The mean volume of neuronal soma (Fig. 1)

The mean volume of neuronal soma in the amygdala in 4 to 8-year old children was 28% less in the autistic group ($2,321 \mu\text{m}^3$) than in the control group ($3,213 \mu\text{m}^3$) and 16% less in the autistic group ($2,621 \mu\text{m}^3$) than in the control subjects ($3,104 \mu\text{m}^3$) from 4 to 56 years of age. The volume of neuronal soma in the amygdala significantly increases with age ($r = 0.56$) in the autistic subjects.

The mean volume of neuronal soma in the entorhinal cortex in 4 to 8-year old children was 28% less in the autistic group ($2,055 \mu\text{m}^3$) than in control group ($2,850 \mu\text{m}^3$) and 20% less in the autistic ($2,197 \mu\text{m}^3$) than in the control ($2,739 \mu\text{m}^3$) subjects from 4 to 56 years of age. The mean volume of neuronal soma in the entorhinal cortex significantly increases with age ($r = 0.67$) in autistic subjects.

The mean volume of neuronal soma in the cornu Ammonis was comparable in 4 to 8-year old autistic and control children ($3,375 \mu\text{m}^3$ and $3,508 \mu\text{m}^3$, respectively) and in autistic ($3,394 \mu\text{m}^3$) and control subjects ($3,677 \mu\text{m}^3$) from 4 to 56 years of age. There was no correlation between the volume of neuronal soma in the cornu Ammonis and age in autistic subjects.

The mean volume of neuronal nucleus

The mean volume of neuronal nuclei in the amygdala in 4 to 8-year old children was 32% less in the autistic group ($429 \mu\text{m}^3$) than in control group ($629 \mu\text{m}^3$) and 23% less in the autistic ($482 \mu\text{m}^3$) than in the control ($624 \mu\text{m}^3$) subjects from 4 to 56 years of age. The mean volume of neuronal nuclei in the amygdala slightly increases with age ($r = 0.40$) in autistic subjects.

The mean volume of neuronal nuclei in the entorhinal cortex in 4 to 8-year old children was 29% less in the autistic group ($432 \mu\text{m}^3$) than in the control subjects ($611 \mu\text{m}^3$) and 22% less in the autistic ($426 \mu\text{m}^3$) than in control ($549 \mu\text{m}^3$) subjects from 4 to 56 years of age. There was no correlation between mean volume of neuronal nuclei in the entorhinal cortex and age in autistic subjects.

The mean volume of neuronal nuclei in the cornu Ammonis was 18% lower in 4 to 8-year old autistic children than in control group ($612 \mu\text{m}^3$ and $743 \mu\text{m}^3$, respectively) and 10% less in the autistic ($648 \mu\text{m}^3$) than in the control subjects ($717 \mu\text{m}^3$) from 4 to 56 years of age. There was no correlation between the volume of neuronal nuclei in the cornu Ammonis and age in autistic subjects.

Summary of results of stereological studies of the limbic system

The quantitative study of the limbic system revealed

1. In autistic subjects from 4 to 8 years of age there is significant decrease in the mean volume of structure and number of neurons in the amygdala and the entorhinal cortex but not in the cornu Ammonis. No correlation between volume, number of neurons and age in the amygdala, the entorhinal cortex and cornu Ammonis was found in autistic subjects from 4 to 56 years of age
2. The decrease mean volume of neurons in the amygdala and the entorhinal cortex by 28%, as compared to control subjects, was detected in autistic subjects from 4 to 8 years of age

3. Autism is associated with profound desynchronization of development of neurons within limbic system with delay of growth of neurons in the amygdala and entorhinal cortex but not in the cornu Ammonis.

2. Delayed development of neurons in striatal networks involved with stereotypic behaviors (caudate, putamen, globus pallidus) and reward (nucleus accumbens) in autism.

Autism signs include lower-order repetitive motor behaviors, intense circumscribed patterns of interests, and higher-order rituals and compulsions that occur regularly and interfere with daily functioning (Gabriels et al., 2005). Several studies have implicated the role of the basal ganglia and frontostriatal circuitry in the pathophysiology of autism, especially in repetitive and stereotyped behaviors. Increased volume of the basal ganglia reported in several MRI studies was linked to repetitive and stereotyped behaviors in autism (Sears et al., 1999, Herbert et al., 2003; Hollander et al., 2005; Langen et al., 2007).

Nevertheless, the nature of cytoarchitectonic changes in the basal ganglia contributing to these behavioral modifications is unknown.

Hypothesis:

- (a) Striatum of autistic subjects is affected by developmental pathology detectable with morphometric methods.
- (b) These changes may contribute to the restricted repetitive and stereotyped behavior in autistic subjects.
- (c) Changes in the nucleus accumbens could be an indicator of the abnormal function of the reward system. Pathology of the reward system is contributing to repetitive and stereotyped behavior.

The volume of striatal subdivisions

The mean volume of the nucleus accumbens (178 mm³), caudate nucleus (2,197 mm³), and globus pallidus (506 mm³) in the 11 autistic subjects from 4 to 56 years of age does not differ from those observed in the 11 age-matched control individuals. No correlation could be identified between the volume of these structures and the age of autistic and control subjects.

The total number of neurons within striatal subdivisions

The mean number of neurons in the nucleus accumbens (8.1 million), caudate nucleus (58 million) and globus pallidus (1.0 million) in the 11 autistic subjects from 4 to 56 years of age does not differ from those observed in the age matched control subjects. The number of neurons does not change with age in autistic and control subjects.

The mean volume of neurons within striatal subdivisions (Fig. 2)

Nucleus accumbens. The mean volume of neurons in 4 to 8 year old children was 37% less in the autistic group than in controls (n = 4; p < 0.02). The mean volume of neuronal soma in the examined autistic group, from 4 to 56 years of age, was insignificantly less than in the control group (p < 0.08). Correlation between the volume of neuronal body

and age in the nucleus accumbens of autistic subjects ($r = 0.66$; $n = 11$), reflects a delay of neuronal growth in the youngest children.

Globus pallidus. The mean volume of neurons in 4 to 8 year old children was 31% less in the autistic group than in controls ($n = 4$; $p < 0.03$). The mean volume of neuronal soma in the examined autistic group, from 4 to 56 year of age, is insignificantly less than in the control group (-12%). The volume of neuronal body in the globus pallidus increases with age ($r = 0.57$; $n = 11$) in autistic subjects but not in the control group.

Caudate nucleus. The mean volume of neurons in 4 to 8-year old autistic children was insignificantly less (-12%) than in the control group. The mean volume of neuronal soma in the entire autistic group ($n = 11$) from 4 to 56 years of age, was less by only 5% (insignificant difference). Insignificant correlation between the volume of neuronal body and age ($r = 0.37$; $n = 11$) is observed in autistic group but not in the control group.

The mean volume of neuronal nuclei within striatal subdivisions

Nucleus accumbens. The mean volume of neuronal nuclei in 4 to 8 year-old children was 43% less in autistic cohort than in the control group ($n = 4$; $p < 0.05$) while in the 4 to 56 years of age cohort, 20% deficit was insignificant. In autistic subjects increase in the volume of neuronal nuclei correlates with age ($r = 0.54$).

Globus pallidus. The mean volume of neuronal nuclei was 37% less in the autistic children from 4 to 8 years of age than in the control group ($n = 4$; $p < 0.02$). The difference in entire cohort (4 – 56 years of age) was insignificantly less (-12%). Weak tendency to increased size of neurons is observed in the globus pallidus of autistic adults ($r = 0.2$)

Caudate nucleus. The volume of neuronal nuclei is less by 29% in the 4 to 8 years of age autistic children. The mean volume for 4-56 year old autistic subjects is comparable.

In autistic subjects the volume of neuronal nuclei does not change with age ($r = 0.04$).

Conclusions

1. Striatal circuitry shows signs of immaturity manifested with very significant growth delay of neurons in the 4 – 8 year old children.
2. There is correlation between the increasing volume of neurons and age is an indicator of maturation of neurons in late childhood and even into adulthood.
2. Developmental abnormalities in the caudate and globus pallidus may contribute to repetitive and stereotyped behaviors.
4. Developmental pathology in the reward circuitry, including n. accumbens, may enhance engagement in rituals and stereotyped behavior.

Functional consequences of delayed maturation of striatal networks

Nucleus accumbens is a brain center processing information concerning reward availability, value and context. This study revealed delayed development of neurons, not only in the n. accumbens, but also in amygdala projecting to nucleus accumbens, and structures translating reward related information in reward motivated motor function (globus pallidus and caudate-putamen). Results support the hypothesis that immature striatal network may contribute to repetitive and stereotypic behaviors in autism.

3. Contribution of thalamic developmental changes to the autistic phenotype.

The thalamus plays a fundamental role in cortex development and has traditionally been referred to as the sensory gateway of the cortex. The thalamus is a key component of the brain implicated in attention, memory, language, emotional processing, which are recognized areas of deficit in autism. MRI studies revealed significantly reduced mean thalamic volume in high functioning autistic subjects. These data indicate that the thalamus may contribute to the clinical signs of autism. However, at present, there is no neuropathological or morphometric evidence of thalamic involvement in autism.

Hypothesis. We assume that an examination of the thalamus may provide insight into autism as an information processing disorder, particularly with regard to:

- (a) developmental shaping of the cortex and subcortical structures architecture and
- (b) contributing to the development of a less functional connectivity and thus producing a less synchronized network.

Aim. The goal of this study is to determine whether the thalamus, in the early stage of brain maturation, is affected by neuronal developmental delay and whether this pathology persists during adulthood.

Volume of the thalamus. The mean volume of the thalamus was very similar in both autistic and control children 4 - 8 years of age (2,805 mm³ and 2,762 mm³, respectively) and almost identical in the entire cohort from 4 to 56 years of age – (2,990 mm³ in autistic and 2,982 mm³ in control subjects). Subtle increase in the volume of the thalamus in the cohort of autistic subjects is not significant ($r = 0.42$). The correlation between the volume of the thalamus and age in the control group is not significant ($r = 0.13$).

Number of neurons. The mean number of neurons in the thalamus of 11 autistic subjects from 4 to 56 years of age was insignificantly less (45 million) than in 11 control subjects from 4 to 52 years of age (48 million), respectively. The number of neurons does not significantly change with the age in the autistic subjects ($r = 0.28$). There is no correlation between the number of thalamic neurons and the age in control group ($r = -0.02$).

Volume of neuronal soma. The mean volume of neuronal soma in 4- to 8-year old children was 32% less in the autistic group (2,739 μm^3 ; $n = 4$) than in controls (4,056 μm^3 ; $n = 4$; $p < 0.001$) (Fig. 3)

The mean volume of neuronal soma in the examined autistic group, from 4 to 56 years of age, is also significantly less than in the control group ($p < 0.015$). Strong correlation between the increasing volume of neuronal body and age in the thalamus of autistic subjects from 4 to 56 years of age ($r = 0.92$; $n = 11$), reflects very severe delay of neuronal growth in the youngest children, and slow maturation during late childhood and adulthood. In the control cohort, the volume of neuronal body decreases slightly with age ($r = -$

.28).

Volume of neuronal nuclei. The mean volume of neuronal nuclei in 4 to 8-year-old children was 46% less in autistic children ($375 \mu\text{m}^3$; $n = 4$) than in the control group ($699 \mu\text{m}^3$; $n = 4$; $p < 0.001$). The mean volume of neuronal nuclei in examined autistic group from 4 to 56 years of age is also significantly less than in the control group ($p < 0.025$). Correlation between the volume of neuronal nuclei in the thalamus of autistic subjects and age ($r = 0.77$; $n = 11$) reflects delayed correction of the size of cell nucleus to level observed in the control group. In control subjects, the volume of cell nucleus show weak tendency to age associated decrease ($r = -0.44$).

Conclusions

1. The study of the thalamus in 11 autistic and 11 age-matched control subjects, from 4 to 56 years of age revealed that the volume of the thalamus and the number of neurons are comparable in both cohorts.
2. However, application of nucleator revealed a strikingly small volume of neuronal body (32% less than in control) and neuronal nucleus (46% less than in control) in the autistic children from 4 to 8 years of age.
3. In contrast to the control cohort, autistic subjects reveal significant correlation between the volume of neurons or neuronal nuclei and age ($r = 0.92$, $r = 0.77$, respectively). This suggests delayed maturation of neurons during late childhood and adulthood.
4. This study provides the first evidence that the thalamus may have a significant contribution to abnormal brain development and functional abnormalities observed in autism.

Fig. 1. Significant delay of neuronal growth within the amygdala (-28% in 4-8 year old autistic children) and in the entorhinal cortex (also -28% in 4-8 year old autistic subject), but no significant difference in size of neurons in four sectors of the cornu Ammonis

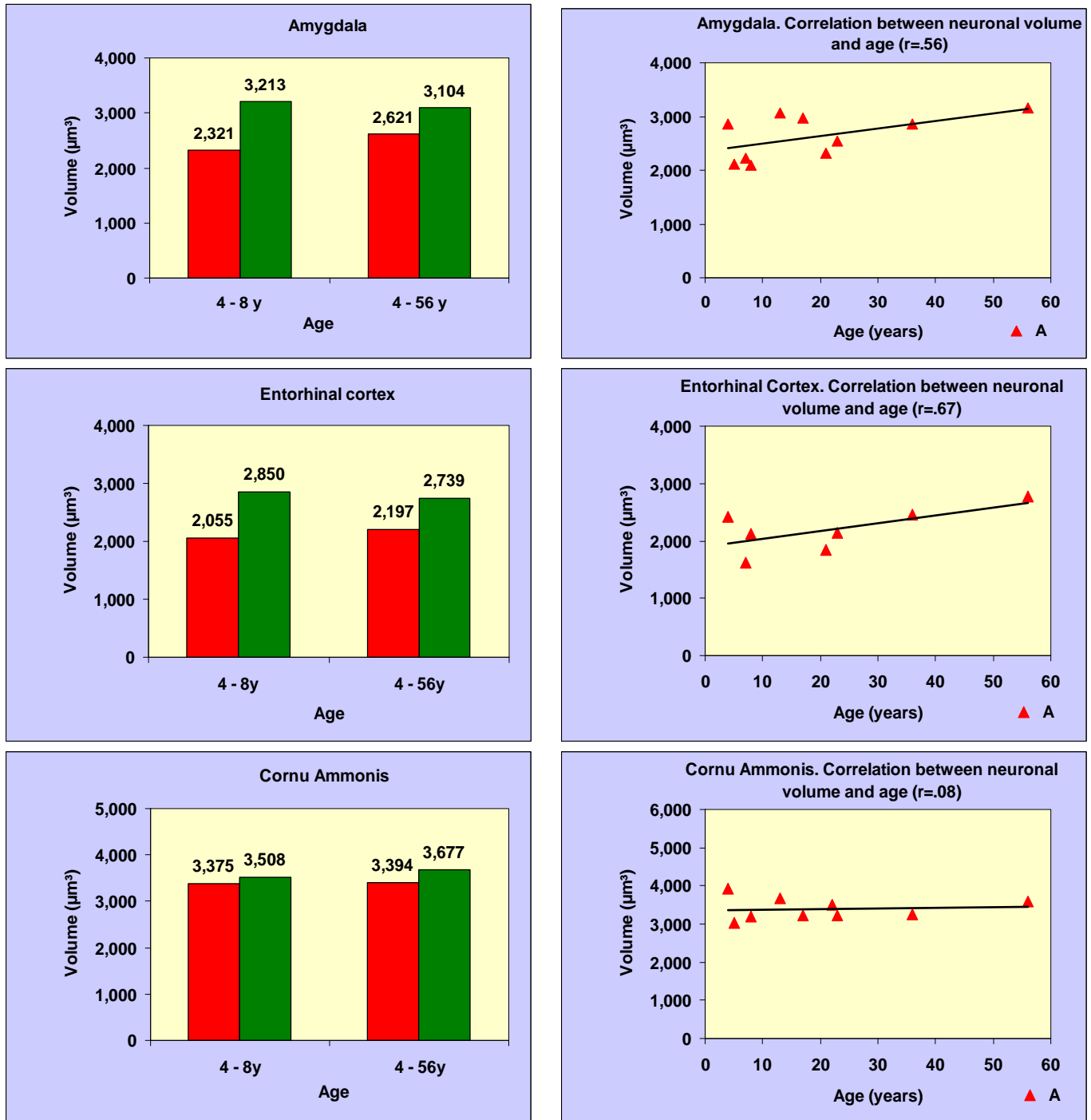


Fig. 2 The volume of neurons in the nucleus accumbens of 4 to 8 year old autistic subjects is reduced by 37% ($p < 0.03$). Caudate nucleus shows not significant reduction of neuronal volume (-12%), whereas neurons in the globus pallidus of autistic children are significantly smaller than in age-matched controls (-31%; $p < 0.02$).

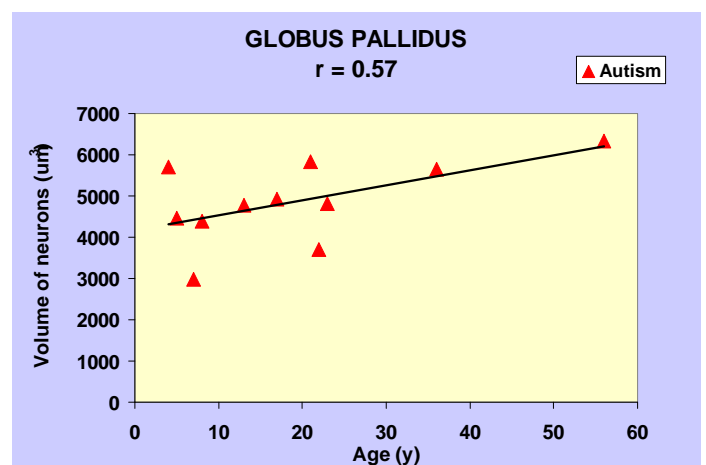
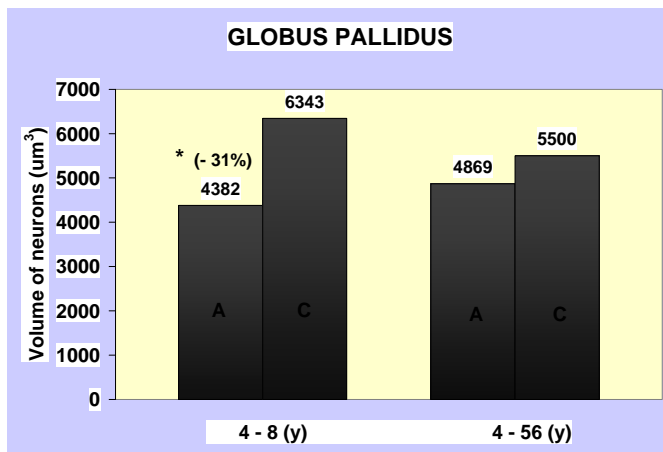
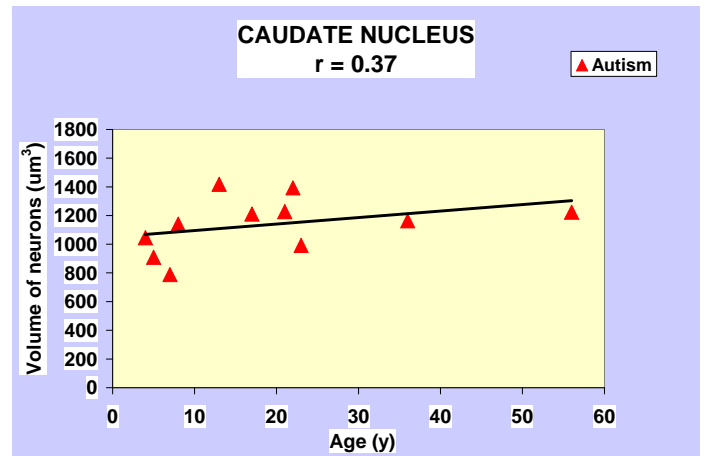
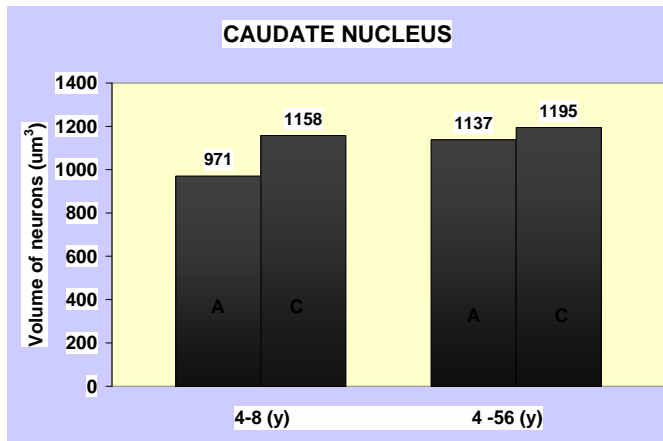
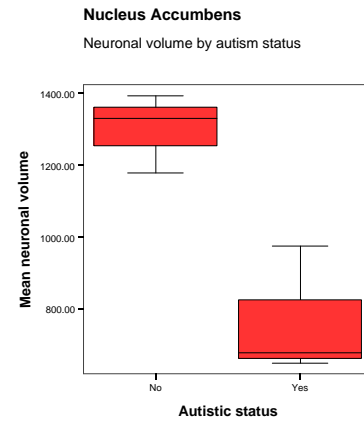
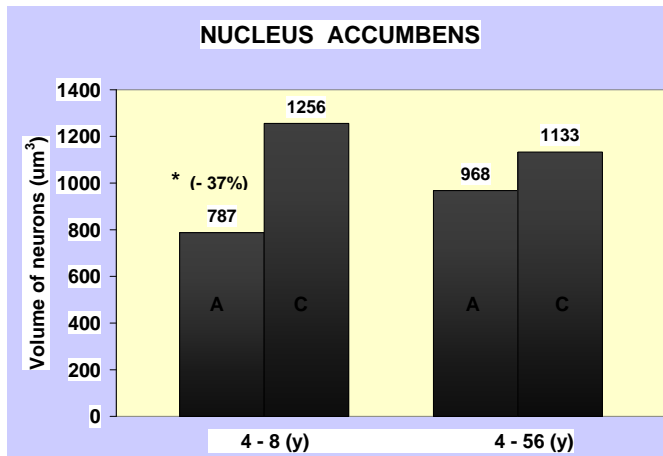
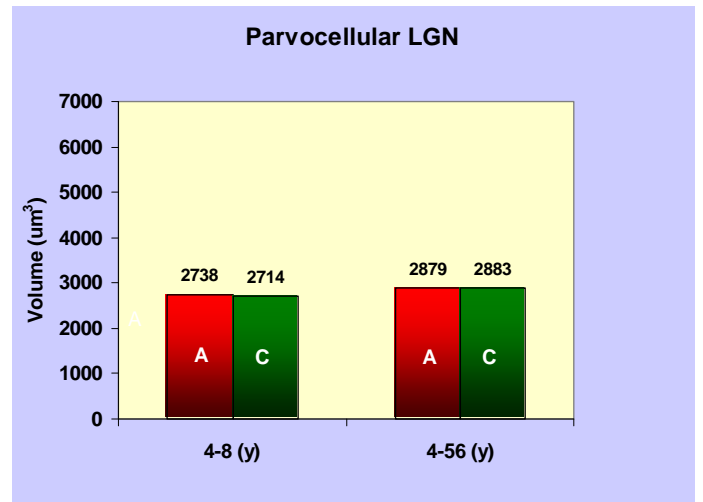
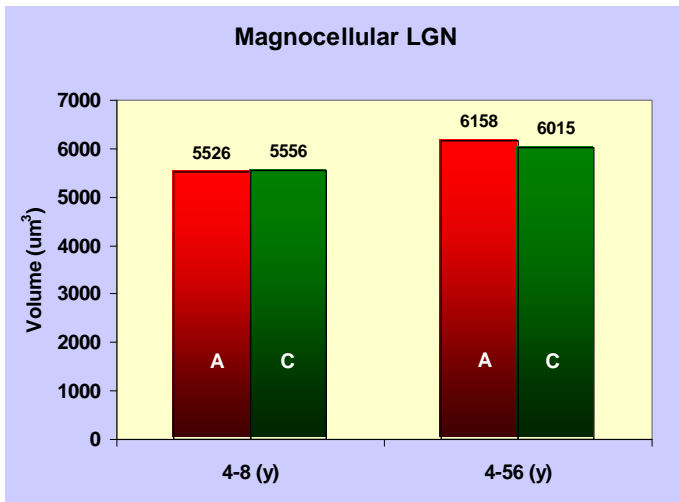
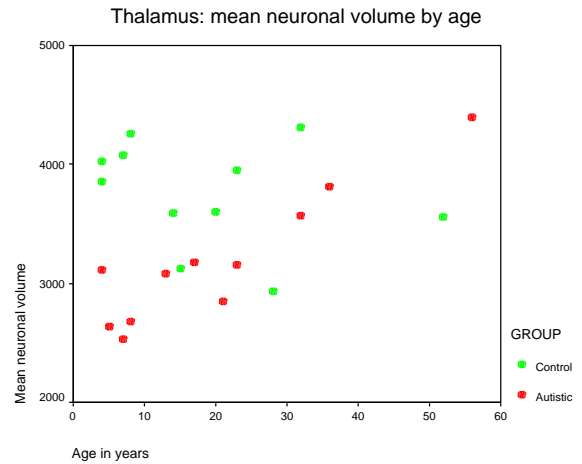
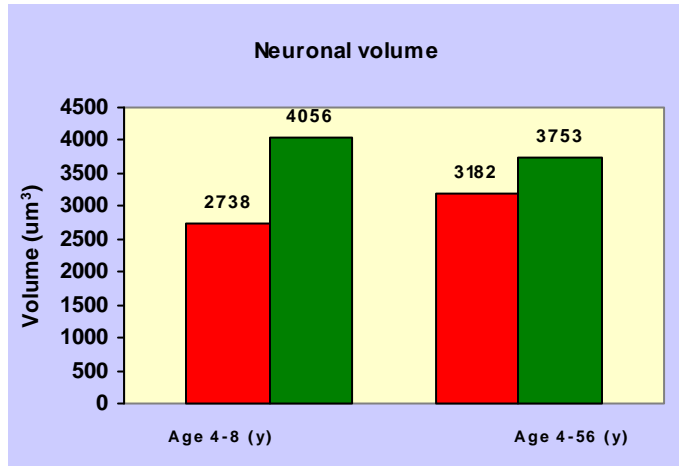


Fig. 3 The mean neuronal volume in the thalamus of 4 to 8 year old autistic subjects is reduced by 32% (upper left and right fig; $p < 0.001$). However, the volume of neurons in magno- and parvocellular part of the lateral geniculate nucleus, which is the part of thalamus, remains unchanged in autistic children.



KEY RESEARCH ACCOMPLISHMENTS

Our studies of the thalamus, striatum, entorhinal cortex and amygdala indicate that:

(a) developmental delay of neuron growth is the most consistent pathology observed in 4 to 8 year old autistic children, and

(b) in late childhood and adulthood, the difference between volume of neurons of autistic and control subjects is significantly reduced or is not detected.

These data suggest desynchronization of neuronal development and maturation in limbic, and striatal system, and in the thalamus, and delayed maturation of neurons in many but not all examined brain regions.

One may assume that factors accelerating brain maturation in a very early stage of development (2 – 4 years) – including intensive behavioral training – may contribute to structural and functional improvement.

The key research accomplishment is determination of the type and the role of focal developmental alterations, and secondly the type and the role of global pattern of desynchronization of neuronal networks development in autism.

Focal alterations: The neuropathological study leads to the conclusion that a broad spectrum of local changes with significant interindividual differences expands the spectrum of clinical phenotypes but is not the core pathology shaping the three major functional domains of autism.

Global alterations: Morphometric study of 22 brain subdivisions leads to the conclusion that desynchronization of brain development with delay of neuronal growth in the subcortical structures and archicortex in early childhood (4-8 years) is the core pathology shaping the three major functional domains of autism.

REPORTABLE OUTCOMES

1. The neurobiological and neuropathological background of this Program Project is summarized in our book chapter (will be published in October 2009; see Appendices):

Wegiel J, Wisniewski T, Chauhan A, Chauhan V, Kuchna I, Nowicki K, Imaki H, Wegiel J, Ma SY, Wierzba Bobrowicz T, Cohen IL, London E, Brown WT (2009) Type, topography and sequelae of neuropathological changes shaping clinical phenotype of autism. In: Autism: Oxidative Stress, Inflammation, and Immune Abnormalities. Ed.: Abha Chauhan, Ved Chauhan and W. Ted Brown. Taylor & Francis/CRC Press, Boca Raton, FL.

2. Results of neuropathological evaluation of brains of 13 autistic and 14 control subjects are summarized in a manuscript ready for submission to Acta Neuropathologica (see Appendices):

Wegiel J, Kuchna I, Nowicki K, Imaki H, Wegiel J, Marchi E, Ma SY, Chauhan A, Chauhan V, Wierzba Bobrowicz T, de Leon M, Saint Louis LA, Cohen IL, London E,

Brown WT, Wisniewski T. The Neuropathology of autism: defects of neurogenesis, neuronal migration and dysplastic changes in autism.

3. Two oral presentations. 8th Annual International Meeting for Autism Research, Chicago, IL; May 7-9, 2009)

Brown WT, Wisniewski T, Cohen I, London E, Flory M, Kuchna I, Nowicki K, Wegiel J, Ma SY, Imaki H, Wegiel J. Potential contributions of developmental and epilepsy-associated neuropathological changes to sudden, unexpected death in four people with chromosome 15 duplication and autism

Wegiel J, Kuchna I, Nowicki K, Wegiel J, Ma SY, Wisniewski T, Cohen IL, London E, Flory M, Brown WT. Emerging patterns of neuronal growth desynchronization in autism.

4. Three posters. 8th Annual International Meeting for Autism Research, Chicago, IL; May 7-9, 2009)

Nowicki K, Kuchna I, Wegiel J, Ma SY, Wisniewski T, Cohen IL, London E, Flory M, Brown WT, Wegiel J. Delayed development of neurons in networks involved with stereotypic behaviors and reward in autism.

Kuchna I, Nowicki K, Wegiel J, Ma SY, Wisniewski T, Cohen IL, London E, Flory M, Brown WT, Wegiel J. Developmental heterochronicity of neuron growth in the memory system of autistic subjects.

Ma SY, Kuchna I, Nowicki K, Wegiel J, Wisniewski T, Cohen IL, London E, Flory M, Brown WT, Wegiel J. Contribution of thalamic developmental changes to the autistic phenotype.

CONCLUSIONS:

The power of this Program Project is based on methodological and conceptual integration of three projects. The first year of study indicates that each project detects new components of developmental defects in the same autistic and control cohort and that integration of the results generates a new view on developmental alterations contributing to different components of the autistic clinical phenotype.

A. Maximization of qualitative neuropathological changes detection by examination of serial hemispheric sections results in evidence that:

1. developmental alterations are present in the brain of 12 (92%) autistic subjects and in the brain of one (7%) control subject.
2. developmental abnormalities represent a spectrum of pathology with significant interindividual differences.
3. subependymal nodular dysplasia (one case), and thickening of the subependymal germinal matrix (two cases), are the evidence of abnormal neurogenesis present in two (14%) autistic subjects.

4. subcortical and periventricular heterotopias are the evidence of focal deregulation of neuronal migration in 4 (28%) autistic subjects.
5. the most common form of developmental changes was dysplasia observed in 11 (85%) of the autistic subjects and reflecting focal abnormal cytoarchitecture.

The neuropathological study leads to the conclusion that a broad spectrum of local changes with significant interindividual differences expands the spectrum of clinical phenotypes but is not the core pathology shaping the three major functional domains of autism.

B. Maximization of quantitative neuropathological change detection by examination of 22 brain structures/subdivisions using unbiased morphometric methods results in an evidence that:

1. Autism is associated with profound global desynchronization of neuronal growth within the developing brain reflected in:
 - unchanged trajectory of neuronal development within the cornu Ammonis (memory system) and in the lateral geniculate nucleus (visual system);
 - moderate delay of neuronal growth within putamen (neurons smaller by 17%), caudate (-16%) and in the cerebellar dentate nucleus (-19%).
 - very significant delay of neuronal growth in the n. accumbens (-37%), thalamus (-33%), reduced volume of Purkinje cells (-32%), globus pallidus (-31%), amygdala (-28%), the entorhinal cortex (-28%).
2. Desynchronization is also detectable within the anatomically and functionally closely related structures:
 - thalamus shows 33% reduction in neuronal size in autistic subjects, however lateral geniculate nucleus which is the part of thalamus does not shows developmental delay.
 - two parts of the limbic system area affected by similar developmental delay: amygdala (-28%), entorhinal cortex (-28%), but developmental delay in the cornu components of Ammonis is undetectable.
 - Two striatal subdivisions striatum show moderate delay of neuronal growth (caudate, -16%; putamen, -17%), and two show very significant delay (n. accumbens, -37%; globus pallidus, -31%).
3. Developmental delay of neuronal growth and related neuronal networks may have a significant contribution to the main functional anomalies observed in autism:
 - developmental delay in the striatal circuitry may contribute to repetitive and stereotyped behaviors. Developmental changes in the nucleus accumbens may enhance engagement in ritual and stereotyped behavior.
 - verbal and nonverbal communication deficits, sensory abnormalities, skeletal muscle hypotonia, and intellectual deficits could be result of developmental abnormalities in the thalamus.
 - selective preservation of the developmental pattern of neurons in the cornu Ammonis involved in storage of information but delayed growth in the entorhinal cortex processing neocortical input may contribute to memory abnormalities mixed with restricted interests and abilities.

- developmental delay of neuron in the putamen and caudate may contribute to repetitive behaviors, whereas changes in the dentate nucleus may affect motor function.

Morphometric study of leads to the conclusion that desynchronization of brain development with delay of neuronal growth in early childhood is the core pathology shaping the three major functional domains of autism.

-

REFERENCES

- Bauman, M. L. and T. L. Kemper. 1985. Histoanatomic observations of the brain in early infantile autism. *Neurology* 35:866-867.
- Bauman, M. L., P. A. Filipek, and T. L. Kemper. 1997. Early infantile autism. *Int. Rev. Neurobiol.* 41:367-386.
- Casanova M F, Buxhoeveden DP, Switala AE, Roy E (2002) Minicolumnar pathology in autism. *Neurology* 58:428-432
- Casanova M F, van Kooten I AE, Switala E H, et al (2006) Minicolumnar abnormalities in autism. *Acta Neuropathol* 112:287-303
- Gabriels, R. L., M. L. Cuccaro, D. E. Hill, B. J. Ivers, and E. Goldson. 2005. Repetitive behaviors in autism: relationships with associated clinical features. *Res. Dev. Disabil.* 26:169-181.
- Herbert, M. R., D. A. Ziegler, C. K. Deutsch, L. M. O'Brien, N. Lange, A. Bakardjiev, J. Hodgson, K. T. Adrien, S. Steele, N. Makris, D. Kennedy, G. J. Harris, and V. S. Caviness, Jr. 2003. Dissociations of cerebral cortex, subcortical and cerebral white matter volumes in autistic boys. *Brain* 126:1182-1192.
- Hollander, E., E. Anagnostou, W. Chaplin, K. Esposito, M. M. Haznedar, E. Licalzi, S. Wasserman, L. Soorya, and M. Buchsbaum. 2005. Striatal volume on magnetic resonance imaging and repetitive behaviors in autism. *Biol. Psychiatry* 58:226-232.
- Langen, M., S. Durston, W. G. Staal, S. J. Palmen, and E. H. van. 2007. Caudate nucleus is enlarged in high-functioning medication-naive subjects with autism. *Biol. Psychiatry* 62:262-266.
- Lord, C., S. Risi, L. Lambrecht, E. H. Cook, Jr., B. L. Leventhal, P. C. DiLavore, A. Pickles, and M. Rutter. 2000. The autism diagnostic observation schedule-generic: a standard measure of social and communication deficits associated with the spectrum of autism. *J. Autism Dev. Disord.* 30:205-223.
- Palmen, S. J., E. H. van, P. R. Hof, and C. Schmitz. 2004. Neuropathological findings in autism. *Brain* 127:2572-2583.

Rapin, I. 1996. Preschool children with inadequate communication: developmental language disorder, autism, low IQ. UK, MacKeith Press, London.

Sears, L. L., C. Vest, S. Mohamed, J. Bailey, B. J. Ranson, and J. Piven. 1999. An MRI study of the basal ganglia in autism. *Prog. Neuropsychopharmacol. Biol. Psychiatry* 23:613-624.

Wegiel J, Wisniewski T, Chauhan A, et al (2009) Type, topography and sequelae of neuropathological changes shaping clinical phenotype of autism. In: Autism: Oxidative Stress, Inflammation, and Immune Abnormalities. Ed.: Abha Chauhan, Ved Chauhan and W. Ted Brown. Taylor & Francis/CRC Press, Boca Raton, FL

APPENDICES

Appendix 1

Wegiel J, Wisniewski T, Chauhan A, Chauhan V, Kuchna I, Nowicki K, Imaki H, Wegiel J, Ma SY, Wierzba Bobrowicz T, Cohen IL, London E, Brown WT (2009) **Type, topography and sequelae of neuropathological changes shaping clinical phenotype of autism.** Chapter in: Autism: Oxidative Stress, Inflammation, and Immune Abnormalities. Ed.: Abha Chauhan, Ved Chauhan and W. Ted Brown. Taylor & Francis/CRC Press, Boca Raton, FL.

Appendix 2

Wegiel J, Kuchna I, Nowicki K, Imaki H, Wegiel J, Marchi E, Ma SY, Chauhan A, Chauhan V, Wierzba Bobrowicz T, de Leon M, Saint Louis LA, Cohen IL, London E, Brown WT, Wisniewski T. **Defects of neurogenesis, neuronal migration and dysplastic changes in autism.** (Manuscript ready for submission to Acta Neuropathologica)

Appendix 3

Abstracts of five presentations: 8th Annual International Meeting for Autism Research, Chicago, IL; May 7-9, 2009

1. Brown WT, Wisniewski T, Cohen I, London E, Flory M, Kuchna I, Nowicki K, Wegiel J, Ma SY, Imaki H, Wegiel J. Potential contributions of developmental and epilepsy-associated neuropathological changes to sudden, unexpected death in four people with chromosome 15 duplication and autism
2. Wegiel J, Kuchna I, Nowicki K, Wegiel J, Ma SY, Wisniewski T, Cohen IL, London E, Flory M, Brown WT. Emerging patterns of neuronal growth desynchronization in autism.

3. Nowicki K, Kuchna I, Wegiel J, Ma SY, Wisniewski T, Cohen IL, London E, Flory M, Brown WT, Wegiel J. Delayed development of neurons in networks involved with stereotypic behaviors and reward in autism.
4. Kuchna I, Nowicki K, Wegiel J, Ma SY, Wisniewski T, Cohen IL, London E, Flory M, Brown WT, Wegiel J. Developmental heterochronicity of neuron growth in the memory system of autistic subjects.
5. Ma SY, Kuchna I, Nowicki K, Wegiel J, Wisniewski T, Cohen IL, London E, Flory M, Brown WT, Wegiel J. Contribution of thalamic developmental changes to the autistic phenotype.

1 Type, Topography, and Sequelae of Neuropathological Changes Shaping Clinical Phenotype of Autism

*Jerzy Wegiel, Thomas Wisniewski,
Abha Chauhan, Ved Chauhan, Izabela Kuchna,
Krzysztof Nowicki, Humi Imaki, Jarek Wegiel,
Shuang Yong Ma, Teresa Wierzba Bobrowicz,
Ira L. Cohen, Eric London, and W. Ted Brown*

CONTENTS

1.1	Introduction.....	2
1.2	Clinical, Etiological, and Neuropathological Diversity in Autism.....	3
1.2.1	Clinic.....	3
1.2.2	Etiology.....	4
1.2.3	Neuropathology.....	4
1.3	Deregulation of Brain Growth in Early Childhood.....	5
1.3.1	Developmental Heterochronicity.....	7
1.3.2	Functional Consequences of Abnormal Brain Development.....	8
1.4	Cortical and Subcortical Neuropathology.....	8
1.4.1	Cortical Dysgenesis, Lamination Defects, Migration Disturbances.....	8
1.4.2	Brain Structure–Specific Delay of Neuronal Growth.....	9
1.4.3	Minicolumnar Abnormalities in Autism.....	9
1.5	Neuronal Oxidative Stress and Metabolic Changes.....	10
1.5.1	Oxidative Stress in Autism.....	10
1.5.2	Lipofuscin in Autism.....	11



2	Autism: Oxidative Stress, Inflammation and Immune Abnormalities	
1.5.3	β -Amyloid Precursor Protein and Intraneuronal Amyloid β in Autism	11
1.6	Clinicopathological Correlations	12
1.6.1	Speech, Language, and Verbal and Nonverbal Communication.....	12
1.6.2	Face Perception.....	13
1.6.3	Social Attachment—The Role of the Hypothalamus in Behavioral Deficits	14
1.6.4	Sensorimotor Deficits, and Repetitive and Stereotyped Behaviors	15
1.6.5	Cognitive Deficits.....	16
1.6.6	Epilepsy-Associated Pathology.....	17
1.7	Mechanisms Affecting Brain Development.....	18
1.7.1	BDNF and Neurotrophins in Autism.....	18
1.7.2	Brain Stem and the Role of Serotonin in Brain Development and Clinical Features of Autism.....	19
1.8	Closing Remarks.....	20
	Acknowledgments.....	20
	References.....	20

1.1 INTRODUCTION

The aim of this chapter is to identify the type, topography, and sequelae of neuropathological changes that contribute to the clinical phenotype of autism. Results of recent magnetic resonance imaging (MRI) and postmortem neuropathological and stereological studies of autism brain suggest a dynamic model of sequential subdivision of age- and brain-specific structural and functional changes. Acceleration of brain growth in the first year of life and deceleration in the second and third years appear to play a pivotal role in the onset of clinical signs of autism (Courchesne et al., 2001, 2003; Courchesne and Pierce, 2005b; Dawson et al., 2007; Dementieva et al., 2005; Gillberg and de Souza, 2002; Redcay and Courchesne, 2005). The range of deviation from the normal trajectory of brain growth may be a factor determining the severity of the disease (Courchesne et al., 2003). Developmental heterochronicity (differential rates of growth of various brain regions compared to controls), resulting in selective overgrowth of some brain regions, appears to be a key factor determining topography and brain region-specific type of cytoarchitectonic changes (Carper and Courchesne, 2005; Carper et al., 2002; Courchesne et al., 2001; Hazlett et al., 2005; Sparks et al., 2002). Topographic developmental heterochronicity may result in impairment of both local and global connectivity, leading to local overconnectivity and impairment of long-distance connectivity (Baron-Cohen, 2004; Casanova et al., 2006; Courchesne and Pierce, 2005a). Stereological studies have revealed neuronal developmental heterochronicity in early childhood, resulting in selective developmental delay of the growth of neurons in some subcortical structures and the cerebellum during the most critical stage of development of social behaviors and communication skills (Wegiel et al., 2008). Distortions of brain and neuronal development are reflected in abnormal



cortical minicolumn organization (Casanova et al., 2002, 2006), local dysgenesis, and ectopias (Bauman and Kemper, 1985; Bauman et al., 1997; Kemper and Bauman, 1993, 1998). These complex developmental abnormalities appear to lay the foundation for secondary and tertiary metabolic, structural, and functional changes, including seizures and risk of sudden unexpected death; signs of oxidative stress, early and enhanced accumulation of products of cell organelle degradation with lipofuscin deposition; modified processing of β -amyloid precursor protein with accumulation of truncated amyloid beta; and other as of yet unidentified changes. Secondary pathologic changes appear to be indicators of the susceptibility of abnormally developing neurons to further modifications during cell maturation and aging. The pattern of morphological changes emerging from these multidisciplinary studies appears to represent a major trend. However, modifications of the course of disease and sub-patterns of developmental changes result in a broad spectrum of morphological and clinical interindividual differences.

1.2 CLINICAL, ETIOLOGICAL, AND NEUROPATHOLOGICAL DIVERSITY IN AUTISM

Autism is the prototype of a pervasive developmental disorder (PDD) and is characterized by (a) qualitative impairments in reciprocal social interactions, (b) qualitative impairments in verbal and nonverbal communication, (c) restricted repetitive and stereotyped patterns of behavior, interests, and activities, and (d) onset prior to the age of 3 years. PDD also includes childhood disintegrative disorder, Asperger's disorder, Rett syndrome, and pervasive developmental disorder—not otherwise specified (PDD-NOS). The common features of all these disorders are qualitative deficits in social behavior and communication (American Psychiatric Association, 2000).

1.2.1 CLINIC

AQ2 In most cases (90%–95%), it is not presently possible to detect a known or specific etiology. These cases are referred to as idiopathic or nonsyndromic autism (Boddaert et al., 2009; Gillberg and Coleman, 1996). In 6% (Fombonne, 2003), 5% (Tuchman et al., 1991), or 10% (Rutter et al., 1994) of cases, autism was diagnosed in association with other disorders. About 30% of children with idiopathic autism have complex autism, defined by the presence of dysmorphic features, microcephaly and/or a structural brain malformation (Miles et al., 2005). About 70% of children with autism have essential autism, defined by the absence of physical abnormalities. For most children, the onset of autism is gradual. However, a multisite study revealed significant regression at ages of 18 to 33 months (regressive autism) in about 13.8% (Colorado) to 31.6% (Utah) of autistic subjects (Department of Health and Human Services, 2007). Moreover, the manifestations of autism vary greatly, depending on developmental level and chronological age of the affected individual. The majority of patients exhibit serious social and communicative impairments throughout life but some improve enough to be able to live relatively independently as adults. In 44.6% of children, autism is associated with cognitive impairment (defined as having intelligence quotient scores of <70; Department of Health and Human Services, 2007). Expressive language function in

individuals with autism may vary from mutism to verbal fluency (Rapin, 1996; Stone et al., 1997; Wetherby et al., 1998). Sensorimotor deficits also show significant interindividual differences, with more frequent and severe impairments of gross and fine motor function (motor stereotypes, hypotonia, limbic apraxia) in subjects with lower IQ (Rogers et al., 1996). Hand mannerisms and body rocking are reported in 37% to 95% of individuals with autism (Lord and Rutter, 1995; Rapin, 1996; Rogers et al., 1996), whereas preoccupation with sensory features of objects, abnormal responsiveness to environmental stimuli, or paradoxical responses to sensory stimuli are seen in 42% to 88% of people with autism (Kientz and Dunn, 1997). Epilepsy is a comorbid complication, occurring in up to 33% of individuals with autism (Tuchman and Rapin, 2002).

1.2.2 ETIOLOGY

The clinical diversity of autism reflects the etiologic heterogeneity of this disorder. Genetic factors; pre-, peri-, and postnatal pathological factors; and concurrent diseases may contribute to autism (Muhle et al., 2004; Newschaffer et al., 2002; Rutter et al., 1994). About 5% to 10% of cases are associated with several distinct genetic conditions including fragile X syndrome, tuberous sclerosis, phenylketonuria, Rett syndrome, and chromosomal anomalies such as Down syndrome (DS) (Folstein and Rosen-Scheidley, 2001; Fombonne, 2003; Smalley et al., 1988; Yonan et al., 2003). Autism spectrum disorders (ASDs) in people with DS have been described in several reports (Ghaziuddin et al., 1992; Howlin et al., 1995; Pracher and Clarke, 1996; Wakabayashi, 1979), and the prevalence of autism in boys with DS was estimated as at least 7% (Kent et al., 1999). The prevalence of autism in the fragile X syndrome is estimated as 15%–28% (Hagerman, 2002). Cytogenetic abnormalities (partial duplications, deletions, inversions) in the 15q11-q13 region account for 1% to 4% of autism cases (Cook, 1998; Gillberg, 1998). Several potential candidate genes have been identified in both autosomes and X chromosomes, including the tuberous sclerosis gene on chromosomes 9 and 16; serotonin transporter on chromosome 17; gamma-aminobutyric acid receptor-beta 3 on chromosome 15; neuroligins on the X chromosome (see Vorstman et al., 2006); and possibly *PTEN* on chromosome 10 (Butler et al., 2005). Modifications in the tryptophan hydroxylase gene may play a modest role in autism susceptibility (Coon et al., 2005).

1.2.3 NEUROPATHOLOGY

While knowledge of the clinical and genetic factors in autism is based on examination of thousands of patients, postmortem neuropathological studies are based on reports of a very small number of brains. A review by Palmen et al. (2004) revealed that between 1980 and 2003, only 58 brains of individuals with autism have been examined, and results of only a few neuropathological and stereological studies were published. Usually, neuropathological reports and morphometric reports were based on evaluation of one or several brains. Due to the broad age spectrum and the etiological and clinical diversity in autism, the pattern of neuropathological changes reported is incomplete and often inconsistent. As a result, the morphological markers and

neuropathological diagnostic criteria of autism have not yet been established (Lord et al., 2000; Pickett and London, 2005). In the past, the contribution of postmortem studies to the detection and characterization of neuropathological changes and mechanisms leading to structural and functional manifestations of autism was limited because of (a) the deficit of autism brains, resulting in a lack of statistical power, (b) the lack of efficient mechanisms for sharing the limited tissue resources, (c) the lack of complex studies of the dynamic of changes during the life span, (d) the infrequent application of unbiased morphometric methods to detect quantitative differences, and (e) the averaging of results from subjects with different clinical and morphological manifestations of autism. Heterogeneity within the autism spectrum is the major obstacle to autism research at all levels (Newschaffer et al., 2002), including neuropathological studies and attempts at detection of clinicopathological correlations. Recent evidence of genetic fractionation of social impairment, communication difficulties, and rigid and repetitive behaviors indicates that heterogeneity in ASD could be an unavoidable consequence of the contribution of nonoverlapping genes. If different features of autism are caused by different genes associated with different brain regions and related to different core cognitive impairments (Happé et al., 2006), it seems likely that many brain networks are involved in the pathology of autism. The diversity of neuropathological findings and the commonly reported inconsistencies in regional findings correspond to developmental impairments in many interacting brain networks and to expansion from “local” abnormalities to “nonlocal” effects of the emerging cognitive system. In spite of these limitations, “localizing” models are still the main approach to the identification of pathological changes as a component of the structural and functional abnormalities of the networks (Müller, 2007).

The possibility that autism is associated with neuropathological changes was explored in the first studies reported between 1980 and 1989 (Bauman and Kemper, 1985; Courchesne et al., 1987, 1988; Damasio et al., 1980; Gaffney et al., 1987; Hashimoto et al., 1989, 1993; Murakami et al., 1989; Ritvo et al., 1986). Expansion of these studies through examination of larger cohorts and application of stereology, functional and structural MRI, and biochemistry resulted in the identification of several major forms of pathology contributing to the clinical phenotype including abnormal acceleration of brain growth in early childhood (Redcay and Courchesne, 2005), delay of neuronal growth (Wegiel et al., 2008), changes in brain cytoarchitecture (Bailey et al., 1998; Bauman and Kemper, 1985; Casanova et al., 2002, 2006), metabolic modifications with abnormal amyloid precursor protein (APP) processing (Bailey et al., 2008; Brown et al., 2008; Sokol et al., 2006), enhanced oxidative stress (reviewed in Chauhan and Chauhan, 2006), and turnover of cell organelle with pigment accumulation and glial activation (Lopez-Hurtado and Prieto, 2008).

1.3 DEREGULATION OF BRAIN GROWTH IN EARLY CHILDHOOD

The major measures of age-related changes are head circumference, MRI-based volumetry of the brain and brain structures, and postmortem brain weight and volume of brain subdivisions. Between 1990 and 2000, several groups reported increased head circumference (Bailey et al., 1995; Bolton et al., 1995; Davidovitch et al., 1996;

Fidler et al., 2000; Fombonne et al., 1999; Lainhart et al., 1997; Miles et al., 2000; Steg and Rapoport, 1975; Stevenson et al., 1997), whereas MRI-based studies revealed increased brain volume (Piven et al., 1995, 1996). According to Fombonne et al. (1999), the prevalence of macrocephaly in autism is about 20%. In a report by Bailey et al. (1998), four of six subjects with autism 4 to 24 years of age had macrocephaly. Increased brain weight was reported in postmortem studies by Bailey et al. (1993) and Kemper and Bauman (1998). Increase in the volume was regional and not generalized, with the greatest enlargement in the occipital and parietal lobes (Filipek, 1996; Filipek et al., 1999; Piven et al., 1995, 1996). However, in several studies, an increase in brain size was not detected (Garber and Ritvo, 1992; Haznedar et al., 2000). Inconsistency in detection of abnormal head and brain size can be associated with interindividual differences, the age of examined individuals, and the methods applied. Courchesne et al. (2003) integrated their work and that of other researchers into the concept of four phases of modified brain growth, described below.

At birth, the head circumference of neonates later diagnosed with autism is normal or slightly less than that observed in normally developing children (Courchesne et al., 2003; Dawson et al., 2007; Dementieva et al., 2005; Dissanayake et al., 2006; Gillberg and de Souza, 2002; Hazlett et al., 2005; Lainhart et al., 1997; Mason-Brothers et al., 1990; Stevenson et al., 1997). Slight undergrowth is independent of body growth and may be a reflection of prenatal neural developmental defects corresponding to pathology detected in postmortem studies of the brains of autistic adults (Bailey et al., 1998; Casanova et al., 2002; Courchesne et al., 2003; Kemper and Bauman, 1998). In only 5% of neonates diagnosed later as autistic was the head circumference more than that in normally developing infants (Courchesne et al., 2003; Dementieva et al., 2005).

In the second phase, by 1 or 2 years of age, a rapid and large increase in head circumference distinguished children diagnosed later with autism from normally developing children (Courchesne et al., 2003; Dawson et al., 2007; Dementieva et al., 2005; Dissanayake et al., 2006; Hazlett et al., 2005). Ninety percent of 2- and 3-year-old children with autism had brain volumes larger than those of control children (Courchesne et al., 2001). According to Dawson et al. (2007), a period of exceptionally rapid head growth is limited to the first year of life, and head growth decelerates after 12 months of age. Acceleration of growth in head circumference appears to begin at about 4 months (Courchesne and Pierce, 2005a; Gillberg and de Souza, 2002; Redcay and Courchesne, 2005). Using meta-analysis based on evaluation of head circumference converted to brain volume, brain volume measured from MRI, and brain weight from postmortem studies, Redcay and Courchesne (2005) revealed that brain size increases from 13% smaller than in control subjects at birth to 10% larger than in control infants at 1 year, but only 2% greater by adolescence. The greater growth rate of head circumference in the first year, and its return to normal rates thereafter, is not accounted for by an overall growth in stature. Studies of behavioral development in infants later diagnosed with autism suggest that the period of acceleration of head growth precedes and overlaps with the onset of behavioral changes, and that the period of deceleration coincides with a period of behavioral decline or worsening of symptoms in the second year of life (Dawson et al., 2007). Coincidence of acceleration of brain growth rate with onset and

worsening of clinical symptoms may indicate that structural developmental changes critical for a lifelong phenotype occur in early infancy. Acceleration of brain growth in the first year and deceleration in the second year of life suggest that failure of the mechanism controlling brain growth in the first year of life plays an essential role in the onset of clinical features of autism. Identification of these mechanisms may lead to conceptualization of early preventive treatments.

In the third phase, of 2 to 4 years, the overall rate of brain growth slows but is still 10% more than in normally developing children (Carper et al., 2002; Courchesne et al., 2001; Hazlett et al., 2005; Sparks et al., 2002). In 4- to 5-year-old autistic children, MRI-based estimated brain volume is 1350 mL, whereas in normally developing children, a comparable volume (1360 mL) is reached about 8 years later. In post-mortem studies, the brain weight of 3- to 5-year-old autistic males was 15% higher (1451 g) than in control males of this age (1259 g) (Redcay and Courchesne, 2005).

In the fourth phase, the volume of the brain decreases, and this trend extends from middle/late childhood through adulthood. Head (Aylward et al., 2002) or brain enlargement (Bailey et al., 1998; Hardan et al., 2001; Lainhart et al., 1997; Piven et al., 1995, 1996) has also been observed in studies of older populations of autistic individuals. However, by adolescence and adulthood, the average size of the brain is only 1% to 3% greater in autistic than in control cohorts (Redcay and Courchesne, 2005).

Moreover, the pattern of brain growth reflects the severity of clinical manifestation of autism (Courchesne et al., 2003). Among infants who have the more severe form of autism, 71% showed increases during their first year of more than 1.5 S.D., with 59% showing increases between 2.0 and 4.3 S.D. In children with a less severe form of autism, PDD-NOS, acceleration of brain growth is observed later, and the increase is less pronounced. Later onset and slower rate of progression of autism appear to be associated with a better outcome.

1.3.1 DEVELOPMENTAL HETEROCHRONICITY

Developmental heterochronicity studies indicate that autism is a disorder involving a transient period of pathological acceleration of brain growth. Developmental heterochronicity, with different rates of growth for different brain regions/structures, appears to be the second major factor contributing to the clinical phenotype. MRI studies showed that overgrowth of the frontal and temporal lobes and amygdala, brain regions that are involved in cognitive, social, and emotional functions as well as language development, is synchronized with brain overgrowth in 2- to 4-year-old autistic children in contrast to a different rate of growth of the occipital cortex (Carper and Courchesne, 2005; Carper et al., 2002; Courchesne et al., 2001; Hazlett et al., 2005; Sparks et al., 2002). The reduced size of the body and posterior subregions of the corpus callosum noted in subjects with autism may indicate disproportions in brain subregions development (Piven et al., 1997b). The cellular and molecular basis for transient acceleration of brain growth and enhanced growth of some brain regions is not known, but Courchesne et al. (2003) proposed that the observed pattern is associated with an excessive number of neurons, enhanced rate of growth of size of neurons, and increased number of minicolumns as well as excessive and premature expansion of the dendritic tree.

1.3.2 FUNCTIONAL CONSEQUENCES OF ABNORMAL BRAIN DEVELOPMENT

Using a computational model analogue of autism, Cohen (2007) has argued that an interaction between stochastic and above-average or “excessive” numbers of neural connection factors has implications for understanding the disorder. In particular, a relative excess of connections could lead to enhanced recognition of complex patterns in the environment. In Cohen’s chapter, it was noted that if large and complex brains are in part familial (Courchesne et al., 2003; Fidler et al., 2000), and brain size is heritable (Pfefferbaum et al., 2000) and positively correlated with IQ (Pennington et al., 2000), then behavioral outcomes both within and across generations of family members could result in (a) individuals who may be unusually gifted in their ability to handle complex nonlinear problems such as mathematics or computer science, (b) individuals with autism, or (c) individuals with a combination of autism or autistic-like behavior and giftedness (many typical Asperger’s cases). These trends are detected among relatives of subjects with autism (Folstein and Rutter, 1988).

The effect of an abnormal trajectory of brain development observed in autism are well-validated characteristics of the learning style of children with autism, including (a) greater attention to idiosyncratic than socially relevant stimuli, (b) stimulus overselectivity or a lack of drive for central coherence, (c) problems with acquiring fuzzy concepts, (d) development of savant skills, (e) problems with generalization of previously acquired skills, (f) rigidity and resistance to change, (g) social and communication deficits, and (h) difficulty in learning complex higher-order concepts (Cohen, 2007).

1.4 CORTICAL AND SUBCORTICAL NEUROPATHOLOGY

1.4.1 CORTICAL DYSGENESIS, LAMINATION DEFECTS, MIGRATION DISTURBANCES

The fundamental characteristics of the neuropathological changes described by Kemper and Bauman (1993, 1998), Bauman and Kemper (1985, 1996), and Bauman et al. (1997) suggest three major neuropathologies in the brain of people with autism: (a) curtailed development of neurons in the structures that are substrates for memory and emotions—the entorhinal cortex, hippocampus, subiculum, anterior cingulate gyrus and mamillary body; (b) a congenital decrease in the number of Purkinje cells in the cerebellum; and (c) age-related differences in cell size and number of neurons in the cerebellar nuclei and in the inferior olivary nucleus. Microdysgenesis is represented by increased neuronal density in the cortical layer, clustering of cortical neurons, disorganization of cortical layers, neuron cytomegaly, ectopic neurons, and nodular heterotopias. A detailed study of serial sections from the brain of a 29-year-old man with autism revealed reduced neuronal size and increased cell-packing density (Bauman and Kemper, 1985), both features of an immature brain (Friede, 1975). Cell-packing density was increased by 66% in the hypothalamus and mamillary body, and by 54% in the medial septal nucleus, with smaller nerve cells. The reduced size of neurons and the selective increase in cell-packing density were seen in central (40%), medial (28%), and cortical nuclei (35%). Atrophy of the neocerebellar cortex, with marked loss of Purkinje cells and, to a lesser extent, of granule cells, was present in gracile, tonsil, and inferior semilunar lobules. Changes were not detected in

the anterior lobe or the vermis. Reduced numbers of cells were noticed in fastigial, globose, and emboliform nuclei, and cells were small and pale. The dentate nucleus was distorted. Retrograde neuronal loss in the inferior olive related to neuronal loss in cerebellar cortex was not found, but olivary neurons were small and pale. Brain cytoarchitecture abnormalities were not associated with gliosis. In a 21-year-old female with autism, Rodier et al. (1996) found that the brain was smaller than a control brain, and the length of facial nerve nucleus was less than 500 μm as compared to 2610 μm in the control subject.

1.4.2 BRAIN STRUCTURE–SPECIFIC DELAY OF NEURONAL GROWTH

The reduced size of neurons and their nuclei in the cortex of autistic subjects reported by Casanova et al. (2006) could be an indicator of reduced or impaired functional connectivity between distant cortical regions (Casanova et al., 2006; Just et al., 2004; Koshino et al., 2005). Our ongoing studies of series of brains from age-matched autistic and control subjects (Wegiel et al., 2008) indicate that reduced size of neurons is a brain structure–specific marker. In 4- to 7-year-old autistic children, Purkinje cells were smaller by 38%. Neurons in the dentate nucleus were reduced by 26%; in the amygdala, by 24%; in the nucleus accumbens, by 41%; in caudate, by 20%; and in the putamen, by 27%. Neurons in the nucleus of the facial nerve and the nucleus olivaris did not show a significant difference from controls. The second significant feature of the pattern of neuronal size abnormalities is the partial or complete correction of the size of neurons (for example, in the nucleus accumbens) observed in late childhood or adulthood. This study indicates that the delay of growth of neurons is the most consistent pathology detected in the brains of examined people with autism. Pathology is brain structure–specific. Changes may range from no delay to severe developmental delay. The youngest examined children (4 to 7 years old) show the most severe deficit in the volume of the neuronal body and nucleus. Partial correction of cell volume is observed in late childhood and adulthood, which indicates that brain structure and function undergo modifications during the life span. The study of basal ganglia and cerebellum supports the hypothesis that clinical manifestations of autism are the result of regional neuronal maldevelopment.

One may assume that mechanisms regulating growth of the neuron in early childhood are the target of factors that are the cause of autism. The result of deregulation of these mechanisms could be (a) significantly delayed growth of neuronal body, nucleus, dendritic tree, spines, and reduced number of synapses and (b) functional deficits corresponding to these structural developmental delays. These abnormalities of very early childhood might be the major contributor to clinical deficits that are the basis for the clinical diagnosis of autism at the age of 3 years.

1.4.3 MINICOLUMNAR ABNORMALITIES IN AUTISM

The next significant contribution to detection of neocortical developmental pathology is the result of studies of minicolumns by Casanova's group (Buxhoeveden and Casanova, 2002; Casanova et al., 2002, 2006). Malformations of cortical development are observed in heterogeneous disorders caused by abnormalities of cell

proliferation, apoptosis, cell migration, cortical organization, and axon pathfinding (Hevner, 2007). Clinically malformations of cortical development are significant causes of mental retardation, seizures, cerebral palsy, and neuropsychiatric disorders (Barkovich et al., 2005; Guerrini and Marini, 2006; Sarnat and Flores-Sarnat, 2004). Minicolumns are considered a basic architectonic and functional unit of the human neocortex (Buxhoeveden and Casanova, 2002; Casanova et al., 2002). Increased neuron density by 23%, reduced size of neurons in minicolumns, and a concomitant increase in the total number of minicolumns appears to illustrate the bias of local rather than global information processing (Casanova et al., 2002, 2006), resulting in a “hyper-specific brain” (McClelland, 2000). Synchronization of interactions requiring the involvement of distant brain regions is impaired in autism as a result of developmental connectivity deficits (underconnectivity) of smaller neurons (Just et al., 2004; Koshino et al., 2005; Zilbovicius et al., 1995). Structural imaging studies also suggest the overrepresentation of short association fibers in autism, with a regional increase in the volume of white matter (Herbert et al., 2004) favoring the local information processing observed in autistic subjects (Happé, 1999).

1.5 NEURONAL OXIDATIVE STRESS AND METABOLIC CHANGES

An increasing body of evidence suggests that the abnormal rate of development of neurons and neuronal networks in early infancy is followed by metabolic changes, with signs of oxidative stress, enhanced autophagocytosis, and lipofuscin accumulation, leading to early selective neuronal structural and functional changes.

1.5.1 OXIDATIVE STRESS IN AUTISM

Oxidative stress is known to be associated with premature aging of cells and can lead to inflammation, damaged cell membranes, autoimmunity, and cell death. The brain is highly vulnerable to oxidative stress due to its limited antioxidant capacity, higher energy requirement, and high amounts of unsaturated lipids and iron (Juurlink and Peterson, 1998). The brain makes up about 2% of body mass but consumes 20% of metabolic oxygen. The vast majority of energy is used by the neurons (Shulman et al., 2004). Glutathione (GSH) is the most important antioxidant for detoxification and elimination of environmental toxins. Due to the lack of glutathione-producing capacity by neurons, the brain has a limited capacity to detoxify reactive oxygen species (ROS). Therefore, neurons are the first cells to be affected by the increase in ROS and shortage of antioxidants and, as a result, they are most susceptible to oxidative stress. Antioxidants are required for neuronal survival during the early critical period (Perry et al., 2004). Children are more vulnerable than adults to oxidative stress because of their naturally low glutathione levels from conception through infancy (Erden-Inal et al., 2002; Ono et al., 2001). The risk created by this natural deficit in detoxification capacity in infants is increased by the fact that some environmental factors that induce oxidative stress are found at higher concentrations in developing infants than in their mothers, and accumulate in the placenta.

Accumulating evidence from our and other groups suggests increased oxidative stress in autism (reviewed in Chauhan and Chauhan, 2006). Lipid peroxidation is a chain reaction between polyunsaturated fatty acids and ROS, producing lipid peroxides

and hydrocarbon polymers that are both highly toxic to the cell. We have reported that levels of malondialdehyde (MDA), a marker of lipid peroxidation, are increased in the plasma from children with autism (Chauhan et al., 2004). Other studies on erythrocytes (Zoroglu et al., 2004) and urine samples (Ming et al., 2005) have also indicated increased levels of lipid peroxidation markers in autism, thus confirming an increased oxidative stress in autism. Recent studies with the postmortem brain samples from autism and control subjects have provided further evidence on increased oxidative stress in autism. Increased levels of lipid-derived oxidative protein modifications, i.e., carboxyethylpyrrole and iso[4]levuglandin E₂-protein adducts, and heme-oxygenase-1 (an inducible antioxidant enzyme) have been reported in the autistic brain, primarily in the white matter (Evans et al., 2008). Sajdel-Sulkowska et al. (2008) have reported elevated levels of 3-nitrotyrosine (a specific marker for oxidative damage to proteins) in the cerebella of subjects with autism. In addition, we have observed increased lipid peroxidation in cerebellum and temporal cortex of brain in autism (Chauhan et al., 2009). MDA levels were significantly increased by 124% in the cerebellum, and by 256% in the temporal cortex in autism as compared to control subjects.

1.5.2 LIPOFUSCIN IN AUTISM

Lopez-Hurtado and Prieto (2008) revealed a significant increase in the number of lipofuscin-containing cells in the brain of 7- to 14-year-old autistic subjects (by 69% in area 22, 149% in area 39, and 45% in area 44). The increase in the number of lipofuscin-containing cells was paralleled by neuronal loss and glial proliferation. Lipofuscin accumulation is a component of aging (Brunk and Terman 2002a,b; Brunk et al., 1992; Szweda et al., 2003), the neurodegeneration observed in Alzheimer's (Stojanovic et al., 1994) and Parkinson's diseases (Tórsdóttir et al., 1999), developmental syndromes such as Rett syndrome (Jellinger et al., 1988), and autism (Lopez-Hurtado and Prieto, 2008), and such psychiatric disorders as bipolar affective disorder (Yanik et al., 2004) and schizophrenia (Akyol et al., 2002; Herken et al., 2001).

Lipofuscin is an intralysosomal deposit of products of autophagocytosis and degradation of cytoplasmic components, including mitochondria, which cannot be degraded further or exocytosed. Oxidative stress is considered the factor contributing to lipid and protein damage and degradation, resulting in lipofuscin production and accumulation (Brunk et al., 1992; Sohal and Brunk, 1989). The presence of oxidatively modified proteins and lipids in lipofuscin supports the causative link between enhanced oxidative stress, autophagocytosis, and deposition of products of degradation in the lysosomal pathway and lipofuscin (Brunk and Terman, 2002a,b; Szweda et al., 2003; Terman and Brunk, 2004) and suggests that in autism, abnormal development is associated with early signs of oxidative stress and enhanced degradation and, possibly, turnover of cytoplasmic components.

1.5.3 β -AMYLOID PRECURSOR PROTEIN AND INTRANEURONAL AMYLOID β IN AUTISM

Sokol et al. (2006) detected signs of overexpression of APP in about 40% of autistic subjects. The levels of secreted APP in plasma in children with severe autistic behavior and aggression were two or more times the levels in children without autism, and up to

fourfold more than in children with mild autism. The trend observed in autistic children, with higher levels of secreted β -APP and nonamyloidogenic secreted β -APP, and lower levels of $A\beta$ 1–40 compared to controls, suggests an increased α -secretase pathway in autism (anabolic nonamyloidogenic APP processing). Enzyme-linked immunosorbent assay (ELISA) study of blood plasma from 25 autistic children 2–4 years of age and 25 age-matched control children revealed significantly increased level of secreted amyloid precursor protein alpha (sAPP- α) in 60% of autistic children (Bailey et al., 2008). Western blotting analysis confirmed higher levels of sAPP- α in autistic children.

AQ3 Amino-terminally truncated intraneuronal amyloid ($A\beta$) is present in the neurons of control subjects, and the amount of intraneuronal $A\beta$ increases with age (Wegiel et al., 2007). This author's study of 10 brains of autistic people revealed enhanced intraneuronal accumulation of amino-terminally truncated $A\beta$ in 50% of autistic subjects, including in one 5-year-old child and four adults 20, 23, 52, and 62 years of age. A similar pattern was also found in four examined brains of people with autism and isodicentric chromosome 15 (idic15) (Brown et al., 2008). In idic15, excessive accumulation of intraneuronal $A\beta$ might be related to an extra copy of one of the amyloid precursor protein-binding protein (APBA-2) genes localized on chromosome 15. In many brain regions, $A\beta$ is accumulated in large cytoplasmic granules corresponding to deposits of lipofuscin. Numerous large lipofuscin deposits with very strong $A\beta$ immunoreactivity in the neurons of several children and adults with autism appear to reflect severe metabolic stress affecting all of the neurons in the amygdala, all large neurons in the caudate/putamen, a majority of Purkinje cells, and the neurons in the dentate nucleus and nucleus olivaris, but only about 30%–40% of cortical pyramidal neurons. Accumulation of truncated $A\beta$ appears to be a by-product of enhanced degradation of transmembrane APP. The aggregated intracellular $A\beta$ induces the production of ROS and lipid peroxidation products and ultimately results in leakage of the lysosomal membrane (Glabbe, 2001). This process appears to affect many neuronal populations, not only in young and old adults, but also in children diagnosed with autism. A metabolic shift with $A\beta$ accumulation in neurons in these brain areas that are involved in the expression of emotions, stereotypic behaviors, and social deficits, such as the amygdala, hippocampus, some striatal subdivisions, and cerebellum, may contribute to cellular dysfunction and the clinical expression of autism.

1.6 CLINICOPATHOLOGICAL CORRELATIONS

Studies of clinicopathological correlations cover several domains of functional deficits in people with autism, including (a) speech, language, and verbal and nonverbal communication, (b) social deficits and face perception, (c) sensorimotor deficits, and (d) cognitive deficits.

1.6.1 SPEECH, LANGUAGE, AND VERBAL AND NONVERBAL COMMUNICATION

Expressive language function of individuals with autism ranges from complete mutism to verbal fluency. Verbal abilities are often accompanied by errors in word meaning (semantics) or language and communicative deficits in social context (social pragmatics) (Rapin, 1996; Stone et al., 1997; Wetherby et al., 1998). Studies of the language-related

neocortex, including Wernicke's area (BA 22, speech recognition), Broca's area (BA 44, speech production) and the gyrus angularis (BA 39, reading) of 7- to 44-year-old autistic and 8- to 56-year-old control individuals, revealed reduced numerical density of neurons by 38% in area 22, and by 24% in area 39 in autistic subjects, as well as an increased numerical density of lipofuscin-containing neurons by 50% in BA 22, and 44% in BA 44. These neuronal changes were paralleled by an increase of numerical density of glial cells in all three examined regions. Lopez-Hurtado and Prieto (2008) hypothesized that structural alteration in one or more of these cortical areas may contribute to the communication impairment observed in autism.

1.6.2 FACE PERCEPTION

All subjects with ASDs have disturbance of social behavior, including abnormalities in social reciprocity and difficulties in use of eye contact, facial expression, and social motivation. Social functioning includes eye contact, processing of faces, identification of individuals, and monitoring of face expression (Baron-Cohen et al., 1994). Patients with autism reveal deficits in face-processing (Grelotti et al., 2001), perception (Schultz, 2005), and recognition (Joseph and Tanaka, 2003).

The face-processing network includes the visual cortex (BA17), which projects via the inferior occipital gyrus to the fusiform gyrus. Fibers from the fusiform gyrus project to the amygdala, and inferior frontal gyrus and orbital cortex (Fairhall and Ishai, 2007; van Kooten et al., 2008). Functional magnetic resonance imaging (fMRI) identified the fusiform gyrus and other cortical regions as supporting face-processing in control subjects, and hypoactivity of the fusiform gyrus in autistic patients (Bolte et al., 2006; Kanwisher et al., 1999; Pierce et al., 2004). Hypoactivation of the fusiform gyrus is believed to be associated with the failure to make direct eye contact in autism (Dalton et al., 2005). Results of imaging-based fusiform volume estimation are inconsistent. Increased (Waiter et al., 2004) and unchanged (Pierce et al., 2001) volume in both hemispheres and increased fusiform gyrus in the left hemisphere (Herbert et al., 2002) were reported. Morphometric studies of the brain of 7 autistic and 10 control subjects revealed a reduced number of neurons in layers III, V, and VI, and reduced volume of neuronal soma in layers V and VI in the fusiform gyrus. No alterations in Brodman area 17 in these autistic individuals suggest that the input from the visual cortex to the fusiform gyrus is intact. These results indicate the underdevelopment of connections in the fusiform gyrus that may contribute to abnormal face perception in autism (van Kooten et al., 2008).

Bailey et al. (1998) noted abnormalities in cytoarchitectonic organization and neuronal density in the superior frontal cortex and superior temporal gyrus in autism. Neurons in the superior temporal sulcus are sensitive to the angle of gaze (Perrett et al., 1985). Neurons that are attuned to particular facial expressions were found in the inferior and superior temporal lobes (Hasselmo et al., 1989). Cortical areas responsive to faces, facial expressions, and angle of gaze send direct projections to the amygdala (Stefanacci and Amaral, 2000). Pathological changes in the amygdala may play a central role in the dysfunction seen in autism, including disturbed components of social cognition such as attention to and interpretation of facial expressions. fMRI studies show that judging from the expression of another

person's eyes what the other person might be thinking or feeling is associated with activation in the superior temporal gyrus, frontal cortex, and amygdala, whereas in subjects with autism, activation appears in the temporal and frontal cortex but not in the amygdala (Baron-Cohen et al., 1999).

1.6.3 SOCIAL ATTACHMENT—THE ROLE OF THE HYPOTHALAMUS IN BEHAVIORAL DEFICITS

Experimental studies revealed that the hypothalamic nucleus paraventricularis (NPV) and the nucleus supraopticus (NSO), producing oxytocin (OT) and vasopressin (VAS), regulate emotional responses, social attachment, cognitive functions, sleep, and appetite (Barden, 2004; Ehler et al., 2001; Manaye et al., 2005). OT and VAS are relayed from the human brain into the bloodstream via the posterior pituitary. The presence of receptors for both peptides throughout the forebrain, limbic system, thalamus, brain stem, and spinal cord (Raggenbass, 2001) indicates that hypothalamic neuropeptides modulate the function of many brain regions. Developmental changes in the distribution and expression of receptors suggest that the hypothalamic peptides play a significant role both in brain development and function (Shapiro and Insel, 1989). OT is required for the development of social memory. In OT knockout mice, the loss of social memory could be rescued by OT treatment (Ferguson et al., 2000). VAS is necessary for the formation of social memory and OT for retention of newly formed social memories (Popik and Van Ree, 1992; Popik et al., 1992). OT facilitates the learning of social interactions and the formation of associations that are specifically related to the mother (Nelson and Panksepp, 1996).

The initial product of oxytocin mRNA is a polypeptide containing both nanopeptide OT and neurophysin I, separated by tripeptide glycine-lysine-arginine. The result of enzymatic cleavage are intermediate forms containing 10, 11, or 12 amino acids, collectively referred to as carboxy-extended forms of OT (OT-X), and oxytocin (Gabreels et al., 1998; Gainer et al., 1995; Mitchell et al., 1998; Rao et al., 1992). In 5.8- to 11.5-year-old autistic individuals, reduced plasma OT level, deficits in OT prohormone processing (increase in OT-X), and an increase in the ratio of C-terminal extended forms to OT were found. In control children, nearly all OT-X is metabolized to OT, whereas in autistic children, the immature OT forms serve as the primary circulating molecule in the absence of or in compensation for OT (Green et al., 2001). However, experimental studies show that OT-X is not an effective agonist at OT-sensitive sites (Mitchell et al., 1998). Deficient conversion of OT-X to OT in autism could be the result of alterations in the level of prohormone convertases associated with genetic defects (Cook, 1998; Szatmari et al., 1998). The identification of four single nucleotide polymorphisms located within the OT receptor gene of 195 Chinese autistic subjects indicates that abnormal modulation of the OT receptor results in autism (Wu et al., 2005). OT and VAS are known to play a role in repetitive behaviors. Patients with ASDs show a significant reduction in repetitive behaviors following OT infusion (Hollander et al., 2003). In about 60% of subjects with autism, abnormal sleep patterns are observed. VAS is involved in the control of circadian rhythmicity (Swaab, 1997). VAS enhances aggressiveness, anxiety, stress levels, and the consolidation of fear memory (Bielsky et al., 2004; Griebel et al., 2002; Landgraf and Neumann, 2004). OT decreases anxiety

and stress; facilitates social encounters, maternal care, and the extinction of conditioned avoidance behavior (Bale et al., 2001; Champagne et al., 2001; Windle et al., 1997); reduces activation of the amygdala and modulates fear processing (Kirsch et al., 2005). The presence of abnormal levels of hypothalamic neuropeptides in patients with autism provides strong evidence that an abnormality in OT, VAS and other hypothalamic neuropeptides may have a significant contribution to the behavioral features of autism. However, the morphology and biochemistry of the hypothalamus of autistic subjects remains unknown. The only study of the hypothalamic mammillary body of a 26-year-old autistic man revealed that the cell-packing density was increased by 66% (Bauman and Kemper, 1985).

1.6.4 SENSORIMOTOR DEFICITS, AND REPETITIVE AND STEREOTYPED BEHAVIORS

In individuals with autism, impairments of gross and fine motor function recognized as hypotonia, limbic apraxia, and motor stereotypes are common findings and are more severe in subjects with lower IQ (Rogers et al., 1996). Hand mannerisms, body rocking, or unusual posturing are reported in 37% to 95% of individuals (Lord, 1995; Rapin, 1996; Rogers et al., 1996). In 42% to 88% of subjects with autism, aberrant sensory processing results in a preoccupation with sensory features of objects, over- or underresponsiveness to environmental stimuli or paradoxical responses to sensory stimuli (Kientz and Dunn, 1997). Sensorimotor deficits may be associated with pathological changes in both the nigrostriatal system (basal ganglia) and the cerebellum (Bailey et al., 1998; Kemper and Bauman, 1998; Ritvo et al., 1986; Saitoh and Courchesne, 1998; Sears et al., 1999). Cerebellar abnormality with a deficit/loss of Purkinje cells (Bailey et al., 1998; Kemper and Bauman, 1993, 1998; Ritvo et al., 1986) has been a common finding. Individuals with autism have been classified as affected by cerebellar hyper- or hypoplasia (Saitoh and Courchesne, 1998). A reduced number of Purkinje cells without significant glial activation and a reduced size of Purkinje cells were noticed in the majority of cerebellar reports (Bailey et al., 1998; Fehlow et al., 1993; Kemper and Bauman, 1993; Lee et al., 2002; Ritvo et al., 1986) in 21 of 29 examined cases (Palmen et al., 2004).

Results of evaluation of the size of the cerebellum using MRI are inconsistent. In several MRI studies, smaller cerebellar hemispheres (Gaffney et al., 1987; Murakami et al., 1989) and vermis (Ciesielski et al., 1997; Courchesne et al., 1988; Hashimoto et al., 1995) were reported. In a study by Piven et al. (1997a), the total cerebellar volume was found to be greater in subjects with autism than in the control group, and the increase was proportional to the increased total brain volume. In the cerebellum, boys with autism had less gray matter, a smaller ratio of gray to white matter, and smaller lobules VI and VII than did controls. Despite the inconsistency of reports characterizing topographic autism-associated vermian hypoplasia (Hashimoto et al., 1993; Kaufmann et al., 2003; Levitt et al., 1999; Piven et al., 1997a; Schaefer et al., 1996), several reports show associations between the size of the vermis and deficits in attention-orienting (Harris et al., 1999; Townsend et al., 1999), stereotypic behavior, and reduced exploration in autism (Pierce and Courchesne, 2001).

The reduced size of the pons, midbrain, and medulla in autism reported by Hashimoto et al. (1992, 1993, 1995) was not confirmed in other studies (Hsu et al., 1991; Piven et al., 1992).

Changes in neurons in the deep cerebellar nuclei were noticed by some authors (Kemper and Bauman, 1998) but not by others (Bailey et al., 1998). Structural MRI shows variable patterns of changes. Volumetry of the cerebellum may show no change, hypoplasia, or hyperplasia. Courchesne et al. (1988) reported selective hypertrophy of lobules VI and VII, but these results were not confirmed in other subjects. In part, the pattern may correspond to the functional status of subjects. In highly functioning subjects with autism, hypoplasia of the cerebellum has not been detected (Holttum et al., 1992).

A decrease in the number of GABAergic Purkinje cells is considered the most consistent neuropathological finding in autism, as it was detected in at least 50% of examined cases (Arin et al., 1991; Bailey et al., 1998). Recent studies indicate that preserved Purkinje cells reveal a 40% decrease in the expression of glutamic acid decarboxylase 67 (GAD67) mRNA in autistic subjects relative to control patients (Yip et al., 2007). Moreover, in autism, the basket cells likely provide increased GABAergic feed-forward inhibition to Purkinje cells. The result may include disruption in the timing of Purkinje cell firing and altered inhibition of the cerebellar nuclei, which could directly affect cerebellocortical output, leading to changes in motor behavior and cognition (Yip et al., 2008).

Repetitive and stereotyped behaviors defined as recurring, nonfunctional activities, or interests that occur regularly and interfere with daily functioning are a defining signs of autism. These behaviors include lower-order repetitive motor behavior, intense circumscribed patterns of interests, and higher-order rituals and compulsions (Gabriels et al., 2005). Several studies implicated the role of basal ganglia and frontostriatal circuitry in the pathophysiology of autism, especially in repetitive and stereotyped behaviors. Increased volume of the basal ganglia was reported in several MRI studies (Herbert et al., 2003; Hollander et al., 2005; Langen et al., 2007; Sears et al., 1999). Sears et al. (1999) and Hollander et al. (2005) observed a positive correlation between caudate volumes and repetitive behavior scores. A significant increase in caudate nucleus volume, disproportional to brain volume, was detected in MRI studies in two independent samples of medication-naïve subjects with autism (21 high-functioning children and adolescents, and 21 typically developing subjects; 21 high-functioning adolescents and young adults, and 21 healthy subjects) (Langen et al., 2007). Our studies showing a significantly smaller size of neurons in the caudate, putamen, and nucleus accumbens, especially in the brains of children 4–7 years of age suggest a developmental delay in the growth of neurons in the basal ganglia of autistic subjects, which may contribute to basal ganglia dysfunction (Wegiel et al., 2008). MRI and postmortem morphometric studies support the hypothesis that developmental abnormalities in frontostriatal circuitry contribute to repetitive and stereotyped behaviors, which are one of three defining symptoms of autism.

1.6.5 COGNITIVE DEFICITS

Many individuals with autism demonstrate a particular pattern on intellectual tests that is characteristic of autism. Performance IQ is usually higher than verbal IQ, and block design is the highest subtest, whereas comprehension is usually the lowest (Siegel et al., 1996). Individuals with autism have poorer adaptive function than would be predicted by IQ alone (Volkmar et al., 1993).

Cognitive deficits might be related in part to the memory system and limbic region abnormalities. Reduced volume of both the hippocampal formation and amygdala were noticed in subjects examined by Aylward et al. (1999), but not in populations examined by other researchers (Piven et al., 1998). Neurons in the hippocampus have reduced complexity of dendritic arbors. They are smaller and more densely packed in various portions of the hippocampal formation, entorhinal cortex, medial nuclei of the amygdala, medial septal nucleus, mammillary nuclei, and anterior cingulate gyrus (Bauman and Kemper, 1985; Kemper and Bauman, 1993). Haznedar et al. (1997) observed reduced volume of the anterior cingulate gyrus and decreased positron emission tomography (PET) activity in subjects with autism. Because the cerebellum is involved in a variety of cognitive and affective processes, abnormalities of both the limbic system and the cerebellum may be linked to the core social and communicative deficits in autism.

The caudate nucleus is an integral component of the frontostriatal network involved in cognitive functions (Chow and Cummings, 1999; Voelbel et al., 2006), including learning (Poldrack et al., 1999), short- and long-term memory (Fuh and Wang, 1995), and planning and problem-solving (Mendez et al., 1989; Schmidtke et al., 2002). The increased volume of the caudate observed in autistic children may be indicative of impaired neuronal pruning, contributing to a decrease in executive function (Voelbel et al., 2006).

1.6.6 EPILEPSY-ASSOCIATED PATHOLOGY

The 1% prevalence of epilepsy in the general population increases to 8% in DS, 10% in AD (Menendez, 2005; Risse et al., 1990; Velez and Selwa, 2003), and 33% in autism (Tuchman and Rapin, 2002). The interpretation of developmental changes in autism has been challenged by the need to differentiate among lesions that are not associated with epilepsy, that cause epilepsy, and that are produced by epilepsy (Sutula and Pitkanen, 2001). Recent studies support the hypothesis that epilepsy induces brain alterations that contribute to changes in circuitry, which potentiates the seizure-genic focus (Armstrong, 2005).

Studies of nonautistic subjects indicate that epilepsy-associated pathology includes patchy or laminar neuronal loss and gliosis in the cerebral cortex in one or both hemispheres. In temporal epilepsy, abnormalities were reported in 75% of the specimens examined, and hippocampal sclerosis was found in 50% (Bruton, 1988). Loss of hippocampal neurons correlates with the frequency of tonic-clonic seizures and the total duration of epilepsy (Dam, 1980; Tasch et al., 1999). Loss is accentuated in the CA4 sector and is observed in the granule cell layer in the dentate gyrus. Dispersion of dentate gyrus granular neurons might be a result of seizure-related, disturbed migration of neurons (Bengzon et al., 1997), or epilepsy-enhanced neurogenesis (Ericksson et al., 1998). Ammon horn sclerosis is a progressive lesion that can be induced and propagated by seizures (Armstrong et al., 2005).

AQ4

In nearly all cases with hippocampal pathology, changes are also observed in other brain regions. In about 25%, the amygdala, thalamus and mammillary body are affected with neuronal loss. More severe neuronal loss and gliosis in the hippocampus is paralleled by severe neuronal loss and gliosis in the lateral nucleus in the amygdala (Bruton, 1988; Hudson et al., 1993; Thom et al., 1999). Ectopias

with more than 8 neurons per 2sq. mm of white matter occurred in 43% of epileptic patients but in none of the controls (Hardiman et al., 1988). In 45% of severely affected epileptics, significant neuronal loss and astrocytosis spreading out into the overlying molecular layer is observed in the cerebellar cortex. The severity of the cerebellar damage may range from gross atrophy of most or many folia to the restricted neuronal loss in some folia, especially at their basal portion (Gessaga and Urich, 1985).

Central apnea, asphyxia, and pulmonary edema occurring during a seizure (Nashef et al., 1996) as well as life-threatening cardiac arrhythmias during seizures (Earnest et al., 1992; Jallon, 1997; Nashef et al., 1996; Reeves et al., 1996; Saussu et al., 1998) have been suggested as possible causes of sudden unexpected death in epilepsy (Thom et al., 1999).

Enhanced electric activity of neurons and/or increased cell synaptic transmission with enhanced vesicle exocytosis, both in normal and in disease-affected brains are a common cause of modifications of APP processing and A β levels. Epilepsy is associated with an elevation of APP expression (Sheng et al., 1994) and occurs in 10 of 11 examined subjects with diffuse nonfibrillar A β plaque formation (mean age 47.9 ± 8.8 years of age) (Mackenzie and Miller, 1994; Mackenzie et al., 1996).

1.7 MECHANISMS AFFECTING BRAIN DEVELOPMENT

1.7.1 BDNF AND NEUROTROPHINS IN AUTISM

The neurotrophins, a related family of growth factors, including nerve growth factor (NGF), brain-derived neurotrophic factor (BDNF), and neurotrophins (NT) NT-3 and NT-4/5, have a major role in the survival, growth, and differentiation of neurons (Conner et al., 1997). During typical brain development, only neurons making the appropriate connections survive and form synapses, whereas neurons that fail to obtain adequate neurotrophins die (Oppenheim, 1991). BDNF is broadly distributed throughout the human central nervous system (CNS) and provides neurotrophic support for many neuronal populations in the cortex, amygdala, hippocampus, and striatum (Murer et al., 2001; Schmidt-Kastner et al., 1996; Tapia-Arancibia et al., 2004). The hypothalamus is the brain structure that contains the highest BDNF protein levels (Katoh-Semba et al., 1997; Nawa et al., 1995; Yan et al., 1997) and BDNF mRNA (Castren et al., 1995; Kawamoto et al., 1996; Yan et al., 1997). In the cerebellum, immunoreactivity was observed in Purkinje cells and the olivary complex of the nuclei (Kawamoto et al., 1996; Murer et al., 2001).

In the basal forebrain of autistic individuals, the level of BDNF was three times higher than in controls (Perry et al., 2001). Miyazaki et al. (2004) observed a higher level of BDNF in the blood samples of young children with autism than in adult control subjects. The mean BDNF levels in sera of children diagnosed with autism and childhood disintegrative disorder were about four times higher than in control children (Connolly et al., 2006). Children with autism and childhood disintegrative disorder have both elevated BDNF levels and levels of autoantibodies against BDNF. Serum BDNF has been shown to be increased after seizures (Binder et al., 2001; Chavko et al., 2002).

1.7.2 BRAIN STEM AND THE ROLE OF SEROTONIN IN BRAIN DEVELOPMENT AND CLINICAL FEATURES OF AUTISM

Because 5-hydroxytryptamine (5-HT; serotonin) serves as both a neurotransmitter and an important developmental signal in the brain, dysregulation of the 5-HT system during development may be responsible for many of the abnormalities seen in autism (Whitaker-Azmitia, 2005). In fact, all known chemical inducers of autism including cocaine, thalidomide, valproate, and alcohol modulate 5-HT levels in the brain (Harris et al., 1995; Kramer et al., 1994; Narita et al., 2002; Rathbun and Druse, 1985; Stromland et al., 1994; Williams et al., 2001). A high proportion of children with autism exhibit elevated blood 5-HT levels (hyperserotonemia) and specific alterations in 5-HT biosynthesis. The severity of hyperserotonemia is correlated with the severity of autistic behaviors (Chandana et al., 2005; Chugani et al., 1999; Kuperman et al., 1987). A causal role for serotonergic abnormalities in the etiology of autism is also suggested by studies indicating autism-specific genetic polymorphisms in 5-HT metabolizing enzyme, transporter, or receptor genes (Cohen et al., 2003; Sutcliffe et al., 2005). Also, gender-specific differences in serotonergic regulation during development (Chandana et al., 2005; Chugani et al., 1999), combined with a 52% higher rate of 5-HT biosynthesis in the male than female brain (Nishizawa et al., 1997), and the increased susceptibility of males to early insults imposed by elevated levels of 5-HT (Johns et al., 2002), may contribute to the fourfold higher propensity of males to develop autism compared to females.

As a result of the regulatory role of serotonin affecting the size of neurons, the size of dendritic tree and the number of synapses in innervated cortical and subcortical structures and cerebellum, developmental abnormalities in the serotonergic system may contribute to structural and functional changes in target brain regions and structures. Virtually all regions of the brain receive serotonergic afferents from raphe system neurons. The rostral raphe nuclei form ascending pathways of axons mainly to the forebrain. The caudal raphe system innervates the lower brain stem and the spinal cord (Aitken and Törk, 1988; Lidov and Molliver, 1982). The functions of serotonin are mediated by 14 subtypes of 5-HT receptors in the nervous system (Hoyer et al., 1994; Martin and Humphrey, 1994; Saudou and Hen, 1994a,b). The serotonin_{2A} (5-HT_{2A}) receptor is known to be one of the major subtypes and is associated with psychological and mental events (Roth, 1994). The 5-HT_{2A} receptor plays a role in facilitating the formation and maintenance of synapses (Niitsu et al., 1995). Staining for 5-HT_{2A} shows the entire somata and dendritic tree of Purkinje cells in a rat cerebellum (Maeshima et al., 1998). *In vitro* studies have shown that 5-HT inhibits the growth and arborization of Purkinje cell dendrites through 5-HT_{2A} receptors and stimulates them through the 5-HT_{1A} receptor (Kondoh et al., 2004). 5-HT promotes the formation of synapses in developing and mature brain and spinal cord (Chen et al., 1997; Niitsu et al., 1995; Okado et al., 1993), and this process is mediated by the 5-HT_{2A} receptor in the spinal cord (Niitsu et al., 1995). Biochemical studies support the hypothesis that developmental defects of the raphe nuclei may make a major contribution to the structural and functional defects of cortical and subcortical structures. However, raphe nuclei have not yet been examined in autistic subjects.

1.8 CLOSING REMARKS

The detected brain structure-specific patterns of structural aberrations in a majority of examined anatomic subdivisions in autism brain may contribute to deficits in expression of emotions, processing of social stimuli, learning of social behaviors, verbal and nonverbal communication, and stereotypic behaviors. Pathological acceleration of brain growth and immaturity of neurons and neuronal networks in early childhood indicate that (a) a significant portion of structural/functional defects starts in early infancy and (b) causative factors dysregulate the mechanisms controlling brain/neuron development. The deceleration of brain growth in the second year of life and the increase of neuronal size in late childhood/adulthood suggests delayed activation of correcting mechanisms. However, the delayed correction of brain and neuronal size does not result in functional recovery. Analysis of the detected pattern of abnormal brain development in autism indicates that early diagnosis and early treatment may prevent or reduce developmental delay, reduce/eliminate secondary structural and functional changes, and improve clinical status throughout the life span.

ACKNOWLEDGMENTS

This study was supported in part by funds from the New York State Office of Mental Retardation and Developmental Disabilities and grants from Autism Speaks and the Department of Defense Autism Spectrum Disorders Research Program (AS073234).

REFERENCES

- Aitken, A. R. and I. Tork (1988). Early development of serotonin-containing neurons and pathways as seen in wholemount preparations of the fetal rat brain. *J. Comp. Neurol.* 274:32–47.
- Akyol, O., H. Herken, E. Uz, E. Fadillioglu, S. Unal, S. Sogut, H. Ozyurt, and H. A. Savas (2002). The indices of endogenous oxidative and antioxidative processes in plasma from schizophrenic patients: The possible role of oxidant/antioxidant imbalance. *Prog. Neuropsychopharmacol. Biol. Psychiatry* 26:995–1005.
- American Psychiatric Association (2000). *Diagnostic and Statistical Manual of Mental Disorders DSM-IV-TR*. American Psychiatric Association, Washington, DC.
- AQ5 Arin, D. M., M. L. Bauman, and T. L. Kemper (1991). The distribution of Purkinje cell loss in the cerebellum in autism. 307.
- Armstrong, D. D. (2005). Epilepsy-induced microarchitectural changes in the brain. *Pediatr. Dev. Pathol.* 8:607–614.
- Aylward, E. H., N. J. Minshew, K. Field, B. F. Sparks, and N. Singh (2002). Effects of age on brain volume and head circumference in autism. *Neurology* 59:175–183.
- Aylward, E. H., N. J. Minshew, G. Goldstein, N. A. Honeycutt, A. M. Augustine, K. O. Yates, P. E. Barta, and G. D. Pearlson (1999). MRI volumes of amygdala and hippocampus in non-mentally retarded autistic adolescents and adults. *Neurology* 53:2145–2150.
- Bailey, A., C. A. Le, I. Gottesman, P. Bolton, E. Simonoff, E. Yuzda, and M. Rutter (1995). Autism as a strongly genetic disorder: Evidence from a British twin study. *Psychol. Med.* 25:63–77.
- Bailey, A., P. Luthert, P. Bolton, C. A. Le, M. Rutter, and B. Harding (1993). Autism and megalencephaly. *Lancet* 341:1225–1226.



- Bailey, A., P. Luthert, A. Dean, B. Harding, I. Janota, M. Montgomery, M. Rutter, and P. Lantos (1998). A clinicopathological study of autism. *Brain* 121 (Pt 5):889–905.
- Bailey, A. R., B. N. Giunta, D. Obregon, W. V. Nikolic, J. Tian, C. D. Sanberg, D. T. Sutton, and J. Tan (2008). Peripheral biomarkers in autism: Secreted amyloid precursor protein-alpha as a probable key player in early diagnosis. *Int. J. Clin. Exp. Med.* 1:338–344.
- Bale, T. L., A. M. Davis, A. P. Auger, D. M. Dorsa, and M. M. McCarthy (2001). CNS region-specific oxytocin receptor expression: Importance in regulation of anxiety and sex behavior. *J. Neurosci.* 21:2546–2552.
- Barden, N. (2004). Implication of the hypothalamic-pituitary-adrenal axis in the physiopathology of depression. *J. Psychiatry Neurosci.* 29:185–193.
- Barkovich, A. J., R. I. Kuzniecky, G. D. Jackson, R. Guerrini, and W. B. Dobyns (2005). A developmental and genetic classification for malformations of cortical development. *Neurology* 65:1873–1887.
- Baron-Cohen, S. (2004). The cognitive neuroscience of autism. *J. Neurol. Neurosurg. Psychiatry* 75:945–948.
- Baron-Cohen, S., H. Ring, J. Moriarty, B. Schmitz, D. Costa, and P. Ell (1994). Recognition of mental state terms. Clinical findings in children with autism and a functional neuroimaging study of normal adults. *Br. J. Psychiatry* 165:640–649.
- Baron-Cohen, S., H. A. Ring, S. Wheelwright, E. T. Bullmore, M. J. Brammer, A. Simmons, and S. C. Williams (1999). Social intelligence in the normal and autistic brain: An fMRI study. *Eur. J. Neurosci.* 11:1891–1898.
- Bauman, M. L., P. A. Filipek, and T. L. Kemper (1997). Early infantile autism. *Int. Rev. Neurobiol.* 41:367–386.
- Bauman, M. L. and T. L. Kemper (1985). Histoanatomic observations of the brain in early infantile autism. *Neurology* 35:866–867.
- Bauman, M. L., and T. L. Kemper (1996). Observation on the Purkinje cells in the cerebellar vermis in autism. *J. Neuropath. Exp. Neurol.* 55:613.
- Bengzon, J., Z. Kokaia, E. Elmer, A. Nanobashvili, M. Kokaia, and O. Lindvall (1997). Apoptosis and proliferation of dentate gyrus neurons after single and intermittent limbic seizures. *Proc. Natl. Acad. Sci. USA* 94:10432–10437.
- Bielsky, I. F., S. B. Hu, K. L. Szegda, H. Westphal, and L. J. Young (2004). Profound impairment in social recognition and reduction in anxiety-like behavior in vasopressin V1a receptor knockout mice. *Neuropsychopharmacology* 29:483–493.
- Binder, D. K., S. D. Croll, C. M. Gall, and H. E. Scharfman (2001). BDNF and epilepsy: Too much of a good thing? *Trends Neurosci.* 24:47–53.
- Boddaert N., M. Zilbovicius, A. Philipe, L. Robel, M. Bourgeois, C. Barthelemy, D. Seidenwurm, I. Meresse, L. Laurier, I. Desguerre, N. Bahi-Buisson, F. Brunelle, A. Munnich, Y. Samson, M-C. Mouren, and N. Chabane (2009). MRI findings in 77 children with non-syndromic autism. *PLOS one* (www.plosone.com) 4:4415e.
- Bolte, S., D. Hubl, S. Feineis-Matthews, D. Prvulovic, T. Dierks, and F. Poustka (2006). Facial affect recognition training in autism: Can we animate the fusiform gyrus? *Behav. Neurosci.* 120:211–216.
- Bolton, P., J. Powell, M. Rutter, V. Buckle, J. R. Yates, Y. Ishikawa-Brush, and A. P. Monaco (1995). Autism, mental retardation, multiple exostoses and short stature in a female with 46,X,t(X;8)(p22.13;q22.1). *Psychiatr. Genet.* 5:51–55.
- Brown, W. T., T. Wisniewski, I. L. Cohen, E. London, M. Flory, H. Imaki, I. Kuchna, J. Wegiel, S. Y. Ma, K. Nowicki, J. Wang, and J. Wegiel (2008). Neuropathologic changes in chromosome 15 duplication and autism. In 7th Annual International Meeting for Autism Research (IMFAR).
- Brunk, U. T., C. B. Jones, and R. S. Sohal (1992). A novel hypothesis of lipofuscinogenesis and cellular aging based on interactions between oxidative stress and autophagocytosis. *Mutat. Res.* 275:395–403.



- Brunk, U. T. and A. Terman (2002a). Lipofuscin: Mechanisms of age-related accumulation and influence on cell function. *Free Radic. Biol. Med.* 33:611–619.
- Brunk, U. T. and A. Terman (2002b). The mitochondrial–lysosomal axis theory of aging: Accumulation of damaged mitochondria as a result of imperfect autophagocytosis. *Eur. J Biochem.* 269:1996–2002.
- Bruton, C. J. (1988). *The Neuropathology of Temporal Lobe Epilepsy*. In Maudsley Monographs. Oxford University Press, New York.
- AQ6 Buitelaar, J. K. and S. H. Willemsen-Swinkels (2000). Autism: Current theories regarding its pathogenesis and implications for rational pharmacotherapy. *Paediatr. Drugs* 2:67–81.
- Butler, M. G., M. J. Dasouki, X. P. Zhou, Z. Talebizadeh, M. Brown, T. N. Takahashi, J. H. Miles, C. H. Wang, R. Stratton, R. Pilarski, and C. Eng (2005). Subset of individuals with autism spectrum disorders and extreme macrocephaly associated with germline PTEN tumour suppressor gene mutations. *J. Med. Genet.* 42:318–321.
- Buxhoeveden, D. P. and M. F. Casanova (2002). The minicolumn and evolution of the brain. *Brain Behav. Evol.* 60:125–151.
- Carper, R. A. and E. Courchesne (2005). Localized enlargement of the frontal cortex in early autism. *Biol. Psychiatry* 57:126–133.
- Carper, R. A., P. Moses, Z. D. Tigue, and E. Courchesne (2002). Cerebral lobes in autism: Early hyperplasia and abnormal age effects. *Neuroimage* 16:1038–1051.
- Casanova, M. F., D. P. Buxhoeveden, A. E. Switala, and E. Roy (2002). Minicolumnar pathology in autism. *Neurology* 58:428–432.
- Casanova, M. F., K. van, I. A. E. Switala, H. van Engeland, H. Heinsen, H. W. Steinbusch, P. R. Hof, J. Trippe, J. Stone, and C. Schmitz (2006). Minicolumnar abnormalities in autism. *Acta Neuropathol.* 112:287–303.
- Castren, E., H. Thoenen, and D. Lindholm (1995). Brain-derived neurotrophic factor messenger RNA is expressed in the septum, hypothalamus and in adrenergic brain stem nuclei of adult rat brain and is increased by osmotic stimulation in the paraventricular nucleus. *Neuroscience* 64:71–80.
- Champagne, F., J. Diorio, S. Sharma, and M. J. Meaney (2001). Naturally occurring variations in maternal behavior in the rat are associated with differences in estrogen-inducible central oxytocin receptors. *Proc. Natl. Acad. Sci. USA* 98:12736–12741.
- Chandana, S. R., M. E. Behen, C. Juhasz, O. Muzik, R. D. Rothermel, T. J. Mangner, P. K. Chakraborty, H. T. Chugani, and D. C. Chugani (2005). Significance of abnormalities in developmental trajectory and asymmetry of cortical serotonin synthesis in autism. *Int. J. Dev. Neurosci.* 23:171–182.
- Chauhan, A., V. Chauhan, W. T. Brown, and I. Cohen (2004). Oxidative stress in autism: Increased lipid peroxidation and reduced serum levels of ceruloplasmin and transferrin—the antioxidant proteins. *Life Sci.* 75:2539–2549.
- Chauhan, A. and V. Chauhan (2006). Oxidative stress in autism. *Pathophysiology* 13:171–181.
- Chauhan, A., B. Muthaiyah, M. M. Essa, T. W. Brown, J. Wegiel, and V. Chauhan (2009). Increased lipid peroxidation in cerebellum and temporal cortex in autism. International Meeting for Autism Research, Chicago, IL, May 8, 2009.
- Chavko, M., N. S. Nadi, and D. O. Keyser (2002). Activation of BDNF mRNA and protein after seizures in hyperbaric oxygen: Implications for sensitization to seizures in re-exposures. *Neurochem. Res.* 27:1649–1653.
- Chen, L., K. Hamaguchi, S. Hamada, and N. Okado (1997). Regional differences of serotonin-mediated synaptic plasticity in the chicken spinal cord with development and aging. *J. Neural Transplant. Plast.* 6:41–48.
- Chow, T. W. and J. L. Cummings (1999). Frontal-subcortical circuits. In B. L. Miller and J. L. Cummings, (eds.), *The Human Frontal Lobes: Functions and Disorders*. Guilford Press, New York, pp. 3–26.

- Chugani, D. C., O. Muzik, M. Behen, R. Rothermel, J. J. Janisse, J. Lee, and H. T. Chugani (1999). Developmental changes in brain serotonin synthesis capacity in autistic and nonautistic children. *Ann. Neurol.* 45:287–295.
- Ciesielski, K. T., R. J. Harris, B. L. Hart, and H. F. Pabst (1997). Cerebellar hypoplasia and frontal lobe cognitive deficits in disorders of early childhood. *Neuropsychologia* 35:643–655.
- Cohen, I. L. (2007). A neural network model of autism: Implications for theory and treatment. In D. Mareschal, S. Sirois, G. Westerman, and M. H. Johnson (eds.), *Neuroconstructivism*. Oxford University Press, Oxford.
- Cohen, I. L., X. Liu, C. Schutz, B. N. White, E. C. Jenkins, W. T. Brown, and J. J. Holden (2003). Association of autism severity with a monoamine oxidase A functional polymorphism. *Clin. Genet.* 64:190–197.
- Conner, J. M., J. C. Lauterborn, Q. Yan, C. M. Gall, and S. Varon (1997). Distribution of brain-derived neurotrophic factor (BDNF) protein and mRNA in the normal adult rat CNS: Evidence for anterograde axonal transport. *J. Neurosci.* 17:2295–2313.
- Connolly, A. M., M. Chez, E. M. Streif, R. M. Keeling, P. T. Golumbek, J. M. Kwon, J. J. Riviello, R. G. Robinson, R. J. Neuman, and R. M. Deuel (2006). Brain-derived neurotrophic factor and autoantibodies to neural antigens in sera of children with autistic spectrum disorders, Landau-Kleffner syndrome, and epilepsy. *Biol. Psychiatry* 59:354–363.
- Cook, E. H. Jr. (1998). Genetics of autism. *Mental Retardation Dev. Disabil. Res. Rev.* 4:113–120.
- Coon, H., D. Dunn, J. Lainhart, J. Miller, C. Hamil, A. Battaglia, R. Tancredi, M. F. Leppert, R. Weiss, and W. McMahon (2005). Possible association between autism and variants in the brain-expressed tryptophan hydroxylase gene (TPH2). *Am. J. Med. Genet. B Neuropsychiatr. Genet.* 135B:42–46.
- AQ7 Courchesne, E. (2001). Unusual brain growth patterns in early life in patients with autistic disorder: An MRI study. *Neurology* 57:245–254.
- Courchesne, E., R. Carper, and N. Akshoomoff (2003). Evidence of brain overgrowth in the first year of life in autism. *JAMA* 290:337–344.
- Courchesne, E., J. R. Hesselink, T. L. Jernigan, and R. Yeung-Courchesne (1987). Abnormal neuroanatomy in a nonretarded person with autism. Unusual findings with magnetic resonance imaging. *Arch. Neurol.* 44:335–341.
- Courchesne, E., C. M. Karns, H. R. Davis, R. Ziccardi, R. A. Carper, Z. D. Tigue, H. J. Chisum, P. Moses, K. Pierce, C. Lord, A. J. Lincoln, S. Pizzo, L. Schreibman, R. H. Haas, N. A. Akshoomoff, and R. Y. Courchesne, E., R. Yeung-Courchesne, G. A. Press, J. R. Hesselink, and T. L. Jernigan (1988). Hypoplasia of cerebellar vermal lobules VI and VII in autism. *N. Engl. J. Med.* 318:1349–1354.
- Courchesne, E. and K. Pierce (2005a). Why the frontal cortex in autism might be talking only to itself: Local over-connectivity but long-distance disconnection. *Curr. Opin. Neurobiol.* 15:225–230.
- Courchesne, E. and K. Pierce (2005b). Brain overgrowth in autism during a critical time in development: Implications for frontal pyramidal neuron and interneuron development and connectivity. *Int. J. Dev. Neurosci.* 23:153–170.
- Dalton, K. M., B. M. Naciewicz, T. Johnstone, H. S. Schaefer, M. A. Gernsbacher, H. H. Goldsmith, A. L. Alexander, and R. J. Davidson (2005). Gaze fixation and the neural circuitry of face processing in autism. *Nat. Neurosci.* 8:519–526.
- Dam, A. M. (1980). Epilepsy and neuron loss in the hippocampus. *Epilepsia* 21:617–629.
- Damasio, H., R. G. Maurer, A. R. Damasio, and H. C. Chui (1980). Computerized tomographic scan findings in patients with autistic behavior. *Arch. Neurol.* 37:504–510.
- Davidovitch, M., B. Patterson, and P. Gartside (1996). Head circumference measurements in children with autism. *J. Child Neurol.* 11:389–393.

- Dawson, G., J. Munson, S. J. Webb, T. Nalty, R. Abbott, and K. Toth (2007). Rate of head growth decelerates and symptoms worsen in the second year of life in autism. *Biol. Psychiatry* 61:458–464.
- Dementieva, Y. A., D. D. Vance, S. L. Donnelly, L. A. Elston, C. M. Wolpert, S. A. Ravan, G. R. DeLong, R. K. Abramson, H. H. Wright, and M. L. Cuccaro (2005). Accelerated head growth in early development of individuals with autism. *Pediatr. Neurol.* 32:102–108.
- Department of Health and Human Services, Centers for Disease Control and Prevention (2007). *Morbidity and Mortality Weekly Report* 56:1–28.
- Dissanayake, C., Q. M. Bui, R. Huggins, and D. Z. Loesch (2006). Growth in stature and head circumference in high-functioning autism and Asperger disorder during the first 3 years of life. *Dev. Psychopathol.* 18:381–393.
- Earnest, M. P., G. E. Thomas, R. A. Eden, and K. F. Hossack (1992). The sudden unexplained death syndrome in epilepsy: Demographic, clinical, and postmortem features. *Epilepsia* 33:310–316.
- Ehlert, U., J. Gaab, and M. Heinrichs (2001). Psychoneuroendocrinological contributions to the etiology of depression, posttraumatic stress disorder, and stress-related bodily disorders: The role of the hypothalamus-pituitary-adrenal axis. *Biol. Psychol.* 57:141–152.
- Erden-Inal, M., E. Sunal, and G. Kanbak (2002). Age-related changes in the glutathione redox system. *Cell Biochem. Funct.* 20:61–66.
- Ericksson, P. S., E. Perfilieva, T. Bjork-Eriksson, A. M. Alborn, C. Nordborg, D. A. Peterson, and F. H. Gage (1998). Neurogenesis in the adult human hippocampus. *Nat. Med.* 4:1313–1317.
- Evans, T., S. L. Siedlak, L. Lu, X. Fu, Z. Wang, W. R. McGinnis, E. Fakhoury, R. J. Castellani, S. L. Hazen, W. L. Walsh, A. T. Levis, R. G. Salomon, M. A. Smith, G. Perry, and X. Zhu (2008). The autistic phenotype exhibits a remarkably localized modification of brain protein by products of free radical-induced lipid oxidation. *Am J Biochem. Biotechnol., Special Issue on Autism Spectrum Disorders* 4:61–72.
- Fairhall, S. L. and A. Ishai (2007). Effective connectivity within the distributed cortical network for face perception. *Cereb. Cortex* 17:2400–2406.
- Fehlow, P., K. Bernstein, A. Tennstedt, and F. Walther (1993). Early infantile autism and excessive aerophagy with symptomatic megacolon and ileus in a case of Ehlers-Danlos syndrome. *Pediatr. Grenzgeb.* 31:259–267.
- Ferguson, J. N., L. J. Young, E. F. Hearn, M. M. Matzuk, T. R. Insel, and J. T. Winslow (2000). Social amnesia in mice lacking the oxytocin gene. *Nat. Genet.* 25:284–288.
- Fidler, D. J., J. N. Bailey, and S. L. Smalley (2000). Macrocephaly in autism and other pervasive developmental disorders. *Dev. Med. Child Neurol.* 42:737–740.
- Filipek, P. A. (1996). Brief report: Neuroimaging in autism: The state of the science 1995. *J. Autism Dev. Disord.* 26:211–215.
- Filipek, P. A., P. J. Accardo, G. T. Baranek, E. H. Cook Jr., G. Dawson, B. Gordon, J. S. Gravel, C. P. Johnson, R. J. Kallen, S. E. Levy, N. J. Minshew, S. Ozonoff, B. M. Prizant, I. Rapin, S. J. Rogers, W. L. Stone, S. Teplin, R. F. Tuchman, and F. R. Volkmar (1999). The screening and diagnosis of autistic spectrum disorders. *J. Autism Dev. Disord.* 29:439–484.
- Folstein, S. E. and B. Rosen-Sheidley (2001). Genetics of autism: Complex aetiology for a heterogeneous disorder. *Nat. Rev. Genet.* 2:943–955.
- Folstein, S. E. and M. L. Rutter (1988). Autism: Familial aggregation and genetic implications. *J. Autism Dev. Disord.* 18:3–30.
- Fombonne E. (2003). Epidemiological surveys of autism and other pervasive developmental disorders. *J. Autism Dev. Disord.* 33:365–382.
- Fombonne, E., B. Roge, J. Claverie, S. Courty, and J. Fremolle (1999). Microcephaly and macrocephaly in autism. *J. Autism Dev. Disord.* 29:113–119.
- Friede, R. L. (1975). *Developmental Neuropathology*. Springer Verlag, Berlin.

- Fuh, J. L. and S. J. Wang (1995). Caudate hemorrhage: Clinical features, neuropsychological assessments and radiological findings. *Clin. Neurol. Neurosurg.* 97:296–299.
- Gabreels, B. A., D. F. Swaab, D. P. de Kleijn, N. G. Seidah, J. W. Van de Loo, d. Van, V. G. J. Martens, and F. W. Van Leeuwen (1998). Attenuation of the polypeptide 7B2, pro-hormone convertase PC2, and vasopressin in the hypothalamus of some Prader-Willi patients: Indications for a processing defect. *J. Clin. Endocrinol. Metab.* 83:591–599.
- Gabriels, R. L., M. L. Cuccaro, D. E. Hill, B. J. Ivers, and E. Goldson (2005). Repetitive behaviors in autism: Relationships with associated clinical features. *Res. Dev. Disabil.* 26:169–181.
- Gaffney, G. R., L. Y. Tsai, S. Kuperman, and S. Minchin (1987). Cerebellar structure in autism. *Am. J. Dis. Child* 141:1330–1332.
- Gainer, H., M. O. Lively, and M. Morris (1995). Immunological and related techniques for studying neurohypophyseal peptide-processing pathways. *Methods Neurosci.* 23:195–207.
- Garber, H. J. and E. R. Ritvo (1992). Magnetic resonance imaging of the posterior fossa in autistic adults. *Am. J. Psychiatry* 149:245–247.
- Gessaga, E. C. and H. Urich (1985). The cerebellum of epileptics. *Clin. Neuropathol.* 4:238–245.
- Ghaziuddin, M., L. Y. Tsai, and N. Ghaziuddin (1992). Autism in Down's syndrome: Presentation and diagnosis. *J. Intellect. Disabil. Res.* 36 (Pt 5):449–456.
- Gillberg, C. (1998). Chromosomal disorders and autism. *J. Autism Dev. Disord.* 28:415–425.
- Gillberg C. and M. Coleman (1996). Autism and medical disorders: A review of the literature. *Dev. Med. Child. Neurol.* 38:191–202.
- Gillberg, C. and L. de Souza (2002). Head circumference in autism, Asperger syndrome, and ADHD: A comparative study. *Dev. Med. Child Neurol.* 44:296–300.
- Glabe, C. (2001). Intracellular mechanisms of amyloid accumulation and pathogenesis in Alzheimer's disease. *J. Mol. Neurosci.* 17:137–145.
- Green, L. A., D. Fein, C. Modahl, C. Feinstein, L. Waterhouse, and M. Morris (2001). Oxytocin and autistic disorder: Alteration in peptide forms. *Biol. Psychiatry* 50:609–613.
- Grelotti, D., I. Gauthier, and R. T. Shultz (2001). Social interest and the development of cortical face specialization: What autism teaches us about face processing. *Dev. Psychobiol.* 40:213–225.
- Griebel, G., J. Simiand, G. C. Serradeil-Le, J. Wagnon, M. Pascal, B. Scatton, J. P. Maffrand, and P. Soubrie (2002). Anxiolytic- and antidepressant-like effects of the non-peptide vasopressin V1b receptor antagonist, SSR149415, suggest an innovative approach for the treatment of stress-related disorders. *Proc. Natl. Acad. Sci. USA* 99:6370–6375.
- Guerrini, R. and C. Marini (2006). Genetic malformations of cortical development. *Exp. Brain Res.* 173:322–333.
- Hagerman, R. J. (2002). The physical and behavioral phenotype. In R. J. Hagerman and P. J. Hagerman (eds.), *Fragile X Syndrome: Diagnosis, Treatment, and Research*. Johns Hopkins University Press, Baltimore, MD, pp. 206–248.
- Happe, F. (1999). Autism: Cognitive deficit or cognitive style? *Trends Cogn. Sci.* 3:216–222.
- Happe, F., A. Ronald, and R. Plomin (2006). Time to give up on a single explanation for autism. *Nat. Neurosci.* 9:1218–1220.
- Hardan, A. Y., N. J. Minshew, M. Mallikarjunn, and M. S. Keshavan (2001). Brain volume in autism. *J. Child Neurol.* 16:421–424.
- Hardiman, O., T. Burke, J. Phillips, S. Murphy, B. O'Moore, H. Staunton, and M. A. Farrell (1988). Microdysgenesis in resected temporal neocortex: Incidence and clinical significance in focal epilepsy. *Neurology* 38:1041–1047.
- Harris, N. S., E. Courchesne, J. Townsend, R. A. Carper, and C. Lord (1999). Neuroanatomic contributions to slowed orienting of attention in children with autism. *Brain Res. Cogn. Brain Res.* 8:61–71.

- Harris, S. R., L. L. MacKay, and J. A. Osborn (1995). Autistic behaviors in offspring of mothers abusing alcohol and other drugs: A series of case reports. *Alcohol Clin. Exp. Res.* 19:660–665.
- Hashimoto, T., M. Tayama, M. Miyazaki, K. Murakawa, and Y. Kuroda (1993). Brainstem and cerebellar vermis involvement in autistic children. *J. Child Neurol.* 8:149–153.
- Hashimoto, T., M. Tayama, M. Miyazaki, N. Sakurama, T. Yoshimoto, K. Murakawa, and Y. Kuroda (1992). Reduced brainstem size in children with autism. *Brain Dev.* 14:94–97.
- Hashimoto, T., M. Tayama, K. Mori, K. Fujino, M. Miyazaki, and Y. Kuroda (1989). Magnetic resonance imaging in autism: Preliminary report. *Neuropediatrics* 20:142–146.
- Hashimoto, T., M. Tayama, K. Murakawa, T. Yoshimoto, M. Miyazaki, M. Harada, and Y. Kuroda (1995). Development of the brainstem and cerebellum in autistic patients. *J. Autism Dev. Disord.* 25:1–18.
- Hasselmo, M. E., E. T. Rolls, and G. C. Baylis (1989). The role of expression and identity in the face-selective responses of neurons in the temporal visual cortex of the monkey. *Behav. Brain Res.* 32:203–218.
- Hazlett, H. C., M. Poe, G. Gerig, R. G. Smith, J. Provenzale, A. Ross, J. Gilmore, and J. Piven (2005). Magnetic resonance imaging and head circumference study of brain size in autism: Birth through age 2 years. *Arch. Gen. Psychiatry* 62:1366–1376.
- Haznedar, M. M., M. S. Buchsbaum, M. Metzger, A. Solimando, J. Spiegel-Cohen, and E. Hollander (1997). Anterior cingulate gyrus volume and glucose metabolism in autistic disorder. *Am. J. Psychiatry* 154:1047–1050.
- Haznedar, M. M., M. S. Buchsbaum, T. C. Wei, P. R. Hof, C. Cartwright, C. A. Bienstock, and E. Hollander (2000). Limbic circuitry in patients with autism spectrum disorders studied with positron emission tomography and magnetic resonance imaging. *Am. J. Psychiatry* 157:1994–2001.
- Herbert, M. R., G. J. Harris, K. T. Adrien, D. A. Ziegler, N. Makris, D. N. Kennedy, N. T. Lange, C. F. Chabris, A. Bakardjiev, J. Hodgson, M. Takeoka, H. Tager-Flusberg, and V. S. Caviness Jr. (2002). Abnormal asymmetry in language association cortex in autism. *Ann. Neurol.* 52:588–596.
- Herbert, M. R., D. A. Ziegler, C. K. Deutsch, L. M. O'Brien, N. Lange, A. Bakardjiev, J. Hodgson, K. T. Adrien, S. Steele, N. Makris, D. Kennedy, G. J. Harris, and V. S. Caviness Jr. (2003). Dissociations of cerebral cortex, subcortical and cerebral white matter volumes in autistic boys. *Brain* 126:1182–1192.
- Herbert, M. R., D. A. Ziegler, N. Makris, P. A. Filipek, T. L. Kemper, J. J. Normandin, H. A. Sanders, D. N. Kennedy, and V. S. Caviness Jr. (2004). Localization of white matter volume increase in autism and developmental language disorder. *Ann. Neurol.* 55:530–540.
- Herken, H., E. Uz, H. Ozyurt, S. Sogut, O. Virit, and O. Akyol (2001). Evidence that the activities of erythrocyte free radical scavenging enzymes and the products of lipid peroxidation are increased in different forms of schizophrenia. *Mol. Psychiatry* 6:66–73.
- Hevner, R. F. (2007). Layer-specific markers as probes for neuron type identity in human neocortex and malformations of cortical development. *J. Neuropathol. Exp. Neurol.* 66:101–109.
- Hollander, E., E. Anagnostou, W. Chaplin, K. Esposito, M. M. Haznedar, E. Licalzi, S. Wasserman, L. Soorya, and M. Buchsbaum (2005). Striatal volume on magnetic resonance imaging and repetitive behaviors in autism. *Biol. Psychiatry* 58:226–232.
- Hollander, E., S. Novotny, M. Hanratty, R. Yaffe, C. M. DeCaria, B. R. Aronowitz, and S. Mosovich (2003). Oxytocin infusion reduces repetitive behaviors in adults with autistic and Asperger's disorders. *Neuropsychopharmacology* 28:193–198.
- Holttum, J. R., N. J. Minshew, R. S. Sanders, and N. E. Phillips (1992). Magnetic resonance imaging of the posterior fossa in autism. *Biol. Psychiatry* 32:1091–1101.

- Howlin, P., L. Wing, and J. Gould. 1995. The recognition of autism in children with Down syndrome—Implications for intervention and some speculations about pathology. *Dev. Med. Child Neurol.* 37: 406–414.
- Hoyer, D., D. E. Clarke, J. R. Fozard, P. R. Hartig, G. R. Martin, E. J. Mylecharane, P. R. Saxena, and P. P. Humphrey (1994). International Union of Pharmacology classification of receptors for 5-hydroxytryptamine (Serotonin). *Pharmacol. Rev.* 46:157–203.
- Hsu, M., R. Yeung-Courchesne, E. Courchesne, and G. A. Press (1991). Absence of magnetic resonance imaging evidence of pontine abnormality in infantile autism. *Arch. Neurol.* 48:1160–1163.
- Hudson, L. P., D. G. Munoz, L. Miller, R. S. McLachlan, J. P. Girvin, and W. T. Blume (1993). Amygdaloid sclerosis in temporal lobe epilepsy. *Ann. Neurol.* 33:622–631.
- Jallon, P. (1997). Epilepsy and the heart. *Rev. Neurol.* 153:173–184.
- Jellinger, K., D. Armstrong, H. Y. Zoghbi, and A. K. Percy (1988). Neuropathology of Rett syndrome. *Acta Neuropathol.* 76:142–158.
- Johns, J. M., D. A. Lubin, J. A. Lieberman, and J. M. Lauder (2002). Developmental effects of prenatal cocaine exposure on 5-HT1A receptors in male and female rat offspring. *Dev. Neurosci.* 24:522–530.
- Joseph, R. M. and J. Tanaka (2003). Holistic and part-based face recognition in children with autism. *J. Child Psychol. Psychiatry* 44:529–542.
- Just, M. A., V. L. Cherkassky, T. A. Keller, and N. J. Minshew (2004). Cortical activation and synchronization during sentence comprehension in high-functioning autism: Evidence of underconnectivity. *Brain* 127:1811–1821.
- Juurink, B. H. and P. G. Paterson (1998). Review of oxidative stress in brain and spinal cord injury: Suggestions for pharmacological and nutritional management strategies. *J. Spinal Cord. Med.* 21:309–334.
- Kanwisher, N., D. Stanley, and A. Harris (1999). The fusiform face area is selective for faces not animals. *Neuroreport* 10:183–187.
- Katoh-Semba, R., I. K. Takeuchi, R. Semba, and K. Kato (1997). Distribution of brain-derived neurotrophic factor in rats and its changes with development in the brain. *J. Neurochem.* 69:34–42.
- Kaufmann, W. E., K. L. Cooper, S. H. Mostofsky, G. T. Capone, W. R. Kates, C. J. Newschaffer, I. Bukelis, M. H. Stump, A. E. Jann, and D. C. Lanham (2003). Specificity of cerebellar vermian abnormalities in autism: A quantitative magnetic resonance imaging study. *J. Child Neurol.* 18:463–470.
- Kawamoto, Y., S. Nakamura, S. Nakano, N. Oka, I. Akiguchi, and J. Kimura (1996). Immunohistochemical localization of brain-derived neurotrophic factor in adult rat brain. *Neuroscience* 74:1209–1226.
- AQ8 Kemper, T. L. and M. L. Bauman (1992). Neuropathology of infantile autism. In H. Naruse and E. M. Ornitz (eds.), *Neurobiology of Infantile Autism*. Elsevier Science, Amsterdam, pp. 43–57.
- Kemper, T. L. and M. L. Bauman (1993). The contribution of neuropathologic studies to the understanding of autism. *Neurol. Clin.* 11:175–187.
- Kent, L., J. Evans, M. Paul, and M. Sharp (1999). Comorbidity of autistic spectrum disorders in children with Down syndrome. *Dev. Med. Child Neurol.* 41:153–158.
- Kientz, M. A. and W. Dunn (1997). A comparison of the performance of children with and without autism on the sensory profile. *Am. J. Occup. Ther.* 51:530–537.
- Kirsch, P., C. Esslinger, Q. Chen, D. Mier, S. Lis, S. Siddhanti, H. Gruppe, V. S. Mattay, B. Gallhofer, and A. Meyer-Lindenberg (2005). Oxytocin modulates neural circuitry for social cognition and fear in humans. *J. Neurosci.* 25:11489–11493.
- Kondoh, M., T. Shiga, and N. Okado (2004). Regulation of dendrite formation of Purkinje cells by serotonin through serotonin 1A and serotonin 2A receptors in culture. *Neurosci. Res.* 48:101–109.

- Koshino, H., P. A. Carpenter, N. J. Minshew, V. L. Cherkassky, T. A. Keller, and M. A. Just (2005). Functional connectivity in an fMRI working memory task in high-functioning autism. *Neuroimage* 24:810–821.
- Kramer, K., E. C. Azmitia, and P. M. Whitaker-Azmitia (1994). In vitro release of [³H]5-hydroxytryptamine from fetal and maternal brain by drugs of abuse. *Brain Res. Dev. Brain Res.* 78:142–146.
- Kuperman, S., J. Beeghly, T. Burns, and L. Tsai (1987). Association of serotonin concentration to behavior and IQ in autistic children. *J. Autism Dev. Disord.* 17:133–140.
- Lainhart, J. E., J. Piven, M. Wzorek, R. Landa, S. L. Santangelo, H. Coon, and S. E. Folstein (1997). Macrocephaly in children and adults with autism. *J. Am. Acad. Child Adolesc. Psychiatry* 36:282–290.
- Landgraf, R. and I. D. Neumann (2004). Vasopressin and oxytocin release within the brain: A dynamic concept of multiple and variable modes of neuropeptide communication. *Front. Neuroendocrinol.* 25:150–176.
- Langen, M., S. Durston, W. G. Staal, S. J. Palmen, and H. van Engeland (2007). Caudate nucleus is enlarged in high-functioning medication-naive subjects with autism. *Biol. Psychiatry* 62:262–266.
- Lee, M., C. Martin-Ruiz, A. Graham, J. Court, E. Jaros, R. Perry, P. Iversen, M. Bauman, and E. Perry (2002). Nicotinic receptor abnormalities in the cerebellar cortex in autism. *Brain* 125:1483–1495.
- Levitt, J. G., R. Blanton, L. Capetillo-Cunliffe, D. Guthrie, A. Toga, and J. T. McCracken (1999). Cerebellar vermis lobules VIII-X in autism. *Prog. Neuropsychopharmacol. Biol. Psychiatry* 23:625–633.
- Lidov, H. G. and M. E. Molliver (1982). Immunohistochemical study of the development of serotonergic neurons in the rat CNS. *Brain Res Bull.* 9:559–604.
- Lopez-Hurtado, E. and J. J. Prieto (2008). A microscopic study of language-related cortex in autism. *Am. J. Biochem. Biotechnol. Special Issue on Autism Spectrum Disorders*, 4:130–145.
- Lord, C., S. Risi, L. Lambrecht, E. H. Cook Jr., B. L. Leventhal, P. C. DiLavore, A. Pickles, and M. Rutter (2000). The autism diagnostic observation schedule-generic: A standard measure of social and communication deficits associated with the spectrum of autism. *J. Autism Dev. Disord.* 30:205–223.
- Lord, C. and M. Rutter (1995). Autism and pervasive developmental disorders. In M. Rutter, E. Taylor, and L. Hersov (eds.), *Child and Adolescent Psychiatry, Modern Approaches*. Blackwell Science, Oxford, pp. 569–593.
- Mackenzie, I. R., R. S. McLachlan, C. S. Kubu, and L. A. Miller (1996). Prospective neuropsychological assessment of nondemented patients with biopsy proven senile plaques. *Neurology* 46:425–429.
- Mackenzie, I. R. and L. A. Miller (1994). Senile plaques in temporal lobe epilepsy. *Acta Neuropathol.* 87:504–510.
- Maeshima, T., F. Shutoh, S. Hamada, K. Senzaki, K. Hamaguchi-Hamada, R. Ito, and N. Okado (1998). Serotonin_{2A} receptor-like immunoreactivity in rat cerebellar Purkinje cells. *Neurosci. Lett.* 252:72–74.
- Manaye, K. F., D. L. Lei, Y. Tizabi, M. I. Vila-Garcia, P. R. Mouton, and P. H. Kelly (2005). Selective neuron loss in the paraventricular nucleus of hypothalamus in patients suffering from major depression and bipolar disorder. *J. Neuropathol. Exp. Neurol.* 64:224–229.
- Martin, G. R. and P. P. Humphrey (1994). Receptors for 5-hydroxytryptamine: Current perspectives on classification and nomenclature. *Neuropharmacology* 33:261–273.
- Mason-Brothers, A., E. R. Ritvo, C. Pingree, P. B. Petersen, W. R. Jenson, W. M. McMahon, B. J. Freeman, L. B. Jorde, M. J. Spencer, and A. Mo (1990). The UCLA-University of Utah epidemiologic survey of autism: Prenatal, perinatal, and postnatal factors. *Pediatrics* 86:514–519.



- McClelland, J. L. (2000). The basis of hyperspecificity in autism: A preliminary suggestion based on properties of neural nets. *J. Autism Dev. Disord.* 30:497–502.
- Mendez, M. F., N. L. Adams, and K. S. Lewandowski (1989). Neurobehavioral changes associated with caudate lesions. *Neurology* 39:349–354.
- Menendez, M. (2005). Down syndrome, Alzheimer's disease and seizures. *Brain Dev* 27:246–252.
- Miles, J. H., L. L. Hadden, T. N. Takahashi, and R. E. Hillman (2000). Head circumference is an independent clinical finding associated with autism. *Am. J. Med. Genet.* 95:339–350.
- Miles, J. H., T. N. Takahashi, S. Bagby, P. K. Sahota, D. F. Vaslow, C. H. Wang, R. E. Hillman, and J. E. Farmer (2005). Essential versus complex autism: Definition of fundamental prognostic subtypes. *Am. J. Med. Genet. A* 135:171–180.
- Ming, X., T. P. Stein, M. Brimacombe, W. G. Johnson, G. H. Lambert, and G. C. Wagner (2005). Increased excretion of a lipid peroxidation biomarker in autism. *Prostaglandins Leukot. Essent. Fatty Acids* 73:379–384.
- Mitchell, B. F., X. Fang, and S. Wong (1998). Role of carboxy-extended forms of oxytocin in the rat uterus in the process of parturition. *Biol. Reprod.* 59:1321–1327.
- Miyazaki, K., N. Narita, R. Sakuta, T. Miyahara, H. Naruse, N. Okado, and M. Narita (2004). Serum neurotrophin concentrations in autism and mental retardation: A pilot study. *Brain Dev.* 26:292–295.
- Muhle, R., S. V. Trentacoste, and I. Rapin (2004). The genetics of autism. *Pediatrics* 113:e472–e486.
- Muller, R. A. (2007). The study of autism as a distributed disorder. *Ment. Retard. Dev. Disabil. Res. Rev.* 13:85–95.
- Murakami, J. W., E. Courchesne, G. A. Press, R. Yeung-Courchesne, and J. R. Hesselink (1989). Reduced cerebellar hemisphere size and its relationship to vermal hypoplasia in autism. *Arch. Neurol.* 46:689–694.
- Murer, M. G., Q. Yan, and R. Raisman-Vozari (2001). Brain-derived neurotrophic factor in the control human brain, and in Alzheimer's disease and Parkinson's disease. *Prog. Neurobiol.* 63:71–124.
- Narita, N., M. Kato, M. Tazoe, K. Miyazaki, M. Narita, and N. Okado (2002). Increased monoamine concentration in the brain and blood of fetal thalidomide- and valproic acid-exposed rat: Putative animal models for autism. *Pediatr. Res.* 52:576–579.
- Nashef, L., F. Walker, P. Allen, J. W. Sander, S. D. Shorvon, and D. R. Fish (1996). Apnoea and bradycardia during epileptic seizures: Relation to sudden death in epilepsy. *J. Neurol. Neurosurg. Psychiatry* 60:297–300.
- Nawa, H., J. Carnahan, and C. Gall (1995). BDNF protein measured by a novel enzyme immunoassay in normal brain and after seizure: Partial disagreement with mRNA levels. *Eur. J. Neurosci.* 7:1527–1535.
- Nelson, E. and J. Panksepp (1996). Oxytocin mediates acquisition of maternally associated odor preferences in preweanling rat pups. *Behav. Neurosci.* 110:583–592.
- Newschaffer, C. J., D. Fallin, and N. L. Lee (2002). Heritable and nonheritable risk factors for autism spectrum disorders. *Epidemiol. Rev.* 24:137–153.
- Niitsu, Y., S. Hamada, K. Hamaguchi, M. Mikuni, and N. Okado (1995). Regulation of synapse density by 5-HT_{2A} receptor agonist and antagonist in the spinal cord of chicken embryo. *Neurosci. Lett.* 195:159–162.
- Nishizawa, S., C. Benkelfat, S. N. Young, M. Leyton, S. Mzengeza, M. C. de, P. Blier, and M. Diksic (1997). Differences between males and females in rates of serotonin synthesis in human brain. *Proc. Natl. Acad. Sci. USA.* 94:5308–5313.
- Okado, N., L. Cheng, Y. Tanatsugu, S. Hamada, and K. Hamaguchi (1993). Synaptic loss following removal of serotonergic fibers in newly hatched and adult chickens. *J. Neurobiol.* 24:687–698.



- Ono, H., A. Sakamoto, and N. Sakura (2001). Plasma total glutathione concentrations in healthy pediatric and adult subjects. *Clin. Chim. Acta* 312:227–229.
- Oppenheim, R. W. (1991). Cell death during development of the nervous system. *Annu. Rev. Neurosci.* 14:453–501.
- Palmen, S. J., H. van Engeland, P. R. Hof, and C. Schmitz (2004). Neuropathological findings in autism. *Brain* 127:2572–2583.
- Pennington, B. F., P. A. Filipek, D. Lefly, N. Chhabildas, D. N. Kennedy, J. H. Simon, C. M. Filley, A. Galaburda, and J. C. DeFries (2000). A twin MRI study of size variations in human brain. *J. Cogn. Neurosci* 12:223–232.
- Perrett, D. I., P. A. Smith, D. D. Potter, A. J. Mistlin, A. S. Head, A. D. Milner, and M. A. Jeeves (1985). Visual cells in the temporal cortex sensitive to face view and gaze direction. *Proc. R. Soc. Lond B Biol. Sci.* 223:293–317.
- Perry, E. K., M. L. Lee, C. M. Martin-Ruiz, Court JA, S. G. Volsen, J. Merrit, E. Folly, P. E. Iversen, M. L. Bauman, R. H. Perry, and G. L. Wenk (2001). Cholinergic activity in autism: Abnormalities in the cerebral cortex and basal forebrain. *Am. J. Psychiatry* 158:1058–1066.
- Perry, S. W., J. P. Norman, A. Litzburg, and H. A. Gelbard (2004). Antioxidants are required during the early critical period, but not later, for neuronal survival. *J. Neurosci. Res.* 78:485–492.
- Pfefferbaum, A., E. V. Sullivan, G. E. Swan, and D. Carmelli (2000). Brain structure in men remains highly heritable in the seventh and eighth decades of life. *Neurobiol. Aging* 21:63–74.
- Pickett, J. and E. London (2005). The neuropathology of autism: A review. *J. Neuropathol. Exp. Neurol.* 64:925–935.
- Pierce, K. and E. Courchesne (2001). Evidence for a cerebellar role in reduced exploration and stereotyped behavior in autism. *Biol. Psychiatry* 49:655–664.
- Pierce, K., R. A. Muller, J. Ambrose, G. Allen, and E. Courchesne (2001). Face processing occurs outside the fusiform “face area” in autism: Evidence from functional MRI. *Brain* 124:2059–2073.
- Pierce, K., F. Haist, F. Sedaghat, and E. Courchesne (2004). The brain response to personally familiar faces in autism: Findings of fusiform activity and beyond. *Brain* 127:2703–2716.
- Piven, J., E. Nehme, J. Simon, P. Barta, G. Pearlson, and S. E. Folstein (1992). Magnetic resonance imaging in autism: Measurement of the cerebellum, pons, and fourth ventricle. *Biol. Psychiatry* 31:491–504.
- Piven, J., S. Arndt, J. Bailey, S. Haverkamp, N. C. Andreasen, and P. Palmer (1995). An MRI study of brain size in autism. *Am. J. Psychiatry* 152:1145–1149.
- Piven, J., S. Arndt, J. Bailey, and N. Andreasen (1996). Regional brain enlargement in autism: A magnetic resonance imaging study. *J. Am. Acad. Child Adolesc. Psychiatry* 35:530–536.
- Piven, J., K. Saliba, J. Bailey, and S. Arndt (1997a). An MRI study of autism: The cerebellum revisited. *Neurology* 49:546–551.
- Piven, J., J. Bailey, B. J. Ranson, and S. Arndt (1997b). An MRI study of the corpus callosum in autism. *Am. J. Psychiatry* 154:1051–1056.
- Piven, J., J. Bailey, B. J. Ranson, and S. Arndt (1998). No difference in hippocampus volume detected on magnetic resonance imaging in autistic individuals. *J. Autism Dev. Disord.* 28:105–110.
- Poldrack, R. A., V. Prabhakaran, C. A. Seger, and J. D. Gabrieli (1999). Striatal activation during acquisition of a cognitive skill. *Neuropsychology.* 13:564–574.
- Popik, P. and J. M. Van Ree (1992). Long-term facilitation of social recognition in rats by vasopressin related peptides: A structure–activity study. *Life Sci.* 50:567–572.
- Popik, P., J. Vetulani, and J. M. Van Ree (1992). Low doses of oxytocin facilitate social recognition in rats. *Psychopharmacology* 106:71–74.

- AQ9 Pracher, V. P. and D. E. J. Clarke (1996). Case report: Challenging behaviour in a young adult with Down's syndrome and autism. *Brit. J. Learning Disab.* 24:167–169.
- Ragenbass, M. 2001. Vasopressin- and oxytocin-induced activity in the central nervous system: Electrophysiological studies using in-vitro systems. *Prog. Neurobiol.* 64:307–326.
- Rao, V. V., C. Loffler, J. Battey, and I. Hansmann (1992). The human gene for oxytocin-neurophysin I (OXT) is physically mapped to chromosome 20p13 by in situ hybridization. *Cytogenet. Cell Genet.* 61:271–273.
- Rapin, I. (1996). *Preschool Children with Inadequate Communication: Developmental Language Disorder, Autism, Low IQ*. MacKeith Press, London.
- Rathbun, W. and M. J. Druse (1985). Dopamine, serotonin, and acid metabolites in brain regions from the developing offspring of ethanol-treated rats. *J. Neurochem.* 44:57–62.
- Redcay, E. and E. Courchesne. (2005). When is the brain enlarged in autism? A meta-analysis of all brain size reports. *Biol. Psychiatry* 58:1–9.
- Reeves, A. L., K. E. Nollet, D. W. Klass, F. W. Sharbrough, and E. L. So (1996). The ictal bradycardia syndrome. *Epilepsia* 37:983–987.
- Risse, S. C., T. H. Lampe, T. D. Bird, D. Nochlin, S. M. Sumi, T. Keenan, L. Cubberley, E. Peskind, and M. A. Raskind (1990). Myoclonus, seizures, and paratonia in Alzheimer disease. *Alzheimer Dis. Assoc. Disord.* 4:217–225.
- Ritvo, E. R., B. J. Freeman, A. B. Scheibel, T. Duong, H. Robinson, D. Guthrie, and A. Ritvo (1986). Lower Purkinje cell counts in the cerebella of four autistic subjects: Initial findings of the UCLA-NSAC Autopsy Research Report. *Am. J. Psychiatry* 143:862–866.
- Rodier, P. M., J. L. Ingram, B. Tisdale, S. Nelson, and J. Romano (1996). Embryological origin for autism: Developmental anomalies of the cranial nerve motor nuclei. *J. Comp. Neurol.* 370:247–261.
- Rogers, S. J., L. Bennetto, R. McEvoy, and B. F. Pennington (1996). Imitation and pantomime in high-functioning adolescents with autism spectrum disorders. *Child Dev.* 67:2060–2073.
- Roth, B. L. (1994). Multiple serotonin receptors: Clinical and experimental aspects. *Ann. Clin. Psychiatry* 6:67–78.
- Rutter, M., A. Bailey, P. Bolton, and C. A. Le (1994). Autism and known medical conditions: Myth and substance. *J. Child Psychol. Psychiatry* 35:311–322.
- Saitoh, O. and E. Courchesne (1998). Magnetic resonance imaging study of the brain in autism. *Psychiatry Clin. Neurosci.* 52 Suppl:S219–S222.
- Sajdel-Sulkowska, E. M., B. Lipinski, H. Windom, T. Audhya, and W. McGinnis (2008). Oxidative stress in autism: Cerebellar 3-nitrotyrosine levels. *Am. J. Biochem. Biotechnol. Special Issue on Autism Spectrum Disorders*, 4:73–84.
- Sarnat, H. B. and L. Flores-Sarnat (2004). Integrative classification of morphology and molecular genetics in central nervous system malformations. *Am. J. Med. Genet. A* 126A:386–392.
- Saudou, F. and R. Hen (1994a). 5-Hydroxytryptamine receptor subtypes in vertebrates and invertebrates. *Neurochem. Int.* 25:503–532.
- Saudou, F. and R. Hen (1994b). 5-Hydroxytryptamine receptor subtypes: Molecular and functional diversity. *Adv. Pharmacol.* 30:327–380.
- Saussu, F., K. van Rijckevorsel, and T. de Barsey (1998). [Bradycardia: An unrecognized complication of some epileptic crises]. *Rev Neurol.* 154:250–252.
- Schaefer, G. B., J. N. Thompson, J. B. Bodensteiner, J. M. McConnell, W. J. Kimberling, C. T. Gay, W. D. Dutton, D. C. Hutchings, and S. B. Gray (1996). Hypoplasia of the cerebellar vermis in neurogenetic syndromes. *Ann. Neurol.* 39:382–385.
- Schmidt-Kastner, R., C. Wetmore, and L. Olson (1996). Comparative study of brain-derived neurotrophic factor messenger RNA and protein at the cellular level suggests multiple roles in hippocampus, striatum and cortex. *Neuroscience* 74:161–183.
- Schmidtke, K., H. Manner, R. Kaufmann, and H. Schmolck (2002). Cognitive procedural learning in patients with fronto-striatal lesions. *Learn. Mem.* 9:419–429.

- Schultz, R. T. (2005). Developmental deficits in social perception in autism: The role of the amygdala and fusiform face area. *Int. J. Dev. Neurosci.* 23:125–141.
- Sears, L. L., C. Vest, S. Mohamed, J. Bailey, B. J. Ranson, and J. Piven (1999). An MRI study of the basal ganglia in autism. *Prog. Neuropsychopharmacol. Biol. Psychiatry* 23:613–624.
- Shapiro, L. E. and T. R. Insel (1989). Ontogeny of oxytocin receptors in rat forebrain: A quantitative study. *Synapse* 4:259–266.
- Sheng, J. G., F. A. Boop, R. E. Mrak, and W. S. Griffin (1994). Increased neuronal beta-amyloid precursor protein expression in human temporal lobe epilepsy: Association with interleukin-1 alpha immunoreactivity. *J. Neurochem.* 63:1872–1879.
- Shulman, R. G., D. L. Rothman, K. L. Behar, and F. Hyder (2004). Energetic basis of brain activity: Implications for neuroimaging. *Trends Neurosci.* 27:489–495.
- Siegel, D. J., N. J. Minshew, and G. Goldstein (1996). Wechsler IQ profiles in diagnosis of high-functioning autism. *J. Autism Dev. Disord.* 26:389–406.
- Smalley, S. L., R. F. Asarnow, and M. A. Spence (1988). Autism and genetics. A decade of research. *Arch. Gen. Psychiatry* 45:953–961.
- Sohal, R. S. and U. T. Brunk (1989). Lipofuscin as an indicator of oxidative stress and aging. *Adv. Exp. Med. Biol.* 266:17–26.
- Sokol, D. K., D. Chen, M. R. Farlow, D. W. Dunn, B. Maloney, J. A. Zimmer, and D. K. Lahiri (2006). High levels of Alzheimer beta-amyloid precursor protein (APP) in children with severely autistic behavior and aggression. *J. Child Neurol.* 21:444–449.
- Sparks, B. F., S. D. Friedman, D. W. Shaw, E. H. Aylward, D. Echelard, A. A. Artru, K. R. Maravilla, J. N. Giedd, J. Munson, G. Dawson, and S. R. Dager (2002). Brain structural abnormalities in young children with autism spectrum disorder. *Neurology* 59:184–192.
- Stefanacci, L. and D. G. Amaral (2000). Topographic organization of cortical inputs to the lateral nucleus of the macaque monkey amygdala: A retrograde tracing study. *J. Comp. Neurol.* 421:52–79.
- Steg, J. P. and J. L. Rapoport (1975). Minor physical anomalies in normal, neurotic, learning disabled, and severely disturbed children. *J. Autism Child Schizophr.* 5:299–307.
- Stevenson, R. E., R. J. Schroer, C. Skinner, D. Fender, and R. J. Simensen (1997). Autism and macrocephaly. *Lancet* 349:1744–1745.
- Stojanovic, A., A. E. Roher, and M. J. Ball (1994). Quantitative analysis of lipofuscin and neurofibrillary tangles in the hippocampal neurons of Alzheimer disease brains. *Dementia* 5:229–233.
- Stone, W. L., O. Y. Ousley, P. J. Yoder, K. L. Hogan, and S. L. Hepburn (1997). Nonverbal communication in two- and three-year-old children with autism. *J. Autism Dev. Disord.* 27:677–696.
- Stromland, K., V. Nordin, M. Miller, B. Akerstrom, and C. Gillberg (1994). Autism in thalidomide embryopathy: A population study. *Dev. Med. Child Neurol.* 36:351–356.
- Sutcliffe, J. S., R. J. Delahanty, H. C. Prasad, J. L. McCauley, Q. Han, L. Jiang, C. Li, S. E. Folstein, and R. D. Blakely (2005). Allelic heterogeneity at the serotonin transporter locus (SLC6A4) confers susceptibility to autism and rigid-compulsive behaviors. *Am. J. Hum. Genet.* 77:265–279.
- Sutula, T. P. and A. Pitkanen (2001). More evidence for seizure-induced neuron loss: Is hippocampal sclerosis both cause and effect of epilepsy? *Neurology* 57:169–170.
- Swaab, D. F. (1997). Prader-Willi syndrome and the hypothalamus. *Acta Paediatr. Suppl.* 423:50–54.
- AQ10 Szatmari, P., M. B. Jones, L. Tuff, G. Bartolucci, S. Fisman, and W. Mahoney (1993). Lack of cognitive impairment in first-degree relatives of children with pervasive developmental disorders. *J. Am. Acad. Child Adolesc. Psychiatry* 32:1264–1273.
- Szatmari, P., M. B. Jones, L. Zwaigenbaum, and J. E. MacLean (1998). Genetics of autism: Overview and new directions. *J. Autism Dev. Disord.* 28:351–368.

- Szweda, P. A., M. Camouse, K. C. Lundberg, T. D. Oberley, and L. I. Szweda (2003). Aging, lipofuscin formation, and free radical-mediated inhibition of cellular proteolytic systems. *Ageing Res. Rev.* 2:383–405.
- Tapia-Arancibia, L., F. Rage, L. Givalois, and S. Arancibia (2004). Physiology of BDNF: Focus on hypothalamic function. *Front. Neuroendocrinol.* 25:77–107.
- Tasch, E., F. Cendes, L. M. Li, F. Dubeau, F. Andermann, and D. L. Arnold (1999). Neuroimaging evidence of progressive neuronal loss and dysfunction in temporal lobe epilepsy. *Ann. Neurol.* 45:568–576.
- Terman, A. and U. T. Brunk (2004). Lipofuscin. *Int. J. Biochem. Cell Biol.* 36:1400–1404.
- Thom, M., B. Griffin, J. W. Sander, and F. Scaravilli (1999). Amygdala sclerosis in sudden and unexpected death in epilepsy. *Epilepsy Res* 37:53–62.
- Torsdottir, G., J. Kristinsson, S. Sveinbjornsdottir, J. Snaedal, and T. Johannesson (1999). Copper, ceruloplasmin, superoxide dismutase and iron parameters in Parkinson's disease. *Pharmacol. Toxicol.* 85:239–243.
- Townsend, J., E. Courchesne, J. Covington, M. Westerfield, N. S. Harris, P. Lyden, T. P. Lowry, and G. A. Press (1999). Spatial attention deficits in patients with acquired or developmental cerebellar abnormality. *J. Neurosci.* 19:5632–5643.
- Tuchman, R. and I. Rapin (2002). Epilepsy in autism. *Lancet Neurol.* 1:352–358.
- van Kooten, I., S. J. Palmén, P. von Cappeln, H. W. Steinbusch, H. Korr, H. Heinsen, P. R. Hof, H. van Engeland, and C. Schmitz (2008). Neurons in the fusiform gyrus are fewer and smaller in autism. *Brain* 131:987–999.
- Velez, L. and L. M. Selwa (2003). Seizure disorders in the elderly. *Am. Fam. Physician* 67:325–332.
- Voelbel, G. T., M. E. Bates, J. F. Buckman, G. Pandina, and R. L. Hendren (2006). Caudate nucleus volume and cognitive performance: Are they related in childhood psychopathology? *Biol. Psychiatry* 60:942–950.
- Volkmar, F. R., A. Carter, S. S. Sparrow, and D. V. Cicchetti (1993). Quantifying social development in autism. *J. Am. Acad. Child Adolesc. Psychiatry* 32:627–632.
- Vorstman, J. A. S., W. G. Staal, E. van Daalen, H. van Engeland, P. F. R. Hochstenbach, and L. Franke (2006). *Mol. Psych.* 11:18–28.
- Waiter, G. D., J. H. Williams, A. D. Murray, A. Gilchrist, D. I. Perrett, and A. Whiten (2004). A voxel-based investigation of brain structure in male adolescents with autistic spectrum disorder. *Neuroimage.* 22:619–625.
- Wakabayashi, S. (1979). A case of infantile autism associated with Down's syndrome. *J. Autism Dev. Disord.* 9:31–36.
- Wegiel, J., I. Kuchna, K. Nowicki, J. Frackowiak, B. Mazur-Kolecka, H. Imaki, J. Wegiel, P. D. Mehta, W. P. Silverman, B. Reisberg, M. Deleon, T. Wisniewski, T. Pirttilla, H. Frey, T. Lehtimäki, T. Kivimäki, F. E. Visser, W. Kamphorst, A. Potempska, D. Bolton, J. R. Currie, and D. L. Miller (2007). Intraneuronal Abeta immunoreactivity is not a predictor of brain amyloidosis-beta or neurofibrillary degeneration. *Acta Neuropathol.* 113:389–402.
- Wegiel, J., E. London, I. L. Cohen, M. Flory, T. Wisniewski, H. Imaki, I. Kuchna, J. Wegiel, S. Y. Ma, K. Nowicki, J. Wang, and W. T. Brown (2008). Detection of leading developmental defects in brains of autistic subjects. In 7th Annual International Meeting for Autism Research (IMFAR).
- Wetherby, A. M., B. M. Prizant, and T. Hutchinson (1998). Communicative, social-affective, and symbolic profiles of young children with autism and pervasive developmental disorder. *Am. J. Speech Language Pathol.* 7:79–91.
- Whitaker-Azmitia, P. M. (2005). Behavioral and cellular consequences of increasing serotonergic activity during brain development: A role in autism? *Int. J. Dev. Neurosci.* 23:75–83.
- Williams, J. H., A. Whiten, T. Suddendorf, and D. I. Perrett (2001). Imitation, mirror neurons and autism. *Neurosci. Biobehav. Rev.* 25:287–295.

- Windle, R. J., N. Shanks, S. L. Lightman, and C. D. Ingram (1997). Central oxytocin administration reduces stress-induced corticosterone release and anxiety behavior in rats. *Endocrinology* 138:2829–2834.
- Wu, S. P., M. X. Jia, Y. Ruan, Y. Q. Guo, M. Shuang, X. H. Gong, Y. B. Zhang, X. L. Yang, and D. Zhang (2005). Positive association of the oxytocin receptor gene (OXTR) with autism in the Chinese Han population. *Biol. Psychiatry* 58:74–77.
- Yan, Q., R. D. Rosenfeld, C. R. Matheson, N. Hawkins, O. T. Lopez, L. Bennett, and A. A. Welcher (1997). Expression of brain-derived neurotrophic factor protein in the adult rat central nervous system. *Neuroscience* 78:431–448.
- Yanik, M., H. Vural, H. Tutkun, S. S. Zoroglu, H. A. Savas, H. Herken, A. Kocyigit, H. Keles, and O. Akyol (2004). The role of the arginine-nitric oxide pathway in the pathogenesis of bipolar affective disorder. *Eur. Arch. Psychiatry Clin. Neurosci.* 254:43–47.
- Yip, J., J. J. Soghomonian, and G. J. Blatt (2007). Decreased GAD67 mRNA levels in cerebellar Purkinje cells in autism: Pathophysiological implications. *Acta Neuropathol.* 113:559–568.
- Yip, J., J. J. Soghomonian, and G. J. Blatt (2008). Increased GAD67 mRNA expression in cerebellar interneurons in autism: Implications for Purkinje cell dysfunction. *J. Neurosci. Res.* 86:525–530.
- Yonan, A. L., M. Alarcon, R. Cheng, P. K. Magnusson, S. J. Spence, A. A. Palmer, A. Grunn, S. H. Juo, J. D. Terwilliger, J. Liu, R. M. Cantor, D. H. Geschwind, and T. C. Gilliam (2003). A genomewide screen of 345 families for autism-susceptibility loci. *Am. J. Hum. Genet.* 73:886–897.
- Zilbovicius, M., B. Garreau, Y. Samson, P. Remy, C. Barthelemy, A. Syrota, and G. Lelord (1995). Delayed maturation of the frontal cortex in childhood autism. *Am. J. Psychiatry* 152:248–252.
- Zoroglu, S. S., F. Armutcu, S. Ozen, A. Gurel, E. Sivasli, O. Yetkin, and I. Meram (2004). Increased oxidative stress and altered activities of erythrocyte free radical scavenging enzymes in autism. *Eur. Arch. Psychiatry Clin. Neurosci* 254:143–147.

AUTHOR QUERIES

- [AQ1] Running head is edited. Please check.
- [AQ2] Tuchman et al. (1991) is not listed. Please supply the reference.
- [AQ3] Please suggest which author. There are many authors for this chapter.
- [AQ4] Armstrong (2005) in the reference list. Please reconcile.
- [AQ5] Please provide missing details for Arin et al. (1991).
- [AQ6] Buitelaar and Willemsen-Swinkels (2000) is not cited in the text.
- [AQ7] Courchesne et al. (2001) in the text. Please reconcile.
- [AQ8] Kemper and Bauman (1992) is not cited in the text.
- [AQ9] Please verify the author names in Pracher et al. (1996).
- [AQ10] Szatmari et al. (1993) is not cited in the text.
- [AQ11] Year added from citation. Please confirm.

The neuropathology of autism: defects of neurogenesis, neuronal migration and dysplastic changes

Jerzy Wegiel^{1*}, Izabela Kuchna¹, Krzysztof Nowicki¹, Humi Imaki¹, Jarek Wegiel¹, Elaine Marchi¹, Shuang Yong Ma¹, Abha Chauhan³, Ved Chauhan³, Teresa Wierzba Bobrowicz⁴, Mony de Leon^{2,8}, Leslie A. Saint Louis^{2,7}, Ira L. Cohen⁵, Eric London⁵, W. Ted Brown⁶, Thomas Wisniewski^{1,2}

¹ Department of Developmental Neurobiology, NYS Institute for Basic Research in Developmental Disabilities (IBR), Staten Island, NY, USA

² Departments of Neurology, Pathology and Psychiatry, New York University School of Medicine, New York, NY, USA

³ Department of Neurochemistry, IBR

⁴ Department of Neuropathology, Institute of Psychiatry and Neurology, Warsaw, Poland

⁵ Department of Psychology, IBR

⁶ Department of Human Genetics, IBR

⁷ Corinthian Diagnostic Radiology, New York, NY, USA

⁸ Nathan Kline Institute, New York, NY, USA

* Corresponding author: Jerzy Wegiel; NYS Institute for Basic Research in Developmental Disabilities, 1050 Forest Hill Road, Staten Island, NY 10314, USA, Tel. (718) 494-5231; Fax (718) 982-4856; E-mail address: Jerzy.Wegiel@omr.state.ny.us

This study was supported in part by funds from the New York State Office of Mental Retardation and Developmental Disabilities, a grant from the Department of Defense Autism Spectrum Disorders Research Program (AS073234, Program Project; J.W., T.W., A.C.), a grant from the Autism Speaks (Princeton, NJ), and grant R01 HD43960 (J.W.) from The National Institutes of Health, The National Institute of Child Health and Human Development.

Abstract Autism is characterized by a broad spectrum of clinical manifestations including qualitative impairments in social interactions and communication, and repetitive and stereotyped patterns of behavior. Abnormal acceleration of brain growth in early childhood, signs of slower growth of neurons, and minicolumns developmental abnormalities suggest multiregional alterations. The aim of this study was to detect the patterns of focal qualitative developmental defects and to identify brain regions prone to developmental alterations in autism. Formalin-fixed brain hemispheres of 13 autistic (4 – 60 years of age) and 14 age-matched control subjects were embedded in celloidin, and cut into 200 μm -thick coronal sections, which were stained with cresyl violet and used for neuropathological evaluation. Thickening of the subependymal germinal matrix in two brains and subependymal nodular dysplasia in one of them, is indication of active neurogenesis in two autistic children. Subcortical, periventricular, hippocampal and cerebellar heterotopias detected in the brains of four autistic subjects (31%) reflect abnormal neuronal migration. Multifocal cerebral dysplasia resulted in local distortion of the cytoarchitecture of the neocortex in four brains (31%), entorhinal cortex in two brains (15%), cornu Ammonis in four brains and in dentate gyrus in two. Cerebellar flocculonodular dysplasia detected in six subjects (46%) and hypoplasia in one case indicate local failure of cerebellar development in 54% of autistic subjects. Detection of flocculonodular dysplasia only in one control subject and a broad spectrum of focal qualitative neuropathological developmental changes in 12 out of 13 examined brains of autistic subjects (92%), reflects multiregional dysregulation of neurogenesis, neuronal migration and maturation in autism, which may contribute to the heterogeneity of the clinical phenotype.

Keywords Autism . Developmental neuropathology . Subependymal nodular dysplasia
Heterotopia . Dysplasia

Introduction

Autism is characterized by a broad spectrum of clinical manifestations including: (a) qualitative impairments in reciprocal social interactions, (b) qualitative impairments in verbal and nonverbal communication, (c) restricted repetitive and stereotyped patterns of behavior, interests and activities, and (d) onset prior to the age of 3 years [1]. In most cases, the etiology is unknown and patients are diagnosed with idiopathic or non-syndromic autism [10, 3]. About 70% of individuals with idiopathic autism have essential autism, defined by the absence of physical abnormalities, but in 30% complex autism with dysmorphic features such as microcephaly and/or a structural brain malformation is diagnosed [70]. In 5 to 10% of cases, autism is diagnosed in association with other disorders such as fragile X syndrome, Rett syndrome, Down syndrome, and tuberous sclerosis [83, 92]. Intellectual impairments, defined as intelligence quotient (IQ) scores less than 70, were reported in 44.6% of children diagnosed with autism [27]. Epilepsy is observed in up to 33% of individuals with autism [93].

The phenotypic heterogeneity is a major obstacle in all areas of autism research [74] and may be the result of a contribution of non-overlapping gene effects. Genetic fractionation of social impairment, communication difficulties, and rigid and repetitive behaviors suggests that different features of autism are caused by different genes associated with different brain regions and related to different cognitive impairments and functional abnormalities [44].

In spite of a broad spectrum of clinical manifestations and striking inter-individual differences, studies of thousands of children has resulted in establishing the clinical diagnostic criteria of Pervasive Developmental Disorder [1]; however, corresponding neuropathological diagnostic criteria do not exist. One of the reasons for the disproportionate progress in clinical and neuropathological studies is the limited tissue resources available for postmortem studies. Between 1980 and 2003, only 58 brains of individuals with autism were examined [75]. Due to the diversity of aims, of protocols for tissue preservation, of methods of sampling and examination, and the small number of brains examined in an individual project, the pattern of neuropathological changes emerging from these studies remains incomplete and inconsistent.

The hypothesis that autism is associated with neuropathological changes was explored in the first reports published between 1980 and 1993 [7, 20, 21, 26, 38, 46, 47, 73, 80]. Since then, implementation of broader diagnostic terms such as Autism Spectrum Disorder (ASD),

examination of larger cohorts, applications of stereology, and functional and structural magnetic resonance imaging (MRI), has resulted in the detection of several major types of pathology, most likely contributing to the clinical phenotype. An emerging concept of autism related brain pathology integrates evidence of (a) abnormal acceleration of brain growth in early childhood [79], (b) minicolumn pathology [12, 13], (c) curtailed neuronal development [7] and brain-structure specific delays of neuronal growth [97] with indications of abnormalities in brain cytoarchitecture [5, 7], metabolic modifications with abnormal amyloid protein precursor (APP) processing [5, 89], enhanced oxidative stress [see review 16], and enhanced turnover of cell organelles with pigment accumulation and glial activation [60].

In spite of the conceptual limitations, “localizing” models are still the main approach to the identification of pathological changes as a component of the networks’ structural and functional abnormalities [72]. We hypothesize that dysregulation of neurogenesis, neuronal migration, and maturation is also reflected in qualitative focal developmental alterations of brain microarchitecture. The aim of this study is to detect the pattern of focal qualitative developmental defects including their type, topography, and severity, and to identify structures and brain regions prone to developmental alterations in autism.

Materials and methods

The autistic cohort studied consisted of 13 subjects (4 to 62 years of age) including 9 males (69%) and 4 females (31%), while the control cohort consisted of 14 subjects (4 to 64 years of age), including 9 males and 5 females (Table 1).

Clinical characteristics of the autistic subjects

The medical records of the autistic subjects were the source of our clinical data and consisted of psychological, behavioral, neurological and psychiatric evaluation reports. All of the records were obtained after death. The Autism Diagnostic Interview-Revised (ADI-R) was administered to the donor family as a standardized assessment tool in order to confirm the diagnosis on a postmortem basis. Inclusion of the subject in this study was based on a summary of scores of four domains: (a) qualitative abnormalities in reciprocal social interaction; (b) qualitative

abnormalities in verbal and nonverbal communication; (c) restricted, repetitive, and stereotyped patterns of behavior, and (d) abnormality of development evident at or before 36 months [61]. All 13 autistic subjects met ADI-R criteria for autism. For some subjects, the intellectual evaluation was available and was based on the Wechsler Intelligence Scale for Children III and the Woodcock-Johnson Tests of Achievement-Revised (Table 2). Eight subjects were diagnosed with intellectual disability, usually in the range from mild to severe (61%). Six of 13 autistic subjects had seizures (46%). In five cases the age of onset of seizures was from 14 month to 5 years of age. A 23-year old autistic male had only one seizure, which was reported as the cause of his death. In one child, an abnormal EEG was detected, but without seizures.

Several forms of challenging behaviors and behavioral disorders were noted including: self-injurious behavior (six cases; 46%), aggression (four cases; 31%), hyperactivity (three cases; 23%), obsessive compulsive disorder (two cases, 12%) and in single cases depression and mania.

Brain tissue preservation

Brains of 13 autistic and 14 age-matched control subjects were examined by postmortem MRI and neuropathologically. The postmortem interval (PMI) varied in time ranging from 6 to 27.8 hours in the control group (16 h on average; SD 6h) and from 8 to 30 hours in the autistic group (20 hours on average; SD 12h). The median postmortem interval was 15 hours.

The brain hemispheres were removed using standard techniques exercising extra care to avoid damaging the brain tissue. The brain was weighed in the fresh state. The fresh brain was sagittally cut through the corpus callosum and brainstem. Half of the brain was fixed in 10% buffered formalin. Following at least 3 weeks of fixation, the brain hemisphere was scanned using MRI. The aim of the MRI application was to determine the type of developmental changes detectable by MRI and to microscopically characterize MRI findings. MRI scans were acquired on a 1.5 T GE Signa Imager (General Electric, Milwaukee, USA). The research scan consisted of a 124 slice T1-weighted fast gradient echo acquired in a coronal orientation perpendicular to the long axis of the hippocampus with a 1.3 – 1.7 mm slice thickness, which encompassed the entire brain hemisphere without gap or wrap artifact (FOV = 25 cm; NEX = 1; matrix =256 x 192; TR 35 ms and FA = 60°). All file names were assigned sequential code numbers and demographic information was removed from image headers. Images were transferred to a database and then to

a satellite Sun workstation for further processing. Image analysis was done using MIDAS software running on a UNIX operating system. The original images were reformatted in a one sync interpolation step to a standardized “pathological angle” coronal plane with a 1.5 mm slice thickness. The pathological angle coronal plane was perpendicular to the plane running through the inferior surface of the frontal and occipital lobes and was designed to match the sections obtained at postmortem [9].

The brain hemisphere was fixed with 10% buffered formalin. Formalin was washed out from the tissue during an overnight tap water rinsing. Brains were dehydrated using a series of increasing ethyl alcohol concentrations (50% ethanol 3 days; 70% ethanol 4 days; 80% ethanol 3 days; 95% ethanol 4 days). The brain hemisphere was embedded in 8% celloidin [49]. During hardening, celloidin blocks were exposed to chloroform vapors for approximately 2.5 weeks and celloidin blocks were then stored in 70% ethanol. For sectioning, the block was attached to the block holder with 10-15 ml of 8% celloidin. To fasten adhesion of the block to the holder, the block with the holder attached was immersed into 70% ethanol overnight. Serial 200 μ m-thick sections were separated with filter paper and stored in 70% ethanol. Sections were washed in water for 2-3 hours, stained with cresyl violet (CV) and mounted with Acrytol.

The CV-stained sections were the subject of neuropathological evaluation. Each serial hemispheric section at 1.2 mm distance was examined to detect qualitative cytoarchitectonic abnormalities.

Tissue acquisition for this Program Project is based on individual Tissue Transfer Agreements between the Program Project principal investigator and several tissue banks including: (a) The Brain and Tissue Bank at the University of Maryland, (b) The Harvard Brain Tissue Resource Center and (c) the Brain Bank for Developmental Disabilities and Aging of the NYS Institute for Basic Research in Developmental Disabilities. Each brain hemisphere number given by the institution that received the donation was used as the only identifier of clinical records and tissue samples. Brain Bank identification of tissue samples are listed in Tables 1-3 to keep non-overlapping records of results of examination of brains in different projects and research groups. The methods applied in this study were approved by the Institutional Review Board at the New York State Institute for Basic Research in Developmental Disabilities.

Results

Neuropathological evaluation of serial coronal hemispheric sections from the cerebral and cerebellar hemispheres of 13 autistic and 14 control subjects revealed more details characterizing topography and severity of changes than standard sampling of brains for routine neuropathological evaluation. A broad range of changes was found. Developmental abnormalities included subependymal nodular dysplasia, heterotopia and very common dysplastic changes within the neo- and archicortex, hippocampus, and cerebellum in 12 of 13 examined brains of the autistic subjects (92%) (Table 3). The general result of these developmental defects was a multifocal disorganization of gray and white matter. Developmental pathology observed in control brains was limited to one cerebellar dysplasia.

Alterations of the subependymal germinal matrix and subependymal nodular dysplasia

In two autistic subjects, there was a several-fold local increase in the thickness of the subventricular germinal zone. Numerous subependymal nodules were found within a pathologically thickened subependymal germinal zone, in the wall of the occipital horn of lateral ventricle of a 7-year old male, which reflects a subependymal nodular dysplasia (Fig. 1 a-e). Nodules occupied 13.3 mm of the caudal portion of the occipital horn of the lateral ventricle. The diameter of round/oval nodules varied in size from 285 μm to 3,310 μm . While the smallest nodules were dispersed within the subventricular germinal zone, the large nodules expanded partially into the white matter, and partially into the lumen of the ventricles and were detectable on MRI (Fig. 1 a) and CV-stained histological sections (Fig. 1 b, c). The effect seen was a narrowing of the ventricle and a tuberous appearance of the ventricular wall. There were large tubers that contained dysplastic neurons with a partially modified morphology of pyramidal, multipolar or bipolar large neurons (Fig. 1 d) and irregularly shaped medium and small size neurons. Neurons in the small nodules were small and poorly differentiated (Fig. 1 e). In the large nodules, several hypocellular areas were observed. The nodules were free of oval or polygonal giant cells or ballooned glial cells, as well as signs of calcification.

In the brain with the subependymal nodular dysplasia an abnormal tuberous expansion of the caudate nucleus was detected on MRI (Fig. 1f) and in histological sections (Fig. 1 g, h). Only

ependyma separated the tuber-like expansion of the caudate from the ventricle lumen. The very thick subependymal germinal matrix that was present close to the caudate was substituted by loosely arranged and poorly differentiated neurons in the affected area.

Heterotopia

Heterotopias were found in the brains of four autistic subjects and none of control subjects. The topography of lesions was different in each case. Subcortical heterotopias were detected in the white matter of the anterior cingulate gyrus in 5-year old (Fig. 2a, b) and in the inferior frontal gyrus in 11-year old subject. Periventricular heterotopias were detected near the wall of lateral ventricle in 7-year old subject (Fig. 2c, d). A single heterotopia was noted in the stratum oriens of the hippocampus. In the cerebellum of 11-year old child heterotopias were detected in the vermis and in cerebellar white matter close to the dentate nucleus (Fig. 2 f-h). These defects of migration were observed in two brains as a single aggregate of gray matter, in one brain as two aggregates, and in one brain as three lesions measuring from 1 to 3 mm in diameter. Subcortical and periventricular heterotopias were built of poorly differentiated oval or multipolar neurons without spatial orientation (Fig. 2a) or had a distorted laminar organization (Fig. 2e). Cerebellar heterotopias had a distorted morphology of the granule and molecular layers with a few dispersed Purkinje cells (Fig. 2 g, h).

Dysplasia within neo- and archicortex, hippocampus and cerebellum

The multifocal neocortical dysplasia detected in four brains of autistic subjects (31%) was associated with a local loss of vertical and horizontal organization of the neocortex, formation of abnormal layers, loss of orientation of neurons (Fig. 3a, b), and thickening of the affected portion of the cortical ribbon. A focal dysplasia in the entorhinal cortex, observed mainly in the second layer with a local absence of islands and/or reduced number of neurons, was found in the 23-year old and the 60-year old autistic subjects (15%) (Fig. 3 c, d). A lack of giant multinuclear neurons and large, ballooned glial cells typical of focal cortical dysplasia indicated that the observed developmental changes in neo- and archicortex reflect a more subtle cortical malformation, classified usually as focal cortical microdysgenesis.

Two types of changes were observed in the dentate gyrus. An abnormal migration of granule neurons into the molecular layer resulted in the formation of an additional fragmentary granule cell layer (Fig. 3e). In other areas, granule cells formed irregular circles and loops (Fig. 3f).

In the CA1 sector of a 13-year old male, several areas of dysplastic changes with a significant deficit of pyramidal neurons without gliosis were found (Fig. 3g). In affected areas, the size and shape of neurons varied over a wide range. Pyramidal neurons were very rare, whereas small irregular or oval-shaped, poorly differentiated neurons prevailed (Fig. 3h). In the dysplastic area in the CA1 sector of the 56-year old autistic subject, an opposite trend was present with thickening of the pyramidal layer and an increased packing of dysplastic neurons (not shown).

The most common developmental abnormality within the cerebellum was dysplasia, which was detected in 6 autistic subjects (46%) and in the cerebellum of one control subject. Flocculonodular dysplasia (Fig. 4a, b) usually affecting the entire nodule was found in the cerebellum in 5 autistic subjects (38%). In the dysplastic areas, a thin granule layer formed the labyrinth, which was mixed with irregular islands of the molecular layer. Clusters of granule cells and a few Purkinje cells were dispersed within the distorted molecular layer. The only developmental abnormality detected in control group was flocculonodular dysplasia in the cerebellum of 51-year old control subject (not shown). Local cortical dysplasia was also detected within the vermis of the 13-year old autistic male. In the affected area, the cytoarchitecture of the molecular and granule layers and the Purkinje cells was completely disorganized (Fig. 4c, d).

In the cerebellum of the 60-year old autistic male, severe hypoplasia affected lobes 1-4 (Fig. 4e). The thickness of the molecular and granular layer was decreased by almost 50% in comparison to non-affected areas (Fig. 4 e, f). The number of Purkinje cells was significantly reduced in the hypoplastic area. Hypoplastic changes within the portion of cerebellar cortex were observed together with a significantly reduced convolution of the dentate nucleus (Fig. 4g).

Discussion

This neuropathological study revealed a broad spectrum of focal developmental abnormalities in 92% of the autistic subjects brains and striking interindividual differences in the type and

topography of changes. Evidence that different features of autism are caused by different genes associated with different brain regions [44] suggests a link between regional developmental alterations in the brain and different components of the autistic phenotype.

Altered neurogenesis in autism

Increased brain mass in autistic children and some adults [79], increase in the numerical density of neurons [12, 13], reduced size of neurons [7], and brain structure specific delay of neuronal growth [97] indicates alterations in neuronal and brain growth in autistic individuals. The subventricular zone of the lateral ventricles [25] and the dentate gyrus [32] are active sites of neurogenesis in adult humans. Several our findings support the hypothesis of altered neurogenesis in autistic subjects. The increased thickness of the subependymal germinal matrix, subependymal nodular dysplasia, abnormal growth of the dentate nucleus, and dysplasia of the granule layer in the dentate gyrus, detected in this study, appear to be signs of abnormal neurogenesis in the brains of three autistic subjects. Subependymal nodules were reported in approximately 80% of patients with tuberous sclerosis, a disorder that is highly associated with epilepsy, autism and mental retardation [65]. Tuberous sclerosis nodules were detected in a fetus [11] suggesting fetal development of subependymal nodules leading to an early onset of epilepsy that was diagnosed at the age of 14 months in neuropathologically examined autistic male. The subependymal nodules detected in this autistic male's brain are partially similar to tubers seen in subjects diagnosed with tuberous sclerosis [23]. The cause of subependymal nodular dysplasia in the examined subject is unknown. In the reported subjects, bilateral periventricular nodules are linked to mutations of Filamin A (FLNA) gene located on chromosome Xp28. Filamin A is an actin-crosslinking protein that is essential for cell locomotion [15] and nodule formation might be related to a defect in cell migration. The presence within the subependymal germinal matrix of miniature nodules that were built of poorly differentiated small neurons, and an increase in nodular size with signs of growth and differentiation of neurons suggests that neurogenesis, differentiation and maturation of neurons were in progress within the subependymal germinal matrix of the seven year old autistic child. This interpretation of subependymal nodules genesis is consistent with lineage studies demonstrating that cells in nodules express cellular markers that are typical for progenitors derived from the subventricular germinal zone [32, 59]. However,

in contrast to the subependymal nodules seen in subjects with tuberous sclerosis, in the examined autistic subject the nodules seen were small (from 258 μm to 3,310 μm in diameter), and did not have the characteristic ovoid or polygonal 80 μm to 150 μm in diameter giant cells with multiple and peripherally displaced nuclei [24] or ballooned cells considered the *sine qua non* histopathological features of cortical tubers and subependymal nodules observed in tuberous sclerosis [65].

An enlarged caudate nucleus detected in the brain of the 7-year old autistic subject is consistent with MRI reports documenting an increased volume of basal ganglia, including the caudate, in autism [50, 51, 58, 88]. A disproportionate increase of the caudate nucleus volume [58] suggests that in brains of some autistic individuals, extended neurogenesis within the germinal matrix may contribute to abnormal growth of the caudate nucleus. A similar process is observed in the brains of people diagnosed with Huntington disease, showing an enhanced neurogenesis in the subependymal layer and suggesting renewal of the neuronal population in a degenerating caudate nucleus [25]. The caudate nucleus is a part of the fronto-striatal network involved in several functional domains that are impaired in autism including lower-order repetitive motor behavior, intense circumscribed patterns of interests and higher-order rituals and compulsions [37], defects of cognitive functions [18, 96], planning and problem-solving skills [69, 87], short- and long-term memory [36] and learning [78].

Defective migration in autism

Heterotopia is a sign of altered migration leading to an abnormal distribution of gray matter nodular masses with disorganized or rudimentary lamination within the periventricular area (periventricular heterotopia) or subcortical white matter (subcortical heterotopia) [2]. In the examined cohorts, heterotopia was detected in brains of four autistic subjects and in the brain of one control subject. Heterotopias are associated with mutations in the filamin 1 gene (FLNA1) [35, 42] and the chromosome X-linked DCX gene that codes for doublecortin, a protein expressed during embryogenesis in migrating neurons, and in the cortical plate [28, 40, 41], which is involved in the formation of microtubules necessary for neuronal migration [14]. Periventricular nodular heterotopia has been reported to be associated with pharmaco-resistant seizures in 80-90% of patients [29]. In the examined cohort, two periventricular heterotopias

were detected in the brain of a child with subependymal nodular dysplasia and seizures diagnosed at 14 months of age (B-6403). Early onset epilepsy, diagnosed at the age of 4.5 months might be related to the multiple heterotopias found within the frontal inferior gyrus, vermis and cerebellar white matter, coexisting with a focal cortical dysplasia and dentate gyrus dysplasia (B-5342).

Cortical, hippocampal and cerebellar dysplasia in autism

The most common form of developmental changes detected in the examined brains was focal dysplasia and observed in 11 (85%) of the autistic subjects. The morphology of focal dysplasias appears to reflect signs of abnormal migration, neuronal immaturity, and altered cell arrangement resulting in focal distortion of cytoarchitecture. In spite of similarities, the dysplastic changes in the neo- and archicortex, dentate gyrus and cornu Ammonis, and in the cerebellum also reveals a brain structure-specific patterns of dysplastic changes in autism.

Dysplasias encompass a spectrum of changes ranging from a mild form of cortical disruption, without cellular abnormalities, to the most severe form with cortical dyslamination, with abnormal morphology of neurons and astrocytes [82, 85, 94]. Focal cortical dysplasias with giant neurons and balloon cells [94, 98] are histopathologically similar to tubers containing giant cells in tuberous sclerosis complex [24, 65] suggesting a common pathogenic basis [98]. However, activation of the mammalian target of rapamycin (mTOR) pathway observed in the tuberous sclerosis complex is not present in focal cortical dysplasia [8, 71]. The giant neurons and ballooned cells, which are histopathological features of tuberous sclerosis and focal cortical dysplasia, were absent both in the subependymal nodules and in the focal cortical dysplasia observed in the examined autistic cohort. These findings suggest that in spite of similarities, the pathomechanisms of developmental alterations is different in the examined autistic subjects than that in tuberous sclerosis heterotopias or focal cortical dysplasia. The development of giant neurons- and ballooned cells-free dysplasias observed in the autistic subjects might be related to differences in cause and/or mechanism. The detection of changes similar to focal cortical dysplasia in association with prenatal ischaemia [57] or in shaken infant syndrome [66] may support these speculations.

In the examined brains of autistic subjects, signs of neuronal immaturity were a common finding. Failure of maturation of neuronal precursors caused by altered expression of cytoskeletal proteins and loss of neuronal polarity, results in defects of migration to the destined layer and incorrect vertical and horizontal orientation [82]. Immaturity of dysplastic neurons is reflected in the expression of a variety of proteins and mRNA that are not present in mature neurons, including nestin (embryonic intermediate filament protein), and cell cycle markers like Ki67 or cyclin D1. An immature neuronal phenotype is also associated with an altered expression of developmentally regulated cytoskeletal elements, such as α internexin [56], microtubule associated protein 1B (MAP1B) [22] and MAP2B [3, 67] known to be crucial for dendrite arborization, spine formation, axon outgrowth and maintenance of cell size and shape. Reduced cell size, dendritic arborization and spine expression are characteristic of dysplastic neurons [6, 82].

Cortical dysplasias are the most epileptogenic lesions of the brain [94] and are observed in up to 25% of all epileptic surgeries [90]. More subtle cortical malformations or dysgenesis encountered in adults with epilepsy may lack histological criteria for focal cortical dysplasia. They have been described as mild cortical dysplasia or microdysgenesis [68].

Microdysgenesis within the entorhinal cortex of the 23- and the 60-year old autistic subjects in examined cohort is unique because the selective deficit of neurons was limited almost exclusively to the stellate neurons in the second layer. It is possible that the observed dysgenesis is an result of defective migration of neurons to their intended destinations. The presence of a thicker molecular layer and deeper location of islands in the entorhinal cortex of subjects with schizophrenia was previously interpreted as evidence that the stellate neurons do not reach their destinations during development, probably due to abnormal migration [33, 53]. Studies indicating the involvement reelin and Bcl2 genes in the pathogenesis of schizophrenia [34, 43, 55] and reduced expression of reelin and Bcl2 in people with autism suggest that these two genes may play a role in abnormal brain development and contribute to the structural and functional anomalies seen in autism and schizophrenia [34].

The distortion of dentate gyrus development detected in two autistic subjects was reflected in granule cell migration into the molecular layer and formation of an additional granule cell layer. Distortion of the shape of the dentate granule cell layer with the formation of irregular circles and loops appears to be the another piece of evidence suggesting abnormal

neuronal migration and networking. Numerous factors up-regulate neurogenesis in the hippocampus [30] including seizures [62, 63], antidepressant drugs [54, 64] and lithium [17]. Several areas of dysplastic changes with a significant deficit of pyramidal neurons were found in the CA1 sector in three autistic subjects, but thickening of the pyramidal layer and an increased packing of dysplastic neurons in the CA1 sector of the 56-year old subject suggests a diversity of CA dysplasia patterns in autism. Lack of gliosis indicates that the observed pathology is a sign of microdysgenesis rather than an effect of hypoxic neuronal loss. A significant deficit of mature pyramidal neurons and the presence of small irregular or poorly differentiated oval neurons suggest the defect of neuronal maturation in autism.

We report a spectrum of focal developmental changes seen in the cerebellum of eight autistic subjects including: nodular (lobe X) [86] dysplasia in the cerebellum in five, vermal dysplasia in one, severe focal hypoplasia in one, and heterotopias present in another subject. The presence of heterotopia only in one control subject is evidence of a strong tendency for focal developmental changes of cerebellar microarchitecture that was present in 61% of the autistic subjects. Floculonodular dysplasia affecting almost the entire lobe indicates that mechanisms leading to focal dysplasia, that were present in five (38%) of the autistic subjects, show extremely strong topographic predilection. The observed focal dysplasia was associated with profound local disorganization of granule cells, Purkinje cells and molecular layers. However, the pathology was limited to a small cerebellar compartment with unknown clinical manifestations. Similar cerebellar dysplastic changes classified as heterotaxias (clusters of poorly-organized mixed cells) were identified in 14% of normal infants but in 83% of infants with trisomy of different chromosomes [81].

Identification of cohorts with signs of hyperplasia, hypoplasia and normal sized cerebellum [84] reflect heterogeneity of the autistic population. Piven et al., [77] reported that cerebellar volume correlates with an increased total brain volume. In the majority of autistic subjects, reduced size of the cerebellar hemisphere is observed [38, 73] but this trend is not detectable in cohorts of high functioning autistic individuals [52]. Regional hypoplasia affects the vermis in autistic individuals relatively often [19, 21, 48] and may be associated with deficits in attention-orienting [45, 91], stereotypic behavior and reduced exploration observed in autism [76]. In the examined autistic cohort, selective and severe hypoplasia of lobes 1-4 associated with hypoconvolution of a large portion of the dentate nucleus appears to correspond to clinically

detected defects of movement coordination. These findings suggest that differences in type, topography and severity of cerebellar developmental defects may contribute to different clinical manifestations.

In 4- to 7- year-old autistic children examined in this study, the volume of the Purkinje cells was smaller by 38% than that of the age-matched control group [97]. Moreover, it has been reported that Purkinje cells of the autistic subjects revealed a 40% decrease in the expression of glutamic acid decarboxylase 67 (GAD67) mRNA [99]. In autism, the basket cells provide an increased GABAergic feed-forward inhibition to Purkinje cells. The effect could be disruption in the timing of Purkinje cell firings and altered inhibition of the cerebellar nuclei, which could directly affect cerebello-cortical output, and contribute to the changes in motor behavior and cognition observed in autism [100]. These findings and the reduced volume (by 26%) of the neurons of the dentate nucleus seen in the 4-7 year old autistic children [97] suggest that in autism interactions between the Purkinje cells and dentate nucleus are modified on structural, molecular and functional levels.

The detected changes (a) within the subependymal germinal matrix with subependymal nodular dysplasia, (b) subcortical and periventricular heterotopias, and (c) neo- and archicortex, dentate gyrus and cornu Ammonis, and cerebellar dysplasia reflect focal modification of neurogenesis, migration and alterations of the cytoarchitecture of brain cortex, subcortical structures and cerebellum in autism. Detection of dysplastic changes only in one control brain and the broad spectrum of focal developmental alterations in the brain of 92% of the autistic subjects indicate that focal changes are a reflection of global developmental abnormalities and that regional changes may have own contribution to clinical heterogeneity of autism.

Acknowledgments

Tissue and clinical records acquisition was coordinated by The Autism Tissue Program (Princeton; Directors: Jane Pickett, Ph.D. and Daniel Lightfoot, Ph.D.). The tissue was obtained from the Harvard Brain Tissue Resource Center supported in part by PHS grant number R24-MH 068855, the Brain and Tissue Bank for Developmental Disorders of the National Institute of Child Health and Human Development at the University of Maryland, and Brain Bank at The New York State Institute for Basic Research in Developmental Disabilities, Staten Island, NY. We thank Drs. Helmut Hainsen and Christoph Schmitz for help in implementation of celloidin

protocol and Mrs. Jadwiga Wegiel, Cathy Wang, and En Wu Zhang for histology. We are deeply indebted to the families of tissue donors who have made this study possible.

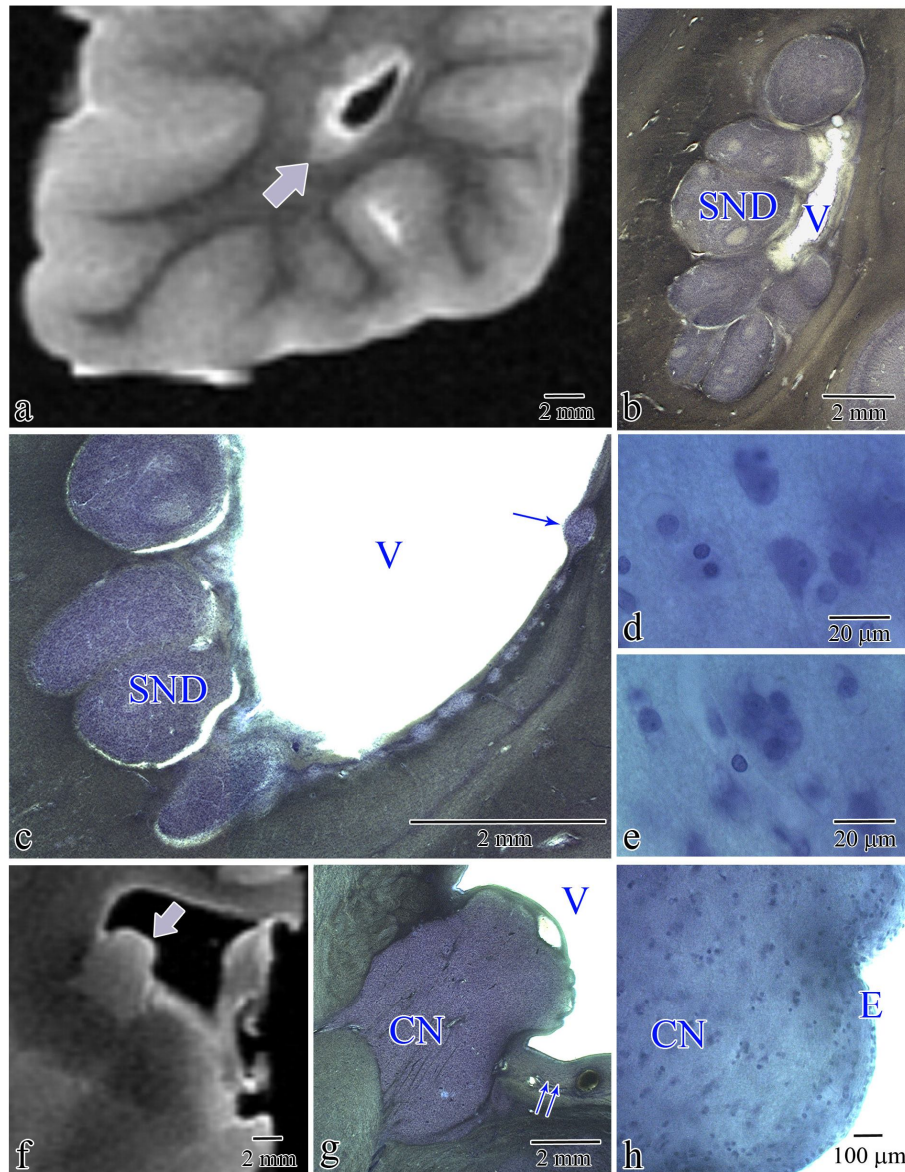


Fig. 1 Nodules in the wall of the lateral ventricle detected in postmortem MRI in the brain of 7-year old male diagnosed with autism (B-6403) revealed features of subependymal nodular dysplasia (SND; b) in examination of CV stained sections. Fig. 1c shows numerous large and small nodules (arrow) dispersed within subependymal germinal matrix. They contained a few

pyramidal-like neurons (d) and numerous poorly-differentiated cells (e). Tuber-like expansion of the caudate nucleus (arrow) into the ventricle lumen is shown in MRI (f) and in CV-stained section (g). Fig. 1g shows a thick layer of the subependymal germinal matrix above and below (two arrows) caudate nucleus (CN), and the absence of matrix in tuber-like area. Under ependymal (E) cap of the caudate nucleus (CN) tuber-like expansion a small poorly differentiated neurons are present (h).

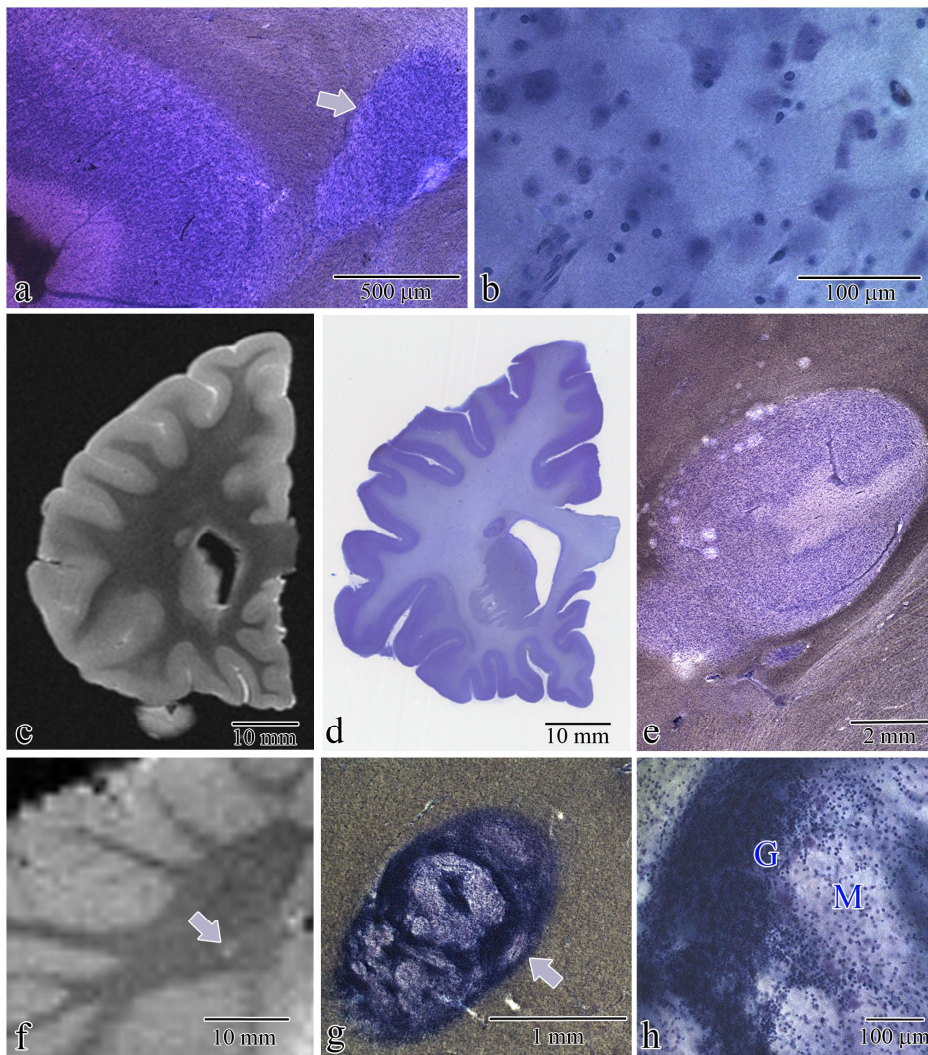


Fig. 2 Large subcortical heterotopia within anterior cingulate gyrus in 5-year old autistic child (UMB-1627) (a) contained dysplastic neurons without spatial orientation (b). Periventricular

heterotopia near the frontal horn of the lateral ventricle (fig. c: MRI; fig. d, e: CV-stained section) shows a structure resembling molecular, granule and pyramidal layers in 7-year old autistic subject (B-6403) (c). MRI (f), low (g) and large (h) magnification of heterotopia (arrow) with dysplastic granule (G) and molecular layer (M) detected within cerebellar white matter in 11-year old autistic subject (B-5342).

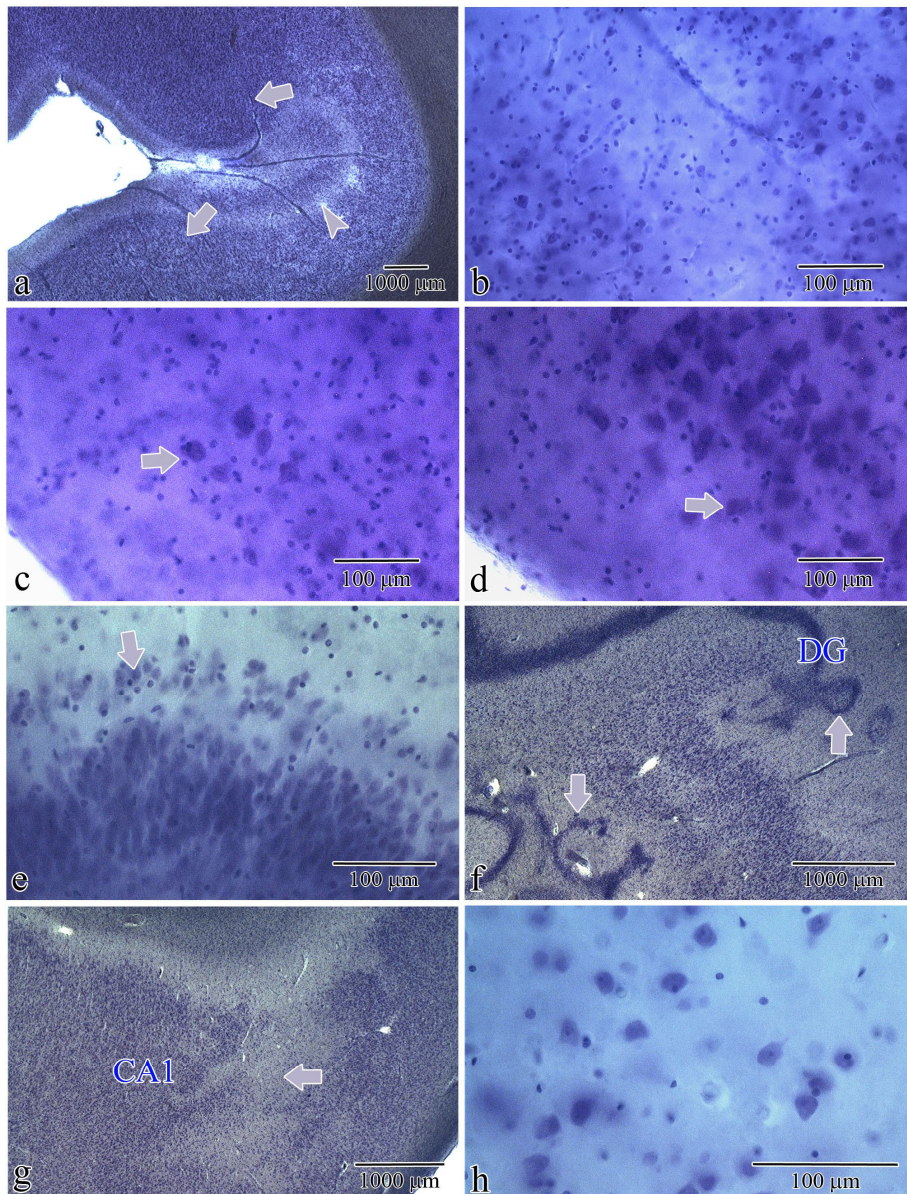


Fig. 3 Figure shows dysplastic changes within neocortex (Fig. a and b), entorhinal cortex (Fig. c and d), dentate gyrus (Fig. e and f) and the cornu Ammonis (Fig. g and h). Focal dysplasia in

frontal cortex with loss of vertical and horizontal cytoarchitecture (two arrows) and abnormal (arrowhead) laminar organization (a). Dysplastic neurons within affected area (B-6212) (b). Microdysgenesis within the entorhinal cortex with deficit of stellate neurons in the islands (c) and normal morphology of islands in adjacent cortex (d) in 60 year of age autistic subject (B-7090). Microdysgenesis of the dentate gyrus with dispersion of granule cells within molecular layer (e; arrow) and distortion of the granule cell layer shape (f, arrows) in 13 year of age autistic male (B-5535). CA1 sector microdysgenesis with local deficit of pyramidal neurons (g, arrow) without markers of gliosis but with signs of poor differentiation of dysplastic abnormally arranged neurons (h) in 13-year old autistic subject (B-5535).

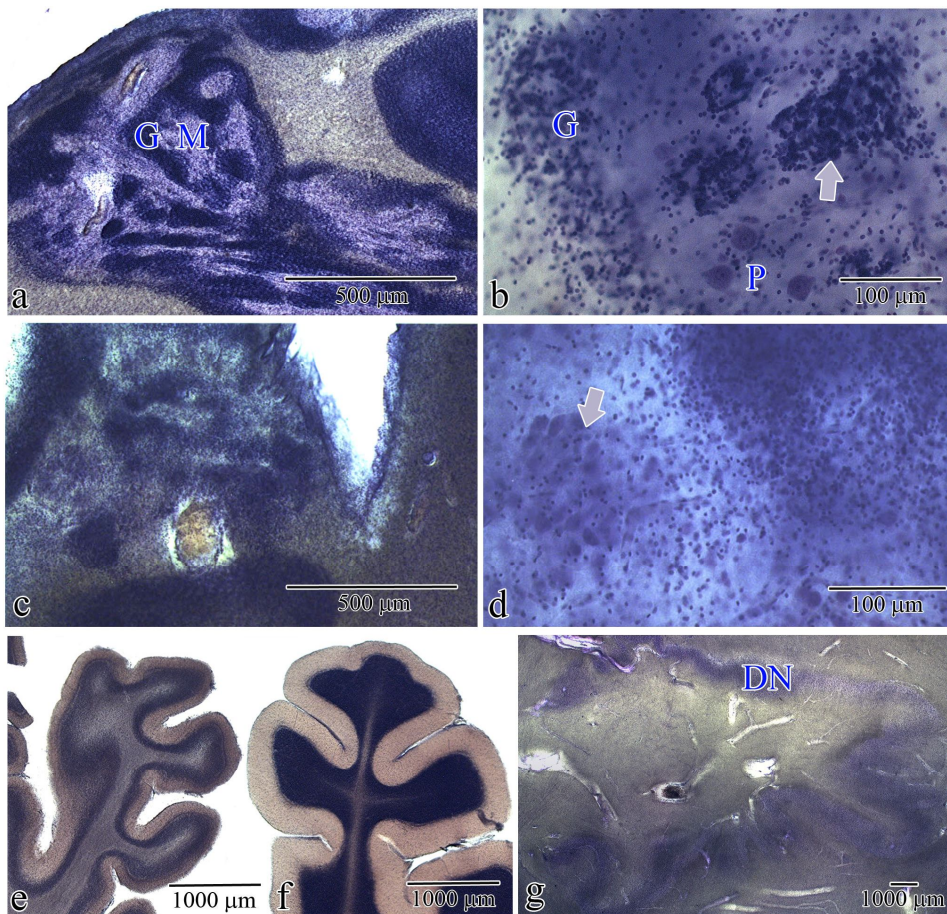


Fig. 4 Flocculodular dysplasia in cerebellum of 56-years old autistic subject (B-6276) (a) with thin irregular granule (G) and molecular (M) layer. Fig. b shows dysplastic granule layer (G), ectopic granule cells (arrow) in the molecular layer, and loosely dispersed Purkinje cells (P) (B-

6276). Cortical dysplasia within vermis of 13 year old autistic male (c) with dysplastic granule neurons mixed with heterotopic (arrow) large cells (d) (B-5535). Fig. 4e shows severe hypoplasia of cerebellar lobe 3 and unmodified lobe 6, respectively, within cerebellum of 60-year old autistic male (B-7090). In affected region thickness of hypoplastic molecular and granule cell layer was reduced by about 50%. Almost half of dentate nucleus (DN) was less convoluted than unaffected part (i).

Table 1 Material examined

#	Group	Brain Bank #	Sex	Age (y)	Cause of death	PMI (h)	H	Brain weight (g)
1	A	IBR425-02	M	4	Drowning	30	R	1,280
2	A	UMB-1627	F	5	Traumatic multiple injuries	13.2	R	1,390
3	A	B-6403	M	7	Drowning	25	R	1,610
4	A	B-5666	M	8	Rhabdomyosarcoma	22.2	R	1,570
5	A	B-5342	F	11	Drowning seizure related	12.9	L	1,460
6	A	B-5535	M	13	Seizure related	8	L	1,470
7	A	B-6115	F	17	Cardiac arrest related to cardiomyopathy	25	L	1,580
8	A	UMB-1638	F	21	Seizure related respiratory failure	50	R	1,108
9	A	B-6337	M	22	Seizure related	25	R	1,375
10	A	IBR93-01	M	23	Status epilepticus related respiratory failure	14	R	1,610
11	A	B-6212	M	36	Cardiac arrest	24	R	1,480
12	A	B-6276	M	56	Cardiac arrest	3.35	R	1,570
13	A	B-7090	M	60	Pancreatic cancer	26.5	R	1,210
1	C	B-6736	F	4	Acute bronchopneumonia	17	R	1,530
2	C	UMB-1499	F	4	Lymphocytic myocarditis	21	R	1,222
3	C	UMB-4898	M	7	Drowning	12	R	1,240
4	C	UMB-1708	F	8	Traumatic multiple injuries	20	R	1,222
5	C	BTB-3638	M	14	Electrocution	20	R	1,464
6	C	UMB-1843	F	15	Traumatic multiple injuries	9	R	1,250
7	C	UMB-1846	F	20	Traumatic multiple injuries	9	R	1,340
8	C	UMB-1646	M	23	Ruptured spleen	6	R	1,520
9	C	UMB-4543	M	29	Traumatic multiple injuries	13	R	1,514
10	C	UMB-1576	M	32	Traumatic compressional asphyxia	24	R	1,364
11	C	BTB-3899	M	48	Atherosclerotic heart disease	24	L	1,412
12	C	IBR252-02	M	51	Myocardial infarct	18	L	1,450
13	C	BTB-3983	M	52	Heart atherosclerosis	13	R	1,430
14	C	B-6874	M	64	Cardiac arrest	28	R	1,250

Table 2 Behavioral, and neurological signs in autistic subjects

Brain Bank #	Psychiatric disorders and neurological symptoms	Mental retardation (MR)	Seizures age of onset
IBR 425-02	Hyperactivity. Frequent tantrums. Self-injurious behavior	-	-
UMB-1627	Aggression.	-	-
B-6403		-	14 m
B-5666		-	Abnormal EEG without seizures
B-5342	Pervasive developmental disorder. Hyperlexia	Mild MR	4.5 m
B-5535	Hyperactivity. Self-injurious behavior including head banging.	Moderate to severe MR	2 y
B-6115	Sensory integration disorder	-	-
UMB-1638	ADHD	Moderate MR	5 y
B-6337	Obsessive compulsive disorder. Mania. Tourette syndrome. Socially offensive. Self-injurious behavior	MR	-
IBR93-01	Hyperactivity. Aggressive and self-injurious behavior.	Severe MR	23 y
B-6212	Obsessive compulsive disorder. Recurrent depression. Aggression, self-injurious behavior, and anxiety.	Severe MR	-
B-6276	Aggression and self-injurious behavior, anxiety, and agitation.	Moderate MR	-
B-7090	Disturbed movement coordination (walking like drunk).	MR	3 y

Table 3 Developmental abnormalities in brains of autistic subjects

Brain Bank #	Type and topography of developmental abnormalities
IBR425-02	No changes
UMB-1627	Focal neuronal heterotopia in white matter of the anterior cingulate gyrus.
B-6403	Subependymal nodular dysplasia in the wall of the occipital horn of the lateral ventricle. Two periventricular nodular heterotopias (2 and 4 mm in diameter) near the frontal horn of the lateral ventricle. Tuber-like expansion of the tail of caudate nucleus into the lumen of the lateral ventricle. Flocculonodular dysplasia affecting almost entire lobe.
B-5666	Cortical dysplasia in the middle and inferior temporal gyri with focal dyslamination, with clustering of dystrophic neurons and local neuronal deficit by up to 80%. Several focal dysplastic changes within CA with irregular loose neuronal aggregates or multilayer neuronal formations. Very significant neuronal dysplasia with change of size, shape and spatial orientation of all neurons within affected areas. Flocculonodular dysplasia affecting almost entire lobe.
B-5342	Focal cortical dysplasia. Dysplasia of the granule layer of the dentate gyrus. Subcortical heterotopia in the inferior frontal gyrus. Heterotopia in vermis and in cerebellar white matter.
B-5535	Thickening of the subependymal germinal zone. Focal dysplasia within CA1 pyramidal layer with neuronal deficit, and loss of pyramidal neurons morphology and spatial orientation. Multifocal dysplasia of the dentate gyrus with distortion of the shape of granule and molecular cell layers (loops, circles and other forms of dysfiguration). Focal dysplasia within vermis.
B-6115	Flocculonodular dysplasia affecting the majority of lobe volume. Angioma within occipital cortex.
UMB-1638	Focal dysplasia within CA1 with diffuse neuronal deficit but without glial activation.
B-6337	Minor focal flocculonodular dysplasia.
IBR93-01	Focal dysplasia within islands in the entorhinal cortex. Pineal gland cysts.
B-6212	Several areas of focal cortical dysplasia within frontal cortex (2.4 mm long) and insula (more than 2.4 mm long) with local loss of vertical and horizontal organization. Merger of ventral portion of the claustrum with insula. Flocculonodular dysplasia affecting the majority of lobe volume.
B-6276	Focal dysplasia within CA1 sector with clustering of dysplastic neurons or focal neuronal deficit. Focal heterotopia within stratum oriens. Flocculonodular dysplasia affecting approximately 70% of the lobe.
B-7090	Three focal dysplasias in the frontal cortex. Dysplasia of layers 1-3 in the entorhinal cortex with missing numerous islands of the stellate neurons. Severe hypoplasia of cerebellar lobes 1-4 with reduction of volume of the molecular and granule cell layers by half and deficit of Purkinje cells. Reduced convolutions within almost half of the dentate nucleus.

References

1. American Psychiatric Association (2000) Diagnostic and Statistical Manual of Mental Disorders DSM-IV-TR. American Psychiatric Association Washington, DC.
2. Andrade D M (2009) Genetic basis in epilepsies caused by malformations of cortical development and in those with structurally normal brain. *Hum Genet* 126:173-193
3. Avila J, Dominguez J, Diaz-Nido J (1994) Regulation of microtubule dynamics by microtubule-associated protein expression and phosphorylation during neuronal development. *Int J Dev Biol* 38:13-25.
4. Bailey A P, Luthert A, Dean B, et al (1998) A clinicopathological study of autism. *Brain* 121:889-905.
5. Bailey A R, Giunta BN, Obregon D, et al (2008) Peripheral biomarkers in Autism: secreted amyloid precursor protein-alpha as a probable key player in early diagnosis. *Int J Clin Exp Med* 1:338-344.
6. Barth P G, (1987) Disorders of neuronal migration. *Can J Neurol Sci.* 14:1-16.
7. Bauman M L, Kemper TL (1985) Histoanatomic observations of the brain in early infantile autism. *Neurology* 35:866-867.
8. Baybis M, Yu J, Lee A, Golden JA, et al (2004) mTOR cascade activation distinguishes tubers from focal cortical dysplasia. *Ann Neurol* 56:478-487
9. Bobinski M, de Leon MJ, Convit A, et al (1999) MRI of entorhinal cortex in mild Alzheimer's disease. *Lancet* 353:38-40.
10. Boddaert N, M. Zilbovicius, A. Philipe, et al (2009) MRI findings in 77 children with non-syndromic autistic disorder. *PLoS One* 4:e4415.
11. Carlson B A, Houser OW, Gomez MR (1999) Brain Imaging in the tuberous sclerosis complex. In: Gomez M, Sampson J, Whittemore V, (ed) *Tuberous sclerosis complex*, 3rd edn. Oxford University Press, New York, New York, pp 85-93

12. Casanova M F, Buxhoeveden DP, Switala AE, Roy E (2002) Minicolumnar pathology in autism. *Neurology* 58:428-432
13. Casanova M F, van Kooten I AE, Switala E H, et al (2006) Minicolumnar abnormalities in autism. *Acta Neuropathol* 112:287-303
14. Caspi M, Atlas R, Kantor A, Sapir T, Reiner O (2000) Interaction between LIS1 and doublecortin, two lissencephaly gene products. *Hum Mol Genet* 9:2205-2213
15. Chang B S, Walsh CA (2009) The genetic basis of human cerebral cortical malformations. In: Runge MS, Patterson C (ed) *Principles of Molecular Medicine Human Press Inc, Totowa, New Jersey* pp1073-1079.
16. Chauhan A, Chauhan V (2006) Oxidative stress in autism. *Pathophysiology* 13:171-181
17. Chen G, Rajkowska G, Du F, Seraji-Bozorgzad N, Manji NH (2000) Enhancement of hippocampal neurogenesis by lithium. *J Neurochem* 75:1729-1734.
18. Chow T W, Cummings JL (1999) Frontal-subcortical circuits. In: Miller BL, Cummings JL, (ed) *The Human Frontal Lobes: Functions and Disorders*. Guilford Press, New York. pp 3-26
19. Ciesielski K T, Harris RJ, Hart BL, and Pabst H (1997) Cerebellar hypoplasia and frontal lobe cognitive deficits in disorders of early childhood. *Neuropsychologia* 35:643-655.
20. Courchesne E, Hesselink JR, Jernigan TL, Yeung-Courchesne R (1987) Abnormal neuroanatomy in a nonretarded person with autism unusual findings with magnetic resonance imaging. *Arch Neurol* 44:335-341
21. Courchesne E, Yeung-Courchesne R, Press GA, Hesselink JR, Jernigan TL (1988) Hypoplasia of cerebellar vermal lobules VI and VII in autism. *N Engl J Med* 318:1349-1354
22. Crino P B, Trojanowski JQ, Eberwine J (1997) Internexin, MAP1B, and nestin in cortical dysplasia as markers of developmental maturity. *Acta Neuropathol* 93:619-627

23. Crino P B, Henske EP (1999) New developments in the neurobiology of the tuberous sclerosis complex. *Neurology* 53:1384-1390
24. Crino P B, Miyata H, Vinters HV (2002) Neurodevelopmental disorders as a cause of seizures: neuropathologic, genetic, and mechanistic considerations. *Brain Pathol* 12:212-233
25. Curtis M A, Penney EB, Pearson J, Dragunow M, Connor B, Faull RL, (2005) The distribution of progenitor cells in the subependymal layer of the lateral ventricle in the normal and Huntington's disease human brain. *Neuroscience* 132:777-788
26. Damasio H, Maurer RG, Damasio AR, Chui HC (1980) Computerized tomographic scan findings in patients with autistic behavior. *Arch. Neurol.* 37:504-510
27. Department of Health and Human Services (2007) Morbidity and mortality weekly report. In: Department of Health and Human Services, Centers for Disease Control and Prevention, pp1-28
28. des Portes V, Francis F, Pinard JM, et al (1998) doublecortin is the major gene causing X-linked subcortical laminar heterotopia (SCLH). *Hum Mol Genet* 7:1063-1070
29. Dubeau F, Tampieri D, Lee N, et al (1995) Periventricular and subcortical nodular heterotopia: a study of 33 patients. *Brain* 118:1273-1287
30. Duman R S, Nakagawa S, Malberg J. (2001) Regulation of adult neurogenesis by antidepressant treatment. *Neuropsychopharmacology* 25:836-844
31. Eriksson P S, Perfilieva E, Bjork-Eriksson T, et al (1998) Neurogenesis in the adult human hippocampus. *Nat Med* 4:1313-1317
32. Ess K C, Kamp CA, Tu BP, Gutmann DH (2005) Developmental origin of subependymal giant cell astrocytoma in tuberous sclerosis complex. *Neurology* 64:1446-1449

33. Falkai P, Schneider-Axmann T, Honer WG (2000) Entorhinal cortex pre-alpha cell clusters in schizophrenia: quantitative evidence of a developmental abnormality. *Biol Psychiatry* 47:937-943
34. Fatemi S H, Kroll JL, Strydom JM (2001) Altered levels of Reelin and its isoforms in schizophrenia and mood disorders. *Neuroreport* 12:3209-3215
35. Fox J W, E. D. Lamperti ED, Eksioglu YZ (1998) Mutations in filamin 1 prevent migration of cerebral cortical neurons in human periventricular heterotopia. *Neuron* 21:1315-1325
36. Fuh J L, Wang SJ (1995) Caudate hemorrhage: clinical features, neuropsychological assessments and radiological findings. *Clin Neurol Neurosurg* 97:296-299
37. Gabriels R L, Cuccaro ML, Hill DE, Ivers BJ, E. Goldson E (2005) Repetitive behaviors in autism: relationships with associated clinical features. *Res Dev Disabil* 26:169-181
38. Gaffney G R, Tsai LY, Kuperman S, Minchin S (1987) Cerebellar structure in autism. *Am J Dis Child* 141:1330-1332
39. Gillberg C, Coleman M. (1996) Autism and medical disorders: a review of the literature. *Dev Med Child Neurol* 38:191-202
40. Gleeson J G, Allen KM, Fox JW, (1998) Doublecortin, a brain-specific gene mutated in human X-linked lissencephaly and double cortex syndrome, encodes a putative signaling protein. *Cell* 92:63-72
41. Gleeson J G, Lin PT, Flanagan LA, Walsh CA. (1999) Doublecortin is a microtubule-associated protein and is expressed widely by migrating neurons. *Neuron* 23:257-271
42. Gorlin, J B, Henske E, Warren ST (1993) Actin-binding protein (ABP-280) filamin gene (FLN) maps telomeric to the color vision locus (R/GCP) and centromeric to G6PD in Xq28. *Genomics* 17:496-498

43. Guidotti A, Auta J, Davis JM (2000) Decrease in reelin and glutamic acid decarboxylase67 (GAD67) expression in schizophrenia and bipolar disorder: a postmortem brain study. *Arch Gen Psychiatry* 57:1061-1069
44. Happe F, Ronald A, Plomin R (2006) Time to give up on a single explanation for autism. *Nat Neurosci* 9:1218-1220
45. Harris N S, Courchesne E, Townsend J, Carper RA, Lord C (1999) Neuroanatomic contributions to slowed orienting of attention in children with autism. *Brain Res Cogn Brain Res* 8:61-71
46. Hashimoto T, Tayama M, Mori K, Fujino K, Miyazaki M, Kuroda Y (1989) Magnetic resonance imaging in autism: preliminary report. *Neuropediatrics* 20:142-146
47. Hashimoto T, Tayama M, Miyazaki M, Murakawa K, Kuroda Y (1993) Brainstem and cerebellar vermis involvement in autistic children. *J Child Neurol* 8:149-153
48. Hashimoto, T, Tayama M, Murakawa K, Yoshimoto T, Miyazaki M, Harada M, Kuroda Y (1995) Development of the brainstem and cerebellum in autistic patients. *J. Autism Dev. Disord.* 25:1-18
49. Heinsen H, Arzberger T, Schmitz C, (2000) Celloidin mounting (embedding without infiltration) - a new, simple and reliable method for producing serial sections of high thickness through complete human brains and its application to stereological and immunohistochemical investigations. *J Chem Neuroanatomy* 20:49-59
50. Herbert M R, Ziegler DA, Deutsch CK (2003) Dissociations of cerebral cortex, subcortical and cerebral white matter volumes in autistic boys. *Brain* 126:1182-1192
51. Hollander E, Anagnostou E, Chaplin W (2005) Striatal volume on magnetic resonance imaging and repetitive behaviors in autism. *Biol. Psychiatry* 58:226-232
52. Holttum J R, Minshew NJ, Sanders RS, Phillips NE. 1992. Magnetic resonance imaging of the posterior fossa in autism. *Biol Psychiatry* 32:1091-1101

53. Honer W G, Bassett AS, Falkai P, Beach TG, and Lapointe JS (1996) A case study of temporal lobe development in familial schizophrenia. *Psychol Med* 26:191-195
54. Jacobs B L, Fornal CA, (1999) Activity of serotonergic neurons in behaving animals. *Neuropsychopharmacology* 21:9S-15S
55. Jarskog L F, Gilmore JH, Selinger ES, Lieberman JA (2000) Cortical bcl-2 protein expression and apoptotic regulation in schizophrenia. *Biol Psychiatry* 48:641-650
56. Kaplan M P, Chin SS, Fliegner KH, Liem RK (1990) Alpha-internexin, a novel neuronal intermediate filament protein, precedes the low molecular weight neurofilament protein (NF-L) in the developing rat brain. *J Neurosci* 10:2735-2748
57. Kremer S, De Saint MA, Minotti L et al (2002) Focal cortical dysplasia possibly related to a probable prenatal ischemic injury. *J Neuroradiol* 29:200-203
58. Langen M, Durston S, Staal WG, Palmen SJ, van Engelan H (2007) Caudate nucleus is enlarged in high-functioning medication-naive subjects with autism. *Biol Psychiatry* 62:262-266
59. Lee A, Maldonado M, Baybis M, et al (2003) Markers of cellular proliferation are expressed in cortical tubers. *Ann. Neurol.* 53:668-673
60. Lopez-Hurtado E, Prieto JJ (2008) A microscopic study of language-related cortex in autism. *Am J Biochem Biotechn* 4:130-145
61. Lord C, Risi S, Lambrecht L, et al (2000) The autism diagnostic observation schedule-generic: a standard measure of social and communication deficits associated with the spectrum of autism. *J. Autism Dev. Disord.* 30:205-223
62. Madsen T M, Treschow A, Bengzon J, Bolwig TG, Lindvall O, Tingstrom A. (2000) Increased neurogenesis in a model of electroconvulsive therapy. *Biol. Psychiatry* 47:1043-1049

63. Malberg JE, Eisch AJ, Nestler EJ, Duman RS (2000) Chronic antidepressant treatment increases neurogenesis in adult rat hippocampus. *J Neurosci* 20:9104-9110
64. Manev H, Uz T, Smalheiser NR, Manev R (2001) Antidepressants alter cell proliferation in the adult brain in vivo and in neural cultures in vitro. *Eur J Pharmacol* 411:67-70
65. Marcotte L, Crino PB (2006) The neurobiology of the tuberous sclerosis complex. *Neuromolecular Med.* 8:531-546
66. Marin-Padilla M, Parisi JE, Armstrong DL, Sargent SK, Kaplan JA (2002) Shaken infant syndrome: developmental neuropathology, progressive cortical dysplasia, and epilepsy. *Acta Neuropathol* 103:321-332
67. Matus A (1988) Microtubule-associated proteins: their potential role in determining neuronal morphology. *Ann Rev Neurosci* 11:29-44
68. MeenckeHJ, Janz D (1985) The significance of microdysgenesis in primary generalized epilepsy: an answer to the considerations of Lyon and Gastaut. *Epilepsia* 26:368-371
69. Mendez M F, Adams NL, Lewandowski KS (1989) Neurobehavioral changes associated with caudate lesions. *Neurology* 39:349-354
70. Miles J H, Takahashi TN, Bagby S et al (2005) Essential versus complex autism: definition of fundamental prognostic subtypes. *Am J Med Genet A* 135:171-180
71. Miyata H, Chiang AC, and Vinters H (2004) Insulin signaling pathways in cortical dysplasia and TSC-tubers: tissue microarray analysis. *Ann Neurol* 56:510-519
72. Muller R A, (2007) The study of autism as a distributed disorder. *Ment Retard Dev Disabil Res Rev* 13:85-95
73. Murakami J W, Courchesne E, Press GA, Yeung-Courchesne R, Hesselink JR (1989) Reduced cerebellar hemisphere size and its relationship to vermal hypoplasia in autism. *Arch Neurol* 46:689-694

74. Newschaffer C J, Fallin D, LeeNL (2002) Heritable and nonheritable risk factors for autism spectrum disorders. *Epidemiol Rev* 24:137-153
75. Palmen S J, van Engelan H, Hof PR, Schmitz C (2004) Neuropathological findings in autism. *Brain* 127:2572-2583
76. Pierce K, Courchesne E (2001) Evidence for a cerebellar role in reduced exploration and stereotyped behavior in autism. *Biol Psychiatry* 49:655-664
77. Piven J, Saliba K, Bailey J, Arndt S (1997) An MRI study of autism: the cerebellum revisited. *Neurology* 49:546-551
78. Poldrack R A, Prabhakaran V, Seger CA, Gabrieli JD (1999) Striatal activation during acquisition of a cognitive skill. *Neuropsychology* 13:564-574
79. Redcay E, Courchesne E (2005) When is the brain enlarged in autism? A meta-analysis of all brain size reports. *Biol Psychiatry* 58:1-9
80. Ritvo ER, Freeman BJ, Scheibel AB, et al (1986) Lower Purkinje cell counts in the cerebella of four autistic subjects: initial findings of the UCLA-NSAC Autopsy Research Report. *Am. J. Psychiatry* 143:862-866
81. Rorke L B, Fogelson MH, Riggs HE (1968) Cerebellar heterotopia in infancy. *Dev Med Child Neurol* 10:644-650
82. Rorke LB (1994) A perspective: the role of disordered genetic control of neurogenesis in the pathogenesis of migration disorders. *J Neuropathol Exp. Neurol.* 53:105-117
83. Rutter M, Bailey A, Bolton P, Le Couteur A (1994) Autism and known medical conditions: myth and substance. *J Child Psychol Psychiatry* 35:311-322
84. Saitoh O, Courchesne E (1998) Magnetic resonance imaging study of the brain in autism. *Psychiatry Clin Neurosci* 52 Suppl: S219-S222
85. Sarnat H B, Benjamin DR, Siebert JR, et al (1992) Cerebral dysgenesis: embryology and clinical expression. *Cell* 69:581-595

86. Schmahmann J D, Doyon J, McDonald D, et al (1999) Three-dimensional MRI atlas of the human cerebellum in proportional stereotaxic space. *Neuroimage* 10:233-260
87. Schmidtke K, Manner H, Kaufmann R, Schmolck H (2002) Cognitive procedural learning in patients with fronto-striatal lesions. *Learn Mem* 9:419-429
88. Sears L L, Vest C, Mohamed S, Bailey J, Ranson BJ, Piven J (1999) An MRI study of the basal ganglia in autism. *Prog Neuropsychopharmacol Biol Psychiatry* 23:613-624
89. Sokol D K, Chen D, Farlow MR, et al (2006) High levels of Alzheimer beta-amyloid precursor protein (APP) in children with severely autistic behavior and aggression. *J Child Neurol* 21:444-449
90. Tassi L, Colombo N, Garbelli R, et al (2002) Focal cortical dysplasia: neuropathological subtypes, EEG, neuroimaging and surgical outcome. *Brain* 125:1719-1732
91. Townsend J, Courchesne E, Covington J, et al (1999) Spatial attention deficits in patients with acquired or developmental cerebellar abnormality. *J Neurosci* 19:5632-5643
92. Tuchman R F, Rapin I, Shinnar S (1991) Autistic and dysphasic children. I: clinical characteristics. *Pediatrics* 88:1211-1218
93. Tuchman R F, Rapin I, (2002) Epilepsy in autism. *Lancet Neurol* 1:352-358
94. Usui, N, Matsuda K, Mihara T, et al (2001) MRI of cortical dysplasia-correlation with pathological findings. *Neuroradiology* 43:830-837
95. van Kooten I, Palmen SJ, von Engelan CP, et al (2008) Neurons in the fusiform gyrus are fewer and smaller in autism. *Brain* 131:987-999
96. Voelbel G T, Bates ME, Buckman JF, Pandina G, Hendren RL (2006) Caudate nucleus volume and cognitive performance: Are they related in childhood psychopathology? *Biol Psychiatry* 60:942-950
97. Wegiel J, Wisniewski T, Chauchan A, et al (2009) Type, topography and sequelae of

- neuropathological changes shaping clinical phenotype of autism. In: Autism: Oxidative Stress, Inflammation, and Immune Abnormalities. Ed.: Abha Chauhan, Ved Chauhan and W. Ted Brown. Taylor & Francis/CRC Press, Boca Raton, FL
98. Wolf H K, Normann S, Green AJ, et al (1997) Tuberos sclerosis-like lesions in epileptogenic human neocortex lack allelic loss at the TSC1 and TSC2 regions. *Acta Neuropathol* 93:93-96
 99. Yip J, Soghomonian JJ, Blatt GJ (2007) Decreased GAD67 mRNA levels in cerebellar Purkinje cells in autism: pathophysiological implications. *Acta Neuropathol* 113:559-568
 100. Yip JJ, Soghomonian J, Blatt GJ (2008) Increased GAD67 mRNA expression in cerebellar interneurons in autism: implications for Purkinje cell dysfunction. *J Neurosci Res* 86:525-530

1. **Title:** Delayed development of neurons in networks involved with stereotypic behaviors and reward in autism.

Authors: Krzysztof Nowicki MD¹, Izabela Kuchna, MD, PhD¹, Jarek Wegiel, BA, MS¹, Shang Yong Ma, MD, PhD¹, Thomas Wisniewski, MD¹, Ira L Cohen, PhD², Eric London, MD², Michael Flory, PhD³, W Ted Brown, MD, PhD⁴, Jerzy Wegiel, PhD¹
¹Developmental Neurobiology, ²Psychology, ³Research Design, ⁴Human Genetics, New York State Institute for Basic Research in Developmental Disabilities, 1050 Forest Hill Road, Staten Island, NY 10314

Background: Autism signs include lower-order repetitive motor behaviors, intense circumscribed patterns of interests, and higher-order rituals and compulsions that occur regularly and interfere with daily functioning (Gabriels et al., 2005). Several studies have implicated the role of basal ganglia and frontostriatal circuitry in the pathophysiology of autism, especially in repetitive and stereotyped behaviors. Increased volume of the basal ganglia was reported in several MRI studies (Herbert et al., 2003; Hollander et al., 2005; Langen et al., 2007; Sears et al., 1999). However, the nature of cellular changes in the basal ganglia is unknown.

Objectives: We suggest that the application of sensitive, unbiased morphometric methods may reveal cellular developmental changes in the striatum that contribute to the restricted repetitive and stereotyped behavior in autistic subjects. The presence of changes in the nucleus accumbens could be an indicator of the abnormal function of the reward system. We hypothesize also that changes in the reward system may amplify repetitive and stereotyped behaviors in early childhood.

Methods: To test this hypothesis, we examined the caudate nucleus, putamen and globus pallidus, contributing to restricted repetitive and stereotyped behaviors, and the nucleus accumbens, which is a component of the reward system, in the brains of 14 subjects diagnosed with idiopathic autism and of 14 age-matched controls. The Cavalieri method was applied to evaluate the volume of the examined structures; the fractionator method, to estimate the number of neurons; and a nucleator, to estimate the volume of neurons and nuclei.

Results: Our study showed a significantly smaller size of neurons in the caudate, putamen, and globus pallidus in the brains of autistic children 4 - 8 years of age. This suggests a developmental delay in the growth of neurons, which may contribute to the dysfunction of all components of the basal ganglia network. The significant developmental delay of neuron growth in the nucleus accumbens suggests that the reward system is also affected.

Conclusion: Our results provide new evidence that developmental abnormalities in the striatal circuitry contribute to repetitive and stereotyped behaviors and that developmental changes in the nucleus accumbens may enhance engagement in rituals and stereotyped behavior.

Sponsors: Autism Speaks, the Department of Defense Autism Spectrum Disorders Research Program (AS073234), and the NYS Office of Mental Retardation and Developmental Disabilities. The Harvard Brain Tissue Resource Center (R24-MH 068855), and the Brain and Tissue Bank at the University of Maryland, Baltimore, provided tissue. The Autism Tissue Program coordinated tissue acquisition.

2. **Title:** Developmental heterochronicity of neuron growth in the memory system of autistic subjects.

Authors: Izabela Kuchna, MD, PhD¹, Krzysztof Nowicki MD¹, Jarek Wegiel, BA, MS¹, Shang Yong Ma, MD, PhD¹, Thomas Wisniewski, MD¹, Ira L Cohen, PhD², Eric London, MD², Michael Flory, PhD³, W Ted Brown, MD, PhD⁴, Jerzy Wegiel, PhD¹
¹Developmental Neurobiology, ²Psychology, ³Research Design, ⁴Human Genetics, New York State Institute for Basic Research in Developmental Disabilities, 1050 Forest Hill Road, Staten Island, NY 10314

Background: Reduced volume of both the hippocampal formation and the amygdala were noted in subjects examined by Aylward et al. (1999), but not in populations examined by other researchers (Piven et al., 1998). Smaller and more densely packed neurons were found in various portions of the hippocampal formation, entorhinal cortex and medial nuclei of the amygdala (Bauman and Kemper, 1985; Kemper and Bauman, 1993).

Objectives: We hypothesize that postmortem morphometric studies will help to identify the type, distribution and severity of developmental abnormalities in major components of the memory system. These may contribute to memory system abnormalities in a structure-specific way. The entorhinal cortex is a developmental hybrid providing major input from association cortices and the amygdala to the hippocampus. The hippocampus is involved in processing and storage of information. The amygdala is the component of the memory system that processes social and emotional signals.

Methods: To test this hypothesis, we examined neurons in entorhinal cortex layers II, III, V and VI; in cornu Ammonis sectors 1, 2, 3 and 4; and in four nuclei of the amygdala of 10 autistic and 10 control subjects 4 to 56 years of age. Unbiased morphometric methods of estimation of brain structure volume, number of neurons and volume of neurons and neuronal nuclei were applied.

Results: Finding a reduced size of neurons in 4 to 8 years old children in layer II (islands) by 20%, in layer III by 33%, and layers V and VI by 33% and 26%, respectively, and a similar range of reduction of size of neurons in the amygdala (from 22% in accessory basal to 34% in basal nucleus), but the lack of a significant difference in the volume of neurons in all four sectors of the cornu Ammonis suggests that the memory system is affected in an early stage of brain development but in a structure-specific way.

Conclusions: The cornu Ammonis does not show a pattern of cortical and basal ganglia developmental delay. Selective preservation of the developmental pattern of neurons in the cornu Ammonis involved in storage of information from affected structures including the entorhinal cortex and amygdala may help explain memory abnormalities mixed with restricted interests and abilities.

Sponsors: Autism Speaks, the Department of Defense Autism Spectrum Disorders Research Program (AS073234), and the NYS Office of Mental Retardation and Developmental Disabilities. The Harvard Brain Tissue Resource Center (R24-MH 068855), and the Brain and Tissue Bank at the University of Maryland, Baltimore, provided tissue. The Autism Tissue Program coordinated tissue acquisition.

3. **Title:** Contribution of thalamic developmental changes to the autistic phenotype.

Authors: Shuang Yong Ma, MD, PhD¹, Izabela Kuchna, MD, PhD¹, Krzysztof Nowicki MD¹, Jarek Wegiel, MS¹, Thomas Wisniewski, MD¹, Ira L Cohen, PhD², Eric London, MD², Michael Flory, PhD³, W Ted Brown, MD, PhD⁴, Jerzy Wegiel, PhD¹

¹Developmental Neurobiology, ²Psychology, ³Research Design, ⁴Human Genetics, New York State Institute for Basic Research in Developmental Disabilities, 1050 Forest Hill Road, Staten Island, NY 10314

Background: Some clinical signs of autism, such as verbal and nonverbal communication deficits, sensory abnormalities, skeletal muscle hypotonia, and cognition could be a result of developmental abnormalities in the thalamus. The lateral thalamus is closely related to language function including mechanical processes for articulation and respiration (Ojemann, 1971, 1977; Oke et al., 1978). The thalamus is involved in sensory (pain) and motor function and cognition, including memory. Pallidal input to the thalamus serves to control muscle tone. These data indicate that the thalamus may contribute to the clinical signs of autism.

Objectives: We assume that the thalamus, interacting with the neocortex and entorhinal cortex, and very closely with the amygdala and the striatal system, may have its own developmental changes contributing to motor, sensory and language deficits observed in autism. The goal of this study is to determine whether the thalamus is affected by a similar neuronal developmental delay as are the basal ganglia and cortex.

Methods: In the human thalamus, more than 50 subnuclei with specific connectivities have been identified. To detect a global pattern of neuronal development and maturation in the thalamus, rather than thalamic subregion - specific characteristics, the mean volume of neurons and neuronal nuclei was determined in the entire thalamus in 7 autistic and 7 control subjects 4 to 23 years of age. Unbiased morphometric methods of estimation of thalamic volume, number of neurons, and volume of neurons and neuronal nuclei were applied.

Results: The volume of the thalamus in autistic and control subjects is the same. However, the mean volume of neuronal soma in 4- to 8- year old children was 27% less in autistic subjects than in controls, but the difference was undetectable in older children and young adults (11-23 years old). The volume of neuronal nuclei in the youngest autistic children was reduced by 37%, whereas in older subjects, it was insignificantly higher than in controls.

Conclusions: A smaller volume of the cell body and cell nucleus in thalamic neurons in the youngest autistic children and an almost normal size in late childhood and adulthood suggests a significant delay of neuronal growth in the early stages of brain development and acceleration of growth in late childhood compensating for developmental deficits. The presence of a similar developmental delay of neuronal growth in the thalamus and the neuronal networks interacting with the thalamus suggests that each component of these complex neuronal networks may make its own contribution to the clinical phenotype of autism.

Sponsors: Autism Speaks, the Department of Defense Autism Spectrum Disorders Research Program (AS073234), and the NYS Office of Mental Retardation and Developmental Disabilities. The Harvard Brain Tissue Resource Center (R24-MH 068855), and the Brain and Tissue Bank at the University of Maryland, Baltimore, provided tissue. The Autism Tissue Program coordinated tissue acquisition.

4. **Title:** Emerging patterns of neuronal growth desynchronization in autism.

Authors: Jerzy Wegiel, PhD¹, Izabela Kuchna, MD, PhD¹, Krzysztof Nowicki MD¹, Jarek Wegiel, BA, MS¹, Shang Yong Ma, MD, PhD¹, Humi Imaki, PhD¹, Thomas Wisniewski, MD¹, Ira L Cohen, PhD², Eric London, MD², Michael Flory, PhD³, W Ted Brown, MD, PhD⁴

¹Developmental Neurobiology, ²Psychology, ³Research Design, ⁴Human Genetics, New York State Institute for Basic Research in Developmental Disabilities, 1050 Forest Hill Road, Staten Island, NY 10314

Background: Pathological acceleration of brain growth in the first year of life and deceleration in the second and third year appear to play a pivotal role in the onset of clinical signs of autism (Courchesne et al., 2001, 2003; Courchesne and Pierce, 2005). Distortions of brain development are reflected in abnormal neuronal development and cortical minicolumn organization (Casanova et al 2002, 2006), and local dysgenesis (Bauman and Kemper, 1995, 1996; Kemper and Bauman 1993, 1998).

Objectives: We hypothesize that the (a) acceleration and deceleration of brain growth is a reflection of developmental cellular pathology, (b) acceleration of brain growth results in production of immature and smaller than normal neurons, (c) deceleration of brain growth results in acceleration of growth of neurons, (d) desynchronization of the growth of neurons in the brain in early childhood may play a critical role in shaping the clinical manifestations of autism.

Methods: To characterize sequential age and brain-subdivision-specific patterns of neuronal growth, 11 major subdivisions of the brain in one brain hemisphere of 14 autistic and 14 control subjects 4 to 56 years of age were examined. Unbiased morphometric methods of estimation of brain structure were applied, including the Cavalieri method, fractionator, and nucleator (Microbrightfield).

Results: Early childhood (4 - 8 years) was the period of significant delay of neuronal growth in the majority of examined brain structures including four nuclei of the amygdala, three striatal subdivisions (caudate, putamen and nucleus accumbens), thalamus, entorhinal cortex, dentate nucleus and Purkinje cells. None or insignificant delay was observed in the cornu Ammonis sectors 1-4, lateral geniculate body, inferior olive and nucleus of facial nerve. Late childhood was the period of significant acceleration of neuronal growth compensating for an early childhood delay.

Conclusion: The presence of a similar developmental delay of neuronal growth in the majority of examined structures in early childhood may indicate that (a) the developmental delay of the growth of neurons is regulated in a similar way in many brain regions, and that (b) each component of these complex neuronal networks may have its own contribution to the clinical phenotype of autism. The absence of a significant delay of neuronal growth in other brain regions suggests desynchronization of mechanisms controlling the growth of neurons. We hypothesize that interactions of incorrectly developing neurons/networks with non-affected brain networks may still result in dysfunction of both, affected and non-affected networks.

Sponsors: Autism Speaks, the Department of Defense Autism Spectrum Disorders Research Program (AS073234), and the NYS Office of Mental Retardation and Developmental Disabilities. The Harvard Brain Tissue Resource Center (R24-MH 068855), and the Brain and Tissue Bank at the University of Maryland, Baltimore, provided tissue. The Autism Tissue Program coordinated tissue acquisition.

5. **Title:** Potential contribution of developmental and epilepsy associated changes to sudden unexpected death of people with chromosome 15 duplication and autism.

Authors: W Ted Brown, MD, PhD¹, Thomas Wisniewski, MD², Ira L Cohen, PhD³, Eric London, MD³, Michael Flory, PhD⁴, Izabela Kuchna, MD, PhD², Krzysztof Nowicki MD², Jarek Wegiel, BA, MS², Shang Yong Ma, MD, PhD², Humi Imaki, PhD², Jerzy Wegiel, PhD²

¹Human Genetics, ²Developmental Neurobiology, ³Psychology, ⁴Research Design, New York State Institute for Basic Research in Developmental Disabilities, 1050 Forest Hill Road, Staten Island, NY 10314

Background. The 1% prevalence of epilepsy in a general population increases to 33% in autism (Tuchman and Rapin, 2002). The interpretation of developmental changes in autism and in duplication of chromosome 15/autism has been challenged by a need to separate lesions not associated with epilepsy from lesions that cause epilepsy and are produced by epilepsy (Sutula and Pitkanen 2001). Epilepsy induces brain alterations that contribute to changes in circuitry, which potentiates the seizure-genic focus (Armstrong 2005). The studies of epilepsy in non-autistic subjects show that epilepsy is associated with an elevation of APP expression (Shang et al., 1994) and diffuse nonfibrillar A β plaque formation (Mackenzie et al., 1994, 1996). The pattern of neuropathological changes caused by chromosome 15 duplications is in a very early stage of studies of a few brains.

Objective: Separation of developmental changes from associated with epilepsy and potentially increasing risk of sudden death.

Methods: Brains of four autistic subjects (11, 15, 20, and 25 years old) with chromosome 15 duplications, and four age-matched controls were examined by light microscopy including unbiased morphometric method and immunocytochemistry, and by electron microscopy. Three affected subjects were diagnosed with epilepsy and all four died suddenly and unexpectedly.

Results: The study suggests that reduced size of the brain, and reduced volume of neurons and neuronal nuclei in the striatum, amygdala, entorhinal cortex and Purkinje cells, correspond to developmental abnormalities. Changes observed in two subjects including hippocampal microdysgenesis with hyperconvolution and duplication of the granule cell layer in the dentate gyrus appear to contribute to seizures and could be enhanced by seizures. Chaslin's gliosis observed in one subject and local neuronal loss may reflect epilepsy-related brain damage. Enhanced cytoplasmic accumulation of amyloid beta protein in all four subjects is a reflection of modified APP processing.

Conclusion: Neuropathological study of brains of four subjects with chromosome 15 duplications, shows developmental changes. In three subjects changes associated with seizures and caused by seizures could contribute to sudden death. However, central apnea, asphyxia and pulmonary oedema, as well as life threatening cardiac arrhythmias during seizures (Earnest et al., 1992, Nashef et al., 1996, Reeves et al., 1996; Jallon 1997; Saussu et al., 1998, Thom et al., 1999) can not be excluded as a direct cause of sudden unexpected death.

Sponsors: Autism Speaks, the Department of Defense Autism Spectrum Disorders Research Program (AS073234), and the NYS Office of Mental Retardation and Developmental Disabilities. The Harvard Brain Tissue Resource Center (R24-MH 068855), and the Brain and Tissue Bank at the University of Maryland, Baltimore, provided tissue. The Autism Tissue Program coordinated tissue acquisition.