

AD _____

AWARD NUMBER: W81XWH-08-2-0065

TITLE: Pathogenesis of Heterotopic Ossification in Traumatic Brain Injury

PRINCIPAL INVESTIGATOR: Frederick P. Heinzl, M.D.; Xin Li, M.D.

CONTRACTING ORGANIZATION: James A. Haley VA Hospital
Tampa, FL 33612

REPORT DATE: April 2009

TYPE OF REPORT: Annual

PREPARED FOR: U.S. Army Medical Research and Materiel Command
Fort Detrick, Maryland 21702-5012

DISTRIBUTION STATEMENT: Approved for Public Release;
Distribution Unlimited

The views, opinions and/or findings contained in this report are those of the author(s) and should not be construed as an official Department of the Army position, policy or decision unless so designated by other documentation.

REPORT DOCUMENTATION PAGE				Form Approved OMB No. 0704-0188	
Public reporting burden for this collection of information is estimated to average 1 hour per response, including the time for reviewing instructions, searching existing data sources, gathering and maintaining the data needed, and completing and reviewing this collection of information. Send comments regarding this burden estimate or any other aspect of this collection of information, including suggestions for reducing this burden to Department of Defense, Washington Headquarters Services, Directorate for Information Operations and Reports (0704-0188), 1215 Jefferson Davis Highway, Suite 1204, Arlington, VA 22202-4302. Respondents should be aware that notwithstanding any other provision of law, no person shall be subject to any penalty for failing to comply with a collection of information if it does not display a currently valid OMB control number. PLEASE DO NOT RETURN YOUR FORM TO THE ABOVE ADDRESS.					
1. REPORT DATE 1 April 2009		2. REPORT TYPE Annual		3. DATES COVERED 1 Apr 2008 – 31 Mar 2009	
4. TITLE AND SUBTITLE Pathogenesis of Heterotopic Ossification in Traumatic Brain Injury				5a. CONTRACT NUMBER	
				5b. GRANT NUMBER W81XWH-08-2-0065	
				5c. PROGRAM ELEMENT NUMBER	
6. AUTHOR(S) Frederick P. Heinzl, M.D.; Xin Li, M.D. E-Mail: frederick.heinzl@va.gov				5d. PROJECT NUMBER	
				5e. TASK NUMBER	
				5f. WORK UNIT NUMBER	
7. PERFORMING ORGANIZATION NAME(S) AND ADDRESS(ES) James A. Haley VA Hospital Tampa, FL 33612				8. PERFORMING ORGANIZATION REPORT NUMBER	
9. SPONSORING / MONITORING AGENCY NAME(S) AND ADDRESS(ES) U.S. Army Medical Research and Materiel Command Fort Detrick, Maryland 21702-5012				10. SPONSOR/MONITOR'S ACRONYM(S)	
				11. SPONSOR/MONITOR'S REPORT NUMBER(S)	
12. DISTRIBUTION / AVAILABILITY STATEMENT Approved for Public Release; Distribution Unlimited					
13. SUPPLEMENTARY NOTES					
14. ABSTRACT Heterotopic ossification (HO) is the pathologic formation of bone in soft tissues. HO develops during the physical rehabilitation of patients with traumatic injuries, such as brain, spinal cord or orthopedic injury. When adjacent to joints or pressure points, HO causes pain, pressure sores and physical obstruction that significantly limits rehabilitation. The incidence is as high as 50% after traumatic amputation due to blast injury, when the amputation is through damaged soft tissue. Much of the clinical management of HO has been empiric. We show that an atraumatic mouse model of subcutaneous HO reproduces essential features of clinical HO in humans. (1) There is an early inflammatory phase, (2) HO progresses towards bone maturity and (3) damaged soft tissue promotes local HO development. Preliminary attempts to activate osteoclast resorptive function in vivo failed, probably due to insufficient bioavailability and the rapid decline of osteoclast numbers after 2 weeks. Our observations show that this mouse model of HO an accessible and clinically relevant system for detailed in vivo analysis of HO pathogenesis and treatment. The mechanism of wound-exacerbated HO progression in mice may usefully inform the medical care of HO in amputated limbs. In the next 6 months we propose to confirm that COX2 inhibitors prevent HO progression in this model and to determine if FDA-approved vascular endothelial growth factor antagonists will disrupt endothelial formation and COX2 expression that are necessary for new bone formation in this mouse model.					
15. SUBJECT TERMS HO, heterotopic ossificaiton; COX2, cyclooxygenase-2					
16. SECURITY CLASSIFICATION OF:			17. LIMITATION OF ABSTRACT	18. NUMBER OF PAGES	19a. NAME OF RESPONSIBLE PERSON
a. REPORT	b. ABSTRACT	c. THIS PAGE			USAMRMC
U	U	U	UU	12	19b. TELEPHONE NUMBER (include area code)

Table of Contents

	<u>Page</u>
Introduction.....	1
Body.....	1
Key Research Accomplishments.....	8
Reportable Outcomes.....	8
Conclusion.....	8
References.....	9

INTRODUCTION

Our goal in this project was to develop a mouse model of heterotopic ossification (HO) that shared important clinical characteristics of human HO. This validated model will be used to identify the pathophysiology of HO formation and to serve as a testbed for standard and experimental therapies. Using bone morphogenetic protein-2 infused collagen sponges implanted subcutaneously, we showed reproducible formation of subcutaneous bone with intense neutrophilic and osteoblastic infiltration at two weeks. The mechanism of ossification was through endochondral calcification. The HO showed progressive histologic maturation up to six weeks, when the bone displayed normal skeletal features, including a thick cortex, normal trabecular structure and a normal trilineage bone marrow. Unexpectedly, we observed that the mature size of HO was increased by proximity to experimental wounds. This was confirmed experimentally, with significant increases apparent at 2 and 4 weeks. Although we had hypothesized that depletion or neutralization of osteoclast activating agents would affect size of developing HO, we saw no significant response in HO weight to recombinant RANKL and IL-17 given subcutaneously or to neutralizing antibodies against RANKL and IL-17 given systemically. Osteoclasts were present in large numbers for the first two weeks, but declined dramatically thereafter, independent of the therapy employed. As a result, the remaining tasks are being revised to show that COX-2 inhibitory drug will prevent HO formation in the mouse model. The use of this clinical "gold standard" of HO prevention will further define the relevance of this model to therapeutics study. We also propose pilot studies to show that vascular endothelial growth factor (VEGF) is essential for HO formation. Since VEGF is produced by healing wounds, paracrine effects of this cytokine may account for the exacerbation of HO developing near soft tissue injuries. VEGF promotes endothelial formation and COX2 expression, both of which are essential for endochondral ossification. Sunitinib (VEGF receptor tyrosine kinase inhibitor) and aflibercept (VEGF antagonist) are both in the FDA approval pipeline and are known to be active in mouse and human studies. If effective against HO or wound-accelerated HO development in mice, these drugs would be suitable candidates for translational studies of combat-related heterotopic ossification, including the exacerbated growth of HO in the setting of traumatic amputation.

BODY

To this end, we developed a mouse model of subcutaneous heterotopic ossification, based on observations by others that recombinant bone morphogenetic protein-2 absorbed into collagen sponges induces bone formation in different mammalian species (1, 2). Our model reproduces some of the clinical aspects of trauma-induced HO. First, there is an early neutrophilic inflammatory response in the developing bone that may be related to the local and systemic inflammatory effects observed in clinical HO (3). Second, increasing size of experimental mouse HO correlates with increasing proximity to the surgical wound used to implant the bmp2 infused sponges, which resembles the increase in HO development when limb amputation is through or adjacent to injured soft-tissues (4). By six weeks, the experimental HO reaches maturity. Our primary goals were to show that this model would determine whether HO size could be regulated by manipulating the IL-12/IL-23 and RANKL and IL-17 cascades that activate osteoclast resorption of bone. Instead, we found that osteoclast numbers declined significantly even in RANK-L treated mice, suggesting that manipulation of osteoclast activity by cytokines was ineffective. Others have recently shown that osteoclast activity can be activated by RANKL, but only using large doses given twice daily that resulted in systemic osteoporosis. We will plan revise our SOW to propose alternative experiments that focus on VEGF supported COX2 activity as a therapeutic target for therapy of HO.

Task Number 1: To develop a mouse model of heterotopic ossification.

Based on the work of Wang and Wozney (Wang et al., 1990, #73001, Wozney et al., 1988, #16364), we implanted bmp2-infused collagen sponge implants into the subcutaneous tissues of ICR (CD-1) female mice (Harlan Labs). The absorbable collagen sponge and recombinant human bmp2 was kindly donated by the Medtronic Corporation (Infuse Kit, Spinal and Biologics Division, Memphis, TN). In initial studies, we implanted 4 mm cubes absorbable collagen sponges sterilized by irradiation and incubated at least 15 minutes, but no longer than 120 with 20 ug of recombinant human bmp2 in 14 ul of sterile saline. Under isoflurane general anesthesia, PBS- or bmp2-containing sponges were placed bilaterally 10 mm to either side of the midline of

the back through 4-5 mm incisions closed with VetBond surgical glue. Palpable bone was evident after the first week.

At 2, 4 and 6 weeks, mice were euthanized and HO pieces carefully dissected free from soft tissue, measured and weighed. The pieces were bisected with scalpel and fixed in 10% formalin. After washing four times in PBS (7.4) for 30 minutes each, one of the HO pieces was decalcified in 14% EDTA (pH 7.4) for one week and then washed in PBS four times again. The sample was embedded in paraffin blocks and sectioned in 5 μ m thicknesses. Slides were deparaffinized in sequential xylenes and alcohols and the stained with hematoxylin and eosin (H&E).

At two weeks, bmp2-containing implants had increased in size and were gritty in texture when cut by scalpel (**Figure 1A**). PBS-infused sponges were not identifiable in control mice at week 2 or later (**Figure 1B**). In a second study, we recently compared the average weight (\pm SEM) of bone at 1, 2, 4 and 6 weeks (**Figure 1C**).

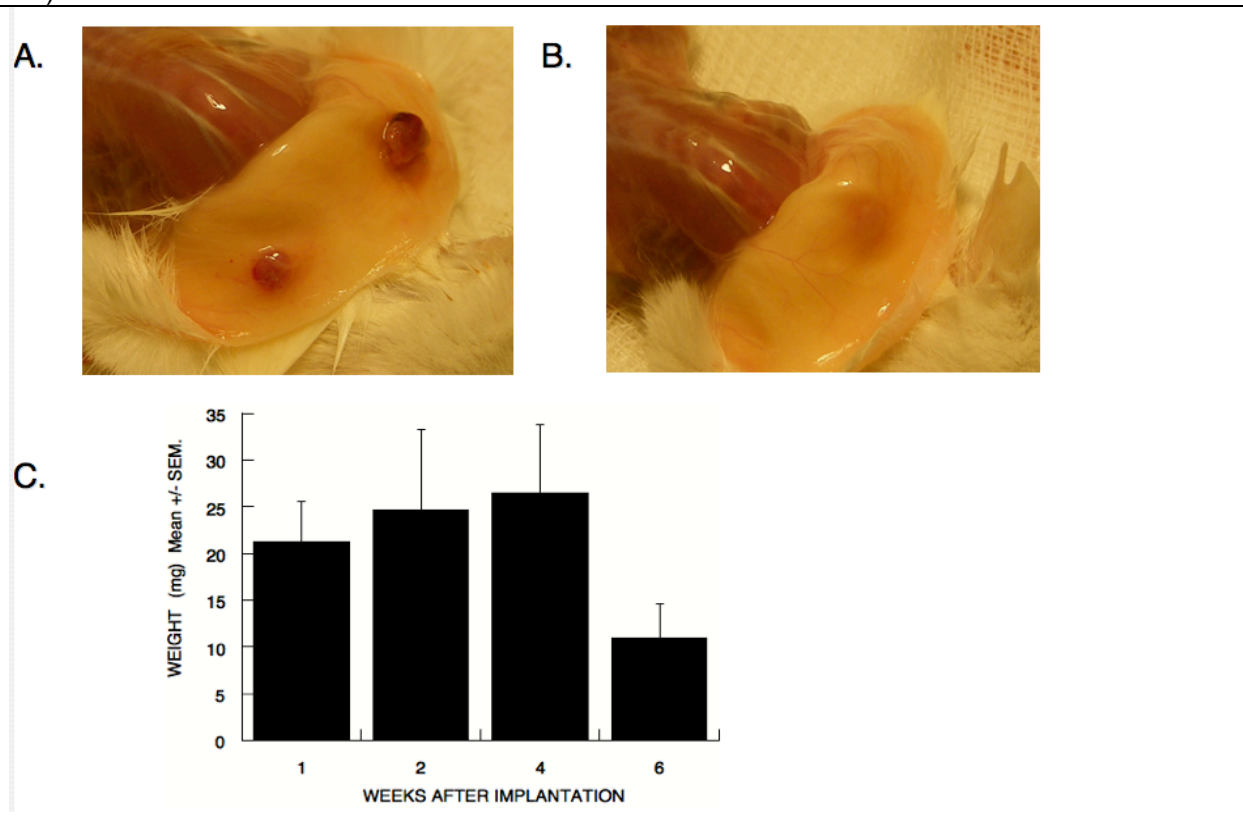


FIGURE 1. Subcutaneous HO In situ; four weeks after implantation

A. BMP-2-infused sponge implants.

B. PBS- infused sponge implants.

C. HO weight over time, using 5 mice per timepoint (no difference between groups, $p > 0.05$) using Mann Whitney, t-test or ANOVA.

Although the HO weight was similar at different times, there were distinct and progressive histologic changes over the timecourse studied. **Figure 2** shows selected images of two-week bone at the indicated magnifications. There are large numbers of osteoblasts with signs of pronounced synthetic activity (plasmacytoid appearance), calcified matrix is present, and there is neutrophilic infiltration and apoptosis suggestive of active inflammation. Angiogenic changes are present within the developing bone. These findings are representative of three different time courses.

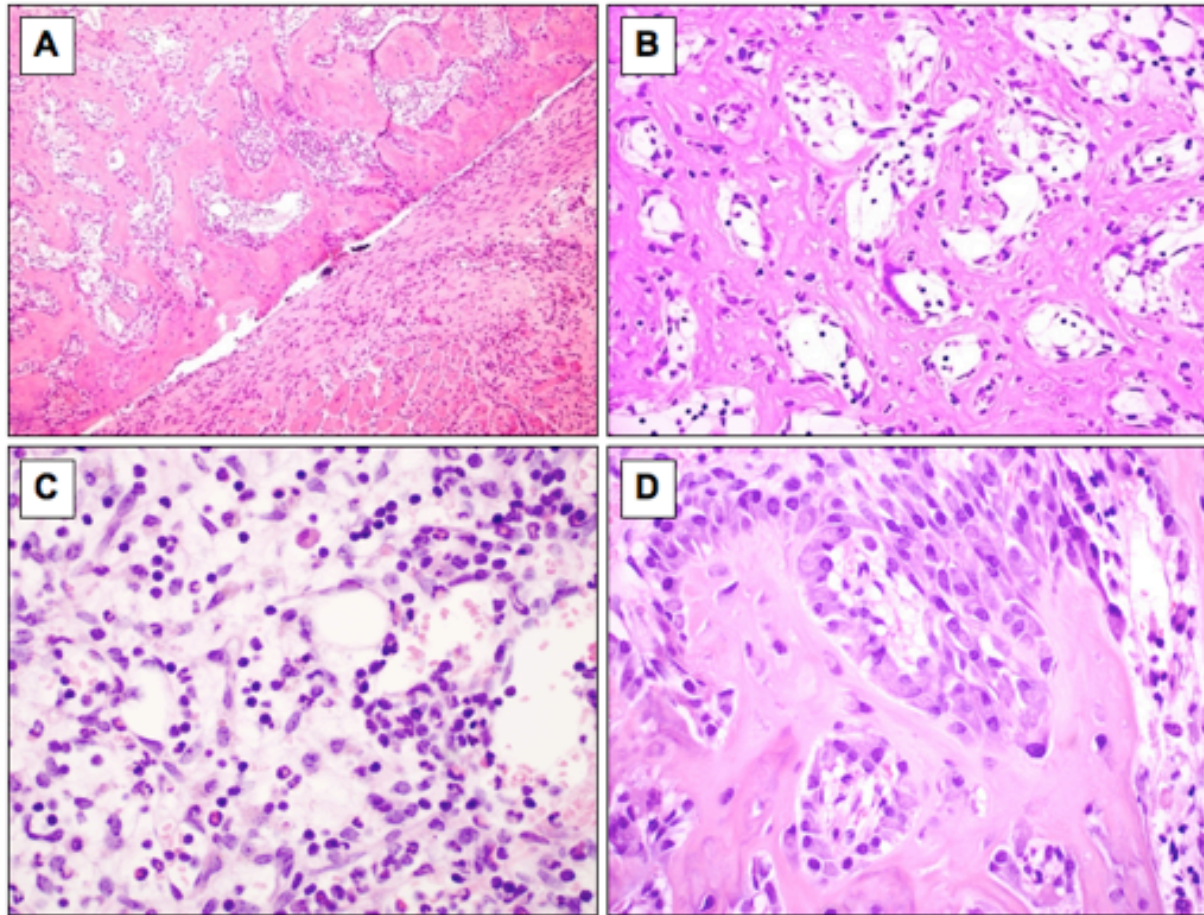


FIGURE 2. Mouse heterotopic ossification at two weeks (Decalcified bone stained with H&E).

- A. **(50X)** New bone formation (left) and host fibrous tissue and skeletal muscle (right). Cortex-like structure with endosteal proliferation and cancellous bone formation is evident.
- B. **(200X)** Dense bone spicules show lamellar structure and osteoblastic rimming.
- C. **(200X)** Bone marrow spaces are predominantly filled with endothelial cells, marrow stroma cells, erythrocytes, apoptotic cells and numerous neutrophils.
- D. **(200X)** Osteoblasts lining the cancellous bone are prominent and plasmacytoid, adopting an osteblastoma-like picture. Minimal osteoclastic activity is identified.

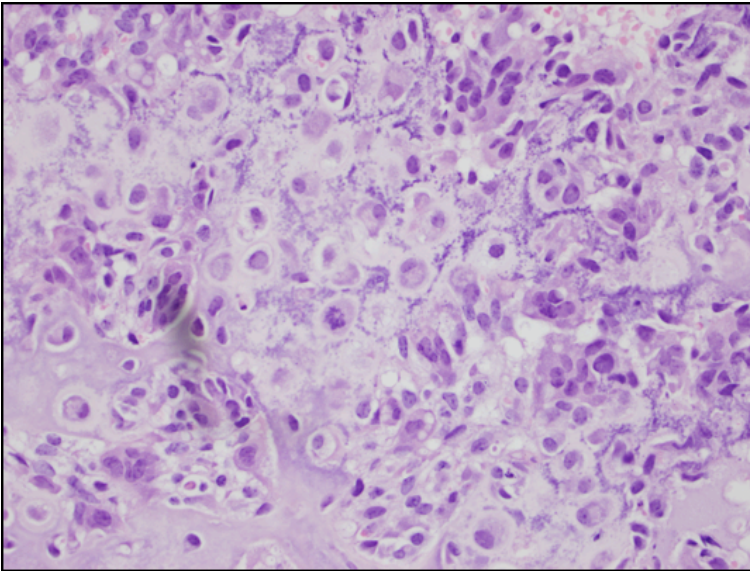


Figure 3. 2nd Week - Chondrocytes are present, some with signs of apoptosis. Matrix calcification is present, as shown by the speckled purple material in the developing bone.

At four weeks (**Figure 4**), cortical bone had become well-developed with abundant capillary penetration. Osteoblastic activity was variably reduced compared to the earlier timepoint, and the marrow contained developing multilineage bone marrow with small amounts of fat. At six weeks (**Figure 5**), the cortex was fully developed and contained many embedded osteocytes. There was a normal ratio of bone marrow cells and fat. Osteoblastic activity was again variable, with some areas showing flattened cells consistent with decreased activity, with other areas showing cells with a more active plasmacytoid appearance. Osteoclasts were rarely observed.

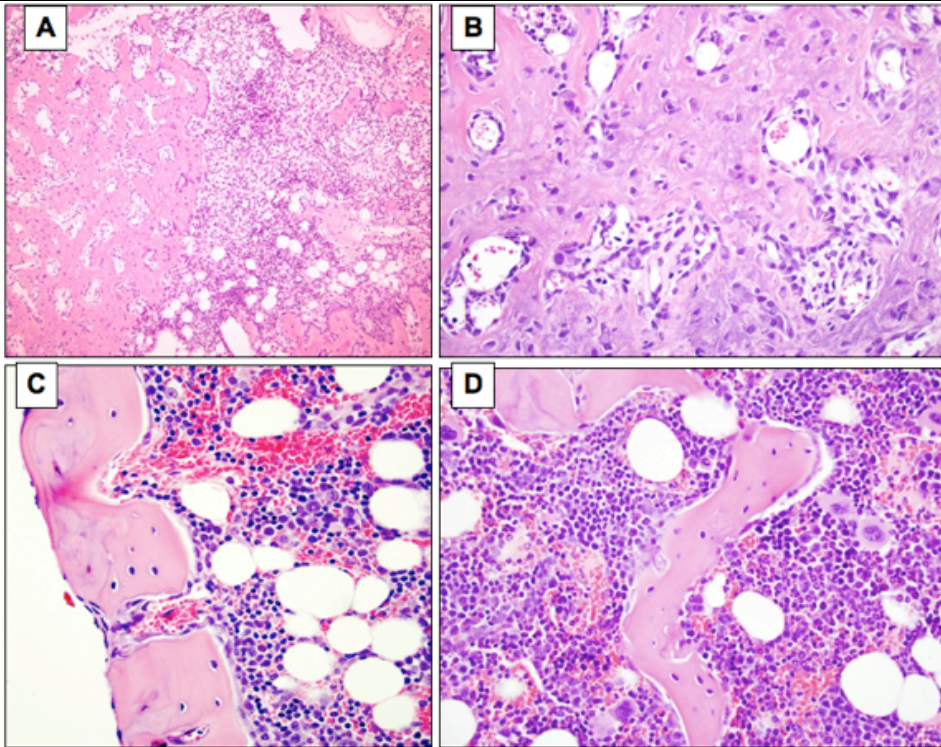


FIGURE 4. Mouse Heterotopic ossification at four weeks

A. (50X) Areas of bone (left) appear quiescent with rimming of flat osteoblasts, while other areas undergo active remodeling with prominent, plasmacytoid osteoblasts (lower right).
 B. (100X). Dense bone formation with numerous osteoblasts. Osteoclastic activity is minimal.
 C. (200X). Well-formed cortex penetrated by vessels adjacent to a normal-appearing bone marrow with hematopoietic elements of all lineages and bone marrow fat.

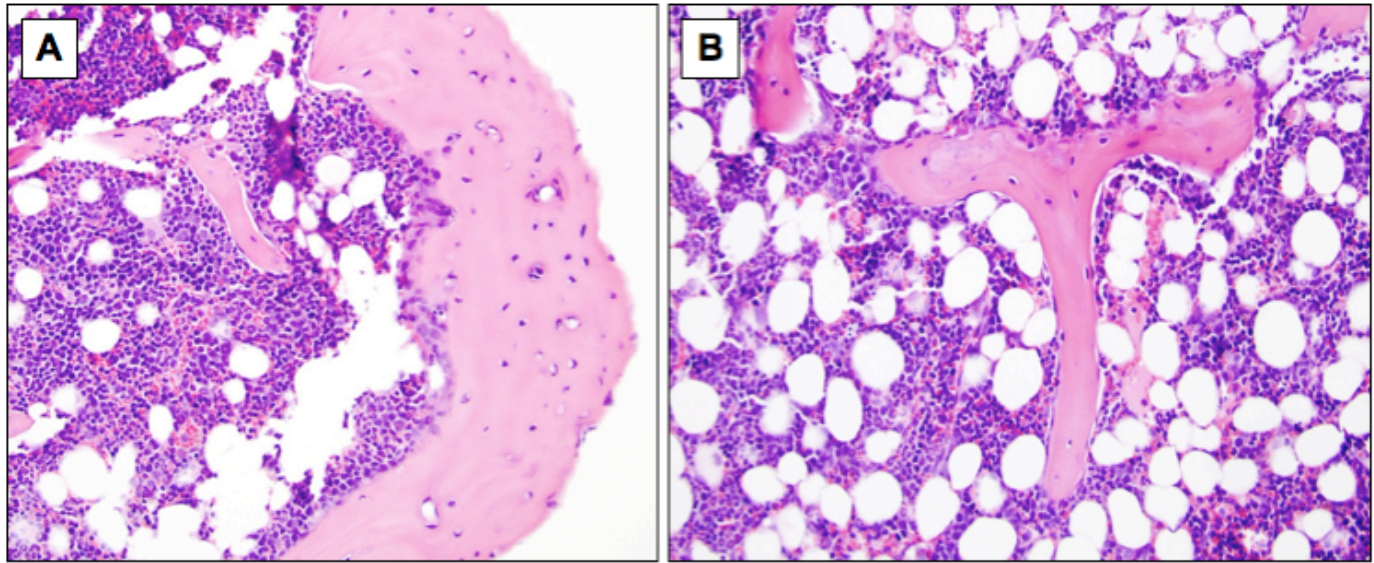


FIGURE 5. Mouse Heterotopic Ossification at six weeks (200X)

A. Well-defined cortex-like structure and adjacent bone marrow.

B. Bone spicules characteristic of mature trabecular bone and bone marrow with approximately equal amounts of cellularity and fat.

Osteoclasts that were present at two weeks along the inner cortex, as recognized by multinucleate morphology (greater than 3 nuclei) and the presence of a resorptive pit in the inner cortex, rapidly decreased and were not obvious from week 4 to week 6. Staining for osteoclasts with tartrate-resistant acid phosphatase (TRAP) reagents demonstrated only a few TRAP+ cells at four and six weeks. Only EDTA-based decalcification methods were used to preserve TRAP staining characteristics in these studies. TRAP stain sensitivity was confirmed using mouse RAW macrophage line transformed into osteoclasts in the presence of 50 ng/ml RANKL and CSF-1 (not shown).

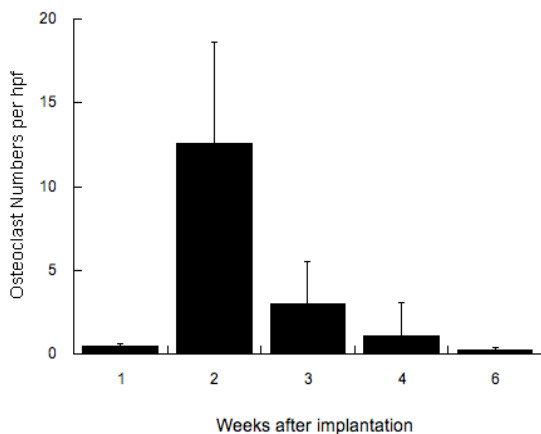


Figure 6 Osteoclast numbers per high power field over time.

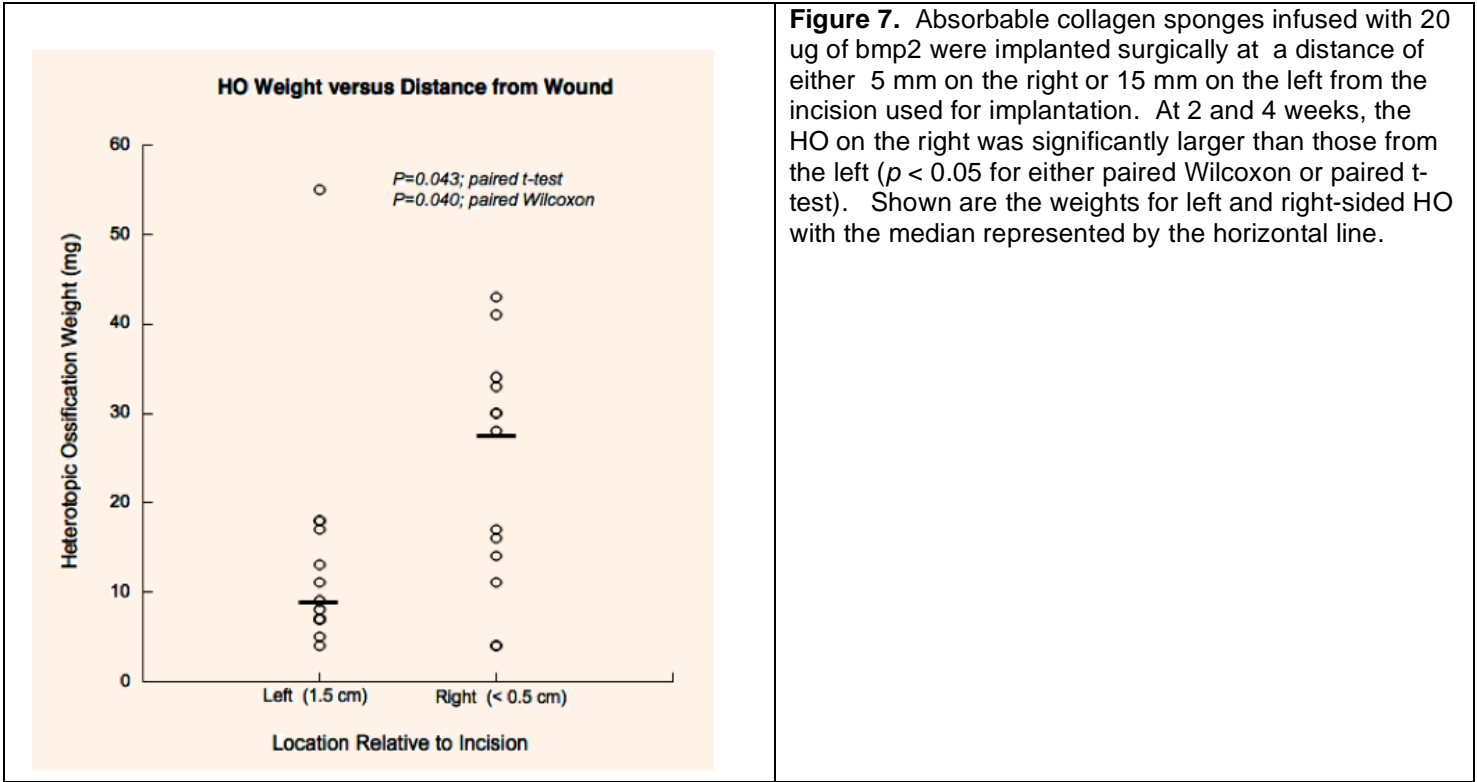
Multinucleated giant cells (3 or more nuclei) were counted per hpf (x 250) for a total of six fields per slide for two slides. Shown are the mean and standard deviation of osteoclast numbers by week after implantation. The decrease in numbers from week 2 to week 3, 4 and 6 was significant ($p < 0.05$, Mann Whitney U).

Size variation in HO correlates with proximity to cutaneous wounding.

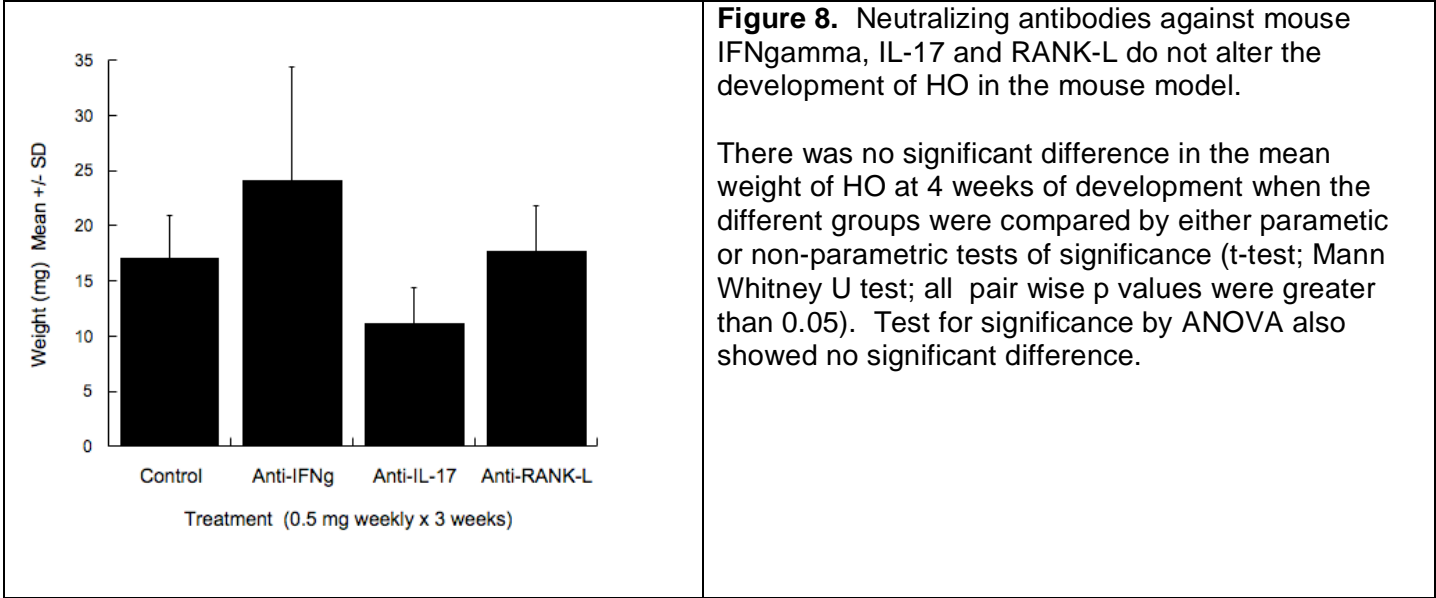
In these studies, we observed an initial and significant heterogeneity in the size of subcutaneous HO. This correlated with the distance between the bmp2-infused sponges and the incision used for subcutaneous insertion. In a study dedicated to confirming this relationship, we showed that bmp2-infused sponge placed 5 mm compared to 15 mm from the insertional wound resulted in a significant change in HO weight (**Figure 7**).

These findings suggest that this mouse model can reproduce an effect observed clinically, wherein limb amputation through damaged soft tissue results in more frequent and extensive HO formation compared to amputation through normal soft tissue (4). Others have recently described a similar exacerbative effect on HO formation when it develops near

wounds that are infected, persistent or multiply debrided in non-amputees (5). We propose this pattern of HO development, now seen in both clinical and experimental murine settings, is consistent with bone growth acceleration due to paracrine factors released from wounds, among which VEGF as a likely candidate (6).

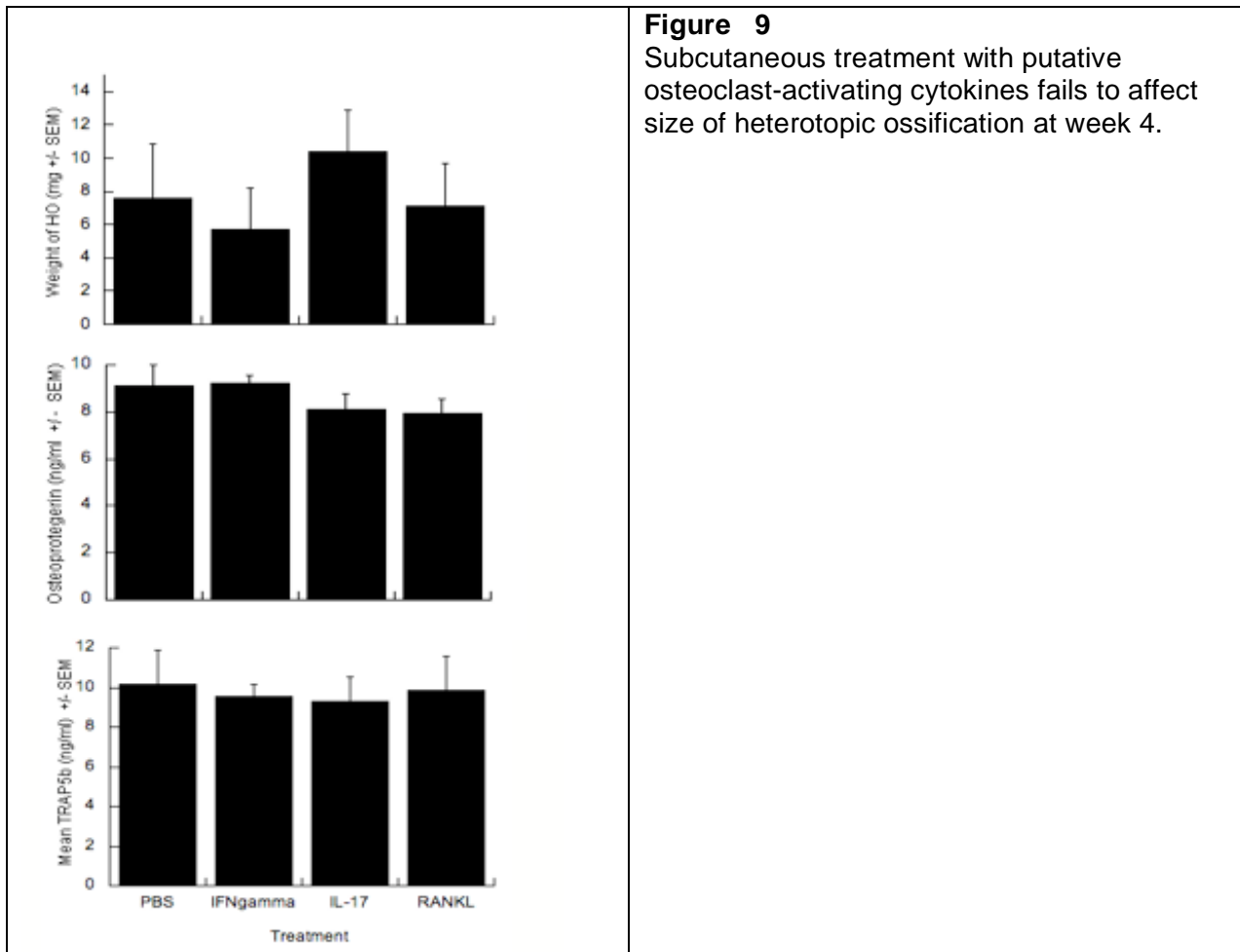


Task Number 2 Show that endogenous osteoclast activating cytokines are necessary for regulating the rate and extent of heterotopic bone growth. In this study, we injected 0.5 mg of neutralizing antibody against mouse IFNgamma, mouse IL-17 and mouse RANKL once weekly for the first three weeks of HO development. We used rat IgG antibody for control injections.



Although there was a nonsignificant trend towards reduced HO size in the anti-IL-17 treated group, the difference was 2-fold at best and may not represent a change with sufficient clinical significance.

Task Number 3. Develop novel therapies that specifically target the local pathogenesis of heterotopic ossification in the mouse model.



We hypothesized that activation of osteoclasts *in vivo* by RANK-L would be sufficient to limit the growth of HO and might represent a clinically viable therapy for clinical use. Since RANKL is a critical activator of osteoclast function, we treated mice subcutaneously with 5 ug of recombinant mouse RANKL injected every 3rd day at the site of heterotopic bone. The amounts used, which were limited by cost considerations, did not produce any significant change in HO weight compared to saline treated controls. We compared RANKL to similar dosing regimens using the RANKL-activating cytokine, IL-17, and recombinant murine IFN-gamma. These also failed to alter HO growth relative to PBS-injected controls. We measured serum TRAP5b levels as surrogate markers for osteoclast activation, but there was no significant change in the different groups using serum obtained after the last cytokine therapy. Because these cytokines may induce the RANKL decoy receptor, osteoprotegerin (OPG), we used the same sera to assay for osteoprotegerin levels. Again, there was no significant difference between groups or relative to PBS-treated control mice, suggesting that osteoprotegerin production in response to these cytokines was not suppressing osteoclast activity as a negative feedback loop. In discussion with scientists at Amgen Corp, it became apparent that much larger doses of RANKL are needed to increase TRAP5b in mice or rats, but these doses also cause generalized bone mineral loss that would be unacceptable as a model for HO preventative therapy (7, 8). On this basis, we suspended these studies due to the nonspecific lytic effects of RANKL on normal or heterotopic bone.

Task Number 4. Show that IL-17 and IFN γ producing cytokines IL-23 and IL-12 regulate heterotopic bone development in the mouse implant model.

This study is planned for the near future.

Task Number 5. Final analysis, report writing and closeout of the project.
The information provided above is being written for a future publication.

KEY RESEARCH ACCOMPLISHMENTS

1. We demonstrate a reproducible mouse model for subcutaneous heterotopic ossification that resembles clinical HO in the following characteristics:
 - a. Early formation is associated with local inflammatory changes, as indicated by histologic evidence of neutrophil infiltration and apoptosis at week 2.
 - b. Experimental HO is initiated by endochondral ossification. This predicts that HO formation in this model will be dependent on vascular endothelial growth factor, which would be a suitable subject of study for the remaining duration of this project or as a new proposal.
 - c. Experimental HO progresses to form fully mature cortical bone.
 - d. The size of the HO is increased by proximity to cutaneous wounding, which strongly resembles a clinical phenomenon observed in combat-related heterotopic ossification, wherein the frequency and size of HO increases when adjacent to soft tissue wounds.

REPORTABLE OUTCOMES

Abstracts submitted and accepted:

Pathogenesis of Heterotopic Ossification in Traumatic Brain Injury
PRMRP Military Health Research Forum 8/31 to 9/03/2009
Kansas City, Missouri

Funding applied for with this award:

"A mouse model of heterotopic ossification for experimental therapeutics design"
CDMRP proposal PR093237 submitted 4/23/2009

CONCLUSION

This report describes our development of a mouse model of heterotopic ossification. This model is suitable for the experimental study of unique therapeutics proposed to prevent or reverse heterotopic ossification. Since the initial HO lesion develops through the process of endochondral ossification, we suspect a major role for VEGF-induced vasculogenesis as an early and essential factor in the pathologic formation of ectopic bone. In addition to supporting capillary proliferation, VEGF also promotes COX2 expression in endothelia. Because COX2 inhibitors potentially protect against HO formation, these findings have prompted our

interest in using VEGF or VEGF receptor antagonists in the treatment of HO. At least two such drugs are now active in clinical therapy as anti-neoplastic agents. Sunitinib is a receptor tyrosine kinase inhibitor that blocks two distinct VEGF receptor functions. This drug has an acceptable toxicity profile and is advanced in the FDA approval pathway. Aflibercept is a decoy receptor that neutralizes soluble VEGF and is also in clinical trials with favorable results. Because we hypothesize that tissue wound-accelerated HO exacerbation is also driven by paracrine VEGF from damaged tissue, this approach may be well suited for use in combat-related amputations. We intend to revise our SOW to include a pilot study comparing the HO prophylactic activity of celecoxib (the current gold standard for HO prevention) to sunitinib.

REFERENCES

1. E. A. Wang *et al.*, *Proc Natl Acad Sci U S A* **87**, 2220 (1990).
2. J. M. Wozney *et al.*, *Science* **242**, 1528 (1988).
3. I. M. Estrores, A. Harrington, K. Banovac, *J Spinal Cord Med* **27**, 434 (2004).
4. B. K. Potter, T. C. Burns, A. P. Lacap, R. R. Granville, D. A. Gajewski, *J Bone Joint Surg Am* **89**, 476 (2007).
5. K. Evans *et al.*, *Journal of Surgical Research* **151**, 272 (2009).
6. H. P. Gerber *et al.*, *Nat Med* **5**, 623 (1999).
7. S. A. Lloyd *et al.*, *Calcif Tissue Int* **82**, 361 (2008).
8. Y. Y. Yuan *et al.*, *Osteoporos Int* **19**, 625 (2008).