

Award Number: W81XWH-04-1-0275

TITLE: Antioxidant Prophylaxis in the Prevention of Prostatic  
Intraepithelial Neoplasia (PIN)

PRINCIPAL INVESTIGATOR: A. Pratap Kumar, Ph.D.

CONTRACTING ORGANIZATION: University of Texas Health Science Center  
San Antonio, TX 78229

REPORT DATE: February 2008

TYPE OF REPORT: Annual

PREPARED FOR: U.S. Army Medical Research and Materiel Command  
Fort Detrick, Maryland 21702-5012

DISTRIBUTION STATEMENT: Approved for Public Release;  
Distribution Unlimited

The views, opinions and/or findings contained in this report are those of the author(s) and should not be construed as an official Department of the Army position, policy or decision unless so designated by other documentation.

# REPORT DOCUMENTATION PAGE

*Form Approved*  
*OMB No. 0704-0188*

Public reporting burden for this collection of information is estimated to average 1 hour per response, including the time for reviewing instructions, searching existing data sources, gathering and maintaining the data needed, and completing and reviewing this collection of information. Send comments regarding this burden estimate or any other aspect of this collection of information, including suggestions for reducing this burden to Department of Defense, Washington Headquarters Services, Directorate for Information Operations and Reports (0704-0188), 1215 Jefferson Davis Highway, Suite 1204, Arlington, VA 22202-4302. Respondents should be aware that notwithstanding any other provision of law, no person shall be subject to any penalty for failing to comply with a collection of information if it does not display a currently valid OMB control number. **PLEASE DO NOT RETURN YOUR FORM TO THE ABOVE ADDRESS.**

<b>1. REPORT DATE</b> 28-02-2008			<b>2. REPORT TYPE</b> Annual		<b>3. DATES COVERED</b> 1 FEB 2004 -31 JAN 2008	
<b>4. TITLE AND SUBTITLE</b> Antioxidant Prophylaxis in the Prevention of Prostatic Intraepithelial Neoplasia (PIN)					<b>5a. CONTRACT NUMBER</b>	
					<b>5b. GRANT NUMBER</b> W81XWH-04-1-0275	
					<b>5c. PROGRAM ELEMENT NUMBER</b>	
<b>6. AUTHOR(S)</b> A. Pratap Kumar, Ph.D.  Email: kumarp@amc.org					<b>5d. PROJECT NUMBER</b>	
					<b>5e. TASK NUMBER</b>	
					<b>5f. WORK UNIT NUMBER</b>	
<b>7. PERFORMING ORGANIZATION NAME(S) AND ADDRESS(ES)</b>  University of Texas Health Science Center San Antonio, TX 78229					<b>8. PERFORMING ORGANIZATION REPORT NUMBER</b>	
<b>9. SPONSORING / MONITORING AGENCY NAME(S) AND ADDRESS(ES)</b> U.S. Army Medical Research and Materiel Command Fort Detrick, Maryland 21702-5012					<b>10. SPONSOR/MONITOR'S ACRONYM(S)</b>	
					<b>11. SPONSOR/MONITOR'S REPORT NUMBER(S)</b>	
<b>12. DISTRIBUTION / AVAILABILITY STATEMENT</b> Approved for Public Release; Distribution Unlimited						
<b>13. SUPPLEMENTARY NOTES</b>						
<b>14. ABSTRACT</b> Clinically significant prostate cancer usually occurs in men who are 65 and older although precursor lesions are known to exist many years prior to cancer diagnosis. Histopathological changes referred to as Prostatic Intraepithelial Neoplasia (PIN) are considered to be the most likely precursor of prostate cancer. The mechanism(s) involved in progression of indolent to active disease remains elusive although a role for age-related increase in oxidative stress has been proposed. There are a variety of reactive oxygen species (ROS) that ultimately cause oxidative stress and any particular oxidant has not been identified as being primarily involved. We rationalized that a combination of antioxidants may be necessary to neutralize the different classes of ROS to prevent the progression of latent precursor foci to active cancer. Therefore we devised a combination of antioxidants with varied antioxidant properties to determine whether such supplementation could prevent the progression of PIN in Noble rats that are stimulated to develop PIN with hormones. Results from this study show for the first time that dietary intervention with a combination of antioxidants caused a significant decrease (p< 0.04) in high grade PIN formation compared to animals on control diet. Levels of p65 (a component of NFκB), Superoxide dismutase (SOD) and Cox-2 were elevated in the prostate from hormone-stimulated rats. These data provide evidence regarding the involvement of oxidants in the progression of precursor lesions and the need to evaluate combinations of antioxidants as prostate cancer preventive agents.						
<b>15. SUBJECT TERMS</b> Oxidative Stress; prostatic intraepithelial neoplasia (PIN); antioxidants and Prevention						
<b>16. SECURITY CLASSIFICATION OF:</b>				<b>17. LIMITATION OF ABSTRACT</b>	<b>18. NUMBER OF PAGES</b>	<b>19a. NAME OF RESPONSIBLE PERSON</b> USAMRMC
<b>a. REPORT</b> U	<b>b. ABSTRACT</b> U	<b>c. THIS PAGE</b> U	<b>19b. TELEPHONE NUMBER</b> (include area code)			
				UU	8	

## Table of Contents

	Page
<b>Introduction.....</b>	<b>3</b>
<b>Key Research Accomplishments.....</b>	<b>4</b>
<b>Reportable Outcomes.....</b>	<b>7</b>
<b>Conclusions.....</b>	<b>7</b>
<b>References.....</b>	<b>8</b>
<b>Appendices.....</b>	<b>8</b>

### **Introduction:**

Although prostate cancer is considered to be a disease of older men, a significant number of relatively young men exhibit the earliest signs of prostate cancer. This suggests that the disease is initiated early and remains latent until some factors trigger it to become malignant. This long latency of prostate cancer progression provides an opportunity for intervention to prevent the initial disease from becoming cancerous. Since treatment options for prostate cancer are very limited for initial stages of the disease and unavailable for metastatic disease, it is imperative that other means to control the disease be vigorously tested to reduce the number of prostate cancer-related deaths in the United States.

Oxidants produced as by-products of cellular metabolism have been implicated in the genesis of prostate cancer. Oxidative stress is caused by an imbalance of cellular endogenous oxidant and antioxidant levels. Laboratory studies using different model systems indicate that oxidative stress markers increase and antioxidant enzyme levels decrease during prostate cancer progression. Oxidative stress generated by dietary fat and androgens has been implicated in prostate cancer. Further epidemiological studies with a variety of antioxidants such as selenium, tocopherols, lycopene,  $\beta$ -carotene etc. have been found to be effective in lowering prostate cancer risk. Although these data suggest the importance of oxidative stress and antioxidants

in prostate cancer, they are flawed in that they do not add to our understanding of the nature and amounts of antioxidants that are beneficial. This is extremely important since several classes of oxidants are produced and a single antioxidant cannot quench all the different species of oxidants produced from cellular metabolism. Further, time is an extremely important factor for successful antioxidant prophylaxis. Taken together, the stage of prostate development and the kinds of antioxidants used would play a major role in determining the success of antioxidant prophylaxis. This proposal is a first step in beginning to understand whether antioxidants can prevent or delay the formation of PIN. Based on evidence presented in the literature, ***we hypothesize that a combination of antioxidants can prevent or delay the development of Prostatic Intraepithelial Neoplasia in a T/E<sub>2</sub> model of PCA by modulating the level of oxidative stress markers and endogenous antioxidant levels.*** To test our hypothesis we propose three specific aims.

- 1) Determine the ability of antioxidants to prevent or delay the development of Prostatic Intraepithelial Neoplasia (PIN) and relate it to changes in T/E<sub>2</sub> in the serum and AR.
- 2) Determine the levels of oxidative stress markers of DNA, protein and lipids following antioxidant supplementation.
- 3) Determine the levels and functional ability of endogenous antioxidant components following antioxidant supplementation.

**There has been no change in the specific aims proposed.**

#### **Key Research Accomplishments:**

**We focused solely on completing the tasks as proposed in the grant application.**

As mentioned in the previous report due to relocation and time involved in setting up the laboratory at the new location experiments to accomplish the proposed tasks are still ongoing. Overall we are very excited about the findings coming out of the proposal. In order to successfully complete the proposed work we have requested second no cost extension for an additional year until the end of March 2009.

We have submitted a manuscript describing the inflammatory changes in the ventral prostate of Noble rats in response to hormones.

As mentioned in the previous report additional pathologists (Drs Lucia, Smith and Hanes) have confirmed the histopathological analysis of the tissues generated from the study. These results are described below:

**Antioxidant supplementation prevents development of PIN:** Noble rats were purchased from Charles River Laboratories (Wilmington, MA). Animal experiments were conducted in accordance with approved protocols by the institutional animal care committee. Animals were housed in groups of 4 under a 12 hour light-dark cycle and a temperature of 23±2°C with access to food and water. At 6 weeks of age animals were randomized into 4 groups of 10 animals each for control with no hormone stimulation, control with hormone stimulation and antioxidant intervention (two doses). Control group of animals received AIN-93G diet without antioxidant supplementation until the end of the study. Control and special diet (AIN-93G supplemented with antioxidants was obtained from Dyets Inc., (Bethlehem, PA). 10 animals from control, 10 animals from low dose and 10 from high dose antioxidant supplementation diet were implanted with slow release hormone pellets containing 200 mg of testosterone propionate and 25 mg of 17β-estradiol benzoate. Another group of 10 animals from control were implanted with placebo control pellets (Innovative Research America, FL). Food cups were weighed before and after feeding to determine the amount of food and antioxidant consumed. All animals were weighed weekly and observed daily for signs of illness. Antioxidant intervention lasted for 7 weeks.

The intervention group animals were put back on control diet prior to stimulation with hormones so that antioxidants did not modulate hormone level and or activity. All animals except group 1 were treated with

testosterone and estradiol. Slow release pellets containing 240 mg testosterone propionate and 25 mg 17  $\beta$ -estradiol benzoate (Innovative Research America, FL) were implanted *sc* into the flanks of the animals. Control animals received placebo pellets. Hormone stimulation lasted for 16 weeks.

Body weight changes were measured during the experiment. All the animals were sacrificed at 16 weeks after initiation of hormone treatment. At this age animals have been reported to develop PIN the dorso-lateral prostate. Animals were sacrificed by CO<sub>2</sub> asphyxiation followed by cervical dislocation. The abdominal cavity was opened and all the organs were examined for gross changes. Prostate was dissected from the rest of the genitourinary organs, weighed, cut longitudinally along the urethra, and fixed in 10% buffered formalin. Serial sections of prostate tissue were stained with H&E and evaluated based on published criteria.

**Histopathology of prostate lesions:** Serial sections of prostate tissue were stained with H&E. PIN was diagnosed according to the criteria suggested by Leav et al (1). According to these criteria PIN in Noble rats is recognized by the presence of multiple layers of dysplastic epithelial cells that form alveolar or papillary structures, increased nuclear and nucleolar size, variability in shape and stainability. Prostate tissues exhibiting the presence of variable nuclear enlargement and irregular cell spacing with some nuclear stratification and crowding were denoted with + and graded as low grade PIN (LGPIN). Cells that had additional nuclear enlargement, fine nuclear chromatin pattern, with prominent nucleoli were denoted +++ and graded as high grade PIN (HGPIN). Three different pathologists analyzed the histopathology slides in a blinded fashion (grading is described in the methods section).

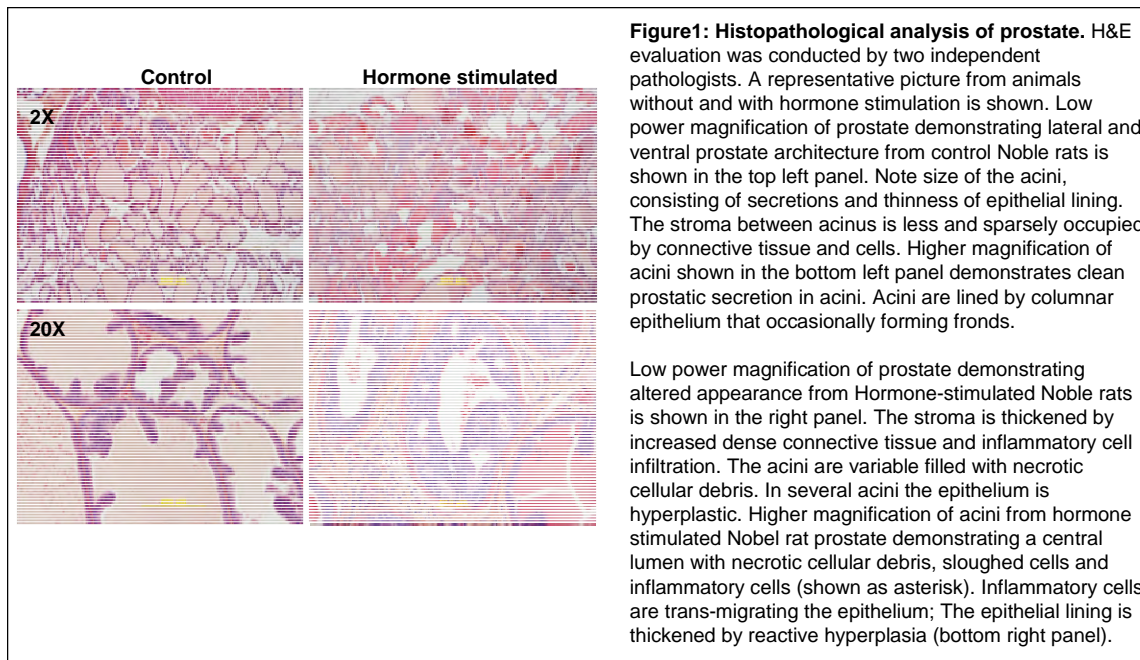


Figure 1 shows low power magnification of prostate demonstrating lateral and ventral prostate architecture from control Noble rats. Note size of the acini, consisting of prostatic secretions and thinness of epithelial lining. The stroma between acinus is less and sparsely occupied by connective tissue and cells (top left panel). Higher magnification of acini lined by columnar

epithelium those occasionally forming fronds and demonstrating clean prostatic secretions is shown (bottom left panel).


Top right panel shows low power magnification demonstrating altered appearance of prostate from hormone-stimulated Noble rats. The stroma is thickened by increased dense connective tissue and inflammatory cell infiltration. The acini are variable and filled with necrotic cellular debris. In several acini the epithelium is hyperplastic. Higher magnification of acini from hormone stimulated Nobel rat prostate demonstrating a central lumen with necrotic cellular debris, sloughed cells and inflammatory cells (shown as asterisk) is shown in bottom right panel. Inflammatory cells are trans-migrating the epithelium; and the epithelial lining is thickened by reactive hyperplasia (bottom right panel).

H&E scores were significantly higher for controls compared with high dose animals by Mann-Whitney U test ( $p = 0.040$ ). The median H&E score for controls was 1+. Only 4 of 17 animals from control group had a negative H&E score, while 7 of 10 animals on experimental diet had negative H&E scores. This rate of negative scores was significantly different by Fisher's Exact Test ( $p = 0.040$ ). The statistical analysis was performed using Stata 10.0 (StataCorp, College Station, TX).

These data show that there was a highly significant ( $p = 0.04$ ) difference in HGPIN formation between animals that were on the control diet compared with those on the antioxidant supplemented diet. These data also suggest that the group that did not receive the special diet had a significantly higher proportion of animals progressing to HGPIN. In contrast higher proportion of animals on antioxidant supplemented diet did not progress beyond low grade PIN.

**Increased expression of p65 and Cox-2 in the prostate from hormone stimulated rats:** We investigated

whether the observed histopathological changes in the prostate is associated with increased expression of inflammation associated genes such as NF $\kappa$ B and down stream effectors such as Cox-2. As shown in **figure 2**, immunohistochemical analysis showed higher expression of both Cox-2 and p65 (a component of NF $\kappa$ B) in the prostate from hormone stimulated rats. In contrast, prostate tissue of unstimulated rats showed low level of Cox-2 immunoreactivity (**left panel in figure 2**). We also observed increased expression of Ki67 in the prostate from hormone stimulated animals compared to placebo group animals indicating increased proliferation upon hormone stimulation. **Given that both NF $\kappa$ B and Cox-2 are associated with**

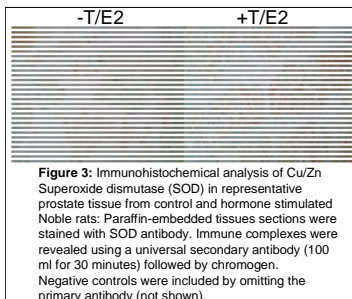


**Figure 2:** Proliferation and Immunohistochemical analysis of representative prostate tissue from control and hormone stimulated Noble rats. Paraffin-embedded tissues sections were stained with Ki-67 (SP6) antibody (Lab vision, Fremont, CA; top 3 panels) to assess proliferation. The secondary and tertiary antibodies were a biotinylated link and streptavidin HRP (Biossare 4 Plus Kit, Biossare Medical, Concord, CA). Negative controls were included by omitting the primary antibody (data not shown).

Paraffin-embedded tissues sections were stained with p65 and Cox-2 antibodies. The antibodies used were at a dilution of 1:100 in PBS and incubated overnight at 4 $^{\circ}$ C. Immune complexes were revealed using a universal secondary antibody (100 ml for 30 minutes) followed by chromogen. Negative controls were included by omitting the primary antibody (not shown).

**inflammatory signaling, these data suggest that activation of this signaling pathway may lead to development of inflammation in the prostate in response to hormones through modulation of oxidative/redox balance. Experiments are ongoing to examine the status of various oxidative stress markers and antioxidant defense enzymes in response to antioxidant supplementation as proposed in the application.**

**Superoxide dismutase (SOD) in hormone stimulated rats:** In order to determine whether oxidative stress created by hormones play a role in the observed histopathological changes associated with inflammation and



**Figure 3:** Immunohistochemical analysis of Cu/Zn Superoxide dismutase (SOD) in representative prostate tissue from control and hormone stimulated Noble rats. Paraffin-embedded tissues sections were stained with SOD antibody. Immune complexes were revealed using a universal secondary antibody (100 ml for 30 minutes) followed by chromogen. Negative controls were included by omitting the primary antibody (not shown).

PIN, we determined the level of superoxide dismutase (Cu/Zn SOD) in the prostate tissue from hormone stimulated and placebo control rats using immunohistochemistry. As shown in figure 3 expression of SOD was higher in prostate from hormone stimulated rats. **These data suggest that hormone stimulated animals probably have increased superoxide radicals and increase SOD level to cope with it. We expect to see decrease in the levels of such enzymes in the tissues from antioxidant supplementation group.**

**Reportable outcomes:** The outcome of the study is that

- Antioxidant supplementation significantly reduced the development of high grade PIN.
- We have confirmed the previous observations that antioxidant supplementation prevents development of PIN (manuscript submitted).
- Expression of both NF $\kappa$ B and Cox-2 associated with inflammatory signaling and SOD has been increased in the prostate from Noble rats in response to hormones.
- These data suggest that activation of this signaling pathway may lead to development of inflammation in the prostate through modulation of oxidative/redox balance (detailed studies are ongoing).

**Conclusions:** Primary management of prostate cancer for a majority of patients consists of radical surgery or radiation therapy. Although this is adequate for disease control in some patients a significant number of patients relapse and ultimately develop metastatic disease. There are limited treatment options for patients who have undergone primary therapy with curative intent. Early initiation of hormonal ablation is associated with significant morbidity and effect on quality of life including hot flashes, loss of libido, decreased muscle mass, and osteoporosis with long term use. Since PIN precedes prostate cancer delaying the progression of PIN or reversing HGPIN to LGPIN serves as an excellent mechanism to ensure quality of life for elderly men. Several lines of evidence suggest a beneficial role for vitamin consumption against prostate cancer. In this context Meyer and colleagues have shown that supplementation with nutritional doses of vitamin C, vitamin E,  $\beta$ -carotene, selenium and zinc daily for 8 years significantly reduced the rate of prostate cancer development in men with normal PSA (< 3ng/ml; 2). The  $\alpha$ -tocopherol,  $\beta$ -carotene (ATBC) cancer prevention trial in Finland found that consumption of vitamin E reduced clinical prostate carcinoma by 32% and prostate cancer mortality by 41% and no effect of vitamin E on latent prostate cancer (3). The double-blinded selenium chemoprevention trial by Clark and colleagues originally directed towards high-risk skin cancer patients found that selenium reduced prostate carcinoma risk significantly (4-5). While these studies suggest a role for antioxidant vitamin supplementation in the development of prostate carcinoma they do not shed any light regarding their effectiveness in preventing the progression of early PIN lesions towards clinically significant prostate cancer.

In this report we have shown that by supplementing the diet of Noble rats prior to stimulating with hormones LGPIN does not progress to HGPIN. At this time we do not know whether this supplementation has resulted in delaying the progression of LGPIN to HGPIN or whether HGPIN formation has been completely suppressed in these animals. We stopped dietary antioxidant supplementation before inducing the animals with hormones to ensure that both the control and antioxidant groups received hormone stimulation under the same conditions. Yet a vast majority of the animals in the special diet group did not develop HGPIN suggesting that the antioxidants modified the prostate environment in a way to prevent the progression of LGPIN to HGPIN upon hormone stimulation. Our results also suggest that antioxidant intervention enabled the environment not only to remove damaged cells through induction of apoptosis but also suppressed hormone-induced proliferation of prostatic epithelial cells. In addition it may modulate inflammatory signaling molecules including NF $\kappa$ B and Cox-2. Since the animals were stimulated with hormones under the same conditions we were able to separate the effect of antioxidants on hormone levels from the effect of the antioxidants on PIN development. The levels of testosterone or the ratio of testosterone to estradiol at the end of the study was not significantly different between animals on control vs. special diet (data not shown). None of the animals in any group were found to have gross abnormalities in kidney, bladder, seminal vesicle, prostate and liver. The data from this study clearly demonstrate the importance of an antioxidant combination in preventing the progression of precursor LGPIN to HGPIN in the noble rat model.

Although this study was not designed to examine the ability of antioxidants to extend the life of the animals stimulated to develop prostate cancer, it is an important discovery as a prophylactic for hundreds of thousands of men on 'watchful waiting' for their latent disease to progress to full blown cancer. Alternatively this antioxidant combination may be a useful adjuvant for men who have undergone androgen deprivation therapy as well as radiation therapy. Since dysplastic prostatic epithelium is considered to be hormone-dependent, androgen deprivation has been found to decrease high grade PIN by 50% (6-7). However it is also known that neoplastic cells that arise subsequently are not responsive to hormone deprivation. Since antioxidant intervention caused a significant decrease in HGPIN formation our results suggest that it may work through androgen-independent mechanism and may be useful in post-androgen deprivation therapy. It may be useful even for men who have received radiation therapy that does not successfully remove all HGPIN foci. A report from Memorial Sloan Kettering found PIN in 8.8% of biopsies after a course of 3-dimensional external beam conformal radiation therapy (8). Currently there is neither a routine treatment nor prevention format for HGPIN. This antioxidant combination holds promise to fill this void.

### References:

1. Leav, I, Ho, S-M, Ofner, P et al 1988 Biochemical alterations in sex hormone-induced hyperplasia and dysplasia of the dorsolateral prostates of noble rats. *J Natl. Cancer Inst.* 80: 1045-52.
2. Meyer, F, Galan, P, Douville, P. 2005. Antioxidant vitamin and mineral supplementation and prostate cancer prevention in the SU.VI.MAX trial. *Int J Cancer.* 116: 182-186
3. Hennekens, CH, Buring JE, Manson, JE et al. 1996 Lack of effect of long-term supplementation with beta carotene on the incidence of malignant neoplasms and cardiovascular disease. *N Engl. J Med.* 334: 1145-1149.
4. Clark LC, Combs GF Jr., Turnbull BW et al 1996 Effects of selenium supplementation for cancer prevention in patients with carcinoma of the skin. A randomized controlled trial. *Nutritional Prevention of Cancer Study Group. JAMA* 276: 1957-63
5. Brooks JD, Metter EJ, Chan DW. et al 2001 Plasma selenium level before diagnosis and the risk of prostate cancer development. *J Urol.* 166: 2034-2038.
6. Balaji, KC, Rabbani, F, Tsai, H et al 1999 Effect of neoadjuvant hormonal therapy on prostatic intraepithelial neoplasia and its prognostic significance. *J Urol.* 162: 753-57
7. Ferguson, J, Zincke, H, Ellison, E et al 1994 Decrease of prostatic intraepithelial neoplasia following androgen deprivation therapy in patients with stage T3 carcinoma treated by radical prostatectomy. *Urology* 44: 91-95
8. Gaudin, PB, Zelefsky, MJ, Leibel, SA et al 1999 Histopathological effects of three-dimensional conformal external beam radiation therapy on benign and malignant prostate tissues. *Am J Surg. Pathol.* 23: 1021-31

### Manuscripts under preparation/submitted:

- Ghosh, R., Garcia, G. E., Arevalo, N., I-Tien Yeh, Troyer, D. A. Chan, D. E and Kumar, A. P. Antioxidant combination blocks progression of prostatic intraepithelial neoplasia.
- Ghosh, R., Garcia, G. E., Arevalo, N., Smith, M., M Scott Lucia and Kumar, A. P. Hormone induced inflammatory changes in the ventral prostate of Nobel rats.