

Woods Hole Oceanographic Institution



Marine Mammal Necropsy: **An introductory guide for stranding responders and field biologists**

by

Katie R. Pugliares¹

Andrea Bogomolni²

Kathleen M. Touhey¹

Sarah M. Herzig¹

Charles T. Harry¹

Michael J. Moore²

¹The Cape Cod Stranding Network, Inc
P.O. Box 287
Buzzard's Bay, MA 02532
508-743-9805

²Woods Hole Oceanographic Institution
Biology Department
Woods Hole, MA 02543
508-289-3228

September 2007

Technical Report

Funding was provided by the National Oceanic and Atmospheric Administration
under Cooperative Grant No. NA05NMF4391165.

Approved for public release; distribution unlimited.

20071218003

WHOI-2007-06

**Marine Mammal Necropsy:
An introductory guide for stranding responders and field biologists**

by

Katie R. Pugliares, Andrea Bogomolni, Kathleen M. Touhey, Sarah M. Herzig,
Charles T. Harry, and Michael J. Moore

August 2007

Technical Report

Funding was provided by the National Oceanic and Atmospheric Administration under
Cooperative Grant No. NA05NMF4391165.

Reproduction in whole or in part is permitted for any purpose of the United States
Government. This report should be cited as Woods Hole Oceanog. Inst. Tech. Rept.,
WHOI-2007-06.

Approved for public release; distribution unlimited.

Approved for Distribution:


Judith McDowell, Chair

Department of Biology

This page intentionally left blank.

TABLE OF CONTENTS

ACKNOWLEDGEMENTS.....	11
SECTION ONE: INTRODUCTION AND PRELIMINARY DATA.....	13
INTRODUCTION.....	13
SAFETY.....	14
PRELIMINARY DATA.....	14
ANIMAL HISTORY.....	14
HUMAN INTERACTION EVALUATION.....	15
MORPHOMETRICS.....	17
PHOTOGRAPHY.....	19
SECTION TWO: SAMPLE MANAGEMENT.....	21
HISTOPATHOLOGY.....	21
CYTOLOGY.....	22
VIROLOGY.....	22
MICROBIOLOGY.....	23
PARASITOLOGY.....	23
CONTAMINANTS.....	23
BIOTOXINS.....	24
LIFE HISTORY AND GENETICS.....	24
STORAGE.....	25
TRACKING.....	27
SECTION THREE: PINNIPED NECROPSY TECHNIQUE AND ANATOMY.....	29
EXTERNAL EXAMINATION.....	29
CONDTION CODE.....	29
NUTRITIONAL CONDITION.....	30
SEX DETERMINATION.....	31
INTEGUMENT.....	32
SKIN & TEETH SAMPLING.....	33
REMOVAL OF EXTERNAL LAYERS.....	34
SKIN & BLUBBER.....	34
SKELETAL MUSCLE.....	34
INTERNAL EXAMINATION.....	35
SCAPULA AND PRESCAPULAR LYMPH NODE.....	35
THYROID.....	36
THYMUS.....	37
REMOVAL OF RIB CAGE.....	37
TRACHEOBRONCHIAL LYMPH NODE.....	39
LUNGS.....	40
TRACHEA.....	41
HEART MUSCLE & VALVES.....	41
DIAPHRAGM.....	43
LIVER.....	43

TABLE OF CONTENTS (cont.)

GALL BLADDER.....	43
SPLEEN.....	44
PANCREAS.....	45
MESENTERY & MESENTERIC LYMPH NODE.....	45
ADRENAL GLANDS.....	46
KIDNEYS.....	47
URINARY BLADDER.....	47
OVARIES & UTERUS.....	48
TESTES.....	48
STOMACH.....	49
ESOPHAGUS.....	50
SMALL INTESTINE.....	50
LARGE INTESTINE.....	50
COLON.....	50
REMOVAL OF THE BRAIN.....	51
EXAMINATION OF THE BRAIN.....	52
PITUITARY GLAND.....	52
 SECTION FOUR: SMALL CETACEAN NECROPSY TECHNIQUE	
AND ANATOMY	53
EXTERNAL EXAMINATION.....	53
CONDITION CODE.....	53
NUTRITIONAL CONDITION.....	55
SEX DETERMINATION.....	55
INTEGUMENT.....	57
SKIN & TEETH SAMPLING.....	59
REMOVAL OF EXTERNAL LAYERS.....	60
SKIN & BLUBBER.....	60
SKELETAL MUSCLE.....	63
INTERNAL EXAMINATION.....	63
SCAPULA AND PRESCAPULAR LYMPH NODE.....	63
REMOVAL OF RIB CAGE.....	64
THYROID.....	66
THYMUS.....	66
TRACHEOBRONCHIAL LYMPH NODE.....	66
LUNGS.....	67
TRACHEA.....	68
HEART MUSCLE & VALVES.....	69
DIAPHRAGM.....	71
LIVER.....	72
SPLEEN.....	73
PANCREAS.....	74
MESENTERY & MESENTERIC LYMPH NODE.....	75
ADRENAL GLANDS.....	76

TABLE OF CONTENTS (cont.)

KIDNEYS.....	77
URINARY BLADDER.....	79
OVARIES & UTERUS.....	80
TESTES & PENIS.....	82
STOMACH.....	83
ESOPHAGUS.....	85
SMALL INTESTINE.....	86
LARGE INTESTINE.....	86
COLON.....	86
REMOVAL OF THE BRAIN.....	87
EXAMINATION OF THE BRAIN.....	88
PITUITARY GLAND.....	89
EAR EXTRACTION.....	89
SECTION FIVE: LARGE WHALE EXAMINATION AND NECROPSY	91
ON-SHORE NECROPSY.....	91
PLANNING & LOGISTICS.....	91
NECROPSY SITE LOCATION.....	91
DISPOSAL.....	91
TEAM MEMBER ROLES.....	92
FLOATING CARCASS.....	93
RELOCATION.....	94
TOWING.....	94
LANDING.....	95
NECROPSY.....	95
CASE HISTORY.....	96
SITE SAFETY.....	96
EXTERNAL EXAMINATION.....	96
INTERNAL GROSS EXAMINATION.....	96
AT SEA EXAMINATION.....	97
NECROPSY LOGISTICS.....	97
DOCUMENTATION.....	97
CREW.....	97
SAMPLING.....	97
APPENDICES.....	101
APPENDIX A: Gross Necropsy Report.....	101
APPENDIX B: Guidelines to Writing a Gross Necropsy Report.....	108
APPENDIX C: Human Interaction Evaluation Form & Instructions.....	110
APPENDIX D: Equipment Necessary for a Complete Necropsy on Pinnipeds and Small Cetaceans	121
APPENDIX E: Pinniped Morphometric Data Record	122
APPENDIX F: Cetacean Morphometric Data Record	123
APPENDIX G: Blank Photo ID Card.....	124
APPENDIX H: Necropsy Sample Collection Inventory	125

TABLE OF CONTENTS (cont.)

GLOSSARY OF TERMS.....	127
RESOURCES.....	131

LIST OF FIGURES AND TABLES

SECTION ONE

Figure 1-1: Incisions for blubber thickness.....	18
Figure 1-2: Incisions for blubber thickness.....	18
Figure 1-3: Blubber thickness measurement.....	18

SECTION TWO

Table 2-1: Samples to collect according to decomposition code.....	21
Figure 2-1: Single tissue bagging and tagging.....	26
Figure 2-2: Multiple tissue bagging and tagging.....	27

SECTION THREE

Figure 3-1: Fresh pinniped carcass.....	29
Figure 3-2: Moderately decomposed pinniped carcass.....	29
Figure 3-3: Advanced decomposition of a pinniped carcass.....	30
Figure 3-4: Mummified or skeletal remains of a pinniped carcass.....	30
Figure 3-5: Robust pinniped.....	30
Figure 3-6: Emaciated pinniped.....	30
Figure 3-7: Male pinniped external ID.....	31
Figure 3-8: Female pinniped external ID.....	31
Figure 3-9: Fungal dermatitis with alopecia.....	32
Figure 3-10: Fungal dermatitis.....	32
Figure 3-11: Chronic dermal ulcer.....	33
Figure 3-12: Removal of lower left jaw.....	33
Figure 3-13: Removal of lower left jaw.....	33
Figure 3-14: Removal of lower left jaw.....	33
Figure 3-15: Removal of skin and blubber.....	34
Figure 3-16: Reflection of blubber along the fascial plane.....	34
Figure 3-17: Reflection of blubber along the fascial plane.....	35
Figure 3-18: Normal blubber.....	35
Figure 3-19: Panniculitis.....	35
Figure 3-20: Location of the prescapular lymph node in situ.....	36
Figure 3-21: Normal lymph node.....	36
Figure 3-22: Lymphoid hyperplasia.....	36
Figure 3-23: Location of thyroid.....	37
Figure 3-24: Normal thyroid with parathyroid.....	37
Figure 3-25: Lateral rib cage articulation.....	38
Figure 3-26: First view of exposed body cavity.....	38
Figure 3-27: Location of the tracheobronchial lymph node.....	39
Figure 3-28: Lymphoid hyperplasia.....	39
Figure 3-29: Lung.....	40
Figure 3-30: Interstitial pneumonia.....	40
Figure 3-31: Pulmonary edema.....	40
Figure 3-32: Pulmonary abscess.....	41

LIST OF FIGURES AND TABLES (cont.)

SECTION THREE (cont.)

Figure 3-33: Lobar pneumonia.....	41
Figure 3-34: Lung worms.....	41
Figure 3-35: Structures of the heart (external).....	42
Figure 3-36: Suggested pathway to open heart.....	42
Figure 3-37: Liver with intact gallbladder.....	43
Figure 3-38: Liver, stomach, spleen in situ.....	44
Figure 3-39: Icterus or fatty change of the liver.....	44
Figure 3-40: Spleen.....	44
Figure 3-41: Mesentery and mesenteric lymph node.....	45
Figure 3-42: Reactive mesenteric lymph node.....	46
Figure 3-43: Location of the adrenal gland and kidney in situ.....	46
Figure 3-44: Normal adrenal glands.....	46
Figure 3-45: Reniculi.....	47
Figure 3-46: Location of urinary bladder in situ.....	47
Figure 3-47a: Stenosis of bladder.....	48
Figure 3-47b: Stenosis of bladder.....	48
Figure 3-48: Location of testes in situ.....	49
Figure 3-49: Normal testes.....	49
Figure 3-50: Stomach removed from cavity.....	49
Figure 3-51: Stomach mucosa.....	50
Figure 3-52: Separation of skull from atlas.....	51
Figure 3-53: Flensed skull.....	51
Figure 3-54: Exposed brain in skull.....	52
Figure 3-55: Brain hemorrhage.....	52

SECTION FOUR

Figure 4-1: Fresh cetacean carcass.....	53
Figure 4-2: Moderate decomposition of a cetacean carcass.....	54
Figure 4-3: Advanced decomposition of a cetacean carcass.....	54
Figure 4-4: Mummified or skeletal remains of a cetacean.....	54
Figure 4-5: Robust cetacean.....	55
Figure 4-6: Emaciated cetacean.....	55
Figure 4-7: Female delphinid.....	56
Figure 4-8: Male delphinid.....	56
Figure 4-9: Fungal dermatitis.....	57
Figure 4-10: Lesions caused by a sea lamprey.....	57
Figure 4-11: Skin lesion.....	58
Figure 4-12: Tattoo lesion.....	58
Figure 4-13a: Dolphin pox.....	58
Figure 4-13a: Dolphin pox.....	58
Figure 4-14: Dermal papilloma.....	58
Figure 4-15: Skin sample.....	59
Figure 4-16: Removal of lower teeth.....	59
Figure 4-17: Removal of lower teeth.....	59

LIST OF FIGURES AND TABLES (cont.)

CHAPTER FOUR (cont.)

Figure 4-18: Removal of lower teeth.....	59
Figure 4-19: Multiple full blubber thickness incisions.....	60
Figure 4-20: Reflection of blubber along the fascial plane.....	60
Figure 4-21: Reflection of blubber along the fascial plane.....	60
Figure 4-22: Panels of blubber reflected away from carcass.....	61
Figure 4-23: Separation of skin from blubber.....	61
Figure 4-24: <i>Phyllobothrium</i> sp.	61
Figure 4-25: <i>Crassicauda</i> sp.	61
Figure 4-26: <i>Monorygma</i> sp.....	62
Figure 4-27: Bubbles within the blubber/muscle fascia.....	62
Figure 4-28: Focal abscessation.....	62
Figure 4-29: Removal of the epaxial muscle mass.....	63
Figure 4-30: Location of the prescapular lymph node in situ.....	63
Figure 4-31: Removal of the scapula.....	63
Figure 4-32: Costal rib articulation.....	64
Figure 4-33: Removal of ribs at the sternum articulation.....	64
Figure 4-34: Double-articulated rib.....	65
Figure 4-35: Viscera with the ribs removed.....	65
Figure 4-36: Location of the tracheobronchial lymph node.....	66
Figure 4-37: Lung removed from carcass.....	67
Figure 4-38: Lymphosarcoma—lung.....	67
Figure 4-39: Pleural fibrosis—lung.....	67
Figure 4-40: Aspergilloma—lung.....	68
Figure 4-41: Parasitic cyst—lung.....	68
Figure 4-42: Pulmonary abscess.....	68
Figure 4-43: Pulmonary hemorrhage.....	68
Figure 4-44: External structure of the heart.....	69
Figure 4-45: Suggested pathway to open the heart.....	69
Figure 4-46: Endocardium.....	70
Figure 4-47: Normal A-V valves.....	70
Figure 4-48: Valvular Endocardiosis.....	70
Figure 4-49: Fibrosis; arteriosclerosis; mineralization.....	71
Figure 4-50: Abdominal viscera in situ.....	71
Figure 4-51: Liver in situ.....	72
Figure 4-52: Fibrin tag.....	72
Figure 4-53: Lymphosarcoma—liver.....	72
Figure 4-54: Liver flukes.....	73
Figure 4-55: Location of spleen.....	73
Figure 4-56: Multifocal granulomas—spleen.....	74
Figure 4-57: Normal spleen.....	74
Figure 4-58: Location of the pancreas.....	74
Figure 4-59: Normal pancreas.....	75
Figure 4-60: Intraductal trematodes.....	75

LIST OF FIGURES AND TABLES (cont.)

CHAPTER FOUR (cont.)

Figure 4-61: Mesentery.....	75
Figure 4-62: Lymphosarcoma—mesentery.....	76
Figure 4-63: Lymphadenitis—mesenteric lymph node.....	76
Figure 4-64: Follicular hyperplasia—mesenteric lymph node.....	76
Figure 4-65: Location of adrenal gland.....	77
Figure 4-66: Cortico-medullary adrenal hemorrhage.....	77
Figure 4-67: Reniculi.....	78
Figure 4-68: Adrenomegaly.....	78
Figure 4-69: Renal lymphosarcoma.....	78
Figure 4-70: Inter-lobular renal fat; or steatosis—kidney.....	79
Figure 4-71: Bubbles within the renal capsule.....	79
Figure 4-72: Location of urinary bladder.....	79
Figure 4-73: Female reproductive tract.....	80
Figure 4-74: Stigma on ovary.....	81
Figure 4-75: Corpus luteum hemorrhage.....	81
Figure 4-76: Ovarian cyst.....	81
Figure 4-77: Capsular fibrosis.....	81
Figure 4-78: Location of testes.....	82
Figure 4-79: Normal, immature testes.....	82
Figure 4-80: Cross section of the vas deferens.....	82
Figure 4-81: <i>Monorygma</i> sp.....	83
Figure 4-82: <i>Monorygma</i> sp.....	83
Figure 4-83: Stomach removed from carcass.....	84
Figure 4-84: Fore stomach mucosa.....	84
Figure 4-85: Main stomach mucosa.....	84
Figure 4-86: Adhesions of the omentum.....	85
Figure 4-87: Lymphosarcoma—gastric.....	85
Figure 4-88: Stomach ulcer.....	85
Figure 4-89: Stomach ulcer.....	85
Figure 4-90: Intestine mucosa.....	86
Figure 4-91: <i>Acanthocephalans</i> sp.....	86
Figure 4-92: Skull cap removed to expose brain tissue.....	87
Figure 4-93: Brain removed from skull.....	88
Figure 4-94: Internal structures of the brain.....	88
Figure 4-95: Parasitic abscess—brain.....	88
Figure 4-96: Necrotizing encephalitis.....	89
Figure 4-97: Meningoencephalitis and hemorrhage.....	89

SECTION FIVE

Figure 5-1: Line impressions around peduncle.....	94
Figure 5-2: Towing bridle.....	95
Figure 5-3: Heavy equipment on the beach.....	95

Acknowledgements:

We would like to thank the NOAA Prescott Program for support to do this work, and the CCSN volunteers who assisted through the many hours of necropsies, especially Joy Marzolf and Aelaria Rupploa (IFAW) for their photography expertise during such necropsies. A major thank you to Sue Barco and staff from the Virginia Aquarium Stranding Program, Greg Early of Mote Marine Laboratory, Steven Raverty from the Department of Fisheries and Oceans in Canada, David Rotstein from the University of Tennessee and Judy St Leger of Sea World, San Diego for their constructive edits on earlier versions of this manual.

This page intentionally left blank.

- SECTION ONE -

Introduction and Preliminary Data

Introduction

Necropsies are performed to get further insight into the cause of death: in the case of marine mammals this may establish the cause for stranding or other mortalities. The necropsy generates a series of gross observations that establishes a differential diagnosis. Subsequent investigations, such as histopathology, are then guided as the various potential diagnoses are eliminated until an etiology is established. Regardless of whether it is a common chronic disease, fisheries interaction, or an emerging zoonoses, by consistently conducting necropsies, trends in population health can be monitored.

This guide is designed to establish a base level of proficiency in marine mammal necropsy techniques. It is written for stranding network members who do not have a formal pathobiological training and have limited knowledge of anatomy. Anatomical and pathological jargon has been kept to a minimum.

This manual is divided into six sections: preliminary data, sample management, pinniped, small cetacean, large whale (at sea and on the beach), and multiple appendices (A-H). A well-illustrated, carefully written gross necropsy report is essential to an adequate diagnostic investigation. Gross reports with significant detail and description tend to engender useful histopathological findings. A sample blank gross necropsy report and guidelines in writing a report can be found in Appendices A & B.

Overall, this guide aims to lead the enquiring mind through the necessary steps to produce such reports. While this manual focuses on process and interpretation, it is important to understand that the gross necropsy is primarily about making detailed, descriptive observations without bias as to possible etiology. The necropsy should establish a list of differential diagnoses and the sampling be directed by an attempt to discriminate between them.

Throughout this manual there are images of both normal and abnormal tissues documented in cases of stranded marine mammals on Cape Cod, Massachusetts. These images serve to give the beginner an example of what normal and abnormal may look like. We do not encourage the prosector to utilize these photos as a way to identify a specific pathology. The most important part of a necropsy is to accurately describe what you see as you see it. If experience has allowed one to recognize specific conditions, this information may be added to the report **following** the initial gross description.

Note: To avoid confusion regarding the asymmetry of marine mammals, photos have not been arranged in the conventional manner with the cranial aspect to the left. Images are inserted into this manual as they were originally taken. Also, many of the images have been cropped for clarity, at times hiding the sample identification tag that should be included in every image.

A gross description and morphologic diagnosis and/or etiology are provided with the majority of gross images throughout this manual. The morphologic diagnosis reflects subsequent histological

observations where available which are designated with an asterisk. Where histology is not available for a particular gross lesion image, similar prior cases with histological analysis have been used to infer a morphologic diagnosis. In addition, many gross appearances and common pathologies are similar among marine mammal species and photos throughout this manual can be applied to all orders discussed.

This manual, although targeted for a US audience, has utility for any region of the world.

Safety

Harmful zoonotic organisms can be encountered within the carcasses of marine mammals, thus, personal and public safety precautions should be taken when handling dead marine mammals and tissues. Protective gear, such as disposable gloves, goggles, face masks, or splash shields should be worn to reduce the risk of contamination. All existing wounds should be well bandaged prior to beginning the necropsy and any injuries sustained during the necropsy should be thoroughly cleaned, bandaged and documented. Well stocked first aid kits should be on site at all times. If professional medical attention is required, be sure to inform the provider of your exposure to marine mammal diseases. Proper disposal receptacles for blades, knives, and needles as well as chemical spill treatment kits should be easily accessible. All chemicals should be handled in a well ventilated area. Exposed skin should be thoroughly scrubbed before leaving the lab or site. Equipment should be cleaned and disinfected. Disposal of the carcass should be well thought out as to not expose the general public to the potential hazards. Please refer to the Geraci and Lounsbury (2005) for proper disposal options.

Preliminary Data

Prior to commencement of a necropsy, all necessary equipment should be set up and accessible. A sample equipment list can be found in Appendix C of this guide.

Animal History

Strandings offer a unique opportunity to study marine mammals when observed and documented by bystanders and stranding network personnel. Knowledge of the animal's stranding history is helpful in evaluating the animal for evidence of human interaction and determining the cause and manner of death. It is imperative to remember that a thorough necropsy begins with the stranding event itself. Information that you should collect before the necropsy begins includes:

- Time and date of stranding. (Months are best written in words to avoid US/ European confusion of day and month)
- Environmental conditions prior to and at time of stranding
- Location of stranding, including GPS coordinates and topographic features
- Behavior prior to and during stranding
- Single or mass stranding (note single or multi-species)
- Time and date of death
- Euthanized or natural death
- If there is a current Unusual Mortality Event (UME) under investigation
- Mode of storage prior to necropsy*

Details of any rope or other gear or debris attached to the carcass during recovery,
including gear no longer on the animal at time of collection/necropsy
Record of any trauma known to be inflicted (pre- or post mortem)

*If storage prior to necropsy is necessary, such as overnight, refrigerate the carcass as soon as possible. The carcass must be examined for evidence of human interaction and morphometric data collected before storage. Try to avoid freezing prior to necropsy, as this interferes with microscopic assessment of tissues.

Other information that may prove to be helpful is time lapse between first sighting and response as well as treatment or action plans undertaken during response. Also, request photo documentation taken by the first responder. These are often taken when a carcass is in better (fresher) condition than at the time of necropsy.

The life history stages of wild marine mammal populations have been a topic of focus for many marine mammal researchers. Age determinations for the two extreme stages, adulthood and neonate, are well understood, thus, estimations can be made for the various stages in between. Initial age classifications are based on total body length. Accurate classifications can be made through tooth (age), gonad (maturity) analyses, and, most recently, using amino acids in the lens of the eye. At the time of necropsy, the Cape Cod Stranding Network (CCSN) uses total body length to categorize both cetaceans and pinnipeds into the following categories: adult, juvenile, young of the year, and neonate. Please reference a marine mammal field guide for species-specific age estimations by length. Geraci and Lounsbury (2005) as well as Wynne and Shwartz (1999) have both proven to be helpful.

Human Interaction Evaluation

In the US, every stranded marine mammal is required to be examined thoroughly for evidence of human interaction. A complete guide to recognizing and documenting human interaction (HI) and an accompanying training program can be found in the *Handbook for Recognizing, Evaluating, and Documenting Human Interaction in Stranded Cetaceans and Pinnipeds* (Barco and Touhey, 2007). Proper training is essential in conducting these examinations. The following general information is provided from the above mentioned handbook. Please see the reference material for data sheets, instructions, and complete training materials before conducting HI examinations. An additional HI Evaluation Form and complete instructions for filling out the form can be found in Appendix C of this manual.

Goals and objectives of the evaluation

The goal of the evaluation is to determine if signs of human interaction are present on the carcass. With proper training, the HI protocol can provide stranding network personnel with the tools needed to evaluate marine mammals for signs of human interaction (HI) and to collect HI data consistently in all regions of the United States. The protocol will yield two important pieces of information. The first is an objective evaluation of an animal or carcass that determines whether any signs of human interaction are present on the animal (regardless of whether they are pre- or postmortem, healed or recent). The second is a subjective finding in which the examiner uses all available information to evaluate the likelihood that any observed evidence of HI contributed to the stranding event.

Why evaluate stranded marine mammals for signs of human interaction?

When human interaction data are gathered objectively and consistently they can provide a solid scientific foundation for conservation and management measures. Documenting the types of interactions that take place and identifying the spatial and temporal patterns associated with the interactions can highlight resource use conflicts. With a better understanding of the interactions, appropriate measures can be taken to resolve conflicts. Furthermore, in the United States, the collection of human interaction data is mandated under the Marine Mammal Protection Act. The National Oceanic and Atmospheric Administration (NOAA) Fisheries Service requires that HI data be submitted with other basic information (such as species, stranding date and location, length, etc.) on each stranded animal.

Putting the data to use

Human interaction data are frequently and easily misinterpreted. In the United States, Level A Data, including human interaction findings, are collected from each stranded marine mammal. The Level A data sheet asks “Findings of human interaction?” with multiple choice answers of YES, NO, or CBD (Could not Be Determined). The federal instructions for the data sheet state that the question is designed to determine whether or not there are signs of interaction present on the animal. This does not necessarily mean the interaction caused the stranding or the death of the animal.

Tips for conducting an evaluation

- **Develop a routine** - follow it for every exam
- **Be conservative and objective**
- **Document everything**
 - Photograph (include tag & scale in every image)
 - Measure marks/lesions (all dimensions)
 - Sample (especially for histopathology)
 - Collect other evidence and maintain chain of custody
- **Interact with others** - share unusual cases and lesions with other stranding personnel, fishery managers, and veterinarians
- **Understand and acknowledge confounding variables** - decomposition, scavenger damage, sunburn, and logistics are all things that make HI evaluation difficult. Never be afraid to score something as CBD

The importance of being conservative

In addition to standardizing our protocols and maintaining objectivity when examining animals, it is essential to be conservative in our evaluations. Since these data may be used to generate policies and management strategies, they must stand up to scientific scrutiny. By making very conservative evaluations, we then ensure our data are robust and strong. Again, for the sake of consistency, we must establish what it means to be conservative. The most conservative diagnosis is always CBD (Could not Be Determined). This is a fundamental premise of this protocol. It is best understood by thinking of it this way: *every animal or carcass is a CBD until proven otherwise*. If evidence of human interaction is found, then the objective finding is YES, there were signs of HI. If the animal is thoroughly examined and no evidence of HI is found, then the answer is NO. However, if any factors compromise your ability to evaluate the carcass properly or thoroughly, then the finding must remain CBD. Factors that can affect your ability to

evaluate a stranded animal for signs of HI include, but are not limited to: decomposition, scavenger damage, predation, inexperience in conducting these exams, logistics (large animals that one cannot manipulate to examine both sides), etc. By standardizing the way we examine the animals, collect data, and document interactions, we ensure that we are not only answering the same question, but using the same basis to draw our conclusions. All organizations implementing this protocol and utilizing the data sheet will collect comparable data, affording the opportunity to analyze data on a broader scale. When collected carefully and consistently, these data can be used to describe the types of interaction taking place (e.g. monofilament vs. multifilament net entanglement, small or large vessel interaction, ingestion of debris, harassment, etc.). These data can provide a sound scientific basis for policy and management decisions, but the nature of strandings makes it inadvisable to use human interaction data to estimate mortality or changes in mortality rate due to human interaction.

Images and video

In addition to describing what you observe, it is very important to document your observations through images and video. Digital, 35mm, and slide images are excellent means of capturing your observations. If possible, video taping or digitally recording images can also provide an outstanding record of your observations. If you don't have the means to photograph or video the animal, sketch what you see. These images are important in the human interaction evaluation. Documenting the presence or absence of HI serves to support your evaluation and final diagnosis. In addition, proper documentation allows those analyzing or utilizing HI data in the future to better understand your conclusions.

When documenting your examination, remember these tips:

- Photograph/video everything – even if you don't see marks
- Always use a label and scale in all images – label should include Field #, date of stranding, species, organization; close-up shots should include the name of the lesion/body part
- Always take a wide angle image first to allow viewer to place close ups in context.
- Be aware of shadows, glare and fingers – eliminate anything that obscures image and take images from different angles
- Draw and describe all marks

Collecting physical evidence

In some instances, human interaction cases may be considered as enforcement cases in which law enforcement officers will pursue the interaction as a criminal or civil offense. For this reason, it is important to treat every HI case as a possible enforcement case. Consult with your local law enforcement officials to determine their requirements for evidence handling. Evidence, which can include gear or debris removed from the animal, photos, and tissue samples, etc., should be collected and handled in a systematic manner.

Morphometrics

Morphometric data allow for a better understanding of the relationships among age estimation, growth rate, reproductive status, and disease processes of marine mammal populations. For consistency, all measurements should be recorded in centimeters. The only exception is the measurement of blubber thickness (recorded in mm). Weight should be recorded as either an actual or estimated value in kilograms. Sample morphometric data sheets with a convenient

self-explanatory measurement diagram for both pinnipeds and small cetaceans can be found in Appendices E & F.

The procedure for collecting morphometrics is essentially the same for both small cetaceans and pinnipeds. All measurements, except for girths, should be straight measurements parallel to the long axis of the body, not following the contours of the body. A measuring tape should be set out flat next to the animal, the starting end of the tape should remain in a constant position for all the necessary measurements. This will ensure accurate and consistent data collection. For cetaceans, straight length is measured from the tip of the maxilla (upper jaw) to the fluke notch with the animal ventral side down. Pinnipeds are measured from the tip of the muzzle (nose) to the tip of the tail with the animal ventral side down. For pinnipeds, an additional measurement, curvilinear total length, is required. For this measurement, the tape should be laid on top of the animal's dorsal midline, starting at the tip of the nose and following the body contour along to the tip of the tail.

The procedure for measuring blubber thickness is the same for both cetaceans and pinnipeds. To measure blubber thickness, create three **separate** single 2" – 3" long dorsal to mid-ventral incisions through the blubber layer down to the blubber/muscle interface: one intersecting the dorsal midline, one intersecting the lateral midline, and one intersecting the ventral midline along the plane of the axillary insertion of the forelimbs (Figures 1-1 & 1-2). Place the ruler inside the incision and measure only the thickness of the blubber from the blubber/muscle interface to the skin/blubber interface (Figure 1-3). Do not include the thickness of the skin in the measurement.

Figure 1-1. Incisions for blubber thickness.

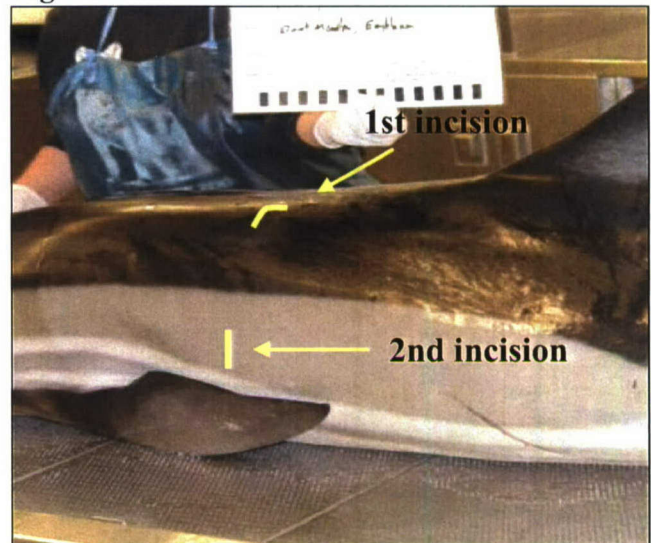


Figure 1-2. Incision for blubber thickness.

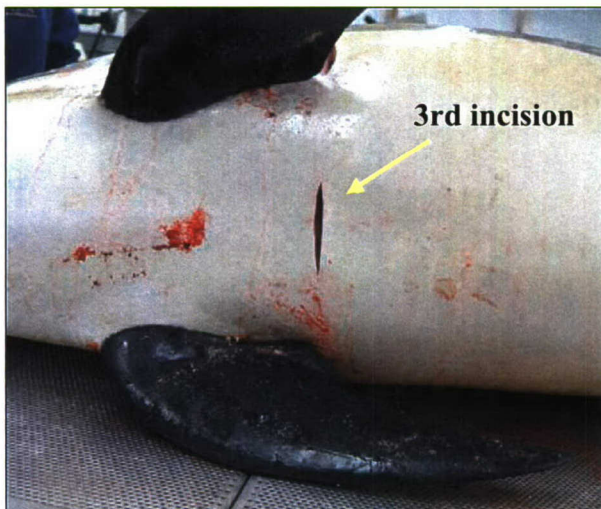
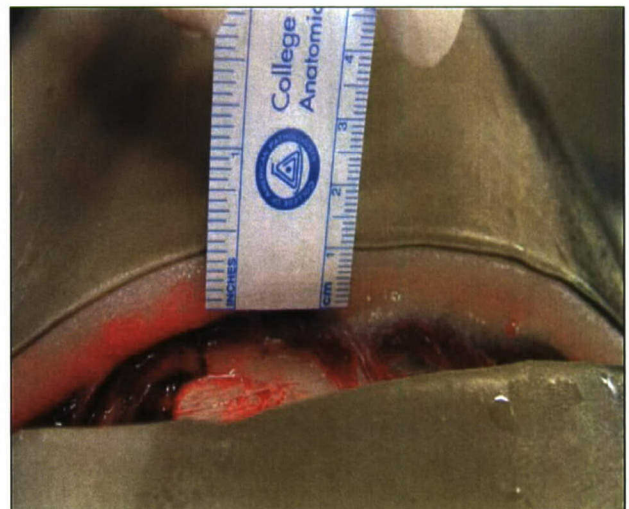

Figure 1-3. Blubber thickness measurement.



Photography

Photographs serve as the visual component to the written descriptions of each area examined on the carcass. They also allow pathologists to assess gross lesions/observations in relation to samples for analyses. When photographing during a necropsy, include a photo ID card with every picture displaying the following information:

Field number/ tag/paint stick number

Species

Date of death and necropsy

Location of stranding

Tissue/lesion

Be sure to also include a scale (cm) in each frame and make sure that the photo card, the scale, and the area of interest are all in focus and legible (watch for glare). Prior to beginning the necropsy, take photos of the external surface of the animal, with at least one full body shot of both the left and right sides of the carcass. In the case of lesions such as propeller cuts, where measurements may be taken from an image, arrange the camera to be perpendicular to the surface of interest. When photographing specific lesions, be sure to get a frame of the entire organ/tissue to reference the location of the lesion on the organ/body, as well as a closer shot to depict details of the abnormality. If the tissue has been removed from the body, rinse excess blood using a light stream of cool water to better capture the lesion. In the world of digital cameras, you can never take too many pictures. Any abnormality is worthy of a photo. A blank photo ID card is located in Appendix G.

This page intentionally left blank.

- SECTION TWO - Sample Management

A necropsy should be driven by an accumulation of observations, leading to indicated diagnostic tests. Such tests drive the precise sampling regimen. Additionally, laboratories often screen specific tissues for a given suite of potential etiologies. It is important that, while meeting routine screening goals, samples should always be taken to ensure a full differential diagnosis is considered. Thus this manual focuses on the routine screens undertaken on Cape Cod, but it should not limit the user to those goals. A necropsy sample inventory list is helpful during the necropsy to ensure that all the samples for required analyses have been taken and stored appropriately. A sample inventory list can be found in Appendix H.

The quality of samples collected diminishes with the progression of the condition code, creating greater uncertainty with results. (Determining condition codes for cetaceans and pinnipeds is discussed at the beginning of the relevant sections.) It is important to understand the priority of samples to be collected. When in doubt, collect it, and unnecessary samples can be disposed of at a later time. Table 2-1 outlines the samples of value according to condition code.

Table 2-1. Valuable sample analysis according to decomposition code.

Code 2 Fresh Carcass	Histology, Cytology, Virology (tissue), Microbiology (swabs or tissue for culture, tissue for PCR), Parasitology, Contaminants, Biotoxins, Life History, Genetics
Code 3 Moderate Decomposition	Histology (limited), Virology (PCR), Microbiology (PCR), Parasitology, Contaminants, Biotoxins, Life History, Genetics
Code 4 Advanced Decomposition	Histology (limited) Virology (PCR), Life History, Genetics
Code 5 Mummified/Skeletal Remains	Life History, Genetics

Sampling for Histopathology:

Histopathology is the microscopic examination of tissue in order to study the manifestations of disease. Histopathology is most effective when collected from the freshest (code 2) carcasses. Decomposition significantly affects the structures of tissue cells and diminishes the value of histopathology, thus only a limited reading can be expected from carcasses of a later code.

Two sets of samples are collected for histological analysis: one for the analysis, the other to archive. As a rule, the tissues should be fixed using a ratio of at least 10:1 of 10% neutral-buffered formalin to tissue. Anything less will prevent adequate fixation and the tissues will decompose. It is helpful to rinse excessively bloody samples with a light stream of water to allow for more efficient fixation. Plastic, wide-mouth, screw-top 1.0L+ jars (Nalgene™) are preferred for storing histology samples. Ideally, fixative is changed after the first hour of exposure (Luna 1992).

The histology column on the inventory list encompasses the majority of tissue requirements. Unless an abnormality is observed in lymph nodes in other locations throughout the body, only the tracheobronchial, prescapular, and mesenteric lymph nodes are suggested for histology. If tissues appear abnormal, be sure to obtain a single section that includes both normal and abnormal tissue and sample the full depth of the abnormality penetrating down to the normal tissue. It is helpful to the pathologist if a laundry tag is used to identify lymph nodes and abnormal tissue. For larger, major tissues (i.e. lung or liver) collect representative samples from all sections - caudal, cranial, medial or distal portions. Any additional tissues collected for histology should be listed at the bottom of the inventory list.

When sampling tissue for histological analysis, only a small 1 to 2 cubic cm sized section of the tissue is required. If a tissue must be larger, it is helpful to make 1 to 2 parallel incisions to allow the formalin to adequately penetrate and fix the tissue.

Try not to disrupt the surface layers or mucosa of the tissue intended for histology. Crush artifacts are easily noticeable under the microscope. The best way to ensure that the highest tissue quality is submitted for histology is to trim tissues on a cutting board with a sharp knife or scalpel, and to avoid significant pressure with forceps.

Sampling for Cytology:

Simple impression smears can give real time feed back in a variety of scenarios. Impression smears are collected by pressing a clean microscope slide on a cut surface of interest, dried and stained with one of a variety of common staining protocols. It can then be examined on site, if a microscope is available.

Sampling for Virology:

For most virology screening methods, the basic target samples are: serum, lung, liver, spleen, lymph nodes and brain. Additional samples may include skin, mucocutaneous junctions or the oral cavity, rectum, and urogenital tract. If a fetus is present, sample from the fetal tissues outlined above, as well as adrenal glands and placenta. Required tissues for morbillivirus screening are itemized on the sample inventory list provided in the appendix, along with suggested storage media. For other specific tests, consult the researcher or lab for required tissues and proper sample storage protocols (chill, fix, freeze and/or place in viral transport media).

The most accurate virology results are derived from code 2 carcasses. However, code 3 carcasses can be successfully screened for virology by Polymerase Chain Reaction (PCR) analysis. Fresh tissues should be stored in a sterile whirl pack bag or in viral transport media and transported on ice to the receiving laboratory as soon as possible. If fresh tissues will not be sent for analysis immediately, store samples at -80° C.

Virus isolation from frozen samples can be detected through PCR. Samples should be transported to the receiving laboratory on dry ice only.

With some pathogens, fixed tissues can also be utilized for specific antibody detection staining via immunohistochemical detection (IHC). Viruses may also be detected morphologically using

electron microscopy (Dykstra 1993). Use fixatives as directed by your EM laboratory.

Sampling for Microbiology:

Culture Swabs

Before establishing a bacteriology sampling protocol, discuss with your diagnostic service the nature of the swabs and media to be used to ensure a broad diagnostic capacity for aerobic and anaerobic bacteria. To prevent contamination of tissues intended for microbiology culture swabs, sterile procedures are required. External samples should be taken prior to opening the body cavity. Sample internal tissues immediately as they are exposed within the body cavity. Using a butane torch, flame a new sterile stainless steel scalpel blade rinsed in ETOH. Flame the intended incision site for 1 – 2 seconds. Make one straight incision into the tissue or cavity. Thoroughly swab inside the area with a sterile culture swab. Fluids may be aspirated into a sterile syringe and cytology, PCR, and cultures may be undertaken with the contained material. Contain swabs in appropriate transport media and seal as soon as possible to decrease chances of contamination. Swabs should be sent for bacterial and fungal (mycotic) analysis the same day. If the analysis must wait until the next day, store the swab at room temperature. Do not allow samples to freeze and do not refrigerate.

Results received from culture swabs should be interpreted with caution as bacteria tend to multiply and travel through multiple organs shortly after death. For this reason, culture swabs are preferably taken from early code 2 animals unless an unusual lesion is observed in a carcass of a later code.

Tissue Samples and PCR

Tissue samples can be taken for molecular analysis of microbial agents from carcasses of varying condition. Target tissues for this analysis vary by microorganism but can include: liver, kidney, lung, spleen, pancreas, gonads, brain, lymph nodes, conjunctiva, and mucocutaneous junctions of the oral and urogenital tracts. Consult the working researcher or lab in advance for required tissues. A small amount of tissue is needed and can be collected in centrifuge tubes or cryovials. Sterile dry swabs can also be used to collect DNA for analysis. Place swab in cryovial or collection tube. Store swabs and tissues at -80 C.

Sampling for Parasitology:

The collection of parasites is important not only for the species identification and documentation of specific parasites in marine mammals, they may also harbor pathogens and can be useful in viral isolation, such as morbillivirus. Dead parasites can be stored in ethanol at room temperature. It is always helpful to fully rinse the parasite with saline before storing in ethanol. If there is an in-house parasitologist that will look at the parasites while they are still alive, ideally within 24hrs, store samples in saline at room temperature. In any case, consult with your parasitologist for more specific guidance on sample preservation.

Sampling for Contaminants:

Toxins and other chemicals that exist in the marine environment, whether naturally occurring or

human produced, have the potential to be consumed by marine life and incorporated into their tissues. Contaminants can bioaccumulate in the tissues of marine life as they move up the food chain, and as top predators, marine mammals have the potential to retain high levels of toxins in their tissues. High contaminant levels can have numerous, negative impacts on the health of marine mammals, including compromising the immune system and affecting behavior and/or development through hormonal disruption (Geraci & Lounsbury 2005). Therefore, sampling tissues for the presence of contaminants can lead to a better understanding of the overall health and the factors involved in the animal's demise.

Blubber, muscle, liver, and kidney are tissues collected for analysis of contaminant levels. When collecting blubber, be sure to remove any skin or muscle attached. (Some laboratories may require skin and muscle to be attached to blubber. Check with receiving laboratory.) Each tissue section should be at least 100.0 grams and wrapped completely in acetone washed aluminum foil, shiny side away from the tissues. (Prior to wrapping the tissue sample, the side that will be in contact with tissue should be coated with a small amount of acetone and allowed to air dry.) The wrapped sample is then placed in a ziplock bag and stored in a -20°C freezer.

Sampling for Biotoxins:

Biotoxins are naturally occurring toxins produced by dinoflagellates and other marine algae that accumulate in animals as they are passed through the food web. Fish and invertebrates carry biotoxins that, when ingested in large quantities, prove to be harmful in larger predators, such as marine mammals. Common toxins found in marine mammals include domoic acid, brevetoxin, and saxitoxin, all of which are neurotoxins. See O'Hara and O'Shea (2001) for background. Biotoxin samples should be collected when an algal bloom is suspected in the surrounding area and/or the live animal exhibited neurological symptoms.

Biotoxin samples include tissues and fluids such as: liver, kidney, serum, aqueous humor, stomach contents, intestinal contents, feces, and urine. Tissue samples can be stored in plastic, ziplock bags. Stomach contents, intestinal contents, and feces can be collected into vials of appropriate size, usually 10-20mL containers will suffice. Collect 5—10mls of urine and 1—2 mls of aqueous humor, the thick, watery substance that is located in front of the lens of the eye, using sterile syringes and needles and store in vials of appropriate size. These samples should be stored in a -80°C freezer unless being shipped immediately on dry ice.

Life History and Genetics:

Many species that strand along the shore of Cape Cod are not resident or near-shore species, thus, little is known about their life history. Even for species where information on the local populations is sufficient, collecting and analyzing these data allow us to recognize changing trends. Age estimation, genetics, trophic position, habitat usage, and reproductive status of the stranding populations can be assessed through the collection of teeth, skin, stomach contents, gonads, and skeleton. This information not only helps us understand the dynamics of these specific populations but can also help us to interpret other findings, i.e. histopathology and contaminants, and we can recognize the impacts and vectors of potential threats to the marine environment at large.

Life History:

- The lower left jaw of a seal or 5–7 teeth from the mid-lower left mandible of an odontocete are collected into a ziplock bag and frozen at -20°C .
- Any discharge from the mammary glands can be collected into a $>10.0\text{ml}$ tube and frozen at -20°C .
- Sections of the reproductive system should be fixed separate from all other tissues intended for histology. For females, collect both ovaries and a section of the uterine horn. For males, take a section of one testis with epididymus still attached. (Notch the left ovary and testis for differentiation).
- If a fetus is present and is not large enough to conduct an individual necropsy, open the abdomen and store the entire body in formalin.
- Stomach contents are to be put into an air-tight container, leveled off with water, and chilled at 38°F . If the samples can not be processed within 48hrs, contents alone, no water, can be frozen at -20°C . Diet scientists routinely request an unopened stomach. This however compromises the gross pathology data, disallowing examination and sampling of the inner surface. This protocol achieves a workable compromise.
- Retain entire skeleton for cleaning and museum archiving. A necropsy is incomplete until all cleaned bones have been examined. Store at -20°C until ready for cleaning.

Genetics:

Two, full thickness, skin samples are taken from each animal for genetic analysis. One sample (~ 1 sq. inch) is placed in a ziplock bag and frozen at -20°C . The other of similar size is diced into 1.0 mm cubic pieces and placed in 20% dimethylsulfoxide (DMSO) salt-saturated (NaCl) solution.

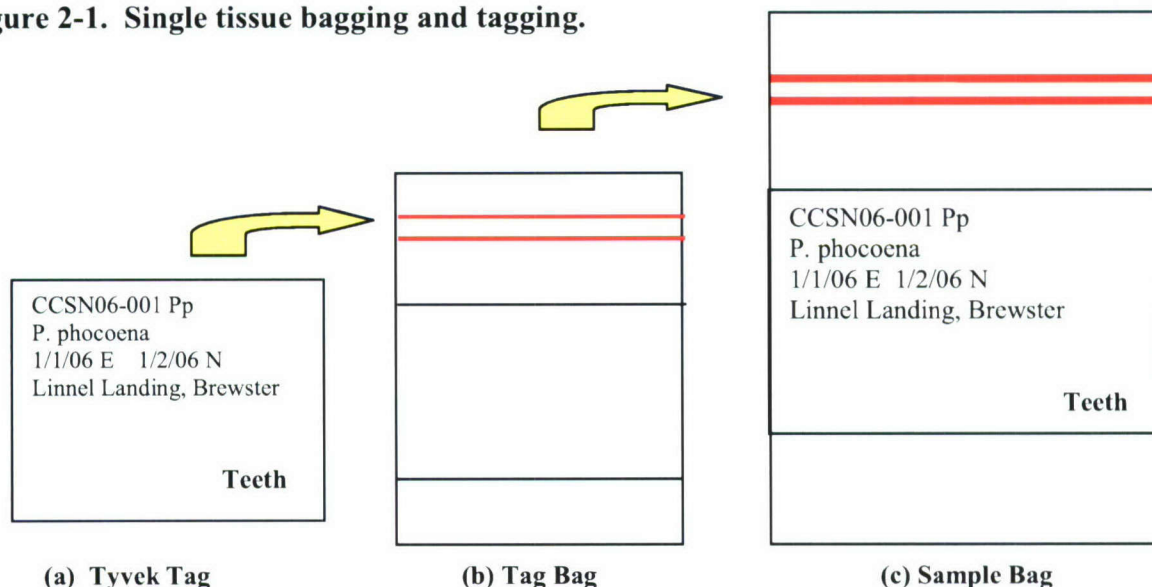
Creating Labels:

“Two is one. One is none.” At first, the labeling system may seem a little redundant, but having everything double labeled not only ensures organization to the samples taken during the necropsy process, but it also helps identify samples in the future when retrieving them for specific research. A tissue without a legible label is useless. The “Two is one. One is none.” motto means that each individual sample should have two labels: one inside the sample bag/ container and one on the outside of the sample bag/container. Please refer to the Figure (2-1) for further explanation on frozen sample storage.

The first label is written in black Sharpie on a 1 – 2 square inch piece of Tyvek tag, or other matter/chemical proof paper (Figure 2-1a). Include the animal’s field number; genus and species ID, date of animal’s death followed by how animal died if it is a code 1 (use E for euthanasia, D for natural death) or date of stranding (S) if code 2 or later, date of necropsy (N), location of stranding, and tissue type. Sometimes an animal may have a tag or paint stick number, be sure to include this information on all the labels as well. The Tyvek label (Figure 2-1a) goes into a 2 x 3 inch ziplock bag (tag bag) (Figure 2-1b) which then goes into a larger bag (Figure

2-1c) containing the individual sample. For virology samples, an ID tag (in a tag bag) can be inserted into the whirl pack bag once the tissue has been collected. The individual sample bag should be labeled in black Sharpie on the white space provided. All information should be consistent throughout the labeling process.

Figure 2-1. Single tissue bagging and tagging.

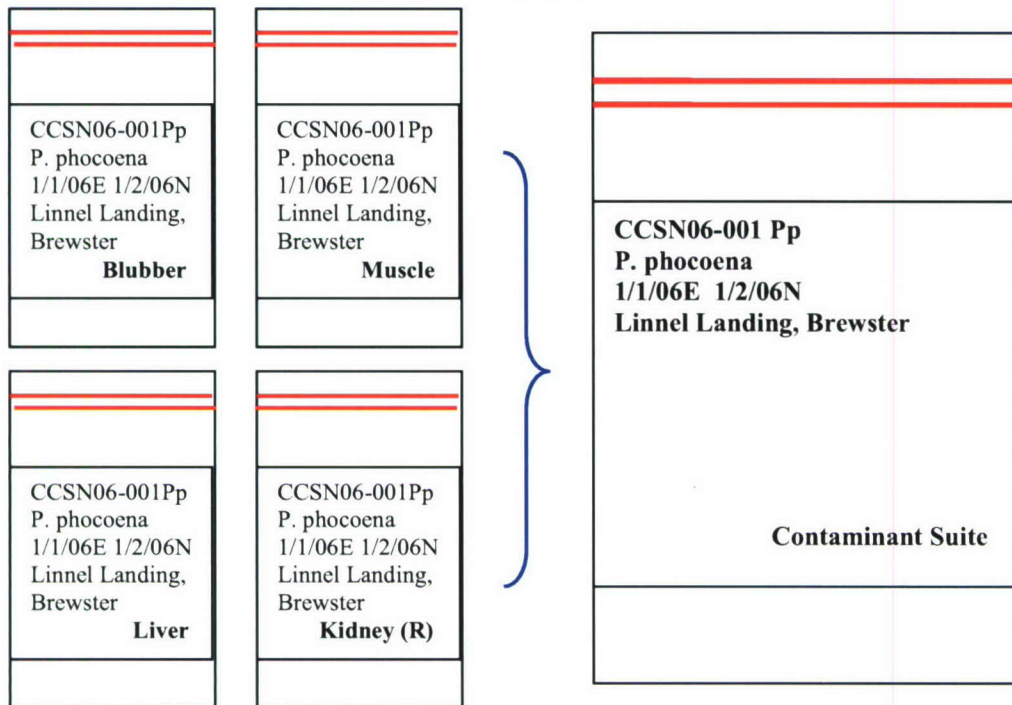


For histology samples, a label can be affixed to the outside of the jar using a black Sharpie marker on label tape. Clear packaging tape can be put over this label for reinforcement. The second label should be written on a 1 -2 square inch piece of Tyvek paper, using pencil, and placed inside the jar with the formalin and tissues.

Once all samples have been collected and placed in the appropriate bags, it is helpful to then store them in to a larger sample suite bag: frozen samples taken for life history and genetics can be put together into a larger (~ 8 x 10 inch) ziplock bag and appropriately labeled as life history and genetics; all samples for contaminants can go into a contaminants suite bag, and like-wise for herpes, morbillivirus, etc. (Figure 2-2). This is a very efficient system when retrieving samples for specific research.

The bagged sample suites can be placed together into one final large (9 x 13 inch or larger) zip-lock bag and labeled appropriately, including sample suite types.

Figure 2-2. Multiple tissue bagging and tagging.



Tracking samples:

It is extremely important that all samples archived or sent for analysis are well documented. Marine mammals and their parts are federally protected and the reporting institution is legally responsible for knowing the location of each part. Where practical, samples and data should be archived using museum curation standards.

This page intentionally left blank.

- SECTION THREE -

Pinniped Necropsy Technique and Anatomy

As a reminder, it is helpful to have all necessary equipment and sampling needs set up and accessible prior to the start of the necropsy. A sample equipment list is provided in Appendix D of this manual

External Exam

Condition Code:

Before beginning the necropsy, carcass condition must be determined to decide what degree of sampling will be of greatest value. Preferably, necropsies are performed on fresh carcasses (within 48 hours of death); however, environmental conditions can greatly impact condition code. For example, very warm weather will accelerate carcass deterioration. If human interaction is suspected, or forensic data are of value, necropsies should be conducted irrespective of tissue quality. Carcasses are classified in one of five code categories based on specific levels of decomposition:

Code 1: Alive

Code 2: Fresh carcass (Figure 3-1); < 24 hours post-mortem; normal appearance, usually with little scavenger damage; fresh smell; minimal drying and wrinkling of skin, eyes and mucous membranes; eyes clear; carcass not bloated, tongue and penis not protruded;

Code 3: Moderate decompositions (Figure 3-2); Carcass intact, bloating evident (tongue and penis protruded) and skin cracked and sloughing; possible scavenger damage; characteristic mild odor; mucous membranes dry, eyes sunken or missing;

Figure 3-1. Fresh carcass

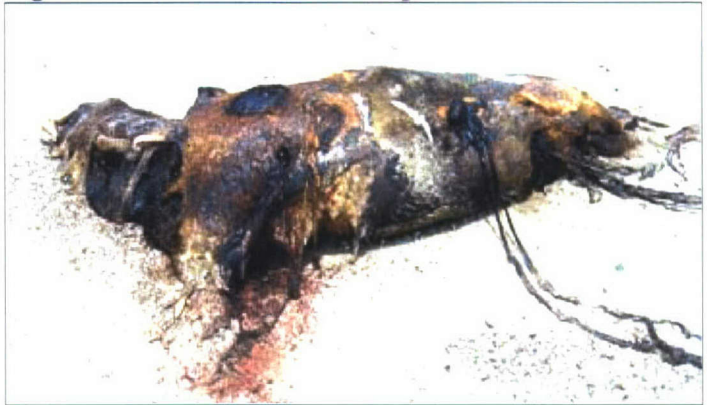

Figure 3-2. Moderate decomposition.



Code 4: Advanced decomposition (Figure 3-3); Carcass may be intact, but collapsed; skin sloughing; often severe scavenger damage; strong odor; blubber and muscle easily torn or falling off of bones; liquefied internal organs.

Figure 3-3. Advanced decomposition.



Code 5: Mummified or skeletal remains (Figure 3-4); carcass desiccated; dry pelt may be left over bones.

Figure 3-4. Mummified or skeletal remains.



Nutritional Condition:

The nutritional condition of a pinniped can be assessed by looking at the pelvic and neck regions of the animal. A **robust** animal will have a rounded, fusiform body shape (Figure 3-5). Distinction of pelvic bones and neck will not be obvious. The pelvic bones and neck will be slightly visible in a **thin** animal. An animal that is **emaciated** will have obvious protruding pelvic bones, a visible neck and a possible visible outline of the rib cage (Figure 3-6).

Figure 3-5. Robust pinniped.




Figure 3-6. Emaciated pinniped.



Sex Determination:

To determine the sex of a pinniped you must examine the ventral surface of the animal. Male seals will have a penile opening on the ventral midline caudal to the umbilical scar (Figure 3-7). You can also feel for the os penis, or penile bone, through the skin. With lactating females, two horizontally spaced, off center teats will be visible caudal to the umbilicus. For non-lactating females, the teats will be less obvious and may appear as small areas of baldness (Figure 3-8). To differentiate male and female you can also examine the peri-anal region. Females will have two openings: the anus and the vagina. Males will have only an anal opening.

Figure 3-7. Male pinniped.

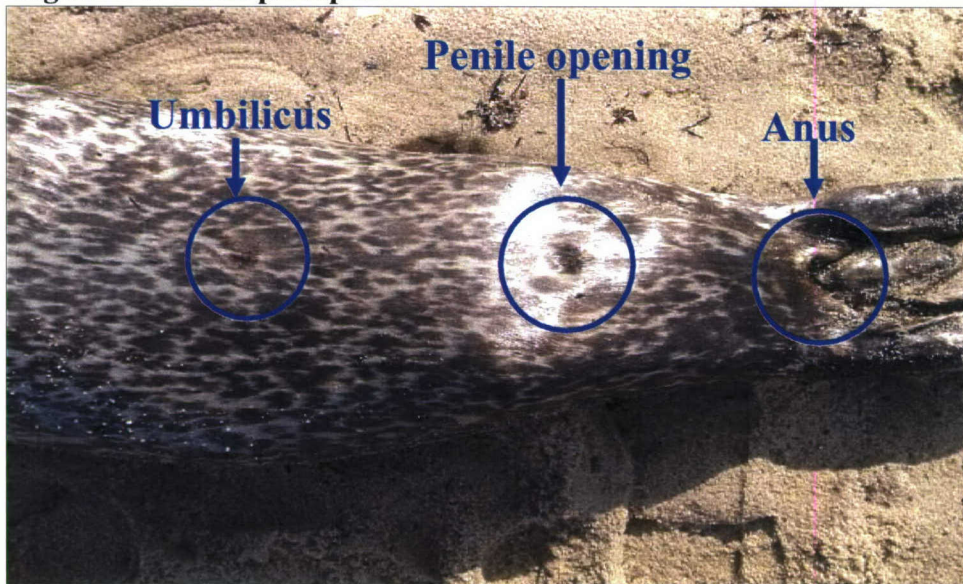



Figure 3-8. Female pinniped.

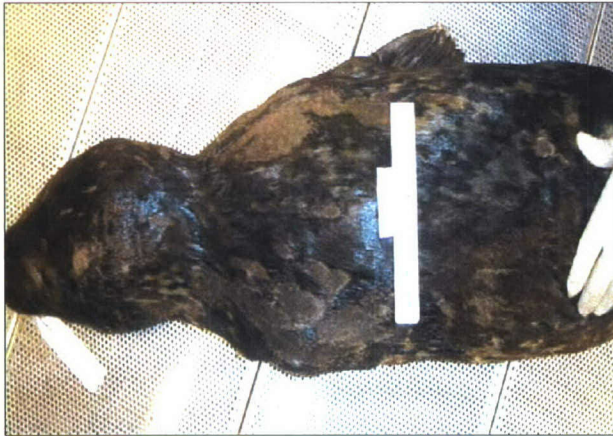

Integument:

Where collecting samples for analysis is prompted, please refer to Section 2: Sample Management.

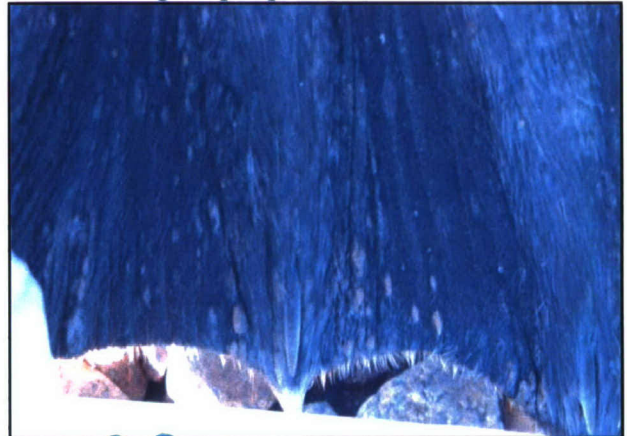
An external examination should include the investigation and description of the eyes, ears, mouth, nostrils, umbilicus, genital aperture, anus, fur, and skin. When examining the eyes, look for discoloration, injuries, or discharge. Note any swelling or discharge around the surface area of the ear opening. Document any lesions, parasites, and the mucus membrane color in the mouth. Make note of worn or missing teeth. Describe color and amount of discharge from nostrils. Obtain nasal and/or ocular culture swabs as well as culture swabs of external lesions. PCR and electron microscopy samples can also be taken. Examine the umbilicus in neonates for signs of infection as well as degree of healing. Look for lesions such as ulcerations and erosions, as well as discharge, growths, or staining around the genital area and anus. If the animal has mammary glands, attempt to express milk and note color, consistency, and estimate amount in cc's. Milk can be expressed by pressing on the body about 10cm lateral and cranial to the mammary slits and massaging downward toward the slits. Evaluate quality of fur. Look for thinning or hair loss. Thoroughly examine and document any scars, abscesses, wounds, and parasites on the skin. Make note of the size (length x width x depth/height), shape, color, texture, location, and distribution of all abnormalities. Sample unusual findings as described in the Sample Management section. Pay particular attention to regions commonly affected by fishing gear interactions such as axilla, snout, oral cavity, neck and peduncle. Lacerations, strictures, hematomas and fractures are commonly associated with entanglement in fishing gear and other debris.

Figure 3-9. Gross Description: Multifocal fur loss disseminated over the dorsal trunk and head.



Morphologic Diagnosis: *Fungal Dermatitis with alopecia

Figure 3-10. Gross Description: Multifocal, 1.0x 0.3cm oval shaped, raised, orange, firm interdigital plaques.



Morphologic Diagnosis: Fungal dermatitis.

Figure 3-11.

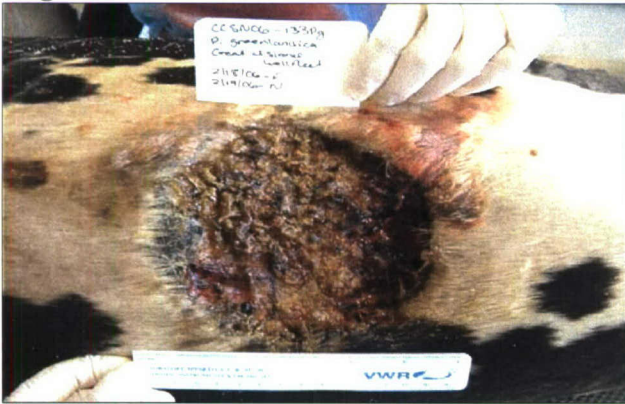

Figure 3-11. Gross Description: Large, chronic, 13.0cm circular 4.0cm deep ulceration on the caudal dorsal midline that is mottled light black to brown and has an irregular surface.

Morphologic Diagnosis: Chronic dermal ulcer.

Skin & Teeth Sampling:

Skin:

Using a scalpel blade, remove a two inch piece of skin from between the 1st and 2nd digit of the left rear flipper. Sample a section for genetics (frozen and DMSO) and histology.

Teeth:

The entire lower left jaw is removed for life history analysis (aging). This is done by first separating the right from left by cutting through the mandibular symphysis (Figure 3-12). The left mandible can be dislocated from the zygomatic arch (on the skull) by trimming away the connective tissue and muscle while rotating the bone in its joint (Figures 3-13 & 3-14). Try to avoid breaking the jaw bone during removal.

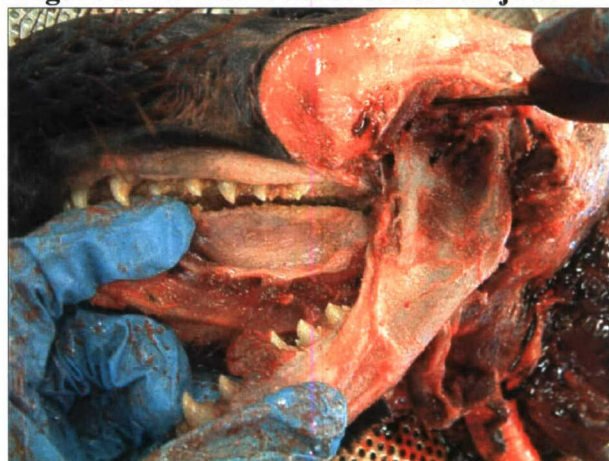
Figure 3-12. Removal of lower left jaw.

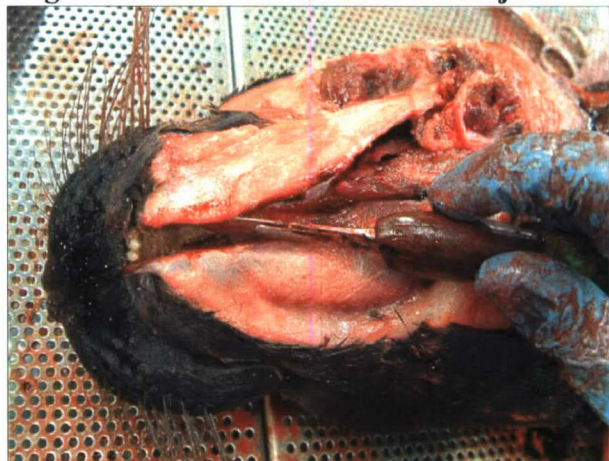

Figure 3-13. Removal of lower left jaw.

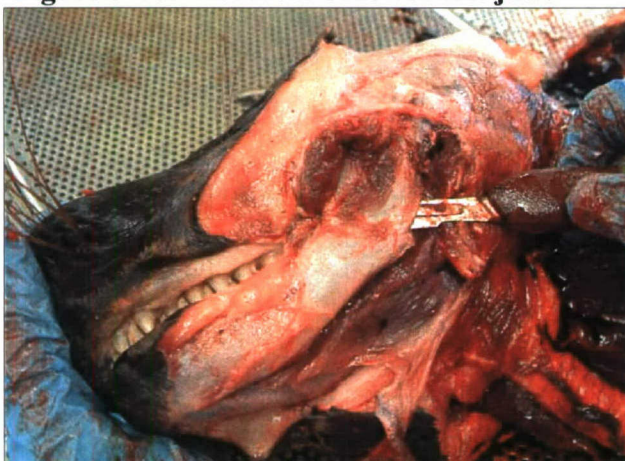

Figure 3-14. Removal of lower left jaw.



Removal of External Layers - Skin, Blubber and Muscle

Skin and Blubber:

To enter the cavity of the animal the skin, blubber, and muscle must first be removed. Begin with the animal ventral side up. With a scalpel blade, make the first incision, under the chin, near the apex of the throat, and continue down the midline to the anus. If the animal is male, course slightly left of the penile opening. The incision must incise down to the blubber/muscle interface. Do not penetrate the skeletal muscle. Next, make perpendicular incisions on either side of the midline incision approximately 15.0cm apart creating a series of panels down the length of the animal (Figure 3-15).

Figure 3-15. Animal in dorsal recumbence with numerous full blubber thickness incisions.



The blubber can easily be removed by cutting through the fascia plane and reflecting the sections of skin and blubber away from the body, in a ventral to dorsal manner (Figure 3-16). Again, do not penetrate the skeletal muscle, remain at the blubber/muscle interface (Figure 3-17). Note the thickness, texture, and color of the blubber layer. Look for parasites, bruising, and abnormalities within the blubber. Sample for histology and contaminants.

Figure 3-16. Reflection of blubber along the fascial plane.

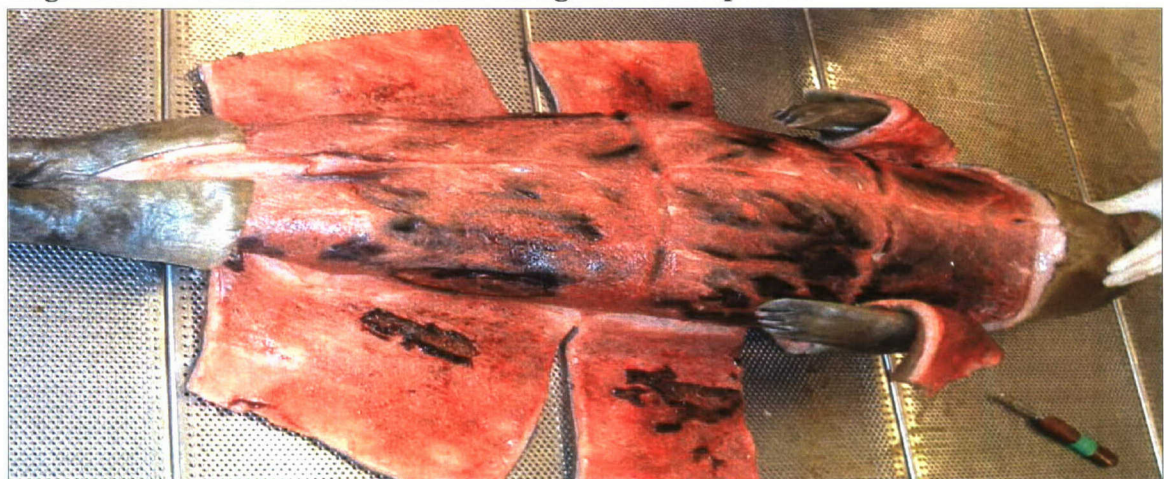


Figure 3-17. Reflection of blubber along the fascial plane.

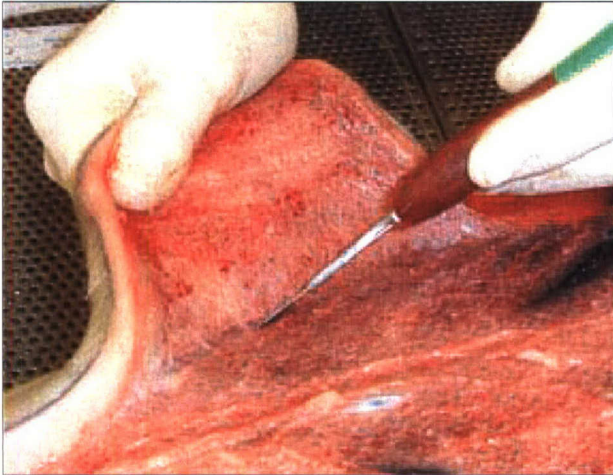


Figure 3-18. Normal blubber: Thick, firm, creamy white to light pink.

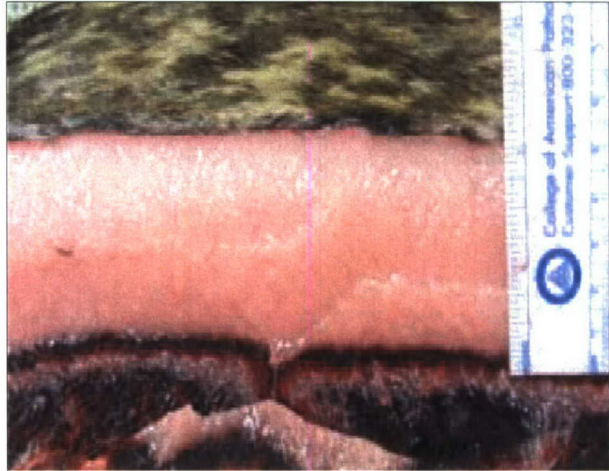
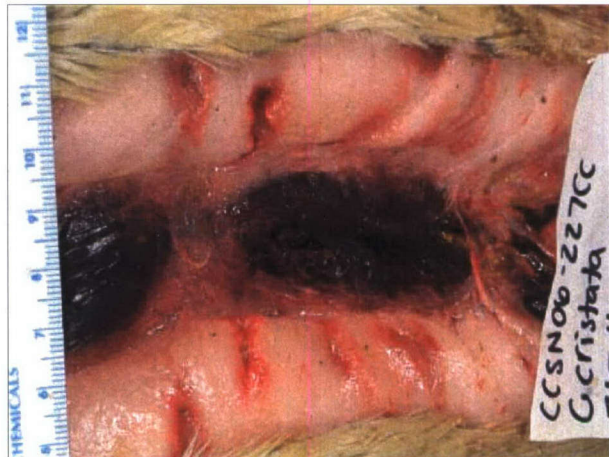


Figure 3-19. Gross Description: Several lesions spanning the thickness of the blubber of the caudal ventral abdomen characterized by cavitations and deep red, poorly demarcated edges with a green tinged center.

Morphologic diagnosis: *Panniculitis— inflammation/necrosis of subcutaneous fat.



Skeletal Muscle:

Remove the panels of blubber and skin from the carcass. Examine the quality of the fascia and muscle before removing it. Note the color, thickness, texture, and abnormalities of the muscle mass. Look for signs of bruising and hemorrhaging. Trim away excess muscle from the ventral and lateral surfaces of the rib cage. Be sure not to penetrate the body cavity. Obtain muscle samples for contaminants and histology.

Internal Examination

Removal of the Scapula and Prescapular Lymph Node:

With the animal still ventral side up, begin to remove both front flippers. Pull the appendage away from the body toward the table surface and carefully cut through the tissue that connects the flipper and scapula to the body wall. Locate the prescapular lymph node prior to the complete removal of the scapula. The oval, beige tissue is located between the scapula and body just cranial to the leading edge of the bone (Figure 3-20). Normal lymph nodes throughout the body usually share the same characteristics: a well defined round or oval shape, slightly firm texture,

color is diffusely beige to peach, with very slight differentiation between the cortex and medulla. If the lymph begins to vary from the homogenous peach to tan, it may be indicative of a reaction. Note the size, shape, color and texture of the prescapular lymph node. Be sure to distinguish changes of the cortex and changes of the medulla. Sample for histology, microbiology, molecular and other ancillary investigations.

Figure 3-20. Location of the prescapular lymph node in situ.

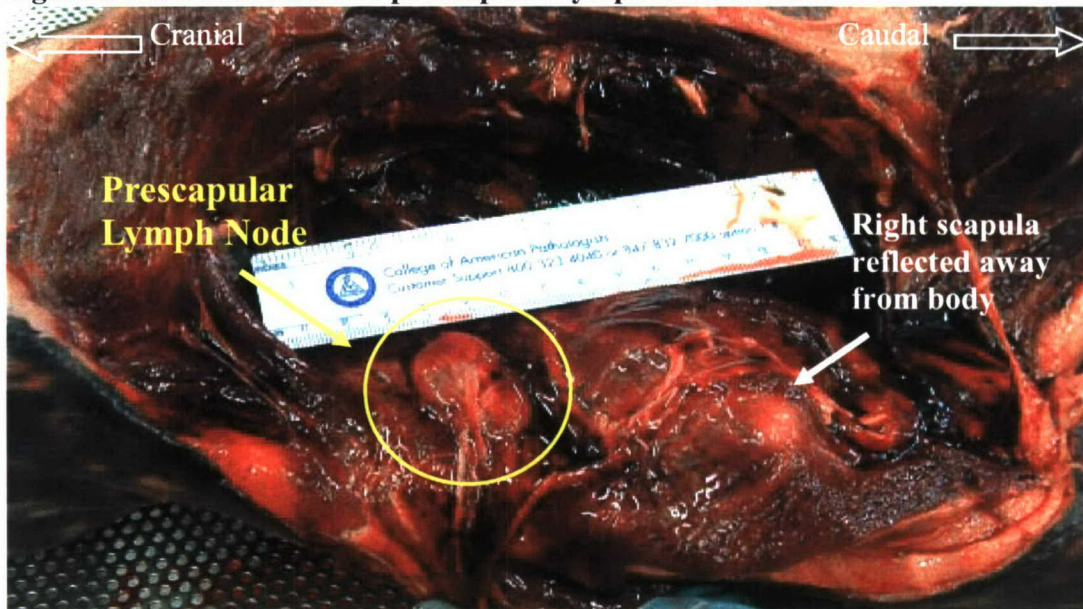


Figure 3-21. Normal lymph node

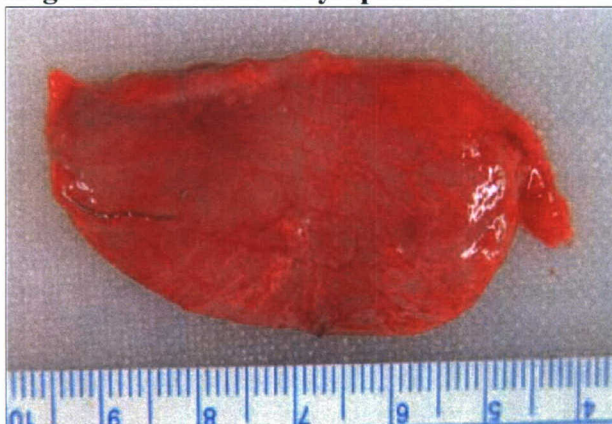
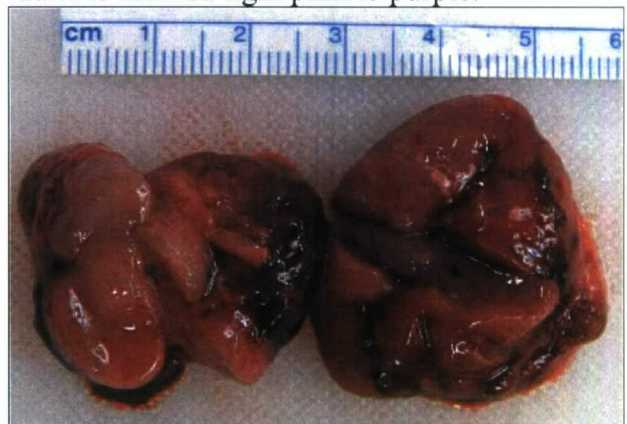

Figure 3-22. Gross Description: Connective tissue surrounding lymph node is dark red and edematous; cortex is slightly thickened; medulla is mottled light pink to purple.



Morphologic Diagnosis: Lymphoid hyperplasia.

Thyroid

Locate the paired, dark purple, discoid shaped thyroids located along either lateral side of the cranial trachea (Figure 3-23). The color and texture is often similar to smooth muscle. The parathyroid is a small, light colored tissue attached to the thyroid along the cranial margin of the thyroid

and can aid in correct tissue identification, if it can be found (Figure 3-24). Remove the tissue and describe its size, shape, color and texture. Sample for histology.

Figure 3-23. Location of thyroid; ventral side up.

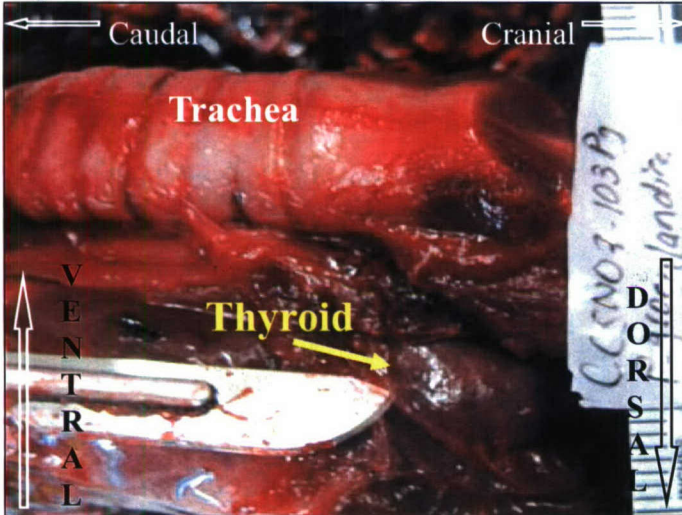
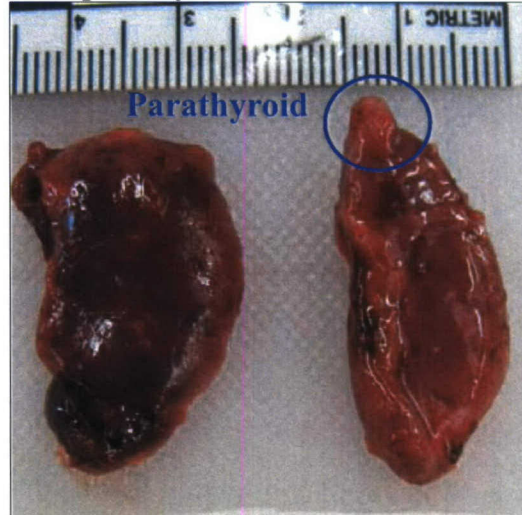


Figure 3-24. Normal, paired thyroid with parathyroid attached.



Thymus:

The thymus, a large, lymphoid organ, is primarily found in neonates and some juveniles. It is situated at the base of the thoracic inlet, cranial to the anterior margin of the heart. The primary function of this organ is to generate T-cells. The thymus is absorbed with time after weaning, thus is not usually visible in adult marine mammals. Examine the tissue externally and internally. Note the size, shape, color and texture. Sample for histology, microbiology, molecular and ancillary investigations.

Before cutting into the body cavity of an animal, to obtain uncontaminated bacterial and viral samples from the thoracic and abdominal cavities, sear a section of the body surface with a flame (such as from a propane torch), then, with a flamed blade, incise into the body cavity and insert a swab.

To expose the abdominal organs, incise the abdominal wall from the last rib mid-ventral to the hip. Extend the most cranial cut laterally along the thoracic arch and reflect the abdominal musculature to expose the internal tissues. Visually assess the orientation of the organs and collect any free fluids aseptically in a sterile syringe prior to proceeding with the internal examination.

Removal of the Rib Cage:

Before collecting any samples or cutting the ribs, the diaphragm should be punctured with a scalpel or scissors and deflation should be noted. If the diaphragm is already deflated, it is possible that a pneumothorax or severe pneumonia may be present. To open the thoracic cavity, feel for where the muscle attaches to the rib and trim away excess muscle without penetrating the diaphragm. Without breaking the bones, remove the rib cage by cutting through each thoracic rib mid-articulation, or "sweet spot". The "sweet spot" is the cartilaginous flex point that allows movement of the rib cage during inhalation and exhalation and can be felt upon palpation. To

note, age and disease may effect the way joints disarticulate. As you move cranially and are able to reflect the rib cage away from the cavity, look at the internal surface of the rib cage and you can easily see each articulation in line with another (Figure 3-25). Using this visual guide, the ribs should easily separate without breaking. Continue to remove the rib cage by reflecting back toward the cranial end of the body. Once the ventral cartilaginous rib cage is removed, examine the thoracic cavity with all organs in place (Figure 3-26). Note any discoloration, lesions, adhesions, odor, or fluid.

Figure 3-25. Lateral rib cage articulation can easily be seen from within the cavity.

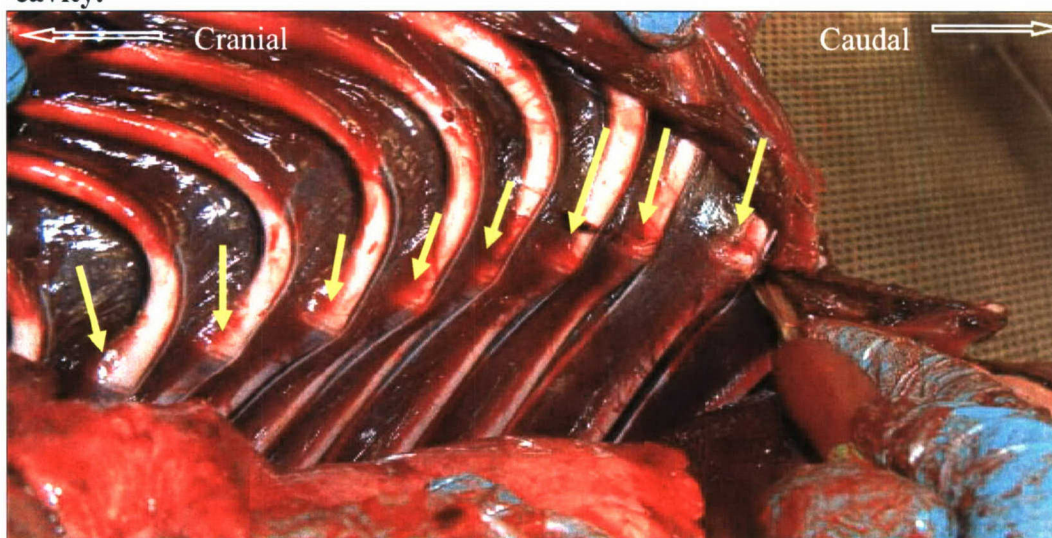
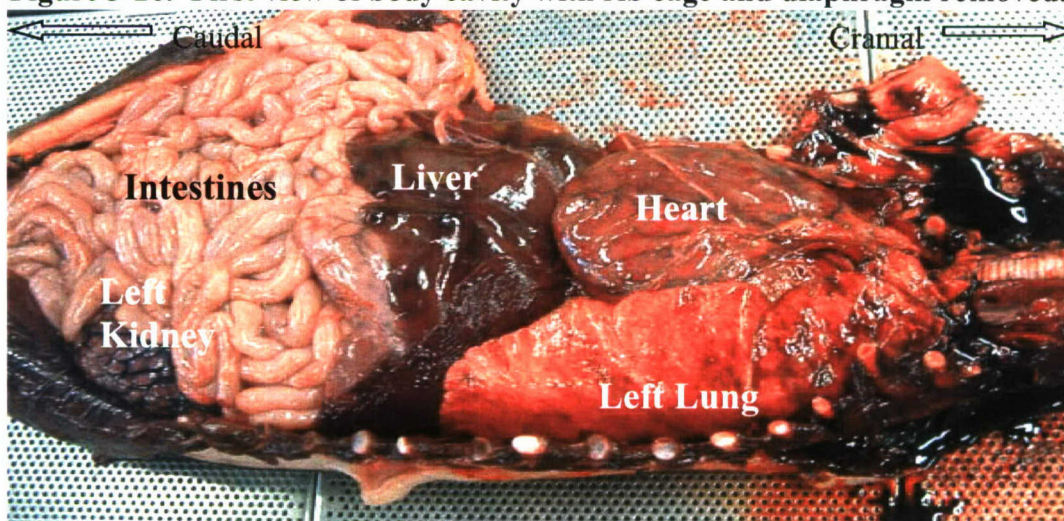


Figure 3-26. First view of body cavity with rib cage and diaphragm removed.



At this point, a systematic examination of the internal tissues needs to be followed. The organs may be removed as a pluck (organs still attached to one another), or may be removed one by one. The method of sampling can be guided by sampling needs, condition code, and personal preference. For microbiology sample collection, it is recommended that internal fluids, such as those in the gastro-intestinal system do not contaminate other tissues.

Tracheobronchial (TB) Lymph Node:

The TB lymph node is located proximal to the bifurcation of the trachea. It can easily be located by reflecting the cranial lung tissue away from the cavity and palpating the connective tissue between the lung and trachea bifurcation (Figure 3-27). It is recommended that this tissue be identified and removed prior to removal of the lung or trachea, as it can be easily lost without anatomical landmarks. Examine the lymph node externally and internally. Note the size, shape, color, and texture. Sample for histology, microbiology, molecular and ancillary investigations.

Figure 3-27. Location of the TB lymph node.

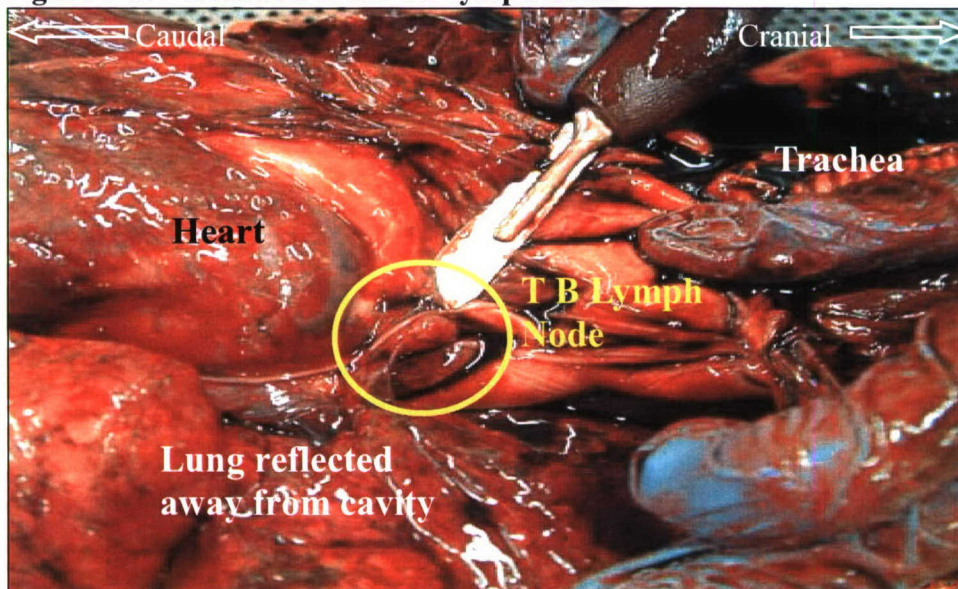
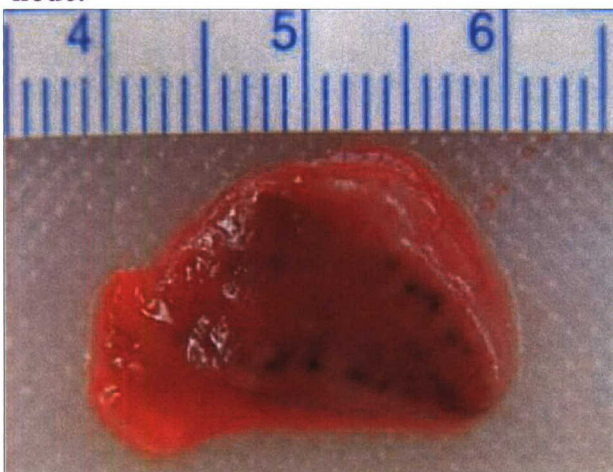

Figure 3-28. Cross section of the TB lymph node.

**Figure 3-28. Gross Description:**

Multifocal, black, focal spots along the cortico-medullary junction of the TB lymph.

Morphologic Diagnosis: Multi-focal, pigmented lymphoid hyperplasia.

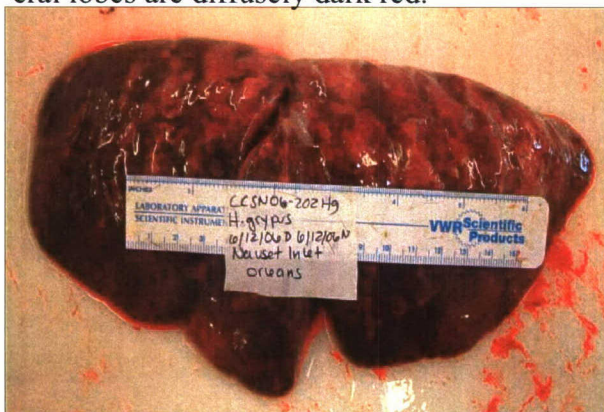
Lungs:

The lungs dominate the thoracic cavity and are the large, normally bright pink tissue with a consistent sponge-like texture. Detach the lung from the trachea at the bifurcation. Examine the pleural surface: note color pattern, and texture. Normal, air-filled lung tissue should bounce back immediately after being depressed with a finger (like a sponge) and float when placed in water or formalin. Seal lungs are comprised of a number of lobules, joined by a normally thin, translucent connective tissue which can become gas filled (emphysematous). To examine the internal structure, using scissors, trace the trachea from the bifurcation along the bronchi and into the bronchioles of each lung. Note whether fluid, froth, and/or parasites are present and describe (amount, color, etc.). Next, make serial cuts into the tissue by “bread-slicing” (making multiple, full thickness, parallel slices into the tissue) perpendicular to the long axis of the body. This is best done with a long knife using a single sweeping cut in order to avoid tearing or serrating the lung tissue. Examine the parenchyma and note color pattern and texture. Sample for histology, microbiology, molecular and ancillary investigations.

Figure 3-29. Three distinct lobes of the lung. Note the mottled pink to purple pattern on the surface.

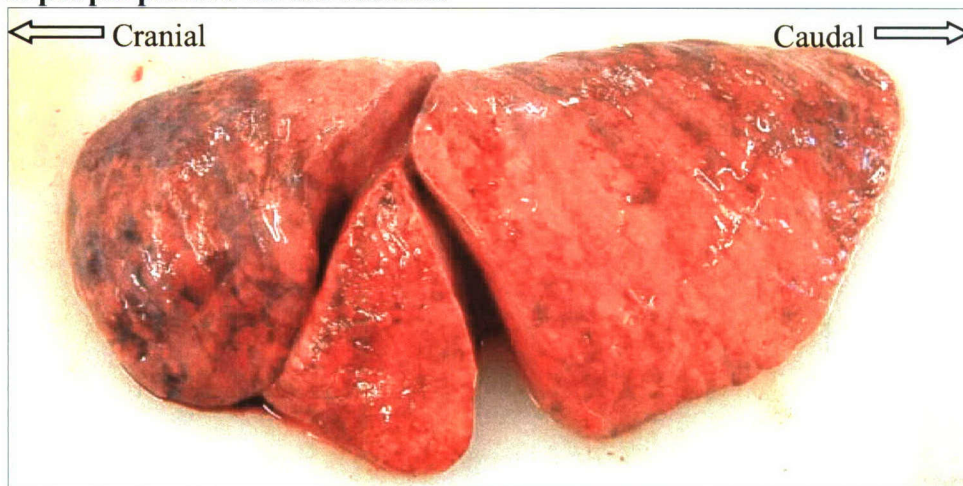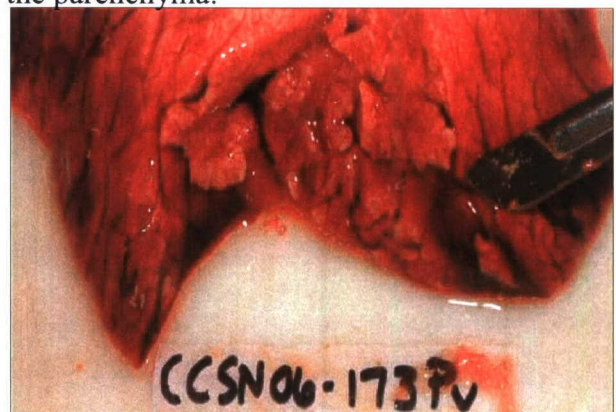


Figure 3-30. Gross Description: The pleural surface is mottled pink to maroon; peripheral lobes are diffusely dark red.



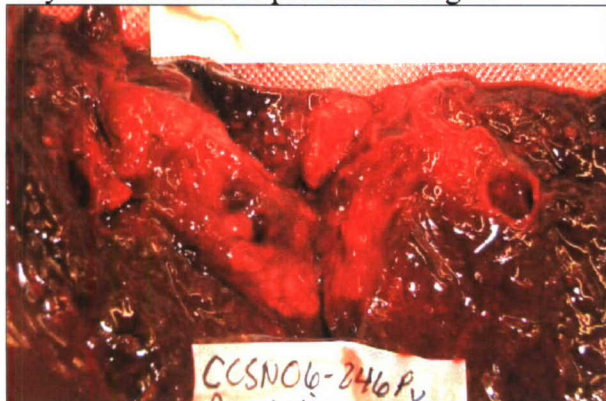Morphologic Diagnosis: *Interstitial pneumonia

Figure 3-31. Gross Description: Multifocal areas of gelatinous, deep red tissue throughout the parenchyma.



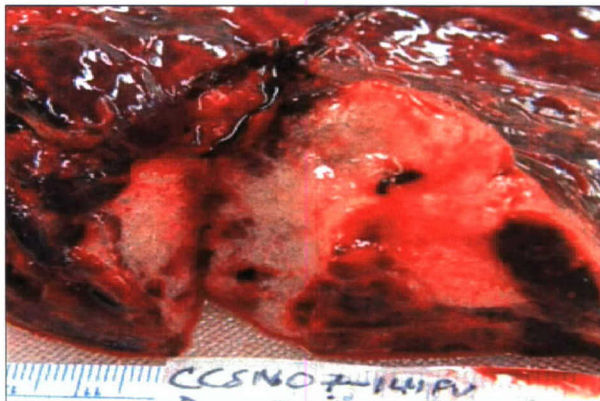
Morphologic Diagnosis: *Diffuse, interlobular pulmonary edema

Figure 3-32. Gross Description: Large (4.8 x 5.0 x 2.5cm), firm, multinodular mass with focal areas of hemorrhage within the parenchyma of the lower proximal margin.



Morphologic Diagnosis: Pulmonary abscess.

Figure 3-33. Gross Description: Focal, 6.0 x 4.0 x 2.0cm area of fibrous consolidation.



Morphologic Diagnosis: Chronic, resolved lobar pneumonia.

Figure 3-34. Opened bronchioles.

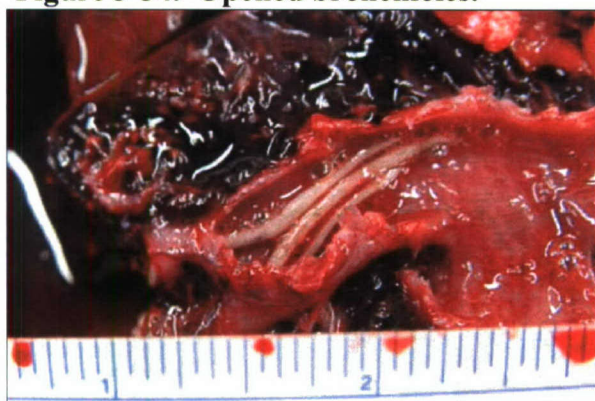

Figure 3-34. Gross Description: >1.0cm long, round white worms throughout the bronchioles with luminal mucus.

Morphologic Diagnosis: Verminous catarhal (mucoid) bronchitis.

Trachea:

The trachea is a long, firm, off-white, flexible, ridged, tubular organ. Using scissors, cut through the entire length of the trachea from the bifurcation up to the apex of the throat. Examine the mucosa and identify contents (froth, fluid, blood, color, etc.). Sample for histology.

Heart Muscle and Valves:

Before handling the heart, observe and describe the pericardium. There should be a small amount of clear fluid within the pericardium to allow for lubrication. Note if there is excessive fluid and describe the characteristics. Also, note the presence of gas bubbles within the pericardium and note thickness of the tissue. Trim away the pericardium and observe the epicardium (external surface of heart) in situ. Note size, color, and texture of the right and left atria and ventricles, aorta, pulmonary valve, as well as the mitral and tricuspid valves. (Figure 3-35). Remove the heart by cutting transversely across the aorta and pulmonary artery leaving approximately 6.0 cm of each vessel still attached to the heart muscle. There are number of techniques for examin-

-ing the internal structures of the heart. One way is to use scissors to make a small opening in the right atrium and cut down along the peripheral edge of the right ventricle down to the apex. Continue cutting along the right ventricle side of the septum until this chamber joins the pulmonary artery and cut up through this vessel. Next, snip the left ventricle side of the apex, cut through the muscle along the septum, and continue through the aorta (Figure 3-36). This process leaves both sides of the heart intact.

A simpler way to examine the endocardium (inner surface of the heart) is by slicing the organ completely in half starting at the apex going laterally toward the vessels, so that it opens up like a book. Examine each chamber for the presence of worms or other foreign matter. Note the size/thickness of each atrium and ventricle, as well as color and texture. The left ventricle should be substantially thicker than the right (~2:1 ratio). Thor-

Figure 3-35. External view of the heart.

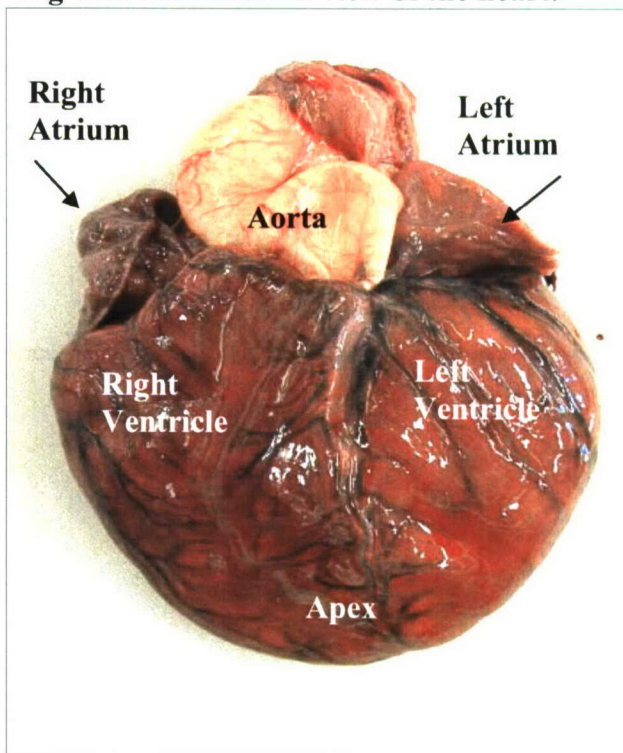
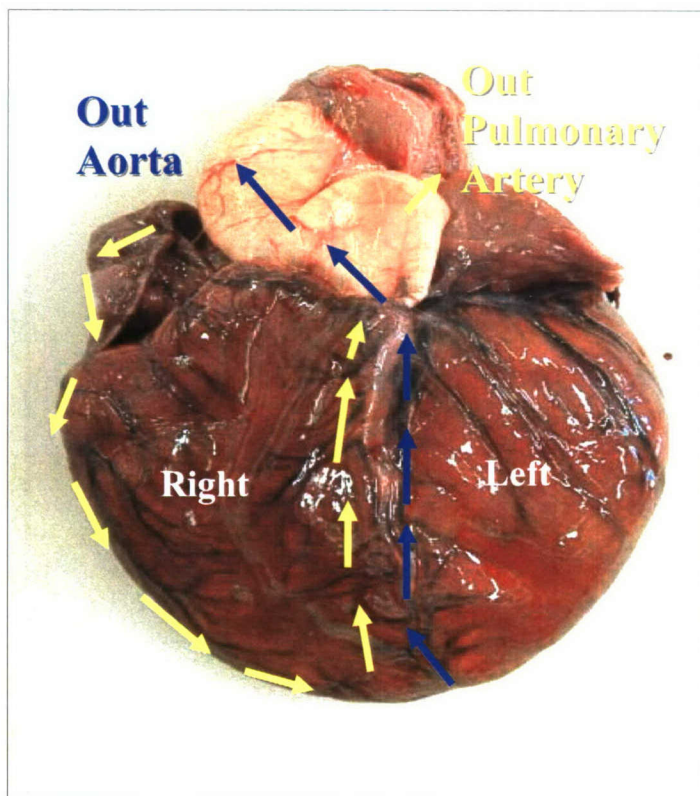


Figure 3-36. Incision pathway to open the heart.



oroughly examine the interior of the valves for a change in texture or the presence of lesions. Normal mitral and tricuspid valves should be thin and slightly opaque. Once the endocardium is examined, bread-slice the ventricles to examine changes in the myocardium. Sample the left and right ventricles and atria, septum, apex, and aorta for histology.

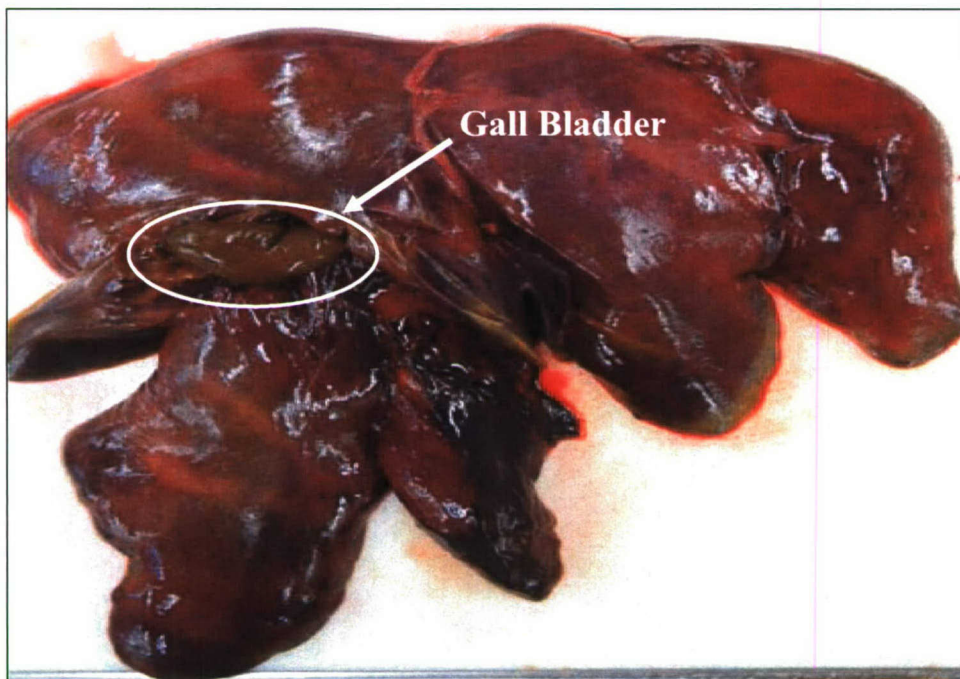
Diaphragm:

The diaphragm is the thin, smooth textured, dark maroon, expandable muscle that is attached to the caudal rib cage and separates the thoracic and abdominal cavities. Note the texture and color as well as any tears or adhesions. White striations over the surface of the diaphragm are normal. Trim away the diaphragm enough so that there is complete access to the abdominal organs. Sample for histology.

Liver:

The multi-lobular, diffusely maroon liver is quite large in pinnipeds and lies over the stomach, dominating most of the abdominal cavity (Figure 3-38). Once removed from the abdominal cavity, examine the parietal (toward the body wall) and visceral (toward the organs) surfaces of the liver and note color pattern, texture and size of the lobes (Figure 3-37). Examine the parenchyma of the liver by bread-slicing through the tissue. Again, note the color and texture within. Examine bile ducts for presence of parasites. Sample tissue for contaminants, histology, microbiology, molecular and ancillary investigations.

Figure 3-37. View of the parietal surface of a multicolored, multilobular liver with the gallbladder intact.

**Gall bladder:**

The gall bladder is a green, round, thin walled sac and can be viewed ventrally between the right and central lobes of the liver (Figure 3-37). To check for duct patency, cut into the duodenum, and observe bile flow. Aseptically collect bile for contaminants using a sterile syringe and needle. The gall bladder can be further sampled once the liver has been removed from the cavity and examined. This technique prevents contaminating the surface of the organ and remaining tissues with dark green to orange bile once punctured. Examine the gall bladder for stones and parasites. Sample for histology.

Figure 3-38. View of liver, stomach, and spleen in situ.

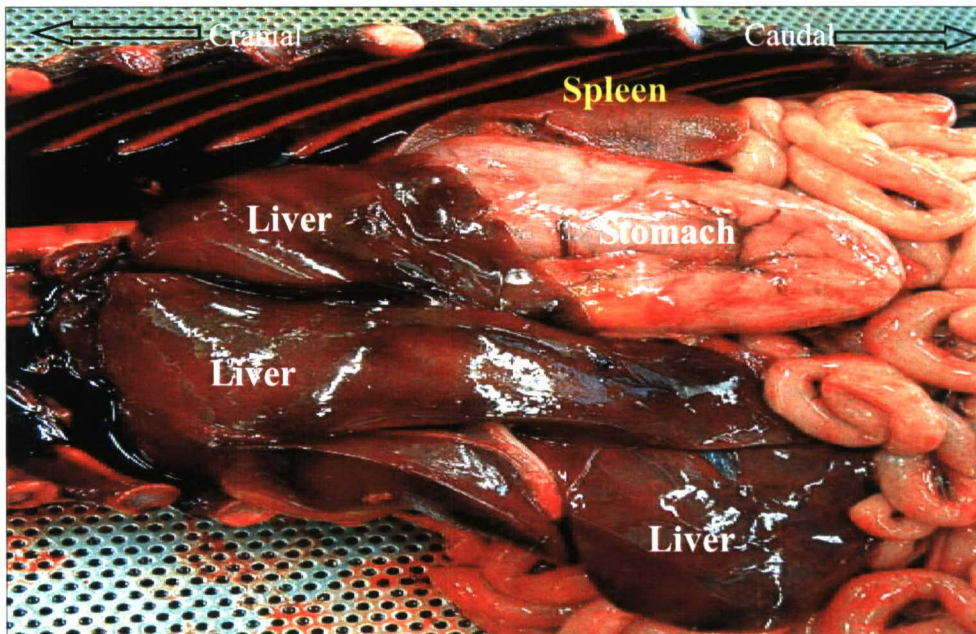
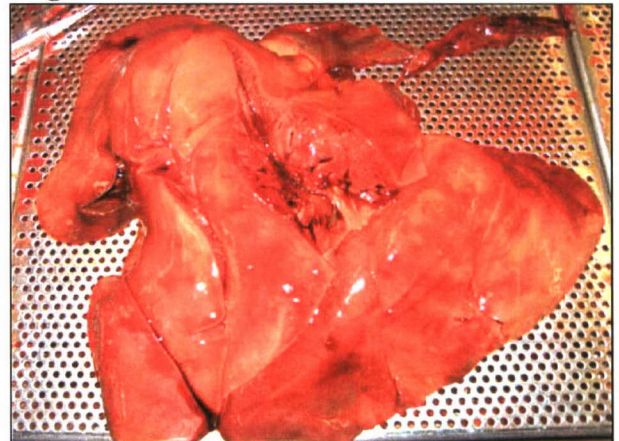


Figure 3-39. Liver removed from carcass.

Figure 3-39. Gross Description: Diffusely yellow/orange liver.

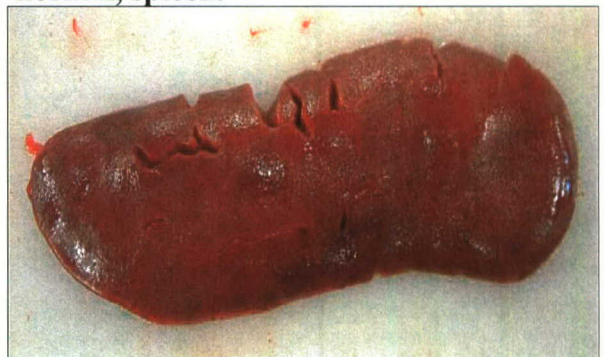Differential Diagnosis: Icterus or fatty change.



Spleen:

The spleen is a flattened, oblong, mottled purple to white organ (Figure 3-40) located underneath the stomach along the left body wall (Figure 3-38). It is common for pinniped spleens to have irregular, serrated margins. Remove the spleen by detaching it from the omentum tissue. Note size, shape, color, and texture of both the surface and the parenchyma of the spleen. Examine the internal structures by bread-slicing. Sample for histology, microbiology, molecular and ancillary investigations.

Figure 3-40. Slightly pale, but otherwise normal, spleen.



Pancreas:

The pancreas is a peach colored, irregularly shaped, lobulated, softer tissue that is attached to the mesentery and sits in the curve of the duodenum. Remove the pancreas from the cavity by detaching it from the mesenteric tissue. Note the size, shape, color and texture of the surface. Cut into the parenchyma and note changes in color or texture. Examine ducts for parasites. Sample for histology, microbiology, molecular and ancillary investigations.

Mesentery and the mesenteric lymph node:

The mesentery is the window-pane-like connective tissue band attached to the intestines (Figure 3-41). This connective tissue should be translucent and show some resistance when attempting to bluntly dissect. Examine the mesentery for any abnormal adhesions as well as congestion or thickening of the vessels. If the lymphatic vessels are distended with milky fluid it is a sign of recent feeding. Note thickness and opacity of connective tissue. The mesenteric lymph node is a finger-like, gray to tan colored, larger lymph node that is centrally attached to the mesentery (Figure 3-41). Remove the lymph node from the mesentery. Note the size and shape of the mesenteric lymph node. Examine the exterior and interior aspects for changes in color and texture. Unlike previous lymph nodes discussed, the mesenteric lymph node tends to have a more defined cortex and medulla and can be a light shade of gray. Be sure to describe these structures separately. Sample for histology, microbiology, molecular and ancillary investigations.

Figure 3-41. Mesenteric lymph node in situ attached to the mesentery.

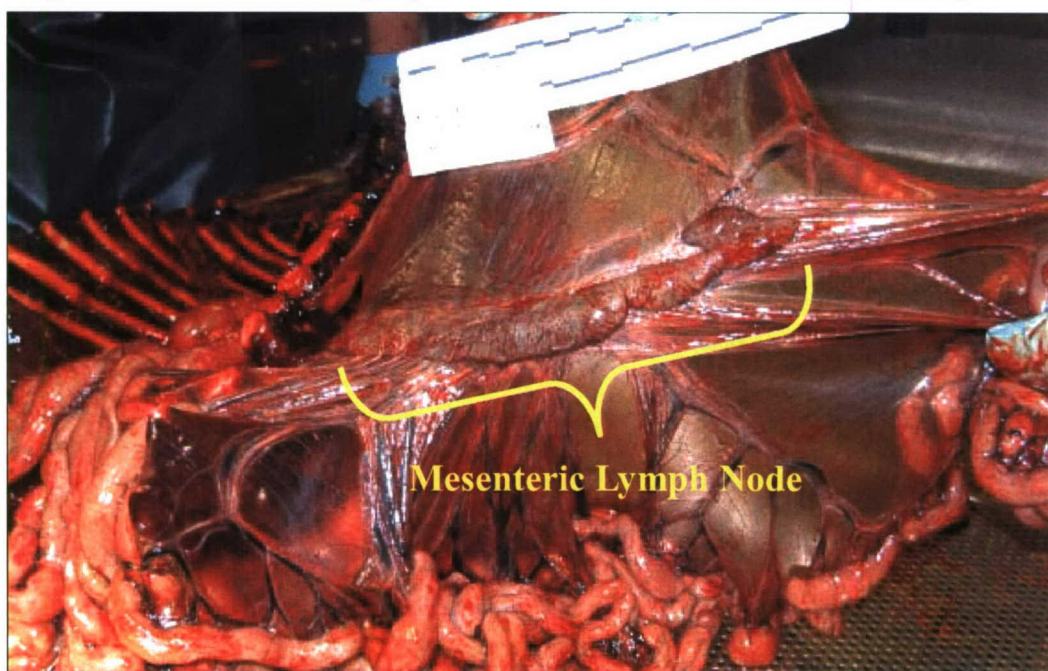


Figure 3-42. Cross-section of the mesenteric lymph node.

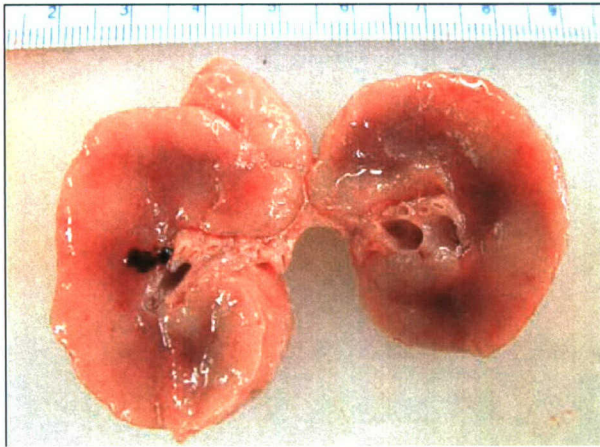


Figure 3-42. Gross Description: Lymph node is slightly enlarged and firm; cortex is thick and pink with a slight lobular pattern that infiltrates the medulla; medulla is soft and purple.

Morphologic Diagnosis: Reactive lymph node.

Adrenal Glands:

The right and left adrenal gland are located just anterior to the cranial pole of each kidney and are adhered to the dorsal abdominal wall (Figure 3-43). The adrenals are small, oblong, light maroon tissues possessing irregular furrows over the surface (Figure 3-44). Locating and extracting the adrenals prior to removing the kidneys is highly recommended, as they can be difficult to locate without the kidneys as an anatomical reference. To remove the adrenals, grasp and pull the tissue away from the body wall and cut the surrounding connective tissue. Before sectioning, measure (LxWxH) and weigh each adrenal. When cut in half, a normal adrenal will present a distinct darkened center (medulla) with a lighter perimeter (cortex). Note size, shape, color and texture of the external and internal tissue. Also, note relative size of the aperture, or opening in the medulla, which would indicate usage of the vessel. Normal apertures should be no larger than the tip of a pin. Sample each adrenal gland for histology.

Figure 3-43. Location of adrenal in relation to the kidney; adrenal is pale

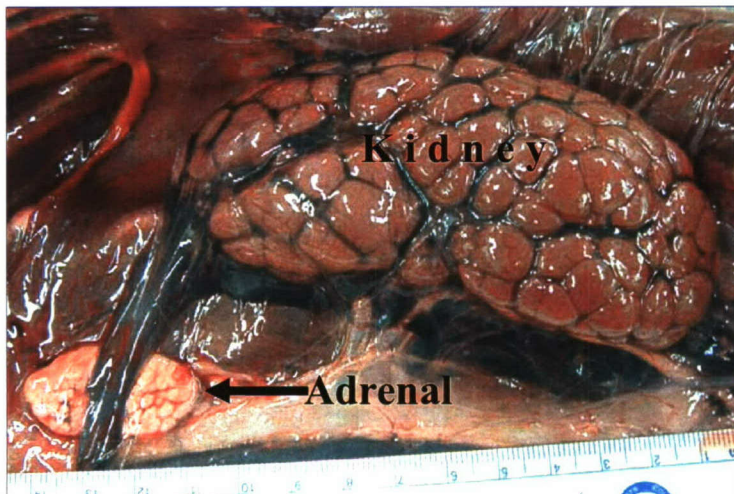
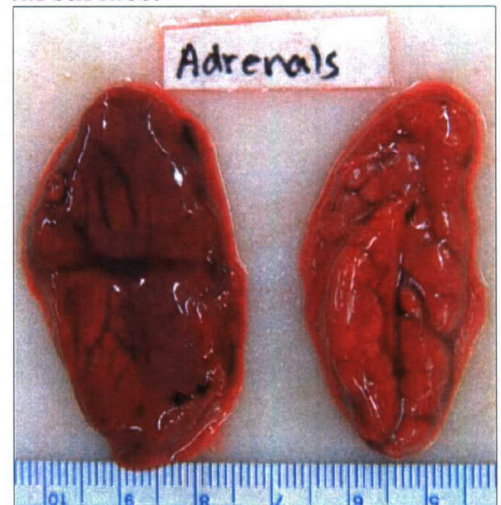


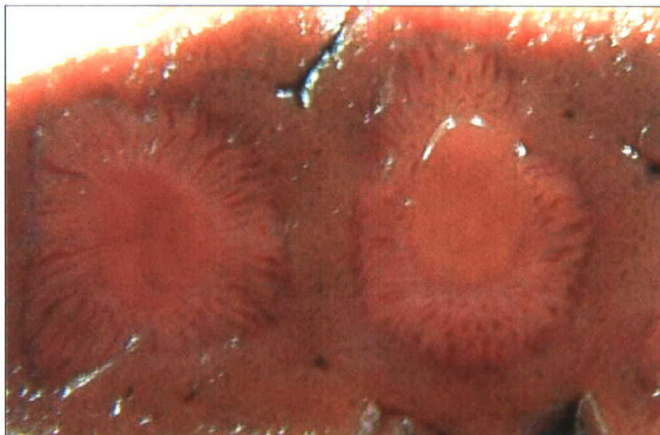Figure 3-44. Normal adrenals; left is visceral surface, right is the parietal surface.



Kidneys:

The left and right kidneys are dark maroon, ovoid, tissues comprised of numerous, clustered reniculi (miniature kidneys) and are attached to the caudal dorsal abdominal wall (Figure 3-43). Examine the capsule (connective tissue surrounding the kidney) for the presence of fluid or bubbles and note color, thickness, and opacity. Remove the renal capsule by making a longitudinal incision and reflect each half away from the kidney to examine the internal surface of the capsule. Detach the kidney from the abdominal wall. Note the size, shape, external color and texture of each kidney. Examine the internal structure of each kidney by bread-slicing. Note color and presence of stones. Observe the degree of differentiation between the cortex and medulla as well as the medulla:cortex ratio within each reniculi (Figure 3-45). Each reniculi should be well demarcated but clustered together within the kidney itself. Sample for contaminants, histology, microbiology, molecular and ancillary investigations.

Figure 3-45. Close up of reniculi.

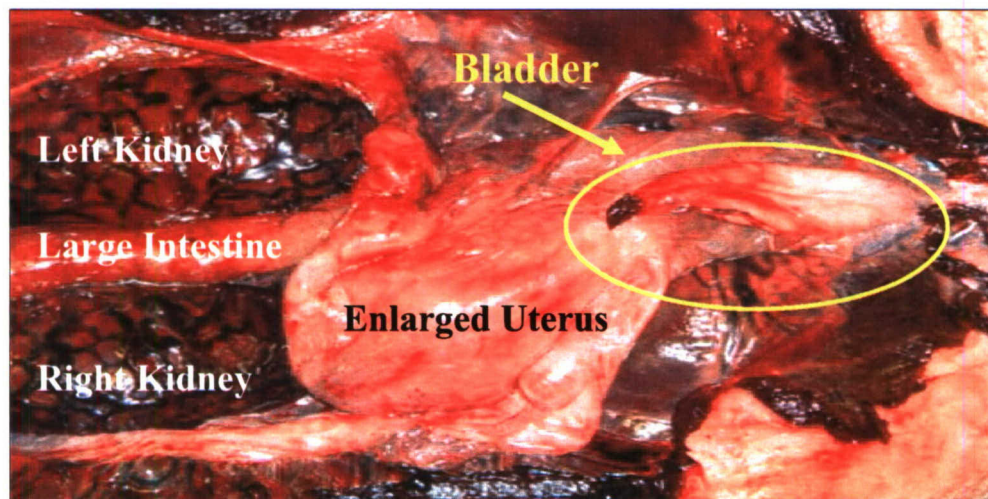


Urinary Bladder:

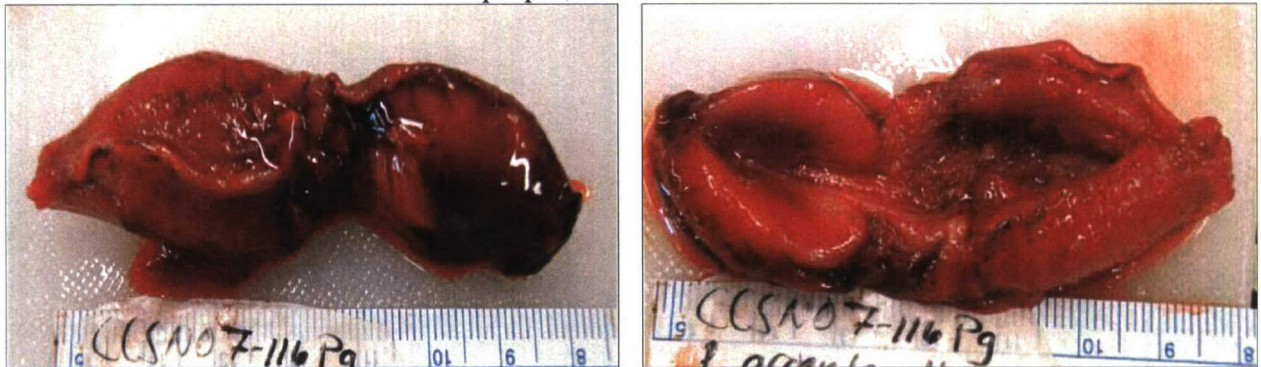
The bladder is a smaller, light pink, organ that is found just anterior to the pelvic bone along the ventral body wall (Figure 3-46). The organ often appears as a thick walled muscular organ, but if distended with urine, the walls may be thinned and semi-translucent. Before removing the bladder from the body, extract contents using a sterile syringe and medium gauge needle. If none are available, be sure to clamp the bladder using a hemostat before removing the organ in order to retain urine. Note color, consistency, and amount of urine. Remove the bladder and examine internally by cutting along the length of the organ to expose the mucosal surface.

Note color and texture of the mucosa. Sample the cranial tip of the bladder for histology.

Figure 3-46. Location of bladder in situ.



Figures 3-47a & 3-47b. Gross Description: Obvious stricture of the bladder wall in the middle of the organ; caudal serosa is dark red and gelatinous; cranial bladder wall is thickened; mucosa of the caudal end is dark red to purple;



Morphologic Diagnosis: Stenosis, or narrowing, of the bladder with associated hemorrhage of the serosa and mucosa of the caudal end.

Reproductive tract:

Female- Ovaries and uterus

The uterus and ovaries can most easily be identified by following the reproductive tract from the vagina to the uterus where it bifurcates to a right and left horn, each ending at the attachment of the ovaries. The uterus is a tan to pink tissue that will vary in size and thickness depending on the maturity of the animal and its reproductive history. Note size, shape, color, and texture of the external and internal surfaces of the organ. If a fetus is present and is too small for a sufficient individual necropsy, incise the abdomen, collect microbiology and molecular samples, then preserve fetus whole in formalin. If the lung tissue floats in formalin (or water), this signifies that bronchiole expansion of the fetal lungs has occurred.

An off-white spindle-shaped ovary is attached to the end of each uterine horn. Detach the organ from the uterus and examine the external surface. Note size, shape, color and texture. A mature ovary will possess random darkened notches or scars (corpus albicans) which signify previous ovulations. The ovary of a pregnant female will possess a corpus luteum, or a large yellow mass attached to the ovary. Before internal examination, measure (LxWxH) and weigh each ovary. Also count and note the number of scars and presence/absence of a corpus luteum. Examine the tissue internally and note color and texture. Sample both the uterus and ovaries for life history, histology, microbiology, molecular and ancillary investigations.

Male- Testes

The elongated, spindle shaped, off-white paired testes are located outside of the abdominal cavity along the ventral body wall proximal to the ventral hip bones (Figure 3-48 & 3-49). Remove the testis, with the epididymus attached, from the body and obtain the measurements (LxWxH) and weight of each. Examine the size, shape, color, and texture externally and internally. Section epididymus for presence/absence of sperm. Obtain samples of each testis for life history, histology, microbiology, molecular and ancillary investigations.

Figure 3-48. Location of testes outside of the abdominal wall.

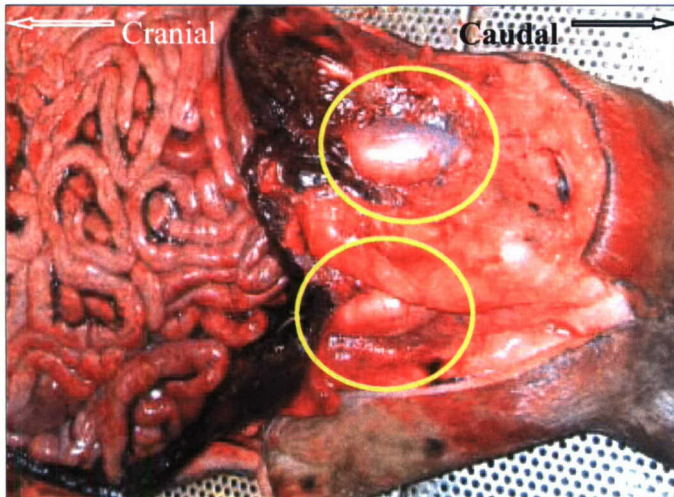
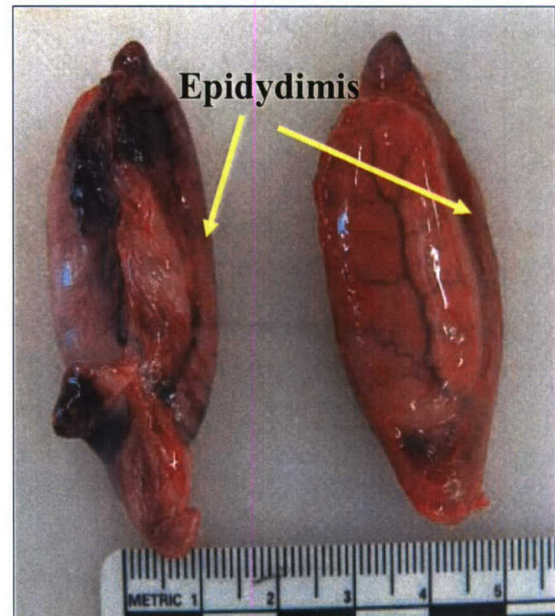


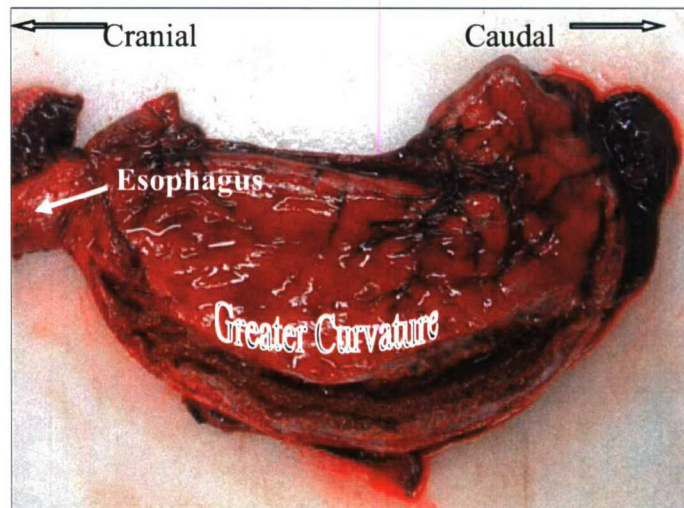
Figure 3-49. Normal, immature testes; left is visceral surface; right is the parietal surface.



Stomach:

To ensure a thorough analysis of stomach contents, it is necessary to tie off both ends of the stomach prior to extracting, so that no material is lost during the removal process. With some twine, tie a tight, secure knot at the location of the attachment of the esophagus to the stomach. A second piece of twine can be tied just below the base of the stomach where the small intestine begins. Remove the stomach from the carcass by cutting beyond both knots. Examine the serosal (external) surface of the stomach for discoloration and lesions. If an internal pathology is present, the perigastric lymph nodes attached to the stomach may be noticeably enlarged and reactive. Sample the lymph node for histology and make note on the sample inventory sheet. Otherwise, remove all excess attached tissue from the exterior of the stomach and weigh the stomach full. Using a scalpel, make an incision through the wall along the greater curvature large enough to allow examination of the contents and entire mucosal surface (Figure 3-50). Note the composition of stomach contents (fluid; whole or partially digested fish; fish bones; parasites; foreign objects). Be sure to describe amounts, color, and texture. Before further manipulation, collect a sample of contents for biotoxins. The remaining contents can be emptied and rinsed into a sieve to ensure solid materials are not lost and are thoroughly

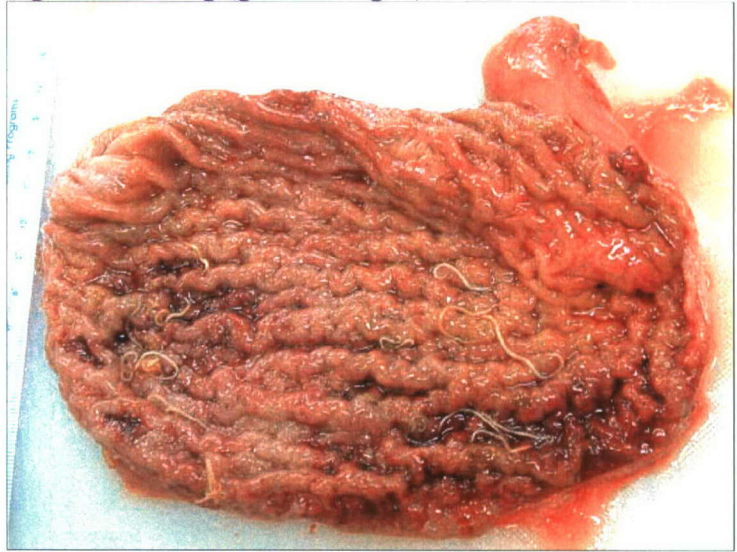
Figure 3-50. Stomach removed from carcass.



examined. Photograph and save all foreign objects for human interaction documentation. Collect and store the remaining solid materials as outlined in the Sample Management section (Section 2) of this manual.

Once empty, examine the lining of the stomach (Figure 3-51). Note the color and texture of the mucosa. Look for ulcers, areas of discoloration, parasites (such as the nematodes shown in this image), and other lesions. Weigh the stomach empty. Sample for histology.

Figure 3-51. Stomach is incised along the greater curvature and reflected to demonstrate prominent folding of the lining (gastric rugae).



Esophagus:

Trace the esophagus from the exposed caudal end to the mouth. Open the esophagus in the same manner as done with the trachea. Observe the lining of the esophagus. Note, color, texture, and contents. Sample for histology.

Small intestine:

Examination of the intestines is preferably left until the end of the necropsy so as to not contaminate the other organs. Examine the serosal surface of the small intestine first. Look for areas of hemorrhaging or discoloration as well as parasites. The inside of the small intestine can be examined by spot checking: at 5 – 10 random, separate areas, using scissors to cut about 10.0 cm down the length of the lumen. Note color, consistency and amounts of contents as well as thickness of the lumen and texture and color of the mucosa. Sample several sections for histology, microbiology, molecular and ancillary investigations.

Large intestines:

To locate the beginning of the large intestine, look for the ileo-ceco-colic junction, which usually is a ridged junction between the smaller diameter small intestine and the larger diameter large intestine. The large intestines can be examined in the same manner as the small intestines. Note any discoloration or the presence of parasites externally. Describe the color, consistency and amounts of contents. Note the thickness of the lumen as well as texture and color of the mucosa. Sample for histology, microbiology, molecular, and ancillary investigations.

Colon:

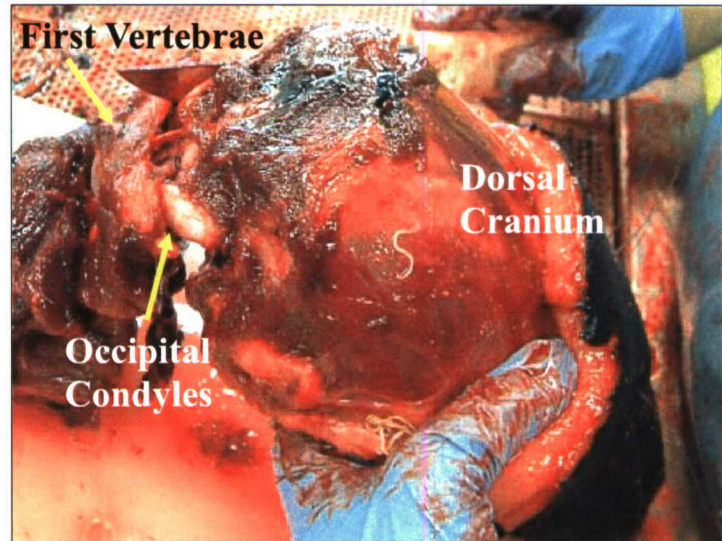
Examine the serosal surface of the colon for areas of discoloration. Cut through the lumen of the colon from the anus to the large intestine. Describe the color, consistency and amount of contents. Note the thickness of the lumen as well as texture and color of the mucosa. Sample for histology. Collect feces for biotoxin analysis.

Removal of the Brain:

The brain is the most fragile and easily disrupted tissue in the entire body, thus extreme care must be taken when removing the brain from the case. Before removing the head, cerebrospinal fluid (CSF) can be collected for cytology and culture. To do so, remove the overlying soft tissue at the back of the head and neck to gain access to the atlanto-occipital joint. Insert a sterile needle and syringe and collect the clear, viscous CSF.

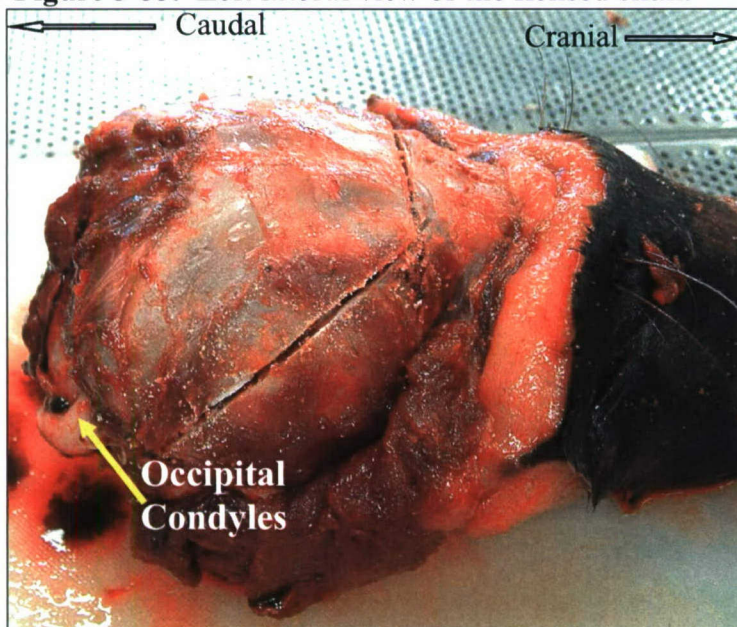
The head must first be detached from the body to safely remove the brain. Do so by cutting behind the base of the skull down between the occipital condyles and first vertebra (Figure 3-52). It is easier to separate at this joint while pulling the muzzle toward the ventrum. Once separated, remove all excess skin, blubber, muscle and connective tissue from around the dorsal and caudal skull. Then, using a Stryker saw or a hacksaw, make cuts from left to right through the middle of each occipital condyle, then up along the left and right lateral skull, and then across the dorsum, just caudal to the marked transverse ridge at the apex of the skull (Figure 3-53). The connecting cuts on the surface of the skull will create the shape of a pentagon (Figure 3-54). Be sure to fully penetrate the bone, but avoid penetrating the brain tissue. This can be very difficult, so proceed with caution. It will take some practice to successfully remove the cranium without penetrating the brain. Carefully place a chisel between

Figure 3-52. Separation of the skull from the first vertebrae.



the cut bone and turn the tool to crack the remaining bone until the back of the skull comes away in one piece. Be careful to pull it off evenly, without using one edge as a lever, otherwise the bony shelf (the tentorium cerebellae) that is positioned between parts of the brain will penetrate the tissue and damage the brain. Using your fingers to bluntly dissect, gently tease the meninges away from the skull, and work under the brain to sever each cranial nerve. Inversion of the head often allows the brain to gently descend into the palm of your hand.

Figure 3-53. Left lateral view of the flensed skull.



Examination of the Brain:

Again, the brain is the most delicate tissue in the body and will fall apart if handled excessively. Observe the external surface of the brain and note symmetry of each distinct structure, color, texture, and presence of worms or lesions. Cut through the brain, cranial to caudal, separating the two hemispheres. Again, note symmetry, color, texture and the presence of worms or lesions. Each section of the brain has a diffusely distinct pattern. The cerebrum is comprised of two separate lobes and is the most anterior section of the brain. The cerebellum is the most caudal portion and sits dorsal to the brain stem. The brain stem originates from the ventral midline of the brain and extends into the spinal cord. Sample the cerebrum, cerebellum, brain stem and spinal cord for microbiology, molecular and ancillary investigations. Fix the remaining brain tissue in formalin for histology. It is important to include a sample of normal and abnormal meninges in the histology sample set.

Figure 3-54. Incised skull with reflection of the cap to expose the brain in situ.

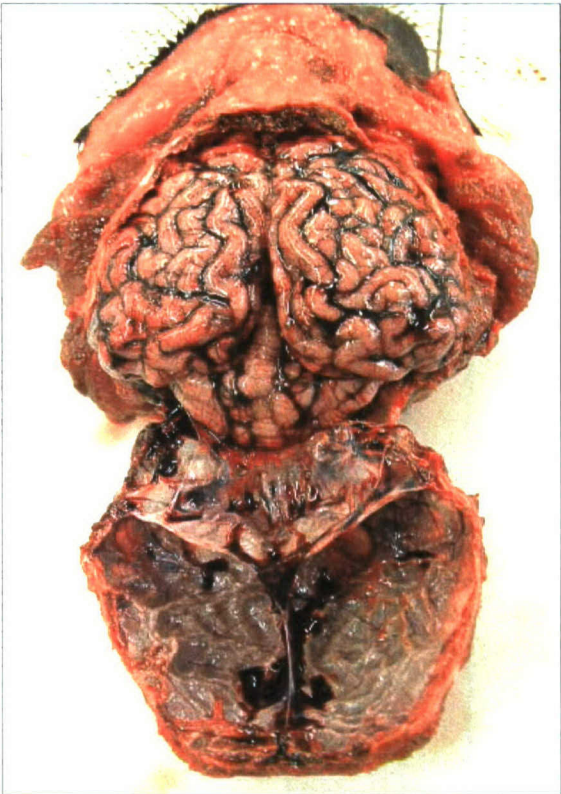
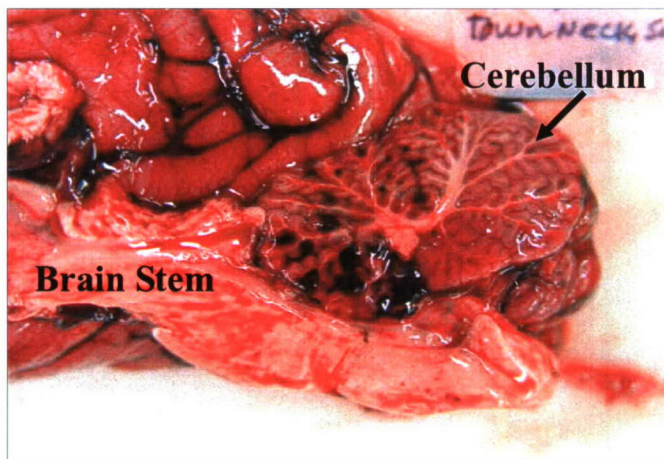


Figure 3-55. Gross Description: Thick, dark blood within the folia of the cerebellum.



Morphological Diagnosis: Punctate foci of acute hemorrhage.

Pituitary Gland:

Once the brain has been removed, immediately under the crossover of the optic nerve, the usually small pituitary gland can be extracted after incision through the overlying dura. The organ is within a bony recess and has to be lifted out using a scalpel blade and small forceps. Sample for histology and other priority testing.

- SECTION FOUR -

Small Cetacean Necropsy Technique and Anatomy

As a reminder, it is helpful to have all necessary equipment and sampling needs set up and accessible prior to the start of the necropsy. A sample equipment list is provided in Appendix C of this manual

Stranded cetaceans are out of habitat and undergo resultant pathology simply by the stressful act of being ashore. Such changes include epidermal lacerations and tendon, ligament, blubber and muscle bruising. Lungs and other major organs are also compressed and may contain abnormal amounts of fluid, especially on the dependent side. These factors should be considered throughout the exam.

External Exam

Condition Code:

Before initiating the necropsy, carcass condition must be determined. Preferably, necropsies are performed on fresher carcasses (within 48 hours of death); however, environmental conditions can greatly impact condition code. For example, very warm weather will accelerate carcass deterioration. If human interaction is suspected or forensic data are of value, necropsies should be performed irrespective of tissue quality. Carcasses are classified in one of five code categories depending on the level of decomposition:

Code 1: Alive

Code 2: Fresh carcass (Figure 4-1); < 24 hours post mortem; normal appearance, usually with little scavenger damage; fresh smell; minimal drying and wrinkling of skin, eyes and mucous membranes; eyes clear; carcass not bloated, tongue and penis not pro-

Figure 4-1. Fresh carcass



Code 3: Moderate decomposition (Figure 4-2); Carcass intact, bloating evident (tongue and penis protruded) and skin cracked and sloughing; possible scavenger damage; characteristic mild odor; mucous membranes dry, eyes sunken or missing;

Figure 4-2. Moderate decomposition



Code 4: Advanced decomposition (Figure 4-3); Carcass may be intact, but collapsed; skin sloughing; often severe scavenger damage; strong odor; blubber or muscle easily torn or falling off bones; liquefied internal organs.

Figure 4-3. Advanced decomposition.



Code 5: Mummified or skeletal remains (Figure 4-4); often with dried skin draped over bones; completely desiccated.

Figure 4-4. Mummified or skeletal remains.



Nutritional Condition:

The body condition of a cetacean can be assessed by looking along the dorsal axis of the animal. The dorsal muscle mass (epaxial muscle) to either side of the dorsal fin of a **robust** animal will be rounded, or convex (Figure 4-5). A **thin** animal will have a slight loss in epaxial muscle girth and could have a minor sunken aspect to the dorsal-lateral body. An **emaciated** animal (Figure 4-6) will have a greater loss of epaxial muscle girth and will be concave down the dorsal-lateral body. Emaciated animals may also have a more prominent indentation at the nape.

Figure 4-5. Robust cetacean





Figure 4-6. Emaciated cetacean



Sex determination:

To determine the sex of a small cetacean, examine the ventral midline of the animal. Both male and female cetaceans possess a genital slit between the umbilicus and anus. For female cetaceans, there should generally be less than 10 cm distance between the centers of the anal opening and the genital slit (Figure 4-7). Whereas with a male, the distance between the anus and genital slit is much greater (Figure 4-8). The distance between the genital slit and anus is most pronounced in the male harbor porpoise, in which the genital slit lies closer to the umbilicus than to the anus. A single short mammary slit can be seen on either side of the genital slit in most female cetaceans, though some males may also possess this feature. A more definitive method to sex a cetacean is by blunt-probing the genital slit. If the probe angles forward it has entered the vagina and is, thus, a female. If the probe angles backward it has entered the penile opening of a male (often the distal end of the penis can be felt as well). When probing, be sure that your finger has penetrated past the first knuckle in order to ensure accurate sex determination. It is important to note also, that different species are easier to probe than others; common dolphins are often quite difficult to accurately probe due to very small genital apertures. Final confirmation of gender will always be a result of internal examination.

Figure 4-7. Female delphinid

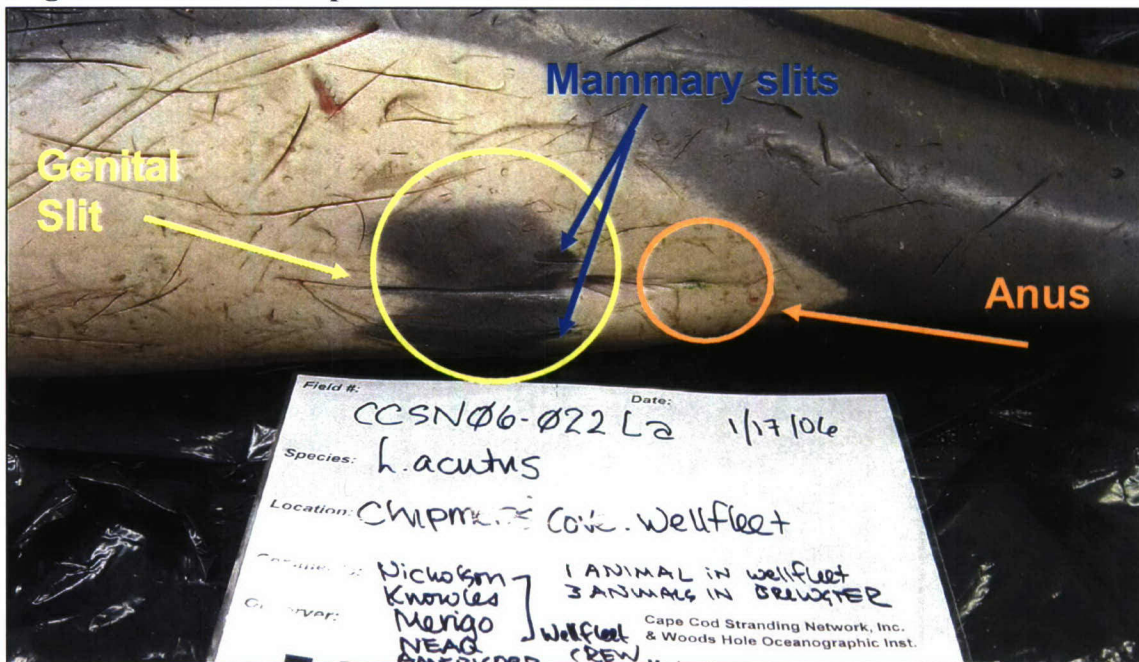
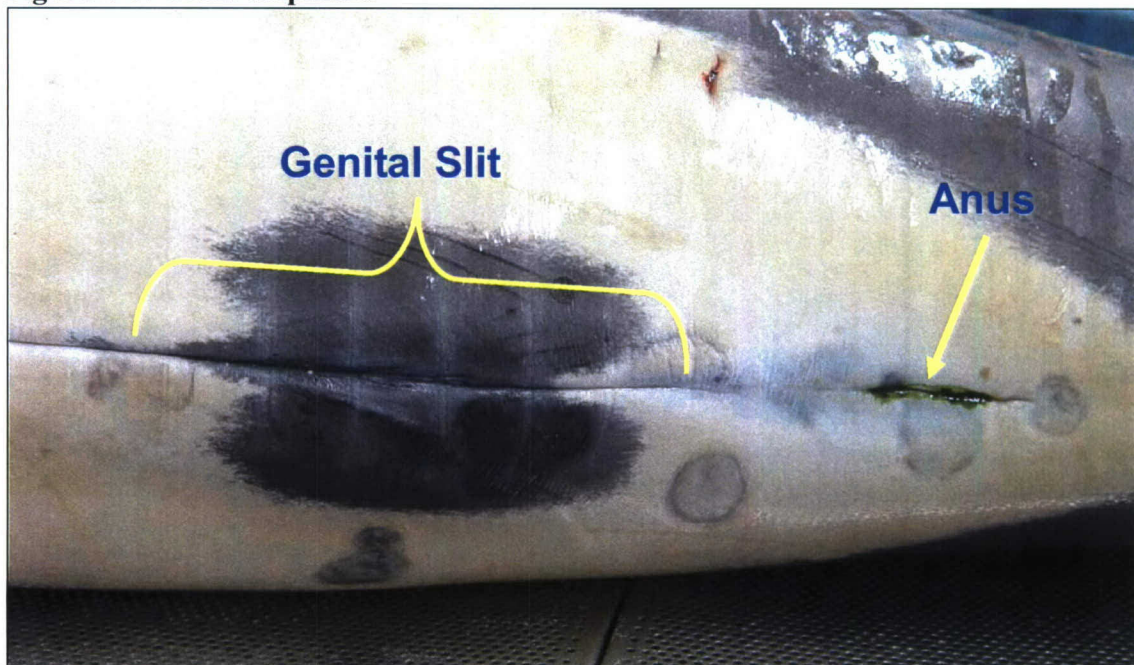


Figure 4-8. Male delphinid



Integument:

Where collecting samples for analysis is prompted, please refer to Section 2: Sample Management.

An external examination should include the investigation and description of the eyes, mouth, blowhole, umbilicus, genital opening, anus, and skin. When examining the eyes, look for discoloration, injuries, or discharge. Document any lesions, parasites, and the mucus membrane color in the mouth. Make note of worn, broken, or missing teeth. Describe color and amount of discharge from blowhole as well as the presence of parasites or obstructions. Obtain culture swabs. Examine the umbilicus in neonates for signs of infection and degree of healing. Look for lesions, discharge or growths around the genital opening and anus. Obtain samples of abnormalities for histology, microbiology, molecular and ancillary investigations. If the animal has mammary glands, attempt to express milk and note color, consistency, and estimate amount in cc's or mls. Milk can be expressed by pressing on the body about 10cm dorsal and cranial to the mammary slit and massaging downward toward the slit. Thoroughly examine and document any scars, abscesses, ulcerations, erosions, wounds, and parasites on the skin. Make note of the size (length x width x depth/height), shape, color, texture, location, and distribution of all abnormalities. Sample unusual findings as described in Section 2: Sample Management .

Figure 4-9. Gross Description: Multifocal to coalescing, demarcated 0.5-3.0cm circular, yellow depressions over the caudal ventral skin.

Morphologic Diagnosis: *Granulomatous dermatitis or fungal dermatitis.

Figure 4-9.

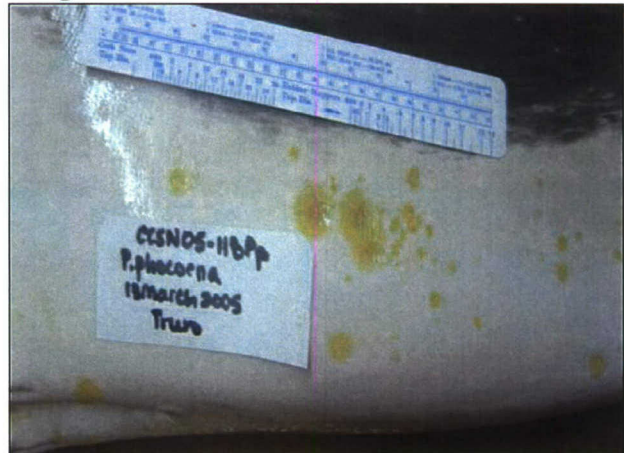


Figure 4-10.

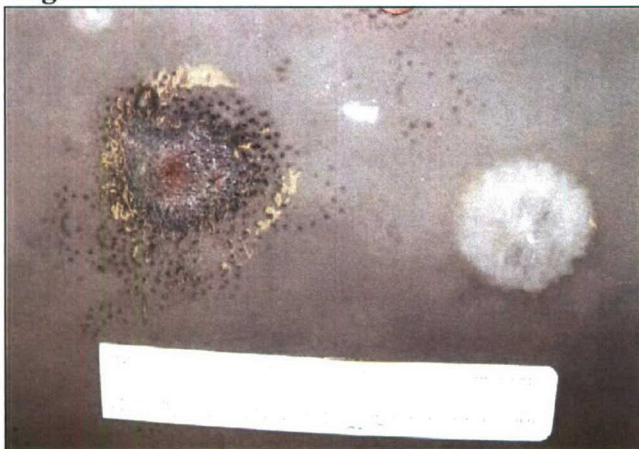

Figure 4-10. Gross Description: Multifocal to coalescing, circular, 0.1cm pits of the epidermis with central ulceration of the wound in the left example and scarring in the right example.

Morphologic Diagnosis: Peracute, acute, and chronic lamprey bites.

Figure 4-11.

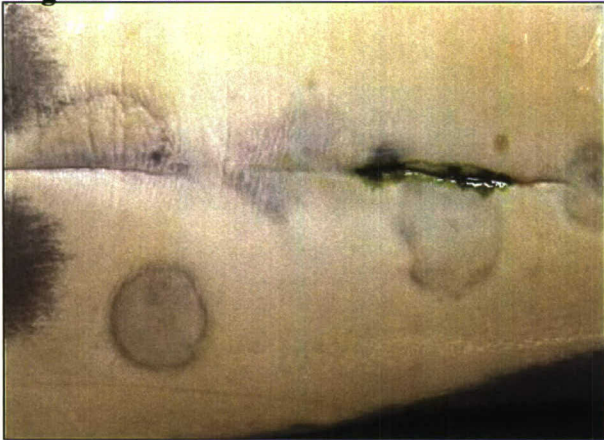

Figure 4-11. Gross Description: Focal 0.5-4.5cm well demarcated light gray depressions of the dermis proximal to the genital region

Morphologic Diagnosis: Dermatitis and panniculitis with intralesional cestodes; Etiology: *Monorygma sp.*

Figure 4-12.




Figure 4-12. Gross Description: On the dermis of the lateral left body there is a dark gray to black, stippled pattern with a well demarcated, irregular perimeter, multifocal to coalescing.

Etiologic Diagnosis: Pox-viral dermatitis (tattoo lesion).

Figure 4-13a.




Figure 4-13b.

Figures 4-13a & 13b. Gross Description: Multifocal 0.2 - 0.4cm, circular, volcanic lesions disseminated over the dermal surface; some depressions are ulcerative.

Etiologic Diagnosis: Dolphin pox

Figure 4-14.

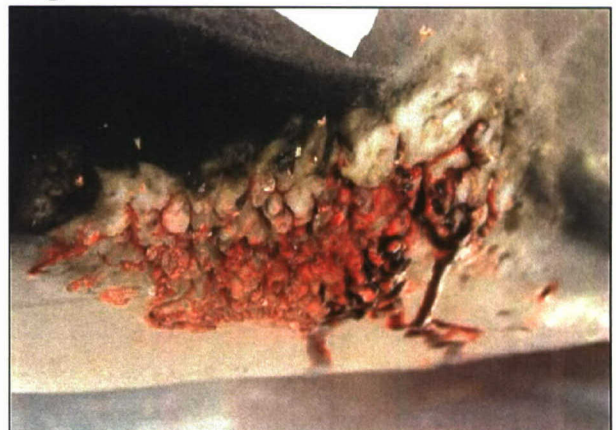


Figure 4-14. Gross Description: Epithelial proliferation characterized by multiple fungiform, pappillomatous, semi-firm, tan to brown projections; cyamids attached.

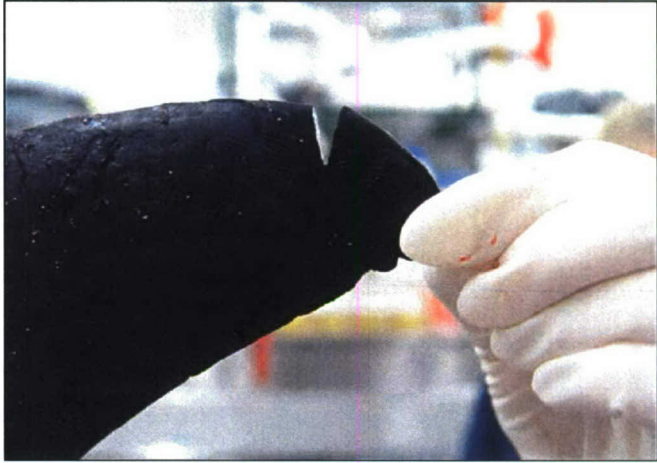
Morphologic Diagnosis: Dermal papilloma with secondary cyamadiasis.

Skin & Teeth Sampling:

Skin:

Remove about two inches of skin from the tip of the dorsal fin (Figure 4-15) or flukes for genetic (frozen and DMSO) and histology samples. A skin sample with no blubber attached is preferred. Trim the skin as cleanly as possible from the other tissue. (Be sure all morphometrics have been completed before collecting this sample.)

Figure 4-15. Skin is removed from the dorsal fin tip for sampling.



Teeth:

Teeth from the center of the lower left mandible are collected for life history analysis. Using a scalpel blade, transversely cut in between and around 5 -7 teeth (Figures 4-16& 4-17). Teeth can be extracted by inserting tooth extractor or a flat head screwdriver in the incision made between the teeth and wiggling the tool down to the base of the mandible until the entire, undamaged, tooth becomes loose (Figure 4-18). Avoid snapping or crushing the tooth, as such damage can render the sample useless for analysis. In some species and in older animals, a sturdy knife may be advisable over a scalpel to avoid breaking the blade.

Figure 4-16. Removal of lower left teeth.



Figure 4-17. Removal of lower left teeth.

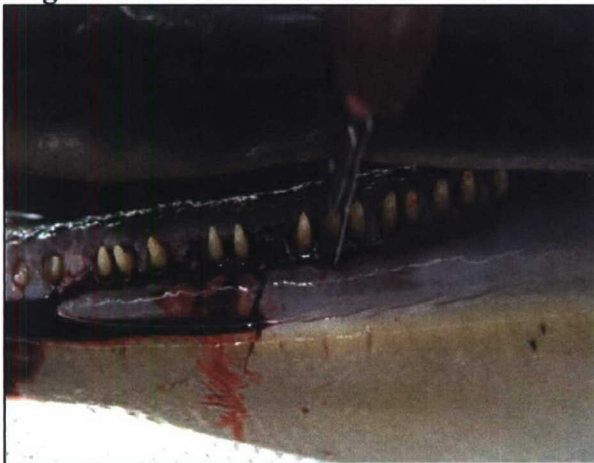
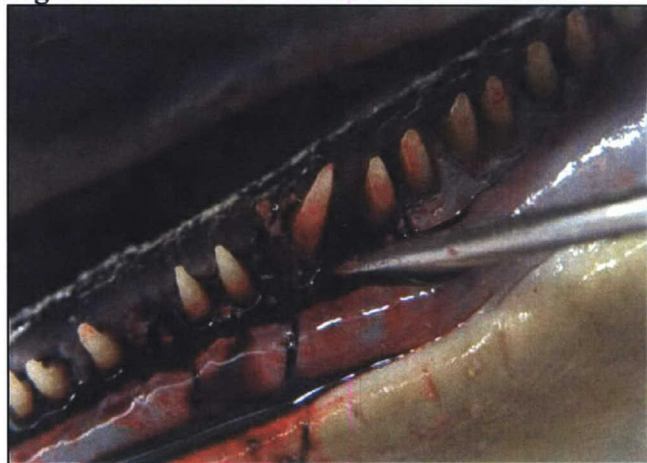
Figure 4-18. Removal of lower left teeth.



Removal of the External layers –Skin, Blubber, Muscle

Skin & Blubber:

The first step to examine the body cavity of the animal is removal of the blubber. Position the animal left side up. Using a scalpel blade or knife, start just left of the dorsal midline posterior to the blowhole and make a longitudinal incision down the length of the animal ending at the dorsal tail stock. Do not penetrate into the skeletal muscle, cut only through the skin and blubber layers. Next, make a dorso-ventral incision perpendicular to the previous body length incision just cranial to the anterior insertion of the left pectoral flipper. Continue making perpendicular incisions down the length of the animal that are ~ 10 inches apart, creating a series of panels along the lateral body (Figure 4-19). At the top of each panel begin to separate the blubber from the muscle by cutting through the fascia, or connective tissue (Figure 4-20). If you remain between the blubber/ muscle interface (fascia) and reflect the panel of skin down and away from the body, in a dorsal to ventral direction, the blubber should easily separate from the muscle (Figures 4-21 & 4-22).

Figure 4-19. Animal in lateral recumbency with numerous transverse, full blubber thickness incisions.



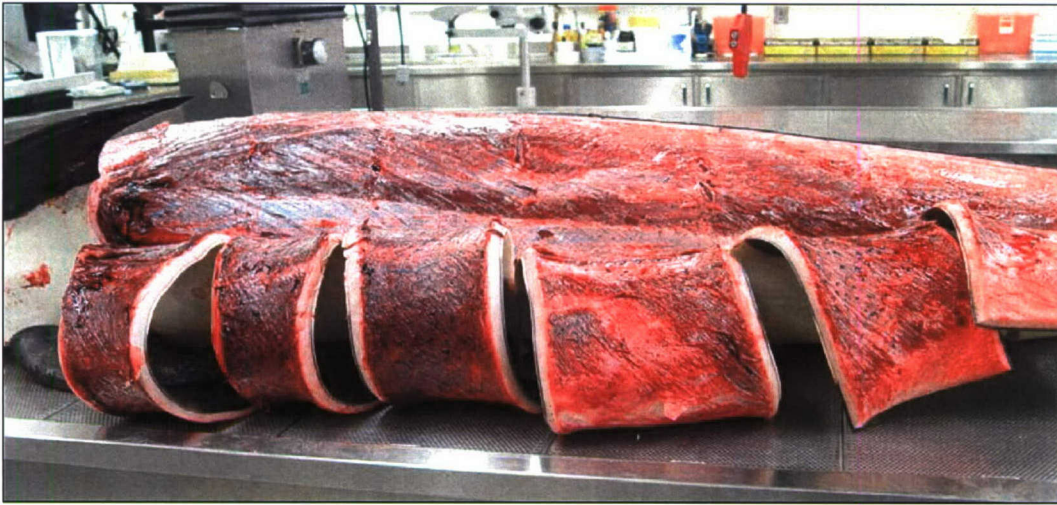
Figure 4-20. Reflection of the blubber along fascial plane.

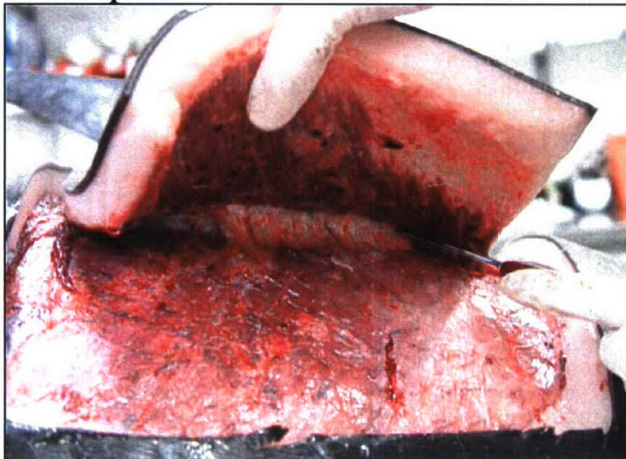

Figure 4-21. Reflection of the blubber along fascial plane.

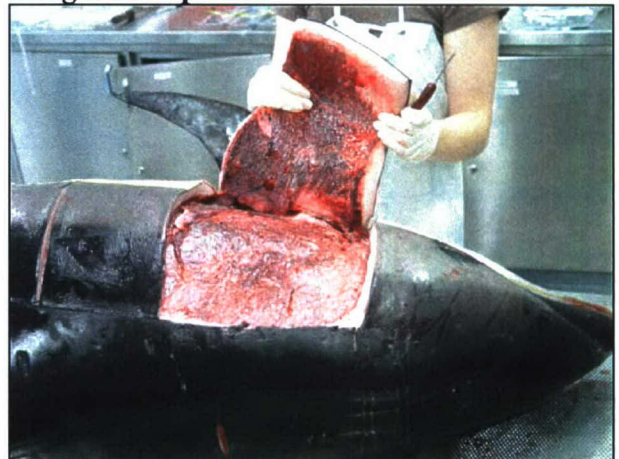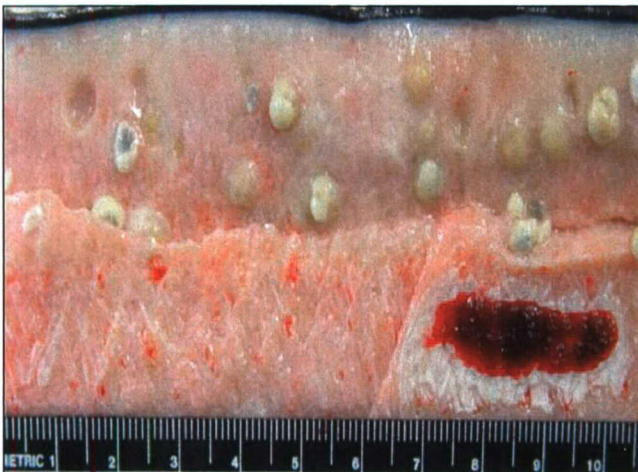


Figure 4-22. Panels of blubber reflected away from carcass.



Note the thickness, color, and texture of the blubber. Look for parasites and abnormalities within the blubber layer. Obtain blubber samples for histology and contaminants. When collecting these samples, be sure to collect blubber without any skin (Figure 4-20) or muscle attached and be sure to take the sample from the same location on each carcass, generally from the dorsal mid-thoracic region. Once the blubber has been examined, make a cut along each reflected panel at the ventral midline and discard the blubber.

Figure 4-24. Gross Description: Multifocal, spherical, white to yellow cysts.



Morphologic Diagnosis: Pannicular parasitic cysts; **Etiology:** *Phyllobothrium* sp.

Figure 4-23. Separation of skin from blubber.

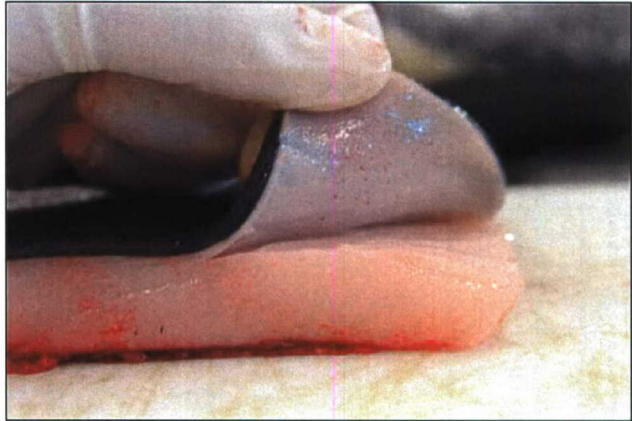
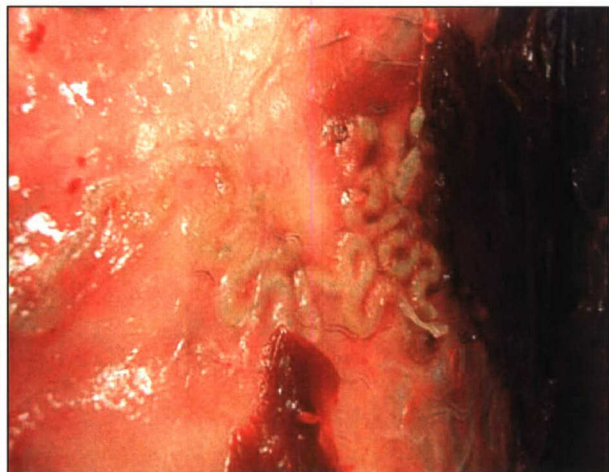
Figure 4-25. Gross Description: Light yellow to brown worms within the blubber-muscle fascia with associated tissue necrosis.



Etiologic Diagnosis: Fascial nematodiasis;
Etiology: *Crassicauda* sp.

Figure 4-26.

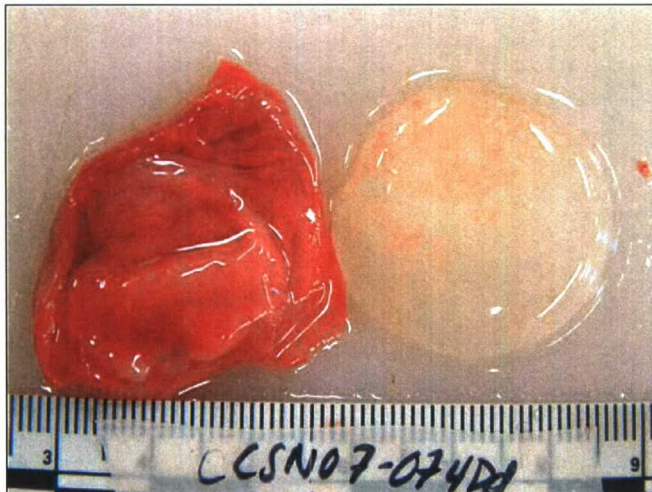

Figure 4-26. Gross Description:

3.0cm spherical pink sack attached to external abdominal muscle; contains an opaque white, gelatinous circular structure.

Etiologic Diagnosis: *Monorygma* sp.

Figure 4-27. Gross Description:
Multifocal to coalescing bubbles within the blubber-muscle fascia.

Morphologic Diagnosis: Most commonly gas produced by bacteria during decomposition; can also be localized gas emboli.

Figure 4-27.




Figure 4-28.

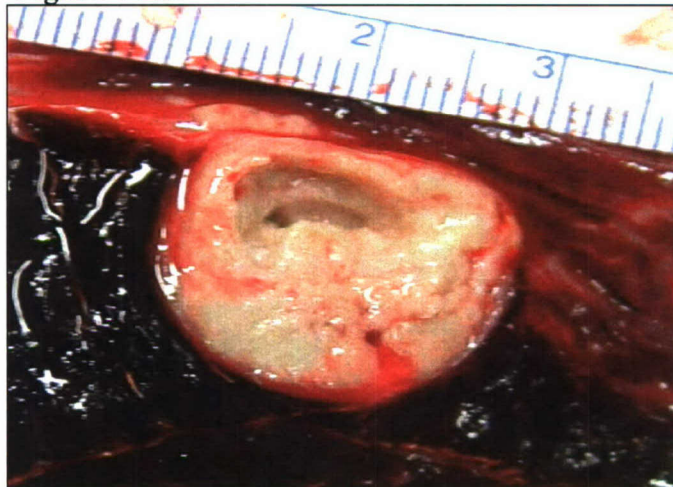


Figure 4-28. Gross Description:

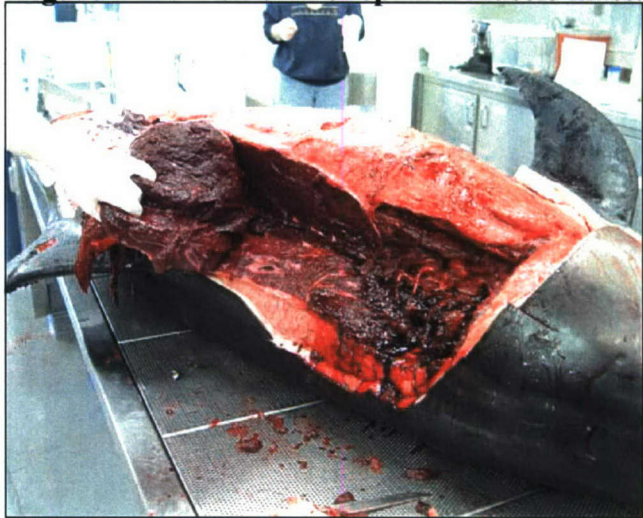2.0cm spherical abscess within the ventral midline muscle layer slightly penetrating the abdominal wall; abscess is comprised of light green caseous material.

Morphologic Diagnosis: *Focal abscessation;

Skeletal Muscle:

Examine the quality of the fascia and muscle on the body before removing it. Note the color, texture, thickness and abnormalities. Look for hemorrhage, post mortem pooling of blood in vessels (hypostasis or post mortem lividity) and bruising (hematoma). Bruising usually has a gelatinous texture and is deep maroon to purple. Remove the large dorso-lateral muscle mass, or epaxial muscle that spans from the occipital ridge down to the tail stock (Figure 4-29). Use the dorsal and lateral spinal processes as landmark boundaries for this muscle. Trim away as much muscle as possible from the backbone and ribs. Obtain muscle samples for histology and contaminants.

Figure 4-29. Removal of epaxial muscle mass.



Internal Examination

Removal of the Scapula and Prescapular Lymph Node:

Locate the prescapular lymph node prior to the complete removal of the scapula. The oval to triangular shaped, beige to peach tissue is located just underneath the cranial corner of the scapula, proximal to the location of the external ear (Figure 4-30). Normal lymph nodes throughout the body usually share the same characteristics: a well defined oval shape, slightly firm texture, color is diffusely beige to peach, with very slight differentiation between the cortex (outer layer) and medulla (center area). If the tissue begins to vary from the homogenous peach to tan it is indicative of a reaction. Note the size, shape, color and texture of the prescapular lymph node. Be sure

Figure 4-30. Location of prescapular lymph node in situ.

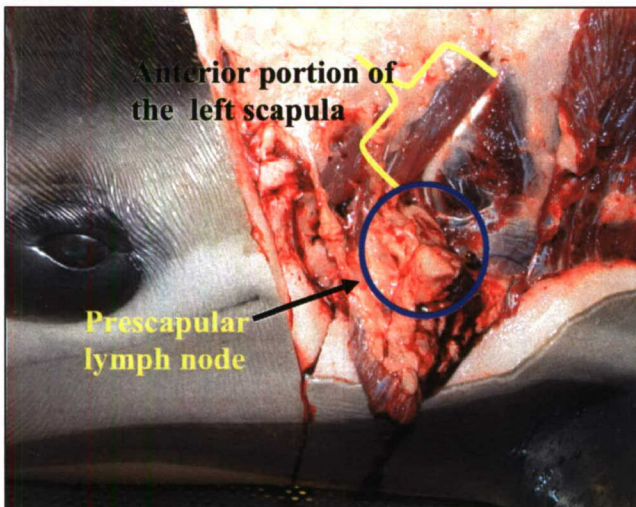
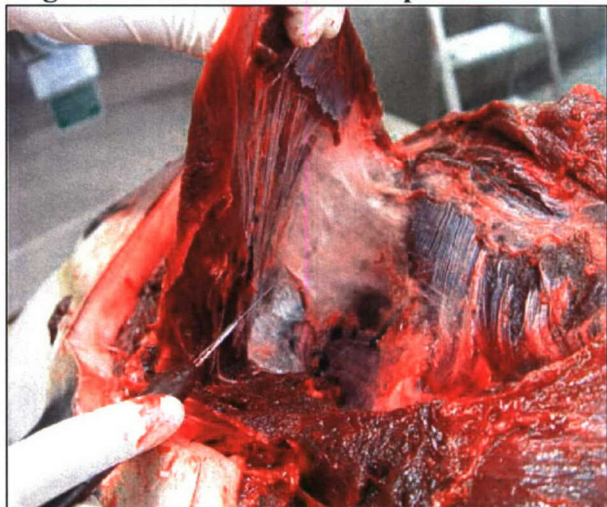


Figure 4-31. Removal of scapula.



to distinguish changes of the cortex from changes of the medulla. Sample for histology, microbiology, molecular and ancillary investigations. Remove the left scapula and appendage by cutting through the connective tissue and muscle just underneath the bone. If you pull the scapula ventro-laterally, reflecting it down as done with the blubber layer, the scapula will detach easily (Figure 4-31). You should hear a crackling sound as you pull and cut indicating that you are in the correct spot between muscle groups.

Before cutting into the body cavity of an animal, to obtain uncontaminated bacterial and viral samples from the thoracic and abdominal cavities, sear a section of the body surface with a flame (such as from a propane torch), then, with a flamed blade, incise into the body cavity and insert a swab.

Removal of the Rib Cage:

Before collecting any samples or cutting the ribs, the diaphragm should be punctured with a scalpel or scissors and deflation should be noted. If the diaphragm is already deflated, it is possible that a pneumothorax or severe pneumonia may be present. To open the thoracic cavity, start at the caudal end of the left rib cage and feel for the articulation between each individual rib and vertebrae. The ribs and vertebrae should easily separate, without breaking, if you cut through the articulation, or “sweet spot”, with a scalpel blade or small knife (Figure 4-32). Also to note, age and disease may effect the way the joints disarticulate. Move cranially from rib to rib maintaining a constant angle with your scalpel as you cut and moving the rib to find the articulation (Figure 4-33).

Figure 4-32. Separation of the ribs at the costal articulation.

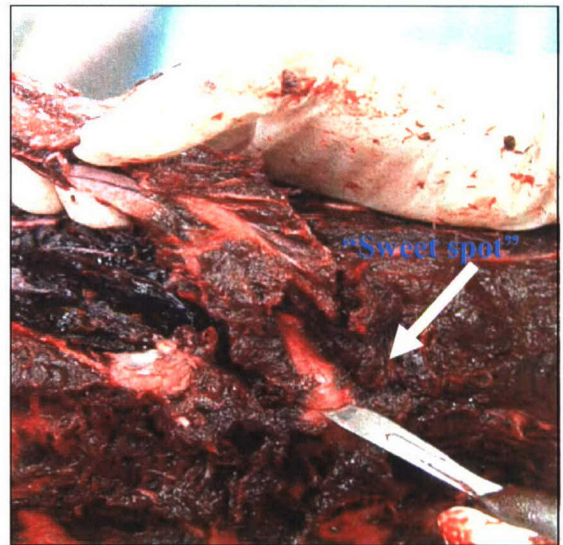
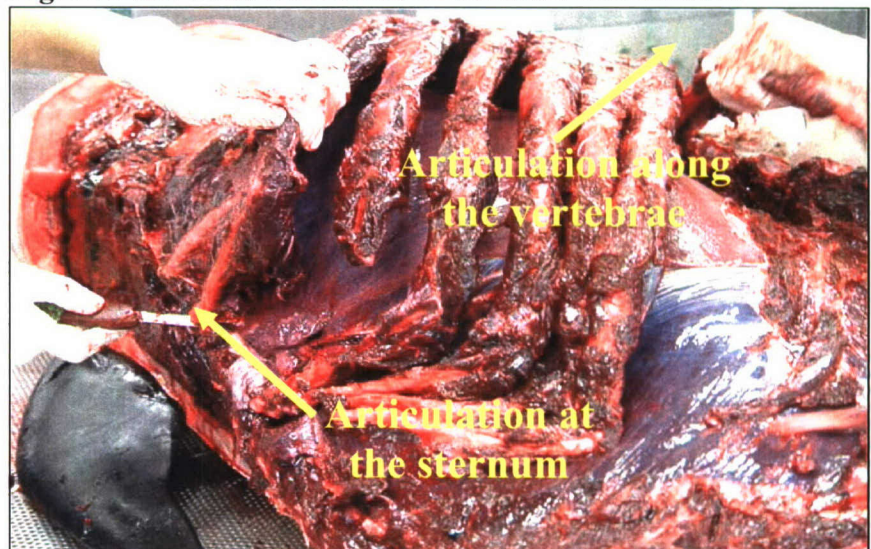


Figure 3-33. Removal of ribs at sternum articulation.



Note that the most cranial ribs are double-headed along the vertebrae (Figure 4-34). The double-headed ribs can be removed by first severing the first articulation, then by sliding the scalpel along the inside of the second head to reach its articulation with the spine. The articulation can be cut by sweeping the scalpel parallel to the long axis of the animal. The rib articulations should feel smooth, not granular. Feel for fractures and bone spurs on the rib cage. Removed in this manner, the skeleton may be of more value for future bone pathology studies, educational outreach or as museum specimens. Once the rib cage is removed, examine the body cavity with all organs in place (Figure 4-35). Note any discoloration, lesions, adhesions, odor, or fluids.

Figure 4-34. Double articulation along the vertebrae.

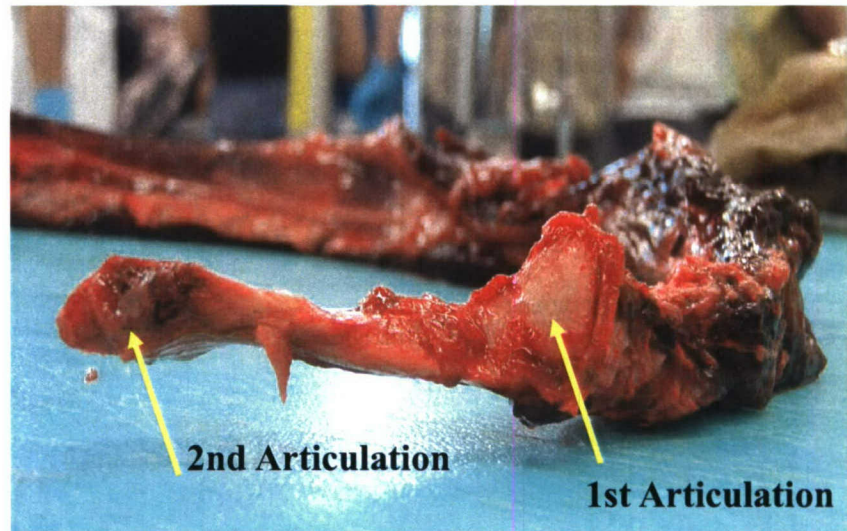
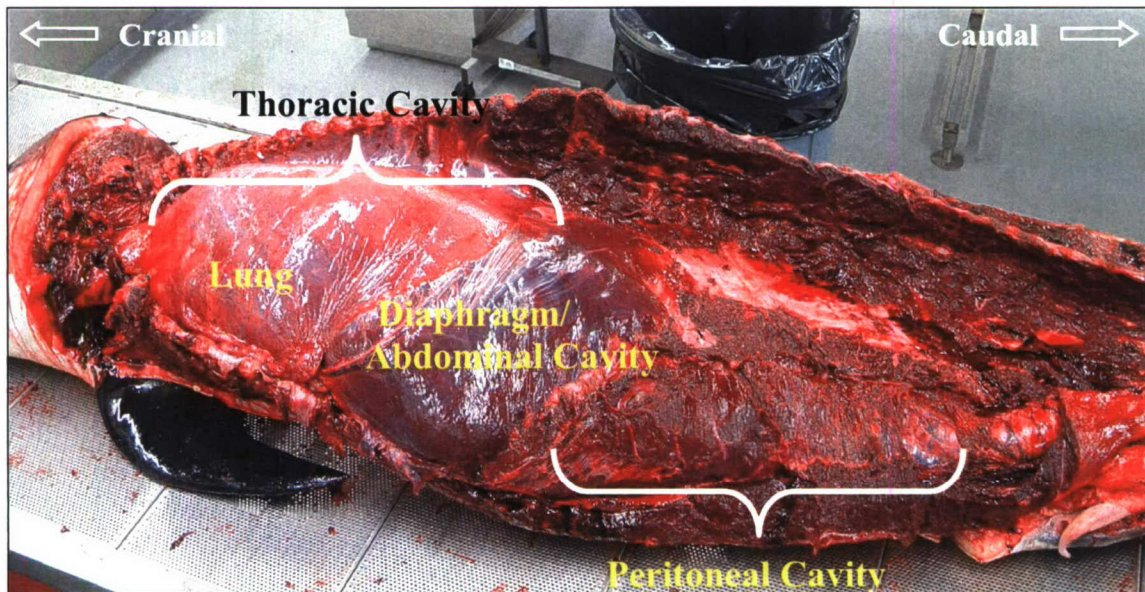


Figure 4-35. View of viscera with ribs removed.



At this point, one needs to adhere to a systematic examination of the internal tissues. The organs may be removed as a pluck, or may be examined in situ. The method of sampling can be guided by sampling needs, condition code, and personal preference. It is recommended that internal fluids, such as those in the gastro-intestinal system do not contaminate other tissues.

Thyroid:

The thyroid sits ventrally on the cranial trachea and spans the width of the trachea. The thyroid is one of the more difficult tissues to locate and identify. The color and texture are often similar to smooth muscle. The parathyroid is a small, light colored tissue attached to the thyroid along the cranial margin of the thyroid and can aid in correct tissue identification if it can be found. Examine the tissue externally and internally. Note the size, shape, color and texture. Sample for histology, microbiology, molecular and ancillary investigations.

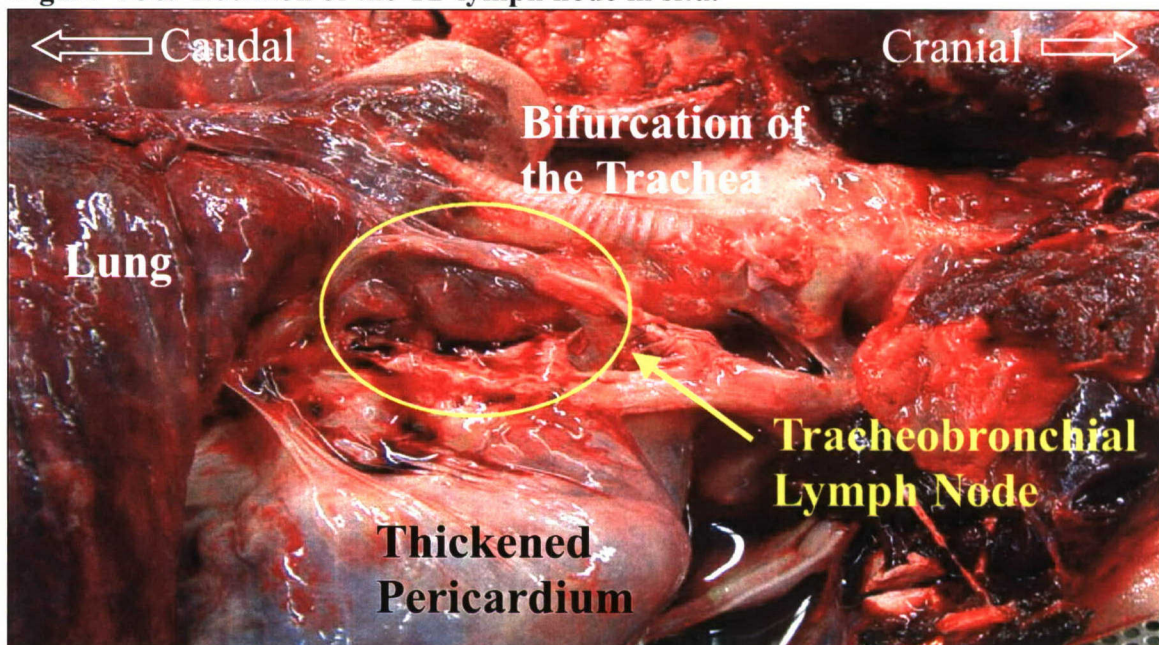
Thymus:

The thymus is a large, lymphoid organ, that is primarily found in neonates and some juveniles. It is situated at the base of the thoracic inlet, cranial to the anterior margin of the heart. The primary function of this organ is to generate T-cells. The thymus is absorbed with time after weaning, thus is not usually visible in adult marine mammals. Examine the tissue externally and internally. Note the size, shape, color and texture. Sample for histology, microbiology, molecular and ancillary investigations.

Tracheobronchial (TB) Lymph Node:

The TB lymph node is located along the distal cranial ventral surface of the lung proximal to the bifurcation of the trachea. It can easily be located by reflecting the cranial lung tissue away from the cavity and palpating the connective tissue between the lung and anterior to the trachea bifurcation (Figure 4-36). It is recommended that this tissue be identified and removed prior to removal of the lung or trachea, as it can be easily lost without anatomical landmarks. Examine the lymph node externally and internally. Describe any differences between the cortex and medulla. Note any other changes in size, shape, color and texture. Sample for histology, microbiology, molecular and ancillary investigations.

Figure 4-36. Location of the TB lymph node in situ.



Lungs:

The lungs occupy the majority of the thoracic cavity and are the large, normally bright pink, tissue with a consistent sponge-like texture (Figure 4-37). Detach the lung from the trachea at the bifurcation. Examine the pleural surface: note color pattern, and texture. Normal, air-filled lung tissue should bounce back immediately after being depressed with a finger (like a sponge) and float when placed in water or formalin. To examine the internal structures, using scissors, trace the trachea from the bifurcation along the bronchi and into the bronchioles of each lung. Note whether fluid, froth, and/or parasites are present and describe amount, color, *etc.*). Next, make serial cuts into the tissue by “bread-slicing” (making multiple, parallel slices into the tissue) perpendicular to the long axis of the body to examine the parenchyma. This is best done with a long knife using a single sweeping cut in order to avoid tearing or serrating the lung tissue. Examine the parenchyma and note color pattern and texture. Sample for histology, microbiology, molecular and ancillary investigations.

Figure 4-37. Pleural surface of the removed lung.

Collapsed lung tissue of the cranial ventral quadrant

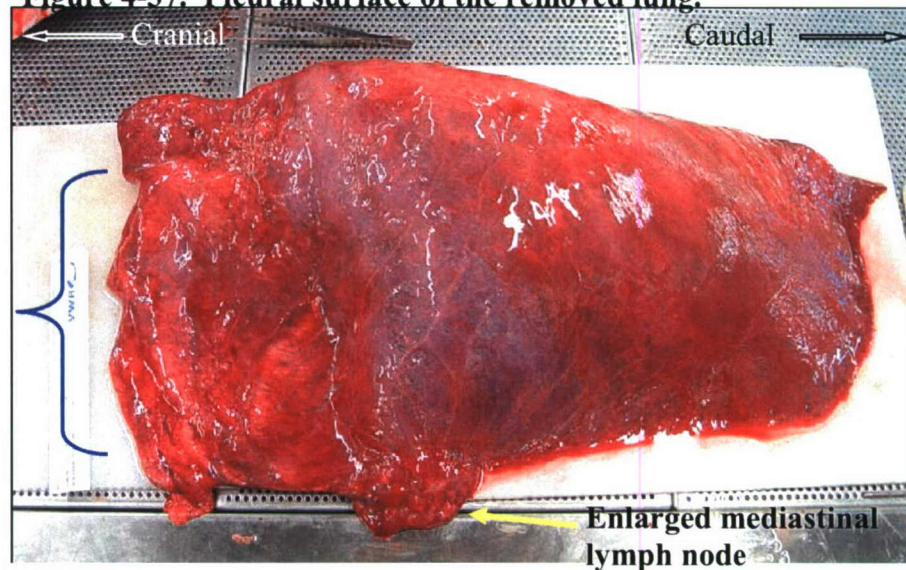
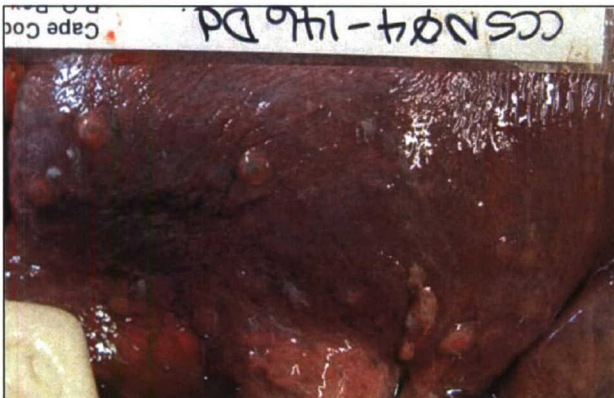
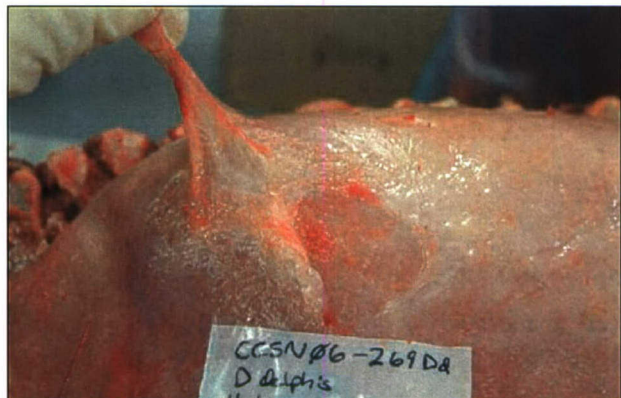
Figure 4-38. Gross Description: Multifocal, firm, light gray, variably sized nodules throughout the tissue.



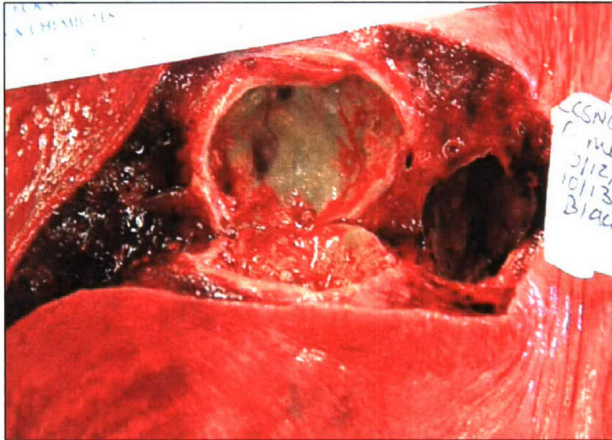
Morphologic Diagnosis: *Lymphosarcoma

Figure 4-39. Gross Description: Thick, opaque, elastic consistency of the pleura (external surface of lung).



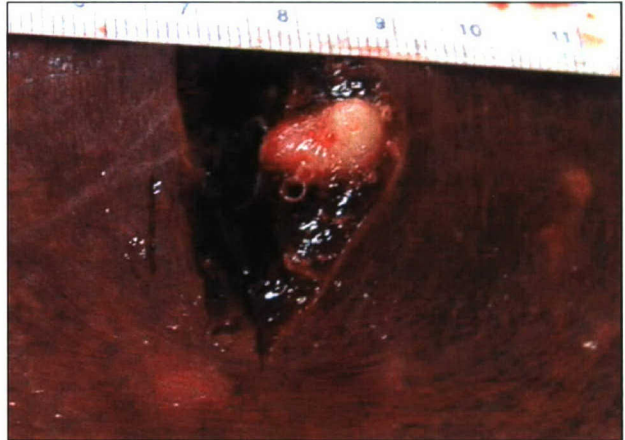
Morphologic Diagnosis: Pleural fibrosis.

Figure 4-40. Gross Description: Distinct, firm walled, 4.5cm spherical capsule with an irregularly textured internal surface containing light green caseous material.



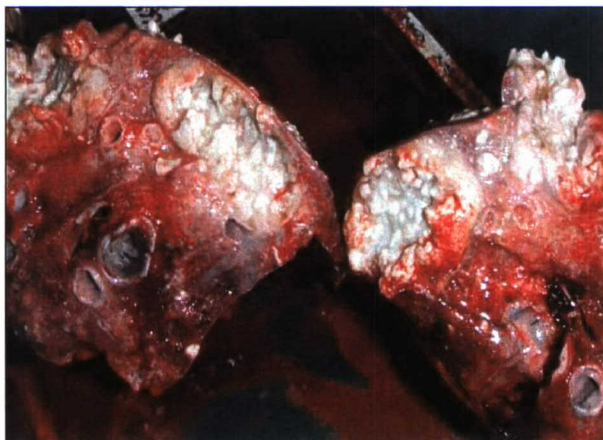
Morphologic Diagnosis: *Aspergilloma;
Etiologic diagnosis: pulmonary aspergillosis.

Figure 4-41. Gross Description: Single, focal, well demarcated, 1.0 x 0.5 cm oval, white capsule within the lung parenchyma (internal structures).



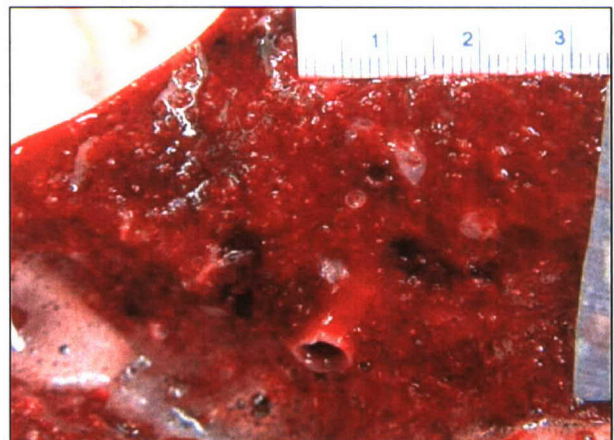
Morphologic Diagnosis: *Parasitic cyst

Figure 4-42. Gross Description: Large (4.5 x 4.9 x 1.4cm), raised, firm, light pink, capsule that contains light green mucopurulent fluid with white caseous material.



Morphologic Diagnosis: Pulmonary abscessation.

Figure 4-43. Gross Description: Multifocal, poorly demarcated, dark red tissue within the parenchyma proximal to the bronchioles.



Morphologic Diagnosis: Pulmonary hemorrhage.

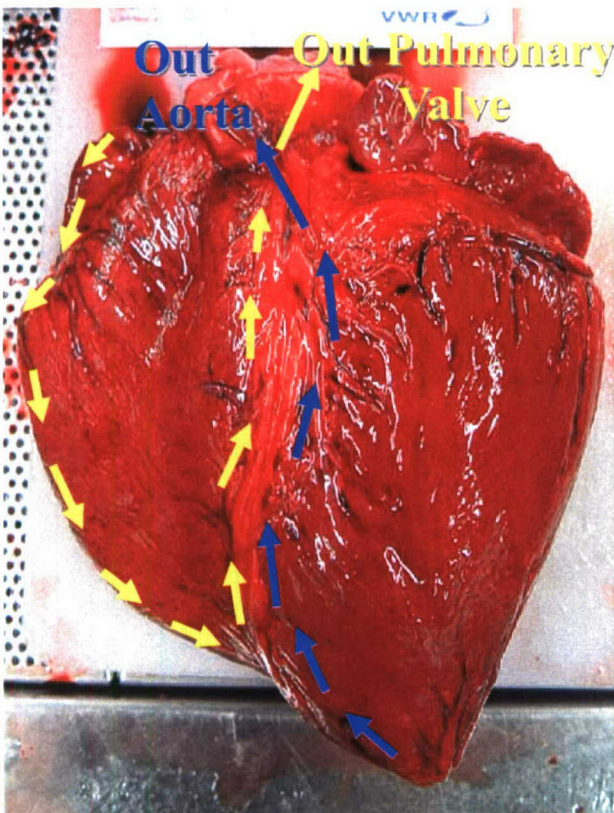
Trachea:

The trachea is a long, firm, off-white, flexible, ridged, tubular organ that extends from the larynx to the tracheal bifurcation. Using scissors, cut through the entire length of the trachea from the bifurcation up to the apex of the throat. Examine the mucosa and identify and describe contents (froth, fluid, blood, color, etc.). Sample for histology.

Heart Muscle and Valves:

Before handling the heart, observe and describe the pericardium. There should be a small amount of clear fluid within the pericardium to allow for lubrication. Note if there is excessive fluid and describe the characteristics. Also, note the presence of gas bubbles within the pericardium and vessels and note thickness of the tissue. Trim away the pericardium and observe the epicardium (external surface of heart) in situ. Note size, color, and texture of each structure (right and left atria and ventricles, aorta, and pulmonary vessel) (Figure 4-44). Remove the heart by cutting transversely across the aorta and pulmonary artery leaving approximately 6.0 cm of each vessel still attached to the heart muscle. There are varying techniques for examining the internal structures of the heart. One way is to use scissors to make a small opening in the cranial right atrium and cut down along the medial edge of the right ventricle down to the apex. Continue cutting along the right ven-

Figure 4-45. Recommended incision pathway to open the heart.



Right and Left Atria

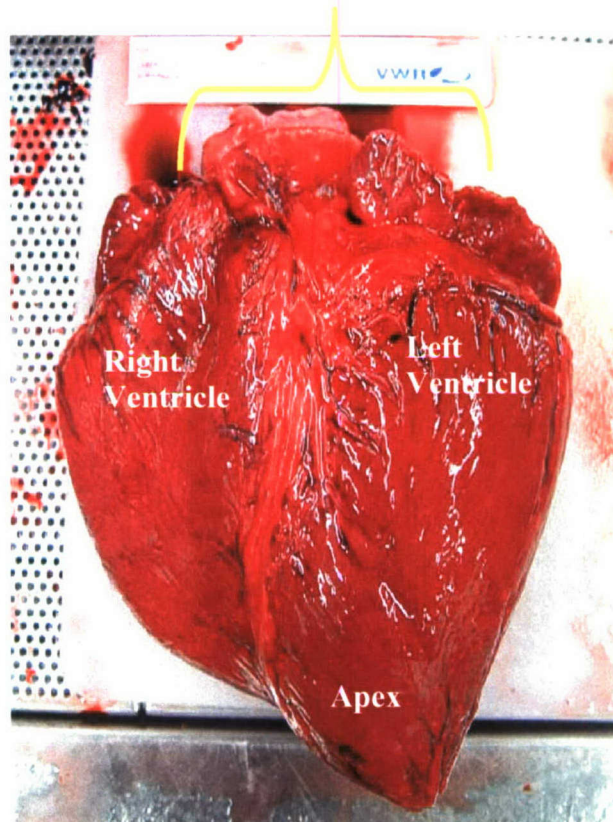


Figure 4-44. External structures of the heart.

tricle side of the septum until this chamber joins the pulmonary artery and cut up through the vessel. Next, snip the left ventricle side of the apex, cut through the muscle along the septum, and up through the aorta (Figure 4-45). This process leaves both sides of the heart intact.

A simpler way to examine the endocardium (inner surface of the heart) is by slicing the organ completely in half starting at the apex going laterally toward the vessels, so that it opens up like a book (Figure 4-46). Examine each chamber for the presence of worms or other foreign matter. Note the size/thickness of each atrium and ventricle, as well as color and texture. The left ventricle should be substantially thicker than the right. Thoroughly examine the interior of the valves for changes in texture or thickness. Normal mitral and tricuspid valves should be thin and slightly opaque. Once the endocardium is examined, bread-slice the ventricles to examine changes in the myocardium. Sample the right and left ventricles and atria, septum, apex, atria, and aorta for histology.

Figure 4-46. View of the Endocardium; heart is opened longitudinally.

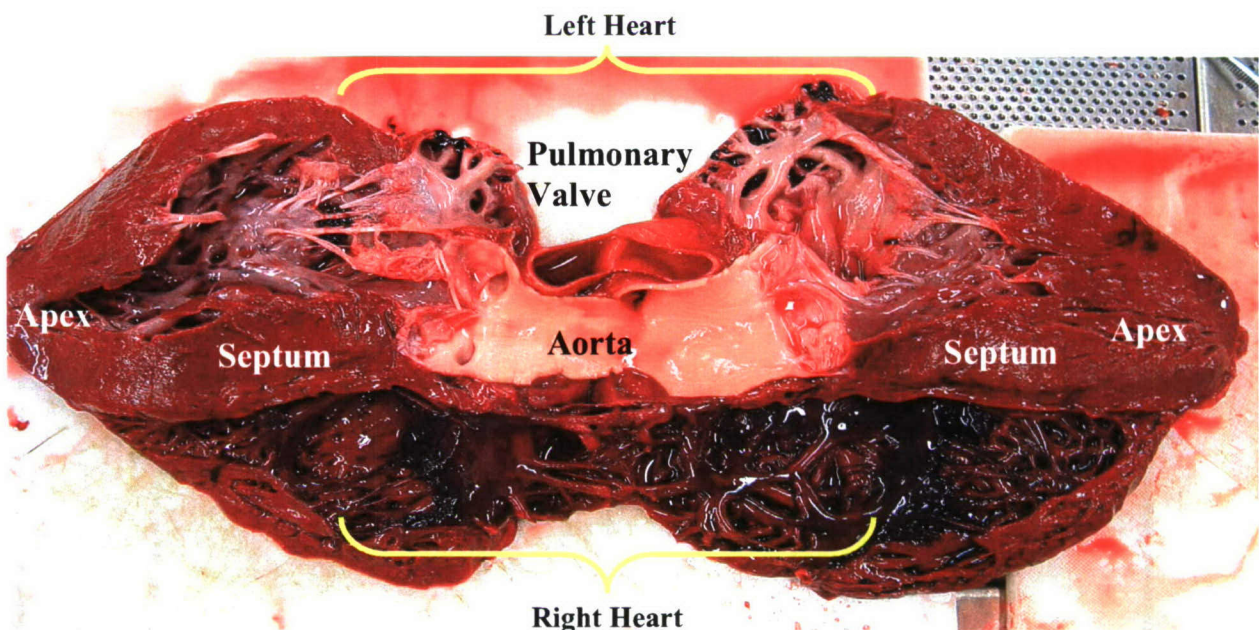
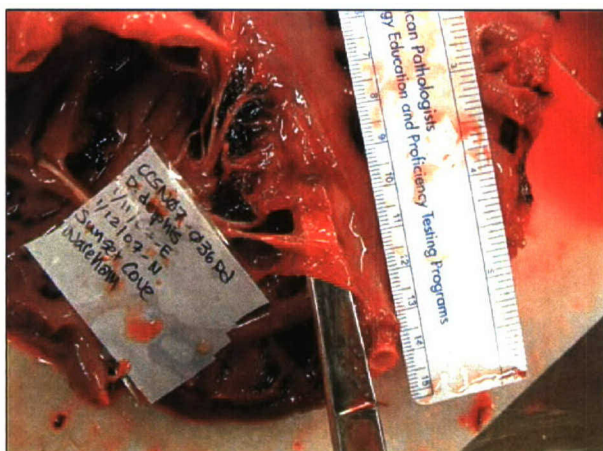
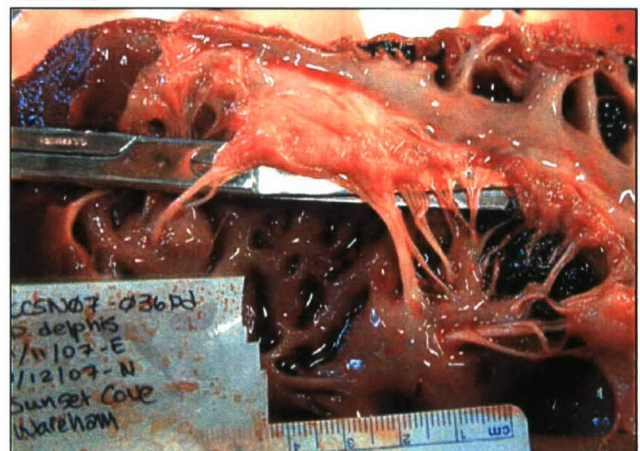

Figure 4-47. Gross Description: Translucent heart valves.



Morphologic Diagnosis: Normal A-V valves.

Figure 4-48. Gross Description: Thick, opaque, irregular textured mitral or tricuspid valves.



Morphologic Diagnosis: Valvular Endocardiosis

Figure 4-49.

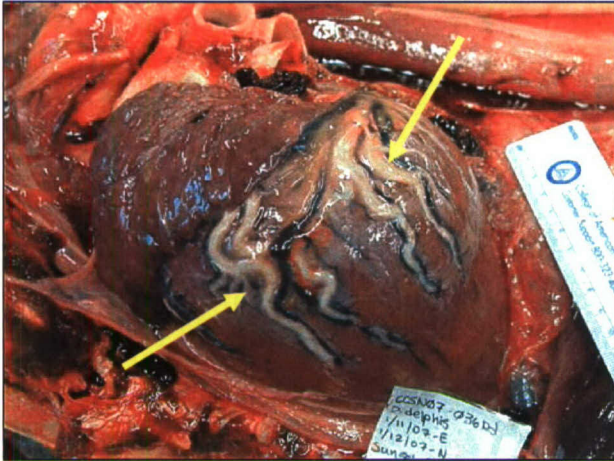


Figure 4-49. Gross Description: Thick, white, endocardial vessels.

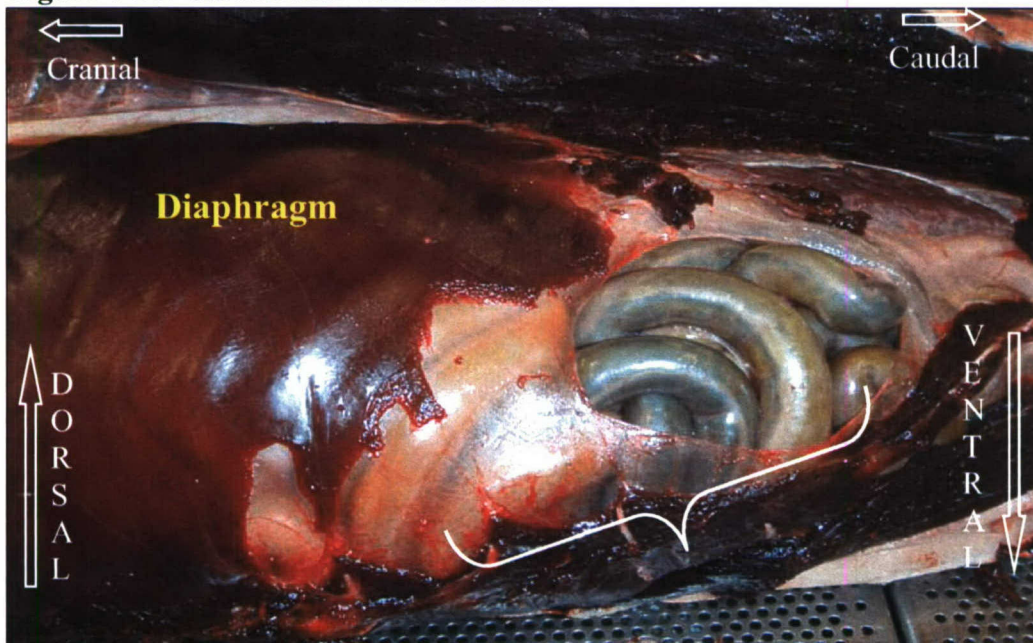
Differential Diagnosis: Fibrosis; atherosclerosis; mineralization; or arteriosclerosis

Diaphragm:

The diaphragm is the thin, smooth textured, dark maroon, expandable muscle that is attached to the caudal rib cage and separates the thoracic and abdominal cavities (Figure 4-50). Note the texture and color as well as any tears or adhesions. White striations over the surface of the diaphragm are normal. Trim away the diaphragm enough so that there is complete access to the abdominal organs. Sample for histology.

To expose the abdominal organs, incise the abdominal wall from the last rib mid-ventral to the level of the anus. Extend the most cranial cut laterally along the thoracic arch and reflect the abdominal musculature to expose the internal tissues. The orientation of the organs should be visually assessed and any free fluids aseptically collect in a sterile syringe prior to proceeding with the internal examination.

Figure 4-50. Abdominal viscera in situ.



Liver:

The multi-lobular, diffusely maroon liver is large, lies over the stomach and dominates most of the abdominal cavity (Figure 4-51). Examine the parietal (toward the body wall) and visceral (toward the organs) surfaces of the liver and note color pattern, texture and size of the lobes. Examine the parenchyma of the liver by bread-slicing through the tissue. Again, note the color and texture within. Examine bile ducts for presence of parasites. Sample for contaminants, histology, microbiology, molecular and ancillary investigations. **Note: all cetaceans lack a gall bladder.**

Figure 4-51. Location of liver in situ.

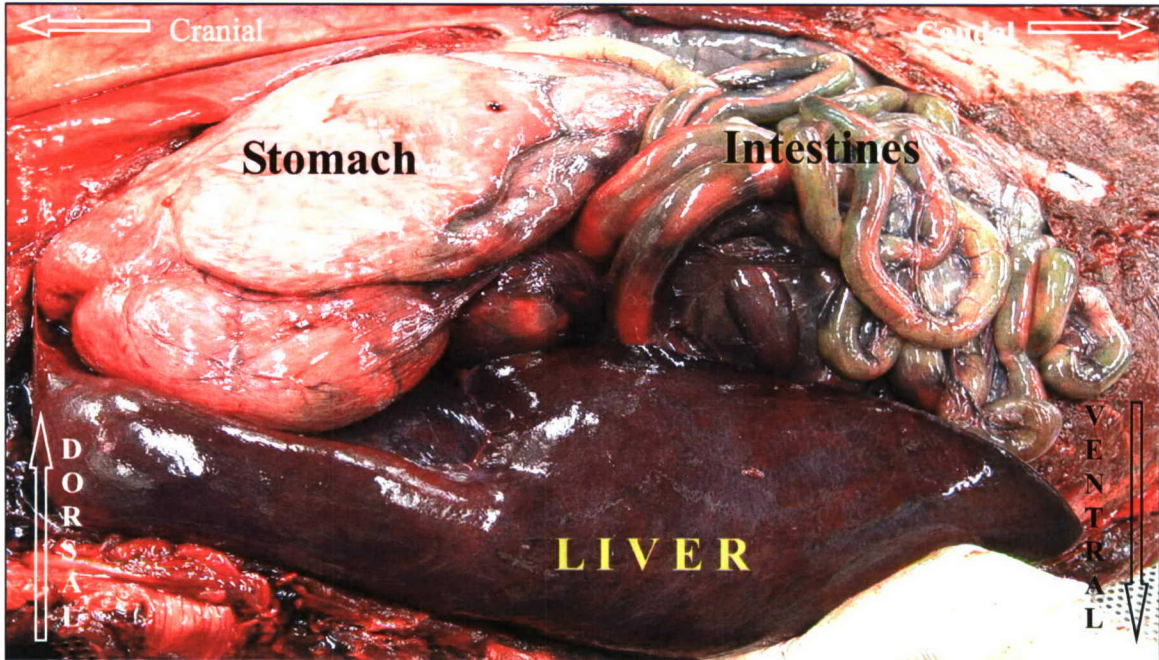
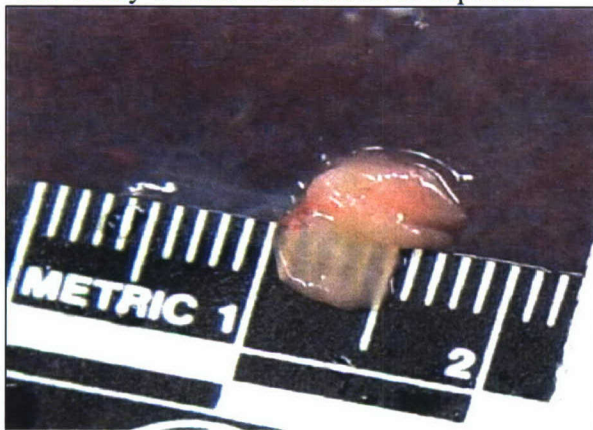
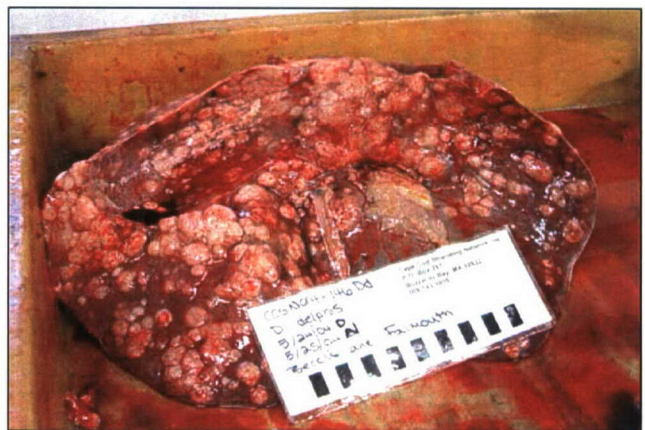
Figure 4-52. Gross Description: Multiple, translucent off-white 0.8 x 0.5cm adhesions that easily detach from the liver capsule.



Morphologic Diagnosis: Fibrin tag

Figure 4-53. Gross Description: Multifocal to coalescing firm, cream colored nodules diffusely throughout the liver affecting >80% of the tissue.



Morphologic Diagnosis: *Lymphosarcoma

Figure 4-54.

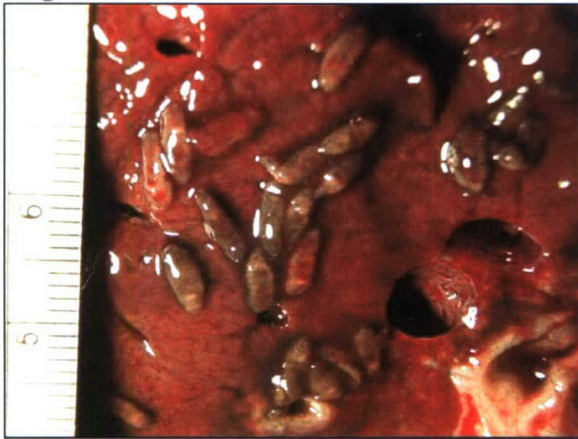


Figure 4-54. Gross Description: Approximately 15cc's of mucopurulent, light green fluid and >200, 0.5cm, flat, light green parasites exuding from the bile ducts of the liver.

Morphologic Diagnosis: Cholangiohepatitis with intraluminal trematode parasites and associated periductular fibrosis, bile ductular hyperplasia, and ductular cholestasis.

Spleen:

The shape and size of the spleen vary among cetacean species. The spleens of most delphinids are palm-sized, spherical and mottled dark purple to white with a smooth external texture. For other species, the spleen may share these characteristics or be smaller and oblong. Regardless of physical characteristics, the organ is always located underneath the main stomach toward the left side of the body (Figure 4-55). Remove the spleen by detaching it from the omentum (thin, web-like, connective tissue). Note size, shape, color, and texture of both the surface and the parenchyma of the spleen. In some cases, smaller (0.2—1.0cm), accessory spleens may be attached to the visceral surface of the spleen. These smaller spleens share the same characteristics as the larger spleen. Sample for histology, microbiology, molecular and ancillary investigations.

Figure 4-55. Stomach lifted to reveal the location of the spleen.

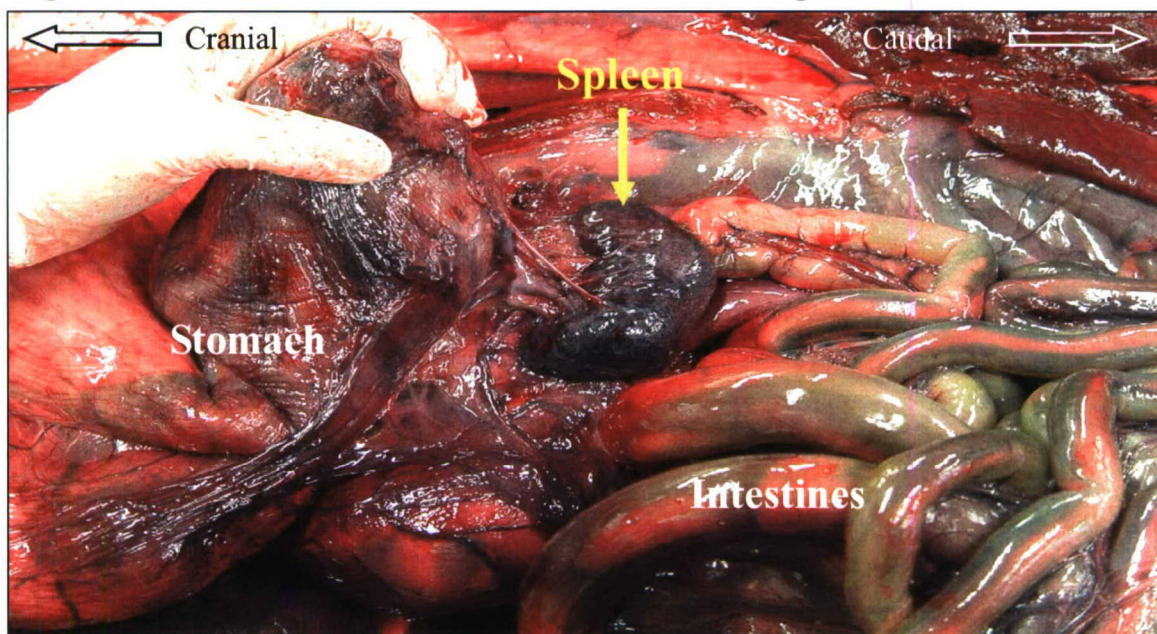
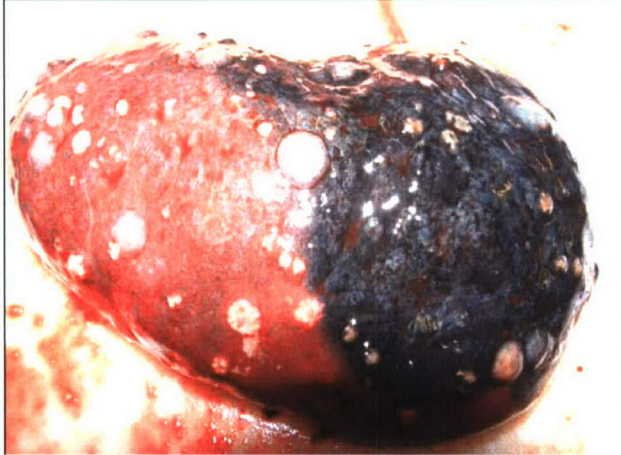


Figure 4-56. Gross Description: Multifocal, 0.5-3.0cm, firm, white nodules diffusely throughout the spleen; one half of the spleen is pink the other is purple (normal).



Morphologic Diagnosis: *Multifocal granulomas.

Figure 4-57. Gross Description: Multifocal, maroon, 0.1-0.3cm, circular, flat to slightly raised, superficial, foci.



Morphologic Diagnosis: Normal, extruded red pulp

Pancreas:

The pancreas is a peach colored, irregularly shaped, pyramidal, softer tissue that is attached to the mesentery and sits in the curve of the duodenum (Figure 4-58). Remove the pancreas from the cavity by detaching it from the connective tissue and duodenum. Note the size, shape, color, and texture of the surface. Cut into the parenchyma and note changes in color or texture (Figure 4-59). Examine ducts for parasites. Sample for histology, microbiology, molecular and ancillary investigations.

Figure 4-58. Location of the pancreas in situ.

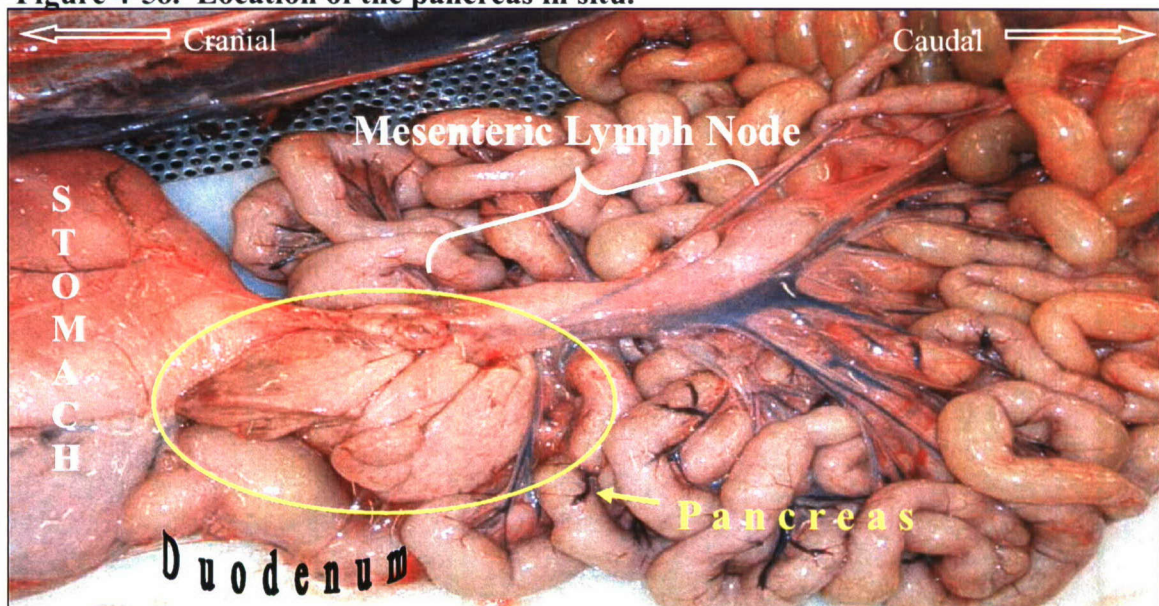


Figure 4-59. Normal pancreas incised and margins reflected to expose cut surfaces.

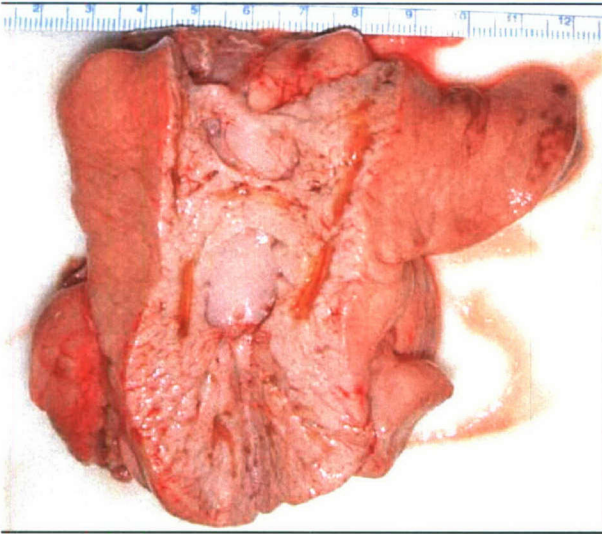
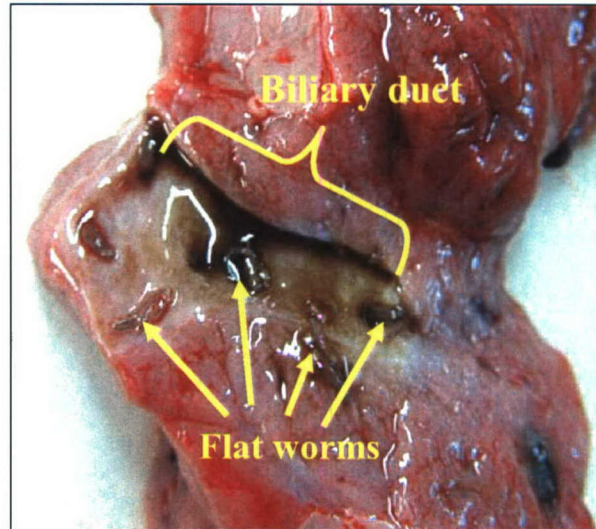


Figure 4-60. Gross Description: Bile ducts are thickened, white and contain multiple ~1.0cm flat worms and dark brown fluid.



Morphologic Diagnosis: *Intraductal trematode and periductular fibrosis and ductal ectasis.

Mesentery and the mesenteric lymph node:

The mesentery is a broad sheet of connective tissue which attaches the intestines (and other viscera) to the mesenteric root. This connective tissue should be translucent and show some resistance when attempting to bluntly dissect (Figure 4-61). Examine the mesentery for parasitic or fungal attachments or other abnormalities. Note thickness and opacity. The mesenteric lymph node is a finger-like, gray to tan colored, larger lymph node that is centrally attached to the mesentery (Figure 4-58). Remove the lymph node by detaching it from the mesentery. Note the size, shape, and color of the mesenteric lymph node. Examine the external surface and internal structures for changes in color and texture. Unlike previous lymph nodes discussed, the mesenteric lymph node tends to have a more defined cortex and medulla. Be sure to describe each structure separately. Sample for histology, microbiology, molecular and ancillary investigations.

Figure 4-61. Mesentery.

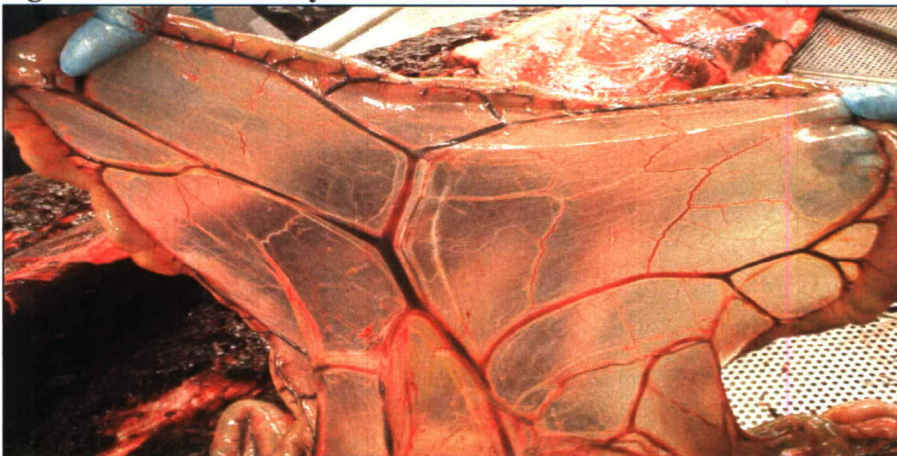


Figure 4-62.

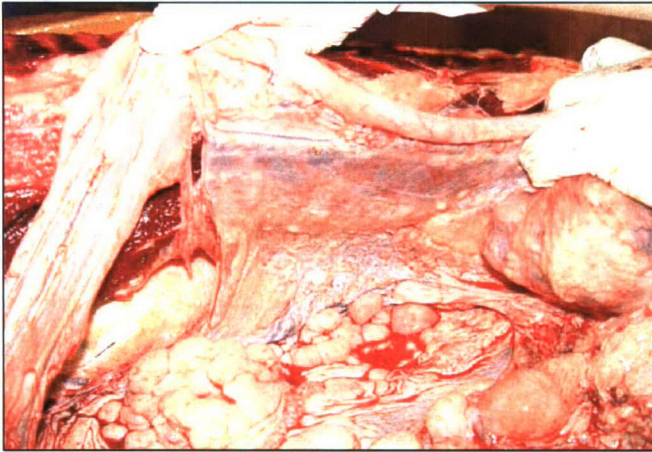
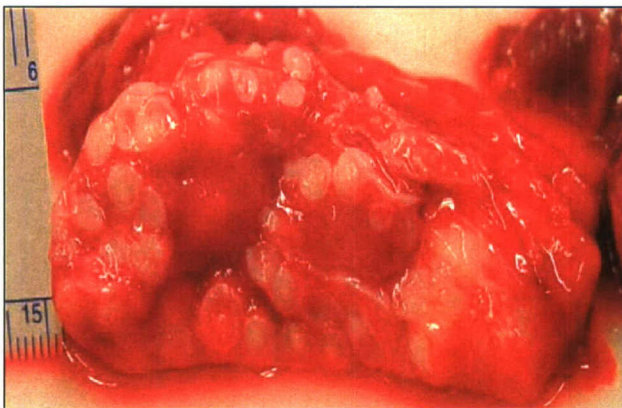


Figure 4-62. Gross Description: Multifocal to coalescing firm, raised, creamy white, sessile masses diffusely attached to the mesentery.

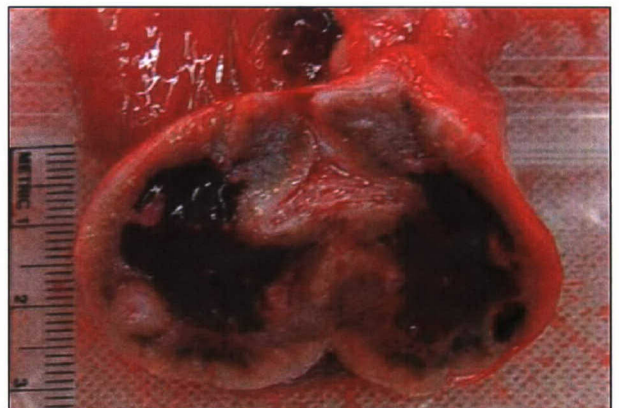
Morphologic Diagnosis: *Multicentric lymphosarcoma.

Figure 4-63. Gross Description: Extremely enlarged mesenteric lymph node with multiple clusters of circular, white, firm nodules with yellow centers infiltrating the cortex effecting >80% of the tissue.



Morphologic Diagnosis: Lymphadenitis or neoplastic process.

Figure 4-64. Gross Description: Well demarcated yellow to tan cortex with multiple, small (0.2 –0.5) circular nodules that slightly infiltrate the medulla; focal areas of hemorrhage at the cortico-medullary junction; medulla is severely edematous and hemorrhagic.



Morphologic Diagnosis: *Follicular hyperplasia

Adrenal Gland:

The right and left adrenal glands are located just anterior to the cranial pole of each kidney and are attached to the dorsal abdominal wall (Figure 4-65). The adrenal glands are small, oblong, light maroon tissues possessing irregular furrows over the surface. Locating and extracting the adrenals prior to removing the kidneys is highly recommended, as they can be difficult to locate without the kidneys as an anatomical reference. To remove the adrenals, grasp and pull the tissue away from the body wall and cut the surrounding connective tissue. Before sectioning, measure (LxWxH) and weigh each adrenal. When cut in half, a normal adrenal will present a distinct darkened center (medulla) with a lighter perimeter (cortex). Note size, shape, color and texture of the external and internal tissue. Also, note relative size of the aperture, or opening in

the medulla, which would indicate usage of the vessel. Normal apertures should be no larger than the tip of a pin. Sample each adrenal for histology and ancillary investigations.

Figure 4-65. Location of the adrenal in situ.

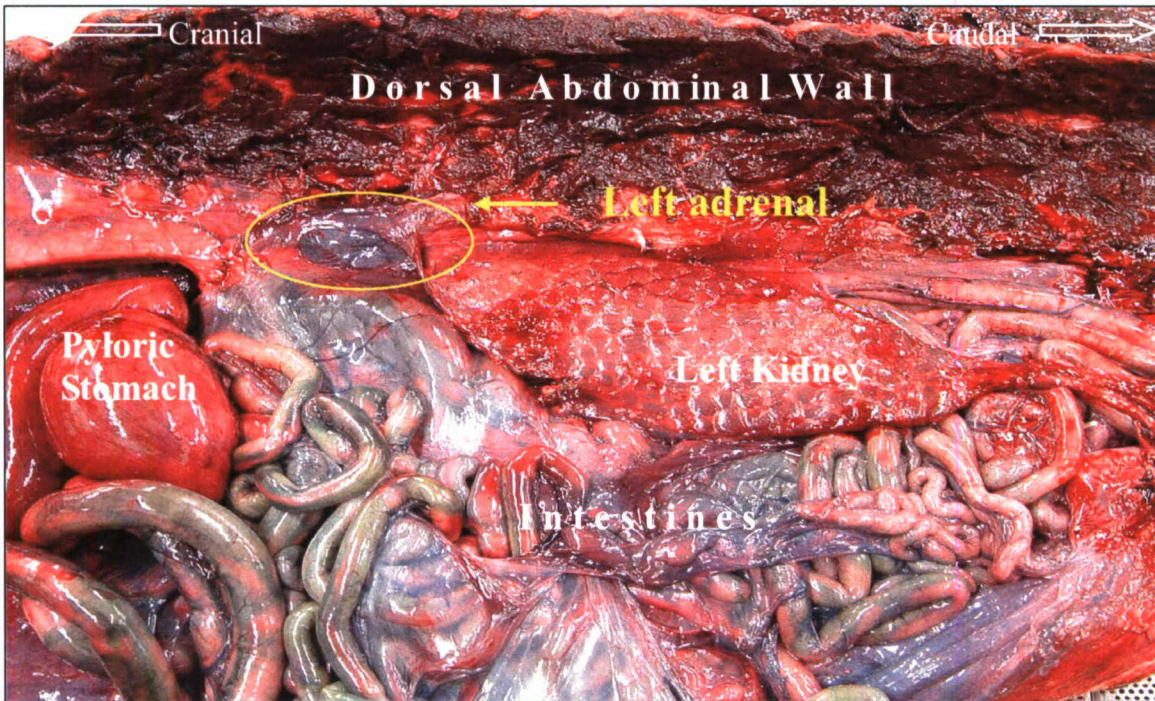


Figure 4-66.

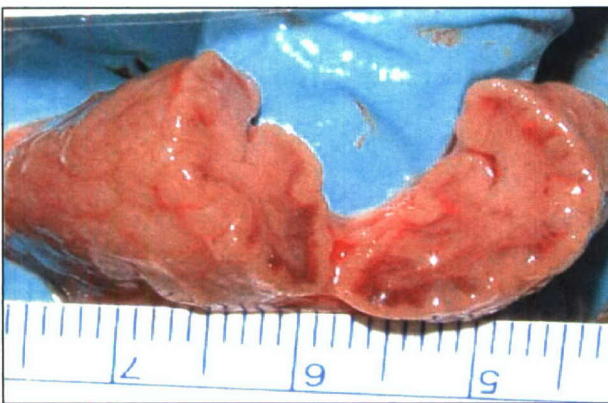


Figure 4-66. Gross Description: Adrenals are diffusely pale pink with multifocal hemorrhage at the cortico-medullary junction.

Morphologic Diagnosis: Cortico-medullary adrenal hemorrhage.

Kidney:

The left and right kidneys are maroon, ovoid, tissues comprised of numerous, clustered reniculi (miniature kidneys) and are attached to the caudal dorsal abdominal wall (Figure 4-65). Examine the capsule (connective tissue surrounding the kidney) for the presence of fluid, hemorrhage, or bubbles and note color, thickness, and opacity. Create a longitudinal incision through the capsule and reflect the margins to assess for adhesions or sub-capsular hemorrhage. Detach the kidney from the abdominal wall and remove the capsule to examine the external surface. Note the size,

shape, external color and texture of each kidney. Examine the internal structure of each kidney by bread- slicing. Note color and presence of stones. Observe the degree of differentiation between the cortex and medulla as well as the medulla:cortex ratio within each reniculus (Figure 4-67). Each reniculus should be well demarcated but clustered together within the kidney itself. Sample for contaminants, histology, microbiology, molecular and ancillary investigations.

Figure 4-67. Cross section of reniculi.

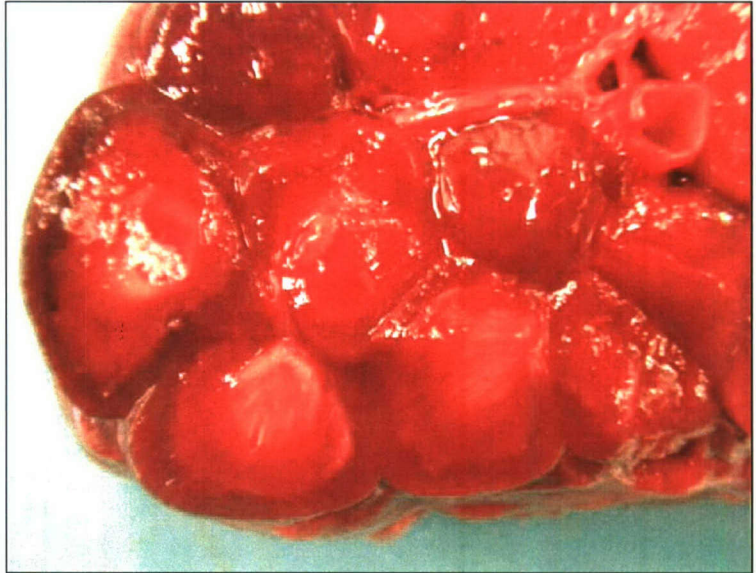
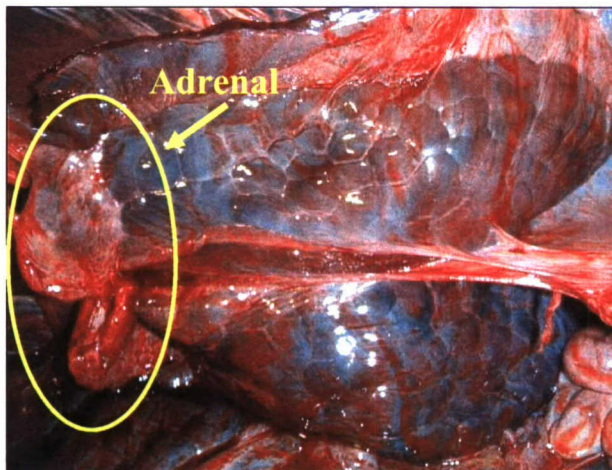
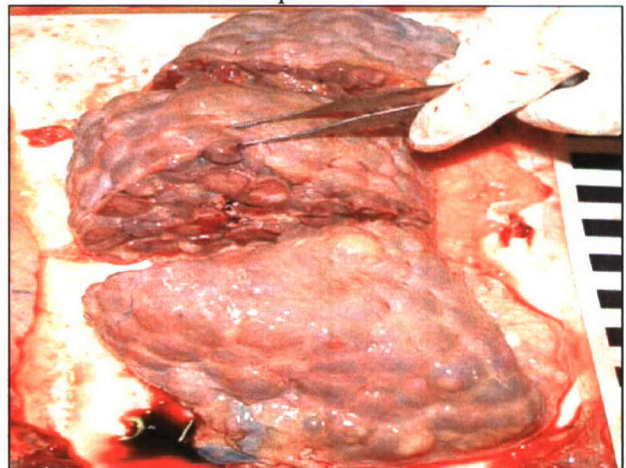


Figure 4-68 . Both the left and right kidneys are adhered together at the cranial pole and share the same ureter; there is only one large adrenal that spans the width of the conjoined kidneys.



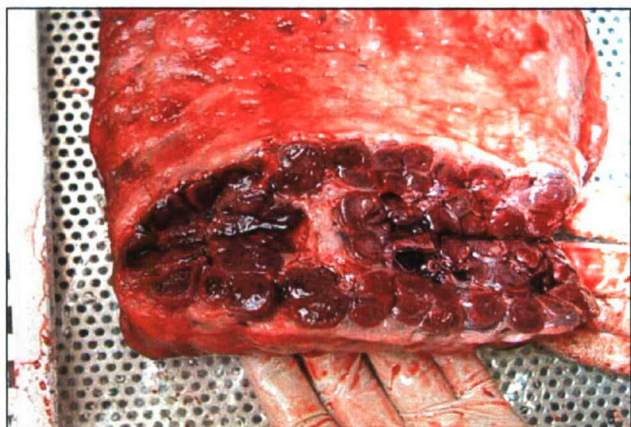
Morphologic Diagnosis: Anterior pole renal adhesions; adrenomegaly.

Figure 4-69. Gross Description: Capsule is thickened, pale pink with multiple nodules; internal structures are pale.



Morphologic Diagnosis: *Disseminated renal lymphosarcoma.

Figure 4-70. Gross Diagnosis: Thick, white, sponge-like material surrounding the entire kidney as well as the internal vessels.



Morphologic Diagnosis: Commonly interlobular renal fat; or steatosis.

Figure 4-71. Gross Description: Bubbles within the renal capsule.

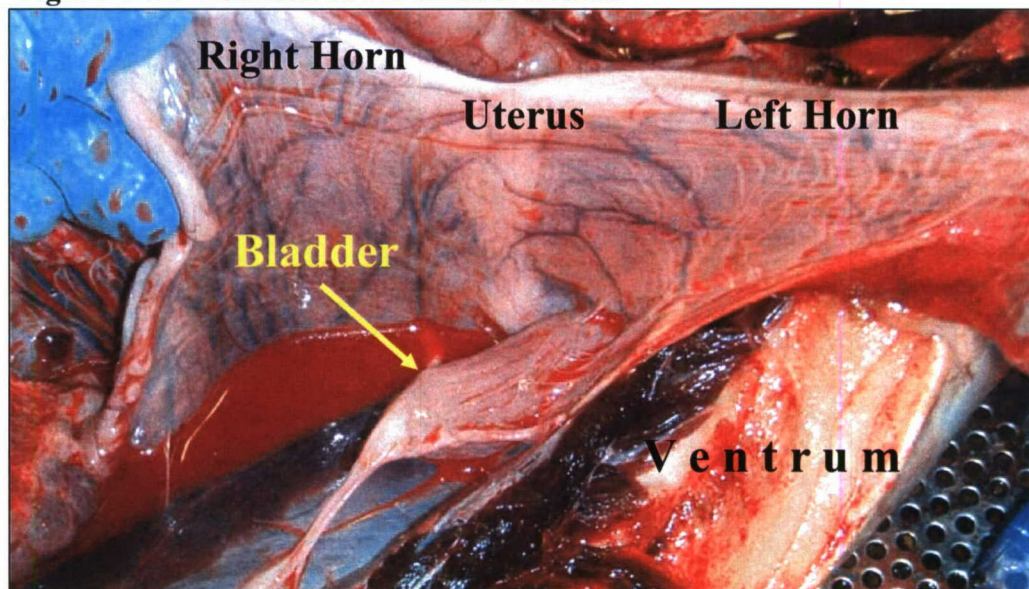


Differential Diagnosis: Post-mortem gas or ante-mortem gas emboli.

Urinary Bladder:

The bladder is a smaller, light pink, organ that is found along the ventral body wall (Figure 4-72). The organ may appear as a thick walled, muscular organ, but if distended with urine, the walls may be thinned and semi-translucent. Before removing the bladder from the body, extract contents using a sterile syringe and medium gauge needle. If none are available, be sure to clamp the bladder using a hemostat before removing the organ in order to retain urine. Note color, consistency, and amount of urine. Remove the bladder and examine internally by cutting along the length of the organ to expose the mucosal surface. Note color and texture of the mucosa. Sample the cranial tip of the bladder for histology.

Figure 4-72. Location of the bladder in situ.



Reproductive tract:

Female- Ovaries and uterus

The uterus and ovaries can most easily be identified by following the reproductive tract from the vagina to the uterus where it bifurcates to a right and left horn, each ending at the attachment of the ovaries (Figure 4-73). The uterus is a tan to pink tissue that will vary in size and thickness depending on the maturity of the animal and its reproductive history. Note size, shape, color, and texture of the external and internal surfaces of the organ. If a fetus is present and is too small for a sufficient individual necropsy, incise the abdomen, collect microbiology and molecular samples, then preserve fetus whole in formalin. If the lung tissue floats in formalin (or water), this signifies that bronchiole expansion of the fetal lungs has occurred.

An off-white spindle-shaped ovary is attached to the end of each uterine horn. Detach the organ from the uterus and examine the external surface. Note size, shape, color and texture. A mature ovary will possess random darkened notches or scars (corpus albicans) which signify previous ovulations (Figure 4-74). The ovary of a pregnant female will possess a corpus luteum, or a large yellow mass attached to the ovary (Figure 4-75). Before internal examination, measure (LxWxH) and weigh each ovary. Also count and note the number of scars and presence/absence of a corpus luteum. Examine the tissue internally and note color and texture. Sample both the uterus and ovaries for life history, histology, microbiology, molecular and ancillary investigations.

Figure 4-73. Reproductive tract of an adult, female *D. delphis*; note the cluster of large monorygma attached.

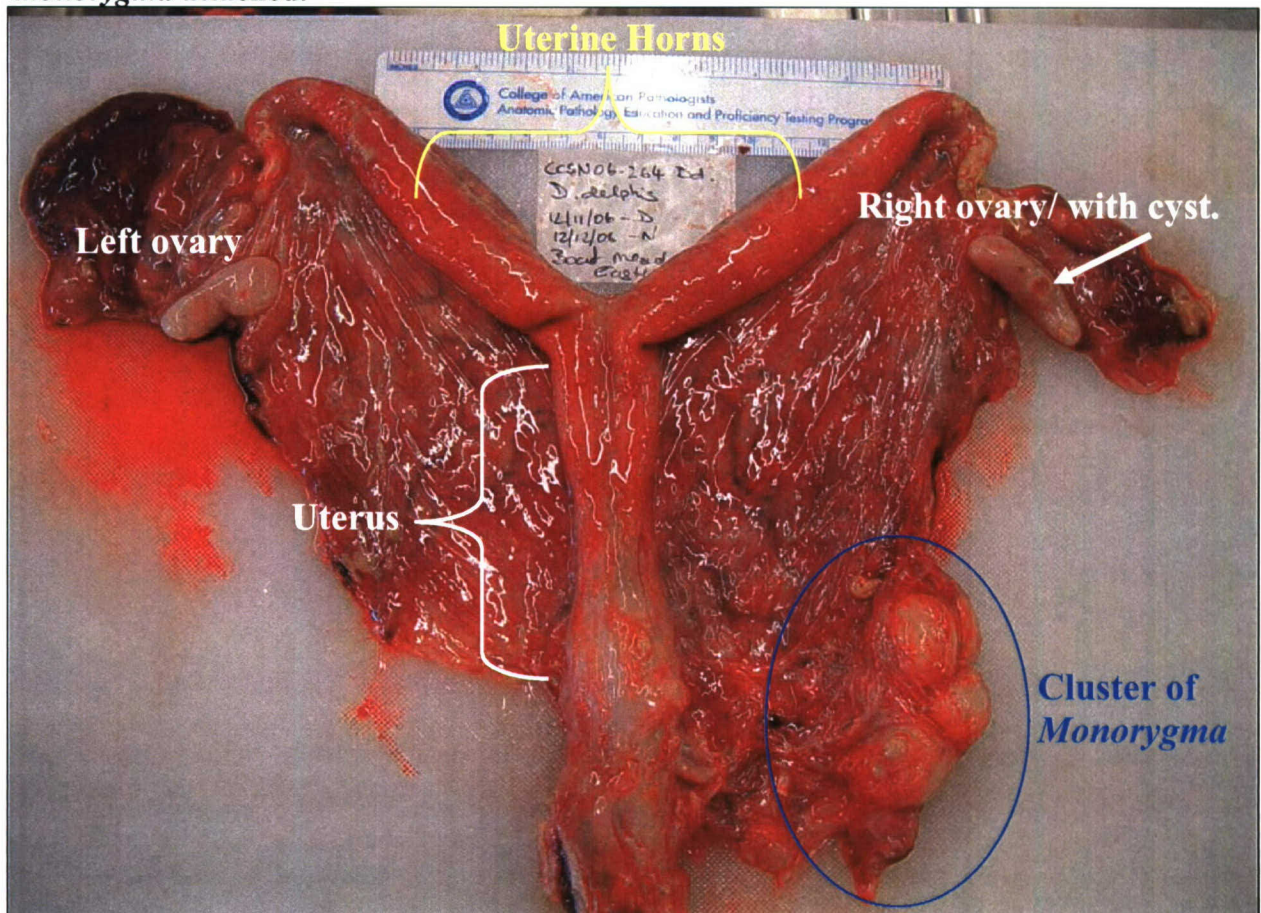
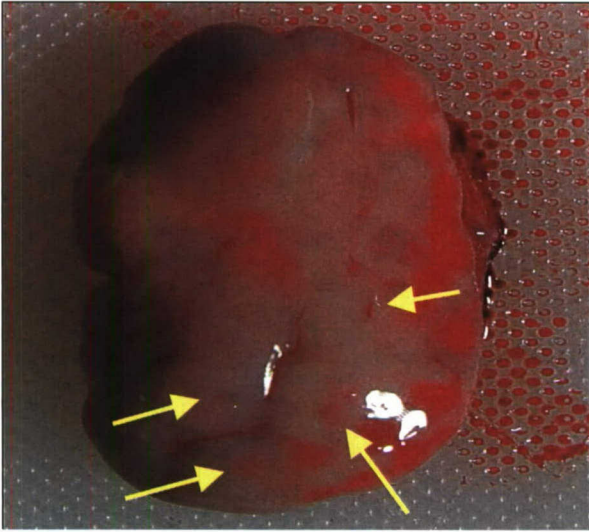
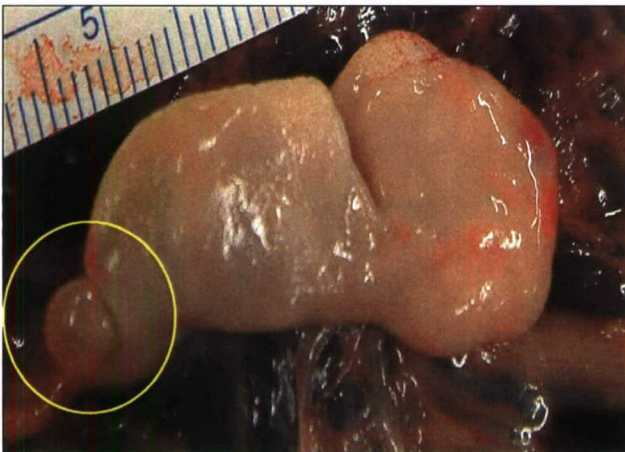


Figure 4-74. Gross Description: Multifocal dark, slightly depressed notches on the surface tissue.



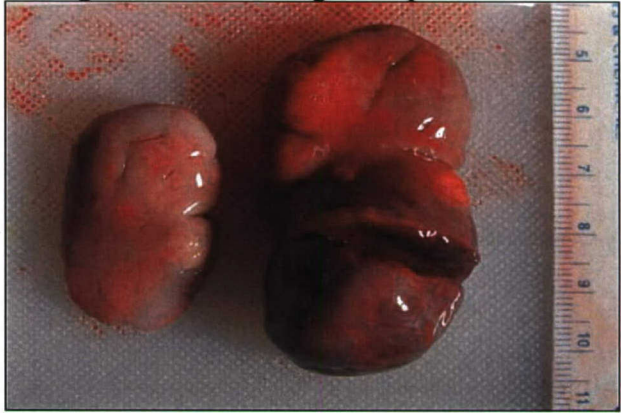Morphologic Diagnosis: Stigma on the surface of the ovary indicative of previous ovulation.

Figure 4-76. Gross Description: There is a 0.4cm spherical, clear fluid-filled nodule attached to the surface of the ovary.



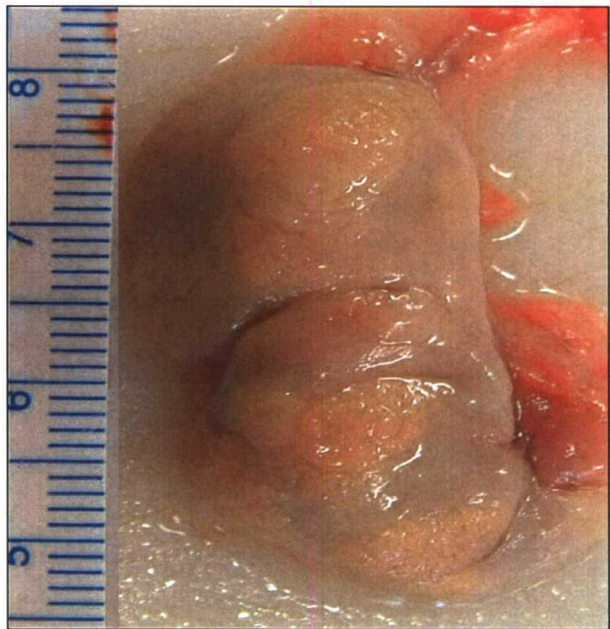Morphologic Diagnosis: Ovarian Cyst.

Figure 4-75. Ovaries from a pregnant *L. acutus*: Left is an active ovary with multiple corpus albicans; right is the ovary from which the fertilized follicle was released—notice enlarged, but hemorrhaged corpus luteum.



Morphologic Diagnosis: Corpus luteum hemorrhage.

Figure 4-77. Gross Description: Multifocal areas where the ovarian capsule is raised and roughened.



Morphologic Diagnosis: Capsular fibrosis.

Male- Testis and Penis

The elongated, spindle shaped, off-white paired testes are located within the caudal abdominal cavity along the ventral wall, posterior to the kidneys, each one just off the ventral midline (Figure 4-78). Remove the testes (with the epididymus attached) from the body. Obtain measurements (LxWxH) and weight of each one. Examine the size, shape, color, and texture externally and internally. Section epididymus for the presence/absence of sperm. Obtain samples of each testis for life history, histology, microbiology, molecular and ancillary investigations. Examine the penis externally and look for discharge or the presence of papillomas or other lesions.

Figure 4-78. Left testis in situ with penis dissected.

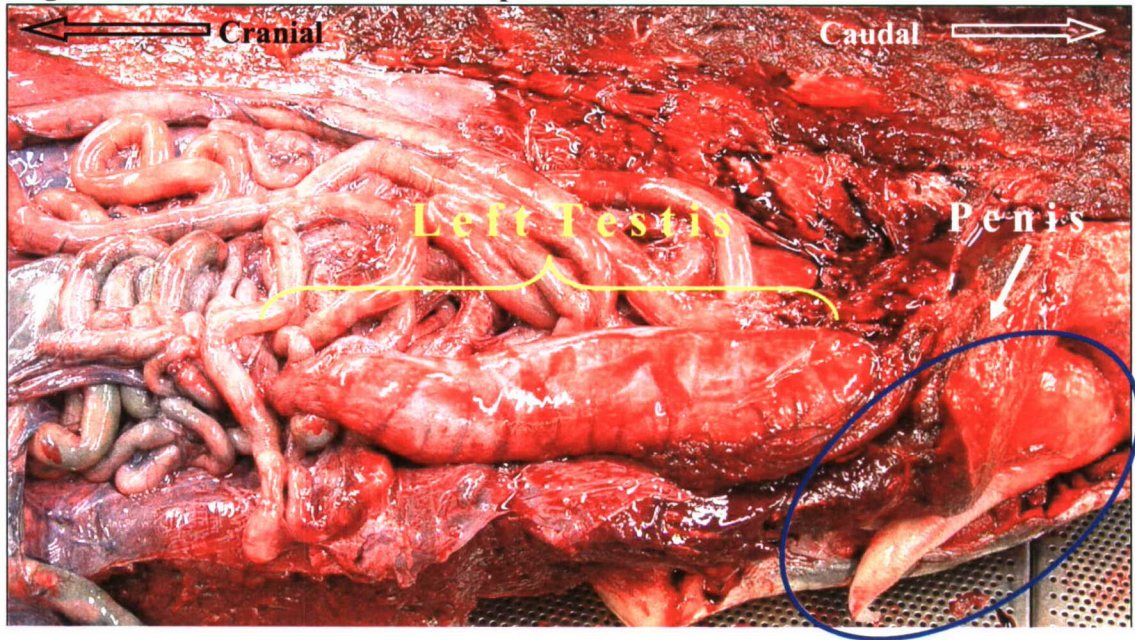


Figure 4-79. Normal, immature testes with epididymus.

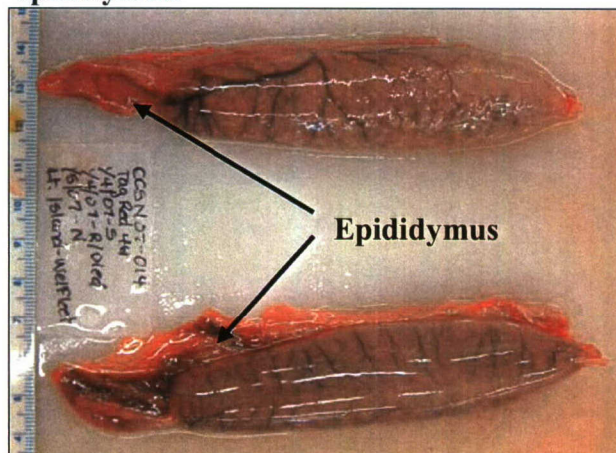


Figure 4-80. Cross section of vas deferens.

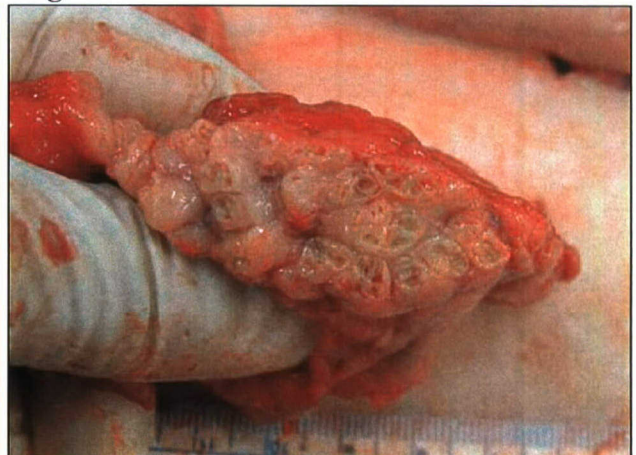
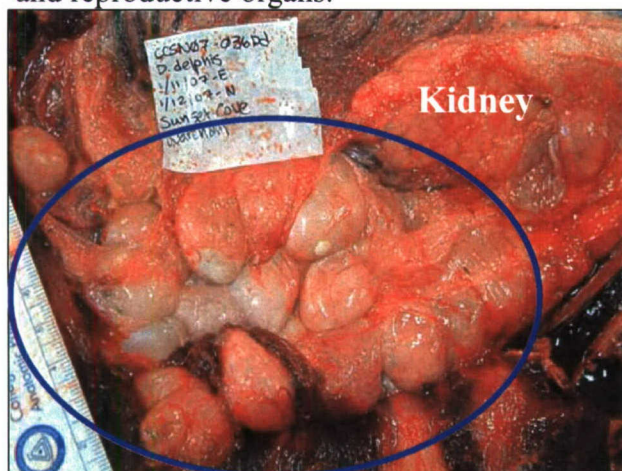
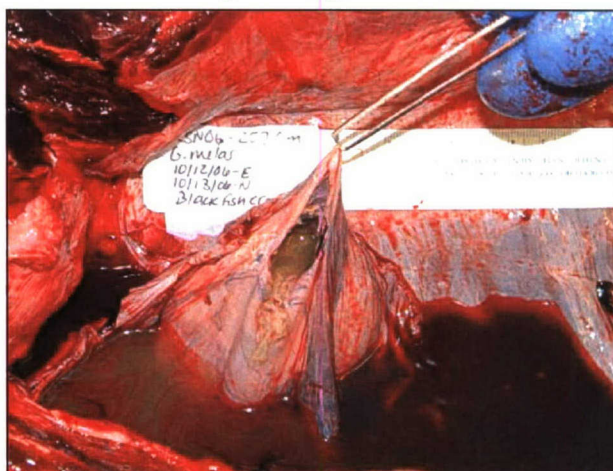


Figure 4-81. Gross Description: Multiple (>15), large (2.0cm), spherical, thin walled, parasitic cysts clustered around the urinary and reproductive organs.



Morphologic Diagnosis: Pericystic cestodes;
Etiology: *Monorygma* sp.

Figure 4-82. Gross Description: Attached to the lower, ventral abdominal wall, proximal to the testis, there is an 8.0cm, thin walled, spherical cyst containing green/brown translucent fluid and yellow plaques and a single 1.3cm diameter yellow, gelatinous ball.



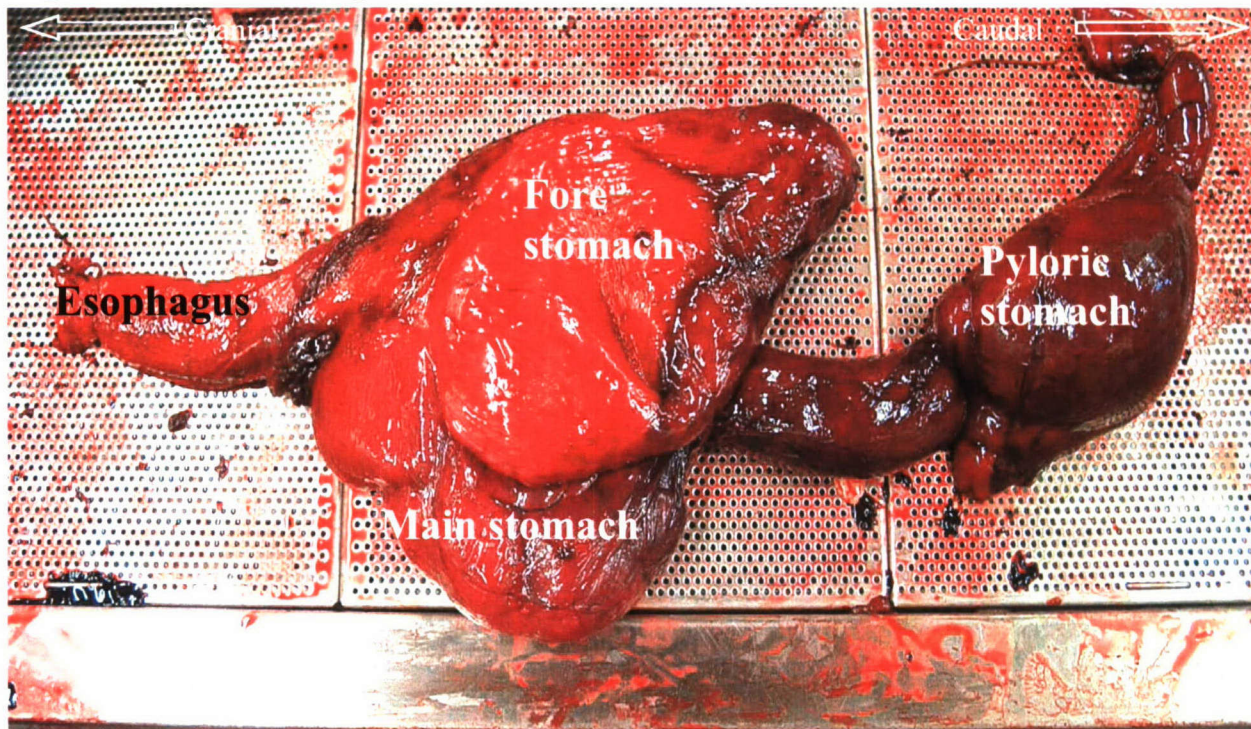
Morphologic Diagnosis: Pericystic cestode;
Etiology: *Monorygma* sp.

Stomach:

The stomach of most odontocetes is comprised of three compartments: the fore stomach, main stomach, and pyloric stomach (Figure 4-83). There is a thin, net-like connective tissue that is attached to the visceral side of the stomach. This is the **omentum**. To avoid contaminating the remaining tissues in the body cavity or losing contents, it is necessary to tie off both ends of the stomach prior to extracting. With some twine, tie a tight, secure knot at the location of the attachment of the esophagus to the fore stomach. A second piece of twine can be tied just below the base of the pyloric stomach where the small intestines begin. Remove the stomach from the carcass by cutting beyond both knots. Examine the serosal (external) surface of the stomach for discoloration and lesions. If an internal pathology is present, the peri-gastric lymph nodes attached to the stomach should be noticeably enlarged. Sample for histology, microbiology, molecular and ancillary investigations and make note on the sample inventory list if this is the case. Otherwise, remove all excess attached tissue from the exterior of the stomach and weigh the stomach full.

Using a scalpel, make an incision through the wall along the greater curvature of each stomach large enough to allow examination of the contents and entire mucosal surface. Describing the contents of each compartment separately, note the composition of stomach contents (fluid; whole or partially digested fish; fish bones; parasites; foreign objects). Be sure to describe amounts, color, and texture. Prior to further manipulation, collect a sample of contents for biotoxins. The remaining contents can be emptied and rinsed into a sieve to ensure solid material is not lost and is thoroughly examined. Save all foreign objects for human interaction documentation. Collect and store the remaining solid materials as outlined in the Sample Management section (Section 2) of this manual.

Figure 4-83. Three-compartment stomach removed from the carcass.



Once empty, examine the mucosa of the stomach. Note the color and texture of the mucosa of each compartment separately. The mucosa of the fore stomach is composed of squamous tissue and is usually white (Figure 4-84). The wall of the main stomach is stratified and usually thicker than that of the fore stomach. The mucosa is usually dark red (Figure 4-85). The pyloric stomach tends to be thin walled, glandular, and the mucosa is pink or stained with bile. Look for ulcers, areas of discoloration and other abnormalities. Weigh the stomach empty. Sample each compartment for histology.

Figure 4-84. Mucosa of the fore stomach

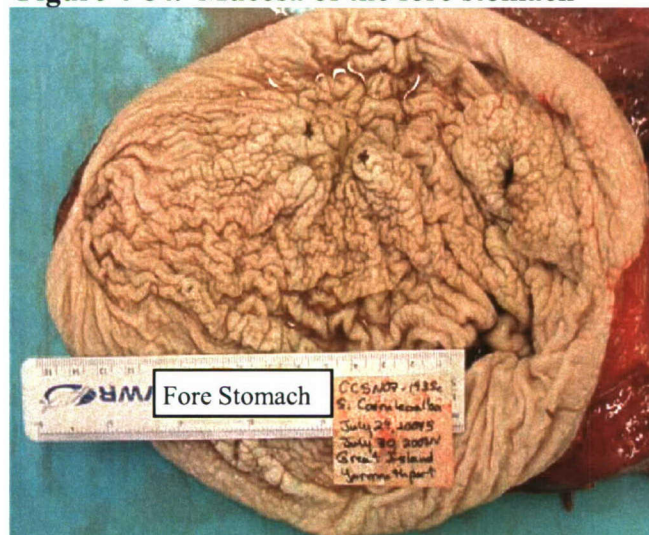
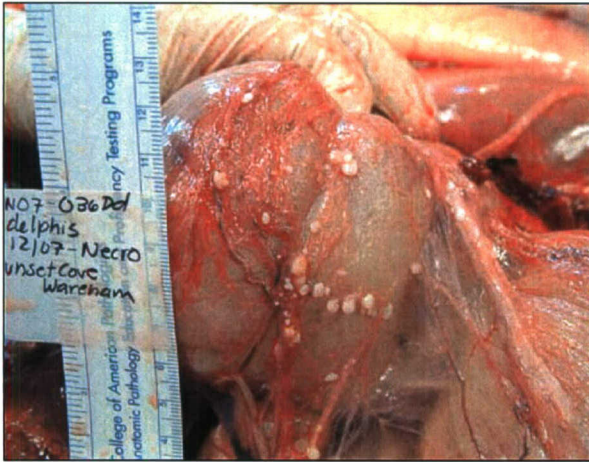


Figure 4-85. Mucosa of the main stomach

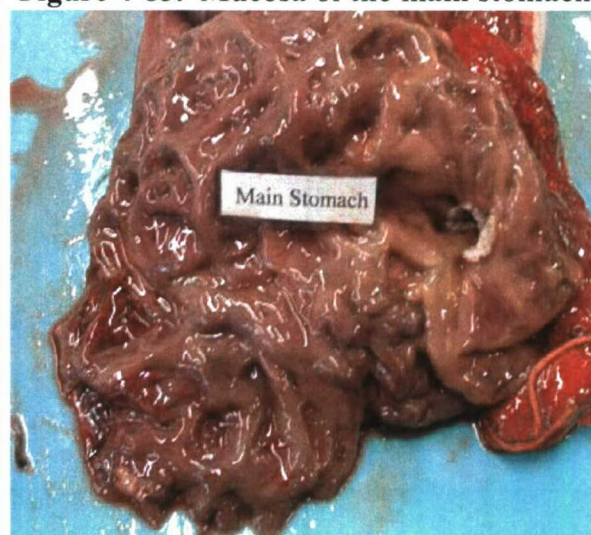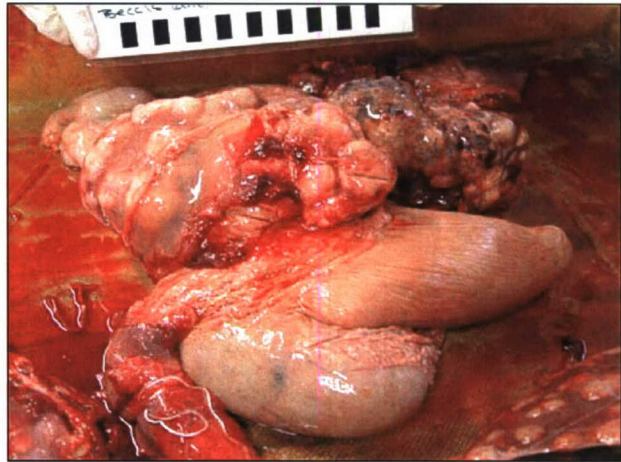


Figure 4-86. Gross Description: Multifocal 0.1-0.3cm circular, white, firm attachments on the major vessels of the omentum.



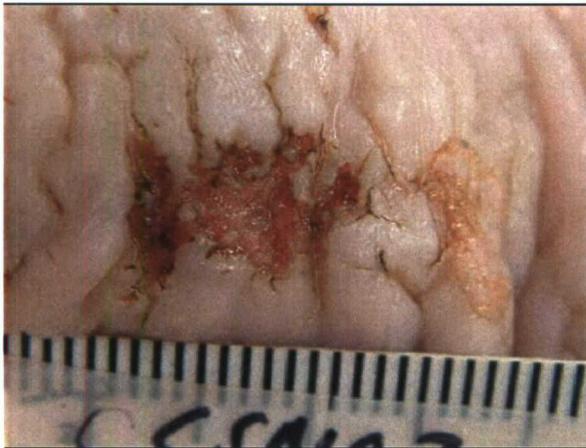Morphologic Diagnosis: Unclear, but consider encysted parasites or granulomas

Figure 4-87. Gross Description: Firm, cream colored nodules varying in size adhered to the omentum and covering the stomach.



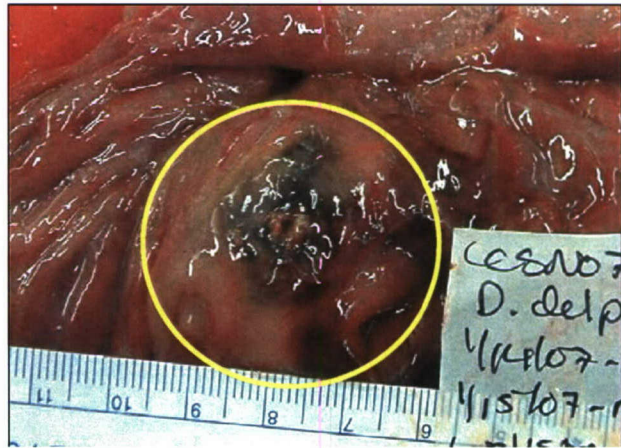
Morphologic Diagnosis: *Gastric and omental lymphosarcoma.

Figure 4-88. Gross Description: Approximately 1.0cm, irregular edged, granulated, depressed, red, ulceration of the fore stomach mucosa.



Morphologic Diagnosis: Chronic stomach ulcer.

Figure 4-89. Gross Description: Large (3.5cm), circular, gray-black ulcer of the main stomach mucosa with a marked depressed center penetrating the mucosa and submucosa of the main stomach.



Morphologic Diagnosis: Stomach ulcer with associated necrosis and hemorrhage.

Esophagus:

Trace the esophagus from the exposed caudal end to the mouth, opening the esophagus in the same manner as done with the trachea. Observe the serosal and mucosal surfaces of the esophagus. Note, color, texture, and contents. Sample for histology.

Small intestine:

Examination of the intestines is preferably left until the end of the necropsy so as to not contaminate the other organs. Examine the serosal surface of the small intestine first. Look for areas of hemorrhage or discoloration as well as parasites. The inside of the small intestine can be examined by spot checking: at 5 – 10 random, separate areas, using scissors to cut about 10.0 cm down the length of the lumen. Note color, consistency and amount of contents as well as thickness of the lumen and the texture and color of the mucosa. Sample several sections for histology.

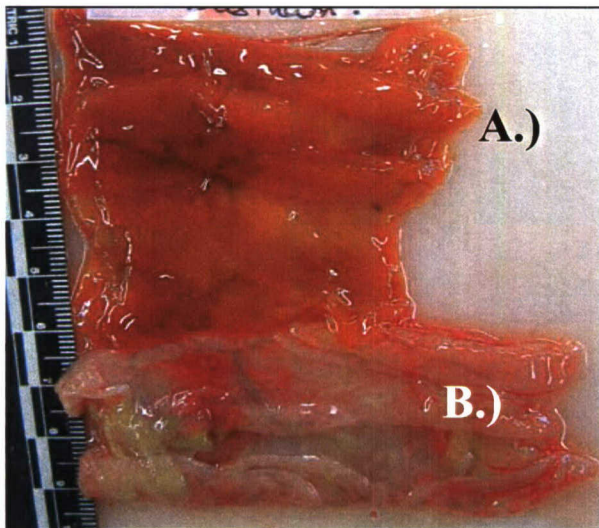
Large intestine:

To locate the beginning of the large intestine, look for the ileo-ceco-colic junction, which usually is a ridged junction between the smaller diameter small intestine and the larger diameter large intestine. The large intestine can be examined in the same manner as the small intestine. Note any discoloration or the presence of parasites. Describe the color, consistency and amounts of contents. Note the thickness of the lumen as well as texture and color of the mucosa. Sample for histology.

Colon:

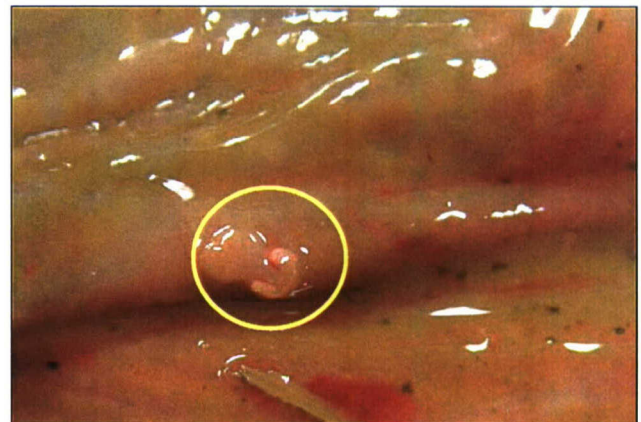
Examine the serosal surface of the colon for areas of discoloration. Cut through the lumen of the colon from the anus to the large intestine. Describe the color, consistency and amount of contents. Note the thickness of the lumen as well as texture and color of the mucosa. Sample for histology. Collect feces for biotoxins analysis.

Figure 4-90. Gross Description: Mucosa of top intestinal section is thick and yellow to dark orange (A); mucosa of lower section is light pink with scant amount of yellow mucoid material (B).



Morphologic Diagnosis: (A) Enteritis; (B) Normal mucosa.

Figure 4-91. Gross Description: Small (0.3cm), white, flat, thorny head worm attached to the mucosal surface of the intestine.



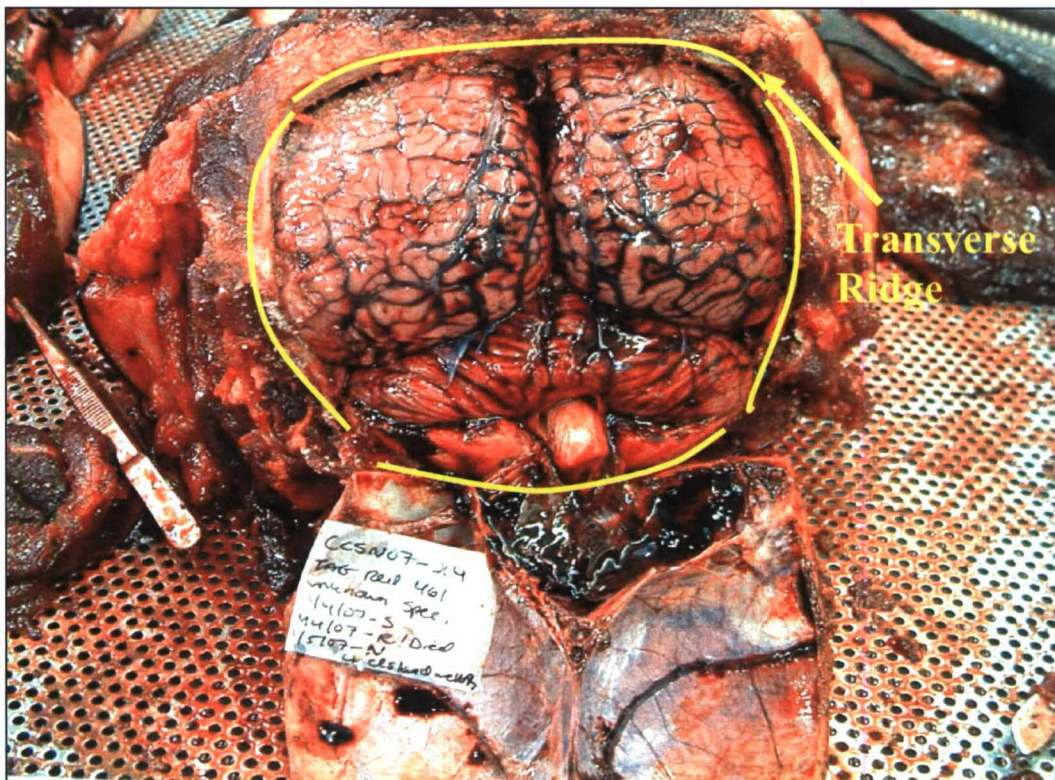
Etiology: *Acanthocephalan* sp.

Removal of the Brain:

The brain is the most fragile and easily disrupted tissue in the entire body, thus extreme care must be taken when removing the brain from the skull. Before removing the head, cerebrospinal fluid (CSF) can be collected for cytology and culture. To do so, remove the overlying soft tissue at the back of the head and neck to gain access to the atlanto-occipital joint. Insert a sterile needle and syringe and collect the clear, viscous CSF.

First the head must be detached from the body to safely remove the brain. Do so by cutting behind the blowhole down to the joint between the skull and cervical vertebrae, and then completing the cut ventrally. Once separated, remove all excess skin, blubber, muscle and connective tissue from around the dorsal and caudal skull. Then, using a Stryker saw or a hacksaw, make cuts from left to right through the middle of each occipital condyle, up each side of the lateral skull, and then across the dorsum, just posterior to the marked transverse ridge at the apex of the skull (Figure 4-92). Be sure to fully penetrate the bone, but avoid contact with the brain. This can be very difficult, so proceed with caution. It will take some practice to successfully remove the cranium without penetrating the brain. Carefully place a chisel between the cut bone and turn the tool to crack the remaining bone until the back of the skull comes away in one piece (Figure 4-92). Be careful to pull it off evenly, without using one edge as a lever, otherwise the bony shelf (the tentorium cerebellae) that is positioned between parts of the brain will penetrate the tissue and damage the brain. Using fingers, gently tease the meninges (thin membranes enveloping the brain) away from the skull, and work under the brain to sever each cranial nerve. Inversion of the head often allows the brain to gently descend in to the palm of your hand.

Figure 4-92. Dorsal aspect of the skull has been removed to expose the brain. Note: Vascular congestion of meninges.



Examination of the Brain:

Again, the brain is the most delicate tissue in the body and will fall apart if handled excessively. Observe the external surface of the brain and note symmetry of each distinct structure (right and left cerebral hemispheres, cerebellum, and brain stem) (Figure 4-93) while noting the color, texture, and presence of worms or lesions. Vascular congestion can be a result of positioning or post mortem lividity. Cut through the brain in one long motion, cranial to caudal, using a large, thin knife so that the two hemispheres evenly separate. Again, note symmetry, color, texture and the presence of worms or lesions. Each section of the brain has a distinct pattern (Figure 4-94). The cerebrum is comprised of two distinct lobes and is the most cranial section of the brain. The cerebellum is the most caudal portion and sits dorsal to the brain stem. The brain stem originates from the ventral midline of the brain and extends into the spinal cord. Sample the cerebrum, cerebellum, and spinal cord for microbiology, molecular and ancillary investigations. Fix the remaining brain tissue for histology. It is important to include a sample of normal and abnormal meninges in the histology sample set.

Figure 4-93. Brain is removed from carcass to view structures.

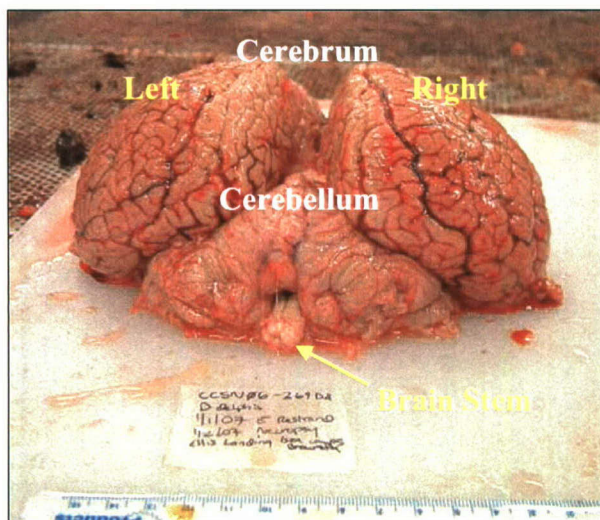


Figure 4-94. Structures of the brain upon cut section.

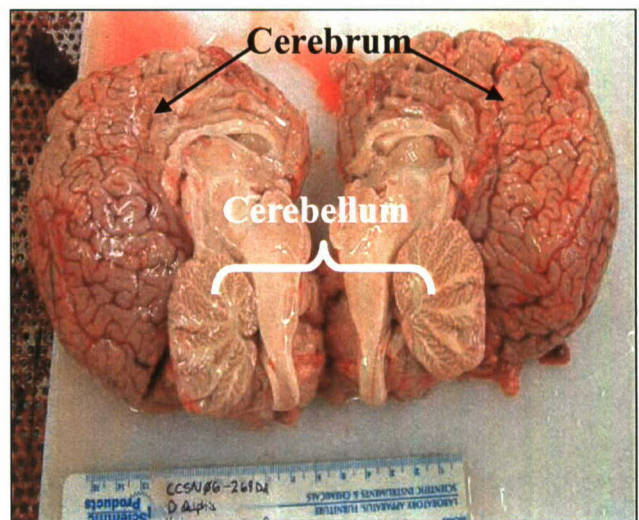


Figure 4-95.

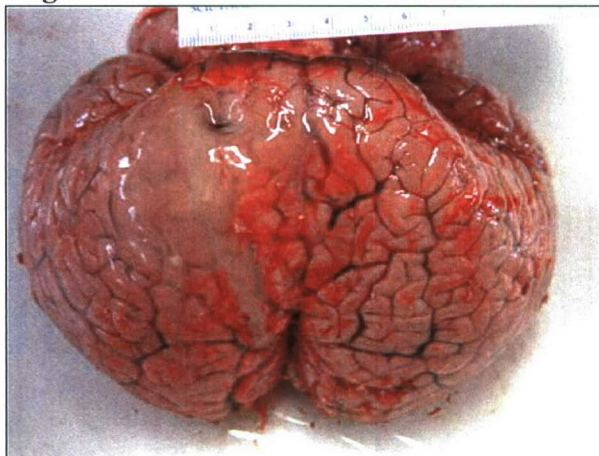
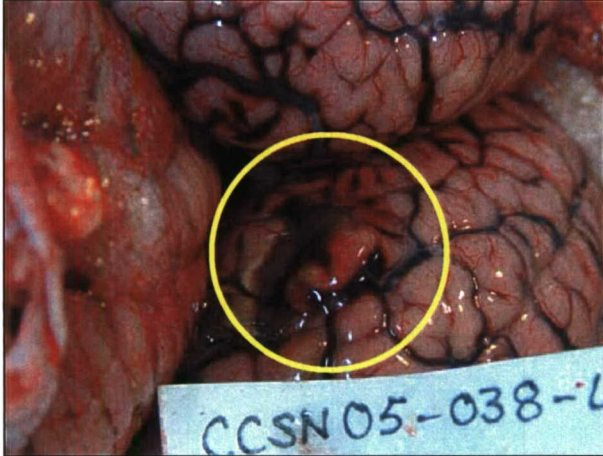


Figure 4-95. Gross Description: Brown, necrotic 2.0cm depression of the left frontal lobe with tan fibrino-purulent exudates.

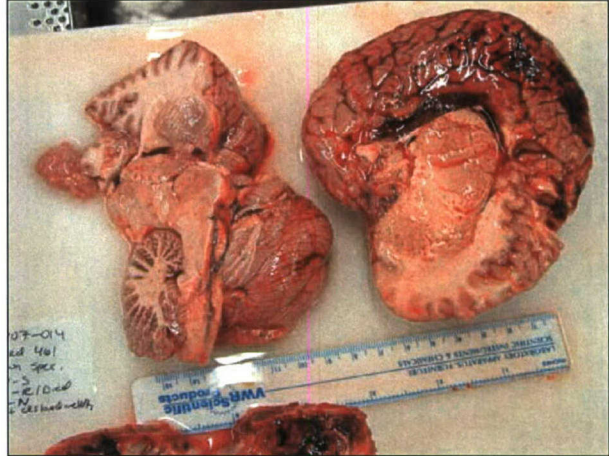
Morphologic Diagnosis: *Parasitic abscessation.

Figure 4-96. Gross Description: Brown/black lesion with clear exudates penetrating the brain parenchyma of the right occipital lobe proximal to the hemispheric division and apex of the cerebellum.



Morphologic Diagnosis: *Necrotizing encephalitis with parasitic tract formation.

Figure 4-97. Gross Description: Meninges and folia of the cerebellum are dark red.



Morphologic Diagnosis: *Mild, chronic meningoencephalitis and peracute hemorrhage.

Pituitary Gland:

Once the brain has been removed, immediately under the crossover of the optic nerve, the usually small pituitary gland can be extracted after incision through the overlying dura. The organ is within a bony recess and has to be lifted out using a scalpel blade and small forceps. Sample for histology and other priority testing.

Ear Extraction:

After removal of the brain, the middle and inner ear complex can be removed and preserved as appropriate. Detailed protocols for this procedure can be found in Ketten *et al* (2007).

This page intentionally left blank.

- SECTION FIVE -

Large Whale Examination and Necropsy

On-Shore Necropsy

Planning and Logistics:

A large whale necropsy event requires substantial coordination and rapid planning, as each event is unique and presents different constraints. However, they are all driven by the same basic issues: location/relocation, towing, landing, case history, examination, sampling, sample analysis, reporting and most pressing of all, waste disposal. The extent to which these are all possible depend on the availability of funds, which in turn is dictated by the pressure to obtain quality information. Thus, one's ability to work up a right whale carcass usually exceeds that of a less endangered species.

Logistical planning begins with the first report of the carcass. It is important to keep a detailed phone log of every call received or made throughout the large whale stranding event. Information on the log should include date and time of conversation as well as the person's name, affiliation, and contact number. For floating carcasses still at sea, a printed map of the initial location and weather predictions for the following few days should be on hand until the carcass is finally landed.

For all large whale necropsies, there is a significant amount of advanced planning that must be completed. It is essential to have these elements secured before beginning the necropsy:

Necropsy Site Location:

In most cases, large whale carcasses wash ashore and necropsies can be conducted on-site. Often, on both state, federal, and privately owned properties, the land owners/authorities are eager to remove the carcass and are thus very cooperative in facilitating the necropsy and disposal.

For carcasses found floating at sea and towed to shore or stranded at a site that prohibits a necropsy, it may be necessary to transport the carcass over land to a suitable necropsy site. Towing floating carcasses into large marinas with travel-lifts is the best way to facilitate transport. Travel-lifts permit fairly easy transfer of the carcass from the water into a truck. Land transport using a flatbed truck is reasonable, but it is preferable and cleaner to use large dump-trailer (when carcass size can be accommodated). This helps contain the carcass and any run-off during transport and, once at the new site, it can easily be slid out of the container.

Disposal:

Once a necropsy site is determined, the next step is to establish a disposal plan. Disposal ultimately drives the entire necropsy event, as without a disposal plan the event should not begin. Do not commit to a necropsy (even hooking up to a tow) until you are satisfied that the disposal plan is viable and appropriate, or that the necessary people are informed so that a plan will emerge in

time. Only your experience with the locality and participants determine this. Obviously, if the animal is already beached then the landowner is much more willing to work with you to make such a plan a reality.

Disposal options include:

Surface Decay: Realistically, this is rarely a viable option with land owners and local agencies. However, if the necropsy was conducted on a remote beach and burial is not practical, the fastest decay is achieved by leaving the carcass open for maggots and other scavengers. Be sure to obtain good images of the state of the carcass as left at the site. Thus, if a storm washes it offshore and it is found floating or stranded on a new beach, it will be identifiable. It is vital to be able to recognize carcasses that have already been worked up.

Beach burial: Where the ecology and human use of the beach allows, beach burial is the most affordable and easiest action. This should be done away from water supply and other environmentally sensitive areas. This option allows the leachate to flush out to sea, and avoids extensive transport costs. A suitable backhoe, excavator, or other heavy equipment is required. Ideally, a hole is dug beside the carcass and as flesh and blubber are stripped off they are examined, sampled and pushed in to the hole. The hole is then backfilled. Attempt to dig such holes away from likely tracks of future vehicles. If a museum is likely to want the skeleton, it is best that the bones are collected immediately. Bones left on a beach are likely to be stolen overnight. If the interested person is not able to collect the bones right away, rather within 24 - 48 hours, using a machine to cover them with large pieces of soft tissue waste has proven an adequate deterrent. If the bones will be collected much later, take careful note of the exact location, using a map, GPS, triangulated landmark sightlines and a buried piece of metal to enable later use of a metal detector.

Offshore dumping: If the material can be loaded on a barge and dumped offshore, this is a good plan, as long as the risk of the material washing ashore again is minimal. Legally you have to be at least 12 miles offshore, but in all likelihood a greater distance will be required to ensure tissues will not float ashore again. The local currents and tides will dictate exactly how far and where to go. In addition, NOAA fisheries, the Environmental Protection Agency, and the US Coast Guard (USGS) will likely need to approve of such a plan.

Land filling: Often, landfills are the optimal (or only) option. Some landfills may not accept whale carcasses or necropsy waste. To be environmentally sound, only lined landfills should be used. The impact of a whole carcass or just necropsy waste deposited at landfills must also be well planned and the associated costs considered. Note: for floating carcasses towed ashore, landfills can also be the best necropsy site as well.

Composting: there is a growing movement, with the demise of the livestock rendering industry, to compost livestock waste. Protocols for marine mammals are still under development, but the general principles can be obtained from the following website: <http://cwmi.css.cornell.edu/> and specifically <http://compost.css.cornell.edu/naturalrenderingFS.pdf>

Team Member Roles:

Once necropsy personnel are assembled, hold a group meeting to assign roles, discuss safety, personal protective clothing (boots, foul weather gear with duct taped cuffs, safety glasses and

double gloves) and outline the goals for the event, along with pertinent known case history.

Large whale events require a number of key personnel:

Off-Site coordinator – Serves to streamline communications among the responsible agencies, solve logistical issues, and coordinate the general process.

On-Site Coordinator – Arranges logistics for landing site, beach equipment, disposal and necropsy crew. Assists with sample dissemination and tracking.

Necropsy Team Leader – Manages the necropsy crew, gathers all available data with the help of the scribe, supervises direct sample submission and analysis, collates and pursues data, drafts and completes a full gross necropsy report. Ultimately responsible, along with the On-Site Coordinator, for human safety and environmental protection of the site. Although ideally there should be a separate individual overseeing all safety issues.

Photographer – Records the subject of the filename of each image. Photograph all external and internal abnormalities. Ideally, sections of all lesions should be photographed prior to preservation. Such images should bear an identifying number or letter in the image that relates to the sample ID, and the necropsy record. Maintains a log of all images. Ideally, images are cross referenced by the same letter or number shown in the image and on the sample tag.

Cutting crews – Crew of 2-3 – a cutter, a hooker and a spotter to watch for safety issues with other crew members and run samples to the sampling team. Each crew disassembles different aspects of the animal – such as head, thorax and abdomen, communicating continuously with the team leader, the photographer and the scribe.

Sampling team – Crew of 2-3- Receives samples from cutting crews. Dictate notes to scribe regarding all samples. Follow proper sampling and labeling protocols for all samples (genetics, life history, contaminants, biotoxins, *etc.*).

Scribe – Records all gross necropsy observations, prompts necropsy cutting crews for information on each organ system as exposed. Records descriptions of samples from sampling team.

Floating Carcass:


The investigation of large whale mortalities is often important enough that carcasses found floating at sea warrant an examination. Conduct as complete an external examination as possible before handling or moving the carcass. This will help to differentiate existing marks and possible human interaction from the marks resulting from the towing, landing, and transporting of the carcass. Furthermore, these will be the “freshest” photos of the carcass and in most cases are critical in the final diagnosis. The image below (Figure 5-1) was taken at sea and was critical to the final diagnosis.

Relocation:

Cases at sea are usually initially reported by aerial surveys, ships or the USCG. Often, it takes hours or days to organize a response. In these cases, drift models can be consulted to predict the likely position at the time of attempted relocation. However, such models are not always 100% accurate. Thus, search patterns should start close to the last known position and head downwind from there, crossing the likely line of drift perpendicularly if possible, to maximize the chance of encountering the oil slick emanating from the carcass. Such slicks are often miles in length and may be populated with sharks. Birds often mark the carcass. Tides are usually of little net impact if more than 12 hours have elapsed, but if there is

a persistent current, this too should be factored into the analysis. Once the carcass is re-sighted, be sure to obtain images of the external condition of the carcass prior to initiating a response. These images will serve to document any changes since the animal was first sighted. In addition, they can be transmitted back to the Off-site Coordinator and other authorities to aid in determining the best course of action. The extent of decomposition and scavenger damage will affect possible examination options (towing to shore vs. at sea exam). Very decomposed, deflated carcasses are likely to fall apart when towed and will yield only limited information. Intact carcasses, often still bloated, are more likely to withstand the strain of the tow and make it to shore, yielding greater results.

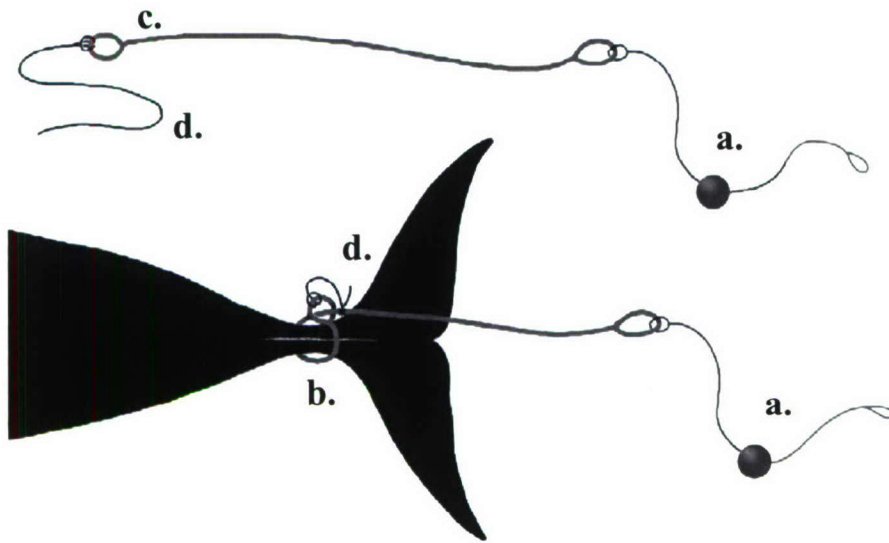
Figure 5-1. Line impressions around the peduncle of a large whale carcass at sea.

**Towing:**

It is always preferable to bring a carcass ashore, if feasible, to conduct a complete and thorough necropsy. If the carcass is in good enough condition to be towed (intact, not completely deflated), one must assess the logistical considerations of towing—distance from shore, appropriate landing site, disposal plan, *etc.* Once all elements of the plan are established, proceed with towing.

As a rule of thumb, the vessel should be significantly longer in length than the whale to be towed. A towing bridle makes hooking up to a carcass much easier (Figure 5-2). Using a boathook, push the float ball (a) under the narrowest part of the tail (b) until it floats up the other side of the whale. Pass the float and line it is attached to through the eye splice on the opposite end of the heavy line (c). Cinch it tight. Use the short rope tail (d) on that splice to tie the splice to the heavy line that passes through it to ensure that the bridle does not slip off the whale when no tension is applied. Use the smaller line with the float (a) attached to catch the line when hooking up a tow line to the larger rope. Alternatively, a sinking line with a weight attached can be thrown over the upstream side of the peduncle, the whale will then drift in to this line making it stream out below and behind the moving carcass, allowing one to catch the line with a boathook and draw it up to encircle the peduncle.

Figure 5-2.



Drawing by Scott Landry, Provincetown Center for Coastal Studies

Landing:

The amount of power required to haul the carcass up and onto land/beach depends on the nature of the site, and the size of the whale (Figure 5-3). In order of increasing friction we have found that the easiest to hardest surfaces are as follows: wet slab rock such as basalt, cobble, slick mud, gravel, sand. If the necropsy site is on a dock or paved area or if the site is away from the landing area requiring transport, a crane or boat hoist (travel-lift) is a good option for moving the carcass onto the dock or into the transport truck. For landing carcasses in beaches, track laying machines are better than wheeled. Adequate heavy rope is critical for dragging the carcass above the high tide line. Ropes, chains or cables of 90 ton breaking strain are not unreasonable. Be extremely careful to keep bystanders out of any possible zones of influence of recoiling broken lines and cables.



Figure 5-3. Equipment required to move a decapitated right whale up a sandy beach.

Necropsy:

For the full necropsy examination of a large whale carcass, whether beached or landed, the primary aspects of the process are the same. The process for performing a necropsy on a large whale is covered in great detail, with excellent data sheets, in the Right Whale Necropsy Protocol (McLellan et al, 2004), which can be easily adapted for other species. Outlined below is a brief overview of the key aspects.

Case History:

Be sure to obtain a full history of the carcass. Inquire of all relevant on-site and off-site personnel for all data concerning first sighting, location, timing, known life history, and post-mortem handling to maximize understanding of the carcass as it is now. Be sure to ask about any rope that has been tied to or removed from the carcass post mortem (in the process of towing, landing or manipulating the carcass).

Site Safety:

Before beginning the necropsy, as stated previously, all on-site personnel should meet and be briefed on the plan for the necropsy and other important issues, especially safety. There are many dangers on-site, including, but not limited to: working around large equipment, large knives, use of chemicals, the movement of large pieces of tissue, and often uneven substrate, weather, and other environmental concerns. All personnel should have proper personal protective equipment for their role. When possible, one individual should be named as the Safety Officer to monitor the scene. All personnel should sign into the scene when they arrive and sign out when leaving. Discuss the importance of keeping track of all tools, and never leaving knives or hooks resting in a carcass. All injuries should be reported immediately to the on-site coordinator.

External Examination:

Once the animal is at the necropsy site, make another careful assessment of the external condition, noting swellings, scars, lacerations, contusions and other lesions. Take many photos of noted abnormalities. Liaise with the relevant catalog holders to ensure the right images are acquired. For instance a right whale needs images of all callosities, scars, flukes, and flippers. Humpbacks require ventral fluke images. Ensure images are taken of all aspects that will assist with photo-identification of the individual as well as record the standard suite of measurements. This can often be done while the necropsy crew is assembling. The initial process is much like that for small cetaceans: 1) Photos and video; 2) Human interaction evaluation; 3) Morphometrics; 4) Blubber thickness.

Internal Gross Examination:

The most dangerous aspect of this is the first incision. Be sure to have the crew stand back while one experienced cutter decompresses the abdomen and thorax with a careful, iterative incision to avoid any explosive decompression event. Remove the blubber in circumferential slabs, allowing blubber thickness to be measured on the blubber that remains on the carcass. Note all areas of hemorrhage, edema, swelling and abscessation. Look for focal changes in color pattern and texture. Patterns of change that are widespread and uniform are often post mortem in nature. Take histology samples of all identifiable as well as suspect tissues – they can always be discarded later, but cannot be retrieved once buried or disposed. Have multiple individuals examine as much of the carcass as possible. Many eyes see different things. Proceed logically through the carcass using the gross necropsy report form as a prompt to ensure all organ systems are examined. Follow the same organ by organ process as described for small cetaceans.

Sample preparation and analysis: See Section 2: Sample Management

Report Preparation: See Appendix A.

At Sea Examination of Whale Carcasses

Where distance offshore, cost, carcass condition or other factors preclude towing a large whale carcass to shore for examination, there is some benefit to the limited examination that can be undertaken at sea in certain situations. Such events need careful coordination and rarely succeed unless the carcass has been satellite or VHF tagged, or aerial support is available on the day of the attempt, as relocation of the carcass can often be difficult.

Necropsy Logistics:

The following approaches have been used by members of the North East Region Stranding Network for the examination of large whales at sea. Prior to leaving shore all necessary equipment should be packed and accessible.

Documentation:

Slowly circle the carcass to obtain images (photograph and video). Observe and note the degree of scavenging and extent of decomposition. Note body condition (robust, emaciated, *etc.*). Try to obtain photos of the fluke if possible (specifically the trailing edge and the ventral surface) and other species-specific aspects suitable for photo ID (dorsal fin, callosities, scars, *etc.*). Any and all media are appropriate and every effort should be made to document the animal using multiple media: digital still photos, 35mm photos, and video.

Be sure to examine the carcass for evidence of human interaction (entanglement marks, scars, ship strike, *etc.*). Fully document any suspected evidence using digital, video, and still photos. Sample any areas of possible or suspected HI for histology whenever possible.

Next, measure the total length of the animal. This can be challenging at sea, as some of the carcass may be at depth (often the flukes hang down in the water column). As you approach the carcass, be aware of the likely presence of sharks. The length will not be the “standard length” as the carcass is belly-up, but one can obtain a reasonable estimate. To measure, lay the tape along carcass to obtain total length. If necessary, the tape can be “pinned” to one end to hold it in place while the tape is played out (forceps stuck through the end of the tape and into the blubber will accomplish this). Alternatively a large vessel can be laid alongside the whale and the position of the head and tail marked on the vessel at a moment in time and the distance measured.

In significant sea states, a partial external examination can be conducted using aerial and under-water pole cam video. Analysis of such material frame by frame later can reveal substantial information about rope marks, propeller wounds, lesions, *etc.*

Crew:

If using a small boat, a minimum of five people is ideal on the sampling boat: 1 boat operator, 2 “hookers” to hold boat to the carcass, 1 cutter, 1 sample handler/data recorder. Usually one of the “hookers” can use a free hand to pass sample collection jars to the cutter and also pass tissue samples from the cutter to the sample handler to collect. Personnel on the large support vessel should serve as observers, documenters, and shark spotters.

Sampling:

Where there is essentially no sea state, or at worst a long swell, it has been possible to obtain internal samples to a limited degree from free-floating large whale carcasses. Most carcasses present ventral side up, making access to tissues feasible. Some are heavily shark scavenged from underneath, but often the viscera are still intact. Dissection is best done with an extra long-handled flensing knife. Carcasses can be worked from moderate sized ships (assuming a platform close enough to the water), or smaller boats. If possible, secure lines around the flipper and tail stock to lash the vessel alongside the whale (be sure to carry a safety knife with you to sever these lines if necessary). If attaching lines is not possible, two persons each with a whale hook on either end of the vessel (bow and stern) can hold the whale and vessel together if the vessel is small.

The animal should be opened up with a long cut along the mid ventral line from sternum to anus. Make an initial exploratory cut to determine the level of gas build-up inside the animal prior to proceeding with the ventral midline incision. The underlying organs emerge much more readily if the cut is truly mid line. Samples can be obtained from the colon, bladder, small intestine and stomach in addition to skin, muscle, and blubber. Obviously this is in no way a complete necropsy, but it will allow analysis for biotoxins, contaminants, *etc.* Large whales are quite broad, making sample collection from a boat alongside very challenging, as most of the organs of interest are in the midline. Given the significant risk of unexpected shark attack, getting out of the vessel is not recommended, so do what can be done using long handled knives, hooks, bailers, and suction devices from a stable vessel platform. Do NOT stand on the carcass at any time.

Sampling Preparation:

Pre-label a set of bags, Nalgene jars and vials to take to the carcass for initial sample collection (See attached sample collection guide). Small tubes and jars can be used as bailers once an organ has been opened. Where intestinal contents are scant, a large knife can be used as a scraper to remove contents adherent to the mucosa. A large turkey baster can also be useful in obtaining samples from stomach, colon, bladder, *etc.*

Sample collection:

1. If possible, collect a **blood** sample into a red top blood tube. This can be done on male carcasses by severing the penis and collecting a sample as it bleeds out. In females (and males from which blood cannot be collected from the penis) blood can be collected from the flukes, behind the eye, or snout.

2. Collect a **skin** sample. The carcasses tend to be fairly decomposed and often desiccated. The skin is usually peeling off. Try to collect a sample that is in good condition (e.g., not crispy). Place it in a whirl pack.
3. Collect a **blubber** sample (approx. 10x10x5cm), store in whirl pack.
4. If access permits, incise region at and forward of genital slit. Collect a **muscle** sample (approx. 10x10x5cm) and place it in a whirl pack. The bladder should be a white fibrous bag immediately under the blubber/ muscle coat. Incise bladder and bail out available **urine** with a centrifuge tube, turkey baster or syringe. Place in a centrifuge tube for storage. Collect 2 tubes if possible.
5. Beneath the bladder the colon will be a white tubular structure. Incise the wall and remove available contents (**feces**). They are usually pasty green and the consistency of toothpaste. If possible, use a Nalgene bottle for both collection and storage. You may need to use your knife to scrape the inside of the colon to extract feces.
6. Continue incision cranially along the ventral midline to the sternum, making lateral cuts if need be, to allow the body wall to fall away. Scoop up the largest chambers (stomach) that are evident behind the liver (if visible). Incise and sample **stomach contents** if present. (Use a Nalgene bottle to collect the samples or scoop them out with a knife, then store in the Nalgene bottle). Sample **liver** if intact: approx. 10x10x5cm in a whirl pack.
7. The kidneys lie along each side of the body wall in the abdominal cavity. If visible, collect a sample of one **kidney** (approx. 10x10x5cm), place in a whirl pack.
8. If possible collect an eye and store in a Ziploc bag.
9. If any evidence of human interaction was noted during carcass examination, sample appropriate tissue if possible. Store frozen or in formalin as appropriate.

Sample processing and storage:

1. Once back onboard the main vessel, process samples immediately.
2. Bagged samples: prepare a second set of bags with full labels to double bag samples. This reduces mess and provides a second label. (Remove blubber, liver, and kidney samples from original bag, wrap in acetone-washed aluminum foil, and place back in original bag before double bagging.) To ensure identification of tissues, an ID tag bag can be placed within the sample bag with the actual tissue. Please refer to the sample management section of this manual for details.
3. Skin sample: cut small pieces of skin and place in DMSO vials before double bagging the remaining sample.
4. Jars and vials: wipe down outside of each container. Fill out a Tyvek tag and tape to outside of container using clear packing tape. Be sure not to cover the existing info on the label tape.

5. Be sure to fully clean all gear between whales to avoid cross contamination. Use new scalpel blades for each animal's skin samples and use a clean cutting surface.

Quick Sample Collection Guide

Sample collection can be guided by the steps outlined in the Section 2: Sample Management of this manual. However, sampling from large whales is slightly different and decomposition makes collection difficult. The following is a brief outline of samples to collect and method of storage as described above. (Note: **BOLD** face indicates priority sampling)

Collect in whirl packs or Ziploc bags: **Skin**, blubber, muscle, liver, kidney, eye.

Collect in Nalgene jars or centrifuge tubes: **Urine, feces, stomach contents**

Collect in red top tubes: **Blood**

Appendix A. Blank Gross Necropsy Report



Necropsy Examination Report

CCSN# ____ - ____
Tag color/# ____
Species ____

Event Info

Strand date: ____
Recovery date: ____
Euthanized / Died
Date & TOD: ____
Necro date & time: ____
Storage prior to necropsy: ____
Stranding location: ____

Lat/Long: ____ N/ ____ W

Animal Info

Sex: M F CBD
Length: ____ cm / in / ft
Weight: ____ lbs / Kg
Pup / Calf / YOY / Sub-adult / Adult / CBD
Condition at Stranding: 1 2 3 4 5 6
Condition at Necropsy: 1 2 3 4 5 6
Human Interaction: Yes / No / CBD / NE
Mass Stranding: Yes / No
animals: ____

Necropsy Summary – Differential diagnosis from gross exam:

History

Necropsy Observations: Please note general observations of color, condition, textures, etc. even when utilizing NA= not applicable, NE= not examined, NSF= no significant findings, NVL= no visible lesions. List weights (g) next to each organ examined.

External Exam

Body Condition: robust thin emaciated CBD

Skin/Hair coat (color, condition):



Necropsy Examination Report

CCSN# ____ - ____
Tag color/# ____
Species ____

Wounds/scars:

Lesions:

Parasites:

Nostrils/Blowhole:

Mouth (tongue, teeth condition, ulcers)/ /Mucous membranes (color):

Eyes (discharge, color, ruptures): (R) (L)

Ears: (R) (L)

Genital slit/anus:

Umbilicus: Pink Open Healed

Musculo/Skeletal System

Blubber:



Necropsy Examination Report

CCSN# ____ - ____

Tag color/# ____

Species ____

Muscle:

Diaphragm:

Skeletal:

Circulatory System

Pericardium:

Heart:

Vessels:

Pulmonary System

Trachea:

Bronchi:

Lungs (color, condition, edema, congestion, consolidation, granulomas, emphysema, lesions):

(R)

(L)



Necropsy Examination Report

CCSN# ____ - ____
Tag color/# ____
Species ____

Tracheobronchial Lymph:

Gastro Intestinal System

Esophagus:

Stomach (contents, ulcers, mucosa, parasites):

Small Intestine:

Large Intestine:

Colon:

Peritoneum, mesentery, omentum:

Liver (color, congestion, lesions, size):

Gall Bladder/ Bile Duct/ Pancreaticoduodenal duct (color, amount):

Pancreas:

Associated Lymph:



Necropsy Examination Report

CCSN# _____ - _____
Tag color/# _____
Species _____

Urinary/Reproductive Systems

Kidneys (reniculi differentiation, color, condition):
(R)

(L)

Bladder:

Testes / Ovaries: Immature / Mature

(R)

Lx W x H cm:

(L)

Lx W x H cm:

Mammary glands:

Uterus/ Cervix/ Vagina:

Pregnant? : Y / N / NA (male) / CBD

Lymphatic System

Spleen:

Scapular Lymph node:

Mesenteric Lymph node:



Necropsy Examination Report

CCSN# _____ - _____

Tag color/# _____

Species _____

Other Lymph (list location):

Endocrine System

Adrenals:

(R)

Lx W x H cm:

(L)

Lx W x H cm:

Other:

CNS

Spinal cord:

Brain:

Pterygoid Sinuses:

Other

Peritoneal cavity:

Abdominal cavity:

Thoracic cavity:

Thyroid:

Internal Parasites (location, type, #)



Necropsy Examination Report

CCSN# ____ - ____

Tag color/# ____

Species ____

SUMMARY- Differential Diagnosis from Gross Exam:

CARCASS DISPOSITION:

Soft tissue:

Skeleton:

PROSECTORS (list names and primary prosector signature)

SAMPLES/Disposition

See attached list

PHOTOS/VIDEO

Camera

Roll#

Frames:

Description:

ASSOCIATED DATA SHEETS

- ☐ NMFS Data Report
- ☐ Human Interaction Protocol
- ☐ Pinniped / Cetacean Data Record
- ☐ necropsy/ archive sample list

Researcher Sample Collection List

Researcher	Affiliation	Sample type	# of samples	Method of storage/location

Appendix B. Guidelines to Writing a Gross Necropsy Report.

The most important things to remember when writing a gross report are:

1. Describe what you see, smell, feel, and hear.
2. Do not worry too much about using all technical terms. Learning the language will come with time. Write it how you see it.
3. Provide a detailed, but concise, description of each individual organ. Record NVL (no visible lesions) or NSF (no significant findings) if no abnormalities are observed. Never leave a field blank.
4. Common objects may be used as analogies but should never stand alone. It is helpful to describe what you see first, followed by the analogy.
5. Be aware of the organs in relation to other tissues.
6. Describe both external and internal findings of each tissue.
7. Follow the report systematically to ensure that all organs are examined and described.
8. Be sure to write the summary of gross findings or morphological diagnosis **immediately** after the conclusion of the necropsy while the details are still fresh in your mind.

With these criteria considered, the necropsy report should enable the pathologist to identify the pathologic process and connect multiple gross conditions to accurately diagnose a cause of death.

The following list of questions and answers have been provided to assist with describing abnormal lesions found grossly:

Where is it? Dorsal, ventral, lateral, medial, proximal, distal, cranial, caudal, anterior, posterior.

What is the distribution? Diffuse, disseminated, focally extensive, multifocal, coalescing, segmental, transmural

How big is it? Give dimensions in cm (length x width x height) and estimate volume in mls or ccs.

What is the shape? Round, spherical, ovoid, crescent, nodular, conical, lobular, tortuous, discoid, bulbous, sessile, stellate, reticular, fusiform, irregular, loculated, branched, amorphous

What does it feel like? Wet, dry, tacky, hard, firm, soft, friable, gas-filled, viscous, gelatinous, gritty, resilient, rubbery, granular, flaccid, depressed, raised, smooth, rough, nodular, grooved, crusted, spongy, thick, thin.

What color/ pattern is it? Mottled, patchy, mosaic, translucent, opaque, dark, pale, degree of demarcation, striated, primary colors, multicolored –list all

To what extent is it affecting the tissue? < 10, dozens to hundreds, % of tissue

Is it odorous? Strong or faint smell, ammonia-like.

Appendix C. Human Interaction Evaluation Form and Instructions.

PROTOCOL FOR EXAMINING MARINE MAMMALS FOR SIGNS OF HUMAN INTERACTION

Exam Information (fill in or circle most appropriate)

- 1 Field #: _____ Species: _____
- 2 Examiner: _____ Recorder: _____
- 3 Date of exam: _____ Condition code (at exam): 1 2 3 4 5 CBD
- 4 Preservation: alive fresh frozen frozen/thawed Body condition: emaciated not emaciated CBD
- 5 Documentation: digital print slide video Image disposition: _____
- 6 Integument: normal abnormal decomposed % Skin missing: <10% 10-25% 25-50% >50%

- 7 Explanation of terms:
 YES = I have examined the area and found signs of human interaction
 NO = I have examined the area did not find signs of human interaction
 CBD = I have examined the area and could not determine whether there were signs of human interaction (i.e. the part was missing, degraded, or signs were ambiguous)
 NE = I did not examine the area
 NA = this animal doesn't normally have that part (i.e. seals have no dorsal, dolphins have no rear flippers)

	WHOLE BODY EXAM	YES	NO	CBD	NE	NA	Image taken (Y or N)
8	Head/appendages removed (with instrument)					X	
9	Pelt removed (with instrument)					X	
10	Body sliced (with instrument)					X	
11	Gear/debris present on animal					X	
12	Gear retained (name & contact info in Comments)			X	X	X	X
13	External pathology (pox, tattoo lesion, abscess)					X	
14	Natural markings (scars, tooth rakes, unusual pigmentation)					X	
15	Other HI lesions (gaff, gunshot, propeller, healed HI)					X	

- 16 Predation/scavenger damage (circle all anatomical areas where damage hinders evaluation; numbers coincide with anatomical areas below): 17 18 19 20 21 22 23 24 25 26 27 28 29 30 NONE

FILL IN TABLE FOR ALL POSSIBLE FINDINGS OF HI

FILL IN TABLE FOR ALL POSSIBLE FINDINGS OF HI											Origin of Lesion									
Do not fill in for natural markings/other lesions.						Type of Lesion				Gear						Other				
DETAILED EXAM OF ANATOMICAL AREAS	YES	NO	CBD	NE	NA	impression	laceration	abrasion	other	twine/line	net	unknown	monofilament	multifilament	unknown	propeller	other	CBD	image taken?	
rostrum/snout																				
mandible																				
head																				
R front appendage																				
R body																				
dorsum/dorsal fin																				
L front appendage																				
L Body																				
ventrum																				
peduncle																				
R rear appendage																				
L rear appendage																				
flukes/tail																				

Field #: _____

	INTERNAL EXAM	YES	NO	Partial	CBD	Image taken	Detailed Info (circle all that apply)
31	Internal exam conducted				X	X	Details in Comments section -use line number
32	Bruising/blunt trauma			X	X		Details in Comments section -use line number
33	Skeleton examined				X		Details in Comments section -use line number
34	Broken bones present			X	X		Associated tissue reaction: YES NO CBD
35	GI tract examined (circle contents)				X		intact prey partially digested hard parts only debris/gear empty other
36	Lungs/bronchi examined				X		Details in Comments section -use line number
37	Lung/bronchi contents			X			froth fluid air (color:)
38	Other pathologies noted			X			Details in Comments section -use line number

39 **Comments** (note line number from left margin before each comment):

40 **Signs of Human Interaction Observed:** YES NO CBD (transfer to Level A Datasheet)

41 **Stranding Event History/Circumstances:**

42 **FINAL HUMAN INTERACTION EVALUATION:** If you circled YES above (#40), evaluate the external exam, necropsy, caracss condition and circumstances surrounding the stranding event to answer the question below.

What is the likelihood that the observed signs human interaction contributed to the stranding event?

0: CBD 1: Improbable 2: Uncertain 3: Probable 4: Certain

43 **Justification:**



PROTOCOL FOR EVALUATING MARINE MAMMALS FOR SIGNS OF HUMAN INTERACTION



Introduction

Evaluating marine mammals for signs of human interaction requires consistent, objective examination by trained personnel. This document is meant to accompany formal training by experienced stranding network participants. This new protocol is divided into an objective data collection section and a more subjective final diagnosis. The primary goal of this protocol is to determine whether evidence of human interaction is present on the animal. The secondary, and more difficult, goal is to determine whether human activities contributed to the stranding event. A positive score for signs of human interaction results from an objective evaluation of an animal or carcass. This evaluation does not attempt to determine whether the signs of human interaction occurred before, during or after a stranding event and does not attempt to qualify the severity of the interaction.

The final, subjective human interaction evaluation takes into account the circumstances of the stranding event and the animal's physical condition. A high score indicates that human activities most likely caused the stranding. A low score indicates that although signs of human interaction are present, the likelihood that the interaction caused the stranding is very low. For example, old, healed, propeller scars on a known whale are unlikely to have caused a stranding during a domoic acid event and a dead dolphin calf covered by debris on a beach following a hurricane is unlikely to have died due to entanglement.

Determining the cause of death is not an objective of this protocol. Without further evaluation such as histopathology and review by veterinarians, pathologists and/or other experts, the exact reason for stranding and cause of death cannot be accurately determined.

Human interaction (HI) data illustrate where problems between marine mammals and humans occur. When collected carefully and consistently, these data can be used to describe the types of interaction taking place (e.g. monofilament net, multifilament net, small or large vessel interaction, ingestion of debris, etc.), thus providing a sound scientific basis for policy and management decisions. The nature of strandings makes it inadvisable to use human interaction data to estimate mortality or changes in the mortality rate due to human interaction.

Definitions

In order to effectively evaluate marine mammals for signs of human interaction, you must understand what you are looking for. Below are terms and explanations of data sheet sections:

For most of the sections, you must choose among the following answers:

- YES you have examined the area (*i.e.* left front appendage, or snout) and you found signs of human interaction
- NO you have examined the area (*i.e.* left front appendage, or snout) and you found NO signs of human interaction
- CBD (Could not Be Determined) which means either: (1) you have examined the area and could not determine whether the marks you saw were signs of human interaction, (2) you could not properly examine the area because it was degraded (scavenged, skin/pelt

*Document developed by CCSN and VAQS (9/2007) with funding from the
John H. Prescott Grant Program*

- missing, mangled, etc.), or (3) you could not examine the area because it was missing (removed, decomposed)
- NE you did not examine the area (an explanation as to why is often helpful – e.g. it was too dark; the animal was too large to roll over, etc.)
- NA this question is not applicable to this animal (e.g. it is a seal and doesn't have a dorsal fin, or it is a dolphin and doesn't have rear appendages)

Strategy for filling out the human interaction data sheet

Each new line on the data sheet is numbered in the left hand margin. These numbers serve two purposes: (1) each number corresponds to a section within these instructions with details about how to fill in that line; (2) the line numbers should be entered in the comments section on the second page of the data sheet to indicate to which item the comment refers.

Page 1:

EXAM INFORMATION: Fill in or circle the most appropriate answer for each of the fields.

- 1 Field #: unique identifying number originally assigned to the animal by response personnel. Note: the field number NEVER changes. If other filing numbers are added or accession numbers from other institutions are added, they should be noted as "additional identifiers".
Species: note the genus and species, or common name of the animal.
- 2 Examiner: the person evaluating the animal.
Recorder: the person recording the information on the data sheet.
- 3 Date of exam: the date that you are conducting the human interaction evaluation.
Condition Code (at exam): the condition code of the animal at the time of the human interaction evaluation. Use Smithsonian Institution condition codes (Geraci and Lounsbury, 1993).
- 4 Preservation: circle one of following - ALIVE, FRESH (not previously frozen), FROZEN (completely or partially frozen while exam was conducted), or FROZEN/THAWED (previously frozen, but completely thawed before exam).
Body condition: circle one of following - EMACIATED (clearly thin, concave epaxial muscle, obvious neck, ribs, scapulae, hip bones, and/or vertebral processes), NOT EMACIATED (robust or slightly thin, but not fitting the description of emaciated above) or CBD could not be determined (bloated, decomposed, not examined, etc.).
- 5 Documentation: circle all forms of photo/video documentation that apply.
Image disposition: indicate which camera, disk, tape, etc. that images were taken or stored on and the acronym of the organization that is maintaining them.
- 6 Integument: (skin, fur, hide) circle one of following - NORMAL (as if it were healthy and alive), ABNORMAL (conditions not associated with decomposition such as: alopecia, skin lesions, sloughing, abrasions, etc.) or DECOMPOSED/SCAVENGED (post-mortem changes such as peeling, sunburn, or scavenger damage).
% Skin missing: Circle the most appropriate number. Note that this does not apply to alopecia (fur loss) but to SKIN loss.
- 7 Explanation of terms: definitions of common terms used throughout the data sheet.

WHOLE BODY EXAM: Before beginning a detailed exam, take a look at the whole animal. If possible, look at all angles and surfaces. Following your whole animal exam, check the most appropriate choice for each category. If you check YES or CBD, describe what you see in the

Comments section on the next page, noting the appropriate line number. Indicate whether you collected an image of an area with a Y (Yes) or N (No) in the *Image taken* section. If you are unable to examine any areas, note the details in the *Comments* section.

- 8 Head/appendages removed (with instrument): Check YES if the head or other appendages (limbs, dorsal fin, fluke, *etc.*) appear to have been removed from the animal with an instrument (*e.g.* if there are obvious straight line cuts or straight nicks to the bone). In the lower 48 states of the US, this would be consistent with mutilation. In other areas, such as AK, this may be evidence of the legal harvest of a marine mammal. It is essential to work with local communities and agencies to interpret your findings in these cases. Check NO if all appendages are intact. Check CBD if you are unsure why an appendage is missing or if you cannot examine all appendages. If an appendage was completely removed by scavenging or predation (*e.g.* shark bite removed entire dorsal fin) you should check CBD.
- 9 Pelt removed (with instrument): – Check YES if the pelt appears to have been removed with an instrument (knife, scraper). Check NO if the pelt is intact (even if the animal's skin is intact but the hair/fur is missing). Check CBD if you are unsure (due to decomposition, *etc.*) of whether the animal's pelt was removed. Again, removal of the pelt in most regions of the US would be considered mutilation; however, in areas where harvesting is permitted, care must be taken in interpreting and documenting the interaction. Check NA if the animal has no pelt (cetacean or manatee).
- 10 Body sliced (with instrument) – Check YES if the carcass appears to be sliced with one or more cuts (from a knife or other blade), consistent with either legal harvest or mutilation (as above, dependent on the region). Multiple parallel cuts are often indicative of propeller wounds and should be noted under the *HI Lesions* category. Check NO if the body is intact or open body cavity is obviously due to natural causes (*e.g.* scavenging, predation). Check CBD if the body cavity has been penetrated and you are unsure of the cause.
- 11 Gear/debris present on animal– check YES if the animal is entangled in gear (net, line, pot, buoy, line with hook, *etc.*) or debris (anything else). Check NO if there is no gear/debris on the animal. Check CBD if you are unsure for any reason (*e.g.* gear/debris is found on, but not around the animal, or gear/debris was reported on the animal but apparently removed before you responded). Note *gear/debris present on animal* = YES if tags are present on the animal.
- 12 Gear retained – Check YES if the gear was retained by a stranding network or NOAA enforcement official. Note the name and contact information if the gear was retained by anyone other than your organization. Check NO if the gear was not retained. Check NA if there was no gear/debris present on the animal.
- 13 External pathology – If the animal has any lesions that appear to be disease-related such as pox lesions, tattoo lesions, abscesses, or other unexplained lumps, bumps or sores, check YES. Check NO if the animal has no disease-related lesions. Check CBD if you observe lesions and are unsure of their origin or if the integument is too degraded to assess.
- 14 Natural marking – If the animal has any natural markings (*e.g.* tooth rakes, unusual pigmentation, any non-HI scars) check YES. If the natural marks hamper your examination please note in the COMMENTS section. If there are no natural markings, check NO. If you cannot tell if there are any marks or are unsure of the origin of marks/scars check CBD.

- 15 HI lesions – Note lesions that may be associated with human interaction (fresh or healed entanglement or propeller scars, gaff marks, gunshot, healed HI scars, brands, etc.). Check YES if any human interaction lesions are observed. Check NO if no other lesions are observed. Check CBD if you observe lesions and are unsure of their origin or if the integument is too degraded to assess. A detailed exam of these lesions will occur in the next section.
- 16 Predation/scavenger damage – If there is evidence of predation or scavenger damage, circle the number(s) that correspond to the anatomical areas where evidence is seen. If the area affected is not numbered, circle #30, and note the area in the table below (e.g. genital slit, umbilicus, tongue) and note details of the damage in *Comments*.

17-29 DETAILED EXAM OF ANATOMICAL AREAS– Use this table to record findings of all suspected or possible evidence of human interaction. This means that any mark that the observer believes is consistent with some type of HI should be noted here. In addition, any marks for which the source Could not Be Determined, but that do not appear natural, should also be recorded in this table. Do NOT record information on natural markings or other lesions in this space. Examine the animal carefully starting at the head and working caudally down the right, then left, side, finishing with the tail or flukes. For this section, indicate whether you observe any SIGNS OF HUMAN INTERACTION in each *anatomical area* by checking the YES, NO or CBD column. If you were not able to examine an area, check NE, if it does not apply to your animal, check NA. Be consistent; examine anatomical areas in the same order each time you do an exam.

TYPE OF LESION- If you checked YES or CBD in any area, proceed to the Type of Lesion section and check all columns that apply.

- An *impression* occurs when a line or net leaves an indentation but does not lacerate or abrade the skin/pelt. Impressions left by net or line usually wrap around the leading and/or trailing edges of a fin, flipper or fluke. Impressions on the leading edge of an appendage may line up with a similar mark on the trailing edge.
- A *laceration* occurs when the skin/pelt is cut. Net and line usually leave linear lacerations. These lacerations may be evenly spaced along an appendage (indicating net) and may be accompanied by impressions.
- A *penetrating wound* occurs when a foreign object punctures or deeply penetrates the body, generally characterized by a small external wound and a wound tract that extends deep into the tissue and often into the body cavity. Sources of penetrating wounds include gaff, knife stab, spear, arrow, gunshot (especially bullet), etc.
- A *healed HI scar* is similar to a natural scar in pigmentation, but exhibits similar characteristics to the other types of lesions described here (e.g. linear scars on leading edges of appendages consistent with entanglement, parallel scars consistent with prop strike, etc.). It is as important to note healed HI scars as it is to note recent (unhealed) HI wounds. Evidence of HI, even if healed and not likely associated with the stranding event, should still be scored positive (YES) for HI.
- An *abrasion* occurs when gear or debris rubs an area and scrapes the skin/pelt without forming an obvious laceration. This often occurs with heavy line or twine entanglement or when loose or trailing ends of gear/debris rub (abrade) parts of the body.
- Choose *other / CBD* for any other types of lesions and describe in the comments section.

ORIGIN OF LESION - Once you determine the type of lesion, move to the origin of lesion section and check all that apply.

LINE is made up of many individual strands (multifilament) and is large in diameter. It is used for moorings, tow lines, forms the float and lead line of nets and attaches buoys and anchors.

TWINE is a small diameter line and can be multi- or mono- filament. Twine is constructed of various materials and is combined in different ways:

MONOFILAMENT twine – a single strand of nylon twine that leaves a single, straight, narrow impression or laceration (Figure 1, A).

MULTIFILAMENT – line or twine made up of multiple strands of material that are twisted or braided together and can leave a distinctive impression (a series of parallel, angled lines or ovals, Figure 1, B and C). If heavier twisted or braided line rubs on a body part or becomes tightly wrapped, it can cause an abrasion.

NET – nets can be made of either monofilament or multifilament twine and have various characteristics: twine diameter, square mesh size (knot to knot), and stretch mesh size (diagonal between opposite knots of a mesh with one knot between; Figure 2). Net impressions are often characterized by either a criss-cross pattern or a bunching of impressions with or without knot marks evident where lines intersect.

Based on the descriptions above, indicate the origin of the lesion:

- *Twine/Line* - select TWINE/LINE if the impression, laceration or abrasion is consistent with the descriptions above, but is not indicative of interaction with a net.
- *Net* – select NET if the marks are consistent with the descriptions above. Nets made of monofilament may leave multiple impressions or lacerations, but each lesion is a straight furrow.
- *Other/CBD* select this column if the marks appear consistent with entanglement or interaction with some type of gear, but you cannot determine which type.




Figure 1: Impressions left by (A) monofilament, (B) twisted twine and (C) twisted line. Impressions are most visible on cetaceans.

If you checked *Twine/Line*, *Net*, or *Other/CBD*, indicate whether lesions were caused by *monofilament* or *multifilament* gear. Select *CBD* if you observe linear marks and you are unsure of the origin.

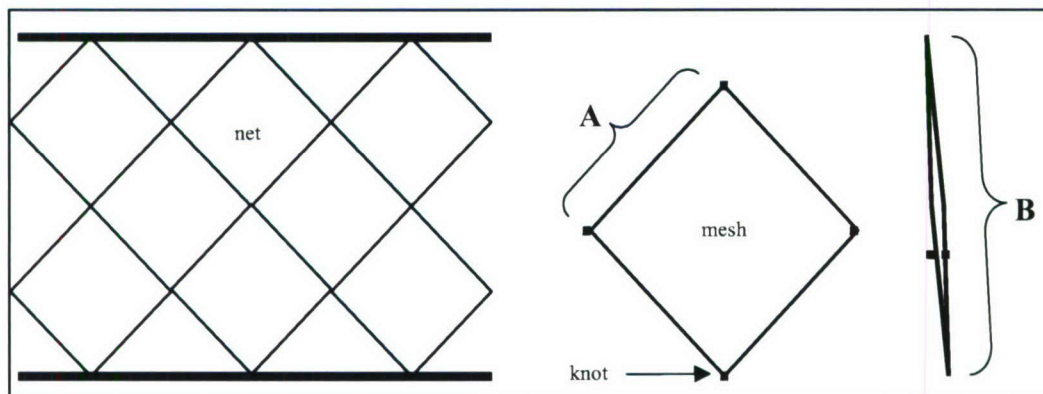


Figure 2: Typical net design. Nets are measured by the depth and length of the meshes hung between the top and bottom lines (float line and lead line on gill nets) and the horizontal length of the meshes. The mesh size can be measured from knot to knot (A) which is called the square or bar mesh size or (B) at it's maximum diagonal width which is called a stretch mesh size. Twine size is the diameter of the twine the makes up the mesh.

If the lesion you noted was not made by gear (line, net/twine), check the appropriate box to indicate the source:

- **Propellers** usually leave deep, roughly parallel lacerations (Figure 3). Lesions can be (A) straight, (B) Z or S-shaped, (C) curved, or open in the middle with thin trails (not illustrated). Large vessels may bisect an animal. Propellers have different sizes, numbers of blades, pitch, and configurations. Vessels can have a single propeller or two propellers separated by varying distances. Two propellers can be mounted on the same shaft rotating in different directions. The latter configuration causes very unusual lesions, unlike those in Figure 3.
- **Gunshot** wounds vary based on the weapon used (shotgun, rifle, hand gun) and the distance from the weapon. Gunshot wounds can be very difficult to identify through gross exam, but can be characterized by single (bullet) or multiple (pellet) puncture/penetrating wounds. Radiographs are often necessary to confirm the findings.
- **Other/CBD-** select this column for lesions with other origins including, gaff, arrow, and debris entanglement, etc. or if you are unsure of the origin of the lesion(s).

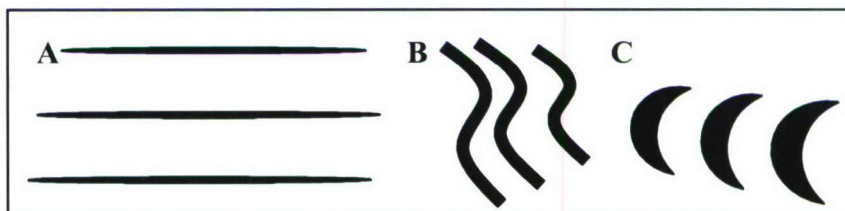


Figure 3: Types of propeller lesions left by different styles and sizes of propeller. The length, depth and spacing between lesions can provide information as to the type of propeller and vessel.

Every area that scores YES or CBD should have an IMAGE TAKEN with identifying information (field number, date of stranding, species, examiner, subject of image, etc.) and a scale (small ruler or something of known size). If film or disk space is not limited, take pictures of all areas. Note Y (yes) or N (no) in the IMAGE TAKEN column.

Every area that scores YES or CBD should have a comment associated with it. Number each COMMENT with the corresponding line number for that anatomical area.

30 If you find lesions in an area not listed in the Detailed Exam table, add the area here and complete the table as explained above.

Page 2:

FIELD # - Be sure to fill out the field number on both sides of all pages associated with this animal.

INTERNAL EXAM – An evaluation is not complete without a thorough necropsy (internal examination). Some forms of interaction are only evident through internal exam (e.g. ingestion of debris or gear) and a final interpretation may change if an animal with external evidence of HI is found to be suffering from disease, pregnancy complications, injuries, etc. Some observations support a diagnosis of HI (e.g. for fishery interactions-full stomach, froth in lungs) and others provide evidence for HI although nothing was noted externally (e.g. stomach full of man-made debris). Be sure to note the date of the internal exam in the INTERNAL EXAM box.

- 31 Internal examination conducted – If you were able to examine the entire animal, check YES. If you did not examine the animal internally check NO. Check PARTIAL if you examined part of the animal (e.g. abdominal cavity only), then describe in the *Comments* section what was examined.
- 32 Bruising/blunt trauma – indicate if you see any focal area of bruising (discrete area, not diffuse along an entire body region). Note whether the area is associated with an external lesion. If it is not associated with a penetrating lesion or wound, it should be considered blunt trauma. If you check YES or CBD, note the size of the area and the tissue depth (e.g. sub-dermal to blubber, into muscle, through muscle and into mesenteries and organs) in the *Comments* section (do not confuse diffuse post-mortem blood pooling with bruising).
- 33 Skeleton examined – Check YES if the entire skeleton was examined. Check NO if no bones were examined. Check PARTIAL if only some of the skeletal elements were examined. If you check PARTIAL, note in *Comments* section what was examined (e.g. examined skull, head, left ribs and flipper, but not right side or vertebral column).
- 34 Broken bones present - Note whether you observed any broken bones.
Associated tissue reaction -Examine the tissue around the break(s) and circle whether any tissue reaction has occurred (hemorrhage, fibrous tissue, swelling at bone ends, etc.). If you are unsure, check CBD.
- 35 GI tract examined – Check YES if the entire GI tract was examined. Check NO if none of the GI tract was examined. Check PARTIAL if only some elements of the GI tract were examined and note which areas were examined in the *Comments* section (e.g. stomach, but not intestines). Note in the *Detailed Info* column the predominant condition of the contents. Circle *debris/gear* if non-prey items (plastic, line, hooks, etc.) are found. Use the comments section to describe the region of the GI tract (e.g. esophagus, stomach chamber, intestine, or colon) and its contents (e.g. fish, squid, crabs, mussels, milk, plastic bag, unknown). Stranded animals with full stomachs are often suspect cases. Ingestion of gear or debris is considered a human interaction.
- 36 Lungs/bronchi examined - Check YES if both lungs were thoroughly examined. Check NO if the lungs were not examined. Check PARTIAL if you performed a partial examination.
- 37 Lungs/bronchi contents – Circle all that apply in the *Detailed Info* column and describe the contents of each lung, including content volume, in the *Comments* section.
- 38 Other pathologies noted – Note whether any other pathologies were observed, describe in *Comments* section.

39 COMMENTS – The details of what you observe are required in the section. Provide comments for each item for which you checked YES or CBD. When describing lesions, include measurements (e.g. length, width and depth, distance between lesions), location (e.g. measurement from nearest landmark – 20cm caudal of the right flipper), color, shape and texture. Note the characteristics of the edges (e.g. jagged, straight, rounded) and the direction of linear lesions (e.g. wraps from leading edge of dorsal fin to trailing edge on left side). Number each set of comments using the corresponding line number for that row on the data sheet. Use extra pages if needed and be sure to note the animal's field number in the upper right margin. If this information is provided in the necropsy report or other data sheet, reference that material here.

40 SIGNS OF HUMAN INTERACTION OBSERVED – Review your exam notes and circle YES if you observed any signs of human interaction on the animal. Circle NO if you thoroughly examined the animal and did not find any signs of human interaction. Circle CBD if: (1) you did not examine the animal thoroughly, (2) decomposition or scavenger damage hampered the exam, or (3) you are unsure whether marks on the animal were caused by human interaction. This is an objective analysis. It does not take into account the animal's physical condition, the timing of the human interaction with respect to the stranding or the circumstances surrounding the stranding. **TRANSFER THIS INFORMATION TO THE SIGNS OF HUMAN INTERACTION SECTION ON THE LEVEL A DATA SHEET.**

41 STRANDING EVENT HISTORY/CIRCUMSTANCES – provide any information about the stranding event or circumstances surrounding the event that would be helpful in determining the HI diagnosis (i.e. fishing, drilling, or other activities, oil spill, unusual mortality events, previous sightings of animal, unusual behavior prior to stranding, etc.). Note any objective details provided by the initial reporter, these may be answers to questions you have asked (i.e. Was there any blood in the water next to the animal? What did it look or smell like when you first observed it? How was the animal positioned (belly up, on its side) when you first observed it?).

If harassment is suspected, objectively describe events in this section including names and contact numbers for witnesses and any authorities that were contacted.

42 FINAL HUMAN INTERACTION EVALUATION – This section should be completed if you circled YES under *Signs of Human Interaction Observed* (#40). It should be completed after filling out the entire data sheet. This section is subjective and takes into account the animal's physical condition, necropsy findings, the timing of the human interaction with respect to the stranding, and the circumstances surrounding the stranding. Most importantly it takes into account the evaluator's level of experience. If you have not conducted many evaluations or are not familiar with the region, you may be unable to make an accurate final evaluation and should circle CBD.

For this section you are estimating how likely you think it is that the documented human interaction contributed to the stranding event. This estimate or confidence interval is expressed in a scale of 0-3, as described below. Circle the most appropriate number. The higher the number, the more likely it is that the interaction contributed to the stranding. If you do not feel that you can provide an evaluation, circle 0 – Uncertain (CBD). [Note: We

do not say that the human activity *caused* the stranding because the human interaction could have indirectly contributed to the event without being the direct cause of the stranding.]

0. Uncertain (CBD) – You cannot provide an evaluation of the likelihood that human interaction contributed to the stranding (e.g. a Code 4 carcass is found with propeller marks; it is too decomposed to determine whether the interaction was pre- or post-mortem).
1. Improbable - It is unlikely that the observed human interaction contributed to the stranding (e.g. there are healed entanglement scars on the flukes of a known humpback whale that died with a full-term fetus; it is unlikely that the past entanglement contributed to the stranding).
2. Suspect – It is possible that human interaction contributed to the stranding (e.g. there is a small amount of plastic found in the animal's stomach, but you are unsure of its effect).
3. Probable - It is very likely that human interaction contributed to the stranding (e.g. clear evidence of mutilation, a full stomach, plus one mark that may be indicative of entanglement).

43 JUSTIFICATION – Provide a brief justification of your answer for the *Final Human Interaction Evaluation* score. Include information from all sources available to you.

Appendix D. Equipment Necessary for a Complete Necropsy on Pinnipeds and Small Cetaceans.

Most supplies can be found at local supply stores or in lab supply catalogues. Equipment that is difficult to locate is denoted with an asterisk and the supplier's information is listed at the bottom of the page.

Equipment list:

Documentation

Digital camera with sufficient battery power and memory cards
Disposable camera (for back-up)
Photo ID card
Forms: necropsy report with sample inventory list, morphometric data form, HI evaluation form
Clipboards
2 – 4 Sharpie markers (fine point and ultra fine point)
Pencils and black ink pens
Label tape*
Packaging tape

Sampling

Measuring tape
Ruler with cm
Tyvek labels*
2 x 3, 3 x 5 or 4 x 6, 8 x 10, and 9 x 13 write-on zip lock bags
4 x 6 whirlpack bags
Laundry tags*
2 1.0L bottles filled $\frac{3}{4}$ with 10% NB formalin for histology samples
1 250ml – 1000ml bottle filled $\frac{3}{4}$ with 10% NB formalin for life history samples
1 $\frac{1}{2}$ gallon seal tight container for stomach contents
DMSO vial
Plastic centrifuge tubes(10-20mL)
Syringes (various sizes)
Aluminum foil
Acetone

Flagging tape—www.LSS.com, **Flagging tape**, biodegradable
Laundry tags— www.golps.com,**Daily Delivery Tag**, 1-Ply fiber;
Label tape— www.VWR.com
Tyveck tags—www.LSS.com; **Blank tags**; white tyveck.

Sampling (cont.)

EtOH and saline for parasites
Culture swabs – aerobic and anaerobic
Butane flame
Cutting board
Sharpening steel
5 toothed forceps
2 - 3 Stainless steel dissecting scissors
5 Sharp stainless steal knives 6"- 9"
Box of scalpel blades
Scalpel blade handles (3 -5)
Scalpel blade remover
Flat head screwdriver (tooth extractor)
Stryker saw
Chisel
Hammer
Cotton string
Small pan scale for tissue weights (mg or g)
Large scale for full carcass weight

Safety/Personal Protection

First aid kit
Sharps container
Latex or Nitrile gloves
Rubber boots
Aprons
Protective eyewear
Masks

Clean-up

Paper towels
Heavy Duty construction bags
30 gallon barrels for soft tissue disposal and skeletal remains

Appendix E. Pinniped Morphometric Data Record.

Cape Cod Stranding Network, Inc.
Pinniped Data Record

Field #: _____

Accession #: _____

Species: _____

Condition Code: 1 2 3 4 5

Sex: M F CBD

Length: _____

Weight: _____

Human Interaction: Y N CBD

Carcass: Fresh Frozen

Field Notes:

Date of Death: _____

Date of Recovery: _____

Date of Necropsy/Exam: _____

Observers: _____

Location: _____

Lat/Long: _____ N/ _____ W

Photos: Y N Roll #: _____

Video: Y N Tape #: _____

Necropsy: Y N; Location: _____

Tag Color / #: _____

Morphometrics: Left / Right

Measurer: _____

Units: _____

Straight Line (taken from tip of nose to...)

1 (total, straight to tip of tail)	.
2 (total, curvilinear)	.

Appendages

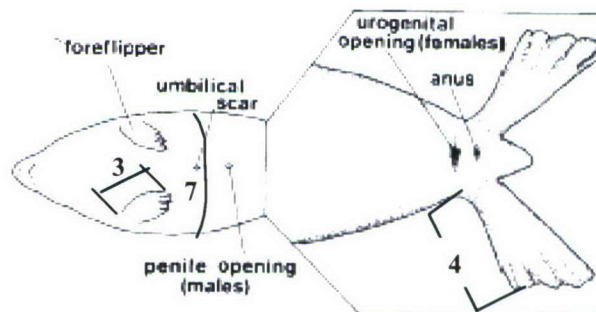
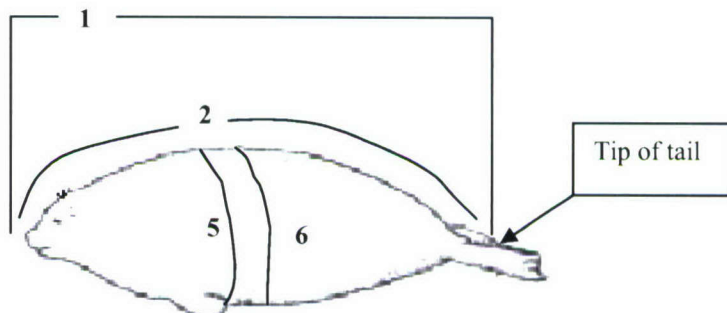
3 (Front flipper, ant.)	.
4 (Hind flipper, ant.)	.

Girths

5 (axilla)	.
6 (Max, location)	.
7 (Umbilical)	.

Blubber Thickness (mm)

5-Dor	.
5-Lat	.
5-Vent	.



Emaciated: Yes / No / CBD

External Exam:

(lesions, scars, parasites, etc.)

Tooth Counts: LL: _____ UL: _____ LR: _____ UR: _____

**Cape Cod Stranding Network, Inc.
Cetacean Data Record**

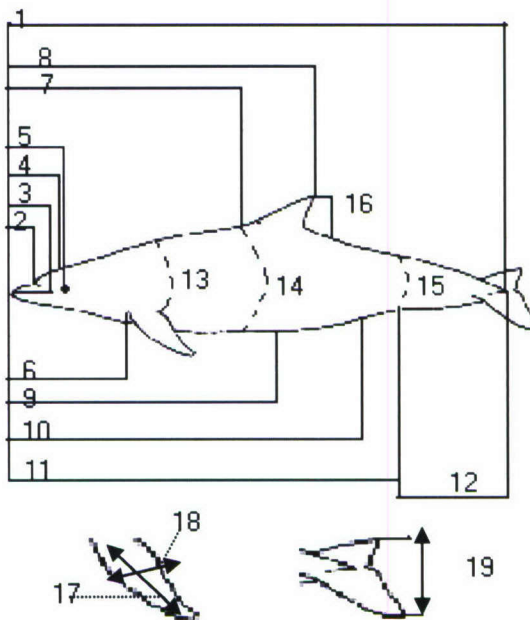
Field #: _____
 Accession #: _____
 Species: _____
 Condition Code: 1 2 3 4 5
 Sex: M F CBD
 Length: _____
 Weight: _____
 Human Interaction: Y N CBD
 Carcass: Fresh Frozen
 Field Notes: _____

Date of Death: _____
 Date of Recovery: _____
 Date of Necropsy/Exam: _____
 Observers: _____
 Location: _____
 Lat/Long: _____ N/ _____ W
 Photos: Y N Roll #: _____
 Video: Y N Tape #: _____
 Necropsy: Y N; Location: _____
 Tag color: _____ Tag#: _____

Morphometrics: Left / Right Measurer: _____ Units: _____

Straight Line (taken from tip of upper jaw to...)

1 (total: to fluke notch)	.
2 (apex of melon)	.
3 (gape of mouth)	.
4 (center of eye)	.
5 (center of blowhole)	.
6 (ant. insert pec.)	.
7 (ant. insert d. fin)	.
8 (d. fin tip)	.
9 (umbilicus)	.
10 (center of genital slit)	.
11 (anus)	.
12 (fluke notch to anus)*	.



Births

13 (axilla)	.
14 (ant. insert d. fin)	.
15 (anus)	.

Appendages

16 (d. fin height)	.
17 (pec. fin ant. length)	.
18 (pec. fin max width)	.
19 (fluke width)	.

Blubber Thickness (mm)

13-Dor	.
13-Lat	.
13-Vent	.

Emaciated: Yes / No / CBD

Tooth Counts: LL: _____ UL: _____ LR: _____ UR: _____

External Exam:

(Lesions, scars, parasites, etc.)

Appendix G. Blank Photo ID Card.

CCSN#:

Date:

Species:

Location:

Comments:

Cape Cod Stranding Network, Inc.
P.O. Box 287
Buzzards Bay, MA 02532
508.743.9805

Observer:



Appendix H. Necropsy Sample Inventory Check List.

Note: This is only an example. Sampling should not be limited to this list.

	Standard Samples				Pinn. Only			UME ONLY
	Life History	Genetics	Contam.	Histo.	Herpes	Morbilli	Brucella	Biotox
Tissue	(Frozen or fixed as below)	(Frozen &/or DMSO)	(Foil wrapped and frozen)	(2 sets in 10% NBF)	(Frozen)	(Frozen)	(Frozen)	(Frozen -80°)
Skin		<input type="checkbox"/>		<input type="checkbox"/>				
Teeth	FR <input type="checkbox"/>							
Oral mucosa					<input type="checkbox"/>			
Blubber			<input type="checkbox"/>	<input type="checkbox"/>				
Muscle			<input type="checkbox"/>	<input type="checkbox"/>				
Liver			<input type="checkbox"/>	<input type="checkbox"/>	<input type="checkbox"/>		<input type="checkbox"/>	<input type="checkbox"/>
Kidney (R)			<input type="checkbox"/>	<input type="checkbox"/>	<input type="checkbox"/>		<input type="checkbox"/>	<input type="checkbox"/>
Kidney (L)				<input type="checkbox"/>				
Stomach				<input type="checkbox"/>				
Lung (R)				<input type="checkbox"/>			<input type="checkbox"/>	
Lung (L)				<input type="checkbox"/>		<input type="checkbox"/>		
Tracheobronchial				<input type="checkbox"/>		<input type="checkbox"/>		
Lymph				<input type="checkbox"/>			<input type="checkbox"/>	
Spleen				<input type="checkbox"/>			<input type="checkbox"/>	
Blood/Serum					<input type="checkbox"/>	<input type="checkbox"/>		<input type="checkbox"/>
Esophagus				<input type="checkbox"/>				
Trachea				<input type="checkbox"/>				
Prescapular				<input type="checkbox"/>		<input type="checkbox"/>		
Lymph							<input type="checkbox"/>	
Heart				<input type="checkbox"/>				
Diaphragm				<input type="checkbox"/>				
Pancreas				<input type="checkbox"/>			<input type="checkbox"/>	
Mesenteric Lymph				<input type="checkbox"/>		<input type="checkbox"/>	<input type="checkbox"/>	
Intestine				<input type="checkbox"/>				
Adrenal (L)				<input type="checkbox"/>				
Adrenal (R)				<input type="checkbox"/>				
Colon				<input type="checkbox"/>				
Bladder				<input type="checkbox"/>				
Testis	FX <input type="checkbox"/>			<input type="checkbox"/>			<input type="checkbox"/>	
Uterus	FX <input type="checkbox"/>			<input type="checkbox"/>			<input type="checkbox"/>	
Ovary	FX <input type="checkbox"/>			<input type="checkbox"/>			<input type="checkbox"/>	
Feces								<input type="checkbox"/>
Stomach Contents	CH <input type="checkbox"/>							<input type="checkbox"/>
Urine								<input type="checkbox"/>
Aqueous humor								<input type="checkbox"/>
Milk/Mammary								
Discharge	FR <input type="checkbox"/>							
Brain				<input type="checkbox"/>			<input type="checkbox"/>	
Other:								
Lesions (list)	FR <input type="checkbox"/>			<input type="checkbox"/>				
Fungal growths	FR <input type="checkbox"/> SW <input type="checkbox"/>			<input type="checkbox"/>				
Parasites (EtOH)	<input type="checkbox"/>							
Culture (swab)	SW <input type="checkbox"/>	List sites:						

This page intentionally left blank.

Glossary of Terms

<u>Acute</u>	Rapid onset.
<u>Amorphous</u>	Lacking a definitive shape.
<u>Caseous</u>	Resembling cheese.
<u>Catarrhal</u>	Containing mucous.
<u>Chronic</u>	Refers to a persistent or lasting disease, or one that has developed slowly.
<u>Caudal</u>	Towards the tail.
<u>Coalescing</u>	To come together as to form one.
<u>Cortex</u>	The outer most layer of an organ, such as lymph nodes, kidney, or adrenal glands.
<u>Cranial</u>	Towards the head.
<u>Cyamids</u>	Whale lice.
<u>Demarcate</u>	To mark out the limits or boundaries of something.
<u>Differential Diagnosis</u>	List of potential etiologies for a suite of observations used to focus further diagnostic testes to adequately discriminate and derive the actual etiology.
<u>Diffuse</u>	Entire surface involved.
<u>Dorsal</u>	The upper, or top, side of the animal's body.
<u>Ectasis</u>	Widening; dilation of a hollow organ.
<u>Edematous</u>	Excessive accumulation of serous, gelatinous fluid in tissue spaces or body cavity.
<u>Emphysema</u>	An abnormal distention of body tissue caused by retention of air.
<u>Etiology</u>	The cause of the condition(s).
<u>Etiologic Diagnosis</u>	The cause(s) of the condition(s) observed using all available diagnostic data.

<u>Fascia</u>	Soft tissue component of the connective tissue system that interpenetrates and surrounds muscles, bones, organs, nerves, blood vessels and other structures.
<u>Flaccid</u>	Lacking firmness.
<u>Fusiform</u>	Spindle-shaped.
<u>Granulomatous</u>	Highly vascular fibrous connective tissue involved with the resolving phase of an inflammatory process.
<u>Histology</u>	The study of tissue sectioned as a thin slice, using a microtome.
<u>Histomorphology</u>	The form and structure of an organism or any of its parts as seen through a microscope.
<u>Histopathology</u>	The microscopic study of diseased tissue.
<u>Hyperplasia</u>	An abnormal increase in the number of cells in an organ or a tissue with consequent enlargement.
<u>Hypostasis</u>	Post-mortem pooling of blood in dependant part of the body.
<u>Immunohistochemistry</u>	The process of localizing proteins and other components in cells of a tissue section exploiting the principle of antibodies binding specifically to antigens in biological tissues.
<u>Lateral</u>	Along the length, or side or the animal's body
<u>Lividity</u>	The settling of the blood in the lower (dependent) portion of the body, causing a purplish red discoloration of the skin
<u>Loculated</u>	Having divided into small cavities or compartments
<u>Maxilla</u>	Upper jaw
<u>Medulla</u>	The inner part of an organ
<u>Milliary</u>	Resembling a millet seed
<u>Morphologic Diagnosis</u>	A summary of the grossly evident abnormalities

<u>Morphometric</u>	Measurement of the form of organisms or of their parts.
<u>Mosaic</u>	Patterned in small squares.
<u>Mottled</u>	Spotted or blotched with different shades or colors.
<u>Mucopurulent</u>	Containing mucus and pus.
<u>Mucosa</u>	The moist, inner lining of some organs and body cavities.
<u>Multifocal</u>	More than one location.
<u>Opaque</u>	Impenetrable by light; neither transparent nor translucent.
<u>Parenchyma</u>	The functional parts of an organ in the body; the bulk of a substance.
<u>Parietal surface</u>	Surface of tissues that are in contact with the body wall.
<u>Pathology</u>	The study and diagnosis of disease through examination of organs, tissues, cells and bodily fluids.
<u>Peracute</u>	Very acute; violent.
<u>Pericystic</u>	Alongside the bladder.
<u>Petechia</u>	A small purplish spot on a body surface, such as the skin or a mucous membrane, caused by a minute hemorrhage.
<u>Pleura</u>	The thin covering that protects and cushions the lungs.
<u>Purulent</u>	Containing, discharging, or causing the production of pus.
<u>Resilient</u>	Capable of returning to an original shape or position, as after having been compressed.
<u>Reticular</u>	Net-like.

<u>Serosa</u>	Smooth membrane consisting of a thin layer of cells which excrete a fluid, known as serous fluid.
<u>Serous fluid</u>	Bodily fluids that are typically pale yellow and transparent.
<u>Sessile</u>	Permanently attached; not free moving.
<u>Steatosis</u>	Abnormal retention of lipids within a cell.
<u>Stellate</u>	Arranged like a star; radiating from the center.
<u>Stenosis</u>	Abnormal narrowing in a blood vessel or other tubular organ or structure.
<u>Tortuous</u>	Having many turns; winding or twisting.
<u>Ventral</u>	The underside, or belly of the animal's body.
<u>Visceral surface</u>	The surface of the organ that faces adjacent organs.
<u>Viscous</u>	Having relatively high resistance to flow.
<u>Zoonosis</u>	Infectious disease that can be transmitted from animals to humans or humans to animals.

Resources

- BARCO, S. and K. TOUHEY. 2007. In prep. *Handbook for Recognizing, Evaluating, and Documenting Human Interaction in Stranded Cetaceans and Pinnipeds*. Virginia Aquarium Stranding Program, 717 General Booth Blvd., Virginia Beach, VA 23451
- DIERAUF, L.A. and F. GULLARND. 2001. *Marine Mammal Medicine*. CRC Press, Boca Raton.
- DYKSTRA, M. 1993. *A manual of techniques for applied biological electron microscopy*. Springer.
- GERACI, J.R., and V.L. LOUNSBURY. 2005. *Marine mammals ashore: a field guide for strandings*, Second Edition. National Aquarium in Baltimore, Baltimore, MD.
- KETTEN, D., S. CRAMER, and J. ARRUDA. 2007. Procedure for the Removal, Fixation, and Preservation of Cetacean Ears. Pages 3.1 to 3.22
<https://reefshark.nmfs.noaa.gov/pr/mm/sysadmin/nrsworkshop/> in N. YOUNG ed. *Odontocete Salvage, Necropsy, Ear Extraction, and Imaging Protocols*.
- LUNA, L. 1992. *Histopathologic methods and color atlas of special stains and tissue artifacts*. American Histolabs Gaithersburg, MD.
- MCLELLAN, W., S. ROMMEL, M. MOORE and D. PABST. 2004. Right Whale Necropsy Protocol. Final Report to NOAA Fisheries for contract # 40AANF112525 U.S. Department of Commerce, National Oceanic and Atmospheric Administration, National Marine Fisheries Service, Office of Protected Resources, Silver Spring, Maryland. Pages 51 pp.
- MEYER, D. and J. HARVEY. *Veterinary Laboratory Medicine, Interpretation and Diagnosis*, 3rd edition. Elsevier.
- O'HARA, T. and T. O'SHEA. 2005. Toxicology. Pages 471 in L. DIERAUF and F. GULLAND eds. *Maine Mammal Medicine*. CRC Press, Boca Raton, FL.
- RAVERTY, S. and J. GAYDOS. Unpubl. Killer whale necropsy and disease testing protocol. Pages 1-63. Animal Health Center, Ministry of Agriculture, Food and Fisheries, Abbotsford, British Columbia, Canada.
- YOUNG, N. 2007. Odontocete Salvage, Necropsy, Ear Extraction, and Imaging Protocols. Pages 1-171 <https://reefshark.nmfs.noaa.gov/pr/mm/sysadmin/nrsworkshop/>.
- WYNNE, K. and M. SHWARTZ. 1999. *The Guide to Marine Mammals & Turtles of the U.S. Atlantic & Gulf of Mexico*. Rhode Island Sea Grant, University of Rhode Island, Narragansett, RI.

REPORT DOCUMENTATION PAGE	1. REPORT NO. WHOI-2007-06	2.	3. Recipient's Accession No.
4. Title and Subtitle Marine Mammal Necropsy: An introductory guide for stranding responders and field biologists		5. Report Date August 2007	
		6.	
7. Author(s) Katie R. Pugliares, Andrea Bogomolni, Kathleen M. Touhey, Sarah M. Herzig, Charles T. Harry, and Michael J. Moore		8. Performing Organization Rept. No.	
9. Performing Organization Name and Address Woods Hole Oceanographic Institution Woods Hole, Massachusetts 02543		10. Project/Task/Work Unit No.	
		11. Contract(C) or Grant(G) No. (C)NA05NMF4391165 (G)	
12. Sponsoring Organization Name and Address National Oceanic and Atmospheric Association		13. Type of Report & Period Covered Technical Report	
		14.	
15. Supplementary Notes This report should be cited as: Woods Hole Oceanog. Inst. Tech. Rept., WHOI-2007-06.			
16. Abstract (Limit: 200 words) This necropsy manual is designed to establish a base level of proficiency in marine mammal necropsy techniques. It is written for stranding network members who do not have a formal pathobiological training and have limited knowledge of anatomy. Anatomical and pathological jargon has been kept to a minimum. This manual is divided into six sections: preliminary data, sample management, pinniped, small cetacean, large whale (at sea and on the beach), and multiple appendices (A-H). A well-illustrated, carefully written gross necropsy report is essential to an adequate diagnostic investigation. Gross reports with significant detail and description tend to engender useful histopathological findings. A sample blank gross necropsy report and guidelines in writing a report can be found in Appendices A & B. Overall, this guide aims to lead the enquiring mind through the necessary steps to produce such reports. While this manual focuses on process and interpretation, it is important to understand that the gross necropsy is primarily about making detailed, descriptive observations without bias as to possible etiology. The necropsy should establish a list of differential diagnoses and the sampling be directed by an attempt to discriminate between them.			
17. Document Analysis a. Descriptors Necropsy Pinniped Cetacean b. Identifiers/Open-Ended Terms c. COSATI Field/Group			
18. Availability Statement Approved for public release; distribution unlimited.		19. Security Class (This Report) UNCLASSIFIED	21. No. of Pages 131
		20. Security Class (This Page)	22. Price