

AD\_\_\_\_\_

AWARD NUMBER: W81XWH-04-1-0038

TITLE: Use of Synthetic Nerve Grafts to Restore Cavernous Nerve Function Following Prostate Cancer Surgery: In Vitro and In Vivo Studies

PRINCIPAL INVESTIGATOR: Badrinath R. Konety, M.D.

CONTRACTING ORGANIZATION: University of California  
San Francisco, California 94143-0962

REPORT DATE: March 2006

TYPE OF REPORT: Annual

PREPARED FOR: U.S. Army Medical Research and Materiel Command  
Fort Detrick, Maryland 21702-5012

DISTRIBUTION STATEMENT: Approved for Public Release;  
Distribution Unlimited

The views, opinions and/or findings contained in this report are those of the author(s) and should not be construed as an official Department of the Army position, policy or decision unless so designated by other documentation.

# REPORT DOCUMENTATION PAGE

Form Approved  
OMB No. 0704-0188

Public reporting burden for this collection of information is estimated to average 1 hour per response, including the time for reviewing instructions, searching existing data sources, gathering and maintaining the data needed, and completing and reviewing this collection of information. Send comments regarding this burden estimate or any other aspect of this collection of information, including suggestions for reducing this burden to Department of Defense, Washington Headquarters Services, Directorate for Information Operations and Reports (0704-0188), 1215 Jefferson Davis Highway, Suite 1204, Arlington, VA 22202-4302. Respondents should be aware that notwithstanding any other provision of law, no person shall be subject to any penalty for failing to comply with a collection of information if it does not display a currently valid OMB control number. **PLEASE DO NOT RETURN YOUR FORM TO THE ABOVE ADDRESS.**

<b>1. REPORT DATE (DD-MM-YYYY)</b> 01-03-2006		<b>2. REPORT TYPE</b> Annual		<b>3. DATES COVERED (From - To)</b> 1 Mar 2005 – 28 Feb 2006	
<b>4. TITLE AND SUBTITLE</b>  Use of Synthetic Nerve Grafts to Restore Cavernous Nerve Function Following Prostate Cancer Surgery: In Vitro and In Vivo Studies				<b>5a. CONTRACT NUMBER</b>	
				<b>5b. GRANT NUMBER</b> W81XWH-04-1-0038	
				<b>5c. PROGRAM ELEMENT NUMBER</b>	
<b>6. AUTHOR(S)</b>  Badrinath R. Konety, M.D.  E-Mail: <a href="mailto:bkonety@urology.ucsf.edu">bkonety@urology.ucsf.edu</a>				<b>5d. PROJECT NUMBER</b>	
				<b>5e. TASK NUMBER</b>	
				<b>5f. WORK UNIT NUMBER</b>	
<b>7. PERFORMING ORGANIZATION NAME(S) AND ADDRESS(ES)</b>  University of California San Francisco, California 94143-0962				<b>8. PERFORMING ORGANIZATION REPORT NUMBER</b>	
<b>9. SPONSORING / MONITORING AGENCY NAME(S) AND ADDRESS(ES)</b> U.S. Army Medical Research and Materiel Command Fort Detrick, Maryland 21702-5012				<b>10. SPONSOR/MONITOR'S ACRONYM(S)</b>	
				<b>11. SPONSOR/MONITOR'S REPORT NUMBER(S)</b>	
<b>12. DISTRIBUTION / AVAILABILITY STATEMENT</b> Approved for Public Release; Distribution Unlimited					
<b>13. SUPPLEMENTARY NOTES</b>					
<b>14. ABSTRACT</b>  The hypothesis of this proposal is that interposition of micropatterned biodegradable polymer based nerve grafts to replace resected or damaged cavernous nerves can facilitate return of erectile function by engendering directional nerve growth in an animal model. Micropatterned grafts have been produced using a biodegradable polymer (PDFA). The groove characteristics obtained by micropatterning will be optimized to allow maximal directional neurite growth have been optimized. The effect of laminin +/- polylysine, Schwann cell and neuronal stem cells on neurite growth are being investigated. Tubulized sheets of the polymer with and without these factors/cells have been used to microsurgically replace resected cavernous nerve in male Sprague-Dawley rats. Control groups consisting of ungrafted animals as well as those grafted with native genitofemoral nerve have been generated. After an interval of 2 months, we have attempted to observed the restoration of physiologic function of the cavernous nerve by electrical stimulation of the nerve and/or pelvic ganglion. We are in the process of analyzing the tissue sections of the grafts that have been harvested to look for nNos expression and fluorogold staining which would indicate re-establishment of nerve integrity since that would be required to allow travel of fluorogold injected into the penile tissue to the pelvic ganglion.					
<b>15. SUBJECT TERMS</b> radical prostatectomy, impotence, nerve grafts, physiology					
<b>16. SECURITY CLASSIFICATION OF:</b>			<b>17. LIMITATION OF ABSTRACT</b>	<b>18. NUMBER OF PAGES</b>	<b>19a. NAME OF RESPONSIBLE PERSON</b>
<b>a. REPORT</b> U	<b>b. ABSTRACT</b> U	<b>c. THIS PAGE</b> U			USAMRMC
			UU	9	<b>19b. TELEPHONE NUMBER (include area code)</b>

## Table of Contents

Table of Contents.....	3
Introduction.....	4
Body.....	4
Key Research Accomplishments.....	7
Conclusion.....	8
References.....	9

## INTRODUCTION

Adenocarcinoma of the prostate has become the most common malignancy in American males. In 2003 an estimated 220,900 men will be diagnosed with the disease and 28,900 will die of it<sup>1</sup>. At 50 years of age or older, the estimated probability of developing clinically apparent carcinoma is 9.6% and 11.4% for white and black men, respectively<sup>2,3</sup>. Curative options for prostate cancer include radiation therapy and radical prostatectomy. Radical prostatectomy is considered by many to be the treatment of choice for patients with localized cancer of the prostate and offers these patients the greatest chance for long term survival<sup>4-9</sup>. The major side effects of prostatectomy are impotence and incontinence. Prior to the advent of nerve-sparing surgical techniques, it is estimated that less than 10% of patients who underwent radical prostatectomy recovered erectile function postoperatively and urinary incontinence rates as high as 87% were reported<sup>10</sup>. Since the original description of the importance of the peri-prostatic neurovascular bundle in preserving erectile function by Walsh and Donker<sup>11</sup> the anatomic nerve sparing operation has become the standard approach in most cases. This modified surgical approach significantly reduces the impotence rates in these patients<sup>4,5,12,13</sup>. There is some evidence that the neurovascular bundles may contribute to the preservation of continence as well by maintaining autonomic innervation to the smooth muscle in the distal urethra and the somatic motor supply to the striated sphincter<sup>7,12,13</sup>. The neurovascular bundles are located within the lateral prostatic fascia dorsolateral to the prostate and lateral to the membranous urethra. They are susceptible to injury during the standard radical prostatectomy performed either by the retropubic or the perineal approach. To ensure an adequate cancer operation in cases where the nerves are adherent to the prostate and there is increased suspicion of extraprostatic extension of tumor, it would be necessary to sacrifice the neurovascular bundle on that side. The potency rate can decrease from 21-76% with bilateral neurovascular bundle preservation to as low as 0-56% with unilateral nerve preservation<sup>14-18</sup>. After wide resection of both neurovascular bundles, recovery of spontaneous erections adequate for intercourse is rare<sup>14-16</sup>.

Certain factors such as a serum PSA >10ng/ml, biopsy tumor Gleason >7, clinical stage T2a or higher, and a high number and percentage of biopsy cores involved with cancer, particularly with Gleason component 4 or 5 are believed to place a given individual at high risk for microscopic extraprostatic tumor extension<sup>19</sup>. Wide resection of the neurovascular bundle is necessary in these cases in order to achieve a negative surgical margin which is important to decrease the likelihood of subsequent biochemical recurrence<sup>20</sup>. The bilateral nerve sparing technique should be applied whenever possible. However in an unselected population of men with prostate cancer, a significant proportion will require unilateral nerve resection and rarely bilateral nerve resection to maximize the chance of cure. Even in patients undergoing bilateral nerve sparing radical prostatectomy, the post-operative potency takes time to recover and the rates are not 100%. It is conceivable that factors that improve nerve regeneration and growth could enhance earlier and more complete return of erectile function even in those men who undergo nerve sparing procedures. In addition to patients undergoing radical prostatectomy, neurovascular bundle damage can be sustained by individuals after radical cystoprostatectomy, low anterior colon resection and rectal surgery. The ability to preserve or replace these nerves could potentially increase the likelihood of post-operative potency in these patients as well<sup>21</sup>. This project is aimed at investigating biodegradable polymer conduits impregnated with laminin, schwann cells or neuronal stem cells as possible candidates for replacement of the cavernous nerve in an animal model.

## BODY OF REPORT

**Substrate fabrication:** A chrome lithography mask was produced with the micron scale patterns of 10  $\mu\text{m}$  groove width, and 20  $\mu\text{m}$  groove spacing using conventional lithographic techniques. The mask was deposited onto a two-inch diameter quartz slide or a four-inch diameter silicon

wafer in a vacuum chamber purged with argon at a pressure of less than 1 micro-Torr. Quartz substrates were etched up to 4  $\mu\text{m}$  using deep reactive ion etching (DRIE) through the mask, leaving behind long rectangular areas capped by chrome. After the chrome was removed from the quartz substrate, the quartz substrate was used as a micro die to transfer the geometric microgrooves to the biodegradable polymer, poly(D,L lactide) (PDLA). A scanning electron microscopy image of the PDLA films is shown in Fig. 1. Laminin was selectively adsorbed to the microgrooves using a surface-tension based technique developed in our laboratory.

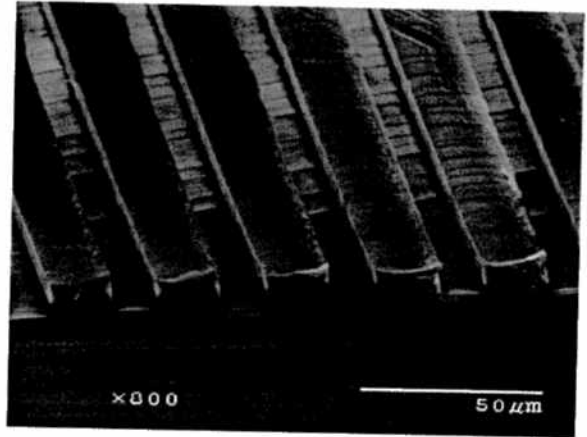


Fig. 1 SEM image of a PDLA micropatterned film

**Conduit fabrication:** PDLA was dissolved in chloroform at a concentration of 30% w/v. Sodium chloride crystals were ground, sieved with 120-gauge mesh, and suspended in the PDLA solution at a concentration of 75% and 50% by volume. A pasteur pipette (OD=1 mm) (Fisher) was dipped into 6% w/v solution of polyvinyl alcohol (PVA) in water and allowed to dry. The PVA acts as a release agent. The pipettes were then dipped in the polymer/salt suspension, slowly removed, and allowed to dry. This step was repeated until the outer diameter was 3mm. The dry conduits were placed under vacuum to remove any residual chloroform. The pipettes were placed in water to release the conduit from the support. Water was replaced every 2 hours until the sodium chloride was fully dissolved, leaving behind the conduit with 75% or 50% porosity. The conduits were dried, and cut into 1.2 cm sections. Depending on the salt concentration used, conduits with different porosities were obtained, as shown in Figs. 2 and 3. The micropatterned films were then cut into 1.2 cm by 1.5 cm sections, wrapped around flame narrowed pasteur pipettes, and inserted into the porous conduit supports. The conduits with micropatterned inserts were stored in desiccators at  $-20\text{ }^{\circ}\text{C}$  until used.

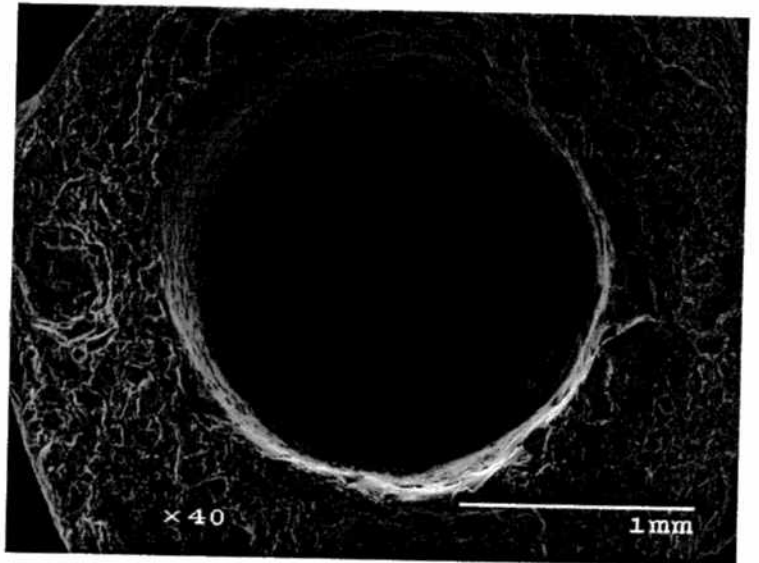


Fig. 2 SEM image of a PDLA conduit made using 50% sodium chloride

#### **Schwann Cell isolation and culture:**

Sprague-Dawley rats, 16-20 days old, were anesthetized and decapitated. The sciatic nerve was removed and kept in chilled Gey's Balance Salt Solution supplemented with 6.5 mg/ml glucose. The epineurium, connective tissue, and blood vessels were removed using fine forceps and the nerve was cut into pieces approximately 1 mm in length. The nerve pieces were placed in 60 mm tissue culture plates. Approximately 0.5 ml of chicken plasma solution (5 mg/mL) was spread evenly over the bottom of the plate. Nerve pieces were placed in the dish spaced 2 mm apart. One hundred microliters of thrombin (10 units/ml) was added to the plate and mixed with chicken plasma. Fibrin from the chicken plasma was allowed to clot for about five minutes before adding media. The media used for the cell cultures was DMEM with 10% v/v fetal bovine serum (FBS) and 5  $\mu\text{L}$  gentamicin/ml medium .

Media was changed every two days. As the nerve pieces degenerated, fibroblasts began to spread onto the plate. When enough fibroblasts spread onto the plate in 5-7 days, the nerve pieces were

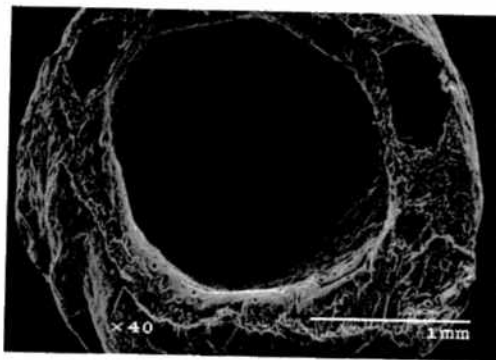


Fig. 3 SEM image of a PDLA conduit

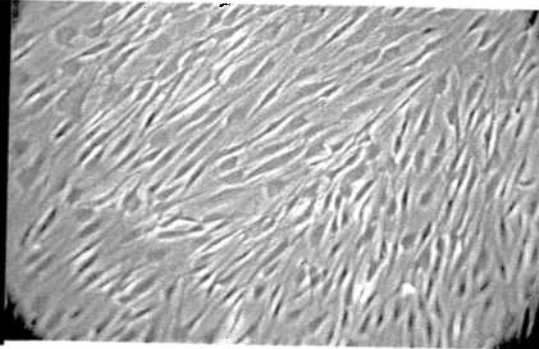


Fig. 4. Schwann cells in culture

transplanted onto new tissue culture plates using the above procedure. After 3 or 4 transplantations, the cells spreading from the nerve pieces consisted mostly of Schwann cells. At this point the nerve pieces were dissociated and then incubated for one hour at 37°C. The media and cell debris were removed and the remaining cells will be resuspended in 1 ml of fresh media. The cell suspension was placed in 75 cm<sup>2</sup> tissue culture flask and enough media was added. Cultures were determined to be greater than 95% pure by immunocytochemistry staining of S-100 protein.

**Schwann cell purification and seeding:** Schwann cell cultures were purified by removing the cells from a 75 cm<sup>2</sup> T-flask and adding 2 mL anti-Thy 1.1 media to the Schwann cells for 30 minutes and adding 1.5 mL rabbit sera complement for another 30 minutes. The cells were resuspended and fed with DMEM/10% FBS supplemented with 0.5 mM forskolin, 0.5 mM isobutylmethylxanthate (IBMX) and 0.1 µg/mL human heregulin-β1 (EGF domain). This combination reduced fibroblasts while greatly enhancing the proliferation of the Schwann cells. Cells were not passaged more than 2 times to reduce chances of immortalization of Schwann cells. Schwann cell numbers were determined by trypan blue exclusion using a hemacytometer.

The Schwann cells were frozen down until required. Just prior to the *in vivo* studies, the Schwann cells cultures were thawed, allowed to become confluent, and were injected into each of conduit lumens 24 hours prior to surgery to allow for adhesion.

### Animal studies

Following the *in vitro* studies, we have proceeded with the animal studies as planned. We originally obtained segments of cavernous nerve from several Sprague-Dawley rats and they were stored at -70°C and shipped on dry ice to our collaborators (Dr. Mallapragada) at Iowa State University. Attempts at schwann cell extraction from these nerves were not very successful as the cells did not grow well in culture. We then resorted to using sciatic nerve derived schwann cells as described above.

For most of the animal experiments we obtained aged rates (retired male breeders). The rats were divided into groups by type of procedure/implant as follows:

- |   |     |
|---|-----|
| 1. Controls/sham surgery                                  | n=5 |
| 2. Nerve resection  | n=5 |
| 3. Laminin coated polymer tube grafts                     | n=5 |
| 4. Genitofemoral nerve grafts                             | n=5 |
| 5. Laminin coated polymer tubes plated with Schwann cells | n=5 |

The animals underwent resection of 2mm of the cavernous nerve on either side after the nerve had been dissected out all the way to the pelvic ganglion. Following surgery/implantation, animals were observed for 2 months. All surgeries were performed under sterile conditions with ketamine/xylazine anesthesia initially followed by phenobarbitol anesthesia. An operating microscope with a 4x or 10x magnification was used for performing the surgery. The conduits as well as genitofemoral nerves were implanted using 10.0 nylon with a single suture at either end. The conduits (4mm long) were used as a sleeve to slide over the cut ends of the resected cavernous nerve. Laminin was applied to the conduits by injecting approx. 2mls of 10ug/ml solution (prepared in Earle's Balanced Salt Solution or PBS) into the middle of the conduit. Each tube was plated with 50,000 schwann cells. The Schwann cells were thawed and initially plated onto a T-25 flask with appropriate medium and used to plate the conduits after the second passage.

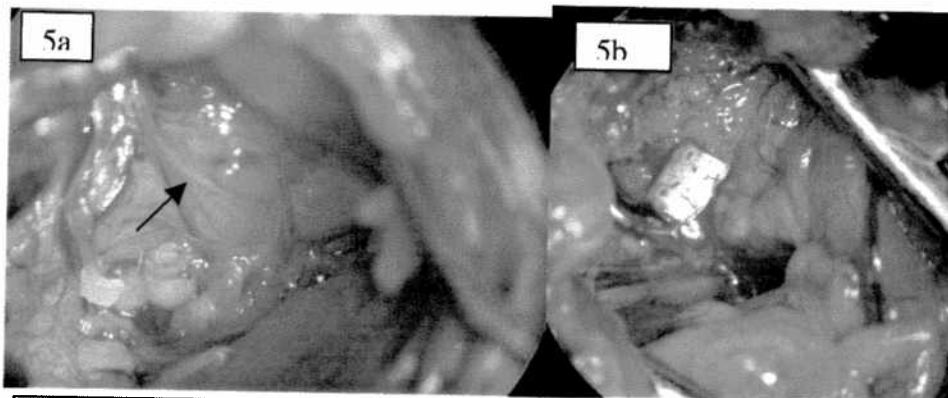


Fig. 5. Dissected cavernous nerve exiting pelvic ganglion in a rat shown by arrow (a). Implanted polymer conduit replacing resected cavernous nerve (b)

Approximately one week prior to the 2 month time point two rats from each of groups 1-4 and three rats from group 5 underwent injection of fluorogold into the corpus cavernosum of the penis. All of these

animals were sacrificed by phenobarbitol overdose one week later. We performed direct stimulation of the proximal end of the dissected cavernous nerve at the level of the pelvic ganglion to determine if we could elicit an erectile response from regenerated nerves. A Grass square wave generator was used as the power source and impulses at 4volts and a frequency of 20-60 Hz was delivered for 5-10 milliseconds. While no complete erections were observed, contraction of perineal musculature and penile tissue were observed visually in 60% of the animals. Following the electrical stimulation, cavernous nerve segments including the pelvic ganglion on each side were resected and submitted for histology. Immunofluorescence microscopy to assess for presence of fluorogold is currently pending. If the cavernous integrity has been restored or if there has been regrowth of the nerve, we expect to observe presence of fluorogold in the pelvic ganglion or proximal to the inserted nerve/conduit segment. Resected segment of cavernous nerve tissue from the other animals has been obtained and submitted for hematoxylin and eosin staining and will also be subjected to immunohistochemical analysis to look for nNOS expression using a polyclonal antibody to nNOS. These studies are currently underway.

#### KEY RESEARCH ACCOMPLISHMENTS (related to statement of work):

##### Task 1:

To determine if biodegradable polymers alone or when impregnated with laminin +/- polylysine can result in nerve growth in vitro and can be used as a cavernous nerve interposition graft in vivo.

1. Production of micropatterned PDFA sheets and impregnation with laminin +/- polylysine and quantitate extent and direction of neurite growth (months 1-6) **COMPLETED**
2. In vitro optimization of micropatterning to yield maximal directional neurite growth (months 7-12) **COMPLETED**
3. Perform cavernous nerve interposition grafts using genitofemoral nerve and micropatterned polymer PDFA tubule graft alone or impregnated with laminin +/- polylysine in a rat model (month 7-8) **COMPLETED**
4. Analyze return of cavernous nerve function in animals receiving no nerve grafts and those receiving nerve grafts using electrical stimulation, behavioral observation and nNOS expression (months 9-12). **ELECTRICAL STIMULATION ANALYSIS COMPLETED. HISTOLOGIC ANALYSIS IN PROGRESS. BEHAVIORAL OBSERVATION COMPONENT MODIFIED TO USE PENILE BLOOD PRESSURE MEASUREMENTS AS THAT IS THE MORE COMMONLY USED METHOD CURRENTLY.**

## CONCLUSIONS

We have able to successfully harvest and culture schwann cells in vitro. We have also developed biodegradable polymer conduits that have been optimized for groove size to facilitate maximal directional neurite growth. We have been able to successfully implant the conduits and replace the cavernous nerve in experimental animals. We are awaiting results of histologic examinations to determine the adequacy of nerve regrowth and recovery of physiologic function which will be evaluated in the next phase of the experiments where animals will be examined after a longer period of recovery.



## REFERENCES

1. Jemal A, Murray T, Samuels A, Ghafoor A, Ward E, Thun M. Cancer statistics 2003. *CA Cancer Clin.* 53-26, 2003.
2. Seidman H, Mushinski MH, Gelb SK, Silverberg E: Probabilities of eventually developing or dying of cancer - United States, 1985. *CA - Cancer J Clin* 35:36-56, 1985.
3. Levine RL, Wilchinsky M: Adenocarcinoma of the prostate: a comparison of the disease in blacks versus whites. *J Urol* 121:761-762, 1979.
4. Catalona WJ: Nerve-sparing radical retropubic prostatectomy. *Urol Clin N Am*, 12:187-199, 1985.
5. Catalona WJ, Dresner SM: Nerve-sparing radical prostatectomy: extraprostatic tumor extension and preservation of erectile function. *J Urol*, 134:1149-1151, 1985.
6. Elder JS, Jewett HJ, Walsh PC: Radical perineal prostatectomy for clinical stage B2 carcinoma of the prostate. *J Urol*, 127:704-706, 1982.
7. Walsh PC: Radical prostatectomy, preservation of sexual function, cancer control: the controversy. *Urol Clin N Am*, 14(4):663-673, 1987
8. Walsh PC, Jewett HJ: Radical surgery for prostatic cancer. *Cancer*, 45:1906-1911, 1980.
9. Walsh PC, Mostwin JL: Radical prostatectomy and cystoprostatectomy with preservation of potency: results using a new nerve-sparing technique. *Br J Urol*, 56:694-697, 1984.
10. Rudy DC, Woodside JR, Crawford ED. Urodynamic evaluation of incontinence in patients undergoing modified Campbell radical retropubic prostatectomy: a prospective study. *J Urol* 132:708-712, 1984.
11. Walsh PC, Donker PJ. Impotence following radical prostatectomy: insight into etiology and prevention. *J. Urol.* 128:492, 1982.
12. Eggleston JC, Walsh PC: Radical prostatectomy with preservation of sexual function: pathological findings in the first 100 cases. *J Urol*, 134:1146-1148, 1985.
13. Steiner MS, Morton RA, Walsh PC: Impact of anatomical radical prostatectomy on urinary incontinence. *J Urol*, 145:512-514, 1991.
14. Quinlan DM, Epstein JI, Carter BS, Walsh PC. Sexual function following radical prostatectomy: influence of preservation of neurovascular bundles. *J Urol*, 145: 998,1991.
15. Geary ES, Dendinger TE, Freiha FS, Stamey TA. Nerve sparing radical prostatectomy: a different view. *J Urol*, 154:145-9, 1995.
16. Rabbani F, Stapleton AMF, Kattan MW, Wheeler TM, Scardino PT: Factors affecting recovery of erections after radical prostatectomy. *J Urol*, 164:1929-1934, 2000.
17. Catalona WJ, Carvahal GF, Mager DE, et al. Potency, continence and complication rates in 1,870 consecutive radical prostatectomies. *J. Urol.* 162:433-438, 1999.
18. Talcott JA, Rieker P, Propert KJ, et al. Patient reported impotence and incontinence after nerve sparing radical prostatectomy. *J. Natl. Cancer Inst.* 89:1117-1123, 1997.
19. Graefen M, Haese A, Pichlmeier U, Hammerer PG, Noldus J, Butz K, Erbersdobler A, Henke RP, Michl U, Fernandez S, Huland H. *J Urol*, 165:857-863, 2001.
20. Hull GW, Rabbani F, Abbas F, Wheeler TM, Kattan MW, Scardino PT. Cancer control with radical prostatectomy alone in 1000 consecutive patients. *J Urol*, 167:528-534, 2002.
21. Schoenberg MP, Walsh PC, Breazeale DR, Marshall FF, Mostwin JL, Brendler CB. Local recurrence and survival following nerve sparing radical cystoprostatectomy for bladder cancer: 10-year followup. *J Urol*, 155:490-494, 1996.