

Trauma Induced Pain and Wound Management in Emergency Environment by Low Energy Photonic Therapy

Dr Natasha Salansky (Filonenko), PhD, DAc

International Medical Instruments Inc
202-72 Steeles Ave. W., Toronto, ON, A4J 1A1
Tel: (416) 667-8330
Fax: (416) 667-1416

E-mail: nsalansky@rogers.com

Dr Anthony Galea, MD

Institute of Sport Medicine & Wellness Centre Inc
2 Gibbs Road #2, Toronto, ON, M9B 6L6
Tel: (416) 620-6861
Fax: (416) 620-9774

E-mail: anthonygalea@aol.com

Dr Norman Salansky, PhD

International Medical Instruments Inc
202-72 Steeles Ave. W., Toronto, ON, A4J 1A1
Tel: (416) 667-8330
Fax: (416) 667-1416

E-mail: imi@interlog.com

ABSTRACT

Low Energy Photonic Therapy (LEPT) is a new non-drug, non-invasive treatment modality for acute trauma and wound healing acceleration that utilizes monochromatic light. Various monochromatic optical sources (lasers, laser diodes and light emitting diodes) are used for LEPT. LEPT can be applied immediately after trauma. LEPT is administered with a short-term goal to achieve fast resolution of symptoms (pain, swelling, and inflammation) and function improvement. In a long run LEPT is expected to result in faster quality healing and function recovery (after trauma or surgery). A number of clinical studies on LEPT efficacy for wound healing, pain relief, and musculoskeletal conditions were performed using LEP2000 multi-modality therapeutic system for LEPT (IMI Inc., Toronto).

A large body of cellular and animal studies suggests that monochromatic light can activate phenomena vital for body healing. The effects induced by monochromatic light in cells could be of substantial magnitude, e.g., a 1.9-fold increase in cellular ATP or 3-fold increase in percentage of dividing fibroblasts and keratinocytes. Animal (rat, porcine) models confirm substantial (by 25-70%) acceleration of wound healing by LEPT. In a porcine wound model we discovered immunomodulation phenomena that resulted in faster resolution of systemic inflammation and wound healing in wounded (140 wounds) animal treated by LEPT. Animal studies

Paper presented at the RTO HFM Symposium on "Combat Casualty Care in Ground Based Tactical Situations: Trauma Technology and Emergency Medical Procedures", held in St. Pete Beach, USA, 16-18 August 2004, and published in RTO-MP-HFM-109.

Report Documentation Page

Form Approved
OMB No. 0704-0188

Public reporting burden for the collection of information is estimated to average 1 hour per response, including the time for reviewing instructions, searching existing data sources, gathering and maintaining the data needed, and completing and reviewing the collection of information. Send comments regarding this burden estimate or any other aspect of this collection of information, including suggestions for reducing this burden, to Washington Headquarters Services, Directorate for Information Operations and Reports, 1215 Jefferson Davis Highway, Suite 1204, Arlington VA 22202-4302. Respondents should be aware that notwithstanding any other provision of law, no person shall be subject to a penalty for failing to comply with a collection of information if it does not display a currently valid OMB control number.

1. REPORT DATE 01 SEP 2004	2. REPORT TYPE N/A	3. DATES COVERED -	
4. TITLE AND SUBTITLE Trauma Induced Pain and Wound Management in Emergency Environment by Low Energy Photonic Therapy		5a. CONTRACT NUMBER	
		5b. GRANT NUMBER	
		5c. PROGRAM ELEMENT NUMBER	
6. AUTHOR(S)		5d. PROJECT NUMBER	
		5e. TASK NUMBER	
		5f. WORK UNIT NUMBER	
7. PERFORMING ORGANIZATION NAME(S) AND ADDRESS(ES) International Medical Instruments Inc 202-72 Steeles Ave. W., Toronto, ON, A4J 1A1		8. PERFORMING ORGANIZATION REPORT NUMBER	
9. SPONSORING/MONITORING AGENCY NAME(S) AND ADDRESS(ES)		10. SPONSOR/MONITOR'S ACRONYM(S)	
		11. SPONSOR/MONITOR'S REPORT NUMBER(S)	
12. DISTRIBUTION/AVAILABILITY STATEMENT Approved for public release, distribution unlimited			
13. SUPPLEMENTARY NOTES See also ADM001795, Combat Casualty Care in Ground-Based Tactical Situations: Trauma Technology and Emergency Medical Procedures (Soins aux blessés au combat dans des situations tactiques : technologies des traumatismes et procédures médicales d'urgence), The original document contains color images.			
14. ABSTRACT			
15. SUBJECT TERMS			
16. SECURITY CLASSIFICATION OF:			17. LIMITATION OF ABSTRACT
a. REPORT unclassified	b. ABSTRACT unclassified	c. THIS PAGE unclassified	UU
			18. NUMBER OF PAGES 36
			19a. NAME OF RESPONSIBLE PERSON

demonstrating acceleration and improved quality of healing by LEPT in various tissues (skin, muscles, tendons, bones, and nerves) will be presented. Recovery of median nerve function with LEPT as measured by nerve conduction test was demonstrated in a clinical trial in patients with carpal tunnel syndrome. Double blind study (DBS) on LEPT for chronic wounds confirmed 3.4-fold acceleration of wound healing in the LEPT-treated group. Another controlled clinical trial confirmed 1.79-fold acceleration of wound healing in LEPT-treated group that was accompanied by substantial pain relief.

Two double blind clinical studies and a number of open protocol studies demonstrated fast and substantial (by 30-100%) pain relief using LEPT. In a recent DBS involving 72 subjects with post-traumatic pain around joints LEPT resulted in a 4-fold greater pain relief as compared to therapeutic ultrasound. Anecdotal clinical evidence suggests that if LEPT is applied within 4 hours after injury, the recovery is extremely fast for injuries of ISS<9. If LEPT is applied within 72 hours after injury, a 2-3-fold acceleration in recovery is possible. No adverse effects were reported from using LEPT.

LEPT could be self administered by injured personnel. A portable device for LEPT delivery in a field environment is described. Visual materials of fast healing with LEPT will be presented. In summary, presented data suggest that LEPT induces fast pain relief, function and mobility improvement in operational environment after injuries of ISS<9, and accelerated quality rehabilitation to bring the soldier back to duties after injury.

Part of the research presented in this paper was supported by the Department of National Defence of Canada (DIR Program), National Research Council of Canada, and Defence & Civil Institute of Environmental Medicine of Canada.

1. BASIC CONCEPTS AND ADVANTAGES OF LOW ENERGY PHOTONIC THERAPY FOR ACUTE TRAUMA

1.1 State Of The Art In Pain And Acute Trauma Management

Despite recent breakthrough in basic research in medicine, there are no effective treatments for musculoskeletal pain available. The conclusion of a recent review on pharmacological pain treatment for musculoskeletal disorders was that “the effectiveness of currently available drugs in the treatment of musculoskeletal pain conditions is disappointing”.¹

Authors of a recent review on the efficacy of current non-pharmacological treatments for musculoskeletal pain (ultrasound, electrotherapy, acupuncture, etc.) made a conclusion: “There seems to be evidence from basic science research to suggest that many of the therapies could have potentially therapeutic effects. However, there appears to be limited high-quality evidence from randomised clinical trials to support the therapeutic effectiveness of these therapies²”.

A group of “Quebec Task Force on Whiplash” analysed over 10,000 abstracts and articles in an attempt to identify effective treatment/s for acute whiplash injury³. They did not find conclusive evidence in clinical trials that would support the efficacy of current treatment modalities for acute whiplash injury, except exercises and mobilization.

Current paradigm of treatment for acute injury comprises passive modalities: rest, icing, elevation, and compression (RICE). There is no other effective conventional therapy currently available within the first

24-48 hours after trauma. As a result, the “golden hour” for the treatment is missed, an injured tissue condition rapidly deteriorates and recovery takes a long time.

1.2 What Is Low Energy Photonic Therapy? Integrated Clinical Protocols Of LEPT

Low Energy Photonic Therapy (LEPT) is a new non-invasive multi-facet modality for pain relief and soft tissue healing acceleration that involves the irradiation of tissue with monochromatic light at intensities that do not cause thermal changes or ionisation in tissues. Low-energy photons (LEPs) are quanta of monochromatic electromagnetic waves in the visible (400-700nm) and near-infrared (700-1100nm) ranges of wavelengths. Unlike high-energy photons (ultraviolet or X-Ray), LEPs have much less ($< 2\text{ev}$) energy than needed to break chemical bonds or ionise biomolecules. Different monochromatic optical sources (lasers, laser diodes and light emitting diodes) can be used for LEPT depending on the particular application^{4,5,6,7,8,9,10}. Low Energy (Low Level) Laser Therapy is a subset of LEPT.

For a medicine to be effective an appropriate dose must be administered. This also applies to physical modalities but is often ignored to the detriment of patient response and the validity of clinical trials. As a result of basic and clinical research supported by the Canadian Government, Drs. Norman and Natasha Salansky discovered^{11,12} that:

- Specific sets of optical parameters of low energy photons are required to produce significant improvement for various soft tissue pathologies (e.g., ischemia, swelling, acute, sub-acute or chronic inflammation). These sets of optical parameters include specific wavelength and bandwidth, modulation frequency, pulse duration and duty cycle, optical fluence and fluence rate, and three-dimensional photon distribution within the tissue. These sets of optical parameters are called “therapeutic optical windows” (TOW).
- To achieve substantial acceleration of healing for particular medical condition (e.g., acute trauma, tendonitis) it is required to combine several specific sets of optical parameters (TOWs) that work in synergy to produce maximum therapeutic effect. Combined therapy is provided by the integrated clinical protocols of LEPT.

The above concepts, the knowledge of “therapeutic optical windows” and integrated clinical protocols have been implemented in the medical device LEP2000 Multi-Modality Therapeutic System (IMI Inc., Toronto) for LEPT. A portable field unit with similar efficacy was developed for the use by the injured person. The field unit is small (cigarette pack size), light (less than 0.5 pounds), simple to use (a push button to activate requested optical protocols) and is battery operated. The unit is built using surface mount technology and it has demonstrated same level of efficacy for a specific application as the office unit.

LEP2000 Multi-Modality Therapeutic System has been used in all our basic and clinical research presented in this paper.

1.3 Basic Concepts In Pain Research. Innovation And Advantages Of Drs. Salansky’s Integrated LEPT Protocol For Acute Trauma

There are multiple pathologies that contribute to pain, soft tissue pathology, and function impairment after trauma (e.g., cell ischemia). The following basic approaches to the treatment of pain could be considered:

1. To attenuate or abolish transmission and/or reception of pain signal
2. To improve soft tissue pathologies that cause pain and accelerate tissue healing
3. A combination of 1 & 2.

The vast majority of current research on new therapies for pain relief is focused around the first approach in attempts to induce inhibitory control over pain transmission or pain receptors. However, despite the explosion of new knowledge in pain processing and in molecular background for neuroplasticity, this progress has unfortunately not resulted in a radical improvement of the ability to treat pain.

We use for pain control and soft tissue healing acceleration after acute trauma special integrated protocol of LEPT (Drs. Salansky's protocol) that is aimed to improve soft tissue pathologies as well as to induce a release of pain-relieving biomolecules (a combination of the above approaches 1 & 2, see section 4.4). This protocol of LEPT consists of several specific procedures that are aimed to improve specific soft tissue pathologies (e.g., reduce cell ischemia, swelling) involved in acute trauma. These treatment procedures used in sequence one after another and include applications of single and cluster optical probes with required sets of optical parameters to the injured area.

Clinical research suggests that proposed integrated protocol of LEPT results not only in fast pain relief after an acute trauma: this protocol also appears to accelerate both inflammatory and repair phases of soft tissue healing and a functional recovery after an acute trauma. The acceleration of soft tissue healing is believed to be a direct result of the targeted by LEPT healing mechanisms involved and synergy between them. Advantages of the proposed integrated LEPT protocol for acute trauma include:

- It is non-invasive, no side effects, safety is proven.
- The treatment procedure is short, comfortable, simple (anybody could be trained to use it) and could be applied immediately after injury with or without ice.
- Uses synergy between several "therapeutic optical windows". Results in extensive set of therapeutic effects (pain, swelling, inflammation relief).
- Pain relief and function improvement is almost immediate.

This integrated LEPT protocol is hypothesized to produce both antinociceptive effect and, in addition, acceleration of soft tissue healing and function recovery.

1.4 Early Intervention With LEPT Is Critical. 3-Hour And 72-Hour Time Windows To Achieve Substantial Acceleration Of Recovery After Acute Trauma

Substantial therapeutic benefits of LEPT can be achieved at any stage (acute, sub-acute, or chronic) after acute trauma. Drs. Salansky's integrated clinical protocols are adjusted accordingly to the stage of the healing process. However, clinical research indicates that early LEPT treatment is critical to achieve maximum therapeutic benefits, immediate pain relief and fastest function recovery. LEPT could be applied immediately after trauma in combination with or without ice. Clinical data suggest that there appear to be 2 time "windows" where the most extensive therapeutic benefits are achieved.

The best time window is to administer LEPT within 3 hours after trauma.

If LEPT was administered within 3 hours after trauma, in many cases of Grade 1 sprain/strain injuries immediate complete resolution of symptoms and function recovery was observed, as the injury has never happened, and swelling and inflammation did not develop. In most cases of injuries (Grade 2, ISS<9) LEPT resulted in extremely fast resolution of symptoms.

If LEPT was administered within 72-hour window after trauma (preferably within 24-hours after trauma) the following results for Grade 1& 2 sprains/strains (ISS<9) were obtained:

- 30-60% pain relief and substantial improvement of function after a single treatment
- 50-100% pain relief and 50-100% function recovery after 2-4 LEPT treatments within 96 hours. In cases of partial tendon tear (Grade 2 sprains), substantial acceleration of symptom

resolution and function recovery was observed, however, the actual tendon healing took longer as it was tested using diagnostic ultrasound

- early LEPT intervention appears to prevent the development of chronic conditions after injuries.

2. BACKGROUND FOR THE USE OF LEPT IN REHABILITATION MEDICINE. BASIC RESEARCH (*IN VIVO*, *IN VITRO*)

2.1 General Comments On LEPT Mechanisms

A large body of cell culture and animal studies suggests that low energy photons (LEPs) can affect a broad range of biological processes vital for tissue healing. Unlike allopathic medicine, low energy photons with appropriate parameters can induce simultaneously a broad range of interconnected and interrelated photo induced phenomena at different levels of biological structures: cellular, tissue, and systemic. Substantial scientific evidence has been accumulated that low energy photons with specific parameters can induce acceleration of healing and improvement of quality of repair in various body tissues:

- Skin
- Muscles
- Nerves
- Connective tissue (tendons and ligaments)
- Bones.

Comprehensive analysis of mechanisms and therapeutic effects of LEPT in various tissues will be presented in the book “LOW ENERGY PHOTONIC AND LASER THERAPY: basic science, dosimetry, clinical applications, new developments”¹³.

As an example, we would like to outline the photo induced healing phenomena that can be observed in nerve tissue (based primarily on the research¹ by S. Rochkind and associates):

- Immediate protective effects which increase the functional activity of the injured peripheral nerve
- Maintenance of functional activity of the injured nerve
- Reduced scar tissue formation at the injured site
- Reduced degeneration in corresponding motor neurons of the spinal cord
- Stimulation of axonal growth and myelination
- Activation of Schwann cell proliferation
- Enhancement of sprouting of nerve processes.

The effects induced by LEPs in cells could be of substantial magnitude. Below are several examples of such magnitude effects induced by LEPs in vitro:

- Two to five-fold increases in growth-phase-specific DNA synthesis in normal fibroblasts, muscle cells, osteoblasts, and mucosal epithelial cells in tissue cultures¹⁴
- A 1.9-fold increase in cellular ATP¹⁵. Two to three-fold increase in percentage of dividing fibroblasts and keratinocytes¹⁶
- Four-fold increase in procollagen production in human skin fibroblast cultures¹⁷. Three-fold increase in keratinocyte motility¹⁸

¹ The references can be easily found in appropriate data bases.

- Five-fold increase in IL-8 and 2.3-fold increase in IL-1 α and their respective mRNA expressions by human keratinocytes¹⁹

Substantial therapeutic effects or favourable alterations of cellular or tissue processes could be induced by LEPs only using specific protocols (sets of optical parameters and an appropriate three-dimensional (3D) photon distribution within the target tissue). We call them “therapeutic optical windows”. In the next section we will describe more in depth LEPT phenomena specific for wound healing acceleration.

2.2 Basic Photo Induced Phenomena Vital For Wound Healing

2.2.1 LEPT *In Vitro*

2.2.1.1 Effects of LEPT on keratinocytes

Keratinocyte motility and proliferation have been found to increase after helium-neon (HeNe) laser (632.8 nm) irradiation^{20,21}. HeNe laser irradiation (0.5, 1, and 1.5 J/cm²) also has been shown to enhance the release of IL-1 α and IL-8 from cultured human keratinocytes²². Maximum secretion (4.2-fold increase in both IL-1 α and IL-8) of cytokines was observed at 1.5 J/cm². Significant inhibition of kidney epithelial cell proliferation by a HeNe laser at much higher doses (12-140 J/cm²) has been reported²³.

2.2.1.2 Effects of LEPT on fibroblasts and collagen production

Numerous studies have shown increased fibroblast proliferation, collagen formation after exposure to laser irradiation^{24,25,26,27,28,14}, while other studies failed to find any alterations^{29,30}.

2.2.1.3 Effects of LEPT on the immunocompetent cells

Bacterium phagocytosis of leukocytes was considerably increased by a pulsed ruby laser (694.3 nm, pulse duration 1ms) *in vitro* at an energy density of 0.05 J/cm² and inhibited at energy densities of (2-4 J/cm²).⁴ Young demonstrated that macrophages release factors that stimulate fibroblast proliferation *in vitro* after exposure to LEPT at wavelengths of 660 nm, 820 nm, and 870 nm³¹. When stimulating human peripheral blood monocytes with mitogens after the irradiation with HeNe laser substantial alterations of interleukin-1 α , interleukin-2, tumour necrosis factor- α , and interferon- γ levels in the supernatants of the cultures were observed³². Significantly increased levels of all cytokines were detected after 30 min of irradiation (18.9 J/cm²), whereas after 60 min of irradiation (37.8 J/cm²) cytokines levels were found significantly decreased. Yu et al found that LEPs (660nm) enhanced secretion of basic fibroblast transforming growth factor (bFGF) by cultured fibroblasts³³ in a dose dependent manner. Substantial increase (by 180-250%) of both spontaneous and Candida-induced reactive oxygen species (ROS) release by spleen phagocytes after an exposure to HeNe laser with energy densities of 10-30 mJ/cm² was reported by Dr. Karu’s group³⁴. Neutrophil chemotaxis was substantially depressed by HeNe laser irradiation with energy densities of 1, 2, and 4 J/cm²³⁵.

2.2.2 LEPT *In Vivo*. Effects Of LEPT On Healing Of Animal Model Wounds

There is clear evidence that LEPT does modify cellular activity (rate of ATP, DNA, RNA and protein synthesis, reproduction rate and cell secretion) *in vitro*, depending on the specific wavelength and optical parameters, but the current literature paints an indistinct picture of its *in vivo* effectiveness in wound healing.^{36,37,38,39,47,48,49,50} Several studies showed significant increase in tensile strength of laser-treated wounds^{40,41,42,27}, enhanced leukocyte infiltration and fibroblast proliferation⁴³, epidermal thickening⁴⁴, dermal vascularity⁴³, and early epithelialization^{43,44} after HeNe laser irradiation of wounds in rabbits, rats and guinea

pigs. Several authors reported acceleration of wound healing in albino rats⁴³ (632.8 nm, 4 J/cm²) and white mice⁴⁵ (694.3 nm, 1.4 and 5 J/cm²), and burn healing in white mice (694.3 nm, 1.1 J/cm²)⁴⁵ after LEPT. Irradiation with either HeNe laser or non-coherent lamp of the same wavelength accelerated healing of full thickness wounds in rats, while Argon laser failed to do so⁴⁶. Although the above early studies in loose-skinned animals (mainly rats, mice and rabbits) could show benefit on wound healing after LEPT, there were conflicting results from other studies that failed to show any significant improvement^{47,48,49}. Unfortunately, the comparison between the above studies is difficult, since optical parameters used were different. Although some of them had positive results, their validity was limited since most of them were either poorly controlled or were performed in loose-skinned animal models. Loose-skinned animals, such as rats, rabbits, dogs and guinea pigs are less adequate models for human wound healing, since they heal primarily through contraction, while tight-skinned animals, like pigs or human, heal primarily through epithelialization. We are aware of only a few studies on the effect of LEPT on wound healing in pigs^{28,38,50}. Two of them failed to show any effect of LEPT on wound healing in pig models while a 6.5-fold increase in type I procollagen levels was observed in the skin of pigs treated with HeNe laser in the third one.

Another series of studies on the acceleration of wound healing by LEPT in Sprague-Dawley (SD) rat model of normal wound healing were accomplished by Al-Watban et al^{51,52,53,54}. Acceleration of wound healing was achieved using HeNe laser with energy densities of 7 to 60 J/cm², while doses outside this range were found to be ineffective. Maximum acceleration (by 33% in days to complete healing and by 54% in size reduction) was achieved at the optimal dose of ~ 25 J/cm². Argon laser (514 nm) was found to induce an acceleration of wound healing in SD rats with doses of 7 to 60 J/cm². HeNe laser was found to be more effective for wound healing than Argon laser. Doses higher than 130 J/cm² inhibited wound healing. Two studies reported beneficial effect of LEPT for compromised wound healing. Statistically significant difference in the rate of healing of wounds contaminated with *Staphylococcus aureus*⁵⁵ was observed in the LEPT (904 mW, 76.4 mJ/cm²) treated group of SD rats. Yu et al⁵⁶ used genetically diabetic mice to compare the effect of bFGF, LEPT (630 nm, 5 J/cm²), and a combination of the growth factor and LEPT. Their results indicated that all three treatments significantly enhanced wound closure, with LEPT alone or in combination with topical application of bFGF being most effective. Histological evaluation showed higher leukocyte infiltration at the initial stage of wound healing, improved wound epithelialization, granulation tissue formation, and collagen deposition in LEPT group as compared to the control.

3. BACKGROUND FOR THE USE OF LEPT IN REHABILITATION MEDICINE. CLINICAL RESEARCH

3.1 General Comments On LEPT Dosimetry

3.1.1 Low Energy Lasers (LELs) Showed Promise As A Possible Therapeutic Modality For Acceleration Of Soft Tissue Healing And Pain Relief. Inconsistency Of Clinical Results.

A large body of *in vitro* and some animal studies that had been accumulated by 1990 demonstrated a surprisingly broad spectrum of photo-induced phenomena in mammalian cells and mammals by so-called low energy lasers (LELs). Many scientists supported the idea that LELs could be used for the acceleration of soft tissue healing and pain relief. However, most attempts to confirm putative therapeutic effects of LELs in rigorous controlled clinical trials failed^{57,58,59,60,61}. Brockhaus and Elger did confirm analgesic effect of needle acupuncture and did not find any analgesia using laser acupuncture. There were a number of negative controlled and double blind studies on the use of LELs for pain and musculoskeletal pathologies published.

3.1.2 Is Coherence And Polarization Important For Healing Phenomena? Dosimetry Is Critical.

In 1985, Dr. Salansky embarked upon the most fundamental aspects of light-biotissue interaction in an attempt to understand the real therapeutic potential of LELs and the reasons of the clinical failures^{62,63,64,65,66,67,68}. This research was initially supported by NRC of Canada and, later on, by DoD of Canada.

One of the basic questions was whether or not the coherence and polarization (specific laser features) was essential for photobiomodulation phenomena? Dr. Salansky discovered that a laser beam quickly loses its coherency and polarization in the biological tissue, except speckles, because of scattering phenomena and forwarded a hypothesis that coherence and polarization may not be important for many biomodulating effects of LEP irradiation. Several scientists presented data supporting this hypothesis, which is generally accepted today. There were enormous ramifications of this discovery, including the possibility of creating a therapeutic device based on light emitting diodes (LEDs, not on lasers) that could safely be used by patients for self-treatment.

Unlike plant cells, mammalian cells could exhibit dramatic responses to LEPs only within very specific narrow ranges of optical parameters. However, the incident optical parameters are very different from those that are actually “seen” by the skin cells because of photon scattering, absorption, reflection, and refraction. This could substantially affect *in vivo* dosimetry of LEPT (sets of optical parameters including wavelength, three-dimensional light (3D) distribution of photon fluence and fluence rate, modulation frequency, etc.). Therefore, theoretical analysis of 3D distribution and laser/LED induced temperature changes within the skin was initiated using several mathematical and computer approaches (diffusion approximation, Monte Carlo, etc.)^{69,70}. Based on these theoretical calculations and the data from *in vitro* and *in vivo* studies we created the first LEPT clinical protocols for wound and soft tissue healing acceleration for further testing in animal and clinical studies.

As a result of photon scattering and absorption, a complex 3D distribution within the tissue takes place. A classical approach to photon distribution modelling in the tissue is based on Monte-Carlo (MC) algorithm.^{71,72} However, this approach does not permit to obtain photon distribution for different optical source parameters in real time. A neural network (NN) approach was developed^{73,74} which could be used for fast multi-parametrical solutions. We combined MC modelling with the NN approach for fast 3D photon distribution observation in the tissue in real time and adjusted the clinical protocols accordingly providing high efficacy.

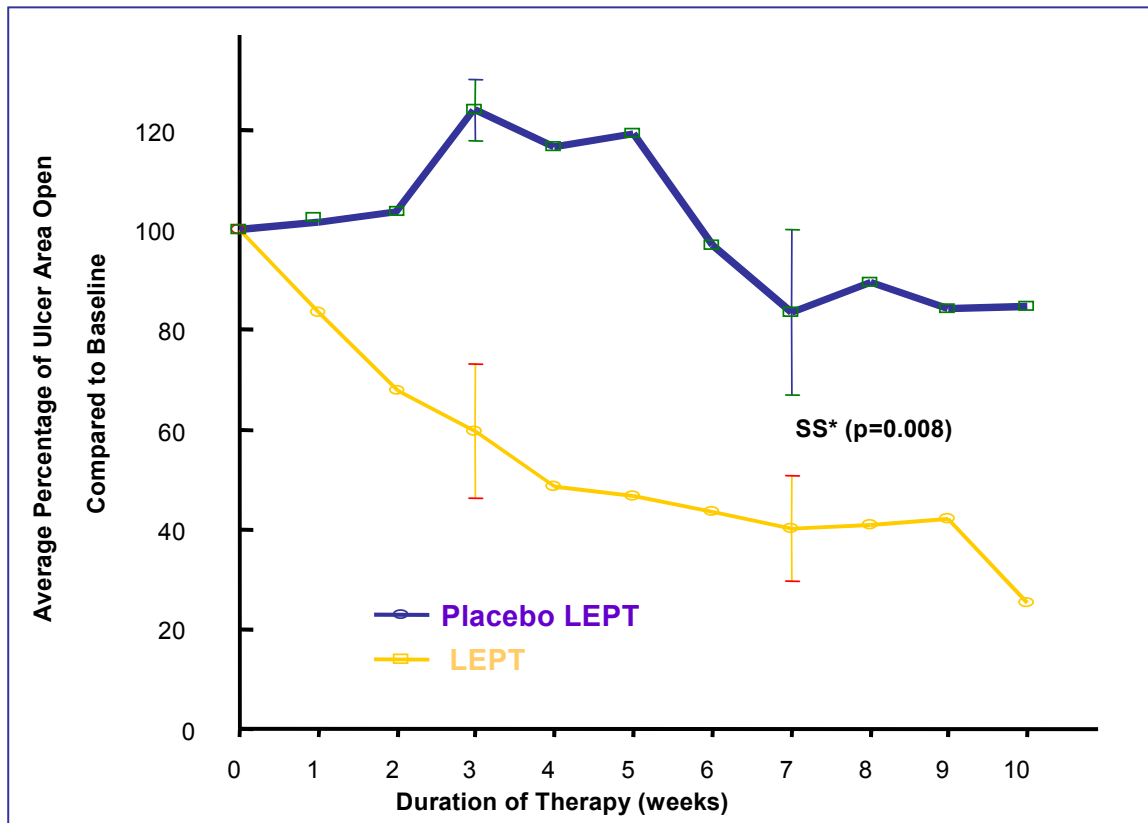
3.2 Effects Of LEPT On Healing Of Human Wounds

Mester et al reported the first encouraging results on the use of LEPT for wound healing. As a result of an uncontrolled clinical trial on the use of HeNe (632 nm) and Argon (488 nm) lasers for wound healing, he reported 78% of complete healing of recalcitrant ulcers of different etiology⁴. In a series of case studies and an uncontrolled clinical trial Schindl et al. demonstrated complete healing of recalcitrant ulcers of several etiologies (diabetes, arterial insufficiency, radiation damage, and autoimmune vasculitis) with the use of LEPT^{75,76}. Dr. Salansky’s group reported complete healing or substantial improvement of 75% of chronic and bacteria contaminated leg ulcers in uncontrolled clinical trials^{7,8}.

However, numerous attempts to prove efficacy of low energy lasers for wound healing in well controlled randomised comparative clinical trials have failed^{77,78,79,80}. There are only a few controlled clinical studies that provide some evidence of beneficial effects of LEPT for wound healing^{81,82,83}. LEPT has been shown to be beneficial for improving skin circulation at patients with diabetic microangiopathy, diabetic

ulcers or gangrenes in a randomised double blind controlled study by Dr. Schindl's group. Another, well-controlled study demonstrated that if given prophylactically LEPT could lessen the severity of mucositis experienced by patients undergoing chemotherapy.

Fig.1 Mean Percentage Of Ulcer Area Open Compared To Baseline

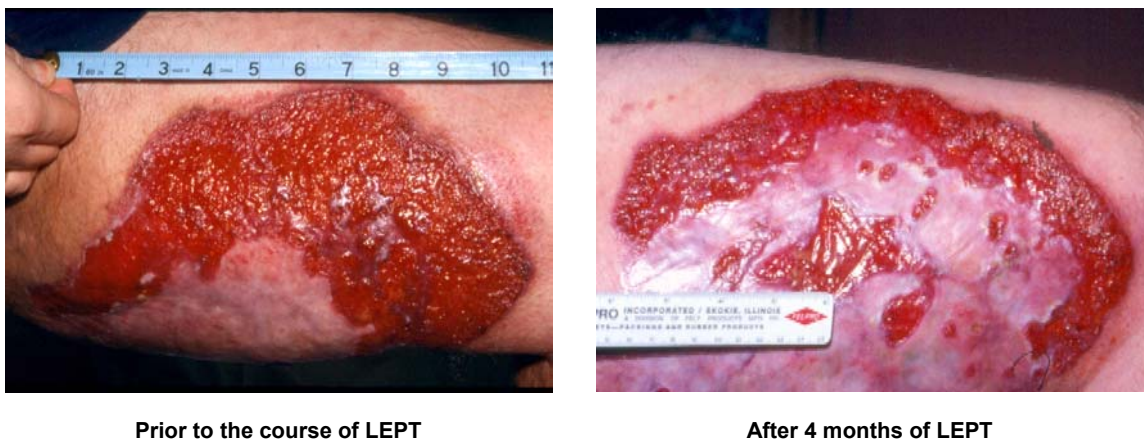


* SS - statistically significant difference

Jointly with the University of Toronto Dr. Salansky's group demonstrated statistically significant superior efficacy of LEPT for chronic venous skin ulcers as compared to placebo in a recent double blind, small sample study. In this study nine patients with a total of twelve venous ulcers were randomised to either a LEPT treatment group or to placebo. The patients who were randomised to placebo treatment received placebo irradiation from an identical appearing light source from the same delivery system. In addition to LEPT both groups received wound care consisting of regular saline rinse followed by dry gauze dressing. The LEPT treatment group received therapy with two wavelengths, 660 nm and 880 nm, for 10 weeks. The ulcers were evaluated in weeks 0, 3, 7 and 10. The clinical parameters used for comparative healing were: change in ulcer area compared to baseline, percentage of ulcer area that remained unhealed, rate of ulcer healing (mm²/week). LEPT was found to be significantly more effective than placebo at weeks 3, 7 and 10, when the efficacy parameters were: change in ulcer area, percentage of ulcer area that remained unhealed. At week 10 (end of the study) patients receiving LEPT had extensive healing of their wounds. Only 24% of their wound area remained unhealed at 10 weeks compared to 85% in the control (see Fig. 1).

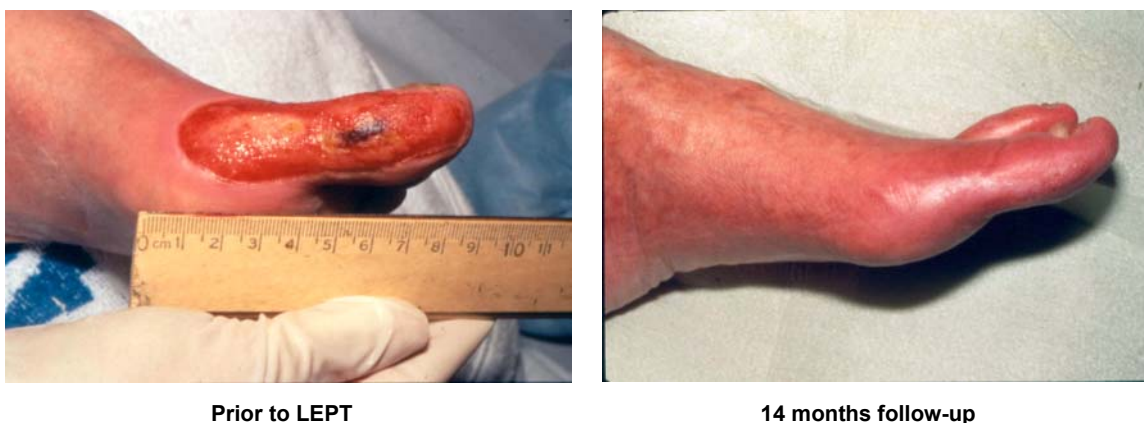LEPT was reported in this trial to significantly decrease pain associated with leg ulcers. In most cases of chronic skin ulcers treated with LEPT in Canada significant pain relief was reported within first 2 weeks of LEPT. In one case², 50-year-old male had been suffering from pyoderma gangrenosum ulcer for 10 years. He experienced excruciating pain and had to take narcotic Darvocet, 1-2 tablets every 4 hours in conjunction with 3-4 Advil every 2 hours in between. After 10 LEPT sessions the patient was free of narcotic. After 4 months of LEPT 60% of the ulcer healed (see Fig. 2).

Fig. 2. LEPT Took off the Patient from Narcotic Medication



LEPT appears to be effective for chronic skin wounds of different etiology (venous insufficiency, decubitus, vasculitis, radiation) including diabetic. Below is a picture of an infected diabetic ulcer in a 72-year-old male that successfully healed after 25 sessions of LEPT³(see Fig. 3).

Fig. 3. Infected Diabetic Ulcer in a Patient with CVD



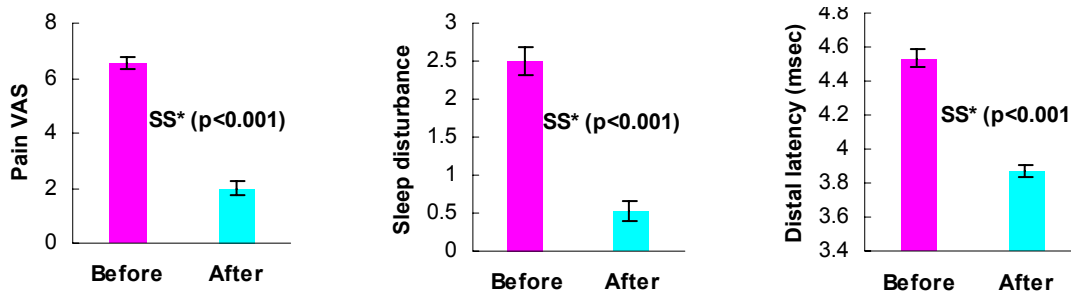
² Courtesy of Scarborough Hospital, General Division (Toronto)

³ Courtesy of Scarborough Hospital, General Division (Toronto)

3.3 LEPT Is Effective For The Restoration Of Median Nerve Conduction And Resolution Of Symptoms In Patients With Carpal Tunnel Syndrome (CTS)

Carpal tunnel syndrome is a debilitating painful disease with high prevalence in many industries that require a lot of manual work. For instance, a staggering seventy-five percent of army dental hygienists reported having hand problems, and 56% exhibited probable or classic symptoms of CTS in a recent study⁸⁴. Jointly with the University of Toronto, we accomplished a prospective, open protocol clinical trial investigating if abnormal median nerve conduction could get restored in patients with persistent CTS⁶. This trial was a new development from our previous clinical study⁸⁵ that resulted in a complete resolution of symptoms in 15 (71.4%) patients with CTS after a course of LEPT. Upon completion of a course of LEPT treatment, most patients experienced substantial pain relief and improvement of their sleep at night (see Fig.4). In addition, normalization of mean median nerve latency from pre-treatment mean value 4.68msec (range 4.0-6.0) to 3.99msec (range 3.5-4.3) suggests a healing effect of LEPT on nerve regeneration (see Fig.4).

Fig. 4. LEPT efficacy for pain relief, sleep restoration, and nerve function recovery in patients with CTS

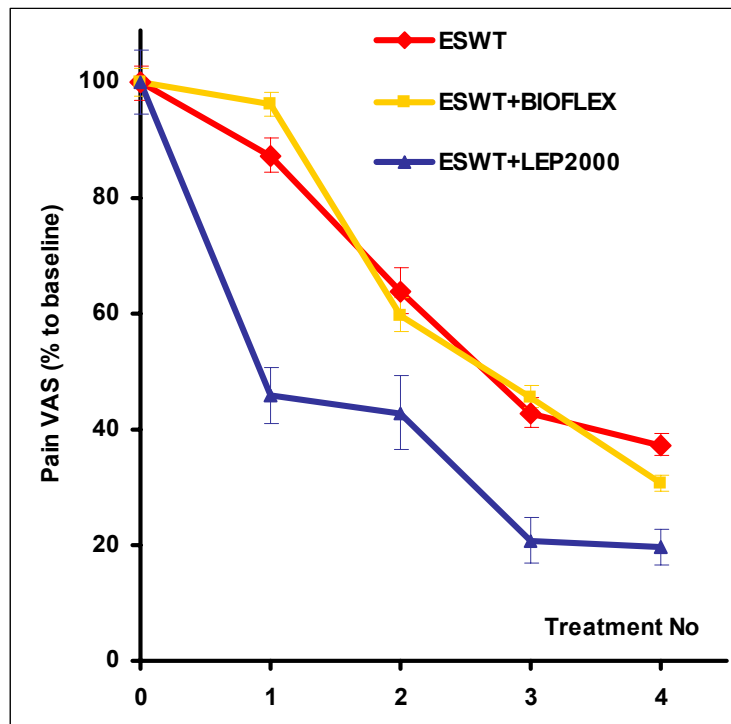


3.4 LEPT Induced Substantial Pain Relief After Extracorporeal Shock Wave Therapy (ESWT) Procedure

Recently we had an opportunity to test the efficacy of LEPT for “acute-on chronic” pain in 13 cases of chronic foot pain that was treated by ESWT followed by LEPT in a non-randomised comparative clinical trial. ESWT is a novel treatment that is hypothesized to convert a chronic pathology to an acute one and, in addition, to numb nerve endings. This is believed to result in pain reduction. LEPT being applied after ESWT induced substantial pain reduction (see Fig. 5) as opposed to ESWT used alone or in conjunction with the other LEPT system Bioflex (Meditech International Inc.)⁴.

⁴ Courtesy of ESWT Pain Clinic (Toronto)

Fig. 5 Pain relief by LEPT combined with ESWT



3.5 LEPT Is Effective For Chronic Whiplash Associated Disorder. Pilot Placebo Controlled Randomised Clinical Trial

While many individuals recover from MVA injury with conventional therapies including active exercise program, others develop chronic pain related to whiplash associated disorder (chronic WAD, >3 months). Recent Cochrane Database review did not reveal any effective therapies or treatment guidelines available for chronic WAD⁸⁶. Active exercise program does not appear to work for the individuals with chronic whiplash. Persistent pain appears to be a stumbling block for their recovery, and, in some cases, their pain is getting worse after exercises.

In this pilot clinical trial integrated protocols of LEPT (real or placebo) were applied to patients with neck and back pain that persisted more than 3 months after car accident. In addition, all patients received conventional therapy (CT, active exercise program and chiropractic care). Treatments were administered twice a week for 6 weeks (12 treatments total). After the course of treatment substantial statistically significant improvements in neck and back pain, and neck and back disability indexes were observed in the real LEPT group (see Fig. 6 -9). There was no improvement in the placebo treated group. Range of motion improved in both groups, however, it was greater in the LEPT treated group.

Fig. 6 Comparison of mean back pain VAS prior to and after the course of treatment (LEPT vs Placebo)

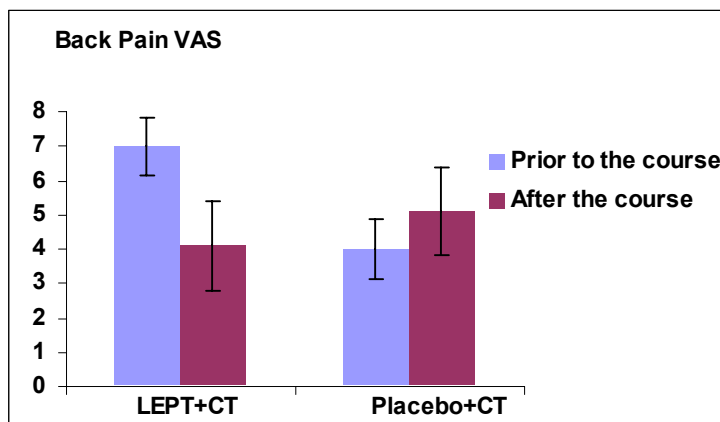


Fig. 7 Comparison of mean low back disability index prior to and after the course of treatment (LEPT vs Placebo)

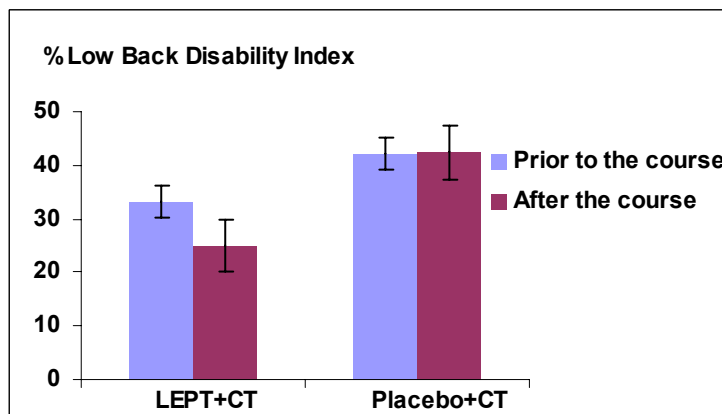


Fig. 8 Comparison of mean neck pain VAS prior to and after the course of treatment (LEPT vs Placebo)

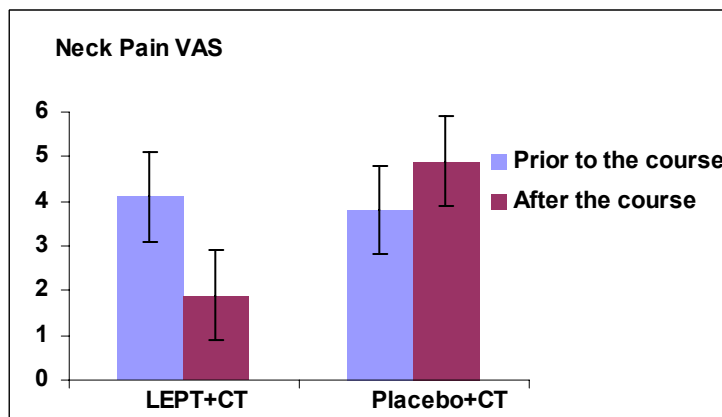
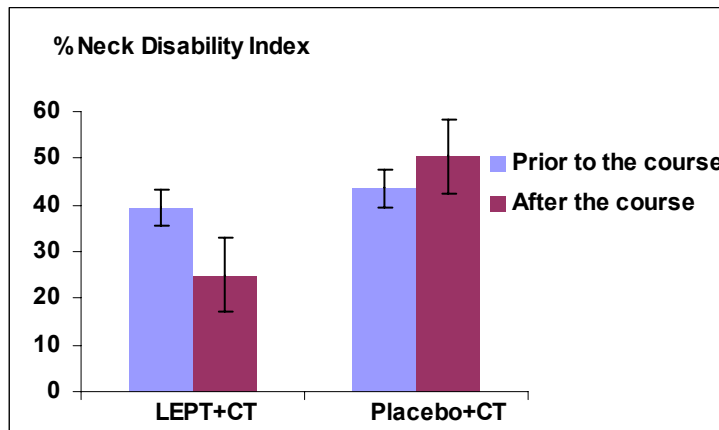


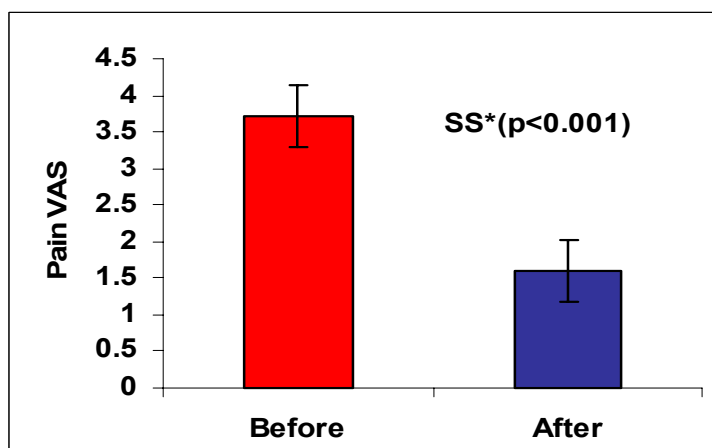
Fig. 9 Comparison of mean neck disability index prior to and after the course of treatment (LEPT vs Placebo)



3.6 LEPT Provided Fast Pain Relief Of 56.8% For Chronic Post-Traumatic Sport Injuries That Did Not Respond To Conventional Therapies

This prospective clinical trial was carried out at the Institute of Sport Medicine & Wellness Centre (Toronto). 15 patients with chronic post-traumatic pain that was not completely resolved with the use of conventional therapies including other LEPT system Bioflex (Meditech International Inc.) received 1-4 treatments (2 treatments on average) with customized protocols of LEPT for a particular patient using LEP2000 system (IMI Inc.). The mean duration of their symptoms was 14.8 months. Significant pain relief by 56.8% was produced by LEPT after 2 treatments on average (see Fig. 10). This pain relief was found to be statistically significant ($p < 0.001$) as compared to the baseline pain score.

Fig. 10 Mean VAS pain relief after 1-4 LEPT sessions



4. LEPT AS A NEW PARADIGM FOR ACUTE TRAUMA MANAGEMENT

4.1 Cell Ischemia (ATP Depletion) As A Central Pathology In Acute Trauma. Cell Deterioration And Death

A large body of research suggests that impairment of microcirculation and ATP depletion in ischemic injured tissues plays a key role in the progressive cell injury⁸⁷. On average, a body cell has ATP resources (10^8 - 10^9 molecules of ATP per cell) that can support its life for 1-2 minutes without additional ATP synthesis. Under disruption of microcirculation, cellular ATP synthesis declines and progressive cell injury occurs. Cell deterioration begins with functional changes in the cell and cell membrane. Membrane transport and membrane potential declines, Na^+ enters and K^+ leaves cells, and Na-K ATPase is activated. ATP is depleted, and mitochondria are stimulated as increased lactate produces acidosis. Cell energy and cAMP levels decrease, ATPase is depleted, Ca^{2+} regulation is compromised, and nuclear function and protein synthesis are depressed. The cell swells, and further membrane changes occur with altered hormonal effects and mitochondrial uncoupling. Finally lysosomes leak, intracellular and mitochondria disruption occurs, and the cell is destroyed.

4.2 Early Intervention With Intravenous ATP Was Proven To Be Beneficial For Ischemia/Reperfusion Injuries

Based on the understanding of ATP depletion as the leading mechanism of cell death after injury, an intravenous (IV) intervention with a compound of ATP and a vasodilator MgCl_2 to prevent ischemia/reperfusion injury was developed and tested in numerous studies^{88,89,90}. Benefits of the treatment with ATP- MgCl_2 have been achieved on myocardial preservation during cardiac operations, kidney preservation for transplantation, and as metabolic support for the injured and septic patients. Substantial reduction or full resolution of I/R injury was achieved with early intervention of compound ATP- MgCl_2 . However, in many studies it has been emphasized that the efficacy of this approach strongly depends on the timing of the IV intervention with ATP- MgCl_2 . The maximum benefit of the therapy was achieved with prolonged intravenous infusion of ATP- MgCl_2 introduced early prior to reperfusion. In a battlefield environment it may often happen that IV intervention becomes available too late, after substantial ischemic tissue damage has occurred.

4.3 Specific Protocols Of LEPT Are Proven To Increase Cellular ATP (*In Vitro*, *In Vivo* Studies)

Many therapeutic phenomena of LEPT in live organisms are believed to be based on the activation of ATP synthesis in cell mitochondria by LEPs. It is hypothesized that LEPs being absorbed by the primary photoacceptors in live cells may induce substantial activation of mitochondrial enzymes, components of the respiratory chain^{91,92,66}. This, in turn, is leading to the activation of ATP synthesis. Additional energy resources resulting from LEPT are used for cell and soft tissue repair. If ATP synthesis is activated in blood cells in substantial quantities, it becomes available for all body tissues via systemic circulation in a matter of minutes. Beneficial phenomena for soft tissue healing that can be induced by LEPT are described below.

Irradiation of low energy (typically 0.01-10Joules/ cm^2 of skin or cell culture) could induce substantial enhancement of ATP synthesis and cell metabolism. For example, ATP synthesis was increased by 70% in liver cell mitochondria after exposure to He-Ne laser of 5J/ cm^2 density⁹³. Similarly, DNA and RNA synthesis was increased by 60-100% after exposure to LEPs of energy density 0.01J/ cm^2 ^{94,66}. The result of LEPs-live cell interaction is almost immediate, although it might have a long-term healing effect even after one LEPT treatment.

In this section we would like to present some encouraging data on the activation of ATP synthesis and other positive phenomena induced by LEPs in different experimental models and some clinical trials. Authors of⁹⁵ hypothesized that photo-irradiation with Argon-dye laser (red emission, wavelength 660 nm) could increase ATP in isolated rat hearts (pre- or post- storage), and, therefore, reduce ischemia and improve their functional preservation. Both pre and post-storage treatment groups showed significant improvement in recovery of aortic flow, cardiac output, and work compared to the corresponding control groups. Investigation using isolated rat cardiomyocytes found that both end-storage ATP and end-reperfusion catalase activity in the laser-treated group were significantly higher than those in the untreated cells. The authors draw the conclusion that photo-irradiation improves functional recovery of the cold-stored rat heart possibly via conservation of ATP and antioxidant enzyme activity.

Dr. Yu and co-authors investigated the effect of photo-irradiation with Argon-dye laser on rat survival in the experimental model of sepsis⁹⁶. The cecal ligation and puncture (CLP) rat model was used. 36 Sprague-Dawley rats were divided equally among four groups: control (non-operative), sham operation, CLP treated with laser irradiation, and CLP without laser irradiation. The peritoneal cavity of each animal in CLP/laser group was irradiated immediately after CLP using an Argon-dye laser at a wavelength of 630 nm and at a fluence of 5 J/cm². Laser irradiation (LI) significantly improved ex-vivo lymphocyte proliferation of cells from septic rats (179.7 vs. 129.5) and survival in septic rats (79% vs. 42%). LI significantly stimulated lymphocyte proliferation in the presence of mitogenic stimuli and enhanced lymphocyte ATP synthesis. The conclusion was drawn that LI may be useful as an adjuvant therapy for sepsis.

Positive phenomena of intravenous laser blood irradiation (IVLBI) were observed in a dog model of I/R injury⁹⁷. The effect of low-intensity intravenous laser blood irradiation (IVLBI) on morphofunctional characteristics of erythrocytes and circulation parameters has been studied experimentally on 22 adult inbred anesthetized dogs, of both sexes, during a 2-hour hemorrhagic shock, and in the first hours after resuscitation. It has been established that the use of IVLBI during 45 min of hemorrhage shock stabilizes erythrocyte membranes and improves myocardial function.

Efficacy of IVLBI with He-Ne laser was investigated as an adjunct therapy in the management of peritonitis involving 350 patients⁹⁸. The patients were randomised to two groups:
Group 1: 245 patients were treated with IVLBI as an adjunct therapy to conventional therapies;
Group 2: 105 patients were treated with conventional therapy only.

The conclusion was made after the completion of the study that IVLBI with He-Ne laser was effective as an adjuvant therapy in the integrative management of peritonitis. Mortality in the laser- treated group was 2.8% as opposed to 14.2 % in the control group. The percentage of post-surgical complications (sepsis, purulent wounds, lung and heart failures, thrombophlebitis, etc.) was reduced from 53.3% in the control group to 21.2% in the laser-treated group. The average stay in the hospital was reduced from 27.4 days in the control group to 18.5 days in the laser-treated group. In the experimental group of patients faster resolution of acute inflammation (leucocytosis, neutrophilia, lymphopenia), normalization of body temperature and blood indexes were noticed as compared to control group.

4.4 Drs. Salansky's Integrated Clinical Protocol For Acute Trauma. Hypothesized Therapeutic Effects.

It is well known that acute trauma can lead to multiple underlying pathologies of the injured tissue, e.g.:

- Cell ischemia
- Physical distention of the joint capsule or fascial compartments by blood or tissue fluid transudate
- Tissue damage followed by activation of kinin and prostaglandin systems
- Massive release of pain and proinflammatory mediators
- Disturbance in acid-alkaline balance
- At later stage extravagated blood or necrotic tissue will initiate non-bacterial inflammation and secondary release of pain and inflammatory mediators.

Each of these pathologies could contribute to the compound pain and function impairment. After thorough analysis of basic and clinical studies, and theoretical modelling of LEPT phenomena, we came to the conclusion that it is not possible to improve all above pathological conditions with a single LEPT approach. Hypothetically, for each particular soft tissue pathology a specific LEPT set of optical parameters (specific "therapeutic optical window") is required. Therefore, in order to increase efficacy of LEPT, we developed a concept of integrated clinical protocols when several LEPT procedures are applied one after another in physiologically justified sequence.

We propose to use for pain control immediately (or any time within 2 weeks) after acute trauma an integrated protocol of LEPT that includes several specific treatment procedures of LEPT applied in sequence one after another. Each of these specific LEPT procedures for acute trauma was designed to induce one of the following healing macro-mechanisms in the injured soft tissue that can result in fast cumulative pain relief and soft tissue condition improvement:

- Photo-induced release of pain-relieving molecules by local stimulation. Additional non-invasive stimulation of related acupuncture points (no-needle acupuncture) could enhance analgesic effect.
- Direct photo-activation of ATP synthesis in the injured tissue. This protocol is believed to reduce ischemic pain in the injured tissue.
- Transient photo-induced vasoconstriction in the injured area. This protocol is believed to reduce edema and, therefore, attenuate pressure pain.
- Photo-immunomodulation is believed to accelerate removal of cell debris from the injured area, reduce the duration of inflammatory stage, and reduce concentrations of pain mediators in the injured tissue: bradykinin, proinflammatory prostaglandins, etc., and, as a result, to attenuate pain related to inflammation.
- Photo-induced relief of abnormal muscle activity (in particular, muscle spasm) that is often accompanies injury. This is believed to relieve pain that may be induced by muscle spasm.

Based on the animal and clinical studies, this integrated clinical LEPT protocol appears to produce substantial fast pain and swelling relief and wound healing acceleration if applied early enough after acute trauma. It was also demonstrated in numerous case stories that cumulative pain relief is greater after application of all above specific procedures one after another as compared to an application of a single procedure only.

4.5 LEPT Is Effective For Acute Whiplash Injury And Post-Traumatic Pain In Joints

4.5.1 LEPT Is More Effective And Provides Faster Recovery After Acute Whiplash Injury Than Conventional Therapies: Controlled, Randomised, Comparative Clinical Trial

This study had an objective to verify if LEPT being applied in addition to conventional therapies could accelerate patient recovery after acute whiplash injury⁹⁹. 54 patients after acute whiplash injury were randomly allotted to the following groups: Group #1 (17 pts) received Chiropractic Manipulative Therapy (CMP); Group #2 (18 pts) received CMT plus Exercise Therapy (Ex); Group #3 (19 pts) received CMT plus Ex plus LEPT. Therapy was administered three times per week during 8 weeks. Extensor muscle strength (EMS) was measured prior to the course and at weeks 2, 4, 6, and 8 of therapy. Uninterrupted sleep (US) at night was evaluated prior to the study and at week 8 using sleep questioner. Statistical analysis revealed that EMS recovered faster in LEPT group in comparison with 2 other groups: statistically significant increase in EMS was observed at week 4 (see Fig.11) as opposed to week 8 in Ex group. There was no statistically significant increase in EMS in the group treated with CMT until the completion of the trial. There was higher increase in EMS (by 23%) in LEPT group in comparison with Ex group (by 15%) and CT group (by 9%) after 8 weeks of therapy. In addition, patients in LEPT group slept better as compared to other treatment groups (see Fig. 12).

Fig. 11 LEPT efficacy for EMS recovery

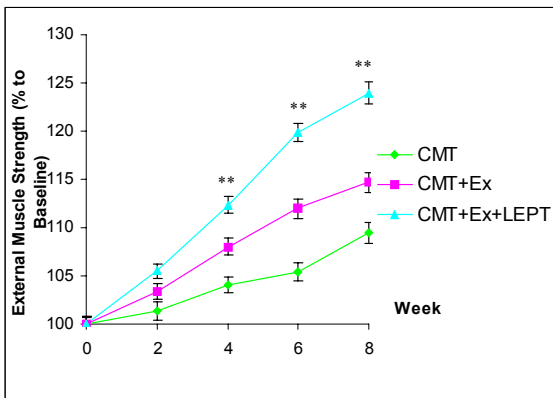
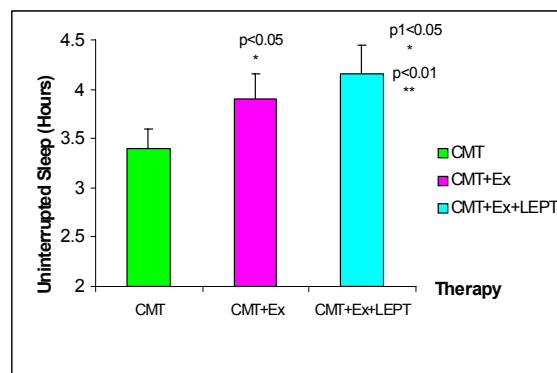


Fig. 12 LEPT Efficacy for sleep improvement



4.5.2 LEPT Is More Effective Than Ultrasound And Placebo For Joint Pain Relief: Proof Of Concept In 2 Double Blind Clinical Trials

Jointly with McMaster University (Hamilton) and a teaching hospital of the University of Toronto (Scarborough Hospital, General Division) were accomplished 2 double blind studies on the efficacy of LEPT for pain relief^{65,100}. LEPT (both real and placebo) equipment and clinical protocols for the trials were provided by IMI Inc.

4.5.2.1 Study 1

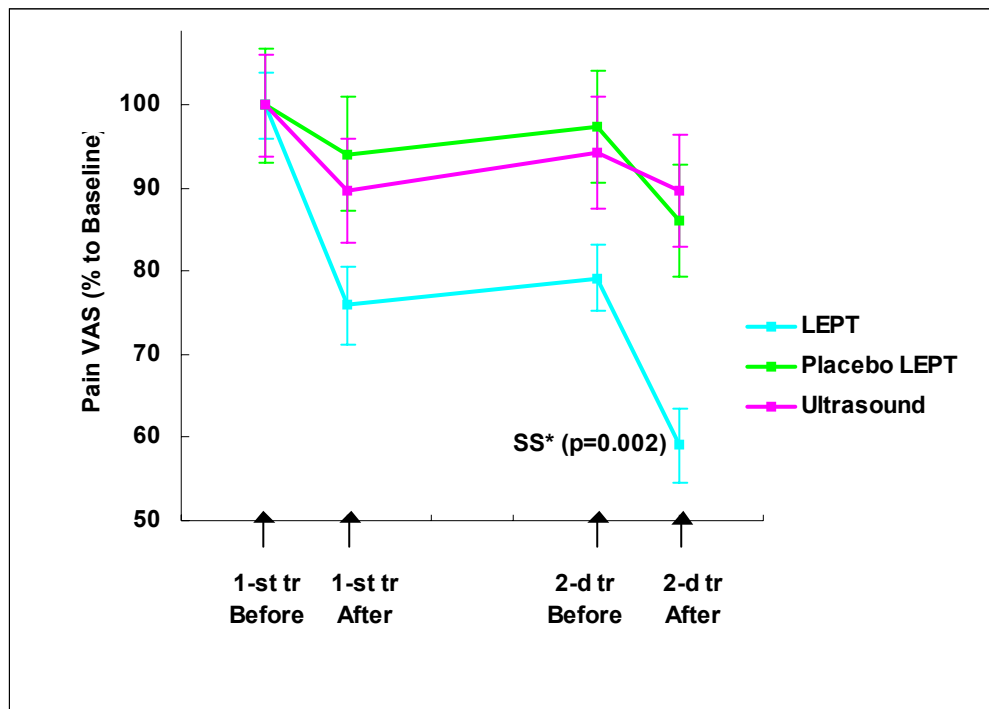
This study was prospective, randomised, comparative, and double blind. 75 subjects (41 females and 31 males with mean age of 47.5 years, range, 18-78) suffering from sub-acute (2 weeks – 6 months duration) or chronic (more than 6 months duration) pain around joints were enrolled in this study in accordance with the inclusion and exclusion criteria: Group #1 (26 subjects) received LEPT; Group #2 (24 subjects) received

placebo LEPT; Group #3 (25 subjects) received ultrasound (US). Two treatments of selected in accordance with the random number treatment modality were administered to the patients on the first and third days of three consecutive days.

No pain, anti-inflammatory medication or steroid injections were used during the study period. Pain at rest by 10 cm vertical visual analogue scale (VAS) was taken prior to and 20 minutes after each treatment. In addition, pain pressure threshold (PPT) using dolorimeter was measured at the most tender spot of the affected area prior to the first treatment. Initial measurements of PPT were included to the study to make assessment of local baseline soft tissue tenderness in different study groups and investigate if randomisation in the study was not biased in regards to this local tenderness parameter.

Neither the patients nor the physiotherapist administering the treatment were aware of which treatment modality (placebo or real LEPT) was used. Outcome measurements were taken by a different evaluator in a separate room from the treatment area. The evaluator, the biostatistician and the investigators were completely blinded in regards to the treatment modality used: ultrasound, placebo or real LEPT. 72 subjects completed the study. There were 3 patients who did not come for the second treatment: one patient dropped out from the placebo group and 2 patients dropped out from the ultrasound group.

Fig. 13 LEPT efficacy for sub-acute and chronic pain relief compared to Placebo and Ultrasound



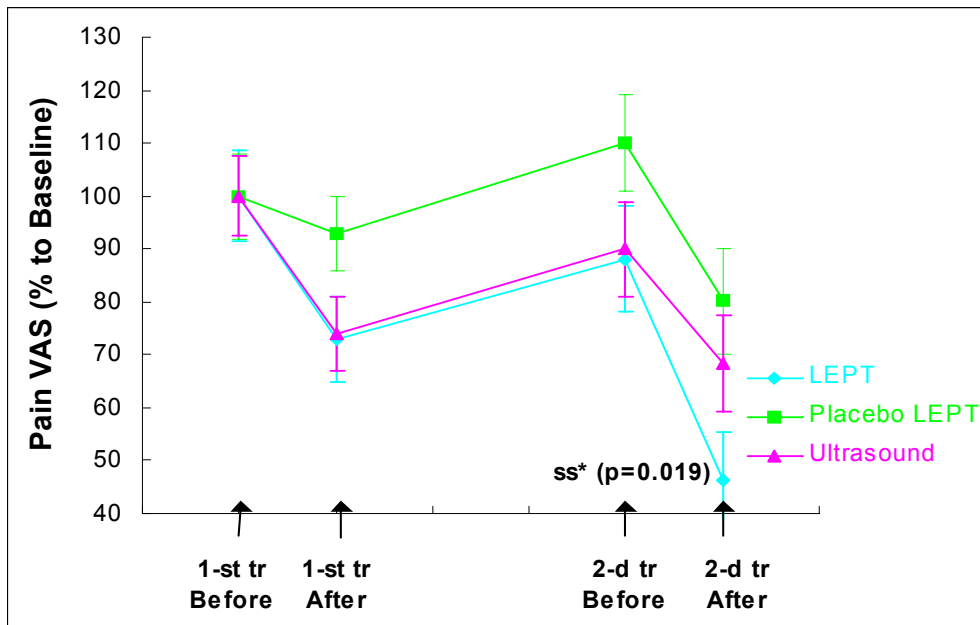
There were no drop-outs from the LEPT group. One-way Analysis of Variance (ANOVA) revealed no statistically significant differences in mean age, symptom duration, initial pain level rating nor pain pressure threshold among the Groups. Chi-square analysis revealed no statistically significant difference among the groups in gender, chronicity, or the relative size of each group. It was no statistically significant difference between groups in the relative numbers of each joint (ankle, knee, wrist or elbow). The lack of significant

differences in the above variables suggests that the methods of randomisation used in the study were effective and the randomisation was not biased. ANOVA revealed a statistically significant difference in the mean change in VAS-measured pain level ratings between Groups ($F=7.78$; $df 2.71$; $p=0.0009$). Post-hoc analysis revealed a statistically significant difference in the mean change in VAS-measured pain level ratings between real LEPT and placebo LEPT ($p=0.005$). There was also a statistically significant difference in the mean change in VAS-measured pain level ratings (PRLs) between the real LEPT and US groups ($p=0.002$). The difference in the mean change in VAS-measured PRLs between placebo LEPT and ultrasound was not statistically significant. Mean VAS-measured pain level ratings declined by 40% (from 4.26 to 2.52) after 2 LEPT treatments in real LEPT group (see Fig. 13). Whereas, these pain measurements indicated, on average, only a 14% decline (from 3.73 to 3.22) in the placebo LEPT group and only a 10% decline (from 4.48 to 4.02) in the US group.

4.5.2.2 Study 2

This study had the same design as the previous one. The difference was in the duration of symptoms. 22 patients suffering from acute (6-14 days) or sub-acute (2 weeks – 6 months duration) pain around joints were randomly allotted to the following treatment groups: Group #1 (7 pts) received LEPT; Group #2 (8 pts) received placebo LEPT; Group #3 (7 pts) received ultrasound. Statistical analysis confirmed statistically significant difference in the mean change in VAS-measured pain level ratings (from pre- to post- treatment) between real LEPT and placebo LEPT ($p=0.0044$). There was also a statistically significant difference in the mean change in VAS-measured pain level ratings (PRLs) between the real LEPT and US groups ($p=0.019$).

Fig. 14 LEPT efficacy for acute and sub-acute pain relief compared to Placebo and Ultrasound



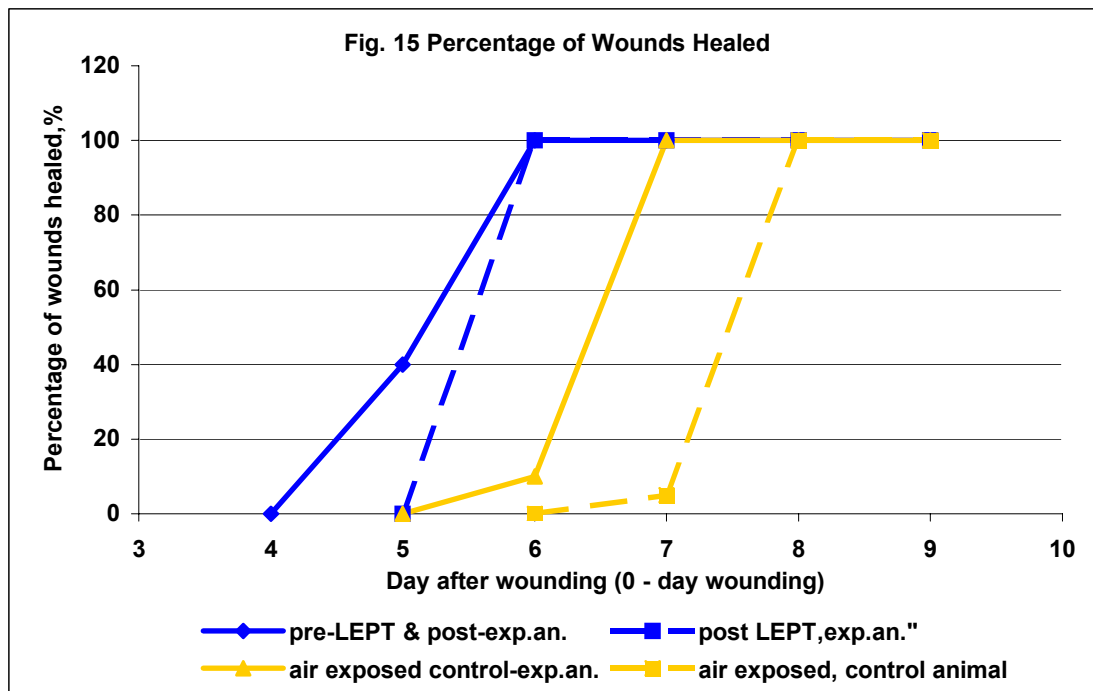
Mean VAS-measured pain level ratings declined by 53.5% (from 4.46 to 2.07) after 2 LEPT treatments in real LEPT group (see Fig.14). Whereas, these pain measurements indicated, on average, a 20% decline (from 3.59 to 2.87) in the placebo LEPT group and a 31.6 decline (from 3.70 to 2.53) in the US group.

4.6 LEPT Assisted To Wound Healing Acceleration In A Partial Thickness Pig Wound Model

In a collaborative effort with the University of Miami a placebo controlled pilot study on LEPT in partial thickness wounds in a pig model¹⁰¹ was accomplished. The pig model was chosen for our experiment because the skin of pigs is the closest animal model available to that of humans.¹⁰² All previous published attempts to find acceleration of wound healing in pig models by LEPT have failed.

One animal was treated with LEPT and the other one served as the control. Wounds were induced on each animal and divided in four groups. A total of 280 wounds were assessed. LEP 2000 (IMI Inc., Toronto) system for LEPT was used in this study. Beginning on Day 4 and each day thereafter Epidermal Migration Assessment was performed to five wounds of each treatment group. Epidermal Migration Assessment is a method for assessing epidermal wound healing.^{103,104,105,106,107} In addition, studies to measure the immune response of the experimental pig to LEPT were also performed.

As one can see in Fig. 15, the greatest rate of healing was observed in the experimental pig in the group that received LEPT prior to and after wounding. This group displayed an increase of 32% in the rate of wound healing observed when compared with control animal. To date, the most effective treatment for this type of wounds is occlusive dressings. The effect of LEPT that we obtained for wound healing in pig is comparable to that induced by the occlusive dressings and various growth factors using this model⁹⁸. An acceleration of 27% was observed in the rate of wound healing for both groups of wounds treated with only red low energy photons and the group treated with the combination of red and infrared low energy photons. The rate of wound healing was accelerated by 16% in air-exposed wounds of the experimental animal, in comparison to the control animal. These results suggest that LEPT accelerates wound healing locally and may have some systematic effects. Moreover, the concept of inducing acceleration of wound healing by pre-treatment with LEPT could be very appealing. It is obvious its potential relevance to clinical applications in which patients are scheduled for elective surgery, as reduction of complications and acceleration of post surgical recovery are of great importance.

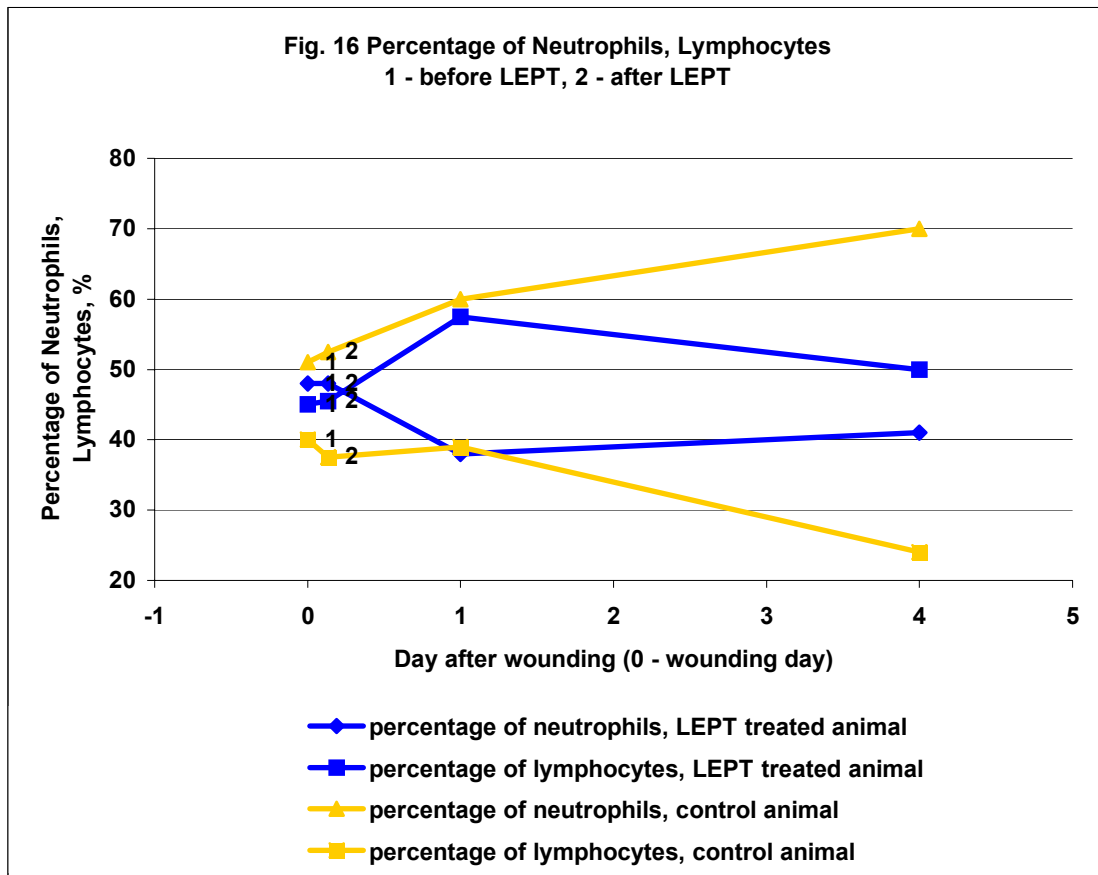


4.7 Systemic Immunomodulation Phenomena Induced By LEPT

We accomplished several pilot studies aimed to investigate if red LEPT (non-coherent monochromatic light of 660 nm wavelength) could induce alterations in systemic blood indexes and non-specific immune system of animals (rabbits, rats, pigs) and healthy human volunteers^{65,68,101}. Phagocytic leukocyte oxygenation activity (PLOA) and differential blood count were chosen as initial markers of systemic body response to LEPs exposure. Numerous studies suggest that PLOA is very sensitive to changes in the organism, its activity, or environment^{108,109}, in particular, to wounding, trauma, inflammation, pathological stress, air pollution, etc. The changes in PLOA in response to LEPT are almost immediate what allows utilizing this measurement as a feedback for a body response to LEPT⁶⁸.

PLOA has been studied using luminol-amplified chemiluminescence measurements in highly (1:400 or 1:800) diluted whole blood stimulated by opsonized zymozan.^{68,110,111} Research suggests that release of reactive oxygen species (ROS) by challenged neutrophils contribute more than 90% of whole blood chemiluminescence (WBCL) under these experimental conditions¹¹². The advantage of measuring PLOA in whole blood is that it could be measured immediately in intact cells avoiding a procedure of isolating neutrophils that could induce alterations in their PLOA. WBCL is proportional to the concentration of active phagocytes in blood and their individual activity. Normalized oxygenation activity per neutrophil has been calculated dividing WBCL value by neutrophil concentration N (WBCL/N).

For the immune studies in our above pig wound model blood was drawn from an ear vein and measurements made prior to and after each LEPT irradiation. Wounding in the control animal resulted in the moderate (18%) activation of neutrophils after wounding, with rapid return (<24 hours) to near baseline activity. This would be expected in an animal with an acute injury and no further trauma or infection. Interestingly though, the LEPT treated animal experienced a slight increase in total WBCL (by 6.2%) and a substantial activation (by 67%) of reactive oxygen species release per neutrophil (WBCL/N) after pre-treatment with LEPT. The neutrophils remained activated for several days thereafter although wounding did not increase the level of activation any further. The results of the differential count of neutrophils and lymphocytes indicated that at the control animal there was neutrophilia and lymphopenia (70% neutrophils, 24% lymphocytes), which persisted after day 4, in response to the wounding. At the same time, there was no neutrophilia or lymphopenia in the LEPT treated animal (see Fig. 16).



Our experiment suggests that local exposure of porcine skin to LEPT with the given optical parameters could induce systemic immunomodulation phenomena, in particular, an activation of individual PLOA per neutrophil. The findings support the hypothesis that LEPT induces not only wound reepithelialization but also activation of non-specific immune responses during the early stages of wound healing and faster resolution of the inflammatory stage.

4.8 LEPT For Acute Trauma. Case Reports.

4.8.1 LEPT Was Administered Within 3 Hours After Injury

4.8.1.1 Case I⁵. Immediate resolution of symptoms and function restoration with LEPT after punch injury

Ms. N.D., 26 y.o.

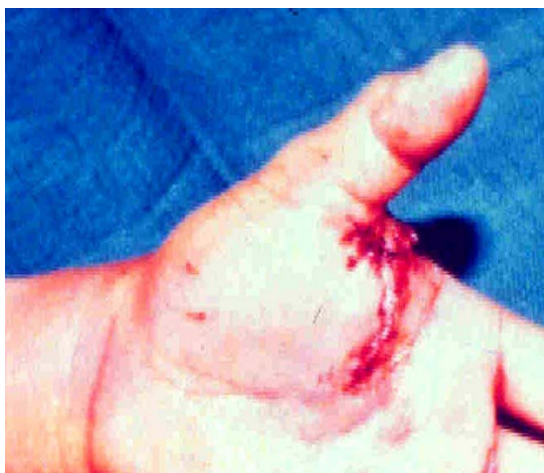Wrist injury sustained in kick-boxing from a punch. VAS 7-8/10. ½ ROM available into both flexion and extension. Unable to weight-bear on hands (e.g., push-up). Within 3 hours, LEPT (protocol for acute trauma) was used, 4-6 minute treatment in total. Immediately post-treatment, there was no pain (0/10), full, pain-free range of motion, and no pain with weight bearing. No further treatment was used, no pain returned. Sport was returned to as normal.

⁵ Courtesy of Honsberger Physiotherapy Clinics (Toronto)

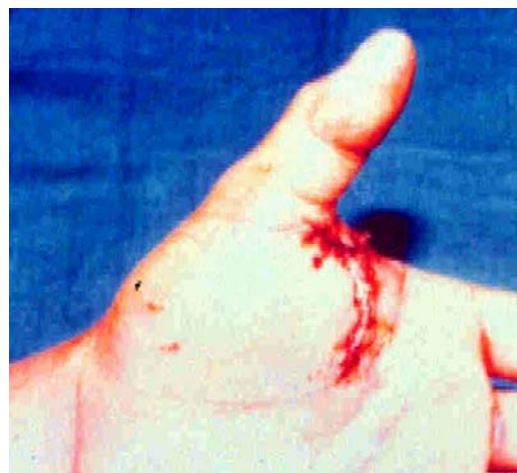4.8.1.2 Case 2⁶ Immediate relief of pain and swelling reduction following LEPT for hand injury

This 47-year-old male presented to the hospital with an acute hand crush injury within 3 hours after the injury. LEPT (acute trauma protocol) was administered to the hand during 20 minutes; no ice was applied. The patient did not change his hand position. The pictures (Fig.17) were taken prior to and immediately after LEPT. Swelling and pain substantially reduced.

Fig. 17 Fast resolution of pain and swelling after LEPT



Prior to LEPT



Immediately after 20 min of LEPT

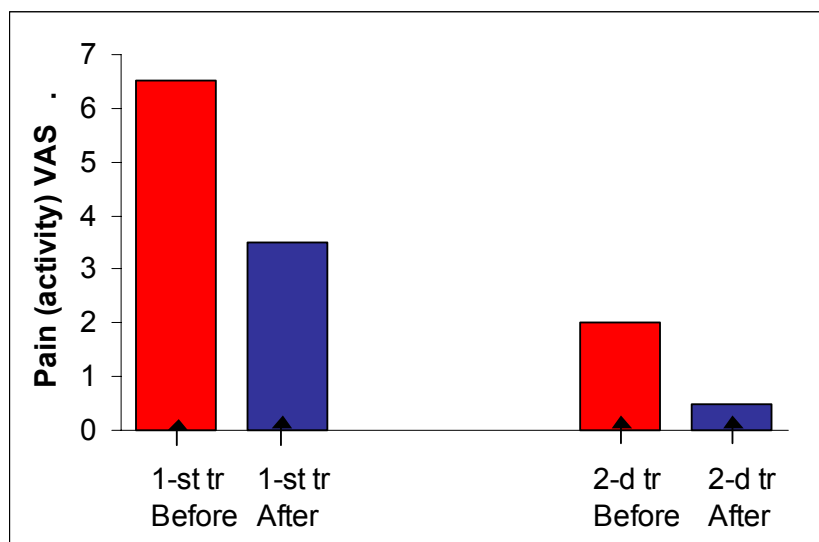
4.8.2 LEPT Was Administered Within 24 Hours After Injury

4.8.2.1 Case 1. Fast resolution of symptoms and function recovery after acute Grade II ankle sprain

This 18-year-old female, competitive volleyball player received first LEPT treatment 24 hours after a Grade II lateral ankle sprain. Immediately after the first LEPT session the pain reduced by 45% and weight bearing substantially improved followed by a substantial swelling reduction 3 hours later. After second LEPT session pain became minimal and stayed at this level since ever (see Fig. 18). In 72 hours she resumed training (like stationary cycling), 9 days after the injury she played in a volleyball tournament with an assistance of ankle support. A follow-up diagnostic ultrasound confirmed complete healing of the tendon. At 6-months follow-up there was no complaints on the ankle and she was able to play beach volleyball. In a testimonial Ms. C.N. stated that similar previous injuries to her ankles kept her away from sports for at least for 5 weeks.

⁶ Courtesy of the Scarborough Hospital, General Division (Toronto)

Fig. 18 Fast resolution of symptoms after Grade 2 ankle sprain



4.8.2.2 Case 2. Fast resolution of symptoms after toe fracture with LEPT. No complaints for 2 years.

Testimonial

September 14, 2001
B. K., B.A.Sc., CA

To whom it may concern

I would like to bear witness to the beneficial effects that Low Energy Photon Therapy (LEPT) had for me for the trauma I experienced last year. Last fall I fractured my toe. I was in severe pain and had great difficulty walking. There was substantial bruising and swelling in the trauma area. My family doctor identified toe fracture. Next day after the injury (on Friday) I received treatment with Low Energy Photon Therapy at the Pain and Injury Clinic (Toronto) using LEP2000 device. After the first treatment I experienced a substantial immediate pain relief that lasted about 2 hours. Then pain stabilized at the lower level as compared to the pre-treatment condition. Next 2 days (it was weekend) I was treating myself with the portable home device for LEPT in accordance with the instructions given to me at the Clinic. On Monday I received second LEPT treatment at the Clinic. Again, I experienced substantial immediate pain relief. After this treatment my pain stayed at low level and I was able to conduct most of my regular activities without any substantial discomfort. In 10 days after the injury my pain was gone. Since that time I did not experience any pain or discomfort in the injured area.

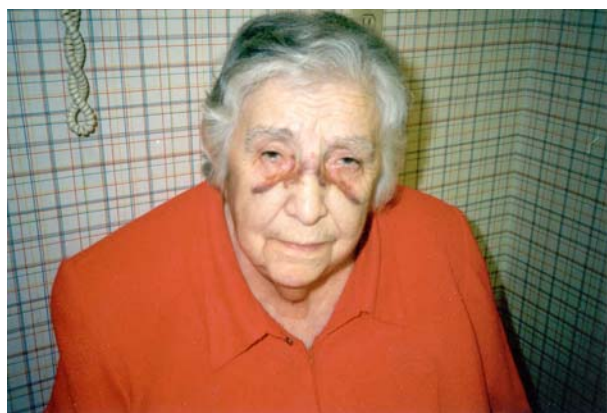4.8.2.3 Case 3⁷. Professional cricket player was able to continue his participation in the International Cricket Cup (ICC) after Grade 2 muscle strain with LEPT treatments

Mr. L. was seen at the on-site clinic covering ICC. He presented with a one-day history of a calf strain. The pain by verbal analogue scale (VAS) was rated at 8/10. Mr. L. demonstrated a limp during gait, had marked tenderness through the right lower leg muscles. The overall assessment indicated a grade 2 muscle strain of the lower leg muscles. His initial treatment included Low Energy Photonic Therapy (LEPT), myofascial release, education in proper stretches and icing protocols, and complete rest from training and competition. The next day Mr. L. was again seen in the clinic. He reported his pain level to be 6/10. His physiotherapy included LEPT and myofascial release. He was to take one more day off, but had a probable return to play next day. Mr. L. was seen the day after playing. Even though playing a full cricket match (7-8 hours), his pain level still dropped. His gait pattern was much improved. Treatment was as above. Mr. L. was seen successfully over the next 3 days. The level of pain continued to drop and he continued to play with full participation.

4.8.2.4 Case 4. Fast resolution of symptoms with early LEPT intervention after double (nose and rib) fractures. No complaints at 20 months follow-up

This 79-year old lady sustained double fracture (nose and rib) from the fall in her bathroom. First LEPT session was administered within first 24 hours after the injury. The nose was pain-free after 2 LEPT sessions. the rib was pain-free after 4 LEPT sessions (see Fig. 19).

Fig. 19 LEPT for the treatment of double fracture



40 hours after injury, 24 hours after 1st LEPT session



12 days after injury, the nose was pain-free after 2 LEPT sessions; the ribs were pain-free after 4 LEPT sessions

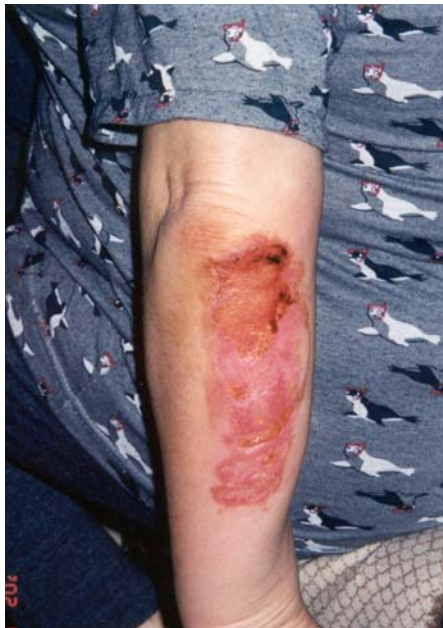⁷ Courtesy of Honsberger Physiotherapy Clinics, Toronto

4.8.3 LEPT Was Administered Within 96 Hours After Injury

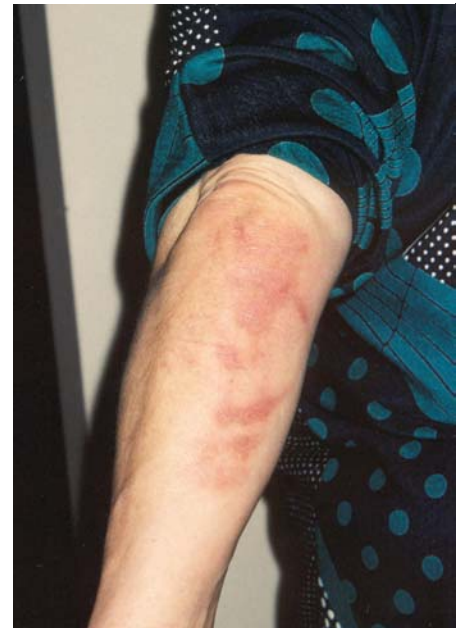4.8.3.1 Case 1. Fast healing of 2-3-degree burn using portable LEP2000 device for LEPT

This 56-year-old female presented with 2-d-to-3d degree domestic burn that she sustained 4 days prior to the first LEPT session. She complained excruciating pain (8 on a 0-10 verbal analogue scale) and drainage from the wound. She started treating herself with the portable LEP2000 device (IMI Inc., Toronto), twice a day. After several LEPT sessions pain substantially reduced (to 2 on a 0-10 VAS) and drainage stopped. 6 days after 1st LEPT treatment the wound was 60% epithelialized and 40% covered by a crust. 7 days after 1st LEPT sessions the crust was off. In 10 days (20 LEPT sessions) the burn completely healed (see Fig. 20). Usually healing of such burn may take 3-4 weeks.

Fig. 20 2-3-fold acceleration of burn healing with LEPT



Day 1. Prior to LEPT

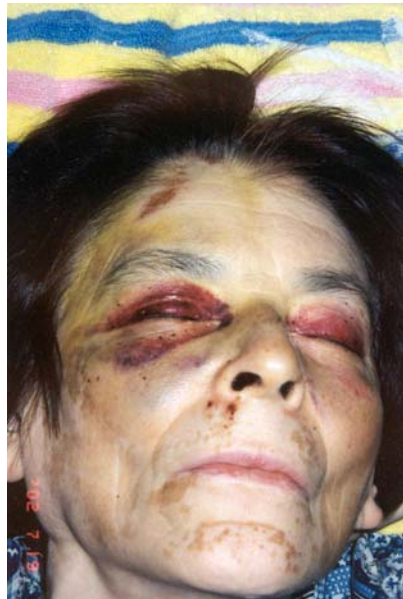

Day 10. After 20 LEPT sessions

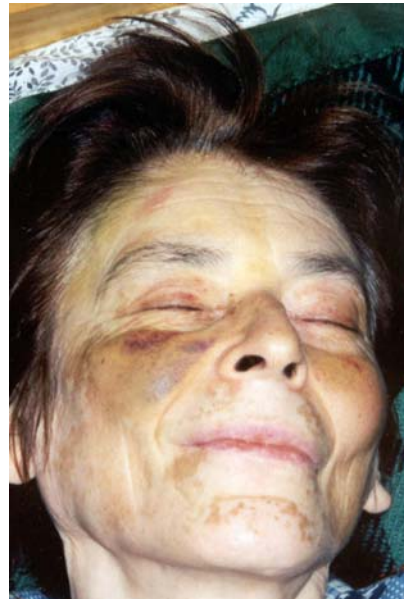4.8.3.2 Fast resolution of bruising with LEPT

This 71-old female sustained severe head injury from a fall. She has been suffering insulin-dependent diabetes type II. She presented with severe bruises around her eyes and on the face, especially on the right side. She complained a moderate pain in the injured area. LEPT was focused on the forehead and the eyelids as the areas of main concern. After 2 LEPT daily sessions, bruising was substantially reduced and pain was gone. In 6 days after 4 LEPT sessions bruises around her eyes and on the forehead disappeared (see Fig. 21). Make a note that the bruise on the non-treated chick area was not resolved. Usually resolution of such bruises in elderly patients may take over 2 weeks. Follow-up 1 year after the injury she did not have any complaints related to the injury.

Fig. 21 Fast resolution of bruising with LEPT



Day 1. Prior to LEPT



Day 6. After 4 LEPT sessions

4.9 Comparative Analysis Of The Rate Of Symptom Relief And Function Recovery After Acute Ankle Sprain (Grade II) Using LEPT Versus Conventional Therapies (CT)

Current passive treatments for acute ankle sprain could not be considered as satisfactory. A recent 6-18-months follow-up (after medical evaluation) survey revealed that 72.6% of patients who had suffered an acute ankle sprain reported some unresolved residual symptoms. Of these, 40.4% reported at least one moderate to severe symptom¹¹³.

The following table represents comparative analysis of the rates of recovery using LEPT (early administration within 72 hours) and conventional therapies. This analysis is based on case reports on LEPT use and existing literature data on CT.

Table 1 Comparative Analysis Of The Rate Of Symptom Relief And Function Recovery After Acute Ankle Sprain (Grade II) Using LEPT Versus CT

<i>Therapy</i> <i>Symptoms</i>	<i>Low Energy Photonic Therapy</i>	<i>Conventional Therapy</i> ^{114,115}
Pain	<ol style="list-style-type: none"> 1. Walking VAS pain reduced by (30-60)% immediately after 1-st LEPT session as compared to baseline. 2. Walking VAS pain reduced further by (50-100)% immediately after 2-d LEPT session as compared to baseline. 3. After 2-3 daily LEPT sessions walking pain is minimal or non-existent 	Patients suffer significant pain for at least 1 week after the injury. This pain gradually subsides during the second week after the injury with a residual pain that may last over 2 weeks.
Swelling Inflammation	<ol style="list-style-type: none"> 1. Swelling is visibly reduced in 1-3 hours after 1-st LEPT session. Next day swelling is much less compared to baseline. 2. After 2-3 daily LEPT sessions swelling is minimal and restricted mostly to the area surrounding tendon tear or sprain as assessed by a diagnostic ultrasound 	Swelling and inflammation is substantial for at least one week after the injury followed by a gradual decline during second week.
Weight bearing	<ol style="list-style-type: none"> 1. Weight bearing with reduced pain restored immediately after 1st LEPT session. 2. Weight bearing with low pain level (0-3 out of 10 by VAS) is possible after 2 LEPT sessions. 3. After 2-3 daily LEPT sessions pain-free or minimal pain weight bearing is restored. 	Weight bearing is accompanied by substantial pain for at least one week after the injury followed by a gradual improvement at weeks 2-3.

4.10 Summary Of Case Reports.

If LEPT (Drs. Salansky’s protocols) was administered within 3-hour window after trauma, in most cases of Grade 1 sprain/strain immediate complete resolution of symptoms and function recovery was observed, as the injury has never happened.

In most cases of Grade 2 injuries (ISS<9) LEPT resulted in fast (within 1-3 days) significant improvement of symptoms and function recovery. Tendon healing as it was assessed by diagnostic ultrasound took longer.

In a small percentage of cases, individuals overused the injured area that was treated with LEPT as they did not have restrictions related to pain and swelling. This was followed by a short exacerbation of pain and restriction of function. After additional LEPT sessions the cases were resolved. Further research is needed to identify the range of functional activity appropriate after fast resolution of symptoms with LEPT.

In several cases of bilateral injury only the worst side was treated by LEPT. In a short-term pain was resolved bilaterally. However, at a follow-up (3-6 months) the untreated areas had pain while treated with LEPT areas continued to be pain-free. This may be suggestive that early intervention with LEPT may reduce chronicity development. Further research on prevention of chronicity development with LEPT is indicated.

5. SUMMARY

1. This paper describes basic concepts and advantages of new LEP therapy for pain and wound management after acute trauma.
This therapy is non-invasive, easy to use and could be applied immediately after trauma. The therapy provides significant pain relief even after a few minutes of treatment and has no side effects.
This therapy is available at institutional environment (office unit) and at the battlefield (with a portable field unit), weight less than half-pound.
2. Background data (basic research *in-vivo* and *in-vitro*, as well as clinical results) are presented to elucidate physiological mechanisms involved in the therapy and substantiate clinical applications of LEPT. The photo-induced healing mechanisms represent justification for LEP therapy.
3. The concept of “therapeutic optical windows” is presented and 3D dosimetry considerations provide a scientific basis for the technology development and explain high efficacy achieved in the clinical trials and case reports with the use of LEP2000 Therapeutic System (IMI Inc.).
4. LEP therapy (LEP2000) has been tested for treatment of different sites of traumatic injuries (neck, ankle, wrist, etc.) exhibiting consistent positive results for both short term (immediate symptom relief) and cumulative healing effects after a course of therapy.
5. Comparative data with conventional therapies are presented that suggest that LEPT using LEP2000 Therapeutic System is more effective than conventional therapies.

6. REFERENCES

- ¹ Curatolo M, and Bogduk N. Pharmacologic pain treatment of musculoskeletal disorders: current perspectives and future prospects. *Clin J Pain*. 2001; 17(1): 25-32.
- ² Wright A, Stuka KA. Nonpharmacological treatments for musculoskeletal pain. *Clin J Pain*. 2001; 17(1): 33-46.
- ³ Spitzer WO, Skovron ML, Salmi LR, et al. Scientific Monograph of the Quebec Task Force on Whiplash-Associated Disorders: Redefining “Whiplash” and its Management. *SPINE* 1995 Suppl: 20(8S): 2S-73S.
- ⁴ Mester E, et al. The biomedical effects of laser application. *Lasers Surg Med* 1985; 5: 31-39.
- ⁵ Gupta AK, Filonenko N, Salansky N, Sauder DN, The use of low energy photon therapy (LEPT) in venous leg ulcers: a double-blind, placebo controlled study. *Dermatologic Surgery* 1998;24: 1383-1386.
- ⁶ Chaiton A, Filonenko N, Salansky N, Durrant N. Low energy photonic therapy is effective for the restoration of median nerve function in patients with chronic carpal tunnel syndrome (clinical trial). Manuscript in preparation. *Muscle & Nerve* (to be submitted 2004).
- ⁷ Gupta AK, Telfer J, Filonenko N, Salansky N, Sauder DN. The use of low-energy laser (photon) therapy in the treatment of leg ulcers – a preliminary study. *Journal of Dermatological Treatment* 1997; 8: 1-6.
- ⁸ Telfer J, Filonenko N, Salansky N. Leg ulcer plastic surgery descent by laser therapy. *Proceedings of SPIE. Medical Applications of Lasers*. 1993; 2086: 258-260.
- ⁹ Filonenko N, Livshitz O, Salansky N. Low Energy Laser Biostimulation Therapy (LELBT) of musculoskeletal disorders: clinical study. *SPIE Laser Surgery* 1992; 1643: 240-50.
- ¹⁰ Filonenko N, Salansky N. Photobiostimulation for the treatment of purulent wounds, burns and post-traumatic conditions. Department of National Defence of Canada. DIR Project No: 215. Final Technical Report. 1997.
- ¹¹ Salansky N, Filonenko N. Method and apparatus for localized low energy photon therapy (LEPT). United States Patent No 6,063,108, May 16, 2000.
- ¹² Salansky N, Filonenko N. Method for localized low energy photon therapy (LEPT). United States Patent No 6,494,900 B1, Dec 17, 2002.
- ¹³ M. Dyson, N. Salansky (Filonenko), N. Salansky, editors. *LOW ENERGY PHOTONIC AND LASER THERAPY: basic science, dosimetry, clinical applications, new developments*. Book manuscript under preparation. 2004.
- ¹⁴ Whelan HT, Buchmann EV, Whelan NT, Turener SG et al: NASA light emitting diode medical applications from deep space to deep sea. *CP552, Space Technology and applications International Forum-2001*; 552: 35-45.
- ¹⁵ Karu T, Pyatibrat L, Kalendo G. Irradiation with He-Ne laser increases ATP level in cells cultivated in vitro. *J Photochem Photobiol B* 1995;27(3):219-23.
- ¹⁶ Lubart R, Friedmann H, Shelpan L and Grossman N. Photosensitized biostimulation of keratinocytes and fibroblasts by low energy visible light. *Proc SPIE* 1995; 2323: 507-514.
- ¹⁷ Lam TS, Abergel RP, Meeker CA, et al. Laser stimulation of collagen synthesis in human skin fibroblast cultures. *Lasers Life Sci* 1986; 1(1): 61-77.
- ¹⁸ Haas AF, Isseroff RR, Wheeland Rg, et al. Low energy helium neon laser irradiation increases the motility of cultured human keratinocytes. *J Invest Dermatol* 1990; 94:822-26.
- ¹⁹ Yu HS, Chang KL, Yu CL et al. Low energy helium-neon laser irradiation stimulates interleukin-1 and interleukin-8 release from cultured human keratinocytes. *J Invest Dermatol* 1996; 107:593-6.
- ²⁰ Haas AF, Isseroff RR, Wheeland Rg, et al. Low energy helium neon laser irradiation increases the motility of cultured human keratinocytes. *J Invest Dermatol* 1990; 94:822-26.
- ²¹ Steinlechner CWB, Dyson M. The effects of low level laser therapy on the proliferation of keratinocytes. *Laser Ther* 1993; 5:65-73.

- ²² Yu HS, Chang KL, Yu CL et al. Low energy helium-neon laser irradiation stimulates interleukin-1 and interleukin-8 release from cultured human keratinocytes. *J Invest Dermatol* 1996; 107:593-6.
- ²³ Gross AJ, Jelkmann W. Helium-neon laser irradiation inhibits the growth of kidney epithelial cells in culture. *Lasers Surg Med* 1990; 10:40-44.
- ²⁴ Lam TS, Abergel RP, Meeker CA, et al. Laser stimulation of collagen synthesis in human skin fibroblast cultures. *Laser Life Sci* 1:61-77, 1986.
- ²⁵ Bosatra M, Jucci A, Olliaro P, et al. *In vitro* fibroblast and dermis fibroblast activation by laser irradiation at low energy. *Dermatologica* 1984; 168:157-62.
- ²⁶ Lyons RF, Abergel RP, Lam TS, et al. Stimulation of wound healing by lasers. *SPIE. Optical and Laser Technology in Medicine* 1986; 605:45-51.
- ²⁷ Abergel RA, Lyons RF, Castel JC, et al. Biostimulation of wound healing by lasers: Experimental approaches in animal models and in fibroblast cultures. *J Dermatol Surg Oncol* 1987; 18:127-33.
- ²⁸ Saperia D, Glassberg E, Lyons RF, et al. Demonstration of elevated type I and III Procollagen mRNA levels in cutaneous wounds treated with helium-neon laser: Proposed mechanism for enhanced wound healing. *Biochem Biophys Res Commun* 1986; 138:1123-8.
- ²⁹ Hallman HO, Basford JR, O'Brien JF, Cummings LA. Does low-energy helium-neon laser irradiation alter "in vitro" replication of human fibroblasts? *Lasers Surg Med* 1988; 8(2): 125-9.
- ³⁰ Colver GB, Priestley GC. Failure of a helium-neon laser to affect components of wound healing in vitro. *Br J Dermatol* 1989; 121(2): 179-86.
- ³¹ Young S, Bolton P, Dyson M, et al. Macrophage responsiveness to light therapy. *Lasers Surg Med* 1989; 9:497-505.
- ³² Funk JO, Kruse A, Kirchner H. Cytokine production after helium-neon laser irradiation in cultures of human peripheral blood mononuclear cells. *J Photochem Photobiol B* 1992; 16(3-4): 347-55.
- ³³ Yu W, Naim JO, Lanzafame RJ. The effect of laser irradiation on the release of bFGF from 3T3 fibroblasts. *Photochem Photobiol* 1994; 59(2): 167-70.
- ³⁴ Karu TI, Ryabykh TP, Fedoseyeva GE, Puchova NI. Helium-neon laser-induced burst of phagocytic cells. *Lasers Surg Med* 1989; 9(6): 585-8.
- ³⁵ Ricevuti G, Mazzone A, Monaia C, et al. *In vivo* and *in vitro* HeNe laser effects on phagocyte functions. *Inflammation* 1989; 13(5): 507-27.
- ³⁶ Hall G, Anneroth G, Schennings T, Zetterqvist L, Ryden H. Effect of low level energy laser irradiation on wound healing. An experimental study in rats. *Swed Dent J*. 1994;18(1-2):29-34.
- ³⁷ Anneroth G, Hall G, Ryden H, Zetterqvist L. The effect of low-energy infrared laser radiation on wound healing in rats. *Br J Oral Maxillofac Surg* 1988; 26(1): 12-7.
- ³⁸ Basford JR, Hallman HO, Sheffield CG, et al. Comparison of cold-quartz ultraviolet, low-energy laser, and occlusion in wound healing in a pig model. *Arch Phys Med Rehabil* 1986; 67:151-154.
- ³⁹ Mester E, Mester AF, Mester A. The biomedical effects of laser application on biological systems. *Laser Rev* 1968; 1:3.
- ⁴⁰ Braverman B, McCarthy RJ, Ivankovich AD, Forde DA, Overfield M, Bapna MS. Effect of He-Ne and infrared laser irradiation on wound healing in rabbits. *Lasers Surg Med* 1989; 9:50-58.
- ⁴¹ Surinchak JS, Alago ML, Bellamy RF, et al. Effects of low-level energy lasers on the healing of full thickness skin defects. *Lasers Surg Med* 1983; 2:267-74.
- ⁴² Lyons RF, Abergel RP, White RA, et al. Biostimulation of wound healing *in vivo* and a helium-neon laser. *Ann Plat Surg* 1987; 18:47-50.
- ⁴³ Bisht D, Gupta SC, Misra VP, and Sharma P. Effect of low intensity laser radiation on healing of open skin wounds in rats. *Indian J Med Res* 1994; 100: 43-6.

- ⁴⁴ Haina D, Brunner R, Landthaler M. Animal experiments in light induced wound healing. *Basic Biomed Res* 1982; 22: 1-3.
- ⁴⁵ Mester E, Spiry I, Szende B, and Tota JG. Effect of laser rays on wound healing. *Am J Surg* 1971; 122: 532-5.
- ⁴⁶ Kana JS, Hutschenreiter G, Haina D, Waidelich W. The effect of low power density laser radiation on healing of open skin wounds in rats. *Arch Surg* 1981; 116:293-96.
- ⁴⁷ Hutschenreiter G, Haina D, Paulini K, and Schumacher G. Wundheilung nach laser- und rotlichtbestrahlung. *L Exp Chir* 1980; 13, 75-85.
- ⁴⁸ Marcel MH, de Braekt I, Frank IM, et al. Effect of low-level laser therapy on wound healing after palatal surgery on beagle dogs. *Lasers Med Surg* 1991;11:462-70.
- ⁴⁹ Allendorf JD, Bessler M, Huang J, et al. Helium-neon laser irradiation at fluences 1, 2, and 4 J/cm² failed to accelerate wound healing as assessed by both wound contracture rate and tensile strength. *Lasers Surg Med* 1997; 20(3): 340-5.
- ⁵⁰ Hunter J, Leonard L, Wilson R, et al. Effects of low energy laser on wound healing in a pig model. *Lasers Surg Med* 3:285-90, 1984.
- ⁵¹ Al-Watban FAH and Zhang XY. Dosimetry-Related Wound Healing Response in the Rat Model Following HeNe Laser, LLLT. *Laser Therapy* 1994; 6(2): 119-24.
- ⁵² Al-Watban FAH and Zhang XY. Stimulative and Inhibitory Effects of Low Incident Levels of Argon Laser Energy on Wound Healing (LLLT). *Laser Therapy* 1995; 7(1): 11-8.
- ⁵³ Al-Watban FAH and Zhang XY. Comparison of the Effects on Wound Healing Using Different Lasers and Wavelengths (LLLT). *Laser Therapy* 1996; 8(2) 127-35.
- ⁵⁴ Al-Watban FAH and Zhang XY. Lasers Acceleration of Open Skin Wound Closure in Rats and its Dosimetric Dependence. *Lasers in the Life Sciences* 1997; 7(4): 237-47.
- ⁵⁵ Lee P, Kim K, and Kim K. Effects of low incident energy levels of infrared laser irradiation on healing of infected open skin wounds in rats. *Laser Therapy* 5 (2): 59-63, 1993.
- ⁵⁶ Yu W, Naim JO, Lanzafame RJ. Effects of photostimulation on wound healing in diabetic mice. *Lasers Surg Med* 1997;20(1):56-63.
- ⁵⁷ Siebert W, Seichert N, Siebert B, and Wirth CJ. What is the efficacy of “soft” and “mid” lasers in therapy of tendinopathies? A double-blind study. *Arch Orthop Trauma Surg.* 1987; 106: 358-363.
- ⁵⁸ Krashennikoff M, Ellitsgaard N, Rogvi-Hansen B, Zeuthen A, Harder K, Larsen R and Gaardbo H. No effect of low power laser in lateral epicondylitis. *Scand J Rheumatol* 1994; 23: 260-263.
- ⁵⁹ Brockhaus A and Elger CE. Hypalgesic efficacy of acupuncture on experimental pain in man. Comparison of laser acupuncture and needle acupuncture. *Pain*, 1990, 43: 181-185.
- ⁶⁰ Klein RG, Eek BC. Low-energy laser treatment and exercise for chronic low back pain: double-blind controlled trial. *Arch Phys Med Rehabil.* 1990;71: 34-37.
- ⁶¹ Gam AN, Thorsen H and Lonnberg F. The effect of low-level laser therapy on musculoskeletal pain: a meta-analysis. *Pain.* 1993; 52: 63-66.
- ⁶² Salansky N. Investigation on “Skin Tissue Optical Windows”. National Research Council of Canada Report. 1988.
- ⁶³ Filonenko N, Gurevich Yu, Salansky N. Laser induced tissue temperature changes. Proceedings of the International Conference on LASERS’92. STS PRESS. McLEAN, VA 1993: 713-720.
- ⁶⁴ Gurevich Yu, Filonenko N, Salansky N. Analytical method for calculation of temperature distribution in laser-irradiated media with an external cooled surface. *Appl Phys Lett* 1994; 64(24): 3216-18.
- ⁶⁵ Filonenko N, Salansky N. International Medical Instruments Inc. Photobiostimulation for the treatment of purulent wounds, burns and post-traumatic conditions. DOD/DIR Project No: 215. Final Technical Report. 1997.
- ⁶⁶ Filonenko N, Salansky N. Low Energy Photon (Laser) Therapy. Basic Mechanisms and Healing Phenomena. IMI Inc. Internal Review. 1990, 1996, 2000, 305 p.

⁶⁷ Filonenko N, Salansky N. Introduction to the dosimetry for low energy photon (laser) therapy. IMI Inc. Internal Report. 1997.

⁶⁸ Salansky N, Filonenko N. Multifunctional equipment for whole blood chemiluminescence and its applications. Proceedings of SPIE. Biomedical Optoelectronic Devices and Systems II. 1994; 2328:224-43.

⁶⁹ Flock ST, et al. Hybrid Monte Carlo –Diffusion theory modelling of light distribution in tissue. SPIE Proceedings. 1988; 908:20-28.

⁷⁰ Wang L and Jacques SL. Hybrid model of Monte Carlo simulation and diffusion theory for light reflectance by turbid media. J Opt Soc A 1993; 10(8):1746-52.

⁷¹ Van de Hulst, H.C., “Multiple light scattering, Volume II”, Academic press, New York, 1980.

⁷² L.Wong, S. Jacques “Optimized radial & angular positions in Monte Carlo Modeling”, Med. Phys. 21, 7, July 1994.

⁷³ D. Rummelhart, G. Hinton, R. Williams “Learning representations by back-propagating errors”, Nature, V.323, pp. 533-536, 1986.

⁷⁴ M. Riedmiller, H. Braun “A direct adaptive method for faster backpropagation learning: The RPROP algorithm”, San Francisco, 1993.

⁷⁵ Schindl M, Kerschman K, Schindl A, Schon H, Heinzl H, Schindl L Induction of complete wound healing in recalcitrant ulcers by low-intensity laser irradiation depends on ulcer cause and size. Photodermatol Photoimmunol Photomed 1999; 15(1): 18-21.

⁷⁶ Schindl A, Schindl M, Pernerstorfer-Schon H, Kerschman K, Knobler R, Schindl L. Diabetic neuropathic foot ulcer: successful treatment by low-intensity laser therapy. Dermatology; 198(3):314-316, 1999.

⁷⁷ Santoianni P, Monfrecola G, Martellotta D, Ayala F. Inadequate effect of helium-neon laser on venous leg ulcers. Photodermatol 1984; 1(5): 245-9.

⁷⁸ Nussbaum EL, Biemann I, Mustard B. Comparison of ultrasound/ultraviolet-C and laser for treatment of pressure ulcers in patients with spinal cord injury. *Physical Therapy*. 1994; 74(9): 812-24.

⁷⁹ Malm M and Lundeberg T. Effect of low power gallium arsenide laser on healing of venous ulcers. Scand J Plast Reconstr Hand Surg. 1991; 25:249-251.

⁸⁰ Gogia PP and Marquez RR. Effects of helium-neon laser on wound healing. *Ostomy/Wound Management*. 1992; 38(6): 38-41.

⁸¹ Schindl A, Schindl M, Schon H, Knobler R, Havelec L, Schindl L. Low-intensity laser irradiation improves skin circulation in patients with diabetic microangiopathy. *Diabetes Care* 1998; 21(4): 580-4.

⁸² Cowen D, Tardieu C, Schubert M et al. Low energy helium-neon laser in the prevention of oral mucositis in patients undergoing bone marrow transplant: results of a double blind randomized trial. *Int J Rad Onc Biol Phys* 38:697-703, 1997.

⁸³ Gupta AK, Filonenko N, Salansky N, Sauder DN, The use of low energy photon therapy (LEPT) in venous leg ulcers: a double-blind, placebo controlled study. *Dermatologic Surgery*, 1998;24:1383-1386.

⁸⁴ Lalumandier JA, McPhee SD. Prevalence and risk factors of hand problems and carpal tunnel syndrome among dental hygienists. *J Dent Hyg* 2001 Spring;75(2):130-4.

⁸⁵ Kleinberg BA, Snider JE, Filonenko N, Salansky N. Low energy photon therapy (LEPT) as a new conservative treatment for carpal tunnel syndrome. *Lasers Surg Med* 1994; Supplement 6: 9.

⁸⁶ Verhagen AP, Scholten-Peters GG, de Bie RA, Bierma-Zeinstra SM. Conservative treatments for whiplash. : *Cochrane Database Syst Rev*. 2004;(1):CD003338.

⁸⁷ Chaundry IH, Clemens MG, et al. Alterations in cell function with ischemia and shock and their correction. *Arch Surg* 1981 Oct; 116 (!)0: 1309-17.

⁸⁸ Frederiks WM, Fronik GM. Quantitative analysis of the effect of ATP-MgCl₂ and adenosine-MgCl₂ on the extent of necrosis in rat liver after ischemia. *J Surg Res* 1986 Nov; 41(5): 518-23.

⁸⁹ Chaundry IH. Use of ATP following shock and ischemia. *Ann NY Acad Sci* 1990; 603: 130-40. A review.

- ⁹⁰ Harkema JM, Chaundry IH. Magnesium-adenosine triphosphate in the treatment of shock, ischemia, and sepsis. *Crit Care Med* 1992 Feb 20 (2): 263-75. A review.
- ⁹¹ Karu T. Photobiology of low-power laser effects. *Health Phys* 56:691-704, 1989.
- ⁹² Karu T, Tiphlova O. Role of primary photoreceptors in low power laser effects: action of HeNe laser radiation on bacteriophage T4-Escherichia coli interaction. *Lasers Surg Med* 9:67-9, 1989.
- ⁹³ Passarella S, Casamassima E, et al. Increase in proton electrical potential and ATP synthesis in rat liver mitochondria irradiated *in vitro* by helium-neon laser. *FEBS Lett* 175:95-9, 1984.
- ⁹⁴ Karu T. Photobiology of low-power laser effects. *Health Phys* 56:691-704, 1989.
- ⁹⁵ Zhu Q, Yu W, et al. Photoirradiation improved functional preservation of the isolated rat heart. *Lasers Surg. Med* 1997; 20 (3): 332-9.
- ⁹⁶ Yu W, Chi LH, Naim JO, Lanzafame RJ. Improvement of host response to sepsis by photomodulation. *Lasers Surg Med* 1997; 21 (3): 262-8.
- ⁹⁷ Kozjura VL, Dvoretiskii SV, et al. The effect of intravascular helium-neon laser blood irradiation on the state of the compensatory processes in the acute period of hemorrhagic shock and after resuscitation. *Anesteziol Reanimatol* 1993; 4: 43-8.
- ⁹⁸ Koshelev BH. Laser in the management of peritonitis. Saratov University's Publishing House. 1992. 112p. (ISBN 5-292-01507-5).
- ⁹⁹ Fitz-Ritson D, Filonenko N, Salansky N. Efficacy of low-energy photon therapy (LEPT) - in extensor neck muscle and sleep pattern recovery after "whiplash" injury-randomized trial. 8th International Symposium. Banff, Canada. Delegate Kit 1995: p. 46.
- ¹⁰⁰ Fargas-Babjak A, Salansky N, Salansky N., Telfer J, Imada S. Low Energy Photonic Therapy is more effective for pain relief than Ultrasound: double blind clinical trial. Manuscript in preparation. *Clinical Journal of Pain*, (to be submitted) 2004.
- ¹⁰¹ Filonenko N, P. Mertz, S. Davis, Salansky N. International Medical Instruments Inc. Low Energy Photon Therapy for Partial Thickness Wound Healing in a Porcine Model. Final Technical Report On the Contract N° W7711-6-7333/001/SRV, 1998: 42p.
- ¹⁰² Eaglstein WH, Mertz PM: effect of topical medicaments on the rate of repair of superficial wounds. (Dineen and Hildick-Smith, eds.) In: The Surgical Wound. Lea & Febiger, Philadelphia 1982; Chapter 14, pp150-70
- ¹⁰³ Eaglstein WH, Mertz PM. New method for assessing epidermal wound healing: The effects of triamcinolone acetonide and polyethelene film occlusion. *J Invest Dermatol* 71:382-384, 1978.
- ¹⁰⁴ Kaiser ME, Davis SC, Mertz PM: The effect of ultraviolet irradiation-induced inflammation on epidermal wound healing. *Wound Rep Reg*, 1995;3(3):311-15
- ¹⁰⁵ Mertz PM, Hebda PA, Eaglstein WH: A porcine model for evaluating epidermal wound healing. *Swine in Biomedical Research*, 1986
- ¹⁰⁶ Davis SC, Bilevich ED, Cazzaniga AL, mertz PM: Early debridement of second degree burn wounds enhances the rate of epithelization / An animal model to evaluate burn wound therapies. *J Burn Care and rehabilitation* 17:558-61, 1996
- ¹⁰⁷ Davis SC, Mertz PM, Eaglstein WH. Second degree Burn healing: The effect of occlusive dressings and a cream. *J Surg Res*. 48:245-48, 1990
- ¹⁰⁸ Lilius EM, and Marnila P. Photon emission of phagocytes in relation to stress and disease. *Experientia*. 1992;48:1083-91.
- ¹⁰⁹ De Sole P. Polymorphonuclear chemiluminescence. Some clinical applications. *J Biolumin & Chemilum*. 1989;4:251-62.
- ¹¹⁰ Allen RC. Phagocytic leukocyte oxygenation activities and chemiluminescence: a kinetic approach to analysis. In: *Methods in Enzymology. Bioluminescence and Chemiluminescence. Part B*. Ed. M. DeLuca and W. WcElroy. Academic Press, Inc. 1986; 133: 449-493.

¹¹¹ Allen RC. Measuring blood phagocyte opsonin receptor expression. Pub. ExOxEmis Inc., San Antonio, TX, 1992, 47 p.

¹¹² Lindena J, Burkhardt H, and Dwenger A. Mechanisms of non-opsonized symosan induced and luminol enhanced chemiluminescence in whole blood and isolated phagocytes. *J Clin Chem & Biochem.* 1987; 25:765-78.

¹¹³ Braun BL. Effects of ankle sprain in a general clinic population 6 to 18 months after medical evaluation. *Arc Fam Med* 1999;8(2):143-8.

¹¹⁴ Verhagen AP, de Bie RA, Lenssen AF, et al. Impact of quality items on study outcome. Treatments in acute lateral ankle sprains. *Int J Technol Assess Health Care* 2000; 16(4):1136-46.

¹¹⁵ Glasoe WM, Allen MK, Awtry BF, Yack HJ. Weight-bearing immobilization and early exercise treatment following a grade II lateral ankle sprain. *J Orthop Sports Phys Ther* 1999; 29(7):394-9.

© 2004, International Medical Instruments Inc. All rights reserved