

NON-INVASIVE METHODS FOR DETERMINING LESION DEPTH FROM VESICANT EXPOSURE

E.H. Braue, Jr., J.S. Graham, B.F. Doxzon, K.A. Hanssen, H.L. Lumpkin, R.S. Stevenson, R.R. Deckert, S.J. Dalal, and Larry W. Mitcheltree, U.S. Army Medical Research Institute of Chemical Defense, Aberdeen Proving Ground, Maryland, 21010-5400, USA,
ernest.braue@amedd.army.mil

SUMMARY

Before sulfur mustard injuries can be effectively treated assessment of lesion depth must occur. Accurate depth assessment is important, because it dictates how aggressive treatment needs to be to minimize or prevent cosmetic and functional deficits. Depth of injury is typically assessed by physical examination. Diagnosing very superficial and very deep lesions is relatively easy for the experienced burn surgeon. Lesions of intermediate depth, however, are often problematic in determining the need for grafting. This study was a preliminary evaluation of three non-invasive bioengineering methodologies, reflectance colorimetry (RC), laser Doppler perfusion imaging (LDPI) and indocyanine green fluorescence imaging (ICGFI), to determine their ability to accurately diagnose depth of sulfur mustard lesions in a weanling swine model. Six female animals (8-12 kg) were exposed to 400 μ l of neat sulfur mustard on 6 ventral sites for 2, 8, 30, or 60 minutes. This exposure regimen produced lesions of varying depth from superficial to deep dermal. Evaluations of lesion depth using the bioengineering techniques were conducted at 24, 48, and 72 hours postexposure. Following euthanasia at 72 hours postexposure, skin biopsies were taken from each site and processed for routine H & E histological evaluation to determine the true depth of the lesion. Preliminary results demonstrated that LDPI (figure 1) and ICGFI (figure 2) were useful tools to characterize skin perfusion and provided a good estimate of HD lesion depth. The RC data are still being analyzed; however, the initial interpretation suggests that the data do not provide useful information concerning lesion depth. A 2-min HD exposure produced a superficial lesion. LDPI and ICGFI showed increase blood flow for the 2-min HD lesion at all observation times. An 8-min HD exposure produced a lesion on intermediate depth with severe diffuse necrosis of the superficial dermis. LDPI and ICGFI showed increase blood flow for the 8-min HD lesion at all observation times. A 30-min HD exposure produced a deep full-thickness lesion with severe, diffuse necrosis of epidermis and dermis and severe hemorrhage and edema extending throughout the deep dermis. LDPI and ICGFI showed decreased blood flow for the 30-min HD lesion at all observation times. A 60-min HD exposure produced a deep full-thickness lesion with severe, diffuse necrosis of epidermis and severe diffuse necrosis, hemorrhage and edema throughout the dermis extending to the deep muscle layer. LDPI and ICGFI showed decreased blood flow for the 60-min HD lesion at all observation times. Lesion depths were confirmed by histological evaluation on selected samples from each exposure time. A complete histological evaluation will be done for all experimental sites. The novel prototype ICGFI instrument used in this study offered several advantages over LDPI and ICGFI instruments currently available, including real-time imaging of blood flow through lesions, cost, small size, portability, and not requiring the patient to be re-positioned. LDPI and ICGFI accurately predicted the need for aggressive treatment (30- and 60-min HD lesions) and non-aggressive treatment (2- and 8-min HD lesions) for the lesions generated in this study.

| Report Documentation Page | | | | Form Approved OMB No. 0704-0188 | |
|--|------------------------------------|-------------------------------------|---|--|---------------------------------|
| Public reporting burden for the collection of information is estimated to average 1 hour per response, including the time for reviewing instructions, searching existing data sources, gathering and maintaining the data needed, and completing and reviewing the collection of information. Send comments regarding this burden estimate or any other aspect of this collection of information, including suggestions for reducing this burden, to Washington Headquarters Services, Directorate for Information Operations and Reports, 1215 Jefferson Davis Highway, Suite 1204, Arlington VA 22202-4302. Respondents should be aware that notwithstanding any other provision of law, no person shall be subject to a penalty for failing to comply with a collection of information if it does not display a currently valid OMB control number. | | | | | |
| 1. REPORT DATE 00 DEC 2004 | | 2. REPORT TYPE N/A | | 3. DATES COVERED - | |
| 4. TITLE AND SUBTITLE Non-Invasive Methods For Determining Lesion Depth From Vesicant Exposure | | | | 5a. CONTRACT NUMBER | |
| | | | | 5b. GRANT NUMBER | |
| | | | | 5c. PROGRAM ELEMENT NUMBER | |
| 6. AUTHOR(S) | | | | 5d. PROJECT NUMBER | |
| | | | | 5e. TASK NUMBER | |
| | | | | 5f. WORK UNIT NUMBER | |
| 7. PERFORMING ORGANIZATION NAME(S) AND ADDRESS(ES) Mitcheltree, U.S. Army Medical Research Institute of Chemical Defense, Aberdeen Proving Ground, Maryland, 21010-5400, USA | | | | 8. PERFORMING ORGANIZATION REPORT NUMBER | |
| 9. SPONSORING/MONITORING AGENCY NAME(S) AND ADDRESS(ES) | | | | 10. SPONSOR/MONITOR'S ACRONYM(S) | |
| | | | | 11. SPONSOR/MONITOR'S REPORT NUMBER(S) | |
| 12. DISTRIBUTION/AVAILABILITY STATEMENT Approved for public release, distribution unlimited | | | | | |
| 13. SUPPLEMENTARY NOTES See also ADM001736, Proceedings for the Army Science Conference (24th) Held on 29 November - 2 December 2005 in Orlando, Florida., The original document contains color images. | | | | | |
| 14. ABSTRACT | | | | | |
| 15. SUBJECT TERMS | | | | | |
| 16. SECURITY CLASSIFICATION OF: | | | 17. LIMITATION OF ABSTRACT UU | 18. NUMBER OF PAGES 2 | 19a. NAME OF RESPONSIBLE PERSON |
| a. REPORT unclassified | b. ABSTRACT unclassified | c. THIS PAGE unclassified | | | |

Figure 1. Graph of image analysis giving the mean (\pm SD) LDPI blood perfusion ratio comparing lesion skin with normal perilesional skin for weanling swine exposed to 400 μ l of neat sulfur mustard for 2, 8, 30, and 60 minutes at 24, 48, and 72 hours postexposure. Partial thickness lesions (2- and 8-min exposure) show equal or increased perfusion, while full-thickness/deep dermal lesions (30- and 60-min) show decreased perfusion.

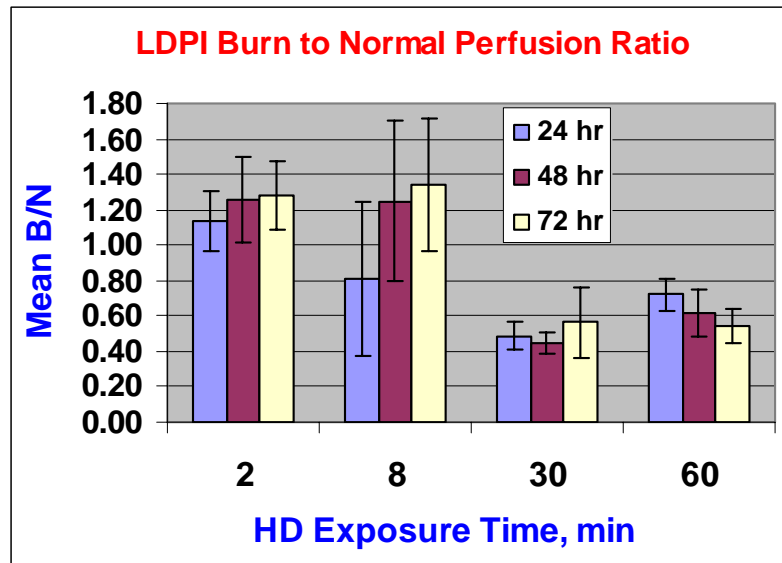


FIGURE 2. Graph of image analysis giving the mean ICG fluorescence brightness ratio comparing lesion skin to normal perilesional skin for weanling swine exposed to 400 μ l of neat sulfur mustard for 2, 8, 30, and 60 minutes at 24, 48, and 72 hours postexposure. Pictures take within 30 seconds of ICG injection. Partial thickness lesions (2- and 8-min exposure) show equal or increased brightness, while full-thickness/deep dermal lesions (30- and 60-min) show decreased brightness.

