

AD_____

Award Number: DAMD17-00-1-0560

TITLE: Characterization of the Hen as a Model for Human Ovarian Cancer

PRINCIPAL INVESTIGATOR: Patricia A. Johnson, Ph.D.

CONTRACTING ORGANIZATION: Cornell University
Ithaca, New York 14853-2801

REPORT DATE: September 2004

TYPE OF REPORT: Final

PREPARED FOR: U.S. Army Medical Research and Materiel Command
Fort Detrick, Maryland 21702-5012

DISTRIBUTION STATEMENT: Approved for Public Release;
Distribution Unlimited

The views, opinions and/or findings contained in this report are those of the author(s) and should not be construed as an official Department of the Army position, policy or decision unless so designated by other documentation.

20050204 100

REPORT DOCUMENTATION PAGEForm Approved
OMB No. 074-0188

Public reporting burden for this collection of information is estimated to average 1 hour per response, including the time for reviewing instructions, searching existing data sources, gathering and maintaining the data needed, and completing and reviewing this collection of information. Send comments regarding this burden estimate or any other aspect of this collection of information, including suggestions for reducing this burden to Washington Headquarters Services, Directorate for Information Operations and Reports, 1215 Jefferson Davis Highway, Suite 1204, Arlington, VA 22202-4302, and to the Office of Management and Budget, Paperwork Reduction Project (0704-0188), Washington, DC 20503

1. AGENCY USE ONLY (Leave blank)		2. REPORT DATE September 2004	3. REPORT TYPE AND DATES COVERED Final (1 Sep 2000 - 31 Aug 2004)	
4. TITLE AND SUBTITLE Characterization of the Hen as a Model for Human Ovarian Cancer			5. FUNDING NUMBERS DAMD17-00-1-0560	
6. AUTHOR(S) Patricia A. Johnson, Ph.D.				
7. PERFORMING ORGANIZATION NAME(S) AND ADDRESS(ES) Cornell University Ithaca, New York 14853-2801 E-Mail: Paj1@cornell.edu			8. PERFORMING ORGANIZATION REPORT NUMBER	
9. SPONSORING / MONITORING AGENCY NAME(S) AND ADDRESS(ES) U.S. Army Medical Research and Materiel Command Fort Detrick, Maryland 21702-5012			10. SPONSORING / MONITORING AGENCY REPORT NUMBER	
11. SUPPLEMENTARY NOTES				
12a. DISTRIBUTION / AVAILABILITY STATEMENT Approved for Public Release; Distribution Unlimited				12b. DISTRIBUTION CODE
13. ABSTRACT (Maximum 200 Words) Investigation of basic factors involved in malignant transformation of the ovary has been hampered by the lack of an appropriate animal model. Most animals, with the exception of the domestic hen, do not spontaneously develop ovarian cancer. The use of two related genetic strains, which differ in spontaneous incidence of ovarian cancer may reveal an important difference between the two strains that could underlie the differential susceptibility to ovarian cancer. We have accumulated many hens of both strains and have observed an increasing incidence of the tumors with age. The C strain of hens was found to have a significantly higher plasma level of estradiol compared to the K strain. This was in spite of no difference in progesterone or laying rate. All ovarian tumors that we have examined express ovalbumin which may indicate that de-differentiation occurs during the disease process. Ovarian surface epithelial cells, the presumed site of origin of the tumors, express estrogen and progesterone receptors. Ovarian tumors also express progesterone receptors, associated with the glandular areas of proliferation. Finally, the transcription factor COUP-TFII which regulates ovalbumin production, is present in RNA isolated from tumor cells.				
14. SUBJECT TERMS Ovarian cancer, hen, animal model				15. NUMBER OF PAGES 30
				16. PRICE CODE
17. SECURITY CLASSIFICATION OF REPORT Unclassified	18. SECURITY CLASSIFICATION OF THIS PAGE Unclassified	19. SECURITY CLASSIFICATION OF ABSTRACT Unclassified	20. LIMITATION OF ABSTRACT Unlimited	

NSN 7540-01-280-5500

Standard Form 298 (Rev. 2-89)
Prescribed by ANSI Std. Z39-18
298-102

Table of Contents

Cover.....	1
SF 298.....	2
Introduction.....	4
Body.....	5
Key Research Accomplishments.....	11
Reportable Outcomes.....	11
Conclusions.....	12
References.....	13
Appendices.....	14

INTRODUCTION

Investigation of basic factors involved in malignant transformation of the ovary has been hampered by the lack of an appropriate animal model. Most animals do not spontaneously develop ovarian cancer. This may be related to the fact that the usual condition of most wild and domestic animals is pregnancy and/or lactation. The exception is the domestic chicken, which has been demonstrated by several investigators to spontaneously develop ovarian cancer (Campbell, 1951; Wilson, 1958; Fredrickson, 1987). In this respect, as well as the fact that the chicken is a persistent ovulator (laying breeds ovulate almost daily), the chicken is similar to modern day women. That is, most women have 10-20 years of monthly ovulations prior to one or two pregnancies, with a subsequent 10-20 years of ovulations prior to menopause. The overall hypothesis of our DOD supported project is that the hen is an excellent model for human ovarian epithelial cell cancer. We took a three-pronged approach in this project. First, we examined differences in spontaneous incidence between the C and K strains of hens as they aged and looked for pathological ovarian changes that may indicate site of origin of the tumors. Second, we evaluated possible differences between the strains in response to reproductive manipulations highly correlated to incidence in women; and third, we examined potential differences in cell signaling that may underlie the different incidence between the strains.

BODY

Task 1. To characterize the incidence of spontaneous ovarian adenocarcinoma in 3-5 year old hens of the C and K strains and document histological changes in the ovary that may precede tumor formation (months 1-30)

We are fortunate to have access to two strains of White Leghorn hens (Cornell strain C and strain K) which were previously compared with respect to incidence of ovarian adenocarcinoma (Cole, unpublished observations; Cole and Hutt, 1973). These strains are derived from a similar genetic background and were determined to have a different incidence of ovarian adenocarcinoma at approximately 2 years of age (C strain 6.2%; K strain 0.3%; $p < 0.02$; Cole and Hutt, 1973) although egg production and body weight did not differ. We repeated this study and found that these differences persist in our current strains and we also found the commonly observed increase in tumor incidence with age (Giles et al., in prep.). We are currently following the K strain for subsequent years and have observed some tumors in K strain hens at 3-4 years but the onset appears to be delayed compared to the C strain. Additional observations in our laboratory of a commercial strain of laying hens (Babcock B300 strain) have indicated an incidence at 4-5 years of age of approximately 45%. These observations and those of Fredrickson (1987) indicate that the incidence of ovarian cancer increases dramatically (32-45%), particularly in the fourth year, in hens that continue to ovulate.

We have begun to investigate the C and K strains for possible differences that could be related to the etiology of the ovarian tumors. We collected blood samples from different aged hens of the two strains at defined stages of the ovulatory cycle and assessed plasma estrogen and progesterone. Plasma estradiol was significantly higher in the C strain compared to the K strain at every year of age examined (Fig. 1; Davignon et al., in prep.), while progesterone was not consistently different between strains over the same time period. Most significantly, ovulation rate was not different between the two strains. These results, while correlative, were very intriguing because of the reported association of estrogen replacement therapy and increased risk of ovarian cancer in women (Lacey et al., 2002).

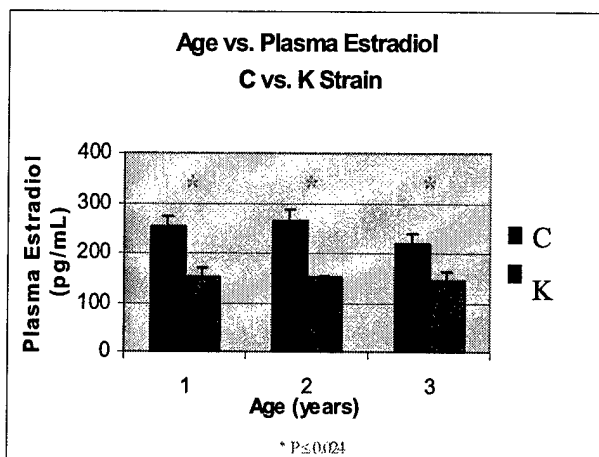


Figure 1 Graph of plasma estradiol in C and K strain hens relative to age. Blood samples were taken at a consistent time during the ovulatory cycle when basal levels were expected. ANOVA (2-way) indicated that overall the C strain had significantly higher estradiol than the K strain ($p < 0.001$) and asterisks indicate that C and K were different at each age (9-10 hens were sampled at each time).

We have also examined ovarian tumors for the expression of ovalbumin (Giles et al., 2004) and our data (Fig. 2) indicate that ovalbumin is expressed in all ovarian tumors, regardless of whether the oviduct is involved. In addition, ovalbumin was not expressed in any of the normal ovaries examined.

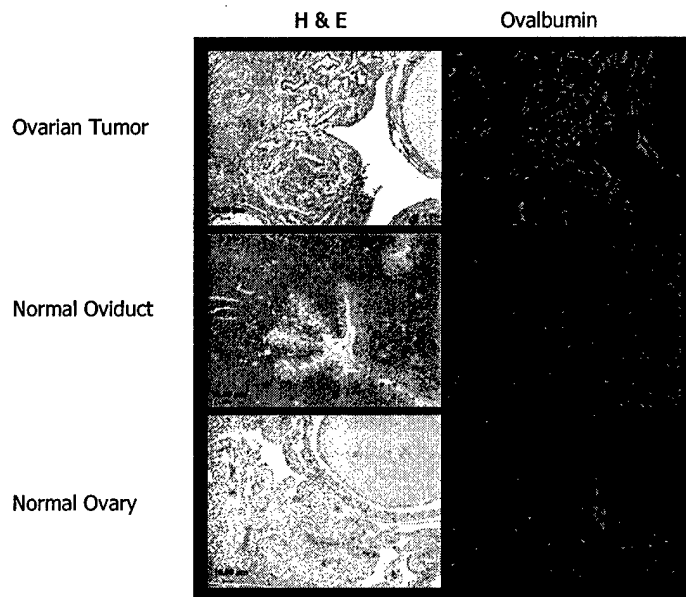


Figure 2 shows hematoxylin and eosin staining on the left and ovalbumin staining on the right (rabbit, anti-chicken ovalbumin; Bethyl Labs; 2nd antibody conjugated to fluorescein). Ovalbumin is present throughout ovarian tumor tissue. The positive control is oviduct and the glandular structure of the oviduct and diffuse ovalbumin staining is obvious in this panel. The negative control is normal ovary which is negative for ovalbumin expression (the slight fluorescence observed in this panel is due to autofluorescence of red blood cells).

We interpreted these data to mean that during the process of carcinogenesis, ovarian tissue may de-differentiate and exhibit characteristics of other mullerian-derived tissue such as the oviduct which normally produces ovalbumin. In addition, ovalbumin is not diagnostic of an oviductal tumor origin since we found it expressed in ovarian tumors when there was no oviductal involvement. More significantly, this process of an ovarian tumor adopting characteristics of mullerian derived tissue is observed in human epithelial cell tumors, most of which exhibit properties of the fallopian tube or oviduct (serous), cervix (mucinous) or endometrium (endometrioid). From that point of view, the tumors in hens resemble the serous type of tumors in women. This type of epithelial ovarian cancer is responsible for approximately 80% of epithelial ovarian cancer diagnosed.

Ascites which accumulates in the abdomen of hens afflicted with ovarian cancer contains cells presumably sloughed off from the ovarian tumors. These cells are thought to be involved in the metastasis of the tumors. **Figure 3** shows cells cultured from ascites fluid and stained with the anti-ovalbumin antibody. The left panels show the staining with ovalbumin antibody and the right ones show the same cells stained with propidium iodide, which stains nuclei. Interestingly, these cells are positive for ovalbumin, revealing a potential route for metastasis of the ovarian tumors




Figure 3 Ovalbumin staining of cells cultured from ascites fluid. The left top panel represents cells stained with ovalbumin antibody and the bottom is the negative control. On the right are the same panels stained with propidium iodide.

Task 2. To manipulate the incidence of ovarian adenocarcinoma in the C and K strain of hens to test the effect of ovulation rate on a different genetic background.

The aim in this study was to investigate the hypothesis that rupture and repair of the ovary during ovulatory events may be a factor in the development of ovarian cancer. Actively laying White Leghorn hens were administered pregnant mare's serum gonadotropin (PMSG) in an attempt to cause increased follicular development and superovulation. Unfortunately, we concluded that the effect of the PMSG on increasing follicular development (and, subsequently, taking the birds out of lay) was preventing further ovulation in these birds after the initial induced multiple ovulation. We attempted a shorter trial period of PMSG administration in the hopes that enough follicles would reach maturity and could be induced to ovulate, yet the effect was not so strong as to cause the bird to cease ovulating entirely. The hens were given PMSG for three days and then administered LH to induce multiple ovulation. Some birds in this treatment were killed and we observed that we were not able to induce multiple ovulation in these hens. Additionally, some of the hens not sacrificed ceased laying after only three days of PMSG treatment.

We concluded that the effect of PMSG varies greatly between the hens. We found it difficult to develop a treatment plan that caused enough follicular development to allow the induction of multiple ovulation yet did not take the birds out of lay. As the intent of our experiment was to increase the ovulation rate of the birds above the normal level, we concluded that the fact that many birds would stop laying as a result of PMSG administration would have adverse effects on our experimental aims.

As an alternate approach to this aim, and on the basis of our findings of the differences in the hormone profiles between the C and K strain hens (Task 1), we have examined the steroid sensitivity and estrogen and progesterone receptor status in the surface epithelial cells. This is the presumed site of origin of the tumors.



Figure 4 This figure shows a paraffin section of normal hen ovary stained with anti-ER-alpha antibody (Biocare Medical, Walnut Creek, CA; clone 1B5). Strong nuclear staining at the basal portion of the surface epithelial cell layer is observed.

10 ng/ml E₂



0 ng/ml E₂



Figure 5 Cultured hen OSE cells after treatment with vehicle (control) or estradiol (10ng/ml). Cells were fixed and stained with anti-P4 receptor antibody (clone PR6; Affinity Bioreagents) and then stained with a second antibody conjugated to fluorescein (AlexaFluor 488). Images were examined with a Nikon E-600 microscope with fluorescence capability and images captured with a Spot Rt Slider camera. Markedly increased nuclear expression of the progesterone receptor was observed after estradiol treatment, suggesting estrogen responsiveness (receptors) of the OSE.

Task 3. To characterize the activity of the Activin/Smad signal transduction system in cell signaling in the normal ovarian epithelial layer and tumors from the C and K strain hens.

As stated in last year's report, we have developed a system for the culture of ovarian surface epithelial cells. More than 90% of human ovarian cancers are believed to arise from the single layer of epithelial cells that covers the ovarian surface. In order to begin the experiments for this task, it was necessary to further characterize our culture system for the ovarian surface epithelial cells. We have been successful in culturing a pure preparation of ovarian surface epithelial cells but these cells are very difficult to grow. Since we know that these cells must be growing in vivo, we previously documented the PCNA staining characteristics of the ovarian surface epithelial (OSE) layer, indicating that cell proliferation is occurring in this layer.

The difficulty that we have had in culturing pure epithelial cells has discouraged us from pursuing the activin/Smad signal transduction system within the OSE. Furthermore, additional data in mammals have suggested that the expression of the inhibin/activin subunits is variable and unlikely to be causally related to ovarian cancer. Our data on the difference in estrogen level between the C and K strain hens and the correlation with incidence focused our interest on steroids. For this reason, we have concentrated on characterizing the steroid receptor status of OSE (after short term culture) and on the characterization of steroid receptors in ovarian tumors and normal ovarian tissue.

We have utilized chicken specific primers for the two types of estrogen receptor (ER), alpha and beta. Interestingly, in non quantitative RT-PCR, we have found consistent expression of the ERalpha and more variable expression of ERbeta in ovarian tumors. We are repeating this analysis with a quantitative PCR technique. If the initial observations are upheld, this would suggest that the ERbeta may have a role in modulating the action of estrogen in the hen and variability in expression of the receptor subtypes may influence susceptibility to the cancer.

The expression of ovalbumin in ovarian tumors suggested that this protein might be regulated by steroids as ovalbumin is in the oviduct. Progesterone is an important steroid involved in the production of ovalbumin in the oviduct. For this reason, we decided to examine normal OSE as well as tumors for the expression of the progesterone receptor. We obtained an antibody which recognized the progesterone receptor in hens and used this antibody in immunocytochemistry. As shown in **Figure 5**, normal OSE (as well as other ovarian cell types) clearly express the progesterone receptor.




Figure 6 This figure shows a paraffin section of a hen ovarian tumor stained with anti-P4 receptor antibody (clone PR6; same as in Fig. 5). Note the distinct nuclear binding in the glandular structures. Similar sections were stained (data not shown) with proliferating cell nuclear antigen (PCNA) and showed strong staining associated with the glandular structures.

In order to study the possibility that progesterone receptor could be involved in the regulation of the tumor, we studied the expression of the progesterone receptor in tumor tissue. As seen in **Figure 5**, nuclear progesterone receptor (green) was observed in the tumor. Although the progesterone receptor was expressed in diverse cell types in the ovary, strong expression in glandular -like structures was consistent a role in regulation of ovalbumin secretion.

In the hen, ovalbumin is specifically stimulated by estrogen. Another factor involved in regulation of ovalbumin expression is the orphan nuclear receptor, COUP-TFII (chicken ovalbumin upstream promoter-transcription factor II). COUP-TFII was isolated from hen oviduct cells and as an orphan nuclear receptor, it is a member of the steroid receptor superfamily. It is required for efficient transcription of the ovalbumin gene. Interestingly, COUP-TFII has been shown to be expressed in ovarian cancer cell lines. This report as well as our observation of ovalbumin expression in the hen ovarian tumors, provoked our interest in the role of COUP-TFII as possibly involved in the de-differentiation of hen ovarian tumors. We designed cDNA primers based on the reported sequence and used RT-PCR to determine if COUP-TFII was expressed in hen ovarian tumors (**Fig. 7**). We saw expression of a COUP-TFII transcript at 220bp, as defined by our primers.

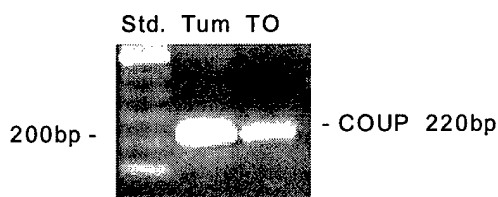


Figure 7 RT-PCR with primers for chicken COUP-TFII using RNA from hen ovarian tumor and normal ovary (TO).

KEY RESEARCH ACCOMPLISHMENTS

1. We have continued to accumulate C and K strain hens of various ages and have evaluated the age-related disease process in the hens. Tumors as well as normal ovaries have been examined in both C and K strain hens at selected intervals. Our data indicate that expression of ovalbumin is not indicative of oviductal origin of the tumors. We conclude that tumors originating in the ovary de-differentiate during the disease process and thereby express ovalbumin.
2. Although it was not possible to effectively increase the ovulation rate in the two strains of hens, we found that the C strain hens had significantly higher circulating estrogen levels as compared to the K strain. There was no difference with respect to age of the hen and average laying rate. This difference in estrogen level provides a convenient model for further study because estrogen has been implicated in the etiology of ovarian cancer.
3. We have characterized the expression of ovalbumin and progesterone receptor in normal ovaries as well as ovarian tumors from hens. Ovalbumin is not expressed in normal ovarian tissue. Expression of ovalbumin in tumor-containing ovaries occurs in regions of the ovary that are actively proliferating as indicated by PCNA.
4. Ascites which accumulates in the abdomen of hens afflicted with ovarian cancer contains cells presumably sloughed off from the ovarian tumors. These cells are thought to be involved in the metastasis of the tumors. Interestingly, these cells are positive for ovalbumin.

REPORTABLE OUTCOMES

- 1) Giles, J.R., C. DeLeonardis and P.A. Johnson. The isolation and primary culture of ovarian surface epithelium cells from the hen: a model for human ovarian cancer. Biology of Reproduction 64(Suppl. 1):316, 2001. (Abstr.)
- 2) Giles, J.R. and P.A. Johnson. Cell death in the ovarian surface epithelial cells from the stigma area of the largest follicles in the hen. Biology of Reproduction 66(Suppl. 1):132, 2002. (Abstr.)
- 3) Giles, J.R., Shivaprasad, H.L. and P.A. Johnson. Expression of Ovalbumin in Ovarian Tumors of the Domestic Hen. Biology of Reproduction 68 (Suppl. 1):236, 2003. (Abstr.)
- 4) Johnson, Patricia A. Ovarian Cancer in the Hen. Invited presentation at the XIVth Ovarian Workshop, Baltimore, MD. July, 2002.
- 5) Giles, J.R., Shivaprasad, H.L. and P.A. Johnson. Expression and Regulation of Ovalbumin Production in Ovarian Tumors of the Hen. Gynecologic Oncology, in press. Appendix.
- 6) Giles, J.R., Olson, L.M. and P.A. Johnson. Characterization of Ovarian Surface Epithelial Cells from the Hen - A Model for Spontaneous Ovarian Adenocarcinoma. In prep.

7) Davignon, D.L., Giles, J.R. and P.A. Johnson. Elevated Plasma Estradiol Levels and Increased Ovarian Mass Correlated to Increased Ovarian Cancer Incidence in the *Gallus domesticus* Model of Ovarian Cancer. In prep.

The above is a summary of work already presented or currently in the process of revision for submission. The funding also supported the research of a M.S. candidate (D. Davignon) who has completed her thesis. Two new Ph.D. students are continuing work on this project based on preliminary data collected during the funding period.

Finally, we have accumulated a sizable tissue bank of tumor and normal tissue from our C and K strain hens. These tissues include formalin fixed and cryopreserved ovarian/oviductal tissue, preserved ovarian tissue and plasma samples. In addition, we have a large flock of aging hens to be utilized in future studies.

CONCLUSIONS

This project is important because the hen spontaneously develops ovarian adenocarcinoma and therefore, questions related to etiology can be examined. This work is innovative because although previous workers have described ovarian adenocarcinoma in the hen, they have not attempted to study the regulation nor characterize the cell types involved. In addition, the use of two related genetic strains which differ in spontaneous incidence of ovarian cancer may reveal an important difference between the two strains that could underlie the differential susceptibility to ovarian cancer.

Our initial studies were directed at comparing ovarian cytology in normal hens and those with ovarian adenocarcinoma. We have examined many hens of both strains and have observed that the marked difference in incidence between the strains has been maintained. We have characterized the tumors in terms of ovalbumin expression as an indication of site of origin. We have also examined the expression of markers in the tumors. Our second approach was to manipulate the rate of follicle development and ovulation to examine the effect of repetitive ovulation on incidence. This experiment was not possible so we have instead focused on hormones related to ovulation. We found that the C strain has higher circulating levels of estrogen as compared to the K strain. Finally, we are studying regulation of the tumor by investigating receptor expression in the tumors.

The main cause of the lethality of ovarian cancer is the fact that it is usually diagnosed at an advanced stage. The availability of an animal model which spontaneously develops ovarian cancer (unlike most other animal models) would enhance the chance of finding a marker for early diagnosis. Knowledge about the etiology of ovarian cancer may help in the design of more optimal treatments. In addition, an animal model would permit the testing of pharmaceuticals that may decrease the growth of this cancer. Characterization of the two genetic strains may permit the identification of potential tumor markers.

REFERENCES

- Campbell, J.G. Some unusual gonadal tumours of the fowl. *Brit. J. of Cancer* 5:69-82, 1951.
- Cole, R.F. and F.B. Hutt. Selection and heterosis in Cornell white leghorns: A review, with special consideration of interstrain hybrids. *Animal Breeding Abstracts* 41:103-118, 1973.
- Fredrickson, T.N. Ovarian tumors of the hen. *Environmental Health Perspectives* 73:35-51, 1987.
- Lacey, J.V., P.A. Mink, J.H. Lubin, M.E. Sherman, R. Troisi, P. Hartge, A. Schatzkin and C. Schairer. Menopausal hormone replacement therapy and risk of ovarian cancer. *JAMA* 288:334-341, 2002.
- Wilson, J.E. Adeno-carcinomata in hens kept in a constant environment. *Poultry Sci.* 37:1253(abs.), 1958.

1

2

3

4

5 Ovarian Tumor Expression of an Oviductal Protein in
6 the Hen: A Model for Human Serous Ovarian
7 Adenocarcinoma

8

9 James R. Giles¹, H. L. Shivaprasad², Patricia A. Johnson³

10

11

12 Affiliations of authors:

13 ^{1,3}Department of Animal Science, Cornell University, Ithaca, New York,

14 ²University of California, CAHFS-Fresno Branch, School of Veterinary Medicine,
15 Davis, CA

16

17 Corresponding author: Patricia A. Johnson, Ph.D., Cornell University, Ithaca,

18 New York 14853 (e-mail: paj1@cornell.edu) fax 607 255 9829

19 **ABSTRACT**

20 Objective: We hypothesized that ovarian tumors without oviductal involvement
21 would not express the oviductal protein ovalbumin, the major protein found in the
22 magnum of the hen's oviduct.

23 Methods: On the basis of gross visual exam, tissues samples were removed from
24 hens determined to have ovarian tumors and were processed, embedded in
25 paraffin, sectioned, mounted on glass slides and stained with haematoxylin and
26 eosin. Ovarian tumors and other peritoneal lesions were evaluated histologically.
27 Paraffin sections of ovarian and oviductal tissue were deparaffinized and
28 evaluated for the protein expression of ovalbumin, proliferating cell nuclear
29 antigen (PCNA) and progesterone receptor (PR).

30 Results: Hens with ovarian adenocarcinoma without (n=10) or with (n=6)
31 oviductal involvement were positive for ovalbumin in the ovary. Ovary sections
32 from normal hens (n=9) were negative and oviductal sections from normal hens
33 (n=3) were positive for ovalbumin. Expression of PCNA protein was abundant in
34 all ovarian tumors (16/16). Oviductal epithelial cells strongly expressed PCNA
35 protein. Expression of PR was observed in 9/14 ovarian tumors.

36 Conclusion: The presence of ovalbumin in ovarian tumors in the absence of any
37 oviductal involvement suggests that ovarian tumors de-differentiate during the
38 disease process and thereby resemble serous-type ovarian tumors in women.

39 INTRODUCTION

40 The lifetime risk of ovarian adenocarcinoma for a woman is approximately
41 1.5% and it is the most lethal of the gynecological malignancies. The etiology and
42 early events in ovarian carcinogenesis are poorly understood. More than 90% of
43 all human ovarian cancers are epithelial in type and most of these are thought to
44 arise from invaginations of the modified mesothelial cell layer overlying the ovary
45 (1). Ovarian tumors are rarely observed in most species with the exception of
46 the domestic hen, which like the human, spontaneously develops ovarian
47 neoplasms (2-5). It is frequently difficult to determine, however, if the
48 reproductive tumors in the hen are of ovarian or oviductal origin because they are
49 often discovered at a late stage and implants are usually found on the ovary and
50 oviduct as well as on the mesentery and pancreas (3, 6). Haritani and co-
51 workers (6) utilized an immunological approach to determine the site of origin of
52 reproductive neoplasms in the hen. They attempted to identify the site of origin
53 of adenocarcinoma of hens using immunohistochemistry to detect ovalbumin in
54 neoplastic tissue. Ovalbumin is the major protein formed in normal oviductal
55 tissue. These authors examined tissues from hens diagnosed with
56 adenocarcinoma and found that the ovarian neoplasms expressed ovalbumin.
57 From these observations they suggested that most adenocarcinomas found in
58 mature hens may be oviductal in origin. Interestingly, hens in the above study
59 had oviductal, as well as ovarian neoplasms. We utilized a similar approach but
60 were fortunate to have hens diagnosed with adenocarcinoma without as well as
61 with oviductal involvement based on both gross and microscopic evidence. We

62 hypothesized that ovarian tumors without oviductal involvement would not
63 express the oviductal protein ovalbumin. In addition, we examined all ovarian
64 tumors for the expression of proliferating cell nuclear antigen (PCNA) and
65 progesterone receptor (PR). Although these proteins are not diagnostic of
66 ovarian or oviductal cancers, we wanted to demonstrate other markers
67 commonly observed in many human epithelial ovarian cancers as well as any
68 possible co-localization of these proteins with ovalbumin.

69 MATERIALS AND METHODS

70 Animals

71 Single-comb White Leghorn hens 2 to 5 years of age (5) were individually
72 caged and were maintained on a lighting schedule of 15L:9D (lights on at 0600
73 h). They were provided a commercial layer diet and had access to water. Animal
74 care and use was in accordance with the Institutional Animal Care and Use
75 Committee guidelines.

76 Sick or dying hens were necropsied and ascites, if present, was noted.
77 The ovary was observed for the presence of small nodules or cysts. Following
78 examination of the serosal surface of the oviduct for any abnormal growths, the
79 tissue was opened longitudinally and examined for any discoloration, thickening
80 of the mucosa or nodular growths. Representative samples of ovary, oviduct,
81 heart and liver as well as any metastatic tissues were fixed in 10% neutral
82 buffered formalin. Tissue samples were processed, embedded in paraffin,
83 sectioned at 4-7 μ m, mounted on glass slides and stained with haematoxylin and
84 eosin. Ovarian tumors and other peritoneal lesions were evaluated histologically.
85 Ovarian samples from those hens diagnosed with ovarian adenocarcinoma (n=10
86 without oviductal involvement; n=6 with oviductal involvement) that had been
87 previously fixed in 10% neutral buffered formalin at necropsy were submitted to
88 the Cornell Histology Laboratory for processing, embedding and section
89 preparation. These sections were evaluated for the protein expression of
90 ovalbumin, proliferating cell nuclear antigen (PCNA) and progesterone receptor
91 (PR) using indirect epifluorescence microscopy. Examinations of ovarian tumors

92 from each hen as well as control tissue were replicated three to five times. The
93 entire tissue section was examined by one observer for any specific cellular
94 expression of the proteins. Samples of ovarian tissue diagnosed to be free of
95 ovarian neoplasms were used as negative controls (n=9). In addition, oviductal
96 tissue from laying hens was used as a positive control for ovalbumin detection
97 (n=3).
98

99 Immunohistochemistry

100 Sections were deparaffinized in xylene and rehydrated in reducing
101 concentrations of ethanol, washed in phosphate buffered saline (PBS) and boiled
102 in 0.01M citrate buffer for 10 min. Tissue sections were blocked with 10% goat
103 serum in PBS for 30 min at 37° C and incubated with primary antibody overnight
104 at 5° C. Antibody controls were incubated with blocking solution alone. Slides
105 were washed in PBS three times and incubated with secondary antibody for 1 h
106 at 37°. Following washing, coverslips were applied and tissue sections were
107 examined with a Nikon E600 microscope under epifluorescence using
108 appropriate excitation and barrier filter sets and photographed with a RT Slider
109 Spot digital camera.

110 Primary antibodies were rabbit anti-chicken ovalbumin (1:100, Bethyl
111 Laboratories, Montgomery, TX), anti-PCNA (2 µg/ml; clone PC10; Santa Cruz
112 Biotechnology, Santa Cruz, CA) and anti-PR Ab-6 (2 µg/ml; Clone hPRa 6;
113 Affinity BioReagents, Golden, CO). Secondary antibodies were Alexa Fluor®
114 488 goat anti-rabbit and anti-mouse IgG conjugate (Molecular Probes, Eugene,
115 OR).

116 RESULTS

117 Ten hens were diagnosed with ovarian adenocarcinoma with no
118 indications of oviductal involvement based on gross or microscopic examination.
119 Six hens were diagnosed with ovarian adenocarcinoma but also had lesions in
120 oviductal tissue. Ovarian tumors from the 16 hens were characterized by firm
121 white cauliflower-like nodules often with fluid filled cysts. Ascites was present in
122 50% of the hens without and 100% of hens with oviductal involvement. The
123 ovarian tumors were often composed of columnar or high cuboidal epithelial cells
124 with basally situated nuclei and abundant eosinophilic cytoplasm (Fig 1, top left).
125 In some areas the nuclei were vesicular with prominent nucleoli. These cells
126 tended to form nests as well as glands of various sizes often accompanied by a
127 desmoplastic reaction in many foci (Fig 1, top left). In addition, often there were
128 atypical cells which had an appearance of squamous epithelial cells.

129 Ovarian tissue of hens (10/10) diagnosed with ovarian adenocarcinoma
130 without oviductal involvement were positive for ovalbumin in the ovary.
131 Furthermore, ovalbumin was detected in all hens (n=6) with tumors on the ovary
132 and oviduct. Ovary sections from normal hens (n=9) were negative and oviductal
133 sections from normal hens (n=3) were positive. Finally, ovalbumin expression in
134 ovarian sections was often localized in quite discrete patches (Fig 1, top middle).

135 Expression of PCNA protein was abundant in all ovarian tumors (16/16)
136 regardless of whether they were from hens with or without oviductal lesions (Fig
137 1, top right). PCNA staining was often observed in the nuclei of cells forming the
138 glandular nests but was also found in areas of stromal proliferation. In addition,

139 PCNA was observed in the surface epithelial cells and in granulosa cells of both
140 tumor and normal ovaries (data not shown). Oviductal epithelial cells strongly
141 expressed PCNA protein. Expression of PR was observed in 9/14 ovarian
142 tumors (Fig 2). Nuclear expression was often observed in the nests and
143 glandular areas of ovarian tumors as well as in the areas of stromal proliferation.
144 It was strongly expressed in the epithelial cells lining the oviduct as well as the
145 surface epithelial cells of the ovary (data not shown) and was not detected in the
146 granulosa cells.

147 **DISCUSSION**

148 Ovalbumin is the major protein of the magnum of the hen's oviduct and is
149 not normally found in other tissues (7). We hypothesized that ovarian tumors
150 without oviductal involvement would not express the oviductal protein ovalbumin,
151 whereas those with lesions in the oviduct may express this protein. Interestingly,
152 we observed expression in all ovarian neoplasms regardless of whether they
153 were from hens without or with oviductal lesions. Haritani and coworkers (6)
154 observed ovalbumin expression in all cancerous tissues from 12 hens diagnosed
155 with adenocarcinoma or peritoneal carcinomatosis. In their study cancerous
156 lesions were observed in the oviducts of all hens. Therefore, it was possible to
157 assume the site of origin may very well have been the oviduct. They concluded
158 that most adenocarcinomas in the abdomen of mature hens are oviductal in
159 origin. The presence of ovalbumin in 100% of the ovarian tumors in the present
160 study in the absence of any oviductal involvement suggests that ovalbumin can
161 not be used as a marker for distinguishing between ovarian and oviductal
162 adenocarcinomas. We cannot eliminate the possibility of micro-metastases from
163 the oviduct but the lack of any defined oviductal tumor suggests that the oviduct
164 may not be the primary site of origin in most ovarian adenocarcinoma. In
165 addition, ovalbumin may be one of the many components found in the ascites of
166 hens with reproductive tract neoplasms and the ovalbumin expression we
167 observed in the ovary could be due to contamination with ascites ovalbumin. We
168 believe this is unlikely since ovalbumin expression was observed within the ovary

169 and never observed near the surface. Furthermore, five hens without oviductal
170 involvement and without ascites expressed ovalbumin.

171 More than 90% of all human ovarian tumors are epithelial in type and are
172 thought to originate from invaginations of the epithelial cells surrounding the
173 ovary. These cells are embryologically derived from the coelomic epithelium and
174 retain the ability to undergo metaplasia and re-express the characteristics of the
175 Mullerian-duct derived epithelia: oviduct, endometrium and uterine cervix (8).
176 Furthermore, the high proportion of these tumor types in human ovarian cancer
177 serve as the basis for classification for many ovarian neoplasms – Fallopian
178 tube-like (serous tumors), endometrium-like (endometrioid), and endocervical-like
179 (mucinous). More than 80% of all epithelial ovarian cancers in the human are
180 serous adenocarcinomas (8). The fact that all ovarian tumors in the present
181 study expressed a major oviductal protein lends support to the possibility that
182 ovarian tumors in the hen may de-differentiate during the disease process.

183 Expression of PCNA was observed in tumors as well as normal tissues. It
184 was prominent in the gland-like areas and was often co-localized with ovalbumin
185 expression. PCNA is a marker for cell cycle activity and is involved in DNA
186 synthesis, repair and replication (9). The general appearance of widespread
187 PCNA staining in these tumors suggests high proliferative activity. Our findings
188 are similar to those of Rodriguez-Burford and co-workers (4) who observed
189 PCNA staining in the ovarian tumors of the hen.

190 Strong PR staining was observed in the glands and areas of stromal
191 proliferation but was absent from similar areas in other tumors. We have no

192 explanation for this observation except that the antibody used in this study
193 recognized only the A form of the receptor and not the B form. In the human,
194 however, PR A and B forms were observed in 33 and 14%, respectively, of 460
195 patients diagnosed with ovarian serous carcinoma (10). Furthermore, in the
196 immature chick oviduct estrogen has been shown not only to induce PR
197 expression but to alter the ratio of the two isoforms (11).

198 In summary, the presence of a major oviductal protein in 100% of hen
199 ovarian tumors in the absence of any oviductal involvement suggests that
200 ovarian tumors may de-differentiate during the disease process and acquire
201 characteristics of mullerian-duct derived epithelia, similar to the human. In this
202 respect, ovarian derived tumors in the hen may be a good model for serous
203 ovarian adenocarcinoma in women.

204 **ACKNOWLEDGEMENTS**

205 This work was supported in part by DOD award number DAMD17-00-1-
206 0296.

207

208 **REFERENCES**

- 209 1. Auersperg N, Maines-Bandiera SL. Culture and characterization of human
210 ovarian surface epithelium. In: Bartlett JMS (ed) Ovarian Cancer Methods
211 Protocols. Humana Press, Totowa, NJ, 2000; pp 169-74.
- 212 2. MacLachlan NJ. Ovarian disorders in domestic animals. Environ Health
213 Perspec 1987;73:27-33.
- 214 3. Fredrickson TN Ovarian tumors of the hen. Environ Health Perspec
215 1987;73:35-51.
- 216 4. Rodriguez-Burford C, Barnes MN, Berry W, Partridge EE, Grizzle WE.
217 Immunohistochemical expression of molecular markers in an avian model:
218 A potential model for preclinical evaluation of agents for ovarian cancer
219 chemoprevention. Gynecol Oncol 2001; 81:272-9.
- 220 5. Barnes MN, Berry WD, Straughn JMJ, Kirby TO, Leath CA, Huh WK,
221 Grizzle WE, Partridge EE. A pilot study of ovarian cancer
222 chemoprevention using medroxyprogesterone acetate in an avian model
223 of spontaneous ovarian carcinogenesis. Gynecol Oncol 2002; 87:57-63.
- 224 6. Haritani M, Kajigaya H, Akashi T, Kamemura M, Tanahara N, Umeda M,
225 Sugiyama M, Isoda M, Kato C. A study on the origin of adenocarcinoma in
226 fowls using immunohistological technique. Avian Diseases 1984;28:1130-
227 34.

- 228 7. Kohler PO, Grimley PM, O'Malley BW. Protein synthesis and differential
229 stimulation of cell specific proteins in epithelial cells of chick oviduct.
230 Science 1968;160:86-7.
- 231 8. Auersperg N, Wong AST, Choi KC, Kang SK, Leung PCK Ovarian surface
232 epithelium: Biology, endocrinology, and pathology Endocrin Rev 2001;
233 22:255-88.
- 234 9. Hall PA, Levison DA, Woods AL, Yu CC-W, Kellock DB, Watkins JA,
235 Barnes DM, Gillett CE, Camplejohn R, Dover R, Waseem NH, Lane DP.
236 Proliferating cell nuclear antigen (PCNA) immunolocalization in paraffin
237 sections: An index of cell proliferation with evidence of deregulated
238 expression in some neoplasms. J Pathol 1990;162:285-294.
- 239 10. Erik M, Heini L, Markku S, Arto L, Ake GJ, Guojun C, Ralf B, Riitta K.
240 Glycodelin in ovarian serous carcinoma: Association with differentiation
241 and survival. Cancer-Research 2003;63:6258-64.
- 242 11. Syvala H, Vienonen A, Ylikomi T, Blauer M, Zhuang Y, Tuohimaa P.
243 Expression of the chicken progesterone receptor forms A and B is
244 differentially regulated by estrogen in vivo. Biochem Biophys Res
245 Commun 1997; 231:573-576.

246 **FIGURE LEGENDS**

247 Fig 1: Ovarian tumor (top), oviduct (middle) and normal ovary (bottom) stained
248 with haematoxylin & eosin (left) or rabbit antiserum raised against chicken
249 ovalbumin (center) or mouse monoclonal antibody (PC10) against PCNA (right).
250 Normal oviduct was used as a positive control for ovalbumin and normal ovary
251 was used as a negative control. Autofluorescence of red blood cells is observed
252 in the normal ovary. Scale bar, 50 μ m.

253 Fig 2: Ovarian tumor stained with PR (Clone hPRa). Strong nuclear staining is
254 shown in the glandular areas of the tumor. Scale bar, 50 μ m.

255

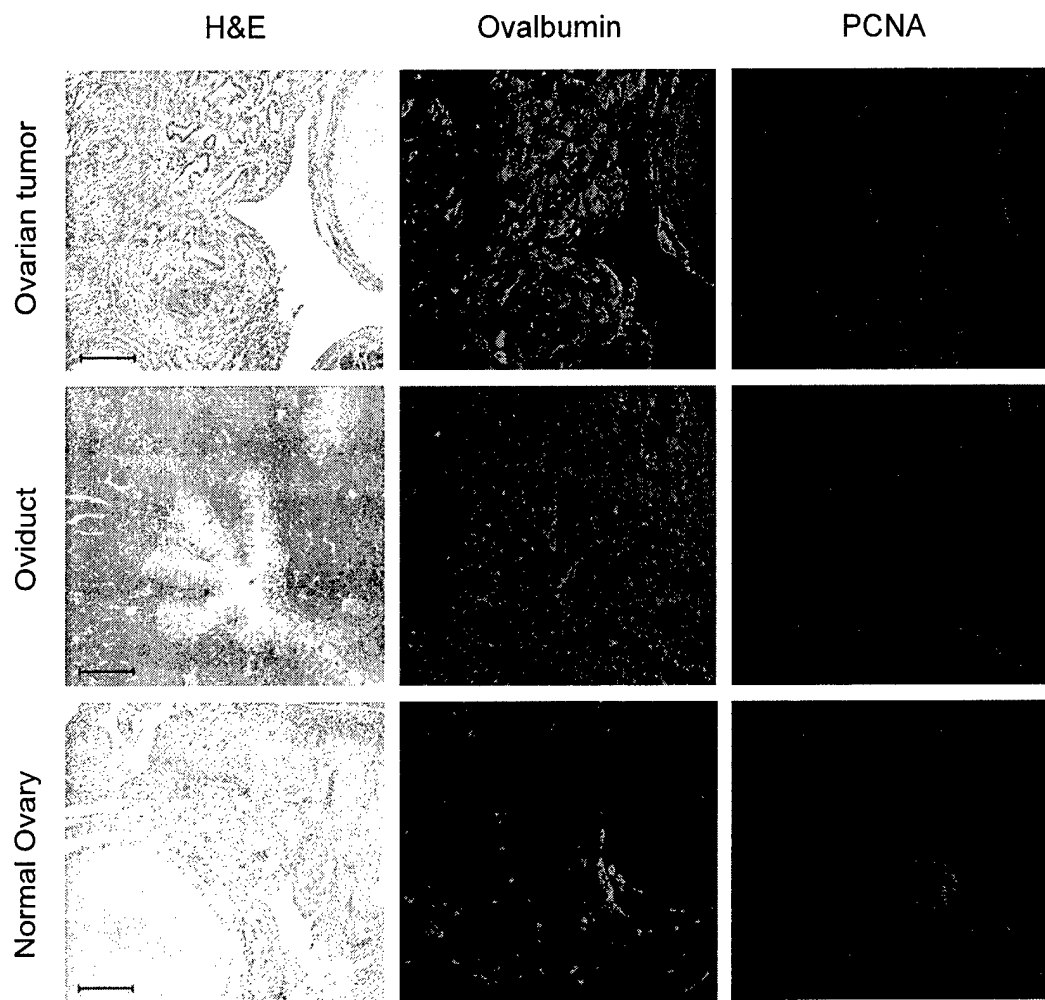


Figure 1




Figure 2