

AD _____

Award Number: DAMD17-01-1-0328

TITLE: Computer-Aided Characterization of Breast Masses on
Volumetric Ultrasound Images: An Adjunct to Mammography

PRINCIPAL INVESTIGATOR: Berkman Sahiner, M.D., Ph.D.

CONTRACTING ORGANIZATION: University of Michigan
Ann Arbor, Michigan 48109-1274

REPORT DATE: October 2002

TYPE OF REPORT: Annual

PREPARED FOR: U.S. Army Medical Research and Materiel Command
Fort Detrick, Maryland 21702-5012

DISTRIBUTION STATEMENT: Approved for Public Release;
Distribution Unlimited

The views, opinions and/or findings contained in this report are those of the author(s) and should not be construed as an official Department of the Army position, policy or decision unless so designated by other documentation.

20030317 005

REPORT DOCUMENTATION PAGE

Form Approved
OMB No. 074-0188

Public reporting burden for this collection of information is estimated to average 1 hour per response, including the time for reviewing instructions, searching existing data sources, gathering and maintaining the data needed, and completing and reviewing this collection of information. Send comments regarding this burden estimate or any other aspect of this collection of information, including suggestions for reducing this burden to Washington Headquarters Services, Directorate for Information Operations and Reports, 1215 Jefferson Davis Highway, Suite 1204, Arlington, VA 22202-4302, and to the Office of Management and Budget, Paperwork Reduction Project (0704-0188), Washington, DC 20503

1. AGENCY USE ONLY (Leave blank)		2. REPORT DATE October 2002	3. REPORT TYPE AND DATES COVERED Annual (6 Sep 01 - 5 Sep 02)	
4. TITLE AND SUBTITLE Computer-Aided Characterization of Breast Masses on Volumetric Ultrasound Images: An Adjunct to Mammography			5. FUNDING NUMBERS DAMD17-01-1-0328	
6. AUTHOR(S) Berkman Sahiner, M.D., Ph.D.				
7. PERFORMING ORGANIZATION NAME(S) AND ADDRESS(ES) University of Michigan Ann Arbor, Michigan 48109-1274 E-Mail: berki@umich.edu			8. PERFORMING ORGANIZATION REPORT NUMBER	
9. SPONSORING / MONITORING AGENCY NAME(S) AND ADDRESS(ES) U.S. Army Medical Research and Materiel Command Fort Detrick, Maryland 21702-5012			10. SPONSORING / MONITORING AGENCY REPORT NUMBER	
11. SUPPLEMENTARY NOTES Original contains color plates: All DTIC reproductions will be in black and white.				
12a. DISTRIBUTION / AVAILABILITY STATEMENT Approved for Public Release; Distribution Unlimited			12b. DISTRIBUTION CODE	
13. Abstract (Maximum 200 Words) (abstract should contain no proprietary or confidential information) The purpose of this project is to develop computer vision techniques for the analysis of sonographic images of breast masses, and to combine computerized sonographic and mammographic analyses. The techniques developed in this project are aimed at providing a second opinion to the radiologists in the task of making a biopsy recommendation. In the first year of the project, we started the collection of 3D, 2D, and volumetric ultrasound data sets. We have developed a graphical user interface for defining ellipsoids on 3D and volumetric sonograms and for ranking the lesions. We have made progress in our image segmentation, feature extraction, and classifier design methods. Specifically, we generalized a 2D segmentation method to 3D, and applied it to a data set of 101 biopsy-proven 3D ultrasound cases. Our characterization results so far are encouraging. When the 3D active contour boundaries were used, 42% of the biopsied benign masses were classified correctly without missing any malignant masses. Some of the major tasks in the second and third years of the project are to collect a larger number of volumetric cases, to improve these techniques and apply them to volumetric ultrasound images, and to combine sonographic analysis with mammographic analysis.				
14. SUBJECT TERMS computer-aided diagnosis, ultrasonography, breast masses, breast cancer detection			15. NUMBER OF PAGES 29	
			16. PRICE CODE	
17. SECURITY CLASSIFICATION OF REPORT Unclassified	18. SECURITY CLASSIFICATION OF THIS PAGE Unclassified	19. SECURITY CLASSIFICATION OF ABSTRACT Unclassified	20. LIMITATION OF ABSTRACT Unlimited	

(3) Table of Contents

(1) Front Cover 1

(2) Standard Form (SF) 298, REPORT DOCUMENTATION PAGE 2

(3) Table of Contents 3

(4) Introduction 4

(5) Body 4

 (A) Collection of Database

 (B) Development of a graphical user interface (GUI) for image analysis

 (C) Development of a 3D lesion segmentation method

 (D) Development of feature extraction techniques from ultrasound images

 (E) Development of a classifier for characterization of lesions on 3D ultrasound images

(6) Key Research Accomplishments 13

(7) Reportable Outcomes 13

(8) Conclusions 15

(9) References 15

(10) Appendix 16

(4) Introduction

At present, biopsy is the gold standard in breast lesion characterization. However, the positive breast biopsy rate is only about 15-30%. This means that 70-85% of breast biopsies are performed for benign lesions. In order to reduce patient anxiety and morbidity, as well as to decrease health care costs, it is desirable to reduce the number of benign biopsies without missing malignancies. Mammography and sonography are two low-cost imaging modalities that may be improved so that radiologists can obtain more accurate diagnostic information to differentiate malignant and benign lesions. Computerized analysis of the lesions on these images is one of the promising tools that may improve the radiologists' accuracy in characterizing these lesions by providing a consistent and reliable second opinion to radiologists.

In this project, our goal is to analyze volumetric images to improve the accuracy of computerized sonographic breast lesion characterization, and to combine these characterization results with those obtained by computerized analysis of mammograms. Computerized image analysis, feature extraction, and classification methods will be developed to characterize breast masses on three-dimensional or volumetric ultrasound images. The output of the classifier will be a computer rating related to the likelihood of malignancy of the mass. The accuracy of this rating will be studied by comparing it to the biopsy results. We will then combine this rating with a similar rating obtained by computerized analysis of the mammograms of the same patient. The combined classifier is expected to be more accurate than either classifier alone.

(5) Body

In the current project year (9/6/01-9/5/02), we have performed the following studies:

(A) Collection of Database

We have started collecting a database of volumetric and 2D sonograms, and we have increased the size of our database of 3D sonograms.

(a) 3D sonograms: We have added 50 new cases to our 3D ultrasound database, so that the number of cases in our 3D database is now 101. We believe that will be able to add about 20 cases in the second year of this project to reach our target of 120 cases. The 3-D image acquisition system consisted of a commercially available ultrasound scanner (GE Logiq MR 700 with a M12 transducer) and a mechanical transducer guiding system. The technologist adjusted the focal distances of our multifocus scanner so that the lesion is centered at the middle of the focal zones. Scan depth was limited to between 4 and 5 centimeters. Images were recorded at approximately 0.5mm steps during the translation of the transducer. The cases were digitally recorded and transferred from the ultrasound machine to our workstations for processing.

(b) Volumetric sonograms: We started the collection of these cases in February 2002 because of the delay in the approval of our human use document. Since then, in the eight months following the start of data collection, we have collected 69 volumetric scans from 52 patients. To reach our target of 360 cases by the end of the project, we need to increase the rate of volumetric data collection. The volumetric scans are performed by the radiologists by scanning the lesion in free-hand mode from one end to the other. The radiologists then press a number of keystrokes on the ultrasound machine to save the collected set of images in cine mode. We are working hard on reminding the radiologists to save these images and providing them feedback on the quality of the data that has been collected.

(c) 2D sonograms: Since February 2002, we have collected 441 2D sonograms from the 52 patients included in our volumetric sonogram data set.

(B) Development of a graphical user interface (GUI) for image analysis

We have developed a graphical user interface to facilitate radiologists' work in viewing and annotating the ultrasound images. The GUI was written based on Matlab on an AlphaStation. The main window of the developed GUI is shown in Fig. 1. The radiologists have an option to change the brightness and the contrast of the image, to draw an ellipse or polygon on the 2D slice, to define a 3D ellipsoid, and to see any previously-defined shape on the screen. The GUI can show the 3D volume as a movie with click of a button. The radiologists can also interactively edit any polygons, ellipses, or ellipsoids that they have defined. Figure 2 shows an instance in which the radiologist is interactively editing a 3D ellipsoid in the "panel view" window. The GUI is user-friendly and has been designed to require a minimum amount of work from radiologists even when they are modifying a 3D ellipsoid. We are currently working on adding new options to the GUI for capturing radiologists' ratings for the 3D, volumetric and 2D data sets.

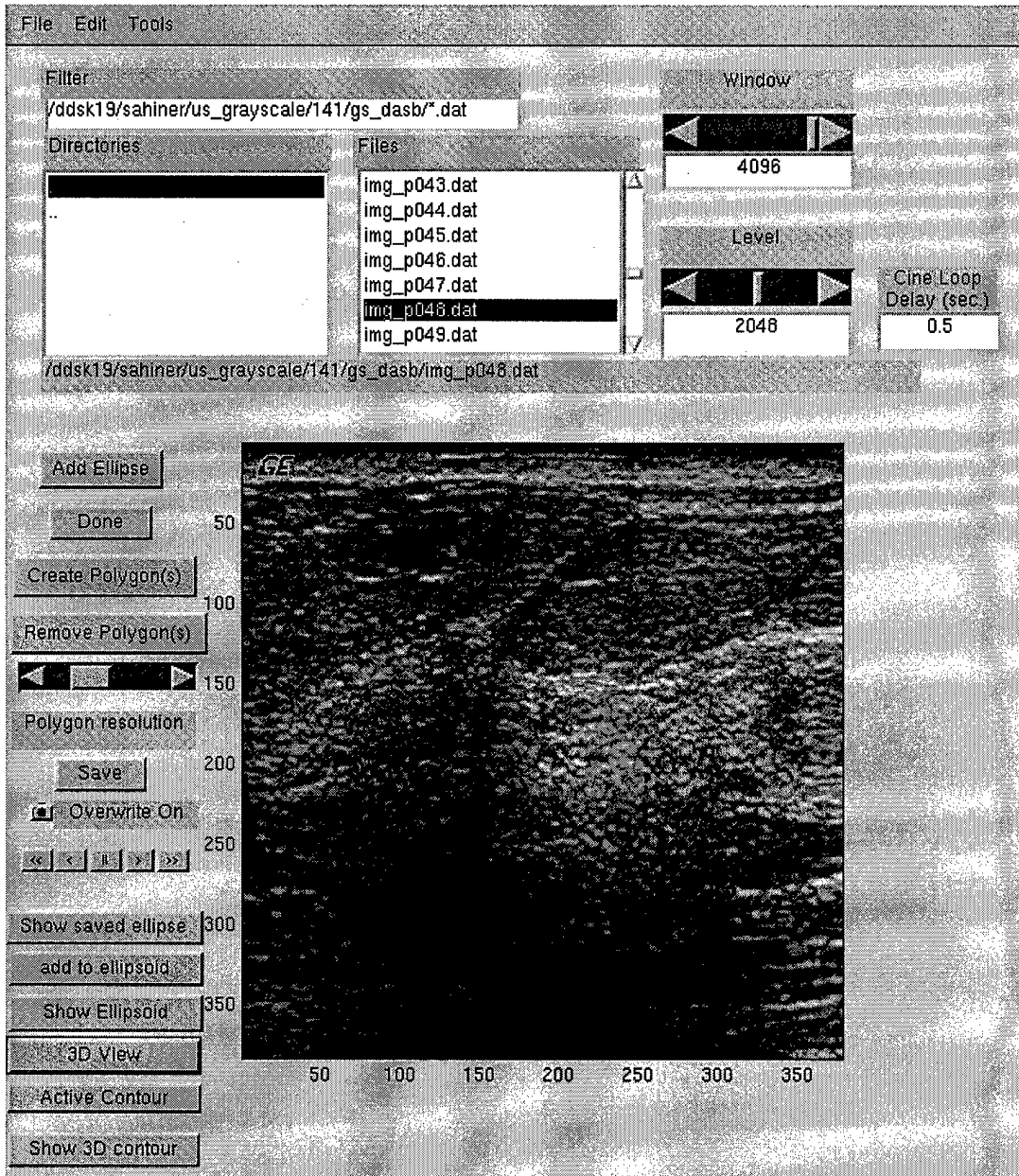


Fig. 1: The first screen of the GUI. The user can draw a polygon or a 2D ellipsoid on this screen, or display previously saved shapes. The user also has the option to add the 2D ellipsoid as part of a 3D ellipsoid shape. The user can move from one slice to another by a mouse click and keep adding new slices to the 3D ellipsoid. When s/he is satisfied, s/he can click a button to define a 3D ellipsoid that best fits the 2D ellipses that have been defined.

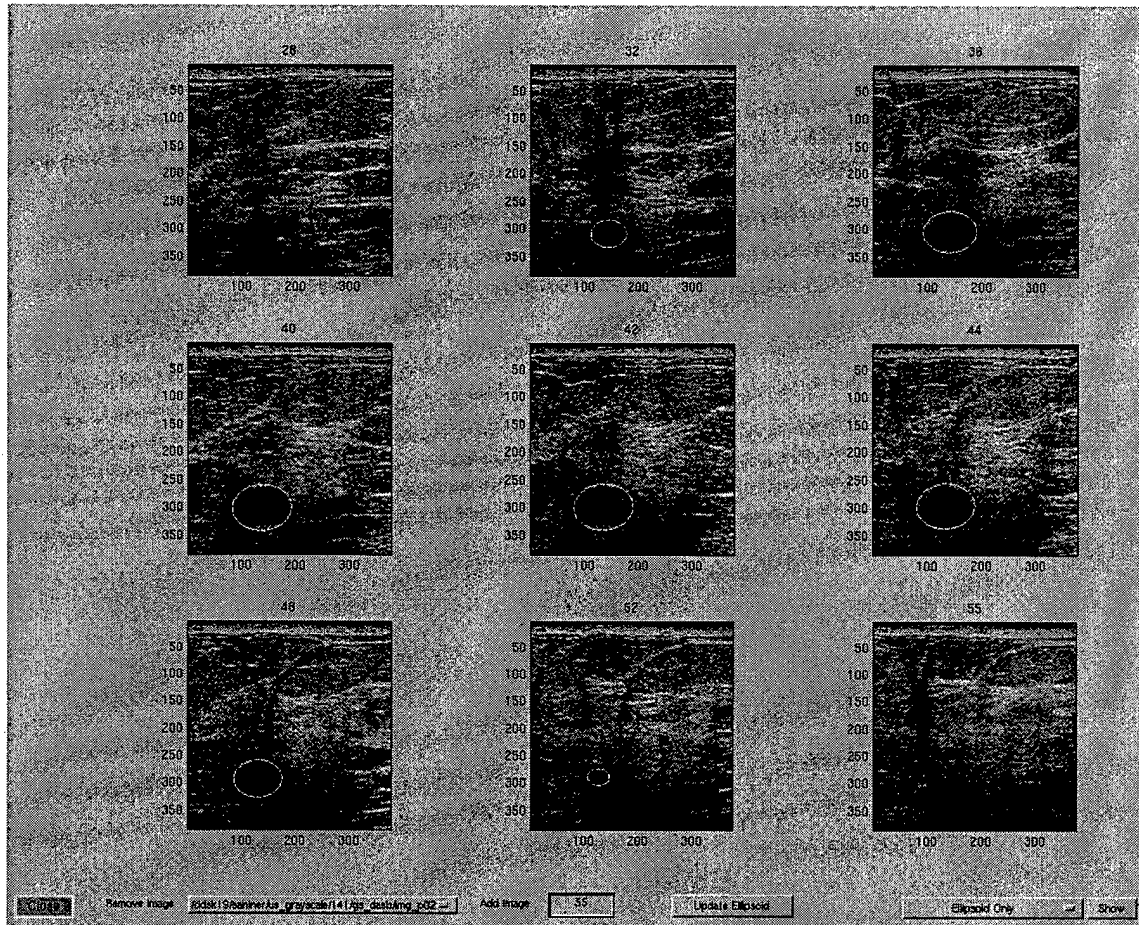


Fig. 2: The “panel view” screen. After the 3D ellipsoid is defined, the user can select a subset of slices to verify the location and shape of the ellipsoid. To change the shape, the user can drag one of the four handles on an ellipse in one or more slices. The ellipsoid is updated when the user clicks the “update ellipsoid” button. To update the ellipsoid, a Matlab program finds the best ellipsoid fit to the defined ellipse slices.

(C) Development of a 3D lesion segmentation method

We had previously designed a 2D segmentation method based on an active contour model to delineate the shapes of masses on ultrasound images. In the first year of this study, we generalized our 2D active contour model to 3D.

An active contour is a deformable continuous curve, whose shape is controlled by internal forces (the model, or a-priori knowledge about the object to be segmented) and external forces (the

image)¹. The internal forces impose a smoothness constraint on the contour, and the external forces push the contour towards salient image features, such as edges. To solve a segmentation problem, an initial boundary is iteratively deformed so that the energy due to internal and external forces is minimized along the contour. In this study, the initial boundary was defined by an experienced radiologist by fitting a 3D ellipsoid to the lesion. Figures 3a and 3b show five slices containing a mass, and the initial ellipsoid, respectively.

The energy components used in our 3D active contour model were (1) the image gradient magnitude; (2) continuity; (3) curvature; and (4) balloon force². The contour in a slice j was represented by an N -point polygon whose vertices were $v(i,j)$. The image gradient magnitude was obtained by smoothing the image with a low-pass filter, finding the partial derivatives in the horizontal and vertical directions, and then computing the magnitude of the partial derivative vector. The continuity energy was used to maintain regular spacing between the vertices along the contour by using the deviation of the length of the line segment between vertices $v(i,j)$ and $v(i+1,j)$ from the average line segment length within the image slice j . The balloon energy was used to push vertices out in a direction normal to the contour tangent. The purpose of the curvature term was to minimize sharp angles in the contour. In a more conventional 2D active contour model, the curvature term is defined as $\|v(i-1,j)-2v(i,j)+v(i+1,j)\|^2$. In our 3D segmentation task, in order to maintain the smoothness of the contour in the out-of-plane direction, the curvature term was defined as a linear combination of $\|v(i-1,j)-2v(i,j)+v(i+1,j)\|^2$ and $\|v(i,j-1)-2v(i,j)+v(i,j+1)\|^2$. The second term in this 3D model represents the interaction of the contours on neighboring slices. Figures 4a and 4b show the segmentation results using the 2D and 3D models, respectively.

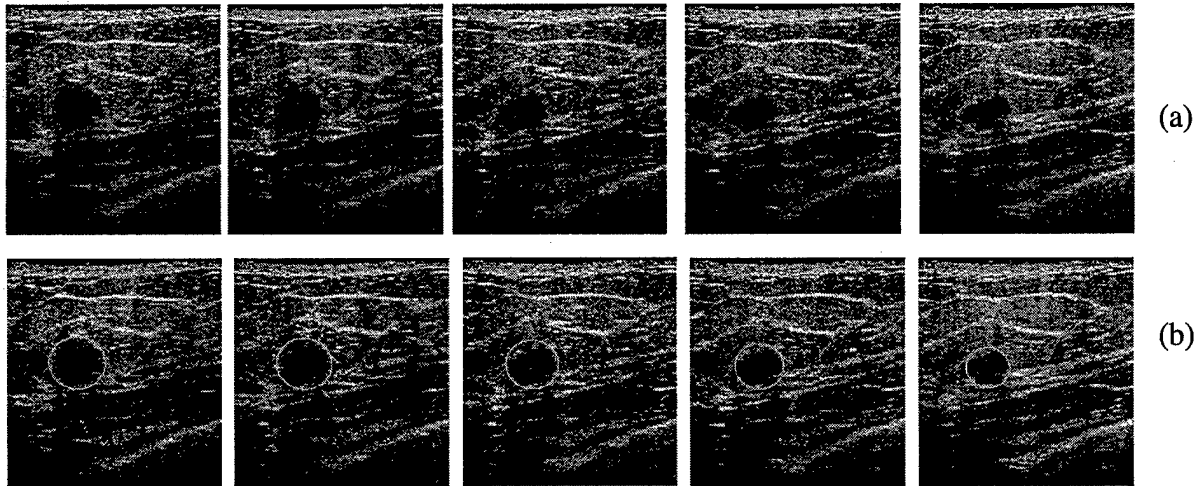


Fig. 3: (a) Five consecutive slices of one of the 3D ultrasound cases in our data set. (b) The initial ellipsoid defined by an experienced radiologist.

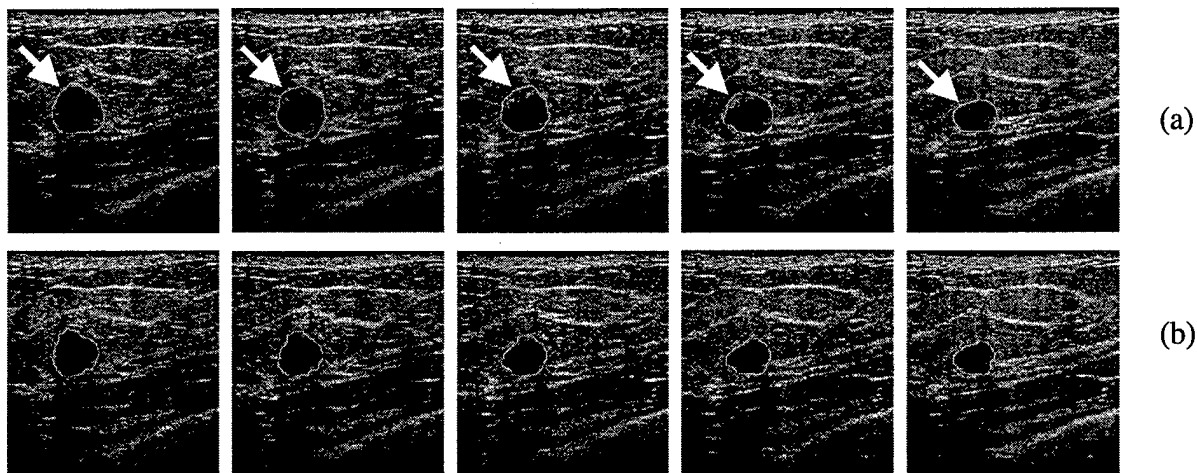


Fig.4: (a) The results of the 2D active contour segmentation. (b) The result of the 3D active contour segmentation. Notice the area shown by the arrows in Fig 4a. Although the 2D segmentation method seems to find the correct mass boundary in this area in the first and the last slices, the boundary in the middle three slices seems overextended. The 2D method is not capable of using the correct segmentation in the first and last slices to improve the segmentation in the middle three slices. The 3D active contour method uses this information, and improves upon the 2D method

(D) Development of feature extraction techniques from ultrasound images

The shape, margins, and attenuation characteristics of a mass on an ultrasound image are important for its characterization as malignant or benign. For example, it is known from clinical experience³ that malignant masses tend to be taller than wide, and that they are more likely to have posterior shadowing. It has been shown by us⁴ and others⁵ that the texture in the mass margins contains useful information about the characterization of the mass as malignant or benign. In the first year of this study, we extracted features related to these characteristics from each 2D slice that contains the mass. The list of the extracted features are shown in Table 1. Figure 5 shows the mass margins from which texture features are extracted. Figure 6 shows the definition of the width to height ratio and the posterior shadowing features. For each extracted feature measure, the feature values from different slices were combined to produce a “case value” for that measure. For texture features, the combination method involved finding the mean of the feature across all the slices containing the mass. For width-to-height and posterior shadowing features, it involved finding the mean, minimum, maximum and the standard deviation.

Spatial gray-level dependence (SGLD) texture features from mass margins	Energy, entropy, sum entropy, difference entropy, information measure of correlation 1, information measure of correlation 2
Width to height feature	Ratio of the widest cross section to the tallest cross section
Posterior shadowing feature	Normalized average gray-level difference between the interior of the segmented mass and horizontal strips posterior to mass

Table 1: The list and description of the extracted features

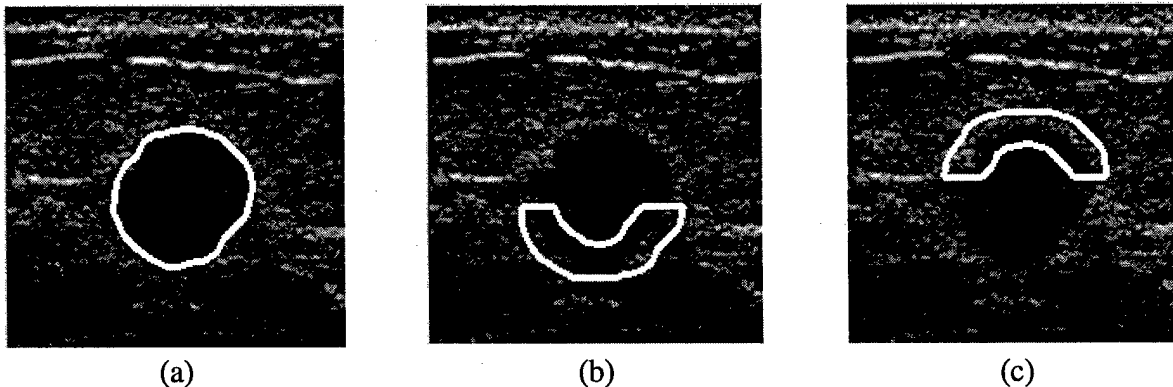
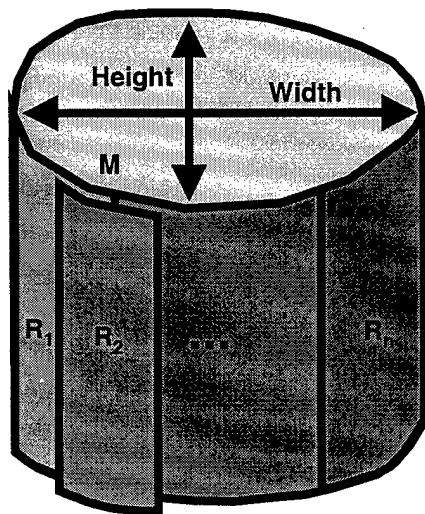


Figure 5: The definitions of the width-to-height and posterior shadowing features



$$\text{Width - to - height - feature} = \text{WHF} = \frac{\text{Width}}{\text{Height}}$$

$$\text{Posterior shadowing feature} = \text{PSF} = \frac{\bar{M} - \min\{\bar{R}_j\}}{\bar{M}}$$

where \bar{M} = mean inside the segmented mass and

\bar{R}_j = mean inside the posterior band j

Figure 6: The definitions of the width-to-height and posterior shadowing features

Feature extraction is one of the most important parts of CAD design, and we still need to improve our feature extraction methods in the second and third years of the project.

(E) Development of a classifier for characterization of lesions on 3D ultrasound images

In the first year of the project, we used our database of 101 3D cases to design and test a characterization method to classify the masses as malignant and benign. Following the 2D and 3D segmentation methods described in Section C and the feature extraction method described in Section D, we combined the features into a malignancy score by designing a linear discriminant analysis (LDA) classifier. The classifier was designed and tested using a leave-one-case-out method⁶. Figure 7 shows the receiver operation characteristic (ROC) curves for the 2D and 3D segmentation methods. The area under the ROC curve was 0.92 for the 3D segmentation method and 0.88 for the 2D segmentation method. By choosing an appropriate threshold on the discriminant scores, 42% of the benign masses could correctly be identified without missing a malignant mass.

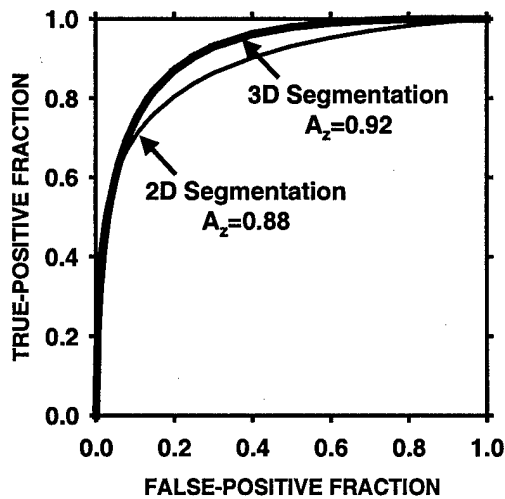


Fig. 7: The ROC curves obtained using the features extracted from the 2D and 3D segmentation methods.

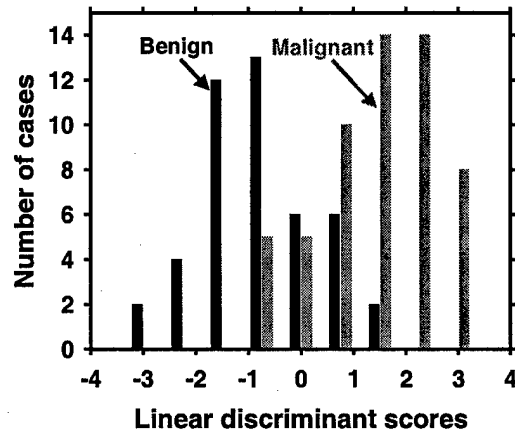


Fig. 8: The distribution of the LDA scores for the malignant and benign cases for the 3D model.

(6) Key Research Accomplishments

- Collect databases of 2D, 3D and volumetric ultrasound images (Tasks 1a and 1b).
- Develop the graphical user interface (GUI) for defining ellipsoids on 3D and volumetric sonograms and for ranking the lesions (Task 1).
- Develop a method for segmentation of sonographic masses in 3D volumes (Task 2a).
- Develop feature extraction methods based on 2D image characteristics (Task 2b).
- Use 101 3D cases for developing a classifier based on extracted features. (Task 3).

(7) Reportable Outcomes

As a result of the support by the USAMRMC BCRP grant, we have (1) developed a 3D segmentation method for more accurate boundary delineation and (2) conducted studies for

5
characterization of 3D masses on ultrasound images. The preliminary results were submitted to three conferences. We are in the process of writing a manuscript for journal submission.

Posters/Scientific Exhibits:

Sahiner B, Ramachandran A, Roubidoux MA, Chan HP, Hadjiiski LM, Helvie MA, LeCarpentier GL, "Computerized Analysis of Solid Masses in 3D Ultrasound Volumes for Breast Cancer Diagnosis," Era of Hope 2002 DoD BCRP Meeting, Orlando, FL, September 25-28, 2002.

Ramachandran A, Sahiner B, Chan HP, Roubidoux MA, Hadjiiski LM, Helvie MA, LeCarpentier GL, "Computer-Assisted Cancer Diagnosis: A Breast Mass Characterization Technique Based on Three-Dimensional Ultrasound Segmentation," to be presented at the University of Michigan Fall Cancer Research Symposium, Ann Arbor, MI, Oct. 31, 2002.

Conference Presentations:

Sahiner B, Ramachandran A, Roubidoux MA, Chan HP, Hadjiiski LM, Helvie MA, LeCarpentier GL, "Computerized Analysis of Solid Masses in 3D Ultrasound Volumes for Breast Cancer Diagnosis," Oral presentation at Era of Hope 2002 DoD BCRP Meeting, Orlando, FL, September 25-28, 2002.

Sahiner B, Ramachandran A, Chan HP, Helvie MA, Hadjiiski LM, Roubidoux MA, Petrick N, Zhou C, "The use of a three-dimensional active contour model for characterization of solid breast masses on three-dimensional ultrasound images," submitted for presentation at the *2003 SPIE Medical Imaging Conference*, San Diego, CA, Feb. 15-20, 2003.

(8) Conclusions

In the first year of the project, we started collecting a database of volumetric and 2D sonograms, and we have doubled the size of our database of 3D sonograms. The 3D sonogram database has almost reached our target of 120 cases. We will be continuing the collection of 2D and volumetric sonograms at an increasing pace in the second and third years of the project. We have developed a 3D segmentation method, and we have improved upon our feature extraction methods. We have designed a classifier that merges the features into a malignancy score, and have analyzed 101 masses with the designed classifier.

The preliminary results obtained so far are encouraging. On our preliminary data set, by choosing an appropriate threshold on the discriminant scores, 42% of the benign masses could correctly be identified without missing a malignant mass. Although we recognize that this a "best-case" scenario, our results indicate that computerized characterization of breast masses in 3D ultrasound volumes can achieve high accuracy. Further improvement of the 3D ultrasound characterization methods and combination with mammographic computer image analyses can provide radiologists with a powerful aid for decision making, which may help reduce unnecessary biopsies and improve patient care.

(9) References

- ¹ M. Kass, A. Witkin, and D. Terzopoulos, "Snakes: active contour models," *Int. J. Comput. Vision* 1, 321-331 (1987).
- ² D. J. Williams and M. Shah, "A fast algorithm for active contours and curvature estimation," *CVGIP: Img. Underst.* 55, 14-26 (1992).
- ³ A. T. Stavros, D. Thickman, C. L. Rapp, M. A. Dennis, S. H. Parker, and G. A. Sisney, "Solid breast nodules: Use of sonography to distinguish between malignant and benign lesions," *Radiology* 196, 123-134 (1995).
- ⁴ B. Sahiner, G. L. LeCarpentier, H.-P. Chan, M. A. Roubidoux, N. Petrick, M. M. Goodsitt, S. S. Gopal, and P. L. Carson, "Computerized characterization of breast masses using three-dimensional ultrasound images," *Proc. SPIE* 3338, 301-312 (1998).

- ⁵ Y. Zheng, J. F. Greenleaf, and J. J. Gisvold, "Reduction of breast biopsies with a modified self-organizing map," *IEEE Trans. Neural Net.* 8, 1386-1396 (1997).
- ⁶ B. Sahiner, H.-P. Chan, N. Petrick, M. A. Helvie, and L. M. Hadjiiski, "Improvement of mammographic mass characterization using spiculation measures and morphological features," *Med. Phys.* 28, 1455-1465 (2001).

(10) Appendix

Copies of the following publications are enclosed with this report:

Conference Abstracts:

Sahiner B, Ramachandran A, Chan HP, Helvie MA, Hadjiiski LM, Roubidoux MA, Petrick N, Zhou C, "The use of a three-dimensional active contour model for characterization of solid breast masses on three-dimensional ultrasound images," submitted for presentation at the *2003 SPIE Medical Imaging Conference*, San Diego, CA, Feb. 15-20, 2003.

Ramachandran A, Sahiner B, Chan HP, Roubidoux MA, Hadjiiski LM, Helvie MA, LeCarpentier GL, "Computer-Assisted Cancer Diagnosis: A Breast Mass Characterization Technique Based on Three-Dimensional Ultrasound Segmentation," to be presented at the University of Michigan Fall Cancer Research Symposium, Ann Arbor, MI, Oct. 31, 2002.

Conference Poster Presentation:

Sahiner B, Ramachandran A, Roubidoux MA, Chan HP, Hadjiiski LM, Helvie MA, LeCarpentier GL, "Computerized Analysis of Solid Masses in 3D Ultrasound Volumes for Breast Cancer Diagnosis," Era of Hope 2002 DoD BCRP Meeting, Orlando, FL, September 25-28, 2002.

Conference Oral Presentation:

Sahiner B, Ramachandran A, Roubidoux MA, Chan HP, Hadjiiski LM, Helvie MA, LeCarpentier GL, "Computerized Analysis of Solid Masses in 3D Ultrasound Volumes for Breast Cancer Diagnosis," Era of Hope 2002 DoD BCRP Meeting, Orlando, FL, September 25-28, 2002.

Computerized Characterization of Breast Masses as Malignant and Benign in 3D Ultrasound Volumes



The University of Michigan
Department of Radiology

AUTHORS

Berkman Sahiner, Ph.D.
Aditya Ramachandran, B.S.
Marilyn A. Roubidoux, M.D.
Heang-Ping Chan, Ph.D.
Lubomir M. Hadjiiski, Ph.D.
Mark A. Helvie, M.D.
Gerald L. LeCarpentier, Ph.D.

PURPOSE

- ❖ Overall goal
 - Computer vision techniques for analysis of multi-modality images of breast masses
 - Improve radiologists' accuracy in biopsy recommendation

PURPOSE

- ❖ This study
 - Characterize solid breast masses as malignant or benign using computer-extracted features from 3-D sonograms
 - Compare the classification results using two different (2-D and 3-D) segmentation techniques

IMAGE ACQUISITION

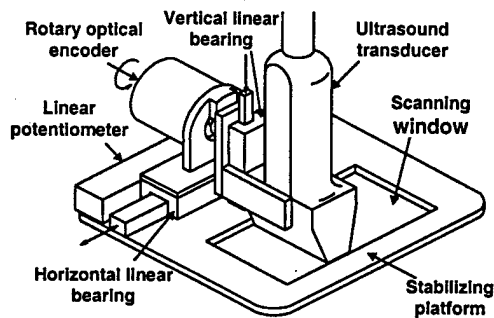
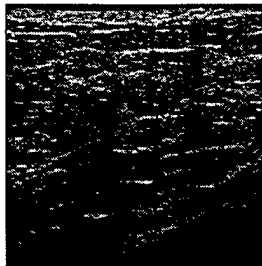


IMAGE ACQUISITION

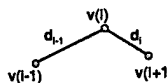
- ❖ Scanner: GE Logiq 700
- ❖ Transducer: M12
- ❖ Transducer frequency: 11 MHz
- ❖ Maximum plane spacing: 0.5 mm
- ❖ Typical image count: 90
- ❖ Images digitally stored and transferred

3D US VOLUME



2D ACTIVE CONTOUR SEGMENTATION

❖ A contour is represented by N vertices



❖ Iteratively minimize energy function

$$E = \sum_{i=1}^N [w_{curv} E_{curv}(i) + w_{cont} E_{cont}(i) - w_{grad} E_{grad}(i) + w_{bal} E_{bal}(i)]$$

2D ACTIVE CONTOUR MODEL

❖ Energy function components

- Curvature
- Continuity
- Image gradients
- Balloon force

2D ACTIVE CONTOUR MODEL

❖ Curvature

$$E_{curv}(i) = \|v(i-1) - 2v(i) + v(i+1)\|^2$$

❖ Continuity

$$E_{cont}(i) = |\bar{d} - d_i|$$

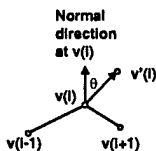
❖ Image gradient magnitude

- Gaussian-based derivative, magnitude

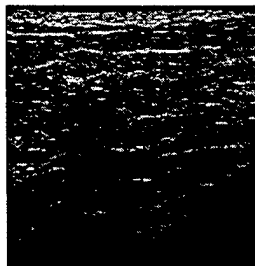
ACTIVE CONTOUR MODEL

❖ Balloon force

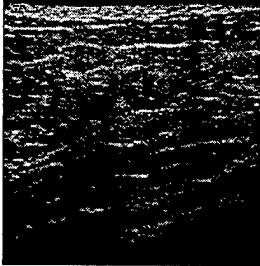
$$E_{bal}(i) = -\cos\theta$$



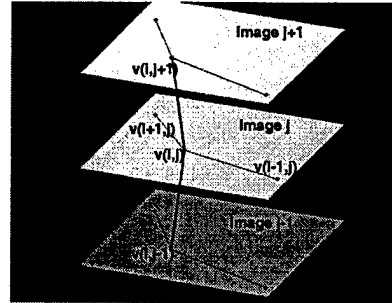
INITIAL ELLIPSOID



2D SEGMENTATION RESULT




3-D MASS SEGMENTATION




$$E_{curv}(i,j) = \|v(i-1,j) - 2v(i,j) + v(i+1,j)\|^2 + \|v(i,j-1) - 2v(i,j) + v(i,j+1)\|^2$$

3D SEGMENTATION RESULT



3D SEGMENTED OBJECT



COMPARISON OF SEGMENTATION

2D Segmentation




3D Segmentation



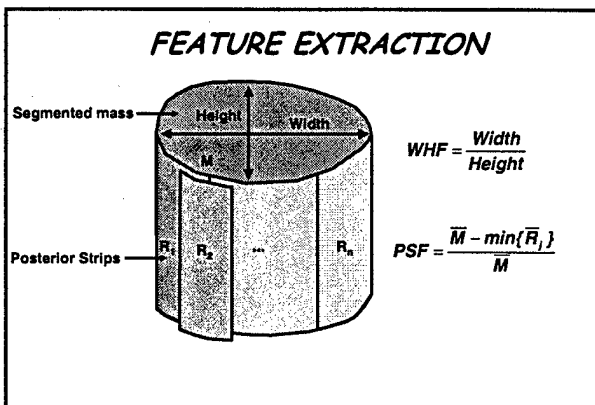
FEATURE EXTRACTION

- ❖ Slice-by-slice extraction
- ❖ Texture features
 - Spatial gray-level dependence features
 - Six texture measures
 - Three distances: d=2, 4, 6
 - Two directions: θ=0°, 90°
 - Two regions at the upper and lower margins of the segmented mass



FEATURE EXTRACTION

- ❖ Width-to-height feature (WHF)
 - Ratio of widest cross-section to the tallest cross-section of the segmented mass
- ❖ Posterior shadowing features (PSF)
 - Normalized average gray-level difference between the interior of the segmented mass and horizontal strips posterior to the mass



FEATURE EXTRACTION

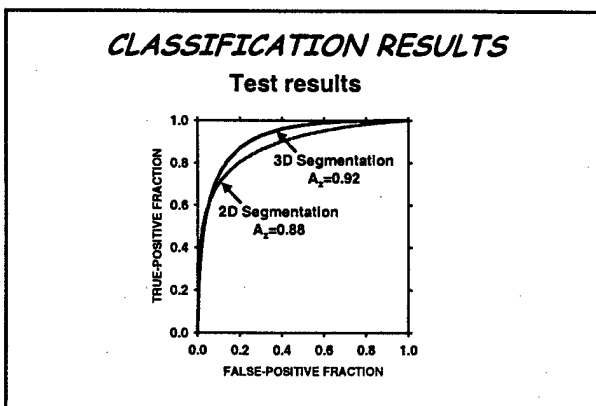
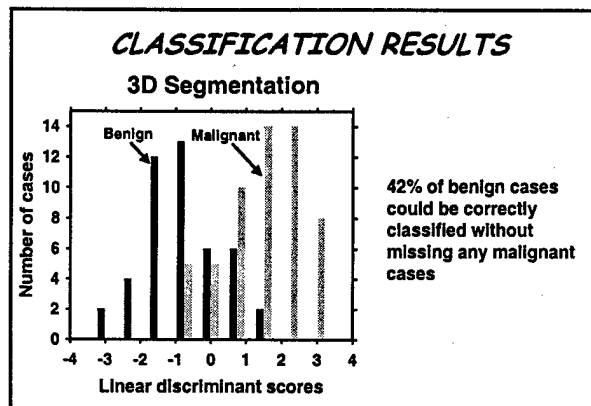
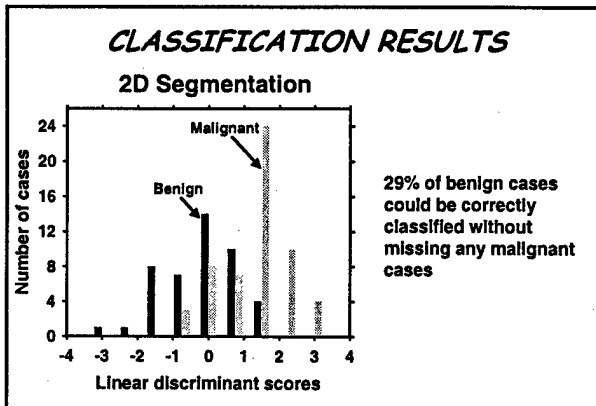
- ❖ Features extracted from all slices of a mass were combined
 - Texture features:
 - Mean
 - Width-to-height, posterior shadowing:
 - Mean, maximum, minimum, std. dev.
 - Texture: 72
 - Width-to-height: 8
 - Shadowing: 8

DATA SET

- ❖ 101 patients with breast masses
 - Identified by mammography and/or clinical examination
- ❖ No simple cysts
- ❖ All masses biopsy-proven
 - 45 benign
 - 56 malignant

CLASSIFIER DESIGN

- ❖ Linear discriminant classifier
- ❖ Leave-one-out
 - Train (feature selection and classifier coefficients) on n-1 cases, test on 1 case
 - Complete testing of all n cases by changing the test case in round robin order
- ❖ Average number of selected features
 - 2-D segmentation: 7
 - 3-D segmentation: 8



SUMMARY

- ❖ A 3D segmentation technique has been developed for the analysis of 3D ultrasound data
- ❖ The computer's accuracy was improved compared to 2D segmentation
- ❖ Computer-aided diagnosis can potentially reduce unnecessary biopsy of benign lesions

FUTURE WORK

- ❖ Improvement of the 3D segmentation
- ❖ Extraction of inherently 3D features
- ❖ Application to free-hand data acquisition
- ❖ Combination with mammographic lesion characterization results

2003 SPIE Medical Imaging Conference, San Diego, CA

SUBMIT TO: MI04, Milan Sonka, J. Michael Fitzpatrick

TITLE OF CONFERENCE: Image processing

PAPER TITLE: The use of a three-dimensional active contour model for characterization of solid breast masses on three-dimensional ultrasound images

PRINCIPAL AUTHOR: Berkman Sahiner

AUTHOR AFFILIATION: The University of Michigan Health System

E-MAIL: berki@umich.edu

ADDRESS: CGC B2102

1500 E. Medical Center Drive

Ann Arbor, MI 48109-0904

USA

PHONE: (734) 647-7429

FAX: (734) 615-5513

BIOGRAPHY: Berkman Sahiner was born in Istanbul, Turkey. He received the B.S. and M.S. degrees from the Middle East Technical University, Turkey, in 1985 and 1988, and the Ph.D. degree from the University of Michigan in 1993. He is currently an Assistant Research Scientist in the Department of Radiology at the University of Michigan Medical Center. His research interests include computer-aided diagnosis, medical imaging, image processing, neural networks, time-frequency and time-scale methods.

ADDITIONAL AUTHOR LIST:

Aditya Ramachandran, The University of Michigan Health System

Heang Ping Chan, The University of Michigan Health System

Mark A. Helvie, The University of Michigan Health System

Lubomir M. Hadjiiski, The University of Michigan Health System

Marilyn A. Roubidoux, The University of Michigan Health System

Nicholas Petrick, Center for Devices and Radiological Health, FDA

Chuan Zhou, The University of Michigan Health System

CONTACT INFORMATION FOR ADDITIONAL AUTHORS:

Aditya Ramachandran, B.S.

CGC B2102, 1500 E. Medical Center Drive, Ann Arbor, MI 48109-0904, (734) 647-7429, Fax (734) 615-5513, acramach@umich.edu

Heang-Ping Chan, Ph.D.

UH B1F510, 1500 E. Medical Center Drive, Ann Arbor, MI 48109-0030, (734) 936-4357, Fax (734) 615-5513, chanhp@umich.edu

Mark A. Helvie, M.D.

TC 2910, 1500 E. Medical Center Drive, Ann Arbor, MI 48109-0326 (734) 936-4352, Fax (734) 936-9723, mahelvie@umich.edu

Lubomir M. Hadjiiski, Ph.D.

CGC B2103, 1500 E. Medical Center Drive, Ann Arbor, MI 48109-0904, (734) 647-7428, Fax (734) 615-5513, lhadjisk@umich.edu

Marilyn A. Roubidoux, M.D.

TC 2910, 1500 E. Medical Center Drive, Ann Arbor, MI 48109-0326 (734) 936-4555, Fax (734) 936-9723, roubidou@umich.edu

Nicholas Petrick, Ph.D.

Center for Devices and Radiological Health, FDA, 12720 Twinbrook Parkway, Rockville, MD 20857, (301) 443-5020 x139, nxp@cdrh.fda.gov

Chuan Zhou

2003 SPIE Medical Imaging Conference, San Diego, CA

Department of Radiology, University of Michigan, CGC B2103, 1500 E. Medical Center Drive, Ann Arbor, MI 48109-0904, Phone: (734) 647-8552, Fax: (734) 615-5513, chuan@umich.edu

PRESENTATION: Oral Presentation

KEY WORDS: Computer-aided diagnosis, 3D ultrasound, breast masses, segmentation, lesion classification

The use of a three-dimensional active contour model for characterization of solid breast masses on three-dimensional ultrasound images

Berkman Sahiner, Aditya Ramachandran, Heang-Ping Chan, Mark A. Helvie, Lubomir M. Hadjiiski, Marilyn A. Roubidoux, Nicholas Petrick*, Chuan Zhou

The University of Michigan Health System, Ann Arbor, MI 48109-0904

*Center for Devices and Radiological Health, U.S. Food and Drug Administration, Rockville, MD 20857

PURPOSE: Breast ultrasound is a commonly used clinical tool for discrimination of malignant and benign masses. The characterization accuracy can potentially be improved by using computer-aided diagnosis (CAD). Three-dimensional (3D) acquisition and processing of ultrasound images provide a more complete description of the lesion compared to two-dimensional (2D) acquisition and processing. In this study, our purpose was to develop automated 3D segmentation and computerized breast mass classification methods. The accuracy of the newly designed method was compared to that of a classifier that used mass boundaries automatically detected using a conventional 2D active contour model.

METHODS: The 3D image acquisition system consisted of a commercially available ultrasound scanner (GE Logiq MR 700 with a M12 array transducer) and a mechanical transducer guiding system. The 3D volumes were recorded by translating the transducer across the lesion in the z-direction while conventional 2D images were acquired in the x-y plane. A 3D image segmentation method based on an active contour model was developed to delineate the mass boundaries in the volumetric scans. The energy function used in the 3D active contour model contained the image gradient, smoothness and continuity terms and an adaptive balloon force in the x-y plane, as well as smoothness and continuity terms in the z-direction. The energy terms defined using the z-direction information helped the model maintain a smooth shape of the object in 3D despite possible gradient variations close to the border locations on individual 2D slices. Using the segmented 3D mass shape, features that described the texture of the lesion margin, the width-to-height ratio, gradient direction and strength along the mass border, and posterior shadowing were automatically extracted. A feature classifier was designed using the leave-one-case-out method to merge the features into a malignancy score. The classifier scores were analyzed using the Receiver Operating Characteristic (ROC) methodology to estimate the classification accuracy. For comparison, a 2D active contour model that was optimized for ultrasound mass segmentation was also applied to each image slice that contained the lesion, and the feature extraction and classification tasks were repeated using the 2D active contour boundaries.

RESULTS: 3D volumes containing solid breast masses with biopsy-proven pathology were collected from 101 patients (45 benign and 56 malignant) and analyzed with our computerized classification method. The area A_z under the ROC curve for the classifier using the 3D active contour boundaries was 0.92. More than 42% of the benign masses could be correctly identified using the scores of this classifier without missing a malignancy. In comparison, when the classifier used the 2D active contour boundaries, the A_z value was 0.88, and 29% of the benign masses could be correctly identified without missing a malignancy.

NEW OR BREAKTHROUGH WORK: Computerized analysis and characterization of 3D breast sonograms is a promising new area for CAD, and the development of inherently 3D techniques for this analysis is expected to improve the computer's accuracy. Designing a 3D segmentation algorithm and applying it for mass classification on 3D breast sonograms is an important step in this direction. Results of this new development will be presented.

CONCLUSION: Our results indicate that an accurate computer classifier, based on a 3D segmentation method, can be designed for differentiation of malignant and benign solid breast masses on 3D sonograms.

Computer-Assisted Cancer Diagnosis: A Breast Mass Characterization Technique Based on Three-Dimensional Ultrasound Segmentation

Aditya Ramachandran, Berkman Sahiner, Heang-Ping Chan, Marilyn A. Roubidoux,
Lubomir M. Hadjiiski, Mark A. Helvie, Gerald L. LeCarpentier
Department of Radiology, The University of Michigan

Purpose: Breast ultrasound (US) is commonly used as an adjunct to mammography for evaluation of suspicious breast masses. US has been proven to be accurate in distinguishing solid masses from benign cysts. However, radiologists' accuracy in discriminating between malignant and benign solid masses on US images still needs to be improved. Computer-aided diagnosis (CAD) of breast masses has the potential to help radiologists achieve higher classification accuracies. The purpose of this project was to develop computer vision methods for three-dimensional (3D) segmentation and characterization of solid breast masses on 3D US images.

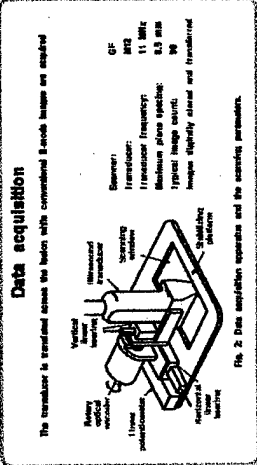

Methods: The 3D imaging system consisted of a scanner (GE Logiq MR 700 w/ M12 array transducer) coupled with a translational guidance mechanism. Two segmentation algorithms were developed. The first algorithm used an active contour model separately on each 2D slice. The second algorithm, based on a 3D active contour model, exploited the interrelationship between consecutive images in the 3D volumetric scan for improved segmentation. Image features were extracted from the segmented boundaries and mass margins, and were used to provide diagnostic information to a linear discriminant classifier for evaluating the mass.

Results: 3D volumes of biopsy-proven solid breast masses were collected from 101 patients (45 benign and 56 malignant). When 2D active contour boundaries were used, 29% of the benign masses were classified correctly by the computer without missing any malignancies. The area under the classifier's receiver operating characteristics curve with the 2D algorithm was 0.88. The corresponding measures of accuracy for the 3D algorithm were 42% and 0.92, respectively.

Conclusion: CAD can be a useful tool in characterization of breast masses on US volumes. The high accuracy of the classifier designed with the 3D features demonstrates the potential of CAD to help reduce unnecessary biopsies and improve patient care.

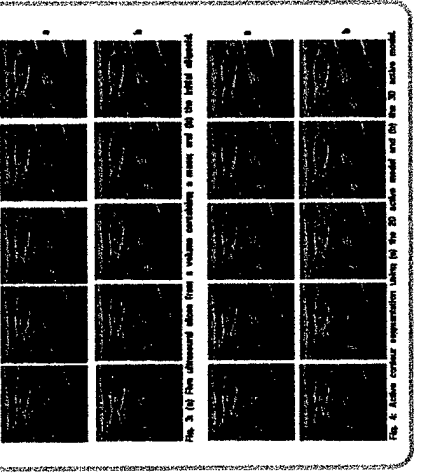
Abstract

The overall goal of this research is to develop computer-aided techniques for analysis of solid masses in 3D ultrasound volumes. In this paper, we describe the methodology for the computerized analysis of solid masses in 3D ultrasound volumes. The methodology is based on the following steps: 1) Data acquisition, 2) Data segmentation, 3) Feature extraction, and 4) Classification. The methodology is based on the following steps: 1) Data acquisition, 2) Data segmentation, 3) Feature extraction, and 4) Classification. The methodology is based on the following steps: 1) Data acquisition, 2) Data segmentation, 3) Feature extraction, and 4) Classification.



Mass Segmentation

The masses in the 3D volume were segmented using an active contour model. An active contour model is a technique for image segmentation. It is based on the idea of an elastic band that is attracted to the boundaries of the object. The active contour model is used to segment the masses in the 3D volume. The methodology is based on the following steps: 1) Data acquisition, 2) Data segmentation, 3) Feature extraction, and 4) Classification.


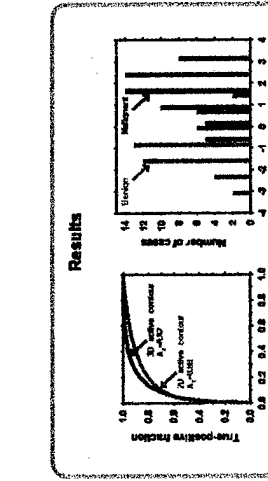


Feature Extraction

Features were extracted from the segmented masses using a set of features. The features were extracted from the segmented masses using a set of features. The methodology is based on the following steps: 1) Data acquisition, 2) Data segmentation, 3) Feature extraction, and 4) Classification.

Classification

A linear discriminant analysis (LDA) classifier was used to classify the masses. The LDA classifier is a statistical method for classifying data. It is based on the idea of finding a linear combination of the features that best separates the classes. The methodology is based on the following steps: 1) Data acquisition, 2) Data segmentation, 3) Feature extraction, and 4) Classification.



Conclusion

The results of this study indicate that computerized characterization of solid breast masses is possible. The methodology described in this paper is a promising approach to the problem of breast cancer diagnosis. The methodology is based on the following steps: 1) Data acquisition, 2) Data segmentation, 3) Feature extraction, and 4) Classification.

Data Set

The data set consisted of 100 masses. The masses were classified as malignant or benign. The methodology is based on the following steps: 1) Data acquisition, 2) Data segmentation, 3) Feature extraction, and 4) Classification.

Acknowledgment

This work was supported by the National Cancer Institute (NCI) under contract number N01-CN-25400.

Abstract

The overall goal of this research is to develop computer vision techniques for analysis of multi-modality images of breast masses to improve the radiologists' accuracy in biopsy recommendation. The specific goal of this study was to develop automated methods for characterizing masses on three-dimensional (3D) sonograms. The sonographic image analysis can be combined with mammographic analysis to improve the accuracy of differentiating malignant and benign masses.

The 3D image acquisition system consisted of a commercially available ultrasound scanner (GE Logiq MR 700 with a M12 array transducer) and a mechanical transducer guiding system. The 3D volumes were recorded by translating the transducer across the lesion in the z-direction while conventional 2D images were acquired in the x-y plane. A 3D image segmentation method based on an active contour model was developed to delineate the mass boundaries. Using the segmented mass shapes, features that described the width-to-height ratio, the texture of the interior and along the margin of the lesion, and posterior shadowing were extracted. A feature classifier was designed using the leave-one-case-out method to combine the features into a malignancy score and to estimate the classification accuracy. The classifier scores were analyzed using the Receiver Operating Characteristic (ROC) methodology.

3D volumes containing solid breast masses with biopsy-proven pathology have been acquired from 101 patients, of which 86 were malignant and 45 were benign. The computer classifier achieved an area under the ROC curve of 0.92. More than 40% of the benign masses in this data set could be correctly identified using the classifier scores without missing a malignancy. These results show promise that an accurate computer classifier can be designed for differentiation of malignant and benign solid breast masses on 3D sonograms. Combination of sonographic and mammographic computer image analyses can provide radiologists with a powerful tool for decreasing the number of benign biopsies without reducing the sensitivity of cancer detection.

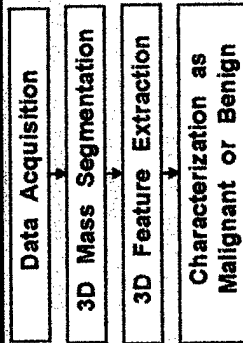


Fig. 1: The block diagram of the computerized 3D ultrasound breast mass characterization algorithm.

Data acquisition

The transducer is translated across the lesion while conventional B-mode images are acquired

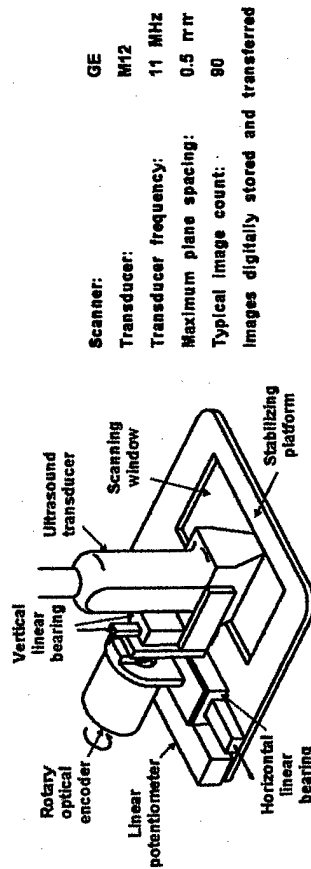


Fig. 2: Data acquisition apparatus and the scanning parameters.

Mass Segmentation

The masses in the 3D volume were segmented using an active contour model. An active contour is a deformable continuous curve, whose shape is controlled by internal forces (the model) or a priori knowledge about the object to be segmented and external forces (the image). The internal forces impose a smoothness constraint on the contour, and the external forces push the contour towards salient image features, such as edges. To solve a segmentation problem, an initial boundary is iteratively deformed so that the energy due to internal and external forces is minimized along the contour. In this study, the initial boundary was defined by an experienced radiologist by fitting a 3D ellipsoid to the lesion. Figures 3a and 3b show five slices containing a mass, and the initial ellipsoid, respectively.

The energy components used in our 3D active contour model were (1) Image gradient magnitude; (2) Continuity; (3) Curvature; and (4) Balloon force. The contour in a slice j was represented by an N -point polygon whose vertices were $v(i,j)$. The image gradient magnitude was obtained by smoothing the image with a low-pass filter, finding the partial derivatives in the horizontal and vertical directions, and then computing the magnitude of the partial derivative vector. The continuity energy was used to maintain regular spacing between the vertices along the contour by using the deviation of the length of the line segment between vertices $v(i,j)$ and $v(i+1,j)$ from the average line segment length within the image slice j . The balloon energy was used to push vertices out in a direction normal to the contour tangent. The purpose of the curvature term was to minimize sharp angles in the contour. In a more conventional 2D active contour model, the curvature term is defined as $|v(i,j)-2v(i,j+1)-v(i,j-1)|$. In our 3D segmentation task, in order to maintain the smoothness of the contour in the out-of-plane direction, the curvature term was defined as a linear combination of $|v(i,j)-2v(i,j+1)-v(i,j-1)|$ and $|v(i,j)-2v(i,j+1)-v(i,j-1)|$. The second term in this 3D model represents the interaction of the contours on neighboring slices. Figures 4a and 4b show the segmentation results using the 2D and 3D models, respectively.




Fig. 3: (a) Five ultrasound slices from a volume containing a mass; and (b) the initial ellipsoid.

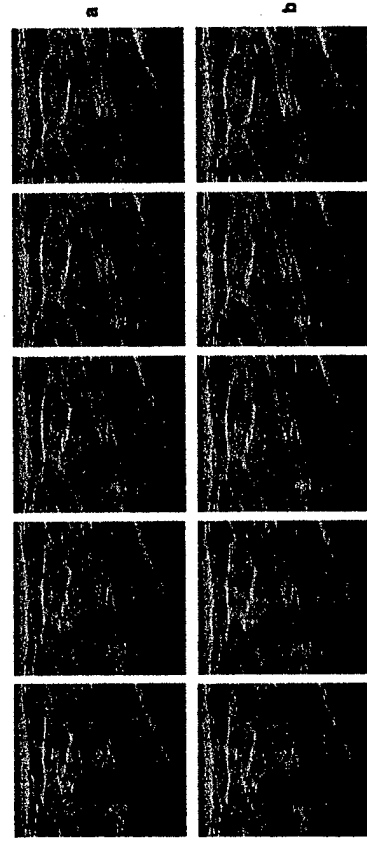


Fig. 4: Active contour segmentation using (a) the 2D active model and (b) the 3D active model.

Feature Extraction

Texture features: Extracted from spatial gray-level dependence matrices based on upper and lower mass margins on each slice containing the mass.
 Width-to-height ratio: Computed as the ratio of the widest cross-section of the segmented object to the tallest cross-section of the segmented object on each slice containing the mass.
 Posterior shadowing feature: Computed using the average gray-level difference between the interior of the segmented object and horizontal strips posterior to the object on each slice containing the mass.

Features extracted from all slices of a mass were combined to form 3D features.
 Texture features: Mean of each texture feature among slices containing the mass.
 Width-to-height ratio, posterior shadowing: Mean, maximum, minimum, standard deviation.

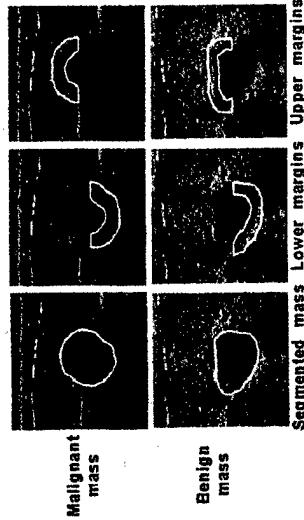


Fig. 5: The definition of the upper and lower margins in the image plane based on the 3D segmentation results.

Classification

A linear discriminant analysis classifier with stepwise feature selection was used to characterize the masses as malignant and benign. A leave-one-case-out method was used to train and test the classifier. In the leave-one-case-out method, the data set containing N cases was partitioned into trainers and testers N times. In each partition, one case was held out as the test case, and the classifier was trained based on the remaining N-1 cases. The classifier training included the selection of the best subset of features for classifying the trainers and the estimation of best coefficients for the selected features. The test case was changed in round-robin order until each case serves as a test sample once and only once.

Data Set

Before 3-D image acquisition, scout images were acquired to localize the lesion. During 3-D image acquisition, the technologist manually translated the transducer, while the image acquisition system recorded B-mode images into a buffer in the ultrasound scanner. The depth of the scans was kept constant at 3 or 4 cm for most of the patients. The technologist was free to set the focal distance and the overall gain adjustment to obtain the best possible image. The data set included 3D ultrasound volumes from 101 patients. Each volume corresponded to a breast mass identified by mammography and/or clinical examination. Masses that proved to be cysts based on ultrasonography were excluded. All patients underwent biopsy as part of their clinical management after ultrasound imaging. Fifty-six of the masses were malignant and 45 were benign.

Results

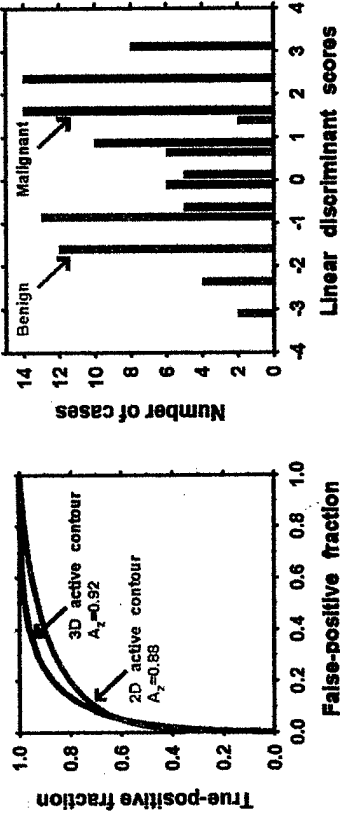


Fig. 6: The receiver operating characteristic (ROC) curve obtained using the features extracted from the 2D and 3D segmentation models. The area under the ROC curve, A_z , was 0.88 for the 2D model and 0.92 for the 3D model.

Fig. 7: The distribution of the linear discriminant scores for the malignant and benign masses for the 3D model. By choosing an appropriate threshold on the discriminant scores, 42% of the benign masses could correctly be identified without missing a malignant mass.

Conclusion

The results of this study indicate that computerized characterization of solid breast masses in 3D ultrasound volumes can achieve high accuracy. For the data set of 101 cases used in this study, 42% of the benign masses could correctly be identified without missing a malignant mass by choosing an appropriate threshold on the discriminant scores. The accuracy of the classifier was improved when a 3D segmentation algorithm was used instead of a 2D algorithm. Further improvement of the potential usefulness of 3D algorithms for segmentation and classification. Further improvement of the 3D ultrasound characterization methods and combination with mammographic computer image analyses can provide radiologists with a powerful aid for decision making, which may help reduce unnecessary biopsies and improve patient care.

Acknowledgment

The U.S. Army Medical Research Materiel Command under DAMD17-01-1-0328 supported this work. The content of this paper does not necessarily reflect the position of the government and no official endorsement of any equipment and product of any companies mentioned should be inferred.