

ELECTRO-ANATOMICAL FOUR-DIMENSIONAL MAPPING OF VENTRICULAR TACHYCARDIA

Dorin Panescu¹, Mansoon Nasir², Stephan Masse², Elias Sevaptisidis², Eugene Downar²

¹Boston Scientific, San Jose, CA 95134, USA

²Toronto General, Toronto, CANADA

Abstract The objectives of this study were: 1) to reconstruct the ventricular 3-D geometry by processing intracardiac echo (ICE) images, 2) to reconstruct the nesting position and orientation of the mapping catheters inside the ventricle, 3) integrate the geometrical information with the cardiac activity data recorded with the catheter and 4) to provide anatomic localization of electrical events during clinical ventricular tachycardia (VT). We employed commercially available 64-electrode mapping catheters, ICE equipment, a custom designed EP recording system and custom reconstruction software. *In vitro*, the positions of basket catheter electrodes were identified correctly. During clinical use, the basket electrode positions were not identified reliably by ICE. However, the nesting position of the basket was identified correctly. The custom software integrated the geometrical information and cardiac activity data off line, during the procedure. Electrical events occurring during VT were correctly displayed on the reconstructed geometry.

Keywords: Ablation, Arrhythmia, Mapping, Ultrasound

I. INTRODUCTION

Recent studies underscore the importance of anatomic mapping. Patients that have been ablated in the pulmonary vein (PV) region reported ulterior stenosis. Anatomic reconstruction by CT has helped understand the frequency of occurrence and effects of PV stenosis [1]. Our group presented that the bi-atrial activation sequence became well understood when cardiac activity data and anatomic information were combined [2]. By 3-D ICE reconstruction, Suzuki et al. presented clinical evidence that patients with atrial flutter may have anatomic abnormalities at the crista terminalis [3]. Simon et al. also report on the efficacy of right atrial mapping combined with anatomic reconstruction [4]. Our goal was to investigate the efficacy of electro-anatomical mapping that integrates correct geometrical information, as reported by ICE, with cardiac activity data acquired at multiple sites simultaneously using a basket catheter.

II. METHODS AND APPARATUS

For mapping, we used a 64-electrode basket catheter (Constellation, Boston Scientific). The electrodes were distributed on 8 self-expanding nitinol splines, 8 electrodes per spline. The shaft of the catheter was 8F diameter and was introduced in the heart by percutaneous deployment through a 8.5F sheath. The data collected by the 64 electrodes were acquired with a custom mapping system (Toronto General) that employed a sampling frequency of 2 kHz, gaining of 10000 and digital filtering in the band 1-300 Hz. The system was battery operated to secure a very high signal-to-noise ratio (SNR). During the mapping process, the activation times were selected from unipolar electrograms (EGM), the dynamic activation maps were constructed from bipolar EGMs, 3-D maps were created using bilinear interpolation on

a grid of 64 by 256 points. For animation purposes, the dynamic data playback step was 40 samples.

The ICE system consisted of 9F 9MHz rotational ICE catheters (UltraView, Boston Scientific) connected to an ICE console (ClearView, Boston Scientific). The ultrasound transducer inside the ICE catheter rotated at 30 rotation/s. The ICE console reconstructed real-time 2-D images from the raw data received from the ICE catheter. In order to analyze 3-D geometries, the ICE catheter was pulled back, with the basket catheter in place, at a constant speed of 1 mm/s. To minimize motion artifacts, the ICE catheter was sustained and stabilized inside a 9.5F sheath. The 2-D images were synchronized at end diastole and then digitized using an off-the-shelf video capture board (Dazzle). The digitized images were processed using custom software (Boston Scientific). A total of 64 2-D slices were used to recreate the geometry of interest. The slices were, on average, separated 0.8 mm apart. The 3-D geometry was rendered using OpenGL code and bilinear interpolation.

After the 3-D geometry of the chamber of interest was reconstructed, the cardiac activity data were added as a fourth dimension. The 4-D maps represented cardiac activity isochronally or dynamically.

The right ventricular (RV) procedures consisted of deploying a 4-electrode pacing catheter at the apex of the RV, deploying and fitting the basket catheter into the RV via the Inferior Vena Cava (IVC), by passing through the Tricuspid Valve (TV), and of deploying the ICE catheter into the RV via the IVC and TV.

The left ventricular (LV) procedures consisted of deploying the pacing catheter in the RV, deploying the basket catheter into the LV retrograde, through the Aortic Valve, and of deploying the ICE catheter into the LV transseptally via the IVC, through the Fossa Ovalis and through the Mitral Valve.

III. RESULTS

A. *In Vitro* reconstruction of basket position and electrode location

With the basket catheter fully expended in a saline tank, the ICE catheter was pulled back at 1-mm/s speed and images were acquired as explained above. The 2-D ICE images revealed that the basket electrodes (made of Pt-Ir) displayed a ringing reflection pattern (Fig. 1). Based on the known pullback velocity, the image of the basket was reconstructed and compared against its actual orientation and position. The reconstructed and actual sizes are shown in Fig. 2(a) and (b).

Report Documentation Page

Report Date 25OCT2001	Report Type N/A	Dates Covered (from... to) -
Title and Subtitle Electro-Anatomical Four-Dimensional Mapping of Ventricular Tachycardia		Contract Number
		Grant Number
		Program Element Number
Author(s)	Project Number	
	Task Number	
	Work Unit Number	
Performing Organization Name(s) and Address(es) Boston Scientific, San Jose, CA 95134		Performing Organization Report Number
Sponsoring/Monitoring Agency Name(s) and Address(es) US Army Research, Development & Standardization Group (UK) PSC 802 Box 15 FPO AE 09499-1500		Sponsor/Monitor's Acronym(s)
		Sponsor/Monitor's Report Number(s)
Distribution/Availability Statement Approved for public release, distribution unlimited		
Supplementary Notes Papers from the 23rd Annual International Conference of the IEEE Engineering in Medicine and Biology Society, October 25-28, 2001, held in Istanbul, Turkey. See also ADM001351 for entire conference on cd-rom., The original document contains color images.		
Abstract		
Subject Terms		
Report Classification unclassified	Classification of this page unclassified	
Classification of Abstract unclassified	Limitation of Abstract UU	
Number of Pages 3		

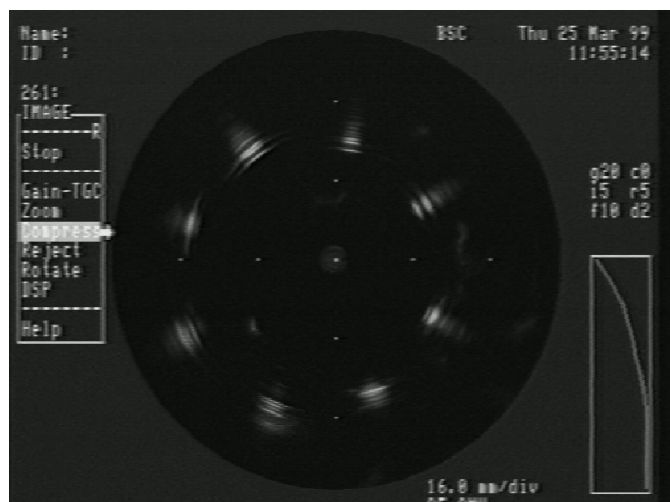


Fig. 1. Basket electrodes display a ringing reflection pattern when placed in the ICE imaging plane.

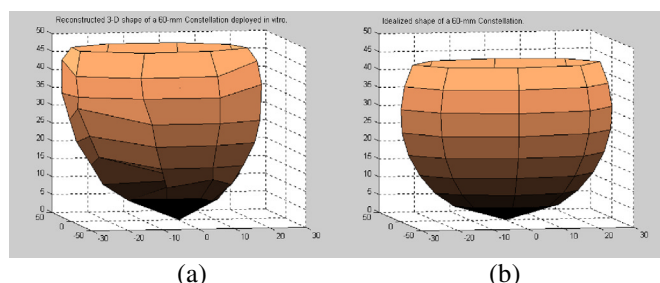


Fig. 2. (a) Reconstructed image of a 60-mm basket. (b) Actual size of the 60-mm basket.

B. In Vivo reconstruction of basket position and electrode location

Figure 3 shows the reflection pattern produced by basket splines in the RV. The contrast is not as good as in the *in vitro* images. Consequently, it was more difficult to detect the electrode location *in vivo*. Figure 4 (a) and (b) show reconstructed and actual-size views of a 75-mm basket that was deployed in the LV. Figure 4 (a) correctly indicates that the basket was compressed radially while deployed in the LV.

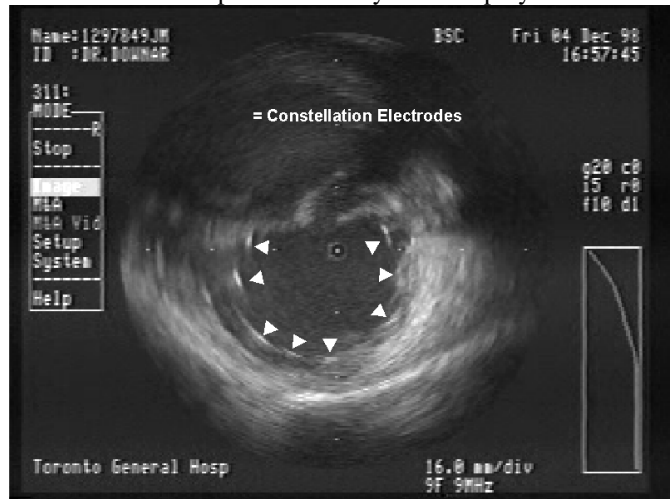


Fig. 3. Spline reflections from a basket deployed in the RV.

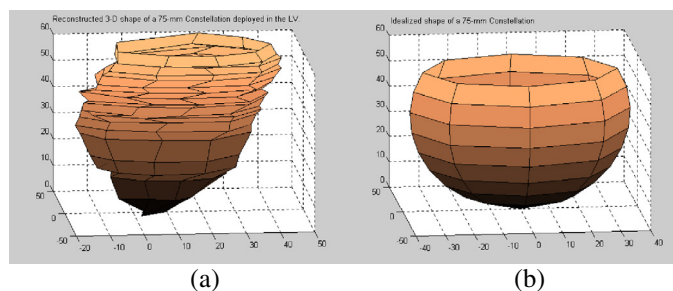


Fig. 4. (a) Reconstructed image of a 75-mm basket deployed in the LV. (b) Actual size of the 75-mm basket.

C. Isochronal mapping of VT

Five patients have been mapped using these technologies. Four patients had idiopathic VT originating from the RV outflow tract (RVOT). One patient had ischemic left ventricular VT. Figures 5 and 6 show reconstructed 4-D maps of the RV and LV activity, respectively. Light colors indicate early activity sites. Red (or dark) colors indicate late activity sites. The animated 4-D map of the left ventricular VT showed re-entrant activity on the superior part of the LV septum. In all cases, the 4-D maps pinpointed to the origin of the VT that was then treated successfully by applications of radiofrequency energy.

IV. DISCUSSION

We conclude that the *in vitro* validation of the technique produced good results. Clinically, the technique was safe, expedient and did not result in any kind of complications. Improvements could be made to speed up the image processing that renders 3-D volumes. For this purpose, fast contour detection algorithms would be beneficial. Using ICE, 3-D anatomic details of ventricles were accurately identified and measured. Mapped electrical activity correlated well with the reconstructed 3-D anatomy and fluoroscopy. 4-D animation of electrical events provided understanding of arrhythmogenic substrates. Use of ICE and basket data provides unique anatomic nesting of electrophysiological information. Combination of the two techniques warrants further clinical investigation

V. REFERENCES

- [1] D. Packer, A. Natale, K. H. Monahan, et al., "Application of multirow spiral computed tomographic scanning to detect pulmonary vein stenosis in patients undergoing circumferential ultrasound ablation," *Circulation*, vol. 102, no. 18, pp. II-597, 2000.
- [2] D. Khoury, H. Sun, E. O. Velipasaoglu, et al., "Four-Dimensional, Batrial Mapping in the Intact Beating Heart," *PACE*, vol. 23, no. 4(2), pp. 750, 2000.
- [3] A. Suzuki, K. Kuga, M. Enomoto, et al., "Findings of the intracardiac echocardiography of the crista terminalis in patients with atrial flutter," *Circulation*, vol. 102, no. 18, pp. II-619, 2000.
- [4] R. D. B. Simon, R. Razavi, M. E. Miquel, et al., "True electro-anatomical mapping achieved by the simultaneous use of a right atrial basket catheter and 3D intracardiac echocardiography," *JACC*, vol. 37, no. 2(A), pp. 426A, 2001.

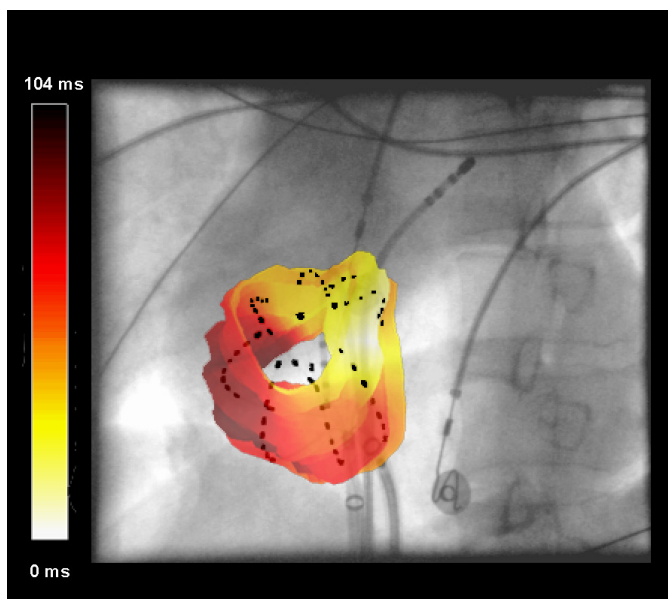


Fig. 5. Early site of RV activity located at the RVOT.

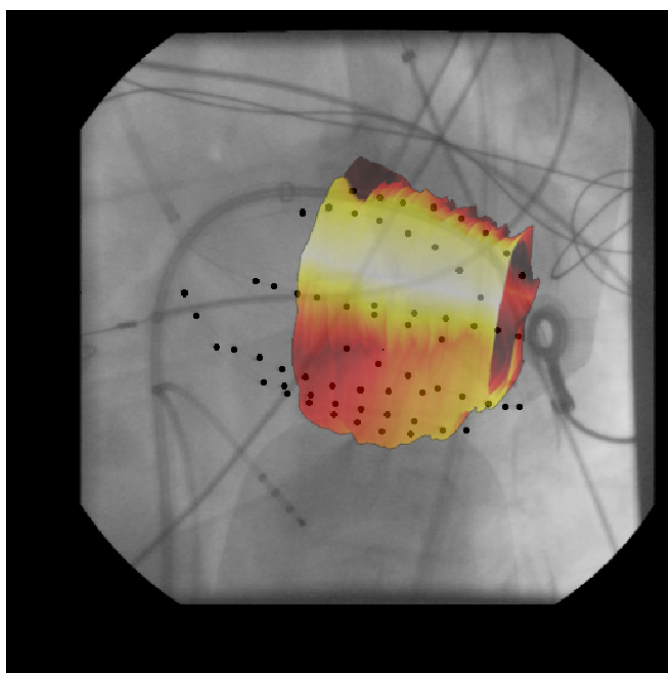


Fig. 6. Snapshot from the re-entrant sequence of LV arrhythmic depolarization on the superior side of the LV septum.