



AD NO. _____
TECOM PROJECT NO. 8-EI-495-BPF-001
REPORT NO. ATC-8199 (VOLUME II)
USAISR INSTITUTE REPORT LEAP 99-2



VOLUME II
FINAL REPORT
OF THE

LOWER EXTREMITY ASSESSMENT PROGRAM (LEAP 99-2)

U.S. ARMY COMMUNICATIONS – ELECTRONICS COMMAND
NIGHT VISION ELECTRONIC SENSORS DIRECTORATE
FORT BELVOIR, VA 22060-5806

U.S. ARMY INSTITUTE OF SURGICAL RESEARCH
EXTREMITY TRAUMA STUDY BRANCH
FORT SAM HOUSTON, TX 78234-6315

U.S. ARMY ABERDEEN TEST CENTER
ABERDEEN PROVING GROUND, MA 21005-5059

U.S. ARMY SOLDIER SYSTEMS COMMAND
NATICK, MA 01760-5019

AUGUST 2000

20030106 029



Robert M. Harris

Mark S. Rountree

Lanny V. Griffin

Roman A. Hayda

Terry Bice

Stephen J. Mannion

*U.S. Army Institute of Surgical Research
Extremity Trauma Study Branch
Fort Sam Houston, Texas*

Abstract

Research conducted by Department of Defense laboratories and facilities, collaborating with leading academic institutions, has demonstrated that currently available landmine protective footwear does not prevent severe injury. This footwear potentially reduces injury severity against some antipersonnel mines. Volume 2 of the Lower Extremity Assessment Program (LEAP 99-2) discusses the change of injury pattern in a cadaver model wearing mine protective footwear during an antipersonnel blast mine detonation. Our analytical methodology developed to assess mine-protective footwear and injury severity associated with blast mines across the spectrum of threat is presented.

Table of Contents

<i>Item</i>	<i>Page</i>
Abstract	iii
Executive Summary	xi
Contributors	xi
Foreword	xiii
Introduction	1
Antipersonnel Landmine Development	1
Antipersonnel Landmine Burden	1
Antipersonnel Landmine Description	1
International Landmine Treaties	2
Demining Programs and Risk Assessment.....	3
Development of U.S. Testing.....	3
USAISR-ETSB Involvement	3
Study Purpose	3
Methods and Materials	3
Protocol Approval	3
Specimen Issues	4
Footwear	4
Mine Data	5
Range Facilities.....	5
Instrumentation	6
MTS	7
Test Procedures	8
Safety Issues	10
Data Collection	10
Statistical Analysis	11
Results	11
Cadaver Demographics.....	11
Environmental Factors.....	11
Photography, Video, and Cineradiography	11
MTS	12
Force Data.....	16
Post-Test Evaluations	16

Statistical Analysis	16
Discussion	20
Summary	20
Medical Aspects of Landmine Injury	21
ICRC Scoring System.....	22
Civilian Scoring System	23
MTS Scoring System.....	24
Models	24
Instrumentation Data	25
Mine Protective Strategies	26
Conclusions	28
Recommendations	31
References	33
Appendices	
<i>Appendix A, (Detailed medical assessments)</i>	A-1
<i>Appendix B, (Pretest X-rays)</i>	B-1
<i>Appendix C, (Post-Test X-rays)</i>	C-1
<i>Mine Trauma Score</i>	
0.....	C-3
1.....	C-3
1A.....	C-4
1B.....	C-4
2.....	C-4
2A.....	C-5
2B.....	C-5
3.....	C-6
4.....	C-6
<i>Appendix D, (Detailed Footwear Damage Assessments)</i>	D-1
<i>Appendix E, (Force Data)</i>	E-1
Shot 1.....	E-3
Shot 5.....	E-3
Shot 6.....	E-4
Shot 7.....	E-4
Shot 8.....	E-5
Shot 10.....	E-5
Shot 12.....	E-6
Shot 15.....	E-6

Shot 18.....	E-7
Shot 19.....	E-7
Shot 20.....	E-8
Shot 21.....	E-8
Shot 25.....	E-9
Shot 26.....	E-9

Illustrations

Tables

Table 1	Boot Types	4
Table 2	Mine Trauma Score System	8
Table 3	Test Matrix.....	9
Table 4	MTS Values	12
Table 5	Range of Injury Severity	13

Figures

Figure 1	Blast Boot Cutaway	5
Figure 2	Exterior View of the Blast Shelter	5
Figure 3	Data Collection ISO Shelters.....	6
Figure 4	Instrumentation Placement	7
Figure 5	Injury Comparison - M-14	13
Figure 6	Injury Comparison - PMA-2	14
Figure 7	Injury Comparison – PMN.....	14
Figure 8	Injury Comparison – Combat Boot.....	15
Figure 9	Injury Comparison – Combat Boot/Over Boot.....	15
Figure 10	Injury Comparison – Blast Boot/Over Boot	16
Figure 11	Calcaneus Fracture by MTS	17
Figure 12	Navicular Fracture by MTS.....	17
Figure 13	Cuboid Fracture by MTS.....	18
Figure 14	Talus Fracture by MTS	18
Figure 15	Pilon Fracture by MTS.....	19
Figure 16	Number of Fractures Associated with MTS	19
Figure 17	MTS to Femur Injury Threshold Curves.....	26

Executive Summary

Landmine proliferation represents an ever-expanding global problem. More international organizations are becoming involved in demining operations. These efforts coupled with an expanding mine threat create a high potential for deminer injury in numerous regions worldwide increasing the need for better deminer protective equipment. This study was designed to assess the effectiveness of protective footwear during direct contact antipersonnel blast mine detonation.

This volume describes the medical aspects of landmine injuries in detail as they relate to clinical presentation and treatment. The medical significance of amputation level to potential outcome is described as a function of patient rehabilitation and cost.

The sharing of knowledge between the participants, combined with experimental trials, has led to a better understanding of the medical aspects of landmine injury and the elements of protective boot design that are clinically significant.

Past research led to recognition of the following requisites:

- ◆ Development of a biofidelic model of the lower extremity.
- ◆ Development of antipersonnel landmine-testing methodology.
- ◆ Medical assessment of injury severity.

Current testing demonstrates:

- ◆ Commercially available mine protective footwear does not prevent severe injury following landmine detonation.
- ◆ No further testing is necessary for the Wellco® Blast Boot and BFR® boots alone.
- ◆ Cadaveric testing is the most biofidelic model to accurately define the level of potential protection of any footwear. This method gives a reproducible method for AP mine injury assessment and should be utilized in future protocols.
- ◆ Mine blast injuries to the lower extremities do not directly correlate with current injury predictive curves developed by the automotive industry for cadaver testing.

Areas that require further investigation include:

- ◆ The effects of secondary missiles from the boot materials (metal attenuators) need to be evaluated by further testing on whole cadavers.
- ◆ The Med-Eng® boot demonstrated potential improvement in protection against the larger mines, but more testing is warranted due to the limited number of samples.
- ◆ Several nations (UK, Canada, Russia) have developed mine protective footwear employing various types of materials, standoff distance, and actuation mechanisms for protection. Evaluation of this new footwear using the testing methodology developed in this study is recommended.

- ◆ This study evaluated the protective footwear only. Additional testing will need to be performed to determine if there is any benefit or detriment to the lower extremity with the use of the Body Armor Set, Individual Countermine (BASIC) suit.
- ◆ The BASIC suit requires further testing to evaluate its limitations in protecting the wearer against the full range of antipersonnel landmine types and injury patterns (head, upper extremity, torso, contralateral limb, etc.).
- ◆ Due to the variability in live mine detonation, a mine surrogate utilizing cast and pressed TNT (based on threat mine prevalence) may give the most reproducible blast profile.

Contributors

Investigators: U.S. Army Institute of Surgical Research - Extremity Trauma Study Branch

Robert M. Harris M.D.
Mark S. Rountree
Roman Hayda M.D.
Lanny Griffin PhD
Terry G. Bice
Stephen Mannion FRCS, Fellow

U.S. Army Aberdeen Test Center

Ellory Sanderson
Walter Andrefsky
Merle Truitt
William Nori
James Aguiar
Jeff Adams

University of Virginia – Automotive Safety Laboratory

Jeff Crandall PhD
Ricky Bryant

Participants: U.S. Army Communications and Electronics Command – Night Vision and Electronic Sensor Development – Humanitarian Demining

Beverly Briggs
Sean Burke
Charles Chichester
Audrey Bashar
Karen Breiter

U.S. Army Institute of Surgical Research - Extremity Trauma Study Branch

Johannes Blom M.D.
Michael Frisch M.D.
Halena Haywood
Robert Shelton R.N.
Michael Fox
John Thompson M.D.
Brian Krakover
Nigel Rossiter, FRCS, Fellow

797th Ordnance Company (EOD)

Christopher J. Lenker
Spiachel L. Rucker
John W Hilliard

U.S. Army Soldier Systems Command

Denise Tolliver

DEPMED, Camp Bullis, Texas

Sean Komorn

U.S. Army Aeromedical Research Laboratory

Nabib Alem PhD

Foreword

This volume documents the detailed medical report of the injury patterns of the lower extremities produced by the M-14, PMA-2, and PMN antipersonnel mines as they relate to various levels of footwear protection. This volume addresses the effectiveness of the footwear based on medical diagnoses and treatment plans, the mechanism of injury and injury patterns associated with the different landmines tested, and builds on the information contained in Volume 1.

Introduction

The first recorded use of explosive landmines occurred during the American Civil War with the invention of triggering mechanisms for "land torpedoes" by Confederate General Gabriel Raines (Time-Life Books, 1998). The introduction of tanks during World War I led to renewed interest in antitank mine development and current antipersonnel landmine design and employment techniques (Croll, 1998). Further refinement of landmine technology occurred during the Second World War, the first conflict to see large-scale use of landmines. Anti-personnel landmines have played a significant role in every major conflict since. In the 1970s and 1980s, numerous low intensity conflicts fuelled by Cold War rivalries led to a proliferation of landmine use.

This proliferation has led to a worldwide landmine problem of epidemic proportions. It is estimated that landmines kill 800 people per month and injure an additional 1200, amounting to 24,000 new victims per year (Landmine Survivor's Network report, 1998). It is widely accepted that these are conservative figures, which do not reflect the actual number of casualties. Many victims never reach the medical treatment facilities where these statistics are compiled (Gray, 1997).

The presence of landmines has been shown to impede the economic and social rehabilitation of countries recovering from conflict. The safe use of productive farmland and valuable water sources can be denied to residents. When faced with starvation, communities are forced to cultivate mined areas often leading to worker injury. In agrarian countries, handicapped landmine victims are often unable to support themselves, becoming an economic burden on their families and war-torn communities. The International Committee of the Red Cross (ICRC) estimates the cost of providing a 10-year-old child with a lifetime of basic prosthetic limbs to be \$3125 (Garachon, 1993).

Antipersonnel landmines are categorized into five groups as described by Taylor (1999).

(1) Blast: These are the most prevalent type worldwide and are usually surface laid or buried to a depth of 10-40mm. They are pressure activated and normally triggered by stepping on the mine. Protection from this type of mine is the goal of current anti-mine footwear design. An example of this type of mine is the Soviet PMN mine (Banks, 1997).

(2) Fragmentation: These mines rely on the explosive distribution of fragments from the shattered mine casing to create injury (Taylor, 1999). They are typically mounted above ground and tripwire activated. An example of this type of mine is the Soviet POMZ mine.

(3) Bounding fragmentation: These mines are a variant of the fragmentation mine. When activated, a propellant charge is ignited in the base of the mine causing the body of the mine to rise to a height of approximately one meter. A second fuse detonates the main charge distributing the fragments in a wider radius (Taylor, 1999). An example of this type of mine is the Soviet OZM-3.

(4) Directional fragmentation: This is a variant in which, the shape of the explosive charge determines fragment direction. These mines are designed to direct their explosive charge; usually in a fan, in the general direction determined by the operator. The fragments are normally pre-formed objects, such as ball bearings, which are set in a resin matrix. An example of this type is the U.S. M18A1 "Claymore" antipersonnel mine.

(5) Shaped charge: This type of mine is a variation of the blast mine, also pressure activated, in which the explosive force is directed by the shape of the charge. Although very rare, this mine type is designed to overcome protective measures. The Canadian C3A2 “Elsie” is an example is the (Taylor 1999).

Typical blast mines can be roughly grouped into three categories based on explosive weight:

- (1) Small: Explosive weight of 25 – 50 grams
 - (a) US M-14, 28 grams
 - (b) Chinese Type 72, 34 grams
 - (c) Yugoslav PMA-3, 35 grams
- (2) Medium: Explosive weight of 50 – 150 grams
 - (a) Soviet PMN-2, 100 grams
 - (b) Yugoslav PMA-2, 100 grams
- (3) Large: Explosive weight of over 200 grams
 - (a) Soviet PMN, 240 grams
 - (b) Yugoslav PMA-1A, 200 grams

Most AP blast mines are pressure-operated devices, utilizing a mechanical fuzing system that initiates the main charge. Some mine cases are plastic, others are cased in wood while metallic casings are less common. A majority of mines are cylindrical in shape with a pressure plate bearing on an internal fuse or spigot fuse protruding from a central well. Activating pressure can be as low as 2 kg. Most mines use TNT (explosive power 3019 KJ/cm³g-1 – Taylor, 1999) as the main charge but some of the smaller mines use more powerful explosives such as Tetryl (explosive power 3675KJ/cm³g-1 – Taylor, 1999). Explosive geometry and density also contribute to energy potential. The combination of these factors makes it impossible to determine the relative explosive power of mines by explosive weight alone.

A blast mine is usually initiated by pressure on a fuzing mechanism, which detonates a booster or the main charge. Upon detonation, a small volume of explosive is converted into a large volume of hot gas. There is a resulting rise in pressure along a shock front resulting in a propagating “blast wind”, which is the primary injury mechanism. Particulate matter from the footwear, mine casing and from the ground can cause secondary fragment injury (King, 1969). The amount of secondary fragmentation is determined by the mine’s casing material, depth of burial, and the medium in which it is buried. The type of soil the mine is buried in has important effects as well. Heavy, wet soils are relatively resistant to blast propagation, thus directing more of the blast energy upward into the initiating limb, while soft soils absorb energy (The Technical Cooperation Program, 1998).

The use of landmines has long been restricted under International Humanitarian Law (Geneva 1998). Recent efforts have sought to completely ban the use, stockpiling, production, and transfer of anti-personnel landmines. One hundred and fifty-three countries signed the Ottawa Treaty of 1997 and seventy-one have ratified it as of 31 March 1999 (International Humanitarian Law, 1998). Landmines continue to be used in contemporary conflicts despite international treaties banning their use.

In response to the global landmine epidemic, the United Nations and other non-governmental organizations (NGOs) have initiated demining programs. Although several techniques for clearing mined areas exist (vehicles, dogs, etc.), human deminers remain the most reliable and effective means. This method however, is quite dangerous and exposes the deminer to the risk of severe injury or death. In the aftermath of World War II, one deminer was killed or injured per 3279 mines cleared (Bowyer, 1996). For current humanitarian demining programs, preliminary data suggests that approximately 100 deminers are injured per year (Landmine casualty data report: Deminer injuries, 2000).

To better protect US soldiers operating in mined areas, the United States Army Infantry School at Ft. Benning, Georgia developed a written requirement for footwear capable of defeating the M-14 antipersonnel landmine. The U.S. Army Test and Evaluation Command, U.S. Army Soldier Systems Command, and Aberdeen Test Center (ATC) were involved in the initial mechanical testing of the footwear produced for the Body Armor Set, Individual Countermine Pre-planned Product Improvement (BASIC P3I) (U.S. Army Yuma Proving Ground, 1999). ATC was tasked to quantify the relative effectiveness of the footwear and conducted testing utilizing a mechanical leg construct. In an attempt to correlate the footwear's blast attenuation properties to resultant medical outcomes, the U.S. Army Institute of Surgical Research, Extremity Trauma Study Branch (USAISR-ETSB) was enlisted in 1998.

Elements of this Department of Defense (DOD) interagency working group, designed a scientific research protocol called Lower Extremity Assessment Program (LEAP). Funded by the U.S. Army Communications and Electronics Command, Night Vision Electronic Sensor Development (CECOM-NVESD) for the purpose of humanitarian deminer protection, the USAISR-ETSB was tasked to evaluate the mechanism of injury and determine current levels of protection provided by commercially produced anti-mine footwear through correlation with medical outcomes.

Landmine protective footwear is designed to protect the lower extremity from proximity and direct contact explosions. Our study was designed to biomechanically evaluate blast landmine injuries and to correlate the medical outcomes based on various levels of footwear protection. The objectives for this study were:

- 1) Provide data for the initial assessment of the effectiveness of mine protective footwear.
- 2) Acquire strain and axial force measurements on a cadaver lower limb during anti-personnel mine detonations.
- 3) Document the blast event.
- 4) Provide empirical data for development of injury criteria.

Methods and Materials

The USAISR's Institute Review Board in accordance with all Federal, State, and Local regulations, approved the LEAP protocol after review. In addition, the Medical Research Material Command Human Subject Review Board reviewed the protocol considering all ethical issues.

Twenty fresh-frozen full body human cadavers were obtained from the Willed Body Program at Southwestern Medical Center in Dallas, Texas. All Federal, State, Local and Regulatory Commission rules were observed in the purchase, disclosure, transportation, and storage of the cadavers. Cadavers were maintained at -4 °C prior to testing and then thawed in a refrigeration unit maintained at 7.2 °C for five days. The pretest radiographs of the lower extremity from the pelvis to the foot were performed to identify any preexisting pathology. Transportation to the range was in a refrigerated truck, where final instrumentation and testing took place. Before the test, the subject was clothed in Battle Dress Uniform (BDU) and outfitted with the selected protective footwear. Following testing, the instrumentation was removed and the cadaver was returned to the USAISR and placed in cold storage until post-test radiographs and clinical dissections were completed.

The protocol specifications called for males ≤ 70 years of age. However, due to availability issues, the study's upper limit was 96 years of age, and two females were accepted for testing.

The Willed Body Program in accordance with all Federal, State, and Local regulations cremated the cadaver remains.

Various types and combinations of commercially available standard footwear and landmine protective footwear were evaluated and are listed in Table 1. The main objective of the study was to evaluate the level of protection of the Wellco® boots (study) compared to the standard combat boot (control). A small number of mines were tested against the BFR boot, Med-Eng boot, and improvised footwear to ascertain the potential effectiveness of these protective measures. The detailed descriptions of this footwear can be found in Volume 1 of this report. Figure 1 shows a cutaway of the Wellco® anti-mine footwear sole's construction showing the V-shaped blast attenuation plate and aluminum honeycomb. The pre- and post-blast weights of the boots as well as fragment weights were recorded. Photographs and descriptions of the footwear post-blast are contained in this volume in Appendix D, Detailed Footwear Damage Assessments. Two specimens were tested in a striding position against PMN mines wearing the BASIC P3I pants to ascertain their potential benefit in contralateral limb injury reduction.

Table 1: Boot Types

<i>Boot Type</i>	<i>Manufacturer</i>	<i>Abbreviation</i>
Sandal	Improvised	Sandal
Combat Boot	Ro-Search	CB
Blast Boot	Wellco®	BB
BFR V-40	BFR	BFR, Singapore, Sing
Over Boot	Wellco®	OB, OS
Spider Boot	Med-Eng®	Canadian, Med-Eng, FPS

Figure 1: BB Cutaway



Three different mine types were utilized for testing: the PMN, 240 g TNT (large); PMA-2, 100 g TNT (medium); and the M-14, 28 g Teteryl (small). They were selected to represent a sampling across the spectrum of AP mine threat worldwide. The detailed descriptions of the tested mines are contained in Appendix A of Volume 1 of this report.

Testing was conducted at Camp Bullis, Texas, at the USAISR-ETSB Field Test Site. All shots were performed in a blast/biohazard containment shelter manufactured at ATC. Figure 2 shows the blast shelter. Cadavers were suspended from the ceiling using a specially designed harness constructed at the USAISR-ETSB. The mines were detonated in an 18" x 24" x 24" deep steel box constructed in the floor of the shelter. The shelter was elevated ~34" above ground level. Data collection equipment was housed in a mobile army surgical suite (ISO Shelter) shown in Figure 3.

Figure 2: Exterior View of the blast Shelter.




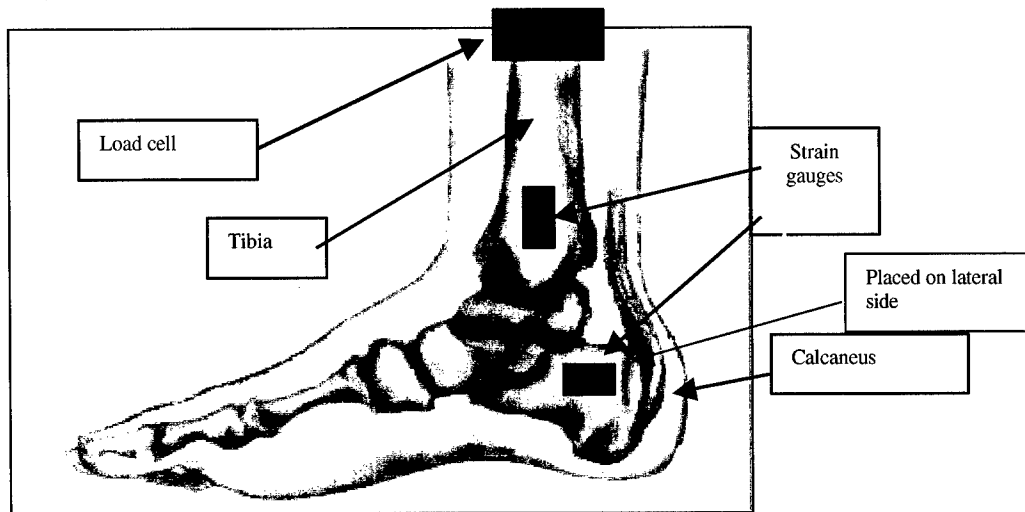
Figure 3: Data Collection ISO shelters.



The initial PMN test was uninstrumented in order to evaluate the injury patterns, facilitate the placement, and access instrumentation survivability in subsequent PMN tests. Load cells were used to measure force. Utilizing previous models from automotive tests, a four-inch segment was removed from the proximal tibia using a surgical saw (Stryker, Santa Clara, CA). The load cell fixture was potted into place using polymethyl methacrylate (PMMA, Richards, Memphis, TN) and further secured by drilling transversely through the bone and using 2-mm diameter stainless steel wires at the proximal and distal ends of the load cell. A polyethylene spacer was used to maintain alignment and stability of the limb for transportation to the field test facility. Once on site, the spacer was replaced with the appropriate load cell. The strain gauge was placed on the distal medial aspect of the tibia and on the lateral surface of the calcaneus as shown in Figure 4. Several load cells were used during the course of the study. A uniaxial load cell was used in LEAP 99-1 to measure force, but it was determined that more axes were needed to properly understand the mechanism of injury and thus for LEAP 99-2 multi-axis load cells were used. All force and strain measurement equipment is fully described in Volume 1 of this report.

Fuji® Prescale Film: Pressure-sensitive film (Sensor Products, Inc., Forest Hills, NY) was used between the foot and the inner boot as well as between the inner and outer boots in an attempt to quantify force transmission properties of the footwear.

Figure 4: Instrumentation Placement



No scoring system has previously been described which addresses the severity of landmine injury in this context. A new scoring system, the Mine Trauma Score (MTS), was developed to compare the severity of mine events under different test conditions. The MTS does not rely on the use of any physiological parameters in order to be applicable to the cadaver test model. The vast majority of landmine injuries in the field will require either transtibial or transfemoral amputations (Coupland, 1991). However, the scope of the MTS includes values appropriate to lesser degrees of injury, which allows for the evaluation of any protective effect of the footwear.

The following terms are defined for use in the MTS:

(1) Closed injury: Injury of the lower extremity that does not violate (lacerate, tear) the skin. There may be underlying fractures that will compromise functional outcome but the potential infective sequelae of injury may be avoided.

(2) Open contained injury: Any lower extremity in which the skin is breached (lacerated, torn) but little evidence of contamination is present. An example would be a laceration to the skin of a foot contained within an intact boot. By avoiding, the gross contamination usually associated with mine injury it is hypothesized that this group would sustain fewer complications such as infection.

(3) Open contaminated injury: Any blast mine injury to the lower extremity in which the skin is not only violated but the exposed soft tissue is visibly contaminated. This contamination may be from the soil, footwear debris, or mine fragments.

(4) Salvageable limb: A lower extremity in which the severity of the injury does not render primary amputation inevitable.

(5) Transtibial/transfemoral amputation. In some blast mine detonations, the injury will be of a severity to make it difficult to determine the level of amputation required. This occurs when the area of injury extends into the proximal third of the tibia. Even when the extent of soft tissue damage does not extend above the knee, there may be insufficient tibial stump to fit a workable prosthesis or there may be so much skin and muscle loss as to anticipate difficulties in delayed primary closure. In this circumstance, every attempt is made to keep the

level of amputation transtibial for functional reasons. Revision to transfemoral may be required at a later stage. An MTS value of 3 represents this category of uncertainty of the final level of amputation.

Table 2: Mine Trauma Score System

Injury Assessment	MTS	Injury
No major injury	0	
Salvageable limb	1	Closed
	1A	Open contained
	1B	Open contaminated
Transtibial amputation	2	Closed
	2A	Open contained
	2B	Open contaminated
Transtibial / transfemoral	3	
Transfemoral	4	

Thirty-one mines were tested against various combinations of footwear for LEAP 99-2; seven mines were tested in LEAP 99-1, "Pilot Study" (PS1-PS7). The test matrix is listed in Table 2. Before the test, the feet of the subject were outfitted with the various protective measures listed in Table 2. The load cell spacers were removed and replaced with the selected load cell. To prevent damage during transportation, the apposite strain gauges were implanted last. The strain gauges were attached to the cortical surface of each bone with fibrin glue after removing all tissue with acetone.

Table 3: Test Matrix

Shot #	Mine Type	Boot Type (Inner/Outer)	Shot #	Mine Type	Boot Type (Inner/Outer)
01	M-14	CB	20	M-14	BFR
02	PMN	CB	21	PMN	CB/Canadian
03	M-14	BB/OB	22	PMN	BFR/OB
04	M-14	CB/OB	23	PMN	BFR/Canadian
05	M-14	CB/OB	24	PMA-2	BFR/OB
06	M-14	BB/OB	25	PMN	BB/OB
07	M-14	CB/OB	26	M-14	Sandal
08	M-14	BB/OB	27	PMN	Sandal
09	PMA-2	BB/OB	28	PMN	BB/OB
10	M-14	BB/OB	29	PMA-2	BB/Canadian
11	PMN	CB/OB	30	PMN	BB/OB
12	M-14	CB/OB	31	PMN	BB/Canadian
13	PMA-2	CB/OB	<i>PS1</i>	<i>M-14</i>	<i>CB</i>
14	PMN	BB/OB	<i>PS2</i>	<i>M-14</i>	<i>CB</i>
15	PMA-2	BB/OB	<i>PS3</i>	<i>M-14</i>	<i>CB/OB</i>
16	PMA-2	BB/OB	<i>PS4</i>	<i>M-14</i>	<i>CB</i>
17	PMA-2	BB/OB	<i>PS5</i>	<i>M-14</i>	<i>BB</i>
18	PMA-2	BB/OB	<i>PS6</i>	<i>M-14</i>	<i>CB</i>
19	M-14	BFR	<i>PS7</i>	<i>M-14</i>	<i>BB/OB</i>

The specimen was suspended upright in a specially designed harness incorporating a modified Thoracic Lumbosacral Orthosis (TLSO) brace that stabilized the hips. The knee was fitted with an immobilizer to maintain axial alignment and simulate muscle rigidity.

The mines were employed flush with the surface of the dry sand in a steel box; similar to actual deployment. The heel of the boot was positioned directly over the anti-personnel blast mine in line with the tibia, with sufficient body weight to activate the mine. Case studies show there is substantial risk of injury to the contralateral limb during a mine event like the PMN. To mitigate this risk and prevent additional damage to the previously tested limb, smaller mines were used against the primary limb and then that limb was amputated prior to testing a PMN against the opposite limb. When testing the smaller mines the contralateral limb was secured in a flexed position away from the detonation and protected with Kevlar® fabric.

Explosive Ordnance Disposal (EOD) personnel using RP-80 commercial blasting caps armed the mines. Personnel from ATC, under direct supervision of EOD personnel, performed the firing and timing of data collection. This procedure and associated equipment are fully described in Volume 1 of this report. For the purposes of this study it is assumed that there is little variation in explosive profile between mines of the same type.

All explosive material was transported, stored, employed, and disposed of by Fort Sam Houston Explosive Ordnance Disposal (EOD) personnel in accordance with all Federal and DOD regulations. All range operations were performed in compliance with all DOD and Department of the Army regulations.

All personnel involved in the handling and instrumentation of the cadaveric specimens were trained in and utilized universal precautions. All cadavers were tested for communicable diseases before delivery from the Willed Body program. Cadaver preparation and testing facilities were cleaned and maintained in accordance with Brooke Army Medical Center (BAMC) operating room standard operating procedures.

Radiographic/cineradiographic procedures were conducted under approved Federal and DOD regulations and all range personnel were trained in safety procedures.

Weather data was obtained from the local weather station for the testing period. The temperature, barometric pressure, and relative humidity were reported for each day in three-hour blocks. The individual tests have been correlated to the specific period and the weather data specific to that time recorded in the database.

Before testing the cadavers underwent complete lower extremity evaluation to identify any preexisting pathology, and after testing to assess blast effects. Pretest radiographic assessments can be found in Appendix B, Pretest X-rays. The BAMC radiology department performed the following studies:

The cadavers were evaluated using Anterior-Posterior (AP) views of the pelvis, and AP and Lateral views of the femur, knee, leg, ankle, and foot. Complete lower extremity examination in 5-mm slices was conducted using a CT (Picker PQ 5000). MRIs were performed on the LEAP 99-1 cadavers, but after review by Orthopaedic traumatologists and a Radiologist, MRIs were deemed to be of no value in this type of cadaver testing and were discontinued.

For each specimen anatomical dissections were performed by one of two board-certified Orthopaedic Traumatologists blinded to the specific footwear and mine threat.

Force and Strain Data Collection was performed by personnel from ATC. All data collection methods and equipment used are fully described in Volume 1 of this report.

Photographic Data Collection was performed by personnel from ATC. All data collection methods and equipment used are fully described in Volume 1 of this report.

Photographs were taken of the cadaver just before detonation and again immediately following mine detonation.

Photographic Data: Personnel from ATC took high-speed video of all tests and the equipment used is fully described in Volume 1 of this report.

Personnel from ATC obtained high-speed radiographic images of each blast event. Methods and materials used are fully described in Volume 1 of this report.

Protective footwear combinations were compared by mean MTS values, utilizing a scale from 0 to 8 with an MTS of 0 equal to zero and a MTS of 4 equal to 8. Standard deviations were calculated based on our sample size. Variables considered in our statistical analysis are listed in Table 4. A bivariate correlation analysis was performed in order to determine important relationships between variables and factors, having a *p* value of less than 0.10. The data was evaluated statistically using a cross tabulation procedure. Given the limited number of tests performed on the sandal, Singapore (BFR) boot, and the Canadian boot, these types of footwear were not included in the statistical analysis. For the purposes of this analysis the MTS was assigned a binary value. The threshold between the values was assigned as an MTS of 2A; a score of 2A or below being the lesser severity binary value and that greater than 2A representing the more severe pattern. The clinical rationale for assigning this value is that a 2A score represents an injury, which, requires a transtibial amputation, is unlikely to require revision to transfemoral amputation. An MTS of above 2A is at risk of resulting in a transfemoral amputation, which is associated with a markedly less favorable functional outcome.

Comparisons for the cross tabulations were (1) MTS and boot type for the M14 mine and (2) MTS and mine type for the blast boot/over boot combination (BB/OB). For the purposes of (1) the single blast boot alone shot was included in the combat boot group, this boot being taken as offering no greater protection than the combat boot. Similarly in (1) all over boot combinations were considered individually and together. Mines were ordered on the basis of explosive weight, such that the M-14 (28 g) was the lowest and the PMN (250 g) the highest. ANOVA was used to determine if continuous data, such as time-to-peak force, were related to MTS. Statistics were evaluated using SPSS (version 9.0, Chicago, IL).

The lower extremity bones considered in this analysis are the calcaneous, navicular, cuboid, talus, and pilon area of the distal tibia. For these purposes, a binary value was assigned, 1 indicating that a fracture with severe comminution was present, 0 indicating either no fracture or a fracture that is minimally displaced. These data are compared to the mine trauma score and evaluated for correlation.

Results

Twenty cadavers were utilized for thirty-eight total shots (Seven shots were conducted during LEAP 99-1). Two cadavers were female and eighteen were male. (Two females and two males were utilized during LEAP 99-1). The mean age of cadavers was 77 years with a range from 37 years to 96 years of age. The mean cadaver weight was 159 pounds with a range from 97 pounds to 205 pounds.

The weather data is on file in the LEAP 99-2 database maintained by the USAISR-ETSB.

A series of still photographs were taken of each cadaver just before and immediately following detonation. High-speed video was captured for all the tests and eight individual x-rays of the initial blast wave were captured for every shot (Cineradiography). All photographic data (still and high-speed) as well as cineradiographic images are on file at ATC and will be further addressed in Volume 3 of this report. All audiovisual images are on file at both ATC and the USAISR-ETSB.

The MTS value was assigned to each test cadaver by one of two experienced board-certified military Orthopaedic Traumatologists, each of who has a domestic practice consisting entirely of orthopaedic trauma. One surgeon gained field experience during the armed conflicts in Somalia and Haiti, the other in Bosnia and in treating Gulf War casualties. For the purposes of MTS evaluation, the surgeon was blinded to both the nature of footwear and the mine type in each case. Determination of the MTS value was done predominantly by inspection and dissection of the tissues; similar to the way it would be performed at initial surgery in the field. Post-test radiographs and computerized axial tomographs (CT scans) were also available for review during this process. In each case, the dissection was videotaped. An UK-trained Orthopaedic Surgeon who independently assigned MTS values reviewed the videotaped dissections. This surgeon gained extensive experience while engaged in humanitarian surgical programs treating landmine injuries in Afghanistan, Cambodia, Angola, Rwanda, and Sri Lanka. Interobserver agreement with regard to the independently assigned MTS values was 100%. The MTS values are listed in Table 4.

Fractures occurring at the cemented interface between the load cell and tibia were regarded as artifacts (occurring due to the presence of a stress riser at this point) and not taken into account in the MTS scoring. Furthermore, when surgical closure failure at the instrumentation site occurred, it was not graded as an open injury unless wound propagation was noted.

Table 4: MTS Values

Shot #	Mine Type	Boot Type (Inner/Outer)	MTS	Shot #	Mine Type	Boot Type (Inner/Outer)	MTS
01	M-14	CB	4	21	PMN	CB/Canadian	Low Order
02	PMN	CB	3	22	PMN	Singapore/OB	2A
03	M-14	BB/OB	2A	23	PMN	Singapore/Canadian	2A
04	M-14	CB/OB	1A	24	PMA-2	Singapore/OB	2B
05	M-14	CB/OB	2A	25	PMN	BB/OB	2B
06	M-14	BB/OB	2	26	M-14	Sandal	2B
07	M-14	CB/OB	2A	27	PMN	Sandal	4
08	M-14	BB/OB	2A	28	PMN	BB/OB	3
09	PMA-2	BB/OB	2B	29	PMA-2	BB/Canadian	2A
10	M-14	BB/OB	1	30	PMN	BB/OB	2B
11	PMN	CB/OB	2B	31	PMN	BB/Canadian	1
12	M-14	CB/OB	1A	PS1	M-14	CB	3
13	PMA-2	CB/OB	2B	PS2	M-14	CB	3
14	PMN	BB/OB	2B	PS3	M-14	CB/OB	2
15	PMA-2	BB/OB	3	PS4	M-14	CB	3
16	PMA-2	BB/OB	3	PS5	M-14	BB	2B
17	PMA-2	BB/OB	2B	PS6	M-14	CB	3
18	PMA-2	BB/OB	2B	PS7	M-14	BB/OB	1
19	M-14	Singapore	3	Contra lateral Limb Results			
20	M-14	Singapore	2B	28 / 30	PMN	CB	0

Note: Shots PS1 – PS7 represent LEAP 99-1 Pilot Study MTS values awarded in a retrospective study of original clinical findings.

Table 5: Range of Injury Severities

Boot Type	Range of Mine Trauma Scores					
	M-14		PMA-2		PMN	
	Range	n	Range	n	Range	n
CB Alone	3-4	5	Not tested	0	3	1
Sandal	2B	1	Not tested	0	4	1
BB Alone	2B	1	Not tested	0	Not tested	0
OB Combinations	1-2A	10	2B-3	7	2A-3	6
BFR Alone	2B-3	2	Not tested	0	Not tested	0
Med-Eng Combinations	Not tested	0	2A-2B	1	1-2A	2

Figure 5: Injury Comparisons M-14

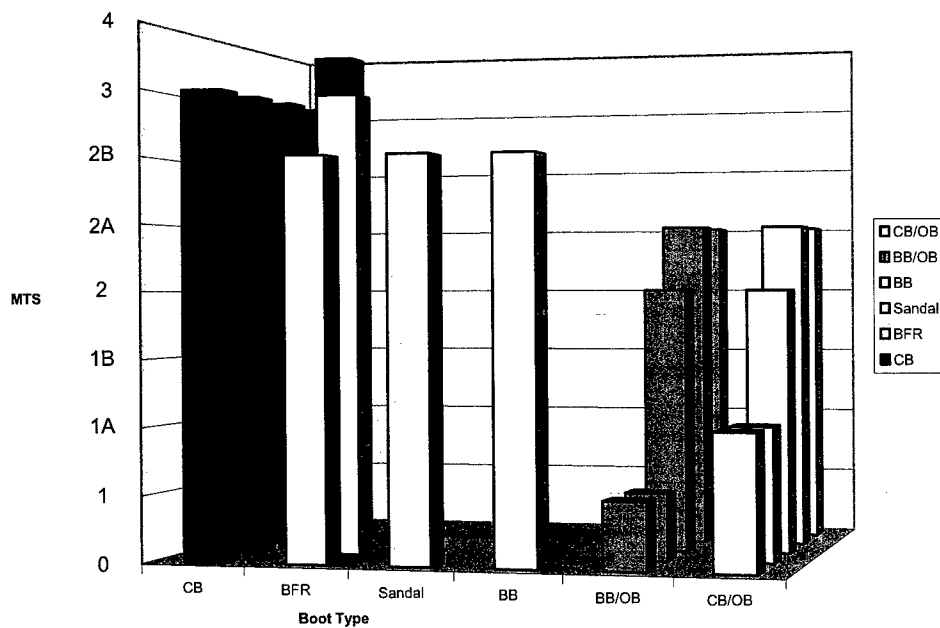


Figure 6: Injury Comparisons PMA-2

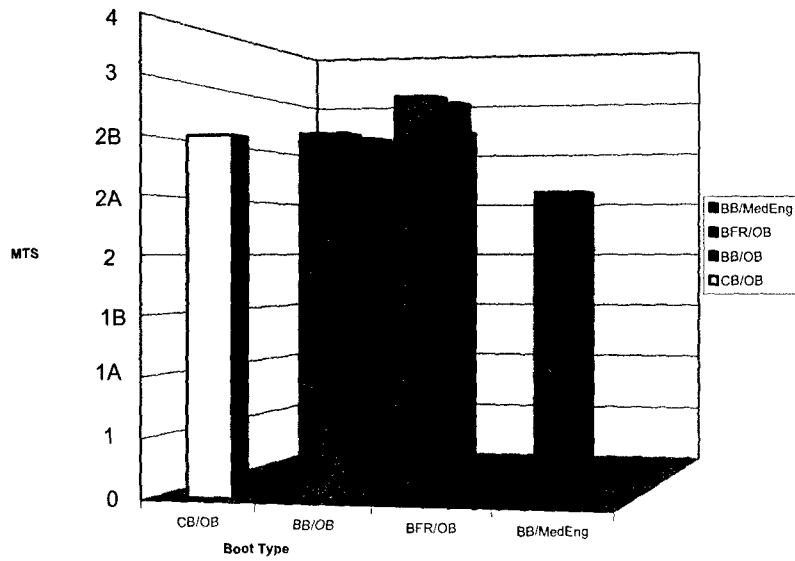


Figure 7: Injury Comparisons PMN

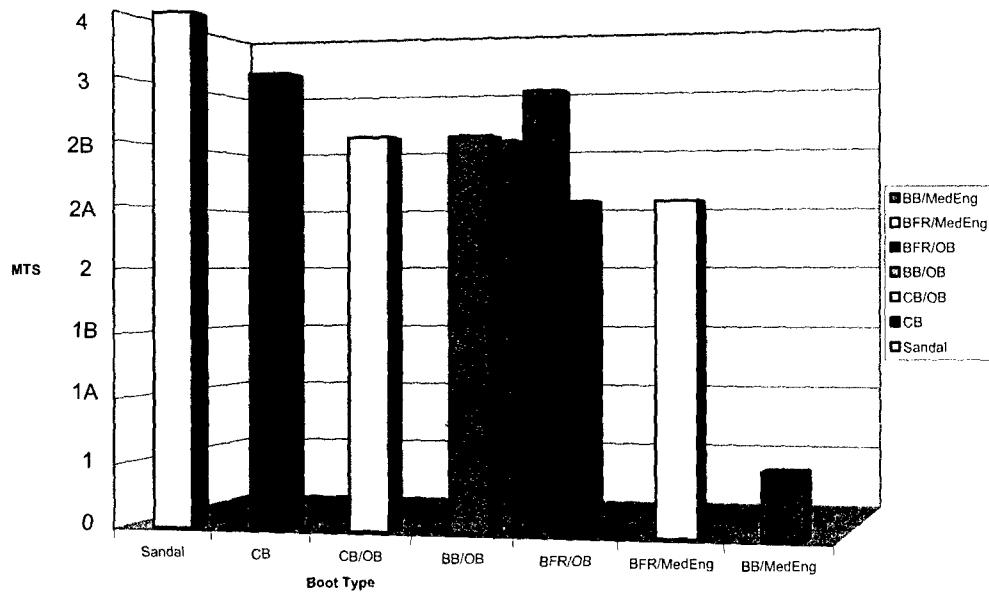


Figure 8: Injury Comparisons Combat Boot

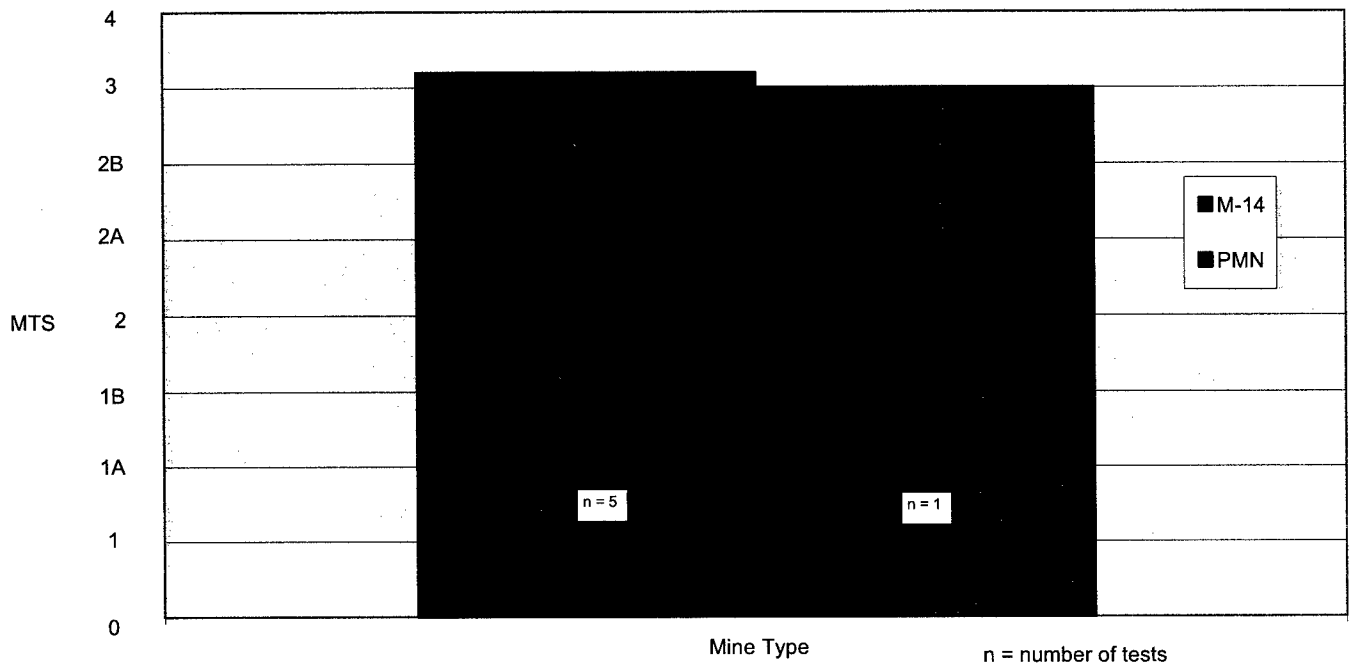


Figure 9: Injury Comparisons CB/OB

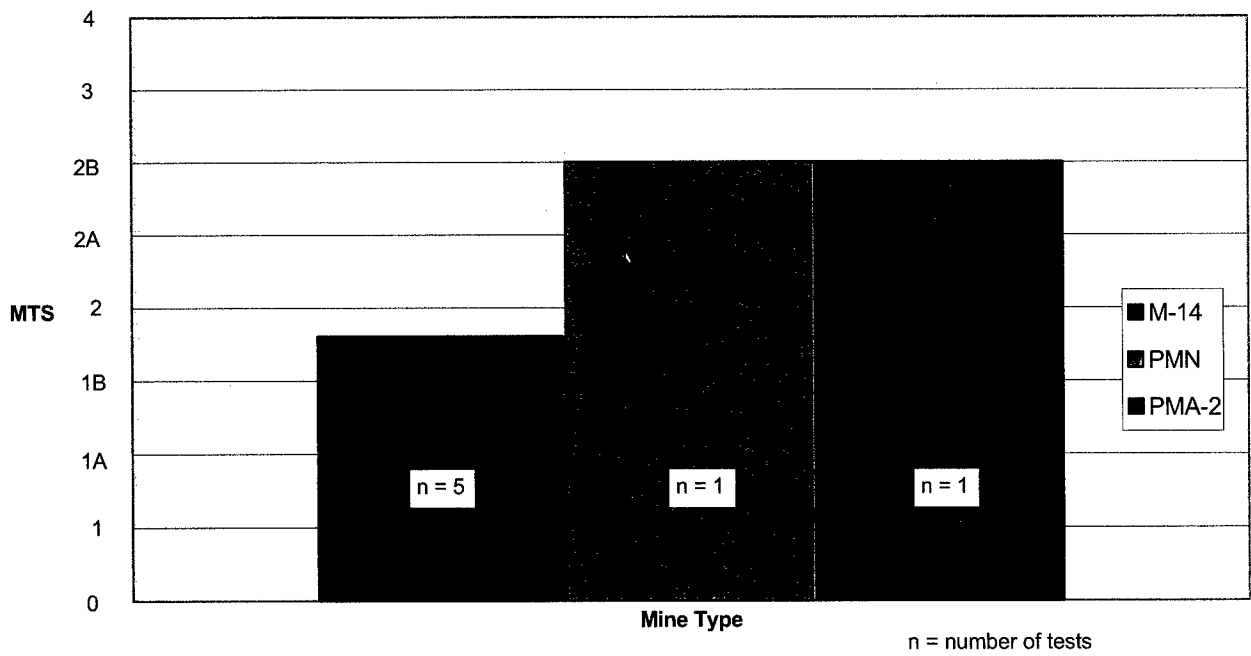
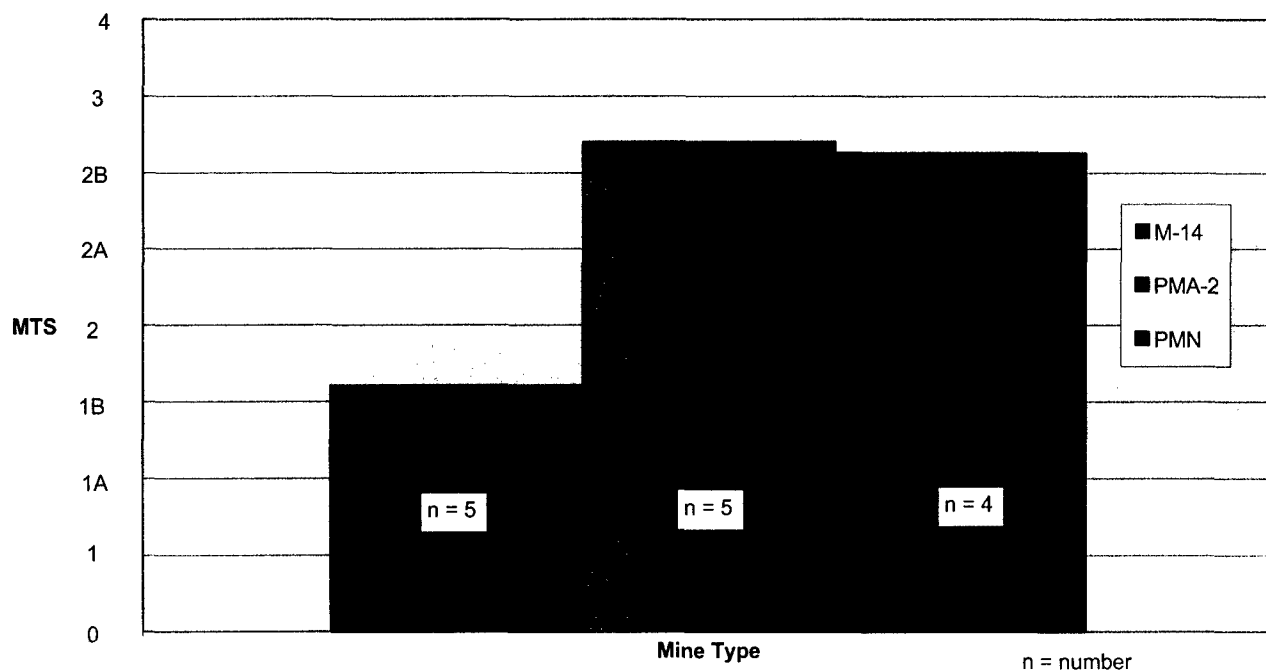


Figure 10: Injury Comparisons BB/OB



Selected force data is listed in Appendix E (Force Data). The detailed force data can be found in Volume 1 of this report. The Fuji film was either contaminated by body fluids or destroyed beyond evaluation in all cases.

Clinical dissections (Appendix A, Detailed Medical Assessments) were conducted following posttest radiographic evaluation. The posttest radiographic data (Appendix C, Posttest X-rays) and gross clinical examinations were both utilized in assigning MTS values.

The pre- and post-blast weights of the boots and remaining fragments were recorded. Post-blast digital photographs and descriptions of the footwear are contained in Appendix D, Detailed Footwear Damage Assessments. These data are on file at the USAISR-ETSB.

Detailed medical evaluations can be found in Appendix A. Example pretest radiographs can be found in Appendix B. Post-test radiograph can be found in Appendix C. Detailed boot damage assessments can be found in Appendix D.

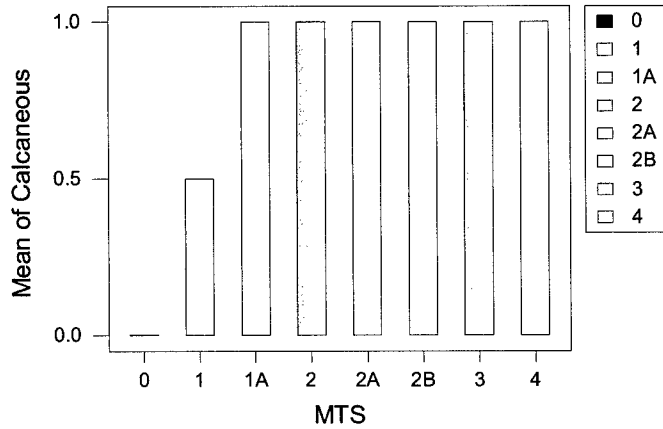
The correlation analysis revealed that the boot and mine type were significant factors as well as the time to peak force. It was found that a significant increase in protection ($p = 0.007$) is obtained by using the over boot with either the combat boot or blast boot. Further, it was found that no statistical improvement in medical outcome is obtained by using the blast boot instead of the combat boot with the over boot. Analyses of the protective measures showed that no boot was able to reduce MTS score below the 2A threshold for the PMA-2 and PMN mines. The over boot in combination with the blast boot or combat boot is able to do this for the M-14 mine only. ANOVA revealed that the over boot combination significantly reduced the time to peak force ($p = 0.031$).

Each bone will be considered independently then the collective results will be used to evaluate the MTS.

Calcaneus.

Figure 11 shows the average value of calcaneus fractures that occurred with MTS for all mines. It is interesting to observe that a fracturing of the calcaneus is characteristic of the mine injury.

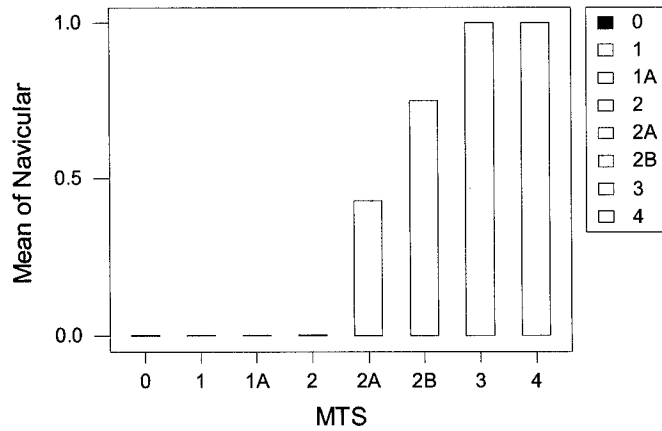
Figure 11: Calcaneus fracture by MTS.



Navicular

Figure 12 shows the probability of navicular fracture occurrence that compared to the MTS. Fractures of the navicular were not observed for MTS less than 2A, and that a fracture of the navicular is characteristic of MTS of 3 or greater.

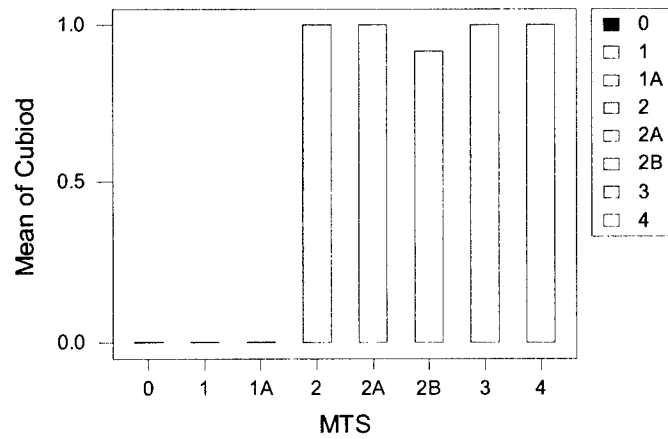
Figure 12: Navicular fracture by MTS.



Cuboid.

Figure 13 shows that a fracture of the cuboid is characteristic of the MTS of 2 or greater.

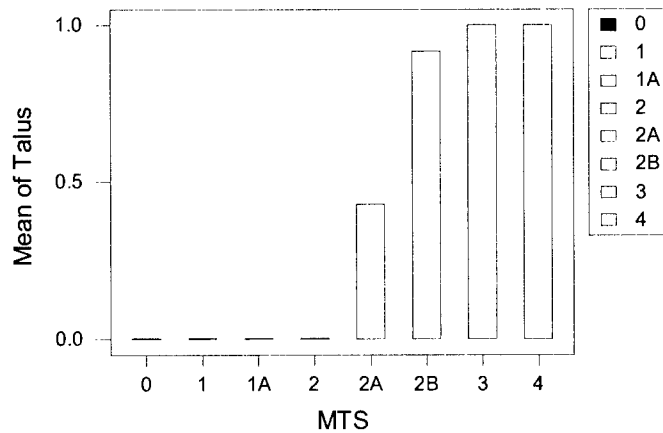
Figure 13: Cuboid fracture by MTS.



Talus

Figure 14 shows that fracture of the talus follows the same trend as the navicular, with a talar fracture not occurring with a MTS less than 2A.

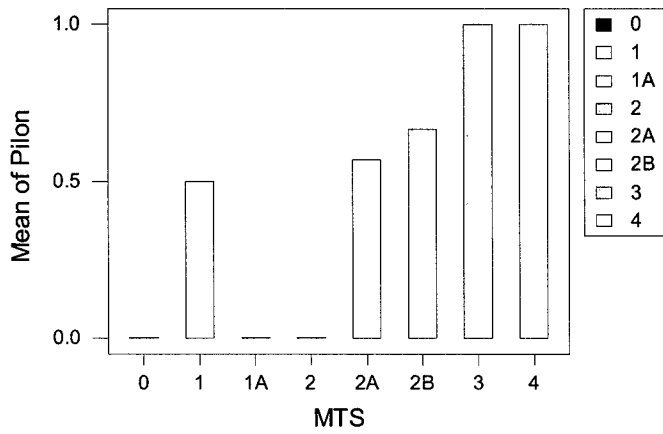
Figure 14: Talus Fracture by MTS.



Pilon Fractures

Fracture of the pilon area with respect to the MTS is shown in figure 15. Significant pilon fractures occur with higher MTS.

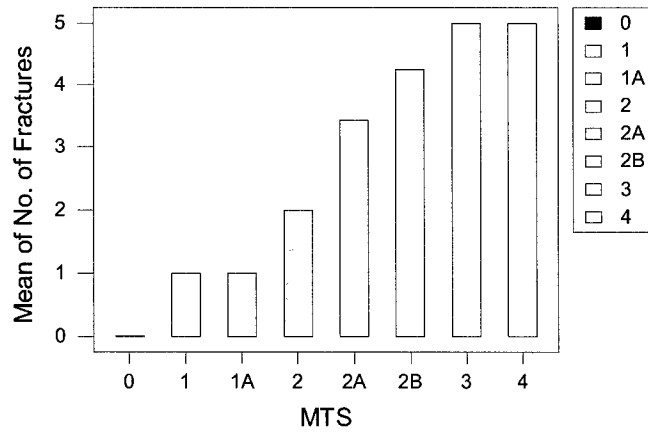
Figure 15: Pilon fracture by MTS.



Number of bone fractures.

Figure 16 shows the number of fractures that generally are associated with a mine injury.

Figure 16: Number of fractures associated with MTS.



Discussion

The purposes of our study were: a) to evaluate the relative protection offered by various combat and protective footwear; b) to determine the *in-situ* forces and strains experienced by the lower extremity under antipersonnel landmine blast conditions; c) to document the blast event; and d) medically evaluate the mine injury to the lower extremity that results from activation of a blast anti-personnel mine. Regardless of the degree of protection offered by the boot, it must be comfortable and permit the user to perform his routine tasks. For the manual deminer this includes squatting, lying in the prone position, and walking on uneven ground. Ergonomic aspects have not been considered in the LEAP study.

In an effort to reduce the level of trauma to the lower extremity from anti-personnel mines, attempts have been made to design protective footwear. In the early 1950s, the U.S. Marine Corps developed a 6-inch sabot attachment for the combat boot, while the Army evaluated protective shanks in the 1960s. Work conducted at the U.S. Army Natick Research, Development and Engineering Center in the 1990s has led to the development of new anti-mine footwear. Before our study, anti-mine footwear has never been evaluated to determine its protective capability from a medical perspective.

Landmine injuries have reached epidemic proportions in third-world nations, and affect both combatants and civilians. From 1980 to 1993, the incidence of landmine-related injuries doubled, resulting in an estimated 2000 deaths or injuries per month (Landmine survivors network report, 1998). By United Nations estimates, there are more than 100 million uncleared mines worldwide (Korver, 1993). However many sources now consider this number to be overestimated (Cameron, 1998).

In our study, all footwear tests against AP landmines resulted in severe injuries to the lower extremity. Differing degrees of injury severity can result in different medical outcomes and this injury reduction is the area affected by current footwear.

The Wellco OB demonstrated a trend of marginal improvement in protection against the smallest mine tested (M-14). This footwear combination allowed for the conversion of a possible transfemoral amputation to a definite transtibial amputation with some potential for a salvageable limb with undetermined function.

Instrumentation of the cadavers led to a better understanding of the explosive event and provided a method of mine output comparison. Significant correlation of force data to the predicted medical outcome has been established and will be addressed in Volume 3 of this report. The surgical incisions and stress risers created in the tibia by load cell implantation may also affect the resultant injury pattern.

Direct contact blast has a different mechanism of injury than that of blunt trauma and thus AP mine injuries do not lend themselves to prediction using current automotive industry force-time data. However they do follow similar trends at a different magnitude and this correlation will be further explored in Volume 3 of this report.

The cadaver model combined with the MTS offers the most reproducible biofidelic model currently available to scientifically study the AP mine injury to the lower extremities.

Based on sample sizes of 1 or 2 we found the following trends in our study:

- a) The Wellco blast boot alone probably offers no better protection than the standard CB alone.

- b) The BFR boot alone probably offers no better protection than the standard CB alone.
- c) The Med-Eng boot, which uses a different protection design, demonstrated some potential improvement in protection against the larger mines.
- d) When the Wellco OB is combined with inner protective (BB, BFR) footwear, there may be marginal additional protective effects against the medium and large mines when compared to the OB/CB combination.

Surgical management of blast mine injury is determined by the extent of injury to the bony and soft tissue structures. The soft tissue injury is often the most important of these factors, the amputative level being determined by the level at which, following debridement of dead and contaminated soft tissue, it is anticipated that there will be an adequate myoplastic flap and skin coverage for delayed primary closure. Amputation level will ultimately determine the degree of function for the landmine victim.

There is undoubtedly some difficulty and uncertainty in determining the level of tissue viability in the cadaver model. Whereas the level to which contamination extends can be relatively easily determined, the extent of the non-viable tissue from the blast injury is more uncertain. Except for gross tissue disruption, none of the clinically significant tests of tissue viability can be applied to the cadaver model.

The MTS value was assigned to each test cadaver by one of two experienced Board- certified military Orthopaedic Traumatologists, each of whom has a domestic practice consisting entirely of orthopaedic trauma. One surgeon gained field experience during the armed conflicts in Somalia and Haiti, the other in Bosnia and in treating Gulf War casualties. For the purposes of MTS evaluation, the surgeon was blinded to both the nature of footwear and the mine type in each case. Determination of the MTS value was done predominantly by inspection and dissection of the tissues; similar to the way it would be performed at initial surgery in the field. Post-test radiographs and computerized axial tomographs (CT scans) were also available for review during this process. In each case, the dissection was videotaped. An UK-trained Orthopaedic Surgeon who independently assigned MTS values reviewed the videotaped dissections. This surgeon gained extensive experience while engaged in humanitarian surgical programs treating landmine injuries in Afghanistan, Cambodia, Angola, Rwanda, and Sri Lanka.

Fractures occurring at the cemented interface between the load cell and tibia were regarded as artifacts (occurring due to the presence of a stress riser at this point) and not taken into account in the MTS scoring. Furthermore, when surgical closure failure at the instrumentation site occurred, it was not graded as an open injury unless wound propagation was noted.

Compared to other war injuries, landmine victims have been shown to require more operations (5.1 compared to 2.2) and a longer hospital stay (37.3 days versus 10) (Korver, 1993). Reduction in injury severity as a result from protective equipment may reduce the number of operations needed.

Patients requiring amputations (80% mine injured) require far greater volumes of post-operative blood transfusion than other war-injured patients. Korver (1993) reported that the requirements of the non-amputated group were 29.2 units of blood per 100 patients compared to 354 units of blood for the amputated group. This difference is even more significant when viewed in the context of third-world mine-affected countries where blood

supplies are scarce and storage facilities limited. Reduction in the severity of injury as exemplified by the protection provided by the over boot against the M-14 mine may reduce the demand for transfusion.

In mine-affected countries, the large numbers of amputees have led to a massive demand for prostheses. For example, in Cambodia the incidence of amputees is 1 of every 236 persons in the population (Chaloner, 1996). Despite initiatives by governmental and NGOs to train native people to produce prostheses using locally available materials, the demand still far exceeds supply. Replacement prosthesis is needed every 3-5 years in an adult and every six months for a child, and so this increased demand will persist for many decades. In four of our test cases the injury to a foot protected by an over boot was thought not to require amputation (MTS 1 or 1A). Clinical cases with this pattern of injury would possibly avoid the need for prosthetic replacement.

Most of the countries with significant mine problems are third-world nations with agriculturally based economies. In the absence of prostheses, amputees are often deprived of their means of subsistence, becoming an economic burden on their families and communities. Where prostheses are available, there is a considerable functional difference between transfemoral and transtibial amputees. Through-knee amputations are seldom undertaken as they present very great difficulties for prosthetic production and fitting. It has been shown that transfemoral amputees are considerably less mobile, make less use of their prostheses, and have greater metabolic requirements in order to mobilize than transtibial subjects. With prostheses, the energy expenditure in a young amputee is 25% over baseline for a transtibial amputation, 40% for bilateral transtibial amputations, 65% for a transfemoral amputation, and 150% for bilateral transfemoral amputations. In victims who do not receive prosthesis, the energy requirements are increased 32% over the normal baseline of walking for a transtibial amputation victim with a three-point gait (Walters, 1987). Failure to consider the increased energy requirements for amputees explains why patients discontinue walking despite the availability of prosthetic care. Therefore, from a surgical perspective every attempt should be made to preserve the knee joint if possible. Preservation of the limb or an amputation that spares the knee joint carries many physiological advantages. Transtibial amputations in young people can have near normal function in certain activities of daily living with a minimal increase in the energy expenditure.

The International Committee of the Red Cross (ICRC) regularly deploys surgical teams to war zones around the world where the indigenous healthcare infrastructure is unable to cope with the numbers of injured or has collapsed because of the conflict. As such, the ICRC has extensive experience in the treatment of war-injured patients, including those injured by landmines, and has meticulous records of greater than 26,000 total cases.

Clinical experience and analysis of the ICRC data has led to the classification of landmine injury into three groups. (Coupland, 1991)

a) Type I: Blast injuries to the lower body: This type of injury is the most common and is sustained from stepping on a buried blast mine, resulting in an amputation of the triggering limb, either above or below the knee. Mud, footwear debris, vegetation, and mine fragments are driven proximally in the limb, spreading along fascial and soft tissue planes. Contralateral limb soft tissue damage is often associated with this type of injury and the extent of damage is directly related to the relative size of the mine's explosive charge. Injury to the perineum (groin) has been seen in larger mine blasts.

b) Type II: Fragmentation injury: This injury results from triggering a fragmentation mine or being in proximity to a blast mine explosion. This pattern involves multiple fragment wounds, most of which will be concentrated in the lower limbs but also may involve the abdomen and thorax.

c) Type III: Detonations of a blast mine in proximity to the face, body, and hands: This injury arises from the detonation of a blast mine in proximity to the hand or face. It typically occurs when the victim is handling a mine or when a mine clearance worker inadvertently detonates a buried blast mine by probing it while in the prone or squatting position. This pattern of injury involves partial amputation of the upper limb(s) and blast/fragmentation wounds to the face, neck, and trunk. Each pattern of injury has its own type of specific mortality and morbidity in terms of sepsis, blood transfusion requirements, prosthetic needs, and rehabilitation concerns.

Several scoring systems exist which attempt to classify the extent and severity of war injury or severe injury to the limbs. Recognizing that scoring systems relating to peacetime injuries are not applicable to war wounds, the ICRC has developed its own wound scoring system. Although this system has been well received and widely used, Coupland in 1992 notes that a traumatic amputation resulting from a landmine cannot be scored easily by this system (Coupland, 1992 & Bowyer, 1993).

(1) Categories: Designed for quick and easy use in the field, this system assigns scores to each of 6 categories:

- (a) E (Entry wound)
- (b) X (Exit wound)
- (c) C (Presence or absence of a wound cavity)
- (d) F (Fracture characteristics, if present)
- (e) V (Injury to a vital structure)
- (f) M (Presence or absence of metallic foreign bodies in the wound)

(2) Grades: By evaluating each category and combining the scores, the war wound can then be graded as 1-3:

- (a) Grade 1: Represents only minimal tissue damage.
- (b) Grade 2: Represents significant tissue damage or comminuted fracture.
- (c) Grade 3: The most severe of penetrating wounds.

Numerous clinical studies have been performed to devise classification systems relating medical outcome to severe limb injury. The purpose of most of these studies was to develop predictive indices that can assist a surgeon's evaluation of the injured limb based on the degree of skeletal and soft tissue injury, the presence or absence of limb ischemia, and the presence of a hypovolemic state, in his decision to salvage versus amputate the severely injured limb. Several authors have described different scoring systems for severely damaged extremities such as the Mangled Extremity Severity Score (MESS) (Johansen, 1990), Mangled Extremity Syndrome Index (MESI) (Gregory, 1985); Nerve, Ischemia, Soft tissue, Skeletal, Age (NISSA) (McNamara, 1994); and others. However, these systems are based on retrospective data from civilian trauma centers and rely on the assessment of physiologic parameters such as blood pressure and the integrity of the nerve and vascular structures to determine if amputation or salvage is indicated.

None of the mangled extremity scores have been validated outside the originating institution. Based on retrospective data, the scoring systems do not define the injury and are often too complex. They are difficult to apply in the clinical setting, and do not address the issue of eventual function of the amputated or salvaged limbs, nor do they consider the impact of differing levels of amputation. It must be recognized that an amputated limb does not necessarily represent a surgical failure as the function with prosthesis may exceed that of the salvaged limb even after extensive reconstructive surgery. Furthermore, these scores rely on assessment of physiological parameters and are thus inappropriate to a cadaver model of landmine injury. The MTS predicts the possible clinical outcome for each of the types of footwear and mines tested in the cadaver model.

In view of the above extremity scoring system's weaknesses, there is a need to develop a severity scale for landmine blast injury. This system should be based on the anatomic assessment of severity to define the injury. In our study the MTS is introduced as a method of evaluating the extent of injury, offering prognostic medical diagnosis and predicting the type of surgical intervention required. It also correlates the predicted medical outcomes to the level of protection provided by various types footwear against different mine threats. The MTS scores were assigned via surgical dissection of the injured limb in conjunction with radiographic views of the post-test specimen. In this regard the findings from the surgical dissection were by far the most useful and predictive for MTS purposes. Plain X-rays had little bearing on the MTS values other than in one case with a non-reconstructable severely comminuted intercondylar femur fracture requiring transfemoral amputation. The situation is similar to the surgical treatment of landmine victims in the field where, if faced with large numbers of injured patients, radiographs are unlikely to alter the initial operative plan for those wounds that obviously require amputation (Coupland, 1993). CT scans were similarly found to have little bearing on MTS scoring but did accurately determine the extent of periarticular fractures and are predicted to be useful in the development of a mathematical model of landmine injury. MRI was included in the pilot study to define the extent of soft tissue damage. However, this imaging study did not prove to be worthwhile. MRI relies on physiologic changes in fluid content to define the zone of injury. In the cadaver model, these changes did not occur and therefore resolution was poor. As a result, MRI scanning was discontinued as part of the experimental protocol after the pilot study.

Experimental Models for Landmine Injury: In order to assess the potential benefits of mine protective footwear a suitable test model is needed to simulate the injury pattern.

Although live and cadaveric animal models have been utilized to study other aspects of ballistic and penetrating injury (Bowyer, 1996) these are of limited use when investigating blast mine protection or injury because there is no animal model equivalent in complexity to the anatomy of the human foot, with or without footwear.

Surrogates of the lower extremity remain at a preliminary state of development (Hybrid II, THOR, FSL) and need to be validated against a more biofidelic model before widespread application. Many of these manikins were developed by the motor vehicle industry (United States Army Aeromedical Research Laboratory, 1997) and are designed to mimic human injury patterns from frontal impacts. These surrogates have been adapted for use in the absence of any injury criteria relating to blast injury to the lower limb. The parameters used to determine the risk of

long bone fracture were taken from automotive crash testing data, but requires validation before manikins can be used in antipersonnel mine testing.

Similarly, mathematical models of landmine injury using finite element analysis (FEA) are in the embryonic state of development and in need of input from experimentally derived biomechanical data to accurately simulate the injury process.

Currently the best model for antipersonnel landmine injury is whole-body human cadaver testing. As single limb and partial body models lack accurate mass and movement, this limits their use for precise reproduction of the injury. While full body cadaver testing represents the closest available model for blast injury research, it is recognized that there is some loss of biofidelity in modeling soft tissue and neurovascular response.

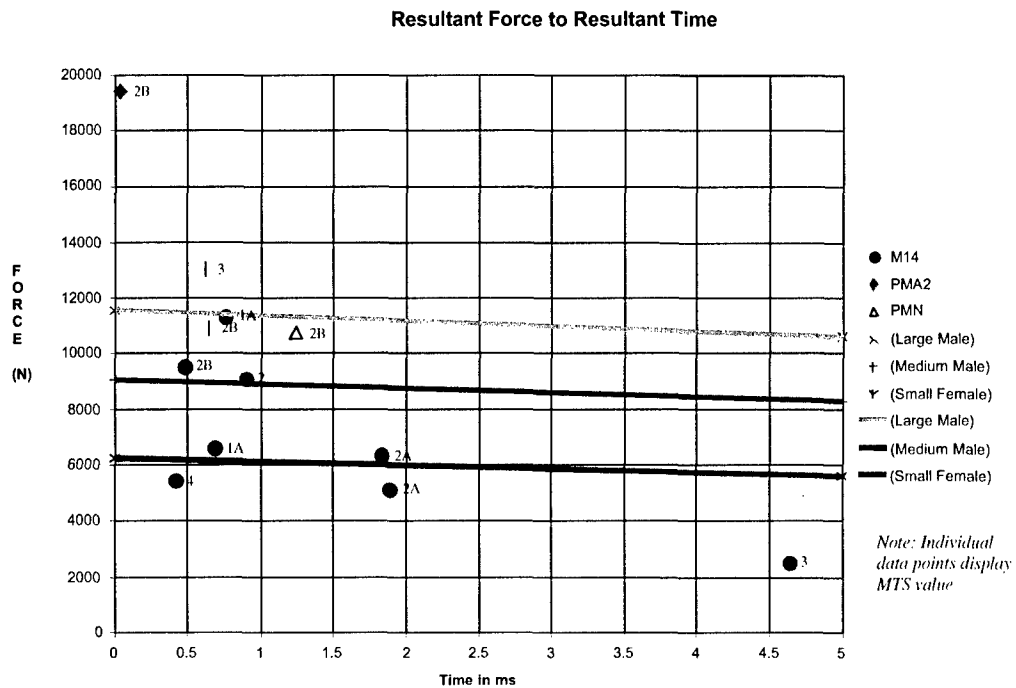
The model adopted for cadaver instrumentation was based on those used in automotive crash testing (Walters, 1976), with a combination of a load cell and strain gauges. Clinical experience dictated that diaphyseal long bone fracture was unlikely to be seen in the axial-loading of landmine injury. However, it was hoped that the instrumentation data would lead to an objective estimation of the quantity of blast attenuation provided by each type of footwear. The load cell data showed minimal differences with regard to peak load and loading rates for any of the footwear types or for the different types of mine. In most cases, the peak tibial load occurred in the first 2 milliseconds with a possible trend towards slower subsequent decay of the measured load with the blast attenuating footwear. Disruption of the combat boot sole with subsequent destruction of the soft and bony tissue possibly leads to a faster decay of the axially transmitted load. In contrast, the protective boots attenuate a large amount of blast energy protecting the sole of the inner boot, which remains largely intact, especially for the smaller mines, and thus acts as a force plate prolonging the transmission of this load.

Consistency of the load cell data offered a degree of quality assurance with regard to each explosive event. For example, test 21 was a "low order" mine detonation, a recognized and occasional anomaly of explosive detonation in which the some of the charge fails to initiate. This was evidenced not only by lumps of residual explosive both within and around the mine but also by the load cell data where the characteristic peak was absent. In each of the other test cases, the characteristic peak loads were noted, suggesting that no further low order detonations occurred.

In the pilot study, strain gauges were placed on the distal femur. Realizing that strain failure was not occurring in the long bones and that there were no differences between the time to peak strain or peak strain for the various types of footwear, the gauges were moved distally to distal tibia and calcaneus where bone failure occurred. It was hoped that this instrumentation would deliver "strain to failure" data for these bones. However, the instrumentation was almost uniformly disrupted by the explosive event.

When resultant peak load data is plotted against time to peak load for the various MTS scores (*Figure: 17*) there does not appear to be a correlation. Superimposed on the same figure are injury predictive curves for long bone failure in axial loading of the lower limb derived from automotive crash testing (United States Army Aeromedical Research Laboratory, 1997). MTS values denoting severe injury fell below the low risk threshold curves invalidating the use of existing automotive crash test risk curves in predicting direct contact mine injury.

Figure 17: MTS to Femur Injury Threshold Curves (Hybrid III) (Mertz, 1993)



The detonation of a blast mine is composed of several events. These begin with a single positive pulse that radiates from the source with a velocity in air approximately 1500 m/s, a negative phase, and then a mass movement of air behind the shock front with very high velocity and pressure, known as the dynamic overpressure. The measured rise time and duration of the force pulses roughly correspond to those reported for detonations of TNT.

When the shock wave encounters a solid surface, such as a boot sole, some of the energy will be absorbed and some transmitted. If the amount absorbed exceeds a critical level, the surface will fail, leading to the direct transmission of blast to the foot. In the absence of any blast-absorbing material most of the absorbed energy will be transmitted through the boot sole and into the tissues of the foot. The relative acceleration of the tissues will lead to stretching and tearing. Rapid multidirectional loading of the bones of the foot can cause fractures. As the blast wave continues to propagate, the injury spreads proximally, particularly following fascial planes, which represent the line of least resistance. If the sole of the boot is breached then there will be secondary blast injury due to fragments of soil, landmine and footwear, becoming embedded in the tissues.

For the purposes of this study, it was assumed that there was little variation in explosive profile between mines of the same type. The force generated by the detonation of an explosive is dependent on the type of explosive, weight, shape, and the density with which it is packed. Most of these parameters can be assumed the same for each mine type. There may be some variation in the explosive profile depending upon the “shelf life” and explosive storage conditions for the individual mines. Good quality control of U.S. manufactured mines can be assumed; however, the same cannot necessarily be said for foreign mines.

In those cases where the hind foot and ankle were not completely disrupted, we detected a distinct pattern of anatomical injury. Typically, there would be a longitudinal skin laceration over the plantar surface of the foot,

often associated with tangential lacerations over the medial side of the ankle. The incision for strain gauge instrumentation was performed on the lateral side of the hind foot and ankle. This wound was, in many cases, extended distally along the lateral border of the foot by the mine injury. On deep dissection, a characteristic pattern of bony failure was noted. This would typically involve a comminuted calcaneal fracture, fracture of the dome of the talus extending from anteromedial to posterolateral, and a pilon fracture of the ankle. Associated fractures were to the navicular and talar neck.

In order to be effective in preventing injury, mine protective footwear has to reduce the amount of energy transferred to the tissues of the foot. Design philosophy for this centers around four strategies. The first is *standoff*, where the bearing platform is distanced from the explosive. As blast energy transmission will attenuate in air according to the cube root of the propagation distance, so the amount of energy impacting the sole of the foot will be reduced. Where standoff is achieved only through increased sole thickness, there is still direct contact; energy transfer and energy transmission will not be reduced as effectively. The second involves blast *attenuation*, utilizing materials in the construction of the sole whose physical properties are altered during the explosive event. This allows the blast energy transmission to be reduced through the work needed to alter the footwear's physical properties. The third strategy involves blast *deflection*, where an angled plate or the angled design of the sole is used to redirect the blast wave away from the foot. However, in real world application, foot location or plate orientation can vary, resulting in a plate orientation that increases energy transmission. For example, a 45°-midline angle that possibly deflects blast energy for a centerline mine detonation could potentially become a flat plate due to a side of the boot detonation. The fourth method is *off-axis* detonation, where the mine is detonated at some distance out away from the foot, which allows the bulk of the blast energy to bypass the limb.

The Wellco over boot appeared to mitigate the effects of M-14 landmine injury. This boot utilizes both standoff and blast attenuation as design factors. Standoff is achieved by virtue of a combination of the height of the over boot and inner boot soles, which increases the distance between the point of mine detonation and the sole of the foot. The aluminum honeycomb attenuator in combination with the Kevlar Aramid insole provides blast attenuation. A V-shaped deflective device positioned in the heel and instep areas is also utilized for blast deflection. The boot upper is also lined with two layers of Kevlar. On inspection of the fast frame photography it appears that the boot acts by a decoupling mechanism, by "peeling off" the inner boot as the explosive event progresses. There may be a slight trend towards improved MTS scores (from 3 to 2B) when the over boot is used in combination with another blast protective boot rather than the standard combat boot for the larger mines. Furthermore, gross inspection of the inner boot (appendix D) would suggest a lesser degree of disruption of blast protective inner boots when compared to the standard combat boot.

Conclusions

The results of our study suggest some improvement in MTS with the use of the over boot when confronted with the smallest mine, the M-14, containing only 28 g of explosive. (Figure 3). The level of potential improvement is approximately one point on the MTS, converting a “3” injury (transtibial amputation and possibly transfemoral) to an injury defined by a mean MTS of between 1B and 2, a transtibial amputation but with the possibility of limb salvage. Although the LEAP study tested different types of footwear, sufficient tests to reach meaningful conclusions were conducted only for the over boots in comparison to the standard combat boot. Limited testing was done on other types of anti-mine protective footwear. These included the blast protective combat boot, the BFR boot, and the Med-Eng boot.

The Wellco® Blast Boot and the BFR boot, based on only one and two tests, respectively, both resulted in a severe spectrum of injury (2B's and 3's) when subjected to the smallest test mine, the M-14 (figure 3). Given limited experimental resources and the severity of injury produced with even the smallest test mine, no further tests using these boots *alone* were conducted. There remains the potential that some demonstrable benefit could be seen by using these boots, with more extensive testing. Based on the limited tests conducted, the study team concluded that these boots were unlikely to offer any greatly increased protection when compared to the standard combat boot.

The Med-Eng boot utilizes differing design principles than the other footwear tested and was the boot that showed the most promise against medium and larger size mines. The boot was tested in two configurations; two tests (in the manner for which designed) with the PMN mine under the pod and one test with the PMA-2 mine on the center of the boot midline. The PMN tests both resulted in closed injury with MTS scores of 1 and 2A, respectively, and the PMA-2 test in an injury of MTS 2A (Figures, 4 & 5).

Until recently, sandals have been a common form of footwear used by deminers around the world. There have even been largely anecdotal reports suggesting that by early failure of the footwear and lower extremity with minimal secondary wound fragment damage; this may produce a less severe spectrum of injury than more substantial footwear (Traverso, 1981). During the Vietnam conflict, there was a common belief that wearing footwear and stepping on a landmine would result in a more severe injury compared to the bare foot. For comparison two tests were performed, using improvised sandals. These tests resulted in an MTS of 2B for an M-14 mine and an MTS of 4 for a PMN mine. From these tests, it appears that the spectrum of injury when wearing sandals is approximately equal to that of the combat boot (Figures, 3 & 5).

Several tests with over boots produced closed injuries (MTS 1 or 2), however even the closed injuries all feature various degrees of severe hind foot and ankle injury with any combination of calcaneal, talar, or tibial pilon fractures. While a closed injury avoids the gross contamination and potential septic sequelae of a standard mine injury, the eventual functional outcome of such severe hind foot bony disruption may be no better than a transtibial amputation. The fact that the MTS does not address the eventual functional outcome of these closed injuries represents a weakness in the scoring system.

In countries experiencing landmine casualties, comparison of functional outcomes is dependent on local factors beyond the mere extent of the injury. Medical supplies and the availability of open reduction and internal

fixation resources for the hind foot fractures and prosthetic provision for the amputees will determine the treatment options in third-world countries. While no specific reference exists regarding the likely outcome of these closed, severe, mid foot, and/or hind foot fractures, it is reasonable to conclude that overall function is likely to be poor. A stiff, painless ankle and foot may act as a biologic prosthesis, however limbs with severe pain may require an ankle and/or subtalar arthrodesis. The ability to perform open reduction and internal fixation of these hind foot fractures is rarely available in a third-world setting.

With reference to the ICRC data and publications relating to mine injuries, it is possible to draw conclusions with regard to the nature of injuries seen in the LEAP study test cases. In ICRC hospitals mortality from landmine injury is 3.5% (Eshaya-Chauvin, 1992). However, it is well recognized that this is an underestimate of the true overall mortality, as many cases will die at the point of wounding or during the prolonged evacuation times necessary to reach a surgical facility. In approximately 30% of cases, this evacuation time is over 24 hours (Coupland, 1991).

Similar to other war wounds, landmine injuries are grossly contaminated with mud, vegetation, mine casing, and footwear debris. Initial surgery with wound debridement and excision is designed to reduce the burden of this contamination and when combined with postoperative antibiotics to prevent sepsis. Despite these measures, in ICRC hospitals postoperative fever is seen in around 50% of amputees (mostly mine victims) once malaria has been excluded (Korver, 1993). The conversion of an open injury with contamination to a contained or even a closed injury should decrease the risk of infection and allow the extent of surgical resection to remain a transtibial amputation. The LEAP study demonstrated that use of the over boot against the smaller AP mines may result in closed injury or in a contained injury, without the gross contamination typically associated with landmines. As such, the burden of septic complications may be reduced.

Recommendations

- ◆ The Med-Eng boot demonstrated potential improvement in protection against the larger mines and additional testing of this type of footwear is warranted.
- ◆ Over the period of this study, several nations (United Kingdom, Canada, Russia) have developed mine protective footwear. Each employs various types of protective materials, standoff distance, and trigger mechanisms. An evaluation of this new footwear using the testing methodology developed in this study is recommended.
- ◆ Cadaveric testing is the most biofidelic model to accurately define the level of potential protection of any footwear. This method gives a reproducible, cost-effective test method for AP mine injury assessment and should be utilized in future protocols.
- ◆ Due to the possibility of variability in live mine detonation, a mine surrogate utilizing cast and pressed TNT (based on threat mine prevalence) will give the best repeatable blast profile.
- ◆ Our model evaluated the footwear only without the Kevlar pants. Additional testing is required to determine if there is any benefit or detriment to the lower extremity with the use of the P3I suit.
- ◆ The P3I countermine suit requires further testing to define the limitations of the equipment and to evaluate its ability to protect against Type II and III landmine injuries.
- ◆ The effects of secondary missiles from the metal attenuators or other boot materials warrant evaluation with further testing on whole body cadavers.
- ◆ No further testing is necessary for the BB and BFR boots alone.

References

- Banks E., (1997). Anti-personnel landmines: Recognizing and disarming. London: Brassey's.
- Bowyer, G. W., Cooper, G. J., & Rice, P. (1996). Small fragment wounds: Biophysics and pathophysiology. The Journal of Trauma, 40 (3), S159-S164.
- Bowyer, G.W., Stewart, M. P. M., & Ryan, J. M., (1993). Gulf war wounds: application of the Red Cross wound classification. Injury, 24, 597-604.
- Cameron, M. A., Lawson R. J., & Tomlin, B.W. (Eds.) (1998). To walk without fear: The global movement to ban landmines. Toronto: Oxford University Press.
- Chaloner, E. J., & Mannion, S. J., (1996). Antipersonnel mines: the global epidemic. Annals of the Royal College of Surgeons of England, 78, 1-4.
- Coupland, R. M., (1993). Management Principles. In: War wounds of limbs: surgical management. Oxford: Butterworth-Heinemann.
- Coupland, R. M., (1992). The Red Cross classification of war wounds: The E.X.C.F.V.M. scoring system. World Journal of Surgery, 16, 910-917.
- Coupland, R. M., & Korver, A. J. H., (1991). Injuries from antipersonnel mines: the experience of the International Committee of the Red Cross. British Medical Journal, 303, 1509-1512.
- Croll M., (1998). The history of landmines. Barnsley, Great Britain: Pen & Sword Publications.
- Eshaya-Chauvin, B., & Coupland, R. M., (1992). Transfusion requirements for the management of war injured: the experience of the International Committee of the Red Cross. British Journal of Anesthesia, 68, 221-223.
- Garachon, A., (1993). ICRC rehabilitation programs on behalf of war disabled. In: Report of the Symposium on Anti-personnel mines. Montreux, Geneva: International Community of the Red Cross.
- Gray, B., Henningsen, M., Leeson, K., Maddocks, I., Poy, P. P., Teague, D., & Von der Borch, A., (1997). The landmine epidemic. In Landmines, a global health crisis: International Physicians for the Prevention of Nuclear War report number 2 (pp. 1-7). Cambridge: USA, International Physicians for the Prevention of Nuclear War.
- Gregory, R. T., Gould, R. J., Pecllet, M., Wagner, J. S., Gilbert, D. A., Wheeler, J. R., Synder, S. O., Gayle, R. G., & Schwab, W., (1985). The mangled extremity syndrome (MES): A severity grading system for multisystem injury of the extremity. Journal of Trauma, Injury, Infection and Critical Care, 25 (12), 1147-1150.
- International Humanitarian Law. (Version 5) [CD-ROM]. (1998). Geneva: International Committee of the Red Cross Publications [Producer and Distributor].
- Johansen, K., Daines, M., Howey, T., Helfet, D., & Hansan, Jr., S., (1990). Objective criteria accurately predict amputation following lower extremity trauma. Journal of Trauma, 30(5), 568-573.
- King, K. F., (1969). Orthopaedic aspects of war wounds in South Vietnam. Journal of Bone and Joint Surgery, 51(B), 112-117.
- Korver, A. J. H., (1993). Injuries of the lower limbs caused by antipersonnel landmines: the experience of the International Committee of the Red Cross. Injury, 24, 607-609.

Landmine casualty data report: Deminer injuries. (2000, February). United States Department of Defense, Office of the Assistant Secretary of Defense for Special Operations / Low Intensity Conflict. Washington, DC:

Landmine Survivors Network. (1998, July). Surviving the scourge of landmines. (Conference report). Amman, Jordan:

McNamara, M. G., Heckman, J. D., & Corley, F. G., (1994). Severe open fractures of the lower extremity: a retrospective evaluation of the Mangled Extremity Severity Score. Journal of Orthopaedic Trauma, 8 (2), 81-87.

Taylor, J. H. B., (1999, September). Blast mines study, (Available from CBD Porton Down Biomedical Sciences Division, England)

The Technical Cooperation Program. (1998). Protection of soft-skinned vehicle occupants from landmine effects. (Technical Report, Technical Panel W-1, Key Technical Activity 1-29). Quebec, Canada: Defence Research Establishment Valcartier.

Time-Life Books. (1998). The south's infernal machines. In Time-Life Books' Echoes of glory: Arms & equipment of the confederacy. (pp. 302-303). USA: Time Life Inc.

Traverso L. W., & Fleming, M. C., (1981). Combat casualties in northern Thailand: Emphasis on land mine injuries and levels of amputation. Military Medicine, 146, 682-685.

United States Army Aeromedical Research Laboratory (1997, July). Mine blast acceleration injury assessment: Methods, criteria and software. (USAARL Report No 97-28). Fort Rucker, AL: Alem, N. M.

United States Army Yuma Proving Ground (1999, September). Final test report for the developmental test (DT) /operational test (OT) of the body armor set, individual countermine preplanned product development (Basic P3I). (YPG Document No. 99-015). Yuma Proving Ground Tropic Test Center, Panama: Tijerino, D., & Hay, L.

Walters, R. L., Campbell, J., & Perry, J. (1987). Energy cost of three-point crutch ambulation in fracture patients. Journal of Orthopaedic Trauma, 1 (2), 170-173.

Walters, R. L., Perry, J., Antonelli, E. E., & Hislop, H., (1976). Energy cost of walking of amputees: The influence of level of amputation. Journal of Bone and Joint Surgery, 58-A, 42-46.

Appendix A

Detailed Medical Evaluations

This page intentionally left blank

Shot #	ID #	Age	Weight Lbs.	Sex	Cadaver ID #
01	99103-01- ALAA	96	144.4	M	37732

Post-test boot damage assessment: (Single-boot test) Boot sustained sufficient damage to permit foreign body contamination.

Post-test radiographic findings: (Left leg)

Pelvis: Normal.

Femur: Displaced supracondylar femur fracture without apparent intercondylar extension.

Knee: Supracondylar fracture with intercondylar extension (non-displaced) lateral condyle (sagittal)

Leg: Minimal distal tibia fracture above test fixture. Minimally displaced pilon

Ankle: Pilon displaced 3-4 mm. Question central impaction?

Foot: 5th metatarsal base fracture. Comminuted cuboid fracture. Calcaneus and talus crushed. Navicular tuberosity fracture.

Post-test clinical dissection findings:

Pelvis: No fracture

Femur: There is instability in the supracondylar area and the dissection reveals a supracondylar femur fracture with intercondylar extension, with no evidence of contamination. The intercondylar and supracondylar fractures do not demonstrate any significant comminution. The capsule is not violated, and there is no apparent communication of this wound with the outside.

Knee: The ligaments of the knee are intact, as is the plateau.

Tibia: The tibia demonstrates a pilon fracture with anterior impaction, and the posterior half of the plafond is intact. The fibula is intact with periosteal stripping proceeding approximately 2 to 3 cm proximal to the distal tip. There is a fracture above the proximal test fixture on the tibia, again with gross contamination.

Foot/ankle: There are some small fragments of the calcaneus remaining on the Achilles tendon. There is a pilon fracture with impaction, however the posterior half of the plafond is intact as is fibula. The posterior aspect of the lateral malleolus is fractured and not present. There are some metatarsal fractures. The cuboid is comminuted and unidentifiable. The medial and middle cuneiform has fractures that are grossly contaminated but minimally displaced, and the lateral cuneiform is highly comminuted and hardly recognizable. The syndesmosis ligament is disrupted with fragmentation of the talus. The calcaneus and the navicular are not identifiable. The pilon fracture demonstrates periosteal stripping as stated previously.

Soft tissue: The soft tissue demonstrates a near complete traumatic amputation at the ankle level, with a 7 to 8 cm dorsal skin bridge. There is no remnant of the plantar fascia from the mid-foot proceeding posteriorly. There is gross contamination around the fascia and muscle layers of the foot. In the leg there is gross contamination particularly at the medial knee. Note that the pant leg was not disrupted, but there is an area 12 cm x 12 cm of the medial aspect of the knee that has significant blast residue, though the muscle does not appear to have any gross disruption in the leg. Dissection of the left limb demonstrates that the plantar fascia was excised and draped over the foot. There is no distal extension. Proceeding proximally, there is no other proximal muscle disruption, however, at the distal tibia fracture proximally, there is gross contamination in the fracture site with a significant amount of blast powder. There is no apparent tracking proximal to this level on close clinical evaluation.

Assessment: Traumatic amputation of the foot with gross contamination to the level of the knee.

Treatment: Above the knee amputation (AKA).

MTS: 4

Shot #	ID#	Age	Weight Lbs.	Sex	Cadaver ID #
02	99103-02- BRAA	96	144.4	M	37732

Post-test boot damage assessment: (Single-boot test) Boot sustained sufficient damage to permit foreign body contamination.

Post-test radiographic findings: (Right leg)

Pelvis: Normal.

Femur: Normal.

Knee: Normal.

Leg: Traumatic long BKA with embedded foreign material, lateral mid leg.

Ankle: No foot.

Foot: N/A

Post-test clinical dissection findings:

Pelvis: No Fractures.

Femur: No Fractures.

Knee: No Fractures.

Tibia: No proximal bony injury is noted; the interosseous ligament is disrupted up to the proximal third.

Foot/ankle: Complete traumatic amputation at the distal tib/fib level with severe contamination of blast residue in the soft tissues and bone ends.

Soft tissue: Complete traumatic amputation at the distal tib/fib level with severe contamination of blast residue in the soft tissues and bone ends. There is significant periosteal stripping of the tibia extending to the mid-tibial level where the strain gauges were placed, with no stripping apparent proximal to the strain gauges. All soft tissues have very severe contamination of grit and blast residue. There is no apparent disruption of the fascial layers or contamination, above the mid-calf on the medial side. Likewise, laterally there is no contamination in the muscle layers. The interosseous membrane appears to be disrupted up to the proximal one-third, but there is no gross contamination in that area. The deep superficial posterior compartments are also free of any gross contamination.

Assessment: Traumatic amputation of the distal lower extremity; highly contaminated to the level of the proximal third of the tibia.

Treatment: Below the knee amputation (BKA) with delayed primary closure with probable revision to AKA depending on soft-tissue involvement.

MTS: 3

Shot #	ID #	Age	Weight Lbs.	Sex	Cadaver ID #
03	99103-03- ALBC	80	202.2	M	37887

Post-test boot damage assessment: (Two-boot test) Inner boot did not sustain sufficient damage to permit foreign body contamination.

Post-test radiographic findings: (Left leg)

Pelvis: Normal.

Femur: Normal.

Knee: Normal.

Leg: Comminuted pilon fracture.

Ankle: Severe pilon fracture with anterior bone loss.

Foot: Severely comminuted pilon and mildly comminuted calcaneus fracture. Talar neck fracture. 4th and 5th metatarsal fracture.

Post-test clinical dissection findings:

Pelvis: No fractures

Femur: No fractures

Knee: No fractures

Tibia: No fractures are noted at the tibia.

Foot/ankle: Dissection of the foot reveals a highly comminuted pilon fracture. There is a coronal fracture through the talus, minimally displaced. The calcaneus is severely comminuted. The talonavicular joint is intact; calcaneal cuboid severely comminuted; cuneiforms are fractured; fibula is severely comminuted.

Soft Tissue: There is a superficial break medially, and extension of the lateral strain gauge incision with some mild blast staining. Higher on the leg, there is significant powder staining at the incision site that extends up to the tibial tubercle. The muscle is generally without lacerations.

Assessment: Open, highly comminuted, and mangled lower extremity

Treatment: BKA with delayed primary closure

MTS: 2A

Shot #	ID #	Age	Weight Lbs.	Sex	Cadaver ID #
04	99103-04- ARAC	80	202.2	M	37887

Post-test boot damage assessment: (Two-boot test) Inner boot did not sustain sufficient damage to permit foreign body contamination.

Post-test radiographic findings: (Right leg)

Pelvis: Normal.

Femur: Normal (right hip degenerative joint disease).

Knee: Normal.

Leg: Segmental fibula. Distal instrumentation fixture fractured off.

Ankle: Normal.

Foot: Calcaneus fracture. Chopart's dislocation. 4th and 5th metatarsal neck fractures. 3rd, 4th, and 5th metatarsal base fractures. Cuboid and talus intact.

Post-test clinical dissection findings:

Pelvis: No fractures.

Femur: No fractures.

Knee: No fractures.

Tibia: No gross fractures of the lower leg are noted.

Foot/ankle: The calcaneus is grossly comminuted. There are no fractures of the talus or cuboid, and the tibiotalar joint is grossly normal. The talonavicular joint is dislocated.

Soft tissue: There is a small, 3 cm transverse laceration medially without gross contamination. There is extension of the lateral surgical wound and vertical laceration. The neurovascular bundle is in continuity despite the medial lacerations. There is mild soiling with blast residue along the extent of the incision. The muscle is generally undamaged without gross lacerations.

Assessment: Contained, grossly comminuted fracture of the calcaneus without neurovascular involvement.

Treatment: Immobilization with supplemental care; treatment of superficial wounds.

MTS: 1A

Shot #	ID #	Age	Weight Lbs.	Sex	Cadaver ID #
05	99104-05- ALAC	94	148.2	M	37872

Post-test boot damage assessment: (Two-boot test) Inner boot did not sustain sufficient damage to permit foreign body contamination.

Post-test radiographic findings: (Left leg)

Pelvis: Normal.

Femur: Normal.

Knee: Normal.

Leg: Normal.

Ankle: Medial malleolus fracture.

Foot: 3rd, 4th and 5th metatarsal neck fractures. 3rd, 4th, and 5th metatarsal base fracture. Dislocated tibiotalar joint. Comminuted calcaneus fracture (tuberosity spared). Possible fracture of the talus (body or posterior process).

Post-test clinical dissection findings:

Pelvis: No fracture.

Femur: No fracture.

Knee: No fracture.

Tibia: The proximal tibia is fractured. No major muscular injury or contamination is noted.

Foot/ankle: Medial dissection reveals that the talus is displaced laterally, with a fracture on the anterior edge of the mortise joint. The tendons remain intact. The navicular is fractured and displaced dorsally. No gross contamination is noted, and the laceration that was present at the time of injury is superficial and does not appear to penetrate deeply. The talus is comminuted posteriorly with a coronal split, but the neck and the head are grossly spared. The talonavicular joint is disrupted from the plantar aspect, but intact dorsally. The calcaneus and the cuboid are grossly comminuted, but the tendons are spared. There is no evidence of contamination in the forefoot from the blast.

Soft tissue: The syndesmotomic ligaments are intact. The fibula is also intact and stable. A vertical laceration 4 cm in length is present, distal to the medial malleolus. A number of superficial abrasions of the dorsal aspect of the foot are noted. A 6 cm laceration, just through the skin on the lateral aspect of the foot with no gross contamination is present. There is a lateral, jagged laceration, approximately 15 cm in length, from the mid-foot in the midline of the plantar aspect, which proceeds laterally & dorsally to end at the lateral malleolus.

Assessment: Open, contained mangled foot with proximal tibia fracture.

Treatment: BKA with delayed primary closure, open reduction with internal fixation of the tibia fracture.

MTS: 2A

Shot #	ID #	Age	Weight Lbs.	Sex	Cadaver ID #
06	99104-06- ARBC	94	148.2	M	37872

Post-test boot damage assessment: (Two-boot test) Inner boot did not sustain sufficient damage to permit foreign body contamination.

Post-test radiographic findings: (Right leg)

Pelvis: Normal.

Femur: Normal.

Knee: Normal.

Leg: Normal.

Ankle: Non-displaced Weber A fibula fracture; medial malleolus fracture.

Foot: 3rd, 4th, and 5th metatarsal neck fracture; 5th metatarsal base fracture; Cuboidal fracture; Talar neck fracture with dislocation.

Post-test clinical dissection findings:

Pelvis: No fracture.

Femur: No fracture.

Knee: No fracture.

Tibia: Evaluation of the leg reveals no fracture or contamination proximally. No additional contamination or muscle injury is noted.

Foot/ankle: The calcaneus and cuboid are severely comminuted. The talus is displaced, and embedded in the plantar fascia with a neck fracture. The plantar capsule of the talonavicular joint is disrupted, but the joint is not dislocated. No contamination is apparent. Laterally, the tendons are spared and the pilon area shows a fracture anteriorly, but otherwise the pilon area and the syndesmosis are generally intact. The tuberosity of the calcaneus is in one large piece with some comminution.

Soft Tissue: Gross examination of the right leg reveals superficial abrasions on the dorsum of the forefoot and right toe, lateral incision is extended proximally. Examination of the leg shows slight evidence of blast dust in the muscle, but otherwise no lacerations are present.

Assessment: Highly comminuted mangled foot, with no evidence of contamination above the ankle.

Treatment: BKA with delayed primary closure.

MTS: 2

Shot #	ID #	Age	Weight Lbs.	Sex	Radiographic ID #
07	99-104-07- ALAC	81	144.4	M	37878

Post-test boot damage assessment: (Two-boot test) Inner boot did not sustain sufficient damage to permit foreign body contamination.

Post-test radiographic findings: (Left leg)

Pelvis: Normal.

Femur: Normal.

Knee: Bicondylar – Schatzker V plateau fracture, non-displaced.

Leg: Bicondylar plateau fracture, non-displaced.

Ankle: Weber B fibular fracture. Pilon fracture of the tibia with anterior joint depression

Foot: 5th metatarsal fracture, neck and shaft. 5th metatarsal base fracture. Comminuted calcaneus fracture. Posterior talar process fracture.

Post-test clinical dissection findings:

Pelvis: No fracture.

Femur: No fracture.

Knee: There is a fracture at the medial and lateral plateau, with no obvious propagation of the wound from the instrumentation up into this fracture segment. The fascia is completely intact up at this level. The articular surface of the plateau is intact and the articular cartilage does not appear violated, but subchondral bone is fractured on the medial side. Laterally, the articular surface appears intact, but there is obvious fracturing of the subchondral bone. The fracture extends across the metaphysis.

Tibia: There is a fracture of the anterior plafond articular surface.

Foot /ankle: Examination reveals the tendons are intact. The tibiotalar joint is preserved, as is the talonavicular joint. There is a fracture of the anterior plafond articular surface. The talus demonstrates a fracture of the lateral wall and the posterior process. The tuberosity of the navicular is fractured. The lateral aspect of the foot demonstrates fractures of the lateral malleolus and of the lateral border of the tibia adjacent fibula syndesmosis. The lateral body of the talus is highly comminuted. The calcaneus is highly comminuted, with no fragment being any larger than about 1 cm in size. The cuboid has a small fracture of the lateral wall but is otherwise intact.

Soft tissue: There is some superficial abrasion on the forefoot dorsally over the 4th and 5th metatarsals and over the great and second toe. Two small vertical lacerations (3 cm each) are present on the medial aspect, and a 1 cm laceration posterior medial. Powder staining has occurred at the incision site, but otherwise there is no gross contamination. The leg shows powder staining circumferentially, but is otherwise intact. Other than the powder staining, there is no gross muscular injury.

Assessment: Open contained mangled foot with tibial plateau fracture, with no articular surface involvement.

Treatment: BKA with delayed primary closure.

MTS: 2A

Shot #	ID #	Age	Weight Lbs.	Sex	Cadaver ID #
08	99-104-08- ARBC	81	144.4	M	37878

Post-test boot damage assessment: (Two-boot test) Inner boot did not sustain sufficient damage to permit foreign body contamination.

Post-test radiographic findings: (Right leg)

Pelvis: Total Hip Replacement.

Femur: Normal.

Knee: Minimally displaced depression fracture of the lateral plateau. Transverse metaphyseal fracture.

Leg: Lateral plateau and pilon fracture.

Ankle: Anterior plafond fracture with loss. Medial malleolus fracture with minimal displacement. Fibula fracture with minimal displacement.

Foot: Comminuted calcaneus fracture. Sagittal navicular fracture with minimum displacement. Talar head fracture laterally. 5th metatarsal shaft fracture laterally. Posterior process of the talus is fractured.

Post-test clinical dissection findings:

Pelvis: No fractures.

Femur: No fractures.

Knee: There is destruction of the articular surface of the plafond from the shaft of the tibia, and a metaphyseal transverse fracture.

Tibia: The pilon fracture a significant portion of the plafond is spared anteriorly in triangular shape 3 x 2 x 1 ½ cm.

Foot/ankle: Examination reveals a highly comminuted medial pilon fracture with no fragment being larger than one cm. The medial malleolus is missing. The calcaneus is highly comminuted, with no gross contamination but the tendons remain intact. A pilon fracture is noted, and the distal fibula is also fractured. The talus is contained under the plafond with a lateral process fracture and neck fracture, which are minimally displaced. The posterior process of the talus is also fractured and displaced. The cuboid is fractured and there is clinically a fracture of the plateau. There is no obvious contamination extending up into the plateau fracture site.

Soft tissue: Superficial abrasion of the dorsum is present over the PIP joints of the 2nd and 3rd toes, and over the distal 2nd and 3rd metatarsals. There is a 2 cm medial laceration vertically through the fascia, but no gross contamination. Laterally, some distal extension of the incision has occurred but lacks any significant contamination. The leg muscle is without any evidence of gross disruption. Minimal powder staining of the skin and fascia is observed.

Assessment: Highly comminuted open mangled extremity with minimal contamination.

Treatment: BKA with delayed primary closure.

MTS: 2A

Shot #	ID #	Age	Weight Lbs.	Sex	Cadaver ID #
09	99105-09- CLBC	83	137.4	M	37738

Post-test boot damage assessment: (Two-boot test) Inner boot sustained sufficient damage to permit foreign body contamination.

Post-test radiographic findings: (Left leg)

Pelvis: Old compression fracture of L5.

Femur: Normal.

Knee: Proximal fibula fracture.

Leg: Segmental fibula fracture.

Ankle: Distal fibula fracture. Medial malleolus fractured. Pilon variant fracture.

Foot: Calcaneus missing. Talar body fractured. Navicular fractured. Comminuted Cuboid fracture. Medial and middle Cuneiform fractured. 2nd metatarsal base fracture (Lisfranc). 3rd, 4th and 5th metatarsal neck fracture.

Post-test clinical dissection findings:

Pelvis: No fractures.

Femur: No Fractures.

Knee: No Fractures, ligaments intact.

Tibia: Comminuted pilon fracture.

Foot/ankle: There is a comminuted pilon fracture with involvement of the anterior, medial, and posterior aspects. There is a talar body fracture, but the neck is intact. Most of the calcaneus is missing, with portions of the lateral wall and the calcaneal cuboid joint remaining attached to the soft tissue. There are fractures of all the cuneiforms on the left side, as well as navicular and cuboid fractures. The Chopart's and LisFranc's joints are disrupted. There are fractures of the 3rd through the 5th metatarsals.

Soft Tissue: There is an open laceration the plantar surface from the mid one-third to the heel pad. Soft tissue stripping with contamination has occurred to the distal one-third of the tibia.

Assessment: Highly contaminated mangled extremity. Traumatic BKA.

Treatment: Open below the knee amputation with delayed primary closure.

MTS: 2B

Shot #	ID #	Age	Weight Lbs.	Sex	Cadaver ID #
10	99105-10- ALBC	83	161.4	M	37885

Post-test boot damage assessment: (Two-boot test) inner boot did not sustain sufficient damage to permit foreign body contamination.

Post-test radiographic findings: (Left leg)

Pelvis: Normal.

Femur: Normal.

Knee: Normal.

Leg: Normal.

Ankle: Normal.

Foot: Comminuted calcaneus fracture, with joint depression. Fracture of the cuboid.

Post-test clinical dissection findings:

Pelvis: No fractures.

Femur: No fractures.

Knee: No fractures.

Tibia: The proximal tibia appears to be intact. The metal implants from the load cell are intact and there are no obvious fractures of the medial and lateral malleolus.

Foot/ankle: There is a comminuted joint depression calcaneus fracture. The talus has comminuted fractures of the posterior portion with the talar neck remaining intact. The mid foot, calcaneal cuboid joint, and Chopart's joint appear to be intact. The talus (viewed from the dorsal surface) appears to be intact.

Soft tissue: There are no obvious open areas or lacerations.

Assessment: Closed comminuted calcaneus fracture, with fracture of the posterior one-third of the talus body.

Treatment: Possible open reduction internal fixation with possible subtalar fusion.

MTS: 1

Shot #	ID #	Age	Weight Lbs.	Sex	Cadaver ID #
11	99105-11- BRAC	83	137.4	M	37738

Post-test boot damage assessment: (Two-boot test) Inner boot sustained sufficient damage to permit foreign contamination.

Post-test radiographic findings: (Right leg)

Pelvis: Old compression fracture of L5.

Femur: Possible impaction fracture of the distal femoral condyle.

Knee: Air pocket in the superior aspect of the patellofemoral joint.

Leg: Lateral plateau compression fracture (Schatzker I) of the tibia. Distal tibia fracture at the level of the test fixture. Proximal fibula fracture.

Ankle: Ankle disarticulation.

Foot: Calcaneus is missing. Talar body fractured. Navicular fractured. Cuboid missing. Lateral and middle cuneiform fractured. Base of 2nd metatarsal fractured (Lisfranc). Comminuted 2nd proximal phalanx shaft fracture. Segmental 3rd and 4th metatarsal fracture. 5th metatarsal neck fracture.

Post-test clinical dissection findings:

Pelvis: No Fractures.

Femur: No Fractures.

Knee: No Fractures. Ligaments intact.

Tibia: No Fracture.

Foot/ankle: There is a talar body fracture with loss of the posterior lateral aspect. The majority of the calcaneus is missing to include the body and tuberosity. The lateral wall remains attached to the soft tissue. There is a navicular fracture, a cuboid fracture, and the Chopart's and LisFranc's joints are disrupted. All cuneiforms are fractured. There are metatarsal fractures of the 2nd through 5th. The 2nd toe IP joint is open with a comminuted fracture.

Soft Tissue: A dorsal laceration appears over the foot plantar surface. There is soft tissue loss from the mid-portion of the foot, with disruption of the plantar heel pad. The soft tissue has been stripped to the mid one-half of the tibia. There is blast contamination and debris present.

Assessment: Highly contaminated mangled lower extremity with tissue disruption to the mid-tibia. (Traumatic BKA)

Treatment: Open BKA with delayed closure.

MTS: 2B

Shot #	ID #	Age	Weight Lbs.	Sex	Cadaver ID #
12	99105-12- ARAC	83	161.4	M	37885

Post-test boot damage assessment: (Two-boot test) Inner boot did not sustain sufficient damage to permit foreign body contamination.

Post-test radiographic findings: (Right leg)

Pelvis: Normal.

Femur: Normal.

Knee: Normal.

Leg: Normal.

Ankle: Normal.

Foot: Disruption of talonavicular joint (Chopart's) Calcaneus fracture - comminuted joint depression, missing some anterior process. Navicular fractured dorsally.

Post-test clinical dissection findings:

Pelvis: No fractures.

Femur: The right lower extremity has retained hardware from the implant.

Knee: There does not appear to be any fracture of the femur or proximal tibia region.

Tibia: There are no obvious fractures of the proximal tibia or distal tibia to include the medial and lateral malleolus. There are no obvious fractures of the ankle, medial malleolus, or lateral malleolus. There are no apparent fractures of the tibial shaft. Foot /ankle: Examination of the fractures reveals a comminuted joint depression calcaneus fracture that is contained. The talus is intact, and the calcaneal cuboid joint and mid-foot appear to be intact.

Soft tissue: There is a 1cm open injury on the plantar aspect anterior to the heel pad. All of the tendons are intact.

Neurovascular bundle: The neurovascular bundle on the medial side appears to be intact with little or no damage.

Assessment: Grade I open comminuted calcaneus fracture.

Treatment: Open reduction internal fixation based upon the soft tissue.

MTS: 1A

Shot #	ID #	Age	Weight Lbs.	Sex	Cadaver ID #
13	99109-13- CLAC	61	138.4	M	38252

Post-test boot damage assessment: (Two-boot test) Inner boot sustained sufficient damage to permit foreign body contamination.

Post-test radiographic findings: (Left leg)

Pelvis: Normal.

Femur: Normal. Amputated in the field for testing.

Knee: Tibial eminence fracture.

Leg: Displaced proximal fibula fracture.

Ankle: Destroyed, hard tissue missing to the level of the proximal test fixture.

Foot: 2nd and 3rd metatarsal neck fracture. 5th metatarsal shaft fracture. Comminuted 4th and 5th metatarsal base fracture. Severely comminuted cuboid fracture. Lateral and middle cuneiform fractures. Lisfranc fracture. Navicular fracture. Talar body fractured. Calcaneus missing.

Post-test clinical dissection findings:

Pelvis: No fractures.

Femur: This leg was amputated in the field to prevent contralateral damage. There are no fractures of the proximal femur, femoral shaft, or distal femur.

Knee: The knee and ligaments are intact.

Tibia: There are no fractures of the proximal tibia. The distal one-third of the tibia is missing, and there is a highly comminuted pilon fracture with no articular surface remaining. The medial malleolus is attached to the deltoid ligament only.

Foot/ankle: There is a talar body fracture, and the cuboid is fractured. The talonavicular joint is disrupted, but the navicular is not fractured. There is disruption of Chopart's and Lisfranc's joints. The calcaneus is comminuted and missing majority of the body and tuberosity. There are fractures of the 3rd, 4th, and 5th metatarsal bases. The medial and lateral cuneiforms are fractured.

Soft Tissue: There is a large stellate laceration of the plantar aspect with a dorsal laceration. The heel pad has been stripped and there is a large soft tissue loss of the superficial posterior compartment with contamination and blast residue to the distal one-half.

Assessment: Open highly contaminated mangled extremity with bony loss of the distal one-third of the tibia.

Treatment: Open below the knee amputation with delayed closure.

MTS: 2B

Shot #	ID #	Age	Weight Lbs.	Sex	Cadaver ID #
14	99109-14- BRBC	61	138.4	M	38252

Post-test boot damage assessment: (Two-boot test) Inner boot sustained sufficient damage to permit foreign body contamination.

Post-test radiographic findings: (Right leg)

Pelvis: Normal.

Femur: Normal.

Knee: Normal.

Leg: Proximal fibula fracture. Displaced tibiofibula fracture of the proximal one-third, severely comminuted.

Ankle: Tibial plafond crushed, impaction fracture to the level of the test fixture.

Foot: Severely comminuted calcaneus fracture. Talus crushed. Superior navicular fracture. Cuboid crushed. Lisfranc's joint disrupted. All cuneiforms fractured. 2nd, 3rd, 4th, and 5th metatarsal neck fracture, proximal 2nd Phalangeal fracture.

Post-test clinical dissection findings:

Pelvis: No Fractures.

Femur: No Fractures.

Knee: No Fractures or ligament disruption.

Tibia: There is a fracture at the proximal test fixture and a fracture at the distal test fixture.

Foot/ankle: There is a highly comminuted pilon fracture with the medial malleolus attached to the deltoid ligament only. There is no articular surface remaining. There is a fracture of the distal fibula and the proximal fibula. The talus demonstrates a body fracture with plantar dislocation, however the neck remains intact. The Chopart's and Lisfranc's joints are disrupted. There is no fracture of the navicular or cuboid. There is a comminuted fracture of the calcaneus with portions of the posterior facet, tuberosity, and lateral wall remaining attached to the deltoid ligament tendoachilles. There are fractures of the 2nd, 3rd, 4th and 5th metatarsal bases.

Soft Tissue: Soft tissue has an open stellate laceration that includes the distal one-third of the heel pad, with stripping through the proximal one-third of the tibia. There are traumatic lacerations on the dorsum of the foot over the first web space and over the 4th and 5th metatarsals. There is soft tissue missing over the lateral aspect of the foot.

Assessment: Open, highly contaminated mangled lower extremity.

Treatment: Open below the knee amputation with delayed primary closure.

MTS: 2B

Shot #	ID #	Age	Weight Lbs.	Sex	Cadaver ID #
15	99109-15- CLBC	81	97.2	M	37897

Post-test boot damage assessment: (Two-boot test) Inner boot sustained sufficient damage to permit foreign body contamination.

Post-test radiographic findings: (Left leg)

Pelvis: Normal.

Femur: Normal.

Knee: Fracture of fibular head. Lateral plateau fracture.

Leg: Comminuted pilon fracture.

Ankle: Pilon fracture.

Foot: Calcaneus fracture, majority missing. Entire mid foot fractured. 4th and 5th metatarsal shaft fractures. Talus fractured with plantar dislocation. Disruption of Chopart's joint.

Post-test clinical dissection findings:

Pelvis: No obvious fractures.

Femur: No fractures.

Knee: No distal femur fracture is noted. The patella is not fractured. Examination of the ligaments reveals laxity consistent with an injury to the PCL, posterior lateral corner. There is crepitus in the proximal tibia consistent with a lateral tibia plateau fracture. Dissection of this area reveals an anterior lateral tibial plateau fracture. The ACL is intact and the PCL and posterior lateral corner are disrupted.

Tibia: There is a lateral tibia plateau fracture.

Foot/ankle: There is a fracture of pilon area with the anterior lateral one-third missing. There is a highly comminuted fracture of the calcaneus with the majority of the tuberosity and body missing. The talus is completely dislocated plantarly. There is a fracture of the navicular and the cuboid is crushed. The Chopart's and Lisfranc's joints are disrupted. There are fractures of the cuneiforms, and fractures of the 1st through 5th metatarsal bases.

Soft Tissue: There is an open stellate laceration over the plantar aspect of the foot from the mid one-third with avulsion of the heel pad. There are also open lacerations on the dorsum of the foot. The soft tissue has been stripped to the distal one-third of the tibia and the gastrocnemius is highly contaminated.

Assessment: Left knee dislocation with lateral plateau fractures which could result in possible arterial injury. Open highly contaminated mangled lower extremity.

Treatment: High below the knee amputation, but more than likely above the knee amputation (AKA).

MTS: 3

Shot #	ID #	Age	Weight Lbs.	Sex	Cadaver ID #
16	99109-16- CRBC	81	97.2	M	37897

Post-test boot damage assessment: (Two-boot test) Inner boot sustained sufficient damage to permit foreign body contamination.

Post-test radiographic findings: (Right leg)

Pelvis: Normal.

Femur: Normal.

Knee: Proximal fibula fracture, segmental.

Leg: Tibial fracture at proximal test fixture.

Ankle: Severe pilon fracture.

Foot: Calcaneus fracture, majority missing. Talus fractured with dislocation. Navicular fractured. Cuboid fractured. All cuneiforms fractured. 1st, 3rd, 4th. and 5th metatarsals fractured. Disruption of the entire mid-foot.

Post-test clinical dissection findings:

Pelvis: No obvious fractures.

Femur: No obvious fractures.

Knee: There are no fractures to the proximal tibia or distal femur, and the ligaments are intact. There is a fracture of the proximal test fixture, 6 cm from the joint line.

Tibia: There is an open, highly comminuted pilon fracture with the anterolateral and medial malleolus fragments retained in the soft tissue. The posterolateral two-thirds of the distal tibia is missing.

Foot/ankle: There is a fracture of the calcaneus with majority of the body and tuberosity missing. The talus has a neck fracture with portions of the head missing, but the body is intact. There are fractures of all cuneiforms, and disruption of the Chopart's and Lisfranc's joints. There are fractures of all the proximal tarsals. There is a fracture of the navicular and a fracture of the cuboid bone.

Soft tissue: There is an open laceration of the plantar aspect from the distal one-third with avulsion of the heel pad. There is stripping to the distal one-third with the posterior tissue being highly contaminated.

Neurovascular bundle: In continuity.

Assessment: Open highly contaminated mangled extremity.

Treatment: Below the knee amputation with possible AKA.

MTS: 3

Shot #	ID #	Age	Weight Lbs.	Sex	Cadaver ID #
17	99110-17- CLBC	37	144.6	M	37634

Post-test boot damage assessment: (Two-boot test) Inner boot sustained sufficient damage to permit foreign body contamination.

Post-test radiographic findings: (Left leg)

Pelvis: Normal.

Femur: Normal.

Knee: Possible medial condyle avulsion fracture (minimal displacement).

Leg: Fracture at the distal test fixture. Proximal fibula fracture, non-displaced.

Ankle: Normal.

Foot: Talar neck fracture with comminution. Highly comminuted calcaneus. Navicular is fractured. Comminuted cuboid fracture. 3rd metatarsal neck fracture, non-displaced.

Post-test clinical dissection findings:

Pelvis: No fractures.

Femur: No fracture.

Knee: No fractures or ligament disruption.

Tibia: There is a fracture at the distal test fixture. There are no fractures of the pilon area.

Foot/ankle: There is a fracture of the body and neck of the talus. There is a navicular fracture. The calcaneus is highly comminuted with fragments of the lateral wall and tuberosity remaining attached to the soft tissue. There are fractures of the cuboid, all cuneiforms, and the 3rd metatarsal.

Soft Tissue: There is a plantar laceration from the middle portion of the foot involving the heel pad, which is displaced posteriorly and laterally. There is a large posterior medial laceration over the plantar aspect of the foot. There is blast debris in the plantar aspect of the foot.

Neurovascular bundle: is in continuity.

Assessment: Open contaminated mangled extremity with injury to the mid and hind foot.

Treatment: BKA with delayed primary closure.

MTS: 2B

Shot #	ID #	Age	Weight Lbs.	Sex	Cadaver ID #
18	99110-18- CRBC	37	144.6	M	37634

Post-test boot damage assessment: (Two-boot test) Inner boot did not sustain sufficient damage to permit foreign body contamination.

Post-test radiographic findings: (Right leg)

Pelvis: Endoprosthesis right hip.

Femur: No acute fracture, plate on distal femur.

Knee: Very comminuted bicondylar plateau fracture (Schatzker VI) at flare.

Leg: Fracture at level of the distal test fixture.

Ankle: Medial, and lateral (Weber A) malleolus fracture, mildly displaced.

Foot: Talar neck fracture. Extremely comminuted joint depression calcaneus fracture.

Post-test clinical dissection findings:

Pelvis: No Fracture.

Femur: No Fracture.

Knee: No Fracture, no ligament damage.

Tibia: There are no fractures of the proximal tibia. There is a fracture of the distal one-third at the diaphyseal/metaphyseal junction. There is a highly comminuted pilon fracture.

Foot/ankle: There is a talus body fracture running from anterolateral to posteromedial aspect. The talonavicular joint is disrupted, and there is a fracture of the navicular bone. There are no fractures of the metatarsals. The calcaneus is largely missing with some fragments of the lateral wall remaining attached to the Achilles. The cuboid is crushed. The Chopart's and LisFranc's joints are disrupted and the medial cuneiform is fractured.

Soft Tissue: There is a plantar laceration from the distal one-third to the heel pad, and a laceration over the dorsal lateral aspect of the foot. There is blast residue in the foot and distal one-third of the tibia.

Neurovascular bundle: Is in continuity.

Assessment: Open contaminated mangled extremity.

Treatment: Open below the knee amputation with delayed primary closure.

MTS: 2B

Shot #	ID #	Age	Weight Lbs.	Sex	Cadaver ID #
19	99111-19- ALEE	86	188.2	M	38251

Post-test boot damage assessment: (Single boot test) Boot sustained sufficient damage to permit foreign body contamination.

Post-test radiographic findings: (Left leg)

Pelvis: Normal.

Femur: Amputated in the field for testing purposes. Femoral neck fracture pre-existing with no change.

Knee: Lateral femoral condyle fracture with intercondylar extension. Lateral plateau fracture.

Leg: Proximal tibia fracture at the level of the test fixture. Fracture of the proximal one-third of the fibula.

Ankle: Pilon fracture, severely comminuted.

Foot: Calcaneus is missing. Talus is missing. Fractured navicular and cuboid. Cuneiforms all fractured and comminuted. There are 1st, 2nd, 3rd, 4th, and 5th metatarsal base fractures.

Post-test clinical dissection findings:

Pelvis: No fractures.

Femur: This leg has been amputated in the field. There are no fractures in the proximal femur. In the distal femur, there is a lateral femoral condyle fracture with intercondylar extension consistent with a C-III intercondylar distal femur fracture

Knee: There is ligamentous instability of the ACL and the posterior lateral corner.

Tibia: There are no fractures of the tibial plateau, however there is a pilon fracture.

Foot/ankle: The calcaneus is missing except for fragments of the tuberosity which remain attached to the tendoachilles. The talus is completely missing with only the shell of the dome remaining. The navicular bone is missing and the cuboid has remnants. The cuneiforms are highly comminuted and there are fractures of the 1st through 5th metatarsal shafts.

Soft tissue: There is a plantar laceration of the foot extending from the distal one-third to the heel pad, which has been avulsed. The soft tissue has been stripped to the distal one-third and is highly contaminated with blast residue and foreign bodies

Assessment: Distal femur fracture; CIII highly contaminated mangled lower extremity/traumatic amputation.

Treatment: BKA with probable revision to above knee amputation.

MTS: 3

Shot #	ID #	Age	Weight Lbs.	Sex	Cadaver ID #
20	99111-20- ALEE	80	180.4	M	37734

Post-test boot damage assessment: (Single boot test) Boot sustained sufficient damage to permit foreign body contamination.

Post-test radiographic findings: (Left leg)

Pelvis: Normal.

Femur: Leg amputated in the field for testing purposes.

Knee: Normal.

Leg: Fracture of tibia at level of the distal test fixture. Segmental mid-shaft fibula fracture.

Ankle: Fibula fracture. Impacted talar dome. Talar body fracture. Medial malleolus fracture.

Foot: Severe comminuted cuboid. Comminuted navicular fracture. Cuneiform are fractures. 5th metatarsal base fracture; 5th metatarsal neck fracture. Calcaneus is highly comminuted.

Post-test clinical dissection findings:

Pelvis: No fractures.

Femur: No Fracture. This leg was amputated in the field for testing purposes.

Knee: No Fracture. Ligaments are stable.

Tibia: There is a fracture at the proximal and distal test fixtures.

Foot/ankle: There is transverse talar body fracture, but the talar neck is intact. The calcaneus is highly comminuted with portions of the tuberosity remaining attached to the soft tissue. There is a fracture of the cuboid and the navicular, and all of the cuneiforms are highly comminuted. There is a fracture of the 5th metatarsal. The Chopart's joint is disrupted.

Soft Tissue: There is an open stellate laceration from the distal one-third to the heel pad, with avulsion of the heel pad. There is blast residue present in the soft tissue.

Neurovascular bundle: In continuity.

Assessment: Open highly contaminated mangled extremity with soft tissue stripping to the distal one-third.

Treatment: Open BKA with delayed primary closure.

MTS: 2B

Shot #	ID #	Age	Weight Lbs.	Sex	Cadaver ID #
21	99111-21- BRDA	86	188.2	M	38251

This mine detonated low order due to a malfunction. There was no damage to the CB or to the leg, and the strain gauges remained intact. This leg was later tested on 22 April 1999 as shot number 23.

Shot #	ID #	Age	Weight Lbs.	Sex	Cadaver ID #
22	99111-22- BREC	80	180.4	M	37734

Post-test boot damage assessment: (Two-boot test) Inner boot did not sustain sufficient damage to permit foreign body contamination.

Post-test radiographic findings: (Left leg)

Pelvis: Normal.

Femur: Normal.

Knee: Normal.

Leg: Fracture of tibia at level of the test fixture. Segmental mid-shaft fibula fracture.

Ankle: Fibula fractured. Impacted talar dome. Talar body fracture. Medial malleolus fracture.

Foot: Severe comminuted cuboid. Comminuted navicular fracture. Cuneiform fractures. Base of 5th metatarsal fractured; 5th metatarsal neck fracture.

Post-test clinical dissection findings:

Pelvis: No Fracture.

Femur: No Fracture.

Knee: No Fracture, ligaments intact.

Tibia: The pilon area is highly comminuted.

Foot/ankle: There are highly comminuted fractures of the medial malleolus, anteromedial area, and a transverse fracture with marginal impaction of the pilon area. The fibula has a segmental fracture. There is a talar body fracture oblique from proximal medial to anterior lateral. The talar neck remains intact. The calcaneus is comminuted and missing the majority of the tuberosity. There is a comminuted fractures of the navicular and cuboid. The Chopart's joint is disrupted, but the LisFranc's joint is intact. The cuneiforms are intact. There are fractures of the 2nd, 4th, and 5th metatarsals.

Soft Tissue: There is an open stellate laceration from the distal one-third of the plantar surface to the heel pad. The heel pad has been avulsed. There is soft tissue stripping with blast contamination to the distal one-third of the tibia.

Assessment: Open highly comminuted mangled extremity.

Treatment: Open below the knee amputation with delayed primary closure.

MTS: 2A

Shot #	ID #	Age	Weight Lbs.	Sex	Cadaver ID #
23	99112-23- BRED	86	188.2	M	38251

Post-test boot damage assessment: (Two-boot test) Inner boot sustained sufficient damage to permit foreign body contamination.

Post-test radiographic findings: (Right leg)

Pelvis: Normal.

Femur: Normal.

Knee: Air in the knee capsule. Questionable MCL tear, laterally translated. Dislocated proximal tibia and fibula fracture. Questionable Medial condyle avulsion fracture (minimal displacement).

Leg: Pilon fracture. Segmental fibula fracture.

Ankle: Pilon fracture.

Foot: Talar neck fracture. Comminuted calcaneus fracture. Navicular fracture, sagittal split. 2nd metatarsal base fracture. Medial, middle, and lateral cuneiform fracture. Comminuted cuboid fracture. LisFranc's injury.

Post-test clinical dissection findings:

Pelvis: No fracture.

Femur: No fracture.

Knee: No fracture; no ligament disruption.

Tibia: There is a bicondylar tibia plateau fracture (Schatzker 6), as well as a fracture at the distal test fixture.

Foot/ankle: In the pilon region, there is a fracture of the talar body and neck. The navicular and cuboid are intact. The calcaneus demonstrates a highly comminuted joint depression fracture pattern. The LisFranc's and Chopart's joints are intact. There is a fracture of the first metatarsal head.

Soft Tissue: A small 2-cm laceration on the medial aspect of the calcaneus is observed.

Assessment: Closed comminuted fracture of the distal tibia and talus, with the severely comminuted calcaneus not salvageable.

Treatment: Below the knee amputation with treatment of the Schatzker 6 tibia plateau fracture.

MTS: 2A

Shot #	ID #	Age	Weight Lbs.	Sex	Cadaver ID #
24	99112-24- CREC	71	205.4	M	37727

Post-test boot damage assessment: (Two-boot test) Inner boot sustained sufficient damage to permit foreign body contamination.

Post-test radiographic findings: (Right leg)

Pelvis: Normal.

Femur: Normal. Leg amputated in the field for testing.

Knee: Proximal one-third of tibia comminuted fracture at test fixture. No plateau or tibial tubercle fracture.

Leg: Segmental fibula fracture at the level of the test fixture, and distal one-third pilon variant. Bimalleolar and anterior tibial plafond segment.

Ankle: Pilon variant as above.

Foot: 2nd, 3rd, and 4th comminuted metatarsal neck fracture. 1st metatarsal shaft fracture comminuted (segmental). 3rd, 4th, and 5th metatarsal base fracture. Cuboid severely comminuted. Middle, lateral cuneiform minimally displaced. Navicular tuberosity fractured. Talus and calcaneus severely comminuted.

Post-test clinical dissection findings:

Pelvis: No Fractures.

Femur: No Fractures. Leg amputated in the field for testing.

Knee: Ligaments intact.

Tibia: There is a fracture at the proximal and the distal test fixtures.

Foot/ankle: There is a pilon fracture involving the medial malleolus, anterior portion. The distal fibula demonstrates syndesmosis disruption. A talar body fracture with plantar dislocation is observed. The calcaneus is highly comminuted with only small fragments remaining of the lateral wall. There are fractures of the cuboid and the navicular. The calcaneal cuboid joint is disrupted. The Chopart's joint is disrupted, but the LisFranc's joint remains intact. There are fractures of the 1st through the 5th metatarsals.

Soft Tissue: There is stellate laceration of the plantar surface from the toe pad to the heel pad. The heel pad has been stripped from posterior lateral to anterior medial. There are dorsal lacerations over the 2nd and 3rd metatarsals. There has been soft tissue stripping with blast residue and contamination of the distal one-third of the tibia.

Neurovascular bundle: In continuity.

Assessment: Open mangled extremity; traumatic BKA.

Treatment: Open below the knee amputation with delayed primary closure.

MTS: 2B

Shot #	ID #	Age	Weight Lbs.	Sex	Cadaver ID #
25	99112-25- BLBC	71	205.4	M	37727

Post-test boot damage assessment: (Two-boot test) Inner boot sustained sufficient damage to permit foreign body contamination.

Post-test radiographic findings: (Left leg):

Pelvis: Normal.

Femur: Normal.

Knee: Fracture proximal to proximal test fixture.

Leg: Segmental fibula, and pilon fracture.

Ankle: Pilon fracture with severe anteromedial comminution. 2-3 mm displacement at anteromedial joint.

Foot: 2nd, 3rd, 4th, and 5th proximal phalangeal fracture. 3rd, 4th, and 5th metatarsal neck fractures. 3rd, 4th, and 5th metatarsal base fractures. Cuboid fractured with minimal lateral comminution. Calcaneus severely comminuted.

Post-test clinical dissection findings:

Pelvis: No Fractures

Femur: No Fractures

Knee: No Fractures. Ligaments intact.

Tibia: There is a fracture at the proximal test fixture. The distal one-third demonstrates a comminuted pilon fracture involving the anterior, lateral, and medial aspects.

Foot/ankle: The talus is not fractured. Pieces of the calcaneal medial facet, tuberosity, and posterolateral wall remain in the soft tissue. There are no fractures of the navicular, cuboid or cuneiforms. There are fractures of the 3rd, 4th, and 5th metatarsal bases. The Chopart's joint is intact, but there is disruption of the LisFranc's joint. The talonavicular joint is intact.

Soft Tissue: There is an open stellate laceration from the mid-portion of the foot to the heel pad with anterior lateral stripping of the heel pad. There is a 1 cm x 4 cm and a 6 cm x 4 cm posterior calf laceration of which the fibula has caused the latter. There are two lacerations on the dorsum of the foot.

Neurovascular bundle: In continuity.

Assessment: Open highly comminuted mid and hind-foot fractures with a comminuted pilon fracture.

Treatment: Open below the knee amputation with BKA, with delayed primary closure.

MTS: 2B

Shot #	ID #	Age	Weight Lbs.	Sex	Cadaver ID #
26	99117-26- ALFF	83	158	M	37896

Post-test boot damage assessment: (Single-boot test) The footwear sustained sufficient damage to permit foreign body contamination.

Post-test radiographic findings: (Left leg)

Pelvis: Normal.

Femur: Normal. Amputated in the field for testing purposes.

Knee: Normal.

Leg: Traumatic amputation of the distal one-third of the leg.

Ankle: N/A.

Foot: Traumatic amputation. Pieces of the calcaneus and talus present. Midfoot disrupted with forefoot intact.

Post-test clinical dissection findings:

Pelvis: No Fractures.

Femur: The left femur was amputated to prevent collateral damage from testing of the right lower extremity.

Knee: There are no fractures of the knee to include distal femur and proximal tibia. The knee ligaments are intact.

Tibia: There is an open pilon fracture with the anterior medial portion missing. The fibula remains intact distally.

Foot/ankle: The talus is dislocated. The Chopart's and Lisfranc's joints are disrupted, and there are fractures of the 1st and 2nd metatarsals.

Soft Tissue: There is a large open stellate laceration with heel pad avulsion on the plantar two-thirds of the sole of the foot. There is soft tissue stripping with extensive contamination to the distal one-third of the tibia.

Assessment: Open highly contaminated lower extremity; traumatic BKA with soft tissue stripping to distal one-third of leg.

Treatment: Below the knee amputation with delayed primary closure.

MTS: 2B

Shot #	ID #	Age	Weight Lbs.	Sex	Cadaver ID #
27	99117-27- BRFF	83	158	M	37896

Post-test boot damage assessment: (Single-boot test) The footwear sustained sufficient damage to permit foreign body contamination.

Post-test radiographic findings: (Right leg)

Pelvis: Normal.

Femur: Normal.

Knee: Normal.

Leg: Traumatic amputation of the distal one-third of the leg.

Ankle: N/A.

Foot: Traumatic amputation. Some soft tissue, bone fragments, and tendons present.

(NOTE: *uninstrumented limb*)

Post-test clinical dissection findings:

Pelvis: No fractures.

Femur: No fractures.

Knee: No fractures. Ligaments are intact.

Tibia: The distal one-third of the tibia, to include the foot, pilon, and soft tissue, is missing.

Foot/ankle: A separate portion of the forefoot to include the toes, long toe flexors, great toe metatarsal, and medial cuneiform was found in the debris. A fractured talus and navicular, along with pieces of the pilon area were also found in the debris..

Soft Tissue: The distal one-third, to include the foot, pilon, and soft tissue is missing. There is soft tissue stripping to the level of knee joint. A separate portion of the forefoot to include the toes and long toe flexors was found in the debris.

Assessment: Mangled, highly contaminated lower extremity; traumatic BKA with soft tissue stripping to the level of the knee.

Treatment: Above the knee amputation with delayed primary closure.

MTS: 4

Shot #	ID #	Age	Weight Lbs.	Sex	Cadaver ID #
28	99117-28- BLBC	43	138	M	37888

Post-test boot damage assessment: (Two-boot test) The inner boot sustained sufficient damage to permit foreign body contamination.

Post-test radiographic findings: (Left leg)

Pelvis: Normal.

Femur: Intertroch fracture with subtroch extension.

Knee: Proximal fibula fracture.

Leg: Comminuted, severe pilon fracture.

Ankle: Severely comminuted pilon fracture.

Foot: Comminuted fracture of the calcaneus. Talus body fracture. Cuboid fracture. Medial cuneiform fracture. 4th and 5th metatarsal fracture.

Post-test clinical dissection findings:

Pelvis: No fractures.

Femur: No fracture. The right lower extremity was amputated in order to study contralateral damage.

Knee: The knee is dislocated. There is a fracture of the proximal fibula with disruption of the tibial fibular joint.

Tibia: The distal one-third of the tibia and fibula are missing, and there is no evidence of the medial malleolus or the pilon area.

Foot/ankle: There is a comminuted fracture of the talus, with a fractures across the talar body and neck. The calcaneus has been amputated by the blast, but the posterior facet is still present. The Chopart's joint and Lisfranc's joint are disrupted. There are fractures of the 5th and 4th metatarsal shafts.

Soft Tissue: There is extensive soft tissue stripping with extensive contamination to the proximal one-third of the tibia. There is an anterior medial and an anterior lateral laceration with complete loss of the plantar heel pad.

Neurovascular bundle: Intact, as are the flexor tendons of the long toes.

Assessment: Mangled extremity with open grade IIIB distal tibial fracture; traumatic BKA.

Treatment: High, below knee amputation with delayed primary closure. Multiple debridements will be necessary. It may require possible revision to above-knee amputation depending on soft-tissue involvement.

MTS: 3

Contralateral Limb
(Striding position, trailing)

Shot #	ID #	Age	Weight Lbs.	Sex	Cadaver ID #
28	99117-28- Right Leg	43	138	M	37888

Note: Specimen wearing anti-mine trousers, with the right lower extremity in a trailing position.

Post-test boot damage assessment: (Single boot)

Post-test radiographic findings: (Right leg)

Pelvis: Normal.

Femur: Intertroch fracture with subtroch extension. Previous IM nail removed.

Knee: Normal.

Leg: Normal.

Ankle: Normal.

Foot: Normal.

Post-test clinical dissection findings:

Pelvis: The pelvis is intact.

Femur: The right femur and knee are both intact.

Knee: The right femur and knee are both intact. There is no obvious fracture deformity of the femur.

Tibia: There is no obvious fracture deformity of the proximal tibia and the tibial shaft is without evidence of any fractures.

Foot/ankle: There are no fractures of the ankle, hindfoot, midfoot, or forefoot.

Soft tissue: There are powder burns on the medial malleolus, and there is a 1 x 2 mm area of possible penetration over the medial malleolus. There are no lacerations of the foot, and all joints in the foot are intact. The only damage to the skin is a 1 x 2 cm superficial laceration on the medial malleolus.

Assessment: Small laceration over the medial malleolus, no fractures from the mid-femur to the foot and ankle.

Treatment: Local wound care.

MTS: 0

Shot #	ID #	Age	Weight Lbs.	Sex	Cadaver ID #
29	99117-29- CLBD	73	196	M	37740

Post-test boot damage assessment: (Two-boot test) Inner boot sustained sufficient damage to permit foreign body contamination.

Post-test radiographic findings: (Left leg)

Pelvis: Normal.

Femur: Normal. Leg was amputated in the field for testing purposes.

Knee: Normal.

Leg: Severely comminuted distal one-quarter tibiofibular fracture. Pilon fracture.

Ankle: Same as leg.

Foot: Crushed calcaneus. Talar body fracture. Cuboid fractured. 1st metatarsal shaft fracture. 2nd metatarsal shaft and base fracture. Severely comminuted 3rd, 4th, and 5th metatarsal fracture. Medial cuneiform fracture.

Post-test clinical dissection findings:

Pelvis: No fractures.

Femur: No Fractures.

Knee: No Fractures, ligaments intact.

Tibia: No fracture.

Foot/ankle: There is a comminuted pilon fracture and a distal tibia fracture with disruption of the syndesmosis ligaments. The talar neck and body are highly comminuted as is the calcaneus. There is a fracture of the cuboid. The 4th and 5th metatarsals are comminuted and all the metatarsal shafts are fractured.

Soft Tissue: There is a dorsal laceration over the 3rd, 4th, and 5th metatarsals. Also, there is an open 2 cm laceration on the medial side of the lateral heel and two lacerations over the MTPJ of the great toe.

Assessment: Highly comminuted pilon fracture. calcaneus fracture. open grade IIIA. contained.

Treatment: Below the knee amputation.

MTS: 2A

Shot #	ID #	Age	Weight Lbs.	Sex	Cadaver ID #
30	99117-30- BRBC	45	113	M	38255

Post-test boot damage assessment: (Two-boot test) The inner boot sustained sufficient damage to permit foreign body contamination.

Post-test radiographic findings: (Right leg)

Pelvis: Bilateral vasectomy clips. Possible widening of the SI joint.

Femur: Normal.

Knee: Tibial eminence fracture.

Leg: Proximal and distal fibula fracture.

Ankle: Medial malleolus fracture. Severely comminuted talar body fracture. Talar neck fracture.

Foot: Hallux metatarsal shaft fracture comminuted. 2nd metatarsal proximal avulsion fracture (Lisfranc). 4th and 3rd metatarsal base fracture. 5th metatarsal segmental shaft and base fracture. 5th proximal phalangeal shaft fracture. Lateral cuneiform fracture. Comminuted cuboid fracture. Transverse navicular fracture. Talar neck fracture, with destruction of the body. Comminuted calcaneus fracture.

Post-test clinical dissection findings:

Pelvis: No Fractures.

Femur: No Fractures.

Knee: There is PCL injury and posterior lateral corner injury with posterior lateral rotatory instability. The ACL is intact.

Tibia: The right knee has a tibial eminence fracture with attachment of the ACL origin. The distal tibia bony structures are intact to include the pilon area. The fibula has a segmental fracture.

Foot/ankle: The talus has a highly comminuted body and neck fracture. The calcaneus is highly comminuted with the majority of the body and tuberosity missing. The lateral wall and a portion of the posterior facet are attached to the soft tissue. There is disruption of the Chopart's joint and Lisfranc's joint with a fracture of the cuboid and navicular. The middle cuneiform is fractured. There are base fractures of the 1st and 5th metatarsals.

Soft Tissue: There is an open stellate laceration over the plantar surface of the foot from the toe pad to the heel pad. The majority of the heel pad is missing, and there is soft tissue stripping up to the mid one-half of the tibia. On the dorsum of the foot, there are two large open lacerations. There is evidence of blast residue and contamination to the mid-tibia.

Neurovascular bundle: In continuity.

Assessment: Traumatic BKA. Open, highly contaminated mangled extremity with contamination to the mid-tibia.

Treatment: Below the knee amputation with delayed primary closure. After several washouts, possible revision to an above knee amputation, depending on the vascular status, and soft tissue status.

MTS: 2B

Contralateral Limb
(Striding position, trailing)

Shot #	ID #	Age	Weight Lbs.	Sex	Cadaver ID #
30	99117-30- Left Leg	45	113	M	38255

Note: Specimen wearing anti-mine trousers, with the Left lower extremity in a trailing position.

Post-test boot damage assessment: (Single boot test)

Post-test radiographic findings: (Left leg)

Pelvis: Bilateral vasectomy clips.

Femur: Normal.

Knee: Normal.

Leg: Normal.

Ankle: Normal.

Foot: Normal.

Post-test clinical dissection findings:

Pelvis: No fractures.

Femur: No Fractures.

Knee: No Fractures; ligaments are stable.

Tibia: No Fractures.

Foot/Ankle: No Fractures, no ligament disruption.

Soft tissue: There is no break in the skin.

Assessment: Soft tissue contusion.

Treatment: Conservative measures.

MTS: 0

Shot #	ID #	Age	Weight Lbs.	Sex	Cadaver ID #
31	99117-31- BRBD	73	196	M	37740

Post-test boot damage assessment: (Two-boot test) Inner boot did not sustain sufficient damage to permit foreign body contamination.

Post-test radiographic findings: (Right leg)

Pelvis: Normal.

Femur: Normal.

Knee: Normal.

Leg: Medial malleolus fracture. Comminuted distal fibula fracture. Pilon variant fracture.

Ankle: Same as leg.

Foot: 3rd metatarsal neck and base fracture. 1st metatarsal base fracture.

Post-test clinical dissection findings:

Pelvis: No fractures.

Femur: No Fractures.

Knee: No Fractures, ligaments intact.

Tibia: No proximal fracture. There is a pilon fracture of the anterior half of the distal tibia with marginal impaction.

Foot/ankle: The talus is intact. The mid-foot, Chopart's, and LisFranc's ligaments are intact. The talonavicular joint is disrupted. There is a fracture of the proximal metatarsal of the first toe, and fractures of the 3rd and 4th metatarsal shafts. The calcaneus is intact. The calcaneal-cuboid joint is intact. The cuboid, cuneiforms, and navicular are intact.

Soft Tissue: This is a closed injury with no open wounds or lacerations.

Neurovascular bundle: In continuity.

Assessment: Closed pilon fracture with fractures of several metatarsals.

Treatment: Open reduction, internal fixation vs. external fixation. Salvageable injury.

MTS: 1

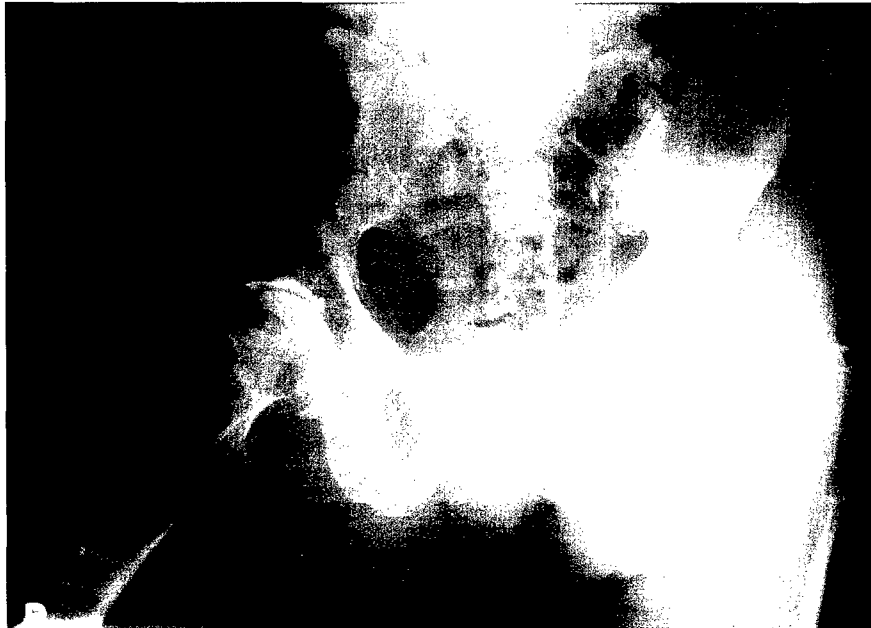Appendix B

Pretest Radiographs

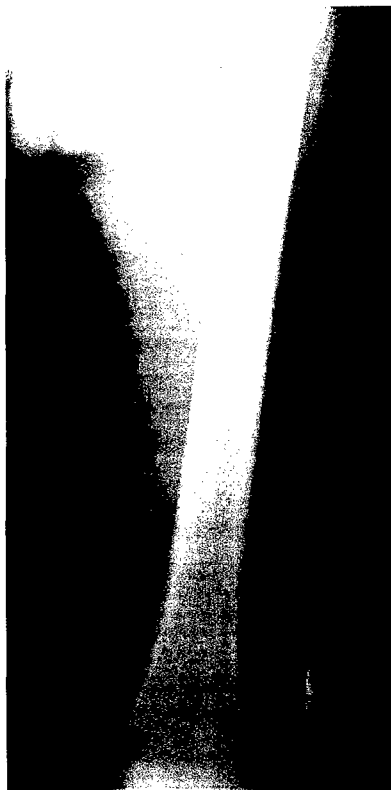This page intentionally left blank

Pretest Radiographic Evaluations: The following pictures illustrate examples of the radiographic views utilized for the LEAP 99-2 study. These are examples of normal specimens taken before testing.

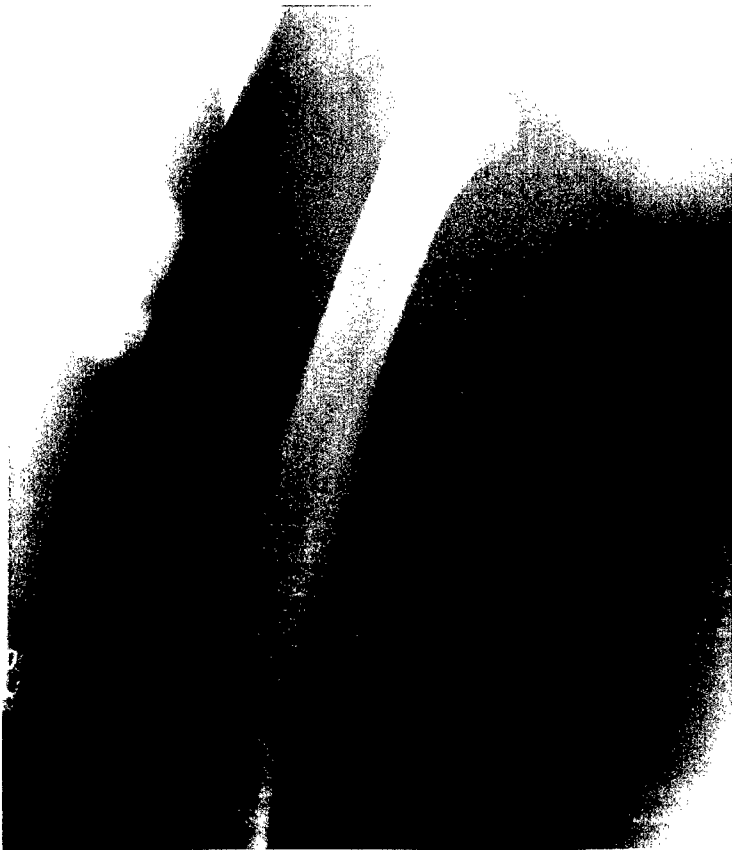Picture 1 AP Pelvis



Picture 2 AP Femur




Picture 3 Lateral Femur




Picture 4 AP Knee



Picture 5 Lateral Knee



Picture 6 AP Leg



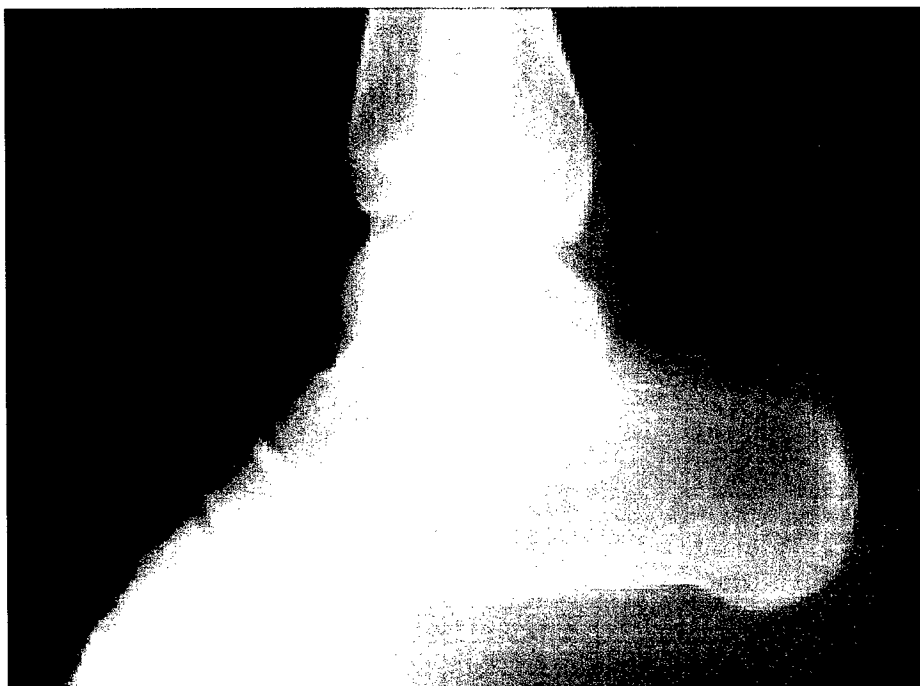Picture 7 Lateral Leg




Picture 8 AP Ankle




Picture 9 Lateral Ankle




Picture 10 AP Foot



Picture 11 Lateral Foot



Picture 12 CT Femur



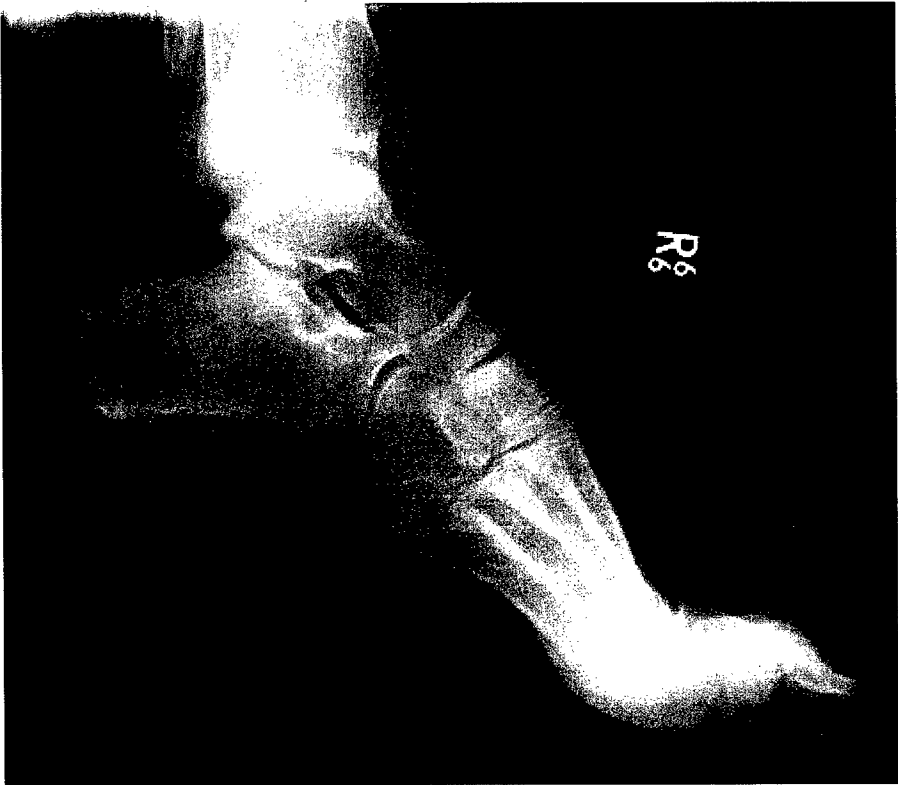Appendix C

Post test Radiographs

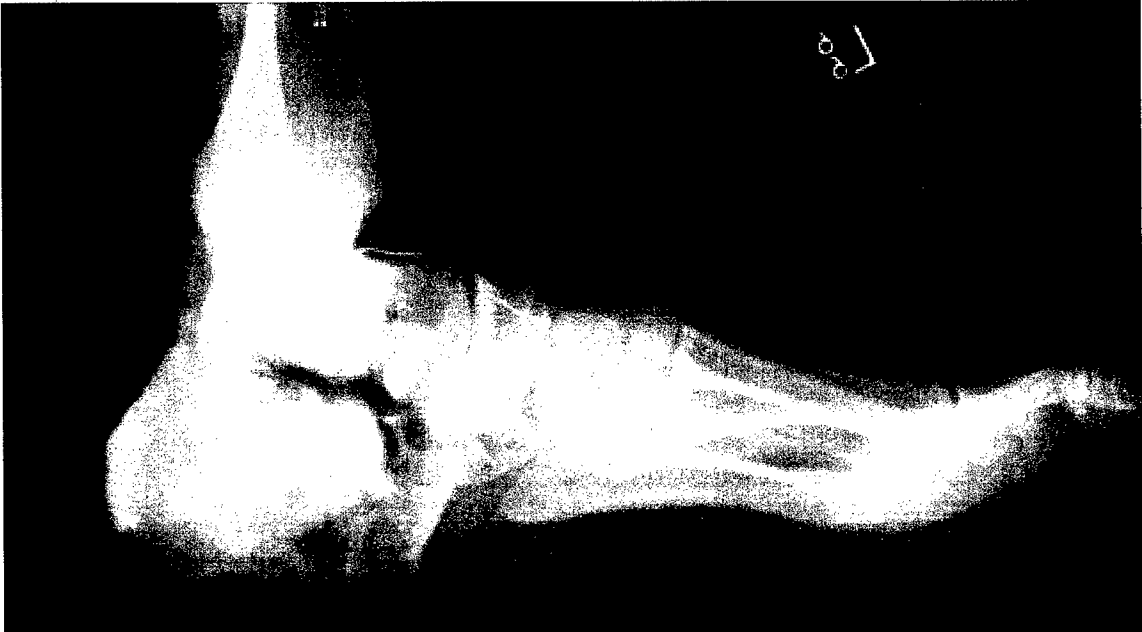This page intentionally left blank

This appendix contains representative radiographic examples of each injury according to the Mine Trauma Score.

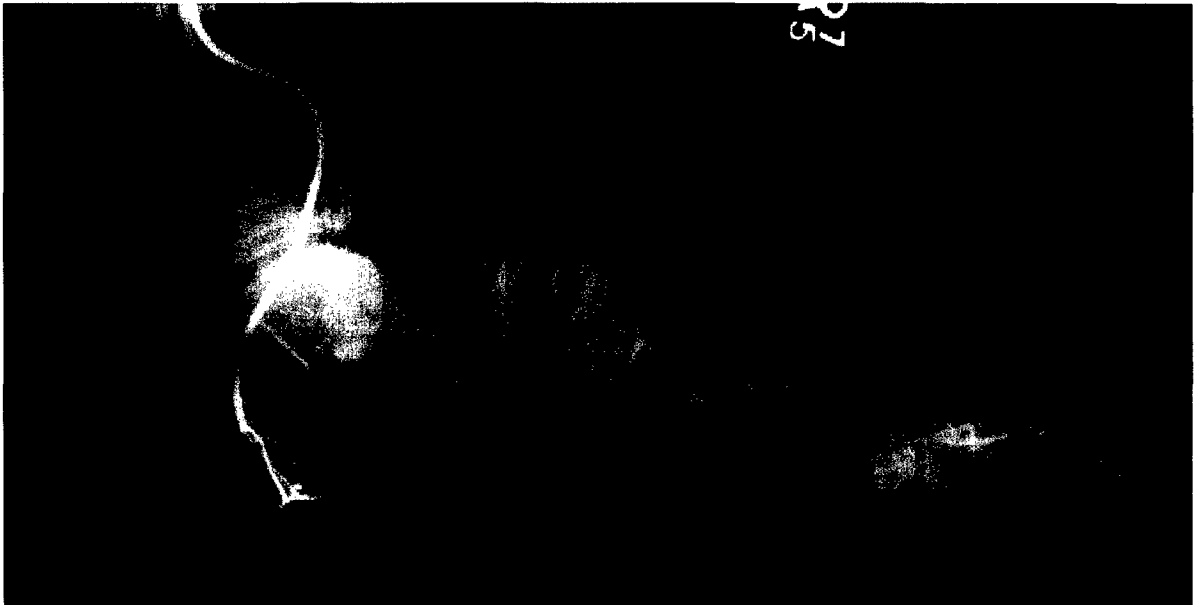Picture 1 MTS 0



Picture 2 MTS 1



Picture 3 MTS 1A



Picture 4 MTS 1B No injuries of this type occurred during testing.

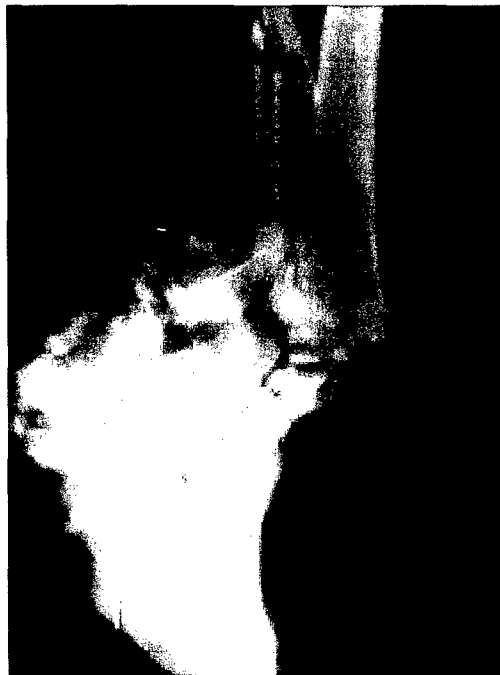
Picture 5 MTS 2



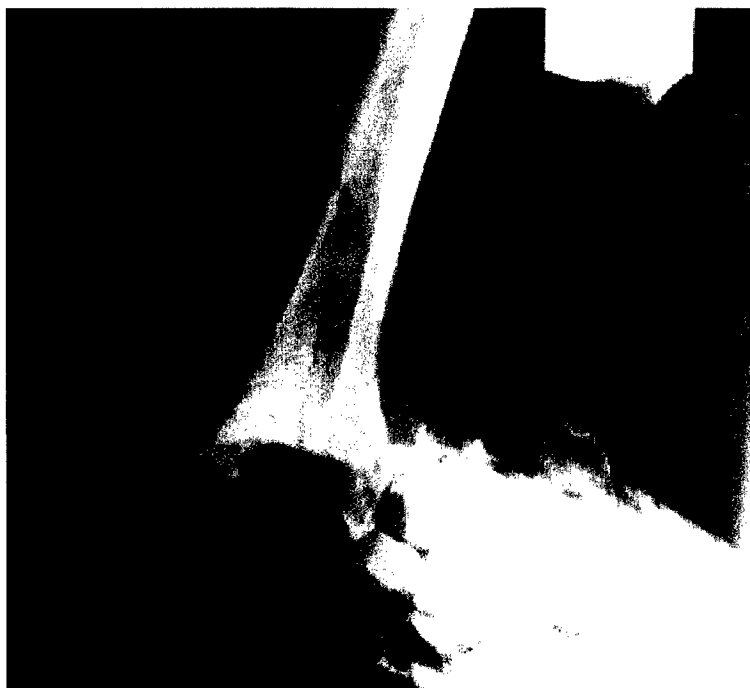Picture 6 MTS 2A



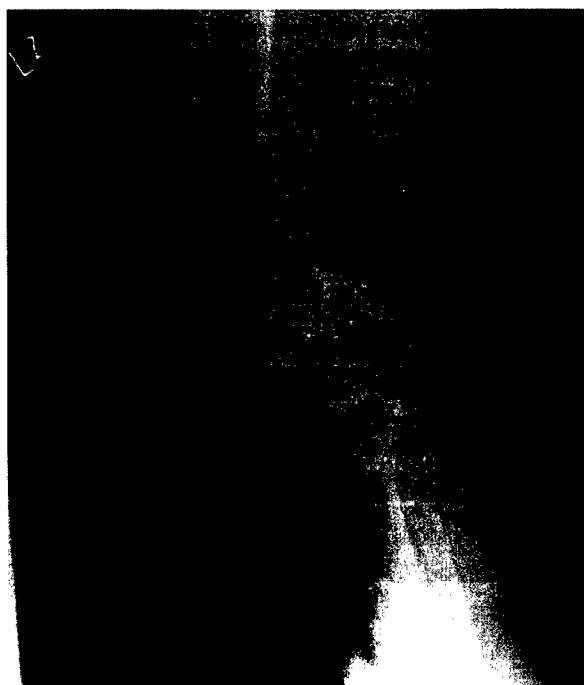Picture 7 MTS 2B



Picture 8 MTS 3



Picture 9 MTS 4



Appendix D

Detailed Footwear Damage Assessments

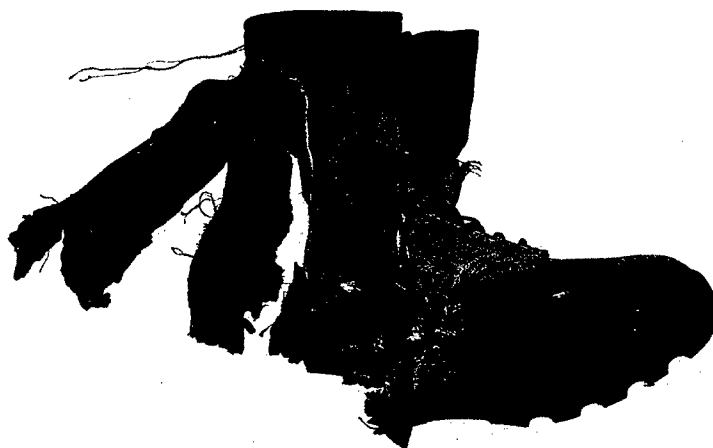This page intentionally left blank

Shot # 01

ID # 99103-01-ALAA

Combat boot and M14 Mine combination:

The heel of the boot has been completely destroyed with approximately 3 inches of sole missing. The heel cap has also been completely destroyed and is missing. The leather upper has been separated from the sole from heel to mid-foot, and has been shredded by five vertical tears, each extending upward approximately 6 inches. There is one longitudinal tear in the leather upper on the lateral side of the boot extending from mid-foot to the first outside eyelet. The cushion insole has approximately 1 1/2 inches of the heel missing and has two parallel 4-inch longitudinal tears extending from the heel to mid-foot.



Shot # 02 ID # 99103-02-BRAA

PMN mine with a standard combat boot

The combat boot was completely destroyed by the blast, with no recognizable fragments being recovered.

Shot # 03

ID # 99103-03-ALBC

M-14 Mine with Blast Boot/Overboot combination.

The overboot has had approximately 3 1/2 inches of the heel portion of its sole completely destroyed. The blast deflector, attenuator, and attenuator plate have been completely separated from the overboot. The rear two-thirds of the blast deflector has been flattened and bent upward approximately 1 inch. The rear two-thirds of the attenuator has been completely compressed and bent upward 1 inch. The Kevlar insole is intact, and apparently undamaged. The cloth covering over the Kevlar insole has two longitudinal tears, one approximately 1 inch, the other 3 inches, both in the heel area. The overboot's Kevlar upper has been completely split down the Achilles seam and is separated from the sole over the entire heel area, but otherwise appears to be intact with no damage to the Kevlar material itself.

The blast boot is intact with the only apparent damage being a slight concavity of the heel area of the sole, and a longitudinal 1 1/2-inch cut in the sole on the lateral one-half of the heel. It appears that there has been a significant internal compression/bending of the deflector/attenuator, but no other damage is noted.



Shot # 04



ID # 99103-04-ARAC

M-14 Mine with combat boot/overboot combination

Approximately 3 inches of the heel portion of the overboot's sole was removed by the blast. The blast deflector has been completely separated from the overboot. The attenuator and attenuator plate remain attached to the overboot. The rear two-thirds of the attenuator has been completely flattened with the front one-third having partial compression. The Kevlar insole remains attached to the overboot. A small metal fragment appearing to be one of the staples that attaches the insole to the sole has been driven through the Kevlar insole, with approximately

2 mm of this object exposed toward the foot. The canvas covering has been separated from the Kevlar insole by the blast, and shredded over the heel area. Both halves of the overboot's upper have been separated from the heel area of the sole, and split down the Achilles seam, but otherwise appear undamaged, and intact.

The sole and leather upper of the standard combat boot are intact and undamaged. Removal of the combat boot's cushion insole reveals two tears in the leather insole of the boot. One is a two-inch lateral tear approximately 1/2-inch from the rear of the heel with the other being a 3-inch longitudinal tear from mid-heel to mid-foot.





Shot # 05

ID # 99104-05-ALAC

M14 Mine with combat boot/overboot combination

The rear 4 inches of the overboot's sole have been separated by the blast and remains partially attached to the canvas covering of the upper. The heel section of the sole was recovered in one large and two small fragments. There is a 2 1/2-inch longitudinal tear in the midline of the sole at mid-foot. The blast deflector and attenuator have been completely separated from the overboot with the attenuator plate remaining affixed to the overboot. The mid-portion of the blast deflector has been flattened and bent upward approximately 1 1/4 inch. The rear 1 inch and the forward 1 1/2 inches of the attenuator have sustained little or no compression. The mid-portion of the attenuator has been completely compressed and bent upward approximately 1 inch. The attenuator plate remains affixed to the overboot and has a slight indentation in its center. The Kevlar insole and its canvas covering appear to be intact and undamaged. The Kevlar upper remains attached to the insole, and remains joined along the Achilles seam.



The sole and leather upper of the combat boot appear to be intact and undamaged. Removal of the combat boot's cushion insole reveals a 1-inch lateral tear in the leather insole at mid-heel, which curves 90° and extends 3 inches longitudinally.



M14 Mine with blast boot/overboot combination.




The rear one-third of the overboot's sole has been removed by the blast. The majority of this portion of the sole, including the heel, was recovered in one piece. The blast deflector, attenuator, and attenuator plate were completely separated from the overboot. The front one-half of the blast deflector was flattened and bent upward approximately 1/2 inch. The front two-thirds of the attenuator has been completely compressed, with partial compression of the rear one-third. Several long strips have been shredded from the attenuator, and exhibit the same compression pattern. The attenuator plate has been bent slightly upward in the center. The Kevlar insole and its canvas covering appear to be intact and undamaged. The Kevlar upper has been separated from the sole from heel to mid-foot and has been separated down the Achilles seam, but otherwise it appears to be undamaged.

The sole of the blast boot has sustained a 3-inch longitudinal tear down the mid-line from mid-heel to mid-foot. There appears to be slight internal bending/compression of the blast deflector/attenuator resulting in a slight concavity of the sole at mid-heel. There has been a slight separation of the leather upper from the sole on both sides of the heel. The Kevlar insole, leather upper, and cushion insole are undamaged.



M14 Mine with combat boot/overboot combination.



The rear 3 inches of the overboot's sole has been removed by the blast. There is a 3-inch longitudinal tear down the midline of the sole from mid-heel to the front of the blast deflector. The blast deflector and attenuator have been completely separated from the overboot. The attenuator plate remains attached to the overboot. The rear one-half of the blast deflector has been flattened. There has been complete compression of the rear one-half of the attenuator, with the front half remaining uncompressed. There is a slight indentation in the attenuator plate at the center of the heel. The Kevlar insole and canvas covering remain attached to the overboot and appear to be undamaged. The Kevlar upper has been separated from the sole around the heel area on both sides and has been separated down the Achilles seam, but is otherwise undamaged. The sole and leather upper of the combat boot appeared to be undamaged. Removal of the boot's cushion insole reveals a 1½-inch lateral tear in the leather insole of the boot across the mid-point of the heel, and a 2-inch longitudinal tear at mid-heel.



M14 Mine with blast boot/overboot combination.

The rear 3 1/2 inches of the overboot's sole have been blown off. The blast deflector has been completely separated from the overboot. The attenuator and attenuator plate remain attached to the overboot. The rear one-half of the blast deflector has been flattened and bent upward approximately 1/2 inch. The rear one-half of the attenuator has been completely flattened with the front half remaining relatively uncompressed. The attenuator plate has sustained no damage. The Kevlar insole and canvas covering are intact and appear to be undamaged. The Kevlar upper has been separated from the sole over the entire heel area. The lateral section of the Kevlar upper sustained a 1-inch vertical tear at mid-heel.

The sole and leather upper of the blast boot have sustained no obvious damage. There appears to be internal flattening/compression of the blast deflector/attenuator resulting in a slight concavity of the sole at mid-heel.



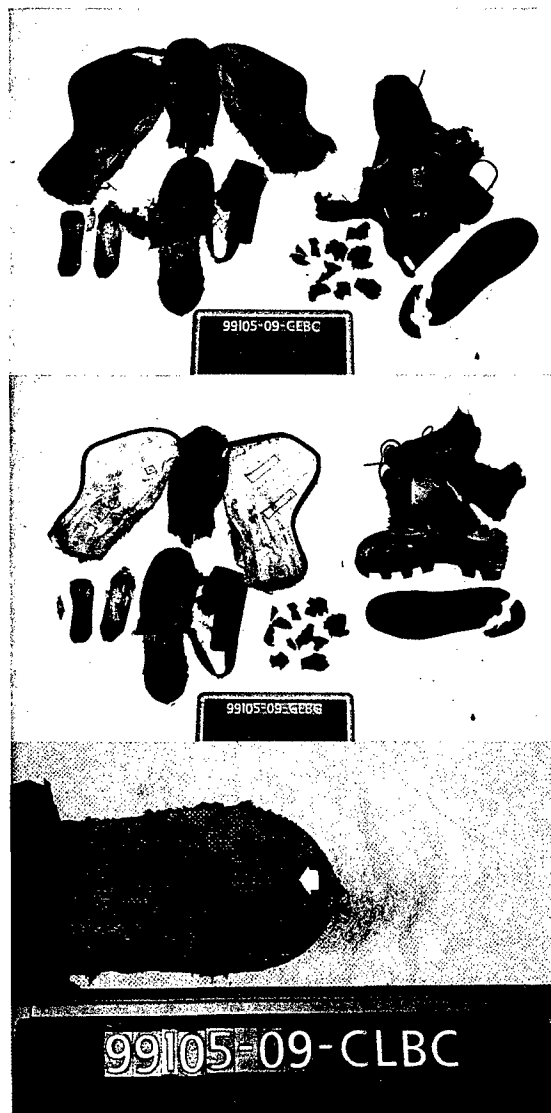
Shot # 09

ID # 99105-09-CLBC

PMA-2 Mine with blast boot/overboot combination.

The overboot has sustained significant damage. The entire heel portion of the sole has been completely destroyed. Both halves of the Kevlar upper have been completely separated from the sole, and split down the Achilles seam. The blast deflector, attenuator, attenuator plate, and Kevlar insole have been separated from the overboot by the blast. The rear two-thirds of the blast deflector has been flattened and bent upward approximately 1 inch and has a 2-inch split down the mid-line. The attenuator has been flattened and shredded and separated from the attenuator plate, with only about one-half of the honeycomb material being recovered. The Kevlar insole has sustained a 1-inch, L-shaped split in the Kevlar material at mid-heel. The canvas covering over the insole has been shredded and separated from the insole from the heel to mid-foot.

The sole of the blast boot has a 4-inch split down the mid-line of the heel exposing the blast deflector. The sole has been peeled up and over the insole on the lateral side. The rear one-half of the blast deflector has been flattened with subsequent compression of the attenuator. The Kevlar insole appears to be intact and undamaged. The leather upper has been completely separated from the rear one-half of the blast boot, and shredded by three vertical tears: one from the sole through the padded-collar of the upper, one 6-inch tear in the rear of the boot, and one 2-inch tear on the medial side of the heel.



Shot # 10

ID # 99105-10-ALBC

M14 Mine with blast boot/overboot combination.

The rear 4 inches of the sole of the overboot has been blown away by the mine and recovered in several large pieces. The blast deflector has been completely separated from the overboot. The attenuator and attenuator plate remain affixed to the overboot. The rear two-thirds of the blast deflector have been flattened and bent upward approximately 1 inch. The rear two-thirds of the attenuator has been completely compressed with little or no compression of the forward one-third. The Kevlar insole and canvass covering appear to be intact and undamaged. The Kevlar upper has been separated from the sole approximately 4 inches on each side of the heel area, and has been separated down the Achilles seam, but the Kevlar material itself is undamaged.

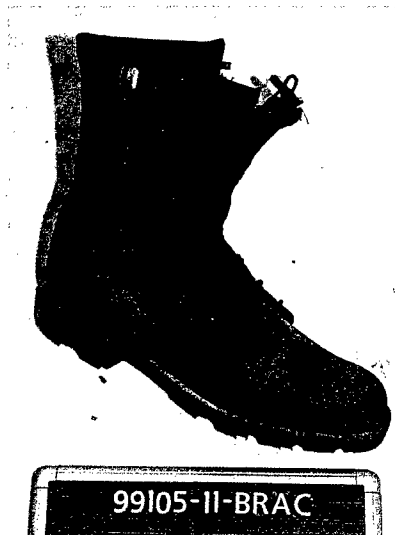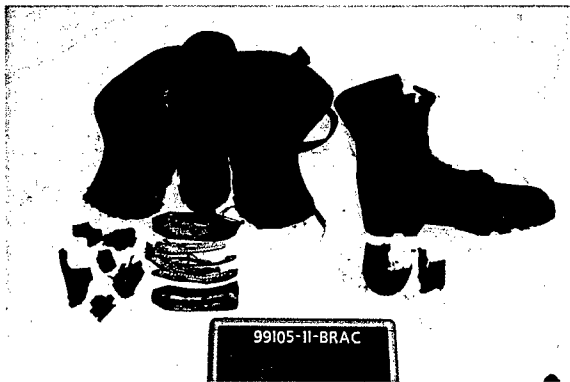
The sole of the blast boot has sustained a 2 1/2-inch longitudinal tear on the medial portion of the heel area. There has been a slight separation of the leather upper from the sole on the medial portion of the heel. There also appears to be internal bending/compression of the blast deflector/attenuator forming a 3/4-inch concavity of the sole at the mid-point of the heel. The Kevlar and cushion insoles are undamaged.



PMN Mine with combat boot/overboot combination.

The rear 4 inches of the medial and lateral sides of the overboot's heel have been removed by the mine, with a 1 inch x 2 inch section of the sole remaining along the mid-line of the heel. The blast deflector, attenuator, and attenuator plate were completely separated from the overboot. The majority of the deflector has been flattened, and bent upward approximately 1/2 inch in its center. The attenuator has been completely compressed, shredded, and was recovered in several long strips. The center of the attenuator plate has been bent upward, and slightly twisted. The Kevlar insole remains attached to the overboot and appears to be undamaged. The rear 1 inch of its canvas covering has been separated and shredded. The Kevlar upper has been completely separated at the Achilles seam with the lateral portion being separated from the sole to the toe, and the medial portion being separated from the heel to mid-foot. However, the Kevlar material appears to be undamaged.



The sole of the combat boot appears to be undamaged. The leather upper has been separated from the sole of the combat boot at the arch for approximately 3 inches, and has sustained a 2-inch vertical tear at the arch perpendicular to a 5-inch horizontal tear from the arch to the fourth eyelet. There is a 1 1/2 inch vertical tear over the medial side of the heel, and the leather upper has been separated from the sole on the lateral side of the boot about 6 inches at mid foot. There is a tear in the leather upper from the heel extending vertically through the top of the upper, completely opening the boot. The rear 4 inches of the cushion insole have been blown away revealing the leather insole of the boot, which has been badly shredded by tears from heel to mid-foot.



M14 Mine with combat boot/overboot combination.

The rear 4 inches of the overboot's sole have been completely removed by the mine, and recovered in eight large pieces. The blast deflector, attenuator, and attenuator plate have been completely separated from the overboot and remain attached to one another as a single unit. The rear two-thirds of the blast deflector/attenuator has been flattened/compressed, and bent upward approximately 1 inch with the front one-third remaining relatively undamaged. The Kevlar insole remains attached to the overboot, and appears to be undamaged. The Kevlar upper has been separated from the sole and insole around the entire heel area of the overboot. The Kevlar upper has been completely separated at the Achilles seam, but appears not to have sustained any damage to the Kevlar material itself.


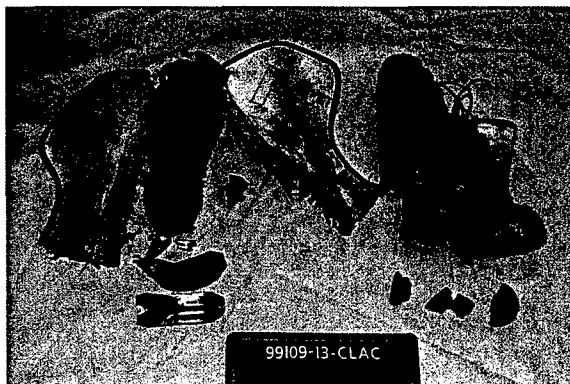
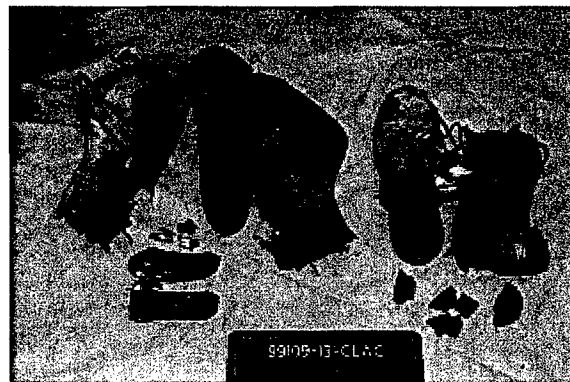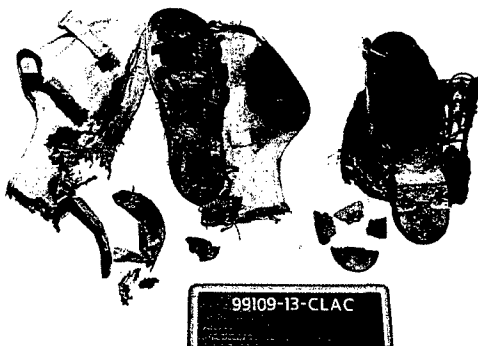
The sole and leather upper of the combat boot are intact and undamaged. Removal of the combat boot's cushion sole reveals a 3 1/2-inch longitudinal tear and a 1-inch lateral tear at mid-heel of the boot's leather insole. There are small, superficial tears in the underside of the cushion insole, which correspond to the tears in the leather insole.





PMA-2 Mine with Combat boot/overboot combination.

The overboot has sustained extensive damage with approximately 5 inches of the heel portion of the sole destroyed and missing. The blast deflector, attenuator, and attenuator plate have been completely separated from the sole. The rear two-thirds of the blast deflector have been flattened and bent upward 1 inch. The attenuator has been completely compressed and shredded with only half remaining attached to the attenuator plate. The attenuator plate has been bent upward and twisted. The Kevlar insole has sustained some damage to the center of the heel area. There is separation of the Kevlar layers with a one-inch diagonal tear in the top layers, but the insole remains attached to the overboot. The canvas covering of the Kevlar insole has been shredded and separated from the insole approximately 4 inches from the heel toward mid-foot. The lateral portion of the Kevlar upper has been completely separated from the sole and has a 2-inch vertical tear in the Kevlar material approximately 3 inches forward of the Achilles seam. The medial portion of the Kevlar upper has been separated from the sole from heel to toe, and has been torn and shredded in an area approximately 3 inches x 3 inches on the medial portion of the heel. Both halves of the Kevlar upper have been completely separated at the Achilles seam.

The sole of the combat boot is intact with the only damage being a 3-inch lateral cut in the heel. The leather upper has been completely separated from the sole from heel to mid-foot. Four vertical tears have shredded the leather upper, each approximately 6 inches in length. The heel area of the leather insole has been removed by the blast and there are two 3-inch longitudinal tears in the leather insole at mid-foot.





PMN Mine with blast boot/overboot combination.

The rear 4 inches of the medial and lateral sides of the overboot's heel have been removed by the blast, leaving a 1 inch x 1 1/2 inch section of the sole intact at the mid-point of the heel. The blast deflector has been completely separated from the overboot and has been flattened over its rear two-thirds and bent upward approximately 1/2 inch in its center. The attenuator and attenuator plate remain attached to the overboot, with the attenuator being completely compressed for the majority of its length. Three strands have been shredded from the medial side of the attenuator, but remain attached to the overboot. The Kevlar insole remains attached to the overboot, and appears to be undamaged. The lateral half of the Kevlar upper has been separated from the sole from heel to toe, and the rear 5 inches of the medial half have been separated from the sole. The two sides of the Kevlar upper have been completely separated at the Achilles seam, but appear to not have sustained any damage to the Kevlar material itself.

The sole of the blast boot appears to be undamaged, but has been separated from the leather upper from the rear of the heel to the arch medially approximately 6 inches. The blast deflector, attenuator, and attenuator plate remain attached to the sole of the boot, with the medial portion of the attenuator plate and attenuator exposed. There has been upward bending/compression of the center portion of the blast deflector/attenuator, and the sole exhibits a 1/2-inch concavity at mid-heel. The leather upper has been torn on the medial side from the first eyelet down the seam to the arch. There is also a tear in the lateral side of the leather upper extending 4 inches horizontally from the Achilles seam to the fifth eyelet, and then vertically 1-1/2 inch. There appears to be no damage to the Kevlar insole or the cushion insole.



99109-14-BRBC



99109-14-BRBC



99109-14-BRBC

PMA-2 mine with blast boot/overboot combination.

The rear 5 inches of the overboot's sole has been removed by the blast. The components of the overboot have been completely separated by the blast. The blast deflector has been flattened down the rear one-quarter of its length, and bent upward approximately 1 inch at mid-heel. There is a 1-1/2-inch split down the mid-line of the blast deflector at mid-heel. The attenuator has been completely compressed with its medial half missing, and some small shredded fragments being recovered. The attenuator plate has been separated from the Kevlar insole and is badly deformed. The Kevlar insole has been separated from the overboot and is undamaged. The rear 2 inches of its canvas covering is missing and there is a 2-inch longitudinal tear in the cloth at mid-heel. Both the lateral and medial sections of the Kevlar upper have been completely separated from the overboot, with only the toe portion remaining attached to the sole. The medial and lateral portions have also been completely separated at the Achilles seam. The lateral portion of the upper appears to have sustained no damage to the Kevlar material itself. The medial portion of the upper has sustained a 2-inch vertical tear with shredding of the Kevlar material at a point 3 inches forward of the Achilles seam. No other damage to the Kevlar material is noted.

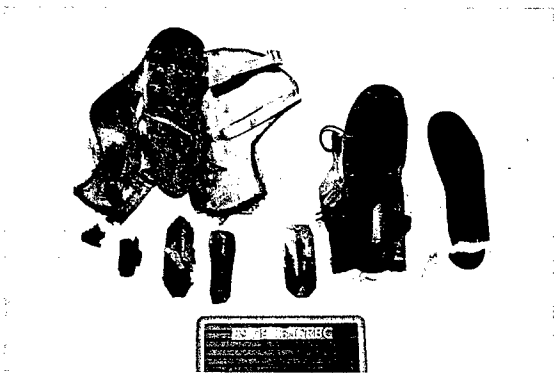


The sole of the blast boot has sustained a 3-inch curved tear from the rear of the heel to the medial side. The forward medial heel lug is missing. The leather upper has been completely separated from the sole from heel to the mid-foot. The blast deflector, attenuator, and attenuator plate have been completely separated from the blast boot. The forward two-thirds of the blast deflector has been flattened and bent upward approximately 1 inch. The attenuator has been completely flattened down the majority of its length and remains attached to the attenuator plate, which is slightly bent upward. The lateral side of the leather upper has been badly shredded by one long vertical tear from the heel through the top of the upper, and a 3-inch vertical tear from mid-foot to the third eyelet. There is also a diagonal tear in leather upper from the first eyelet to the fourth eyelet on the lateral side. The medial side of the leather upper has a 4-inch diagonal tear from the first eyelet to the arch. There is also a 4-inch vertical tear along the rear of the heel. The Kevlar insole remains attached to the blast boot, is intact, and has no apparent damage. The cushion insole has been torn and shredded across the mid-heel area.



PMA-2 Mine with Blast boot/overboot combination.

The rear 4 inches of the overboot sole has been removed by the blast. There are two 2-inch longitudinal tears in the sole at mid-foot. The blast deflector, attenuator, and attenuator plate have been separated from the overboot. The rear one-quarter of the blast deflector has been badly flattened with a 2-inch longitudinal split in the metal down the mid-line at mid-heel. The rear one-half of the blast deflector has been bent upward approximately 1-½ inches. The rear one-half of the attenuator is missing with the remaining portion being completely compressed and remaining attached to the attenuator plate. The Kevlar insole remains attached to the overboot and appears to have a 1-inch lateral tear in the Kevlar material at mid-heel. The medial portion of the Kevlar upper has been completely separated from the overboot, but appears not to have incurred any damage to the Kevlar material itself. The lateral portion of the Kevlar upper remains attached to the overboot, and has been separated from the sole from heel to mid foot, and has a 1-inch vertical tear with shredding, at a point 4 inches forward of the Achilles seam where the upper attaches to the sole.


The sole of the blast boot is badly damaged with a 1-½ inch x 2-½ inch section of the medial portion of the heel missing. There are also two 1-inch diagonal tears at the rear of the heel. The blast deflector has been completely separated from the blast boot, and is almost completely flattened, and bent upward approximately ½ inch at mid-heel. The attenuator and attenuator plate remain attached to the blast boot with the attenuator completely compressed. The leather upper of the blast boot has been completely separated from the sole, from heel to mid-foot. It is also badly shredded on the medial side by a 9-inch vertical tear, from the sole to the padded collar of the upper, and a diagonal tear from the first eyelet to the fourth eyelet. A 5-inch vertical tear has shredded the lateral side of the leather upper, from mid-foot to the fifth eyelet, and a 2-inch horizontal tear over the ankle. The Kevlar insole remains attached to the blast boot, is intact and appears to be undamaged. The heel portion of the cushion insole has been shredded with the rear 1-½ inches missing.

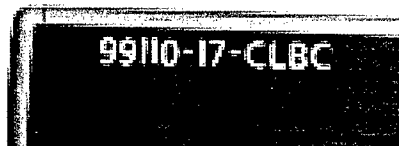
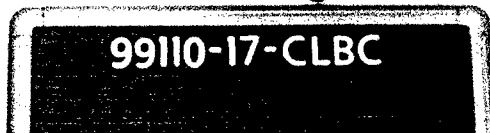
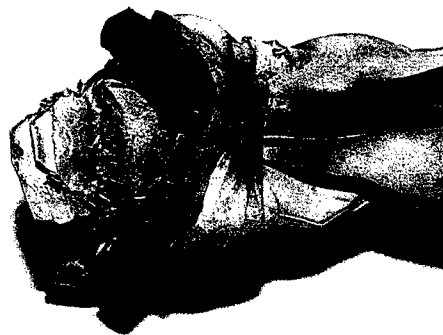

PMA-2 Mine with blast boot/overboot combination.

The rear 5 inches of the medial heel and the rear 3 inches of the lateral side of the heel have been removed by the blast. The blast deflector, attenuator, and attenuator plate have been completely separated from the overboot. The rear one-quarter of the blast deflector has been badly flattened and folded with a 3-inch split in the metal down the mid-line. The blast deflector has been bent upward approximately 1 inch at the heel. The attenuator has been completely compressed, shredded and recovered in several long strips. The attenuator plate is bent upward 1 inch at mid-heel. The Kevlar insole remains attached to the overboot, and appears to be undamaged. Its canvas covering is badly shredded from heel to mid-foot. The medial portion of the Kevlar upper has been completely separated from the overboot, and has sustained a 2-inch vertical tear with shredding at a point 3 inches forward of the Achilles seam. The lateral portion of the Kevlar upper has been separated from the sole from heel to the toe, but remains attached, and is apparently undamaged. Both sections were completely separated at the Achilles seam.

The sole of the blast boot has been split down the mid-line from mid-foot to the rear of the heel approximately 6 inches, and peeled upward over the rear of the heel cap. The rear two-thirds of the blast deflector, attenuator, and attenuator plate are protruding through the split in the sole, but remain attached to the blast boot. The rear one-quarter of the blast deflector has been almost completely flattened, bent downward, and protrudes through the split in the sole. Likewise the rear two-thirds of the attenuator have been completely compressed, bent downward and protrudes through the split in the sole, along with the attenuator plate. The lateral side of the leather upper has been separated from the sole for approximately 6 inches from mid-heel toward the toe. The lateral side of the leather upper has also been badly shredded by a 7-inch vertical tear from the sole at mid-foot extending upward to the sixth eyelet. There is a 1-1/2-inch vertical tear in the medial side of the leather upper at mid-foot above the arch. There appears to be some buckling of the material of the Kevlar insole at the mid-point of the heel.

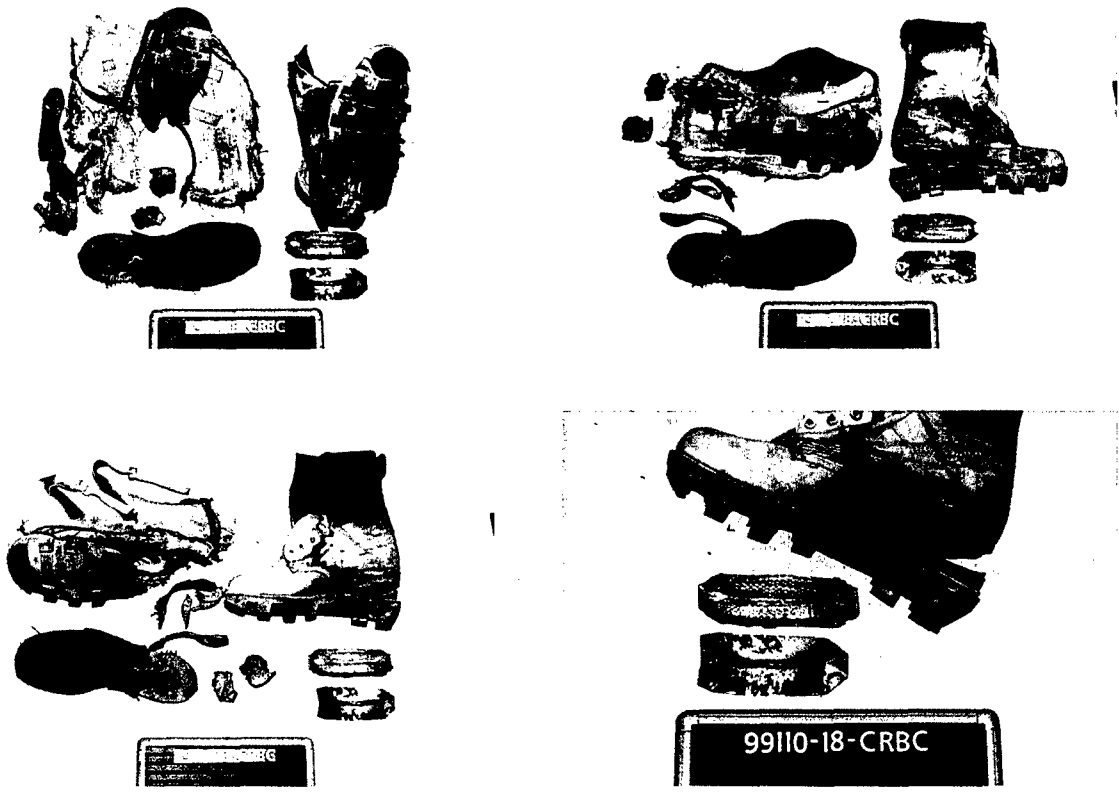




PMA-2 Mine with blast boot/overboot combination.

The rear 5 inches of the overboot sole has been completely destroyed by the blast. There are two 2-inch longitudinal tears in the sole at mid-foot. The blast deflector, attenuator, and attenuator plate have been completely separated from the overboot. The blast deflector has been badly flattened and folded at mid-heel, resulting in a 3-inch split in the metal along the mid-line. The rear one-half of the blast deflector has been bent upward approximately 1 inch. The blast deflector was completely separated from the overboot. The attenuator and attenuator plate have been completely separated from the overboot. The rear one-quarter of the attenuator is missing with the remaining portion compressed and badly shredded. The Kevlar insole has been completely separated from the overboot, but is intact and appears to be undamaged. The insole's canvas covering has been torn and shredded from heel to mid-foot. The lateral portion of the Kevlar upper has been completely separated from the overboot by the blast. It has a 3-inch vertical tear with extensive shredding of the Kevlar material over the lateral portion of the heel. The medial portion of the Kevlar upper has been separated from the sole from heel to toe, but remains attached to the overboot at the toe, and does not appear to have sustained any damaged to the Kevlar material.

The sole of the blast boot has a 5-inch longitudinal tear down the midline of the heel from the rear of the heel to mid-foot. The blast deflector was completely separated from the blast boot. The blast deflector has been flattened and bent upward approximately 1/4-inch in its center. The attenuator and attenuator plate were completely separated from the blast boot and the attenuator completely compressed. The leather upper has been completely separated from the sole of the blast boot from heel to mid-foot. A 6-inch longitudinal tear along the sole in the heel area, and a 5-inch vertical tear from the arch to the fifth eyelet shred the medial side of the leather upper. The lateral side of the boot has a 3-inch diagonal tear from the first eyelet to the sole at mid-foot. The Kevlar insole remains attached to the blast boot and appears to have sustained no damage. The cushion insole has a 6-inch longitudinal tear from mid-heel to mid-foot, a 1-inch lateral tear at mid-heel, and a 1-inch lateral tear in the side of the heel.

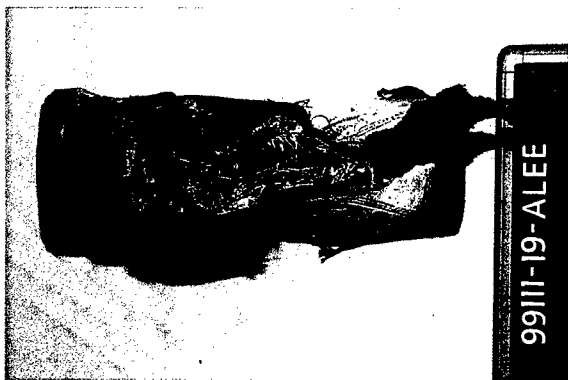


Shot # 19

ID # 99111-19-ALEE

M14 Mine with Singapore manufactured boot.

The rear 4 inches of the heel portion of the sole has been removed by the blast. The Kevlar insole is frayed around the edges and has a 1½-inch lateral tear at mid-heel and a longitudinal tear on the medial side of the heel penetrating the bottom layers of the material. The leather upper remains attached to the Kevlar insole. There is a 3-inch vertical tear in the leather upper, over the medial portion of the heel approximately 3 inches forward of the Achilles seam. A 6-inch vertical tear along the Achilles seam has penetrated the leather upper and the underlying Kevlar liner completely. The leather covering the heel cap portion of the boot has been completely separated from the upper exposing the Achilles seam.



Shot # 20

ID # 99111-20-ALEE

M-14 Mine with Singapore manufactured boot

The rear 4 inches of the heel portion of the sole has been removed by the blast and recovered in several large pieces. There is a 2-inch longitudinal tear in the lateral side of the sole at mid-foot. The leather upper has been completely separated from the sole and the Kevlar insole throughout the heel area. The leather heel cap portion of the upper has been badly shredded and completely separated from the boot. A vertical tear along the Achilles seam, which penetrates the leather upper and Kevlar lining, has opened the entire back of the boot. There is a 1-inch tear in the Kevlar lining at the rear of the heel.



99111-20-ALEE



99111-20-ALEE



99111-20-ALEE


Shot # 21

ID # 99111-21-BRDA

PMN mine with standard combat boot/Canadian overboot combination
(Note: This shot was low order due to a detonation malfunction.)

The left rear leg of the Canadian overboot has been removed by the blast. The area of the sole immediately above the left rear leg has received some damage and several cracks are visible. The right rear leg has received some superficial damage and is missing its rubber pod; otherwise, the overboot appears to be intact and undamaged with no damage to the bindings/attachment plate.


The combat boot is intact and appears to be undamaged. Removal of the cushion insole reveals no damage to the leather insole of the combat boot.



PMN Mine with Singapore manufactured boot/overboot combination.

The heel portion of the overboot sole has been completely destroyed by the blast, and recovered in several large pieces. The blast deflector, attenuator, and attenuator plate were completely separated from the overboot. The blast deflector has been partially flattened and bent upward approximately one-half inch at its center. The attenuator remains attached to the attenuator plate and has been completely compressed throughout its length with several long strips shredded from each side. The attenuator and attenuator plate have been bent upward approximately 1/2 inch in the center and slightly twisted. The Kevlar insole remains attached to the overboot and appears to be intact and undamaged. The medial portion of the Kevlar upper remains attached to the Kevlar insole and is apparently undamaged. Approximately 5 inches of the lateral portion of the Kevlar upper has been separated from the heel area of the Kevlar insole, but is otherwise undamaged. Both sections of the Kevlar upper have been completely separated at the Achilles seam.

The sole of the Singapore blast boot is apparently undamaged. There is a 1 1/2-inch vertical tear in the black cloth lining inside the boot 1 inch above the insole directly over the Achilles tendon. There are no tears or apparent damage to the leather upper of the boot, however the white paint applied to the boot pre-test has flaked off along wrinkle lines indicating there was some compression of the leather upper.





Shot # 23

ID # 99112-23-BRED

PMN mine with Singapore boot/Canadian overboot combination.

The Singapore manufactured blast boot used in this test is missing and not available for examination.

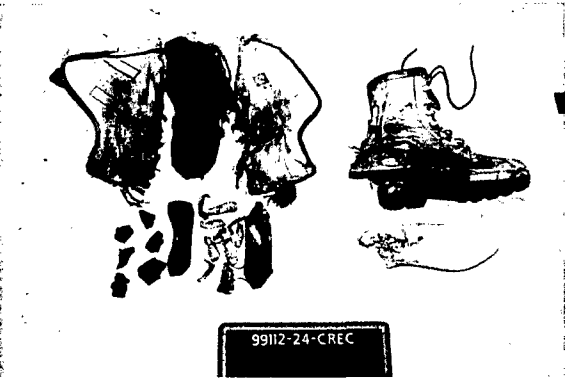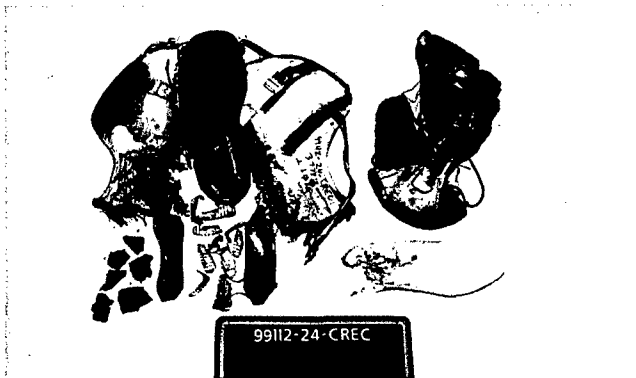The rear two legs of the Canadian overboot were completely removed by the blast. Fragments of the legs were recovered along with one intact pod and one fragmented pod. A 1½ inch x 2 inch section at the extreme rear portion of the overboot has been destroyed. The screws attaching the rear set of legs to the overboot remain in place. The lateral edge of the insole plate of the overboot has sustained a 7-inch crack in the material from the heel to the mid-foot. There appears to be no damage to the bindings or binding attachment plate.





PMA-2 Mine with Singapore boot/overboot combination.

The rear 4 inches of the overboot sole has been completely destroyed by the blast. The blast deflector, attenuator, and attenuator plate have all been completely separated from the overboot. The blast deflector has been badly flattened and folded, resulting in a 3-inch split in the metal along the rear two-thirds of its mid-line. The blast deflector has also been bent upward approximately 1 inch in its center. The attenuator has been separated from the attenuator plate and shredded into several small fragments, which have been completely compressed. The attenuator plate is bent upward approximately 1 inch in its center. The Kevlar insole remains attached to the overboot, and appears to be undamaged. Its canvas cover remains attached, but has sustained several small tears over the mid-point of the heel. Both the medial and lateral portions of the Kevlar upper have been completely separated from the overboot, and have been separated down the Achilles seam. The medial portion of the Kevlar upper appears to be undamaged, while the lateral portion has a 3 1/2-inch vertical tear with extensive shredding in the Kevlar material over the lateral portion of the heel 3 inches forward of the Achilles seam.



The sole of the Singapore boot has sustained a 2 1/2-inch longitudinal tear over the mid-heel. The sole has been separated from the leather upper and insole of the boot from the heel to mid-foot. The Kevlar insole appears to be undamaged. There is a 6-inch vertical tear completely through the leather upper and Kevlar lining along the Achilles tendon. The Kevlar lining over the insole appears to be intact. The heel portion of the cushion insole has been badly shredded. The white paint applied pretest to the boot has flaked off along wrinkle lines indicating compression of the leather upper.





PMN mine with blast boot/overboot combination

The rear 4 inches of the heel portion of the overboot has been destroyed and recovered in several large pieces. The blast deflector and attenuator have been separated from the overboot. The blast deflector has been moderately flattened, and bent upward approximately one-half inch in its center. The attenuator has been compressed and shredded down its entire length. The attenuator plate remains affixed to the underside of the Kevlar insole. The Kevlar insole remains attached to the overboot and appears to be intact and undamaged. Both sides of the Kevlar upper have been separated from the sole of the overboot from the heel to mid-foot. Both halves of the Kevlar upper have been completely separated at the Achilles seam, but there appears to be no damage to the Kevlar material itself. The blast deflector, attenuator, and attenuator plate of the blast boot have been flattened/compressed in the center causing the rear portion to tear through the sole of the blast boot in the heel area between the lugs of the sole. The blast deflector, attenuator, and attenuator plate remain attached to the boot. There appears to be no damage to the Kevlar insole. There is a 3-inch vertical tear in the leather upper on the lateral side of the heel area, and a 1/2-inch tear in the heel cap. There is a 2-inch lateral tear in the cushion insole. There are three small tears in the leather upper over the medial malleolus.



Shot # 26

ID # 99117-26-ALFF

M14 Mine with the improvised footwear/tire sandal

The rear one-third of the sandal has been completely destroyed and recovered in several small pieces.

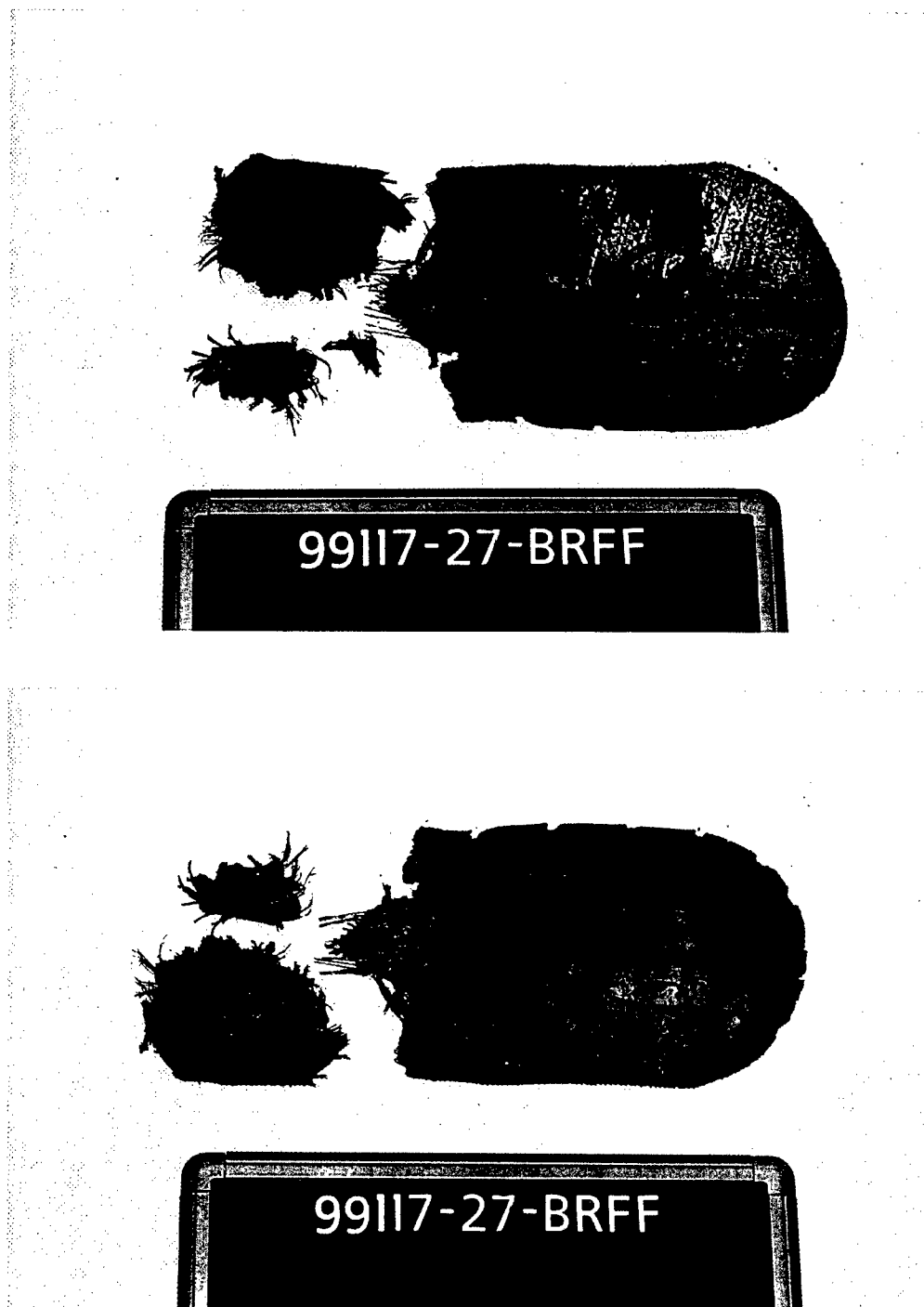


Shot # 27

ID # 99117-27-BRFF

PMN Mine with improvised footwear/tire sandal

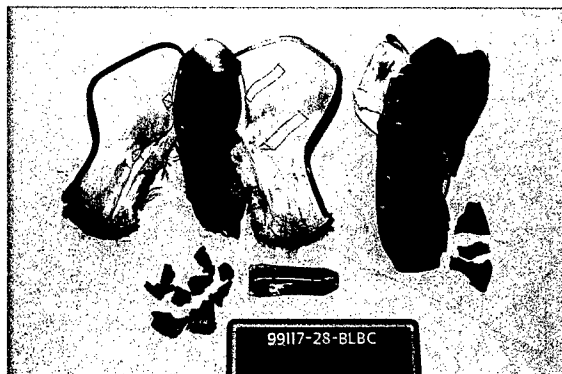The rear one-third of the sandal has been completely destroyed with one large fragment and two smaller pieces being recovered.



PMN Mine with blast boot/overboot combination

The outside 1-inch of the sole around the heel of the overboot has been removed by the blast, including the four heel lugs. Only a 2-1/2-inch x 3-inch portion of the sole is left over the mid-heel. There is a 2-1/2-inch longitudinal tear in the sole from heel to mid-foot. The blast deflector has been completely separated from the overboot and partially flattened down its entire length. The attenuator and attenuator plate remain attached to the overboot, with the attenuator being completely compressed and shredded down its medial side. The Kevlar insole remains attached to the overboot and appears to be undamaged with its canvas covering being separated and shredded over the heel area. The medial and lateral halves of the Kevlar upper have been completely separated down the Achilles seam and separated from the sole from heel to mid-foot. There appears to be no damage to the Kevlar material of either half of the upper.

The sole of the blast boot has a 3-inch diagonal tear across mid-heel. This tear is split open approximately 1-inch exposing the rear portion of the blast deflector. The blast deflector, attenuator, and attenuator plate remain attached to the blast boot. There appears to have been significant flattening/compression of the blast deflector/attenuator within the sole of the blast boot. The Kevlar insole remains attached to the blast boot with the only damage being a piece of bone which has penetrated the top layers on the medial side of the heel. The leather upper has been completely separated from the sole from the rear of the heel to the arch on the medial side. The upper has been shredded by a 6-inch vertical tear extending from the sole upward on the lateral side of the heel. The cushion insole has a 2-inch longitudinal tear at mid-heel and is missing a 2-inch x 1-inch section from the medial side of the heel.





99117-28-BLBC



99117-28-BLBC

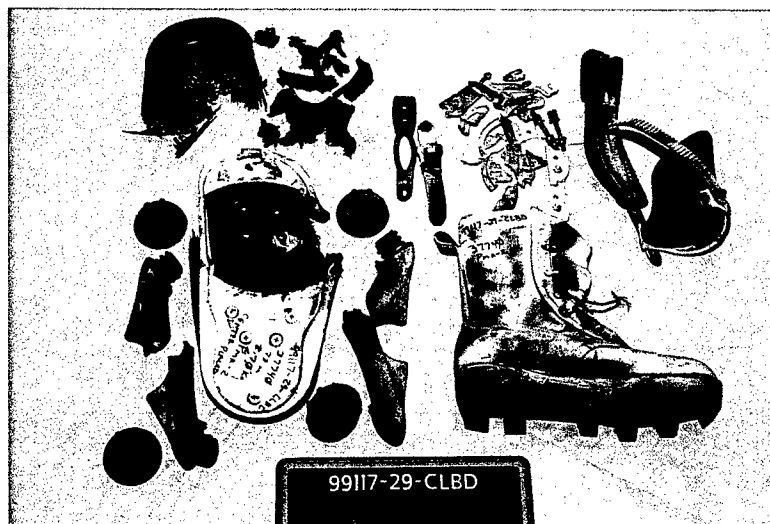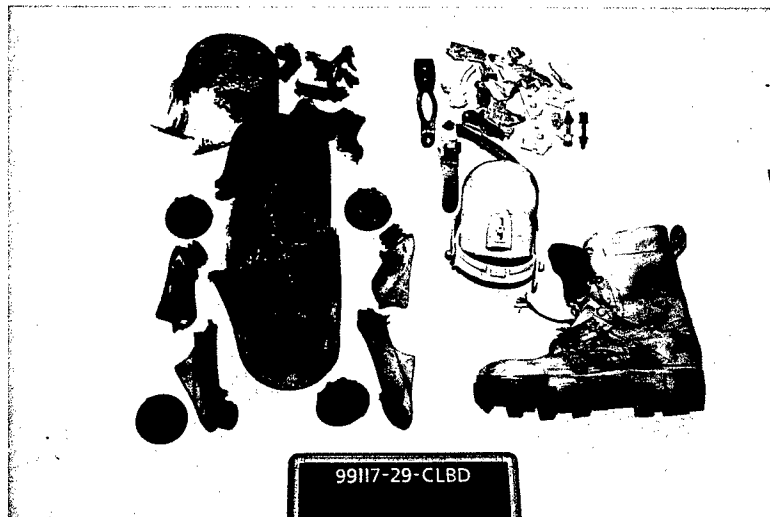Shot # 29

ID # 99117-29-CLBD

PMA-2 Mine with blast boot/Canadian overboot combination (mine placement at mid-foot)

The Canadian overboot has sustained extensive damage with all four legs being blown off, and all four, rubber feet being separated from their respective legs. The blast deflector or underside layer of the overboot has been blown in two at mid-foot. The plate attaching the bindings to the overboot has been shattered into several small pieces resulting in the binding becoming separated from the shoe itself. The floor of the overboot has been cracked completely through at mid-foot.

There is a 1/2-inch tear in the leather upper of the blast boot, below the third eyelet on the lateral side. There appears to be a slight concavity of the sole of the blast boot at mid-heel, indicating possible internal compression of the deflector/attenuator.




PMN Mine with blast boot / overboot combination.

The rear one-half of the overboot sole has been blown off. The blast deflector and attenuator have been separated from the overboot. The attenuator plate remains partially affixed to the underside of the Kevlar insole. The blast deflector has been flattened and bent upward in its center approximately one-quarter inch. The attenuator has been completely flattened and shredded and was recovered in 5 pieces. The Kevlar insole remains attached to the overboot and appears to be undamaged. The canvas covering over the Kevlar insole has been shredded in several places in the heel area. The lateral portion of the Kevlar upper has been torn from the sole to a point about two inches behind the toe, and has sustained a 4-inch vertical tear at about mid foot, with extensive shredding of the Kevlar material. The medial portion of the Kevlar upper has been separated from the sole to a point about mid-foot. Both halves of the Kevlar upper have been completely separated from each other at the Achilles seam.

The sole of the blast boot has been separated from the leather upper from heel to mid-foot, but is intact with the only apparent damage being small tears at the inside base of the heel lugs. The blast deflector remains attached to the sole with the rear one-half being flattened. The attenuator and attenuator plate are completely separated from the boot, with the attenuator being flattened completely and the attenuator plate dented and slightly bent in the middle. The Kevlar insole has been separated from the sole from heel to mid-foot, but otherwise remains attached to the boot and is intact and undamaged. The leather upper of the blast boot has been separated from the sole from heel to mid-foot and has been badly shredded by several tears. The leather upper has a 3½-inch diagonal tear over the lateral ankle, a 4-inch tear from the sole at mid-foot to the eighth eyelet, and a 7-inch vertical tear from the sole up the Achilles seam. There are also two long vertical tears on the lateral side of the boot, one 3-inch vertical tear over the medial ankle, and one diagonal tear from the first eyelet to the arch.





99117-30-BRBC



99117-30-BRBC



99117-30-BRBC


Shot # 31

ID # 99117-31-BRBD

PMN Mine with blast boot/Canadian overboot combination.
(Mine placement – left front leg)

Both of the overboot's front legs were removed by the blast, and recovered in several small pieces. The upper portion of the legs, which remain attached the body of the boot, were badly mangled. A 3-inch x 4-inch section has been blown out of the underside of the body of the boot. The toe area of the insole has been slightly bent upward. The bindings and binding attachment plate appear to be intact and undamaged. The rubber foot of the right rear leg has been removed by the blast.

The blast boot is completely intact and appears to be undamaged.



Appendix E

Force Data

This page intentionally left blank

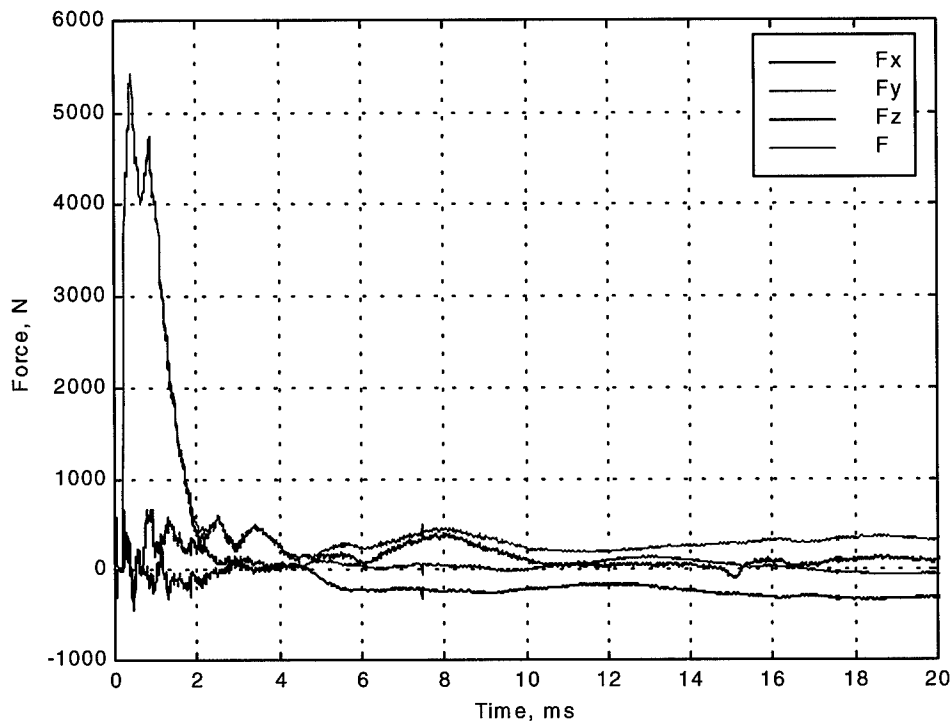


Figure 1: Force data for experiment 1.

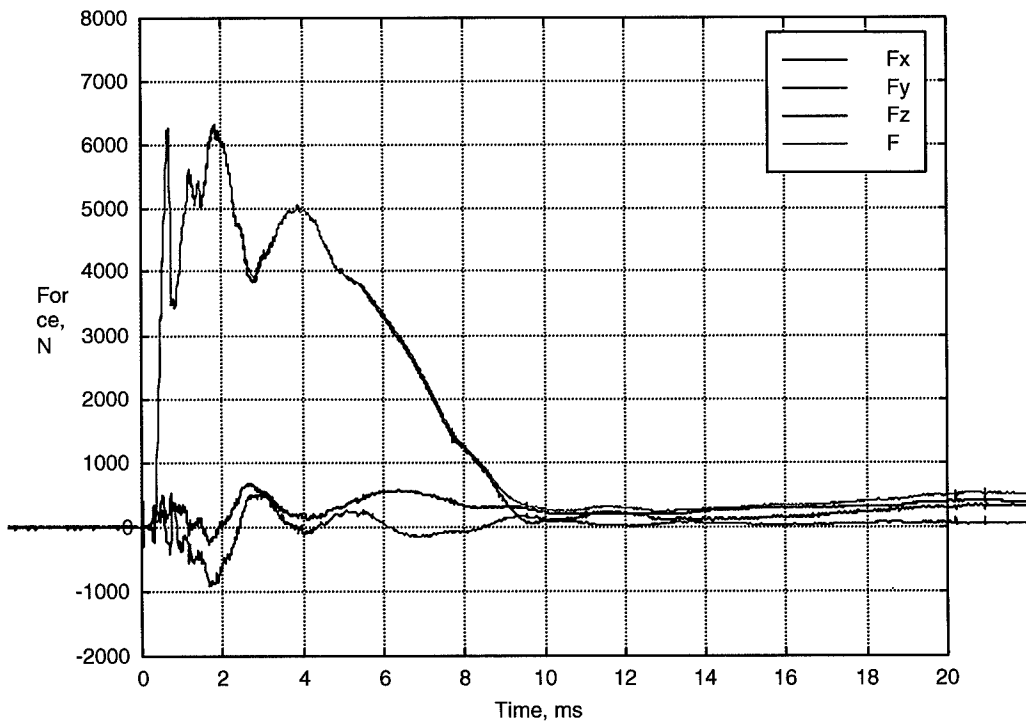


Figure 2: Force data for experiment 5.

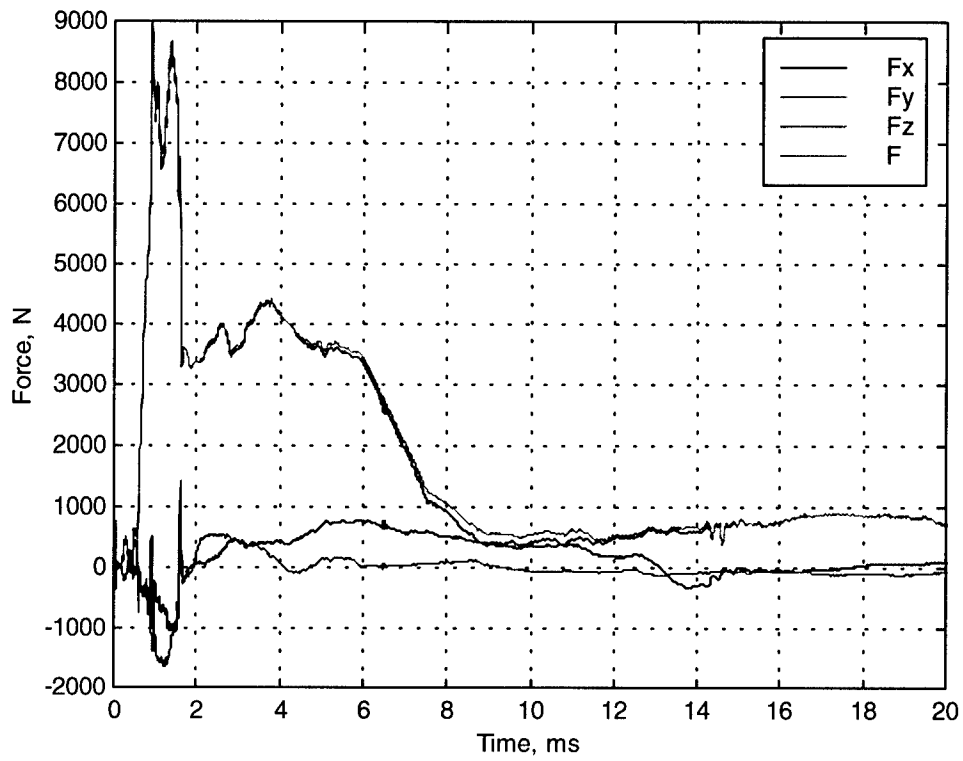


Figure 3: Force data for experiment 6.

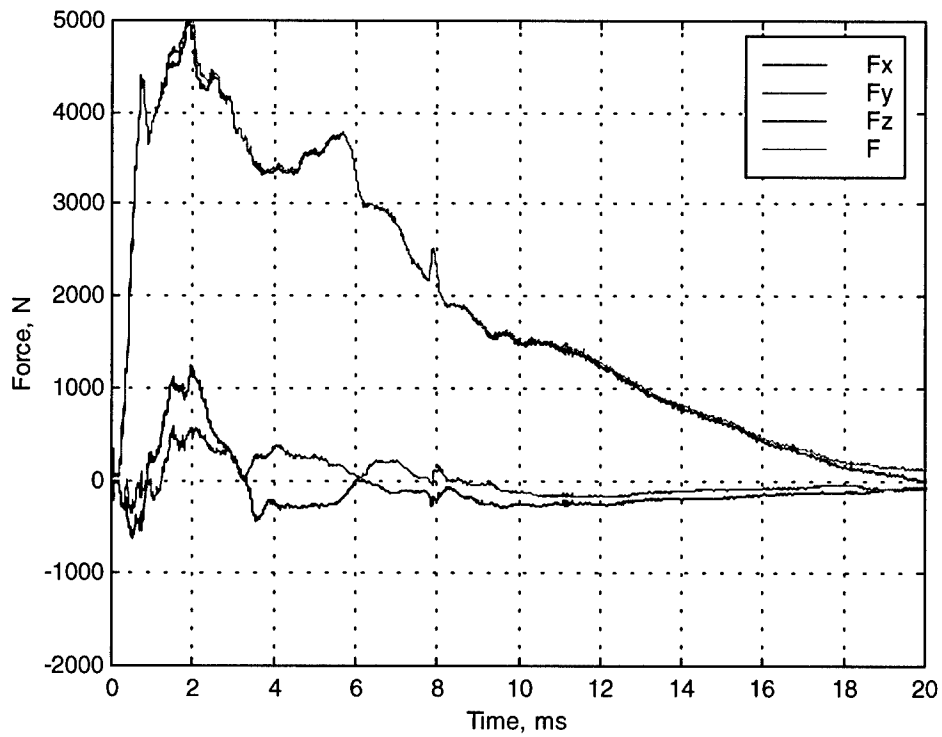


Figure 4: Force data for experiment 7.

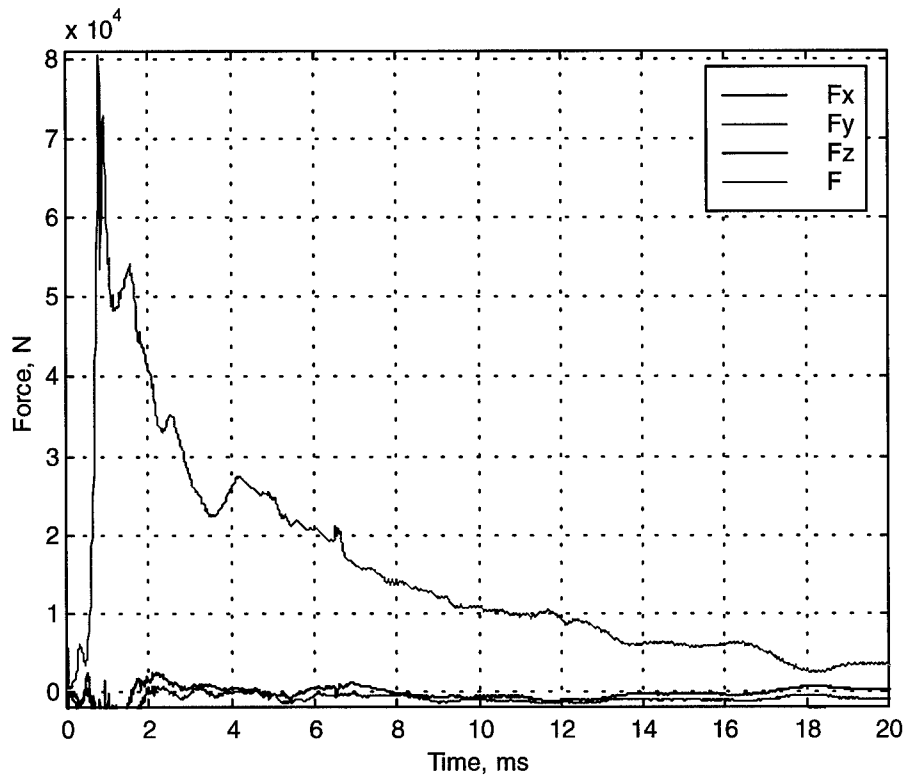


Figure 5: Force data for experiment 8.

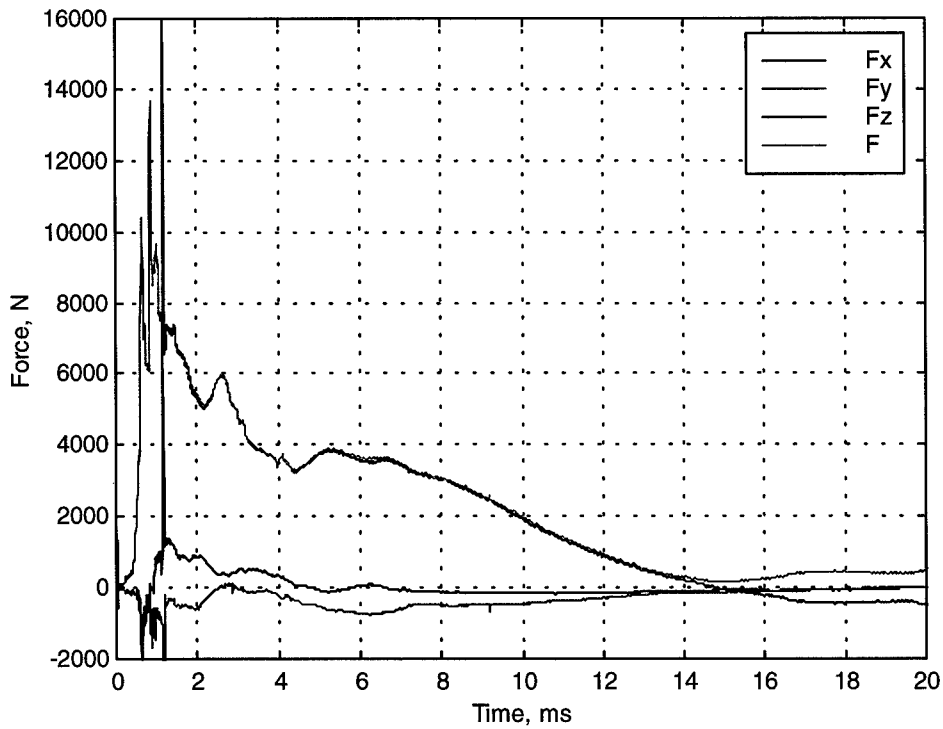


Figure 6: Force data for experiment 10.

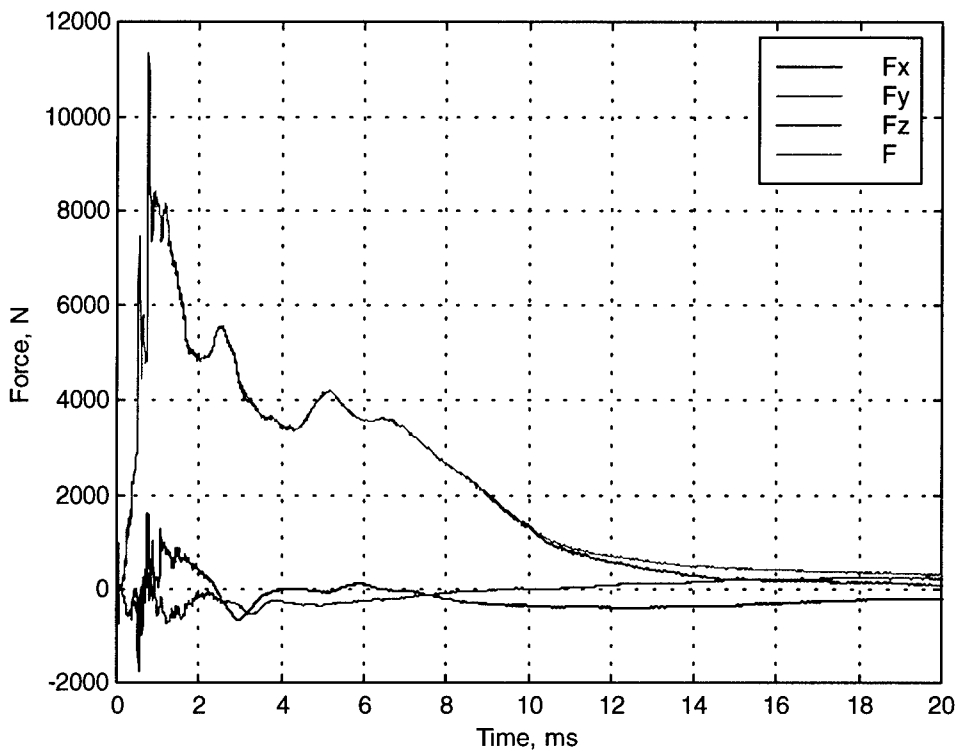


Figure 7: Force data for experiment 12.

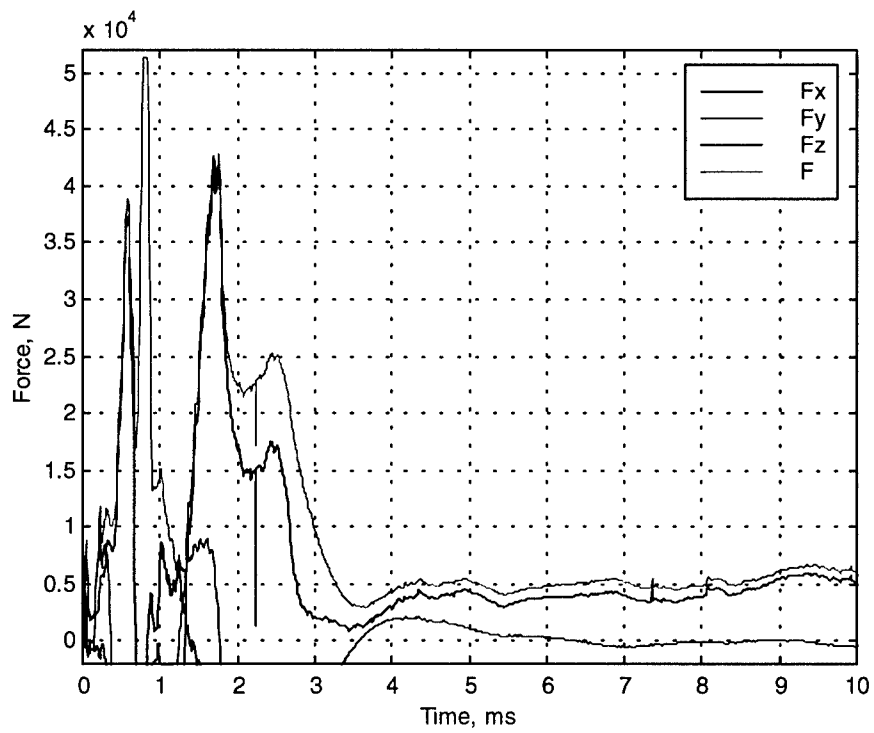


Figure 8: Force data for experiment 15.

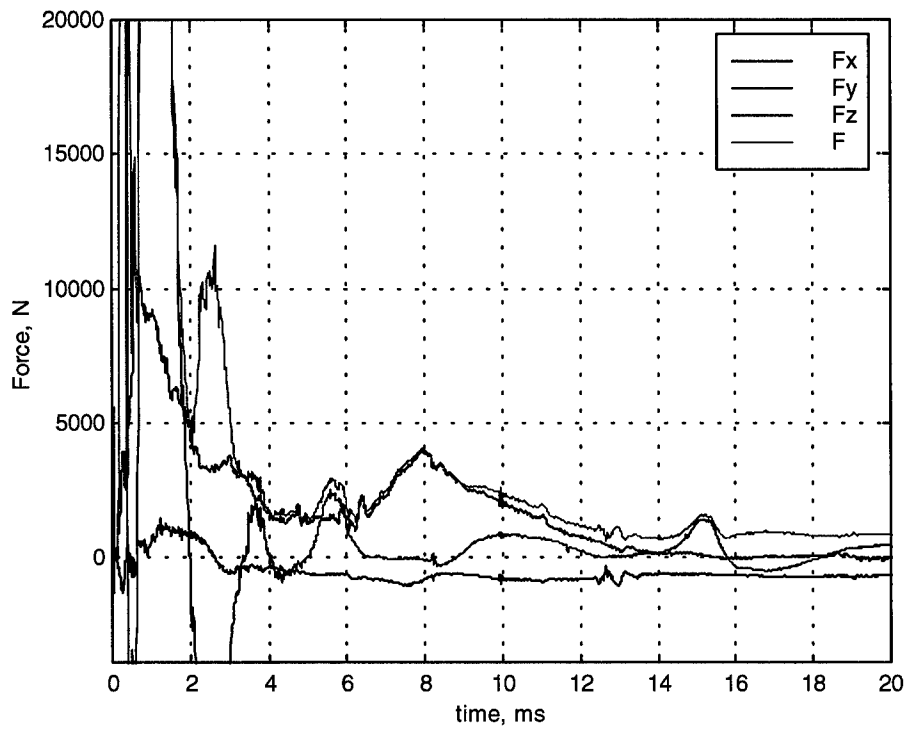


Figure 9: Force data from experiment 18.

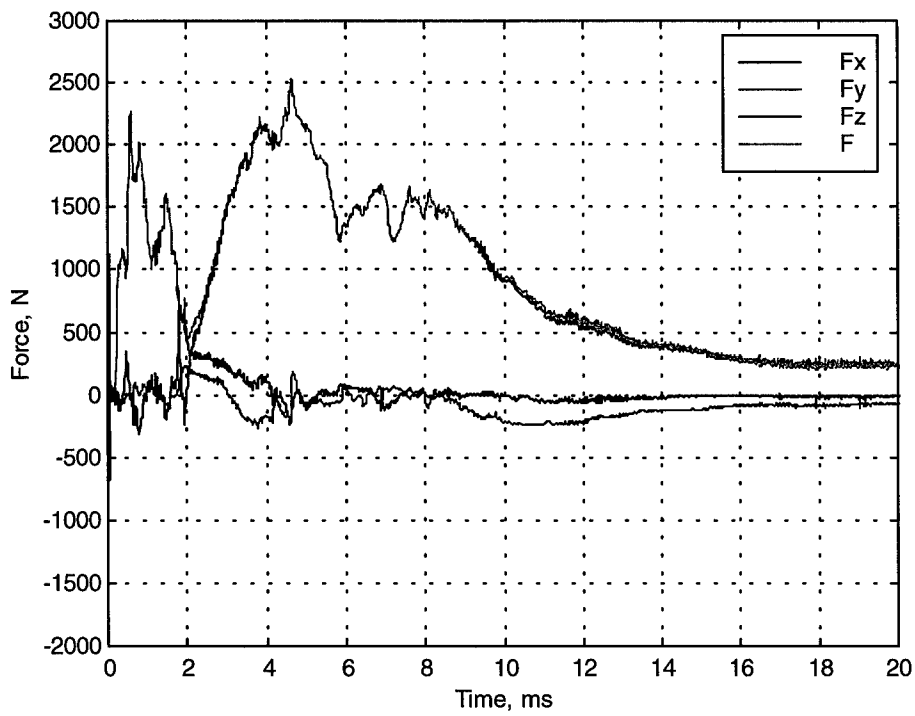


Figure 10: Force data for experiment 19.

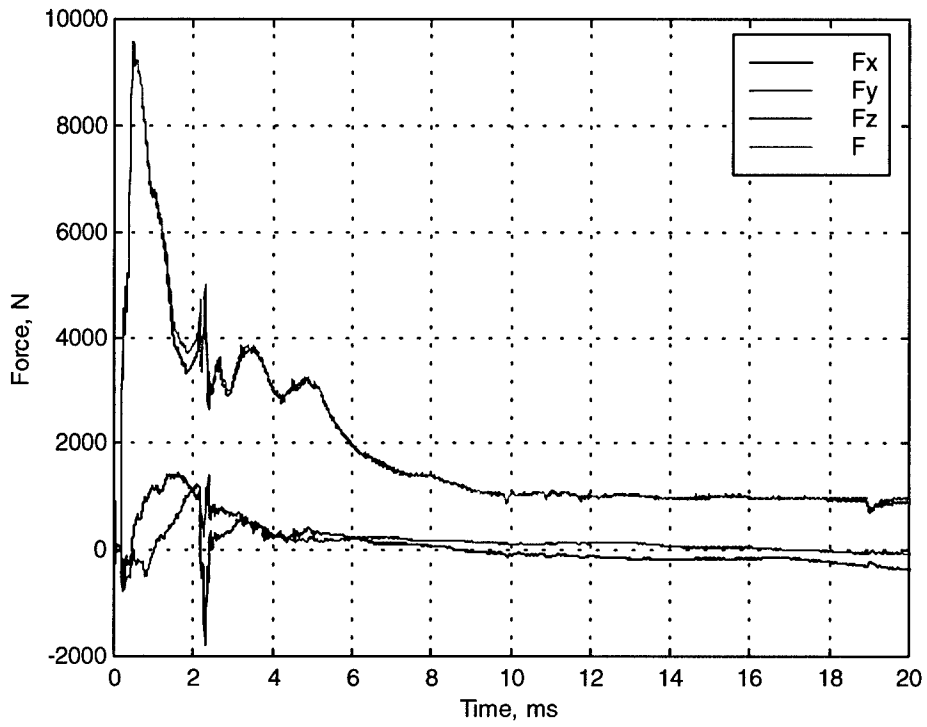


Figure 11: Force data for experiment 20.

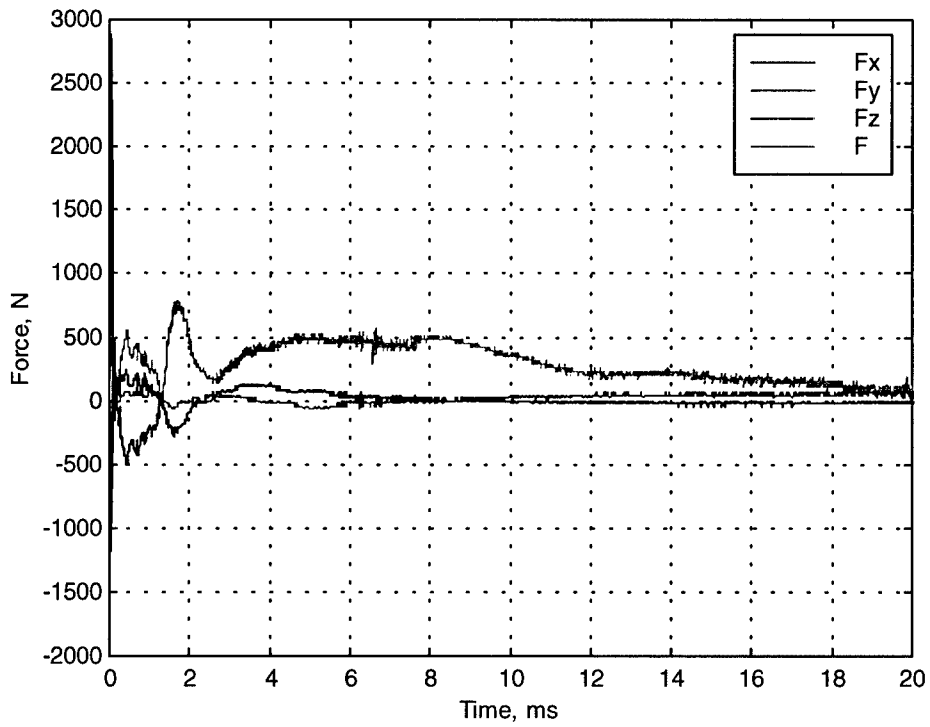


Figure 12: Force data for experiment 21.

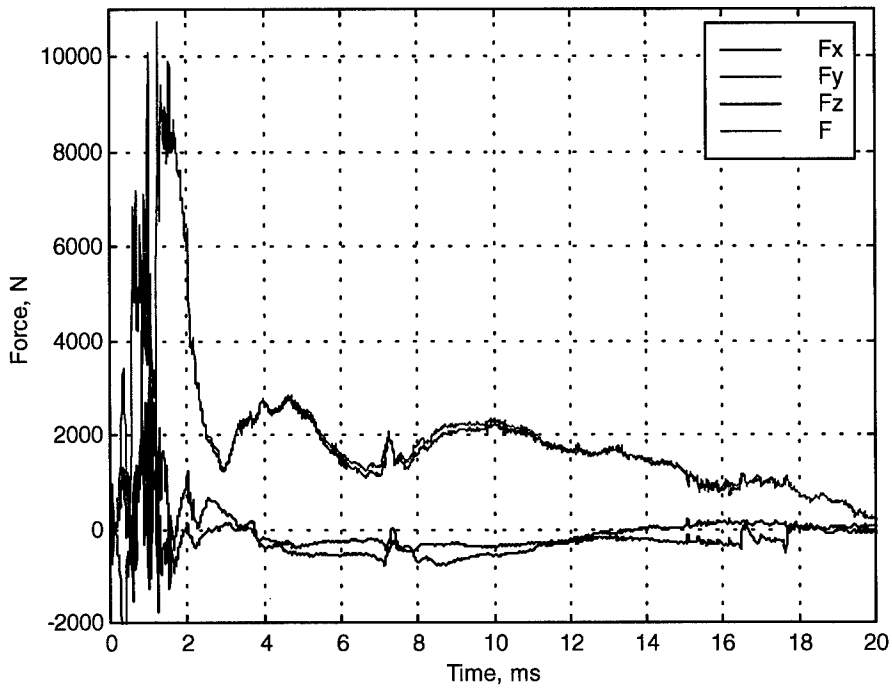


Figure 13: Force data for experiment 25.

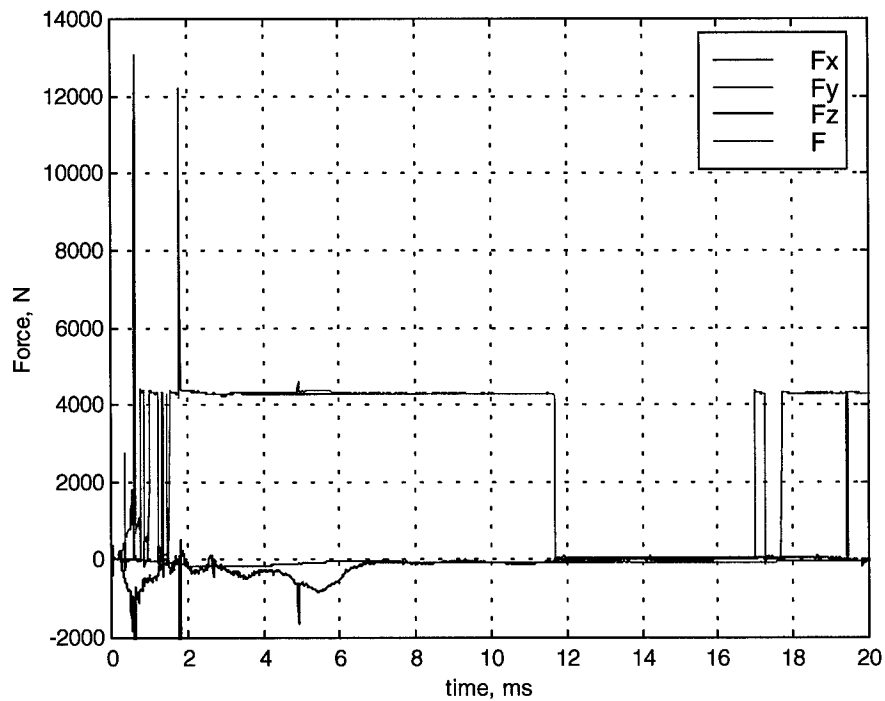


Figure 14: Force data for experiment 26.

REPORT DOCUMENTATION PAGE

Form Approved
OMB No. 0704-0188

Public reporting burden for this collection of information is estimated to average 1 hour per response, including the time for reviewing instructions, searching existing data sources, gathering and maintaining the data needed, and completing and reviewing the collection of information. Send comments regarding this burden estimate or any other aspect of this collection of information, including suggestions for reducing this burden, to Washington Headquarters Services, Directorate for Information Operations and Reports, 1215 Jefferson Davis Highway, Suite 1204, Arlington, VA 22202-4302, and to the Office of Management and Budget, Paperwork Reduction Project (0704-0188), Washington, DC 20503.

1. AGENCY USE ONLY <i>(Leave blank)</i>	2. REPORT DATE 30 Aug 2000	3. REPORT TYPE AND DATES COVERED	
4. TITLE AND SUBTITLE Final Report of the Lower Extremity Assessment Program (LEAP 99-2)		5. FUNDING NUMBERS	
6. AUTHOR(S) Robert M. Harris, MD; Mark S. Rountree; Lanny V. Griffin, PhD; Roman A. Hayda, MD; Terry Bice; Stephen J. Mannion		8. PERFORMING ORGANIZATION REPORT NUMBER	
7. PERFORMING ORGANIZATION NAME(S) AND ADDRESS(ES) U S Army Institute of Surgical Research 3400 Rawley E Chambers Ave Bldg 3611 Fort Sam Houston TX 78234 6315		10. SPONSORING / MONITORING AGENCY REPORT NUMBER	
9. SPONSORING / MONITORING AGENCY NAME(S) AND ADDRESS(ES) U S Army Medical Research and Materiel Command		11. SUPPLEMENTARY NOTES	
12a. DISTRIBUTION / AVAILABILITY STATEMENT Unlimited		12b. DISTRIBUTION CODE	
13. ABSTRACT <i>(Maximum 200 words)</i> Research conducted by Department of Defense laboratories and facilities, collaborating with leading academic institutions, has demonstrated that currently available landmine protective footwear does not prevent severe injury. This footwear potentially reduces injury severity against some antipersonnel mines. Volume 2 of the Lower Extremity Assessment Program (LEAP 99-2) discusses the change of injury pattern in a cadaver model wearing mine protective footwear during an antipersonnel blast mine detonation. Our analytical methodology developed to assess mine-protective footwear and injury severity associated with blast mines across the spectrum of threat is presented.			
14. SUBJECT TERMS Landmine, Extremity Trauma, Amputation, Mine Blast Injuries, Mine Protective Footwear		15. NUMBER OF PAGES 129	16. PRICE CODE
17. SECURITY CLASSIFICATION OF REPORT Unclassified	18. SECURITY CLASSIFICATION OF THIS PAGE Unclassified	19. SECURITY CLASSIFICATION OF ABSTRACT Unclassified	20. LIMITATION OF ABSTRACT Unlimited