

JOURNAL

U.S. ARMY MEDICAL DEPARTMENT

January–March 2002

Perspective		1
MG Kevin C. Kiley		
Operating at Ground Zero: Observations of an OR Nurse		3
MAJ John E. Eiland, AN, USA		
Anthrax: A Significant Biological Threat		8
MAJ Bret K. Purcell, MC, USA/LTC Michael J. Morris, MC, USA		
2001 ACP-ASIM Army Regional Meeting		13
COL Richard L. Marple, MC, USA		
2001 ACP-ASIM Abstract Winners – Poster	DISTRIBUTION STATEMENT A Approved for Public Release Distribution Unlimited	16
2001 ACP-ASIM Abstract Winners – Podium		18
Dentin Dysplasia Type I: A Case Report		20
LCDR Michael Wolfgang, DC, USN, et al		
Using Bitewing Film as a Substitute for Occlusal Radiographs		23
COL Steven L. Eikenberg, DC, USA/SSG Greg Courtright, USA		
Operation Shadow Warrior: A Quantitative Analysis of the Ultraviolet Radiation Protection Demonstrated by Various Headgear		25
MAJ Daniel J. Schissel, MC, USA		
Infection of Pediatric Hip Fracture: A Case Report		29
MAJ Kenneth F. Taylor, MC, USA/COL Kathleen A. McHale, MC, USA		
Recruitment and Retention of ARNG Nurses: A Qualitative Study		36
COL Rita M. Paxson, AN, ARNG/MG Marianne Mathewson-Chapman, AN, ARNG		
Risk Communication: The Leadership Tool for the 21st Century		40
COL Bradley D. Freeman, MC, USA		
Detecting Corneal Abnormalities in Potential Military Aviators		44
Thomas O. Salmon, et al		
AMEDD DATELINE		54
Wayne R. Austerman, PhD		

JOURNAL

U.S. ARMY MEDICAL DEPARTMENT
A Professional Bulletin for the AMEDD Community

The current issue and some back issues of the AMEDD Journal are available (Adobe Acrobat format) at <http://das.cs.amedd.army.mil/>.

LTG James B. Peake
The Army Surgeon General
Commander, U.S. Army Medical Command

MG Kevin C. Kiley
Commander, U.S. Army Medical Department
Center and School



COL James W. Kirkpatrick
Dean, Academy of Health Sciences
Neta T. Lesjak
Chief, Department of Academic Support and
Quality Assurance
Bruce Nelson
Editor
Don Aldridge
Associate Editor
LTC Michael J. Morris
Contributing Editor
Linda Nelson
Editorial Assistant / Desktop Publishing

Editorial Review Board

COL James M. Lamiell, Chairman
Chief, Clinical Investigation Regulatory Office

COL Thomas R. Cole
Chief, Consultant Div, U.S. Army Dental Command

COL George J. Dydek
Pharmacy Advisor, U.S. Army Center for Health
Promotion & Preventive Medicine

MAJ Rachel K. Evans
Research Physical Therapist, Mil Performance Div,
USA Research Institute of Environmental Medicine

COL Janet R. Harris
Chief, Department of Nursing Science, AHS

SGM Carolyn S. Miller
Corps-Specific Branch Proponent Officer, Enlisted
Corps, OTSG

COL Glenn W. Mitchell
Chief, Clinical Services Division, USA MEDCOM
& Chief Consultant, Medical Corps, OTSG

LTC Michael J. Morris
Chief, Physician Extenders Branch, Department of
Medical Science, AHS

COL Gary A. Vroegindewey
Asst Chief, Veterinary Corps & Corps-Specific
Branch Proponency Officer

By Order of the Secretary of the Army:
ERIC K. SHINSEKI
General, United States Army
Chief of Staff
Official:

JOEL B. HUDSON
Administrative Assistant to the
Secretary of the Army
DISTRIBUTION: Special

0131002

The Army Medical Department Journal (ISSN: 1524-0436) is prepared quarterly for The Surgeon General by the U.S. Army Medical Department Center & School, ATTN: MCCS-HSA, 2250 Stanley Road Ste 250, Fort Sam Houston, TX 78234-6150.

CORRESPONDENCE: Manuscripts, photographs, official unit requests to receive copies, & unit address changes or deletions should be sent to the Journal at the above address. Telephone: (210) 221-6916/7326, DSN 471-6916/7326.

DISCLAIMER: The Journal presents clinical & nonclinical professional information to expand knowledge of domestic & international military medical issues & technological advances; promote collaborative partnerships among Services, components, Corps, & specialties; convey clinical & health service

support information; & provide a peer-reviewed high quality print medium to encourage dialogue concerning healthcare initiatives.

Views expressed are those of the author(s) & do not necessarily reflect official U.S. Army or U.S. Army Medical Department positions, nor does the content change or supersede information in other Army Publications. The Journal reserves the right to edit all material submitted for publication.

CONTENT: Content of this publication is not copyrighted. Material may be reprinted if credit is given to the author(s).

OFFICIAL DISTRIBUTION: This publication is targeted to U.S. Army Medical Department units & organizations & other members of the medical community worldwide.

REPORT DOCUMENTATION PAGE

Form Approved
OMB No. 0704-0188

Public reporting burden for this collection of information is estimated to average 1 hour per response, including the time for reviewing instructions, searching existing data sources, gathering and maintaining the data needed, and completing and reviewing the collection of information. Send comments regarding this burden estimate or any other aspect of this collection of information, including suggestions for reducing this burden, to Washington Headquarters Services, Directorate for Information Operations and Reports, 1215 Jefferson Davis Highway, Suite 1204, Arlington, VA 22202-4302, and to the Office of Management and Budget, Paperwork Reduction Project (0704-0188), Washington, DC 20503.

1. AGENCY USE ONLY (Leave blank)		2. REPORT DATE January 2002	3. REPORT TYPE AND DATES COVERED Quarterly	
4. TITLE AND SUBTITLE U. S. Army Medical Department Journal			5. FUNDING NUMBERS	
6. AUTHOR(S) Bruce Nelson, Editor				
7. PERFORMING ORGANIZATION NAME(S) AND ADDRESS(ES) U. S. Army Medical Department Center and School Department of Academic Support and Quality Assurance AMEDD Journal Branch Fort Sam Houston, TX 78234-6160			8. PERFORMING ORGANIZATION REPORT NUMBER	
9. SPONSORING / MONITORING AGENCY NAME(S) AND ADDRESS(ES) U. S. Army Medical Department Center and School Building 2840 2250 Stanley Road Fort Sam Houston, TX 78234-6160			10. SPONSORING / MONITORING AGENCY REPORT NUMBER	
11. SUPPLEMENTARY NOTES				
12a. DISTRIBUTION / AVAILABILITY STATEMENT Approved for public release: Distribution is unlimited.			12b. DISTRIBUTION CODE	
13. ABSTRACT (Maximum 200 words) Clinical and nonclinical professional information designed to keep U. S. Army Medical Department personnel informed of healthcare, research, and combat and doctrine development information.				
14. SUBJECT TERMS Medicine - Periodicals; Military Medicine - Periodicals			15. NUMBER OF PAGES 56	
			16. PRICE CODE	
17. SECURITY CLASSIFICATION OF REPORT N/A	18. SECURITY CLASSIFICATION OF THIS PAGE	19. SECURITY CLASSIFICATION OF ABSTRACT	20. LIMITATION OF ABSTRACT Unlimited	

20020314 121

A New Role for the AMEDD

This is my first opportunity to comment in the *AMEDD Journal* on the events of September 11th that involved terrorist bombings of the World Trade Center and the Pentagon. These tragic events have profoundly changed the United States as a country and have altered forever how we perform our duties in the military every day. We have all experienced how the tightened security at military bases has altered schedules and initially caused a major disruption of beneficiary health care. This already difficult situation was made worse by the discovery of anthrax sent through the postal system. As a result, much of my time in the past several months has been heavily involved in keeping our forces safe and planning how the Army Medical Department will respond to these and other new threats.

The primary mission of the AMEDD is to support the fighting force. Our fellow AMEDD soldiers and civilians are performing that well-defined mission today in support of Operation Enduring Freedom and the Special Forces soldiers now actively involved in ending the reign of terror caused by Osama Bin Laden and his al-Qaida network. That role, the medical support of deployed forces in an overseas Theater of Operations, has been the mission of Army Medicine for almost our entire history. Since the events of September 11, however, we have recognized that our nation is also a Theater of Operations with its own requirements for forces and medical support. How the AMEDD supports the campaign of Homeland Security begun by our Commander-in-Chief and led by a Cabinet-level official is the hard intellectual challenge of our day. Unquestionably, a key piece of AMEDD support to Homeland Security is the integration of appropriate Chemical-Biological-Radiological-Nuclear and high-yield Explosive skills and tasks into every course taught by the AMEDD Center and School or contained in the Professional Postgraduate Short Course Program. This effort is a matter of direct, personal interest for The Surgeon General and deserves the attention of the entire AMEDD.

As an early response, plans have been made to provide Special Medical Augmentation Response Teams and medical contingency packages to support civil defense in the



Major General Kevin C. Kiley

event of another major catastrophe. Further work in this area is going on daily, involving the staff and faculty of the AMEDD Center and School and the MEDCOM staff.

The AMEDD does not come to this challenge unprepared or empty-handed. The U.S. Army and the Army Medical Department have always been on the forefront of technology to detect and combat terrorism and weapons of mass destruction. For instance, the United States Army Military Research Institute for Infectious Disease at Fort Detrick and the United States Army Military Institute for Chemical Defense at Aberdeen Proving Ground have devoted endless hours of research to protect our soldiers on the battlefield. Along with many other Army Medical Research and Materiel Command research institutions, and the numerous Army experts in these fields, the AMEDD is able to contribute much by providing our services to the country in the event of further terrorist attacks. General Shinseki's Army Strategic Campaign Plan for the transition of the Army to assist in the combat against terrorism includes 11 tasks assigned specifically to the AMEDD.

This edition of the *AMEDD Journal* touches upon several issues of particular interest. The lead article by MAJ John Eiland, an operating room nurse, details his observations after visiting Ground Zero, the site of the World Trade Center bombings, and the enormous devastation he witnessed firsthand. The second article by MAJ Bret Purcell, an infectious disease specialist from Brooke Army Medical Center, gives an overview of anthrax and the most recent medical information about the

release of this very lethal contagion through the postal system.

Other articles in this issue of the *AMEDD Journal* include:

- *2001 ACP-ASIM Army Regional Meeting*. This article details the recent American College of Physicians – American Society of Internal Medicine meeting held in San Antonio, TX, focusing on convention proceedings and organizational awards.

- *Case Abstracts from the ACP-ASIM Meeting*. These are summaries of the ACP-ASIM award-winning case reports in the Podium and Poster categories, selected at the 2001 convention.

- *Risk Communication: The Leadership Tool for the 21st Century*. The author discusses the role of effective communication to convey the risk analysis of hazards and the risk management actions necessary to minimize these hazards.

- *Operation Shadow Warrior: A Quantitative Analysis of the Ultraviolet Radiation Protection Demonstrated by Various Headgear*. This article investigates which Army-issue headgear provides the most protection against ultraviolet radiation.

- *Dentin Dysplasia Type I: A Case Report*. In this report, the authors describe a rare disturbance of dentin formation characterized by normal enamel but atypical dentin formation with abnormal pulpal morphology and outlines the approach to treating this disorder.

- *Infection of Pediatric Hip Fracture: A Case Report*. An unusual case of infection is chronicled after closed reduction and pinning of an intracapsular hip fracture in a child. An in-depth review of the literature is also provided.

- *Recruitment and Retention of ARNG Nurses: A Qualitative Study*. This article surveys the motivating factors for recruitment of nurses into the Kentucky Army National Guard and examines the reasons for which many commit to a 20-year career.

- *Using Bitewing Film as a Substitute for Occlusal Radiographs*. This is a case report describing where bitewing films were used in a field setting to determine the presence of foreign bodies in a patient suffering severe facial trauma.

- *Detecting Corneal Abnormalities in Potential Military Aviators*. The authors examine the use of the EyeSys Corneal Analysis System to measure the topographic elevation of the cornea to detect abnormalities.

Operating at Ground Zero: Observations of an OR Nurse

MAJ John E. Eiland, AN, USA†

The site of the World Trade Center (WTC) has become known as Ground Zero. No other term could be more appropriate. Regardless of the number of news accounts we see on television, there is absolutely no way to truly grasp the enormity of the situation without seeing, touching, and feeling it. I was given the opportunity to visit Ground Zero and speak with a number of individuals who had been on the scene from the beginning and will probably be there for the duration. I was afforded a chance to get advice "for the next time we need medical support" from those intimately involved with an event that has never before occurred on American soil.

On Friday, 21 September, I had an opportunity to visit the WTC area firsthand. I was sure I was well prepared for what I was about to see. I've been working in the Emergency Room/Operating Room (OR) since 1972 and have been in a few actual mass casualties over the past 30 years. Likewise, I thought I had already seen everything, having been glued to my television for the first several days.

But I was wrong ... very wrong. There was simply no way for me to honestly understand the scope, to take in the sheer enormity of the absolute devastation, or to truly "appreciate" it until I had been there. I'm not sure that I could faithfully explain what I saw (maybe "felt" is more accurate), so I would like to pass on what some of the individuals at the scene told me.

I was TDY at the U.S. Military Academy at West Point to conduct a Site Assistance Visit for the OR Technician Program at the Keller Army Community Hospital (KACH) Phase 2 site. Sergeant First Class Clarice Gross, Noncommissioned-Officer-in-Charge, OR/Central Materiel Services, offered to take me to Manhattan before I returned to Fort Sam Houston. She introduced me to a KACH physician who had been to the WTC a few times since the attack and he strongly encouraged me to take advantage of being in the area; to simply "walk by it – there's no other way to get a true perspective of the area. It is definitely a worthwhile learning venture that you could take back to the Academy" (of Health Sciences). He suggested I initially start by speaking to the personnel from the North Atlantic Regional Medical Command (NARMC) who were in the WTC area. He also

recommended wearing a uniform rather than civilian attire: "the uniform somehow gives them (the workers in the WTC area) some encouragement." That same advice was echoed by the staff working in Security/Emergency Operations at KACH.

As I introduced myself to several people, I explained that my presence was entirely unofficial and that my duty position at the Army Medical Department Center and School is Assistant Chief of the OR Branch. Each individual was adamant that I spend time at the scene. They had strong comments as they escorted me around Ground Zero and said it was imperative that I take back what I saw. They seemed genuinely pleased to see someone in a military uniform. "It makes me feel like somebody knows I'm out here. I'll take care of this mess. You go take care of yours," another policeman told me.

The first military – looking individual that SFC Gross and I found in the WTC area was an Air Force Lt Col. When I asked for the whereabouts of the NARMC personnel, he said, "Good luck, we're scattered everywhere. We just go where they need us at the time." He motioned in the direction that he believed would be his "best guess at the time" and we headed off for the New York Police Officer in the direction he sent us.

As I approached the WTC, I dug a 5 pound piece of granite out of a pile of dirt and debris. I asked if this is where the "bucket brigade" started dumping the wreckage. The policeman I was talking with explained that the rubble, including that chunk of rock, was not where the refuse had been dumped. It was, in fact, part of the "dust

cloud” that initially rolled down the streets as the towers collapsed.

As I trudged through the ankle-deep mud, I asked how long it took before the heavy tractors and machinery tore up the pavement. The area looked like a typical muddy Army training environment. It is only in hindsight that I now realize the “mud” was only at Ground Zero and not a block away or even around the corner. The fireman walking with me said, “It’s not mud. It rained pretty good yesterday. That’s ash and whatever makes ash; dust, building material, water, you know (and he paused for



Fig 1. Ground Zero rescuers (circled) are dwarfed by massive piles of debris.




Fig 2. The World Finance Center Winter Garden atrium lies partially demolished.

awhile) and other stuff . . . the stuff that made the ash in the first place.” He pointed to fellow firemen on the pile of what was left of 2WTC and said, “We’ve been here a week and a half now. It still makes them look like ants doesn’t it?” (Figure 1). He then pointed to what was left of the observation deck and said, “Imagine just getting to that thing and then trying to move it.” Even “minor” damage to the WTC area has a warlike appearance (Figure 2).

The Emergency Operations Center (EOC) Commander said “Yes, you must walk through this mess. Make sure the students AND the instructors know that this is real – what this is like – that they are probably going to have to deal with something just like this. Make sure they realize how absolutely vital it is that they learn their job and learn it well.” When he tried to explain the first moments following the attack, he described it like this, “During the first 30 seconds you’re going to forget everything you know. You won’t be able to think, process or even react in the slightest way. But those next 30 seconds are what will define who you are; they will define what you are. If you have trained right so that you REACT as you were trained, you can save yourself and your buddy. If you don’t, well, somebody is gonna die.”

As I entered a triage center near Liberty Command Post, I was struck by the empty beds; they looked unused. The Triage Medical Director said after the initial surge, “they’ve always been empty but I could have used a lot more chairs.” Most of his care had been given for burns, bruises, blisters, irritated eyes, and dehydration – and virtually all of his patients were “repeat offenders.” Even his more serious patients, the firemen and policemen hurt on the scene, refused to be evacuated. They came in each day to have their wounds rebanded (in some cases completely resutured) so they could return to duty. One fireman in particular was struck across the top of his forearm by falling glass, resulting in a very deep and severe cut. He was sutured, bandaged and put on the ambulance to be taken to the local hospital. The ambulance wasn’t even to the first corner when he told the ambulance crew, “You’re going the wrong direction. My ladder is the other way.” He then got out of the ambulance and headed back to join his crew. For 4 days he had been returning to the triage center to have his arm resewn and redressed. The senior medical staff told him that he risked losing the use of that muscle or, at the very least, a severe infection. The

fireman replied that he didn't "need that muscle to haul buckets. I'll go to the hospital when I find the rest of my crew and my work is done."

I asked the triage Senior Medical Officer on Duty what "lessons learned" I might take back with me. He said that what surprised him the most was how the paperwork utterly and completely failed the system. The paperwork was set up for an initial triage and then rapid evacuation of trauma victims. But as the Director had said, most of the patients, at least after the initial attack, were returning patients. "There was simply no way of tracking them, their injuries, or their treatment." A few days after the attack, they had instituted a method using "a stubby pencil and a legal pad" to establish some sort of record keeping mechanism. "It's getting better, but next time we need to have this on our laptops down here," he added. After the initial flood of patients, the sudden stop in the flow of injured was something else he was not prepared for, "I've never seen anything like it. The medical volunteers came out of nowhere and they just kept coming; we weren't ready for that kind of response. And then I never would have dreamed that I couldn't find work for them." Ten thousand volunteer health care workers descended upon lower Manhattan and "suddenly found they had nothing to do but watch the show." He felt that his staff had responded well and, even after 10 straight days, were holding up remarkably well although the lack of true trauma casualties was now starting to affect them. He noted that one Emergency Department physician had told him, "That's what I'm trained to do; what I've done for the past 20 years. Where's my patients?"

Another staff member of the Triage Center, a retired Vietnam Vet and about to retire again from the NYC Fire Department, emphatically added, "Go back and train 'em hard, then train 'em some more, then train 'em hard again. Train 'em so they can do their job without thinking. So that their job is second nature to them - so that their job is nothing more than a reaction." He said later that, "there was nothing, thank God, like this in Vietnam. But I'm damned glad I had my Army training." He went on to explain how he has routine, scheduled disaster training at the Fire Department yet how thoroughly inadequate the preparation and supplies had been for such an immense event. But "it's only because of our disaster drills that the injuries didn't lead to more deaths." I asked what he would

recommend to prepare and drill in the future. He answered with, "Just drill the basics. How can you prepare for 50,000 possible casualties at one time?"

On our way to be issued hard hats, we walked through a makeshift "mess tent." I talked to a policeman who had been there since the beginning. "We're working 16-hour shifts. We're lucky if we get four hours of sleep a night. But I think that's a good thing right now. I don't sleep too good anyway and it's the work that keeps me sane. I don't have to think about anything but doing my job." I asked him what he was going to do when he actually got back home. He almost smiled when he said, "Get something to eat that's not wrapped in plastic and something to drink that doesn't come out of a carton." His faint smile faded just as quickly when he looked away and finished, "Actually, I'd take anything that doesn't taste like this smell out here." It was odd to see so many firemen and policemen pass each other but never utter a word. It was like they were going out of their way to avoid that accidental contact with each other that might lead to conversation. I could see the "thousand-yard stare" in the eyes of the dozen or so firemen who were taking a break. They were lined up, sitting on a concrete barrier. They may be eating or drinking, but there wasn't a word spoken. They might nod at me, or maybe the uniform, as I walked by, but I felt as if they were looking right through me.

I spoke with a roving Stress Team made up of a Reserve Psychiatrist (an Army CPT) and two Army National Guard Psych Techs (one SPC and the other a SGT). They were one of several teams on duty around-the-clock. They speak with literally thousands of individuals each day. The most common discussions are recognizing the symptoms of stress and how to deal with it in a disaster setting. They emphasized the importance of the Stress Teams debriefing each other at the end of EVERY day, "to take care of the caretakers." The CPT warned me that even though I was "only passing through, I don't want you to be surprised when this has a overwhelming emotional impact on you." He explained that, aside from the profound scope of the devastation, it is the actual LACK of patients that can strike as hard as the scenes of the wreckage. Regardless of how much somebody has seen on the news, very few can be prepared for the sheer extent of the destruction. "And no one from a health care profession can be prepared for the absence of patients." That is, they

quickly find that the skills they had practiced for years are completely useless. “That actual absence of injuries can lead to a severe depression due to a feeling of being powerless, of helplessness and eventually even to hopelessness. It’s hard to reconcile the extent of the total devastation and then find that there’s nothing for you to do here.”

I was urged to go to the top of a building that stood directly across the street from the north tower. The Director of Security took me to the top of “his building” and out on to the roof. From 51 stories up, the destruction was even more overwhelming (Figures 3 and 4). By the time I arrived, more than 70,000 tons of debris had been removed and yet it appeared as if they had only just begun. The smoke that was still billowing from the looming piles of rubble gave a hazy appearance to an otherwise crystal clear morning (Figure 5). Later that afternoon, when I walked through the piles of debris, I found my shoes were scorched and the soles melted. Some firemen told me they have had to replace their boots “a couple times a week.” When I felt as if I had seen enough, I asked to leave and started back towards the door when I was told “Walk slower, you’re shaking my building.” A triage center was set up in the lobby of that very same building. “You wouldn’t believe the initial chaos,” he said. He explained that it was the extraordinary numbers of relief workers as well as those who were evacuated that rapidly led to a shutdown of all communications. The phone system went completely dead and the cell phone traffic quickly overwhelmed the system’s capacity. “And here I have



Fig 3. Partial skeletal remains of WTCs 1 and 2.

a triage center in my lobby that can’t call the EOC around the block.”



Fig 4. Looking east from three World Finance Center roof, showing extent of devastation.



Fig 5. Billowing smoke from Ground Zero obscures Manhattan skyline.

I talked to many individuals: firemen, policemen, active duty and reserve component military personnel, volunteer doctors, and private security officers for neighboring buildings. A universal theme emerged: to paraphrase, “There was no ‘us,’ ‘we,’ or ‘them’ . . . regardless if we have trained together for the past 10 years and arrived enmasse as a team, the entire WE became the team. As we were needed, with what skills we came with

and what we could do for the particular mission, we then made our teams. Structure was easy – whoever was senior, he was the one in charge. What uniform he wore or job he had didn't matter. In the absolute first moments with the instant chaos there was a 'who's in charge here' mentality but that rapidly changed. Now, 10 days later, each profession or organization is beginning to cordon off their duty or area of operations. I guess that's as normal as it was for us to simply do what was needed in the very beginning."

As I said previously, there was nothing that could have prepared me for what I experienced. The one thing that stays with me even now is the smell. As I was about six blocks away, it was sort of like the smell when you light the fireplace for the first time each season. But as I got closer, it began to take on a sickening stench like the landfills where we used to take our trash once a month. As I got closer still, the smell became that of garbage on fire. Finally, as I began to walk through Ground Zero, it became a smell that I could actually taste. I could taste it

even if I held my nose; a smell I could taste even as I breathed out. It was still in my uniform the next day when I opened the closet. As the people working the site said, the smell is in everything you eat or drink.

There is no really good way to sum up my time at Ground Zero. I certainly was not ready for the immensity and extent of the destruction, nor the power of the emotions that welled up every time I allowed myself to remember that it was the result of an act of hate. However, I know that I am now more prepared to train my students ... I am more prepared to "take the lessons learned" to the instructors ... and I am much more prepared to make sure that those in my charge are, indeed, equipped with the skills they will need.

AUTHOR:

†Army Nurse Corps, U.S. Army. Major Eiland is the Assistant Chief, Operating Room Branch, Department of Nursing Science, Academy of Health Sciences, U.S. Army Medical Department Center and School, Fort Sam Houston, TX.

CORRECTION

In the article "Depleted Uranium: Managing Battlefield Risks" published in the October-December 2001 of the Journal, the **Introduction** paragraph on page 31 contained the following sentence: "Unfortunately, approximately 35 U.S. soldiers were in the vehicles hit by DU fired by friendly forces during ODS." The sentence should read: **"Unfortunately, approximately 35 U.S. soldiers were in the vehicles hit by DU fired by friendly forces during ODS and consequently, have embedded fragments of DU in their bodies."**

The article's authors regret any confusion this error might have caused.



CHANGE TO THE JOURNAL EDITORIAL BOARD

Major Rachel K. Evans has replaced LTC Thomas Sutlive as the Army Medical Specialist Corps representative on the Editorial Board. Major Evans is a Research Physical Therapist assigned to the Military Performance Division, U.S. Army Research Institute of Environmental Medicine, Natick, MA.

Anthrax: A Significant Biological Threat

MAJ Bret K. Purcell, MC, USA†
LTC Michael J. Morris, MC, USA††

As the world has tragically witnessed, asymmetric war has now breached the shores of the continental United States resulting in large numbers of civilian and military casualties. These forms of terror are diverse, effective and often easily achievable by our enemies. Although the recent act of biological terrorism using anthrax has not been directly linked to the events of 11 September 2001, this organism and many other biological agents pose significant threats to both our military and civilian populations. This article briefly reviews the pertinent information concerning the microbiology, pathogenesis, clinical manifestations, and treatments of anthrax related diseases. In addition, several key Internet web sites are listed at the end of this article to provide general as well as detailed information on anthrax and biological warfare (BW).

Introduction

Until recently, anthrax had remained just a potential agent of BW.¹ Although extensive research and development of anthrax spores as a weapon of mass destruction has been conducted by numerous groups and nations across the globe, the effective use of this agent as a weapon of terror had not been successfully implemented until the introduction of anthrax-laden letters into the United States Postal System (USPS) and the subsequent delivery of several of these letters. To date, this criminal act has resulted in 11 cases of pulmonary anthrax with five deaths, and 11 cases of cutaneous anthrax, seven of which have been confirmed, of nonlethal cutaneous anthrax.² Over 32,000 persons have received initial prophylactic antimicrobial therapy; approximately 5,000 of these individuals have been identified as having potentially significant anthrax exposure requiring 60 days of prophylactic therapy. Greater than 300 postal and other facilities have been found to be contaminated, with some of these sites requiring extensive decontamination. In particular, the Hart Senate Building recently underwent chlorine dioxide gas treatment in an attempt to reduce the overall spore burden without significantly effecting office materials or documents. Expenses incurred from these few tainted letters has been estimated to have cost the USPS alone approximately \$2.8 billion dollars.

The identification of the individuals responsible for this event and the source of the highly refined anthrax

endospore preparations are under extensive investigation by numerous local, state, and federal law enforcement officials. Analysis of thousands of environmental and clinical samples has been conducted by the U.S. military and the Center for Disease Control (CDC) in Atlanta, GA. Working in collaboration, the epidemiologic and criminal investigations are being performed by the CDC and the Federal Bureau of Investigation, respectively.

The U.S. Army has played a key role in analysis of environmental and clinical samples from these events. As of 30 November 2001, in the National Capital Area alone, the U.S. Army Medical Research Institute of Infectious Diseases (USAMRIID) has received and analyzed 7,181 specimens and U.S. Armed Forces Institute of Pathology has processed 1,963.³ The combined North Atlantic, Great Plains, Western and Pacific Regional Medical Commands for the Army have processed 4,539 samples. Specimens from across the country continue to arrive at numerous military facilities. The U.S. military will continue to play a central role in the defense of the nation against the present and any future bioterrorism attacks.

Microbiology

Bacillus anthracis, the etiologic agent of anthrax, is a gram-positive, spore-forming bacillus. This aerobic organism is nonmotile, catalase positive and forms large, gray-white to white, nonhemolytic colonies on sheep-

blood agar plates.⁴ On nutrient agar containing 0.7% sodium bicarbonate, the bacilli form large capsules and appear as mucoid colonies when incubated at 37°C in an atmosphere of 5-20% carbon dioxide.⁵ The bacteria grown *in vitro* form long chains, but in clinical specimens they may appear as large bacilli in short chains of two or three organisms.

Clinical samples such as blood, cerebrospinal fluid, pleural fluid, or skin lesion material such as vesicular fluid or eschar can be tested for anthrax using culture and bacterial staining of material. Preliminary identification of *B anthracis* is performed at a level A hospital laboratory as established by the CDC Laboratory Response Network (LRN) for Bioterrorism.⁶ These labs should utilize Biological Safety Level 2 (BSL 2) precautions for processing clinical samples or testing bacterial isolates suspected to contain *B anthracis*.⁷ Note, however, all environmental samples suspected of containing *B anthracis* endospores need to be sent to a lab which possesses a higher level of biological containment (BSL 3 LRN lab levels B, C, or D). In addition, it is recommended by the CDC that gloves, laboratory coat, and safety glasses or eye shield be used when handling specimens or performing tests. However, anthrax vaccination is not currently recommended for routine clinical laboratory personnel.⁷

Confirmation of *B anthracis* is available through many LRN level B State Public Health laboratories.⁶ These tests are based on visual identification of a capsule produced by the isolate, most often by India ink staining and either bacterial lysis by gamma-phage or direct fluorescent antibody assays. Additional verification as well as characterization of the strain and highly specialized testing is performed at the LRN level C lab (CDC) or a level D lab (USAMRIID and CDC).

Pathogenesis

Anthrax is primarily a zoonotic disease of herbivores worldwide.^{1,3} In the U.S., it is sometimes found as outbreaks in unvaccinated domestic herds such as cattle, goats, and sheep. *B anthracis* has also been associated with wildlife epidemics in deer, elk, and bison and these foci probably serve as the natural reservoir for anthrax spores in the environment. The transmission of anthrax to humans has, in the past, been through contact with contaminated

animal products or infected animals. These human infections have been divided into three categories: cutaneous, gastrointestinal and inhalational. Cutaneous anthrax accounts for approximately 95% of the naturally occurring cases of anthrax in the U.S.

The bacterium *B anthracis* can enter the host either in a dormant, highly stable endospore state or as a vegetative bacterial form from contaminated animals through either abrasions in the skin, forming cutaneous anthrax, or via the mucous membranes following the consumption of contaminated meat producing gastrointestinal anthrax.^{4,5,8} Pulmonary anthrax is produced by inhalation of endospores into the lungs where, if the particle size is between 1-5 μm , these organisms will be deposited into the alveoli of the lung. Pulmonary macrophages will then engulf the endospores and transport them to the mediastinal lymph nodes where the endospores germinate to form vegetative cells. These replicating bacteria produce toxins which are responsible for the clinical manifestations and virulence of anthrax.

Protective antigen (PA), edema factor (EF) and lethal factor (LF) proteins comprise the bacterial exotoxins of anthrax.^{4,5,8} The PA protein facilitates the entry of the EF and LF into the host cells by binding to specific cell receptors and forming a membrane channel into the mammalian. These two factors are thought to act in combination to modify cellular function, inhibit macrophage and polymorphonuclear cell activity, and produce cytotoxic effects. The EF is a calmodulin-dependent adenylate cyclase which increases intracellular levels of cyclic-adenosine mono-phosphate and, in turn, disrupts water homeostasis resulting in massive edema. In addition, this exotoxin has been shown to inhibit neutrophil function and cytokine production. The LF exotoxin is a zinc-metalloprotease that inactivates mitogen-activated protein kinase which stimulates macrophages to release interleukin-1B and tumor necrosis factor and is probably the cause of the severe toxic effects and sudden death of infected individuals.

Clinical Manifestations

Cutaneous Anthrax.

Of the cases of anthrax that occurred prior to this

year, approximately 95% of the cases in the U.S. were cutaneous. Either occupational or recreational exposure to animals or animal products accounted for most of these cases and the lesions were found to primarily occur on the extremities, head, or neck of these patients. The incubation period for the most recent outbreak is 1 to 7 days, however, in some cases it may be as long as 12 days post-exposure. The lesion begins as a painless, pruritic vesicle or papule and evolves into an ulcer often with satellite lesions surrounding the site over the next 3 to 7 days. The fluid within these vesicles is clear or serosanguinous containing few leukocytes but many large gram-positive bacilli provided antimicrobial therapy has not been initiated prior to biopsy. The ulcer will continue to progress and form a characteristic black eschar despite the initiation of antibiotic treatment. Often, extensive tissue edema is noted surrounding these lesions and of the 11 recent cases of cutaneous anthrax, 8 of 11 cases demonstrated local edema, 7 of 11 developed eschars, and 7 of 11 experienced systemic symptoms of fever, headache, and lymphadenopathy.^{9,10} If untreated, the mortality rate is stated to be 20%, whereas with treatment the rate is < 1%. Of the 11 patients either having confirmed or suspected lesions of cutaneous anthrax recently, all have survived. An internet web site, listed at the end of this article, provides a site available for viewing photographs of a variety of cutaneous anthrax lesions with comparison photographs of lesions associated with brown recluse spider bites.

Gastrointestinal Anthrax.

The consumption of undercooked, anthrax-contaminated meat results in the development of gastrointestinal infection in 2 to 5 days.^{4,5,8} Symptoms include severe abdominal pain, nausea, vomiting, and fever. The disease progresses rapidly with the development of bloody diarrhea and signs of an acute abdomen with rebound tenderness. Ascites often develops with the peritoneal fluid appearing clear to purulent and *B anthracis* can frequently be cultured. Oropharyngeal anthrax may also develop causing cervical edema and local lymphadenopathy which can potentially cause dysphagia and respiratory compromise. Intestinal biopsy with histopathological evaluation reveals ulcerations, significant tissue edema, mucosal necrosis, mucosal and submucosal lymphadenitis. Mortality in untreated cases ranges between 40 and 60%.

Pulmonary Anthrax.

Inhalational or pulmonary anthrax occurs when particles of between 1-5 μm and containing between 8,000 and 15,000 endospores reach the alveoli of the lung. The endospore is phagocytized by alveolar macrophages and these cells migrate to the mediastinal lymph nodes. The endospores then germinate, forming vegetative bacteria and these organisms produce the exotoxins responsible for mediastinal lymph node enlargement, hemorrhage, and necrosis. In all the current cases of pulmonary anthrax, chest radiographs appeared abnormal (10/10 cases), demonstrating either infiltrates or consolidation, widened mediastinum, and/or large pleural effusions (10/10 cases).^{10,11} Of the 11 cases of inhalational anthrax, seven were associated with pulmonary infiltrates or consolidation.¹² Large and recurrent hemorrhagic pleural effusions were also prominent in several of these recent cases.

The incubation period for this disease is 1 to 6 days. The time of onset of clinical symptoms may vary based upon the inhaled endospore burden and immunologic status of the person exposed.^{4,5,8} The initial phase of the illness is characterized by fever, malaise, myalgia, chest discomfort, nonproductive cough, or abdominal pain. In this outbreak, gastrointestinal symptoms of abdominal pain, nausea and vomiting were common (9/10), and chest discomfort was also found to be prominent in seven of 10 cases.¹¹ Within 2 or 3 days of these initial symptoms, the patient rapidly enters the second phase of the illness with symptoms of high fever and chills, episodes of diaphoresis, acute dyspnea or stridor, shock, hypothermia, often resulting in rapid death within 1 or 2 days. In the current cases, five of the 11 patients presented in the second phase of the illness and all five died.^{8,9,12-15}

Laboratory findings in the recent 10 cases demonstrated elevated average white cell count of $9.8 \times 10^3 \text{ mm}^3$ (range 7,500 to 13,300/ mm^3) with a left shift in seven patients.¹¹ Elevated transaminases defined as Serum Glutamic Oxaloacetic Transaminase or Serum Glutamic Pyruvic Transaminase > 40 were present in nine patients, hypoxemia in six, metabolic acidosis in two, and elevated creatinine in only one patient. Blood cultures also found to yield growth of *B anthracis* if collected prior to antibiotic therapy (7/7 patients). These cultures grew *B anthracis* in a range of 12-24 hours with a median of 18 hours.

However, bacterial growth could be detected within 6 hours of plating on sheep-blood agar of the cerebrospinal fluid.¹⁴

Treatment

The current treatment guideline established by the CDC for cutaneous and pulmonary anthrax were published in the Oct 16th, 26th, and Nov 2d issues of the Morbidity and Mortality Weekly Report (MMWR) prepared by the CDC.^{7,10,16} These guidelines are available on the CDC Internet web site listed at the end of this article. The brief summary outlined below lists the major recommendations on treatment and prophylaxis, however, we recommend accessing the references listed for complete details on the current recommendations on treatment of anthrax.

Cutaneous Anthrax.

Briefly, the treatment for cutaneous anthrax can be divided into two groups.^{9,16} The first group includes those patients that have signs of systemic infection, extensive edema, or lesions on the head or neck. These patients should be treated with intravenous antibiotics until clinical improvement and stability are noted. Then it is recommended that these patients complete a 60 day course of antibiotics if the infection is found to be associated with a bioterrorist event. This recommendation is based upon the possible simultaneous aerosolized anthrax exposure and the potential of latent infection.

The second group are those patients who lack any signs of systemic infection and only present with a cutaneous lesion. These individuals may be treated with oral antimicrobial therapy with close patient follow-up. The recommended initial therapy for adults is oral ciprofloxacin 500 mg twice daily or doxycycline 100 mg twice daily.^{9,16} For children, ciprofloxacin at 10-15 mg/kg every 12 hours is recommended, not to exceed one gm/day; doxycycline at 100 mg every 12 hours for children greater than 8 years old and that weigh more than 45 kg. Children under 45 kg and greater than 8 years old, the recommendation is 2.2 mg/kg doxycycline every 12 hours. Children less than 8 years old, it is recommended that doxycycline be given at 2.2 mg/kg every 8 hours. Amoxicillin at 80 mg/kg/day, divided every 8 hours, may be substituted in children after clinical improvement has

been demonstrated. In pregnant women, ciprofloxacin or doxycycline at the adult doses are recommended, however, fluoroquinolones and tetracyclines are not recommended during pregnancy except for life-threatening infections due to potential adverse effects on the bone and teeth of the fetus. With clinical improvement, oral amoxicillin 500 mg 3 times a day may be substituted for either ciprofloxacin or doxycycline in pregnant women. Immunocompromised persons can be treated using the same guidelines outlined above for immunocompetent adults and children.

Gastrointestinal and Pulmonary Anthrax.

The CDC treatment guidelines are identical for both gastrointestinal and pulmonary anthrax.^{9,16} For adults, intravenous ciprofloxacin 400 mg every 12 hours or doxycycline 100 mg every 12 hours plus one or two additional antibiotics are recommended. These antibiotics include clindamycin, rifampin, vancomycin, imipenem, ampicillin, chloramphenicol, penicillin, and clarithromycin. The fact that bacterial protein synthesis is inhibited by the antibiotic clindamycin makes the choice of this drug as augmented therapy very appealing, particularly in light of the extreme toxic effects of *B anthracis* exotoxins. Of note, if meningitis is suspected in cases of pulmonary anthrax, doxycycline should not be used as primary therapy due to poor central nervous system penetration of this drug, whereas rifampin should be added to the primary therapy. For children, intravenous ciprofloxacin 10-15 mg/kg every 12 hours or intravenous doxycycline at the doses provided for cutaneous anthrax plus an additional one or two antimicrobial agents. The additional antibiotics are the same as those listed above for the treatment of adult infections. The treatment for pregnant women and immunocompromised patients are identical to those for adults and children listed above.

Post-Exposure Prophylaxis for Prevention of Pulmonary Anthrax.

The CDC guidelines on post-exposure prophylaxis for prevention of inhalational anthrax are found in the 19 October 2001 issue of MMWR.⁷ In adults, pregnant women, and immunocompromised patients, oral ciprofloxacin 500 mg twice daily or doxycycline 100 mg twice daily should be used for a total of 60 days for those

individuals who have had a significant risk of exposure to aerosolized anthrax. Children should undergo antimicrobial prophylaxis with either oral ciprofloxacin or doxycycline using the same dosing schedule as outlined for cutaneous anthrax treatment. When antibiotic susceptibility of the anthrax strain is determined and if found susceptible to penicillin, then pregnant women and children should be changed to amoxicillin 80 mg/kg divided every 8 hours and not to exceed 500 mg 3 times per day. Of note, stains of *B anthracis* are resistant to both trimethoprim/sulfamethoxazole and cephalosporins and these antibiotics should not be used in suspected or confirmed cases of anthrax. And finally, if anthrax is suspected in any case, Infectious Disease consultation is highly recommended.

References

1. Pile JC, JD Malone, EM Eitzen, AM Friedlander. Anthrax as a potential biological warfare agent. *Arch Intern Med.* 1998;158:429-434.
2. Anthrax, Human USA (39). December 6, 2001. Promed. www.promedmail.org. Archive number: 2001112062963.
3. Personal Communication: LTC William F. Nauschuetz, Clinical Pathology Service, Brooke Army Medical Center, Fort Sam Houston, TX.
4. Pew DP. *Bacillus anthracis* (Anthrax). In: *G.L. Mandell et al. Principles and Practice of Infectious Diseases.* 5th ed. Churchill Livingstone: Philadelphia, PA; 2000:p 2215-2220.
5. Swartz MN. Recognition and management of anthrax. *NEJM.* November 29, 2001. Preprint version from Web site: www.nejm.org/specialnotice/
6. Biological and chemical terrorism: Strategic plan for preparedness and response. *MMWR.* April 21, 2001;49(RR-4):1-14.
7. Update: Investigation of anthrax associated with intentional exposure and interim public health guidelines. *MMWR.* October 2001;50(41):889-893.
8. Dixon TC, M Meselson J, Guillemin and PC Hanna. Anthrax. *NEJM.* 1999; 341(11):815-826.
9. Bartlett JG. Anthrax Update (11/26/01). Provided to SHEA by Dr Bartlett. 2001.
10. Update: Investigation of bioterrorism-related anthrax and interim guidelines for clinical evaluation of persons with possible anthrax. *MMWR.* November 2, 2001;50(40):941-948.
11. Jernigan JA, et al. Bioterrorism-related inhalational anthrax: The first 10 cases reported in the U.S. *Emerging Infect. Dis.* 7(6):933-944.
12. CDC Satellite/Webcast CDC responds: Clinical diagnosis and management of anthrax -- lessons learned. November 29, 2001. Available at: www.bt.cdc.gov
13. Borio L, et al. Death due to bioterrorism-related inhalational anthrax: Report of 2 patients. *JAMA.* November 28, 2001;286(20):2554-2559.
14. Bush LM, BH Abrams, A Beall, CC Johnson. Index case of fatal inhalational anthrax due to bioterrorism in the U.S. Pre-print version. *NEJM.* November 29, 2001.
15. Mayer TA, et al. Clinical presentation of inhalational anthrax following bioterrorism exposure: Report of two surviving patients. *JAMA.* November 28, 2001;286(20):2549-2553.
16. Update: Investigation of bioterrorism-related anthrax and interim guidelines for exposure management and antimicrobial therapy. *MMWR.* October 2001;(42):909-919.

AUTHORS:

†Medical Corps, U.S. Army. Major Purcell is the Chief, Infectious Disease Clinic and a member of the Infectious Disease Staff, Brooke Army Medical Center, Fort Sam Houston, TX.

††Medical Corps, U.S. Army. Lieutenant Colonel Morris is the Chief, Physician Extenders Branch, Department of Medical Science, Academy of Health Sciences, U.S. Army Medical Department Center and School, Fort Sam Houston, TX.

Web Site References

Excellent sources for information concerning BW agents:

www.usamriid.army.mil/education/bluebook.html
www.nbc-med.org
www.hopkins-biodefense.org
www.bt.cdc.gov
www.idsociety.org
www.asmsa.org/pcsrc/bioprep.htm
www.usfa.fema.org
www.shea-online.org

Archived diagnosis and treatment guidelines for BW agents:

www.jama-assn-assn.org

Specific articles concerning anthrax:

Emerging Infectious Diseases Journal issue containing the report on the first 10 cases of pulmonary anthrax in the 2001:
www.cdc.gov/ncidod/eid/vol7no6/jernigan.htm

Recent anthrax updates in MMWR:

www.cdc.gov/mmwrorld/mmwr.html

Clinical clues to the diagnosis of cutaneous anthrax:

www.info.dom.uab.edu/gorgas/anthrax.html
www.content.nejm.org/cgi/content/full/345/22/1611
www.content.nejm.org/cgi/content/full/345/22/1646

Consensus report for anthrax preparedness published in 1998:

www.bt.cdc.gov/Agent/Anthrax/Consensus.pdf

Inglesby TV, et al. Anthrax as a Biological Weapon: Medical and Public Health Management. *JAMA.* 1999;281(18):1735-45 at:
www.jama.ama-assn.org/issues/v281n18/ffull/jst80027.html

Suspicious mail and package guidelines provided by USPS:

www.usps.com/news/2001/press/pr01_1010tips.htm

APIC/CDC Recommendations for Healthcare Facilities:

www.apic.org/bioterror

International Team of CDC's Emergency Operations Center

E-mail Address:

eocinternational@cdc.gov

2001 ACP-ASIM Army Regional Meeting

COL Richard L. Marple, MC, USA†

The best of Army Internal Medicine was on display at the 18th Annual American College of Physicians-American Society of Internal Medicine (ACP-ASIM) Army Regional Meeting. A record 340 participants attended the meeting, co-sponsored by the Henry M. Jackson Foundation for the Advancement of Military Medicine, at the San Antonio Convention Center and the Menger Hotel in San Antonio, TX, from 15 to 18 November 2001. The ACP-ASIM is the nation's largest medical specialty society. Its mission is to enhance the quality and effectiveness of health care by fostering excellence and professionalism in the practice of medicine. The ACP-ASIM Army Regional Meeting was first held in 1983. Since 1999, it has been held biennially in San Antonio, sponsored by Brooke Army Medical Center's (BAMC) Department of Medicine. Army internists from across the globe returned to the home of the Army Medical Department (AMEDD) to attend. Nurse practitioners, physician assistants, and medical students also were in attendance.

Army internists are experts in adult health care. They are known by several names such as "Doctor of Internal Medicine," "Internist," or "General Internist." They are sometimes confused with *interns* by the general public. Interns are doctors who are trainees. All Army internists have trained for 3 years and many have taken an additional 2-3 years of training and specialize in areas such as cardiology, pulmonary, gastroenterology, and others. The term "internist" comes from the historical notion that adult diseases can be categorized on the basis of the structure of the human *internal* organ systems. Internists study these diseases and are experts in adults medicine, ranging from preventive medicine and wellness care, to care for chronic illnesses such as diseases of the heart and blood vessels, diabetes, high blood pressure, cancer, infections, rheumatism, and diseases of old age.

Despite an ominous world situation, this year's Army Region ACP-ASIM meeting was vibrant and included

many new additions. The Army ACP-ASIM meeting had been cancelled only twice in its history; in 1989 for the San Francisco earthquake, and in 1990 for Desert Shield and Storm. This year's meeting was opened by Brigadier General Daniel Perugini, Commander of the Great Plains Region and BAMC. The Brass Quintet from the 323d Army Band, Fort Sam Houston, TX, added a classic touch and played for the posting of the colors by the BAMC Color Guard in true military fashion. Special guest and Immediate Past President of the ACP-ASIM, Dr Sandra Fryhofer, served as the College Representative. Army Region ACP-ASIM Governor, COL Nathan Erteschik, pointed out that this is the first time a past ACP-ASIM President has attended an Army Regional meeting. Colonel Erteschik, in his first year as the ACP-ASIM Governor, is also the Internal Medicine Consultant to the Surgeon General and was available throughout the meeting to discuss issues related to college, career, and future military assignments with all members. Ms Judy Spahr, from the ACP-ASIM administration, addressed member's questions and concerns as well. As a service, MAJ Gurr of the Medical Corps Branch met with many Army members to review Officer Evaluation Reports and help prepare for promotions and school consideration boards.

The Plenary Session focused on general and military medicine. Guest speakers came from institutions across the country such as the Mayo Clinic, Emory University, and the Memorial Heart Institute and presented, among other topics, the latest on recognizing and treating pulmonary sarcoidosis, thrombocytopenia, and common medical symptoms. Military Medicine took center stage starting with Major General Kevin C. Kiley, Commanding General, Army Medical Department Center and School and Commander, Fort Sam Houston, TX. Major General Kiley presented a thorough update on the AMEDD Activities to include new medical technologies for the field, AMEDD's role in Operation Enduring Freedom, and a view of our future. Colonel (Ret) Artie Shelton

spoke on the lessons from operations other than war. Colonel (Ret) Shelton was the Commander of the 42d Combat Field Hospital which took part in Operation Restore Hope in Somalia in 1993. In his presentation, COL (Ret) Shelton demonstrated how a stable situation of supporting humanitarian food distribution turned into a combat environment. He addressed how native populations may hide or become the aggressor and how an unpredictable and developing combat environment significantly impacted on the 42d and its mission.

On Friday, a special lunchtime address was given on the emergency medical response after the September 11th attack on the Pentagon. Colonel James Geiling, Commander of the DiLorenzo Tricare Health Clinic at the Pentagon in Washington, DC, was across the Potomac River at the onset of the attack. Age-old disaster problems of movement, communication, infrastructure, and process rebuilding were highlighted in this excellent presentation. Prior to his assignment to The Pentagon in July 2000, COL Geiling had attended USA War College Senior Service College Fellowship at the Office of Emergency Preparedness, Department of Health and Human Services, and became aware of the need for an updated, well-organized emergency medical plan. Colonel Geiling also pushed to rehearse that plan. A Pentagon-wide scenario was played out in May 2001. Eerily, the mass casualty scenario consisted of a jet liner from Reagan National Airport crashing into the Pentagon in nearly the same place as the actual attack. This test of the Pentagon Emergency Plan and the medical response improved the unit's performance during the actual attack immeasurably. Security, communication, and command/control were problems, but excellent cooperation between the fire and police departments, Pentagon security, and medical assets maximized the best of a bad situation. Colonel Geiling showed rare video footage shot at the scene by a combat cameraman. Sharing these experiences of field medicine creates an understanding of the challenges, sets expectations for the austere environment, and helps prepare military physicians for future field duty.

The Army Internal Medicine Women's Physician Group, led by COL Alice Mascette, held a working breakfast discussion on challenges facing women in medicine. The panel consisted of Dr Sandra Fryhofer of Emory University, Atlanta GA, Dr Stephanie M. Levine of

the University of Texas Health Science Center, San Antonio TX, and Dr Ellen Pinholt of Walter Reed Army Medical Center, Washington, DC. Topics of mentoring, family issues, and career choices both inside and outside of the Army were openly discussed with audience participation.

The ACP-ASIM meeting is an appropriate time to recognize excellence in Army internal medicine in six diverse and challenging areas:

The Army Region Laureate Award honors the Fellows and Masters of the ACP-ASIM who have demonstrated by their example and conduct an abiding commitment to excellence in patient care, education, or research, and in service to their community and the College. Recipients of this award carry the title Laureate of the Army Region. This year's recipients were MG (Ret) Leslie M. Burger, FACP; COL (Ret) James J. Johnson, FACP; COL (Ret) Arlene J. Zaloznik, FACP; and COL (Ret) Charles F. Miller, FACP.

The Master Teacher Award is designed to honor a member of the ACP-ASIM in the rank of Fellow or higher who has demonstrated the qualities of master mentor and teacher. This year's honoree is LTC Lisa Lynn Zacher, FACP, FCCP.

The Colonel William Crosby Superiority in Research Award honors a member or associate of the Army Chapter of the ACP-ASIM who has demonstrated excellence in the design, performance, and publication of peer-reviewed research which exemplifies the characteristics displayed by COL (Ret) William Crosby, Medical Corps. Colonel Crosby is an internationally recognized expert in Hematology. He was instrumental in establishing the Army Blood Banking Fellowship. This year's recipient is LTC Allen Taylor.

The Colonel Robert H. Moser Internist of the Year Award recognizes an outstanding general internist for superior clinical practice in a MEDDAC setting for two or more years. The recipient must demonstrate clinical competence, professionalism, humanistic values, and compassion toward patients. The 2001 Award was presented to MAJ David Vetter.

The Excellence in Operational Medicine Award

honors an ACP-ASIM member who has demonstrated dedicated care of patients, outstanding leadership, and novel innovation in an Operation Medical environment. Major Mark E. Polhemus was selected as this year's honoree.

The Student Recognition Award was established by the ACP-ASIM, through the USUHS Department of Medicine, to recognize outstanding achievement by a U.S. Army graduating medical student who best demonstrated exemplary academic and personal achievement in their performance on medical clerkships during medical school. The 2001 recipient is 2LT Matthew E. Griffith, MS, USAR.

Afternoons were spent in specialty sessions addressing updates in medical treatment and technology. Internal medicine specialty sessions were held in cardiology, endocrinology, hematology/oncology, gastroenterology, general medicine, military medicine, infectious disease, pulmonary, and rheumatology. As special guests of the Army Region ACP-ASIM, medical students had a great opportunity to see the depth and flexibility of internal medicine and to sample most of its disciplines. Students from as far away as Dallas, Houston, and Galveston, TX, and the Uniformed Services University, Bethesda, MD, were treated to a pre-course at BAMC followed by the ACP-ASIM meeting. The pre-course, designed by MAJ Stephen Harrison, a Gastroenterologist at the Department of Medicine, introduced students to the diverse opportunities offered by a career in internal medicine and to the modern facilities and high tech services of BAMC. Students were treated to hands-on experiences in cardiology auscultation, gastroenterology endoscopy, and rheumatology joint injections. At the meeting, students met with Chiefs and Program Directors of the Departments of Medicine from every Army Medical Center.

The meeting ended on a high note with the first annual Jay P. Sanford History of Medicine presentation. Members received an in-depth look at Stonewall Jackson, the most capable and decorated Civil War General. Colonel Kenneth McAllister gave an illuminating lecture on the life, health, and death of Stonewall Jackson and how it may have altered the outcome of several Civil War battles.

A cutting-edge update in internal medicine, our future with the AMEDD as well as our history, unforgettable lectures from experienced field veterans, networking, interviewing, and educational advancement are hallmarks of the Army Regional ACP-ASIM Meeting. Next year's Army Regional ACP-ASIM meeting will be hosted by Walter Reed Army Medical Center and will be held in Arlington, VA, on 20-23 November 2002. Students and internists interested in future ACP-ASIM Meetings can look at one of the following sites for more information:

<https://scoop.hjf.org/apps/internet/events.nsf>
<http://www.acponline.org/chapters/army/>

or call

COL Richard Marple, 210-916-5313, Brooke Army Medical Center

COL Nathan Erteschik, 910-907-6359, Governor of the Army ACP-ASIM Region

LTC Greg Argyros, 202-782-6205, Walter Reed Army Medical Center

AUTHOR:

†Medical Corps, U.S. Army. Colonel Marple is the Chief of Primary Care and Assistant Chief, Department of Medicine, Brooke Army Medical Center, Fort San Houston, TX.

Intravenous Immunoglobulin (IVIG) Clinically Causes Significant Hyperviscosity Predicated by Hyperproteinemia

CPT Beth Steinberger, MC, USA; MAJ Teresa Coleman, MC, USA;
Dwight David Eisenhower Army Medical Center, Fort Gordon, GA

Background: IVIG therapy is being increasingly associated with peri-infusional thromboembolic events. The mechanism by which IVIG therapy contributes to these events is unclear. We recently reported severe hyponatremia and hyperosmolality in association with a CVA occurring post IVIG therapy in a patient with Guillian-Barre syndrome. The patient also had hyperproteinemia and an osmolar gap suggesting pseudohyponnatremia. We surmised that the patient had become hyperviscous due to a hyperproteinemia and initiated a prospective observational study to evaluate the incidence of hyperviscosity occurring after IVIG therapy and its relationship to serum sodium, protein, osmolality, and the serum osmolar gap.

Methods: Patients were study eligible if receiving IVIG at a dose of 2gms/kg. All patients underwent pre therapy determinations of serum glucose, sodium creatinine, total protein, viscosity, osmolality, ethanol, ketones, and lipids. Patients were excluded for known hyperviscosity, GFR <50, ketosis, severe hyper or hyponatremia, or significant hyperlipidemia. Serum glucose, sodium, total protein, viscosity, and osmolality were repeated 6 hours after the initiation of therapy, 24 hours after the last dose of IVIG, and on post-treatment days 10 and 15. The osmolar gap was calculated at each time point. Serum glucose, sodium, total protein, viscosity, osmolality, and the osmolar gap were compared with paired *t* tests pre and post IVIG infusion. The correlation between serum viscosity, sodium, protein, osmolality, and osmolar gap pre and post IVIG therapy were examined at each time point with a Correlation coefficient. Multivariate analysis was performed with a stepwise linear regression.

Results: To date, 12 IVIG infusions have been prospectively studied. Univariate analysis revealed a statistically significant increase in serum protein ($P=.03$), decrease in serum sodium ($P=.00$), and decrease in calculated serum osmolality ($P=.01$) 6 and 24 hours after the initiation of IVIG therapy. Twenty-four hours after the completion of IVIG therapy the serum viscosity also significantly increased ($P=.05$). In a multivariate analysis, hyperproteinemia at the 24-hour time point remained statistically significant ($P=.00$).

Discussion: These data clearly demonstrate that a state of transient hyperviscosity occurs following IVIG therapy attributable to hyperproteinemia. We suspect that this hyperviscosity may contribute to the thromboembolic phenomena being increasingly reported with IVIG therapy. To our knowledge, this is the only study to definitively document hyperviscosity following IVIG therapy and to explore its possible mechanisms. Our data also suggest that hyperproteinemia, hyponatremia, and elevated osmolar gap are useful markers of hyperviscosity for the clinician unable to obtain immediate serum viscosity determinations.

Acute Structural Right Ventricular (RV) Changes in a Porcine Model of Pulmonary Embolism (PE)

CPT Norma L. Merced, MC, USA; CPT William C. Dixon, MC, USA; LTC Sheri Y.N. Boyd, MC, USA;
MAJ James L. Furgerson, MC, USA; Bernard J. Rubal, PhD; John A. Ward, PhD;
Brooke Army Medical Center, Fort Sam Houston, TX

Background: Previous studies have shown that RV dilation occurs in as many as 30-40% of patients presenting with moderate to large PE. Other studies have shown that acute RV strain can result in myocardial injury as seen by elevations in cardiac enzymes. RV dilation has also been shown to be an adverse prognostic factor after PE. However, there have been no experimentally controlled studies evaluating the acute effect of PE on the RV. The purpose of this study was to document in a swine model the effects of acute PE on RV structure and function via serial transthoracic echocardiography (TTE) and cardiac enzymes measurements.

Methods: A moderate to large sized PE was induced in 11 Yorkshire swine by injecting clotted autologous blood into the pulmonary venous circulation followed by angiography. Real time TTE was performed at baseline, during PE and at 1 and 2 hours post PE to evaluate acute RV changes. Mean RV area and fractional area of shortening were measured by offline planimetry. Troponin I (Tnl) and CK-MB were measured at baseline, 3, 8, and 12 hours post PE. Mean arterial pressure, mean pulmonary arterial pressure and heart rate were continuously monitored.

Results: PE were confirmed in all swine by angiography. TTE images were interpretable in 10 of 11 animals. Mean RV area increased from $5.47 \pm 0.99\text{cm}^2$ to $12.36 \pm 4.40\text{cm}^2$ immediately post PE ($P < 0.001$). In addition, mean RV fractional shortening decreased from 0.33 ± 0.10 to 0.22 ± 0.16 immediately post PE ($P < 0.03$). Interestingly, RV area was not significantly different from baseline by 1 hour post PE. Both Tnl and CK-MB had a statistically significant increase ($P < 0.005$) when baseline levels were compared to mean peak values.

Conclusion: This study confirms results from prior investigators that acute RV strain from an acute PE can result in myocardial necrosis and detectable cardiac enzymes. Most importantly, this study supports prior findings of significant RV dilation following PE, however, our data suggest that these findings may be a transient event and therefore clinically undetectable by the time of presentation.

What is the Marginal Cost of Scanning for Coronary Calcium? A Decision Analysis of the Downstream Costs of Screening Election Beam Computed Tomography (EBCT)

CPT Bruce Greenberg, MC, USA; MAJ Patrick O'Malley, MC, USA; LTC Allen I. Taylor, MC, USA;
Department of Medicine, Walter Reed Army Medical Center, Washington, DC

Background: The cost implications of coronary calcium screening in asymptomatic patients are undefined. Like many prior new medical technologies, the use of this test is growing before its role and effects have been determined. The relationship between the incremental accuracy of EBCT, leading to wider identification of patients at risk of coronary heart disease, and the cost of the study and incidental findings are the major components of the cost benefit equation.

Methods: We used data from a consecutive sample of 1,000 asymptomatic Army personnel presenting for a screening physical and EBCT to develop a decision analysis comparing the costs associated with a screening strategy via the Framingham Risk Index (FRI) with and without EBCT. All costs associated with EBCT, including test costs, costs of further testing, treatment and incidental scan findings, were included. The primary outcome was the marginal cost per additional patient diagnosed with increased cardiovascular risk. Chosen risk thresholds included either FRI of 1%/yr or a calcium score in the upper quartile for age/gender.

Results: Use of FRI + EBCT increased the detection of "at risk" cases from 7.2% (FRI alone) to 22.4%. Incidental findings occurred in 8%, of which 19% were considered major findings. The cost associated with using the EBCT+FRI was 10-fold that of FRI alone. The marginal cost per additional "at risk" case identified by EBCT + FRI was \$2,994. Marginal cost was sensitive to the cost of EBCT and to its relative value for identifying at risk cases. The cost per additional case identified by the combined approach ranged from \$1,800 to \$15,000 as the absolute gain in case identification decreased from 23% to 3%. Multiway sensitivity analysis defined a threshold of approximately 10% for the absolute increase in case identification by EBCT + FRI, below which the cost per additional case identified rose exponentially. The cost per additional case found was not sensitive to the incidence of incidental findings.

Conclusion: Adding EBCT to conventional risk prediction methods is expensive, particularly when the percentage of additional cases identified as "at risk" falls below an absolute difference of 10%. Incidental scan findings affect an important minority of screened individuals, but do not appear to appreciably affect the cost per additional case identified.

Immunosuppressive Drugs Improve Survival of Phytohemagglutinin (PHA)-Stimulated Lymphocytes but Not Tumor Cell Lines When Exposed to Chemotherapeutic Agents

CPT Bryan Fisk, MD; LTC George Peoples, MD; Departments of Internal Medicine and General Surgery, Walter Reed Army Medical Center, Washington, DC

While chemotherapy remains the cornerstone in the treatment of most advanced, metastatic cancers, effective therapeutic regimens often remain elusive. This has led to increased interest in immunotherapy as a possible alternative modality for treatment. CD8⁺ cytotoxic T-lymphocytes (CTL) have a central role in effective anti-tumor responses. Furthermore, animal studies have demonstrated that this immune response can be enhanced by treatment with chemotherapeutic agents. We have previously demonstrated that, in vitro, chemotherapy can enhance antigen presentation by tumor cells, leading to increased cell killing. Furthermore, CTL can deplete cells that are relatively more chemo resistant, providing a rationale for future sequential chemotherapy-immunotherapy regimens. However, such an approach is limited by the well-described immunosuppressive effects of chemotherapy. Chemotherapeutic agents typically have their greatest effect on rapidly proliferating and highly metabolic cells, making activated lymphocytes susceptible. We hypothesized that survival of activated lymphocytes can be improved by inducing a transitory state of cellular "hibernation" during periods of chemotherapeutic exposure.

To test our hypothesis, we first determined which of four immunosuppressant drugs (Cyclosporine, Mycophenolic Acid, Methylprednisolone, and Rapamycin) were most effective at inhibiting proliferation of PHA-stimulated lymphocytes from two separate donors, while having the least effect on viability. Rapamycin at 12 $\mu\text{g/ml}$ met the criteria with inhibition of expansion to 28% of control wells in 2/2 normal donor samples and without significant negative effect on viability. High dose methylprednisolone at 1.0 J. $\mu\text{g/ml}$, was the next most effective, inhibiting proliferation at 60% of control in one sample and 85% in another, without any negative effect on viability. Cells exposed to these two agents and subsequently washed and recultured retained ability to proliferate in-vitro, though the kinetics of expansion after Rapamycin were delayed and decreased compared to control. Rapamycin and methylprednisolone at the noted doses were evaluated for their ability to protect PHA-stimulated lymphocytes survival with three chemotherapeutic drugs: Adriamycin (ADR), Etoposide (VP-16), and Vinblastine. Rapamycin improved survival in both donor cultures exposed to ADR, from 32% to 69% and 29% to 49%. Rapamycin increased viability in 1 of 2 of the VP-16 exposed cultures, from 41 to 56% (nonsignificant in remaining culture). Prednisone also had a protective effect on viability: increased survival in presence of ADR from 32% to 63% in one of 2 donor cultures, and increased from 42% to 60% and 41% to 51% during exposure to VP-16. Interestingly, Vinblastine alone had no negative effect on proliferation or viability when compare to control samples, though it had very significant activity in tumor lines, suggesting that it may be a good agent for combined chemotherapy-immunotherapy even without immunosuppressant protection. With evidence suggesting that immunosuppressive therapy can protect lymphocytes, it was important to demonstrate that there was not a similar effect on tumor cells. Two tumor cell lines, SKOV3 (ovarian) and LNCAP (prostate) were cultured under the same conditions as for the lymphocytes. However, unlike the lymphocyte cultures, the sensitivity of the tumor lines to chemotherapy was unaffected. Further studies are ongoing at this time and new findings will be discussed. In conclusion: (1) Immunosuppressive therapy was capable of reversibly inhibiting proliferation of actively dividing lymphocytes without increasing cell death; (2) Use of these agents during periods of exposure to chemotherapeutic agents resulted in improved cell viability, and finally; (3) Immunosuppressive therapy had no protective effect on viability in 2/2 tumor cell lines. These findings suggest possible utility in using immunosuppressants during periods of administration of chemotherapy. Such a strategy may allow for a future combined therapeutic approach to include immunotherapy earlier in treatment of advanced malignancies.

Family Member Presence During Cardiopulmonary Resuscitation (CPR): A Survey of U.S. and International Critical Care Professionals

CPT Bruce M. McClenathan, MC, USA; COL Kenneth G. Torrington, MC, USA; Catherine F. Uyehara, PhD; Tripler Army Medical Center, Hawaii

Objective: Recent International Emergency Cardiovascular Care (ECC) and CPR Guidelines 2000 recommended that health care professionals allow family members to be present during resuscitation attempts. To study whether critical care professionals support these recommendations, we developed a survey instrument to assess their opinions and to determine reasons why they oppose family witnessed resuscitation (FWR).

Methods: A survey covering CPR experience, opinions of FWR, as well as demographic data was designed. This instrument was distributed to physicians, nurses and allied health care professionals at the international meeting of the American College of Chest Physicians; San Francisco, CA from 23-26 October 2000.

Results: Five hundred-ninety two U.S. and international physicians, nurses and allied health care professionals were surveyed about their opinions on family member presence during CPR. Twenty percent of physicians would allow family member presence during adult CPR, compared to 40% of nurses and allied health care workers ($P=0.006$), while 14% of physicians and 25% of nurses and other allied health care professionals would allow family presence during a pediatric code ($P=0.068$). Variations between U.S. and international professionals were not observed. There was a significant difference between U.S. professionals' opinions based on regional location. The Northeast professionals were less likely to allow FWR during either an adult or pediatric code ($P=0.016$ and <0.001 respectively). Midwest professionals were more likely to allow FWR during an adult code ($P=0.002$). Those with no previous experience in resuscitation were more likely to allow FWR during an adult code ($P=0.043$). Health care professionals disapproved of FWR because of fear of psychological trauma to family members, performance anxiety affecting the CPR team, and medicolegal concerns.

Conclusions: Our survey of 592 U.S. and international critical care physicians, nurses, and allied health professionals demonstrated that most physicians do not support current recommendations provided by the ECC and CPR guidelines of 2000.

Potential False Sense of Security with Ultrasound-Assisted Cannulation of the Internal Jugular (IJ) Vein

CPT Michael Piesman, MC, USA; LTC George Giacoppe, MC, USA;
Pulmonary and Critical Care, Department of Medicine,
Madigan Army Medical Center, Fort Lewis, WA

Background: Several million central venous catheters are inserted each year for volume resuscitation, administration of intravenous medications and hyper-alimentation, hemodynamic monitoring, hemodialysis access, and venous access for patients requiring frequent blood tests. Complication rates vary from 5-10% with cannulation of the IJ vein. Ultrasound use has been reported to reduce complications, improve success rates, and decrease procedure time. We report data on IJ vein cannulation from our institution and examine the impact of ultrasound introduction on complication rates.

Methods: From calendar year (CY) 1996 to CY 2000, 453 records of patients undergoing IJ vein cannulation in our intensive care unit were included for data analysis. Variables recorded were date, operator name, site, type of catheter inserted, whether ultrasound was used and if any complications occurred. A distinction was made whether ultrasound assistance was used for real-time guidance or for scouting the site of insertion. Residents were given a handout explaining the use of ultrasound but a formal training program was not instituted during this period. The goal was to determine if ultrasound use decreased complication rate.

Results: A total of 453 procedure records were identified. Two hundred thirty-eight procedures were performed by post-graduate year (PGY) 1 level interns, 136 procedures by PGY 2 residents and 47 procedures by PGY 3 residents. Fellows and staff performed 32 procedures during this period. By specialty, medicine residents had the most procedures performed (157), followed by transitional interns (103) and then surgery residents (86). Emergency medicine residents, family practice residents, and obstetrics and gynecology residents were also included. Anatomical technique for central lines placed through the right IJ vein was used in 240 procedures with 13 (5.4%) reported complications. Ultrasound assistance was utilized in 120 procedures with nine reported complications (7.5%). Left IJ cannulation using the anatomical technique was performed in 62 patients with six complications (9.7%) and in 31 patients using ultrasound guidance with seven (22.6%) complications.

Conclusions: This retrospective analysis of nearly 5 years of data demonstrates that the introduction of ultrasound to assist with IJ vein cannulation did not decrease complications at our institution. Caution should be used when relying on this technique without formal ultrasound training and/or assistance of a more senior house-officer or staff.

Dentin Dysplasia Type I: A Case Report

LCDR Michael Wolfgang, DC, USN†
LTC Edward B. Fowler, DC, USA††
LTC Lawrence G. Breault, DC, USA†††
CDR Keith E. Sonnier, DC, USN††††
COL David M. Lewis, DC, USA†††††

Introduction

Dentin dysplasia, or “rootless teeth,” is a rare disturbance of dentin formation characterized by normal enamel but atypical dentin formation with abnormal pulpal morphology.¹ This morphology includes partial or complete obliteration of the pulp, defective root formation, and periapical radiolucencies without an obvious etiology.² Both primary and permanent dentitions are affected.

In 1920, Ballschmiede was the first to publish a report on this dysplastic condition of dentin.³ His report described the spontaneous exfoliation of multiple rootless teeth in a family of seven children. In 1939, Rushton published a report on the same phenomenon in a single individual and referred to this condition as dentin dysplasia.⁴ Shields and coworkers utilized radiographic and histologic appearances to divide dentin dysplasia into types I and II.⁵

Dentin dysplasia type II (coronal dentin dysplasia) has the following characteristics: (1) The primary dentition has a brown or blue opalescent color. Although radiographs reveal various degrees of pulpal obliteration, the size and shape of the primary teeth are considered within normal limits. (2) The permanent dentition has a normal clinical appearance. Radiographs generally reveal abnormally enlarged pulp chambers coronally, with only some extension of the pulp into the root. Furthermore, numerous pulp stones are frequently present.⁵ Wesley and associates have described this pulpal appearance as “thistle-tube” shaped.⁶

Dentin dysplasia type I (radicular dentin dysplasia) has the following characteristics for both the primary and permanent dentitions: (1) normal appearing clinical

crowns; (2) short, conical, or absent roots; (3) pulpal obliteration, except for a thin crescent shaped pulpal remnant parallel to the cementenamel junction (CEJ); and (4) periapical radiolucencies.⁵ The following is a case report of a patient seen for a routine dental examination who was subsequently diagnosed with dentin dysplasia type I.

Case Report

A 41-year-old white male Navy Chief Petty Officer reported to the Comprehensive Clinic with a chief complaint of “I would like to get some of my teeth problems taken care of.” His medical history was noncontributory. A soft tissue exam revealed localized edema and erythema of the gingiva at Nos. 2 and 9 (maxillary right second molar and maxillary left central incisor, respectively). Probing depths were 7-10 mm on the mesial aspect of No. 2 and the palatal surface of No. 9. Additionally, there was moderate to severe bleeding on probing and subgingival calculus associated with these teeth. Tooth No. 2 presented with a Miller’s Class 3 mobility (the tooth was clinically depressible within the socket).⁷ All other areas of the dentition had probing depths of 3 mm or less, no bleeding on probing, and only physiologic mobility.⁷

A periapical radiograph demonstrated root resorption and crescent shaped pulp chamber obliteration located near the CEJ of tooth No. 2 (Figure 1). A panoramic view revealed that teeth Nos. 2, 4, 5, 6, 11, 12, 13, 22, 27, and 28 shared this particular phenomenon of pulpal obliteration and root resorption (Figure 2). Tooth No. 2 tested negative to both electric pulp testing and thermal tests.

Physical examination revealed no abnormalities and a

review of systems showed no disorders. Laboratory tests were ordered to determine the serum calcium, organic phosphate, and alkaline phosphate levels. The results of these studies were all within normal limits.

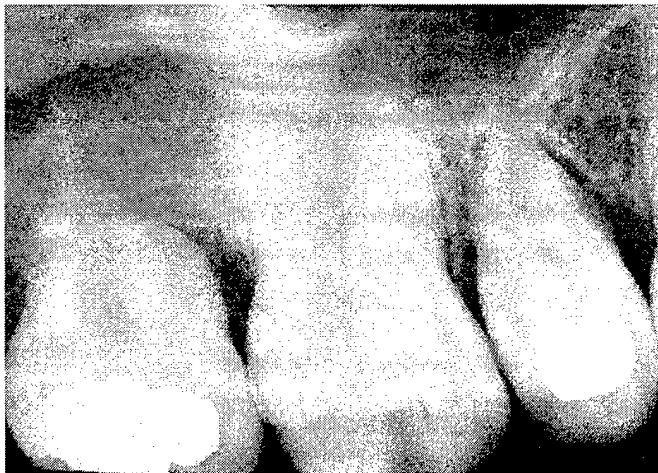

Fig 1. Periapical radiograph demonstrating crescent pulpal obliteration and short root structure of maxillary molar (Tooth No. 2).

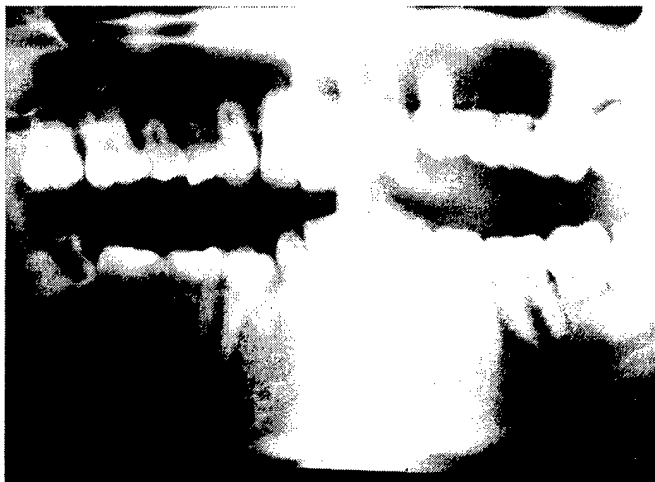

Fig 2. Panoramic radiograph demonstrating several teeth with short roots and pulpal obliteration.

The treatment plan was to maintain tooth No. 9 for esthetics. Tooth No. 2 was to be extracted due to the extreme loss of attachment and excessive mobility. After obtaining local anesthesia, this tooth was extracted with forceps and submitted to the oral pathology department for histologic evaluation.

The gross specimen of the maxillary right second molar revealed a normal appearing crown with ice cream cone shaped roots (Figure 3). Low power histologic

examination demonstrated relatively normal coronal dentin. However, the pulp chamber was malformed and dysplastic dentin was observed with an attenuated root formation (Figure 4). Medium power examination demonstrated areas of dysplastic nodular dentin formation (Figure 5). The microscopic diagnosis from the oral pathologist was dentin dysplasia type I.

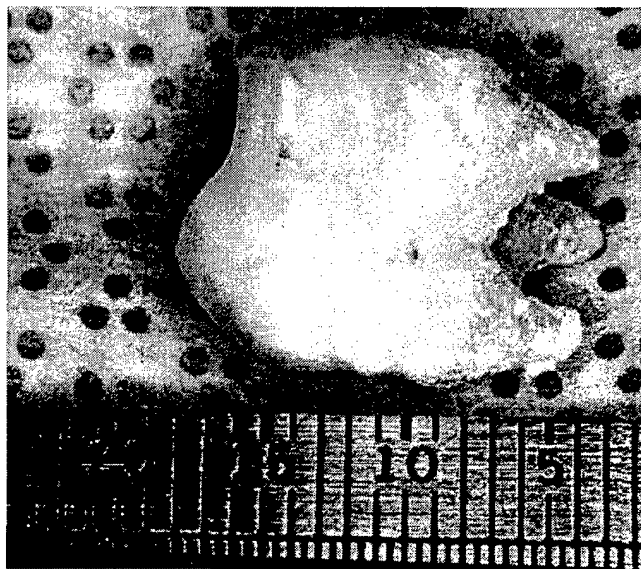


Fig 3. Extracted tooth No. 2.

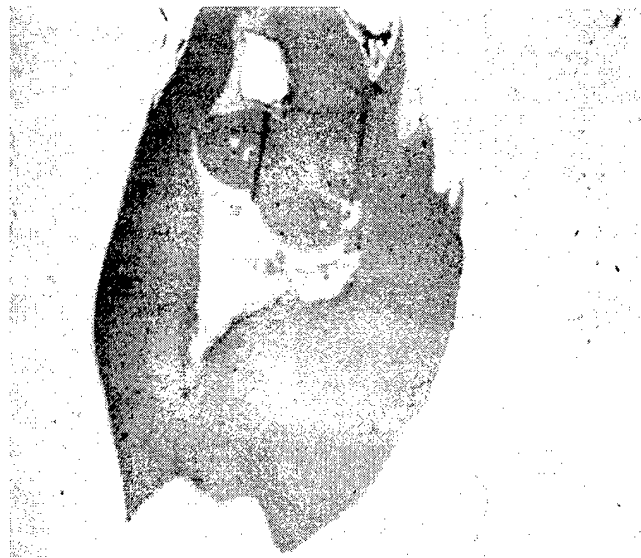


Fig 4. Low power histologic examination demonstrating relatively normal coronal dentin with a malformed pulp chamber, dysplastic dentine, and attenuated root formation.

Discussion

The case report demonstrates the clinical features of

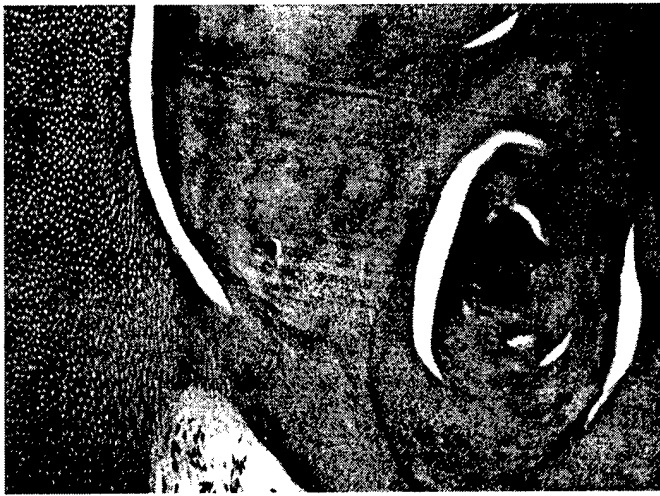

Fig 5. Medium power histologic examination demonstrating areas of dysplastic nodular dentin formation adjacent to relatively normal dentin.

dentin dysplasia type I as described by Witkop.⁸ This process can be easily differentiated from dentin dysplasia type II, and dentinogenesis imperfecta. In dentin dysplasia type I, there is obliteration of the pulp chamber by osteodentin, the roots are severely shortened, and periapical radiolucencies without a definitive cause can be seen.⁸ In dentin dysplasia type II, there is partial pulpal obliteration by amorphous dentin, true denticles are present, the roots are typically of normal shape and length, and the coronal pulp chamber is enlarged, while the radicular pulp is extremely narrow.⁹ Dentinogenesis imperfecta has the characteristics of abnormal color of deciduous and permanent dentitions with marked attrition, bulbous crowns with cervical constrictions at the CEJ, smaller than normal roots, and eventual pulpal obliteration.¹⁰ Dentinogenesis imperfecta can be associated with osteogenesis imperfecta.¹¹

There is no treatment for dentin dysplasia. Prognosis is dependent upon the occurrence of periapical pathology or extreme mobility that often necessitates tooth extraction. Additionally, teeth may exfoliate due to increased mobility. In this case report, 10 teeth exhibited the radiographic appearance consistent with dentin dysplasia, yet only two teeth had severe dental disease clinically. One tooth was extracted, while the anterior tooth was maintained for

esthetic purposes. Histologic examination of the extracted tooth confirmed the diagnosis of dentin dysplasia.

References

1. Shafer WG, Hine MK, Levy BM. *A Textbook of Oral Pathology*. Philadelphia: W.B. Saunders Co;1983:61-63.
2. Logan J, Becks H, Silverman S, Pindborg JJ. Dentinal dysplasia. *Oral Surg Oral Med Oral Pathol*. 1962;15:317-333.
3. Ballschmiede: Dissertation, Berlin, 1922. Quoted in Herbert EH, Apffelstaedt M. *Malformations of the Jaws and Teeth*. New York: Oxford Press; 1930:286.
4. Rushton MA. A case of dentinal dysplasia. *Guys Hosp Rep*. 1939;89:369-373.
5. Shields ED, Bixler D, el-Kafrawy AM. A proposed classification for heritable human dentine defects with a description of a new entity. *Arch Oral Biol*. 1973;18:543-553.
6. Wesley RK, Wysocki GP, Mintz SM, Jackson J. Dentin dysplasia type I: Clinical, morphologic, and genetic studies of a case. *Oral Surg Oral Med Oral Pathol*. 1976;41:516-524.
7. Miller SC. *Textbook of Periodontia*, 3d ed. Philadelphia: Blackston;1950:125.
8. Witkop CJ. Hereditary defects of dentin. *Dent Clin North Am*. 1975;19:25-45.
9. Giansanti JS, Allen JD. Dentin dysplasia, type II, or dentin dysplasia, coronal type. *Oral Surg Oral Med Oral Pathol*. 1974;38:911-917.
10. Ranta H, Lukinmaa PL, Waltimo J. Heritable dentin defects: nosology, pathology, and treatment. *Am J Med Genet*. 1993;45:193-200.
11. Blattner RJ, Heys F, Robinson H. Osteogenesis imperfecta and odontogenesis imperfecta: hereditary opalescent dentin. *J Dent Res*. 1942;21:325-326.

AUTHORS:

†Dental Corps, U.S. Navy. Lieutenant Commander Wolfgang is the Head of Comprehensive Dentistry, Naval Dental Center, Pearl Harbor, Honolulu, HI.

††Dental Corps, U.S. Army. Lieutenant Colonel Fowler is Chief, Periodontics, U.S. Army Dental Activity, Fort Wainwright, AK.

†††Dental Corps, U.S. Army. Lieutenant Colonel Breault is the Chief, Periodontics, U.S. Army Dental Activity, Schofield Barracks, Honolulu, HI.

††††Dental Corps, U.S. Navy. Commander Sonnier is Command Consultant for Periodontics, Naval Dental Center Southeast, Branch Dental Clinic, Naval Air Station, Jacksonville, FL.

†††††Dental Corps, U.S. Army. Colonel Lewis is Chief, Oral Pathology, U.S. Army Dental Activity, Walter Reed Army Medical Center, Washington, DC.

Using Bitewing Film as a Substitute for Occlusal Radiographs

COL Steven L. Eikenberg, DC, USA†
SSG Greg Courtright, USA††

Introduction

Dentoalveolar and maxillofacial trauma are commonly reported injuries in a military population.¹ Occlusal film is an important diagnostic aid to detect foreign objects and to determine the extent and displacement of fractures that are the result of trauma. The occlusal radiographic image is also a useful diagnostic tool to supplement other dental radiographs.² Occlusal film images aid in detecting the position of impacted teeth, the buccolingual extension of bony lesions, calculi in salivary glands and ducts, and retained roots.³

Panographic film is commonly used for the detection of fractures. However, field dental treatment facilities (DTFs) do not have extraoral panographic radiograph capability. Even when a panographic x-ray system is available, there are some limitations to its diagnostic capabilities. Panographic images are not recommended to localize foreign objects in soft tissue as loss of detail, distortion, and superimposition of objects outside the local trough can produce confusing shadows.⁴

Bitewing and periapical films can be used to detect foreign objects in the soft tissue surrounding the oral cavity by placing the film in the buccal vestibule, between the teeth and the buccal mucosa. This technique is inferior for several reasons. Any foreign object apical to the vestibule will not be detected and these films are smaller than occlusal film, therefore multiple images may be required to detect and localize foreign bodies.⁵ Also, because images of the teeth are not captured on the radiograph, there are no anatomical reference points for the dentist to use in order to localize a foreign body.

Clinical Report

A 24-year-old soldier reported to a Forward Army Field DTF during a training exercise at Fort Bragg, NC.

The patient reported that he "stumbled in the dark" and hit his face on a tree trunk. He arrived at the clinic approximately 3 hours after the injury had occurred. His chief complaint was an intraoral laceration on the inferior labial mucosa.

The patient was anaesthetized with lidocaine 2% containing 1:100,000 epinephrine. The lacerated area was irrigated with normal saline and necrotic tissue and tissue tags were removed from the injured area. No foreign material was located in the soft tissue during the debridement and irrigation. An occlusal film was requested to determine if there were any radiopaque foreign bodies, such as composite resin embedded in the tissue.

An occlusal radiograph was requested because the tooth images captured on an occlusal view would serve as a reference point to assist the dentist in locating any foreign objects. However, the x-ray set of this remote field DTF did not contain any occlusal film. Because of the long travel time to a fixed facility clinic, it did not seem practical to evacuate the patient to, or obtain occlusal film from, another dental facility. It was decided to improvise an occlusal film utilizing available bitewing film.

The standard dental x-ray field set (UA 1720, NSN 6545-01-141-9472) contains DF-50 occlusal film and DF-42 bitewing film (Eastman Kodak Company, Rochester, NY). The occlusal film is 3 x 2.25 and the bitewing film is 1.06 x 2.125. To improvise occlusal film from bitewing film, we removed the bite tabs from three bitewing film packets. The orientation dots of three film packets were placed in a straight line with the two end film packets overlapping the middle film packet by approximately 1/16. The three film packets were then taped together (Figure 1). A thin 2 x 3 piece of cardboard was taped to three bitewing films to create a stable film packet. In this case, we obtained the cardboard from a meal, ready-to-eat

entrée box. The packet was placed inside a plastic bag to provide an infection control barrier.




Fig 1. Three DF-42 film packets taped together to create an occlusal film packet.

The film packet was exposed using a Siemens Dentotime x-ray unit at 70kvp, 7 ma, with an exposure time of 0.5 seconds. The bitewing films were manually processed and read individually and as a group on a view box (Figure 2). A foreign body was detected on the radiograph and removed from the wound. A second occlusal film was made to confirm that all foreign objects had been removed. The area was sutured utilizing 4-0 Dexon in the deep portions of the wound and 4-0 silk on the buccal mucosa. The patient was placed on antibiotics and given a nonnarcotic analgesic.

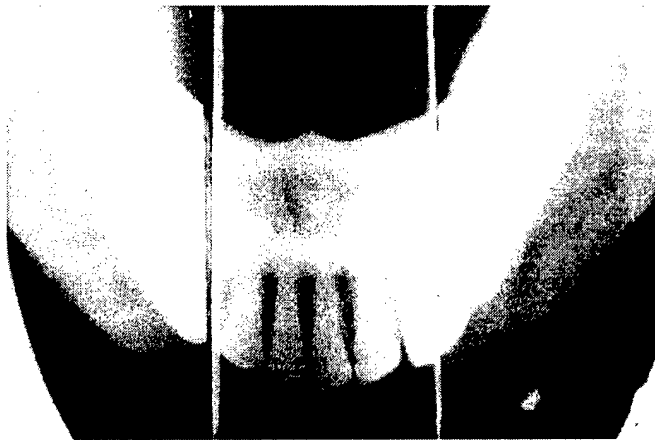


Fig 2. Processed bitewing films oriented to present an occlusal image.

We have continued to use this technique to obtain occlusal images in the field DTF. This method also works

well when utilizing self-developing film in place of conventional dental film. When treating pediatric patients in a humanitarian support mission, a smaller occlusal film can be made using just two of the bitewing film packets.

Conclusion

- This technique to obtain an occlusal radiographic image can be used in any dental clinic or field DTF that does not have occlusal film in stock.

- If an occlusal image of a pediatric patient is desired, two DF-42 bitewing films can be used to create an image approximately 2 x 2.

- Patients who present to the clinic with an intraoral laceration resulting from trauma, should be questioned during the review of "past dental history" to determine if any cosmetic restorations may have been lost as a result of the trauma.

References

1. Ludwig WE, et al. Dental Emergencies Occurring Among Navy-Marine Personnel Serving in Vietnam. *Mil Med.* February 1974;Vol 150:121-123.
2. Cohen G, Burns R. *Pathways of the Pulp.* 3d ed. C.V. Mosby;1979:497.
3. Oral Surgery Trauma Procedures. Review Book. Federal Services Board in General Dentistry Review. December 7, 1995:91:3.
4. Stafne E, Gilbilsco J. *Oral Roentgenographic Diagnosis.* 4th ed. Philadelphia: W.B. Saunders; 1975:401.
5. Tai CC, Miller PA. The Occlusal Radiograph Revisited. *Oral Health.* 1994;11:47-50.

AUTHORS:

†Dental Corps, U.S. Army. At the time this article was written, LTC Eikenberg was assigned to the U.S. Army Dental Research Detachment, Great Lakes, IL. He has since been promoted to COL and is currently assigned to the U.S. Army Dental Activity, Fort Knox, KY.

††At the time this article was written, SSG Courtright was assigned to the 464th Medical Company (Den Svcs), Landstuhl, Germany. He is currently assigned to the Department of Dental Science, Academy of Health Sciences, U.S. Army Medical Department Center and School, Fort Sam Houston, TX.

Operation Shadow Warrior: A Quantitative Analysis of the Ultraviolet Radiation Protection Demonstrated by Various Headgear

MAJ Daniel J. Schissel, MC, USA†

*(Note: This article was previously published in the September 2001 [Vol 166, No. 9, p 783] issue of **Military Medicine: International Journal of AMSUS**.)*

In the last 10 years, the scientific community and the media have highlighted the depletion of atmospheric ozone and the subsequent increase in ultraviolet radiation (UVR) that penetrates to the earth's surface. This UVR is associated with problems such as sunburn, photoaging, cataracts, and skin cancer. In the United States, skin cancer is among the top three reported cancers, and its incidence is increasing rapidly. Physicians agree that human exposure to UVR should be controlled by protecting the skin or limiting its exposure to UVR. As military physicians, our mission is to protect the fighting force and educate the command on the best possible course of action to accomplish this mission. In this article, I quantitatively demonstrate that wearing the inventoried sun, woodland, type III cover is a far superior course of action when a commander desires a UVR counter measure for the fighting force.

Introduction

Intense exposure to UVR has been clearly linked to numerous dermatological conditions. Erythema, sunburn, photoaging, cataracts, nonmelanoma skin cancers ([NMSC]; basal cell carcinoma and squamous cell carcinoma), and malignant melanoma are the common associations.¹ The risk associated with UVR varies depending on patient age, amount and type of UVR exposure, and whether exposure occurs in intense intermittent intervals or is cumulative over many years. Our fighting force is exposed daily to intense UVR with very limited protection.

Cataracts, photoaging, solar keratosis, and NMSC are directly related to the cumulative exposure to UVR.^{1,2} The NMSC occurs most commonly on sun-exposed sites (head, face, ears, neck, arms, and legs), and frequently is associated with outdoor professions. When these cancers are detected early, they are easily treated with a 99% cure rate and rarely metastasize. Nonetheless, these tumors may be quite disfiguring, especially facial lesions. Of the reported cancers, NMSC accounts for more than one-third of all cancer presentations in the United States.³⁻⁶ Because many of these NMSCs are not officially tracked by a

tumor registry, underreporting is common; thus, the true incidence of NMSCs could be considerably higher.

Incidence rates for malignant melanoma have increased faster than those of other cancers.⁷ There are clear and concise data associating the risk of developing malignant melanoma with increased cumulative exposure to UVR.^{7,8} The initial approach to combating this continued increased in melanoma rate in many countries has been to establish an early detection program. This allows the melanomas that occur to be diagnosed and treated early, at a more manageable stage.⁸ Primary prevention is clearly the more long-term goal, and the natural protection of shade, sunscreens, clothing, and hats is clearly the best method.⁹

Previous studies have demonstrated that wearing a brimmed hat reduces UVR exposure and have quantified these effects at different anatomical locations.^{10,11} This is the first study to quantitatively assess protection achieved at various anatomical locations on the head and neck with multiple issued headgears in the U.S. inventories. The U.S. issue, sun, woodland, type III (Figure 1) and the Australian summer cover and insect net (Figure 2) demonstrated a far superior UVR protection than our present battle dress

uniform (BDU) cover (Figure 3) and the future beret.



Fig 1. National Biological Corporation hand-held UVB monitor testing the nose site and the sun, woodland, type III cover.




Fig 2. Australian issued cover.

Methods

Measurements of ultraviolet B (UVB) were taken at standardized locations during a sunny and cloudless summer day in June 1999. The test manikin was fitted with the U.S. beret, baseball, BDU, drill instructor, sun, and Australian headgears while it was mounted on a pole with the top of the manikin 6 feet from the ground. The

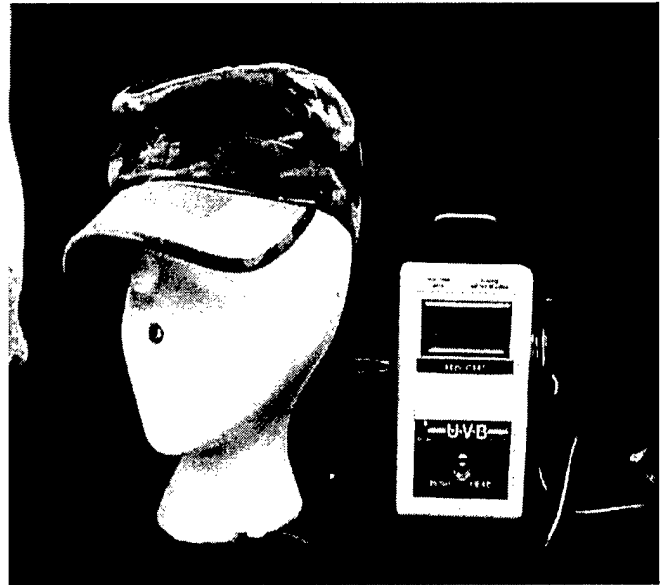

Fig 3. BDU cover testing the nose site.

pole was then placed in the middle of a military parade field. These values were subsequently analyzed after a baseline was established for comparison.

The sites chosen for UVR measurements were the vertex of the head, the tip of the nose, the ear, and the nape of neck, which represent high cancer areas. Measurements were obtained in succession by site. Initially, a pretest measurement of the uncovered manikin was obtained, followed by fitting the manikin with the beret, baseball, BDU, drill instructor, sun, and Australian headgear, followed by a post-test measurement of the exposed manikin. Upon completion of the cycle for that specific location, the UVR monitor was moved to the next site and the measurements were repeated in the same order.

The UVR was measured using the National Biological Corporation's hand-held UVB radiometer modified to fit within the manikin, as demonstrated in Figure 1. Measurements were taken at one setting between the hours of 12:00 noon and 12:30 pm in mid June 1999 in San Antonio, TX (Table 1). Pre- and post-test measurements were averaged to determine a baseline exposure for the specific location being tested during that specific time of the day. The measured readings at the test locations under the protection of the representative headgears were then calculated as a "percentage of the baseline UVB allowed to penetrate to the sensor." The inverse of the allowed UVB exposure was then calculated

as the “percentage of UVB blocked” (100% – percentage allowed) using the various headgears.

Discussion

There are overwhelming data that many dermatological conditions, including NMSCs and the more serious malignant melanoma, are directly related to the cumulative effects of UVR.^{1,3,4,7} Nonetheless, our troop commanders will find neither this important information nor guidance in dealing with the threat of UVR in the “Command Guidance on Irradiated Personnel.”¹² As military physicians, our mission is to protect the fighting force and educate the command on the best possible course of action to protect our soldiers today and in the future. The initial approach in many countries, including the United States, has been to establish an early detection program in an attempt to diagnose and treat the skin cancers that occur at a curable stage. This mission is clearly established and well engaged in our military medical commands. We continue to confirm the long-standing clinical impression that NMSC is more common on sun-exposed areas of the head and neck. For example, 22.4% of NMSCs occur on the ear of men, with 8.0% being basal cell carcinomas and 14.4% being squamous cell

Results

The percentage of UVB radiation blocked by the various headgears is annotated in Table 2. The calculated percentages, then, represent the overall protection at an anatomical site offered by the particular headgear. It is clear that the U.S. issue sun, woodland, type III protects the vertex of the head +6.4% better than the standard BDU cover. There is a far superior improvement, however, in UVB protection with the sun, woodland, type III cover for the ear (+30.2%) and the nape of the neck (+32.9%) compared with the BDU cover. Figure 4 shows the overall average of UVB blocked at the tested anatomical locations ([apex + nose + ear + neck]/4) by the various headgears. An overall +17.5% improvement in UVB protection is noted with the sun, woodland, type III cover over the BDU. An overall +31.5% improvement in UVB protection over the beret is noted with the sun, woodland, type III issue headgear.

	Pretest	Post-Test	Beret	Baseball	BDU	U.S. Sun	Drill	Australian
Vertex	4.33	4.31	1.04	1.09	0.33	0.05	0.33	0.02
Nose	3.41	3.50	3.39	2.08	1.77	1.75	2.00	1.63
Ear	3.94	4.01	3.85	3.90	3.86	2.67	2.88	1.95
Nape	4.05	3.91	3.50	3.56	3.77	2.46	2.50	2.15

Values shown are mW/cm²

Table 1. Raw UVB Measurement at the Representative Test Site in mW/cm²

	Beret	Baseball	BDU	U.S. Sun	Drill	Australian
Vertex	75.90%	74.80%	92.40%	98.80%	92.40%	99.50%
Nose	2.00%	39.90%	48.90%	49.40%	42.20%	52.90%
Ear	2.30%	1.00%	2.00%	32.20%	26.90%	50.50%
Nape	12.10%	10.60%	5.30%	38.20%	37.20%	46.00%

Table 2. Percentage of UVB Blocked by the Respective Headgears at the Specific Test Site

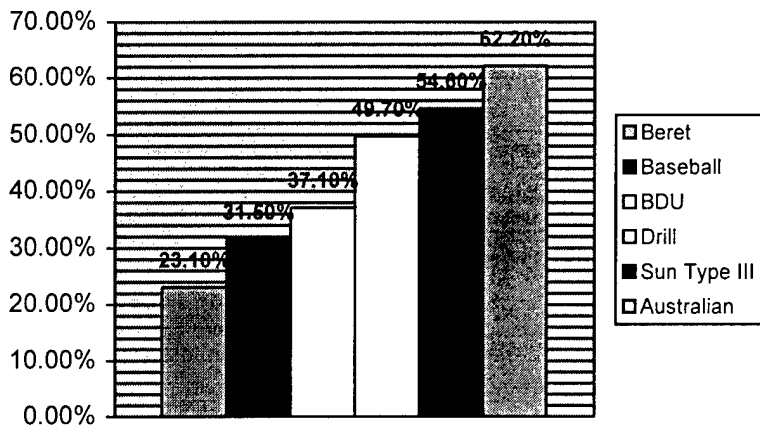


Fig 4. Overall mean percentage of UVB blocked by the various headgear.

carcinomas. The nape of the neck is also a high-risk area for NMSC, with an overall occurrence of 13.5% in men. Of these, 7.4% are basal cell carcinomas and 6.1% are squamous cell carcinomas.¹¹

Primary prevention is clearly the more long-term mission. The natural protection of shade, sunscreens, clothing, and hats is well documented as the best protection.⁹ This is the first study to quantitatively assess the protection achieved at various anatomical locations on the head and neck with multiple issued headgears. The U.S. issue sun, woodland, type III cover that is in our present inventory clearly demonstrated increased protection over the issued BDU headgear. The ear was protected 30.2% more, the nape of the neck was protected 32.9% more, and an overall 17.5% improvement in UVB protection was noted with the sun, woodland, type III cover.

As we move into the new millennium, we have projected and are testing advanced weaponry under "Force XXI." Through "Operation Shadow Warrior" it is clear that the sun, woodland, type III cover is a superior UVR force protector that should be implemented in some fashion in the daily uniform of our soldiers, airmen, and sailors. As our troop commanders move to field our force advancements, we as military physicians must continue to educate our troop commanders on the omnipresent threat of UVR. Our recommendation to exemplify the Army's transformation, continued pride, unflagging

professionalism, and esprit de corps would be to simultaneously implement the beret as the day-to-day headgear and the sun, woodland, type III as the work and field headgear as we continue to seek advancements (Australian cover) in our mission to protect the fighting force.

References

- Gibbons L. Symposium on disease related to UVR: a risk-management approach. *Can Med Assoc J.* 1992;147:1330-2.
- Rosenthal FS, Safran M, Taylor HR. The ocular dose of UVR from sunlight exposure. *Photochem and Photobio.* 1985;42:163-71.
- Hacker SM, Flowers FP. Squamous cell carcinoma of the skin. *Postgrad Med.* 1993; 93:115-26.
- Hacker SM, Browder JF, Ramos-Caro FA. Basal cell carcinoma. *Postgrad Med.* 1993;93:101-11.
- Gallagher RP, et al. Trends in basal cell carcinoma, squamous cell carcinoma and melanoma from 1973 through 1987. *J Am Acad Dermatol.* 1990;23:413-21.
- Harth Y, et al. Sun protection and sunscreen use after surgical treatment of basal cell carcinoma. *Photoderm Photoimmuno and Photomed.* 1995;11:140-2.
- Garland CF, Garland FC, Gorham ED. Rising trends in melanoma; an hypothesis concerning sunscreen effectiveness. *AEP.* 1991;3:103-109.
- Marks R. Photoprotection and prevention of melanoma. *Eur J Dermatol.* 1999;9: 406-12.
- Davis S, et al. Clothing as protection from UVR: which fabric is the most effective. *Int J Dermatol.* 1997;36:374-8.
- Difley BL, Cheeseman J. Sun protection with hats. *Br J Dermatol.* 1992;127:10-2.
- Keeling JH, et al. Hats: design and protection from UVR. *Mil Med.* 1989;154:250-4.
- Effects of Nuclear Weapons and Directed Energy on Military Operations. U.S. Army Correspondence Subcourse. December 1995.

AUTHOR:

†Medical Corps, U.S. Army. Major Schissel is the Chief of Dermatology, U.S. Army Military Hospital, Heidelberg, Germany.

Infection of Pediatric Hip Fracture: A Case Report

MAJ Kenneth F. Taylor, MC, USA+
COL Kathleen A. McHale, MC, USA++

Avascular necrosis, with or without resultant limb length discrepancy, and problems with bony union are not uncommon after femoral neck fractures in the pediatric population. This rare case of infection after closed reduction and percutaneous pinning of an intracapsular fracture of the hip in a child illustrates the difficulty in treatment in the face of joint sepsis and the value of modern scanning techniques.

Introduction

While the proximal femur accounts for less than 1% of all pediatric fractures, complications in this area are disproportionately high.¹ This is due largely to the unique osseous and vascular anatomy, particularly, the end-artery status of the femoral head in a growing child.²⁻⁵ Review of the current literature demonstrates a relatively high incidence of several complications: avascular necrosis (17-47%), premature closure of the epiphyseal plate (5-65%), delayed or nonunion (3.7-10%), and alterations in the femoral neck-shaft angle (8.3-30%).^{1,2,6} Infection is a rare complication with a reported incidence of less than 1%.^{2,4,7-11} Transepiphyseal (Delbet type 1) fractures represent the least common fracture of the femur in the pediatric population, but have been associated with the highest risk of complication.^{2,6} The incidence of avascular necrosis, for instance, is highest in this type approaching 100%. Other complications, such as nonunion, are very possible considering that this is an intra-articular fracture. In a long-term follow-up of femoral neck fractures in children, Leung and Lam reassessed 41 children 13 to 23 years after injury and found that 83% had radiographic abnormalities, 24% complained of a limp or shortening, and 22% had exercise-induced pain.¹² Although metaphyseal osteomyelitis and hip sepsis is a common phenomenon for the pediatric population, infection after hip fractures in children is an extremely rare event. In this case of an otherwise healthy 12 year old who developed an infection as a complication of percutaneous pinning of a transepiphyseal femoral neck fracture, the potential for a poor outcome is extremely high. The risk of avascular necrosis, the possibility of nonunion or delayed union and osteomyelitis, present a challenging triad for the practitioner. A

comprehensive treatment course guided by modern scanning was necessary to assure union, ablate the infection, and minimize dysfunction.

Case Report

A 12-year-old healthy black male sustained a displaced transepiphyseal fracture of the left proximal femoral neck during football practice. That same day, he underwent closed reduction and percutaneous pinning with two cannulated screws. The postoperative course was unremarkable, and he was discharged on postoperative day six.

He returned 1 month later with drainage from the incision site. A pocket of purulent fluid was noted to extend proximally from the inferior border of the wound. A course of intravenous cefotaxime was initiated postoperatively. The patient underwent additional incision and drainage procedures at 48 hours and 5 days, with the wound left open thereafter. He remained febrile despite this treatment regimen. Triple phase bone and gallium scans demonstrated increased uptake in the acetabulum, femoral head, and trochanteric areas. The patient was subsequently transferred to a tertiary care facility for further evaluation and treatment.

Physical examination on presentation to this institution demonstrated a fever (temperature, 101°F). The incision was opened along the proximal lateral aspect of the thigh with scant drainage and good granulation tissue, without evidence of erythema or edema. Passive hip range of motion was limited and there was tender inguinal lymphadenopathy. Plain radiographs demonstrated a

destructive process consistent with osteomyelitis (Figure 1). Laboratory studies were significant only for an erythrocyte sedimentation rate (ESR) of 61. Previous intraoperative cultures by now had grown *Staphylococcus epidermidis*.

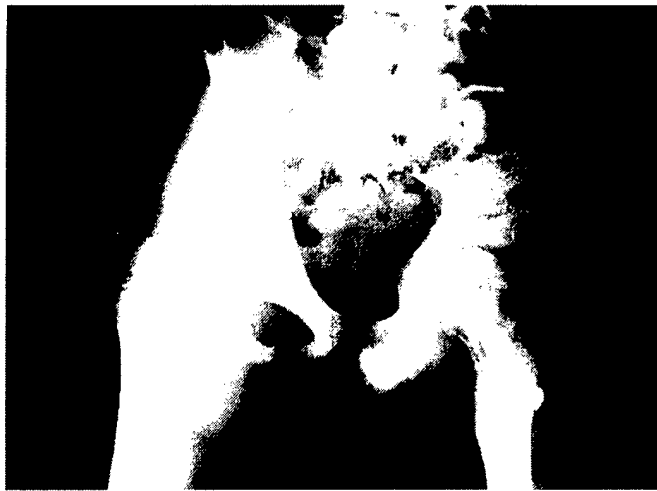


Fig 1. AP radiograph of the hip on arrival to the medical center. The pins are in good position, but destructive changes already can be seen.

The patient underwent immediate aspiration, irrigation, and debridement. The hip aspirate and bone biopsy, obtained just anterior to the cannulated screws, were both positive for staphylococcal organisms. Blood cultures were negative. The patient remained febrile with a fever (temperature, 103.4°F). Intravenous Vancomycin was added. Physical therapy was initiated 2 days postoperatively to address the decreased range of motion. The patient underwent additional irrigation and debridement on the 11th day of admission. He was afebrile postoperatively with a normal serum leukocyte count. Plain radiographs obtained on the 19th day demonstrated lucency of the medullary cavity of the proximal femur with a permeative pattern of the trabeculae. The soft tissues demonstrated loss of definition of the fat planes thought to be secondary to edema.

A computed tomography (CT) scan was obtained at 7 weeks post-injury to determine the extent of fracture healing. Two screws extending from the area of the greater trochanter up to the femoral head were observed, with the inferior screw appearing to extend intra-articularly. There was evidence of lytic lesions on the articulating surface of the femoral head with an irregular area of bone destruction observed in the most superior aspect of the acetabulum

(Figure 2). These findings were accompanied by a significant joint effusion and surrounding soft tissue inflammatory changes. Early periosteal bone formation was noted at the inferior aspect of the percutaneous screws. These radiographic findings were compatible with early bone destruction and were suspicious for sepsis, but confirmed a healed fracture.

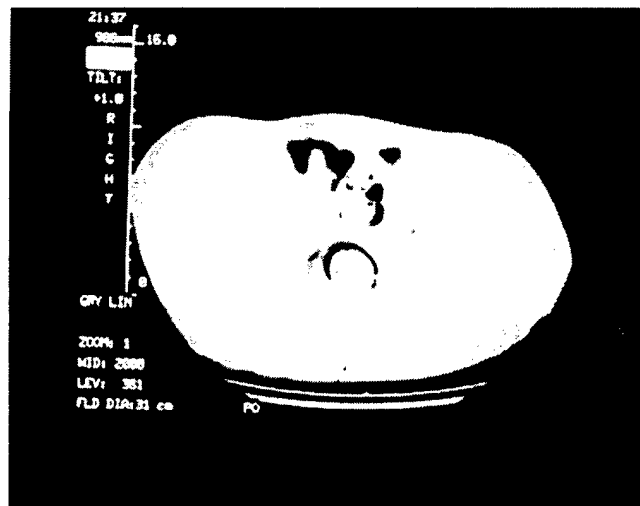


Fig 2. CT scan demonstrating effusion and further destructive changes. Hardware appears to be entering the joint. Other CT images suggested a healed fracture.

On the third irrigation and debridement, the two screws were noted to be loose. Multiple drill holes were made into the proximal femoral epiphysis, resulting in drainage of purulent material. The two cannulated screws were removed and the proximal femur was seen to be stable under fluoroscopy. The patient was begun on immediate touch weight-bearing ambulation.

Although the patient appeared constitutionally better, his inflammatory parameters remained elevated. A magnetic resonance imaging (MRI) study obtained on the 39th day of admission revealed the presence of an abnormal signal intensity pattern within the acetabulum and femoral head extending into the femoral neck, thought to be consistent with edema but not infection (Figure 3). To further confirm that all areas of infection had been addressed, a triple phase bone scan and an indium 111 scan were obtained. Blood pool films revealed a focal area of radiotracer activity in the proximal femur and hip. Soft tissue activity was within normal limits (Figure 4). The indium 111 scan revealed diffuse uptake of the labeled leukocytes in the intertrochanteric region of the femur.

There was no abnormally increased uptake in the acetabular region (Figure 5). Since the scans gave assurance that there was no sequestered sites of infection, the patient was continued on intravenous antibiotics and no further surgery was felt indicated. Serum inflammatory indices gradually decreased towards normal values. The patient was discharged on the 54th day of admission.

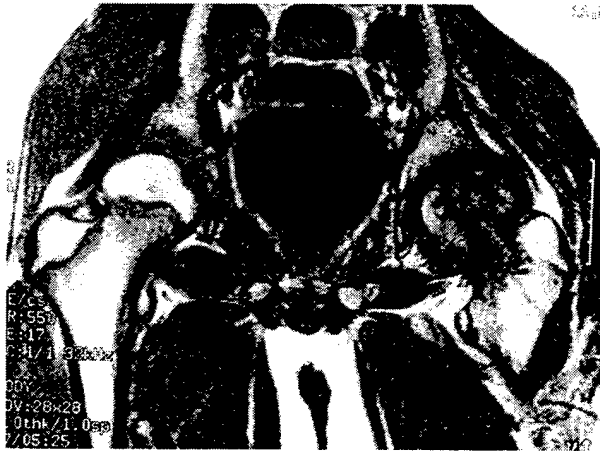


Fig 3. MRI demonstrating edema in the femoral head and metaphysis, and acetabulum. Fracture healing is confirmed. Destructive changes are obvious in the femoral head. Signal in femoral head and acetabulum is not indicative of infection.

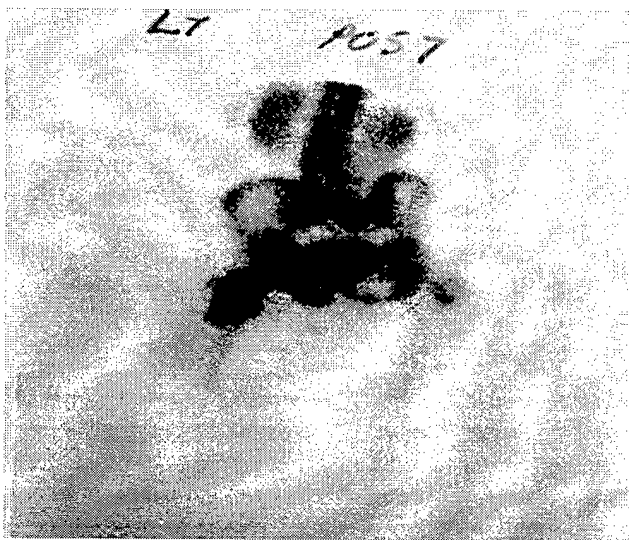


Fig 4. Triple phase bone scan 4 months from injury demonstrates increased uptake in the femoral head and metaphysis as well as the acetabulum.

The patient returned one month later. Physical examination was significant for a 20-degree hip flexion contracture and limited range of motion. Plain film radiographs demonstrated a well-healed femoral neck with loss of the articular surface consistent with chondrolysis. A

small area of chondral collapse measuring 7 mm was located medially on the femoral head. The superior surface was not affected (Figure 6). The MRI demonstrated a persistently abnormal signal intensity within the acetabulum and femoral head with increased water content within the marrow. There was significant improvement though, in the amount of edema noted in the surrounding soft tissues. The hip joint demonstrated only minimal effusion. There was no evidence of femoral head collapse.

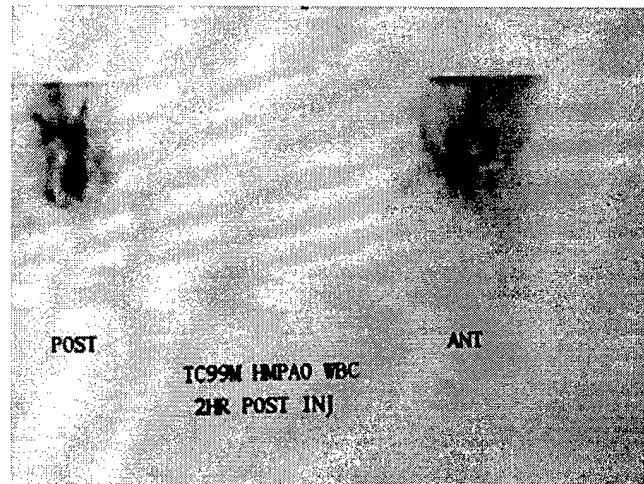


Fig 5. Indium 111 scan with no uptake in these areas, further supporting the absence of joint infection.

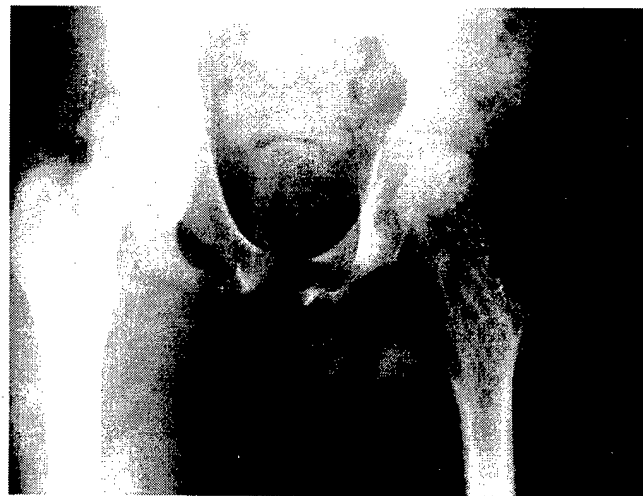

Fig 6. AP radiograph at 5 months post-injury suggesting an area of chondral collapse.

It was recommended that he continue toe-touch weight-bearing crutch ambulation and physical therapy rehabilitation while the femoral head reconstituted its strength to prevent collapse. The MRI at 1-year follow-up demonstrated residual edema within the marrow of the

proximal femur and acetabulum with a small joint effusion (Figure 7). Differential considerations at that time included residual inflammation from chronic infection or early avascular necrosis. At a 2-year follow-up, the patient demonstrated near complete loss of hip rotation. Roentgenograms now revealed definite signs of femoral head collapse and remodeling consistent with avascular necrosis (Figure 8). This patient will continue to be followed clinically. His activities are limited by his symptoms and he will likely require a salvage procedure at a later date.

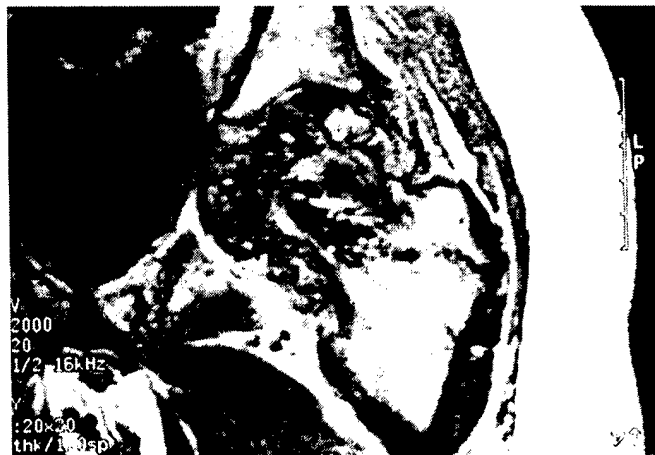

Fig 7. MRI at 1 year demonstrating significant changes within the femoral head, but no significant collapse.

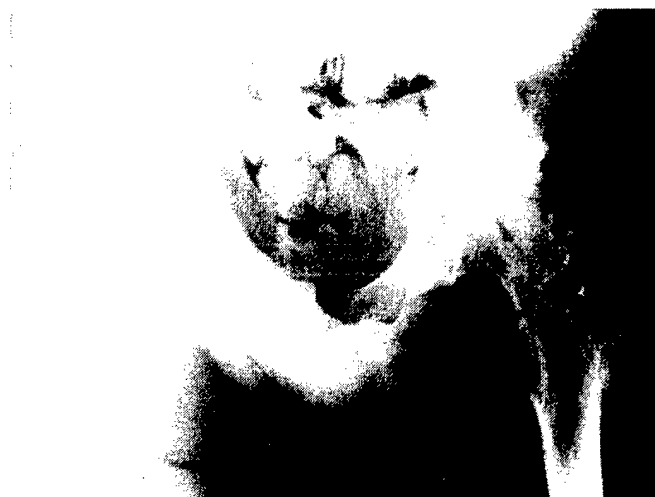

Fig 8. AP radiograph at 2-year follow-up demonstrating subchondral cyst formation and collapse diagnostic of avascular necrosis.

Discussion

This may be the first reported case of deep sepsis as a complication of percutaneous fixation of an intracapsular

hip fracture in a child. Infection following femoral neck fracture at any age is an exceedingly rare event. In one large series of 2,418 adult femoral neck fractures, Homberg et al reported a total of 793 complications of which only 46 were infections.⁹ Of these, only six were deep infections occurring postoperatively. Swiontkowski et al observed no wound infections in 27 trauma patients, aged 12 to 49 years, sustaining femoral neck fracture.¹¹ In a series of 108 pediatric femoral neck fractures in which thirteen (12%) were transepiphyseal, Azouz et al report no cases of osteomyelitis or septic arthritis.² In a series of 16 patients referred to a pediatric tertiary care facility for complications associated with femoral neck fractures, Forlin et al reported a high incidence of avascular necrosis (14 of 16), premature physeal closure (15 of 16), nonunion (7 of 16), and coax vara (2 of 16).⁸ This series noted the possibility of multiple complications, as seen in our patient. There was one case of transepiphyseal fracture in which avascular necrosis, premature epiphyseal closure, and chondrolysis occurred. There were, however, no infections. The reason for deep infection in this case was probably not the cause for infection in the few reported adult cases. Our patient was treated with the most accepted form of management for the displaced pediatric intracapsular fracture, which is closed reduction and percutaneous pinning. The adult cases had been treated with open reduction. Gray and Parker reported 58 intracapsular fractures in patients less than 60 years old in which they observed two cases of septic arthritis with subsequent nonunion, in the only two patients to have open reduction.¹ Davison and Weinstein reported similar findings in a series of 19 patients followed an average of 16 years post-injury.¹³ Two patients developed septic arthritis, both also after open reduction and internal fixation of the fracture. These findings suggest that opening the fracture site may increase the risk of infection.

It became apparent, only at 1 month postoperatively, that this patient had developed an infectious process. A draining wound and pyrexia, refractory to initial irrigation and debridement, warranted further investigation at a tertiary care facility. The infection in this case more than likely represents an indolent pin tract infection which became deep-seated, as evident by the late presentation of symptoms and subsequent drainage. Available laboratory and scanning parameters will guide management in the clinical setting. Culture and sensitivity, laboratory studies

such as white blood count and ESR, plain roentgenograms, special studies such as triple phase bone and indium 111 scanning, and MRI can be used. Culture and sensitivity is mandatory, and the ESR provides insight regarding response to treatment. If the infecting organism is identified, minimal inhibitory concentration titers and Schlicker levels may also be used to follow treatment. In early osteomyelitis, plain radiographs demonstrate change 10 to 14 days after the onset of infection. Triple-phase bone scans are generally very sensitive; positive shortly after the onset of infection. However, this modality is less specific once the integrity of bone has been violated by an insult causing increased turnover (for example, surgery or fracture). False positive results may also arise due to cellulitis in the absence of bone involvement. Indium 111 leukocyte scanning has been reported to be more specific for bone infection. Schauwecker studied 453 patients with suspected osteomyelitis with bone and indium-labelled leukocyte scanning noting the capacity to differentiate between infection of bone and adjacent soft tissue was greater with simultaneous than with sequential studies.¹⁴ An accurate determination of location of infection was possible when overlaying simultaneous bone scan and indium 111 leukocyte images. The CT scanning can be utilized, as in this case, to confirm the healing of the fracture. In the presence of infection, it is still best to ensure fracture healing before removal of the hardware. Although hardware removal may be warranted eventually, early removal could lead to loss of position and/or necessitate hip spica cast treatment, which may result in a stiff joint.

The MRI is in the forefront in determining diagnosis and localization of many hip problems, such as avascular necrosis, chondrolysis, and neoplasm. The MRI has also been useful in diagnosis of musculoskeletal infection.^{15,16} Its ability to accurately distinguish between soft tissue and bony disease has led to its increased use. Unger et al noted a sensitivity of 82% in bone scintigraphy compared to 92% for MRI.¹⁷ Specificity values of 65% and 96% for bone scan and MRI, respectively, further support the use of magnetic resonance in the diagnosis of bone infection.

Normal cortical bone, with few mobile protons, results in a weak signal whereas the intense signal generated by bone marrow within a normal medullary cavity is indicative of short T1 relaxation times characteristic of fat in the marrow spaces. A reduction of

the marrow signal intensity is apparent in acute and subacute osteomyelitis. These lesions, with increased water content, produce relatively long T1 values resulting in a weak, relatively dark MRI equal to that of muscle. T2-weighted images demonstrate an increased signal intensity of marrow, approaching that of water.¹⁷ This reflects the current concept of the pathophysiology of osteomyelitis in which bacterial proliferation evokes an inflammatory response with transcapillary exudation and increased intramedullary pressure.¹⁸ Soft-tissue swelling, with disruption of the normally intense signal of subcutaneous fat, contiguous with the infected bone is an early sign of acute osteomyelitis that is clearly visualized on MRI.¹⁸

Despite its high sensitivity and specificity, MRI, much like other diagnostic modalities, has its limitations. It is difficult to diagnose osteomyelitis in patients with previous fracture or surgery, as pins or plates in the bone will result in artifacts, making interpretation difficult. Bone marrow findings of acute osteomyelitis on MRI are nonspecific. Non-infectious inflammatory conditions of bone, healing fracture, and metastases may have changes similar to those in osteomyelitis.¹⁷ Despite this, findings suggestive of osteomyelitis in the presence of an appropriate clinical setting are highly accurate for the diagnosis of osteomyelitis.

While it is recognized that MRI is the most sensitive modality for use in the early diagnosis of osteoarthritis and avascular necrosis of the femoral head, joint effusions can also be depicted.^{3,5,19-22} In describing increased joint fluid in the presence of early avascular necrosis, Mitchell et al observed intermediate signal intensity on T1-weighted images, just external to the cortex of the femoral neck.²³ Increased contrast in T2-weighted images allowed for the observation of minimal amounts of joint fluid. They suggest that minor degrees of joint fluid asymmetry are common, but the presence of joint fluid sufficient enough to surround the femoral neck (grade 2) or distend the capsular recesses (grade 3) should be viewed with suspicion.

In four patients diagnosed with septic arthritis, Unger et al described the presence of fluid collections within joint spaces with signal intensities less than to slightly greater than that of muscle on the T1-weighted image, and similar to that of water on the T2-weighted image.¹⁷ Adjacent

bone marrow, unless otherwise involved by osteomyelitis, showed normal signal intensity. In our patient, MRI was helpful in diagnosing osteomyelitis of the femoral head, particularly in the presence of fracture. The scan was even more useful in confirming the localization of the infection late in the course of treatment. Although there was edema in the acetabular area and some joint effusion, these findings were not those of sepsis.

The later sequelae of intracapsular hip fracture, such as avascular necrosis and epiphyseal closure, may be difficult to positively identify early in the course of treatment even with good scanning. The progression of osteonecrosis seen on MRI has been described by several authors.²⁴⁻²⁷ Within days to weeks, a diffuse marrow edema develops. It is not until weeks to months that a segmental zone of abnormal signal intensity at the interface between necrotic and viable bone appears. This sclerotic zone of low signal intensity, with a high signal margin representing hyperemic granulation tissue just inside it, known as the "double line sign," is fairly specific for osteonecrosis.^{22,25,26,28} The differential diagnosis of a patient with MRI findings of diffuse marrow edema in the femoral head and neck without a double line sign includes early osteonecrosis, transient osteoporosis, stress fracture, occult interosseous fracture, sickle cell crisis, neoplasia, and osteomyelitis.^{25,27} This patient's delayed development of avascular necrosis is not necessarily atypical after fracture, though early diagnosis would allow predictability of duration of treatment.

Conclusion

This unusual case of deep infection after closed reduction and percutaneous pinning of an intracapsular fracture in a child illustrates the dilemma of treating an infected intra-articular fracture. Application of basic principles of fracture care with guidance from laboratory and scanning is necessary. Avascular necrosis and early epiphyseal closure are predictable in this population. Efforts of treatment should therefore be aimed at healing the fracture while controlling the infection, as nonunion of an intracapsular fracture may represent an even more difficult situation to treat than the coexistent infection.

References

1. Gray AJR, Parker MJ. Intracapsular fractures of the femoral neck in young patients. *Injury*. 1994;25:667-669.
2. Azouz EM, et al. Types and complications of femoral neck fractures in children. *Pediatr Radiol*. 1993;23:415-420.
3. Swiontkowski MF. Intracapsular fractures of the hip. *J Bone Joint Surg*. 1994;76A(1):129-138.
4. Swiontkowski MF, Winquist RA. Displaced hip fractures in children and adolescents. *J Trauma*. 1986;26:384-388.
5. Takatori Y, et al. Avascular necrosis of the femoral head. *J Bone Joint Surg*. 1993;75B(2):217-221.
6. Huges LO, Beatty JH. Fractures of the head and neck of the femur in children. *J Bone Joint Surg*. 1994;76A(2):283-292.
7. Crandall DG, Gabriel KR, Akbaria BA. Second operation for slipped capital femoral epiphysis. Pin removal. *J Pediatr Orthop*. 1992;12(4):434-437.
8. Forlin E, Guille JT, Kumar SJ, Rhee KJ. Complications associated with fracture of the neck of the femur in children. *J Pediatr Orthop*. 1992;12(4):503-509.
9. Holmberg S, Kalen R, Thorngren KG. Treatment and outcome of femoral neck fractures, an analysis of 2,418 patients admitted from their own homes. *Clin Orthop*. 1987;218:42-52.
10. Riley PM, Weiner DS, Gillespie R, Weiner SD. Hazards of internal fixation in the treatment of slipped capital femoral epiphysis. *J Bone Joint Surg*. 1990;72A(10):1500-1509.
11. Swiontkowski MF, Winquist RA, Hansen ST. Fractures of the femoral neck in patients between the ages of 12 and 49 years. *J Bone Joint Surg*. 1984;66A(6):837-846.
12. Leung PC, Lam SF. Long-term follow-up of children with femoral neck fractures. *J Bone Joint Surg*. 1986;68(B)4:537-540.
13. Davison BL, Weinstein SL. Hip fractures in children. A long-term follow-up study. *J Pediatr Orthop*. 1992;12(3):355-358.
14. Schauwecker DS. Osteomyelitis. Diagnosis with indium 111-labeled leukocytes. *Radiology*. 1989;171(1):141-146.
15. Berquist TH, Brown M, Fitzgerald R, May G. MRI. Application in musculoskeletal infection. *Mag Reson Imag*. 1985;3:219-223.
16. Modic MT, et al. MRI of musculoskeletal infections. *Radiol Clin North Am*. 1986;24:247-258.
17. Unger E, et al. Diagnosis of osteomyelitis by MRI. *AJR*. 1988;150:605-610.
18. Fletcher BD, Scoles PV, Nelson AD. Osteomyelitis in children. Detection by MRI. *Radiology*. 1984;150:57-60.
19. Lang P, Genant HK, Jergesen HE, Murray WR. Imaging of the hip joint. CT versus MRI. 1992;274:135-153.
20. Fordyce MJ, Solomon L. Early detection of avascular necrosis of the femoral head by MRI. *J Bone Joint Surg*. 1993;75B(3):365-367.
21. Markisz JA, et al. Segmental patterns of avascular necrosis of the femoral heads. Early detection with MRI. *Radiology*. 1987;162(3):717-720.
22. Mitchell DG, et al. Femoral head avascular necrosis. Correlation of MRI, radiographic staging, radionuclide imaging, and clinical findings. *Radiology*. 1987;162(3):709-715.
23. Mitchell DG, et al. MRI of joint fluid in the normal and ischemic hip. *AJR*. 1986;146:1215-1218.

24. Asnis SE, et al. MRI of the hip after displaced femoral neck fractures. *Clin Orthop.* 1994;298:191-198.

25. Richardson ML. Can MRI distinguish between transient osteoporosis of the femoral head and osteonecrosis? *AJR.* 1994;162:1244.


26. Spear KP, Spritzer CE, Harrison JM, Nunley JA. MRI of the femoral head after acute intracapsular fracture of the femoral neck. *J Bone Joint Surg.* 1990;72A(1):98-104.

27. Turner DA, et al. Femoral capital osteonecrosis. MR finding of diffuse marrow abnormalities without focal lesions. *Radiology.* 1989;171(1):135-140.

28. Sugano N, et al. Prognostication of osteonecrosis of the femoral head in patients with systemic lupus erythematosus by MRI. *Clin Orthop.* 1994;305:190-199.

AUTHORS:

† and †† Medical Corps, U.S. Army. Major Taylor and Colonel McHale are assigned to the Department of Orthopaedic Surgery and Rehabilitation, Walter Reed Army Medical Center, Washington, DC.



Recruitment and Retention of ARNG Nurses: A Qualitative Study

COL Rita M. Paxson, AN, ARNG†
MG Marianne Mathewson-Chapman, AN, ARNG††

Purpose

The purpose of this qualitative study was to identify the reasons why nurses join the Army National Guard (ARNG) and why they stay for over 20 years in the Kentucky Army National Guard (KYARNG).

Background

Recruitment and retention of highly skilled nurses into the ARNG are top priorities today. With the demanding work schedules of civilian nurses, and the shortage of nurses in civilian hospitals, fewer nurses are choosing the additional stresses of a military career and the possibilities of deployment overseas. Commitment to a military career requires additional time away from families and children on the weekend. Deployments overseas may require a minimum of 9 months in Germany, Korea, or Bosnia. It is critical to understand the motivating factors for nurses who join the KYARNG and stay in the military for over 20 years. The reader may wonder what motivates nurses to turn in their white uniforms and don camouflaged uniforms and are willing to experience the severe elements of an outdoor environment. Nurses in the field environment often lack the necessary comforts of home and medical tools that they use daily in their sterile hospital settings. Nurses who join the KYARNG are often asked the following questions: "Why did you join the KYARNG?" "What do you do on the drill weekend?" and "Why do you stay in the National Guard." This study investigated the varied reasons that nurses join the KYARNG and why they stay in.

Sample

Fifteen nurses who regularly participate in reserve drills one weekend each month and 15 days in the summer with the KYARNG were interviewed by the researcher from 1998 to 1999. Twenty percent (3/15) of the nurses interviewed were male nurses and 80% (12/15) were

female. All participants had been in the medical unit over 10 years, were drilling each month with the unit and most had served in an overseas deployment during Operation Desert Storm (1990-91). This deployment was the largest deployment of reserve medical professionals in history. All were members of the 475th Mobile Army Surgical Hospital (MASH) which later deactivated and the STARC Medical Detachment 5 which was designated in December 1997, to assist the state in accomplishing the many medical readiness requirements needed in the ARNG.

Methodology

The purpose and procedure for this study was explained to each of the subjects and consent was obtained to participate. In a private office, the researcher verbally interviewed each of the 15 nurses. Three questions were asked: (1) What are your current responsibilities in the ARNG as compared to your responsibilities several years ago? (2) Why do you stay in the KYARNG? and (3) What professional benefits have you gained by participating with a medical team in the KYARNG? Questions used in the interview were standardized for each subject and the researcher recorded all oral responses.

Analysis of Responses

After the interviews were completed, the responses were reviewed. After analyzing the responses, commonalities were observed. Similar responses were identified and put together under common headings for each question.

- *Question No. 1. What are your current responsibilities in the ARNG as compared to what you did several years ago?*

When nurses replaced their civilian hospital white uniforms with the battle dress uniform and combat boots

for a weekend drill, their duties and responsibilities depended on the mission and training plan of the unit. When the KYARNG had the MASH, subjects stated they accepted the challenges and enjoyed drill weekends. Subjects identified field nursing opportunities and education of the medic as past responsibilities. Current responsibilities include up-to-date training of the medics and education of the soldier to maintain medical readiness.

Past Responsibilities

Field Nursing Opportunities. In the MASH trained medics, licensed practical nurses, registered nurses, doctors, supply personnel, cooks, and motor pool personnel spent the time training for their war-combat mission. They trained with the actual field equipment, cooked military prepared foods, and participated in field training exercises which simulated an actual combat environment. They also were trained to wear protective clothing for chemical/biological warfare. Unit members were proficient in survival skills in a field environment and worked as a team to accomplish the mission of the exercise. Nurses became proficient in field operations, logistics, medical evaluation, medical treatment, and medical evacuation skills.

Field operations were never canceled due to inclement weather. Rainy, cold, wintry weather in the field allowed the nurse to practice problem-solving skills. For example, nurses became innovative in order to get undressed in a tent with a wet (mud) floor and fold up a uniform to keep it dry and neat. Nurses strategically were able to remove their boots, hang them up so critters could not crawl into them overnight, and still get into the cold sleeping bag without freezing or getting wet. Nurses learned to bring all essential items with them to the field. What the Army considers essential and what the nurse knows is essential are often at different ends of the spectrum. For example, several plastic bags were utilized as rugs to stand on while undressing in order to keep the feet dry. A couple of disposable hand warmers placed in the sleeping bag a couple hours before bedtime did wonders on cold nights. Many of these "essential" items made the Desert Storm experience at least more tolerable.

Education of the Medic. During a field exercise, sleeping tents were set up first and then the hospital was set up. Once the hospital was established and fully

functional, simulated patients were brought in to be triaged. Nurses and doctors served as teachers for the medics and each other. Although all medics have completed basic medic classes, many worked in other areas as civilians and only practiced their medical skills at drill.

Review of critical skills, such as initial emergency assessment, were needed not only for the medics but by professionals who practiced in areas such as obstetrics in civilian life. Most nurses found the responsibility of supervising and mentoring a good learning experience.

Current Responsibilities

Up-to-Date Medic Training. When the STARC Medical Detachment 5 was designated, the mission became medical readiness of the soldiers in Kentucky. The nurses found their responsibilities were supervising, teaching, and mentoring the medics in physical examinations to insure all soldiers received quality medical care. Instead of the teaching being done in the field, nurses turned to the classroom. Some of the nurses developed and taught annual medic refresher courses while others brought in a weekend trauma course for the unit. One participant in the study became training officer and another went into an administrative position for the KYARNG.

Education of the Soldier. Since many of the soldiers have weight and tobacco problems, some nurses developed and implemented a health prevention program to ensure a healthier soldier. Physical examinations of the soldiers were done at almost all weekend drills. Nurses met with each soldier individually to review their lifestyle and make recommendations to improve their health habits. One nurse commented, "The best part of being in the KYARNG is when you see a need, you have the autonomy to do something about it."

The interviewees stated the current responsibilities were not as exciting as going to the field for the weekend and preparing for a war-combat mission. To keep their interest and excitement in the KYARNG there were opportunities of 2-week tours in Alaska and Ecuador to provide medical support.

- *Question No. 2. Why do you stay in the KYARNG?*

Military nurses recognize the educational requirements that are critical to advancement in the Army. A nurse corps officer must be competitive in order to be promoted. Eligibility for promotion is dependent on "best qualified" among nursing peers nationally. There are advanced military schools that nurses must attend such as the Officer Basic course, Officer Advanced course, Command and General Staff courses, and War College. These schools are an additional challenge to nurses with a full-time civilian career and family obligations. They require excellent time management skills and additional time away from home in addition to their monthly drills and annual training periods.

Physical fitness must be maintained throughout the military career. Every year nurses are required to complete a certain number of sit-ups, push-ups, and a 2-mile run. Failing to pass this test may mean remedial fitness training, ineligibility to attend additional missions, or not be promoted. In spite of the educational and physical requirements, nurses continue to be active members of the KYARNG. The responses to this question were varied but fell under the following headings: Patriotism, Travel Opportunities, Friends and Comradeship, and Challenges in Field Nursing.

Patriotism and Selfless Service in a Military Career. Some of the nurses joined the KYARNG because they desired a military career, to serve their state, and serve their country. Many were not able to have an active duty career due to age, civilian practice in Kentucky, or other demanding obligations. An appointment as a nurse corps officer in the ARNG was the perfect solution. The nurses felt that they could continue their civilian practices and still serve in a military life to enhance each other. Another nurse said, "I believe we all should do something for our country and this is how I am serving my country."

Travel Opportunities. One nurse said, "I wanted to see the world, but I never intended to travel to the sandy beach with no ocean" (Saudi Arabia). In addition to Desert Storm, nurses had the opportunity to travel all over the world. Many served in Third World countries such as Guatemala, for 2-week missions as part of a medical unit to provide health care to the citizens of the country. Some of the interviewees had the opportunity to provide education to the medical personnel of Barbados, Ecuador, and the Dominican Republic. The purpose of the missions

was an exchange of information between KYARNG medical personnel and Caribbean military medical personnel. Another purpose of the missions was to promote peace and develop positive relationships between the countries by having better understanding and respect for each other. This was part of the program sponsored by the ARNG and Kentucky which was called the State Partnership for Peace Program. Some of the classes taught by the National Guard nurses and medical personnel were cardiopulmonary resuscitation, emergency childbirth procedures, burn care, and other trauma classes. The Ecuadorian military personnel taught the National Guard medics and nurses to survive in the jungle by taking them to the jungle for hands-on survival skills. Two of the KYARNG nurses found the opportunity to serve 2 weeks in the military hospital on an Indian reservation. In describing the experiences, one nurse said, "I felt I was working in a traveling emergency. We provided sick call out in the field and at remote sites in the desert, as well as being available for emergencies."

Friends and Comradeship. With all the demands of physical fitness, additional class work, and added duty on a weekend, why do these nurses stay in the ARNG? The interviewees all answered *unanimous* that the friendship and personal relationships they acquired over the years were the highlight of their personal lives. Nurses stated that, "I have strong ties with these soldiers and medical team due to the experiences we have shared. The outside world can not understand." Most nurses interviewed felt that the KYARNG soldiers were much more than friends; they were family. They shared experiences of juggling careers, family, and school. The leadership responsibilities in the KYARNG prepared them for life experiences and further developed their professional career. They also stated that "ARNG soldiers are very special multi-talented citizen soldiers with a true commitment to their state and their country."

Challenges in Field Nursing and Preventive Medicine. These missions may sound adventurous and glamorous, but the work environment on these missions was not accompanied by many of the comforts of home. Most often the nurses slept in tents or open barracks, lacked privacy, and shared showers and latrines with several other personnel. Many facilities did not have running water. Creative hand washing facilities were installed with soap and handi-wipes and attached to a local

tree. The food most often was standard Army chow called MRE's (meal, ready-to-eat). Local food may also be used to supplement Army chow. Of course, there is always the chance of acquiring a gastrointestinal infection from locally purchased food. There is nothing like the experience of severe diarrhea and vomiting in a barrack with only a limited number of latrine facilities with no privacy.

• *Question No. 3. What professional benefits have you gained by participating in the KYARNG?*

Many of these responses could be combined with question two, "Why do you continue to serve?" The common responses came under Financial Aid for advanced nursing education, Civilian Professional Advancement, and Professional Mentors.

Financial Aid for Advanced Nursing Education. Over 75% of the nurses interviewed had received or were receiving money for additional education such as their bachelors in nursing degree or their master's degree. The ARNG offers many different opportunities for nurses to continue their advanced nursing education and sharpen leadership, management, and clinical nursing skills.

Professional Advancement. In addition to the friendships and personal growth, nurses stayed in the KYARNG because they felt that the leadership skills and attaining personal goals contributed to their advancement in their civilian practice. Several nurses stated, "The military has allowed me to attend many educational courses that have helped me advance in my civilian career." One nurse said, "The military has helped me acquire management and counseling skills that my peers in the civilian sector have not had the opportunity to learn." Other nurses identified that military nurses learn an invaluable skill, and that is the ability to deal with the unexpected and function in a crisis mode.

Professional Mentors. Through the military nurses travel experiences, they have made many contacts and identified mentors in the community, state, nation, and the world. The assertive nurse is able to ferret out new experiences and accept new challenges in the field setting as an Army officer.

Professional Opportunities and Advancing Education. One nurse, who was finishing the nurse practitioner program, served in Ecuador for a 2-week tour. She was part of a 35 member medical team that provided physicals and minor care to the local people. She had been a part of two other missions into Guatemala in the past. She stated that her ARNG experience was an "opportunity to see disorders in developing countries that one can only read about in books." Also, it allowed us to see the "most austere living conditions." As with any overseas deployment, upon returning home, the nurses had a new appreciation of the U.S. and the good life and freedom that we often take for granted.

Summary

There are many reasons why nurses join the KYARNG and are committed for a lifetime. This study identified many of those factors. Further studies are needed to explore motivating factors for new graduates of nursing school that may be used in recruiting strategies for new officers into the Army Nurse Corps. As the nursing shortage will become critical in the future, it is paramount that the ARNG continue to understand motivating factors for recruitment and retention of nurse corps officers in order to recruit and retain highly skilled and competitive nurses to accomplish the ARNG missions and training for continued deployments.

Opportunities for nurses in the ARNG are endless. The rewards and benefits are there for those who are up for the challenge of a lifetime. Those who have served and are serving testify that wearing the uniform makes one stand just a little bit taller and prouder. Military experiences provide opportunities for personal and professional growth while giving back to community and country your dedication and selfless service to others.

AUTHORS:

† and †† At the time this article was written, COL Paxson was the Chief Nurse, State of Kentucky Army National Guard. Major General Mathewson-Chapman was the Deputy Surgeon General/Special Assistant for Army National Guard, National Guard Bureau, Washington, DC.

Risk Communication: The Leadership Tool for the 21st Century

COL Bradley D. Freeman, MC, USA†

Introduction

In response to rising officer attrition, the Chief of Staff of the Army surveyed mid-career officers attending Command and General Staff College. The candid responses from the multiple sensing sessions became one of the most popular e-mails circulated among "army.mil" addresses.¹ The concerns expressed clearly pointed to a lack of communication between the leaders and the led. The problem is not that the leadership is silent but what they are saying is not believed. Lack of effective communication creates lack of trust and threatens leadership credibility. The Army's leadership has been very active in delivering messages on topics like Gulf War Illnesses, anthrax immunizations and depleted uranium rounds, but the troops are skeptical and question the validity of the messages.

The Army attempts to minimize the hazards troops experience. Leaders must effectively communicate this concern for the soldiers' welfare. Ineffective communication creates erroneous perceptions and to most, perception is reality. To create the desired perceptions, leaders must be more effective in communicating their risk analysis of hazards and the risk management actions to minimize the hazards. This is accomplished through a process called risk communication. There may be hazards to the mission or equipment but hazards to ones health are most important to soldiers. The Army's unwavering commitment to the soldier's health places health care professionals on the front line of risk communication. The Army Medical Department (AMEDD) has an opportunity to take the lead in applying risk communication to the leader's toolbox.

Risk Communication

Risk communication is one of the fastest growing parts of environmental health literature with hundreds of

books and articles published within the last several years. Historically, risk communication was a one-way presentation by experts conveying a complex message in a simplified way the public would understand. The field of risk communication has evolved from simplifying complex messages into the entire process of understanding and accepting the message. The field of risk communication now includes the process of creating the message, delivering the message, and measuring message acceptance. Risk communication goes beyond the traditional role of the Public Affairs mission of distributing information. Risk communication is not spin control or manipulation of the facts to create a favorable impression. The National Research Council describes risk communication as "an interactive process of exchanging information and opinions among individuals, groups and institutions."²

The Truth, The Whole Truth and Nothing but The Truth

This exchange of information is more than merely telling the truth. Risk communication deals with issues where there is a range of possibilities as well as scientific uncertainty. The truth may change based upon the degree, intensity, and severity of the risk. The truth may depend upon science where research continuously evolves. Effective risk communication includes the audience or stakeholders as partners in the communication process. It is the receiver of the message, not the sender, who determines message comprehension and acceptance. For the stakeholder to achieve the desired level of understanding, the message and the messenger must be trusted and credible. Presentation of the facts and scientific studies are ignored without trust. The concept of trust presents a challenge for the government as well as health care professionals. Historical events like radiation testing, Agent Orange, and Gulf War Illnesses have contributed to a skeptical and questioning society. Current discussions of

the risks of anthrax vaccinations and exposure to depleted uranium must overcome this perception of distrust. The application of effective risk communication tools can help deliver the message in a fashion that is understood and even accepted by the majority of recipients. In our information society, people no longer accept health care advice solely based upon one physician's recommendation. Patients seek multiple sources of information and actively weigh several options. The Army cannot create a communication program that strongly advocates a message without education. Designing a message to persuade and influence by presenting only the truths that support the desired outcome weakens the messenger's credibility. When the audience discovers another point of view or an undisclosed outcome, they tend to perceive the original message as distorted and claim government conspiracy. When leaders fail to listen or address a soldier's questions or concerns, erroneous perceptions develop.

Risk communication is more than telling both sides of a story or the whole truth. It involves disclosing what is known, what is unknown, and what is remotely possible. Mistakes are quickly acknowledged and addressed. Third party verification is presented to reduce internal biases. Risk comparisons are selectively used to describe an unknown or unfamiliar risk. Only after the messenger has established trust and credibility will the message be understood and, hopefully, accepted as nothing but the truth.

Orders are Nonnegotiable but Justifiable

Risk communication is frequently used to change stakeholder's behavior. An example is the government's educational campaign to use seat belts. The goal is that an educated citizen will make the desired decision and wear seat belts. In the military, soldiers may not have the option of accepting or rejecting the risk management course of action. Soldiers must follow orders that may result in exposure to a risk. Risk communication attempts to convey that the risk management course of action, which may be mandatory, is the best available alternative. To gain this acceptance that mandatory decisions are in the soldiers best interest, the leadership needs to effectively communicate why the decision has been made. The need to justify risk management decisions is most important in

situations where the risk management course of action is perceived to have its own risks.

This concept of taking the time to educate and fully disclose the rationale may appear contrary to the traditional discipline of accepting military orders. There are many situations, especially in tactical situations, where communicating the risk analysis is not possible. If risk communication is used in situations where leaders have the time and resources, it improves credibility, unit moral, effectiveness, mutual respect and unit cohesion. These qualities from risk communication will transcend to the situations where military operations does not permit questioning.

Applying Risk Communication in the Military

The recommendation to apply the emerging field of risk communication in the military is not new. Risk communication has been used to address the Gulf War veterans' rejection of the government's message on Gulf War Illnesses. The veterans' lack of confidence was based upon Veterans Affairs (VA) and Department of Defense (DOD) delays in recognizing that the chronic undiagnosed or unexplained illnesses deserved treatment and compensation. Adding to the distrust was DOD's failure to acknowledge the possibility of exposure to chemical weapons. Failure to fully answer all the questions created a perception of government conspiracy. The Presidential Advisory Committee on Persian Gulf Veterans' Illnesses was created to provide an independent analysis of Gulf War service health concerns. On 31 December 1996, the committee recommended that DOD and VA develop and implement a comprehensive risk communication plan to regain the lost trust and credibility.³ A risk communication plan was created with the following objectives:

- To engage veterans, veterans' groups, and health care providers in an ongoing, constructive dialog on the health risks of service in the Gulf War.
- To increase each veteran's ability to cope with persistent and disabling physical symptoms.
- To improve communication between veterans and health care providers.
- To keep all Gulf War veterans better informed

about the health effects of their service.

- To improve the health and well being of all ill Gulf War veterans.

Presidential Review Directive-5

The Presidential Advisory Committee on Gulf War Veterans' Illnesses also recommended that the National Science and Technology Council "develop an interagency plan to address health preparedness for and readjustment of veterans and families after future conflicts and peacekeeping missions."⁴ The council produced Presidential Review Directive-5, which directed DOD, VA, and Health and Human Services to develop a plan to better safeguard individuals who risk their lives defending our national interests.⁵ To create the plan, four task forces were formed to look at (1) deployment health; (2) record keeping; (3) research; and (4) health risk communication. The task force on health risk communication published its review and recommendations as a guide for developing health risk communication plans. This guide could be adopted as a framework to develop a risk communication plan for deploying, deployed and returning military members, veterans, and their families. On 11 November 1999, President Clinton implemented the recommendations of the National Science and Technology Council to develop an interagency approach to protect the health of service members by creating the Military and Veterans Health Coordinating Board.⁶ The board has three working groups looking at deployment health, research, and health risk communication.

Independent Review

In 1996, DOD asked the National Research Council and the Institute of Medicine to explore the lessons learned from the Gulf War and other deployments to develop a strategy to protect the health of deploying troops. The final report, published in October 2000, recommended six strategies for protecting military personnel sent to potentially contaminated environments.⁷ One of the strategies recommended development of risk communication skills in military leaders at all levels. To accomplish this strategy, the Institute of Medicine suggests that DOD should:

- Provide training in the principles of health risk

assessment and health risk management to leaders at all levels.

- Institutionalize training in risk communication for commanders and health care providers.

- Offer the risk communication training at various levels of service to include initial entry training and leader development training. "DOD should give particular attention to the training of medical officers on initial entry into service"⁸

- Include Stakeholders (service members, family members, community representatives) in the development of risk communication plans to include when and how risk communication should take place.

Opportunity for the AMEDD

The risk communication recommendation from the Institute of Medicine provides the AMEDD an opportunity to become the DOD proponent for health risk communication. The framework for this expanded mission is already in place. Currently, the Commander of the U.S. Army Center for Health Promotion and Prevention serves as the chair of the risk communication working group of the Military and Veterans Health Coordinating Board. The working group, which initially met on 17 May 2000, should use the Institute of Medicine's recommendation for risk communication training as an azimuth to success.

Risk Communication Training in the Military

Doctrine must be developed in order to integrate risk communication training into a resource constrained institutional training system. A good starting place is to rewrite FM 100-14, Risk Management.⁹ This 1998 publication provides guidance on the risk management decision process but falls short on implementation. The integration of risk management is more than implementing controls and supervision; it should include risk communication. Risk Communication can motivate soldiers to accept controls and change behavior in the absence of polices and supervision. A publication that needs to be created is a Commander's Guide to Risk Communication. This guide can include realistic examples of applied risk communication and be disseminated at

leader development courses. A similar guide should be created as a Health Care Providers Primer on Health Risk Communication. The U.S. Army Center for Health Promotion and Prevention's current risk communication training could be expanded into an interactive website that serves as the cornerstone for distance learning of risk communication techniques. The AMEDD can significantly jump-start risk communication utilization by designating one of the medical centers as a center of excellence for risk communication. Full time contractors could serve as trainers and consultants at this designated medical center in order to achieve complete training and utilization of risk communication techniques. This center of excellence can serve as a test-bed for the development of techniques and evaluation measures. This total immersion of risk communication training into one facility would be similar to the cultural focus previously placed on customer service. The AMEDD can also lead by example by being the first to add risk communication training to the officer basic course.

Conclusion

The consensus of several independent analyses clearly indicates that risk communication plays a critical role in protecting the health of deployed and deploying troops. Soldiering is a high-risk business, which includes exposure to hazardous risks not normally found in the U.S. Soldiers will always be exposed to risk, but leaders cannot expect compliance based upon discipline alone. Even when leaders make the right decisions, if the rational is not communicated, then erroneous perceptions may form. Effective risk communication can create the mutual respect, credibility, and trust in the leadership that produces

high moral and unit cohesion. The AMEDD has the unique opportunity to give Army leaders this tool by becoming the proponent for risk communication.

References

1. CGSC Student Perceptions on Army Retention and Leadership. E-mail; April 2000.
2. National Research Council. *Improving Risk Communication*. Washington, DC: National Academy Press; 1989:21.
3. Persian Gulf Veterans Coordinating Board Clinical Working Group. *Comprehensive Risk Communication Plan for Gulf War Veterans*. Washington, DC: U.S. Government Printing Office; December 31, 1996:14.
4. Ibid, 15.
5. National Science and Technology Council Presidential Review Directive-5. *A National Obligation, Planning for Health Preparedness for and Readjustment of the Military, Veterans, and Their Families after Future Deployments*. Washington, DC: Office of Science and Technology Policy; August 1998:3.
6. William JC. "Creation of Military and Veterans Health Coordinating Board." Memorandum for Secretaries of Defense, Veterans Affairs, Health and Human Services, Washington, DC. November 11, 1998.
7. Institute of Medicine. *Protecting Those Who Serve: Strategies to Protect the Health of Deployed U.S. Forces*. Washington, DC: National Academy Press; 2000:3.
8. Ibid, 6.
9. U.S. Department of the Army. Risk Management. Field Manual 100-14. Washington, DC; U.S. Department of the Army. April 23, 1998.

AUTHOR:

†Medical Service Corps, U.S. Army. At the time this article was written, COL Freeman was a Senior Service College Fellow, Army Environment Policy Institute, Atlanta, GA. He is currently the Assistant Chief of Staff for Personnel, Europe Regional Medical Command, Heidelberg, Germany.

Detecting Corneal Abnormalities in Potential Military Aviators

Thomas O. Salmont†
Clarence E. Rash††
John C. Mora†††
Barbara S. Reynolds††††

An investigation was conducted to determine if the EyeSys Corneal Analysis System could measure the topographic elevation of cornea-like test surfaces accurately enough to permit detailed studies of corneal optics as a means of detecting abnormalities, particularly those created by corneal surgery. For this purpose, elevation measurement accuracy should be better than 1.0 μm . Six rotationally symmetric aspheric test surfaces were measured to assess instrument accuracy. Our results showed that, as is, the EyeSys system was not able to achieve this level of accuracy for any of the test surfaces. Depending on the surface, accuracies expressed as root-mean-square (RMS) or 12th ring errors were in the 2 to 9 and -2 to -6 μm ranges, respectively, using the current software. However, the pattern of error suggests that, with better computational software algorithms, the hardware is capable of the sub-micrometer accuracy required for these studies. There is a need for videokeratoscope manufacturers to improve system software to consistently deliver the higher accuracy measurements necessary for corneal research and pre-flight training screening.

Introduction

Approximately half of the world's population have refractive errors significant enough to require correction.¹ Grosvenor, in his 1976 study, estimated that for the age group of 18-30-year-old males, 30-35% wear spectacles.² In 1987, Walsh reported that 33% of entry-level Army infantry wore spectacles; less than 1% wore contact lenses.³ Spectacles and contact lenses are the most commonly used methods for correcting refractive errors, but for nearly a century, physicians have been exploring surgical methods to achieve the same end.

In the last 10 years, refractive surgery has become an increasingly popular alternative to spectacles and contact lenses. These surgical techniques are designed to alter the shape of the anterior corneal surface and thus induce a change in the eye's optical properties. Among the elements of the eye's optical system, the anterior surface of the cornea alone accounts for approximately 75% of the eye's refractive power and is therefore the single most important optical surface in the eye. It is also the most easily accessible for examination and modification.

Refractive surgery can be used to correct myopia

(nearsightedness), hyperopia (farsightedness), and astigmatism. Myopia occurs when the eye's optics form a clearly focused image in front of the retina, and the image which actually falls on the retina is blurred. This may be corrected by flattening the central cornea, shifting the focus backward towards the retina. In hyperopia, the clearly focused image is formed beyond the retina, and again the image, which actually falls on the retina, is blurred. This may be corrected by flattening the peripheral cornea and shifting the focus forward. Astigmatism is a more complicated form of optical defocus, which can be mitigated by flattening only certain zones of the cornea.

Both incisional and photo-ablative techniques are used to surgically reshape the cornea in order to correct refractive errors. The two most widely used incisional procedures are radial keratotomy (RK) and astigmatic keratotomy (AK). In RK, the surgeon makes a series of four to eight radial microincisions in the mid-periphery of the cornea, while the central zone is spared (Figure 1a). The equally spaced incisions are made to a depth of approximately 90% of the cornea thickness, and this causes the central zone of the cornea to flatten. This provides correction for mild levels of myopia. The AK is used to correct astigmatism, and it involves microincisions

made concentrically along the periphery of cornea in the region where the steepest corneal slope exists (Figure 1b). The steepest regions of the cornea are flattened, and this can correct moderately high levels of astigmatism.

Photo-refractive keratectomy (PRK) and laser assisted in-situ keratomileusis (LASIK) are photo-ablative procedures that use an excimer laser to vaporize selected regions of the cornea. Through the mid 1990's, PRK was the most popular refractive surgery method, but among some surgeons, LASIK has supplanted PRK as the treatment of choice for most patients. In PRK, the doctor scrapes off the upper layer of corneal cells (epithelium) and exposes the underlying stroma to the laser beam, which vaporizes portions of the tissue to "sculpt" the cornea into a new shape (Figure 1c). The central cornea is more strongly ablated in myopia, while in hyperopia, peripheral regions are more strongly ablated. A stigmatic correction is also possible. The LASIK is a variant of PRK, which has been nicknamed the "flap and zap" technique. A motorized blade known as a microkeratome slices through the upper portion of the cornea creating a round flap which is pulled back to expose the interior stroma (Figure 1d). As

in PRK, the excimer laser then ablates stromal tissue to a pre-computed depth, and the flap is replaced to cover the ablated portion of the cornea.⁴

A completely different approach, known as intrastromal corneal rings (or Intacs), recently approved by the Food and Drug Administration, indirectly changes central corneal shape by implanting small precision plastic bands (Intacs) in the mid-peripheral zone.^{5,6} These thin, transparent half-rings are inserted at mid-depth within the cornea (Figure 1e). The central cornea flattens due to the anterior bulging of the periphery of the cornea, and this provides correction for myopia. In contrast to LASIK and PRK, Intacs do not require the destructive removal of cornea tissue and the procedure is reversible. This technique has been in general use in Europe since 1996 and is becoming increasingly popular in the U.S.

Surgical correction of refractive error is appealing for both cosmetic and logistical reasons. Glasses and contact lenses are often considered unattractive, inconvenient, or uncomfortable. Proponents of refractive surgery have argued that, over the long-term, it may be more cost-

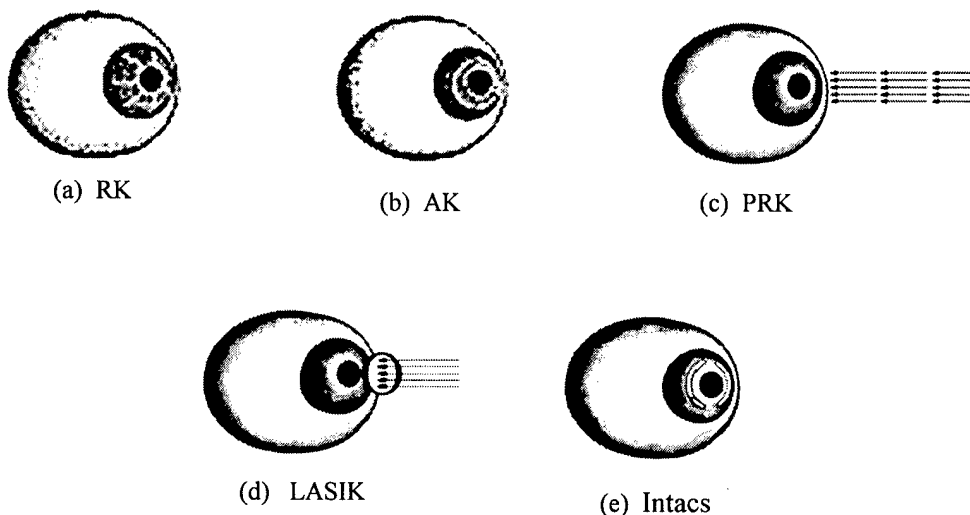


Fig 1. Major types of refractive surgery: (a) In RK, radial incisions are made in the cornea. (b) In AK, arcuate incisions are made on opposite sides of the peripheral cornea. (c) In PRK, a high-energy laser ablates the cornea stroma after the epithelium has been removed. (d) In LASIK, a flap is cut and opened exposing the corneal stroma, which is then ablated with a high-energy laser. (e) Corneal shape and the eye's refractive error may also be changed by inserting a plastic ring into the mid corneal stroma (Intacs).

effective than contact lenses. These arguments, however, do not take into account the risks and complications associated with the surgery. These include light sensitivity, haze, glare, starbursting, induced astigmatism, and uncorrectable optical artifacts. These potential problems may be ignored when the impetus to correct the refractive error is high, as in young individuals seeking to become aviators. Almost always, the visual success of the refractive surgery is measured by the familiar, though limited, metric of Snellen acuity, which may fail to detect degraded vision and complicated optical aberrations. For example, patients may be able to read the 20/20 line on a Snellen letter chart, but have such poor night vision that they can no longer drive at night.⁷

For some individuals preparing to become military aviators, an uncorrected refractive error may be their only obstacle, and in fact, failure to meet vision requirements is a major cause of disqualification. For male U.S. Army flight school candidates for the period January 1987 to December 1996, 11.5% (n = 35,138) failed to meet entry-level vision standards.⁸ And, this issue is not gender specific. For women, the Canadian Forces reported that for the period 1977-1988, 11.5% (n = 477) failed to meet entry-level vision standards; the Belgian Armed forces reported that for the period 1983-1989, 31.0% (n = 74) were disqualified due to inadequate visual acuity.⁹ For female U.S. Army flight school candidates for the period 1987-1990, 11.2% (n = 774) failed to meet entry-level vision standards.¹⁰

To correct vision and gain entry into flight training, highly motivated candidates may be tempted to undergo one of the available refractive surgery techniques. However, even if the refractive surgeries are successful and free of complications, its long-term effects and potential problems are not fully understood. Aviator training is a costly and time intensive process. The cost of training an Army aviator ranges from \$225,000 to more than \$1,000,000, depending on type of aircraft. The loss of an aviator at any point in his or her expected flight career due to medical problems resulting from refractive surgery is an undesirable event.

Warrant officer candidates seeking entry into Army aviation flight training are required to have an uncorrected Snellen visual acuity of at least 20/20 in each eye and a

minimal refractive error (-0.25 to +1.75 diopters [D]), commissioned officers are allowed a refractive error of -0.75 to +2.25 D.^{11,12} The use of spectacles to correct refractive error generally is not desirable under several common operational circumstances in the military aviation environment for various reasons such as fogging, the reduced field of view with image intensifier tubes, or helmet-mounted displays caused by the spectacle-eye vertex distance. Current Army selection policy rejects candidates who have had refractive surgery, but as previously mentioned, the prospect of overcoming a refractive error to gain entry into flight school can motivate certain individuals to surreptitiously undergo such surgeries. Case histories exist where aviator candidates with disqualifying refractive errors have attempted to circumvent vision standards. Mason reports an Army aviator student in the preflight training phase who was discovered to have had contact lens "skid marks" on his corneas.¹³ Upon investigation, it was learned that the student had been wearing hard contacts lenses in an attempt to modify the shape of his corneas. A search of the U.S. Army Aviation Epidemiology Data Register, a family of databases storing medical history and physical parameters of U.S. Army student and trained aviators for the period 1982-1998, found 34 cases where entry-level students were identified as having undergone RK or PRK, and six trained aviators were identified as having undergone one of these surgeries.

While the corneal scars resulting from RK and AK are relatively easy for a doctor to see, the newer techniques of PRK and LASIK are more difficult to detect. In some cases, PRK or LASIK can be detected by the presence of

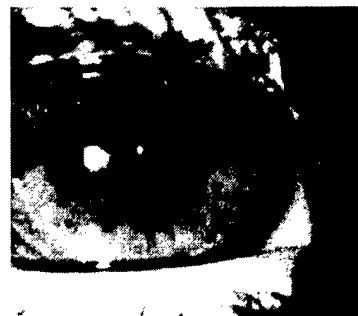

Figure 2. Views of a 1-year post-PRK cornea under low magnification. Note: The faint ring visible in the figure is associated with the iris contour and is not within the 6 mm radius where PRK was performed.

excessive corneal haze; however, this is not always present. Figure 2, previous page, shows a frontal view of the right eye of a 23-year-old female who has undergone PRK. Under low magnification, the eye shows no sign of the PRK. Later examination of this patient, using a magnified slit lamp, still did not reveal any indication of PRK.

Computerized corneal topographers are new clinical instruments, which greatly simplify the task of diagnosing subtle corneal surface anomalies. While these instruments can help Army doctors to detect surgically altered corneas, some lower degrees of refractive correction still can be difficult to detect using this instrument alone.¹⁴ These instruments will also play an important role in military vision research since they will enable researchers to measure the optical properties of the human cornea in greater detail than has ever been possible before. Highly accurate corneal topography measurements are absolutely essential to any study of the complicated optical aberrations, which follow refractive surgery, and this is the key to perfecting these techniques. One day, topography guided lasers may be able to custom design individual corneas for "super-normal" vision.¹⁵ Superior optical correction of the eye also will allow the development of ultra-high resolution retinal photography, which will improve the diagnosis and management of diseases which affect the microscopic structure of the retina.¹⁶

Several technologies have been developed to precisely measure the surface topography of the cornea, but by far the most widely used instruments are known as computerized videokeratoscopes. They are being used clinically to diagnose subtle surface anomalies of the cornea. For example, videokeratoscopes are used routinely prior to refractive surgery to rule out the presence of a keratoconus, a degenerative condition that is an absolute contraindication to refractive surgery. Manufacturers generally claim that their instruments are capable of measuring the corneal surface to an accuracy of 0.1 D, and this is sufficient for current clinical applications. But, higher accuracy is necessary to study the exact optical properties of the cornea in detail.

Keratometry - The Predecessor of Videokeratoscopy.

Prior to computerized videokeratography, the only

instrument available to most clinicians for measuring corneal surface shape was the keratometer. The keratometer estimates the central radius of curvature of the cornea in two principle meridians by optically measuring the local radius of curvature at four paracentral points. The local radii normally are converted to refractive power based on a paraxial power formula ($K=0.3375/r$). Here the apical radius (r) is expressed in meters, and corneal refractive power (K) is in diopters.

By the mid 1990s, computerized videokeratography had become available for widespread clinical use, and it represented a quantum leap beyond the keratometer in the amount of information it provided. These instruments sample 5-10 thousand points covering most of the corneal surface, and for each of these points, a local radius of curvature is estimated. Commonly, a keratometer-like definition for local radius, the *axial radius of curvature*, is used, and each radius value is converted into diopters using $K=0.3375/r$ again. These data are displayed in a color "topographic" map. These axial curvature maps, which depict "K" (keratometer) readings across the cornea, became the clinical standard for corneal topographic mapping, in spite of the fact that the paraxial formula does not correctly estimate surface refractive power except at the center of the cornea.¹⁷⁻¹⁹

Importance of Accurate Surface Elevation Measurements.

For most current clinical applications such as the detection of relative shape anomalies (for example, keratoconus), consistent repeatability is more important than absolute measurement accuracy. However, for advanced studies of corneal performance, absolute local surface elevation data are needed, and greater accuracy becomes critical. If these instruments can measure the surface elevation of a real cornea to micrometer (μm) accuracy, it will be possible to compute a detailed corneal wave front aberration function, which is the key to understanding corneal optics.²⁰

During the 1990s, the two most popular corneal topographers, the EyeSys 2000 Corneal Analysis System and the Tomey TMS-1, used *spherically biased* algorithms to mathematically reconstruct the corneal topography from raw videokeratoscope data; although better algorithms had

been developed.²¹⁻²⁵ In an effort to improve accuracy, another system, Alliance Medical's Keratron, incorporated an *aspheric* algorithm which eliminates many of the assumptions required by older machines. One recent study indicates that, indeed, their "arc-step" algorithm significantly improves accuracy.²⁶ In late 1994, EyeSys Technologies redesigned their instruments and added side cameras to record the position of the corneal apex and an automatic focus mechanism to minimize operator error. In October 1996, software version 3.2 was released with an aspheric reconstruction algorithm designed to improve accuracy and eliminate problems associated with the previous spherically biased programs. The most recent version (4.0) includes new display options but uses the same corneal reconstruction algorithm as in version 3.2. The purpose of the investigation described here was to test whether the EyeSys 2000 Corneal Analysis System, with its aspheric reconstruction algorithm, is capable of measuring corneal topography to the level of accuracy required to compute a detailed corneal wave front aberration function. This preliminary study is necessary before the videokeratoscope can be used to study the optical results of refractive surgery.

Available Estimates of Videokeratoscopy Accuracy.

Standard keratometer calibration uses spherical test surfaces such as steel ball bearings, and early studies of computerized videokeratoscope accuracy similarly tested these instruments with spherical surfaces and expressed results in diopters. First generation instruments had accuracies of 0.25 D, which was similar to that expected for keratometry.^{27,28} Current instruments claim to measure the corneal surface to an accuracy of 0.1 D.²⁹

Most manufacturers specify the accuracy of their instruments in diopters of corneal power, but for the purposes of computing corneal optics, it is preferred to know *surface elevation* measurement error in terms of μm . In order to compare accuracy in diopters to accuracy in μm , dioptric and μm corneal data were calculated for a typical corneal profile represented by an ellipse with apical radius $r = 7.8$ and shape factor $P = 0.8$, where P is defined as $1 - e^2$ ($e = \text{eccentricity}$). These two parameters are related by a simple linear relationship ($\text{Error in } \mu\text{m}) = 14.6 (\text{Error in diopters})$ where 0.1 D error equals approximately 1.5 μm error at the edge of a 6.0 mm zone. A 6.0 mm

diameter zone was selected since this is the normal maximum extent of the portion of the corneal, which is relevant for vision and is the approximate diameter of most PRK and LASIK treatment zones. Error is defined as the measured surface elevation minus the known elevation of the surface at that point.

Until recently, videokeratoscope algorithms assumed that local regions of the cornea could be represented by a series of spheres centered on the instrument's optical axis, and, as a result, these instruments had a strong spherical bias.^{18,21} Therefore, it was no surprise that they measured spherical surfaces accurately, but this was not necessarily an indication of accuracy on human eyes, since the cornea is an aspheric surface. For this reason, recent studies have tested videokeratoscope accuracy using ellipsoidal or other aspheric surfaces, and results usually are expressed in μm of elevation rather than diopters of power. Table 1 summarizes selected results from several studies. These results give a general indication of videokeratoscope accuracy. Two summary statistics are shown: (1) RMS error across the entire measured surface and (2) accuracy at the edge of a 6.0 mm zone.

These studies show that older videokeratoscopes, using older software, would be able to measure the surface elevation of ellipsoids to within 10 to 30 μm ; with newer software, accuracy with the same instruments improves to 2 to 5 μm or better. The corneal wave front aberration function, one of the best descriptors of optical aberrations, can be estimated directly from surface topography, and a 2 to 5 μm surface elevation error translates to a wave front aberration error of 0.7 to 1.7 μm .³⁰⁻³³ Since maximum wave front aberrations for the human eye are in the 1 to 6 μm range, it is desirable to measure corneal topography to single μm accuracy, or better, when computing corneal optics.³⁴ Tripoli et al indicated that the Keratron, one of the newest videokeratoscopes, is capable of this accuracy under ideal conditions.²⁶

Methods

Instrumentation. The EyeSys Technologies Corneal Analysis 2000 system (Figure 3) consists of three cameras (two side-mounted alignment cameras and one digitizing video camera located at the center of an illuminated pattern of concentric rings) and a computer system. The center

Study	Instrument (software version)	Test surface	RMS error (μm)	Maximum error (6 mm zone)
Applegate ^a et al ³⁰	TMS-1 (V1.41)	Ellipsoids	11.6 -18.5	5-16
Applegate ^b et al ³⁰	TMS-1 (V1.41)	Ellipsoids	2.3-5.0	2-5
Douthwaite ^{c31}	EyeSys (V2.00)	Ellipsoids	7-11	6-8
Cohen et al ²²	TMS-1 (V1.41)	Aspheres	8-28	4-8
Tripoli ^d et al ²⁶	Keratron	Aspheres	<1	0.1-0.25

^a Default TMS algorithm

^b Specially designed reconstruction algorithm

^c RMS error estimated from results

^d RMS error estimated from figures

Table 1. Videokeratoscope Accuracy in Measuring Surface Elevation of Aspheres, According to Several Studies

camera images the pattern of the rings that are reflected from the cornea. When the image is acquired, it is digitized, and a proprietary algorithm computes the axial radius of curvature at each point. Radii are mathematically converted to diopters and a color topographic map of the cornea is displayed.



Fig 3. The EyeSys technologies corneal analysis 2000 system.

Test Surfaces.

In a series of tests performed at the U.S. Army Aeromedical Research Laboratory at Fort Rucker, AL, six rotationally symmetric apherical test surfaces were measured to assess instrument accuracy. Prior to making measurements, the EyeSys 2000 system was calibrated (as specified by the operator's manual) and each test surface

was mounted in a holding device, which allowed for proper placement and adjustment with the instrument's optical center. An initial image was taken of each test surface and the color map was evaluated for centration and alignment. Fine adjustments were made, and these steps were repeated until optimal alignment was achieved based upon criteria of minimal surface toricity (astigmatism), correct apical radius, and map symmetry. Eighteen keratographs then were taken of each surface. The black polymethylmethacrylate (PMMA) surfaces were manufactured by Sterling International Technologies which guarantees the surfaces to within $1.0 \mu\text{m}$ over a 10 mm diameter zone. Samples of the surfaces were verified by the manufacturer using a Rank Taylor Hobson Talysurf, a device that makes stylus measurements to a resolution of



Fig 4. Representative test surface.

better than $0.1 \mu\text{m}$. The manufacturer claims that these surfaces are therefore accurate to $0.1 \mu\text{m}$, although they guarantee only $1.0 \mu\text{m}$ accuracy. A representative test surface is shown in Figure 4 (preceding page).

Four of the six surfaces were prolate (curvature flattens peripherally) in form. These were designed to represent the range of shapes expected for most normal corneas. One surface had a spherical profile, and one other surface was oblate (curvature steepens peripherally) in form. These were designed to generally represent post-refractive surgery corneas, though a small number of normal corneas are also oblate in shape.^{35,36} Table 2 summarizes parameters for the test surfaces.

Surface Description	Parameter r/p	RMS error		Measured zone (mm)
sphere	7.8/1.3	$2.0 \mu\text{m}$	0.19 D	8.6
average cornea	7.8/1.0	$4.3 \mu\text{m}$	0.25 D	9.0
more aspheric	7.8/0.17	$7.2 \mu\text{m}$	0.29 D	9.4
oblate ellipse	7.8/0.5	$8.8 \mu\text{m}$	0.27 D	9.8
Steep cornea	8.3/0.7	$7.0 \mu\text{m}$	0.23 D	10.0
Flat cornea	7.3/0.7	$7.3 \mu\text{m}$	0.37 D	8.8

Table 2. RMS Surface Elevation Measurement Error for Six Model Corneas

Most videokeratoscope maps present the corneal surface in terms of local dioptric data, but in order to know the surface elevation in μm , a utility program provided by EyeSys was used to convert the standard curvature data into elevation data. The mean elevations measured for each test surface were taken as the mean data from 18 images of each surface.

Data Analysis.

From the specified apical radius and shape factor for each test surface, it was possible to compute the expected surface elevations at each point on the surfaces, and the measured elevations were compared with these to determine instrument error. Therefore, error was defined as measured minus known elevation for each position. The keratoscope image (keratograph) contains 18 concentric rings, each of which is used to compute the corneal elevation at 18 distances from the center. Within each ring, 360 evenly spaced measurements were made. Therefore,

the keratoscope samples the cornea at 6,480 points on a polar grid composed of 360 spokes and 18 rings. Taking advantage of the rotational symmetry for each surface, a mean surface elevation for each ring then was computed to show how error changed as a function of distance from the center. The result of this analysis was a mean surface elevation error at 18 distances beginning with a point approximately 0.25 mm from the center to approximately 4.5 mm from the center. This covers an approximately 9.0 mm diameter zone of the model corneas. From the 18 elevation error values, a RMS error was computed to represent a mean overall measurement error for each surface. In addition, the elevation error at the 12th ring, which was approximately 3.0 mm from the center, also was noted to evaluate the maximum error expected within a 6.0 mm corneal zone.

Theoretically, to compute optical aberrations of the cornea, surface topography is expressed best as surface elevation in microns, but because axial curvature in diopters is so commonly used, error also was expressed in diopters. The instrument measured the axial curvature in diopters for each sampled point, but the true value had to be computed based on the known apical radius (r_0) and shape factor (p) for each surface. The equation $r_a = \sqrt{r_0^2 + [1-p]y^2}$ was used to compute the axial radius of curvature (r_a) at each distance from the center for which measurements were obtained, and the radii were converted to diopters according to $K=0.3375/r$. Dioptric error was defined as the difference between the measured and known values for each position.

Results

The RMS surface elevation measurement error and measured zone diameter for each surface are listed in Table 3. The best results were for the oblate ellipsoid ($r = 7.8/P = 1.3$), with a RMS error of $2.0 \mu\text{m}$. The range of RMS error for the other surfaces was approximately 4 to $9 \mu\text{m}$. Four of the surfaces had the same apical radius of 7.8 mm but differed in P values ($P = 0.5, 0.7, 1.0, \text{ and } 1.3$). Among them, accuracy was better for surfaces with higher P values. Three surfaces had the same P value (0.7) but differed in their apical radii ($7.3, 7.8, \text{ and } 8.3$). The RMS error for each of these three surfaces was $7.3, 7.2, \text{ and } 7.0 \mu\text{m}$, respectively. Depending on the surface, an 8.6 to 10.0 mm corneal zone was sampled.

Toricity (D)	TMS-1 (v 1.41)	EyeSys (v 2.01)	Visiopic EH-270
0	0.7	0.6	0.8
1	3.7	0.7	1.9
2	2.5	5.3	1.2
3	1.7	7.5	1.5
7	4.2	9.7	2.4

Table 3. RMS Error (μm) for Toric Test Surface with Three Older Videokeratoscopes (8 mm corneal zone)⁴⁰

Additional measurements also calculated the mean surface elevation measurement error for the 12th ring of each surface, which was located at approximately 3 mm from the center. The distance to the 12th ring varied slightly from surface to surface depending on its particular apical radius and P value. Both RMS and the 12th ring dioptric errors were in the general range of 0.25 D. As noted before, accuracy was slightly better for the oblate ellipsoid ($r = 7.8/P = 1.3$) and the result was worst for the steepest surface ($r = 7.3$). The negative values for 12th ring error indicate that the instrument underestimated the dioptric curvatures. Generally, dioptric error was very small near the center of the surfaces, increased to the 0.2 - 0.3 D range at 1 mm from the center, then remained relatively constant peripherally. Some exceptions were noted.

Discussion

The primary purpose of this study was to determine if the EyeSys Corneal Analysis System could measure the topographic elevation of cornea-like test surfaces accurately enough to permit detailed studies of corneal optics. For this purpose, elevation measurement accuracy should be better than 1.0 μm . Our results showed the EyeSys system was not able to achieve this level of accuracy for any of the test surfaces. Depending on the surface, accuracies expressed as RMS or 12th ring errors were in the 2 to 9 and -2 to -6 μm ranges, respectively.

Our findings are generally similar to the accuracy reported by Applegate et al for the TMS-1 topographer, which used an improved reconstruction algorithm; this is better than the accuracy reported for older instruments

using older algorithms.³⁰ This suggests that the aspheric algorithm used by the current EyeSys system is an improvement over previous versions, but is not accurate enough for corneal optics studies in which submicrometer accuracy is needed. Our data showed that measurement error is systematic and varies as a function of: distance from the center, apical radius, and P value. Taking these factors into account, it should be possible to compensate for and eliminate most of the systematic error. This method was used in one recent study to improve surface elevation accuracy using the EyeSys system to a 0.2 μm , or better, accuracy for ellipsoidal test surfaces.³⁷ Since Tripoli et al reported 0.25 μm accuracy for the Keratron, it appears that, with the appropriate calibration and reconstruction software, computerized videokeratoscopes should be capable of measuring the surface of the cornea to submicrometer accuracy.²⁶

All studies with model corneas give best case accuracy estimates. However, greater variance and error can be expected with real eyes due to ocular movements, focusing error, and fluctuations in the tear film caused by blinking and evaporation.

The Problem of Asymmetric Surfaces.

Because the keratoscope mires are concentric rings with no spokes or cues to mark meridional position, current commercial reconstruction algorithms must assume that every point on the data image has been reflected from a point on the target that was in the same radial meridian.³⁸ This assumption simplifies computations by treating each radial meridian as one slice out of a rotationally symmetric surface. In other words, they ignore any possible oblique ray reflections at the corneal surface.³⁹ Current videokeratoscopes use this assumption in reconstructing surfaces, so for rotationally symmetric surfaces such as our model corneas, these algorithms should perform well. Unfortunately, human corneas are almost never so symmetric. The most familiar example of corneal asymmetry is the surface toricity that causes astigmatism. Therefore, we might expect accuracy on real human corneas to be somewhat worse than indicated in this study. Greivenkamp et al tested three older videokeratoscopes for accuracy in measuring the surface elevation of toric surfaces designed to model up to 7 D of corneal astigmatism.⁴⁰ For 1 D of astigmatism, the EyeSys

topographer using software version 2.1 was still accurate to 0.7 μm (RMS), while the TMS-1 (version 1.41) and Visioptic EH-270 (version 3.0) were accurate to 3.7 and 1.9 μm , respectively. For higher degrees of toricity, accuracy with the TMS and EH-270 improved slightly while the EyeSys was worse. For all three instruments, accuracy for the most extremely toric (7 D) surface was better than 10 μm , which is approximately the same magnitude of error reported for the TMS and EyeSys for rotationally symmetric surfaces (Table 1).

Klein investigated the magnitude of videokeratoscope errors in measuring asymmetric surfaces of a variety of shapes.⁴¹ He found that for toric ellipsoids the dioptric error was very small and could be estimated using the equation: $\text{error} = (C/2)^2/2M$ where C is the corneal astigmatism, and M is the mean apical curvature of the cornea, both expressed in diopters. For a typical average cornea with mean spherical power of 43 D and 1.00 D of astigmatism, the maximum expected error is 0.003 D, which according to Equation 2 equates to a 0.04 μm elevation error. Even for an extreme 4.00-D value of corneal astigmatism, the dioptric and elevation errors are only 0.05 D and 0.70 μm , respectively.

For more distorted corneas, such as in keratoconus, the error can be much larger, and Klein developed an arc-step algorithm which eliminates the skew ray error.³⁹ Hilmantel et al modeled corneal asymmetry by using tilted ellipsoids and found that even with an extreme 15 degrees of tilt, RMS error with the TMS-1 (using Applegate's reconstruction algorithm) was 2.7 μm .⁴² These studies indicate that for small degrees of asymmetry, such as the toricity seen in most normal corneas, accuracy is not much different from that found for rotationally symmetric surfaces.

Conclusions

This study tested the accuracy of one widely used videokeratoscope, the EyeSys Corneal Analysis System using PMMA ellipsoidal surfaces designed to model a range of corneal shapes. Without modification, the EyeSys videokeratoscope cannot measure corneal surface topography at the level of accuracy required for detailed studies of corneal optics. However, systematic instrument error can be corrected, and, if compensated, the basic

hardware seems to be capable of the sub- μm accuracy required for these studies. Though these instruments appear to be adequate for most current applications, vision scientists cannot assume that their topographical data are sufficiently accurate for the more rigorous demands of corneal optics research. All such studies should first verify instrument accuracy using aspheric test surfaces, as was done in this study, and appropriate correction factors should be computed to optimize accuracy. Hopefully, manufacturers will improve instrument software to consistently deliver the higher accuracy necessary for future studies of corneal optics.

References

1. International Society of Refractive Surgery. Refractive surgery frequently asked questions. Available at: <http://www.isrs.com/library/faq/index.htm#work>. Accessed March 3, 1998.
2. Grosvenor TP. Refractive anomalies of the eye - Part 1: Incidence of ametropia. *Optom Weekly*. October 1976;44-46.
3. Walsh DJ. *Visual survey of infantry troops, Part 1: Visual acuity, refractive status, interpupillary distance, and visual skills*. Fort Rucker, AL: U.S. Army Aeromedical Research Laboratory; 1989. USAARL Report No. 89-10.
4. Taylor DM, Francis A, L'Esperance, et al. Human excimer laser lamellar keratectomy: A clinical study. *Ophthalmology*. 1989; 96:654-664.
5. Burris TE, et al. Flattening of central corneal curvature with intrastomal corneal rings of increasing thickness: An eye-bank study. *J Cataract Refractive Surg*. 1993;19:182-187.
6. Nagy Z, Krasznai G, Modis L, Sefcsik I, Furka I, Miko I. Intrastomal corneal ring, a new refractive surgical technique to decrease myopia. *Acta Chir Hung*. 1997; 36: 248-250.
7. Halliday B. Refractive and visual results and patient satisfaction after excimer laser photorefractive keratectomy for myopia. *Br J Ophthalmol*. 1995;79: 881-887.
8. Shannon SG. Personal communication based on search of the U.S. Army Aviation Epidemiology Data Register. April 8, 1998.
9. Vancutsem C, Vandenbosch P. *Review of female applicant aircrew in the Belgian Forces. Recruiting, selection, training, and military operations*. Neuilly-sur-seine, France: Advisory Group for Aerospace Research and Development; AGARD-CP-491:13-1-13.5.
10. Mason KT. *U.S. Army aviation epidemiology data register: Descriptive analysis of medical disqualifications among female Army aviator training applicants*. Fort Rucker, AL: U.S. Army Aeromedical Research Laboratory; 1995. USAARL Report No. 95-16.
11. Rabin J. Correction of subtle refractive error in aviators. *Aviat Space Environ Med*. 1996;67: 161-164.
12. Walsh DJ, Levine RR. *Compendium of U.S. Army visual medical fitness standards*. Fort Rucker, AL: U.S. Army Aeromedical Research Laboratory; 1987. USAARL Report No. 87-11.

13. Mason, KT. *U.S. Army aviation epidemiology data register: Rates of exceptions to policy granted due to medically disqualified U.S. Army aviator students from FY 1986 to FY 1990*. Fort Rucker, AL: U.S. Army Aeromedical Research Laboratory; 1996. USAARL Report No. 96-15.
14. Schallhorn SC, Reid JL, Kaupp SE, et al. Topographic detection of photorefractive keratectomy. *Ophthalmology*. 1998; 105: 507-516.
15. Wu C. Supernormal science. *Science News*. 1997; 152: 305-320.
16. Laing J, Williams DR, Miller DT. Supernormal vision and high-resolution retinal imaging through adaptive optics. *J Opt Soc Am*. 1997; 14: 2884-2892.
17. Salmon T, Homer D. Comparison of elevation, curvature and power descriptors for corneal topographic mapping. *Optom Vis Sci*. 1995;72: 800-808.
18. Roberts C. The accuracy of "power" maps to display curvature data in corneal topography systems. *Invest Ophthalmol Vis Sci*. 1994;35: 3525-3532.
19. Mandell RB. The enigma of the corneal contour. *Contact Lens Assoc Ophthalmol J*. 1992;18: 267-273.
20. Hemenger R, Tomlinson A, Oliver K. Corneal optics from videokeratographs. *Ophthalm Physiol Opt*. 1994;15: 63-68.
21. Roberts C. Characterization of the inherent error in a spherically-biased corneal topography system in mapping a radially aspheric surface. *J Refractive Corneal Surg*. 1994b;Vol 10:p 103-111.
22. Cohen KL, Tripoli NK, Holmgren DE, Coggins JM. Assessment of the power and height of radial aspheres reported by a computer-assisted keratoscope. *Am J Ophthalmol*. 1995; Vol 119, p 723-732.
23. Doss JD, Hutson RL, Rowsey JJ, Brown DR. Method for calculation of corneal profile and power distribution. *Arch Ophthalmol*. 1981;Vol. 99:p 1261-1265.
24. Wang J, Rice D, Klyce S. A new reconstruction algorithm for improvement of corneal topographical analysis. *Refractive Corneal Surg*. 1989;Vol 5:p 379-87.
25. Van Saarloos PP, Constable IJ. Improved method for calculation of corneal topography for any photokeratoscopic geometry. *Optometry and Vision Science*. 1991;Vol 68: p 957-965.
26. Tripoli N, Cohen K, Holmgren D, Coggins J. Assessment of radial aspheres by the arc-step algorithm as implemented by the Keratron keratoscope. *Am J Ophthalmol*. 1995;Vol 120:p 658-64.
27. Hannush S, et al. Accuracy and precision of keratometry, photokeratoscopy, and corneal modeling on calibrated steel balls. *Arch Ophthalmol*. 1989;Vol 107:p 1235-1239.
28. Heath G, et al. Reliability and validity of videokeratoscopic measurements. *Optometry and Vision Science*. 1991;Vol 68:p 946-949.
29. Boreas Eye Institute. Corneal topography central home page. Available at: <http://www.getnet.com/~labores/topotoc.html> Accessed April 2, 1998.
30. Applegate R, Nunez R, Buettner J, Howland H. How accurately can videokeratographic systems measure surface elevation? *Optometry and Vision Science*. 1995; Vol. 72 p 785-792.
31. Douthwaite WA. EyeSys corneal topography measurement applied to calibrated ellipsoidal convex surfaces. *Br J Ophthalmol*. 1995;Vol 79; p 797-801.
32. Williams C, Becklund O. *Introduction to the Optical Transfer Function*. New York: John Wiley and Sons; 1989.
33. Howland H, Buettner J, Applegate R. Computation of the shapes of normal corneas and their monochromatic aberrations from videokeratometric measurements. Optical Society of America: Vision Science and its Applications, Technical Digest Series. 1994; Vol 2:p 54-57.
34. Charman W. Wave front aberration of the eye: A review. *Optometry and Vision Science*. 1991;Vol 68: p 574-583.
35. Keiley P, Smith G, Carney L. The mean shape of the human cornea. *Optica Acta*. 1982;Vol 29:p 1027-1040.
36. Eghbali F, Yeung K, Maloney R. Topographic determination of corneal asphericity and its lack of effect on the refractive outcome of radial keratotomy. *Am J Ophthalmol*. 1995;Vol 119:p 275-280.
37. Salmon T, Thibos, L. EyeSys accuracy in surface elevation measurement and estimation of the corneal wave front aberration function. *Optometry and Vision Science*. 1997;Vol 74. No. 12s:p 184.
38. Applegate R, Howland H. Noninvasive measurement of corneal curvature. *IEEE Engineering, in Medicine and Biology*. 1995;Vol 1995; p 30-42.
39. Klein S. Corneal topography reconstruction algorithm that avoids the skew ray ambiguity and the skew ray error. *Optometry and Vision Science*. 1997a; Vol 74:p 945-962.
40. Greivenkamp J, et al. Comparison of three videokeratoscopes in measurement of toric test surfaces. *J Refractive Surg*. 1996;Vol 12; p 229-239.
41. Klein S. Axial curvature and the skew ray error in corneal topography. *Optometry and Vision Science*. 1997b;Vol 74; p 931-944.
42. Hilmantel G, Blunt R, Applegate R, Howland H. Accuracy with which the TMS-1 can measure elevations of asymmetric surfaces. *Investigative Ophthalmol Visual Science*. 1997;Vol 38:p S850.

AUTHORS:

†Dr Salmon (LTC, MS, USAR) is an Assistant Professor of Optometry at Northeastern State University, Tahlequah, OK.

††Mr Rash is a Research Physicist at the U.S. Army Aeromedical Research Laboratory, Fort Rucker, AL.

†††Sergeant Mora is a Research Technician at the U.S. Army Aeromedical Research Laboratory, Fort Rucker, AL.

††††Ms Reynolds is a Research Technician at the U.S. Army Aeromedical Research Laboratory, Fort Rucker, AL, and a secondary science teacher.

AMEDD DATELINE

Wayne R. Austerman PhD†

- 1 Jan The year opened with a polio epidemic striking the U.S., killing 1,151 and crippling thousands more before it ran its course. **(1943)**
- Jan 1LT Charles Schneider, Battalion Surgeon, 905th Field Artillery Battalion, 80th Infantry Division, was attending to casualties at his unit aid station during the closing phases of the Battle of the Bulge when it was subjected to a mistaken strafing attack by an American fighter plane. The angry young surgeon dashed across the road to a .30 caliber machine gun post and chased the erring aviator away with a stream of tracer bullets. **(1945)**
- 3 Jan The SCIENTIFIC AMERICAN reported that paleoanthropologists had examined a 3,500-year-old female Egyptian mummy which sported a fully articulated, flexibly-jointed artificial big toe in place of the digit which had been amputated during life. **(2001)**
- 8 Jan Medical personnel examined two Japanese soldiers following their surrender to the American garrison on the island of Iwo Jima. The duo had successfully eluded the American invasion and occupation forces since the initial wartime landings in February 1945. **(1949)**
- 13 Jan The Emperor Napoleon led 400,000 French troops into an ill-fated invasion of Russia with only 100 surgeons on his medical staff. Exposure, malnutrition, and epidemic typhus reduced his force to 25% of its original strength by the end of the campaign in the spring of 1813. **(1812)**
- 15 Jan United States Navy Surgeon Frederick Leitner was killed in action when a mixed force of soldiers and sailors were ambushed near the headwaters of the Jupiter River by Chief Tuskegee during the Second Seminole War in the Florida Territory. **(1838)**
- 17 Jan Thomas Young, a 16-year-old South Carolina militiaman, recalled the wounds he suffered in fighting British cavalry at the Battle of Cowpens: "In a few minutes, one finger on my left hand was split; then I received a cut on my sword arm. In the next instant a cut from a sabre across my forehead . . . the skin slipped down over my eyes, and the blood blinded me. Then came a thrust in the right shoulder blade, then a cut upon the left shoulder, and a last cut . . . on the back of my head, and I fell upon my horse's neck." **(1781)**
- 25 Jan The Surgeon General authorized local procurement of medical supplies in California 14 years after the AMEDD began operations there. Medicinal wines were the first items purchased from local vendors, but they were subsequently judged to be "either too sweet or too acid, and none were fit for the sick." **(1861)**
- 26 Jan Airline stewardess Vesna Vulovic survived a 33,330 foot fall when the DC-9 jetliner she was aboard exploded over Czechoslovakia. **(1972)**
- 27 Jan Lieutenant Colonel George Peoples, a Walter Reed Army Medical Center oncologist, was named one of the "Ten Outstanding Young Americans for 2001" by the U.S. Junior Chamber of Commerce. Doctor Peoples earned the award through his groundbreaking work in the development and testing of a potential anticancer vaccine. **(2001)**

- 29 Jan A Department of the Army review board cleared Ms Ella Behrens of all earlier charges, changed her discharge from “dishonorable” to “honorable,” and reimbursed her for lost pay. In 1918, Ms Behrens had been serving as a nurse at Camp Bowie, near Fort Worth, TX, when the influenza pandemic of that year swept the post. Wartime paranoia and her Germanic last name prompted officers to arrest her on charges of being an enemy agent and deliberately contaminating the troops’ food with influenza germs. She was jailed for 8 days and then received a dishonorable discharge on AWOL charges. Ms Behrens spent the next 30 years fighting to clear her good name and professional reputation. **(1949)**
- 3 Feb Near Natchez, MS, Captain Winfield Scott fought a duel with Dr William Upshaw, surgeon of the 5th U.S. Infantry, following the surgeon’s referral of courts-martial charges against the line officer. Scott’s shot missed the combative medic during the exchange of fire, but Upshaw’s round creased the officer’s skull, causing a painful wound. Had Dr Upshaw’s aim been a few millimeters lower, the nation would have been deprived of the services of a future hero of the War of 1812, captor of Mexico City during the Mexican-American War of 1846–48, and commanding general of the U.S. Army at the time of the Civil War’s outbreak in 1861. **(1810)**
- 6 Feb Doctor Thomas Bond established the Pennsylvania Hospital in Philadelphia, the first general hospital in North America. **(1752)**
- 8 Feb Former medic Alfred Rascon received the Medal of Honor in a White House ceremony conducted three decades after the exploits which earned him the decoration. On 16 March 1966, 20-year-old Specialist Rascon was a medic serving with the Reconnaissance Platoon, 1st Battalion, 503d Infantry (Airborne), when his unit was heavily engaged with the enemy. Ignoring his own wounds, medic Rascon repeatedly put himself in the line of fire to aid casualties and assist in his unit’s defense. Upon receiving the Medal of Honor the veteran remarked, “I am not a hero; I am just a person doing his duty as he would have any other day.” **(2000)**
- 15 Feb Willis L. Moore, Chief of the U.S. Weather Bureau, issued orders prohibiting the use of tobacco in any of the bureau’s offices due to the belief that nicotine usage created a “shattered physical condition and mental impairment.” **(1900)**
- 19 Feb The 36-day battle for the Japanese-held island of Iwo Jima began. One hundred U.S. Navy surgeons and a thousand pharmacists mates (medics) accompanied three Marine Corps divisions ashore. By the end of the battle, 23 surgeons and 827 medics had been killed or wounded in action. **(1945)**
- 21 Feb Lucy B. Hobbs became the first female graduate of a dental school; the Ohio College of Dental Surgery in Cincinnati. **(1866)**
- 22 Feb Medics of the 341st Infantry Regiment, 86th Infantry Division, took action when the unit sustained six casualties in a firefight with Japanese troops on Lubang Island in the Philippines, 7 months after the formal Japanese surrender in World War II. **(1946)**
- 23 Feb The first mass inoculation of children with the Salk polio vaccine began in Pittsburgh, PA. **(1954)**
- Navy Pharmacist Mate John Bradley was among the group of U.S. Marines who raised the American flag on Mt Suribachi during the bloody battle for Iwo Jima. The month-long battle generated 26,000 American casualties. **(1945)**
- On his 20th birthday, Nathan King of Helena, MT, fell on a pencil which pierced his pericardium and entered the right ventricle of his heart, leaving only 2 to 3 inches of its length still visible as it jutted from

his chest. His mother, a nurse, did not attempt to remove the pencil, and Nathan was airlifted to a hospital in Great Falls, where the pencil was extracted 2 hours later. Nathan returned home after 10 days of recuperation. **(2000)**

- 25 Feb Twenty-eight American soldiers were killed and 89 were injured shortly after 8 pm when fragments from an Iraqi Scud missile struck their barracks in Dhahran, Saudi Arabia, during Operation Desert Storm. **(1991)**
- 2 Mar The Office of The Surgeon General learned that an entire shipment of ether had evaporated en route from New York to Albuquerque, NM, due to poorly fitting glass stoppers in the bottles. The contractor promised to replace the ether if the AMEDD would provide new bottles and stoppers. **(1852)**
- 7 Mar Surgeon General Lawson directed that the focus of medical supply procurement and contracting should be in New York City, "where prices were generally lower than elsewhere." **(1859)**
- 8 Mar Private John Maloney of the British 39th Regiment of Foot was wounded in a skirmish with hostile Baluchi tribesmen in northwestern India. When Maloney bayoneted a Baluchi, the hardbitten native reached down and unfixing the bayonet from the muzzle of the soldier's musket, wrenched the blade from his own body, and then used it to stab the soldier. Maloney survived the wound; the Baluchi died soon afterward. **(1845)**
- 15 Mar Wire service reports announced the development of a new technology which could permit blind people to "see" with their tongues. University of Wisconsin researchers have developed a device which transfers visual clues from a video camera to the brain via electrodes implanted in the highly sensitive nerves of the tongue. Within 5 years, the researchers hope to condense the system into a unit small enough to fit in the user's mouth, with a wireless link from a spectacle-mounted video or infrared camera. **(2001)**
- 19 Mar United States Navy physicians and medics confronted a horrific mass casualty situation when Japanese kamikaze planes crashed into the USS FRANKLIN, killing 800 crewmen and injuring hundreds more. **(1945)**
- 22 Mar Doctor J.R. Heller of the National Cancer Institute reported that cancer of the stomach rates were declining while lung cancer was increasing in the U.S. **(1960)**
- 23 Mar Fight Sergeant Nicholas S. Alkemade of the British Royal Air Force survived an 18,000 foot fall when his Lancaster bomber exploded over Germany. **(1944)**
- 26 Mar Major General Nathan Bedford Forrest, Confederate States of America, abandoned his siege of Union-held Fort Anderson at Paducah, KY, and departed the area when he learned that a smallpox epidemic was raging in the community. **(1864)**
- 29 Mar Development of an effective serum hepatitis vaccine for children was announced by the New York University Research Center. **(1971)**

†Dr Austerman is the Historian, U.S. Army Medical Department Center and School, Fort Sam Houston, TX.

*U. S. GPO: 2002-770-007/2001C

WRITING AND SUBMITTING ARTICLES FOR THE AMEDD JOURNAL

The AMEDD Journal is published quarterly to expand knowledge of domestic and international military medical issues and technological advances; promote collaborative partnerships among Services, components, Corps, and specialties; convey clinical and health service support information; and provide a peer-reviewed high quality print medium to encourage dialogues concerning health care initiatives.

Submit manuscripts with the following guidelines:

1. Manuscripts will be reviewed by the Journal's Editorial Board and, if appropriate, forwarded to the appropriate Subject Matter Expert for further assessment.
2. It may be necessary to revise the format of a manuscript in order to conform to established page composition guidelines.
3. Articles should be submitted in disk form (preferably Microsoft Word on 3.5" disk) accompanied by two copies of the manuscript. Journal format requires four double-spaced typewritten pages to complete one page of two-column text. Ideally, manuscripts should be no longer than **20 to 24 double-spaced pages**. Exceptions will be considered on a case-by-case basis.
4. The American Medical Association Manual of Style should be followed in preparation of text and references. Abbreviations should be limited as much as possible. A list identifying abbreviations and acronyms **must** be included with the manuscript or materials will be returned to the author.
5. Photos submitted with manuscripts can be black and white or color. Color is recommended for best print reproduction quality. Space limitations allow no more than eight photos per manuscript. Photo prints are preferred, but we will accept electronic graphic (i.e., BMP, JPG, or GIF) and photo files in Microsoft Word or PowerPoint. Avoid excessive use of color and shading. Please do not send photos embedded in PowerPoint. Slides, negatives, or X-ray copies will not be published. To avoid possible confusion, the top of photos should be marked on the reverse and their position within the article should be clearly indicated in the manuscript. Photo captions should be taped to the back of photos or submitted on a separate sheet.
6. A complete list of references used in the text **must** be provided with the manuscript. This list should include no more than 25 individual references, if possible. Each should provide the author's last name and initials, title of the article, name of the periodical, volume and page number, year of publication, and address of the publisher.
7. Drugs should be listed by their generic designations. Trade names, enclosed in brackets, can follow.
8. The author's name(s), title, current unit of assignment, PCS date (if applicable), and duty phone number **must** be included on the title page.
9. Submit articles to: COMMANDER, U.S. ARMY MEDICAL DEPARTMENT CENTER & SCHOOL, ATTN MCCS HSA, 2250 STANLEY ROAD STE 250, FORT SAM HOUSTON TX 78234-6150. DSN 471-6916/7326, Comm (210) 221-6916/7326, FAX DSN 471-8720, Comm (210) 221-8720.

